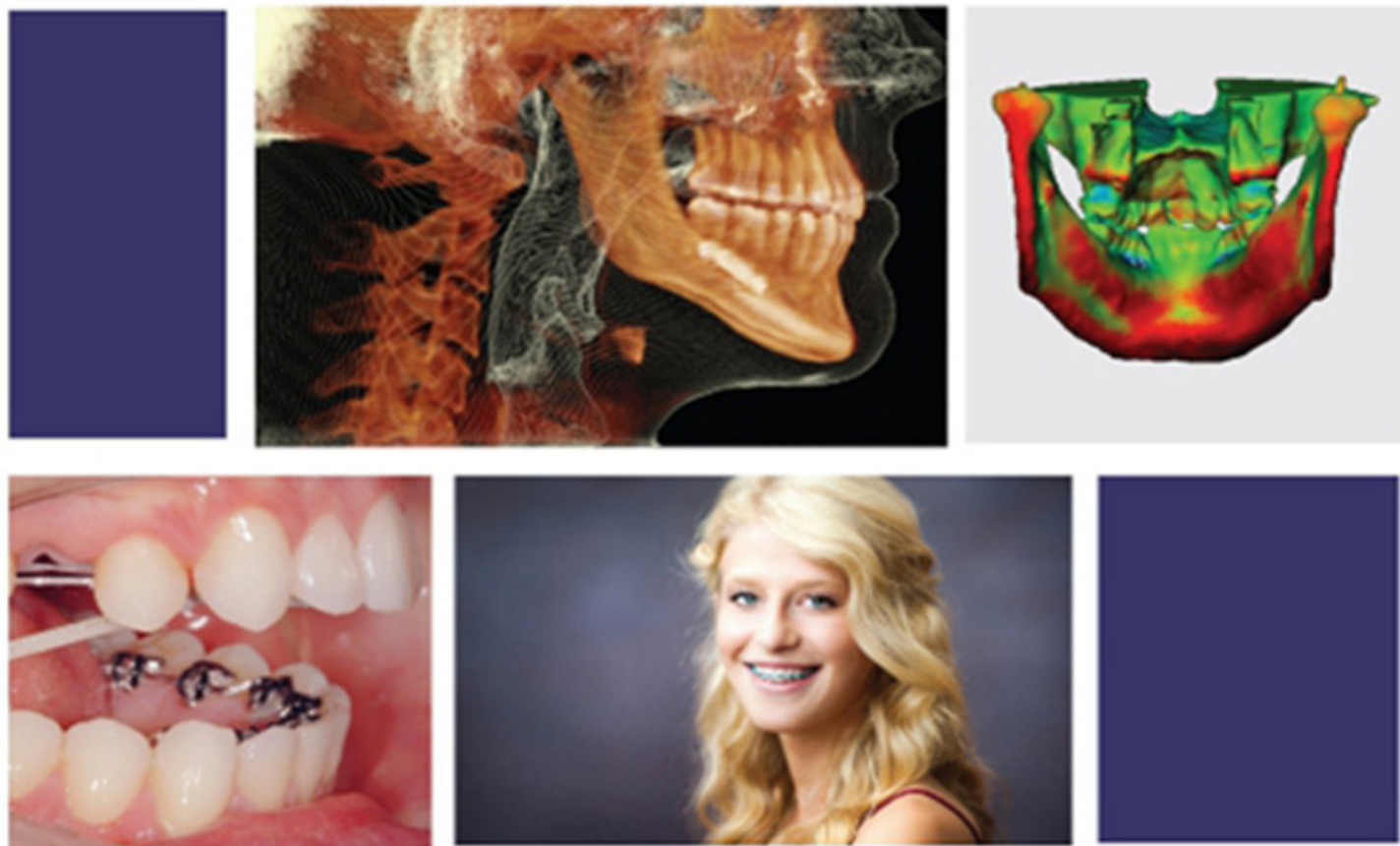

WILLIAM R. PROFFIT

Henry W. Fields | Brent E. Larson | David M. Sarver



# CONTEMPORARY ORTHODONTICS

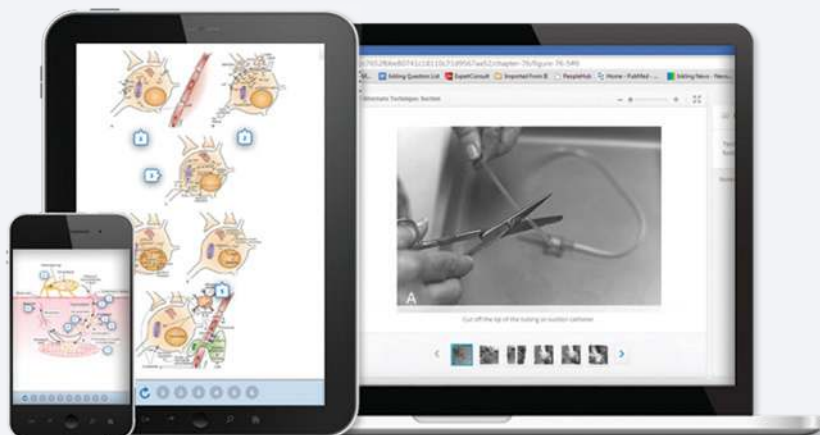---

Sixth Edition

ELSEVIER

# Any screen. Any time. Anywhere.

Activate the eBook version  
of this title at no additional charge.



Expert Consult eBooks give you the power to browse and find content, view enhanced images, share notes and highlights—both online and offline.

## Unlock your eBook today.

- 1 Visit [expertconsult.inkling.com/redeem](http://expertconsult.inkling.com/redeem)
- 2 Scratch off your code
- 3 Type code into “Enter Code” box
- 4 Click “Redeem”
- 5 Log in or Sign up
- 6 Go to “My Library”

It's that easy!

Scan this QR code to redeem your  
eBook through your mobile device:



Place Peel Off  
Sticker Here

**For technical assistance:**  
email [expertconsult.help@elsevier.com](mailto:expertconsult.help@elsevier.com)  
call 1-800-401-9962 (inside the US)  
call +1-314-447-8200 (outside the US)

**ELSEVIER**

Use of the current edition of the electronic version of this book (eBook) is subject to the terms of the nontransferable, limited license granted on expertconsult.inkling.com. Access to the eBook is limited to the first individual who redeems the PIN, located on the inside cover of this book, at expertconsult.inkling.com and may not be transferred to another party by resale, lending, or other means.



# Contemporary Orthodontics



# Contemporary Orthodontics

*Sixth Edition*

## **William R. Proffit, DDS, PhD**

Emeritus Professor (formerly Kenan Distinguished Professor)  
Department of Orthodontics  
School of Dentistry  
University of North Carolina  
Chapel Hill, North Carolina

## **Henry W. Fields, Jr., DDS, MS, MSD**

Professor and Vig/Williams Orthodontic Division Chair  
College of Dentistry  
The Ohio State University  
Chief, Orthodontics, Nationwide Children's Hospital  
Columbus, Ohio

## **Brent E. Larson, DDS, MS**

Professor and Director  
Department of Developmental and Surgical Sciences  
School of Dentistry  
University of Minnesota  
Minneapolis, Minnesota

## **David M. Sarver, DDS, MS**

Adjunct Professor, Orthodontics  
University of Alabama at Birmingham  
Birmingham, Alabama  
University of North Carolina  
Chapel Hill, North Carolina  
Sarver Orthodontics  
Vestavia Hills, Alabama

ELSEVIER

# ELSEVIER

1600 John F. Kennedy Blvd.  
Ste 1600  
Philadelphia, PA 19103-2899

CONTEMPORARY ORTHODONTICS,  
SIXTH EDITION

ISBN: 978-0-323-54387-3

**Copyright © 2019 by Elsevier, Inc. All rights reserved.**

No part of this publication may be reproduced or transmitted in any form or by any means, electronic or mechanical, including photocopying, recording, or any information storage and retrieval system, without permission in writing from the publisher. Details on how to seek permission, further information about the Publisher's permissions policies and our arrangements with organizations such as the Copyright Clearance Center and the Copyright Licensing Agency, can be found at our website: [www.elsevier.com/permissions](http://www.elsevier.com/permissions).

This book and the individual contributions contained in it are protected under copyright by the Publisher (other than as may be noted herein).

## Notices

Knowledge and best practice in this field are constantly changing. As new research and experience broaden our understanding, changes in research methods, professional practices, or medical treatment may become necessary.

Practitioners and researchers must always rely on their own experience and knowledge in evaluating and using any information, methods, compounds, or experiments described herein. In using such information or methods they should be mindful of their own safety and the safety of others, including parties for whom they have a professional responsibility.

With respect to any drug or pharmaceutical products identified, readers are advised to check the most current information provided (i) on procedures featured or (ii) by the manufacturer of each product to be administered, to verify the recommended dose or formula, the method and duration of administration, and contraindications. It is the responsibility of practitioners, relying on their own experience and knowledge of their patients, to make diagnoses, to determine dosages and the best treatment for each individual patient, and to take all appropriate safety precautions.

To the fullest extent of the law, neither the Publisher nor the authors, contributors, or editors, assume any liability for any injury and/or damage to persons or property as a matter of products liability, negligence or otherwise, or from any use or operation of any methods, products, instructions, or ideas contained in the material herein.

Previous editions copyrighted 2013 by Mosby, an imprint of Elsevier, Inc., and 2007, 2000, 1993, 1986 by Mosby, Inc., an affiliate of Elsevier, Inc.

**Library of Congress Control Number: 2018951180**

*Content Strategist:* Alexandra Mortimer  
*Director, Continuity:* Taylor Ball  
*Publishing Services Manager:* Catherine Albright Jackson  
*Senior Project Manager:* Claire Kramer  
*Design Direction:* Bridget Hoette

Printed in China

Last digit is the print number: 9 8 7 6 5 4 3 2 1



Working together  
to grow libraries in  
developing countries

[www.elsevier.com](http://www.elsevier.com) • [www.bookaid.org](http://www.bookaid.org)



# Preface

As with previous editions, this edition of *Contemporary Orthodontics* has been extensively revised to maintain the original goal of the book: to provide an up-to-date overview of orthodontics that is accessible to students, useful for residents, and a valuable reference for practitioners. In each section of the book, basic background information needed by every dentist is covered first and is followed by more detailed information for orthodontic specialists.

New aspects of this edition include:

- an updated section on human embryology in which all the images now consist of human embryos, not experimental animals;
- new material on three-dimensional (3-D) imaging and use of 3-D superimpositions to better understand treatment outcomes;
- a new, visual way to compare the material properties of various orthodontic archwires;
- further information on bonding techniques, bracket developments, and biomechanical considerations;
- an expanded discussion of current growth modification procedures and outcomes;
- new aspects of temporary anchorage device use for skeletal anchorage, especially linked screws for palatal anchorage and the biomechanics of skeletal anchorage; and
- case treatment examples of management of complex problems in comprehensive orthodontic or surgical-orthodontic treatment at all ages.

As before, literature citations have been chosen to include selected classic papers but largely are taken from recent publications that provide current information and cite previous publications. The goal is to open the door to a more detailed evaluation of the subject without including hundreds of older citations in the text. As the emphasis on evidence-based treatment increases, systematic reviews and meta-analysis are pulling together information from multiple studies, and we also have incorporated findings from well-done reviews of this type. Unfortunately, the emphasis must be on well done because by no means are all these reviews focused and conducted in a way that provides clinically useful data. We have attempted to provide recommendations for what are now the preferred approaches to treatment, while indicating how certain

we can be (or how uncertain we ought to be) that current views are correct.

This edition of the book is supported by two types of supplemental teaching material available through Internet connections: (1) self-instructional computer teaching modules primarily oriented toward predoctoral dental students (but quite useful in residency training as well) and (2) video recordings of graduate-level clinical seminars on a variety of topics. Both types of supplemental materials are used at the University of North Carolina and at other schools in the United States and abroad.

The computer modules have been revised and updated recently to match the content of this edition and are available to students at participating dental schools on a dedicated website, [www.orthodonticinstruction.com](http://www.orthodonticinstruction.com). Supplying the modules in this way has two major advantages: (1) once access to the website has been granted, students can use the teaching modules anywhere, and (2) updates and correction of errors are made on the website and are immediately available to all users. A preview of these teaching materials is available on the website. They are available in course packages (four separate courses for the four levels of instruction) that include a syllabus with reading/viewing assignments, unit and course tests, and outlines for the small-group seminars that are an integral part of the teaching approach. Access to individual components of the courses also can be arranged.

The “blended” educational method that includes the use of recorded seminars is based on the finding that orthodontic residents who prepare for a seminar, observe the seminar on that topic that was recorded live at another school, and participate immediately in a follow-up discussion, learn as much as those who participated in the live seminar. The recorded seminars and the seminar preparation materials are available on a different dedicated website, [watchseminars.com](http://watchseminars.com), where orthodontic, oral and maxillofacial surgery, and anesthesia teaching materials can be found.

For further information about the supplemental teaching materials, contact Dr. William Proffit or Dr. Tate Jackson at the Department of Orthodontics, University of North Carolina School of Dentistry, Chapel Hill, North Carolina.

# Acknowledgments

We thank Ramona Hutton-Howe for her usual excellent work with the new photographs and radiographs for this edition and Warren McCollum for his equally excellent artwork. Both have worked with every edition of this book. Dayne Harrison took over the organizational aspect this time, dealt with the hundreds of pages of text, and managed it nicely.

For this edition, Dr. Kathy Sulik's update on human embryology and contribution of human embryo images of early development and the stages of palate closure gave us a clearer and current presentation of this important subject. Dr. Anita's Gohel's contribution of cone-beam CT images and clarification of three-dimensional (3-D) imaging techniques made this section contemporary, and her voice blended in seamlessly. Dr. Tung Nguyen's 3-D superimpositions and his expertise in this area were important in our presentation of advances in 3-D technology and much appreciated, as was Dr. Matt Larson's assistance with the evaluation of new orthodontic materials and biomechanical considerations.

Drs. William Gierie, Dan Grauer, Jack Fisher, Nicole Scheffler, Tim Shaughnessy, and Dirk Wiechmann provided illustrative cases

to illustrate the scope of modern treatment with computer technology and skeletal anchorage. Drs. Alex Culberson and Brennan Skulski also provided images. Dr. Maura Partrick managed the extensive literature searches for the whole book, so that the references for all chapters are up to date to late 2017, and Dr. Katherine (Katie) Born did the cephalometric superimpositions.

We benefited from critical review of sections of the manuscript by a number of colleagues and appreciate their efforts to help us get things as correct as possible. And we are grateful to Drs. Gavin Heymann and Tammy Severt of the University of North Carolina Orthodontic Alumni Association for their management of the book production finances.

To each and all, we greatly appreciate your help.

**William R. Proffit  
Henry W. Fields, Jr.  
Brent E. Larson  
David M. Sarver**

# Contents

## Section I The Orthodontic Problem

---

### **1 Malocclusion and Dentofacial Deformity in Contemporary Society, 2**

*William R. Proffit*

The Changing Goals of Orthodontic Treatment, 2  
The Usual Orthodontic Problems: Epidemiology of Malocclusion, 5  
Why Is Malocclusion So Prevalent? 7  
Who Needs Treatment? 9  
Type of Treatment: Evidence-Based Selection, 11  
Demand for Treatment, 13

### **2 Concepts of Growth and Development, 18**

*William R. Proffit*

Growth: Pattern, Variability, and Timing, 18  
Methods for Studying Physical Growth, 23  
The Nature of Skeletal Growth, 30  
Sites and Types of Growth in the Craniofacial Complex, 32  
Theories of Growth Control, 37  
Social and Behavioral Development, 46

### **3 Early Stages of Development, 60**

*William R. Proffit*

Late Fetal Development and Birth, 60  
Infancy and Early Childhood: The Primary Dentition Years, 60  
Late Childhood: The Mixed Dentition Years, 66

### **4 Later Stages of Development, 84**

*William R. Proffit*

Adolescence: The Early Permanent Dentition Years, 84  
Growth Patterns in the Dentofacial Complex, 88  
Maturational and Aging Changes, 96

### **5 The Etiology of Orthodontic Problems, 107**

*William R. Proffit*

Specific Causes of Malocclusion, 107  
Genetic Influences, 121  
Environmental Influences, 124  
Etiology in Contemporary Perspective, 134

## Section II Diagnosis and Treatment Planning

---

### **6 Orthodontic Diagnosis: The Problem-Oriented Approach, 140**

*William R. Proffit, David M. Sarver, Henry W. Fields, Jr.*

Questionnaire and Interview, 140  
Clinical Evaluation, 146  
Diagnostic Records, 166  
Orthodontic Classification, 193  
Development of a Problem List, 202

### **7 Orthodontic Treatment Planning: From Problem List to Specific Plan, 208**

*William R. Proffit, Henry W. Fields, Jr., Brent E. Larson, David M. Sarver*

Treatment Planning Concepts and Goals, 208  
Major Issues in Planning Treatment, 208  
Treatment Possibilities, 209  
Planning Comprehensive Orthodontic Treatment, 223  
Treatment Planning in Special Circumstances, 236

## Section III Biomechanics, Mechanics, and Contemporary Orthodontic Appliances

---

### **8 The Biologic Basis of Orthodontic Therapy, 248**

*William R. Proffit*

Periodontal and Bone Response to Normal Function, 248  
Periodontal Ligament and Bone Response to Sustained Force, 250  
Anchorage and Its Control, 265  
Deleterious Effects of Orthodontic Force, 268

### **9 Mechanical Principles in Orthodontic Force Control, 276**

*Brent E. Larson, William R. Proffit*

Elastic Materials and the Production of Orthodontic Force, 276  
Design Factors in Orthodontic Appliances, 288  
Mechanical Aspects of Anchorage Control, 292  
Determinate Versus Indeterminate Force Systems, 298

**10 Contemporary Orthodontic Appliances, 310***William R. Proffit, Brent E. Larson*

Removable Appliances, 310

Fixed Appliances, 321

**Section IV Treatment in Preadolescent Children: What Is Different?****11 Moderate Nonskeletal Problems in Preadolescent Children: Preventive and Interceptive Treatment in Family Practice, 356***Henry W. Fields, Jr., William R. Proffit*

Orthodontic Triage: Distinguishing Moderate From Complex Treatment Problems, 356

Management of Occlusal Relationship Problems, 364

Management of Eruption Problems, 375

Space Analysis: Quantification of Space Problems, 385

Treatment of Space Problems, 388

**12 Complex Nonskeletal Problems in Preadolescent Children: Preventive and Interceptive Treatment, 402***Henry W. Fields, Jr., William R. Proffit*

Eruption Problems, 402

Traumatic Displacement of Teeth, 406

Space-Related Problems, 409

**Section V Growth Modification****13 Treatment of Skeletal Transverse and Class III Problems, 430***William R. Proffit, Henry W. Fields, Jr.*

Growth Modification in the Transverse Plane of Space, 430

Class III Growth Modification, 440

**14 Growth Modification in Class II, Open Bite/Deep Bite, and Multidimensional Problems, 455***Henry W. Fields, Jr., William R. Proffit*

Class II Growth Modification, 455

Combined Vertical and Anteroposterior Problems, 484

Facial Asymmetry in Children, 492

**Section VI Comprehensive Orthodontic Treatment in the Early Permanent Dentition****15 Comprehensive Treatment in Adolescents: Alignment and Vertical Problems, 501***William R. Proffit, Brent E. Larson*

Class I Crowding/Protrusion, 501

Leveling, 518

**16 Comprehensive Treatment in Adolescence: Space Closure and Class II/Class III Correction, 528***William R. Proffit, Brent E. Larson*

Space Closure in Incisor Protrusion Problems, 528

Class II Correction in Adolescents, 538

Class III Camouflage, 551

**17 Comprehensive Treatment: Finishing, 556***William R. Proffit, Brent E. Larson*

Adjustment of Individual Tooth Positions, 556

Correction of Vertical Incisor Relationships, 562

Final "Settling" of Teeth, 564

Positioners for Finishing, 567

Special Finishing Procedures to Avoid Relapse, 569

Micro-Esthetic Procedures in Finishing, 570

**18 Retention, 579***William R. Proffit*

Why Is Retention Necessary? 579

Removable Retainers, 584

Fixed Retainers, 586

Active Retainers, 591

**Section VII Treatment for Adults****19 Special Considerations in Treatment for Adults, 599***William R. Proffit, David M. Sarver*

Adjunctive Versus Comprehensive Treatment, 599

Principles of Adjunctive Treatment, 600

Adjunctive Treatment Procedures, 603

Comprehensive Treatment in Adults, 614

Summary, 654

**20 Combined Surgical and Orthodontic Treatment, 657***William R. Proffit, David M. Sarver*

Development of Orthognathic Surgery, 657

The Borderline Patient: Camouflage Versus Surgery, 657

Contemporary Surgical Techniques, 667

Special Considerations in Planning Surgical Treatment, 681

Putting Surgical and Orthodontic Treatment Together: Who Does What and When? 692



# The Orthodontic Problem

This section of the book addresses important questions that are the intellectual and scientific background for the practice of orthodontics:

*Why do we provide orthodontic treatment?*

*Who needs treatment?*

*How do people benefit from it?*

*How prevalent are orthodontic problems?*

*How are these problems related to growth of the head and face?*

*How are these problems related to eruption of the teeth?*

*Can we identify the etiology of these orthodontic problems?*

You need to consider the answers to these questions before you can appropriately diagnose orthodontic problems, plan the treatment that will provide maximum benefit to the patient, and carry out that treatment. The answers, to the best of our ability to provide them now, are in the following chapters.

# Malocclusion and Dentofacial Deformity in Contemporary Society

## CHAPTER OUTLINE

### The Changing Goals of Orthodontic Treatment

The Development of Orthodontics

Modern Treatment Goals: The Soft Tissue Paradigm

### The Usual Orthodontic Problems: Epidemiology of Malocclusion

### Why Is Malocclusion So Prevalent?

### Who Needs Treatment?

Psychosocial Problems

Oral Function

Relationship to Injury and Dental Disease

### Type of Treatment: Evidence-Based Selection

Randomized Clinical Trials: The Best Evidence

Retrospective Studies: Control Group Required

### Demand for Treatment

Epidemiologic Estimates of Orthodontic Treatment Need

Who Seeks Treatment?

## The Changing Goals of Orthodontic Treatment

### The Development of Orthodontics

Crowded, irregular, and protruding teeth have been a problem for some individuals since antiquity, and attempts to correct this disorder go back at least to 1000 BC. Primitive (and surprisingly well-designed) orthodontic appliances have been found in both Greek and Etruscan materials.<sup>1</sup> As dentistry developed in the 18th and 19th centuries, a number of devices for the “regulation” of the teeth were described by various authors and apparently used sporadically by the dentists of that era.

After 1850 the first texts that systematically described orthodontics appeared, the most notable being Norman Kingsley's *Oral Deformities*.<sup>2</sup> Kingsley, who had a tremendous influence on American dentistry in the latter half of the 19th century, was among the first to use extraoral force to correct protruding teeth. He was also a pioneer in the treatment of cleft palate and related problems.

Despite the contributions of Kingsley and his contemporaries, their emphasis in orthodontics remained the alignment of the

teeth and the correction of facial proportions. Little attention was paid to bite relationships, and because it was common practice to remove teeth for many dental problems, extractions for crowding or malalignment were frequent. In an era when an intact dentition was a rarity, the details of occlusal relationships were considered unimportant.

To make good prosthetic replacement teeth, it was necessary to develop a concept of occlusion, and this occurred in the late 1800s. As the concepts of prosthetic occlusion developed and were refined, it was natural to extend this to the natural dentition. Edward H. Angle ([Fig. 1.1](#)), whose influence began to be felt about 1890, can be credited with much of the development of a concept of occlusion in the natural dentition. Angle's original interest was in prosthodontics, and he taught in that department in dental schools in Pennsylvania and Minnesota in the 1880s. His increasing interest in dental occlusion and in the treatment necessary to obtain normal occlusion led directly to his development of orthodontics as a specialty, with himself as the “father of modern orthodontics.”

Angle's classification of malocclusion in the 1890s was an important step in the development of orthodontics because it not only subdivided major types of malocclusion but also included the first clear and simple definition of normal occlusion in the natural dentition. Angle's postulate was that the upper first molars were the key to occlusion and that the upper and lower molars should be related so that the mesiobuccal cusp of the upper molar occludes in the buccal groove of the lower molar. If the teeth were arranged on a smoothly curving line of occlusion ([Fig. 1.2](#)) and this molar relationship existed ([Fig. 1.3](#)), then normal occlusion would result.<sup>3</sup> This statement, which 100 years of experience has proved to be correct except when there are aberrations in the size of teeth, brilliantly simplified normal occlusion.

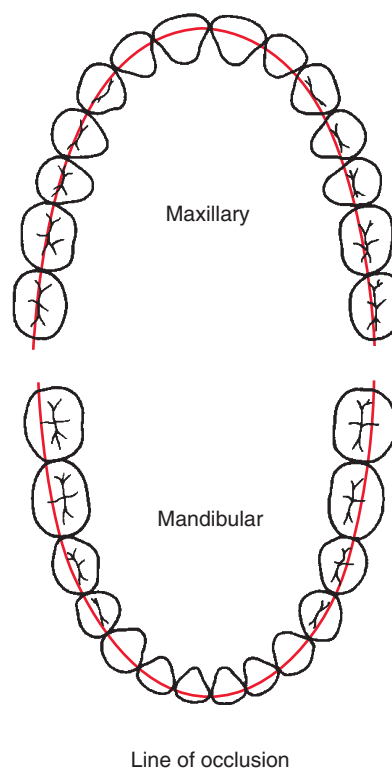
Angle then described three classes of malocclusion, based on the occlusal relationships of the first molars:

- Class I: Normal relationship of the molars, but line of occlusion incorrect because of malposed teeth, rotations, or other causes
- Class II: Lower molar distally positioned relative to upper molar, line of occlusion not specified
- Class III: Lower molar mesially positioned relative to upper molar, line of occlusion not specified

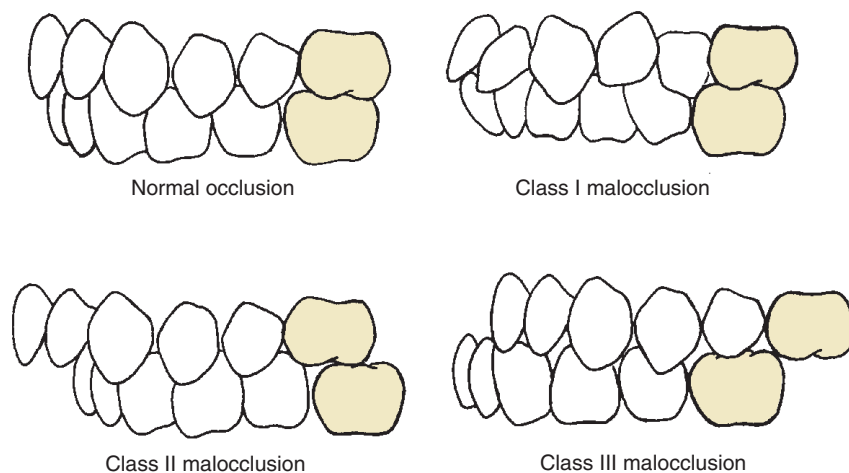
Note that the Angle classification has four classes: normal occlusion, Class I malocclusion, Class II malocclusion, and Class III malocclusion (see [Fig. 1.3](#)). Normal occlusion and Class I malocclusion share the same molar relationship but differ in the arrangement of the teeth relative to the line of occlusion. The line of occlusion may or may not be correct in Class II and Class III malocclusion.



• **Fig. 1.1** Edward H. Angle in his 50s, as the proprietor of the Angle School of Orthodontia. After establishing himself as the first dental specialist, Angle operated proprietary orthodontic schools from 1905 to 1928 in St. Louis, Missouri; New London, Connecticut; and Pasadena, California, in which many of the pioneer American orthodontists were trained.



• **Fig. 1.2** The line of occlusion is a smooth (catenary) curve passing through the central fossa of each upper molar and across the cingulum of the upper canine and incisor teeth. The same line runs along the buccal cusps and incisal edges of the lower teeth, thus specifying the occlusal as well as interarch relationships once the molar position is established.



• **Fig. 1.3** Normal occlusion and malocclusion classes as specified by Angle. This classification was quickly and widely adopted early in the 20th century. It is incorporated within all contemporary descriptive and classification schemes.

With the establishment of a concept of normal occlusion and a classification scheme that incorporated the line of occlusion, by the early 1900s orthodontics was no longer just the alignment of irregular teeth. Instead, it had evolved into the treatment of malocclusion, defined as any deviation from the ideal occlusal scheme described by Angle. Because precisely defined relationships required

a full complement of teeth in both arches, maintaining an intact dentition became an important goal of orthodontic treatment. Angle and his followers strongly opposed extraction for orthodontic purposes. With the emphasis on dental occlusion that followed, however, less attention came to be paid to facial proportions and esthetics. Angle abandoned extraoral force because he decided this

was not necessary to achieve proper occlusal relationships. He solved the problem of dental and facial appearance by simply postulating that the best esthetics always were achieved when the patient had ideal occlusion.

As time passed, it became clear that even an excellent occlusion was unsatisfactory if it was achieved at the expense of proper facial proportions. Not only were there esthetic problems, it often proved impossible to maintain an occlusal relationship achieved by prolonged use of heavy elastics to pull the teeth together as Angle and his followers had suggested. Under the leadership of Charles Tweed in the United States and Raymond Begg in Australia (both of whom had studied with Angle), extraction of teeth was reintroduced into orthodontics in the 1940s and 1950s to enhance facial esthetics and achieve better stability of the occlusal relationships.

Cephalometric radiography, which enabled orthodontists to measure the changes in tooth and jaw positions produced by growth and treatment, came into widespread use after World War II. These radiographs made it clear that many Class II and Class III malocclusions resulted from faulty jaw relationships, not just malposed teeth. By use of cephalometrics, it also was possible to see that jaw growth could be altered by orthodontic treatment. In Europe, the method of “functional jaw orthopedics” was developed to enhance growth changes, while in the United States, extraoral force came to be used for this purpose. At present, both functional and extraoral appliances are used internationally to control and modify growth and form. Obtaining correct or at least improved jaw relationships became a goal of treatment by the mid-20th century.

The changes in the goals of orthodontic treatment, which now focus on facial proportions and the impact of the dentition on facial appearance, have been codified in the form of the soft tissue paradigm.<sup>4</sup>

## Modern Treatment Goals: The Soft Tissue Paradigm

A paradigm can be defined as “a set of shared beliefs and assumptions that represent the conceptual foundation of an area of science or clinical practice.” The soft tissue paradigm states that both the goals and limitations of modern orthodontic and orthognathic treatment are determined by the soft tissues of the face, not by the teeth and bones. This reorientation of orthodontics away from the Angle paradigm that dominated the 20th century is most easily understood by comparing treatment goals, diagnostic emphasis, and treatment approach in the two paradigms (Table 1.1). With the soft tissue paradigm, the increased focus on clinical examination rather than examination of dental casts and radiographs leads to a different approach to obtaining important diagnostic information, and that information is used to develop treatment plans that would not have been considered without it.

More specifically, what difference does the soft tissue paradigm make in planning treatment? There are several major effects:

1. The primary goal of treatment becomes soft tissue relationships and adaptations, not Angle’s ideal occlusion. This broader goal is not incompatible with Angle’s ideal occlusion, but it acknowledges that to provide maximum benefit for the patient, ideal occlusion cannot always be the major focus of a treatment plan. Soft tissue relationships, both the proportions of the soft tissue integument of the face and the relationship of the dentition to the lips and face, are the major determinants of facial appearance. Soft tissue adaptations to the position of the teeth (or lack

**TABLE 1.1** Angle Versus Soft Tissue Paradigms: A New Way of Looking at Treatment Goals

Parameter	Angle Paradigm	Soft Tissue Paradigm
Primary treatment goal	Ideal dental occlusion	Normal soft tissue proportions and adaptations
Secondary goal	Ideal jaw relationships	Functional occlusion
Hard and soft tissue relationships	Ideal hard tissue proportions produce ideal soft tissues	Ideal soft tissue proportions define ideal hard tissues
Diagnostic emphasis	Dental casts, cephalometric radiographs	Clinical examination of intraoral and facial soft tissues
Treatment approach	Obtain ideal dental and skeletal relationships, assume the soft tissues will be all right	Plan ideal soft tissue relationships and then place teeth and jaws as needed to achieve this
Function emphasis	TMJ in relation to dental occlusion	Soft tissue movement in relation to display of teeth
Stability of result	Related primarily to dental occlusion	Related primarily to soft tissue pressure and equilibrium effects

TMJ, Temporomandibular joint.

thereof) determine whether the orthodontic result will be stable. Keeping this in mind while planning treatment is critically important.

2. The secondary goal of treatment becomes *functional occlusion*. What does that have to do with soft tissues? Temporomandibular (TM) dysfunction, to the extent that it relates to the dental occlusion, is best thought of as the result of injury to the soft tissues around the temporomandibular joint (TMJ) caused by clenching and grinding the teeth. Given that, an important goal of treatment is to arrange the occlusion to minimize the chance of injury. In this also, Angle’s ideal occlusion is not incompatible with the broader goal, but deviations from the Angle ideal may provide greater benefit for some patients and should be considered when treatment is planned.
3. The thought process that goes into “solving the patient’s problems” is reversed. In the past, the clinician’s focus was on dental and skeletal relationships, with the tacit assumption that if these were correct, soft tissue relationships would take care of themselves. With the broader focus on facial and oral soft tissues, the thought process is to establish what these soft tissue relationships should be and then determine how the teeth and jaws would have to be arranged to meet the soft tissue goals. Why is this important in establishing the goals of treatment? It relates very much to why patients and parents seek orthodontic treatment and what they expect to gain from it.

The following sections of this chapter provide some background on the prevalence of malocclusion, what we know about the need for treatment of malocclusion and dentofacial deformity, and how



soft tissue considerations, as well as teeth and bone, affect both need and demand for orthodontic treatment. It must be kept in mind that orthodontics is shaped by biological, psychosocial, and cultural determinants. For that reason, when defining the goals of orthodontic treatment, one has to consider not only morphologic and functional factors, but a wide range of psychosocial and bioethical issues as well. All these topics are discussed in much greater detail in the following chapters on diagnosis, treatment planning and treatment.

## The Usual Orthodontic Problems: Epidemiology of Malocclusion

Angle's "normal occlusion" more properly should be considered the ideal. In fact, perfectly interdigitating teeth arranged along a perfectly regular line of occlusion are quite rare. For many years, epidemiologic studies of malocclusion suffered from considerable disagreement among investigators about how much deviation from the ideal should be accepted within the bounds of normal. By the 1970s, a series of studies by public health or university groups in most developed countries provided a reasonably clear worldwide picture of the prevalence of the various types of malocclusion by degree of severity.

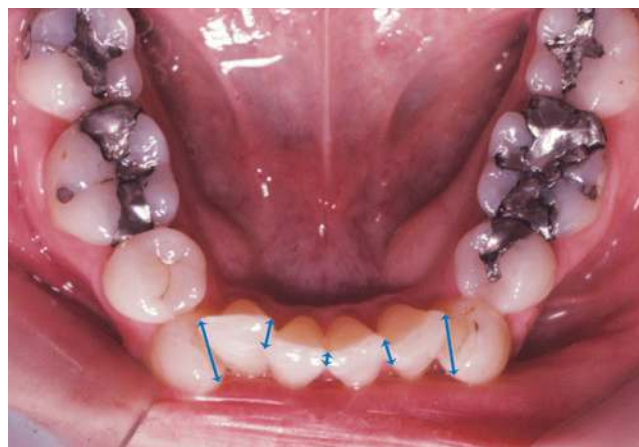
In the United States, two large-scale surveys carried out by the U.S. Public Health Service (USPHS) covered children ages 6 to 11 years from 1963 to 1965 and youths ages 12 to 17 years in 1969 and 1970.<sup>5,6</sup> As part of a large-scale national survey of health care problems and needs in the United States in 1989 through 1994 (Third National Health and Nutrition Examination Survey [NHANES III]), estimates of malocclusion again were obtained. This study of some 14,000 individuals was statistically designed to provide weighted estimates for approximately 150 million persons in the sampled racial or ethnic and age groups. The data provide reasonably current information for U.S. children and youths and include the first good data set for malocclusion in adults, with separate estimates for the major racial or ethnic groups.<sup>7</sup>

The characteristics of malocclusion evaluated in NHANES III included the irregularity index, which is a measure of incisor alignment (Fig. 1.4); the prevalence of midline diastema larger than 2 mm (Fig. 1.5); and the prevalence of posterior crossbite (Fig. 1.6). In addition, overjet (Fig. 1.7) and overbite or open bite (Fig. 1.8) were measured. Overjet reflects Angle's Class II and Class III molar relationships. Because overjet can be evaluated much more precisely than molar relationship in a clinical examination, molar relationship was not evaluated directly.

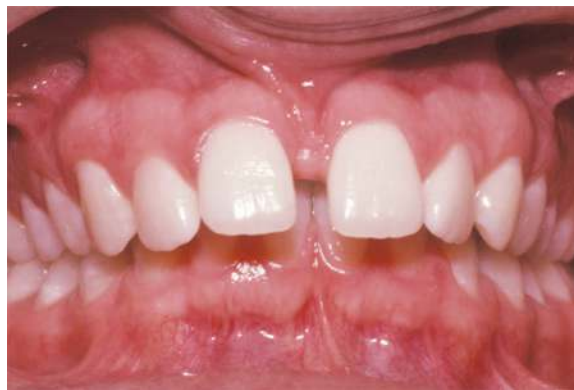Data for these characteristics of malocclusion for children (age 8 to 11), youths (age 12 to 17), and adults (age 18 to 50) in the U.S. population, taken from NHANES III, are displayed graphically in Figs. 1.9 to 1.11.

Note in Fig. 1.10 that in the age 8 to 11 group, just over half of U.S. children have well-aligned incisors. The rest have varying degrees of malalignment and crowding. The percentage with excellent alignment decreases in the age 12 to 17 group as the remaining permanent teeth erupt, then remains essentially stable in the upper arch but worsens in the lower arch for adults. Only 34% of adults have well-aligned lower incisors. Nearly 15% of adolescents and adults have severely or extremely irregular incisors, so that major arch expansion or extraction of some teeth would be necessary to align them (see Fig. 1.10).

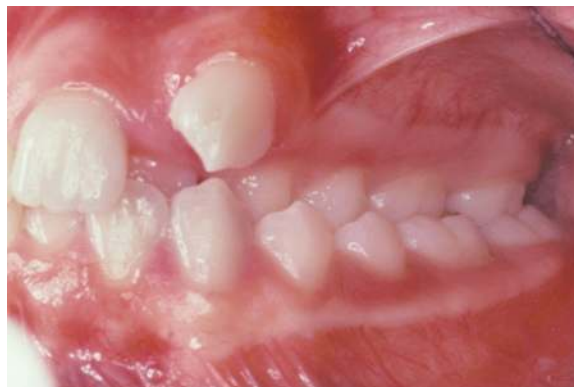A midline diastema (see Fig. 1.5) often is present in childhood (26% have >2 mm space). Although this space tends to close, over



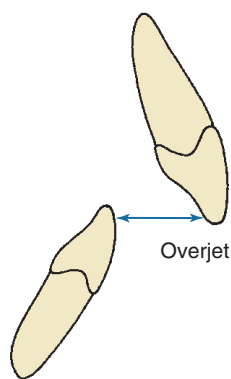
• **Fig. 1.4** Incisor irregularity usually is expressed as the irregularity index: the total of the millimeter distances from the contact point on each incisor tooth to the contact point that it should touch, as shown by the blue lines. For this patient, the irregularity index is 10 (mm).



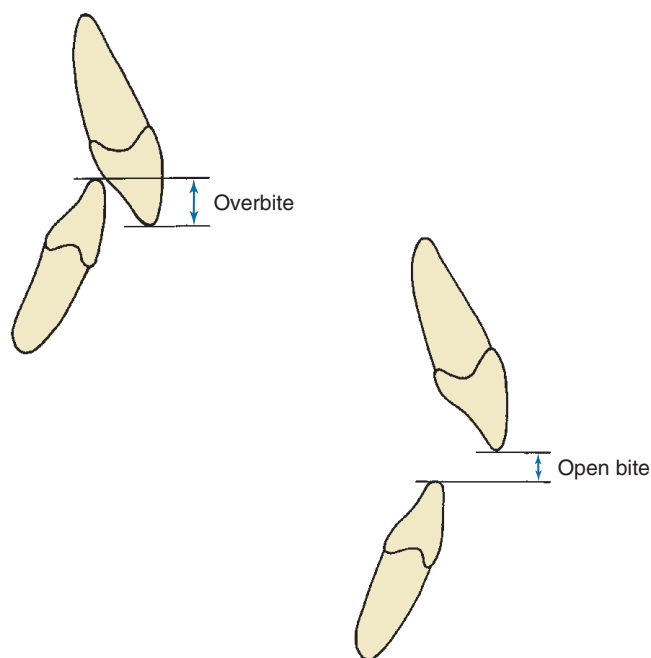
• **Fig. 1.5** A space between adjacent teeth is called a *diastema*. A maxillary midline diastema is relatively common, especially during the mixed dentition in childhood, and disappears or decreases in width as the permanent canines erupt. Spontaneous correction of a childhood diastema is most likely when its width is less than 2 mm, so this patient is on the borderline and may need future treatment.



• **Fig. 1.6** Posterior crossbite exists when the maxillary posterior teeth are lingually positioned relative to the mandibular teeth, as in this patient. Posterior crossbite most often reflects a narrow maxillary dental arch but can arise from other causes. This patient also has a one-tooth anterior crossbite, with the lateral incisor trapped lingually.



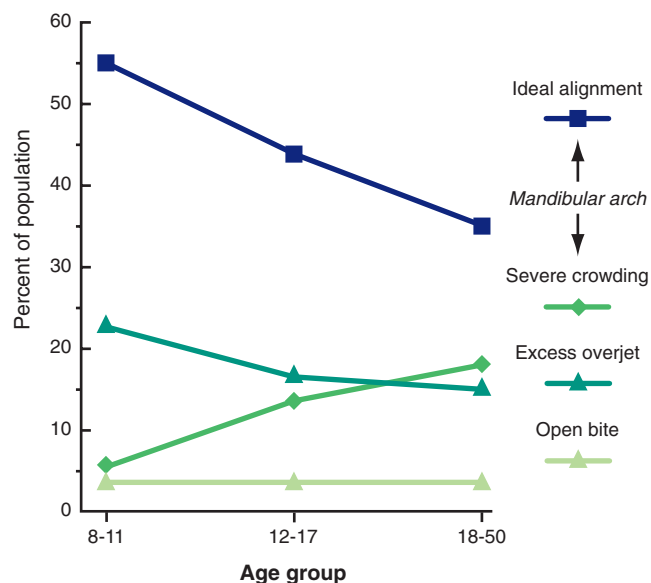
• **Fig. 1.7** Overjet is defined as horizontal overlap of the incisors. Normally the incisors are in contact, with the upper incisors ahead of the lower by only the thickness of their incisal edges (i.e., overjet of 2 to 3 mm is the normal relationship). If the lower incisors are in front of the upper incisors, the condition is called *reverse overjet* or *anterior crossbite*.



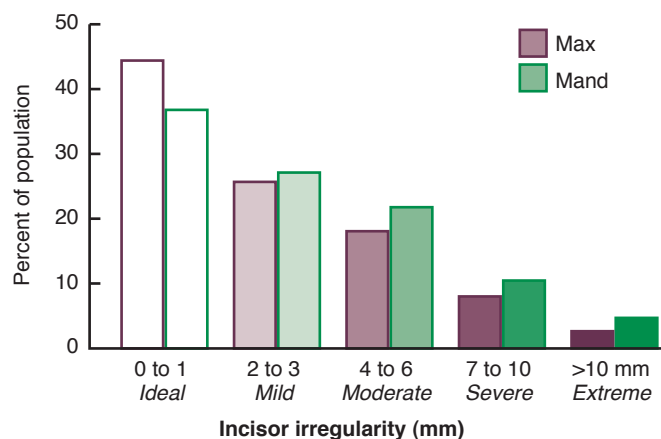
• **Fig. 1.8** Overbite is defined as the vertical overlap of the incisors. Normally, the lower incisal edges contact the lingual surface of the upper incisors at or above the cingulum (i.e., normally there is a 1- to 2-mm overbite). In open bite, there is no vertical overlap, and the vertical separation of the incisors is measured to quantify its severity.

6% of youths and adults still have a noticeable diastema that compromises the appearance of the smile. Blacks are more than twice as likely to have a midline diastema as whites or Mexican-Americans ( $P < .001$ ).

Occlusal relationships must be considered in all three planes of space. Lingual posterior crossbite (i.e., upper teeth lingual to lower teeth; see Fig. 1.6) is the major deviation from the normal transverse dental relationship and reflects deviations from ideal occlusion in the transverse plane of space. According to the NHANES III data,<sup>7</sup> it occurs in 9% of the U.S. population, ranging from 7.6% of Mexican-Americans to 9.1% of whites and 9.6% of blacks.



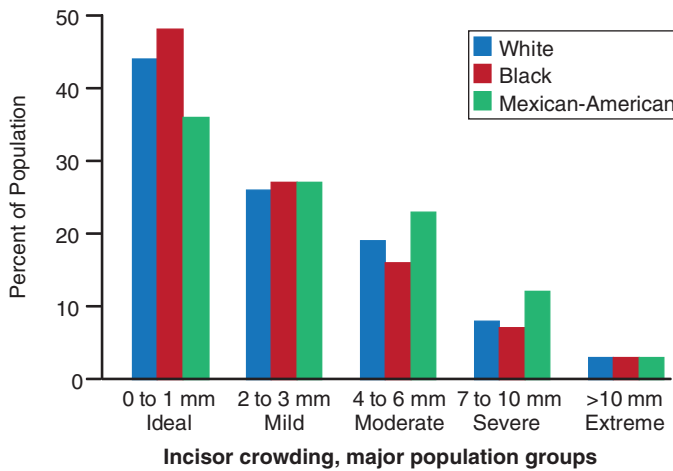
• **Fig. 1.9** Changes in the prevalence of types of malocclusion from childhood to adult life, United States, 1989 to 1994. Note the increase in incisor irregularity and decrease in severe overjet as children mature, both of which are related to more mandibular than maxillary growth.



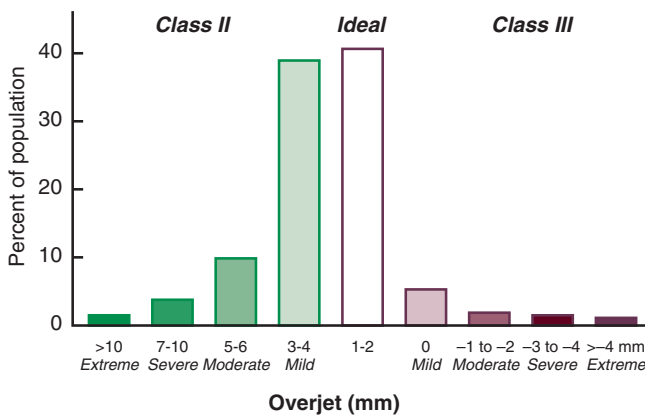
• **Fig. 1.10** Incisor irregularity in the U.S. population, 1989 to 1994. One-third of the population have at least moderately irregular (usually crowded) incisors, and nearly 15% have severe or extreme irregularity. Note that irregularity in the lower arch is more prevalent at any degree of severity.

Overjet or reverse overjet indicates anteroposterior deviations in the Class II or Class III direction, respectively, with Class III being much less prevalent (Fig. 1.12). Normal overjet is 2 mm. Overjet of 5 mm or more, suggesting Angle's Class II malocclusion, occurs in 23% of children, 15% of youths, and 13% of adults. This reflects the greater postnatal growth of the mandible than the maxilla, which is discussed in Chapter 2. Severe Class II problems are less prevalent and severe Class III problems are more prevalent in the Mexican-American than the white or black groups.

Vertical deviations from the ideal overbite of 0 to 2 mm are less frequent in adults than children but occur in half the adult population, with excessive overbite occurring much more frequently



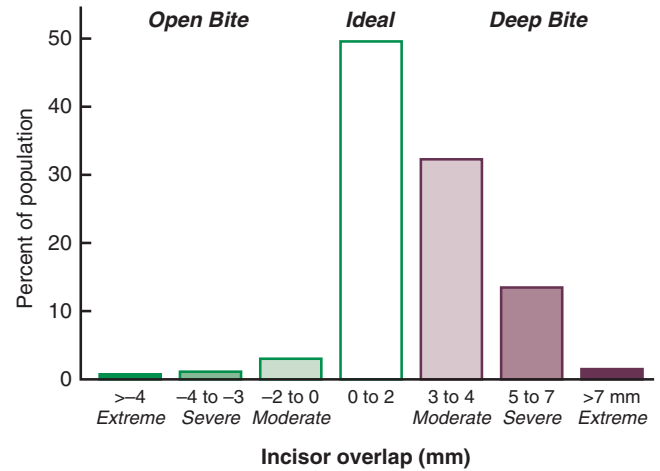
• **Fig. 1.11** Incisor irregularity by racial or ethnic groups. The percentage of the Mexican-American population with ideal alignment is lower than the other two groups, and the percentage with moderate and severe crowding is higher. This may reflect the low number of Mexican-Americans with orthodontic treatment at the time of the Third National Health and Nutrition Examination Survey (NHANES III).



• **Fig. 1.12** Overjet (Class II) and reverse overjet (Class III) in the U.S. population, 1989 to 1994. Only one-third of the population have ideal anteroposterior incisor relationships, but overjet is only moderately increased in another one-third. Increased overjet accompanying Class II malocclusion is much more prevalent than reverse overjet accompanying Class III.

than open bite (negative overbite) (Fig. 1.13). There are striking differences between the racial or ethnic groups in vertical dental relationships. Severe deep bite is nearly twice as prevalent in whites as blacks or Mexican-Americans ( $P < .001$ ), whereas open bite of more than 2 mm is five times more prevalent in blacks than in whites or Mexican-Americans ( $P < .001$ ). This almost surely reflects the slightly different craniofacial proportions of the black population groups (see Chapter 5 for a more complete discussion). In contrast to the higher prevalence of anteroposterior problems, vertical problems are less prevalent in Mexican-Americans than either blacks or whites.

From the survey data, it is interesting to calculate the percentage of American children and youths who would fall into Angle's four groups. From this perspective, 30% at most have Angle's normal occlusion. Class I malocclusion (50% to 55%) is by far the largest single group; there are about half as many Class II malocclusions



• **Fig. 1.13** Open bite and deep bite relationships in the U.S. population, 1989 to 1994. Half the population have an ideal vertical relationship of the incisors. Deep bite is much more prevalent than open bite, but vertical relationships vary greatly among racial groups.

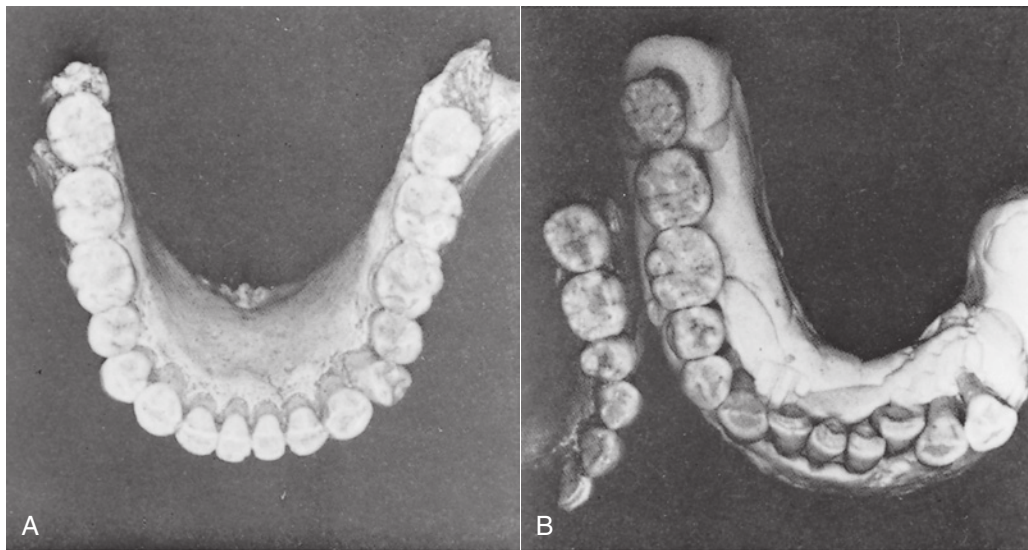
(approximately 15%) as normal occlusions; and Class III (less than 1%) represents a very small proportion of the total.

Differences in malocclusion characteristics between the United States and other countries would be expected because of differences in racial and ethnic composition. Although the available data are not as extensive as for American populations, it seems clear that Class II problems are most prevalent in whites of northern European descent (for instance, 25% of children in Denmark are reported to have Class II malocclusion), whereas Class III problems are most prevalent in Asian populations (3% to 5% in Japan, nearly 2% in China, with another 2% to 3% pseudo-Class III [i.e., shifting into anterior crossbite because of incisor interferences]). African populations are by no means homogenous, but from the differences found in the United States between blacks and whites, it seems likely that Class III and open bite are more frequent in African than European populations and deep bite less frequent.

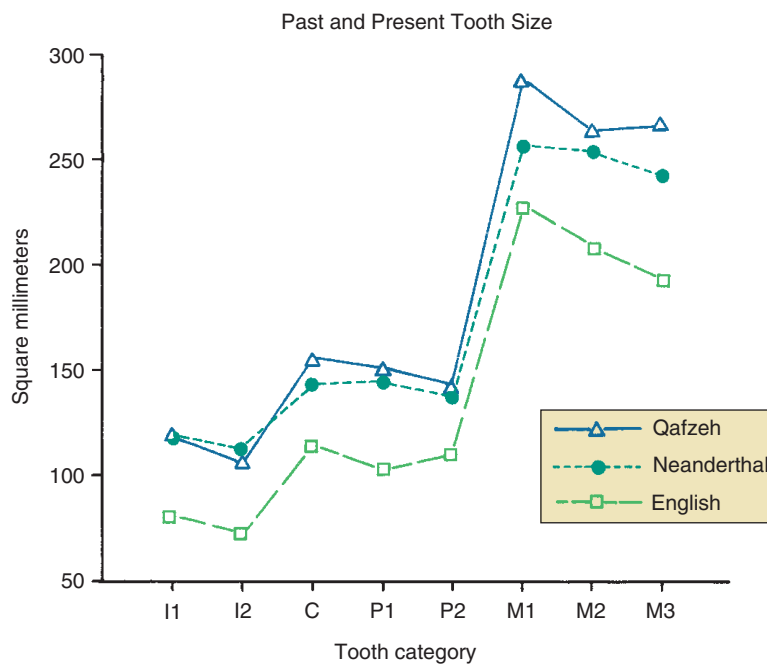
## Why Is Malocclusion So Prevalent?

Crowded and irregular teeth now occur in a majority of the population; skeletal remains indicate that this was unusual until relatively recently, although not unknown (Fig. 1.14). Because the mandible tends to become separated from the rest of the skull when long-buried skeletal remains are unearthed, it is easier to be sure what has happened to alignment of teeth than to occlusal relationships. The skeletal remains suggest that all members of a group might tend toward a Class III or, less commonly, a Class II jaw relationship. Similar findings are noted in present population groups that have remained largely unaffected by modern development: crowding and malalignment of teeth are uncommon, but the majority of the group may have mild anteroposterior or transverse discrepancies, as in the Class III tendency of South Pacific islanders<sup>8</sup> and buccal crossbite (X-occlusion) in aboriginal people of Australia.<sup>9</sup>

Although 1000 years is a long time relative to a single human life, it is a very short time from an evolutionary perspective. The fossil record documents evolutionary trends over many thousands of years that affect the present dentition, including a decrease in the size of individual teeth, in the number of the teeth, and in the size of the jaws. For example, there has been a steady reduction in



• **Fig. 1.14** Mandibular dental arches from specimens from the Krapina cave in Yugoslavia, estimated to be approximately 100,000 years old. (A) Note the excellent alignment in this specimen. Near-perfect alignment or minimal crowding was the usual finding in this group. (B) Crowding and malalignment are seen in this specimen, which had the largest teeth in this find of skeletal remains from approximately 80 individuals. (From Wolpoff WH. *Paleoanthropology*. New York: Alfred A Knopf; 1998.)



• **Fig. 1.15** The generalized decline in the size of human teeth can be seen by comparing tooth sizes from the anthropologic site at Qafzeh, dated 100,000 years ago; Neanderthal teeth, 10,000 years ago; and modern human populations. (Redrawn from Kelly MA, Larsen CS, eds. *Advances in Dental Anthropology*. New York: Wiley-Liss; 1991.)

the size of both anterior and posterior teeth over at least the last 100,000 years (Fig. 1.15). The number of teeth in the dentition of higher primates has been reduced from the usual mammalian pattern (Fig. 1.16). The third incisor and third premolar have disappeared, as has the fourth molar. At present, the human third molar, second premolar, and second incisor often fail to develop, which indicates that these teeth may be on their way out. Compared with other primates, modern humans have quite underdeveloped jaws.

It is easy to see that the progressive reduction in jaw size, if not well matched to a decrease in tooth size and number, could lead to crowding and malalignment. It is less easy to see why dental crowding should have increased quite recently, but this seems to have paralleled the transition from primitive agricultural to modern urbanized societies. Cardiovascular disease and related health problems appear rapidly when a previously unaffected population group leaves agrarian life for the city and civilization.



M-3	PM-4	C	I-3	Basic mammalian
M-3	PM-3	C	I-2	Prosimian
M-3	PM-2	C	I-2	Higher ape
M-3 (2)	PM-2	C	I-2	Man


• **Fig. 1.16** Reduction in the number of teeth has been a feature of primate evolution. In the present human population, third molars are so frequently missing that it appears a further reduction is in progress, and the relatively high prevalence of missing maxillary lateral incisors and mandibular second premolars suggests evolutionary pressure on these teeth.

High blood pressure, heart disease, diabetes, and several other medical problems are so much more prevalent in developed than underdeveloped countries that they have been labeled “diseases of civilization.”

There is some evidence that malocclusion increases within well-defined populations after a transition from rural villages to the city. Corruccini, for instance, reported a higher prevalence of crowding, posterior crossbite, and buccal segment discrepancy in urbanized youths compared with rural Punjabi youths of northern India.<sup>10</sup> One can argue that malocclusion is another condition made worse by the changing conditions of modern life, perhaps resulting in part from less use of the masticatory apparatus with softer foods now. Under primitive conditions, of course, excellent function of the jaws and teeth was an important predictor of the ability to survive and reproduce. A capable masticatory apparatus was essential to deal with uncooked or partially cooked meat and plant foods. Watching an Australian aboriginal man using every muscle of his upper body to tear off a piece of kangaroo flesh from the barely cooked animal, for instance, makes one appreciate the decrease in demand on the masticatory apparatus that has accompanied civilization (Fig. 1.17). An interesting proposal by anthropologists is that the introduction of cooking, so that it did not take as much effort and energy to masticate food, was the key to the development of the larger human brain. Without cooked food, it would not have been possible to meet the energy demand of the enlarging brain. With it, excess energy is available for brain development and robust jaws are unnecessary.<sup>11</sup>

Determining whether changes in jaw function have increased the prevalence of malocclusion is complicated by the fact that both dental caries and periodontal disease, which are rare on the primitive diet, appear rapidly when the diet changes. The resulting dental pathology can make it difficult to establish what the occlusion might have been in the absence of early loss of teeth, gingivitis, and periodontal breakdown. The increase in malocclusion in modern times certainly parallels the development of modern civilization, but a reduction in jaw size related to disuse atrophy is hard to document, and the parallel with stress-related diseases can be carried only so far. Although it is difficult to know the precise cause of any specific malocclusion, we do know in general what the etiologic possibilities are, and these are discussed in some detail in Chapter 5.

What difference does it make if you have a malocclusion? Let's now consider the reasons for orthodontic treatment.



• **Fig. 1.17** Sections from a 1960s movie of an Australian aboriginal man eating a kangaroo prepared in the traditional (barely cooked) fashion. Note the activity of muscles, not only in the facial region, but throughout the neck and shoulder girdle. (Courtesy M. J. Barrett.)

## Who Needs Treatment?

Protruding, irregular, or maloccluded teeth can cause three types of problems for the patient: (1) social discrimination because of facial appearance; (2) problems with oral function, including difficulties in jaw movement (muscle incoordination or pain),

temporomandibular dysfunction (TMD), and problems with mastication, swallowing, or speech; and (3) greater susceptibility to trauma, periodontal disease, or tooth decay.

## Psychosocial Problems

A number of studies in recent years have confirmed what is intuitively obvious: that severe malocclusion is likely to be a social handicap. The usual caricature of an individual who is none too bright includes protruding upper incisors. A witch not only rides a broom, she has a prominent lower jaw that would produce a Class III malocclusion. Well-aligned teeth and a pleasing smile carry positive status at all social levels and ages, whereas irregular or protruding teeth carry negative status.<sup>12,13</sup> Appearance can and does make a difference in teachers' expectations and therefore in student progress in school, in employability, and in competition for a mate. This places the concept of "handicapping malocclusion" in a larger and more important context. If the way you interact with other individuals is affected constantly by your teeth, your dental handicap is far from trivial. There is no doubt that social responses conditioned by the major deviations from the usual appearance of the face and teeth can severely affect quality of life and self-esteem in a way that compromises an individual's whole adaptation to life.<sup>14</sup>

It is interesting that psychic distress caused by disfiguring dental or facial conditions is not directly proportional to the anatomic severity of the problem. An individual who is grossly disfigured (e.g., with a distorted nose and scarred lip after cleft lip or palate repair) can anticipate a consistently negative response.<sup>15</sup> An individual with an apparently less severe problem (e.g., a deficient chin or protruding maxillary incisors) is sometimes treated differently because of this but sometimes not. It seems to be easier to cope with a defect if other people's responses to it are consistent than if they are not. Unpredictable responses produce anxiety and can have strong deleterious effects.<sup>16</sup> The impact of a physical defect on an individual also will be strongly influenced by that person's self-esteem. The result is that the same degree of anatomic abnormality can be merely a condition of no great consequence to one individual but a genuinely severe problem to another.

In short, it seems clear that the major reason people seek orthodontic treatment is to minimize psychosocial problems related to their dental and facial appearance.<sup>17</sup> These problems are not "just cosmetic." They can have a major effect on the quality of life,<sup>18</sup> and the evidence presented in the final section of this chapter documents that orthodontic treatment can improve it.

## Oral Function

Although severe malocclusion surely affects oral function, oral function adapts to form surprisingly well. It appears that malocclusion usually affects function not by making it impossible but by making it difficult, so that extra effort is required to compensate for the anatomic deformity. For instance, everyone uses as many chewing strokes as it takes to reduce a food bolus to a consistency that is satisfactory for swallowing, so if chewing is less efficient in the presence of malocclusion, either the affected individual uses more effort to chew or settles for less well-masticated food before swallowing it. Tongue and lip posture adapt to the position of the teeth so that swallowing rarely is affected (see Chapter 5). Similarly, almost everyone can move the jaw so that proper lip relationships exist for speech, so distorted speech is rarely noted even though an individual may have to make an extraordinary effort to produce

normal speech. As methods to quantify functional adaptations of this type are developed, it is likely that the effect of malocclusion on function will be appreciated more than it has been in the past.

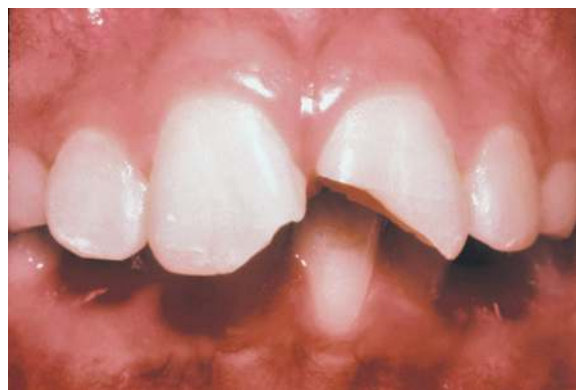The relationship of malocclusion and adaptive function to TMD, manifesting with pain in and around the TMJ, is understood much better now than only a few years ago. The pain may result from pathologic changes within the joint but more often is caused by muscle fatigue and spasm. Muscle pain almost always correlates with a history of clenching or grinding the teeth as a response to stressful situations or of constantly posturing the mandible to an anterior or lateral position.

Some dentists have suggested that even minor imperfections in the occlusion serve to trigger clenching and grinding the teeth. If this were true, it would indicate a real need for perfecting the occlusion in everyone, to avoid the possibility of developing facial muscle pain. Because the number of people with at least moderate degrees of malocclusion (50% to 75% of the population) far exceeds the number with TMD (5% to 30%, depending on which symptoms are examined), it seems unlikely that dental occlusion alone is enough to cause hyperactivity of the oral musculature. A reaction to stress usually is involved. Some individuals react by clenching and grinding their teeth; others develop symptoms in other organ systems. An individual almost never has both ulcerative colitis (also a common stress-induced disease) and TMD.

Some types of malocclusion (especially posterior crossbite with a shift on closure) correlate positively with TMJ problems and other types do not, but even the strongest correlation coefficients are only 0.3 to 0.4. This means that for the great majority of patients, there is no association between malocclusion and TMD.<sup>19</sup> Therefore orthodontics as the primary treatment for TMD almost never is indicated, but in special circumstances (see Chapter 18) it can be a useful adjunct to other treatment for the muscle pain.

## Relationship to Injury and Dental Disease

Malocclusion, particularly protruding maxillary incisors, can increase the likelihood of an injury to the teeth (Fig. 1.18).<sup>20</sup> There is about one chance in three that a child with an untreated Class II malocclusion will experience trauma to the upper incisors, but most of the time the result is only minor chips in the enamel.<sup>21</sup> For that reason, reducing the chance of injury when incisors protrude is



• **Fig. 1.18** Fractured maxillary central incisors in a 10-year-old girl. There is almost one chance in three of an injury to a protruding incisor, though fortunately the damage rarely is this severe. Most of the accidents occur during normal activity, not in sports.

not a strong argument for early treatment of all Class II problems (see Chapter 13), but with previous trauma and age younger than 9 years, the risk of additional trauma is 8.4 times higher than in children with no history of trauma.<sup>22</sup> For such a child, retracting the incisors (but not growth modification) is indicated. Extreme overbite, so that the lower incisors contact the palate, can cause significant tissue damage leading to early loss of the upper incisors and also can result in extreme wear of incisors. Both of these effects can be avoided by orthodontic treatment (see Chapter 18).

It certainly is possible that malocclusion could contribute to both dental decay and periodontal disease by making it harder to care for the teeth properly or by causing occlusal trauma. Multiple studies have indicated, however, that malocclusion has little if any impact on diseases of the teeth or supporting structures.<sup>23</sup> An individual's willingness and motivation determine oral hygiene much more than how well the teeth are aligned, and presence or absence of dental plaque is the major determinant of the health of both the hard and soft tissues of the mouth. If individuals with malocclusion are more prone to tooth decay, the effect is small compared with hygiene status. Occlusal trauma, once thought to be important in the development of periodontal disease, now is recognized to be a secondary, not a primary, etiologic factor. There is only a tenuous link between untreated malocclusion and major periodontal disease later in life.

Could orthodontic treatment itself be an etiologic agent for oral disease? Long-term studies have shown no indication that orthodontic treatment increased the chance of later periodontal problems.<sup>24</sup> The association between early orthodontic and later periodontal treatment appears to be only another manifestation of the phenomenon that one segment of the population seeks dental treatment while another avoids it. Those who have had one type of successful dental treatment, such as orthodontics in childhood, are more likely to seek another such as periodontal therapy in adult life.

In summary, it appears that both psychosocial and functional handicaps can produce significant need for orthodontic treatment. The evidence is less clear that orthodontic treatment reduces the development of later dental disease.

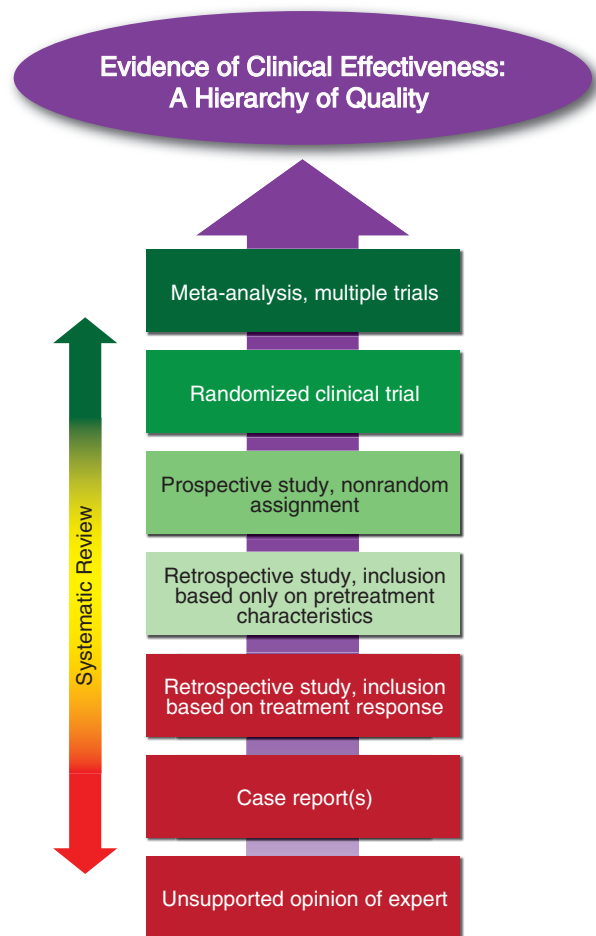
## Type of Treatment: Evidence-Based Selection

If treatment is needed, how do you decide what sort of treatment to use? The present trend in health care is strongly toward evidence-based treatment—that is, treatment procedures should be chosen on the basis of clear evidence that the selected method is the most successful approach to that particular patient's problem(s). The better the evidence, the easier the decision.

### Randomized Clinical Trials: The Best Evidence

Orthodontics traditionally has been a specialty in which the opinions of leaders were important, to the point that professional groups coalesced around a strong leader. Angle, Begg, and Tweed societies still exist, and new ones whose primary purpose is to promulgate their leaders' opinions are still being formed in the 21st century. As any professional group comes of age, however, there must be a focus on evidence-based rather than opinion-based decisions. That very much includes orthodontics.

As Fig. 1.19 illustrates, a hierarchy of quality exists in the evidence available to guide clinical decisions. It reflects, more



• Fig. 1.19 Evidence of clinical effectiveness: a hierarchy of quality.

than anything else, the probability that an accurate conclusion can be drawn from the group of patients who have been studied. The unsupported opinion of an expert is the weakest form of clinical evidence. Often, the expert opinion is supported by a series of cases that were selected retrospectively from practice records.

The problem with that, of course, is that the cases are likely to have been selected because they show the expected outcome. A clinician who becomes an advocate of a treatment method is naturally tempted to select illustrative cases that show the desired outcome, and if even he or she tries to be objective, it is difficult to avoid introducing bias. When outcomes vary, as they often do, picking the cases that came out the way they were supposed to and discarding the ones that didn't is a great way to make your point. Information based on selected cases, therefore, must be viewed with considerable reserve. One important way to control bias in reporting the outcomes of treatment is to be sure that *all* of the treated cases are included in the report.

If retrospective cases are used in a clinical study, it is much better to select them on the basis of their characteristics when treatment began, not on the outcome, and better yet to select the cases prospectively before treatment begins. Even then, it is quite possible to bias the sample so that the "right" patients are chosen. After experience with a treatment method, doctors tend to learn

subtle indications that a particular patient is or is not likely to respond well, although they may have difficulty verbalizing exactly what criteria they used. Identifying the criteria associated with success or failure is extremely important, and a biased sample makes that impossible.

For this reason, the gold standard for evaluating clinical procedures is the randomized clinical trial, in which patients are randomly assigned in advance to alternative treatment procedures. The great advantage of this method is that random assignment, if the sample is large enough, should result in a similar distribution of all variables between (or among) the groups. Even variables that were not recognized in advance should be controlled by this type of patient assignment—and in clinical work, important variables often are identified only after the treatment has been started or even completed. Clinical trials in orthodontics are referred to in some detail throughout this book.

An additional way to gain better data for treatment responses when multiple randomized clinical trials exist is the application of meta-analysis. This draws on recently developed statistical techniques to group the data from several studies of the same phenomenon. Orthodontic research is an excellent example of an area in which numerous small studies have been carried out toward similar ends, often with protocols that were at least somewhat similar but different enough to make comparisons difficult. Meta-analysis is no substitute for new data collected with precise protocols, and including poorly done studies in a meta-analysis carries the risk of confusing rather than clarifying the issue.<sup>25</sup> Nevertheless, applying meta-analysis to clinical questions has considerable potential to reduce uncertainty about the best treatment methods.

An important caveat for meta-analyses is that the emphasis on statistical significance should not lead to overlooking the difference between statistical and clinical significance. Statistical significance evaluates the chance that a difference in the data set would be due just to the random variation that affects any group of treatment responses; clinical significance evaluates whether a difference of this magnitude would have any practical effect on the provision of treatment. Not all statistical differences are clinically significant, and sometimes differences that do not reach statistical significance nevertheless may indicate a clinical advance.

Unfortunately, randomized trials and meta-analysis cannot be used in many situations for ethical or practical reasons. For instance, a randomized trial of extraction versus nonextraction orthodontic treatment would encounter ethical concerns, would be very difficult and expensive to organize and manage if ethical difficulties could be overcome, and would require following patients for many years to evaluate long-term outcomes.

## Retrospective Studies: Control Group Required

A second acceptable way to replace opinion with evidence is by careful retrospective study of treatment outcomes under well-defined conditions. The best way to know—often the only way to know—whether a treatment method really works is to compare treated patients with an untreated control group. For such a comparison to be valid, the two groups must be equivalent before treatment starts. Unless the pretreatment groups were statistically adjusted, you cannot with any confidence say that differences afterward were due to the treatment.

There are a number of difficulties in setting up control groups for orthodontic treatment. The principal ones are that the controls must be followed over a long period of time, equivalent to the

treatment time, and that sequential radiographs usually are required. Radiation exposure for untreated children is problematic. At present, it is very difficult to get permission to expose children to x-rays that will be of no benefit to them personally. This means the longitudinal growth studies in the mid-20th century that used a series of cephalometric radiographs of untreated children cannot be repeated now. In the absence of newer data, they still are being used to provide control data in studies involving growth modification—although it is well established that in the United States and almost all other countries, children now grow larger and mature more quickly than at the time of those studies (see Fig. 3.7). When historic controls are the best that are available, it is better to have them than nothing, but the limitations must be kept in mind. Growth magnitudes and timing, along with so much else, have changed in the last 50 years.

Systematic reviews of the literature, which look primarily at papers based on retrospective data, have received considerable emphasis in the last few years. A typical search for reports on the subject of the systematic review yields a large number of papers to be evaluated. Most are discarded because of obvious weaknesses in the methods, poor quality of the data, or insufficient data. The remaining papers are evaluated for statistical significance. The key step, of course, is discarding the poor papers and keeping the good ones, which inevitably requires judgment on the part of those conducting the review. Unfortunately, many recent systematic reviews conclude only that the data are not good enough to provide a definitive answer, and such reviews are not helpful to clinicians who have to do something even if it's wrong. Fortunately, experienced clinicians can perceive patterns in the data that provide insight into clinical significance, especially when the evidence allows comparing the pluses and minuses of different methods even though statistically significant differences were not demonstrated. The depiction of systematic reviews in Fig. 1.19 is meant to emphasize that caution is needed when they are evaluated.

A final important consideration is that what clinicians consider the important aspects of outcomes of treatment may or may not coincide with how patients perceive the outcome. In orthodontics, it is apparent that the appearance of the teeth on smile is a key outcome for patients. Fortunately, what the patients think now receives more attention than it did all the way through the 20th century, and data for the acceptable range of tooth display have become available recently.<sup>13</sup> Less fortunately, characteristics of the dental occlusion (e.g., the relationship of the dental midlines) that are not important to patients still are considered very important by some dentists when they evaluate the outcome of orthodontic treatment. Patient-centered treatment does not mean the patient is always right, but it does mean that the patient's point of view has to be kept in mind both when treatment is planned and when its success is evaluated.

The era of orthodontics as an opinion-driven specialty clearly is at an end. In the future, it will be evidence driven, which is all for the best. In the meantime, clinical decisions still must be made using the best information currently available. When the latest new method appears with someone's strong recommendation and a series of case reports in which it worked very well, it is wise to remember the aphorism "Enthusiastic reports tend to lack controls; well-controlled reports tend to lack enthusiasm."

In this and the subsequent chapters, recommendations for treatment are based insofar as possible on solid clinical evidence. When this is not available, the authors' current opinions are provided and labeled as such.



## Demand for Treatment

### Epidemiologic Estimates of Orthodontic Treatment Need

Psychosocial and facial considerations, not just the way the teeth fit, play a role in defining orthodontic treatment need. For this reason, it is difficult to determine who needs treatment and who does not just from an examination of dental casts or radiographs. Nevertheless, it seems reasonable that the severity of a malocclusion correlates with need for treatment, and as we will discuss in more detail here, there is good evidence to support that correlation. This assumption is necessary when treatment need is estimated for population groups.

Several indices for scoring how much the teeth deviate from the normal, as indicators of orthodontic treatment need, were proposed in the 1970s but not widely accepted for the screening of potential patients. There now are two major methods for scoring the severity of malocclusion: the peer assessment rating (PAR) system, developed in the United Kingdom, and the American Board of Orthodontics (ABO) discrepancy index, developed in the United States. It is important to keep in mind that these systems consider just the dentition, not skeletal or facial characteristics.

PAR scores are calculated from measurements of maxillary and mandibular anterior alignment (crowding and spacing), buccal segment occlusion (anteroposterior, transverse, and vertical), overjet or reverse overjet, overbite, and midline discrepancies, with use of a weighting scale for each characteristic.<sup>26</sup> ABO index scores are calculated similarly, with the difference primarily that it adds three cephalometric measurements.<sup>27</sup> Both systems were developed as a way to objectively determine the amount of improvement achieved during treatment but have been shown to correlate reasonably well with expert opinions of orthodontic treatment need.

The Index of Treatment Need (IOTN), developed by Brook and Shaw in the United Kingdom,<sup>28</sup> was designed to evaluate need for treatment. It places patients in five grades from “no need for treatment” to “treatment required” that correlate reasonably well with clinician’s judgments of need for treatment. The index has a dental health component derived from occlusion and alignment (Box 1.1 outlines the criteria and shows how the score is calculated) and an esthetic component derived from comparison of the dental appearance versus standard photographs (Fig. 1.20). There is a surprisingly good correlation between treatment need assessed by the dental health and esthetic components of IOTN (i.e., children selected as needing treatment based on one of the scales are also quite likely to be selected when the other scale is used).<sup>29</sup>

With some allowances for the effect of missing teeth, it is possible to calculate the percentages of U.S. children and youths who would fall into the various IOTN grades from the NHANES III data set.<sup>30</sup> Fig. 1.21 shows the percentage of youths age 12 to 17 in the three major racial or ethnic groups in the U.S. population estimated with IOTN to have mild, moderate, or severe treatment need and the percentage who had treatment at that time. As the graph shows, the number of white children who received treatment was considerably higher than the number of black or Hispanic children ( $P < .001$ ). Treatment almost always produces an improvement but may not totally eliminate all the characteristics of malocclusion, so the effect is to move some individuals from the severe to the mild treatment need categories. The higher proportion of severe malocclusion among blacks probably reflects more treatment in the white group, which moved them down the severity scale, rather than the presence of more severe malocclusion in the black population.

### • BOX 1.1 Index of Treatment Needs (IOTN) Treatment Grades

#### Grade 5 (Extreme/Need Treatment)

- 5.i Impeded eruption of teeth (except third molars) due to crowding, displacement, the presence of supernumerary teeth, retained deciduous teeth, and any pathologic cause.
- 5.h Extensive hypodontia with restorative implications (more than one tooth per quadrant) requiring preprosthetic orthodontics.
- 5.a Increased overjet greater than 9 mm.
- 5.m Reverse overjet greater than 3.5 mm with reported masticatory and speech difficulties.
- 5.p Defects of cleft lip and palate and other craniofacial anomalies.
- 5.s Submerged deciduous teeth.

#### Grade 4 (Severe/Need Treatment)

- 4.h Less extensive hypodontia requiring prerestorative orthodontics or orthodontic space closure (one tooth per quadrant).
- 4.a Increased overjet greater than 6 mm but less than or equal to 9 mm.
- 4.b Reverse overjet greater than 3.5 mm with no masticatory or speech difficulties.
- 4.m Reverse overjet greater than 1 mm but less than 3.5 mm with recorded masticatory or speech difficulties.
- 4.c Anterior or posterior crossbites with greater than 2 mm discrepancy between retruded contact position and intercuspal position.
- 4.l Posterior lingual crossbite with no functional occlusal contact in one or both buccal segments.
- 4.d Severe contact point displacements greater than 4 mm.
- 4.e Extreme lateral or anterior open bites greater than 4 mm.
- 4.f Increased and complete overbite with gingival or palatal trauma.
- 4.t Partially erupted teeth, tipped, and impacted against adjacent teeth.
- 4.x Presence of supernumerary teeth.

#### Grade 3 (Moderate/Borderline Need)

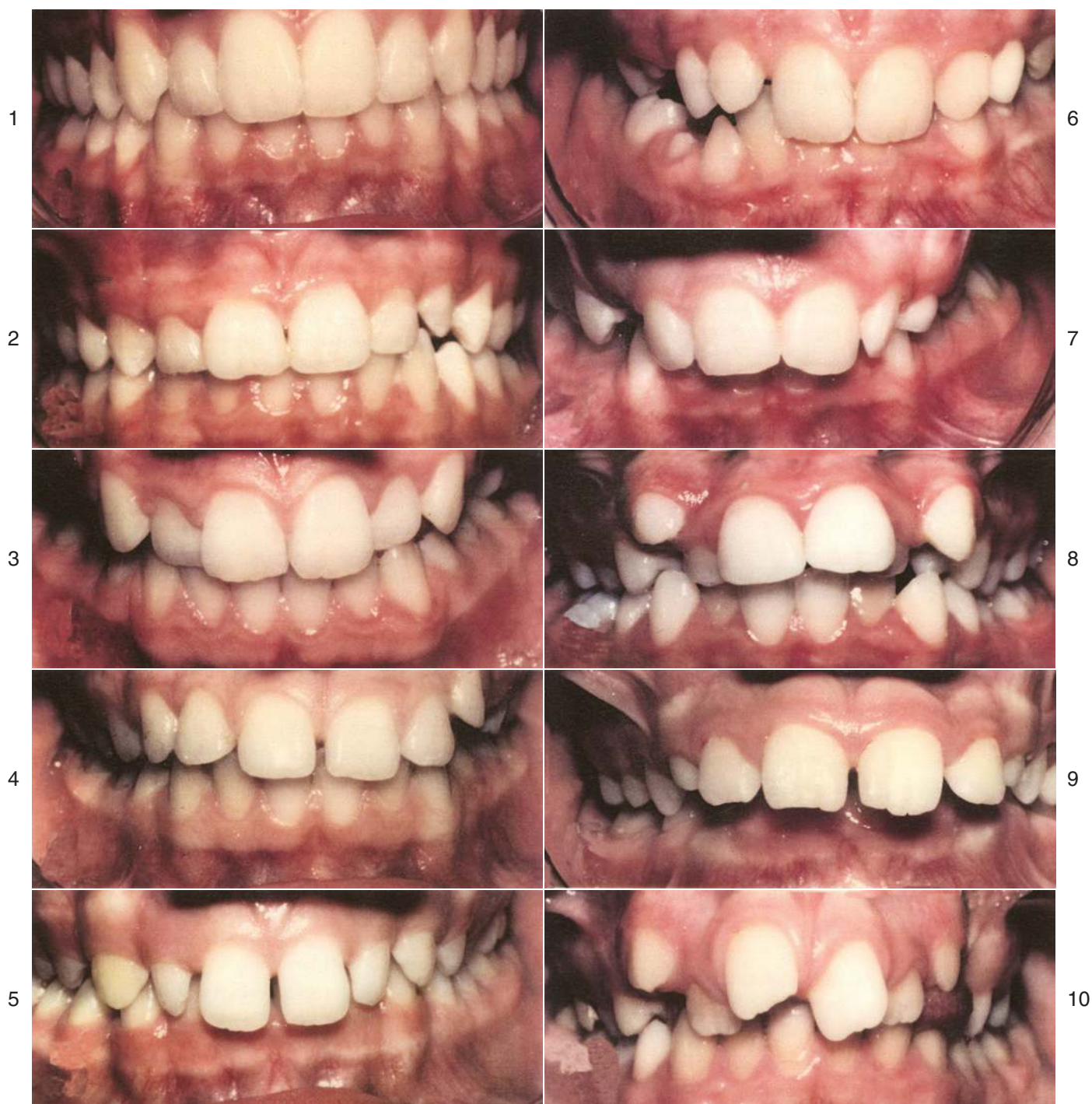- 3.a Increased overjet greater than 3.5 mm but less than or equal to 6 mm with incompetent lips.
- 3.b Reverse overjet greater than 1 mm but less than or equal to 3.5 mm.
- 3.c Anterior or posterior crossbites with greater than 1 mm but less than or equal to 2 mm discrepancy between retruded contact position and intercuspal position.
- 3.d Contact point displacements greater than 2 mm but less than or equal to 4 mm.
- 3.e Lateral or anterior open bite greater than 2 mm but less than or equal to 4 mm.
- 3.f Deep overbite complete on gingival or palatal tissues but no trauma.

#### Grade 2 (Mild/Little Need)

- 2.a Increased overjet greater than 3.5 mm but less than or equal to 6 mm with competent lips.
- 2.b Reverse overjet greater than 0 mm but less than or equal to 1 mm.
- 2.c Anterior or posterior crossbite with less than or equal to 1 mm discrepancy between retruded contact position and intercuspal position.
- 2.d Contact point displacements greater than 1 mm but less than or equal to 2 mm.
- 2.e Anterior or posterior open bite greater than 1 mm but less than or equal to 2 mm.
- 2.f Increased overbite greater than or equal to 3.5 mm without gingival contact.
- 2.g Prenatal or postnatal occlusions with no other anomalies.

#### Grade 1 (No Need)

- 1. Extremely minor malocclusions, including contact point displacements less than 1 mm.

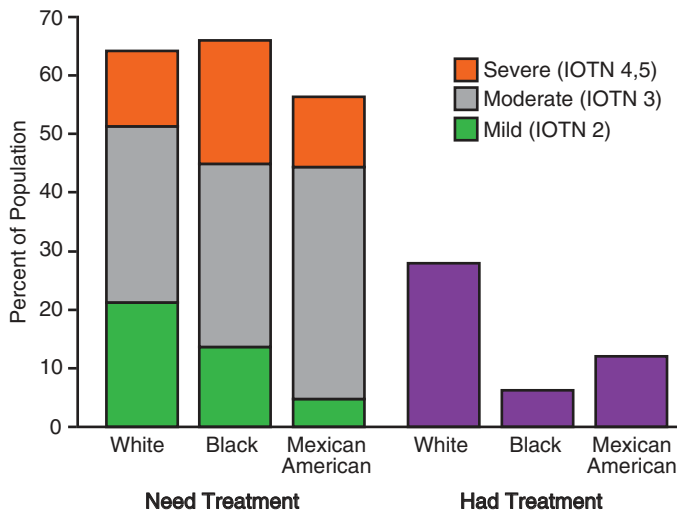


• **Fig. 1.20** The stimulus photographs of the Index of Treatment Need (IOTN) esthetic index. The score is derived from the patient's answer to "Here is a set of photographs showing a range of dental attractiveness. Number 1 is the most attractive and number 10 the least attractive arrangement. Where would you put your teeth on this scale?" Grades 8 to 10 indicate definite need for orthodontic treatment; 5 to 7, moderate or borderline need; 1 to 4, no or slight need.

How do the IOTN scores compare with what parents and dentists think relative to orthodontic treatment need? The existing (rather weak) data suggest that in typical American neighborhoods, about 35% of adolescents are perceived by parents and peers as needing orthodontic treatment. Note that this is larger than the number of children who would be placed in IOTN grades 4 and

5 as having severe problems definitely needing treatment, but smaller than the total of grades 3, 4, and 5 for moderate and severe problems.

Dentists usually judge that only about one-third of their patients have normal occlusion, and they suggest treatment for about 55% (thereby putting about 10% in a category of malocclusion with



• **Fig. 1.21** Orthodontic need by severity of the problem for white, black, and Mexican-American youths age 12 to 17 in the United States, 1989 to 1994, and the percentage of each group who reported receiving previous orthodontic treatment. The greater number of whites who received treatment probably accounts for the smaller number of severe problems in the white population.

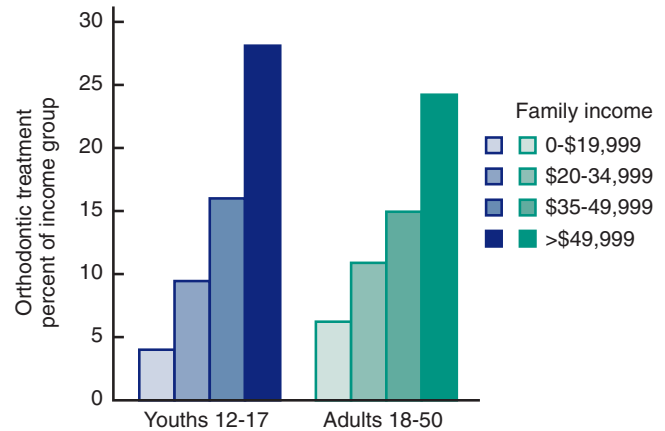
little need for treatment). It appears that they include all the children in IOTN grade 3 and some of those in grade 2 in the group who would benefit from orthodontics. Presumably, facial appearance and psychosocial considerations are used in addition to dental characteristics when parents judge treatment need or dentists decide to recommend treatment.

### Who Seeks Treatment?

Demand for treatment is indicated by the number of patients who actually make appointments and seek care. Not all patients with malocclusion, even those with extreme deviations from the norm, seek orthodontic treatment. Some do not recognize that they have a problem; others feel that they need treatment but cannot afford it or cannot obtain it.

Both the perceived need and demand vary with social and cultural conditions. More children in urban areas are thought (by parents and peers) to need treatment than children in rural areas. Family income is a major determinant of how many children receive treatment (Fig. 1.22). This appears to reflect two things: not only that higher income families can more easily afford orthodontic treatment, but also that good facial appearance and avoidance of disfiguring dental conditions are associated with more prestigious social positions and occupations. The higher the aspirations for a child, the more likely the parents are to seek orthodontic treatment for him or her.

Why do they seek treatment for their children? We have already noted that psychosocial handicaps are the major reason. Another way to put this issue is “Does having a less than ideal smile affect the way people act and live?” This question was examined by the American Dental Association’s Health Policy Institute in 2015.<sup>31</sup> An online survey was conducted by the Harris Poll, and nearly 15,000 responses from a randomly selected group of individuals age 18 and older were analyzed. The study group was evaluated as a whole, by economic status (low, middle, and high household



• **Fig. 1.22** The percentage of the U.S. population, 1989 to 1994, who received orthodontic treatment, as a function of family income. Although severe malocclusion is recognized as an important problem and all states offer at least some coverage to low-income children through their Medicaid programs, this funds treatment for a very small percentage of the population. Nevertheless, nearly 5% of the lowest income group and 10% to 15% of intermediate income groups reported some orthodontic treatment. This reflects the importance given to orthodontic treatment—it is sought even when it stretches financial resources in less-affluent families.

income), and by age (18 to 34, 35 to 49, 50 to 64, and 65 or older). This national data set tells an interesting story related to dental esthetics. Twenty-nine percent of low-income adults and 28% of young adults (18 to 34) believed the appearance of their mouth and teeth affected their ability to interview for a job. That is over one-fourth of these groups. Twenty-five percent of all adults said they avoid smiling, 23% feel embarrassed, and 20% experience anxiety because of the condition of their mouth and teeth. But low-income and young adults felt the greatest impact, with a minimum of 30% in each of these two groups indicating that they experienced a problem related to the appearance of their teeth very often or occasionally. Finally, 82% of all responders agreed with the statement “It is easier to get ahead in life if I have straight, bright teeth.”

So, although the need for treatment and its assessments and benefits are usually determined with carefully quantified dental morphologic and degrees of craniofacial deformity, poor dental esthetics is enough to clearly impair people. Often, we lose track of that simple truth by trying to justify orthodontic treatment at a higher and seemingly more significant level. In fact, people value straight teeth because it makes their lives easier and better.

Because it is widely recognized now that severe malocclusion can affect an individual’s entire life, every U.S. state now provides at least some orthodontic treatment for low-income families through its Medicaid program. Nevertheless, Medicaid and related programs support only a tiny fraction of the population’s orthodontic care. From that perspective, it is interesting that even in the lowest income group, almost 5% of youths and over 5% of adults report having received treatment; 10% to 15% at intermediate income levels have received treatment. This indicates the importance placed on orthodontic treatment by families who judge that it is a factor in social and career progress for their children.

The effect of financial constraints on demand can be seen most clearly by the response to third-party payment plans. When third-party copayment is available, the number of individuals seeking



orthodontic treatment rises considerably, but even when all costs are covered, some individuals for whom treatment is recommended do not accept it. It seems likely that under optimal economic conditions, demand for orthodontic treatment will at least reach the 35% level thought by the public to need treatment. In higher socioeconomic areas in the United States, 35% to more than 50% of children and youths now are receiving orthodontic care. In Switzerland, where high average incomes and supplemental social programs mean that essentially all citizens who want treatment can get it, 56% of the 2012 population aged 15 to 24 years were receiving or had received orthodontic treatment.<sup>32</sup> Acceptance of treatment is at similar levels in the Scandinavian countries for the same reasons.

Orthodontic treatment for adults was rare until the latter half of the 20th century. In the 1960s, only 5% of all orthodontic patients in the United States were adults (age 19 or older). By 1990, about 25% of all orthodontic patients were adults (18 or older) (Fig. 1.23). It is interesting to note that the absolute number of adults seeking orthodontic treatment remained constant for the next decade while the number of younger patients grew, so by 2000 the proportion of adults in the orthodontic patient population had dropped to about 20%. By 2010 it had increased again to over 25% of the total, and the most recent survey by the American Association of Orthodontists (2014) indicated a further increase to about 27%. In 2014 the average American orthodontist was treating 125 adult patients. In 1989, the earliest year in which that figure was recorded, it was 41.

Many adult patients indicate that they wanted treatment earlier but did not receive it, often because their families could not afford it; now they can. Wearing braces as an adult is more socially acceptable than it was previously, although no one really knows

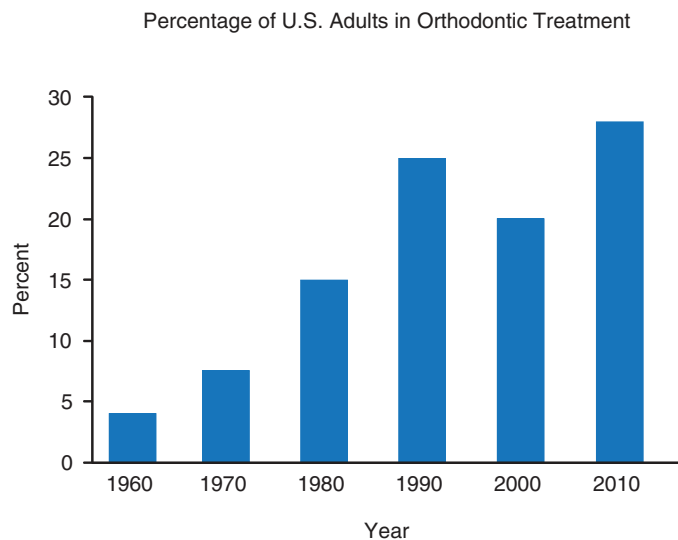
why, and this too has made it easier for adults to seek treatment. Recently, an increased number of older adults (40 and over) have sought orthodontics, usually in conjunction with other treatment, to save their teeth, and the majority of that oldest subgroup were male (every other age group from childhood on has more females). As the population ages, these older adults are likely to be the fastest growing group who seek orthodontic treatment.

Many of the children and adults who seek orthodontic treatment today have dentofacial conditions that are within the normal range of variation, at least by definitions that focus tightly on obvious degrees of handicap. Does that mean treatment is not indicated for those with lesser problems? Today, medical and dental interventions that are intended to make the individual either “better than well” or “beyond normal” are called *enhancements*. Typical medical and surgical enhancements are drugs to treat erectile dysfunction, face lifts, and hair transplants. In dentistry, a good example of enhancement is tooth bleaching.

In this context, orthodontics often can be considered an enhancement technology. It is increasingly accepted that appropriate care for individuals often should include enhancement to maximize their quality of life. If you really want it because you are convinced you need it, perhaps you really do need it—whether it is orthodontics or many other types of treatment. Medicaid and Medicare and many insurance companies now have accepted the reality that at least some enhancement procedures have to be accepted as reimbursable medical expenses. Similarly, when orthodontic benefits are included in insurance coverage, the need for treatment is no longer judged just by the severity of the malocclusion. The bottom line: Enhancement is appropriate dental and orthodontic treatment, just as it is in other contexts.

A key question, of course, is “Does orthodontic treatment really increase quality of life and self-esteem?” A number of studies have documented improvement in quality-of-life scores and self-esteem in children and adolescents,<sup>33</sup> and reports have shown quality-of-life effects after orthodontic treatment in children of African, European, and Asian descent.<sup>34-36</sup> Multiple studies have shown that this is true for adults as well, and the range of improvements in quality of life extend further than one might have thought. For instance, a Brazilian study showed that adults with ideal smiles are considered to be more intelligent and have a greater chance of finding a job,<sup>37</sup> and a systematic review documented patient satisfaction after orthodontic treatment combined with orthognathic surgery.<sup>38</sup> The data can be summarized succinctly: If your dental and facial appearance differs significantly from that of your group, you benefit socially from correcting this.

Orthodontics has become a more prominent part of dentistry in recent years, and this trend is likely to continue. The vast majority of individuals who had orthodontic treatment feel that they benefited from the treatment and are pleased with the result. Not all patients have dramatic changes in dental and facial appearance, but nearly all recognize an improvement in both dental condition and psychological well-being.



• **Fig. 1.23** From the mid-20th century, when almost no adults received orthodontic treatment, to the 1990s, there was an almost steady rise in the number of adult patients. In the 1980s, a “baby bust” period, the increasing number of adult patients was the major source of the overall increase in orthodontics, whereas in the 1990s, a “baby boom” period, the number of adult patients increased a little but most of the growth involved treatment of children, so the adult percentage declined. There was a further increase in the number of adults in treatment and their percentage of the total patient population in the first decade of the 21st century, bringing the percentage back to 25% to 30%.

## References

1. Corruccini RS, Paciani E. “Orthodontistry” and dental occlusion in Etruscans. *Angle Orthod.* 1989;59:61–64.
2. Kingsley NW. *Treatise on Oral Deformities as a Branch of Mechanical Surgery*. New York: Appleton; 1880.
3. Angle EH. Treatment of malocclusion of the teeth and fractures of the maxillae. In: *Angle's System*. 6th ed. Philadelphia: SS White Dental Mfg Co; 1900.



4. Sarver DM. Interactions of hard tissues, soft tissues, and growth over time, and their impact on orthodontic diagnosis and treatment planning. *Am J Orthod Dentofacial Orthop.* 2015;148:380–386.
5. Kelly JE, Sanchez M, Van Kirk LE. *An Assessment of the Occlusion of Teeth of Children.* Washington, DC: National Center for Health Statistics; 1973. DHEW Publication No. (HRA) 74-1612.
6. Kelly J, Harvey C. *An Assessment of the Teeth of Youths 12-17 Years.* Washington, DC: National Center for Health Statistics; 1977. DHEW Pub No. (HRA) 77-1644.
7. Brunelle JA, Bhat M, Lipton JA. Prevalence and distribution of selected occlusal characteristics in the US population, 1988-91. *J Dent Res.* 1996;75:706–713.
8. Baume LJ. Uniform methods for the epidemiologic assessment of malocclusion: results obtained with the World Health Organization standard methods (1962 and 1971) in South Pacific populations. *Am J Orthod.* 1974;66:251–272.
9. Brown T, Abbott AA, Burgess VB. Longitudinal study of dental arch relationships in Australian aboriginals with reference to alternate intercuspation. *Am J Phys Anthropol.* 1987;72:49–57.
10. Corruccini RS. Anthropological aspects of orofacial and occlusal variations and anomalies. In: Kelly MA, Larsen CS, eds. *Advances in Dental Anthropology.* New York: Wiley-Liss; 1991.
11. Wrangham R. *Catching Fire: How Cooking Made Us Human.* New York: Basic Books; 2009.
12. Shaw WC, Rees G, Dawe M, et al. The influence of dentofacial appearance on the social attractiveness of young adults. *Am J Orthod.* 1985;87:21–26.
13. Perrini S, Rossini G, Castorflorio T, et al. Laypeople's perceptions of frontal smile esthetics: a systematic review. *Am J Orthod Dentofacial Orthop.* 2016;150:740–750.
14. Dimberg L, Arnrup K, Bondemark L. The impact of malocclusion on the quality of life among children and adolescents: a systematic review of quantitative studies. *Eur J Orthod.* 2015;37:238–247.
15. Meyer-Marcotty P, Gerdes AB, Reuther T, et al. Persons with cleft lip and palate are looked at differently. *J Dent Res.* 2010;89:400–404.
16. Macgregor FC. Social and psychological implications of dentofacial disfigurement. *Angle Orthod.* 1979;40:231–233.
17. Lin F, Ren M, Yao L, et al. Psychosocial impact of dental esthetics regulates motivation to seek orthodontic treatment. *Am J Orthod Dentofacial Orthop.* 2016;150:476–482.
18. Gavric A, Mirceta D, Jakobovic M, et al. Craniodentofacial characteristics, dental esthetics-related quality of life, and self-esteem. *Am J Orthod Dentofacial Orthop.* 2015;147:711–718.
19. Macfarlane TV, Kenealy P, Kingdon HA, et al. Twenty-year cohort study of health gain from orthodontic treatment: temporomandibular disorders. *Am J Orthod Dentofacial Orthop.* 2009;192:e1–e8.
20. Thiruvengkatachari B, Harrison J, Worthington H, O'Brien K. Early orthodontic treatment for Class II malocclusion reduces the chance of incisal trauma: results of a Cochrane systematic review. *Am J Orthod Dentofacial Orthop.* 2015;148:47–59.
21. Koroluk LD, Tulloch JFC, Phillips C. Incisor trauma and early treatment for Class II division 1 malocclusion. *Am J Orthod Dentofacial Orthop.* 2003;123:117–125.
22. Glendor U, Kouchekei B, Halling A. Risk evaluation and type of treatment of multiple dental trauma episodes to permanent teeth. *Endod Dent Traumatol.* 2000;16:205–210.
23. Bollen AM, Cunha-Cruz J, Bakko DW, et al. The effects of orthodontic therapy on periodontal health: a systematic review of controlled evidence. *Am J Orthod Dentofacial Orthop.* 2008;135:413–422.
24. Jonsson T, Karlsson KO, Ragnarsson B, et al. Long-term development of malocclusion traits in orthodontically treated and untreated subjects. *Am J Orthod Dentofacial Orthop.* 2010;137:277–284.
25. Papageorgiou SN. Meta-analysis for orthodontists: part II—Is all that glitters gold? *J Orthod.* 2014;41:327–336.
26. Firestone AR, Beck FM, Beglin FM, Vig KWL. Evaluation of the peer assessment rating (PAR) index as an index of orthodontic treatment need. *Am J Orthod Dentofacial Orthop.* 2002;122:463–469.
27. Cangialosi TJ, Riolo ML, Owens SA Jr, et al. The ABO discrepancy index: a measure of case complexity. *Am J Orthod Dentofacial Orthop.* 2004;125:270–278.
28. Brook PH, Shaw WC. The development of an index for orthodontic treatment priority. *Eur J Orthod.* 1989;11:309–332.
29. Richmond S, Shaw WC, O'Brien KD, et al. The relationship between the Index of Treatment Need and the consensus opinion of a panel of 74 dentists. *Brit Dent J.* 1995;178:370–374.
30. Proffit WR, Fields HW, Moray LJ. Prevalence of malocclusion and orthodontic treatment need in the United States: estimates from the NHANES III survey. *Int J Adult Orthodon Orthognath Surg.* 1998;13:97–106.
31. American Dental Association, Health Policy Institute. Oral health and well-being in the United States. Available at <https://www.ada.org/en/science-research/health-policy-institute/oral-health-and-well-being>. Accessed July 15, 2016.
32. Stadelmann P, Zemp E, Weiss C, et al. Dental visits, oral hygiene behaviour, and orthodontic treatment in Switzerland. *Schweiz Monatsschr Zahnmed.* 2012;122:104–126.
33. Liu Z, McGrath C, Haag U. The impact of malocclusion/orthodontic treatment need on the quality of life: a systematic review. *Angle Orthod.* 2009;79:585–591.
34. Isiekwe GI, Sofola OO, Olanrewaju O, et al. Dental esthetics and oral health-related quality of life in young adults. *Am J Orthod Dentofacial Orthop.* 2016;150:627–636.
35. Gavric A, Mirceta D, Jakobovic M, et al. Craniofacial characteristics, dental esthetics-related quality of life, and self-esteem. *Am J Orthod Dentofacial Orthop.* 2015;147:711–718.
36. Choi SH, Kim JS, Cha JY, Hwang CJ. Effect of malocclusion severity on oral health-related quality of life and food intake ability in a Korean population. *Am J Orthod Dentofacial Orthop.* 2016;149:384–390.
37. Pithon MM, Nascimento CC, Barbosa GC, Coqueiro RD. Do dental esthetics have any influence on finding a job? *Am J Orthod Dentofacial Orthop.* 2014;146:423–429.
38. Pacheco-Pereira C, Abreu LG, Dick BD, et al. Patient satisfaction after orthodontic treatment combined with orthognathic surgery: a systematic review. *Angle Orthod.* 2016;86:495–508.

# 2

## Concepts of Growth and Development

### CHAPTER OUTLINE

#### Growth: Pattern, Variability, and Timing

##### Methods for Studying Physical Growth

- Measurement Approaches
- Experimental Approaches
- Genetic Influences on Growth

##### The Nature of Skeletal Growth

##### Sites and Types of Growth in the Craniofacial Complex

- Cranial Vault
- Cranial Base
- Maxilla (Nasomaxillary Complex)
- Mandible
- Facial Soft Tissues

##### Theories of Growth Control

- Level of Growth Control: Sites Versus Centers of Growth
- Cartilage as a Determinant of Craniofacial Growth
- Functional Matrix Theory of Growth

##### Social and Behavioral Development

- Learning and the Development of Behavior
- Stages of Emotional and Cognitive Development

A thorough background in craniofacial growth and development is necessary for every dentist. Even for those who never work with children, it is difficult to comprehend conditions observed in adults without understanding the developmental processes that produced these problems. For those who do interact professionally with children—and almost every dentist does so at least occasionally—it is important to distinguish normal variation from the effects of abnormal or pathologic processes. Because dentists and orthodontists are heavily involved in the development of not just the dentition but the entire dentofacial complex, a conscientious practitioner may be able to manipulate facial growth for the benefit of the patient. Obviously, it is not possible to do so without a thorough understanding of both the pattern of normal growth and the mechanisms that underlie it.

The very terms *growth* and *development* can cause difficulties in understanding. Growth and development, although closely related, are not synonymous. In conversational English, *growth* usually refers to an increase in size but tends to be linked more to change than anything else. Only if growth meant change, after all, could someone seriously speak of a period of economic recession as one of “negative economic growth.” Some tissues grow rapidly

and then shrink or disappear, so a plot of physical growth versus time may include a negative phase. On the other hand, if *growth* is defined solely as a process of change, the term becomes almost meaningless. In this chapter, the term *growth* usually refers to an increase in size or number. Occasionally, however, the increase will be in neither size nor number, but in complexity.

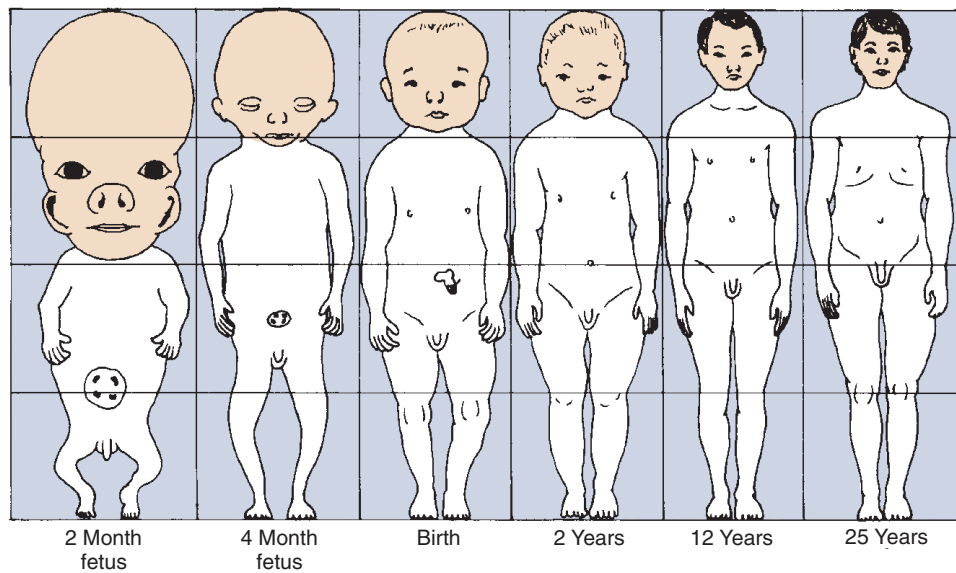
As a general term, *development* connotes an increasing degree of organization, often with unfortunate consequences for the natural environment. With reference to growth, the term *development* is used almost always to refer to an increase in complexity, and it is used in that way in this chapter. Development carries an overtone of increasing specialization, so that one price of increased development is a loss of potential. Growth is largely an anatomic phenomenon, whereas development is physiologic and behavioral.

It should be kept in mind that although dentists work with the physical features of the teeth and face, a major reason for orthodontic treatment is its psychosocial effects. Furthermore, patient cooperation is necessary, and eliciting it in children of different ages requires a knowledge of social and behavioral development. Both physiologic and psychosocial development are important subjects for this chapter. For convenience, not because they are innately more important, physical growth concepts are presented first, and then developmental factors are reviewed.

### Growth: Pattern, Variability, and Timing

In studies of growth and development, the concept of pattern is an important one. In a general sense, pattern (as in the pattern from which articles of clothing of different sizes are cut) reflects proportionality, usually of a complex set of proportions rather than just a single proportional relationship. Pattern in growth also represents proportionality, but in a still more complex way, because it refers not just to a set of proportional relationships at a point in time, but to the change in these proportional relationships over time. In other words, the physical arrangement of the body at any one time is a pattern of spatially proportioned parts. But there is a higher level pattern, the pattern of growth, which refers to the changes in these spatial proportions over time.

Fig. 2.1 illustrates the change in overall body proportions that occurs during normal growth and development. In fetal life, at about the third month of intrauterine development, the head takes up almost 50% of the total body length. At this stage, the cranium is large relative to the face and represents more than half the total head. In contrast, the limbs are still rudimentary and the trunk is underdeveloped. By the time of birth, the trunk and limbs have grown faster than the head and face, so that the proportion of the entire body devoted to the head has decreased to about 30%. The overall pattern of growth thereafter follows this course, with a progressive reduction of the relative size of the head to about 12%



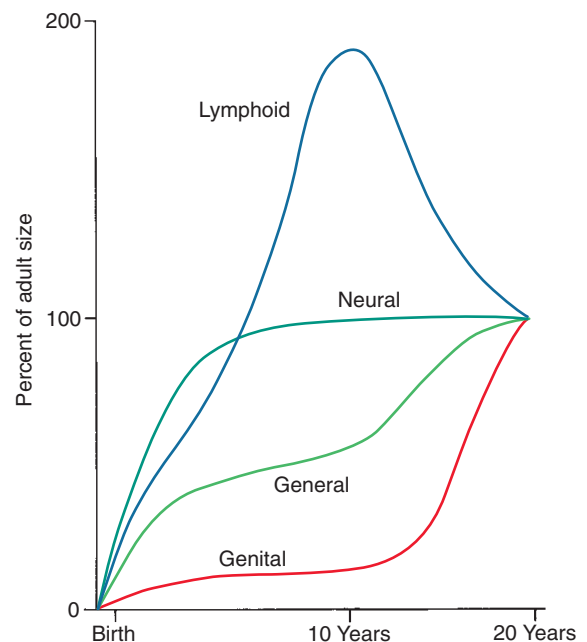
• **Fig. 2.1** Schematic representation of the changes in overall body proportions during normal growth and development. After the third month of fetal life, the proportion of total body size contributed by the head and face steadily declines. (Redrawn from Robbins WJ, et al. *Growth*. New Haven: Yale University Press; 1928.)

in the adult. At birth the legs represent about one-third of the total body length, whereas in the adult they represent about half. As Fig. 2.1 illustrates, there is more growth of the lower limbs than the upper limbs during postnatal life. All of these changes, which are a part of the normal growth pattern, reflect the “cephalo-caudal gradient of growth.” This simply means that there is an axis of increased growth extending from the head toward the feet.

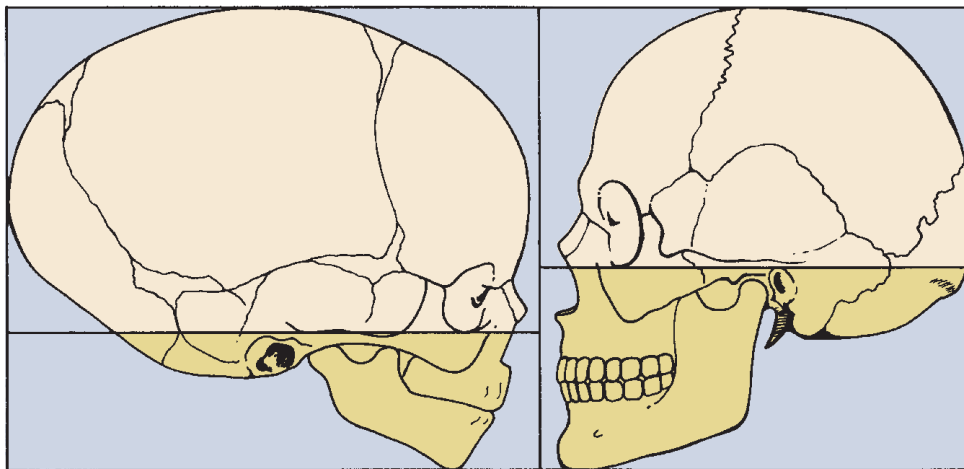
Another aspect of the normal growth pattern is that not all the tissue systems of the body grow at the same rate (Fig. 2.2). Obviously, as the relative decrease of head size after birth shows, the muscular and skeletal elements grow faster than the brain and central nervous system. The overall pattern of growth is a reflection of the growth of the various tissues making up the whole organism. To put it differently, one reason for gradients of growth is that different tissue systems that grow at different rates are concentrated in various parts of the body.

Even within the head and face, the cephalocaudal growth gradient strongly affects proportions and leads to changes in proportion with growth (Fig. 2.3). When the skull of a newborn infant is compared proportionally with that of an adult, it is easy to see that the infant has a relatively much larger cranium and a much smaller face. This change is an important aspect of the pattern of facial growth. Not only is there a cephalocaudal gradient of growth within the body, there also is one within the face. From that perspective, it is not surprising that the mandible, being farther away from the brain, tends to grow more and later than the maxilla, which is closer.

An important aspect of pattern is its predictability. Patterns repeat, whether in the organization of different-colored tiles in the design of a floor or in skeletal proportions changing over time. The proportional relationships within a pattern can be specified mathematically, and the only difference between a growth pattern and a geometric one is the addition of a time dimension. Thinking about pattern in this way allows one to be more precise in defining



• **Fig. 2.2** Scammon's curves for growth of the four major tissue systems of the body. As the graph indicates, growth of the neural tissues is nearly complete by 6 or 7 years of age. General body tissues, including muscle, bone, and viscera, show an S-shaped curve, with a definite slowing of the rate of growth during childhood and an acceleration at puberty. Lymphoid tissues proliferate far beyond the adult amount in late childhood and then undergo involution at the same time that growth of the genital tissues accelerates rapidly. (From Scammon RD. *The measurement of the body in childhood*. In: Harris JA, ed. *The Measurement of Man*. Minneapolis: University of Minnesota Press; 1930.)



• **Fig. 2.3** Changes in proportions of the head and face during growth. At birth, the face and jaws are relatively underdeveloped compared with their extent in the adult. As a result, there is much more growth of facial than cranial structures postnatally. (Redrawn from Lowery GH. *Growth and Development of Children*. 6th ed. Chicago: Year Book Medical Publishers; 1973.)

what constitutes a change in pattern. Change, clearly, would denote an alteration in the predictable pattern of mathematical relationships. A change in growth pattern would indicate some alteration in the expected changes in body proportions.

A second important concept in the study of growth and development is variability. Obviously, all people are not alike in the way that they grow, as in everything else. It can be difficult but clinically very important to decide whether an individual is merely at the extreme of the normal variation or falls outside the normal range.

Rather than categorizing growth as normal or abnormal, it is more useful to think in terms of deviations from the usual pattern and to express variability quantitatively. One way to do this is to evaluate a given child relative to peers on a standard growth chart (Fig. 2.4). Although charts of this type are commonly used for height and weight, the growth of any part of the body can be plotted in this way. The “normal variability,” as derived from large-scale studies of groups of children, is shown by the solid lines on the graphs. An individual who stood exactly at the midpoint of the normal distribution would fall along the 50% line of the graph. One who was larger than 90% of the population would plot above the 90% line; one who was smaller than 90% of the population would plot below the 10% line.

These charts can be used in two ways to determine whether growth is normal or abnormal. First, the location of an individual relative to the group can be established. A general guideline is that a child who falls outside the range of 97% of the population should receive special study before being accepted as just an extreme of the normal population. Second and perhaps more important, growth charts can be used to follow a child over time to evaluate whether there is an unexpected change in growth pattern. Pattern implies predictability. For the growth charts, this means that a child’s growth should plot along the same percentile line at all ages. If the percentile position of an individual relative to his or her peer group changes, especially if there is a marked change (see Fig. 2.4B), the clinician should suspect some growth abnormality and should investigate further. Inevitably, there is a gray area at the extremes of normal variations, at which it is difficult to determine if growth is normal.

A final major concept in physical growth and development is timing. Variability in growth arises in several ways: from normal variation, from influences outside the normal experience (e.g., serious illness), and from timing effects. Variation in timing arises because the same event happens for different individuals at different times—or, viewed differently, the biologic clocks of different individuals are set differently.

Variations in growth and development because of timing are particularly evident in human adolescence. Some children grow rapidly and mature early, completing their growth quickly and thereby appearing on the high side of developmental charts until their growth ceases and their contemporaries begin to catch up. Others grow and develop slowly and so appear to be behind, even though, given time, they will catch up with and even surpass children who once were larger. All children undergo a spurt of growth at adolescence, which can be seen more clearly by plotting change in height or weight (Fig. 2.5), but the growth spurt occurs at different times in different individuals.

Growth effects because of timing variation can be seen particularly clearly in girls, in whom the onset of menstruation (menarche) gives an excellent indicator of the arrival of sexual maturity. Sexual maturation is accompanied by a spurt in growth. When the growth velocity curves for early-, average-, and late-maturing girls are compared in Fig. 2.6, the marked differences in size among these girls during growth are apparent. At age 11, the early-maturing girl is already past the peak of her adolescent growth spurt, whereas the late-maturing girl has not even begun to grow rapidly. This sort of timing variation occurs in many aspects of both growth and development and can be an important contributor to variability.

Although age is usually measured chronologically as the amount of time since birth or conception, it is also possible to measure age biologically, in terms of progress toward various developmental markers or stages. Timing variability can be reduced by using developmental age rather than chronologic age as an expression of an individual’s growth status. For instance, if data for gain in height for girls are replotted, using menarche as a reference time point (Fig. 2.7), it is apparent that girls who mature early, at an average time, or late really follow a very similar growth pattern. This graph substitutes stage of sexual development for chronologic





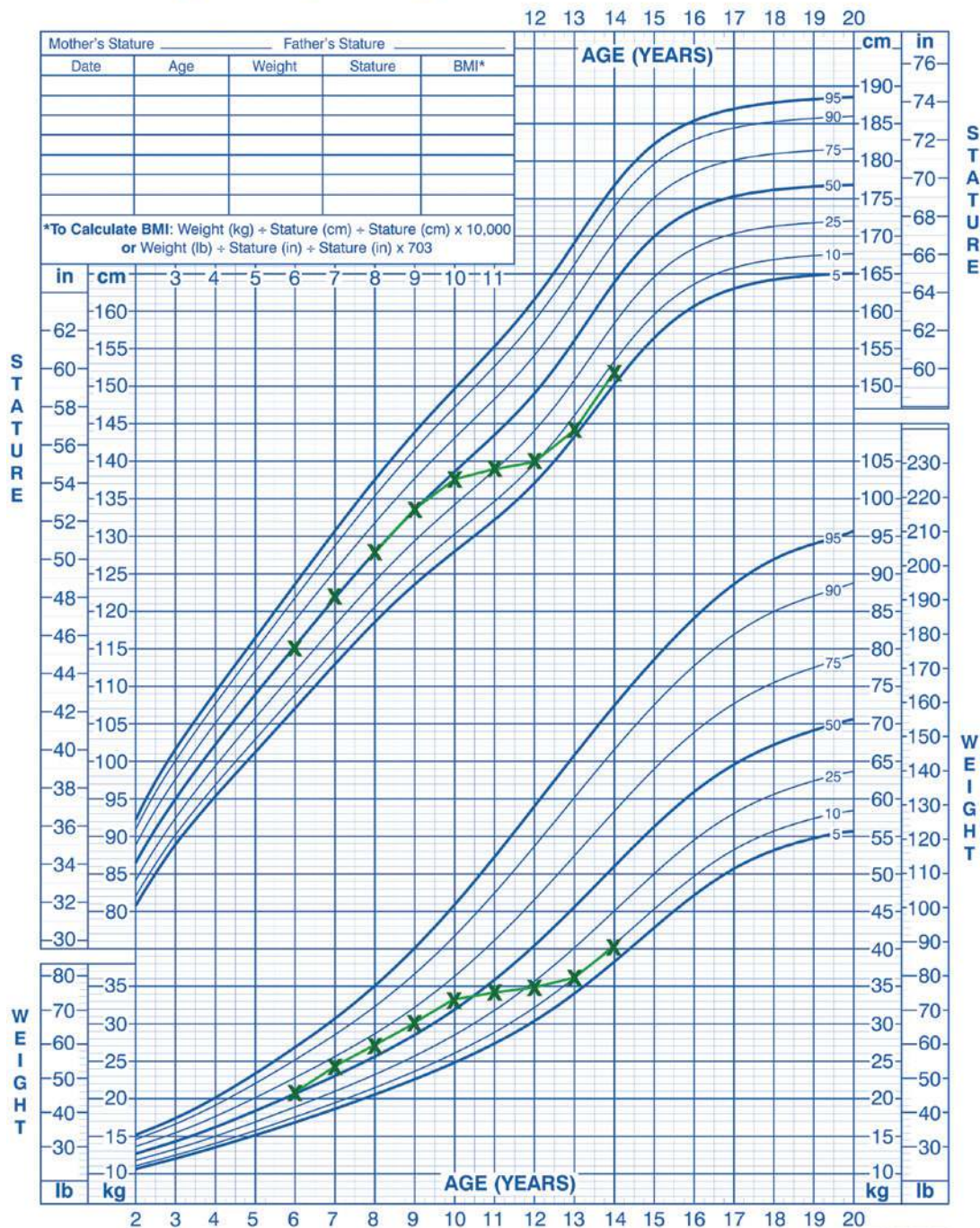


## 2 to 20 years: Boys

### Stature-for-age and Weight-for-age percentiles

NAME \_\_\_\_\_

RECORD # \_\_\_\_\_

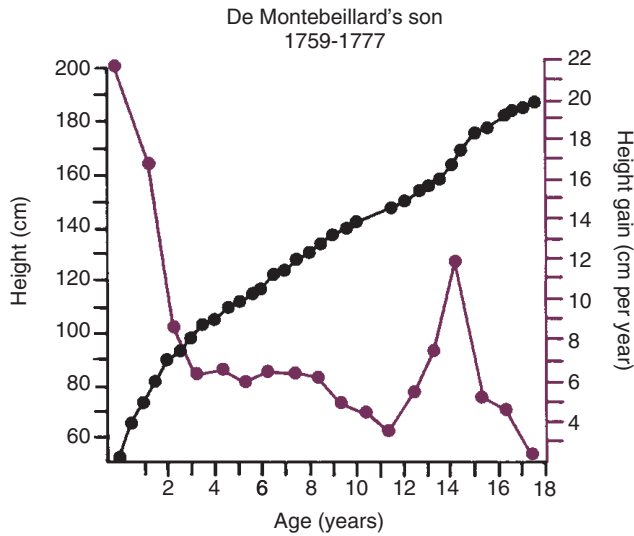


Published May 30, 2000 (modified 11/21/00).  
 SOURCE: Developed by the National Center for Health Statistics in collaboration with  
 the National Center for Chronic Disease Prevention and Health Promotion (2000).  
<http://www.cdc.gov/growthcharts>

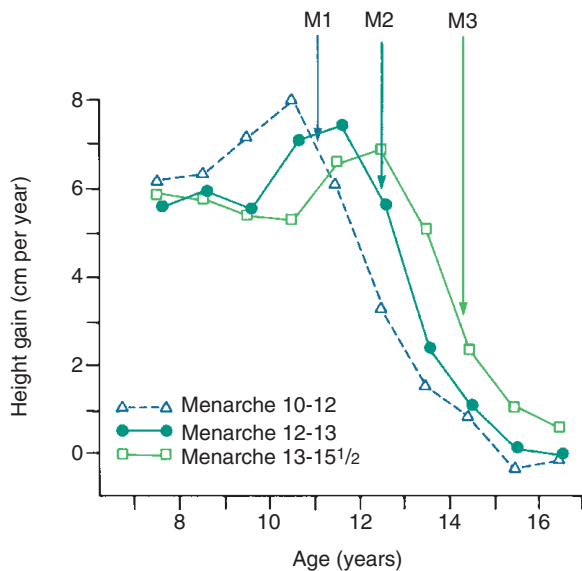
B

• **Fig. 2.4, cont'd** (B) Growth of a boy who developed a medical problem that affected growth, plotted on the male chart. Note the change in pattern (crossover of lines on the chart) between ages 10 and 11. This reflects the impact of serious illness beginning at that time, with partial recovery after age 13 but a continuing effect on growth. (Data from Hamill PV, et al. National Center for Health Statistics, 1979; charts developed by the National Center for Health Statistics in collaboration with the National Center for Chronic Disease Prevention and Health Promotion, published May 30, 2000, revised November 21, 2000.) (Charts available from <http://www.cdc.gov/growthcharts/>.)



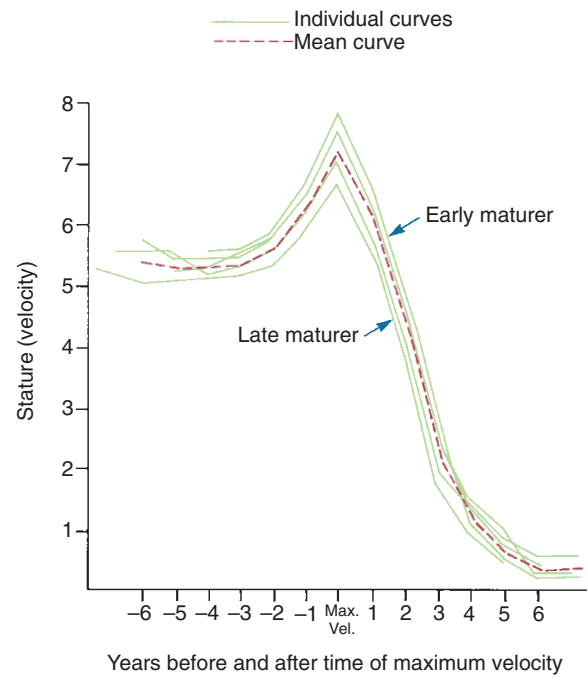


• **Fig. 2.5** Growth can be plotted in either height or weight at any age (*black line*) or the amount of change in any given interval (*maroon line*, showing the same data as the *black line*). A curve like the *black line* is called a *distance curve*, whereas the *maroon line* is a *velocity curve*. Plotting velocity rather than distance makes it easier to see when accelerations and decelerations in the rate of growth occurred. These data are for the growth of one individual, the son of a French aristocrat in the late 18th century, whose growth followed the typical pattern. Note the acceleration of growth at adolescence, which occurred for this individual at about age 14. (Data from Scammon RE. *Am J Phys Anthropol.* 1927.)



• **Fig. 2.6** Growth velocity curves for early-, average-, and late-maturing girls. It is interesting to note that the earlier the adolescent growth spurt occurs, the more intense it appears to be. Obviously, at age 11 or 12, an early-maturing girl would be considerably larger than one who matured late. In each case, the onset of menstruation (menarche) (*M1*, *M2*, and *M3*) came after the peak of growth velocity.

time to produce a biologic time scale and shows that the pattern is expressed at different times chronologically but not physiologically. The effectiveness of biologic or developmental age in reducing timing variability makes this approach useful in evaluating a child's growth status.



• **Fig. 2.7** Velocity curves for four girls with quite different times of menarche, replotted using menarche as a zero time point. It is apparent that the growth pattern in each case is quite similar, with almost all of the variations resulting from timing.

## Methods for Studying Physical Growth

Before beginning the examination of growth data, it is important to have a reasonable idea of how the data were obtained. There are two basic approaches to studying physical growth. The first is based on techniques for measuring living animals (including humans), with the implication that the measurement itself does no harm and that the animal will be available for additional measurements at another time. The second approach uses experiments in which growth is manipulated in some way. This implies that the subject of the experiment will be available for study in some detail, and the detailed study may be destructive. For this reason, such experimental studies are largely restricted to nonhuman species.

## Measurement Approaches

### Acquiring Measurement Data

**Craniometry.** The first of the measurement approaches for studying growth, with which the science of physical anthropology began, is craniometry, based on measurements of skulls found among human skeletal remains. Craniometry was originally used to study the Neanderthal and Cro-Magnon peoples whose skulls were found in European caves in the 18th and 19th centuries. From such skeletal material, it has been possible to piece together a great deal of knowledge about extinct populations and to get some idea of their pattern of growth by comparing one skull with another. Craniometry has the advantage that rather precise measurements can be made on dry skulls; it has the important disadvantage for growth studies that, by necessity, all these growth data must be cross-sectional. *Cross-sectional* means that although different ages are represented in the population, the same individual can be measured at only one point in time.

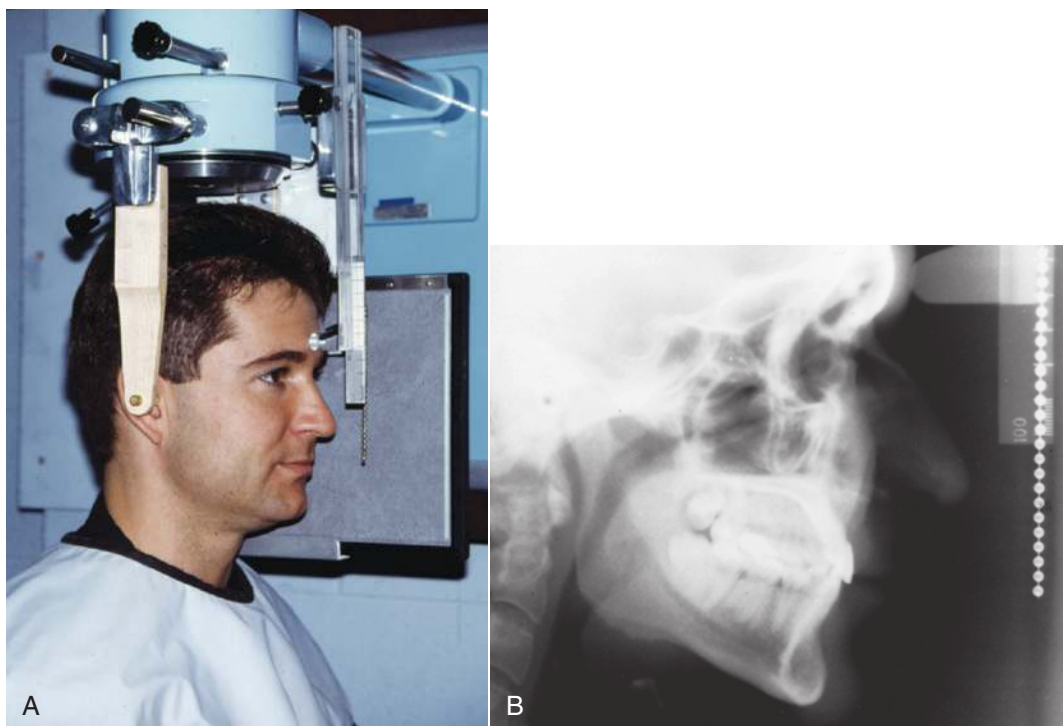
**Anthropometry.** It is also possible to measure skeletal dimensions on living individuals. In this technique, called *anthropometry*, various landmarks established in studies of dry skulls are measured in living individuals simply by using soft tissue points overlying these bony landmarks. For example, it is possible to measure the length of the cranium from a point at the bridge of the nose to a point at the greatest convexity of the rear of the skull. This measurement can be made on either a dried skull or a living individual, but results would be different because of the soft tissue thickness overlying both landmarks. Although the soft tissue introduces variation, anthropometry does make it possible to follow the growth of an individual directly, making the same measurements repeatedly at different times. This produces longitudinal data: repeated measures of the same individual. The best data of that type come from Farkas's anthropometric studies in the late 20th century, which provided valuable new data for human facial proportions and their changes from childhood to adolescence and adult life.<sup>1</sup>

**Cephalometric Radiology.** The third measurement technique, cephalometric radiology, is of considerable importance not only in the study of growth but also in clinical evaluation of orthodontic patients. The technique depends on precisely orienting the head before making a radiograph, with equally precise control of magnification. This approach can combine the advantages of craniometry and anthropometry. It allows a direct measurement of bony skeletal dimensions, because the bone can be seen through the soft tissue covering in a radiograph, but it also allows the same individual to be followed over time. Growth studies are done by superimposing a tracing or digital model of a later cephalogram

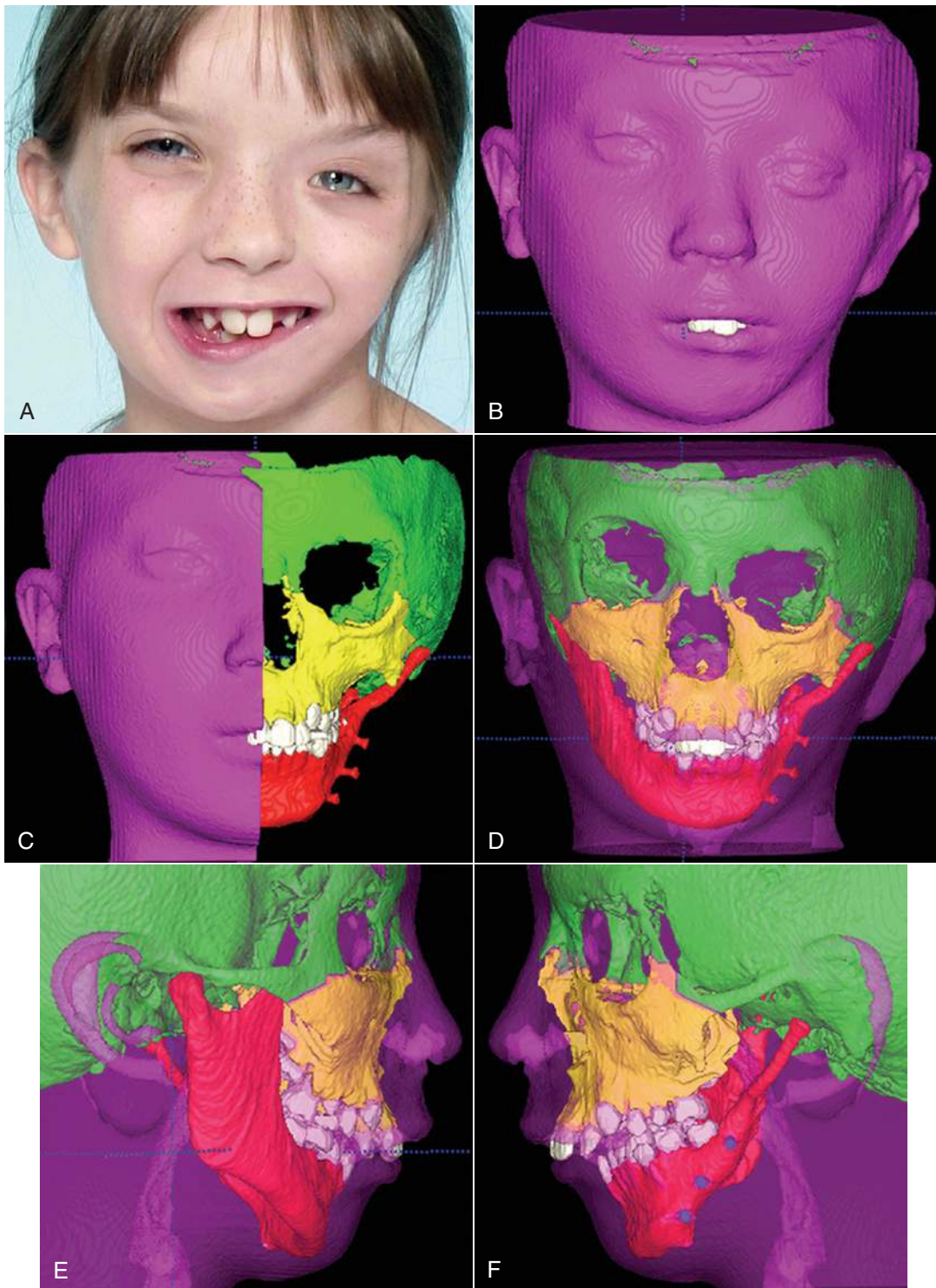
on an earlier one, so that the changes can be measured. Both the locations and amounts of growth can be observed in this way (Fig. 2.8). Cephalometric superimposition techniques are described in detail in Chapter 6.

The disadvantage of a standard cephalometric radiograph is that it produces a two-dimensional (2-D) representation of a three-dimensional (3-D) structure, and so, even with precise head positioning, not all measurements are possible. To some extent, this can be overcome by making more than one radiograph at different orientations and using triangulation to calculate oblique distances. The general pattern of craniofacial growth was known from craniometric and anthropometric studies before cephalometric radiography was invented, but much of the current picture of craniofacial growth is based on cephalometric studies.

**Three-Dimensional Imaging.** New information now is being obtained with the application of 3-D imaging techniques. Computed axial tomography (CAT or, more commonly, computed tomography [CT]) allows 3-D reconstructions of the cranium and face, and this method has been applied in the last 30 years to plan surgical treatment for patients with facial deformities (Fig. 2.9). Recently, cone beam computed tomography (CBCT) rather than axial CT has been applied to scans of the head and face. This significantly reduces both the radiation dose and the cost. CBCT allows scans of patients with radiation exposure that is much closer to the dose from cephalograms. Superimposition of 3-D images is much more difficult than the superimpositions used with 2-D cephalometric radiographs, but methods have been developed to address this difficulty (Fig. 2.10).<sup>2</sup>



• **Fig. 2.8** (A) A cephalometric radiograph merits this name because of the use of a head positioning device to provide precise orientation of the head. This means that valid comparisons can be made between external and internal dimensions in members of the same population group or that the same individual can be measured at two points in time because the head orientation is reproducible. (B) This radiograph (a cephalogram) was taken in natural head position (NHP) (see Chapter 6 for a description of this head-positioning technique).

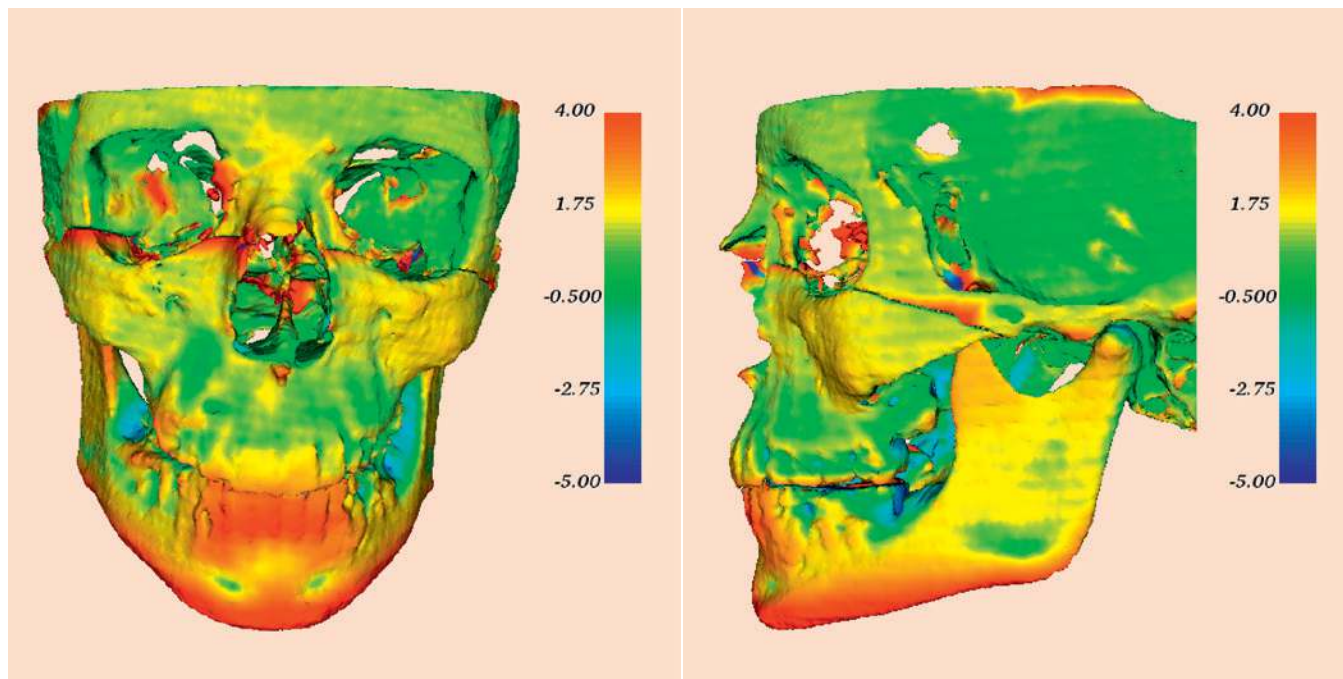


• **Fig. 2.9** Computed tomography (CT) scans are the best way to determine the details of skeletal deformities. These views of a 9-year-old girl (A) with severe hemifacial microsomia (and previous surgical treatment to build up the affected side of the mandible) illustrate that CT scans can show both skin contours and bony relationships from any aspect. Color can be added to different structures to make it easier to visualize them (B), and surface layers can be made transparent (as in [C] to [F]) to reveal the skeletal structures beneath. Views of this type greatly facilitate surgical treatment planning. (Courtesy Dr. L. Cevidanes.)

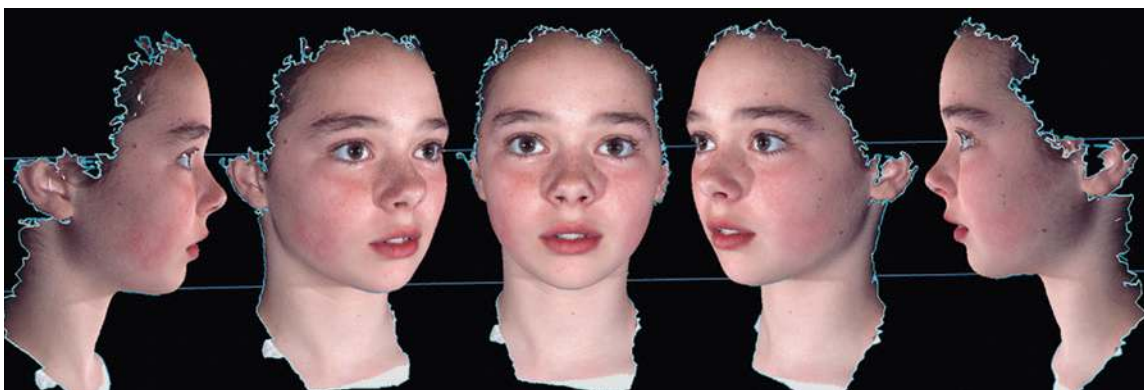


Magnetic resonance imaging (MRI) also provides 3-D images that can be useful in studies of growth, with the advantage that there is no radiation exposure with this technique. This method already has been applied to analysis of the growth changes produced by functional appliances,<sup>3</sup> but it shows soft tissues more clearly than hard tissues, just the reverse of radiographic images.

Three-dimensional photography now makes possible much more accurate measurements of facial soft tissue dimensions and changes (Fig. 2.11). A more detailed examination of 3-D changes in growing patients almost surely will add to current knowledge of growth patterns in the near future.



• **Fig. 2.10** Superimposition of computed tomography (CT) images is much more difficult than superimposition of cephalometric tracings but more accurately detects the amount of change and can be used to see changes in exquisite detail. These images are superimposed on the cranial base; a color map is used to show the change from the initial image of an adolescent with a normal growth pattern at age 12 to the same individual at age 14. In the color map, green shows areas of little or no change; deepening shades of red indicate 3 to 4 mm of movement away from the cranial base; and shades of blue (seen here only on the front of the mandibular ramus) indicate areas that moved closer to the cranial base. The map shows the downward and forward movement of the mandible at a time, as you would expect, of more mandibular than maxillary growth, and resorption of the front of the ramus that lengthens the body of the mandible to provide space for eruption of the second molars. Note that the zygomatic arches and the maxillary teeth moved forward a small amount while the bony area just above the maxilla stayed largely in the same place. Understanding growth changes from carefully examining superimposition images such as these is much easier than deciphering the meaning of a series of measurements and gives a broader view of the skeletal changes due to growth.



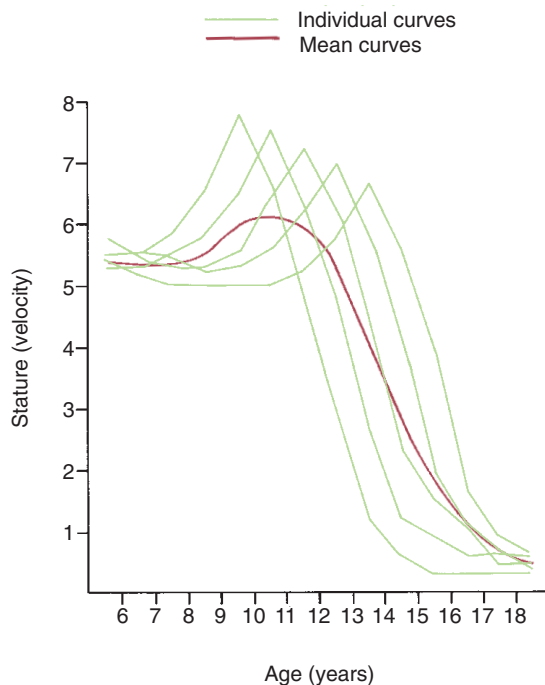
• **Fig. 2.11** Images from a single photograph with a 3dMD camera. Both profile and oblique and frontal views can be captured at the same head position, and measurements of soft tissue dimensions and proportions can be made with great accuracy at any orientation of the face, which makes a camera that provides such three-dimensional views a valuable research tool.

### Analysis of Measurement Data

Both anthropometric and cephalometric data can be expressed cross-sectionally rather than longitudinally. Obviously, it would be much easier and quicker to do a cross-sectional study, gathering data once for any individual and including subjects of different ages, rather than spending many years on a study in which the same individuals are measured repeatedly. For this reason, most studies are cross-sectional. When this approach is used, however, variability within the sample can conceal details of the growth pattern, particularly when there is no correction for timing variation (Fig. 2.12). Fluctuations in the growth curve that may occur for nearly every individual would be seen in a cross-sectional study only if they occurred at the same time for each person, which is unlikely. Longitudinal studies are efficient in the sense that a great deal of information can be gained from a relatively small number of subjects, fewer than would be needed in a cross-sectional study. In addition, the longitudinal data highlight individual variations, particularly variations caused by timing effects.

Measurement data can be presented graphically in a number of different ways, and frequently, it is possible to clarify growth changes by varying the method of display. For example, we have already seen that growth data can be shown either by plotting the size attained as a function of age, which is called a “distance” curve, or as a “velocity” curve, showing not the total length but the increment added each year (see Fig. 2.5). Changes in the rate of growth are much more easily seen in a velocity curve.

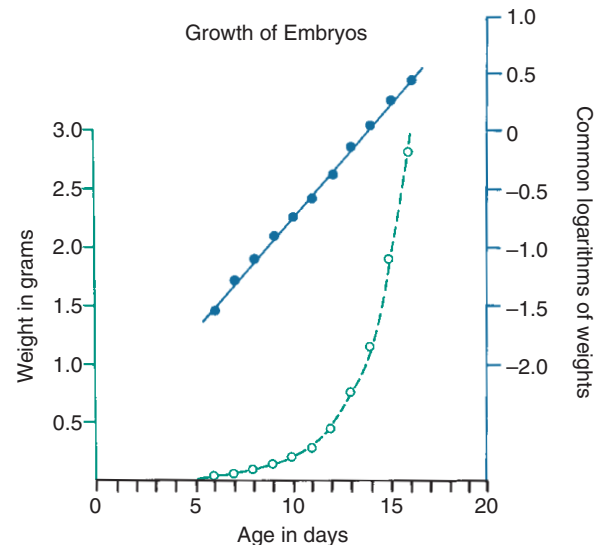
Various other mathematical transformations can be used with growth data to make them easier to understand. For instance, the growth in weight of any embryo at an early stage follows a



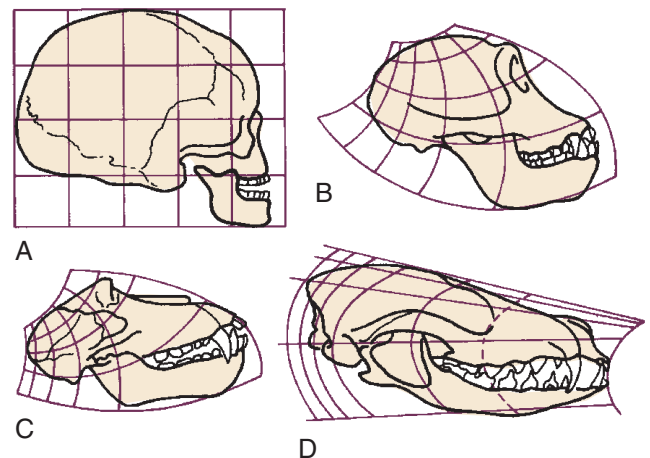
• **Fig. 2.12** If growth velocity data for a group of individuals with different timings for their adolescent growth spurt are plotted on a chronologic scale, it is apparent that the average curve is not an accurate representation of the pattern of growth for many individuals. This smoothing of individual variation is a characteristic of cross-sectional data and a major limitation in use of the cross-sectional method for studies of growth. Only by following individuals through time in a longitudinal study is it possible to see the details of growth patterns.

logarithmic or exponential curve because the growth is based on division of cells; the more cells there are, the more cell divisions can occur. If the same data are plotted using the logarithm of the weight, a straight-line plot is attained (Fig. 2.13). This demonstrates that the rate of multiplication for cells in the embryo is remaining more or less constant.

More complex mathematical transformations were used many years ago by D’Arcy Thompson<sup>4</sup> to reveal similarities in proportions and growth changes that had not previously been suspected (Fig. 2.14). To correctly interpret data after mathematical transformation, it is important to understand how the data were transformed, but



• **Fig. 2.13** Data for the increase in weight of early embryos, with the raw data plotted in green and the same data plotted after logarithmic transformation in blue. At this stage the weight of the embryo increases dramatically, but, as shown by the straight line after transformation, the rate of multiplication of individual cells remains fairly constant. When more cells are present, more divisions can occur, and the weight increases faster. (From Lowery GH. *Growth and Development of Children*. 8th ed. Chicago: Year Book Medical Publishers; 1986.)



• **Fig. 2.14** In the early 1900s, D’Arcy Thompson showed that mathematical transformation of a grid could account for the changes in the shape of the face from man (A) to chimpanzee (B), monkey (C), dog (D), or other animals. Application of this method revealed previously unsuspected similarities among various species. (Redrawn from Thompson DW. *On Growth and Form*. Cambridge: Cambridge University Press; 1961.)

the approach is a powerful one in clarifying growth concepts, and Thompson's classic presentation remains stimulating reading.

## Experimental Approaches

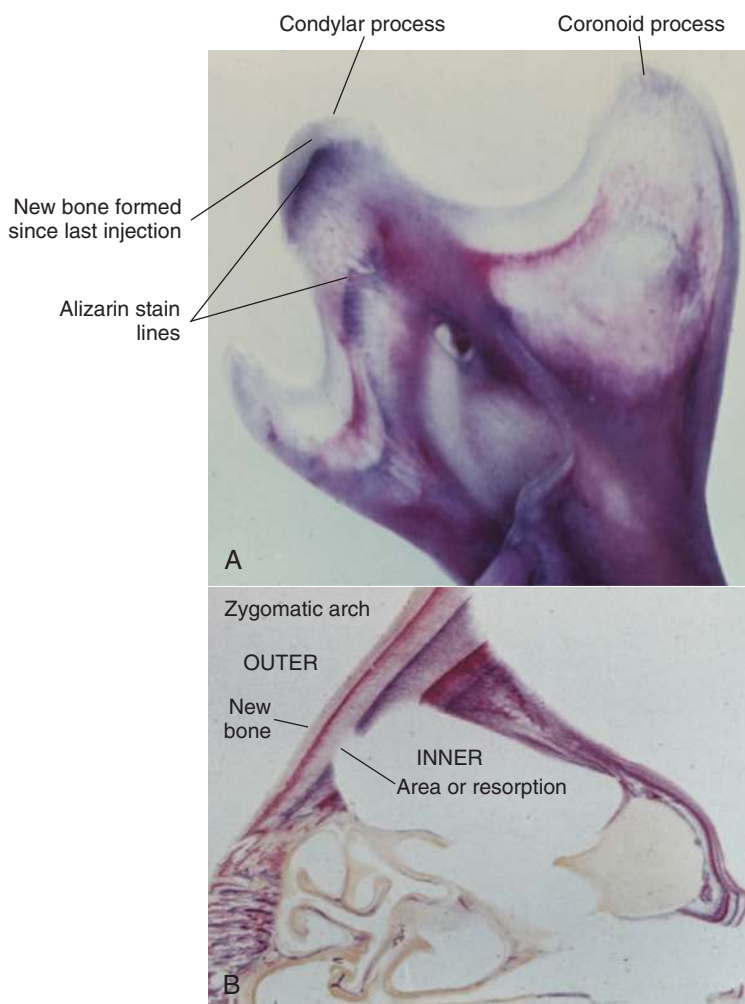
### Vital Staining

Much has been learned about skeletal growth using the technique called *vital staining*, in which dyes that stain mineralizing tissues (or occasionally, soft tissues) are injected into an animal. These dyes remain in the bones and teeth and can be detected later after death. This method was originated by the great English anatomist John Hunter in the 18th century. Hunter observed that the bones of pigs that occasionally were fed textile waste were often stained in an interesting way. He discovered that the active agent was a dye called *alizarin*, which still is used for vital staining studies. Alizarin reacts strongly with calcium at sites where bone calcification is occurring. Because these are the sites of active skeletal growth, the dye marks the locations at which active growth was occurring

when it was injected. Bone remodels rapidly, and areas from which bone is being removed also can be identified by the fact that vital stained material has been removed from these locations (Fig. 2.15). Highly detailed vital staining studies of bony changes in craniofacial development in experimental animals, from work done at the U.S. National Institute of Dental and Craniofacial Research, are available.<sup>5</sup>

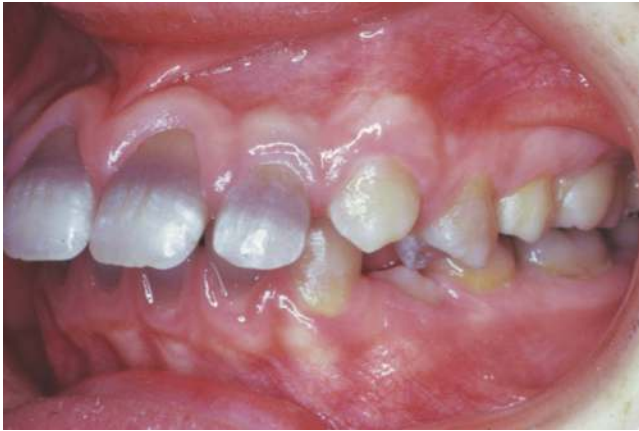Although studies using vital stains are not possible in humans, vital staining can occur inadvertently. Many children born in the late 1950s and early 1960s were treated for recurrent infections with the antibiotic tetracycline. It was discovered too late that tetracycline is an excellent vital stain that binds to calcium at growth sites in the same way as alizarin. The discoloration of incisor teeth that results from tetracycline given when the teeth are mineralizing has been an esthetic disaster for some individuals (Fig. 2.16). Although this should not occur now, it still is seen occasionally.

With the development of radioactive tracers, it has become possible to use almost any radioactively labeled metabolite that

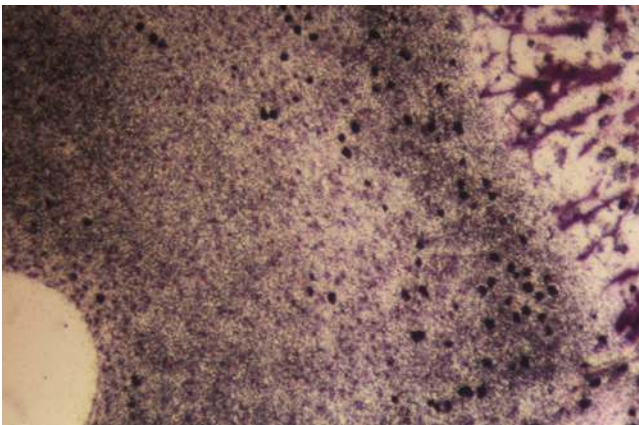


• **Fig. 2.15** (A) The mandible of a growing rat that received four injections of alizarin (red-blue-red-blue) at 2-week intervals and was killed 2 weeks after the last injection (so that the bone formed since then is white). Modeling of the bone as it grows blurs some of the lines of intensely colored bone created by each injection, but the red-blue sequential lines in the condylar process can be seen clearly. (B) Section through the zygomatic arch, from the same animal. The zygomatic arch grows outward by apposition of bone on the outer surface and removal from the inner surface. The interruptions in the staining lines on the inner surface clearly show the areas where bone is being removed. What was once the outer surface of the zygomatic arch becomes the inner surface a relatively short time later and then is removed.



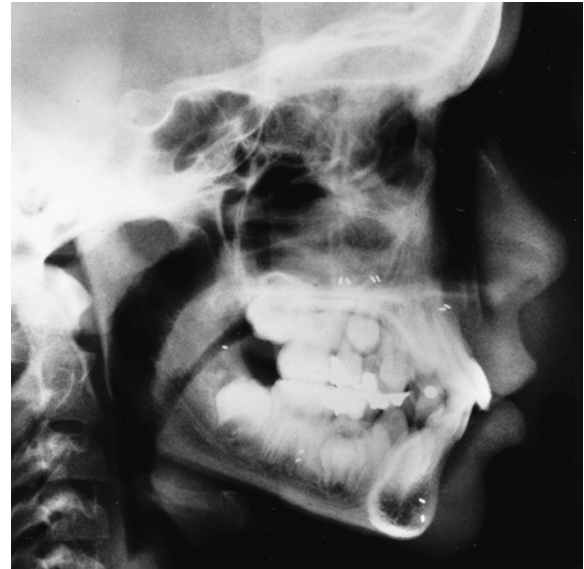

• **Fig. 2.16** Tetracycline staining in the teeth of a boy who received large doses of tetracycline because of repeated upper respiratory infections in early childhood. From the location of the staining, it is apparent that tetracycline was not administered in infancy but was given in large doses beginning when the crowns of the central incisors were about half formed, or at approximately 30 months.



• **Fig. 2.17** Autoradiograph of fetal rat bones growing in organ culture, with carbon 14 ( $^{14}\text{C}$ )–proline and tritium ( $^3\text{H}$ )–thymidine incorporated in the culture medium. Thymidine is incorporated into DNA, which is replicated when a cell divides, so labeled nuclei are those of cells that underwent mitosis in culture. Because proline is a major constituent of collagen, cytoplasmic labeling indicates areas where proline was incorporated, primarily into extracellularly secreted collagen.

becomes incorporated into the tissues as a sort of vital stain. The location is detected by the weak radioactivity given off at the site where the material was incorporated. The gamma-emitting isotope technetium 99m ( $^{99\text{m}}\text{Tc}$ ) can be used to detect areas of rapid bone growth in humans, but these images are more useful in diagnosis of localized growth problems such as condylar hyperplasia (see [Chapter 6](#)) than for studies of growth patterns. For most studies of growth, radioactively labeled materials in the tissues of experimental animals are detected by the technique of autoradiography, in which a film emulsion is placed over a thin section of tissue containing the isotope and then is exposed in the dark by the radiation. After the film has been developed, the location of the radiation that indicates where growth is occurring can be observed by looking at the tissue section through the film ([Fig. 2.17](#)).



• **Fig. 2.18** Lateral cephalometric radiograph from the archives of Björk's implant studies, showing a subject with six maxillary and five mandibular tantalum implants. (Courtesy Department of Orthodontics, University of Copenhagen, Denmark.)

### Implant Radiography

Another experimental method applicable to studies of humans is implant radiography. In this technique, inert metal pins are placed in bones anywhere in the skeleton, including the face and jaws. These metal pins are well tolerated by the skeleton, become permanently incorporated into the bone without causing any problems, and are easily visualized on a cephalogram ([Fig. 2.18](#)). If they are placed in the jaws, a considerable increase in the accuracy of a longitudinal cephalometric analysis of growth pattern can be achieved. This method of study was developed by Professor Arne Björk and coworkers at the Royal Dental College in Copenhagen, Denmark, and was used extensively by workers there (see [Chapter 4](#)). It provided important new information about the growth pattern of the jaws.

With 21st century technology, precise evaluation of dentofacial growth in humans using implant cephalograms has largely been superseded by 3-D imaging via CT or MRI, but it still can be helpful to use implants to provide landmarks for superimposition.

### Genetic Influences on Growth

Rapid advances in molecular genetics are providing new information about growth, its control, and links to the development of orthodontic problems. It now has been shown that homeobox *Msx* and *Dix* genes, which are known to be critically important in the establishment of body plan, pattern formation, and morphogenesis, are expressed differentially not only in development of the teeth but also in growth of the mandible. *Msx-1* predominates in tooth formation and is expressed in basal bone but not in the alveolar process, whereas *Msx-2* is strongly expressed there. *Dix-1* and *Dix-2* are expressed in the dental mesenchyme and in the epithelium of the maxillary and mandibular arch mesenchyme, and other homeobox gene groups have been shown to play a role in dental and facial development.<sup>6</sup> An association between a specific genotype for muscle myofibril anchor proteins and Class II and deep bite malocclusions has been demonstrated.<sup>7</sup>

Proper function of families of growth factors and their cognate receptors is essential in regulating embryonic processes of cell growth and organ development, as well as myriad postnatal processes that include growth, wound healing, bone remodeling, and homeostasis. The U.S. National Institute of Dental and Craniofacial Research has recently announced the establishment of a consortium to accelerate understanding of craniofacial developmental biology by interactive projects including global and specific gene expression patterns, genome-wide association patterns, and transcriptional profiling over the course of embryonic and postnatal development in animal models and humans.<sup>8</sup> Essentially, this is a project toward the use of “big data” to better understand complex genetic interactions. It seems likely that interactive research of this type by groups of investigators will lead to the development of gene therapy for developmental problems.

Interaction between different tissues within the craniofacial complex creates yet another level of regulation of growth and development. One example of this is the convergence of the development of the muscles that attach to the mandible and the bony areas to which they attach. Although many genes are involved in determining mandibular size, genetic alterations in muscle development and function translate into changes in the forces on areas of bone where muscles attach, and this leads to modification of skeletal areas such as the coronoid process and gonial angle area of the mandible. Genetic alterations that affect muscle also would affect these skeletal areas. To understand this, it is necessary both to identify specific genes involved and to deduce how their activity is modified, but already it is apparent that gene expression can be upregulated or downregulated by mechanical stresses.

Another good example of tissue interactions is found in the development of a tooth and the beginning of eruption. Tooth formation begins with the differentiation of ameloblasts (which form the outer enamel layer of the crown of a tooth) and dentinoblasts (which form the inner dentin layer) within the rapidly calcifying alveolar bone, while multipotential cells continue to be present within the forming crown. As crown formation continues, a layer of osteoclasts forms on the upper surface of the crown, in position to resorb bone over the crown so that eruptive movements can occur—but these osteoclasts are downregulated until enamel formation is complete. At that point, just as root formation is beginning, the osteoclasts are upregulated and begin to create a path along which the tooth will erupt and eruptive tooth movement begins.

There has been significant progress in understanding the genetics of human eruption problems, and the identification of a genetic mutation leading to primary failure of eruption (PFE) in 2009 made it possible for the first time to diagnose an orthodontic problem from examination of DNA from a sample of blood or saliva.<sup>9</sup> PFE is discussed further in [Chapters 3 and 12](#).

An exciting prospect for the future is a better understanding of how patients with orthodontic problems that are known to have a genetic component (Class III malocclusion being the best example) will respond to treatment. Chromosomal loci associated with Class III malocclusion have been identified. It is clear that there are multiple subtypes of Class III, and a necessary first step is better characterization of these phenotypes. Establishing phenotypic markers (distinct clinical characteristics) makes it possible to establish definitive correlations with modes of inheritance and is necessary for linkage studies that will clarify the genetic basis for the problem.

It is unlikely that genetic analysis will ever be applicable to planning treatment for the majority of orthodontic problems, but

it could yield valuable information about the best approach to some of the most difficult skeletal malocclusions and perhaps the application of gene therapy to growth problems.

## The Nature of Skeletal Growth

At the cellular level, there are only three possibilities for growth. The first is an increase in the size of individual cells, which is referred to as *hypertrophy*. The second possibility is an increase in the number of the cells, which is called *hyperplasia*. The third is *secretion of extracellular material*, thus contributing to an increase in size independent of the number or size of the cells themselves.

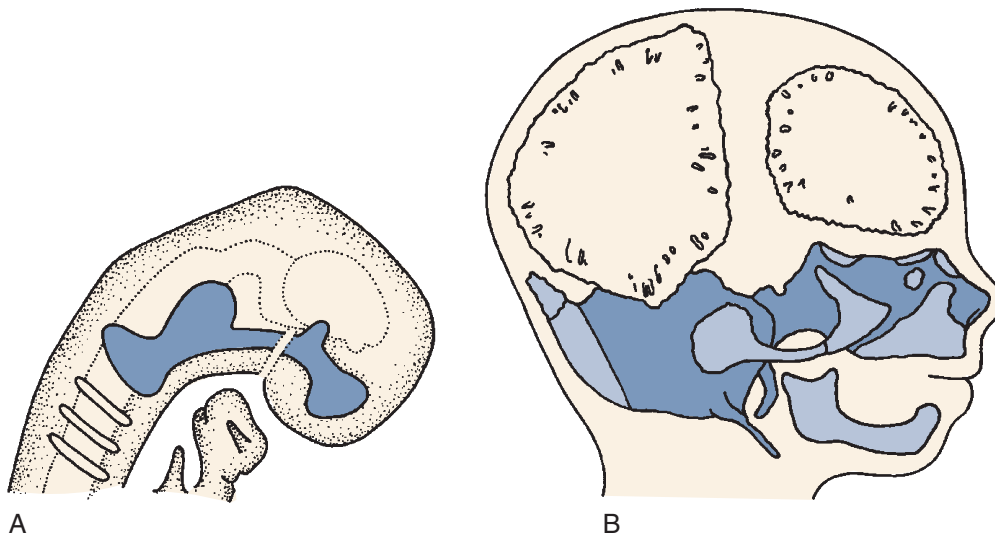
In fact, all three of these processes occur in skeletal growth. Hyperplasia is a prominent feature of all forms of growth. Hypertrophy occurs in a number of special circumstances but is a less important mechanism than hyperplasia in most instances. Although tissues throughout the body secrete extracellular material, this phenomenon is particularly important in the growth of the skeletal system, where extracellular material later mineralizes.

The fact that the extracellular material of the skeleton becomes mineralized leads to an important distinction between growth of the soft or nonmineralized tissues of the body and the hard or calcified tissues. Hard tissues are bones, teeth, and sometimes cartilages. Soft tissues are everything else. In most instances, cartilage, particularly the cartilage significantly involved in growth, behaves like soft tissue and should be thought of in that group, rather than as hard tissue.

Growth of soft tissues occurs by a combination of hyperplasia and hypertrophy. These processes go on everywhere within the tissues, and the result is what is called *interstitial growth*, which simply means that it occurs at all points within the tissue. Although secretion of extracellular material can also accompany interstitial growth, hyperplasia primarily and hypertrophy secondarily are its characteristics. Interstitial growth is characteristic of nearly all soft tissues and of uncalcified cartilage within the skeletal system.

In contrast, when mineralization takes place so that hard tissue is formed, interstitial growth becomes impossible. Hyperplasia, hypertrophy, and secretion of extracellular material all are still possible, but in mineralized tissues, these processes can occur only on the surface, not within the mineralized mass. Direct addition of new bone to the surface of existing bone can and does occur through the activity of cells in the periosteum—the soft tissue membrane that covers bone. Formation of new cells occurs in the periosteum, and extracellular material secreted there is mineralized and becomes new bone. This process is called *direct or surface apposition* of bone. Interstitial growth is a prominent aspect of overall skeletal growth because a major portion of the skeletal system is originally modeled in cartilage. This includes the basal part of the skull, as well as the trunk and limbs.

[Fig. 2.19](#) shows the cartilaginous and neural development of the face and cranium at 8 and 12 weeks of intrauterine development. Cartilaginous skeletal development occurs most rapidly during the third month of intrauterine life. A continuous plate of cartilage extends from the nasal capsule posteriorly all the way to the foramen magnum at the base of the skull. It must be kept in mind that cartilage is a nearly avascular tissue whose internal cells are supplied by diffusion through the outer layers. This means, of course, that the cartilage must be thin. At early stages in development of the fetus (the fetal stage begins at the start of the third month), its extremely small size makes a chondroskeleton feasible, but with further growth such an arrangement is no longer possible without an internal blood supply.



• **Fig. 2.19** Development and maturation of the chondrocranium (cartilage, light blue; bone, stippled dark blue). (A) Diagrammatic representation at about 8 weeks. Note that an essentially solid bar of cartilage extends from the nasal capsule anteriorly to the occipital area posteriorly. (B) Skeletal development at 12 weeks. Ossification centers have appeared in the midline cartilage structures, and in addition, intramembranous bone formation of the jaws and brain case has begun. From this point on, bone replaces cartilage of the original chondrocranium rapidly so that only the small cartilaginous synchrondroses connecting the bones of the cranial base remain.

During the fourth month in utero, there is an ingrowth of blood vascular elements into various points of the chondrocranium (and the other parts of the early cartilaginous skeleton). These areas become centers of ossification, at which cartilage is transformed into bone in the process called *endochondral ossification*, and islands of bone appear in the sea of surrounding cartilage (see Fig. 2.19B). The cartilage continues to grow rapidly but is replaced by bone with equal rapidity. The result is that the amount of bone increases rapidly and the relative (but not the absolute) amount of cartilage decreases. Eventually, the old chondrocranium is represented only by small areas of cartilage interposed between large sections of bone, which assume the characteristic form of the ethmoid, sphenoid, and basioccipital bones. Growth at these cartilaginous connections between the skeletal bones is similar to growth in the limbs.

In the long bones of the extremities, areas of ossification appear in the center of the bones and at the ends, ultimately producing a central shaft called the *diaphysis* and a bony cap on each end called the *epiphysis*. Between the epiphysis and diaphysis is a remaining area of uncalcified cartilage called the *epiphyseal plate* (Fig. 2.20A). The epiphyseal plate cartilage of the long bones is a major center for their growth, and in fact, this cartilage is responsible for almost all growth in length of these bones. The periosteum on the surfaces of the bones also plays an important role in adding to thickness and in reshaping the external contours.

Near the outer end of each epiphyseal plate is a zone of actively dividing cartilage cells. Some of these, pushed toward the diaphysis by proliferative activity beneath, undergo hypertrophy, secrete an extracellular matrix, and eventually degenerate as the matrix begins to mineralize and then is rapidly replaced by bone. As long as the rate at which cartilage cells proliferate is equal to or greater than the rate at which they mature, growth will continue. Eventually, however, toward the end of the normal growth period, the rate of maturation exceeds the rate of proliferation, the last of the cartilage is replaced by bone, and the epiphyseal plate disappears. At that

point, the growth of the bone is complete, except for surface changes in thickness, which can be produced by the periosteum.

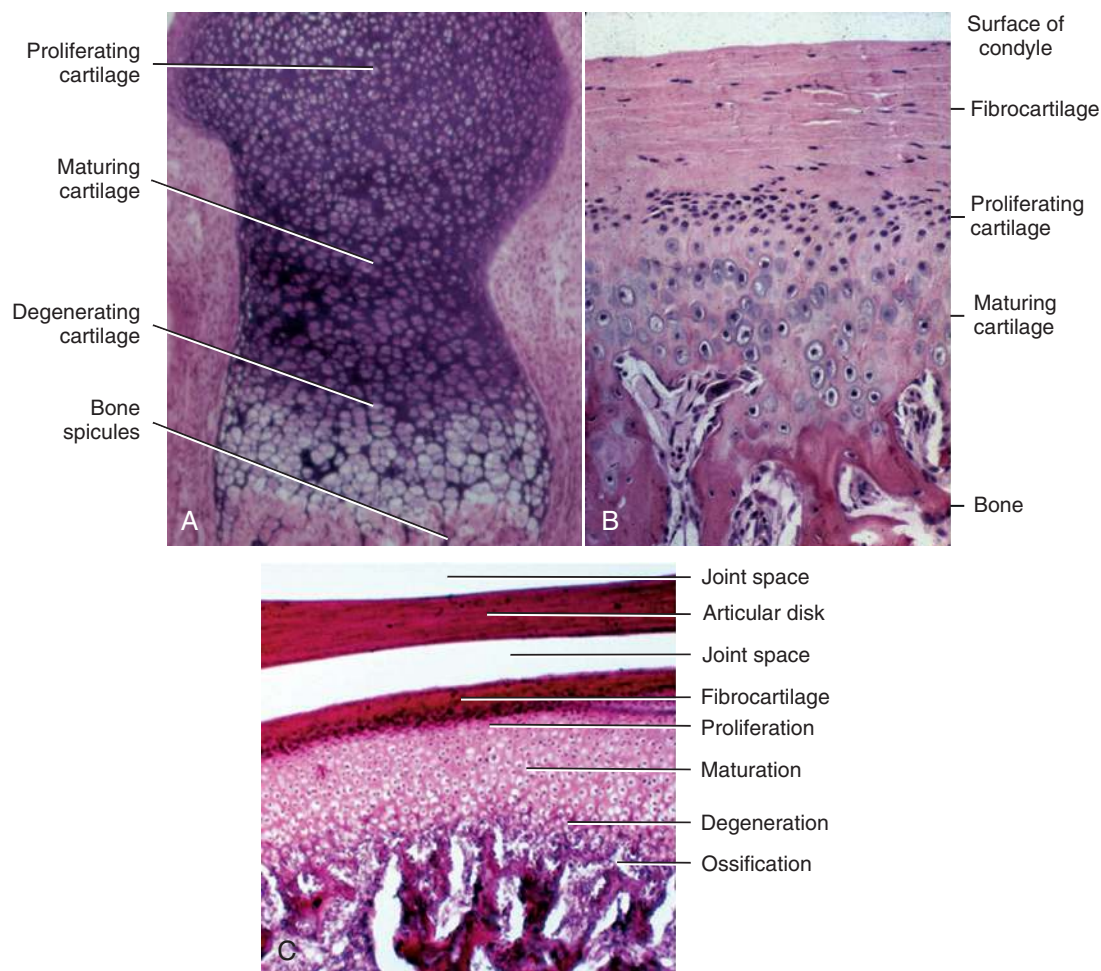
Endochondral ossification also occurs at the mandibular condyle, which superficially looks like half an epiphyseal plate (Fig. 2.20B–C). As we will see, however, the cartilage of the condyle does not behave like an epiphyseal plate—and the difference is important in understanding mandibular growth.

Not all bones of the adult skeleton were represented in the embryonic cartilaginous model, and it is possible for bone to form by secretion of bone matrix directly within connective tissues, without any intermediate formation of cartilage. Bone formation of this type is called *intramembranous ossification*. This type of bone formation occurs in the cranial vault and both jaws (Fig. 2.21).

Early in embryonic life (which is discussed in some detail later at the beginning of Chapter 5), the mandible of higher animals develops in the same area as the cartilage of the first pharyngeal arch—Meckel's cartilage. It would seem that the mandible should be a bony replacement for this cartilage in the same way that the sphenoid bone beneath the brain replaces the cartilage in that area. In fact, development of the mandible begins as a condensation of mesenchyme just lateral to Meckel's cartilage and proceeds entirely by intramembranous bone formation (Fig. 2.22). Meckel's cartilage disintegrates and largely disappears as the bony mandible develops. Remnants of this cartilage are transformed into a portion of two of the small bones that form the conductive ossicles of the middle ear but not into a significant part of the mandible. Its perichondrium persists as the sphenomandibular ligament. The condylar cartilage develops initially as an independent secondary cartilage, which is separated by a considerable gap from the body of the mandible (Fig. 2.23). Early in fetal life, it fuses with the developing mandibular ramus.

The maxilla forms initially from a center of mesenchymal condensation in the maxillary process. This area is located on the lateral surface of the nasal capsule, the most anterior part of the





• **Fig. 2.20** (A) Endochondral ossification at an epiphyseal plate. Growth occurs by proliferation of cartilage, occurring here at the top. Maturing cartilage cells are displaced away from the area of proliferation, undergo hypertrophy, degenerate, and are replaced by spicules of bone, as seen in the bottom. (B) and (C) Endochondral ossification in the head of the condyle. A layer of fibrocartilage lies on the surface, with proliferating cells just beneath. Maturing and degenerating cartilage cells can be seen toward the area of ossification.

chondrocranium, but endochondral ossification does not contribute directly to formation of the maxillary bone. An accessory cartilage, the zygomatic or malar cartilage, which forms in the developing malar process, disappears and is totally replaced by bone well before birth, unlike the mandibular condylar cartilage, which persists.

Whatever the location for intramembranous bone formation, interstitial growth within the mineralized mass is impossible, and the bone must be formed entirely by apposition of new bone to free surfaces. Its shape can be changed through removal (resorption) of bone in one area and addition (apposition) of bone in another (see Fig. 2.15). This balance of apposition and resorption, with new bone being formed in some areas while old bone is removed in others, is an essential component of the growth process. It has two components: *modeling* and *remodeling*.

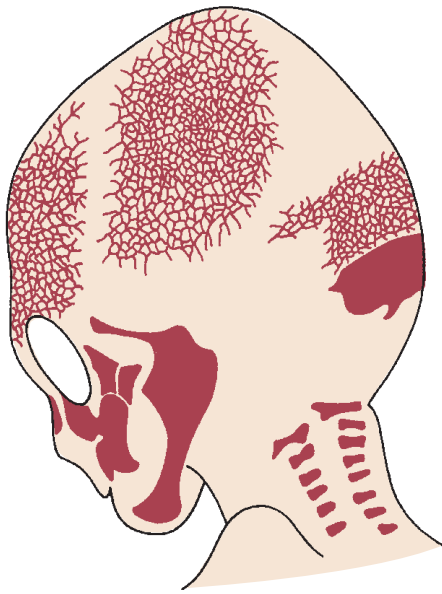
Modeling adapts structure to function by changing bone size and shape to maintain bone strength as loading of the bone changes. This process also includes bone drift, such as the relocation of the mandibular ramus during growth (described in detail later). Remodeling occurs via osteocyte apposition and osteoclast resorption in the same area. An excellent example of remodeling is the process

that takes place with tooth movement, but internal remodeling of bony structures occurs in a continuous cycle.<sup>10</sup> Keeping this distinction between modeling and remodeling in mind can make it easier to understand the bony changes that occur during growth that are discussed in the following sections of this chapter, where these terms are *not* used interchangeably.

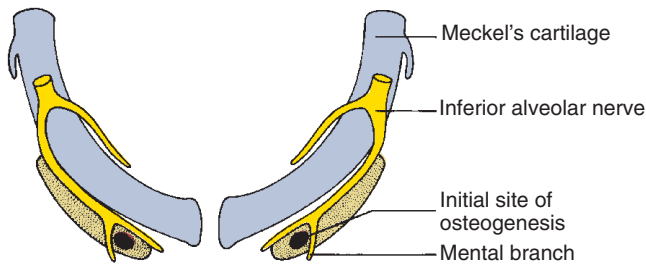
## Sites and Types of Growth in the Craniofacial Complex

To understand growth in any area of the body, it is necessary to understand (1) the sites or location of growth, (2) the type of growth occurring at that location, (3) the mechanism of growth (i.e., how growth changes occur), and (4) the determinant or controlling factors in that growth.

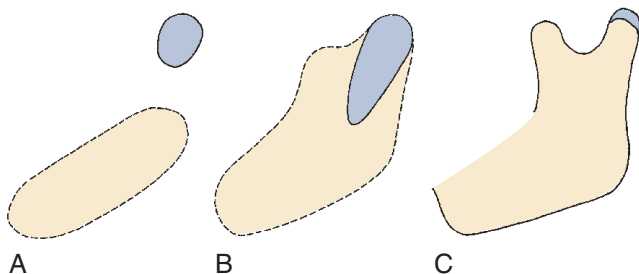
In the following discussion of sites and types of growth in the head and face, it is convenient to divide the craniofacial complex into four areas that grow rather differently: the cranial vault, the bones that cover the upper and outer surface of the brain; the cranial



• **Fig. 2.21** The bones of the skull of a 12-week-old fetus, drawn from a cleared alizarin-stained specimen. (Redrawn from Sadler TW, Langman J. *Langman's Medical Embryology*. 9th ed. Philadelphia: Lippincott Williams & Wilkins; 2003.)



• **Fig. 2.22** Diagrammatic representation of the relation of initial bone formation in the mandible to Meckel's cartilage and the inferior alveolar nerve. Bone formation begins just lateral to Meckel's cartilage and spreads posteriorly along it without any direct replacement of the cartilage by the newly forming bone of the mandible. (Redrawn from Ten Cate AR. *Oral Histology: Development, Structure, and Function*. 5th ed. St. Louis: Mosby; 1998.)



• **Fig. 2.23** The condylar cartilage (blue) develops initially as a separate area of condensation from that of the body of the mandible and only later is incorporated within. (A) Separate areas of mesenchymal condensation at 8 weeks. (B) Fusion of the cartilage with the mandibular body at 4 months. (C) Situation at birth (reduced to scale).

base, the bony floor under the brain, which also is the dividing line between the cranium and the face; the nasomaxillary complex, made up of the nose, maxilla, and associated small bones; and the mandible. The sites and types of growth are discussed in the following section of this chapter. The mechanism and determinants for growth in each area, as they are viewed from the perspective of current theories of growth control, are discussed later.

## Cranial Vault

The cranial vault is made up of a number of flat bones that are formed directly by intramembranous bone formation, without cartilaginous precursors. From the time that ossification begins at a number of centers that foreshadow the eventual anatomic bony units, the growth process is entirely the result of periosteal activity at the surfaces of the bones. Modeling (addition of new bone) and growth occur primarily at the periosteum-lined contact areas between adjacent skull bones, the *cranial sutures*, but periosteal activity also produces both modeling and remodeling changes of the inner and outer surfaces of these platelike bones.

At birth, the flat bones of the skull are rather widely separated by loose connective tissues (Fig. 2.24). These open spaces, the fontanelles, allow a considerable amount of deformation of the skull at birth. This is important in allowing the relatively large head to pass through the birth canal (see Chapter 3 for more detail). After birth, apposition of bone along the edges of the fontanelles eliminates these open spaces fairly quickly, but the bones remain separated by a thin, periosteum-lined suture for many years, eventually fusing in adult life.

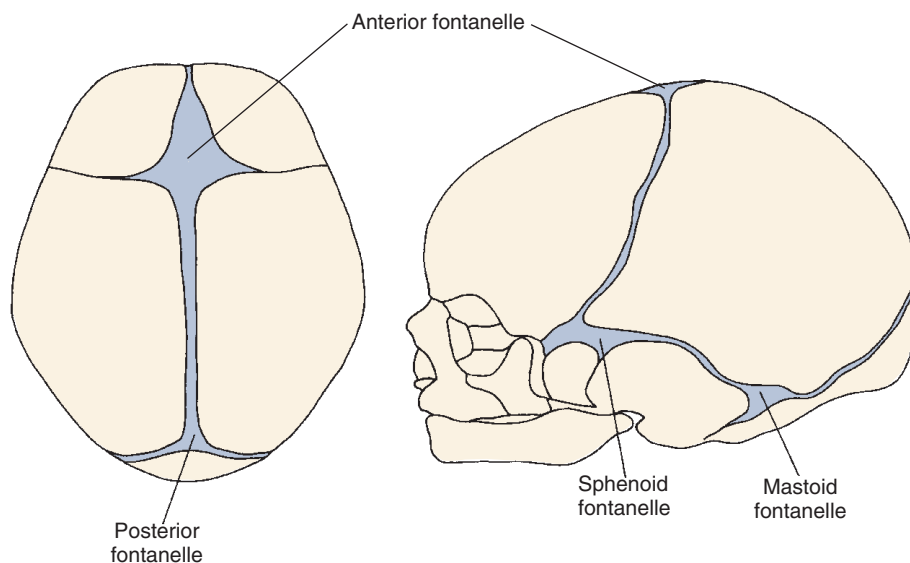
Despite their small size, apposition of new bone at these sutures is the major mechanism for growth of the cranial vault. Although the majority of growth in the cranial vault occurs at the sutures, there is a tendency for bone to be removed from the inner surface of the cranial vault, while at the same time new bone is added on the exterior surface. This modeling of the inner and outer surfaces allows for changes in contour during growth.

## Cranial Base

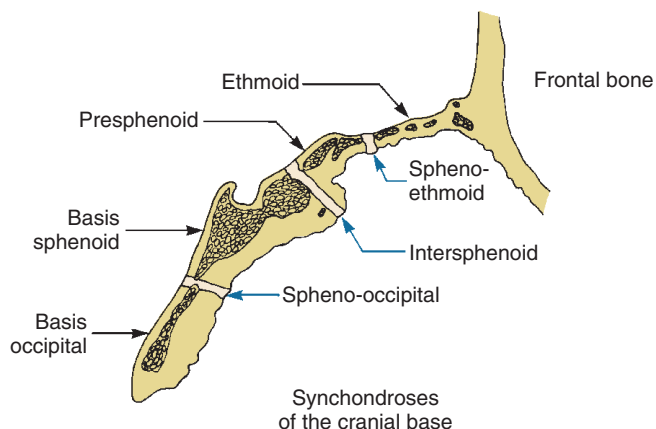
In contrast to the cranial vault, the bones of the base of the skull (the cranial base) are formed initially in cartilage and these cartilage models are later transformed into bone by endochondral ossification. The situation is more complicated, however, than in a long bone with its epiphyseal plates. The cartilage modeling is particularly true of the midline structures. As it moves laterally, growth at sutures and surface remodeling become more important.

As indicated previously, centers of ossification appear early in embryonic life in the chondrocranium, indicating the eventual location of the basioccipital, sphenoid, and ethmoid bones that form the cranial base. As ossification proceeds, bands of cartilage called *synchondroses* remain between the centers of ossification (Fig. 2.25). These important growth sites are the synchondrosis between the sphenoid and occipital bones, or *spheno-occipital synchondrosis*; the *intersphenoid synchondrosis* between two parts of the sphenoid bone; and the *spheno-ethmoidal synchondrosis* between the sphenoid and ethmoid bones. Histologically, a synchondrosis looks like a two-sided epiphyseal plate (Fig. 2.26). The synchondrosis has an area of cellular hyperplasia in the center with bands of maturing cartilage cells extending in both directions, which will eventually be replaced by bone.

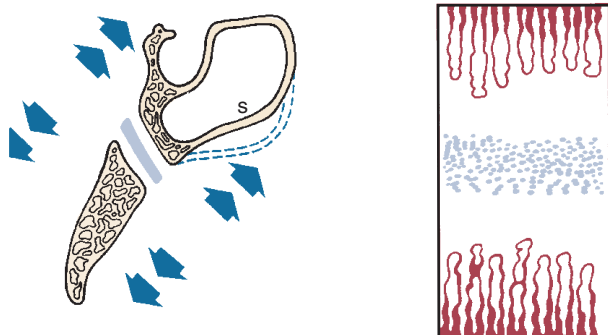
A significant difference from the bones of the extremities is that immovable joints develop between the bones of the cranial



• **Fig. 2.24** The fontanelles of the newborn skull (*blue*).



• **Fig. 2.25** Diagrammatic representation of the synchondroses of the cranial base, showing the locations of these important growth sites.



• **Fig. 2.26** Diagrammatic representation of growth at the intersphenoid synchondrosis. A band of immature proliferating cartilage cells is located at the center of the synchondrosis, a band of maturing cartilage cells extends in both directions away from the center, and endochondral ossification occurs at both margins. Growth at the synchondrosis lengthens this area of the cranial base. Even within the cranial base, bone remodeling on surfaces is also important—it is the mechanism by which the sphenoid sinus(es) enlarges, for instance.

base, in considerable contrast to the highly movable joints of the extremities. The cranial base is thus rather like a single long bone, except that there are multiple epiphyseal plate–like synchondroses. Immovable joints also occur between most of the other cranial and facial bones, the mandible being the only exception. The periosteum-lined sutures of the cranium and face, containing no cartilage, are quite different from the cartilaginous synchondroses of the cranial base.

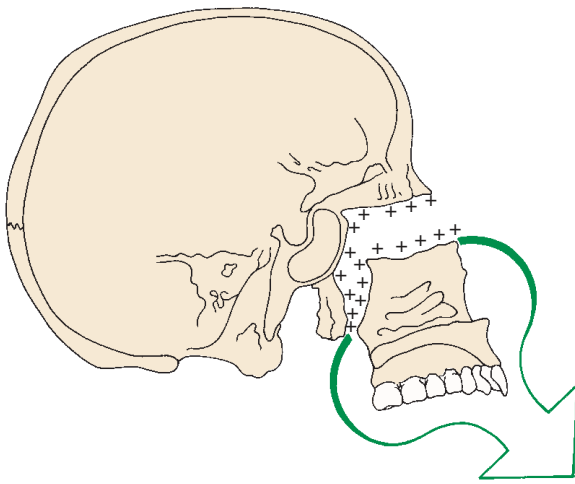
### Maxilla (Nasomaxillary Complex)

The maxilla develops postnatally entirely by intramembranous ossification. Because there is no cartilage replacement, growth occurs in two ways: (1) by apposition of bone at the sutures that connect the maxilla to the cranium and cranial base and (2) by surface modeling and remodeling. In contrast to the cranial vault, however, surface changes in the maxilla are quite dramatic and as important as changes at the sutures. In addition, the maxilla is moved forward by growth of the cranial base behind it.

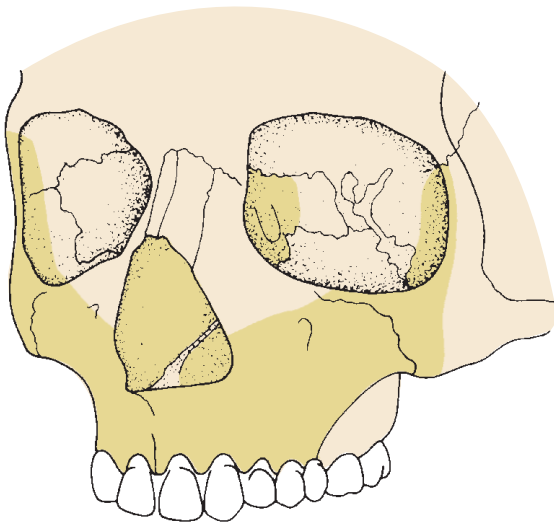
The growth pattern of the face requires that it grow “out from under the cranium,” which means that as it grows, the maxilla must move a considerable distance downward and forward relative to the cranium and cranial base. This is accomplished in two ways: (1) by a push from behind created by cranial base growth and (2) by growth at the sutures. Because the maxilla is attached to the anterior end of the cranial base, lengthening of the cranial base pushes it forward. Up until about age 6, displacement from cranial base growth is an important part of the maxilla’s forward growth. Failure of the cranial base to lengthen normally, as in achondroplasia (see Fig. 5.27) and several congenital syndromes, creates a characteristic midface deficiency. At about age 7, cranial base growth stops, and then sutural growth is the only mechanism for bringing the maxilla forward.

As Fig. 2.27 illustrates, the sutures attaching the maxilla posteriorly and superiorly are ideally situated to allow its downward and forward repositioning. As the downward and forward movement occurs, the space that would otherwise open up at the sutures is filled in by proliferation of bone at these locations. The sutures remain the same width, and the various processes of the maxilla





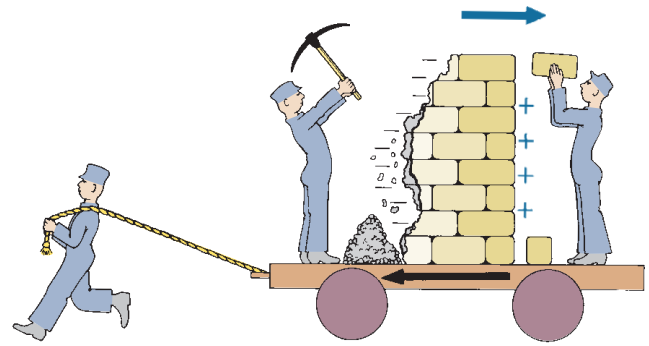
• **Fig. 2.27** As growth of surrounding soft tissues translates the maxilla downward and forward, opening up space at its superior and posterior sutural attachments, new bone is added on both sides of the sutures. (Redrawn from Enlow DH, Hans MG. *Essentials of Facial Growth*. Philadelphia: WB Saunders; 1996.)



• **Fig. 2.28** As the maxilla is carried downward and forward, its anterior surface tends to resorb. Resorption surfaces are shown here in dark yellow. Only a small area around the anterior nasal spine is an exception. (Redrawn from Enlow DH, Hans MG. *Essentials of Facial Growth*. Philadelphia: WB Saunders; 1996.)

become longer. Bone apposition occurs on both sides of a suture, so the bones to which the maxilla is attached also become larger. Part of the posterior border of the maxilla is a free surface in the tuberosity region. Bone is added at this surface, creating additional space into which the primary and then the permanent molar teeth successively erupt.

It is interesting to note that as the maxilla grows downward and forward, its front surfaces are remodeled, and bone is removed from most of the anterior surface. Note in Fig. 2.28 that almost the entire anterior surface of the maxilla is an area of resorption, not apposition. It might seem logical that if the anterior surface of the bone is moving downward and forward, this should be an



• **Fig. 2.29** Surface modeling of a bone in the opposite direction to that in which it is being translated by growth of adjacent structures creates a situation analogous to this cartoon, in which the wall is being rebuilt to move it backward at the same time the platform on which it is mounted is being moved forward. (Redrawn from Enlow DH, Hans MG. *Essentials of Facial Growth*. Philadelphia: WB Saunders; 1996.)

area to which bone is added, not one from which it is removed. The correct concept, however, is that bone is removed from the anterior surface, although the anterior surface is growing forward.

To understand this seeming paradox, it is necessary to comprehend that two quite different processes are going on simultaneously. The overall growth changes are the result of both a downward and forward translation of the maxilla and a simultaneous surface modeling. The whole bony nasomaxillary complex is moving downward and forward relative to the cranium, being translated in space. Enlow, whose careful anatomic studies of the facial skeleton underlie much of our present understanding, illustrated this in cartoon form (Fig. 2.29). The maxilla is like the platform on wheels, being rolled forward, while at the same time its surface, represented by the wall in the cartoon, is being reduced on its anterior side and built up posteriorly, moving in space opposite to the direction of overall growth.

It is not necessarily true that modeling changes oppose the direction of translation. Depending on the specific location, translation and modeling/remodeling may either oppose each other or produce an additive effect. The effect is additive, for instance, on the roof of the mouth. This area is carried downward and forward along with the rest of the maxilla, but at the same time, bone is removed on the nasal side and added on the oral side, thus creating an additional downward and forward movement of the palate (Fig. 2.30). Immediately adjacent, however, the anterior part of the alveolar process is a resorptive area, so removal of bone from the surface here tends to cancel some of the forward growth that otherwise would occur because of translation of the entire maxilla.

## Mandible

In contrast to the maxilla, both endochondral and periosteal activity are important in growth of the mandible, and displacement created by cranial base growth that moves the temporomandibular joint plays a negligible role (with rare exceptions; see Fig. 4.10). Cartilage covers the surface of the mandibular condyle at the temporomandibular joint. Although this cartilage is not like the cartilage at an epiphyseal plate or a synchondrosis, hyperplasia, hypertrophy, and endochondral replacement do occur there. All other areas of the mandible are formed and grow by direct surface apposition (modeling).

The overall pattern of growth of the mandible can be represented in two ways, as shown in Fig. 2.31. Depending on the frame of reference, both are correct. If the cranium is the reference area, the chin moves downward and forward. On the other hand, if data from vital staining experiments are examined, it becomes apparent that the principal sites of growth of the mandible are the posterior surface of the ramus and the condylar and coronoid processes. There is little change along the anterior part of the mandible. From this frame of reference, Fig. 2.31B, is the correct representation.

As a growth site, the chin is almost inactive. It is translated downward and forward, as the actual growth occurs at the mandibular condyle and along the posterior surface of the ramus. The body of the mandible grows longer by periosteal apposition of bone only on its posterior surface, while the ramus grows higher

by endochondral replacement at the condyle accompanied by surface modeling. Conceptually, it is correct to view the mandible as being translated downward and forward, while at the same time increasing in size by growing upward and backward. The translation occurs largely as the bone moves downward and forward along with the soft tissues in which it is embedded.

Nowhere is there a better example of modeling resorption than the backward movement of the ramus of the mandible. The mandible grows longer by apposition of new bone on the posterior surface of the ramus. At the same time, large quantities of bone are removed from the anterior surface of the ramus (Fig. 2.32). In essence, the body of the mandible grows longer as the ramus moves away from the chin, and this occurs by removal of bone from the anterior surface of the ramus and deposition of bone on the posterior surface. On first examination, one might expect a growth center somewhere underneath the teeth, so that the chin could grow forward away from the ramus. But a growth center in that area is not possible, because there is no cartilage and interstitial bone growth cannot occur. Instead, what was the posterior surface at one time becomes the center at a later date and eventually may become the anterior surface as modeling proceeds.

In infancy the ramus is located at about the spot where the primary first molar will erupt. Progressive posterior modeling and remodeling create space for the second primary molar and then for the sequential eruption of the permanent molar teeth. More often than not, however, this growth ceases before enough space has been created for eruption of the third permanent molar, which becomes impacted in the ramus.

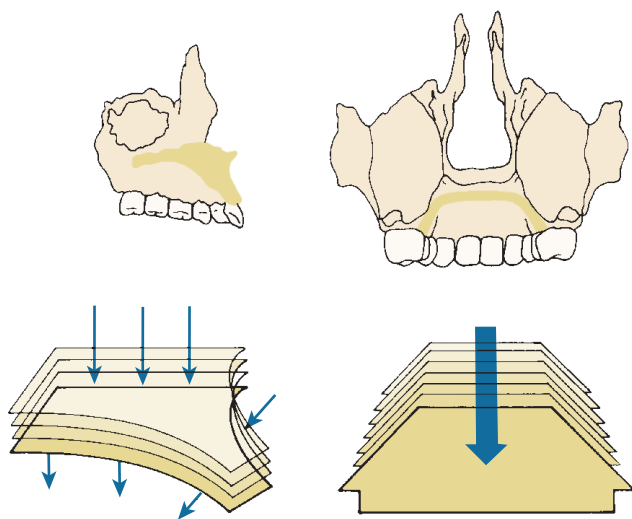
Further aspects of the growth of the jaws, especially in relation to the timing of orthodontic treatment, are discussed in Chapter 4.

## Facial Soft Tissues

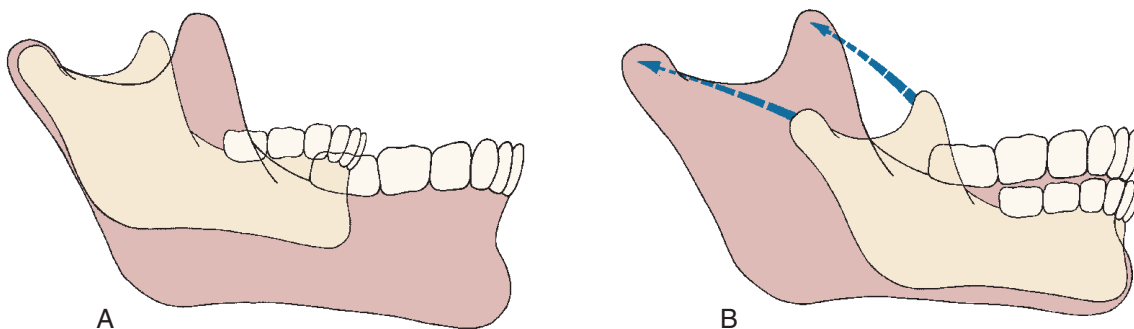
An important concept is that the growth of the facial soft tissues does not perfectly parallel the growth of the underlying hard tissues. Let us consider the growth of the lips and nose in more detail.

### Growth of the Lips

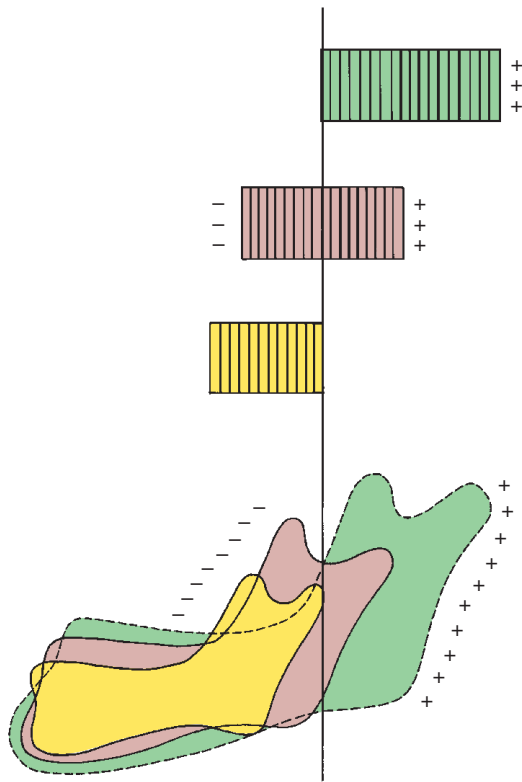
The lips trail behind the growth of the jaws before adolescence, then undergo a growth spurt to catch up. Because lip height is relatively short during the mixed dentition years, lip separation at rest (often termed *lip incompetence*) is maximal during childhood



• **Fig. 2.30** Modeling of the palatal vault (which is also the floor of the nose) moves it in the same direction as it is being translated; bone is removed from the floor of the nose and added to the roof of the mouth. On the anterior surface, however, bone is removed, partially canceling the forward translation. As the vault moves downward, the same process of bone remodeling also widens it. (Redrawn from Enlow DH, Hans MB. *Essentials of Facial Growth*. Philadelphia: WB Saunders; 1996.)



• **Fig. 2.31** (A) Growth of the mandible, as viewed from the perspective of a stable cranial base. The chin moves downward and forward. (B) Mandibular growth, as viewed from the perspective of vital staining studies, which reveal minimal changes in the body and chin area, while there is exceptional growth and modeling of the ramus, moving it posteriorly. The correct concept is that the mandible is translated downward and forward and grows upward and backward in response to this translation, maintaining its contact with the skull.



• **Fig. 2.32** As the mandible grows in length, the ramus is extensively modeled, so much so that bone at the tip of the condylar process at an early age can be found at the anterior surface of the ramus some years later. Given the extent of surface remodeling changes, it is an obvious error to emphasize endochondral bone formation at the condyle as the major mechanism for growth of the mandible. (Redrawn from Enlow DH, Hans MB. *Essentials of Facial Growth*. Philadelphia: WB Saunders; 1996.)

and decreases during adolescence (Fig. 2.33). Lip thickness reaches its maximum during adolescence, then decreases (Fig. 2.34)—to the point that in their 20s and 30s, some women consider loss of lip thickness a problem and seek treatment to increase it.

### Growth of the Nose

Growth of the nasal bone is complete at about age 10. Growth thereafter is only of the nasal cartilage and soft tissues, both of which undergo a considerable adolescent spurt. The result is that the nose becomes much more prominent at adolescence, especially in boys (Fig. 2.35). The lips are framed by the nose above and chin below, both of which become more prominent with adolescent and postadolescent growth, while the lips do not, so the relative prominence of the lips decreases. This can become an important point in determining how much lip support should be provided by the teeth at the time orthodontic treatment typically ends in late adolescence.

Changes in the facial soft tissues with aging, which also must be taken into consideration in planning orthodontic treatment, are covered in Chapter 4.

## Theories of Growth Control

It is a truism that growth is strongly influenced by genetic factors, but it also can be significantly affected by the environment in the form of nutritional status, degree of physical activity, health or

illness, and a number of similar factors. Because a major part of the need for orthodontic treatment is created by disproportionate growth of the jaws, in order to understand the etiologic processes of malocclusion and dentofacial deformity, it is necessary to learn how facial growth is influenced and controlled. Great strides have been made in recent years in improving the understanding of growth control. Exactly what determines the growth of the jaws, however, remains unclear and continues to be the subject of intensive research.

Three major theories in recent years have attempted to explain the determinants of craniofacial growth: (1) bone, like other tissues, is the primary determinant of its own growth; (2) cartilage is the primary determinant of skeletal growth, while bone responds secondarily and passively; and (3) the soft tissue matrix in which the skeletal elements are embedded is the primary determinant of growth, and both bone and cartilage are secondary followers.

The major difference in the theories is the location at which genetic control is expressed. The first theory implies that genetic control is expressed directly at the level of the bone; therefore its locus should be the periosteum. The second, or cartilage, theory suggests that genetic control is expressed in the cartilage, while bone responds passively to being displaced as cartilage grows. Indirect genetic control, whatever its source, is called *epigenetic*. The third theory assumes that genetic control is mediated to a large extent outside the skeletal system and that growth of both bone and cartilage is controlled epigenetically, occurring only in response to a signal from other tissues. In contemporary thought, the truth is to be found in some synthesis of the second and third theories; the first, although it was the dominant view until the 1960s, has largely been discarded.

### Level of Growth Control: Sites Versus Centers of Growth

Distinguishing between a *site* of growth and a *center* of growth clarifies the differences between the theories of growth control. A site of growth is merely a location at which growth occurs, whereas a center is a location at which independent (genetically controlled) growth occurs. All centers of growth also are sites, but the reverse is not true. A major impetus to the theory that the tissues that form bone carry with them their own stimulus to do so came from the observation that the overall pattern of craniofacial growth is remarkably constant. This constancy of the growth pattern was interpreted to mean that the major sites of growth were also centers. In particular, the sutures between the membranous bones of the cranium and jaws were considered growth centers, along with the sites of endochondral ossification in the cranial base and at the mandibular condyle. Growth, in this view, was the result of the expression at all these sites of a genetic program. The mechanism for translation of the maxilla, therefore, was considered to be the result of pressure created by growth of the sutures, so that the maxilla was literally pushed downward and forward.

If this theory were correct, growth at the sutures should occur largely independently of the environment and it would not be possible to change the expression of growth at the sutures very much. While this was the dominant theory of growth, few attempts were made to modify facial growth because orthodontists “knew” that it could not be done.

It is clear now that sutures, and the periosteal tissues more generally, are not primary determinants of craniofacial growth. Two lines of evidence lead to this conclusion. The first is that when an area of the suture between two facial bones is transplanted



• **Fig. 2.33** Growth of the lips trails behind growth of the facial skeleton until puberty, then catches up and tends to exceed skeletal growth thereafter. As a result, lip separation and exposure of the maxillary incisors is maximal before adolescence and decreases during adolescence and early adult life. (A) Age 11-9, prior to puberty. (B) Age 14-8, after the adolescent growth spurt. (C) Age 16-11. (D) Age 18-6.

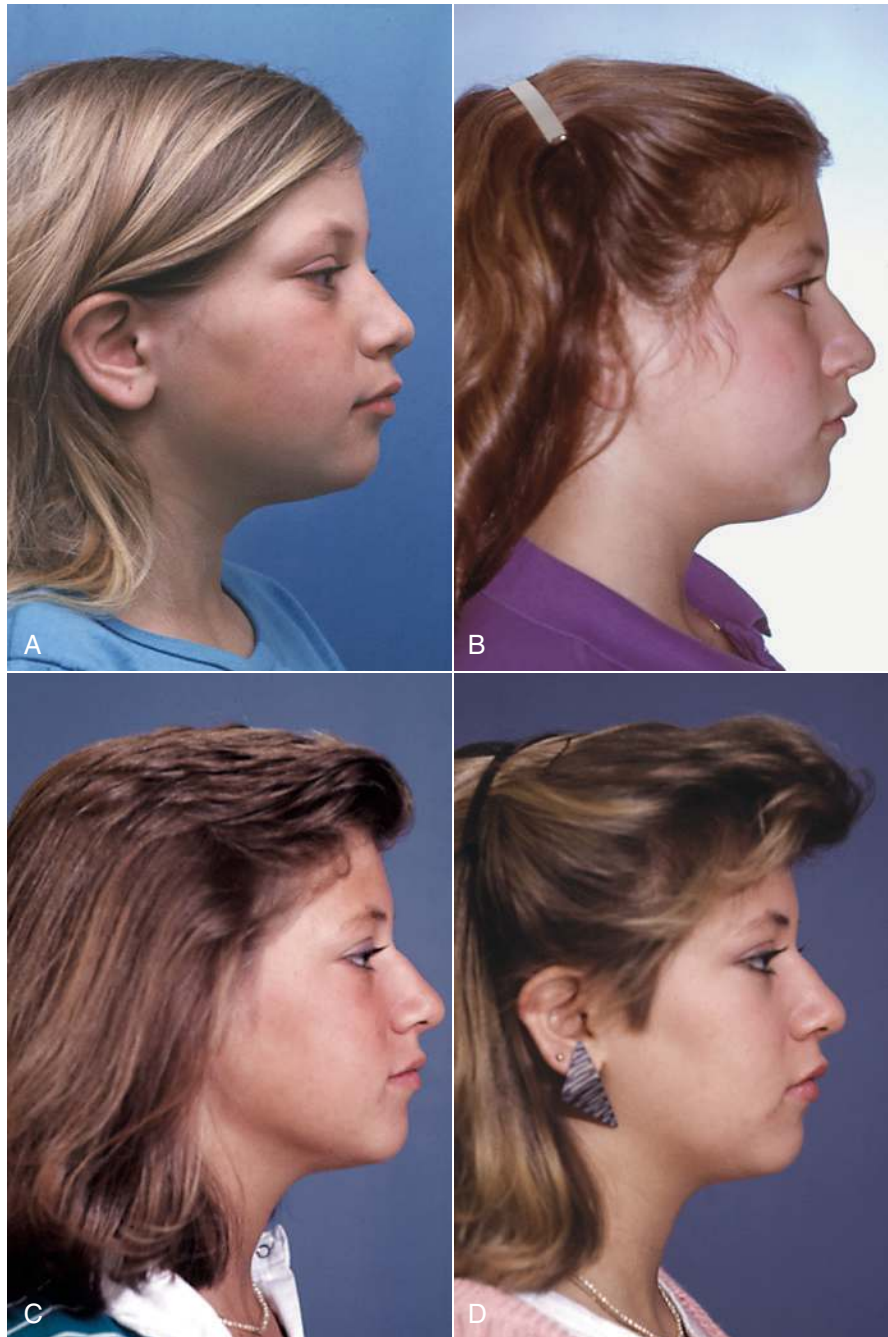to another location (to a pouch in the abdomen, for instance), the sutural tissue does not continue to grow. This indicates a lack of innate growth potential in the sutures. Second, it can be seen that growth at sutures will respond to outside influences under a number of circumstances. If cranial or facial bones are mechanically pulled apart at the sutures, new bone will fill in, and the bones will become larger than they would have been otherwise (see Fig. 2.27). If a suture is compressed, growth at that site will be impeded. Thus sutures must be considered areas that react—not primary determinants. The sutures of the cranial vault,

lateral cranial base, and maxilla are sites of growth but are not growth centers.

### Cartilage as a Determinant of Craniofacial Growth

The second major theory is that the determinant of craniofacial growth is growth of cartilage. The fact that, for many bones, cartilage does the growing while bone merely replaces it makes this theory attractive for the bones of the jaws. If cartilaginous growth were





• **Fig. 2.34** Lip thickness increases during the adolescent growth spurt, then decreases (and therefore is maximal at surprisingly early ages). For some girls, loss of lip thickness is perceived as a problem by their early 20s. (A) Age 11-9, prior to puberty. (B) Age 14-8, after the adolescent growth spurt. (C) Age 16-11. (D) Age 18-6.

the primary influence, the cartilage at the condyle of the mandible could be considered as a pacemaker for growth of that bone and the modeling of the ramus and other surface changes could be viewed as secondary to the primary cartilaginous growth.

One way to visualize the mandible is by imagining that it is like the diaphysis of a long bone, bent into a horseshoe with the epiphyses removed, so that there is cartilage representing “half an epiphyseal plate” at the ends, which represent the mandibular condyles (Fig. 2.36). If this were the true situation, then indeed the cartilage at the mandibular condyle should act as a growth

center, behaving basically like an epiphyseal growth cartilage. From this perspective, the mechanism of downward and forward growth of the mandible would be a “cartilage push” from growth at the condyle.

Growth of the maxilla is more difficult but not impossible to explain on a cartilage theory basis. Although there is no cartilage in the maxilla itself, there is cartilage in the nasal septum, and the nasomaxillary complex grows as a unit. Proponents of the cartilage theory hypothesize that the cartilaginous nasal septum serves as a pacemaker for other aspects of maxillary growth. Note in Fig. 2.37



• **Fig. 2.35** The nasal bone grows up until about age 10, but after age 10, growth of the nose is largely in the cartilaginous and soft tissue portions. Especially in boys, the nose becomes much more prominent as growth continues after the adolescent growth spurt (and this process continues into the adult years). (A) Age 4-9. (B) Age 12-4. (C) Age 14-8. (D) Age 17-8.

that the cartilage is located so that its growth could easily be the model for downward and forward translation of the maxilla. If the sutures of the maxilla served as reactive areas, they would respond to the nasal cartilage growth by forming new bone when the sutures were pulled apart by forces from the growing cartilage. A small area of cartilage would have to influence a large area of sutures, but such a pacemaker role is certainly possible. The mechanism for maxillary growth would be at first a forward push from lengthening of the cranial base, then a forward pull from the nasal cartilage.

Two kinds of experiments have been carried out to test the idea that cartilage can serve as a true growth center. These involve an

analysis of the results of transplanting cartilage and an evaluation of the effect on growth of removing cartilage at an early age.

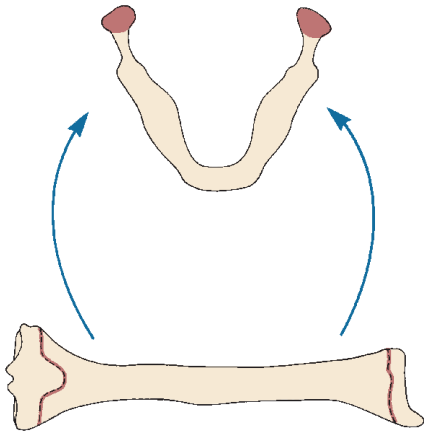
Transplantation experiments demonstrate that not all skeletal cartilage acts the same when transplanted. If a piece of the epiphyseal plate of a long bone is transplanted, it will continue to grow in a new location or in culture, indicating that these cartilages do have innate growth potential. Cartilage from the spheno-occipital synchondrosis of the cranial base also grows when transplanted, but not as well. It is difficult to obtain cartilage from the cranial base to transplant, particularly at an early age when the cartilage is actively growing under normal conditions. Perhaps this explains why it does not grow in vitro as much as epiphyseal plate cartilage.

In early experiments, transplanting cartilage from the nasal septum gave equivocal results—sometimes it grew, sometimes it did not. In more precise later experiments, however, nasal septal cartilage was found to grow nearly as well in culture as epiphyseal plate cartilage.<sup>11</sup> Little or no growth was observed when the mandibular condyle was transplanted, and cartilage from the mandibular condyle showed significantly less growth in culture than the other cartilages.<sup>12</sup> From these experiments, the other cartilages appear capable of acting as growth centers, but the mandibular condylar cartilage does not.

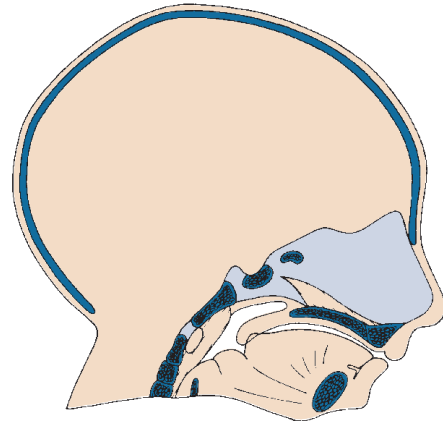
Experiments to test the effect of removing cartilages are also informative. The basic idea is that if removing a cartilaginous area

stops or diminishes growth, perhaps it really was an important center for growth. In rodents, removing a segment of the cartilaginous nasal septum causes a considerable deficit in growth of the midface. It does not necessarily follow, however, that the entire effect on growth in such experiments results from loss of the cartilage. It can be argued that the surgery itself and the accompanying interference with blood supply to the area, not the loss of the cartilage, cause the growth changes.

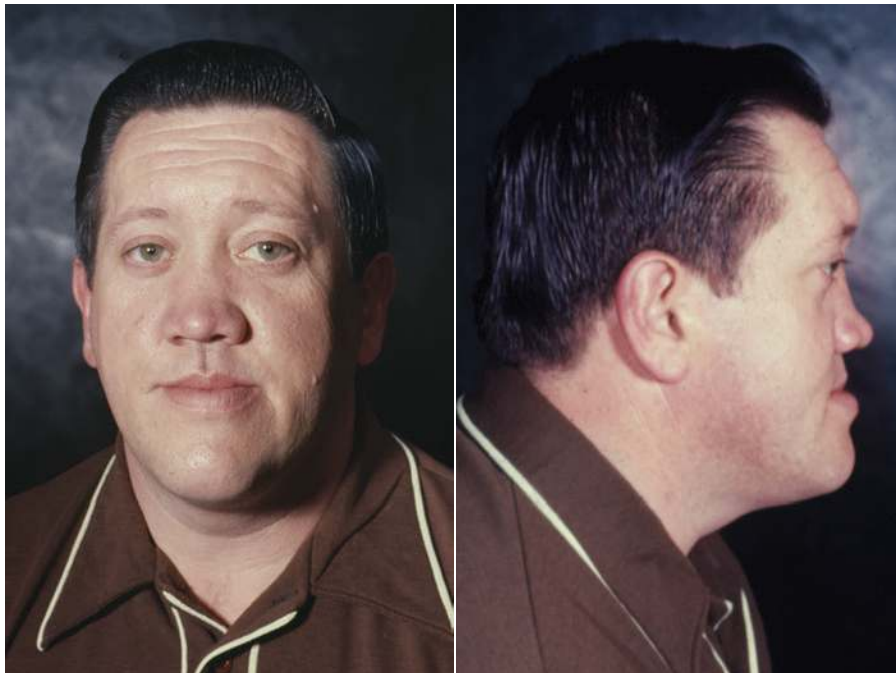There are few reported cases of early loss of the cartilaginous nasal septum in humans. One individual in whom the entire septum was removed at age 8 after an injury is shown in Fig. 2.38. It is apparent that a midface deficiency developed, but one cannot



• **Fig. 2.36** The mandible was once viewed conceptually as being analogous to a long bone that had been modified by (1) removal of the epiphysis, leaving the epiphyseal plates exposed, and (2) bending of the shaft into a horseshoe shape. If this analogy were correct, of course, the cartilage at the mandibular condyles should behave like true growth cartilage. Modern experiments indicate that although the analogy is attractive, it is incorrect.



• **Fig. 2.37** Diagrammatic representation of the chondrocranium at an early stage of development, showing the large amount of cartilage in the anterior region that eventually becomes the much smaller cartilaginous nasal septum—not because it shrank, but because adjacent tissues grew more.



• **Fig. 2.38** Profile view of a man whose cartilaginous nasal septum was removed at age 8, after an injury. The obvious midface deficiency developed after the septum was removed.

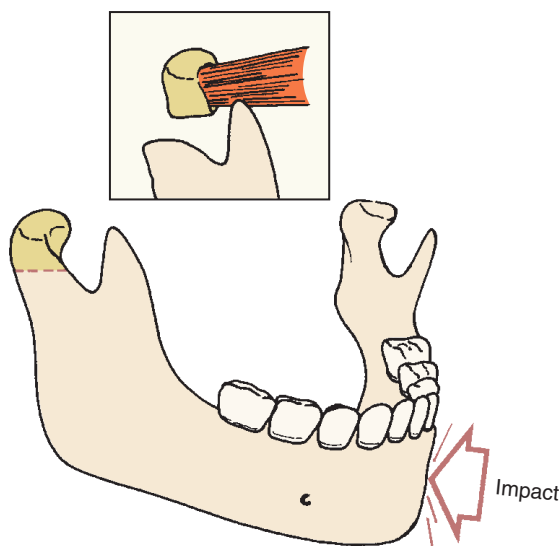


confidently attribute this to the loss of the cartilage. Nevertheless, the loss of growth in experimental animals when this cartilage is removed is great enough to lead most observers to conclude that the septal cartilage does have some innate growth potential and that its loss makes a difference in maxillary growth. The rare human cases support this view.

The neck of the mandibular condyle is a relatively fragile area. When the side of the jaw is struck sharply, the mandible often fractures just below the opposite condyle. When this happens, the condyle fragment is usually retracted well away from its previous location by the pull of the lateral pterygoid muscle (Fig. 2.39). The condyle literally has been removed when this occurs, and it resorbs over a period of time. Condylar fractures occur relatively frequently in children. If the condyle were an important growth center, one would expect to see severe growth impairment after such an injury at an early age. If so, surgical intervention to locate the condylar segment and put it back into position would be the logical treatment.

Two excellent studies carried out in Scandinavia disproved this concept. Both Gilhuus-Moe<sup>13</sup> and Lund<sup>14</sup> demonstrated that after fracture of the mandibular condyle in a child, there was an excellent chance that the condylar process would regenerate to approximately its original size and a small chance that it would overgrow after the injury. In experimental animals and in children, after a fracture, all of the original bone and cartilage resorb, and a new condyle regenerates directly from periosteum at the fracture site (Fig. 2.40). Eventually, at least in experimental animals, a new layer of cartilage forms at the condylar surface. Although there is no direct evidence that the cartilage layer itself regenerates in children after condylar fractures, it is likely that this occurs in humans also.

However, in 15% to 20% of the Scandinavian children studied who sustained a condylar fracture, there was a reduction in growth after the injury. This growth reduction seems to relate to the amount of trauma to the soft tissues and the resultant scarring in the area. The mechanism by which this occurs is discussed in the following section.



• **Fig. 2.39** A blow to one side of the mandible may fracture the condylar process on the opposite side. When this happens, the pull of the lateral pterygoid muscle distracts the condylar fragment, including all the cartilage, and it subsequently resorbs.

In summary, it appears that epiphyseal cartilages and (probably) the cranial base synchondroses can and do act as independently growing centers, as can the nasal septum (perhaps to a lesser extent). Transplantation experiments and experiments in which the condyle is removed lend no support to the idea that the cartilage of the mandibular condyle is an important growth center and neither do studies of the cartilage itself in comparison to primary growth cartilage. It appears that growth at the mandibular condyles is much more analogous to growth at the sutures of the maxilla—which is entirely reactive—than to growth at an epiphyseal plate.

## Functional Matrix Theory of Growth

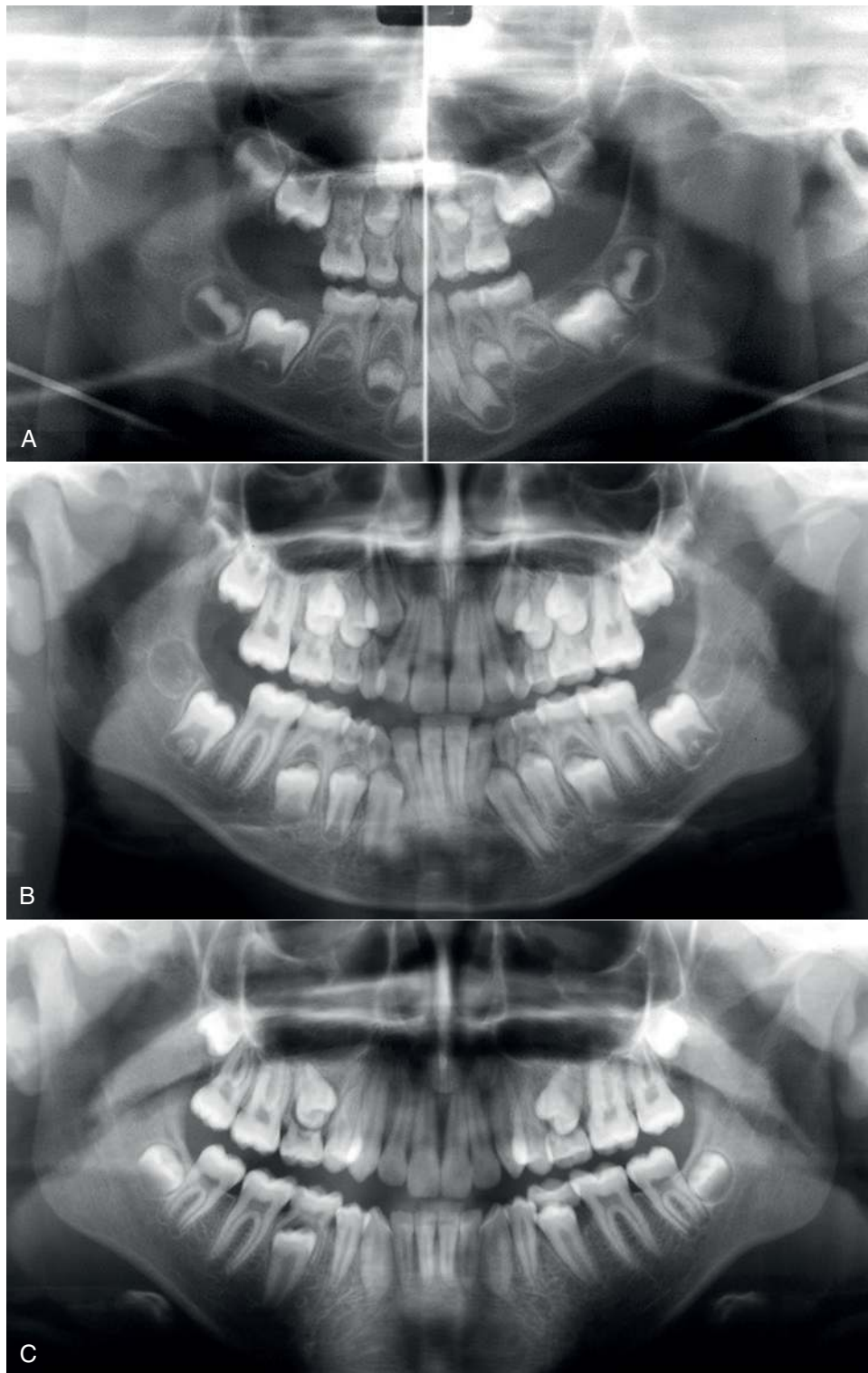
If neither bone nor cartilage is the determinant for growth of the craniofacial skeleton, it would appear that the control would have to lie in the adjacent soft tissues. This point of view was introduced formally in the 1960s by Melvin Moss in his “functional matrix theory” of growth and was reviewed and updated by him in the 1990s.<sup>15</sup> While granting the innate growth potential of cartilages of the long bones, his theory holds that neither the cartilage of the mandibular condyle nor the cartilaginous nasal septum is a determinant of jaw growth. Instead, he theorized that growth of the face occurs as a response to functional needs and neurotrophic influences and is mediated by the soft tissue in which the jaws are embedded. In this conceptual view, the soft tissues grow, and both bone and cartilage react to this form of epigenetic control.

The growth of the cranium illustrates this view of skeletal growth very well. There can be little question that the growth of the cranial vault is a direct response to the growth of the brain. Pressure exerted by the growing brain separates the cranial bones at the sutures, and new bone passively fills in at these sites so that the brain case fits the brain.

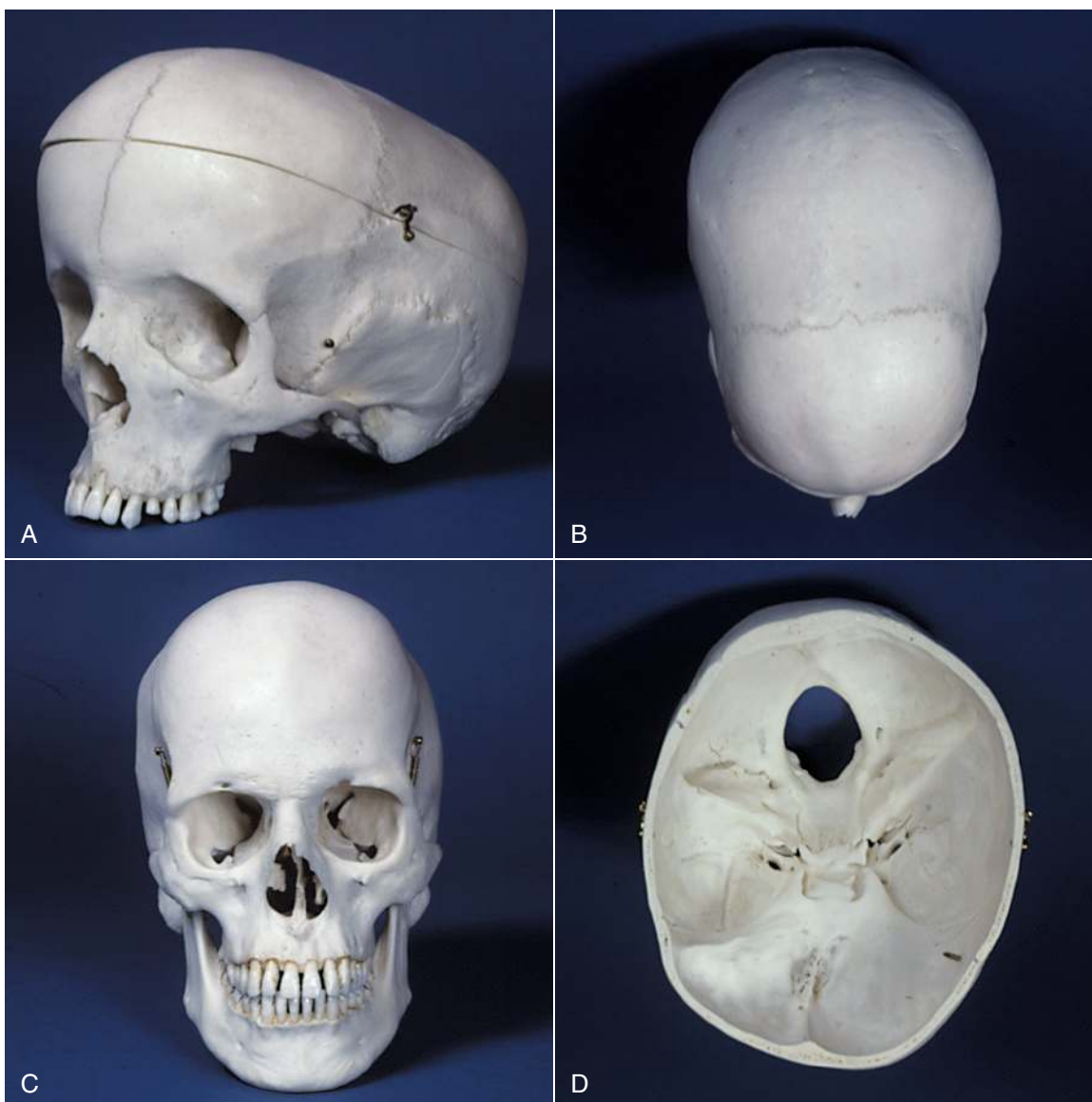This phenomenon can be seen readily in humans in two experiments of nature (Fig. 2.41). First, when the brain is very small, the cranium is also very small, and the result is microcephaly (which is now seen much more frequently because of Zika virus infections in pregnant women that interfere with neural growth in the fetus). In this case, the size of the head is an accurate representation of the size of the brain. A second natural experiment is hydrocephaly. In this case, reabsorption of cerebrospinal fluid is impeded, the fluid accumulates, and intracranial pressure builds up. The increased intracranial pressure impedes development of the brain, so the hydrocephalic may have a small brain and be mentally retarded; but this condition also leads to an enormous growth of the cranial vault. Uncontrolled hydrocephaly may lead to a cranium two or three times its normal size, with enormously enlarged frontal, parietal, and occipital bones. This is perhaps the clearest example of a “functional matrix” in operation. Another excellent example is the relationship between the size of the eye and the size of the orbit. An enlarged eye or a small eye will cause a corresponding change in the size of the orbital cavity. In this instance, the eye is the functional matrix.

Moss theorized that the major determinant of growth of the maxilla and mandible is the enlargement of the nasal and oral cavities, which grow in response to functional needs. The theory does not make it clear how functional needs are transmitted to the tissues around the mouth and nose, but it does predict that the cartilages of the nasal septum and mandibular condyles are not important determinants of growth, and that their loss would have little effect on growth if proper function could be obtained. From the view of this theory, however, absence of normal function would have wide-ranging effects.





• **Fig. 2.40** After a condylar fracture and resorption of the condyle, regeneration of a new condyle is quite possible in humans. Whether it occurs is a function of the severity of the soft tissue injury that accompanied the fracture. (A) Age 5, at the time mandibular asymmetry was noticed on a routine dental visit. Note that the left condylar process is missing. The history included a fall at age 2 with a blow to the chin that created a condylar fracture, with no regeneration up to that time. (B) Age 8, after treatment with an asymmetric functional appliance that led to growth on the affected side and a reduction in the asymmetry. (C) Age 14, at the end of the adolescent growth spurt. Regeneration of a condyle on the affected side is apparent in (B) and (C).



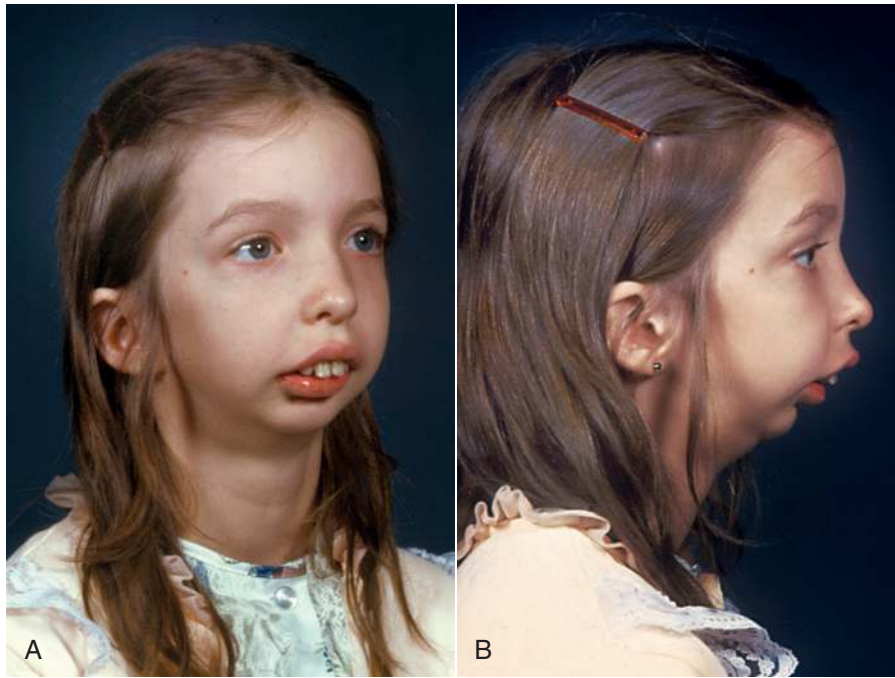• **Fig. 2.41** (A) The skull of a young child who had hydrocephaly. Note the tremendous enlargement of the brain case in response to the increased intracranial pressure. (B) and (C) Superior and front views of the skull of an individual with scaphocephaly, in which the midsagittal suture fuses prematurely. Note the absence of the midsagittal suture and the extremely narrow width of the cranium. In compensation for its inability to grow laterally, the brain and brain case have become abnormally long posteriorly. (D) Cranial base of an individual with premature fusion of sutures on the right side, leading to a marked asymmetry that affected both the cranium and cranial base.

We have already noted that in 75% to 80% of human children who sustain a condylar fracture, the resulting loss of the condyle does not impede mandibular growth. The condyle regenerates very nicely. What about the 20% to 25% of children in whom a growth deficit occurs after condylar fracture? Could some interference with function be the reason for the growth deficiency?

The answer seems to be a clear *yes*. It has been known for many years that mandibular growth is greatly impaired by ankylosis at the temporomandibular joint (see [Fig. 2.39](#)), defined as fusion across the joint so that motion is prevented (which totally stops growth) or limited (which impedes growth). Mandibular ankylosis can develop in a number of ways. For instance, one possible cause

is a severe infection in the area of the joint, leading to destruction of tissues and ultimate scarring ([Fig. 2.42](#)). Another cause, of course, is trauma, which can result in a growth deficiency if there is enough soft tissue injury to lead to scarring that impedes motion as the injury heals. This mechanical restriction impedes translation of the mandible as the adjacent soft tissues grow and leads to decreased growth.

It is interesting and potentially quite significant clinically that under some circumstances, bone can be induced to grow at surgically created sites by the method called *distraction osteogenesis* ([Fig. 2.43](#)). The Russian surgeon Ilizarov discovered in the 1950s that if cuts were made through the cortex of a long bone of the limbs, the arm or leg then could be lengthened by tension to separate



• **Fig. 2.42** Oblique (A) and profile (B) views of a girl in whom a severe infection of the mastoid air cells involved the temporomandibular joint and led to ankylosis of the mandible. The resulting restriction of mandibular growth is apparent.

**TABLE 2.1** Growth of Craniofacial Units

Growth	Cranial Vault	Cranial Base	Maxilla	Mandible
Sites	Sutures (major) Surfaces (minor)	Synchondroses Sutures (laterally)	Sutures Surfaces: apposition remodeling	Condyle Ramus Other surfaces
Centers	None	Synchondroses	None	None
Type (mode)	Mesenchymal	Endochondral Mesenchymal (lateral only)	Mesenchymal	Endochondral (condyle only) Mesenchymal
Mechanism	Pressure to separate sutures	Interstitial growth at synchondroses	Cartilage push (cranial base) Soft tissue pull Cartilage pull? (nasal septum)	Soft tissue pull (neurotrophic?)
Determinant	Intracranial pressure (brain growth)	Genetic (at synchondroses) Cartilage pull (at lateral sutures)	Soft tissue pull (neurotrophic?)	Soft tissue pull (neurotrophic?)

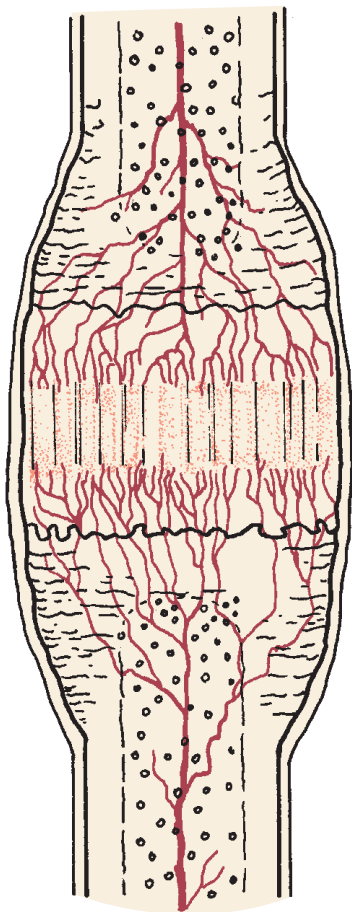
the bony segments. Current research shows that the best results are obtained if tension across the bone injury site starts after a few days of initial healing and callus formation, not immediately, and if the segments are separated at a rate of 0.5 to 1.5 mm per day. Surprisingly, large amounts of new bone can form at the surgical site, lengthening the arm or leg by several centimeters in some cases. Distraction osteogenesis now is widely used to correct limb deformities, especially after injury but also in patients with congenital problems.

The bone of the mandible is quite similar in its internal structure to the bone of the limbs, even though its developmental course is rather different. Lengthening the mandible via distraction osteogenesis clearly is possible (Fig. 2.44), and major changes in mandibular length (a centimeter or more) are managed best in

this way. Precise positioning of the jaw is not possible, however, so conventional orthognathic surgery remains the preferred way to treat mandibular deficiency. In a sense, inducing maxillary growth by separating cranial and facial bones at their sutures is a distraction method. Manipulating maxillary growth by influencing growth at the sutures has been a major part of orthodontic treatment for many years, and this can be done at later ages with surgical assistance as a distraction osteogenesis procedure. The current status of distraction osteogenesis as a method to correct deficient growth in the face and jaws is reviewed in some detail in [Chapter 20](#).

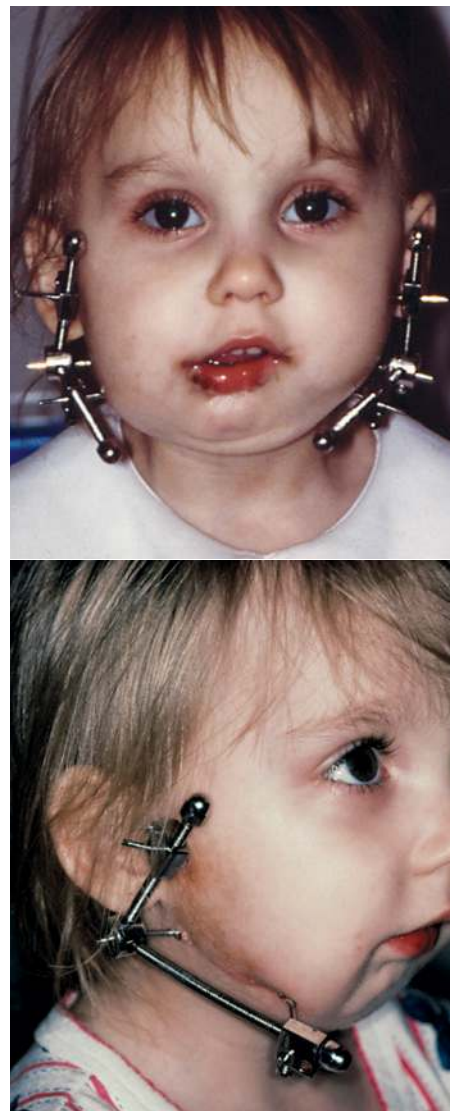In summary, it appears that growth of the cranium occurs almost entirely in response to growth of the brain (Table 2.1). Growth of the cranial base is primarily the result of endochondral growth and bony replacement at the synchondroses, which have





• **Fig. 2.43** Diagrammatic representation of distraction osteogenesis in a long bone. The drawing represents the situation after bone cuts through the cortex, undisturbed initial healing for 3 to 5 days (latency period), and then a few days of distraction. In the center, there is a fibrous radiolucent interzone with longitudinally oriented collagen bundles in the area where lengthening of the bone is occurring. Proliferating fibroblasts and undifferentiated mesenchymal cells are found throughout this area. Osteoblasts appear at the edge of the interzone. On both sides of the interzone, a rich blood supply is present in a zone of mineralization. Beneath that, a zone of remodeling exists. This sequence of formation of a stretched collagen matrix, mineralization, and remodeling is typical of distraction osteogenesis. (Redrawn from Samchukov M, et al. In: McNamara J, Trotman C, eds. *Distraction Osteogenesis and Tissue Engineering*. Ann Arbor, MI: The University of Michigan Center for Human Growth and Development; 1998.)

independent growth potential but perhaps are influenced by the growth of the brain. Growth of the maxilla and its associated structures occurs from a combination of growth at sutures and modeling of the surfaces of the bone. The maxilla is translated downward and forward as the face grows, and new bone fills in at the sutures. The extent to which growth of cartilage of the nasal septum leads to translation of the maxilla remains unknown, but both the surrounding soft tissues and this cartilage probably contribute to the forward repositioning of the maxilla. Growth of the mandible occurs by both endochondral proliferation at the condyle and apposition and resorption of bone at surfaces. It seems clear that the mandible is translated in space by the growth of muscles and other adjacent soft tissues and that addition of new bone at the condyle is in response to the soft tissue changes.



• **Fig. 2.44** External fixation for lengthening the mandible by distraction osteogenesis in a child with severe asymmetric mandibular deficiency secondary to injury at an early age. Because external fixation for mandibular distraction leaves scars on the face, it is rarely used now.

## Social and Behavioral Development

*F.T. McIver, W.R. Proffit*

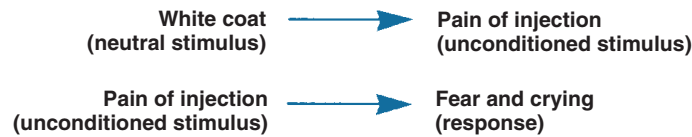
Physical growth can be considered the outcome of an interaction between genetically controlled cell proliferation and environmental influences that modify the genetic program. Similarly, behavior can be viewed as the result of an interaction between innate or instinctual behavioral patterns and behaviors learned after birth. In animals, it appears that the majority of behaviors are instinctive, although even lower animals are capable of a degree of learned behavior. In humans, on the other hand, it is generally conceded that the great majority of behaviors are learned.

For this reason, it is less easy to construct stages of behavioral development in humans than stages of physical development. The

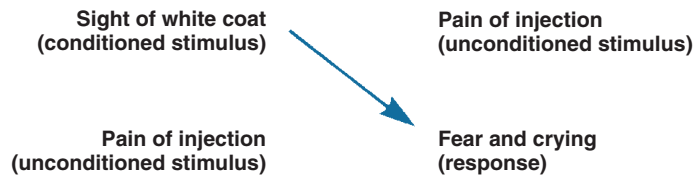


## CLASSICAL CONDITIONING

### First visit



### Second visit



• **Fig. 2.45** Classical conditioning causes an originally neutral stimulus to become associated with one that leads to a specific reaction. If individuals in white coats are the ones who give painful injections that cause crying, the sight of an individual in a white coat soon may provoke an outburst of crying.

higher proportion of learned behavior means that what might be considered environmental effects can greatly modify behavior. On the other hand, there are human instinctual behaviors (e.g., the sex drive), and in a sense the outcome of behavior hinges on how the instinctual behavioral urges have been modified by learning. As a general rule, the older the individual, the more complex the behavioral pattern and the more important the learned overlay of behavior will be.

In this section, a brief overview of social, cognitive, and behavioral development is presented, greatly simplifying a complex subject and emphasizing the evaluation and management of children who will be receiving dental and orthodontic treatment. First, the process by which behavior can be learned is presented. Second, the structural substrate of behavior will be reviewed. This appears to relate both to the organization of the nervous system at various stages and to emotional components underlying the expression of behavior. The relevance of the theoretical concepts to the day-to-day treatment of patients is emphasized.

## Learning and the Development of Behavior

The basic mechanisms of learning appear to be essentially the same at all ages. As learning proceeds, more complex skills and behaviors appear, but it is difficult to define the process in distinct stages—a continuous flow model appears more appropriate. It is important to remember that this discussion is of the development of behavioral patterns, not the acquisition of knowledge or intellectual skills in the academic sense.

At present, psychologists generally consider that there are three distinct mechanisms by which behavioral responses are learned: (1) classical conditioning, (2) operant conditioning, and (3) observational learning.

### Classical Conditioning

Classical conditioning was first described by the Russian physiologist Ivan Pavlov, who discovered in the 19th century during his studies

of reflexes that apparently unassociated stimuli could produce reflexive behavior. Pavlov's classic experiments involved the presentation of food to a hungry animal, along with some other stimulus, for example, the ringing of a bell. The sight and sound of food normally elicit salivation by a reflex mechanism. If a bell is rung each time food is presented, the auditory stimulus of the ringing bell will become associated with the food presentation stimulus, and in a relatively short time, the ringing of a bell by itself will elicit salivation. Classical conditioning, then, operates by the simple process of association of one stimulus with another (Fig. 2.45). For that reason, this mode of learning is sometimes referred to as *learning by association*.

Classical conditioning occurs readily with young children and can have a considerable impact on a young child's behavior on the first visit to a dental office. By the time a child is brought for the first visit to a dentist, even if that visit is at an early age, it is highly likely that he or she will have had many experiences with pediatricians and medical personnel. When a child experiences pain, the reflex reaction is crying and withdrawal. In pavlovian terms, the infliction of pain is an unconditioned stimulus, but a number of aspects of the setting in which the pain occurs can come to be associated with this unconditioned stimulus.

For instance, it is unusual for a child to encounter people who are dressed entirely in white uniforms or long white coats. If the unconditioned stimulus of painful treatment comes to be associated with the conditioned stimulus of white coats, a child may cry and withdraw immediately at the first sight of a white-coated dentist or dental assistant. In this case, the child has learned to associate the conditioned stimulus of pain and the unconditioned stimulus of a white-coated adult, and the mere sight of the white coat is enough to produce the reflex behavior initially associated with pain.

Associations of this type tend to become generalized. Painful and unpleasant experiences associated with medical treatment can become generalized to the atmosphere of a physician's office, so

that the whole atmosphere of a waiting room, receptionist, and other waiting children may produce crying and withdrawal after several experiences in the physician's office, even if there is no sign of a white coat.

Because of this association, behavior management in the dentist's office is easier if the dental office looks as little like the typical pediatrician's office or hospital clinic as possible. In practices where the dentist and auxiliaries work with young children, it helps in reducing children's anxiety if the appearance of the doctor and staff is different from that associated with the physician (Fig. 2.46). It also helps if the child's first visit is different from the previous visits to the physician. Treatment that might produce pain should be avoided if at all possible on the first visit to the dental office.

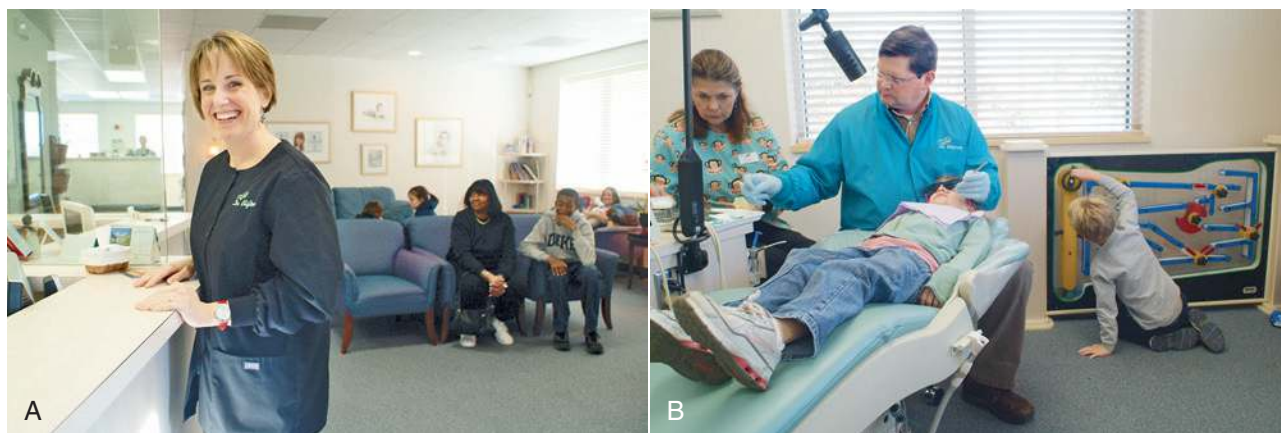The association between a conditioned and an unconditioned stimulus is strengthened or reinforced every time they occur together (Fig. 2.47). Every time a child is taken to a hospital clinic where something painful is done, the association between pain and the general atmosphere of that clinic becomes stronger, as the child becomes more sure of his conclusion that bad things happen in such a place. Conversely, if the association between a conditioned and an unconditioned stimulus is not reinforced, the association between them will become less strong, and eventually, the conditioned response will no longer occur. This phenomenon is referred to as *extinction of the conditioned behavior*. This is the basis for a

"happy visit" to the dentist following a stressful visit. Once a conditioned response has been established, it is necessary to reinforce it only occasionally to maintain it. If the conditioned association of pain with the doctor's office is strong, it can take many visits without unpleasant experiences and pain to extinguish the associated crying and avoidance.

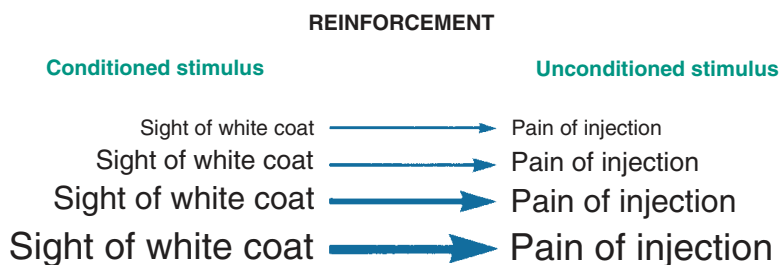
The opposite of generalization of a conditioned stimulus is discrimination. The conditioned association of white coats with pain can easily be generalized to any office setting. If a child is taken into other office settings that are somewhat different from the one where painful things happen, a dental office, for instance, where painful injections are not necessary, discrimination between the two types of offices soon will develop, and the generalized response to any office as a place where painful things occur will be extinguished.

### Operant Conditioning

Operant conditioning, which can be viewed conceptually as a significant extension of classical conditioning, was emphasized by the preeminent behavioral theorist of recent years, B.F. Skinner. Skinner contended that the most complex human behaviors can be explained by operant conditioning. His theories, which downplay the role of the individual's conscious determination in favor of unconscious determined behavior, have met with much resistance



• **Fig. 2.46** (A) As a new child patient enters this orthodontic-pediatric dentistry practice, both the setting and the appearance of the doctor who is saying hello deliberately look nothing like the outpatient clinic at the hospital where bad things might have happened previously. (B) As this boy awaits his turn, having been invited into the treatment area to see what it is like, his sister is being examined. If this is his first trip to the office, nothing that is potentially painful will be done.



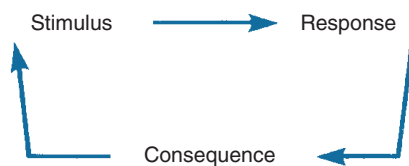• **Fig. 2.47** Every time they occur, the association between a conditioned and unconditioned stimulus is strengthened. This process is called *reinforcement*.

but have been remarkably successful in explaining many aspects of social behavior far too complicated to be understood from the perspective of classical conditioning.

Because the theory of operant conditioning explains—or attempts to explain—complex behavior, it is not surprising that the theory itself is more complex. Although it is not possible to explore operant conditioning in any detail here, a brief overview is presented as an aid in understanding the acquisition of behavior that older children are likely to demonstrate in the dentist's or orthodontist's office.

The basic principle of operant conditioning is that the consequence of a behavior is in itself a stimulus that can affect future behavior (Fig. 2.48). In other words, the consequence that follows a response will alter the probability of that response occurring again in a similar situation. In classical conditioning, a stimulus leads to a response; in operant conditioning, a response becomes a further stimulus. The general rule is that if the consequence of a certain response is pleasant or desirable, that response is more likely to be used again in the future; but if a particular response produces an unpleasant consequence, the probability of that response being used in the future is diminished.

Skinner described four basic types of operant conditioning, distinguished by the nature of the consequence (Fig. 2.49). The first of these is *positive reinforcement*. If a pleasant consequence follows a response, the response has been positively reinforced, and the behavior that led to this pleasant consequence becomes more likely in the future. For example, if a child is given a reward such as a toy for behaving well during her first dental visit, she is



• **Fig. 2.48** Operant conditioning differs from classical conditioning in that the consequence of a behavior is considered a stimulus for future behavior. This means that the consequence of any particular response will affect the probability of that response occurring again in a similar situation.

more likely to behave well during future dental visits; her behavior was positively reinforced (Fig. 2.50).

A second type of operant conditioning, called *negative reinforcement*, involves the withdrawal of an unpleasant stimulus after a response. Like positive reinforcement, negative reinforcement increases the likelihood of a response in the future. In this context, the word *negative* is somewhat misleading. It merely refers to the fact that the response that is reinforced is a response that leads to the removal of an undesirable stimulus. Note that negative reinforcement is not a synonym for *punishment*, another type of operant conditioning.

As an example, a child who views a visit to the hospital clinic as an unpleasant experience may throw a temper tantrum at the prospect of having to go there. If this behavior (response) succeeds in allowing the child to escape the visit to the clinic, the behavior has been negatively reinforced and is more likely to occur the next time a visit to the clinic is proposed. The same can be true, of course, in the dentist's office. If behavior considered unacceptable by the dentist and his staff nevertheless succeeds in allowing the child to escape from dental treatment, this behavior has been negatively reinforced and is more likely to occur the next time the child is in the dental office. In dental practice, it is important to reinforce only desired behavior, and it is equally important to avoid reinforcing behavior that is not desired. An interesting study showed that an alternative scheduled time-out was as successful as an operant conditioning approach to controlling behavior problems during prolonged dental appointments for children.<sup>16</sup>

The other two types of operant conditioning decrease the likelihood of a response. The third type, *omission* (also called *time-out*), involves removal of a pleasant stimulus after a particular response. For example, if a child who throws a temper tantrum has his favorite toy taken away for a short time as a consequence of this behavior, the probability of similar misbehavior is decreased. Because children are likely to regard attention by others as a very pleasant stimulus, withholding attention following undesirable behavior is a use of omission that is likely to reduce the unwanted behavior.

The fourth type of operant conditioning, *punishment*, occurs when an unpleasant stimulus is presented after a response. This also decreases the probability that the behavior that prompted

		Probability of Response Increases	Probability of Response Decreases
Pleasant stimulus (S <sub>1</sub> )  Unpleasant stimulus (S <sub>2</sub> )	I	S <sub>1</sub> Presented  Positive reinforcement or reward	III  S <sub>1</sub> Withdrawn  Omission or time-out
	II	S <sub>2</sub> Withdrawn  Negative reinforcement or escape	IV  S <sub>2</sub> Presented  Punishment

• **Fig. 2.49** The four basic types of operant conditioning.





• **Fig. 2.50** As they leave the pediatric dentist's treatment area, children are allowed to choose their own reward—positive reinforcement for cooperation.

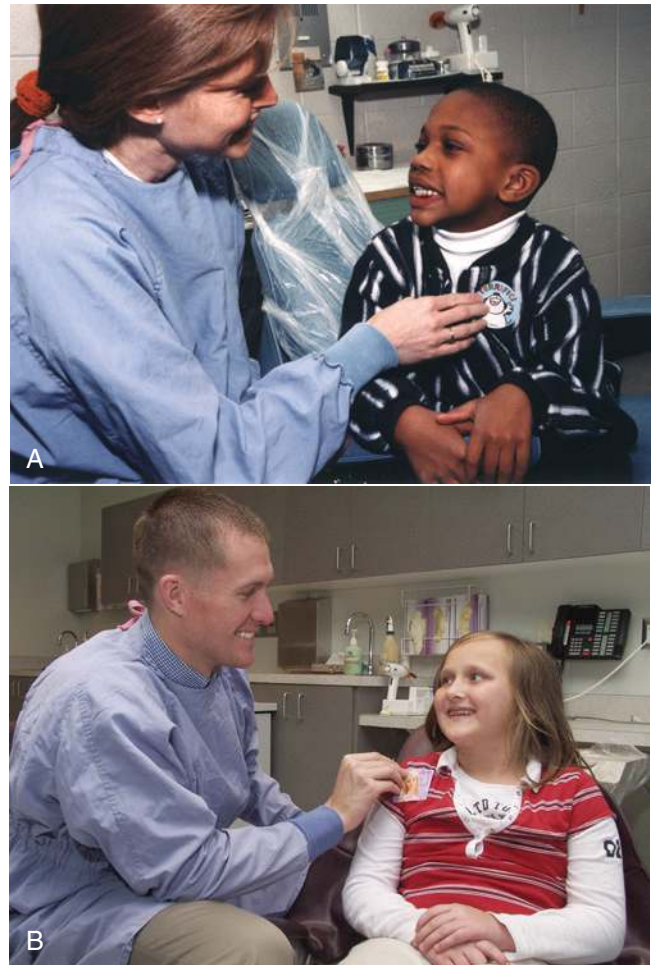punishment will occur in the future. Punishment, like the other forms of operant conditioning, is effective at all ages, not just with children. For example, if the dentist with her new sports car receives a ticket for driving 50 miles per hour down a street marked for 35 miles per hour, she is likely to drive more slowly down that particular street in the future, particularly if she thinks that the same radar speed trap is still operating. Punishment, of course, has traditionally been used as a method of behavior modification in children, more so in some societies than others.

In general, positive and negative reinforcement are the most suitable types of operant conditioning for use in the dental office, particularly for motivating orthodontic patients who must cooperate at home even more than in the dental office. Both types of reinforcement increase the likelihood of a particular behavior recurring, rather than attempting to suppress a behavior as punishment and omission do. Simply praising a child for desirable behavior produces positive reinforcement, and additional positive reinforcement can be achieved by presenting some tangible reward.

Older children are just as susceptible to positive reinforcement as younger ones. Adolescents in the orthodontic treatment age, for instance, can obtain positive reinforcement from a simple pin saying “World’s Greatest Orthodontic Patient” or something similar. A reward system, perhaps providing a T-shirt with some slogan as a prize for three consecutive appointments with good hygiene, is another simple example of positive reinforcement (Fig. 2.51).

Negative reinforcement, which also accentuates the probability of any given behavior, is more difficult to use as a behavioral management tool in the dental office, but it can be used effectively if the circumstances permit. If a child is concerned about a treatment procedure but behaves well and understands that the procedure has been shortened because of his good behavior, the desired behavior has been negatively reinforced. In orthodontic treatment, long bonding and banding appointments may go more efficiently and smoothly if the child understands that his helpful behavior has shortened the procedure and reduced the possibility that the procedure will need to be redone.

The other two types of operant conditioning, omission and punishment, should be used sparingly and with caution in the dental office. Because a positive stimulus is removed in omission, the child may react with anger or frustration. When punishment is used, both fear and anger sometimes result. In fact, punishment can lead to a classically conditioned fear response. Obviously, it



• **Fig. 2.51** (A) This 8-year-old boy is getting positive reinforcement by receiving a “terrific patient” button after his visit to the dentist. (B) The same methods work well for older orthodontic patients, who enjoy receiving a reward such as a “great patient” sticker to put on a shirt or a T-shirt with a message related to orthodontic treatment (e.g., “Braces are Cool”).

is a good idea for the dentist and staff to avoid creating fear and anger in a child (or adult) patient.

One mild form of punishment that can be used with children is called *voice control*. Voice control involves speaking to the child in a firm voice to gain his (or her) attention, telling him that his present behavior is unacceptable, and directing him as to how he (or she) should behave. This technique should be used with care, and the child should be immediately rewarded for an improvement in his behavior. It is most effective when a warm, caring relationship has been established between the dental team and the patient.<sup>17</sup>

There is no doubt that operant conditioning can be used to modify behavior in individuals of any age and that it forms the basis for many of the behavior patterns of life. Behavioral theorists believe that operant conditioning forms the pattern of essentially all behavior, not just the relatively superficial ones. Whether this is true or not, operant conditioning is a powerful tool for learning of behavior and an important influence throughout life.

Concepts of reinforcement as opposed to extinction and of generalization as opposed to discrimination apply to operant conditioning, as well as to classical conditioning. In operant conditioning, of course, the concepts apply to the situation in which a response leads to a particular consequence, not to the



conditioned stimulus that directly controls the conditioned response. Positive or negative reinforcement becomes even more effective if repeated, although it is not necessary to provide a reward at every visit to the dental office to achieve positive reinforcement. Similarly, conditioning obtained through positive reinforcement can be extinguished if the desired behavior is now followed by omission, punishment, or simply a lack of further positive reinforcement.

Operant conditioning that occurs in one situation can also be generalized to similar situations. For example, a child who has received positive reinforcement for good behavior in the pediatrician's office is likely to behave well on the first visit to a dentist's office because he or she will anticipate a reward at the dentist's office also, based on the similarity of the situation. A child who continues to be rewarded for good behavior in the pediatrician's office but does not receive similar rewards in the dentist's office, however, will learn to discriminate between the two situations and may eventually behave better for the pediatrician than for the dentist.

### Observational Learning (Modeling)

Another potent way that behavior is acquired is through imitation of behavior observed in a social context (Fig. 2.52; also see Fig. 2.46B). This type of learning appears to be distinct from learning by either classical or operant conditioning. Acquisition of behavior through imitation of the behavior of others, of course, is entirely compatible with both classical and operant conditioning. Some theorists emphasize the importance of learning by imitation in a social context, whereas others, especially Skinner and his followers, argue that conditioning is more important, although recognizing that learning by imitation can occur.<sup>18</sup> It certainly seems that much of a child's behavior in a dental office can be learned from observing siblings, other children, or even parents.

There are two distinct stages in observational learning: *acquisition* of the behavior by observing it and the actual *performance* of that behavior. A child can observe many behaviors and thereby acquire the potential to perform them, without immediately demonstrating or performing that behavior. Children are capable of acquiring almost any behavior that they observe closely and that is not too

complex for them to perform at their level of physical development. A child is exposed to a tremendous range of possible behaviors, most of which he acquires even though the behavior may not be expressed immediately or ever.

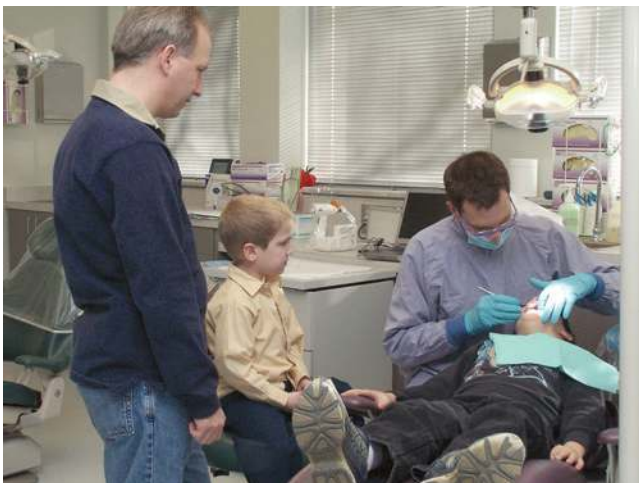Whether a child will actually perform an acquired behavior depends on several factors. Important among these are the characteristics of the role model. If the model is liked or respected, the child is more likely to imitate him or her. For this reason, a parent or older sibling is often the object of imitation by the child. For children in the elementary and junior high school age groups, peers within their own age group or individuals slightly older are increasingly important role models, while the influence of parents and older siblings decreases. For adolescents, the peer group is the major source of role models.

Another important influence on whether a behavior is performed is the expected consequences of the behavior. If a child sees an older sibling refuse to obey his father's command and then sees punishment follow this refusal, he is less likely to defy the father on a future occasion, but he probably still has acquired the behavior, and if he should become defiant, is likely to stage it in a similar way.

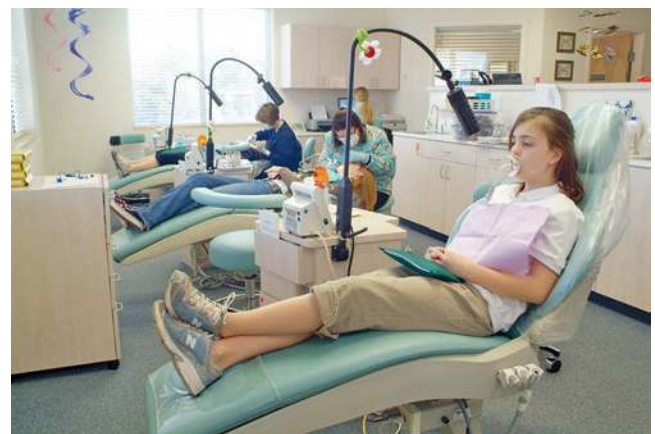Observational learning can be an important tool in management of dental treatment. If a young child observes an older sibling undergoing dental treatment without complaint or uncooperative behavior, he or she is likely to imitate this behavior. If the older sibling is observed being rewarded, the younger child will also expect a reward for behaving well. Because the parent is an important role model for a young child, the mother's attitude toward dental treatment is likely to influence the child's approach.

Research has demonstrated that one of the best predictors of how anxious a child will be during dental treatment is how anxious the mother is. A mother who is calm and relaxed about the prospect of dental treatment teaches the child by observation that this is the appropriate approach to being treated, whereas an anxious and alarmed mother tends to elicit the same set of responses in her child.<sup>19</sup>

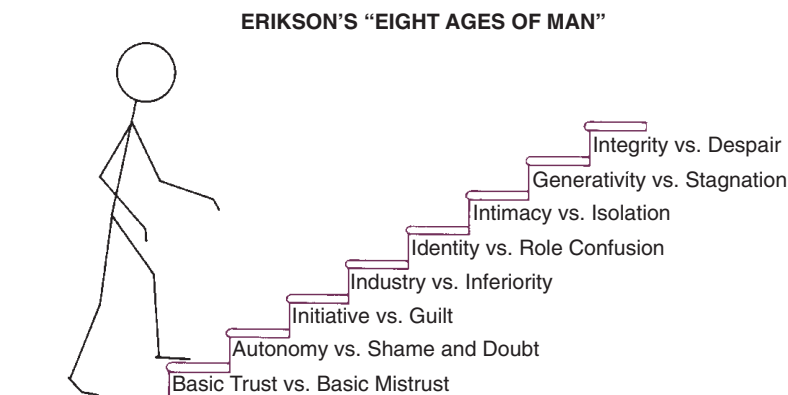
Observational learning can be used to advantage in the design of treatment areas. At one time, it was routine for dentists to provide small private cubicles in which all patients, children and adults, were treated. The modern trend in orthodontics, particularly in treatment of children and adolescents but to some extent with adults also, is an open area with several treatment stations (Fig. 2.53). Sitting in one dental chair watching the dentist work



• **Fig. 2.52** Observational learning. A child acquires a behavior by first observing it and then actually performing it. For that reason, allowing a younger child to observe an older one calmly receiving dental treatment (in this case, an orthodontic examination that will include impressions of the teeth) greatly increases the chance that he will behave in the same calm way when it is his turn to be examined.



• **Fig. 2.53** The orthodontic treatment room in the pediatric dentistry-orthodontic office, with three chairs in an open treatment area. This has the advantage of allowing observational learning for the patients.



• **Fig. 2.54** Erikson's stages of emotional development. The sequence is more fixed than the time when each stage is reached. Some adults never reach the final steps on the developmental staircase.

with someone else in an adjacent chair can provide a great deal of observational learning about what the experience will be like. Direct communication among patients, answering questions about exactly what happened, can add even further learning. Both children and adolescents do better, it appears, if they are treated in open clinics rather than in private cubicles, and observational learning plays an important part in this.<sup>20</sup> The dentist hopes, of course, that the patient waiting for treatment observes appropriate behavior and responses on the part of the patient who is being treated, which will be the case in a well-managed clinical setting.

In a classic article that still is an excellent summary, Chambers reviewed what we have covered in this section in the context of a child going to the dentist.<sup>21</sup>

## Stages of Emotional and Cognitive Development

### Emotional Development

In contrast to continuous learning by conditioning and observation, both emotional or personality development and cognitive or intellectual development pass through relatively discrete stages. The contemporary description of emotional development is based on Sigmund Freud's psychoanalytic theory of personality development but was greatly extended by Erik Erikson.<sup>22</sup> Erikson's work, although connected to Freud's, represents a great departure from psychosexual stages as proposed by Freud. His "eight ages of man" illustrate a progression through a series of personality development stages. In Erikson's view, "psychosocial development proceeds by critical steps—'critical' being a characteristic of turning points, of moments of decision between progress and regression, integration and retardation." In this view, each developmental stage represents a "psychosocial crisis" in which individuals are influenced by their social environment to develop more or less toward one extreme of the conflicting personality qualities dominant at that stage.

Although chronologic ages are associated with Erikson's developmental stages, the chronologic age varies among individuals, but the sequence of the developmental stages is constant. This, of course, is similar to what also happens in physical development. Rather differently from physical development, it is possible and indeed probable that qualities associated with earlier stages may be evident in later stages because of incomplete resolution of the earlier stages.

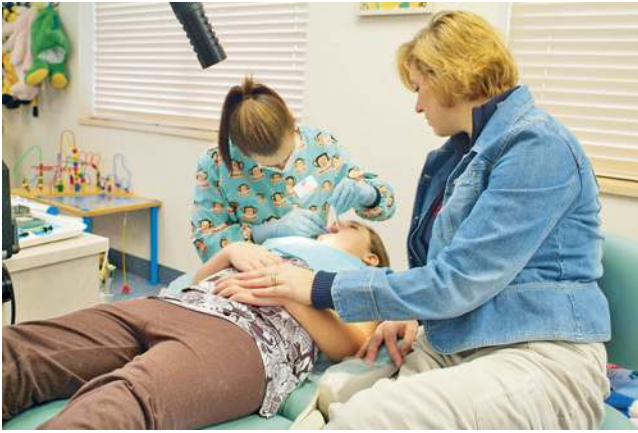Erikson's stages of emotional development are as follows (Fig. 2.54).

**1. Development of Basic Trust (Birth to 18 Months).** In this initial stage of emotional development, a basic trust—or lack of trust—in the environment is developed. Successful development of trust depends on a caring and consistent mother or mother substitute, who meets both the physiologic and emotional needs of the infant. There are strongly held theories but no clear answers to exactly what constitutes proper mothering, but it is important that a strong bond develop between parent and child. This bond must be maintained to allow the child to develop basic trust in the world. In fact, physical growth can be significantly retarded unless the child's emotional needs are met by appropriate mothering.

The syndrome of "maternal deprivation," in which a child receives inadequate maternal support, is well recognized although fortunately rare. Such infants fail to gain weight and are retarded in their physical, as well as emotional, growth. The maternal deprivation must be extreme to produce a deficit in physical growth. Unstable mothering that produces no apparent physical effects can result in a lack of sense of basic trust. This may occur in children from broken families or who have lived in a series of foster homes.

The tight bond between parent and child at this early stage of emotional development is reflected in a strong sense of "separation anxiety" in the child when separated from the parent. If it is necessary to provide dental treatment at an early age, it usually is preferable to do so with the parent present and, if possible, while the child is being held by one of the parents. At later ages, a child who never developed a sense of basic trust will have difficulty entering into situations that require trust and confidence in another person. Such an individual is likely to be an extremely frightened and uncooperative patient who needs special effort to establish rapport and trust with the dentist and staff, and having a parent present in the treatment area during initial visits can be helpful (Fig. 2.55). For further guidance with behavior management techniques and their applicable ages, see the American Academy of Pediatric Dentistry's *Guideline on Behavior Guidance for the Pediatric Dental Patient*.<sup>23</sup>

**2. Development of Autonomy (18 Months to 3 Years).** Children around the age of 2 often are said to be undergoing the "terrible twos" because of their uncooperative and frequently obnoxious behavior. At this stage of emotional development, the




• **Fig. 2.55** For this child who was extremely anxious about dental treatment, having the mother in the treatment room for initial appointments was an important part of developing trust in the dentist. As trust develops, mother's presence is no longer necessary or desirable.

child is moving away from the mother and developing a sense of individual identity or autonomy. Typically, the child struggles to exercise free choice in his or her life. He or she varies between being a little devil who says *no* to every wish of the parents and insists on having his own way and being a little angel who retreats to the parents in moments of dependence. The parents and other adults with whom the child reacts at this stage must protect him against the consequences of dangerous and unacceptable behavior, while providing opportunities to develop independent behavior. Consistently enforced limits on behavior at this time allow the child to further develop trust in a predictable environment (Fig. 2.56).

Failure to develop a proper sense of autonomy results in the development of doubts in the child's mind about his ability to stand alone, and this in turn produces doubts about others. Erikson defines the resulting state as one of shame, a feeling of having all one's shortcomings exposed. Autonomy in control of bodily functions is an important part of this stage, as the young child is toilet trained and taken out of diapers. At this stage (and later!), wetting one's pants produces a feeling of shame. This stage is considered decisive in producing the personality characteristics of love as opposed to hate, cooperation as opposed to selfishness, and freedom of expression as opposed to self-consciousness. To quote Erikson, "From a sense of self-control without a loss of self-esteem comes a lasting sense of good will and pride; from a sense of loss of self-control and foreign over-control come a lasting propensity for doubt and shame."<sup>22</sup>

A key toward obtaining cooperation with treatment from a child at this stage is to have the child think that whatever the dentist wants was his or her own choice, not something required by another person. For a 2-year-old seeking autonomy, it is all right to open your mouth if you want to, but almost psychologically unacceptable to do it if someone tells you to. One way around this is to offer the child reasonable choices whenever possible, for instance, either a green or a yellow napkin for the neck.

A child at this stage who finds the situation threatening is likely to retreat to the mother and be unwilling to separate from her. Allowing the parent to be present during treatment may be needed for even the simplest procedures. Complex dental treatment of children at this age is quite challenging and may require extraordinary behavior management strategies such as sedation or general anesthesia.



• **Fig. 2.56** During the period in which children are developing autonomy, conflicts with siblings, peers, and parents can seem never-ending. Consistently enforced limits on behavior during this stage, often called the "terrible twos," are needed to allow the child to develop trust in a predictable environment.

**3. Development of Initiative (3 to 6 Years).** In this stage, the child continues to develop greater autonomy but now adds to it planning and vigorous pursuit of various activities. The initiative is shown by physical activity and motion, extreme curiosity and questioning, and aggressive talking. A major task for parents and teachers at this stage is to channel the activity into manageable tasks, arranging things so that the child is able to succeed, and preventing him or her from undertaking tasks where success is not possible. At this stage, a child is inherently teachable. One part of initiative is the eager modeling of behavior of those whom he respects.

The opposite of initiative is guilt resulting from goals that are contemplated but not attained, from acts initiated but not completed, or from faults or acts rebuked by persons the child respects. In Erikson's view, the child's ultimate ability to initiate new ideas or activities depends on how well he or she is able at this stage to express new thoughts and do new things without being made to feel guilty about expressing a bad idea or failing to achieve what was expected.

For most children, the first visit to the dentist comes during this stage of initiative. Going to the dentist can be constructed as a new and challenging adventure in which the child can experience success. Success in coping with the anxiety of visiting the dentist can help the child develop greater independence and produce a sense of accomplishment. Poorly managed, of course, a dental visit can also contribute toward the guilt that accompanies failure. A child at this stage will be intensely curious about the dentist's office and eager to learn about the things found there. An exploratory



visit with the mother present and with little treatment accomplished usually is important in getting the dental experience off to a good start. After the initial experience, a child at this stage can usually tolerate being separated from the mother for treatment and is likely to behave better in this arrangement, so that independence rather than dependence is reinforced.

**4. Mastery of Skills (7 to 11 Years).** At this stage, the child is working to acquire the academic and social skills that will allow him or her to compete in an environment where significant recognition is given to those who produce. At the same time, the child is learning the rules by which that world is organized. In Erikson's terms, the child acquires industriousness and begins the preparation for entrance into a competitive and working world. Competition with others within a reward system becomes a reality; at the same time, it becomes clear that some tasks can be accomplished only by cooperating with others. The influence of parents as role models decreases, and the influence of the peer group increases.

The negative side of emotional and personality development at this stage can be the acquisition of a sense of inferiority. A child who begins to compete academically, socially, and physically is certain to find that others do some things better and that whatever he or she does best, someone does it better. Somebody else gets put in the advanced section, is selected as leader of the group, or is chosen first for the team. It is necessary to learn to accept this, but failure to measure up to the peer group on a broad scale predisposes toward personality characteristics of inadequacy, inferiority, and uselessness. Again, it is important for responsible adults to attempt to structure an environment that provides challenges that have a reasonable chance of being met, rather than those that guarantee failure.

By this stage, a child should already have experienced the first visit to the dentist, although a significant number will not have done so. Orthodontic treatment often begins during this stage of development. Children at this age are trying to learn the skills and rules that define success in any situation, and that includes the dental office. A key to behavioral guidance is setting attainable intermediate goals, clearly outlining for the child how to achieve those goals, and positively reinforcing success in achieving these goals. Because of the child's drive for a sense of industry and accomplishment, cooperation with treatment can be obtained, especially if good behavior is reinforced immediately afterward.

Orthodontic treatment in this age group is likely to involve the faithful wearing of removable appliances. Whether a child will do so is determined in large part by whether he or she understands what is needed to please the dentist and parents, whether the peer group is supportive, and whether the desired behavior is reinforced by the dentist.

Children at this stage still are not likely to be motivated by abstract concepts such as, "If you wear this appliance, your bite will be better." They can be motivated, however, by improved acceptance or status from the peer group. This means that emphasizing how the teeth will look better as the child cooperates is more likely to be a motivating factor than emphasizing a better bite, which the peer group is not likely to notice.

**5. Development of Personal Identity (12 to 17 Years).** Adolescence, a period of intense physical development, is also the stage in psychosocial development in which a unique personal identity is acquired. This sense of identity includes both a feeling of belonging to a larger group and a realization that one can exist outside the family. It is an extremely complex stage because of the many new opportunities that arise. Emerging sexuality complicates relationships



• **Fig. 2.57** Adolescence is an extremely complex stage because of the many new opportunities and challenges thrust on the teenager. Emerging sexuality, academic pressures, earning money, increased mobility, career aspirations, and recreational interests combine to produce stress and rewards.

with others. At the same time, physical ability changes, academic responsibilities increase, and career possibilities begin to be defined.

Establishing one's own identity requires a partial withdrawal from the family, and the peer group increases still further in importance because it offers a sense of continuity of existence in spite of drastic changes within the individual (Fig. 2.57). Members of the peer group become important role models, and the values and tastes of parents and other authority figures are likely to be rejected. At the same time, some separation from the peer group is necessary to establish one's own uniqueness and value. As adolescence progresses, an inability to separate from the group indicates some failure in identity development. This in turn can lead to a poor sense of direction for the future, confusion regarding one's place in society, and low self-esteem.

Most orthodontic treatment is carried out during the adolescent years, and behavioral management of adolescents can be extremely challenging. Because parental authority is being rejected, a poor psychologic situation is created by orthodontic treatment if it is being carried out primarily because the parents want it, not the child. At this stage, orthodontic treatment should be instituted only if the patient wants it, not just to please the parents.

Motivation for seeking treatment can be defined as internal or external. External motivation is from pressure from others, as in orthodontic treatment "to get mother off my back." Internal motivation is provided by an individual's own desire for treatment to correct a defect that he perceives in himself, not some defect pointed to by a parent or other authority figure whose values are being rejected anyway.<sup>24</sup> For an early adolescent, bullying from peers because of the appearance of his or her teeth can be a powerful internal motivator.<sup>25</sup> For adolescents, approval of the peer group is extremely important. At one time, there was a certain stigma attached to being the only one in the group so unfortunate as to have to wear braces. Now, in some areas of the United States and other developed countries, orthodontic treatment has become so



common that there may be a loss of status from being one of the few in the group who is not wearing braces. For that reason, some adolescents seek unnecessary treatment in order to remain “one of the crowd.”

It is extremely important for an adolescent to actively desire the treatment as something being done *for*—not *to*—him or her. In this stage, abstract concepts can be grasped readily, but appeals to do something because of its impact on personal health are not likely to be heeded. Typical adolescents feel that health problems are concerns of other people, not them, and this attitude covers everything from accidental death from reckless driving to development of decalcified areas on carelessly brushed teeth.

**6. Development of Intimacy (Young Adult).** The adult stages of development begin with the attainment of intimate relationships with others. Successful development of intimacy depends on a willingness to compromise and even to sacrifice to maintain a relationship. Success leads to the establishment of affiliations and partnerships, both with a mate and with others of the same sex, in working toward the attainment of career goals. Failure leads to isolation from others and is likely to be accompanied by strong prejudices and a set of attitudes that serve to keep others away rather than bringing them into closer contact.

A growing number of young adults are seeking orthodontic care. Often, these individuals are seeking to correct a dental appearance they perceive as flawed. They may feel that a change in their appearance will facilitate attainment of intimate relationships. On the other hand, a “new look” resulting from orthodontic treatment may interfere with previously established relationships.

The factors that affect the development of an intimate relationship include all aspects of each person—appearance, personality, emotional qualities, intellect, and others. A significant change in any of these may be perceived by either partner as altering the relationship. Because of these potential problems, the potential psychologic impact of orthodontic treatment must be fully discussed with a young adult patient before beginning therapy.

**7. Guidance of the Next Generation (Adult).** A major responsibility of a mature adult is the establishment and guidance of the next generation. Becoming a successful and supportive parent is obviously a major part of this, but another aspect of the same responsibility is service to the group, community, and nation. The next generation is guided, in short, not only by nurturing and influencing one's own children but also by supporting the network of social services needed to ensure the next generation's success. The opposite personality characteristic in mature adults is stagnation, characterized by self-indulgence and self-centered behavior.

**8. Attainment of Integrity (Late Adult).** The final stage in psychosocial development is the attainment of integrity. At this stage, the individual has adapted to the combination of gratification and disappointment that every adult experiences. The feeling of integrity is best summed up as a feeling that one has made the best of this life's situation and has made peace with it. The opposite characteristic is despair. This feeling is often expressed as disgust and unhappiness on a broad scale, frequently accompanied by a fear that death will occur before a life change that might lead to integrity can be accomplished.

### Cognitive Development

Cognitive development, the development of intellectual capabilities, also occurs in a series of relatively distinct stages. Like the other psychologic theories, the theory of cognitive development is strongly associated with one dominant individual, in this case, the Swiss psychologist Jean Piaget. From the perspective of Piaget and

his followers, the development of intelligence is another example of the widespread phenomenon of biologic adaptation. Every individual is born with the capacity to adjust or adapt to both the physical and the sociocultural environments in which he or she must live.<sup>26</sup>

In Piaget's view, adaptation occurs through two complementary processes: *assimilation* and *accommodation*. From the beginning, a child incorporates or assimilates events within the environment into mental categories called *cognitive structures*. A cognitive structure in this sense is a classification for sensations and perceptions.

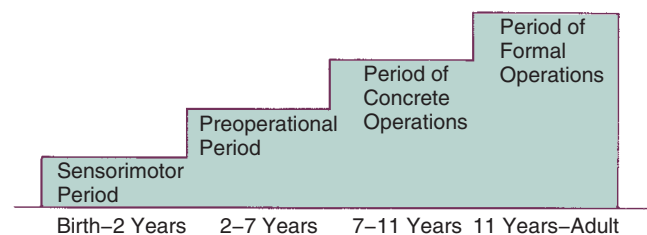
For example, a child who has just learned the word *bird* will tend to assimilate all flying objects into his idea of bird. When he sees a bee, he will probably say, “Look, bird!” However, for intelligence to develop, the child must also have the complementary process of accommodation. Accommodation occurs when the child changes his or her cognitive structure or mental category to better represent the environment. In the previous example, the child will be corrected by an adult or older child and will soon learn to distinguish between birds and bees. In other words, the child will accommodate to the event of seeing a bee by creating a separate category of flying objects for bees.

Intelligence develops as an interplay between assimilation and accommodation. Each time the child in our example sees a flying object, he or she will try to assimilate it into existing cognitive categories. If these categories do not work, he or she will try to accommodate by creating new ones. However, the child's ability to adapt is limited by the current level of development. The notion that the child's ability to adapt is *age related* is a crucial concept in Piaget's theory of development.

From the perspective of cognitive development theory, life can be divided into four major stages (Fig. 2.58): the *sensorimotor* period, extending from birth to 2 years of age; the *preoperational* period, from 2 to 7 years; the *concrete operational* period, from about age 7 to puberty; and the period of *formal operations*, which runs from adolescence through adulthood. Like the other developmental stages, it is important to realize that the time frame is variable, especially for the later ones. Some adults never reach the last stage. The sequence of the stages, however, is fixed.

A child's way of thinking about and viewing the world is quite different at the different stages. A child simply does not think like an adult until the period of formal operations has been reached. Since a child's thought processes are quite different, one cannot expect a child to process and use information in the same way that an adult would. To communicate successfully with a child, it is necessary to understand his or her intellectual level and the ways in which thought processes work at the various stages.

This relates directly to orthodontic treatment for children with a handicap. Orthodontic care is one of the few dental treatments that includes active patient (and parent) involvement beyond keeping



• **Fig. 2.58** Cognitive development is divided into four major periods, as diagrammed here.

the teeth clean. Cognitive development is essential in order to have successful orthodontic care. At the least, patients need to be able to tolerate intraoral record taking and placement and adjustment and removal of appliances, in addition to living with the appliances. That means keeping the appliances intact, cleaning the teeth and appliances, and wearing adjuncts such as elastics. Some handicapped children develop to a level at which they can tolerate these events; others do not. Depending on the situation, some handicapped patients can have routine orthodontic treatment and do well. Some should not be treated because the treatment can cause more risk to the patient and their oral tissues than is merited for a largely elective treatment that may have more benefit for the parents than the child. This can be difficult for some parents to appreciate because it's "just braces" that appear so benign. This is especially true when having a pretty smile seems to be one thing that their child can achieve in spite of other disabilities.

Sometimes compromises can be made to meet realistic parental desires and accommodate the patient's abilities while staying within the realm of clinically viable, safe, and ethical orthodontics. As an example, autism spectrum disorders present a notable array of diagnoses of aberrant social and behavioral development. Some of these children and adolescents make exemplary patients because of their attention to detail and order. Others can be distracted by the presence of the very appliances themselves. This is a challenging treatment interaction, but often can be successfully met with by thoughtful adjustment of the goals and expectations on the part of both the practitioner and parents.

The following discussion considers the cognitive development stages in more detail.

**1. Sensorimotor Period.** During the first 2 years of life, a child develops from a newborn infant who is almost totally dependent on reflex activities to an individual who can develop new behaviors to cope with new situations. During this stage, the child develops rudimentary concepts of objects, including the idea that objects in the environment are permanent; they do not disappear when the child is not looking at them. Simple modes of thought that are the foundation of language develop during this time, but communication between a child at this stage and an adult is extremely limited because of the child's simple concepts and lack of language capabilities. At this stage, a child has little ability to interpret sensory data and a limited ability to project forward or backward in time.

**2. Preoperational Period.** Because children older than age 2 begin to use language in ways similar to adults, it appears that their thought processes are more like those of adults than is the case. During the preoperational stage, the capacity develops to form mental symbols representing things and events not present, and children learn to use words to symbolize these absent objects. Because young children use words to symbolize the external appearance or characteristics of an object, however, they often fail to consider important aspects such as function and thus may understand some words quite differently than adults do. To an adult, the word *coat* refers to a whole family of external garments that may be long or short, heavy or light, and so on. To a preoperational child, however, the word *coat* is initially associated with only the one he or she wears, and the garment that Daddy wears would require another word.

A particularly prominent feature of thought processes of children at this age is the concrete nature of the process and hence the concrete or literal nature of their language. In this sense, concrete is the opposite of abstract. Children in the preoperational period understand the world in the way they sense it through the five

primary senses. Concepts that cannot be seen, heard, smelled, tasted, or felt—for example, time and health—are very difficult for preoperational children to grasp. At this age, children use and understand language in a literal sense and thus understand words only as they have learned them. They are not able to comprehend more than the literal meaning of idioms, and sarcastic or ironic statements are likely to be misinterpreted.

A general feature of thought processes and language during the preoperational period is *egocentrism*, meaning that the child is incapable of assuming another person's point of view. At this stage, his own perspective is all that he can manage—assuming another's view is simply beyond his mental capabilities.

Still another characteristic of thought processes at this stage is *animism*, investing inanimate objects with life. Essentially, everything is seen as being alive by a young child, and so stories that invest the most improbable objects with life are quite acceptable to children of this age. Animism can be used to the dental team's advantage by giving dental instruments and equipment lifelike names and qualities. For example, the handpiece can be called "Whistling Willie," who is happy while he works at polishing the child's teeth.

At this stage, capabilities for logical reasoning are limited, and the child's thought processes are dominated by immediate sensory impressions. This characteristic can be illustrated by asking the child to solve a liquid conservation problem. The child is first shown two equal-size glasses with water in them. The child agrees that both contain the same amount of water. Then the contents of one glass are poured into a taller, narrower glass while the child watches. Now when asked which container has more water, the child will usually say that the tall one does. Her impressions are dominated by the greater height of the water in the tall glass.

With a child at this stage, the dental staff should use immediate sensations rather than abstract reasoning in discussing concepts such as prevention of dental problems. Excellent oral hygiene is very important when an orthodontic appliance is present (a lingual arch to prevent drift of teeth, for instance). A preoperational child will have trouble understanding a chain of reasoning like the following: "Brushing and flossing remove food particles, which in turn prevents bacteria from forming acids, which cause tooth decay." He or she is much more likely to understand "Brushing makes your teeth feel clean and smooth" and "Toothpaste makes your mouth taste good," because these statements rely on things the child can taste or feel immediately.

A knowledge of these thought processes obviously can be used to improve communication with children of this age.<sup>27</sup> A further example would be talking to a 4-year-old about how desirable it would be to stop thumb-sucking. The dentist might have little problem in getting the child to accept the idea that "Mr. Thumb" was the problem and that the dentist and the child should form a partnership to control Mr. Thumb, who wishes to get into the child's mouth. Animism, in other words, can apply even to parts of the child's own body, which seem to take on a life of their own in this view.

On the other hand, it would not be useful to point out to the child how proud his father would be if he stopped sucking his thumb, because the child would think his father's attitude was the same as his (egocentrism). Because the child's view of time is centered around the present and is dominated by how things look, feel, taste, and sound now, there also is no point in talking to the 4-year-old about how much better his teeth will look in the future if he stops sucking his thumb. Telling him that the teeth will feel better now or talking about how bad his thumb tastes, however, may make an impact, because he can relate to that.

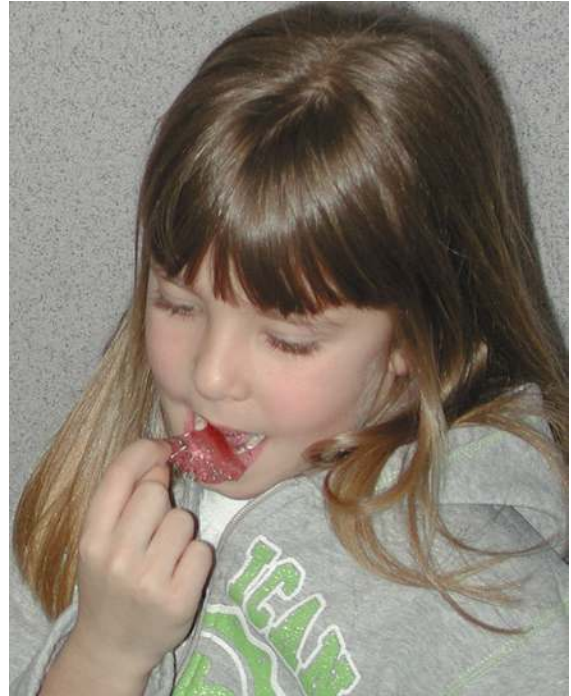
**3. Period of Concrete Operations.** As a child moves into this stage, typically after a year or so of preschool and first grade activity, an improved ability to reason emerges. He or she can use a limited number of logical processes, especially those involving objects that can be handled and manipulated (i.e., concrete objects). Thus an 8-year-old could watch the water being poured from one glass to another, imagine the reverse of that process, and conclude that the amount of water remains the same no matter what size the container is. If a child in this stage is given a similar problem, however, stated only in words with no concrete objects to illustrate it, the child may fail to solve it. The child's thinking is still strongly tied to concrete situations, and the ability to reason on an abstract level is limited.

By this stage, the ability to see another point of view develops, while animism declines. Children in this period are much more like adults in the way they view the world, but they are still cognitively different from adults. Presenting ideas as abstract concepts rather than illustrating them with concrete objects can be a major barrier to communication. Instructions must be illustrated with concrete objects (Fig. 2.59). "Now, this is your retainer. You need to wear it regularly to keep your teeth straight," is too abstract. More concrete directions would be "This is your retainer. Put it in your mouth like this, and take it out like that. Put it in every evening right after dinner, and wear it until the next morning. Brush it like this with an old toothbrush and your parents' dishwashing soap to keep it clean."

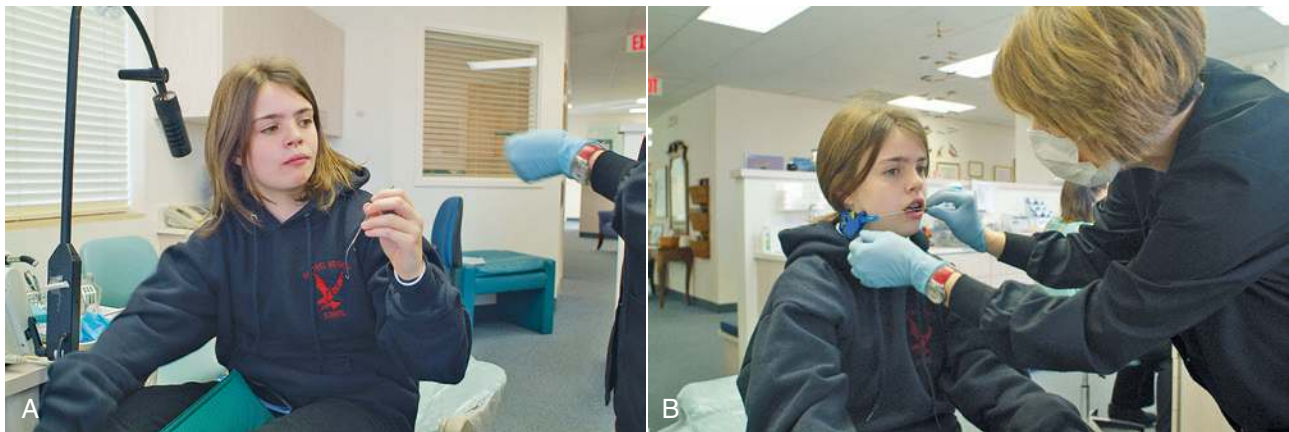**4. Period of Formal Operations.** For most children, the ability to deal with abstract concepts and abstract reasoning develops by about age 11. At this stage, the child's thought process has become similar to that of an adult, and the child is capable of understanding concepts such as health, disease, and preventive treatment. At this stage, intellectually the child can and should be treated as an adult. It is as great a mistake to talk down to a child who has developed the ability to deal with abstract concepts, using the concrete approach needed with an 8-year-old, as it is to assume that the 8-year-old can handle abstract ideas. Successful communication, in other words, requires a feel for the child's stage of intellectual development (Fig. 2.60).

In addition to the ability to deal with abstractions, teenagers have developed cognitively to the point at which they can think about thinking. They are now aware that others think, but usually,

in a new expression of egocentrism, presume that they and others are thinking about the same thing. Because young adolescents are experiencing tremendous biologic changes in growth and sexual development, they are preoccupied with these events. When an adolescent considers what others are thinking about, he assumes that others are thinking about the same thing he is thinking about, namely, himself. Adolescents assume that others are as concerned with their bodies, actions, and feelings as they themselves are. They feel as though they are constantly "on stage," being observed and criticized by those around them. This phenomenon has been called the "imaginary audience" by Elkind.<sup>28</sup>



• **Fig. 2.59** Instructions for a young child who will be wearing a removable orthodontic appliance must be explicit and concrete. Children at this stage cannot be motivated by abstract concepts but are influenced by improved acceptance or status from the peer group.



• **Fig. 2.60** (A) and (B) Instructions for this girl as to how to put her headgear on and take it off are important, but at her stage of development, she can and must understand why she needs to wear it while her jaws are growing. It would be a mistake to talk to her as one would to a younger child.




The imaginary audience is a powerful influence on young adolescents, making them quite self-conscious and particularly susceptible to peer influence. They are very worried about what peers will think about their appearance and actions, not realizing that others are too busy with themselves to be paying much attention to anything else.

The reaction of the imaginary audience to braces on the teeth, of course, is an important consideration to a teenage patient. As orthodontic treatment has become more common, adolescents have less concern about being singled out because they have braces on their teeth, but they are very susceptible to suggestions from their peers about how the braces should look. In some settings, this has led to pleas for tooth-colored plastic or ceramic brackets (to make them less visible and more esthetic); at other times, brightly colored ligatures and elastics have been popular (because everybody is wearing them). At present, both children and adolescents place metal appliances with colored Alastac ties in the most acceptable category, equal to the “esthetic” appliances often favored by adults. This is convenient for practitioners because they can use the most durable and cost-effective appliances for children and most adolescents and be on safe ground.<sup>29</sup>

The notion that “others really care about my appearance and feelings as much as I do” leads adolescents to think they are quite unique, special individuals. If this were not so, why would others be so interested in them? As a result of this thought, a second phenomenon emerges, which Elkind called the “personal fable.” This concept holds that “because I am unique, I am not subject to the consequences others will experience.” The personal fable is a powerful motivator that allows us to cope in a dangerous world. It permits us to do things such as travel on airplanes while thinking that “occasionally they crash, but the one I’m on will arrive safely.”

Although both the imaginary audience and the personal fable have useful functions in helping us develop a social awareness and allowing us to cope in a dangerous environment, they may also lead to dysfunctional behavior and even foolhardy risk-taking. The adolescent may drive too fast, thinking, “I am unique. I’m especially skilled at driving. Other less skillful drivers may have wrecks, but not I.” These phenomena are likely to have significant influence on orthodontic treatment. The imaginary audience, depending on what the adolescent believes, may influence him or her to accept or reject treatment and to wear or not wear appliances. The personal fable may make a patient ignore threats to health such as decalcification of teeth from poor oral hygiene during orthodontic therapy. The thought, of course, is, “Others may have to worry about that, but I don’t.”

The challenge for the dentist is not to try to impose change on reality as perceived by adolescents, but rather to help them more clearly see the actual reality that surrounds them. A teenage patient may protest to his orthodontist that he does not want to wear a particular appliance because others will think it makes him “look goofy.” In this situation, telling the patient that he should not be concerned because many of his peers also are wearing this appliance does little to encourage him to wear it. A more useful approach, in which one does not deny the point of view of the patient, is to agree with him that he may be right in what others will think but ask him to give it a try for a specified time. If his peers do respond as the teenager predicts, then a different but less desirable treatment technique can be discussed. This test of the teenager’s perceived reality usually demonstrates that the audience does not respond negatively to the appliance or that the patient can successfully cope with the peer response. Wearing interarch elastics while in public often falls into this category. Encouraging a reluctant



• **Fig. 2.61** Wearing orthodontic elastics during the championship high school basketball game, as this newspaper photo shows a young athlete doing, is acceptable to peers—but the orthodontist is more likely to convince a teenager of that by encouraging him to try it and test his response, than by telling him that he should do it because everybody else does. (Courtesy T.P. Laboratories.)

teenager to try it and judge his peers’ response is much more likely to get him to wear the elastics than telling him everybody else does it so he should too (Fig. 2.61).

Sometimes, teenage patients have experience with the imaginary audience regarding a particular appliance but have incorrectly measured the response of the audience. They may require guidance to help them accurately assess the view of the audience. Experience with 13-year-old Beth illustrates this point. Following the loss of a maxillary central incisor in an accident, treatment for Beth included a removable partial denture to replace the tooth. She and her parents had been told on several occasions that it would be necessary to wear the removable appliance until enough healing and growth had occurred to permit treatment with a temporary fixed bridge and finally an implant. At a routine recall appointment, Beth asked if the bridge could be placed now. Realizing that this must be a significant concern for Beth, the dentist commented “Beth, wearing this partial must be a problem. Tell me more about it.” Beth replied, “It’s embarrassing.” Inquiring further, the dentist



asked, “When is it embarrassing?” Beth said, “When I spend the night at other girls’ homes and have to take it out to brush my teeth.” “Well, what is the response of the girls when they see you remove your tooth?” Beth replied, “They think it’s cool.” Nothing more was said about making the fixed bridge now, and the conversation moved to the vacation that Beth’s family was planning.

This illustration indicates how it is possible to provide guidance toward a more accurate evaluation of the attitude of the audience and thus allow teenagers to solve their own problems. This approach on the part of the dentist neither argues with the teenager’s reality nor uncritically accepts it. One role of an effective dental professional is to help teenagers test the reality that actually surrounds them.

To be received, the dentist’s message must be presented in terms that correspond to the stage of cognitive and psychosocial development that a particular child has reached. It is the job of the orthodontist as well as the family dentist to carefully evaluate the development of the child and to adapt his or her language so that concepts are presented in a way that the patient can understand them. The adage “different strokes for different folks” applies strongly to children, whose variations in intellectual and psychosocial development affect the way they receive orthodontic treatment, just as their differing stages of physical development do.

## References

1. Farkas LG. *Anthropometry of the Head and Face*. New York: Raven Press; 1994.
2. Cevidanes LH, Motta A, Proffit WR, et al. Cranial base superimposition for 3D evaluation of soft tissue changes. *Am J Orthod Dentofacial Orthop*. 2010;137(suppl 4):S120–S129.
3. Cevidanes LH, Franco AA, Gehrig G, et al. Assessment of mandibular growth and response to orthopedic treatment with 3-dimensional magnetic resonance images. *Am J Orthod Dentofacial Orthop*. 2005;128:16–26.
4. Thompson DT. *On Growth and Form*. Cambridge: Cambridge University Press; 1971.
5. Baer MJ, Bosma JF, Ackerman JL. *The Postnatal Development of the Rat Skull*. Ann Arbor, MI: The University of Michigan Press; 1983.
6. Berdal A, Molla M, Hotton D, et al. Differential impact of MSX1 and MSX2 homeogenes on mouse maxillofacial skeleton. *Cells Tissues Organs*. 2009;189:126–132.
7. Zebrick B, Teeramongkolgul T, Nicot R, et al. ACTN3 R577X genotypes associate with Class II and deepbite malocclusions. *Am J Orthod Dentofacial Orthop*. 2014;146:603–611.
8. Brinkley JF, Fisher S, Harris MP, et al. The FaceBase Consortium: a comprehensive resource for craniofacial researchers. *Development*. 2016;143:2677–2688.
9. Frazier-Bowers SA, Simmons D, Wright JT, et al. Primary failure of eruption and PTH1R: the importance of a genetic diagnosis for orthodontic treatment planning. *Am J Orthod Dentofacial Orthop*. 2010;137:160e1–160e7, discussion 160–161.
10. Maggoli C, Stagi S. Bone modeling, remodeling and skeletal health in children and adolescents: mineral accrual, assessment and treatment. *Ann Pediatr Endocrinol Metab*. 2017;22:1–5.
11. Copray JC. Growth of the nasal septal cartilage of the rat in vitro. *J Anat*. 1986;144:99–111.
12. Delatte M, Von den Hoff JW, van Rheden RE, et al. Primary and secondary cartilages of the neonatal rat: the femoral head and the mandibular condyle. *Eur J Oral Sci*. 2004;112:156–162.
13. Gilhuus-Moe O. *Fractures of the Mandibular Condyle in the Growth Period*. Stockholm: Scandinavian University Books, Universitetsforlaget; 1969.
14. Lund K. Mandibular growth and remodelling process after mandibular fractures: a longitudinal roentgencephalometric study. *Acta Odontol Scand*. 1974;32(64):3–117.
15. Moss ML. The functional matrix hypothesis revisited. *Am J Orthod Dentofacial Orthop*. 1997;112:8–11, 221–226, 338–342, 410–417.
16. Allen KD, Wallace DP. Effectiveness of using non-contingent escape for general behavior management in a pediatric dental clinic. *J Appl Behav Anal*. 2013;46:723–737.
17. Roberts JF, Curzon ME, Koch G, et al. Review: behaviour management techniques in paediatric dentistry. *Eur Arch Paediatr Dent*. 2010;11:166–174.
18. Wright BZ, Kupietzky A. *Behavior Management in Dentistry for Children*. 2nd ed. Ames, IA: John Wiley and Sons; 2014.
19. Gustafsson A. Dental behaviour management problems among children and adolescents—a matter of understanding? Studies on dental fear, personal characteristics and psychosocial concomitants. *Swed Dent J*. 2010;(suppl 202):1–46.
20. Farhat-McHayleh N, Harfouche A, Souaid P. Techniques for managing behavior in pediatric dentistry: comparative study of live modeling and tell-show-do based on children’s heart rates during treatment. *J Can Dent Assoc*. 2009;75:283.
21. Chambers DW. Managing anxieties of young dental patients. *ASDC J Dent Child*. 1970;37:363–373.
22. Erikson EH, Schlein S, ed. *A Way of Looking at Things—Selected Papers from 1930 to 1980*. New York: WW Norton & Co; 1987:1930.
23. American Academy of Pediatric Dentistry. *Guideline on behavior guidance for the pediatric dental patient*. [http://www.aapd.org/media/Policies\\_Guidelines/G\\_BehavGuide.pdf](http://www.aapd.org/media/Policies_Guidelines/G_BehavGuide.pdf).
24. de Paula DF Jr, Santos NC, da Silva ET, et al. Psychosocial impact of dental esthetics on quality of life in adolescents. *Angle Orthod*. 2009;79:1188–1193.
25. Scheffel DLS, Jeremias F, Fragelli CMB, et al. Esthetic dental anomalies as motive for bullying in schoolchildren. *Eur J Dent*. 2014;8:124–128.
26. Wadsworth BJ. *Piaget’s Theory of Cognitive and Affective Development*. New York: Longman; 1989.
27. Oliver K, Manton DJ. Contemporary behavior management techniques in clinical pediatric dentistry: out with the old and in with the new? *J Dent Child*. 2015;82:22–28.
28. Elkind D. The teenager’s reality. *Pediatr Dent*. 1987;9:337–341.
29. Walton W, Fields HW, Johnston WM, et al. Orthodontic appliance preferences of children and adolescents. *Am J Orthod Dentofacial Orthop*. 2010;138:698e1–698e12.

# 3

## Early Stages of Development

### CHAPTER OUTLINE

#### Late Fetal Development and Birth

##### Infancy and Early Childhood: The Primary Dentition Years

- Physical Development in the Preschool Years
- Influences on Physical Development
- Maturation of Oral Function
- Eruption of the Primary Teeth

##### Late Childhood: The Mixed Dentition Years

- Physical Development in Late Childhood
- Assessment of Skeletal and Other Developmental Ages
- Eruption of the Permanent Teeth
- Eruption Sequence and Timing: Dental Age
- Space Relationships in Replacement of the Incisors
- Space Relationships in Replacement of Canines and Primary Molars

#### Late Fetal Development and Birth

By the beginning of the third trimester of intrauterine life, the human fetus weighs approximately 1000 gm and, although far from ready for life outside the protective intrauterine environment, can often survive premature birth. During the last 3 months of intrauterine life, continued rapid growth results in a tripling of body mass to about 3000 gm. Dental development, which begins in the third month, proceeds rapidly thereafter (Table 3.1). Development of all primary teeth and the permanent first molars starts well before birth.

Although the proportion of the total body mass represented by the head decreases from the fourth month of intrauterine life onward because of the cephalocaudal gradient of growth discussed earlier, at birth the head is still nearly half the total body mass and represents the largest impediment to passage of the infant through the birth canal. Making the head longer and narrower obviously would facilitate birth, and this is accomplished by a literal distortion of its shape (Fig. 3.1). The change of shape is possible because at birth, relatively large uncalcified fontanelles persist between the flat bones of the brain case. As the head is compressed within the birth canal, the brain case (calvaria) can increase in length and decrease in width, assuming the desired tubular form and easing passage through the birth canal.

The relative lack of growth of the lower jaw prenatally also makes birth easier because a prominent bony chin at the time of

birth would be a considerable problem in passage through the birth canal. Many a young dentist, acutely aware of the orthodontic problems that can arise later because of skeletal mandibular deficiency, has been shocked to discover how incredibly mandibular deficient his or her own newborn is and has required reassurance that this is a perfectly normal and indeed desirable phenomenon. Postnatally, the normal mandible grows more than the other facial structures and gradually catches up, producing the eventual balanced adult proportions.

Despite the physical adaptations that facilitate it, birth is a traumatic process. In the best of circumstances, being thrust into the world requires a dramatic set of physiologic adaptations. For a short period, growth ceases and often there is a small decrease in weight during the first 7 to 10 days of life. Such an interruption in growth produces a physical effect in skeletal tissues that are forming at the time because the orderly sequence of calcification is disturbed. The result is a noticeable line across both bones and teeth that are forming at the time. However, bones are not visible and are remodeled to such an extent that any lines caused by the growth arrest at birth would soon be covered over at any rate.

Teeth, on the other hand, are quite visible, and the extent of any growth disturbance related to birth can be seen in the enamel, which is not remodeled. Almost every child has a “neonatal line” across the surface of the primary teeth, its location varying from tooth to tooth depending on the stage of development at birth (Fig. 3.2). Under normal circumstances, the line is so slight that it can be seen only if the tooth surface is magnified, but if the neonatal period was stormy, a prominent area of stained, distorted, or poorly calcified enamel can be the result.<sup>1</sup>

Birth is not the only circumstance that can have this effect on developing teeth. As a general rule, growth disturbances lasting 1 to 2 weeks or more, such as the one that accompanies birth or one caused by a febrile illness later, will leave a visible record in the enamel of teeth forming at the time. Permanent as well as primary teeth can be affected by illnesses during infancy and early childhood.

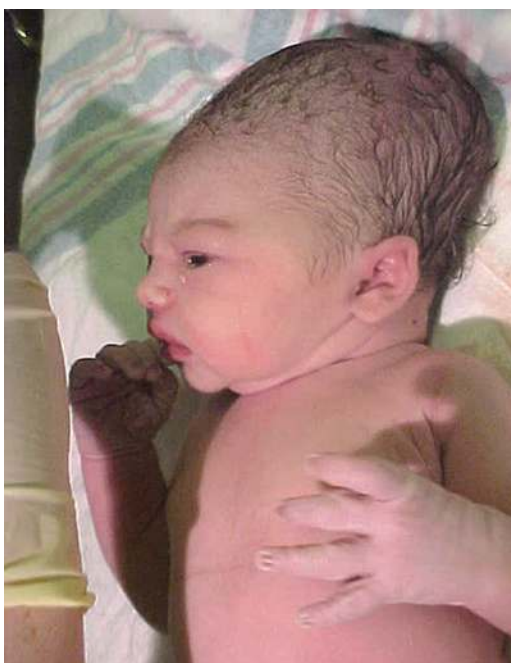#### Infancy and Early Childhood: The Primary Dentition Years

##### Physical Development in the Preschool Years

The general pattern of physical development after birth is a continuation of the pattern of the late fetal period: Rapid growth continues, with a relatively steady increase in height and weight, although the rate of growth declines dramatically as a percentage of the previous body size (Fig. 3.3).

**TABLE 3.1****Chronology of Tooth Development, Primary Dentition**

Tooth	CALCIFICATION BEGINS		CROWN COMPLETED		ERUPTION		ROOT COMPLETED	
	Maxillary	Mandibular	Maxillary	Mandibular	Maxillary	Mandibular	Maxillary	Mandibular
Central	14 wk in utero	14 wk in utero	1½ mo	2½ mo	10 mo	8 mo	1½ yr	1½ yr
Lateral	16 wk in utero	16 wk in utero	2½ mo	3 mo	11 mo	13 mo	2 yr	1½ yr
Canine	17 wk in utero	17 wk in utero	9 mo	9 mo	19 mo	20 mo	3¼ yr	3¼ yr
First molar	15 wk in utero	15 wk in utero	6 mo	5½ mo	16 mo	16 mo	2½ yr	2¼ yr
Second molar	19 wk in utero	18 wk in utero	11 mo	10 mo	29 mo	27 mo	3 yr	3 yr



• **Fig. 3.1** This photograph of a newborn infant clearly shows the head distortion that accompanies (and facilitates) passage through the birth canal. Note that the head has been squeezed into a more elliptical or tubular “cone-head” shape, a distortion made possible by the presence of the relatively large fontanelles.

## Influences on Physical Development

Four circumstances merit special attention.

### 1. Premature Birth (Low Birth Weight)

Infants weighing less than 2500 gm at birth are at greater risk of problems in the immediate postnatal period. Since low birth weight is a reflection of premature birth, it is reasonable to establish the prognosis in terms of birth weight rather than estimated gestational age within a population. Until recent years, children with birth weights below 1500 gm often did not survive. Even with the best current specialized neonatal services, the chances of survival for extremely low birth weight (ELBW) infants (less than 1000 gm) are not good, although some now are saved. In fact, birth weight, illness, and day of life (DOL) combine to be better predictors of

survival. Eighty percent of deaths in ELBW infants occur in the first 3 days of life; consequently, once an infant has survived to DOL 4, the likelihood of survival is dramatically increased and depends more on the extent of illness at that point.<sup>2</sup>

If a premature infant survives the neonatal period, however, there is every reason to expect that growth will follow the normal pattern and that the child will gradually overcome the initial handicap (Fig. 3.4). Premature infants can be expected to be small throughout the first and into the second years of life. In many instances, by the third year of life premature and normal-term infants are indistinguishable in attainment of developmental milestones. Although there was concern about a relationship between ELBW and later coronary disease, this has not been supported by recent clinical trials.<sup>3</sup> For the orthodontist, a history of premature birth is not an indicator of problems with childhood or adolescent orthodontic treatment.

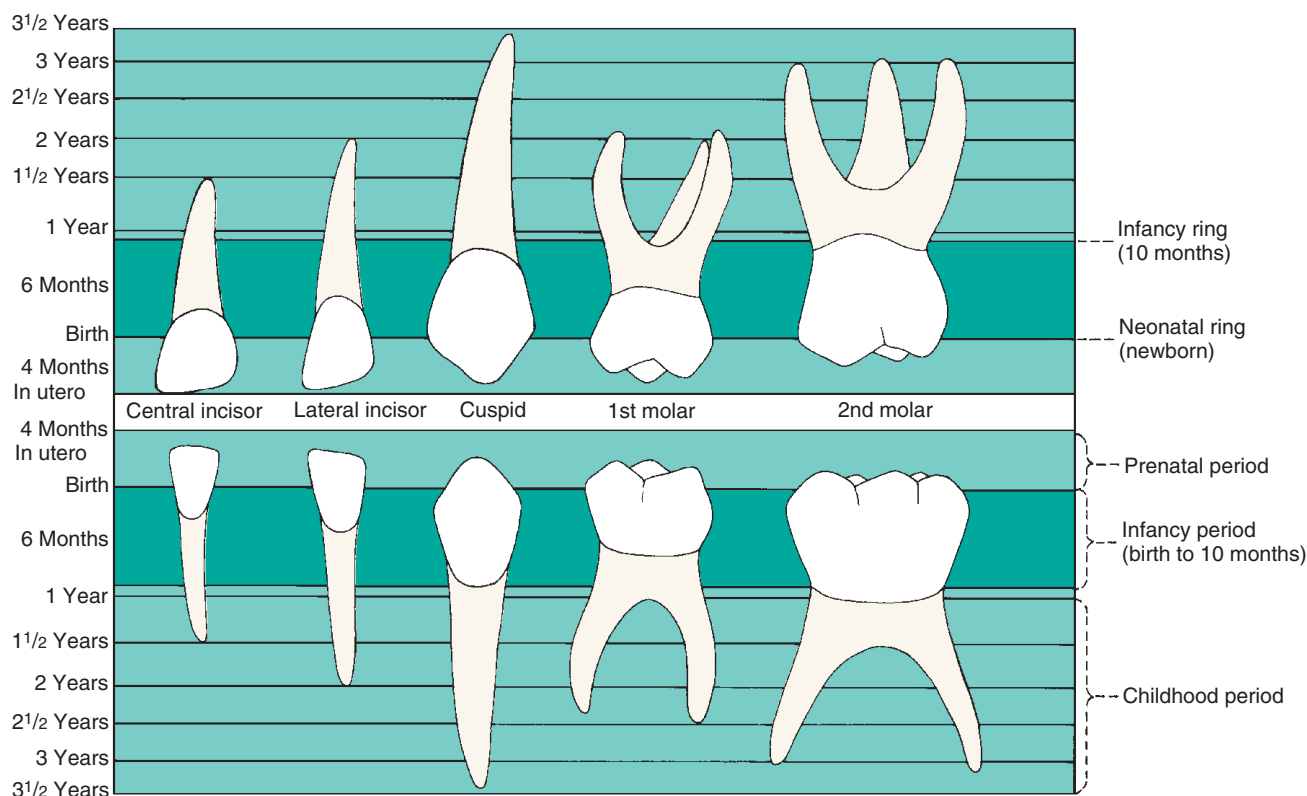
### 2. Chronic Illness

Skeletal growth is a process that can occur only when the other requirements of the individual have been met. A certain amount of energy is necessary to maintain life. An additional amount is needed for activity, and a further increment is necessary for growth. For a normal child, perhaps 90% of the available energy must be “taken off the top” to meet the requirements for survival and activity, leaving 10% for growth.

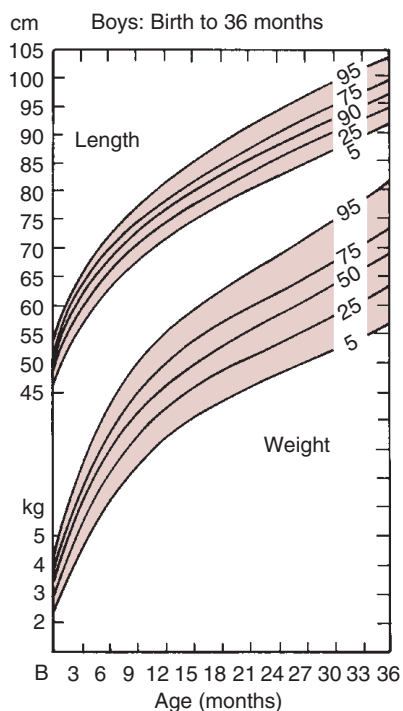
Chronic illness alters this balance, leaving relatively less of the total energy available to support growth. Chronically ill children typically fall behind their healthier peers in height and weight, and if the illness persists, the growth deficit is cumulative. An episode of acute illness leads to a temporary cessation of growth, but if the growth interruption is relatively brief, there will be no long-term effect. The more chronic the illness, the greater the cumulative impact. Obviously, the more severe the illness, the greater the impact at any given time. Children with congenital hormone deficiencies provide an excellent example. If the hormone is replaced, a dramatic improvement in growth and recovery toward normal height and weight often occurs (Fig. 3.5). A congenital heart defect can have a similar effect on growth, and similarly dramatic effects on growth can accompany repair of the defect.<sup>4</sup> In extreme cases, psychologic and emotional stress affect physical growth in somewhat the same way as chronic illness (Fig. 3.6).

### 3. Nutritional Status

For growth to occur, there must be a nutritional supply in excess of the amount necessary for mere survival. Chronically inadequate



• **Fig. 3.2** Primary teeth shown on a developmental scale that indicates the expected location of the neonatal line. From a chart of this type, the timing of illness or traumatic events that led to disturbances of enamel formation can be deduced from the location of enamel lines on various teeth.



• **Fig. 3.3** Graphs of growth in length and weight in infancy for boys (the curves for girls are almost identical at these ages). Note the extremely rapid growth in early infancy, with a progressive slowing after the first 6 months. (Based on data from the National Center for Health Statistics, Washington, DC.)

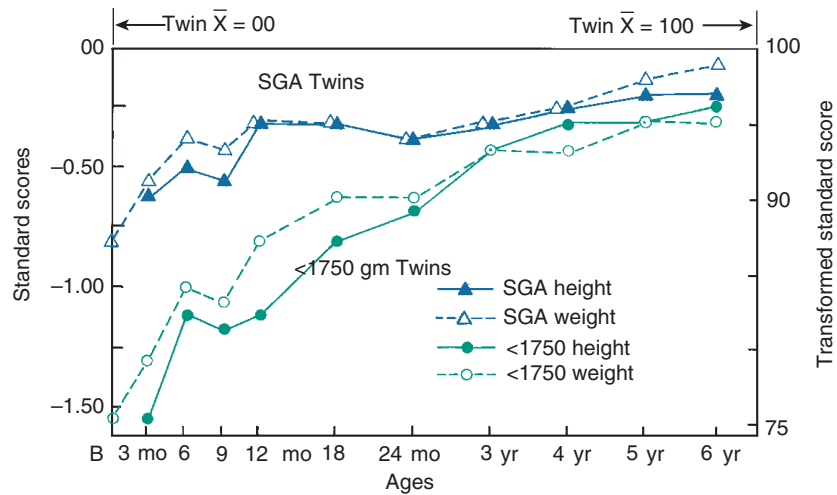
nutrition therefore has an effect similar to chronic illness. On the other hand, once a level of nutritional adequacy has been achieved, additional nutritional intake is not a stimulus to more rapid growth. Adequate nutrition, like reasonable overall health, is a necessary condition for normal growth but is not a stimulus to it.

#### 4. Secular Change in Growth and Development

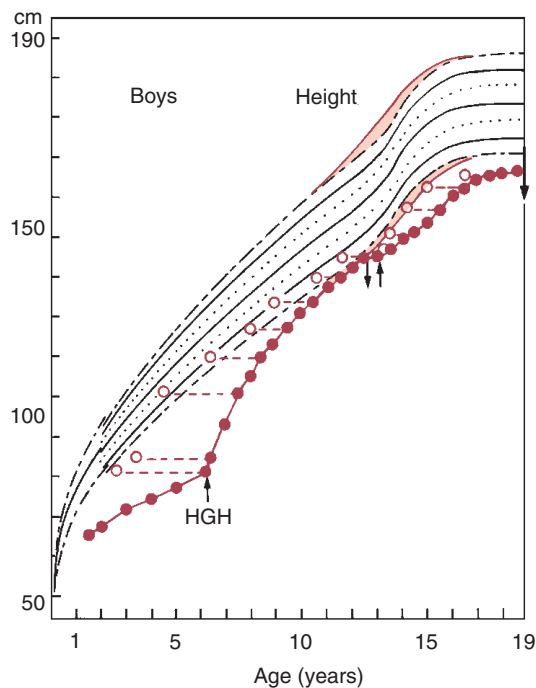
An interesting phenomenon of the last 300 or 400 years, particularly the 20th century, has been a generalized increase in size of most individuals. There has also been a lowering in the age of sexual maturation, so that children recently have grown faster and matured earlier than they did previously. Since 1900, in the United States the average height has increased 2 to 3 inches, and the average age of girls at first menstruation, the most reliable sign of sexual maturity, has decreased by more than 1 year (Fig. 3.7). This “secular trend” toward more rapid growth and earlier maturation continued in most countries throughout the 20th century<sup>5</sup> (e.g., the mean age in Poland in 1982 to 1984 was 13.2 years, and 12.8 years in 1992 to 1994) but seems to be leveling off in the developed countries at present.<sup>6</sup> That still means that signs of sexual maturation now appear in many otherwise-normal girls much earlier than the previously accepted standard dates, which have not been updated to match the secular change.

This trend undoubtedly is related to better nutrition, which allows the faster weight gain that by itself can trigger earlier maturation. Physical growth requires protein, and it is likely that the amount of protein may have been a limiting factor for many populations in the past.<sup>7</sup> A generally adequate diet that was low in trace minerals, vitamins, or other minor but important components also may have limited the rate of growth in the past, so even a small change

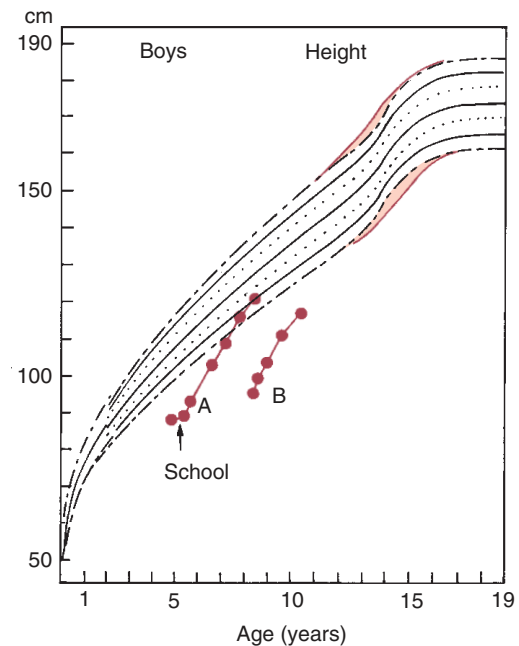




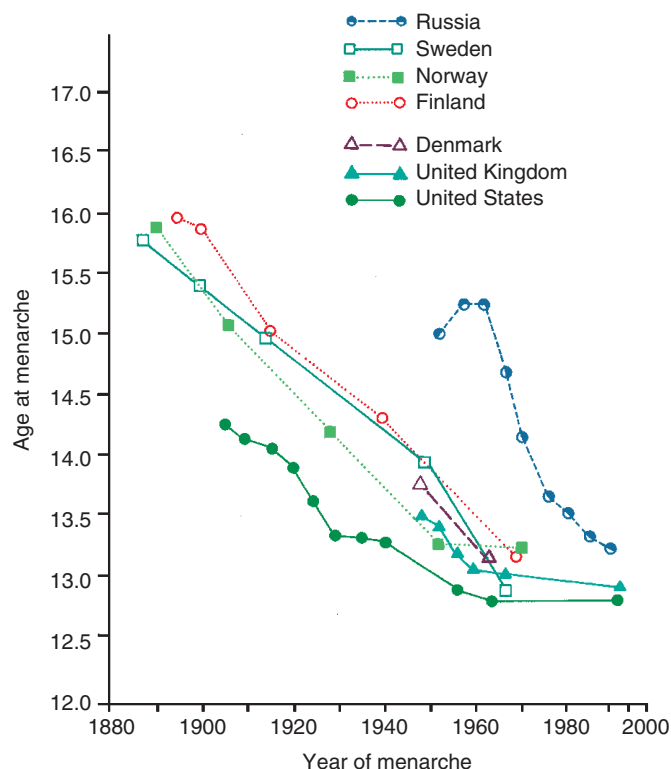
• **Fig. 3.4** Growth curves for two at-risk groups of infants: small-for-gestational age (SGA) twins and twins of less than 1750 gm birth weight (premature birth). In this graph, 100 is the expected height and weight for normal, full-term infants. Note the recovery of the low birth weight infants over time. (Redrawn from Lowery GH. *Growth and Development of Children*. 8th ed. Chicago: Year Book Medical Publishers; 1986.)



• **Fig. 3.5** The curve for growth in height for a boy with isolated growth hormone deficiency. No treatment was possible until he was 6.2 years of age. At that point, human growth hormone (HGH) became available, and it was administered regularly from then until age 19, except for 6 months from 12.5 to 13 years. The beginning and end of HGH administration are indicated by the arrows. The open circles represent height plotted against bone age; thus delay in bone age is represented by the length of each horizontal dashed line. The delay was 3.5 years at the beginning of treatment and 0.8 years at 11 to 12 years, when catch-up was essentially complete. Note the very high growth rate immediately after treatment started, equal to the average rate of a 1-year-old infant. (Redrawn from Tanner JM, Whitehouse RH. *Atlas of Children's Growth*. London: Academic Press; 1982.)



• **Fig. 3.6** The effect of a change in social environment on growth of two children who had an obviously disturbed home environment, but no identifiable organic cause for the growth problem. When both children were placed in a special boarding school where presumably their psychosocial stress was lessened, both responded with above-average growth, though the more severely affected child was still outside the normal range 4 years later. The mechanism by which psychosocial stress can affect growth so markedly is thought to be induction of a reversible growth hormone deficiency, accompanied by disturbance of the nearby appetite center. (Redrawn from Tanner JM, Whitehouse RH. *Atlas of Children's Growth*. London: Academic Press; 1982.)



• **Fig. 3.7** Age at menarche declined in both the United States and northern European countries in the first half of the 20th century. On average, children are now larger at any given age than in the early 1900s, and they also mature more quickly. This secular trend seems to have leveled off in the early part of the 21st century. (Redrawn from Tanner JM. *Foetus into Man*. Cambridge, MA: Harvard University Press; 1978; 1995 U.S. data from Herman-Giddens ME, et al. *Pediatrics*. 1997;99:505–512; 1995 British data from Cooper C, et al. *Br J Obstet Gynaecol*. 1996;103:814–817; Russian data from Dubrova YE, et al. *Hum Biol*. 1995;67:755–767.)

to supply previously deficient items may in some instances have allowed a considerable increase in growth. Because a secular trend toward earlier maturity also has been observed in populations whose nutritional status does not seem to have improved significantly, nutrition may not be the entire explanation. It has been suggested but not clearly demonstrated that exposure to chemicals in the environment that have estrogenic effects (such as some pesticides or animal feed supplements) may also have played a role.

Secular changes in body proportions, which presumably reflect environmental influences, also have been observed. It is interesting that skull proportions changed during the last century, with the head and face becoming taller and narrower.<sup>7</sup> Some anthropologists feel that such changes are related to the trend toward a softer diet and less functional loading of the facial skeleton (see Chapter 5), but firm evidence does not exist.

## Maturation of Oral Function

The principal physiologic functions of the oral cavity are respiration, swallowing, mastication, and speech. Although it may seem odd to list respiration as an oral function, given that the major portal for respiration is the nose, respiratory needs are a primary determinant of posture of the mandible and tongue.

At birth, if the newborn infant is to survive, an airway must be established within a few minutes and must be maintained thereafter. As Bosma<sup>8</sup> demonstrated with a classic radiographic study of newborn infants, to open the airway the mandible must be positioned downward and the tongue moved downward and forward away from the posterior pharyngeal wall. This allows air to be moved through the nose and across the pharynx into the lungs. Newborn infants are obligatory nasal breathers and do not survive without immediate medical support if the nasal passage is blocked at birth. Later, breathing through the mouth becomes physiologically possible. At all times during life, respiratory needs can alter the postural basis from which oral activities begin.

Respiratory movements are “practiced” in utero, although the lungs do not inflate at that time. Swallowing also occurs during the last months of fetal life, and it appears that swallowed amniotic fluid may be an important stimulus to activation of the infant’s immune system.

Once an airway has been established, the newborn infant’s next physiologic priority is to obtain milk and transfer it into the gastrointestinal system. This is accomplished by two maneuvers: suckling (not sucking, with which it is frequently confused) and swallowing.

The milk ducts of lactating mammals are surrounded by smooth muscle, which contracts to force out the milk. To obtain milk, the infant does not have to suck it from the mother’s breast and probably could not do so. Instead, the infant’s role is to stimulate the smooth muscle to contract and squirt milk into his mouth. This is done by suckling, consisting of small nibbling movements of the lips, a reflex action in infants. When the milk is squirted into the mouth, it is only necessary for the infant to groove the tongue and allow the milk to flow posteriorly into the pharynx and esophagus. The tongue, however, must be placed anteriorly in contact with the lower lip so that milk is in fact deposited on the tongue.

This sequence of events defines an infantile swallow, which is characterized by active contractions of the musculature of the lips, a tongue tip brought forward into contact with the lower lip, and little activity of the posterior tongue or pharyngeal musculature. Tongue-to-lower lip apposition is so common in infants that this posture is usually adopted at rest, and it is frequently possible to gently move the infant’s lip and note that the tongue tip moves with it, almost as if the two were glued together (Fig. 3.8). The suckling reflex and the infantile swallow normally disappear during the first year of life.

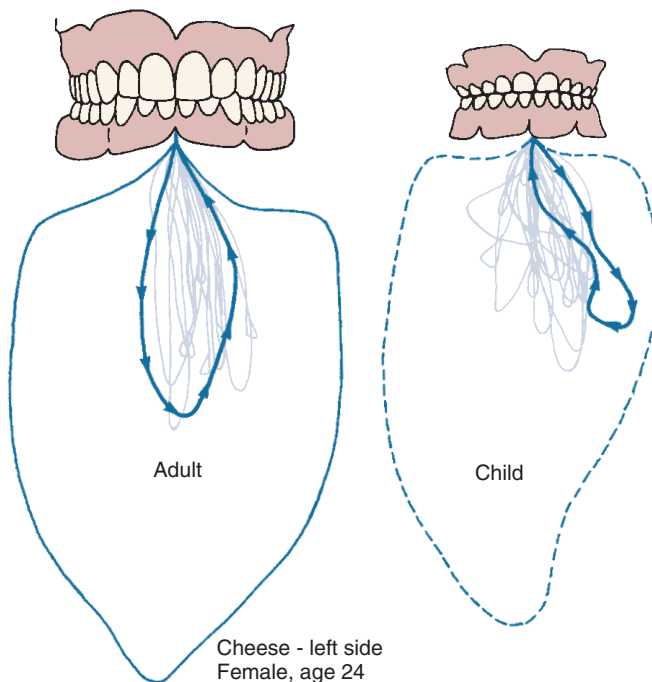
As the infant matures, there is increasing activation of the elevator muscles of the mandible as the child swallows. As semisolid and eventually solid foods are added to the diet, it is necessary for the child to use the tongue in a more complex way to gather up a bolus, position it along the middle of the tongue, and transport it posteriorly. The chewing movements of a young child typically involve moving the mandible laterally as it opens, then bringing it back toward the midline and closing to bring the teeth into contact with the food (Fig. 3.9). By the time the primary molars begin to erupt, this sort of juvenile chewing pattern is well established. Also, by this time, the more complex movements of the posterior part of the tongue have produced a definite transition beyond the infantile swallow.

Maturation of oral function can be characterized in general as following a gradient from anterior to posterior. At birth, the lips are relatively mature and capable of vigorous suckling activity, whereas more posterior structures are quite immature. As time passes, greater activity by the posterior parts of the



• **Fig. 3.8** Characteristic placement of the tongue against the lower lip in an infant at a few months of age. At this stage of development, tongue contact with the lip is maintained most of the time.

Chewing movements at the central incisor



• **Fig. 3.9** Chewing movements of a child contrasted with those of an adult. Children move the jaw laterally on opening, whereas adults open straight down, then move the jaw laterally. (Redrawn from Lundeen HC, Gibbs CH. *Advances in Occlusion*. Boston, MA: John Wright's PSG; 1982.)

tongue and more complex motions of the pharyngeal structures are acquired.

This principle of front-to-back maturation is particularly well illustrated by the acquisition of speech. The first speech sounds are the bilabial sounds /m/, /p/, and /b/, which is why an infant's

first word is likely to be “mama” or “papa.” Somewhat later, the tongue tip consonants such as /t/ and /d/ appear. The sibilant /s/ and /z/ sounds, which require placing the tongue tip close to but not against the palate, come later still. The last speech sound, /r/, which requires precise positioning of the posterior tongue, often is not acquired until age 4 or 5.

Nearly all modern infants engage in some sort of habitual non-nutritive sucking—sucking a thumb, finger, or a similarly shaped object. Some fetuses have been reported to suck their thumbs in utero, and almost all infants do so during the period from 6 months to 2 years or later. This is culturally determined to some extent; children in primitive groups who are allowed ready access to the mother's breast indefinitely rarely suck any other object.<sup>9</sup>

After the primary molars erupt during the second year of life, drinking from a cup replaces drinking from a bottle or continued nursing at the mother's breast, and the number of children who engage in non-nutritive sucking diminishes. When sucking activity stops, a continued transition in the pattern of swallow leads to the acquisition of an adult pattern. This type of swallow is characterized by a cessation of lip activity (i.e., lips relaxed, with the tongue tip placed against the alveolar process behind the upper incisors, and the posterior teeth brought into occlusion during swallowing). As long as sucking habits persist, however, there will not be a total transition to the adult swallow.

Surveys of American children indicate that at age 8 about 60% have achieved an adult swallow, and the remaining 40% are still somewhere in the transition.<sup>10</sup> After sucking habits are extinguished, a complete transition to the adult swallow may require some months. This is complicated, however, by the fact that an anterior open bite, which may well be present if a sucking habit has persisted for a long time, can delay the transition even further because of the physiologic need to seal the anterior space. The relationship of tongue position and the pattern of swallowing to malocclusion is discussed further in [Chapter 5](#).

The chewing pattern of the adult is quite different from that of a typical child: An adult typically opens straight down, then moves the jaw laterally and brings the teeth into contact, whereas a child moves the jaw laterally on opening (see [Fig. 3.9](#)). The transition from the juvenile to the adult chewing pattern develops in conjunction with eruption of the permanent canines, at about age 12. It is interesting to note that adults who do not achieve normal function of the canine teeth because of a severe anterior open bite retain the juvenile chewing pattern.

### Eruption of the Primary Teeth

At birth, neither the maxillary nor the mandibular alveolar process is well developed. Occasionally a “natal tooth” is present, although the first primary teeth normally do not erupt until approximately 6 months of age. The natal tooth may be a supernumerary one, formed by an aberration in the development of the dental lamina, but usually is merely a very early but otherwise normal central incisor. Because of the possibility that it is perfectly normal, such a natal tooth should not be extracted casually.

The timing and sequence of eruption of the primary teeth were shown in [Table 3.1](#) at the beginning of this chapter. The dates of eruption are relatively variable; up to 6 months of acceleration or delay is within the normal range. Preterm infants typically have some delay,<sup>11</sup> and there is some variance among ethnic groups.<sup>12</sup> The eruption sequence, however, is usually preserved. One can expect that the mandibular central incisors will erupt first, closely followed by the other incisors. After a 3- to 4-month interval, the

mandibular and maxillary first molars erupt, followed in another 3 or 4 months by the maxillary and mandibular canines, which nearly fill the space between the lateral incisor and first molar. The primary dentition is usually completed at 24 to 30 months as the mandibular then the maxillary second molars erupt.

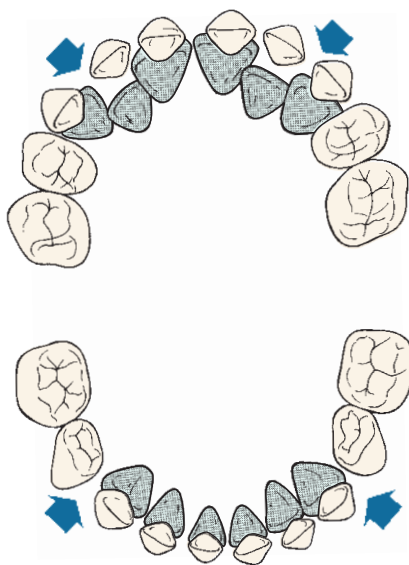
Spaces between the teeth are normal throughout the anterior part of the primary dentition but are most noticeable in two locations, called the *primate spaces*. (Most subhuman primates have these spaces throughout life; thus the name.) In the maxillary arch the primate space is located between the lateral incisors and canines, whereas in the mandibular arch the space is between the canines and first molars (Fig. 3.10). The primate spaces are normally present from the time the teeth erupt. Developmental spaces between the incisors are often present from the beginning but become somewhat larger as the child grows and the alveolar processes expand. Generalized spacing of the primary teeth is a requirement for proper alignment of the permanent incisors.

## Late Childhood: The Mixed Dentition Years

### Physical Development in Late Childhood

Late childhood, from age 5 or 6 to the onset of puberty, is characterized by important social and behavioral changes (see Chapter 2), but the physical development pattern of the previous period continues. The normally different rates of growth for different tissue systems, however, must be kept in mind. The maximum disparity in the development of different tissue systems occurs in late childhood (see Fig. 2.2).

By age 7, a child has essentially completed his or her neural growth. The brain and the brain case are as large as they will ever be, and it will never be necessary again to buy the child a larger cap because of growth (unless, of course, the growth is of uncut hair). Lymphoid tissue throughout the body has proliferated beyond the usual adult levels, and large tonsils and adenoids are common. In contrast, growth of the sex organs has hardly begun and general body growth is only modestly advanced. During early childhood,



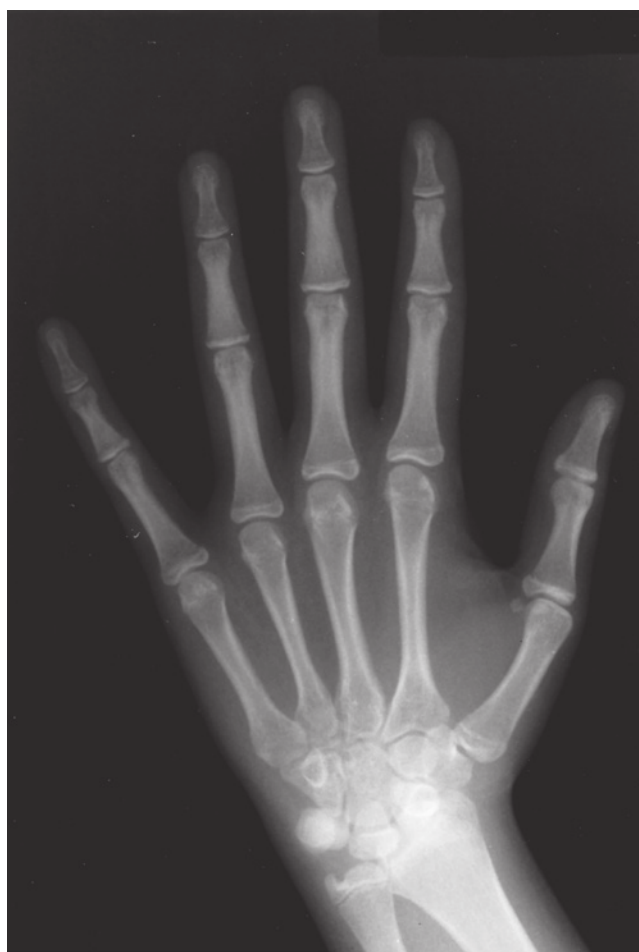• **Fig. 3.10** The crowns of the permanent incisors (gray) lie lingual to the crowns of the primary incisors (yellow), particularly in the case of the maxillary laterals. Arrows point to the primate spaces.

the rate of general body growth declines from the rapid pace of infancy, then stabilizes at a moderate lower level during late childhood. Both nutrition and general health can affect the level at which stabilization occurs.

### Assessment of Skeletal and Other Developmental Ages

In planning orthodontic treatment, it can be important to know how much skeletal growth remains, so an evaluation of skeletal age is frequently needed. This is particularly important when the timing of treatment for Class II patients is considered, because it is most effective when done during the adolescent growth spurt. A reliable assessment of skeletal age must be based on the maturational status of markers within the skeletal system.

The ossification of the bones of the hand and the wrist was for many years the standard for skeletal development (Fig. 3.11). A radiograph of the hand and wrist provides a view of some 30 small bones, all of which have a predictable sequence of ossification. Although a view of no single bone is diagnostic, an assessment of the level of development of the bones in the wrist, hand, and fingers can give an accurate picture of a child's skeletal development status. To do this, a hand–wrist radiograph of the patient is simply



• **Fig. 3.11** A radiograph of the hand and wrist can be used to assess skeletal age by comparing the degree of ossification of the wrist, hand, and finger bones to plates in a standard atlas of hand and wrist development.



compared with standard radiographic images in an atlas of the development of the hand and wrist.<sup>13</sup> It has been shown that stages of hand–wrist development correlate reasonably well with the adolescent spurt in growth of the mandible.

A similar assessment of skeletal age based on the cervical vertebrae, as seen in a cephalometric radiograph (the cervical vertebral maturation [CVM] method), has been developed.<sup>14</sup> The characteristics on which vertebral aging is based are described and illustrated in Fig. 3.12. Because cephalometric radiographs are obtained routinely for orthodontic patients, this method has the advantage over hand–wrist radiographs that additional radiation exposure is not needed to judge the probable timing of the adolescent growth spurt. Although some reports have questioned the reliability and validity of skeletal age derived from the cervical vertebrae,<sup>15</sup> with one study concluding that chronologic age is as good a predictor as the CVM method,<sup>16</sup> a number of other studies of CVM have concluded that intraobserver and interobserver reliability is quite good, about the same as with hand–wrist radiographs, and a recent prospective study provided a review of the literature and confirmed this finding.<sup>17</sup> A reasonable summary of the current data is that (1) the improvement in assessing growth status relative to peak growth at adolescence from using hand–wrist radiographs, if any, is not worth the extra radiation except in special circumstances, and (2) CVM is a better predictor for timing of the adolescence growth spurt than chronologic age.

Developmental ages based on any criteria can be established, if there is some scale against which a child's progress can be measured. For instance, one could measure a child's position on a scale of behavior, equating behavior of certain types as appropriate for 5-year-olds or 7-year-olds. In fact, behavioral age can be important in the dental treatment of children because it is difficult to render satisfactory treatment if the child cannot be induced to behave appropriately and cooperate. The assessment of behavioral age is covered more completely in the section on social and behavioral development in Chapter 2.

The correlation between developmental ages of all types and chronologic age is quite good, as biologic correlations go (Fig. 3.13). For most developmental indicators, the correlation coefficient between developmental status and chronologic age is about 0.8. The ability to predict one characteristic from another varies as the square of the correlation coefficient, so the probability that one could predict the developmental stage from knowing the chronologic age or vice versa is  $(0.8)^2 = 0.64$ . You would have two chances out of three of predicting one from the other. The correlation of dental age with chronologic age (discussed in detail later) is not quite as good, about 0.7, which means that there is only about a 50% chance of predicting the stage of dental development from the chronologic age.

It is interesting that the developmental ages correlate better among themselves than the developmental ages correlate with chronologic age. Despite the caricature in our society of the intellectually advanced but socially and physically delayed child, the chances are that a child who is advanced in one characteristic—skeletal age, for instance—is advanced in others as well. The mature-looking and maturely behaving 8-year-old child is quite likely, in other words, also to have an advanced skeletal age and is reasonably likely to have precocious development of the dentition. What will actually occur in any one individual is subject to the almost infinite variety of human variation, and the magnitude of the correlation coefficients must be kept in mind. Unfortunately for those dentists who want to examine only the teeth, the variations in dental development mean that it often is necessary to assess

skeletal, behavioral, or other developmental ages in planning dental treatment.

## Eruption of the Permanent Teeth

The eruption of any tooth can be divided into several stages. This includes the primary teeth. The physiologic principles underlying eruption that are discussed in this section are not different for the primary teeth, despite the root resorption that eventually causes their loss. The nature of eruption and its control before the emergence of the tooth into the mouth are somewhat different after emergence, and we will consider these major stages separately.

### Preemergent Eruption

During the period when the crown of a tooth is being formed, there is a very slow labial or buccal drift of the tooth follicle within the bone, but this follicular drift is not attributed to the eruption mechanism itself. In fact, the amount of change in the position of the tooth follicle is extremely small, observable only with vital staining experiments and so small that a follicle can be used as a natural marker in radiographic studies of growth. Eruptive movement begins soon after the root begins to form. This supports the idea that metabolic activity within the periodontal ligament is necessary for eruption.

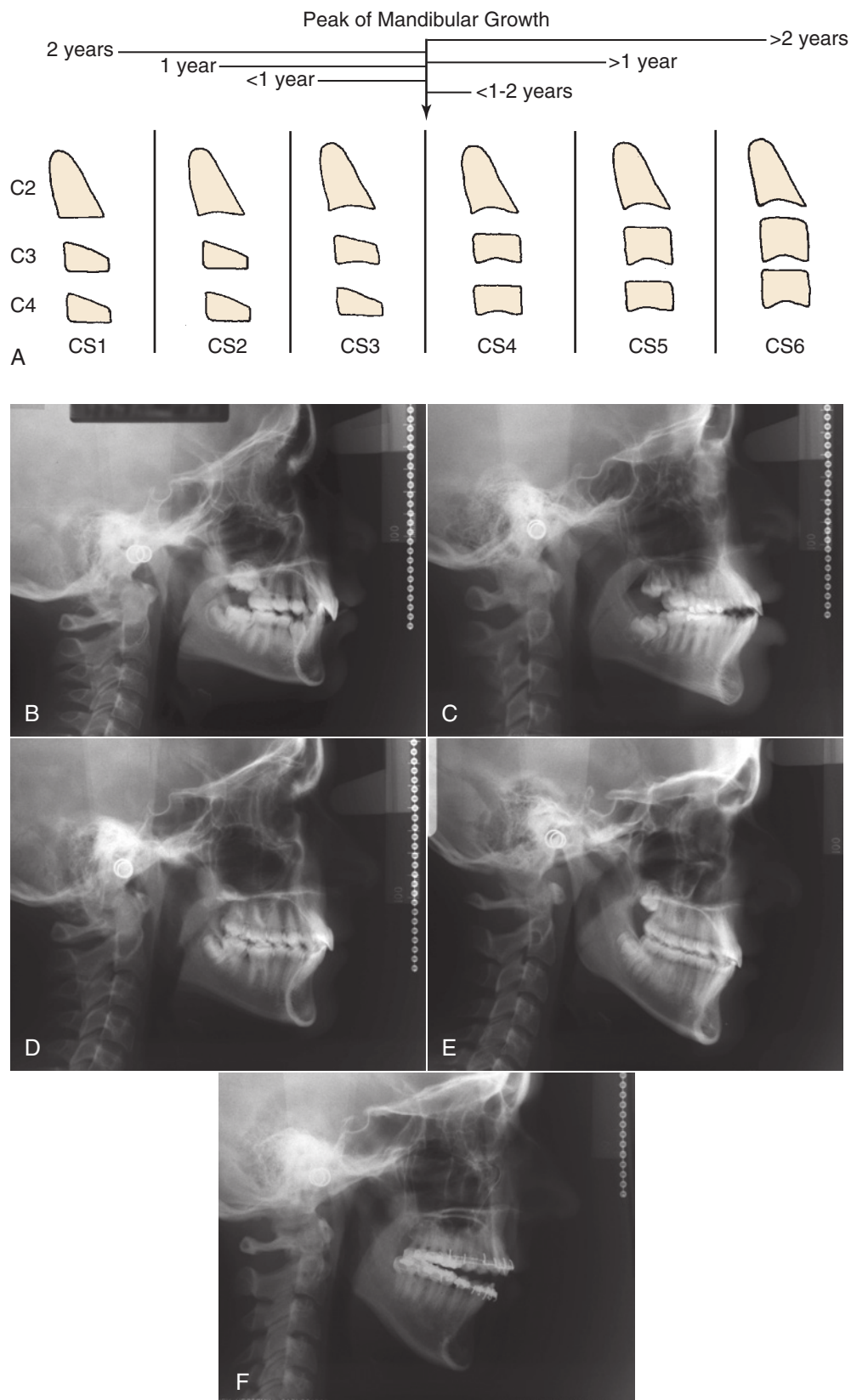
Two processes are necessary for preemergent eruption. First, there must be resorption of bone and primary tooth roots overlying the crown of the erupting tooth; second, a propulsive mechanism then must move the tooth in the direction where the path has been cleared (Fig. 3.14). Although the two mechanisms normally operate in concert, in some circumstances they do not. Investigations of the results of a failure of bone resorption, or alternately of a failure of the propulsive mechanism when bone resorption is normal, have yielded considerable insight into the control of preemergent eruption.

Defective bone resorption occurs in a mutant species of mice, appropriately labeled *ia*, for *incisors absent*. In these animals a lack of bone resorption means that the incisor teeth cannot erupt, and they never appear in the mouth. Failure of teeth to erupt because of a failure of bone resorption also occurs in humans, as for instance in the syndrome of cleidocranial dysplasia (Fig. 3.15). In children with this condition, not only is resorption of primary teeth and bone deficient, but heavy fibrous gingiva and multiple supernumerary teeth also impede normal eruption. The effect is to mechanically block the succedaneous teeth (those replacing primary teeth) from erupting. If the interferences are removed, the teeth often erupt and can be brought into occlusion.

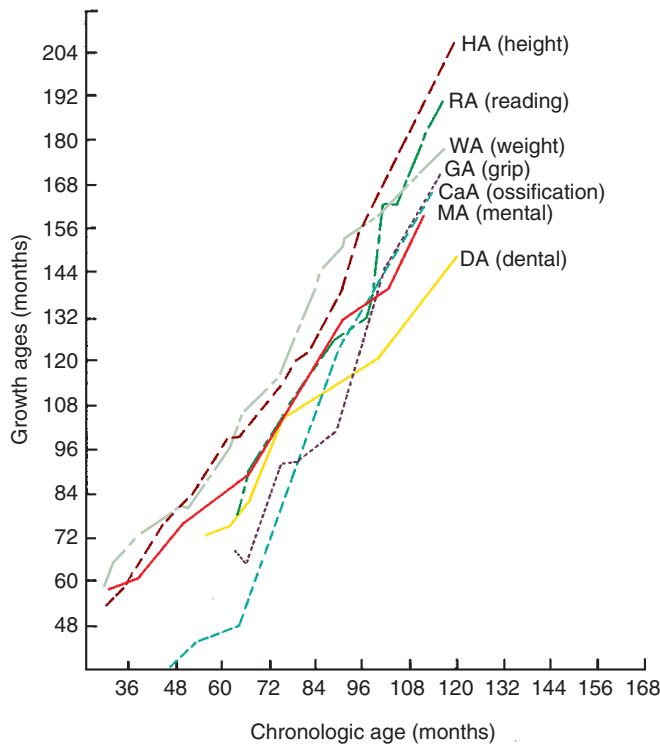
It has been demonstrated experimentally in animals that the rate of bone resorption and the rate of tooth eruption are not controlled physiologically by the same mechanism. For instance, if the tooth bud of a dog premolar is wired to the lower border of the mandible, the tooth can no longer erupt because of this mechanical obstruction, but resorption of overlying bone proceeds at the usual rate, resulting in a large cystic cavity overlying the ligated tooth bud.

On several occasions, the same experiment has inadvertently been done to a child. If an unerupted permanent tooth is wired to the adjacent bone when a jaw fracture is repaired, as in the child shown in Fig. 3.16, the result is the same as in the animal experiments: Eruption of the tooth stops, but bone resorption to clear an eruption path continues.

It seems clear, therefore, that resorption is the rate-limiting factor in preemergent eruption. Normally, the overlying bone and



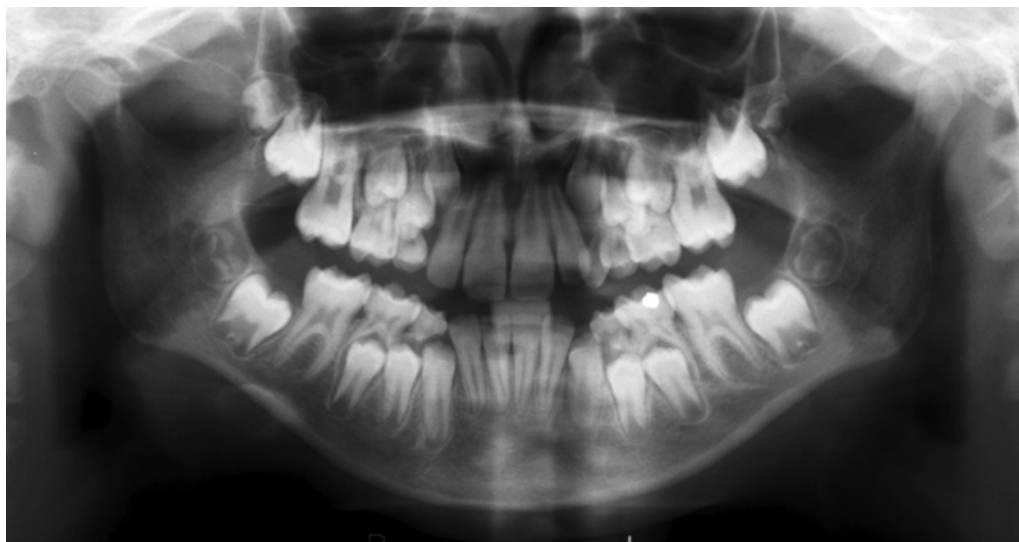
• **Fig. 3.12** Vertebral ages calculated from the image of the cervical vertebrae seen in a lateral cephalometric radiograph. (A) Diagrammatic drawings and relationships of the stages to the peak of mandibular growth. (B) Stage 2, indicating that peak growth at adolescence is still a year or so ahead. (C) Stage 3, which on average occurs less than 1 year prior to peak growth. (D) Stage 4, typically a year or so beyond peak growth. (E) Stage 5, more than 1 year beyond the peak of the growth spurt, probably with more vertical than anteroposterior growth remaining. (F) Stage 6, more than 2 years beyond peak growth (but a patient with a severe skeletal problem, especially excessive mandibular growth, is not necessarily ready for surgery; the best way to determine the cessation of growth is serial cephalometric radiographs). ([A] from Baccetti T, Franchi L, McNamara JA Jr. *Semin Orthod.* 2005;11:119–129.)



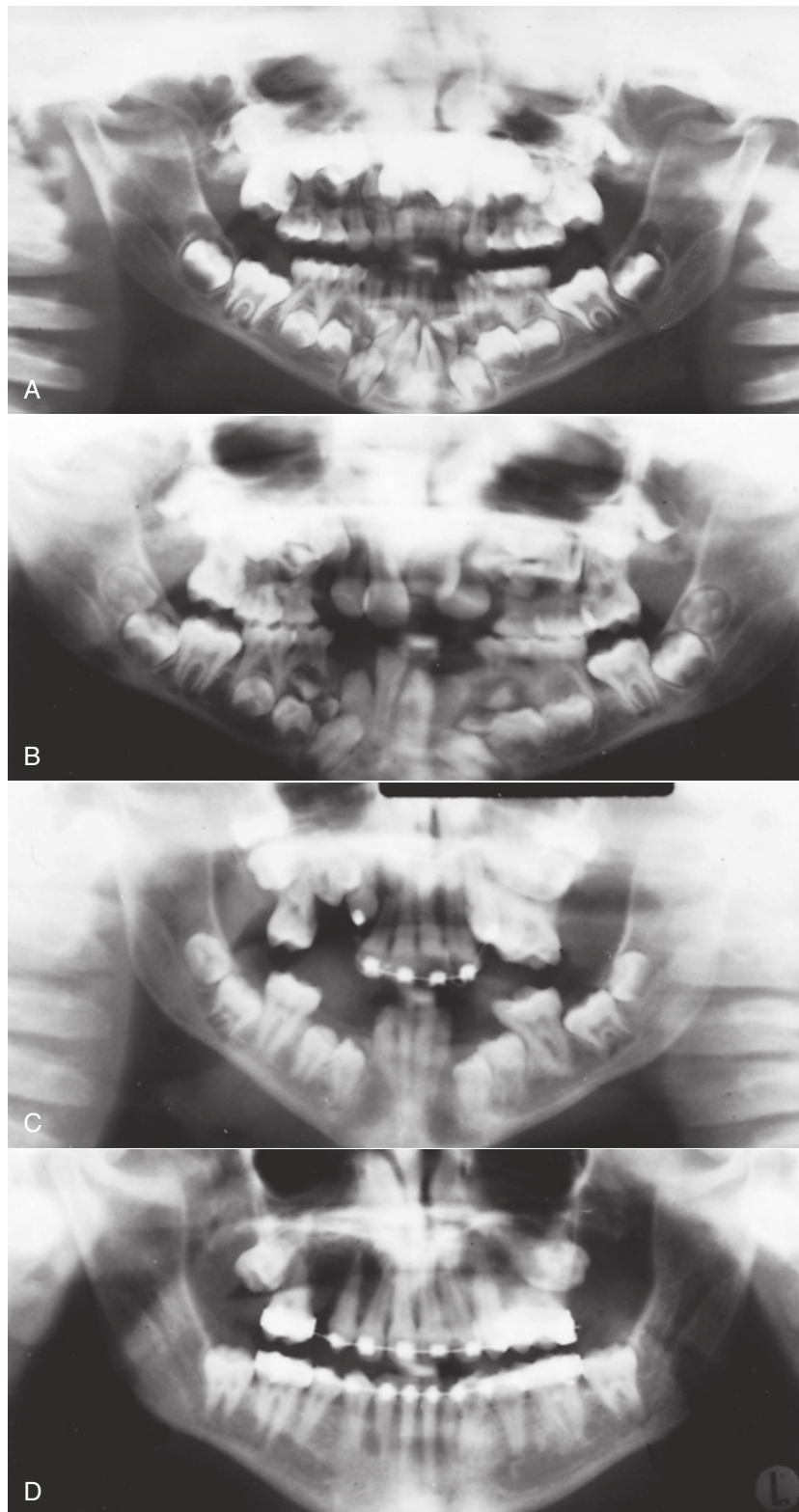
• **Fig. 3.13** Changes in various developmental parameters for one normal child. Note that this child was advanced for his chronologic age in essentially all the parameters and that all are reasonably well correlated. For this individual, as for many children, dental age correlated less well with the group of developmental indicators than any of the others. (Redrawn from Lowery GH. *Growth and Development of Children*. 6th ed. Chicago: Year Book Medical Publishers; 1973.)

primary teeth resorb, and the propulsive mechanism then moves the tooth into the space created by the resorption. The signal for resorption of bone over the crown of the tooth is activated by the completion of the crown, which also removes inhibition of the genes that are necessary for root formation as well as inhibition of the layer of osteoclasts that forms just above the top of the crown and creates the eruption path. Because resorption is the controlling factor, active formation of the root is not necessary for continued clearance of an eruption path or for movement of a tooth along it. A tooth will continue to erupt after its apical area has been removed, so the proliferation of cells associated with lengthening of the root is not an essential part of the mechanism. Normally, the rate of eruption is such that the apical area remains at the same place while the crown moves occlusally, but if eruption is mechanically blocked, the proliferating apical area will move in the opposite direction, inducing resorption where it usually does not occur (Fig. 3.17). This often causes a distortion of root form, which is called *dilaceration*.

The same pattern of unerupted teeth that do not follow the eruption path that has been cleared for them is also seen in the rare but now well-documented human syndrome called primary failure of eruption (PFE)<sup>18</sup> (see Fig. 12.4). In these patients, however, the reason for the eruption failure is different. The teeth are not mechanically prevented from eruption, because when they are surgically exposed, there is no evidence of ankylosis. Instead, it appears that the propulsive mechanism that moves the tooth along the eruption path is defective. A mutation in the parathyroid hormone receptor gene (*PTHRI*) that leads to this condition has been identified, and a genetic test to confirm the diagnosis is possible, but family studies indicate that other genes are involved and the specific mutation that has been identified is not found in all patients.<sup>19</sup> The involved teeth do not respond to orthodontic force and cannot be moved into position, which is evidence of an

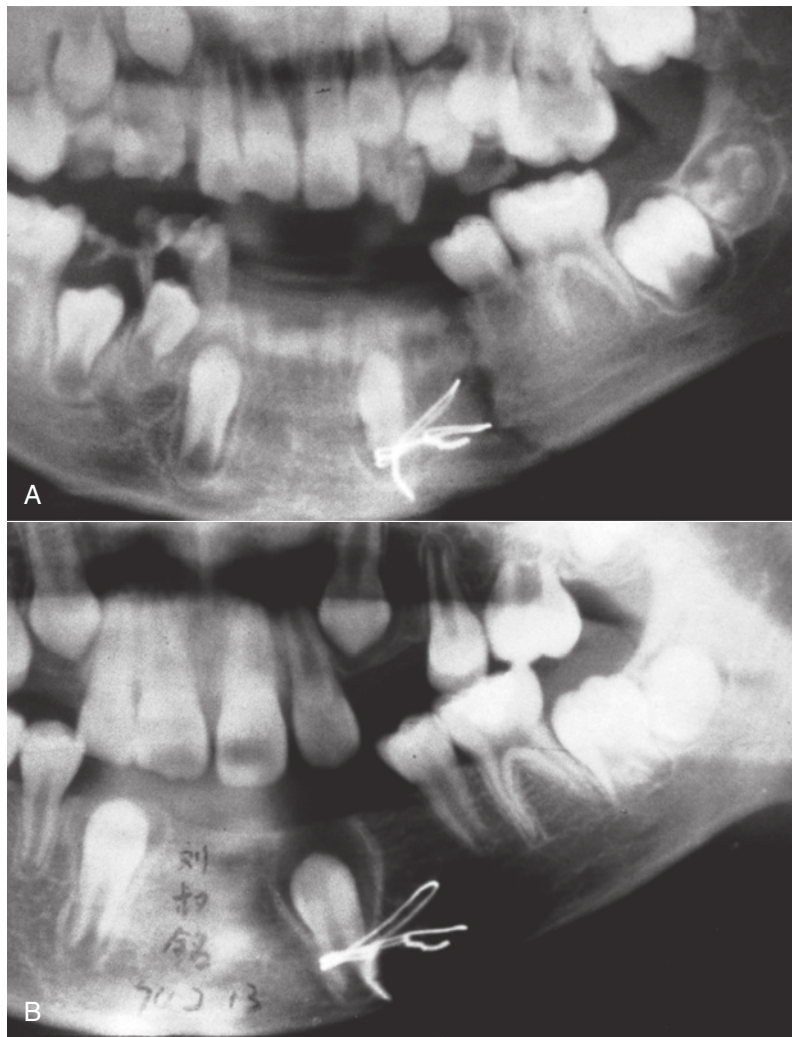


• **Fig. 3.14** Panoramic radiograph of normal eruption in a 10-year-old boy. Note that the permanent teeth erupt as resorption of overlying primary teeth and bone occurs. Resorption must occur to make eruption possible.

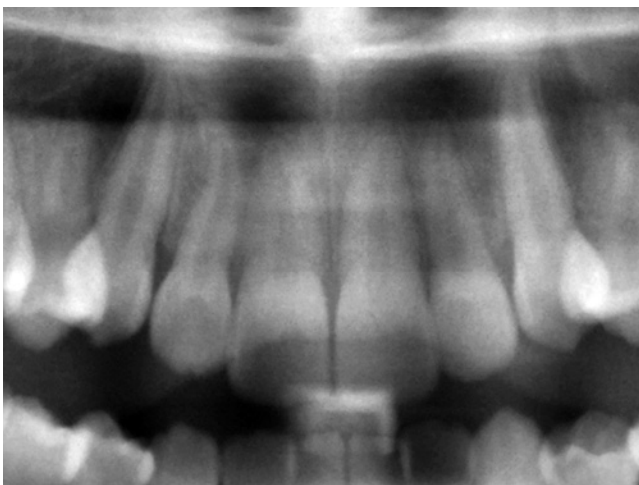


• **Fig. 3.15** (A) Panoramic radiograph of an 8-year-old patient with cleidocranial dysplasia, showing the characteristic features of this condition. In cleidocranial dysplasia, the succedaneous teeth do not erupt because of abnormal resorption of both bone and primary teeth, and the eruption of nonsuccedaneous teeth is delayed by fibrotic gingiva. Supernumerary teeth often are also present, as in this patient, creating additional mechanical obstruction. If the obstruction to eruption is removed, the teeth may erupt spontaneously and can be brought into the arch with orthodontic force if they do not. (B) Age 10, after surgical removal of primary and supernumerary incisors and uncovering of the permanent incisors. (C) Age 14, after orthodontic treatment to bring the incisors into the mouth and surgical removal of primary canines and molars, as well as supernumerary teeth in that area. (D) Age 16, toward the completion of orthodontic treatment to bring the remaining teeth into occlusion. The maxillary right second premolar became ankylosed, but the other teeth responded satisfactorily to treatment.





• **Fig. 3.16** Radiographs of a boy whose mandible was fractured at age 10. (A) Immediately after the fracture, when osseous wires were placed to stabilize the bony segments. One of the wires inadvertently pinned the mandibular left canine to the bone, simulating Cahill's experiments with animals. (B) One year later. Note that resorption over the canine has proceeded normally, clearing its eruption path even though it has not moved. (Courtesy Dr. John Lin.)



• **Fig. 3.17** In this 12-year-old boy, note the curvature of the root apex of the maxillary right lateral incisor. Deformation of the shape of a tooth root is called *dilaceration* and can be significantly more severe than in this instance. It usually occurs as the eruption of a tooth is impeded, but a tooth can continue to erupt normally after dilaceration occurs.

abnormality in the periodontal ligament. Diagnosis and management of patients with PFE is discussed in [Chapter 12](#).

Despite many years of study, the precise mechanism through which the propulsive force is generated remains unknown. It appears that the mechanism of eruption before the emergence of a tooth into the mouth and the mechanism after a tooth has emerged are different. From animal studies, it is known that substances that interfere with the development of cross-links in maturing collagen also interfere with eruption, which makes it tempting to theorize that cross-linking of maturing collagen in the periodontal ligament provides the propulsive force. This seems to be the case after a tooth comes into function, but the collagen fibers are not well organized before emergence of a tooth into the oral environment—which means that collagen maturation cannot be the primary mechanism to move a tooth along its preemergent eruption path.

Other possibilities for the preemergent propulsive mechanism besides collagen maturation are localized variations in blood pressure or flow, forces derived from contraction of fibroblasts, and alterations in the extracellular ground substances of the periodontal ligament similar to those that occur in thixotropic gels.<sup>19</sup>

### Postemergent Eruption

Once a tooth has emerged into the mouth, it erupts rapidly until it approaches the occlusal level and is subjected to the forces of mastication. At that point, its eruption slows and then as it reaches the occlusal level of other teeth and is in complete function, eruption all but halts. The stage of relatively rapid eruption from the time a tooth first penetrates the gingiva until it reaches the occlusal level is called the *postemergent spurt*, in contrast to the following phase of very slow eruption, termed the *juvenile occlusal equilibrium*.

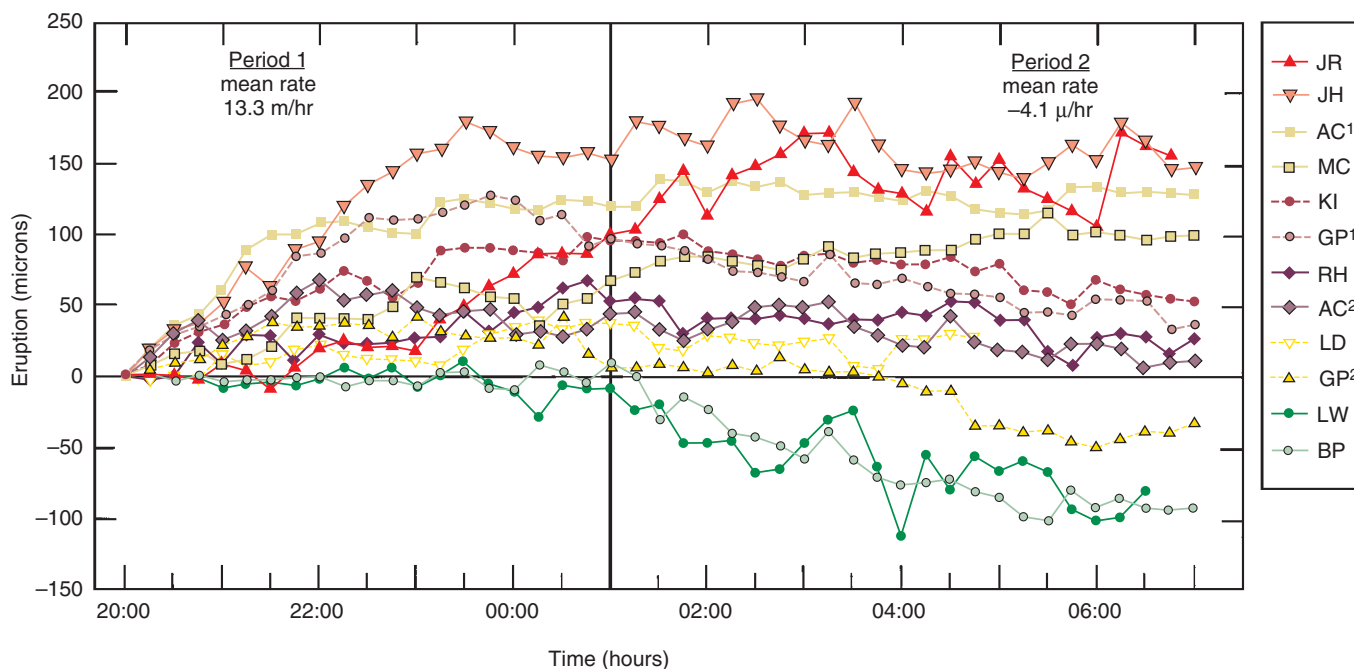
In the 1990s, new instrumentation made it possible to track the short-term movements of a tooth during the postemergent spurt, and this showed that eruption occurs only during a critical period between 8 PM and midnight or 1 AM (Fig. 3.18).<sup>20</sup> During the early morning hours and the day, the tooth stops erupting and often intrudes slightly. The day–night differences in eruption seem to reflect an underlying circadian rhythm, probably related to the very similar cycle of growth hormone release. Experiments with the application of pressure against an erupting premolar suggest that eruption is stopped by force for only 1 to 3 minutes, so food contacts with the erupting tooth, even though it is out of contact with its antagonist, almost surely do not explain the daily rhythm (Fig. 3.19).<sup>21</sup> In humans, the eruption of premolars that are moving from gingival emergence toward occlusion has been shown to be affected by changing blood flow in the apical area. This suggests that blood flow is at least a contributing factor in the eruption mechanism up to that point.<sup>22</sup>

The eruption mechanism may be different after emergence—collagen cross-linking in the periodontal ligament is more prominent

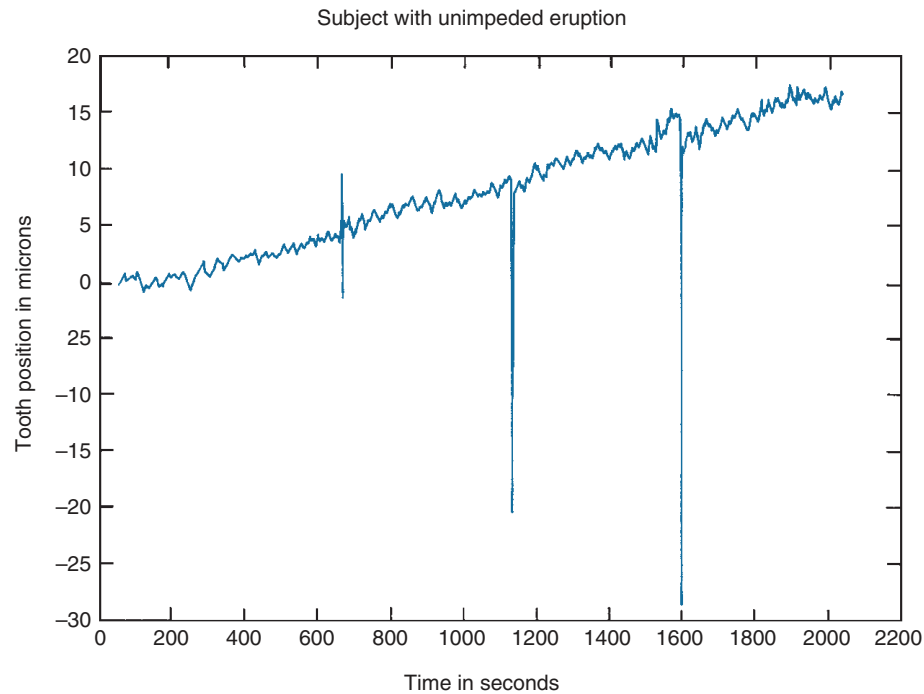
after a tooth has come into occlusal function, so shortening of collagen fibers as the mechanism seems more likely—and the control mechanism certainly is different. It seems obvious that as a tooth is subjected to biting forces that oppose eruption, the overall rate of eruption would be slowed, and in fact exactly this occurs. In humans, after the teeth have reached the occlusal level, eruption becomes almost imperceptibly slow, although it definitely continues. During the juvenile equilibrium, teeth that are in function erupt at a rate that parallels the rate of vertical growth of the mandibular ramus (Fig. 3.20). As the mandible continues to grow, it moves away from the maxilla, creating a space into which the teeth erupt. Exactly how eruption is controlled so that it matches mandibular growth, however, is not known, and because some of the more difficult orthodontic problems arise when eruption does not coincide with growth, this is an important area for further study.

The amount of eruption necessary to compensate for jaw growth can best be appreciated by observing what happens when a tooth becomes ankylosed (i.e., fused to the alveolar bone). An ankylosed tooth appears to submerge over a period as the other teeth continue to erupt, while it remains at the same vertical level (Fig. 3.21). The total eruption path of a first permanent molar is about 2.5 cm. Of that distance, nearly half is traversed after the tooth has reached the occlusal level and is in function. If a first molar becomes ankylosed at an early age, which fortunately is rare, it can “submerge” to such an extent that the tooth is covered over again by the gingiva as other teeth erupt and bring alveolar bone along with them (Fig. 3.22).

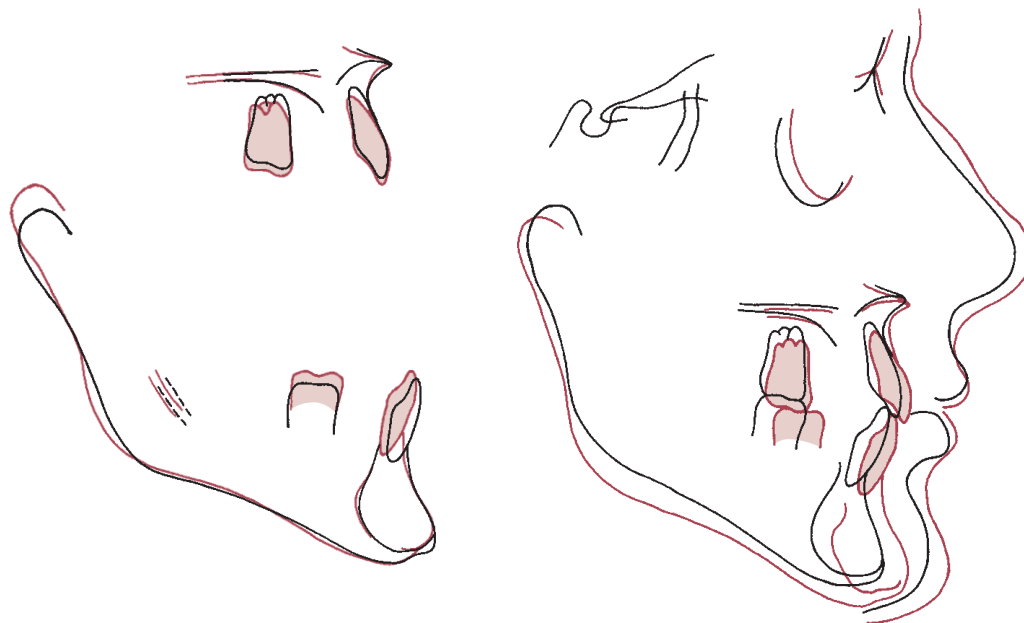
Because the rate of eruption parallels the rate of jaw growth, it is not surprising that a pubertal spurt in eruption of the teeth accompanies the pubertal spurt in jaw growth. This reinforces the



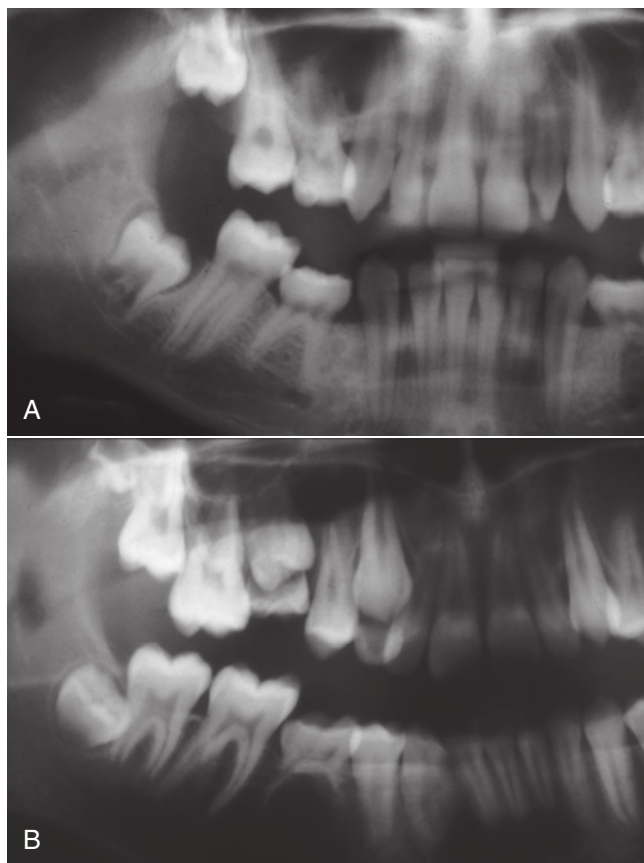
• **Fig. 3.18** Eruption plots for human second premolars observed via a fiber optic cable to a video microscope, which provides 1- to 2-micron resolution, from 8 PM (20:00) to 6 AM (06:00). Note the consistent pattern of eruption in the early evening, trailing off to no eruption or intrusion toward midnight, with no further eruption after that. It now is clear that eruption occurs only during a few critical hours in the early evening. (Redrawn from Risinger RK, Proffit WR. *Arch Oral Biol.* 1996;41:779–786.)



• **Fig. 3.19** Eruption plots for a human second premolar observed via Moire magnification, which provides 0.2-micron resolution, over a 30-minute period in the early evening when force opposing eruption was applied while active eruption was occurring. Note that the tooth erupted nearly 10 microns during this short time. The vertical spikes are movement artefacts produced by the applied force; a short-duration cycle superimposed on the eruption curve (significance unknown) also can be observed. Force applications either have no effect on eruption, as in this subject, or produce a transient depression of eruption that lasts less than 2 minutes. (Redrawn from Gierie WV, Paterson RL, Proffit WR. *Arch Oral Biol.* 1999;44:423–428.)



• **Fig. 3.20** The amount of tooth eruption after the teeth have come into occlusion equals the vertical growth of the ramus in a patient who is growing normally. Vertical growth increases the space between the jaws, and the maxillary and mandibular teeth normally divide this space equally. Note the equivalent eruption of the upper and lower molars in this patient between age 10 (*black*) and 14 (*red*). This is a normal growth pattern.



• **Fig. 3.21** (A) In this patient whose premolars were congenitally absent, the mandibular right second primary molar became ankylosed well before eruption of the other teeth was completed. Its apparent submergence is really because the other teeth have erupted past it. Note that the lower permanent first molar has tipped mesially over the submerged primary molar. In the maxillary arch the second primary molar has erupted along with the permanent canine and first molar. (B) In this patient, an ankylosed maxillary second primary molar has delayed eruption of the second premolar but is resorbing, and the mandibular second primary molar that has no permanent successor also is ankylosed and submerging.

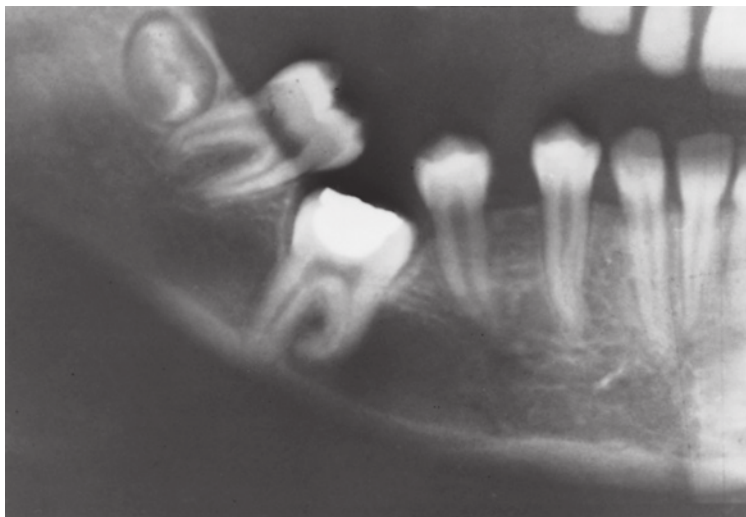
concept that after a tooth is in occlusion, the rate of eruption is controlled by the forces opposing eruption, not those promoting it. After a tooth is in the mouth, the forces opposing eruption are those from chewing, and perhaps in addition soft tissue pressures from lips, cheeks, or tongue contacting the teeth. If eruption occurs only during quiet periods, the soft tissue pressures (from tongue position during sleep, for instance) probably are more important in controlling eruption than the heavy pressures during chewing. Light pressures of long duration are more important in producing orthodontic tooth movement (see [Chapter 8](#)), so it also seems logical that light but prolonged pressures might affect eruption. What would be the source of this type of pressure? Perhaps the way the tongue is positioned between the teeth during sleep?

When the pubertal growth spurt ends, a final phase in tooth eruption called the *adult occlusal equilibrium* is achieved. During adult life, teeth continue to erupt at an extremely slow rate. If its antagonist is lost at any age, a tooth can again erupt more rapidly, demonstrating that the eruption mechanism remains active and capable of producing significant tooth movement even late in life.

Wear of the teeth may become significant as the years pass. If extremely severe wear occurs, eruption may not compensate for the loss of tooth structure, so that the vertical dimension of the face decreases. In most individuals, however, any wear of the teeth is compensated for by additional eruption, and face height remains constant or even increases slightly in the fourth, fifth, and sixth decades of life (see the section on maturation and aging in [Chapter 4](#)).

### Eruption Sequence and Timing: Dental Age

The transition from the primary to the permanent dentition, which is summarized in [Table 3.2](#), begins at about age 6 with the eruption of the first permanent molars, followed soon thereafter by the permanent incisors. The permanent teeth tend to erupt in groups, and it is less important to know the most common eruption sequence than to know the expected time at which various groups of teeth appear. This information is used in the calculation of dental age, which is particularly important during the mixed dentition years. Dental age is determined from three

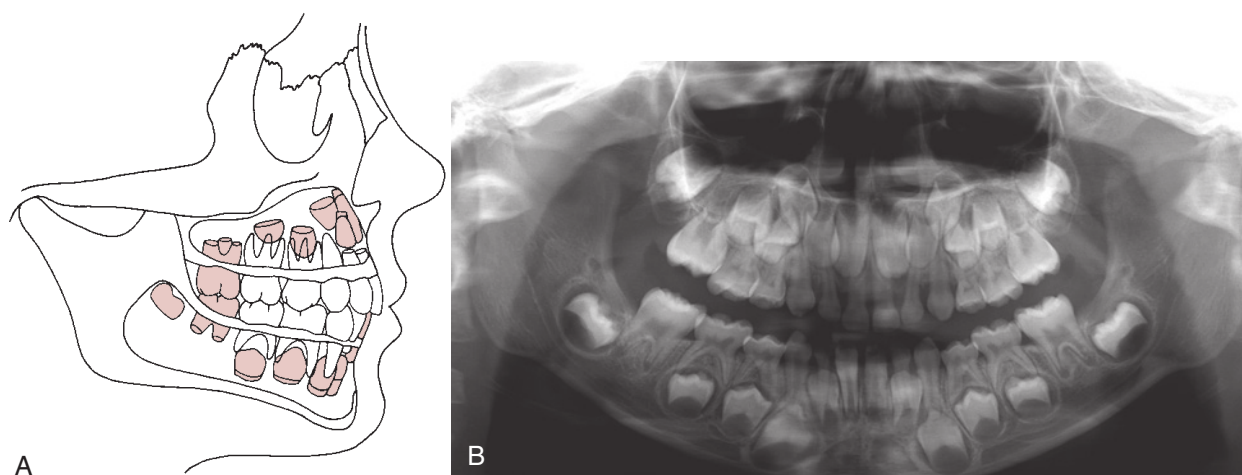


• **Fig. 3.22** The first molar in this 15-year-old girl ceased erupting soon after its emergence into the mouth at age 6 or 7. When the dentist placed an occlusal restoration, the tooth was apparently in or near occlusion, well into the oral cavity. This dramatically illustrates the amount of eruption that must occur after the initial occlusal contact of first molars.



**TABLE**  
**3.2****Chronology of Tooth Development, Permanent Dentition**

Tooth	CALCIFICATION BEGINS		CROWN COMPLETED		ERUPTION		ROOT COMPLETED	
	Maxillary	Mandibular	Maxillary	Mandibular	Maxillary	Mandibular	Maxillary	Mandibular
Central	3 mo	3 mo	4½ yr	3½ yr	7¼ yr	6¼ yr	10½ yr	9½ yr
Lateral	11 mo	3 mo	5½ yr	4 yr	8¼ yr	7½ yr	11 yr	10 yr
Canine	4 mo	4 mo	6 yr	5¾ yr	11½ yr	10½ yr	13½ yr	12¾ yr
First premolar	20 mo	22 mo	7 yr	6¾ yr	10¼ yr	10½ yr	13½ yr	13½ yr
Second premolar	27 mo	28 mo	7¾ yr	7½ yr	11 yr	11¼ yr	14½ yr	15 yr
First molar	32 wk in utero	32 wk in utero	4¼ yr	3¾ yr	6¼ yr	6 yr	10½ yr	10½ yr
Second molar	27 mo	27 mo	7¾ yr	7½ yr	12½ yr	12 yr	15¾ yr	16 yr
Third molar	8 yr	9 yr	14 yr	14 yr	20 yr	20 yr	22 yr	22 yr



• **Fig. 3.23** The first stage of eruption of the permanent teeth, at age 6, is characterized by the near-simultaneous eruption of the mandibular central incisors, the mandibular first molars, and the maxillary first molars. (A) Drawing of right side. (B) Panoramic radiograph.

characteristics. The first is which teeth have erupted. The second and third, which are closely related, are the amount of resorption of the roots of primary teeth and the amount of development of the permanent teeth.

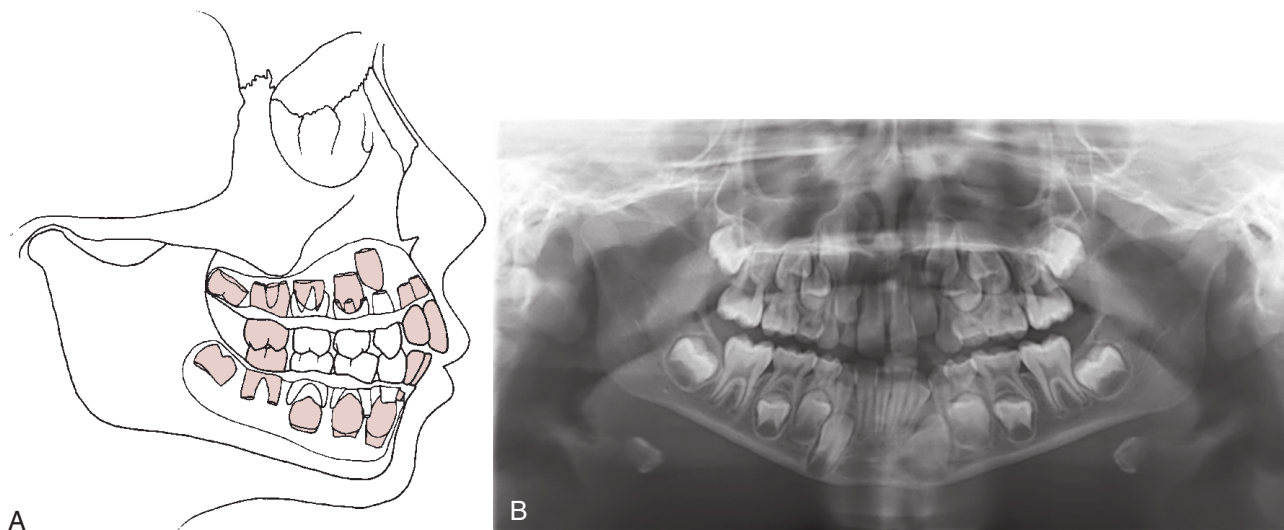
The amount of eruption of the permanent teeth at dental age 6 is illustrated in Fig. 3.23. The most common sequence of eruption is the mandibular central incisor, closely followed by the permanent mandibular first molar and the permanent maxillary first molar. These teeth normally erupt at so nearly the same time, however, that it is within normal variation for the first molars to slightly precede the mandibular central incisors or vice versa. Usually, the mandibular molar will precede the maxillary molar. The beginning eruption of this group of teeth characterizes dental age 6.

At dental age 7, the maxillary central incisors and the mandibular lateral incisors erupt. The maxillary central incisor is usually a year behind the mandibular central incisor but erupts simultaneously with the mandibular lateral incisor. At this age, root formation of the maxillary lateral incisor is well advanced, but it is still about

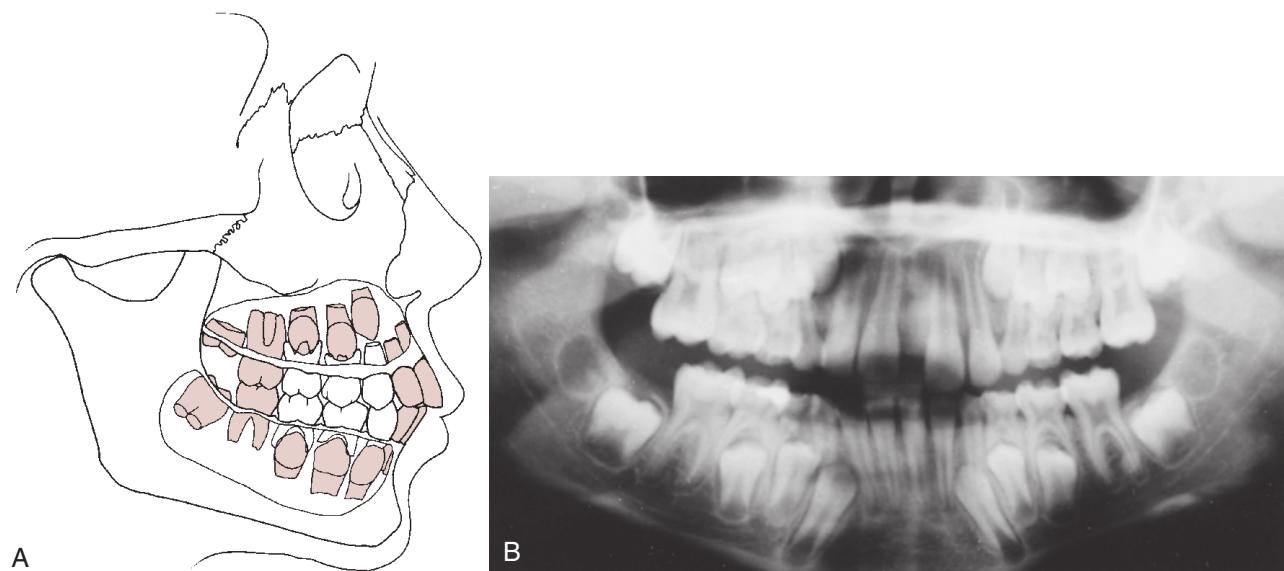
1 year from eruption, while the canines and premolars are still in the stage of crown completion or just at the beginning of root formation.

Dental age 8 (Fig. 3.24) is characterized by eruption of the maxillary lateral incisors. After these teeth come into the arch, there is a delay of 2 to 3 years before any additional permanent teeth appear.

Because no teeth are erupting at that time, dental ages 9 and 10 must be distinguished by the extent of resorption of the primary canines and premolars and the extent of root development of their permanent successors (Fig. 3.25). At dental age 9, the primary canines, first molars, and second molars are present in the mouth. Approximately one-third of the root of each mandibular canine and mandibular first premolar is completed. Root development is just beginning, if it has started at all, on the mandibular second premolar. In the maxillary arch, root development has begun on the first premolar but is just beginning, if it is present at all, on both the canine and the second premolar.



• **Fig. 3.24** Dental age 8 is characterized by eruption of the maxillary lateral incisors.



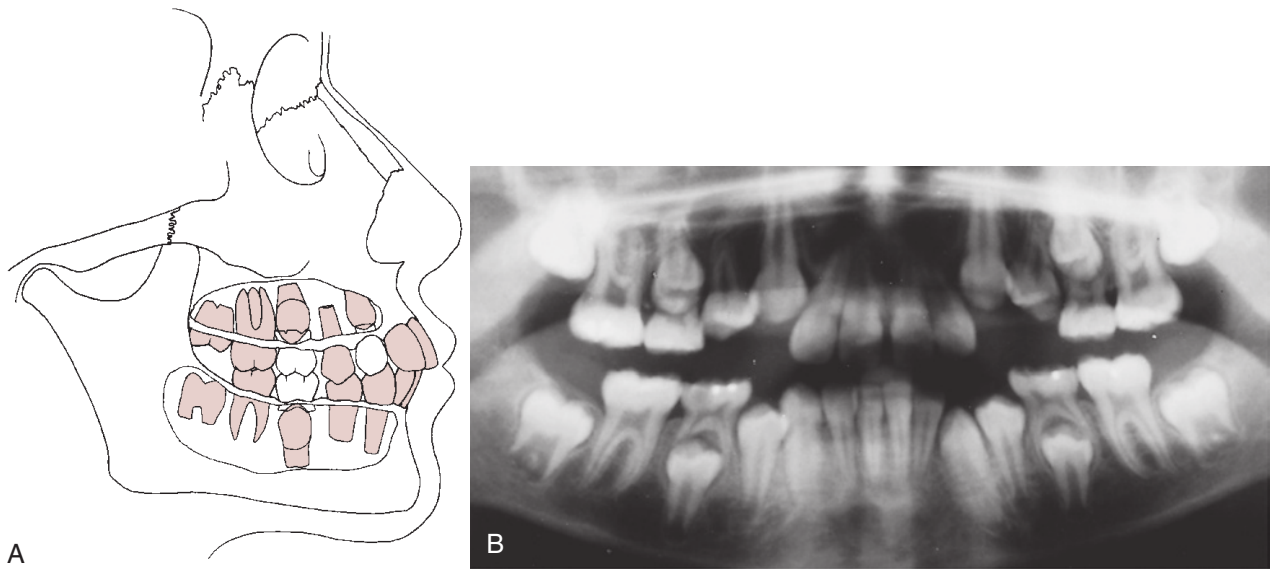
• **Fig. 3.25** At dental age 9, the maxillary lateral incisors have been in place for 1 year, and root formation on other incisors and first molars is nearly complete. Root development of the maxillary canines and all second premolars is just beginning; development of about one-third of the root of the mandibular canines and all of the first premolar roots has been completed.

Dental age 10 is characterized by a greater amount of both root resorption of the primary canines and molars, and root development of their permanent successors. At dental age 10, approximately one-half of the root of each mandibular canine and mandibular first premolar has been completed; nearly half the root of the upper first premolar is complete; and there is significant root development of the mandibular second premolar, maxillary canine, and maxillary second premolar.

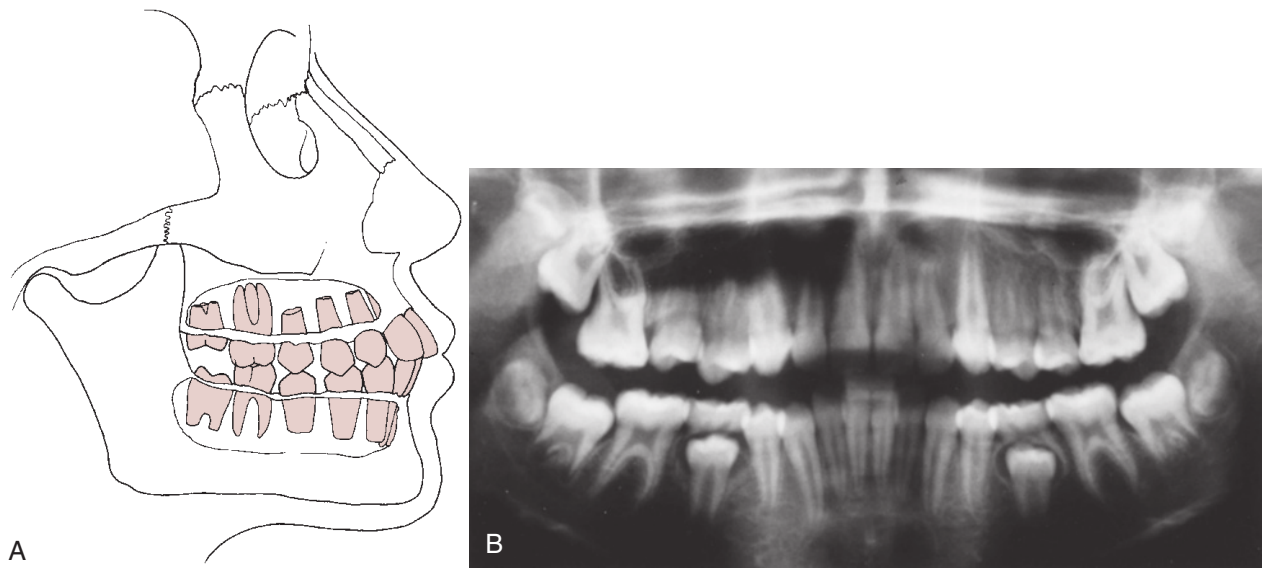
A tooth usually emerges when about three-fourths of its root has been completed. Thus a signal that a tooth should be appearing in the mouth is root development approaching this level. It takes 2 to 3 years for roots to be completed after a tooth has erupted into occlusion.

Another indicator of dental age 10, therefore, would be completion of the roots of the mandibular incisor teeth and near-completion of the roots of the maxillary laterals. By dental age 11, the roots of all incisors and permanent first molars should be well completed.

Dental age 11 ([Fig. 3.26](#)) is characterized by the eruption of another group of teeth: the mandibular canines, mandibular first premolars, and maxillary first premolars, which erupt more or less simultaneously. In the mandibular arch, the canine most often appears just ahead of the first premolar, but the similarity in the time of eruption, not the most frequent sequence, is the important point. In the maxillary arch, on the other hand, the first premolar usually erupts well ahead of the canine. At dental age 11, the only



• **Fig. 3.26** Dental age 11 is characterized by the eruption of the mandibular canines, mandibular first premolars, and maxillary first premolars at about the same time.



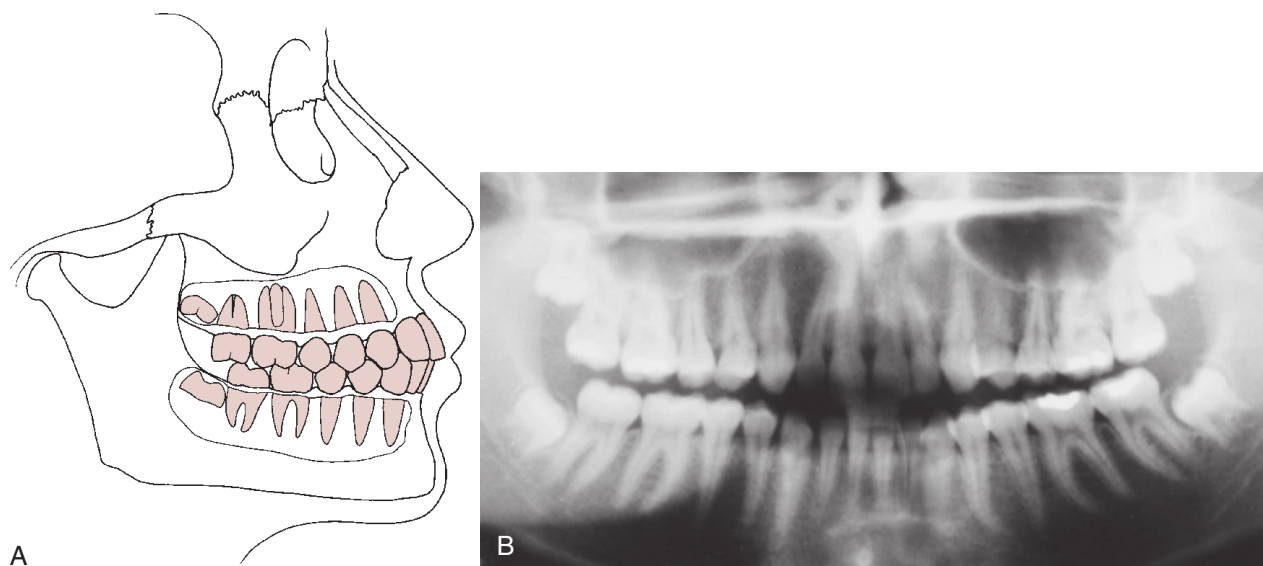
• **Fig. 3.27** Dental age 12 is characterized by eruption of the remaining succedaneous teeth (the maxillary canine and the maxillary and mandibular second premolars) and typically a few months later, the maxillary and mandibular second molars.

remaining primary teeth are the maxillary canine and second molar and the mandibular second molar.

At dental age 12 (Fig. 3.27), the remaining succedaneous permanent teeth erupt. *Succedaneous* refers to permanent teeth that replace primary predecessors; thus a canine is a succedaneous tooth, whereas a first molar is not. In addition, at age 12 the permanent second molars in both arches are nearing eruption. The succedaneous teeth complete their eruption before the emergence of the second molars in most but by no means all normal children. It is usually possible to note the early beginnings of the third molars by age 12, and mineralization of the crown of these teeth begins earlier than that in many children.

Dental ages 13, 14, and 15 are characterized by the extent of completion of the roots of permanent teeth. By dental age 15 (Fig. 3.28), if a third molar is going to form, it should be apparent on the radiographs, and the roots of all other permanent teeth should be complete.

As with all other developmental ages, dental age correlates with chronologic age, but the correlation between dental and chronologic age is one of the weakest. In other words, teeth erupt with a considerable degree of variability from chronologic age standards. It remains true, however, that the teeth erupt in the stages described previously. A child who has precocious dental development might have the mandibular central incisors and first molars erupt at age



• **Fig. 3.28** By dental age 15, the roots of all permanent teeth except the third molars are complete, and crown formation of third molars often has been completed.

5 and could reach dental age 12 by chronologic age 10. A child with slow dental development might not reach dental age 12 until chronologic age 14.

A change in the sequence of eruption is a much more reliable sign of a disturbance in normal development than a generalized delay or acceleration. The more a tooth deviates from its expected position in the sequence, the greater the likelihood of some sort of problem. For example, a delay in eruption of maxillary canines to age 14 is within normal variation if the second premolars are also delayed, but if the second premolars have erupted at age 12 and the canines have not, something probably is wrong.

Several reasonably normal variations in eruption sequence have clinical significance and should be recognized. These are (1) eruption of second molars ahead of premolars in the mandibular arch, (2) eruption of canines ahead of premolars in the maxillary arch, and (3) unusually large asymmetries in eruption between the right and left sides.

Early eruption of the mandibular second molars can be unfortunate when room to accommodate the teeth is marginal. The eruption of the second molar before the second premolar tends to decrease the space for the second premolar and may lead to its being partially blocked out of the arch. For that reason, when the mandibular second molar erupts early it may be necessary to open space for the second premolar so it can complete its eruption.

If a maxillary canine erupts at about the same time as the maxillary first premolar (remember that this is the normal eruption sequence of the lower arch but is abnormal in the upper), the canine probably will be forced labially even if there would have been enough space if it had erupted in the normal sequence. Labial positioning of maxillary canines often occurs when there is an overall lack of space in the arch, because this tooth is the last to erupt normally, but keep in mind that displacement of the canine also can be an unfortunate consequence of this eruption sequence.

A moderate asymmetry in the rate of eruption on the two sides of the dental arch occurs in almost everyone. A striking illustration of genetic influences on eruption timing is seen in identical twins, who frequently have mirror-image asymmetries in the dentition

at the various stages of eruption. For example, if the premolars erupt a little earlier on the left in one of the twins, they will erupt a little earlier on the right in the other. The normal variation is only a few months, however. As a general rule, if a permanent tooth on one side erupts but its counterpart on the other does not within 6 months, a radiograph should be taken to investigate the cause of the discrepancy. Although small variations from one side to the other are normal, large ones often indicate a problem.

It is interesting that an asymmetry in dental age between the two sides of the maxillary arch may be a factor in the development of unilaterally impacted canines. Palatal (but not buccal) canine impaction is more prevalent on the side with delayed development,<sup>23</sup> perhaps because earlier eruption of the contralateral canine tends to displace the incisors toward the delayed side and decreases space for eruption of that canine. If the delayed canine were positioned buccally, it still could erupt, but if positioned lingually, palatal impaction would be the most likely outcome.

### Space Relationships in Replacement of the Incisors

If a dissected skull is examined, it can be seen that in both the maxillary and mandibular arches, the permanent incisor tooth buds lie lingual, as well as apical, to the primary incisors (Fig. 3.29; also see Fig. 3.10). The result is a tendency for the mandibular permanent incisors to erupt somewhat lingually and in a slightly irregular position, even in children who have normal dental arches and normal spacing within the arches. In the maxillary arch, the lateral incisor is likely to be lingually positioned at the time of its emergence and to remain in that position if there is any crowding in the arch. The permanent canines are positioned more nearly in line with the primary canines. If there are problems in eruption, these teeth can be displaced either lingually or labially, but usually they are displaced labially if there is not enough room for them.

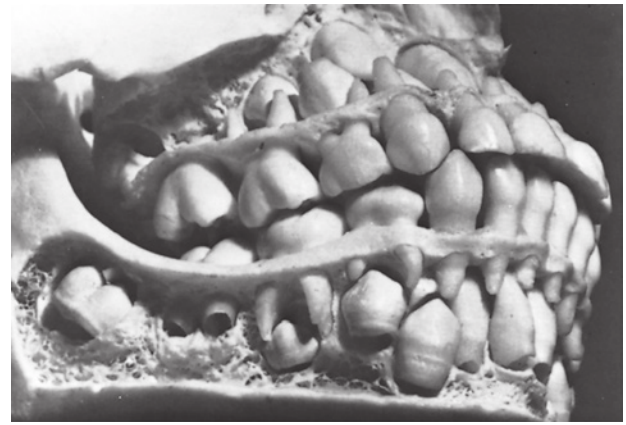The permanent incisor teeth are considerably larger than the primary incisors that they replace. For instance, the permanent mandibular central incisor is about 5.5 mm in width, whereas the



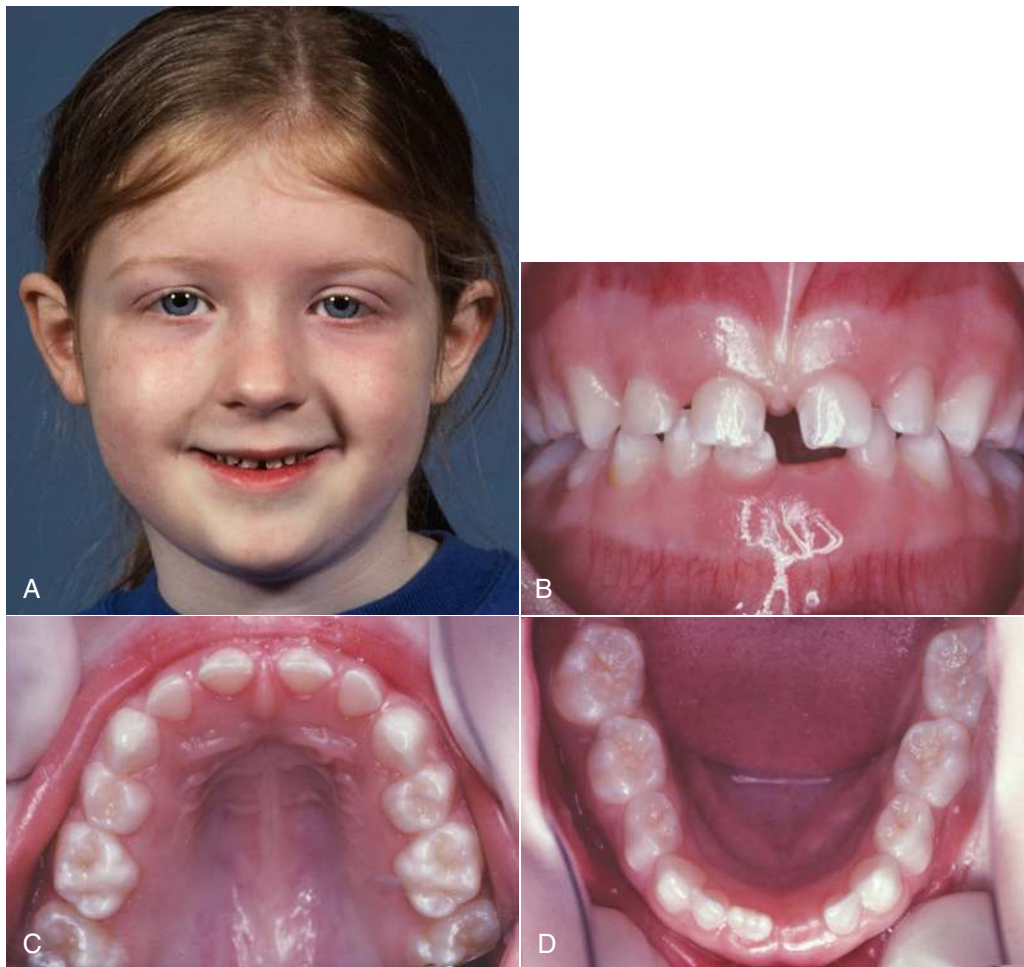primary central it replaces is about 3 mm in width. Because the other permanent incisors and canines are each 2 to 3 mm wider than their primary predecessors, spacing between the primary incisors is not only normal, it is critically important (Fig. 3.30). Otherwise, there will not be enough room for the permanent incisors when they erupt. An adult-appearing smile in a child in the primary dentition is an abnormal, not a normal finding—the spaces are necessary for alignment of the permanent teeth.

Changes in the amount of space mesial to the canine teeth are shown graphically in Fig. 3.31. Note that a normal child will go through a transitory stage of incisor crowding at age 8 to 9, even if there will eventually be enough room to accommodate all the permanent teeth in good alignment. Where did the extra space come from? There is no jaw growth in the area where additional space is needed. Moorrees and Chadha showed in a classic study in the 1960s<sup>24</sup> that it comes from three sources (Fig. 3.31):

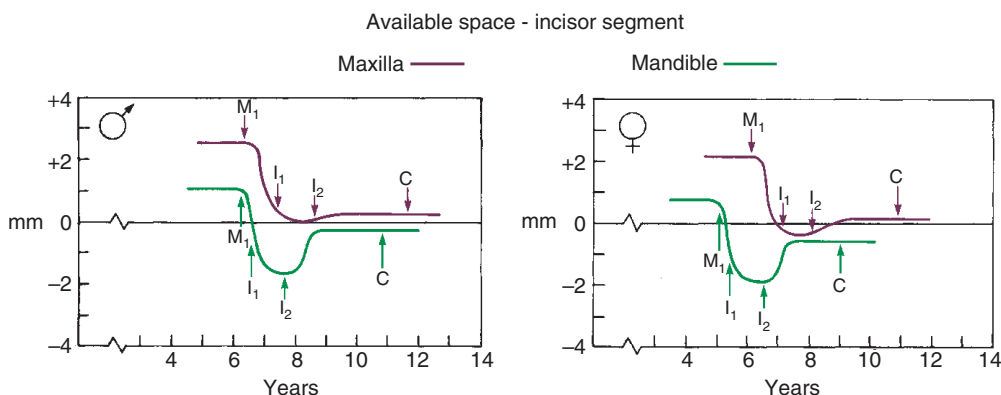
1. A slight increase in the width of the dental arch across the canines. As growth continues, the teeth erupt not only upward but also slightly outward. This increase is most evident when the lateral incisors erupt. It is small, about 2 mm on the average, but it does contribute to resolution of early crowding of the



• **Fig. 3.29** This photograph of the dissected skull of a child of approximately 6 years of age shows the relationship of the developing permanent tooth buds to the primary teeth. Note that the permanent incisors are positioned lingual to the roots of the primary incisors, whereas the canines are more labially placed. (From van der Linden FPGM, Deuterloo HS. *Development of the Human Dentition: An Atlas*. New York: Harper & Row; 1976.)



• **Fig. 3.30** A–D, Facial and intraoral views of a 6-year-old girl, just as the incisor transition is beginning. Spacing of this magnitude between the primary incisors is normal in the late primary dentition and is necessary to provide enough room for alignment of the permanent incisors when they erupt. At age 6, a gap-toothed smile, not a “Hollywood smile” with the teeth in contact, is what you would like to see.



• **Fig. 3.31** Graphic representation of the average amount of space available within the arches in boys (*left*) and girls (*right*). The time of eruption of the first molar ( $M_1$ ), central and lateral incisors ( $I_1$  and  $I_2$ ), and canines ( $C$ ) is shown by arrows. Note that in the mandibular arch in both sexes, the amount of space for the mandibular incisors in boys and girls is negative for about 2 years after their eruption. This is often referred to as the period of incisor liability. It means that a small amount of crowding in the mandibular arch at this time is normal. (From Moorrees CFA, Chadha JM. *Angle Orthod.* 1965;35:12–22.)

incisors. More width is gained in the mandibular than the maxillary arch, and more is gained in boys than girls. For this reason, girls have a greater likelihood of incisor crowding, particularly mandibular incisor crowding.

2. Labial positioning of the permanent incisors relative to the primary incisors. The primary incisors tend to be quite upright. As the permanent incisors replace them, these teeth lean slightly forward, which arranges them along the arc of a larger circle. Although this change is also small, it contributes 1 to 2 mm of additional space in the average child.
3. Repositioning of mandibular canines. As the permanent incisors erupt, the canines not only widen out but move slightly back into the primate space unless it has been closed by an early mesial shift. This contributes to the slight width increase already noted because the arch is wider posteriorly and also provides an extra millimeter of space. Because the primate space in the maxillary arch is mesial to the canine, there is little opportunity for a similar change in the anteroposterior position of the maxillary canines.

It is important to note that all three of these changes occur without significant skeletal growth in the front of the jaws. The slight increases in arch dimension during normal development are not sufficient to overcome discrepancies of any magnitude, so crowding is likely to persist into the permanent dentition if it was severe initially. In fact, crowding of the incisors—the most common form of Angle's Class I malocclusion—is by far the most prevalent type of malocclusion.

The mandibular permanent central incisors are almost always in proximal contact from the time that they erupt. In the maxillary arch, however, there may continue to be a space, called a *diastema*, between the maxillary permanent central incisors. A central diastema tends to close as the lateral incisors erupt but may persist even after the lateral incisors have erupted, particularly if the primary canines have been lost or if the upper incisors are flared to the labial. This is another of the variations in the normal developmental pattern that occur frequently enough to be almost normal. Because the flared and spaced upper incisors are not very esthetic, this is referred to as the “ugly duckling” stage of development (Fig. 3.32).

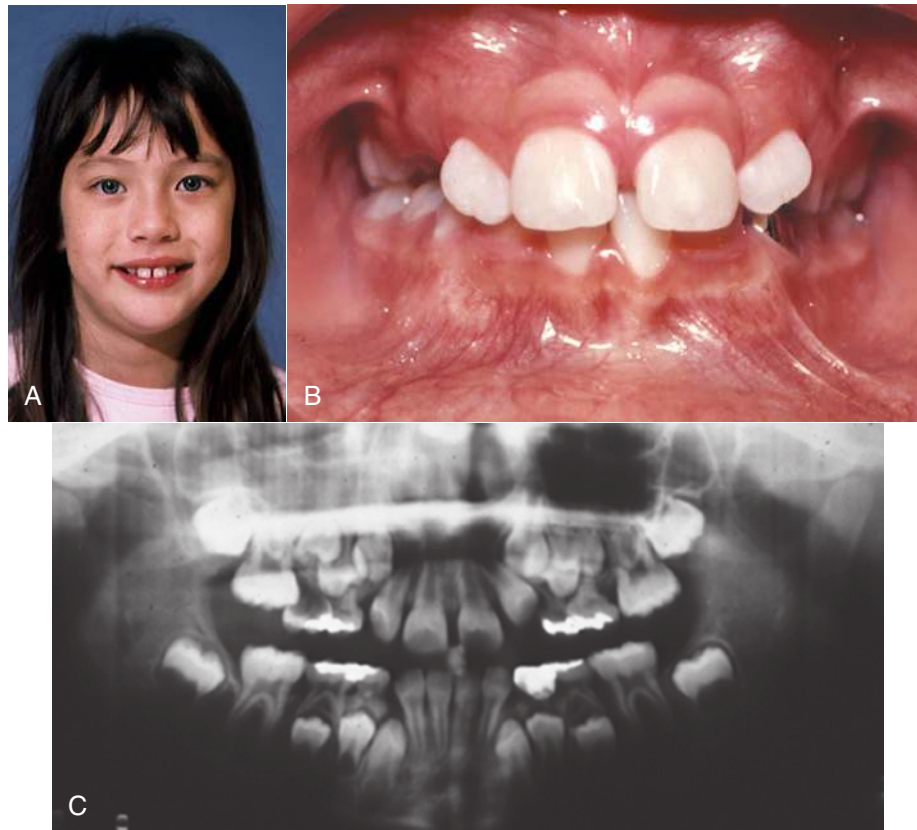
The spaces tend to close as the permanent canines erupt. The greater the amount of spacing, the less the likelihood that a maxillary central diastema will totally close on its own. As a general guideline, a maxillary central diastema of 2 mm or less will probably close spontaneously, whereas total closure of a diastema initially greater than 2 mm is unlikely.

### Space Relationships in Replacement of Canines and Primary Molars

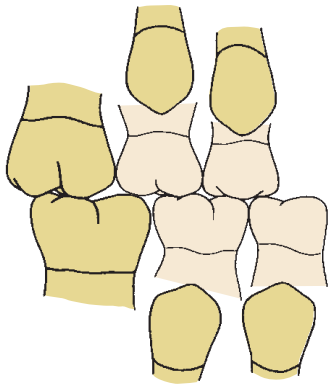
In contrast to the anterior teeth, the permanent canines are larger than the primary canines and the premolars are smaller than the primary teeth they replace. The mandibular primary second molar is on the average 2 mm larger than the second premolar; in the maxillary arch, the primary second molar is 1.5 mm larger (Fig. 3.33). This additional space for the permanent teeth is known as the *E space* because the second primary molars were designated as *E* in the United States before the military numbering scheme was widely adopted, and still are in the international tooth numbering scheme. The primary first molar is only slightly larger than the first premolar but does contribute an extra 0.5 mm in the mandible. The result is that each side in the mandibular arch on average contains about 2.5 mm of what is called *leeway space*; in the maxillary arch, about 1.5 mm is available on average. But remember that this is just the average, not what would be seen in all patients, so the relative size of the primary and permanent molars should be examined in the panoramic radiograph as decisions about space availability are being made.

When the second primary molars are lost, the first permanent molars move forward (mesially) relatively rapidly, into the leeway space. This decreases both arch length and arch circumference, which are related but not the same thing (Fig. 3.34). Even if incisor crowding is present, the leeway space is normally taken up by mesial movement of the permanent molars. An opportunity for orthodontic treatment is created at this time because crowding could be relieved by using the leeway space if it was maintained (see Chapter 11).

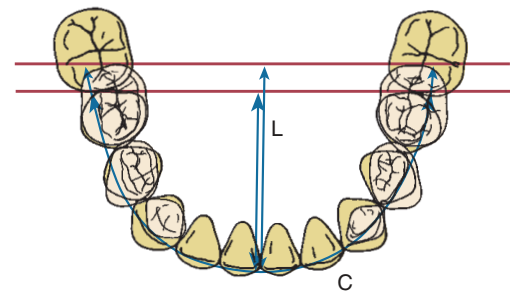
Occlusal relationships in the mixed dentition parallel those in the permanent dentition, but the descriptive terms are somewhat



• **Fig. 3.32** In some children, the maxillary incisors flare laterally and are widely spaced when they first erupt, a condition often called the “ugly duckling” stage. (A) Smile appearance, age 9. (B), Dental appearance. (C) Panoramic radiograph. The position of the incisors tends to improve when the permanent canines erupt, but this condition increases the possibility that the canines will become impacted.



• **Fig. 3.33** The size difference between the primary molars and permanent premolars, as would be observed in a panoramic radiograph.

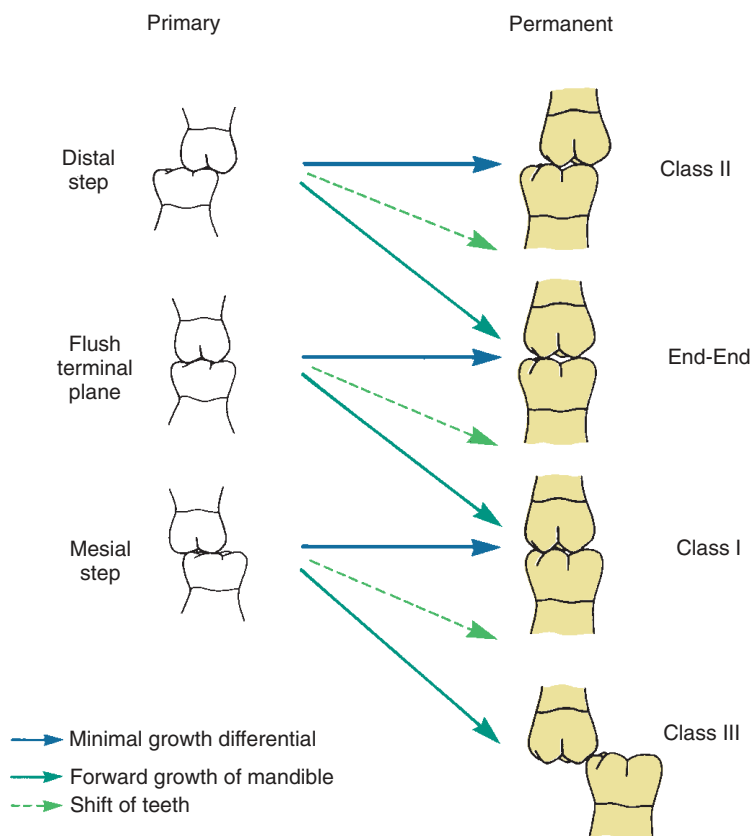


• **Fig. 3.34** Tooth sizes and arch dimensions in the transition to the permanent dentition. Both arch length ( $L$ ), the distance from a line perpendicular to the mesial surface of the permanent first molars to the central incisors, and arch circumference ( $C$ ) decrease as the molars move mesially into the leeway space.

different. A normal relationship of the primary molar teeth is the *flush terminal plane* relationship illustrated in Fig. 3.35. The primary dentition equivalent of Angle's Class II is the *distal step*. A *mesial step* relationship corresponds to Angle's Class I. An equivalent of Class III is not often seen in the primary dentition because of the normal pattern of craniofacial growth in which the mandible lags behind the maxilla. If it is, almost always a large discrepancy in the size of the mandible and maxilla (i.e., a skeletal Class III jaw relationship) is present.

At the time the primary second molars are lost, both the maxillary and mandibular molars tend to shift mesially into the leeway space, but the mandibular molar normally moves more than its maxillary counterpart. This contributes to the normal transition from a flush terminal plane relationship in the mixed dentition to a Class I relationship in the permanent dentition.

Differential growth of the mandible relative to the maxilla is also an important contributor to the molar transition. As we have discussed, a characteristic of the growth pattern at this age is more



• **Fig. 3.35** Occlusal relationships of the primary and permanent molars. The flush terminal plane relationship, shown in the middle left, is the normal relationship in the primary dentition. When the first permanent molars erupt, their relationship is determined by that of the primary molars. The molar relationship tends to shift at the time the second primary molars are lost and the adolescent growth spurt occurs, as shown by the arrows. The amount of differential mandibular growth and molar shift into the leeway space determines the molar relationship, as shown by the arrows as the permanent dentition is completed. With good growth and a shift of the molars, the change shown by the solid black line can be expected. (Modified from Moyers RE. *Handbook of Orthodontics*. 3rd ed. Chicago: Year Book Medical Publishers; 1973.)

growth of the mandible than the maxilla so that a relatively deficient mandible gradually catches up. Conceptually, one can imagine that the upper and lower teeth are mounted on moving platforms and that the platform on which the lower teeth are mounted moves a bit further than the upper platform. This differential growth of the jaws carries the mandible slightly forward relative to the maxilla during the mixed dentition.

If a child has a flush terminal plane molar relationship early in the mixed dentition, about 3.5 mm of movement of the lower molar forward relative to the upper molar is required for a smooth transition to a Class I molar relationship in the permanent dentition. About half of this distance can be obtained from the leeway space, which allows greater mesial movement of the mandibular than the maxillary molar. The other half is supplied by differential growth of the lower jaw, carrying the lower molar with it.

Only a modest change in molar relationship can be produced by this combination of differential growth of the jaws and differential forward movement of the lower molar. It must be kept in mind that the changes described here are those that happen to a child experiencing a normal growth pattern. There is no guarantee in any given individual that differential forward growth of the mandible will occur or that the leeway space will close so that the lower molar moves forward relative to the upper molar.

The possibilities for the transition in molar relationship from the mixed to the early permanent dentition are summarized in Fig. 3.35. Note that the transition is usually accompanied by a one-half cusp (3 to 4 mm) relative forward movement of the lower molar, accomplished by a combination of differential growth and tooth movement. A child's initial distal step relationship may change during the transition to an end-to-end (one-half cusp Class II) relationship in the permanent dentition but is not likely to be corrected all the way to Class I. It also is possible that there will be little if any differential forward growth of the mandible, in which case the molar relationship in the permanent dentition probably will remain a full cusp Class II.

Similarly, a flush terminal plane relationship, which produces an end-to-end relationship of the permanent molars when they first erupt, can change to Class I in the permanent dentition but can remain end-to-end in the permanent dentition if the growth pattern is not favorable.

Finally, a child who has experienced early mandibular growth may have a mesial step relationship in the primary molars, producing a Class I molar relationship at an early age. It is quite possible for this mesial step relationship to progress to a half-cusp Class III during the molar transition and proceed further to a full Class III relationship with continued mandibular growth. On the other



hand, if differential mandibular growth no longer occurs, the mesial step relationship at an early age may simply become a Class I relationship later.

The bottom line is that the amount and direction of mandibular growth, not the movement of the permanent molars when the primary second molars are lost, are the key variables in determining the permanent dentition molar relationship.

## References

1. Eli J, Sarnat H, Talmi E. Effect of the birth process on the neonatal line in primary tooth enamel. *Pediatr Dent*. 1989;11:220–223.
2. Brandt I. Growth dynamics of low-birth-weight infants. In: Falkner F, Tanner JM, eds. *Human Growth*. Vol. 1. 2nd ed. New York: Plenum Publishing; 1986.
3. Gomes FM, Subramanian SV, Escobar AM, et al. No association between low birth weight and cardiovascular risk factors in early adulthood: evidence from Sao Paulo, Brazil. *PLoS ONE*. 2013;8(6):e66554.
4. Peterson RE, Wetzel GT. Growth failure in congenital heart disease: where are we now? *Curr Opin Cardiol*. 2004;19:81–83.
5. McDowell MA, Brody DJ, Hughes JP. Has age at menarche changed? Results from the National Health and Nutrition Examination Survey (NHANES) 1999–2004. *J Adolesc Health*. 2007;40:227–231.
6. Rigon F, Bianchin L, Bernasconi S, et al. Update on age at menarche in Italy: toward the leveling off of the secular trend. *J Adolesc Health*. 2010;46:238–244.
7. Jantz RL. Cranial change in Americans: 1850–1975. *J Forensic Sci*. 2001;46:784–787.
8. Bosma JF. Maturation of function of the oral and pharyngeal region. *Am J Orthod*. 1963;49:94–104.
9. Larsson EF, Dahlin KG. The prevalence of finger- and dummy-sucking habits in European and primitive population groups. *Am J Orthod*. 1985;87:432–435.
10. Gross AM, Kellum GD, Hale ST, et al. Myofunctional and dentofacial relationships in second grade children. *Angle Orthod*. 1990;60:247–253.
11. Pavicin IS, Dumanic J, Badel TE, Vodanovic M. Timing of emergence of the first primary tooth in preterm and full-term infants. *Ann Anat*. 2016;203:19–23.
12. Warren JJ, Fontana M, Blanchette DR, et al. Timing of primary tooth emergence among U.S. racial and ethnic groups. *J Public Health Dent*. 2016;76:259–262.
13. Tanner JM. *Assessment of Skeletal Maturity and Prediction of Adult Height*. New York: WB Saunders; 2001.
14. Baccetti T, Franchi L, McNamara JA Jr. The cervical vertebral maturation (CVM) method for the assessment of optimal treatment timing in dentofacial orthopedics. *Semin Orthod*. 2005;11:119–129.
15. Gabriel DB, Southard KA, Qian F, et al. Cervical vertebrae maturation method: poor reproducibility. *Am J Orthod Dentofac Orthop*. 2009;136:478.e1–478.e7.
16. Gray S, Bennani H, Kieser JA, Farella M. Morphometric analysis of cervical vertebrae in relation to mandibular growth. *Am J Orthod Dentofac Orthop*. 2016;149:92–98.
17. Rainey BJ, Burnside G, Harrison JE. Reliability of cervical vertebral maturation. *Am J Orthod Dentofac Orthop*. 2016;150:98–104.
18. Frazier-Bowers S, Koehler K, Ackerman JL, Proffit WR. Primary failure of eruption: further characterization of a rare eruption disorder. *Am J Orthod Dentofac Orthop*. 2007;131:578e1–578e9.
19. Rhoads SG, Hendricks HM, Frazier-Bowers SA. Establishing the diagnostic criteria for eruption disorders based on genetic and clinical data. *Am J Orthod Dentofac Orthop*. 2013;144:194–202.
20. Risinger RK, Proffit WR. Continuous overnight observation of human premolar eruption. *Arch Oral Biol*. 1996;41:779–789.
21. Trentini CJ, Proffit WR. High resolution observations of human premolar eruption. *Arch Oral Biol*. 1996;41:63–68.
22. Cheek CC, Paterson RL, Proffit WR. Response of erupting human second premolars to blood flow changes. *Arch Oral Biol*. 2002;47:851–858.
23. Naser DH, Abu Alhaija ES, Al-Khateeb SN. Dental age assessment in patients with maxillary canine displacement. *Am J Orthod Dentofacial Orthop*. 2011;140:848–855.
24. Moorrees CF, Chadha JM. Available space for the incisors during dental development—a growth study based on physiologic age. *Angle Orthod*. 1965;35:12–22.

# 4

## Later Stages of Development

### CHAPTER OUTLINE

#### Adolescence: The Early Permanent Dentition Years

Initiation of Adolescence

Timing of Puberty

#### Growth Patterns in the Dentofacial Complex

Dimensional Changes

Rotation of Jaws During Growth

#### Maturational and Aging Changes

Facial Growth in Adults

Changes in Facial Soft Tissues

Changes in Alignment and Occlusion

Aging Changes in Teeth and Supporting Structures

### Adolescence: The Early Permanent Dentition Years

Adolescence is a sexual phenomenon, the period of life when sexual maturity is attained. More specifically, it is the transitional period between the juvenile stage and adulthood, during which secondary sexual characteristics appear, the adolescent growth spurt takes place, fertility is attained, and profound physiologic changes occur. All these developments are associated with the maturation of the sex organs and the accompanying surge in secretion of sex hormones.

This period is particularly important in dental and orthodontic treatment because the physical changes at adolescence significantly affect the face and dentition. Major events in dentofacial development that occur during adolescence include the exchange from the mixed to the permanent dentition, an acceleration in the overall rate of facial growth, and differential growth of the jaws.

#### Initiation of Adolescence

The first events of puberty occur in the brain, and significant recent research findings have clarified the complex interaction between neural and genetic–epigenetic factors that lead to its initiation. Puberty begins when pulsatile release of gonadotropin-releasing hormone (GnRH) from neurosecretory cells in the hypothalamus increases significantly and stimulates the pituitary gland to produce a variety of these hormones, which in turn activate release of both estrogens and androgens from the adrenal gland and ovaries or testes (Fig. 4.1). The neurosecretory cells can produce GnRH before

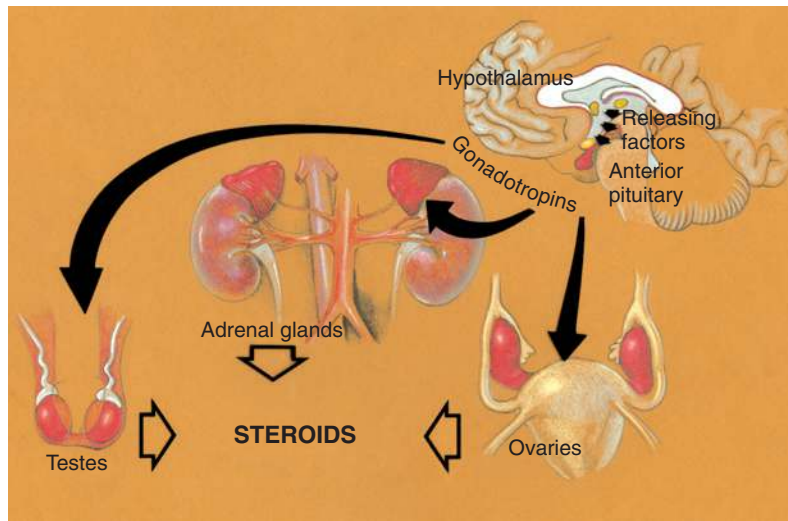
puberty, and it is now thought that epigenetic regulation of GnRH production is important both in restraining its release before puberty and the acceleration of release at puberty. That appears to be controlled by trans-synaptic activity of neurons in the arcuate nucleus. New information about this higher level of control of gene expression is appearing rapidly now, but it still is not known how and when alterations in epigenetic regulation affect the timing of puberty.<sup>1</sup>

Both the secretory cells in the hypothalamus and their method of action are somewhat unusual. These cells look like typical neurons, but they secrete materials in the cell body, which are carried by cytoplasmic transport down the axon toward a richly vascular area at the base of the hypothalamus near the pituitary gland. The substances secreted by the nerve cells pass into capillaries in this vascular region and are carried the short distance to the pituitary by blood flow. It is unusual in the body for the venous return system to transport substances from one closely adjacent region to another, but here the special arrangement of the vessels seems made to order for this purpose. Accordingly, this special network of vessels, analogous to the venous supply to the liver but on a much smaller scale, is called the *pituitary portal system*.

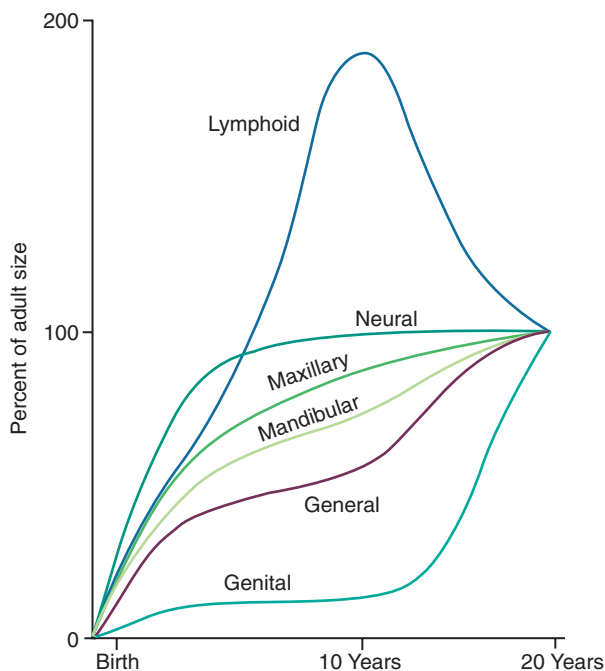
In the anterior pituitary, the hypothalamic releasing factors stimulate pituitary cells to produce several related but different hormones called *pituitary gonadotropins*. Their function is to stimulate endocrine cells in both the adrenal glands and the developing sex organs to produce sex hormones. In every individual a mixture of male and female sex hormones is produced, and it is a biologic fact, as well as an everyday observation, that there are feminine males and masculine females. Presumably this represents the balance of the competing male and female hormones.

In the male, different cell types in the testes produce both the male sex hormone testosterone and the female sex hormones, and possibly some female hormones are produced in the adrenal cortex. A different pituitary gonadotropin stimulates each of these cell types. In the female, the pituitary gonadotropins stimulate secretion of estrogen by the ovaries, and later progesterone by the same organ; male sex hormones are produced in the adrenal cortex, stimulated by still another pituitary hormone.

Under the stimulation of the pituitary gonadotropins, sex hormones from the testes, ovaries, and adrenal cortex are released into the bloodstream in quantities sufficient to cause development of secondary sexual characteristics and accelerated growth of the genitalia. The increasing level of the sex hormones also causes other physiologic changes, including the acceleration in general body growth and shrinkage of lymphoid tissues seen in the classic growth curves described in Chapter 2. Neural growth is unaffected by the events of adolescence because it is essentially complete by age 6. The changes in the growth curves for the



• **Fig. 4.1** Diagrammatic representation of the cascade of endocrine signals controlling sexual development. Releasing factors from the hypothalamus are carried via the pituitary portal circulation to the anterior pituitary gland, where they initiate the release of pituitary gonadotropic hormones. These in turn stimulate cells in the testes, ovaries, and adrenals, which secrete the steroid sex hormones.



• **Fig. 4.2** Growth curves for the maxilla and mandible shown against the background of Scammon's curves. Note that growth of the jaws is intermediate between the neural and general body curves, with the mandible following the general body curve more closely than the maxilla. The acceleration in general body growth at puberty, which affects the jaws, parallels the dramatic increase in development of the sexual organs. Lymphoid involution also occurs at this time.

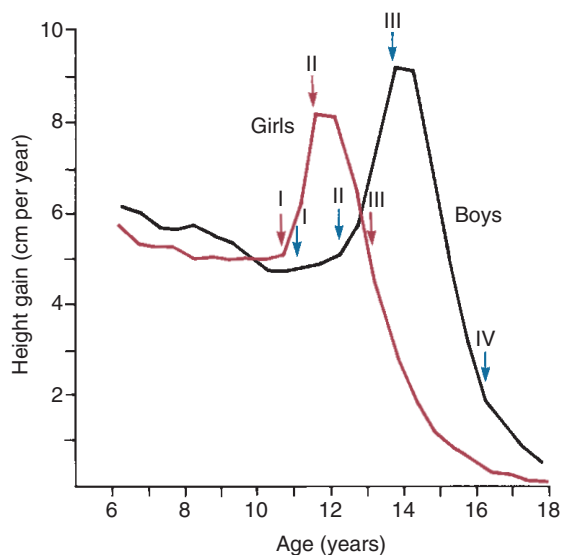
jaws, general body, lymphoid, and genital tissues, however, can be considered the result of the hormonal changes that accompany sexual maturation (Fig. 4.2). Eventually, feedback from the levels of circulating sex hormones affects the amount of GnRH hormones and thereby the amount of gonadotropins that are released,

so control of this endocrine system still is managed from the hypothalamic level.

The system by which a few neurons in the hypothalamus ultimately control the level of circulating sex hormones may seem curiously complex. The principle, however, is one used in control systems throughout the body and also in modern technology. Each of the steps in the control process results in an amplification of the control signal, in a way analogous to the amplification of a small musical signal between the signal source and speakers of a stereo system. The amount of pituitary gonadotropin produced is 100 to 1000 times greater than the amount of gonadotropin-releasing factors produced in the hypothalamus, and the amount of sex hormones produced is 1000 times greater than the amount of the pituitary hormones themselves. The system, then, is a three-stage amplifier. Rather than being a complex biologic curiosity, it is better viewed as a rational engineering design. A similar amplification of controlling signals from the brain is used, of course, in all body systems.

### Timing of Puberty

There is a great deal of individual variation, but puberty and the adolescent growth spurt occur on the average nearly 2 years earlier in girls than in boys (Fig. 4.3). Why this occurs is not known, but the timing of puberty is a highly heritable trait. When it occurs has an important impact on the timing of orthodontic treatment, which must be done earlier in girls than in boys to take advantage of the adolescent growth spurt. Because of the considerable individual variation, however, early-maturing boys will reach puberty ahead of slow-maturing girls, and it must be remembered that chronologic age is only a crude indicator of where an individual stands developmentally. The stage of development of secondary sexual characteristics provides a physiologic calendar of adolescence that correlates with the individual's physical growth status. Not all the secondary sexual characteristics are readily visible, of course, but most can be evaluated in a normal fully clothed examination, such as would occur in a dental office.



• **Fig. 4.3** Velocity curves for growth at adolescence, showing the difference in timing for girls and boys. Also indicated on the growth velocity curves are the corresponding stages in sexual development (see text). (From Marshall WA, Tanner JM. Puberty. In: Falkner F, Tanner JM, eds. *Human Growth*, vol 2. 2nd ed. New York: Plenum Publishing; 1986.)

Adolescence in girls can be divided into three stages, based on the extent of sexual development. The first stage, which occurs at about the beginning of the physical growth spurt, is the appearance of breast buds and early stages of the development of pubic hair. The peak velocity for physical growth occurs about 1 year after the initiation of stage I and coincides with stage II of development of sexual characteristics (see Fig. 4.3). At this time, there is noticeable breast development. Pubic hair is darker and more widespread, and hair appears in the armpits (axillary hair).

The third stage in girls occurs 1 to 1½ years after stage II and is marked by the onset of menstruation (menarche). By this time, the growth spurt is all but complete. At this stage, there is noticeable broadening of the hips with more adult fat distribution, and development of the breasts is complete.

The stages of sexual development in boys are more difficult to specifically define. Puberty begins later and extends over a longer period—about 5 years compared with 3½ years for girls (see Fig. 4.3). In boys, four stages in development can be correlated with the curve of general body growth at adolescence.

The initial sign of sexual maturation in boys usually is the “fat spurt.” The maturing boy gains weight and becomes almost chubby, with a somewhat feminine fat distribution. This probably occurs because estrogen production by the Leydig cells in the testes is stimulated before the more abundant Sertoli cells begin to produce significant amounts of testosterone. During this stage, boys may appear obese and somewhat awkward physically. At this time also, the scrotum begins to increase in size and may show some increase or change in pigmentation.

At stage II, about 1 year after stage I, the spurt in height is just beginning. At this stage, there is a redistribution and relative decrease in subcutaneous fat, pubic hair begins to appear, and growth of the penis begins.

The third stage occurs 8 to 12 months after stage II and coincides with the peak velocity in gain in height. At this time, axillary hair appears and facial hair appears on the upper lip only. A spurt in

muscle growth also occurs, along with a continued decrease in subcutaneous fat and an obviously harder and more angular body form. Pubic hair distribution appears more adult but has not yet spread to the medial area of the thighs. The penis and scrotum are near adult size.

Stage IV for boys, which occurs anywhere from 15 to 24 months after stage III, is difficult to pinpoint. At this time, the spurt of growth in height ends. There is facial hair on the chin and the upper lip, adult distribution and color of pubic and axillary hair, and a further increase in muscular strength.

The timing of puberty makes an important difference in ultimate body size, in a way that may seem paradoxical at first: the earlier the onset of puberty, the smaller the adult size, and vice versa. Growth in height depends on endochondral bone growth at the epiphyseal plates of the long bones, and the impact of the sex hormones on endochondral bone growth is twofold. First, the sex hormones stimulate the cartilage to grow faster, and this is a major factor in the adolescent growth spurt. But the sex hormones also cause an increase in the rate of skeletal maturation, which for the long bones is the rate at which cartilage is transformed into bone. The acceleration in maturation is even greater than the acceleration in growth. Thus during the rapid growth at adolescence, the cartilage is used up faster than it is replaced. Toward the end of adolescence, the last of the cartilage is transformed into bone, and the epiphyseal plates close. At that point, of course, growth potential is lost and growth in height stops.

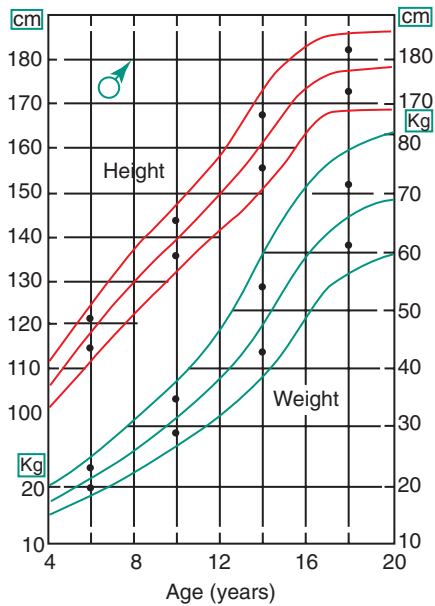
This early cessation of growth after early sexual maturation is particularly prominent in girls. It is responsible for much of the difference in adult size between men and women. Girls mature earlier on the average and finish their growth much sooner. Boys are not bigger than girls until they grow for a longer time at adolescence. The difference arises because there is slow but steady growth before the growth spurt, and so when the growth spurt occurs, for those who mature late, it takes off from a higher plateau. The epiphyseal plates close more slowly in males than in females, and therefore the cutoff in growth that accompanies the attainment of sexual maturity is also more complete in girls.

The timing of puberty seems to be affected by both genetic and environmental influences. There are early- and late-maturing families, and individuals in some racial and ethnic groups mature earlier than others. As Fig. 4.4 shows, Dutch boys are about 5 cm (2 inches) taller and 7 kg (15 pounds) heavier than their American counterparts at age 10, and it is likely that both heredity and environment play a role in producing that considerable difference. In girls, it appears that the onset of menstruation requires the development of a certain amount of body fat. In girls of a slender body type, the onset of menstruation can be delayed until this level is reached. Athletic girls with low body fat often are slow to begin their menstrual periods, and highly trained female athletes whose body fat levels are quite low may stop menstruating, apparently in response to the low body fat levels.

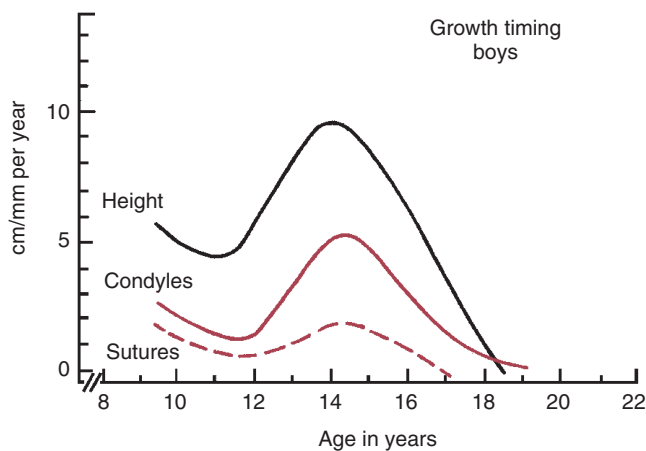
Seasonal and cultural factors also can affect the overall rate of physical growth. For example, everything else being equal, growth tends to be faster in spring and summer than in fall and winter, and city children tend to mature faster than rural ones, especially in less developed countries. Such effects presumably are mediated via the hypothalamus and indicate that the rate of secretion of gonadotropin-releasing factors can be influenced by external stimuli.

In the description given earlier, the stages of adolescent development were correlated with growth in height. Fortunately, growth of the jaws usually correlates with the physiologic events of puberty



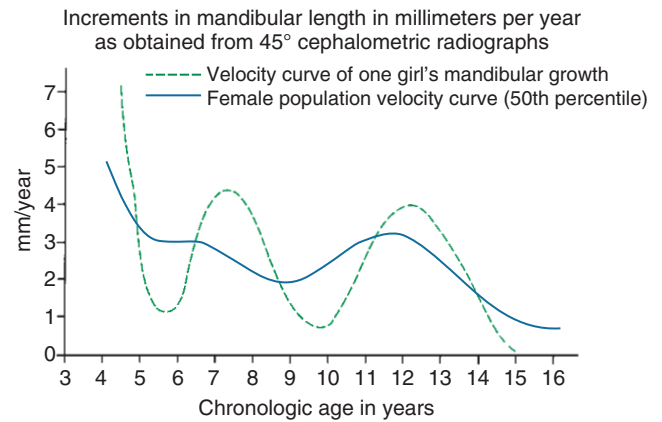


• **Fig. 4.4** Height and weight curves for boys in the United States, showing means  $\pm$  2 standard deviations. Note the black dots on the graphs at ages 6, 10, 14, and 18. The upper dot shows median height and weight for boys in the Netherlands; the lower one shows median height and weight for boys in the United States. Note that at all ages the Dutch boys are larger and heavier than their U.S. counterparts; at age 10 the height and weight differences are nearly 5 cm (2 inches) and 7 kg (15 pounds). This is a dramatic illustration of how growth is affected by racial, ethnic, national, and other variables.



• **Fig. 4.5** On average, the adolescent spurt in growth of the jaws occurs at about the same time as the spurt in height, but it must be remembered that there is considerable individual variation. (Data from the Burlington Growth Study; redrawn from Woodside DG. In: Salzmann JA, ed. *Orthodontics in Daily Practice*. Philadelphia: JB Lippincott; 1974.)

in about the same way as growth in height (Fig. 4.5). There is an adolescent growth spurt in the length of the mandible, though not nearly as dramatic a spurt as that in body height, and a modest although discernible increase in growth at the sutures of the maxilla. The cephalocaudal gradient of growth, which is part of the normal



• **Fig. 4.6** Longitudinal data for increase in length of the mandible in one girl, taken from the Burlington growth study in Canada, demonstrates an acceleration of growth at about 8 years of age (juvenile acceleration) that is about equal in intensity to the pubertal acceleration between ages 11 and 14. Changes of this type in the pattern of growth for individuals tend to be smoothed out when cross-sectional or group average data are studied. (From Woodside DG. In: Salzmann JA, ed. *Orthodontics in Daily Practice*. Philadelphia: JB Lippincott; 1974.)

pattern, is dramatically evident at puberty. More growth occurs in the lower extremity than in the upper, and within the face, more growth takes place in the lower jaw than in the upper. This produces an acceleration in mandibular growth relative to growth of the maxilla and results in the differential jaw growth referred to previously. The maturing face becomes less convex as the mandible and chin become more prominent as a result of the differential jaw growth.

Although jaw growth follows the curve for general body growth, the correlation is not perfect. Longitudinal data from studies of craniofacial growth indicate that a significant number of individuals, especially among girls, have a “juvenile acceleration” in jaw growth that occurs 1 to 2 years before the adolescent growth spurt (Fig. 4.6).<sup>2</sup> This juvenile acceleration can equal or even exceed the jaw growth that accompanies secondary sexual maturation. In boys, if a juvenile spurt occurs, it is nearly always less intense than the growth acceleration at puberty.

This tendency for a clinically useful acceleration in jaw growth to precede the adolescent spurt, particularly in girls, is a major reason for careful assessment of physiologic age in planning orthodontic treatment. If treatment is delayed too long, the opportunity to use the growth spurt is missed. In early-maturing girls, the adolescent growth spurt often precedes the final transition of the dentition, so by the time the second premolars and second molars erupt, physical growth is all but complete. The presence of a juvenile growth spurt in girls accentuates this tendency for significant acceleration of jaw growth in the mixed dentition. For many girls, if they are to receive orthodontic treatment while they are growing rapidly, the treatment must begin during the mixed dentition rather than after all succedaneous teeth have erupted.

In slow-maturing boys, on the other hand, the dentition can be relatively complete while a considerable amount of physical growth remains. In the timing of orthodontic treatment, clinicians have a tendency to treat girls too late and boys too soon, forgetting the considerable disparity in the rate of physiologic maturation.

## Growth Patterns in the Dentofacial Complex

### Dimensional Changes

#### Growth of the Nasomaxillary Complex

As we have noted in the preceding chapters, growth of the nasomaxillary area is produced by two basic mechanisms: (1) passive displacement, created by growth in the cranial base that pushes the maxilla forward, and (2) active growth of the maxillary structures and nose (Fig. 4.7). Because the push from behind decreases greatly as the cranial base synchondroses close at about age 7, most of the growth after that time (i.e., during the time period when most orthodontic treatment is done) is due to active growth at the maxillary sutures and surfaces.

The effect of surface modeling must be taken into account when active growth of the maxilla is considered. Surface changes can either add to or subtract from growth at the sutures by surface apposition or resorption, respectively. In fact, the maxilla grows downward and forward as bone is added in the tuberosity area posteriorly and at the posterior and superior sutures, but the anterior surfaces of the bone are resorbing at the same time (Fig. 4.8). For this reason, the distance that the body of the maxilla and the maxillary teeth are carried downward and forward during growth is greater by about 25% than the forward movement of the anterior surface of the maxilla. This amount of surface modeling, which conceals the extent of relocation of the jaws, is even more prominent when rotation of the maxilla during growth is considered (see the following sections).

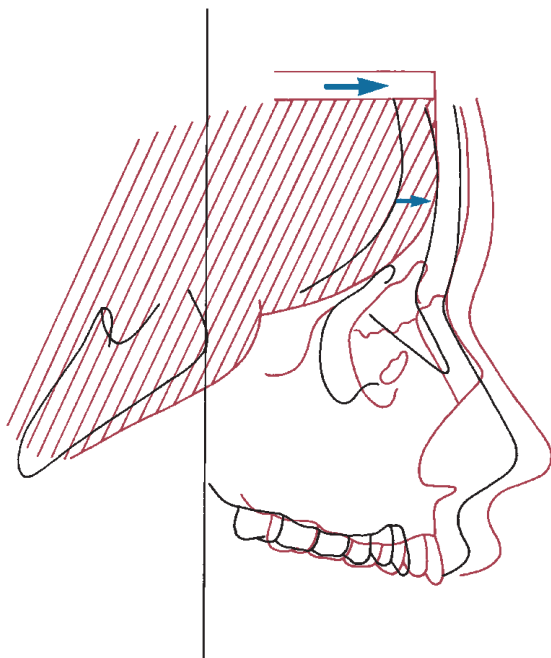
The nasal structures undergo the same passive displacement as the rest of the maxilla. However, the nose grows more rapidly than the rest of the face, particularly during the adolescent growth

spurt. Nasal growth is produced in part by an increase in size of the cartilaginous nasal septum. In addition, proliferation of the lateral cartilages alters the shape of the nose and contributes to an increase in overall size. On average, nasal dimensions increase at a rate about 25% greater than growth of the maxilla during adolescence (Fig. 4.9), but growth of the nose is extremely variable among racial or ethnic groups and quite variable within those groups. There are no fixed proportions for nose size except the more prominent the nose, the more prominent the jaws need to be to produce reasonable facial balance.

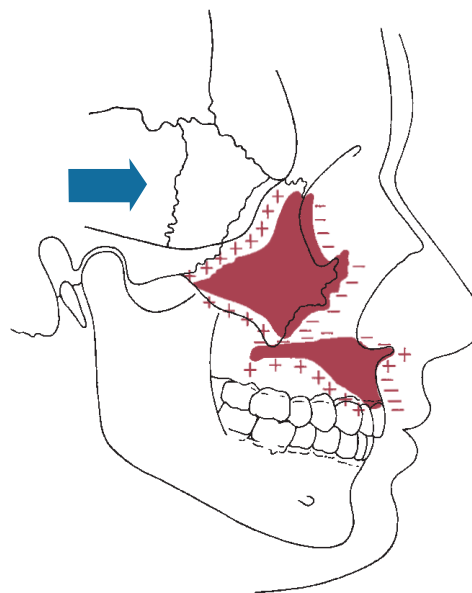
#### Mandibular Growth

Growth of the mandible continues at a relatively steady rate before puberty. On the average, as Table 4.1 shows, ramus height increases 1 to 2 mm per year and body length increases 2 to 3 mm per year. These cross-sectional data tend to smooth out the juvenile and pubertal growth spurts, which do occur in growth of the mandible (see previous discussion).

One feature of mandibular growth is an accentuation of the prominence of the chin. At one time it was thought that this occurred primarily by addition of bone to the chin, but that is incorrect. Although small amounts of bone are added, the change in the contour of the chin itself occurs largely because the area just above the chin, between it and the base of the alveolar process, is a resorptive area. The increase in chin prominence with maturity results from a combination of forward translation of the chin as a part of the overall growth pattern of the mandible and resorption above the chin that alters the bony contours.



• **Fig. 4.7** Diagrammatic representation of a major mechanism for growth of the maxilla: Structures of the nasomaxillary complex are displaced forward as the cranial base lengthens and the anterior lobes of the brain grow in size. (Redrawn from Enlow DH, Hans MG. *Essentials of Facial Growth*. Philadelphia: WB Saunders; 1996.)



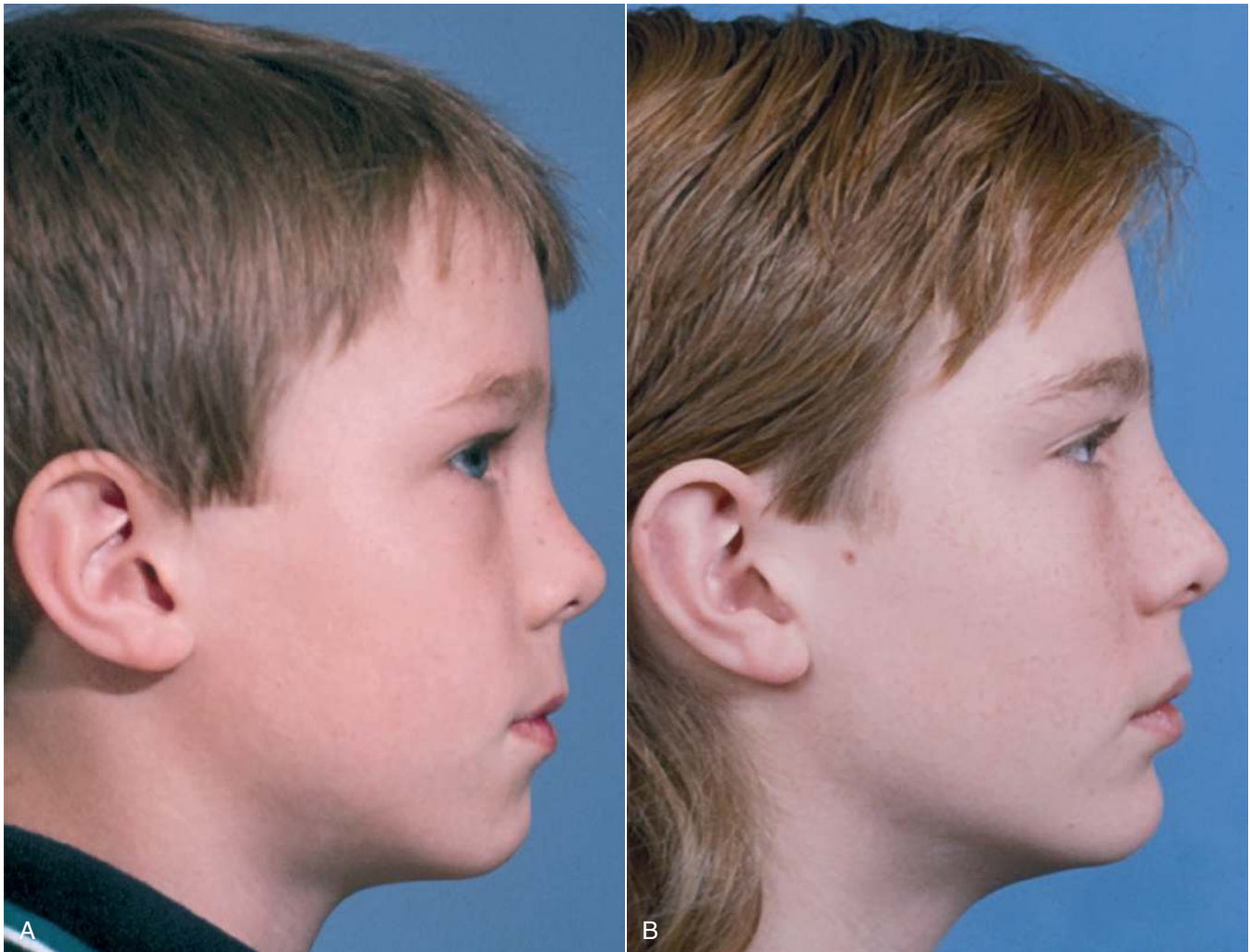• **Fig. 4.8** As the maxilla is translated downward and forward, bone is added at the sutures and in the tuberosity area posteriorly, but at the same time, surface modeling removes bone from the anterior surfaces (except for a small area at the anterior nasal spine). For this reason, the amount of forward movement of anterior surfaces is less than the amount of displacement. In the roof of the mouth, however, surface modeling adds bone, whereas bone is resorbed from the floor of the nose. The total downward movement of the palatal vault, therefore, is greater than the amount of displacement. (Redrawn from Enlow DH, Hans MG. *Essentials of Facial Growth*. Philadelphia: WB Saunders; 1996.)

An important source of variability in how much the chin grows forward is the extent of growth changes at the glenoid fossa. If the area of the temporal bone to which the mandible is attached moved forward relative to the cranial base during growth, this would translate the mandible forward in the same way that cranial base growth translates the maxilla. However, this rarely happens. Usually, the attachment point moves straight down, so that there is no anteroposterior displacement of the mandible, but occasionally it moves posteriorly, thus subtracting from rather than augmenting the forward projection of the chin.<sup>3</sup> In both the patients shown in Fig. 4.10, for instance, there was an approximate 7-mm increase in length of the mandible during orthodontic treatment around the time of puberty. In one of the patients, the temporomandibular joint (TMJ) did not relocate during growth and the chin projected forward 7 mm. In the other patient, the TMJ moved posteriorly, resulting in only a small forward projection of the chin despite the increase in mandibular length.

### Timing of Growth in Width, Length, and Height

For the three planes of space in both the maxilla and mandible, there is a definite sequence in which growth is “completed” (i.e., declines to the very slow rate that characterizes normal adults). Growth in width is completed first, then growth in length, and finally growth in height.

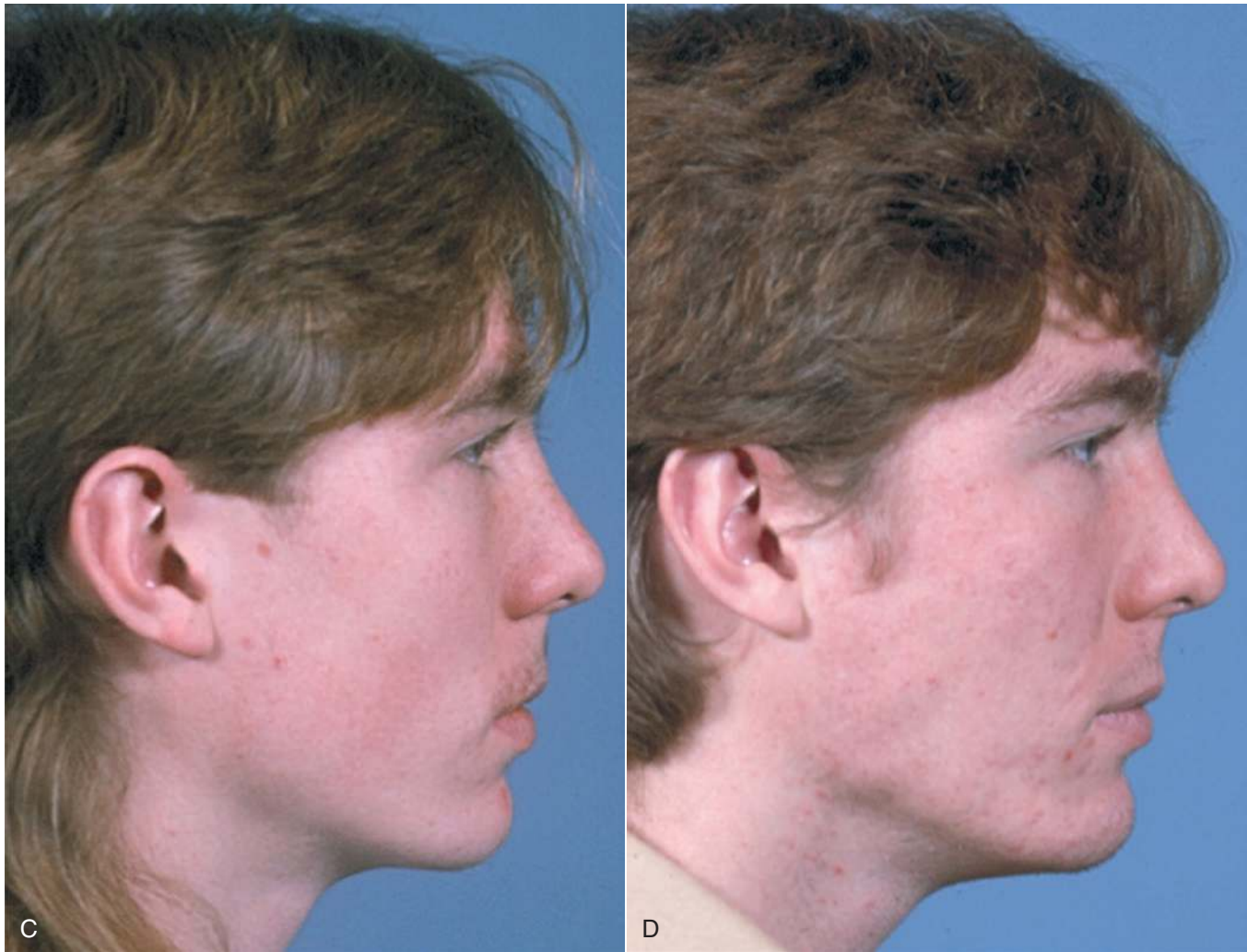Growth in width of both jaws, including the width of the dental arches, tends to be completed before the adolescent growth spurt and is affected minimally if at all by adolescent growth changes (Fig. 4.11). For instance, intercanine width is more likely to decrease than increase after age 12.<sup>4</sup> There is a partial exception to this rule, however. As the jaws grow in length posteriorly, they also grow wider. For the maxilla, this affects primarily the width across the second molars, and if they are able to erupt, the width across the third molars as well. For the mandible, both molar and bicondylar widths show small increases until the end of growth in length. Anterior width dimensions of the mandible stabilize earlier.



• **Fig. 4.9** The nose is small relative to the jaws before adolescence, then grows much more than the jaws in adolescence and continues to grow after forward growth of the maxilla and mandible has all but stopped. This decreases the apparent prominence of the jaws relative to the midface. In the same boy: (A) age 7-0, well prior to adolescence; (B) age 12-8, early adolescence;

*Continued*





• **Fig. 4.9, cont'd** (C) age 15-8, toward the end of the adolescent growth spurt, when forward jaw growth is nearly complete but the nose is still growing; (D) age 18-8, late adolescence. Note the amount of forward nose growth but largely vertical growth of the jaws beyond age 15-8.

Growth in length and height of both jaws continues through the period of puberty. In girls, the maxilla grows slowly downward and forward to age 14 to 15 on average (more accurately, by 2 to 3 years after first menstruation), then tends to grow slightly more almost straight forward (Fig. 4.12).<sup>5</sup> In both sexes, growth in vertical height of the face continues longer than growth in length, with the late vertical growth occurring primarily in the mandible. Increases in facial height and concomitant eruption of teeth continue throughout life, but the decline to the adult level (which for vertical growth is surprisingly large [see the following section]) often does not occur until the early 20s in boys and somewhat earlier in girls.

## Rotation of Jaws During Growth

### Implant Studies of Jaw Rotation

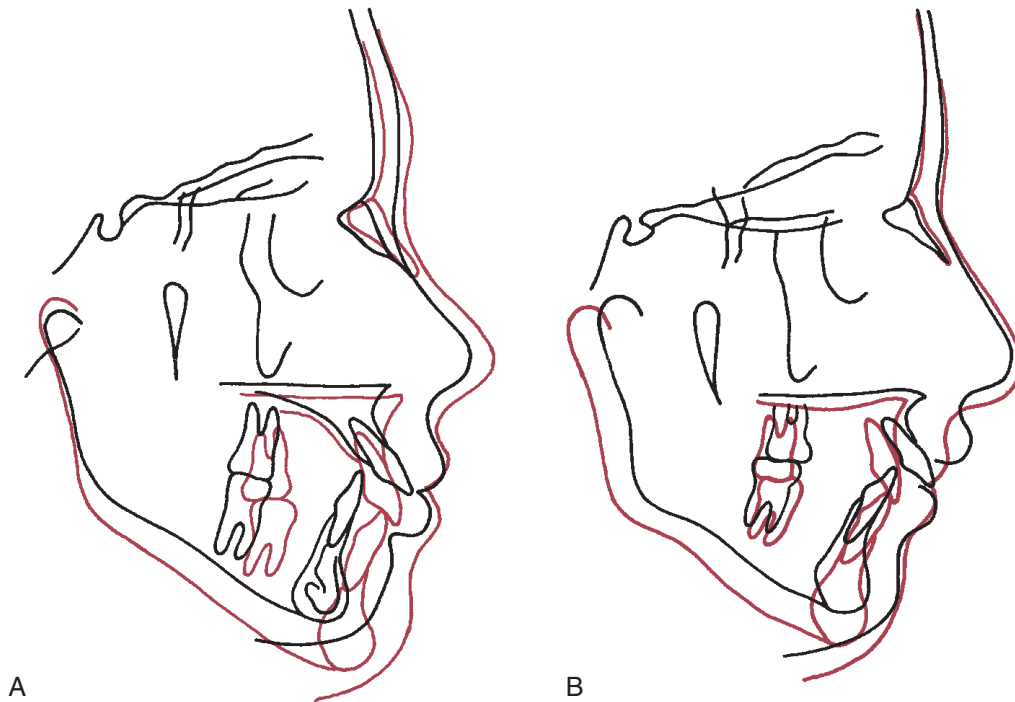
Until longitudinal studies of growth using metallic implants in the jaws were carried out in the 1960s, primarily by Björk and coworkers in Copenhagen (see Chapter 2), the extent to which both the maxilla and mandible rotate during growth was not

appreciated. The reason is that the rotation that occurs in the core of each jaw, called *internal rotation*, tends to be masked by surface changes and alterations in the rate of tooth eruption. The surface changes produce *external rotation*. Obviously, the overall change in the orientation of each jaw, as judged by the palatal plane and mandibular plane, results from a combination of internal and external rotation.

The terminology for describing these rotational changes is itself confusing. The descriptive terms used here, in an effort to simplify and clarify a complex and difficult subject, are not those Björk used in the original papers on this subject<sup>6</sup> or exactly the same as his successors in Copenhagen suggested later.<sup>7</sup> See Table 4.2 for a comparison of terms.

It is easier to visualize the internal and external rotation of the jaws by considering the mandible first. The core of the mandible is the bone that surrounds the inferior alveolar nerve. The rest of the mandible consists of its several functional processes (Fig. 4.13). These are the alveolar process (bone supporting the teeth and providing for mastication), the muscular processes (the bone to which the muscles of mastication attach), and the condylar process,



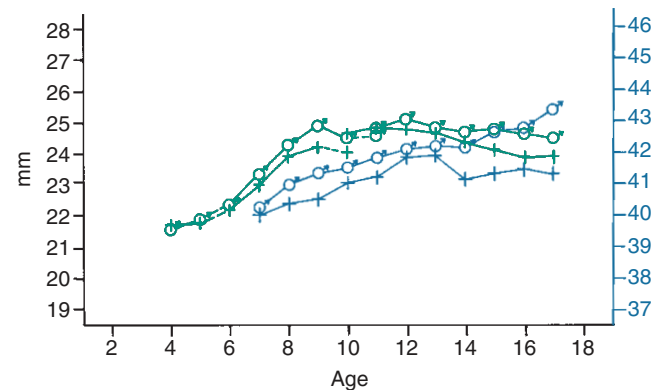


• **Fig. 4.10** Cephalometric tracings showing growth in two patients during the orthodontic correction of moderate Class II malocclusion (superimposed on sphenothmoid triad in cranial base). (A) Changes from age 11 years 10 months to age 14 years 11 months. In this patient, approximately 7 mm of mandibular growth was expressed entirely as forward movement of the chin, whereas the area of the temporomandibular joint remained in the same anteroposterior position relative to the cranial base. (B) Changes in another patient from age 11 years 8 months to age 15 years 0 months. This patient also had approximately 7 mm of mandibular growth, but the temporomandibular joint area moved downward and backward relative to the cranial base, so much of the growth was not expressed as forward movement of the chin. (Courtesy Dr. V. Kokich.)

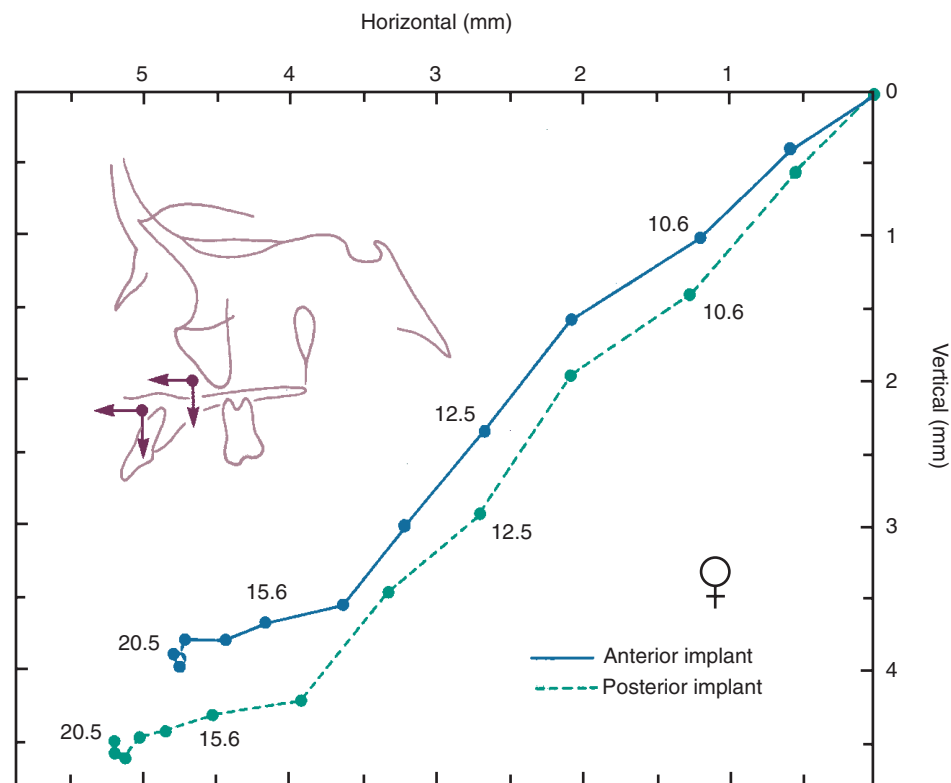
**TABLE 4.1** Mandibular Length Changes

Age	BODY LENGTH INCREASE (MM) (GONION-POGONION)		RAMUS HEIGHT INCREASE (MM) (CONDYLION-GONION)	
	Male	Female	Male	Female
7	2.8	1.7	0.8	1.2
8	1.7	2.5	1.4	1.4
9	1.9	1.1	1.5	0.3
10	2.0	2.5	1.2	0.7
11	2.2	1.7	1.8	0.9
12	1.3	0.8	1.4	2.2
13	2.0	1.8	2.2	0.5
14	2.5	1.1	2.2	1.7
15	1.6	1.1	1.1	2.3
16	2.3	1.0	3.4	1.6

Data from Riolo ML, et al. *An Atlas of Craniofacial Growth*. Ann Arbor, MI: University of Michigan Center for Human Growth and Development; 1974.



• **Fig. 4.11** Average changes in mandibular canine and molar widths in both sexes during growth. Molar widths are shown in blue, canine widths in green. (From Moyers RE, et al. *Standards of Human Occlusal Development*. Ann Arbor, MI: University of Michigan Center for Human Growth and Development; 1976.)



• **Fig. 4.12** Mean growth tracks of anterior and posterior maxillary implants relative to the cranial base and its perpendicular, in a group of Danish girls. The two tracks are shown with their origins superimposed (upper right corner) to facilitate comparison. Note that the posterior implant moves down and forward more than the anterior one, with growth continuing into the late teens at a slow rate. (Courtesy Dr. B. Solow.) The orientation of this graph and of Figs. 4.14, 4.15, 4.18, 4.19, 4.21, 4.22 and 4.23 is the standard orientation of cephalometric tracings in Europe, used here because these figures were published that way.

**TABLE 4.2 Terminology: Rotational Changes of the Jaws**

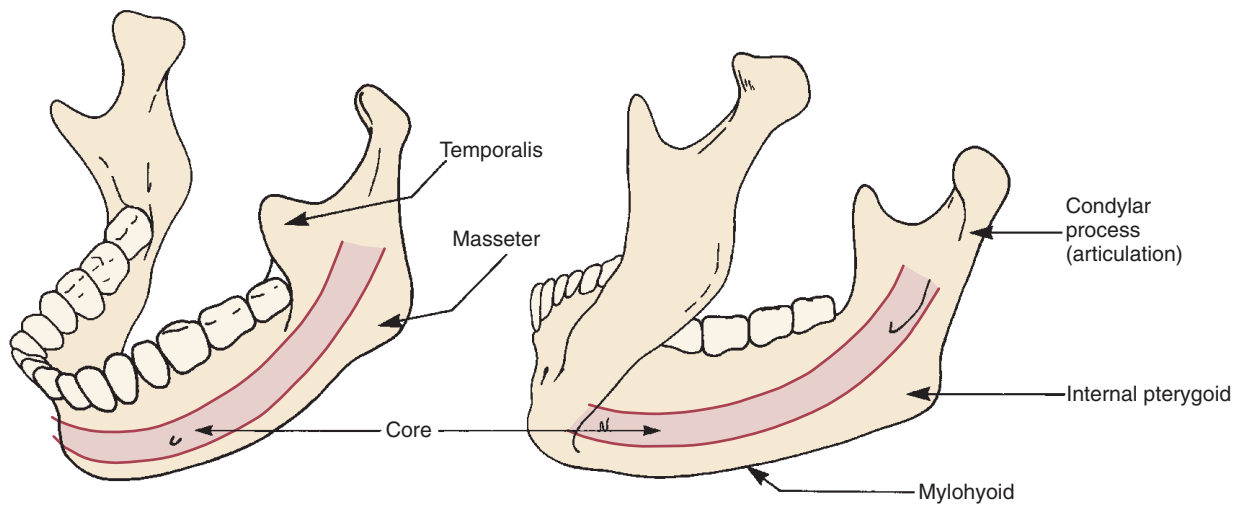
Condition	Björk	Solow, Houston	Proffit
Posterior growth greater than anterior	Forward rotation		
Anterior growth greater than posterior	Backward rotation		
Rotation of mandibular core relative to cranial base	Total rotation	True rotation	Internal rotation
Rotation of mandibular plane relative to cranial base	Matrix rotation	Apparent rotation	Total rotation
Rotation of mandibular plane relative to core of mandible	Intramatrix rotation	Angular modeling of lower border	External rotation

Proffit: Total rotation = internal rotation – external rotation.  
Björk: Matrix rotation = total rotation – intramatrix rotation.  
Solow: Apparent rotation = true rotation – angular modeling of lower border.

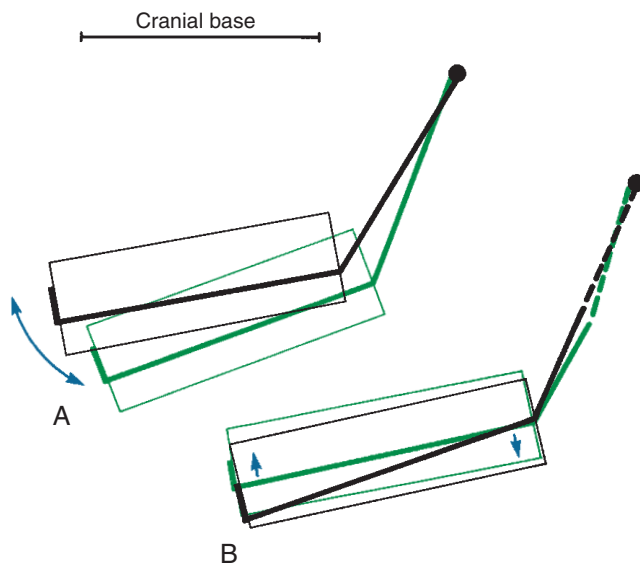
the function in this case being the articulation of the jaw with the skull. If implants are placed in areas of stable bone away from the functional processes, it can be observed that in most individuals, the core of the mandible rotates during growth in a way that would tend to decrease the mandibular plane angle (i.e., up anteriorly and down posteriorly) (Fig. 4.14). This can occur either by rotation around the condyle or rotation centered within the body of the mandible. By convention, the rotation of either jaw is considered “forward” and given a negative sign if there is more growth posteriorly than anteriorly. This would bring the chin upward and

forward. The rotation is “backward” and given a positive direction if it lengthens anterior dimensions more than posterior ones, bringing the chin downward and backward.

One of the features of internal rotation of the mandible is the variation among individuals, ranging up to 10 to 15 degrees.<sup>8</sup> The pattern of vertical facial development, discussed in more detail later, is strongly related to the rotation of both jaws. For an average individual with normal vertical facial proportions, however, there is about a 15-degree internal rotation from age 4 to adult life (Fig. 4.15). Of this, about 25% results from rotation



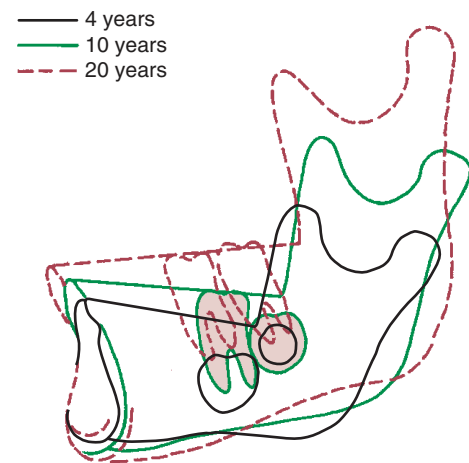
• **Fig. 4.13** The mandible can be visualized as consisting of a core of bone surrounding the inferior alveolar neurovascular bundle and a series of functional processes: the alveolar process, serving the function of mastication; the muscular processes, serving as muscle attachments; and the condylar process, serving to articulate the bone with the rest of the skull.



• **Fig. 4.14** Internal rotation of the mandible (i.e., rotation of the core relative to the cranial base) has two components. (A) Rotation around the condyle, or matrix rotation. (B) Rotation centered within the body of the mandible, or intramatrix rotation. (Redrawn from Björk A, Skieller V. *Eur J Orthod.* 5:1-46, 1983.)

at the condyle and 75% results from rotation within the body of the mandible.

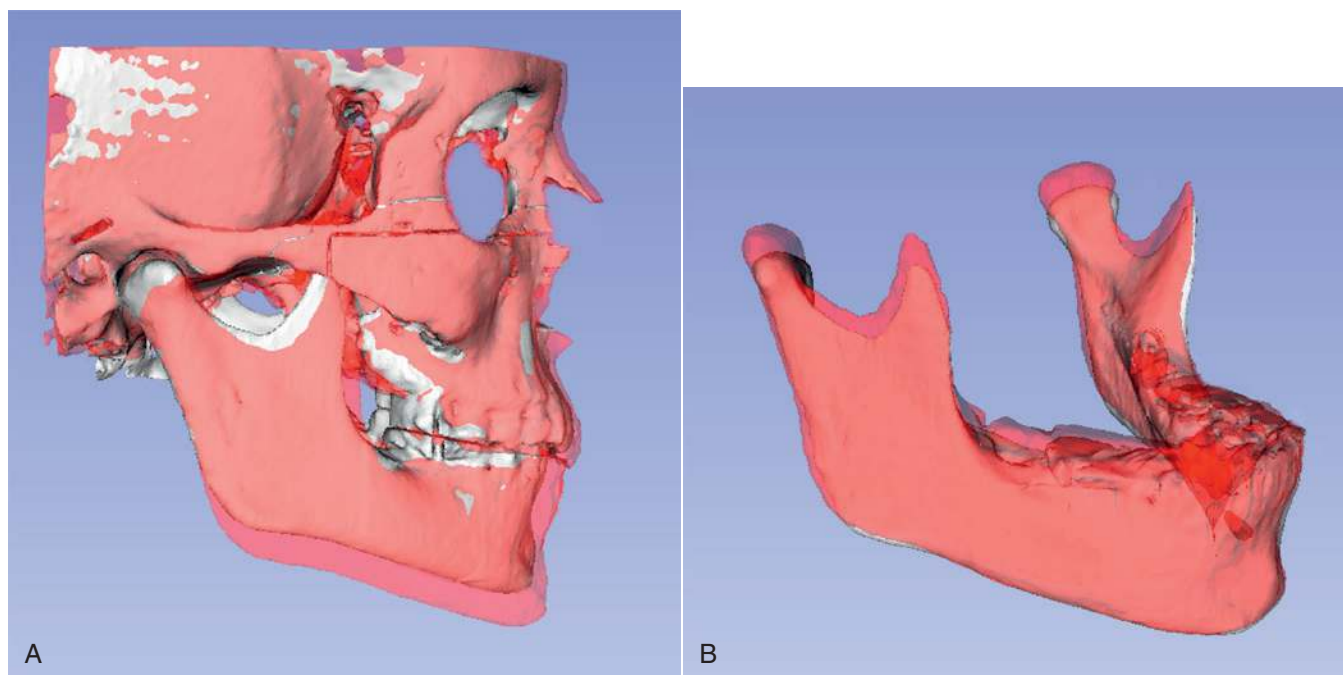
During the time that the core of the mandible rotates forward an average of 15 degrees, the mandibular plane angle, representing the orientation of the jaw to an outside observer, decreases only 2 to 4 degrees on average. The reason that the internal rotation is not expressed in jaw orientation, of course, is that surface changes (external rotation) tend to compensate. This means that the posterior part of the lower border of the mandible must be an area of resorption, whereas the anterior aspect of the lower border is



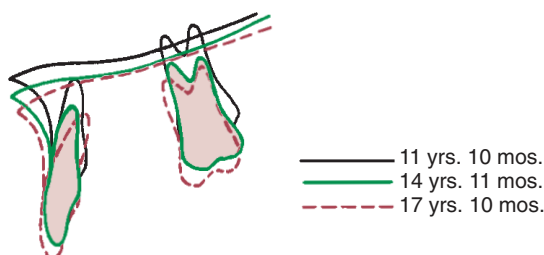
• **Fig. 4.15** Superimposition on implants for an individual with a normal pattern of growth, showing surface changes in the mandible from ages 4 to 20 years. For this patient, there was a 19-degree internal rotation but only a 3-degree change in the mandibular plane angle. Note how the dramatic modeling (external rotation) compensates for and conceals the extent of the internal rotation. (From Björk A, Skieller V. *Eur J Orthod.* 5:1-46, 1983.)

unchanged or undergoes slight apposition. It is possible now to superimpose three-dimensional images of the mandible on the internal surface of the mandibular symphysis, and this allows frontal and oblique views of the surface changes that were not revealed by the two-dimensional implant studies (Fig. 4.16).<sup>9</sup>

It is less easy to divide the maxilla into a core of bone and a series of functional processes. The alveolar process is certainly a functional process in the classic sense, but there are no areas of muscle attachment analogous to those of the mandible. The parts of the bone surrounding the air passages serve the function of



• **Fig. 4.16** Three-dimensional superimposition for a growing child on the cranial base (A) and mandibular symphysis (B). In both views, white and darker pink show surface changes and projection of new growth. You can clearly see, better than in two-dimensional views, the upward and backward growth of the condylar processes and modeling of their base that accompany downward and forward growth of the mandible.



• **Fig. 4.17** Superimposition on implants in the maxilla reveals that this patient experienced a small amount of backward internal rotation of the maxilla (i.e., down anteriorly). A small amount of forward rotation is the more usual pattern, but backward rotation occurs frequently. (From Björk A, Skieller V. *Am J Orthod.* 62:357, 1972.)

respiration, and the form–function relationships involved are poorly understood. If implants are placed above the maxillary alveolar process, however, one can observe a core of the maxilla that undergoes a small and variable degree of rotation, forward or backward (Fig. 4.17).<sup>10</sup> This internal rotation is analogous to the rotation within the body of the mandible.

At the same time that internal rotation of the maxilla is occurring, there also are varying degrees of modeling of the palate. Similar variations in the amount of eruption of the incisors and molars occur. These changes amount, of course, to an external rotation. For most patients, the external rotation is opposite in direction and equal in magnitude to the internal rotation, so that the two rotations cancel and the net change in jaw orientation (as evaluated by the palatal plane) is zero (see Fig. 3.20). Until the implant

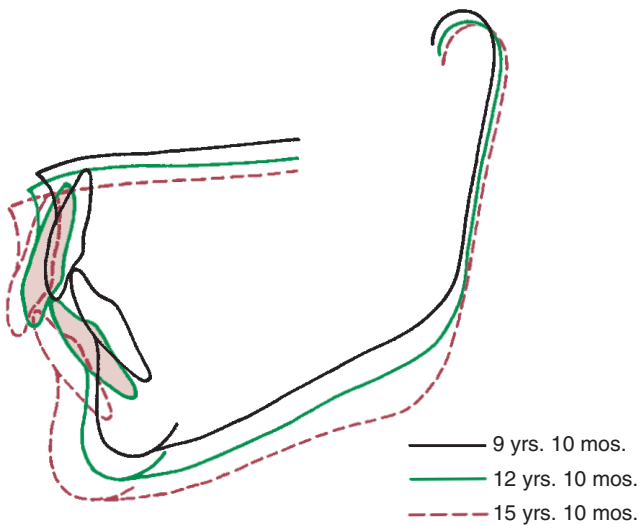
studies were done, rotation of the maxilla during normal growth had not been suspected.

Although both internal and external rotation occur in everyone, variations from the average pattern are common. Greater or lesser degrees of both internal and external rotation often occur, altering the extent to which external changes compensate for the internal rotation.<sup>11</sup> The result is moderate variation in jaw orientation, even in individuals with normal facial proportions. In addition, the rotational patterns of growth are quite different for individuals who have what are called the *short-face* and *long-face* types of vertical facial development.

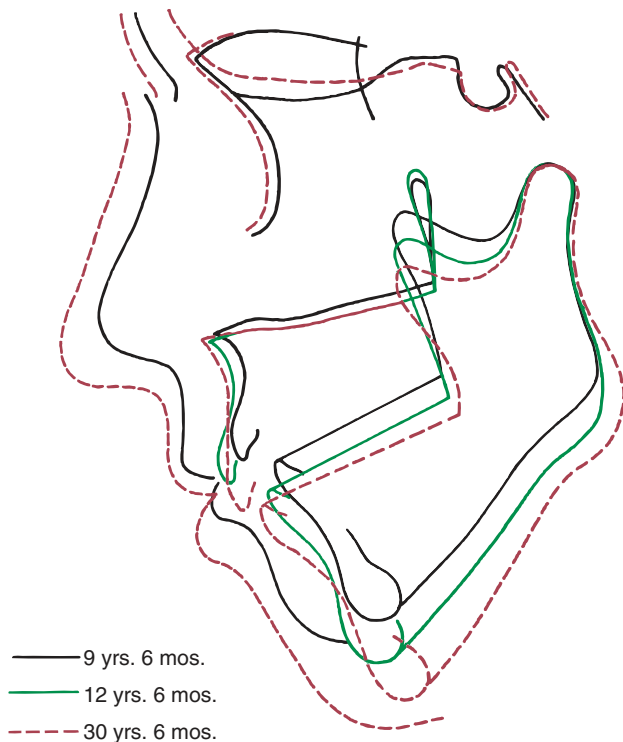
Individuals of the short-face type, who are characterized by short anterior lower face height, have excessive forward rotation of the mandible during growth, resulting from both an increase in the normal internal rotation and a decrease in external compensation. The result is a nearly horizontal palatal plane, a low mandibular plane angle, and a large gonial angle (Fig. 4.18). A deep bite malocclusion and crowded incisors usually accompany this type of rotation (discussed later).

In long-face individuals, who have excessive lower anterior face height, the palatal plane rotates down posteriorly, often creating a negative rather than the normal positive inclination to the true horizontal. The mandible shows an opposite, backward rotation, with an increase in the mandibular plane angle (Fig. 4.19). The mandibular changes result primarily from a lack of the normal forward internal rotation or even a backward internal rotation. The internal rotation, in turn, is primarily centered at the condyle. This type of rotation is associated with anterior open bite malocclusion and mandibular deficiency (because the chin rotates back as well as down). Backward rotation of the mandible also occurs in patients with abnormalities or pathologic changes affecting the





• **Fig. 4.18** Cranial base superimposition shows the characteristic pattern of forward mandibular rotation and a decrease in the mandibular plane angle in an individual with normal growth. This looks very different from the growth pattern shown in Fig. 4.17 with implant superimposition, but the pattern really is similar—you just don't see the internal rotation and compensatory external rotation in a cranial base superimposition. (From Björk A, Skieller V. *Am J Orthod.* 62:344, 1972.)



• **Fig. 4.19** Cranial base superimposition showing the pattern of jaw rotation in an individual with the long-face pattern of growth. These patients do not have the normal amount of forward internal rotation and may even have backward internal rotation. As the mandible rotates backward, anterior face height increases, there is a tendency toward anterior open bite, and the incisors are thrust forward relative to the mandible. (From Björk A, Skieller V. *Eur J Orthod.* 5:29, 1983.)

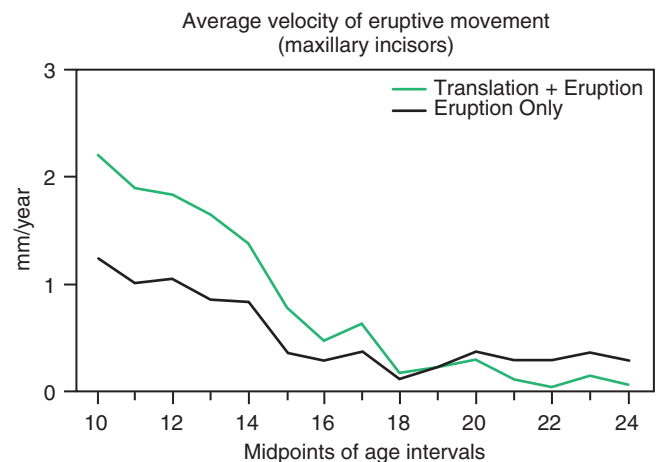
TMJs. In these individuals, growth at the condyle is restricted. The interesting result in three cases documented by Björk and Skieller was backward rotation centered in the body of the mandible, rather than the backward rotation at the condyle that is seen in individuals of the classic long-face type.<sup>12</sup> Jaw orientation changes in both the backward-rotating types, however, are similar, and the same types of malocclusions develop.

### Interaction Between Jaw Rotation and Tooth Eruption

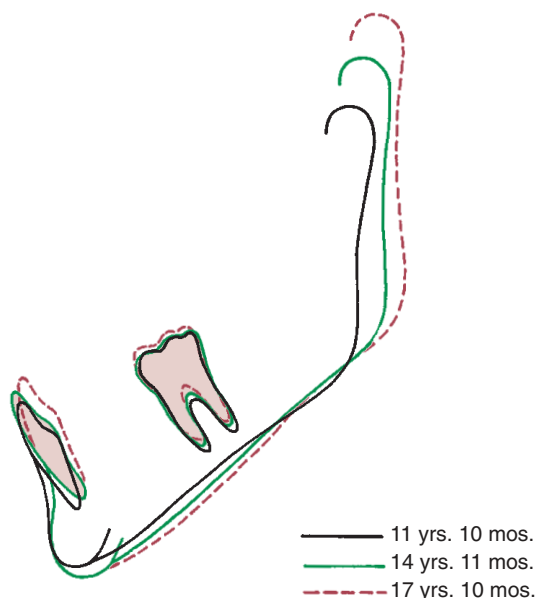
As we discussed in Chapter 3, growth of the mandible away from the maxilla creates a space into which the teeth erupt. The rotational pattern of jaw growth obviously influences the magnitude of tooth eruption. To a surprising extent, it can also influence the direction of eruption and the ultimate anteroposterior position of the incisor teeth.

The path of eruption of the maxillary teeth is downward and somewhat forward (see Figs. 4.12 and 4.17). In normal growth, the maxilla usually rotates a few degrees forward but frequently rotates slightly backward. Forward rotation would tend to tip the incisors forward, increasing their prominence, whereas backward rotation directs the anterior teeth more posteriorly, relatively uprighing them and decreasing their prominence. Movement of the teeth relative to the cranial base obviously could be produced by a combination of *translocation* as the tooth moved along with the jaw in which it was embedded, and true *eruption*, movement of the tooth within its jaw. As Fig. 4.20 shows, translocation contributes about half the total maxillary tooth movement during adolescent growth; the rest is due to eruptive movement of the teeth.

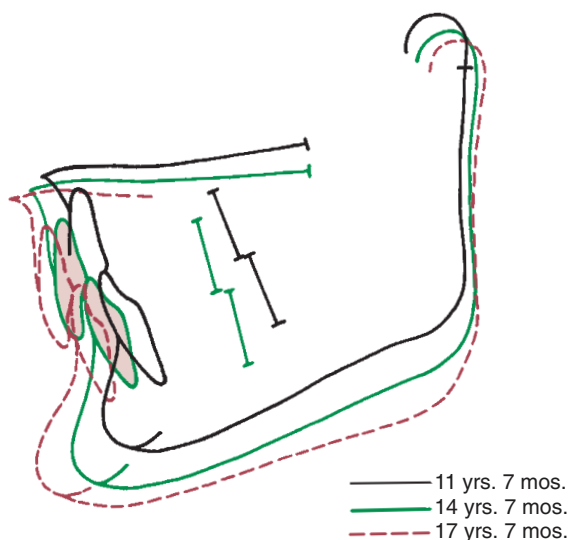
The eruption path of mandibular teeth is upward and somewhat forward. The normal internal rotation of the mandible carries the jaw upward in front. This rotation alters the eruption path of the incisors, tending to direct them more posteriorly than would otherwise have been the case (Fig. 4.21). Because the internal jaw



• **Fig. 4.20** The average velocity of continued eruption (movement of the incisors relative to implants in the maxilla) and translocation (movement away from the cranial base) of maxillary incisors in Danish girls, from a mixed longitudinal sample. Note that movement of the teeth away from the cranial base is due to a combination of eruption and translocation as the jaw grows, and that small changes due to eruption continue after growth has essentially stopped. (Redrawn from Solow B, Iseri H. Maxillary growth revisited: an update based on recent implant studies. In: Davidovitch Z, Norton LA, eds. *Biological Mechanisms of Tooth Movement and Craniofacial Adaptation*. Boston: Harvard Society for Advancement of Orthodontics; 1996.)

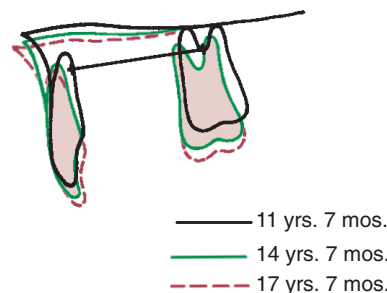


• **Fig. 4.21** Superimposition on mandibular implants shows the lingual positioning of the mandibular incisors relative to the mandible that often accompanies forward rotation during growth. (From Björk A, Skieller V. *Am J Orthod.* 62:357, 1972.)



• **Fig. 4.22** Cranial base superimposition for a patient with the short-face pattern of growth. As the mandible rotates upward and forward, anterior movement of the incisors is impeded and the bite deepens, creating a deep bite malocclusion that usually includes crowded incisors. (From Björk A, Skieller V. *Am J Orthod.* 62:355, 1972.)

rotation tends to upright the incisors, the molars migrate further mesially during growth than do the incisors, and this migration is reflected in the decrease in arch length that normally occurs (Fig. 4.22). Because the forward internal rotation of the mandible is greater than that of the maxilla, it is not surprising that the normal decrease in mandibular arch length is somewhat greater than the decrease in maxillary arch length.



• **Fig. 4.23** Superimposition on the maxilla reveals uprighting of the maxillary incisors in the short-face growth pattern (same patient as Fig. 4.20). This decreases arch length and contributes to progressive crowding. (From Björk A, Skieller V. *Am J Orthod.* 62:355, 1972.)

Note that this explanation for the decrease in arch length that normally occurs in both jaws is different from the 20th century interpretation that emphasized forward migration of the molar teeth. The modern view places relatively greater importance on lingual movement of the incisors and relatively less importance on the forward movement of molars. In fact, the same implant studies that revealed the internal jaw rotation also confirmed that changes in anteroposterior position of the incisor teeth are a major influence on arch length changes.

Given this relationship between jaw rotation and incisor position, it is not surprising that both the vertical and the anteroposterior positions of the incisors are affected in short-face and long-face individuals. When excessive rotation occurs in the short-face type of development, the incisors tend to be carried into an overlapping position even if they erupt very little. This is why there is a strong tendency for deep bite malocclusion in short-face individuals (Fig. 4.23). The rotation also progressively uprights the incisors, displacing them lingually and causing a tendency toward crowding. In the long-face growth pattern, on the other hand, an anterior open bite will develop as anterior face height increases unless the incisors erupt for an extreme distance. The rotation of the jaws also carries the incisors forward, creating dental protrusion.

This interaction between tooth eruption and jaw rotation explains a number of previously puzzling aspects of tooth positioning in patients who have vertical facial disproportions and is a key to understanding the growth pattern in affected individuals.

## Maturational and Aging Changes

Maturational changes affect both the hard and soft tissues of the face and jaws as slow growth continues in adult life, with changes in jaw relationships and greater long-term changes in the soft tissues. There are important aging effects on the teeth, their supporting structures, and the dental occlusion itself.

## Facial Growth in Adults

Although some anthropologists in the 1930s reported small amounts of growth continuing into middle age, it was generally assumed until the late 20th century that growth of the facial skeleton ceased in the late teens or early 20s. In the early 1980s, Behrents<sup>13</sup> succeeded in recalling over 100 individuals who had participated in the Bolton growth study in Cleveland in the 1930s and late 1940s, more than 40 years previously. Only a few had ever had orthodontic treatment. While they were participants in the study, the growth of these

individuals had been carefully evaluated and recorded, by both measurements and serial cephalometric films. The magnification in the radiographs was known precisely, and it was possible to obtain new radiographs more than four decades later with known magnification, so precise measurements of facial dimensions could be made.

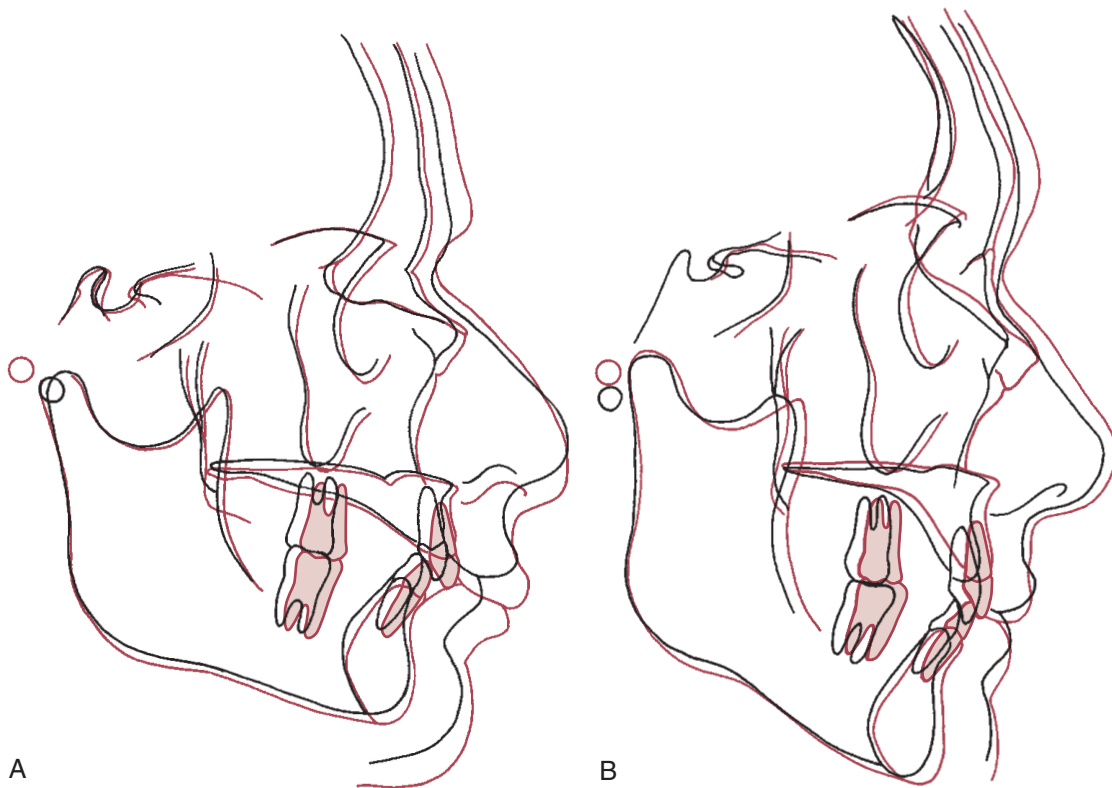
The results were surprising but unequivocal: facial growth had continued during adult life (Fig. 4.24). There was an increase in essentially all the facial dimensions, but both size and shape of the craniofacial complex altered with time. Vertical changes in adult life were more prominent than anteroposterior changes, whereas width changes were least evident, and so the alterations observed in the adult facial skeleton seem to be a continuation of the pattern seen during maturation. In a point of particular interest, an apparent deceleration of growth in females in the late teens was followed by a resumption of growth during the 20s. It appears that a woman's first pregnancy often produces some growth of her jaws. Although the magnitude of the adult growth changes, as assessed in millimeters per year, was quite small, the cumulative effect over decades was surprisingly large (Fig. 4.25).

The data also revealed that rotation of both jaws continued into adult life, in concert with the vertical changes and eruption of teeth. Because implants were not used in these patients, it was not possible to precisely differentiate internal from external rotation, but it seems likely that both internal rotation and surface changes did continue. In general, males showed a net rotation of the jaws

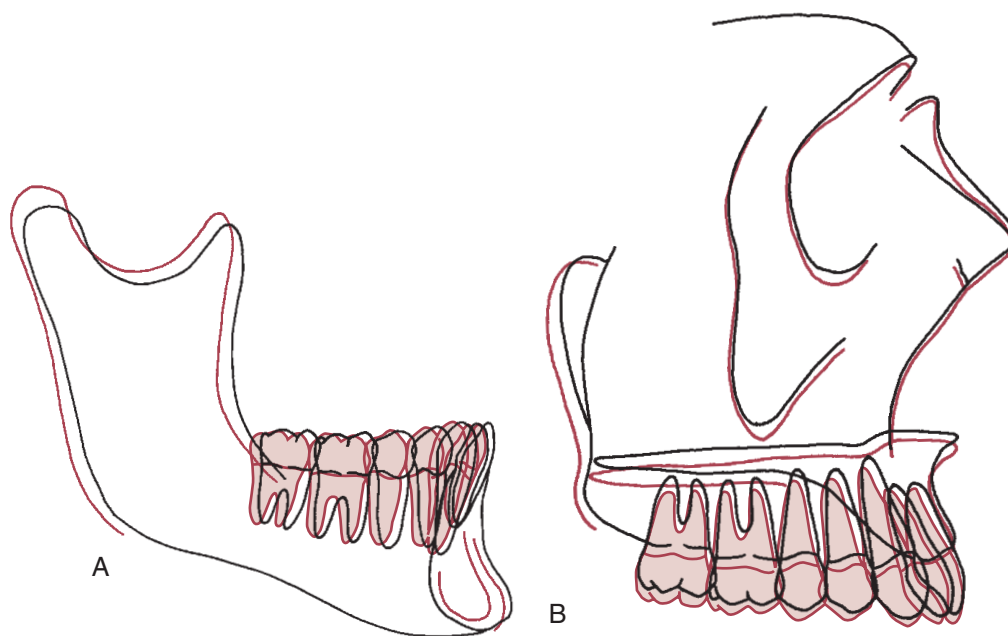
in a forward direction, slightly decreasing the mandibular plane angle, whereas females had a tendency toward backward rotation, with an increase in the mandibular plane angle. In both groups, compensatory changes were noted in the dentition, so occlusal relationships largely were maintained.

Both a history of orthodontic treatment and loss of multiple teeth had an impact on facial morphology in these adults and on the pattern of change. In the smaller group of patients who had undergone orthodontic treatment many years previously, Behrents noted that the pattern of growth associated with the original malocclusion continued to express itself in adult life. This finding is consistent with previous observations of growth in the late teens but also indicates how a gradual worsening of occlusal relationships could occur in some patients long after the completion of orthodontic treatment. It is interesting that in long-face patients who have surgery to decrease face height by moving the maxilla up (see Chapter 20), what looks like a recurrence of the previous growth pattern occurs in some patients long after growth should have stopped.<sup>14</sup>

As expected, changes in the facial soft tissue profile were greater than changes in the facial skeleton. The changes involved an elongation of the nose (which often became significantly longer during adult life), flattening of the lips, and an augmentation of the soft tissue chin. A knowledge of soft tissue changes during aging is important in planning modern orthodontic treatment, and this is discussed further in Chapter 6.



• **Fig. 4.24** Growth changes in adults. (A) Changes in a male from age 37 (black) to age 77 (red). Note that both the maxilla and mandible grew forward, and the nose grew considerably. (B) Growth changes in a woman between age 34 (black) and 83 (red). Note that both jaws grew forward and somewhat downward, and that the nasal structures enlarged. (From Behrents RG. *A Treatise on the Continuum of Growth in the Aging Craniofacial Skeleton*. Ann Arbor, MI: University of Michigan Center for Human Growth and Development; 1984.)



• **Fig. 4.25** Growth changes in adults. (A) Composite mandibular superimposition tracing showing mean dimensional changes in the mandible for males in adult life. It is apparent that the pattern of juvenile and adolescent growth continues at a slower but ultimately significant rate. (B) Composite maxillary superimposition tracing showing the mean positional changes in the maxilla during adult life, for both sexes combined. Note that the maxilla moves forward and slightly downward, continuing the previous pattern of growth. (From Behrents RG. *A Treatise on the Continuum of Growth in the Aging Craniofacial Skeleton*. Ann Arbor, MI: University of Michigan Center for Human Growth and Development; 1984.)

In the light of Behrents's findings, it seems clear that viewing facial growth as a process that ends in the late teens or early 20s is not correct. It is correct, however, to view the growth process as one that declines to a basal level after the attainment of sexual maturity, continues to show a cephalocaudal gradient (i.e., more mandibular than maxillary changes in adult life), and affects the three planes of space differently. Not only is growth in width the first to drop to adult levels, usually reaching essential completion by the onset of puberty, but width changes thereafter are quite low.<sup>15</sup>

Anteroposterior growth continues at a noticeable rate for a longer period, declining to basal levels only after puberty, with small but noticeable changes continuing throughout adult life. Vertical growth, which had previously been observed to continue well after puberty in both males and females, continues at a modest level far into adult life. Although most of the skeletal change occurs between adolescence and mid-adulthood,<sup>16</sup> skeletal growth comes much closer to being a process that continues throughout life than most observers had previously suspected.

### Changes in Facial Soft Tissues

An important concept is that changes in facial soft tissues not only continue with aging, they are much larger in magnitude than changes in the hard tissues of the face and jaws.

The change of greatest significance for orthodontists is that the lips, and the other soft tissues of the face, sag downward with aging. The result is a decrease in exposure of the upper incisors and an increase in exposure of the lower incisors, both at rest

(Fig. 4.26) and on smile (Figs. 4.27 and 4.28). With aging, the lips also become progressively thinner, with less vermilion display (Fig. 4.29). A recent study of individuals followed longitudinally in the Michigan Growth Study revealed that in Americans of European descent, the upper lip lengthened by an average of 3.2 mm and thinned 3.6 mm between adolescence and mid-adulthood. This continued until late adulthood, with a further average mean lengthening and thinning of 1.4 mm.<sup>16</sup>

Because exposure of all the upper incisors and a small amount of gingiva on smile is both youthful appearing and esthetic, it is important to remember in orthodontic treatment that the vertical relationship of the lip to the teeth will change after adolescence. In fact, leaving the upper incisors somewhat more exposed than the ideal adult relationship is necessary in treatment of an adolescent, if this relationship is to be ideal later in life (Fig. 4.30).

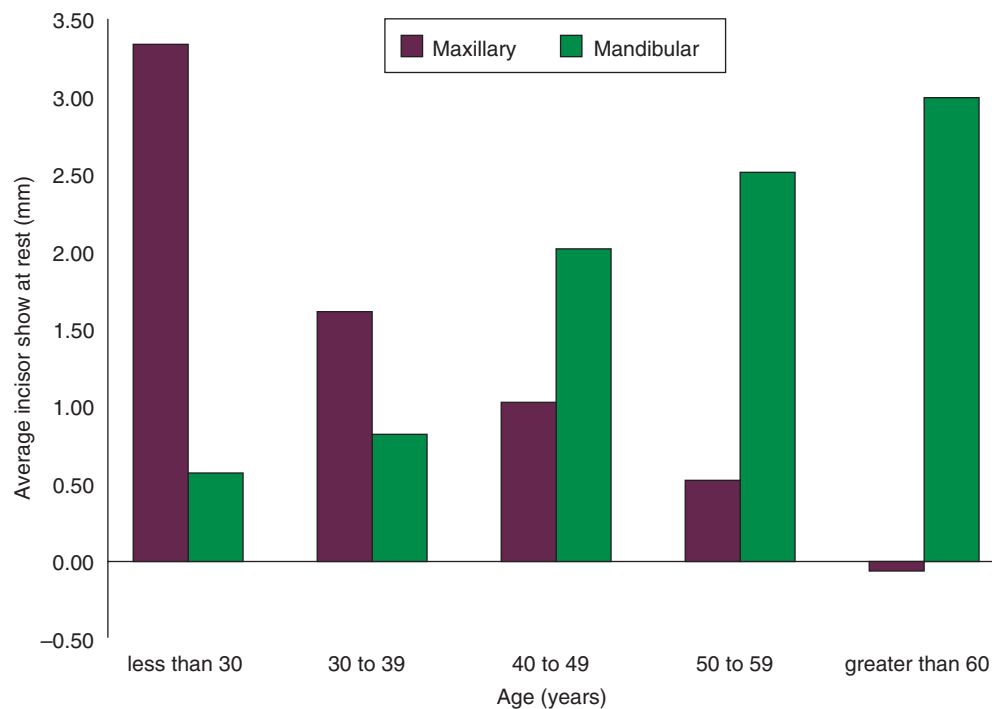
### Changes in Alignment and Occlusion

The alveolar bone bends during heavy mastication, allowing the teeth to move relative to one another (see Chapter 8 for more details). With a coarse diet, not only did occlusal wear reduce the height of the crowns, but also the width of teeth was reduced as interproximal wear occurred. When this type of interproximal wear occurs, spaces do not open up between the posterior teeth, although some spacing may develop anteriorly. Instead, the permanent molars migrate mesially, keeping the contacts reasonably tight even as the contact points are worn off and the mesiodistal width of each tooth decreases. The result in many primitive populations was a reduction





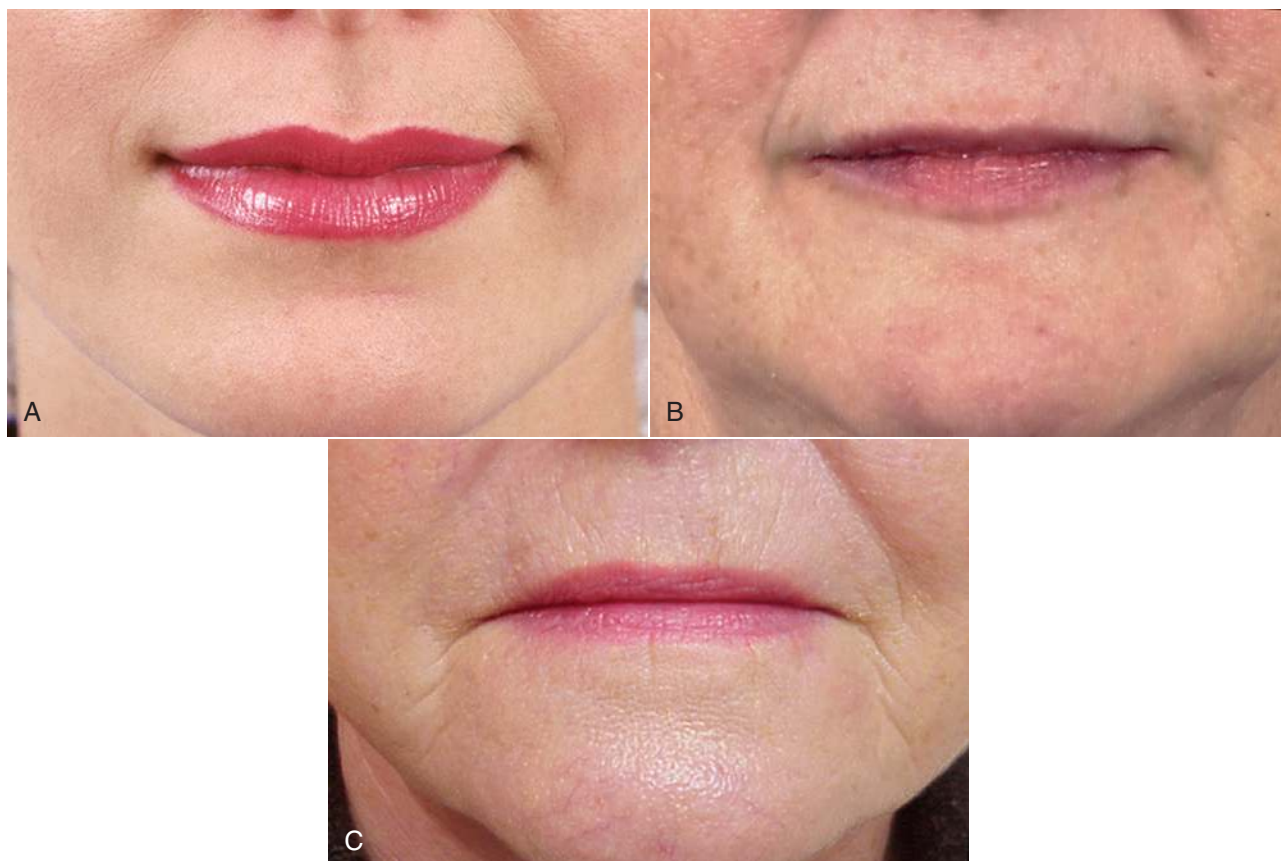• **Fig. 4.26** Maxillary incisor exposure on smile at age 15 (A) and age 25 (B). An important characteristic of facial aging is the downward movement of the lips relative to the teeth, so that the maxillary incisors have progressively decreased exposure over time after adolescent growth is completed. (From Proffit WR, White RP, Sarver DM. *Contemporary Treatment of Dentofacial Deformity*. St. Louis: Mosby; 2003.)




• **Fig. 4.27** Incisor display at rest as a function of age. With aging, both men and women show less of their upper incisors and more of their lower incisors, so display of upper incisors is a youthful characteristic. (Redrawn from Vig RG, Brundo GC. *J Prosthet Dent*. 39:502-504, 1978.)



• **Fig. 4.28** Incisor exposure on smile at the completion of orthodontic treatment at age 30 (A) and 20 years later, at age 50 (B). Note that downward movement of the facial soft tissues continues, so the lower incisors are seen more prominently with increasing age.



• **Fig. 4.29** A decrease in the fullness of the lips is an obvious sign of aging. (A) Age 20. (B) Age 40. (C) Age 70.



• **Fig. 4.30** Because lip height increases and the facial soft tissues move downward relative to the teeth with increasing age, what looks like excessive exposure of teeth and gingiva on smile at age 12 (A) appears to be less excessive at age 14 (B) and has totally disappeared at age 24 (C). The patient received no treatment between ages 12 and 24.

in arch circumference of 10 mm or more after completion of the permanent dentition at adolescence.

In modern populations, there is a strong tendency for crowding of the mandibular incisor teeth to develop in the late teens and early 20s, no matter how well aligned the teeth were initially. Mild crowding of the lower incisors tends to develop if the teeth were initially well aligned, or initially mild crowding becomes worse. These changes appear as early as age 17 to 18 in some individuals and as late as the mid-20s in others. Three major theories to account for this crowding have been proposed.

1. *Lack of “normal attrition” in the modern diet.* As noted in [Chapter 1](#), primitive populations tend to have a much smaller prevalence of malocclusion than contemporary populations in developed countries. If a shortening of arch length and mesial migration of the permanent molars is a natural phenomenon, it would seem reasonable that crowding would develop unless the amount of tooth structure was reduced during the final stages of growth.

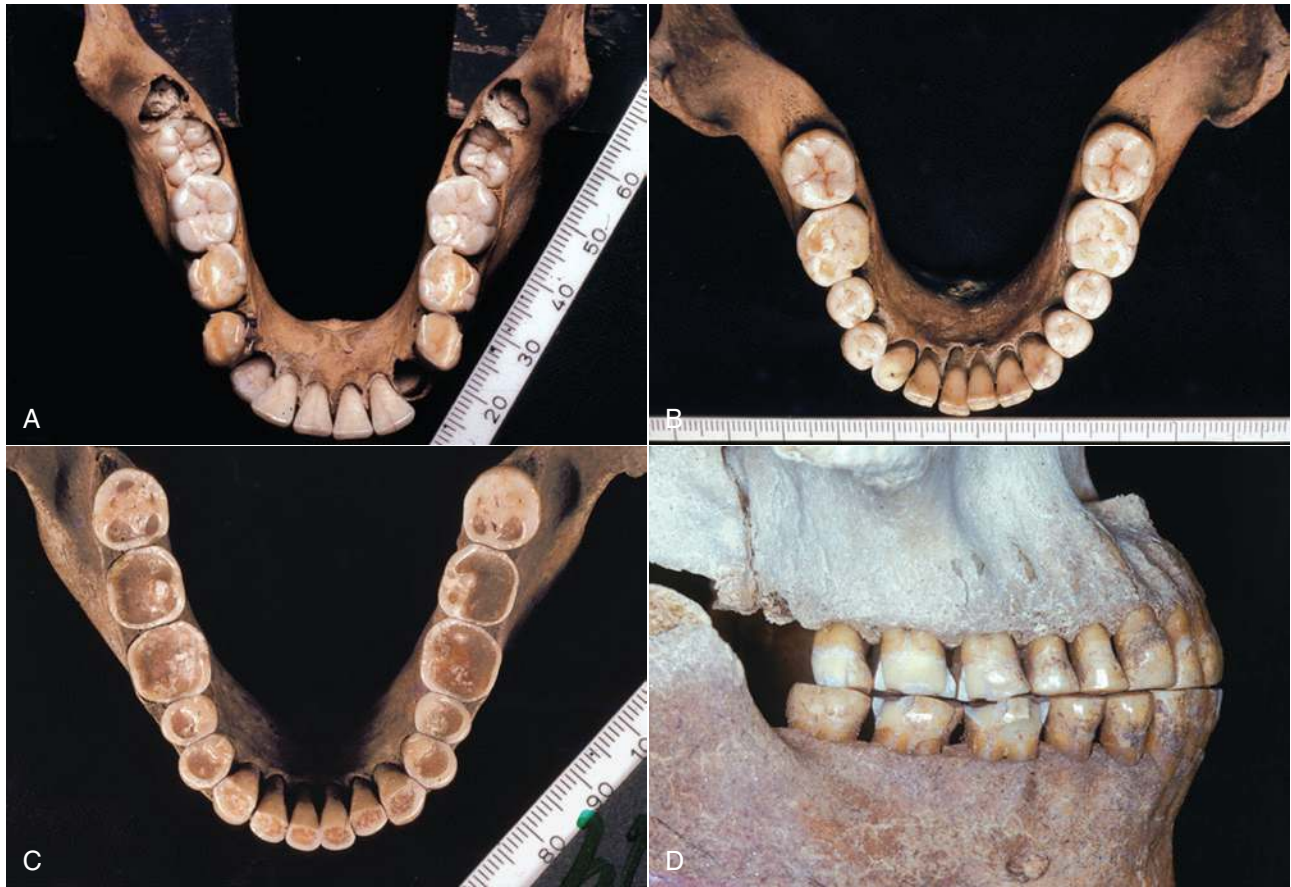Raymond Begg, a pioneer Australian orthodontist, noted in his studies of the Australian aborigines that malocclusion is uncommon but large amounts of interproximal and occlusal attrition occurred ([Fig. 4.31](#)).<sup>17</sup> He concluded that in modern populations the teeth became crowded when attrition did not occur with soft diets, and advocated widespread extraction of premolar teeth to provide the equivalent of the attrition he saw in aborigines. More recent observations have shown that when Australian aborigines change to a modern diet, as they did during the 20th century, occlusal and interproximal wear all but disappears. Nevertheless, late crowding rarely develops,<sup>18</sup> although periodontal disease does become a major problem. It has been observed in other population groups that late crowding may develop even after premolars have been extracted and arch

length has been reduced by modern orthodontic treatment. Thus the Begg theory, although superficially attractive, does not explain late crowding.<sup>19</sup>

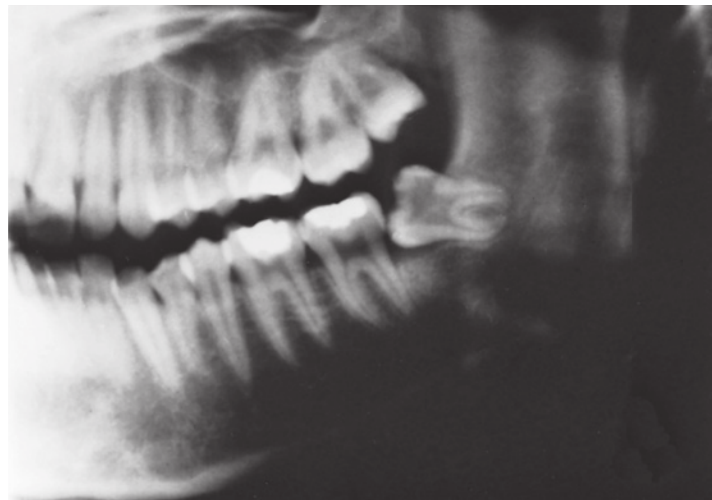2. *Pressure from third molars.* Late crowding develops at about the time the third molars should erupt. In most individuals, these teeth are hopelessly impacted because the jaw length did not increase enough to accommodate them via backward modeling of the ramus ([Fig. 4.32](#)). It has seemed entirely logical to dentists and patients that pressure from third molars with no room to erupt is the cause of late incisor crowding. It is difficult to detect such a force, however, even with modern instrumentation that should have found it if it exists.<sup>20</sup> In fact, late crowding of lower incisors can and often does develop in individuals whose lower third molars are congenitally missing. There is some evidence that incisor crowding may be lessened by early removal of second molars, which presumably would relieve pressure from third molars, but pressure from third molars clearly is not the total explanation either.<sup>21</sup>
3. *Late mandibular growth.* Because of the cephalocaudal gradient of growth discussed in [Chapter 2](#), the mandible can and does grow more in the late teens than the maxilla. Is it possible that late mandibular growth somehow causes late mandibular incisor crowding? If so, how? Björk’s implant studies have provided an understanding of why late crowding occurs and how it indeed relates to the growth pattern of the jaw.

The position of the dentition relative to the maxilla and mandible is influenced by the pattern of growth of the jaws, a concept explored in some detail in previous sections. When the mandible grows forward relative to the maxilla, as it usually does in the late teens, the mandibular incisor teeth tend to be displaced lingually, particularly if forward rotation is also present (as it would be in short-face individuals). This can be seen most



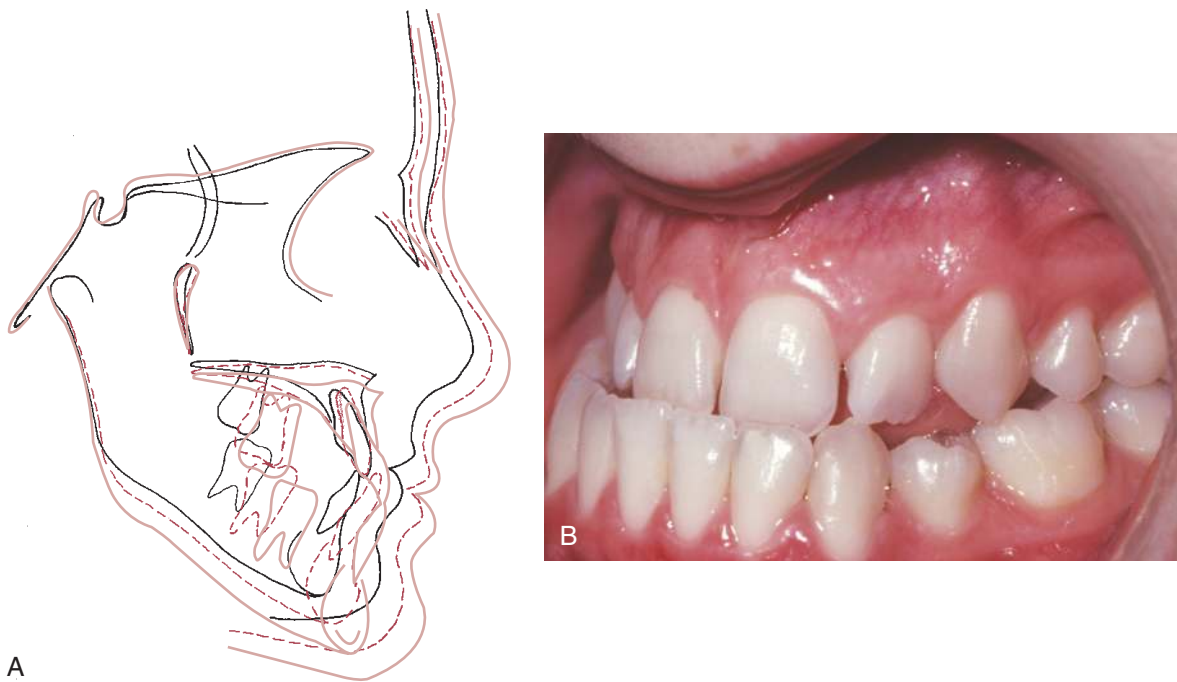


• **Fig. 4.31** Australian aboriginal mandibles of a child approximately at dental age 8 (A), an adolescent at approximately dental age 14 (B), and an adult of indeterminate age ([C] and [D]). Note the increasing attrition of the teeth in the younger specimens and the severe attrition of the adult's teeth, with interproximal, as well as occlusal, wear. Arch length in this population shortened by 1 cm or more after adolescence because of the extensive interproximal wear. (Specimens from the Begg Collection, University of Adelaide, Adelaide, Australia; courtesy Professor W. Sampson.)



• **Fig. 4.32** It seems reasonable that a horizontally impacted third molar would provide pressure against the dental arch, but it is highly unlikely that there is enough pressure from this source to cause the crowding of mandibular incisors that often develops in the late teens.





• **Fig. 4.33** In this patient with a prolonged pattern of excessive mandibular growth (A), the lower incisors were increasingly tipped lingually as the mandible grew forward and were noticeably retroclined (B) by the end of adolescent growth. This is a more obvious demonstration of what often happens under normal circumstances, when a small amount of late mandibular growth occurs in the late teens after maxillary growth stops. Late mandibular growth is a major cause of the mandibular incisor crowding that frequently develops at that time.

clearly when the mandibular growth is excessive (Fig. 4.33), but a milder version of the same uprighting occurs in almost everyone.

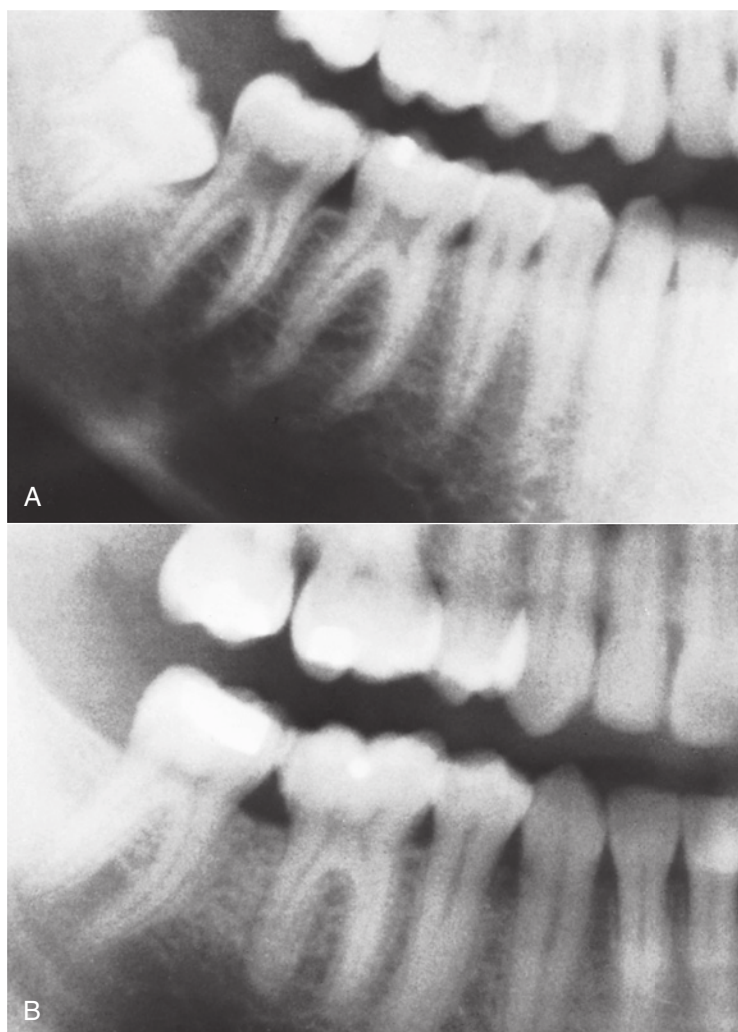
In patients with a tight anterior occlusion before late mandibular growth occurs, the contact relationship of the lower incisors with the upper incisors must change if the mandible grows forward. In that circumstance, one of three things must happen: (1) The mandible is displaced distally, accompanied by a distortion of TMJ function and displacement of the articular disc; (2) the upper incisors flare forward, opening space between these teeth; or (3) the lower incisors displace distally and become crowded.

All three of these phenomena have been reported. The second response, flaring and spacing of the maxillary incisors, is rarely seen. Posterior displacement of a “trapped mandible” can happen and may occasionally be related to myofascial pain and dysfunction, but despite the claims of some occlusion theorists, this too seems to be quite rare. Distal displacement of the lower incisors, with concomitant crowding and a decrease in the lower intercanine distance, is the usual response. It is not even necessary for the incisors to be in occlusal contact for late crowding to develop. This also occurs commonly in individuals who have an anterior open bite and backward, not forward, rotation of the mandible (see Fig. 4.19). In this situation, the rotation of the mandible carries the dentition forward, thrusting the incisors against the lip. This creates light but lasting pressure by the lip, which tends to reposition the protruding incisors somewhat lingually, reducing arch length and causing crowding.

The current concept is that late incisor crowding almost always develops as the mandibular incisors (and perhaps the entire mandibular dentition) move distally relative to the body of the mandible late in mandibular growth. This sheds some light on the possible role of the third molars in determining whether crowding will occur and how severe it will be. If space were available at the distal end of the mandibular arch, it might be possible for all the mandibular teeth to shift slightly distally, allowing the lower incisors to upright without becoming crowded. But impacted third molars at the distal end of the lower arch would prevent the posterior teeth from shifting distally, and if differential mandibular growth occurred, their presence might guarantee that crowding would develop. In this case, the lower third molars could be the “last straw” in a chain of events that led to late incisor crowding. As noted previously, however, late incisor crowding occurs in individuals with no third molars at all, so the presence of these teeth is not the critical variable. Instead, the extent of late mandibular growth is. The more your mandible grows after other growth has essentially stopped, the greater the chance your lower incisors will become crowded, and this is true in both those who have undergone orthodontic treatment and those who have not.<sup>22</sup>

### Aging Changes in Teeth and Supporting Structures

At the time a permanent tooth erupts, the pulp chamber is relatively large. As time passes, additional dentin slowly deposits on the inside of the tooth so that the pulp chamber gradually becomes



• **Fig. 4.34** The size of the pulp chambers of permanent teeth decreases during adolescence, then continues to fill in more slowly for the rest of adult life. (A) Age 16. (B) Age 26.

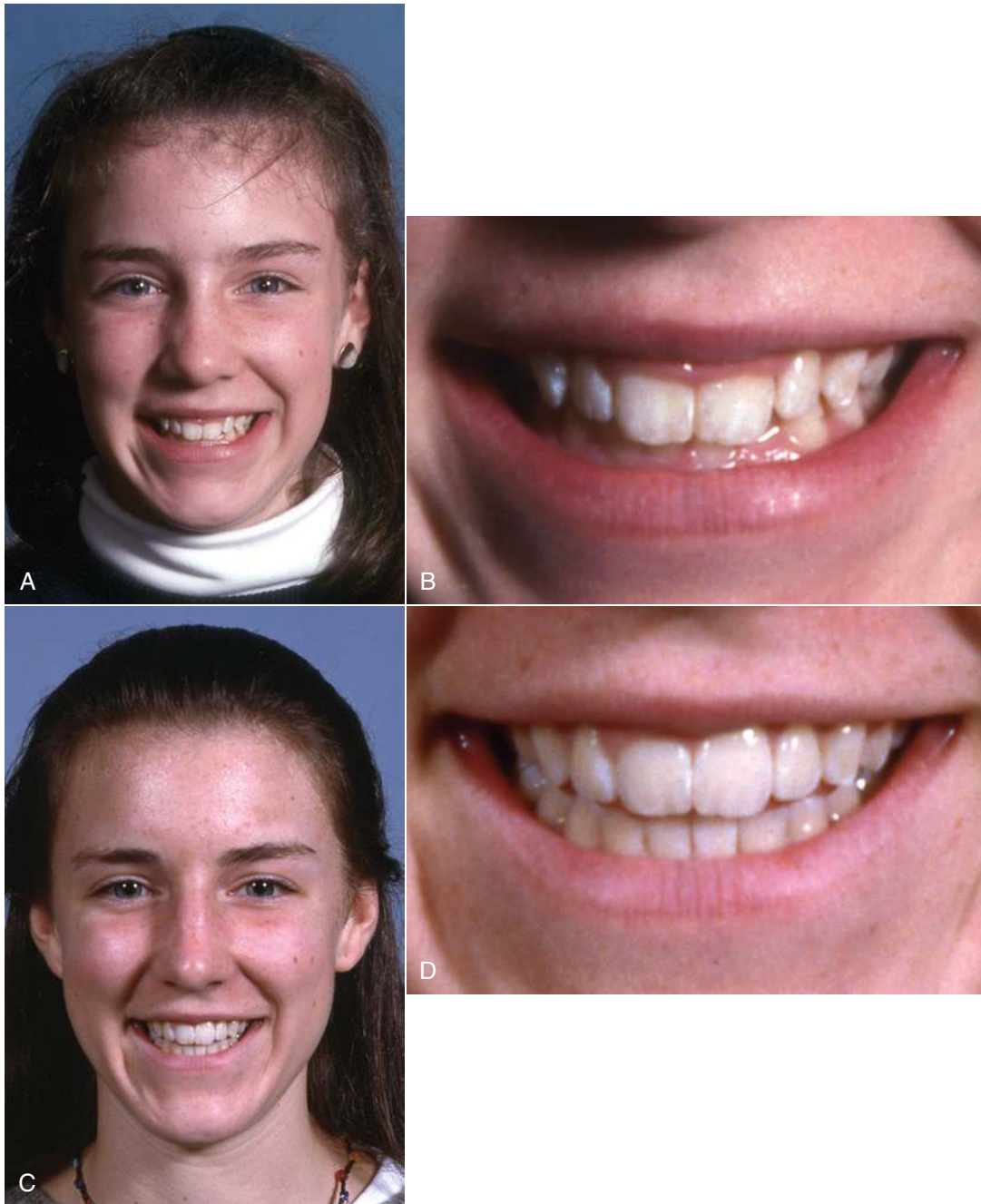smaller with increasing age (Fig. 4.34). This process continues relatively rapidly until the late teens, at which time the pulp chamber of a typical permanent tooth is about half the size that it was at the time of initial eruption. Because of the relatively large pulp chambers of young permanent teeth, complex restorative procedures are more likely to result in mechanical exposures in adolescents than in adults. Additional dentin continues to be produced at a slower rate throughout life, so in old age the pulp chambers of some permanent teeth are all but obliterated.

Maturation also brings about greater exposure of the tooth outside its investing soft tissues. At the time a permanent first molar erupts, the gingival attachment is high on the crown. Typically, the gingival attachment is still well above the cemento-enamel junction when any permanent tooth comes into full occlusion, and during the next few years more and more of the crown is exposed. This relative apical movement of the attachment (in normal circumstances) results more from vertical growth of the jaws and the accompanying eruption of the teeth than from downward migration of the gingival attachment. As we have noted previously, vertical growth of the jaws and an increase in face height continue after transverse and anteroposterior growth have been completed.

By the time the jaws all but stop growing vertically in the late teens, the gingival attachment is usually near the cemento-enamel junction. In the absence of inflammation, mechanical abrasion or pathologic changes, the gingival attachment should remain at about the same level almost indefinitely. In fact, however, many individuals experience some pathology of the gingiva or periodontium as they age, and so further recession of the gingiva is common.

At one time, it was thought that “passive eruption” (defined as an actual gingival migration of the attachment without any eruption of the tooth) occurred. It now appears that as long as the gingival tissues are entirely healthy, this sort of downward migration of the soft tissue attachment does not occur. What was once thought to be apical migration of the gingiva during the teens is really active eruption, compensating for the vertical jaw growth still occurring at that time (Fig. 4.35).

Both occlusal and interproximal wear, often to a severe degree, occurred in primitive people eating an extremely coarse diet. The elimination of most coarse particles from modern diets has also largely eliminated wear of this type. With few exceptions (tobacco chewing is one), wear facets on the teeth now indicate bruxism, not what the individual has been eating.



• **Fig. 4.35** The increasing crown height of permanent teeth during adolescence was once thought to result from a downward migration of the gingival attachment but now is recognized to occur mostly from tooth eruption in response to vertical growth. (A) and (B) Age 10. (C) and (D) Age 16.

## References

1. Lomniczi A, Ojeda SR. The emerging role of epigenetics in the regulation of female puberty. In: Bourguignon JP, Parent AS, Mullis PE, eds. *Puberty from Bench to Clinic: Lessons for Clinical Management of Pubertal Disorders*. Basel, Switzerland: S Karger AG; 2015.
2. Anderson DL, Thompson GW, Popovich F. Interrelationship of dental maturity, skeletal maturity, height and weight from age 4 to 14 years. *Growth*. 1975;39:453–462.
3. Agronin KJ, Kokich VG. Displacement of the glenoid fossa: a cephalometric evaluation of growth during treatment. *Am J Orthod Dentofac Orthop*. 1987;91:42–48.
4. Bishara SE, Jakobsen JR, Treder J, et al. Arch width changes from 6 weeks to 45 years of age. *Am J Orthod Dentofac Orthop*. 1997;111:401–409.
5. Solow B, Iseri H. Maxillary growth revisited: an update based on recent implant studies. In: Davidovitch Z, Norton LA, eds. *Biological Mechanisms of Tooth Movement and Craniofacial Adaptation*. Boston: Harvard Society for Advancement of Orthodontics; 1996.
6. Björk A. The use of metallic implants in the study of facial growth in children: method and application. *Am J Phys Anthropol*. 1968;29:243–254.
7. Solow B, Houston WJ. Mandibular rotations: concept and terminology. *Eur J Orthod*. 1988;10:177–179.

8. Björk A, Skieller V. Normal and abnormal growth of the mandible: a synthesis of longitudinal cephalometric implant studies over a period of 25 years. *Eur J Orthod*. 1983;5:1–46.
9. Ruellas A, Devito K, Visconti M, et al. 3D mandibular superimposition: comparison of regions of reference for voxel-based registration. *PLoS ONE*. 2016;11(6):e0157625.
10. Björk A, Skieller V. Postnatal growth and development of the maxillary complex. In: McNamara JA, ed. *Factors Affecting Growth of the Midface*. Ann Arbor, MI: University of Michigan Center for Human Growth and Development; 1976.
11. Houston WJ. Mandibular growth rotations—their mechanisms and importance. *Eur J Orthod*. 1988;110:369–373.
12. Björk A, Skieller V. Contrasting mandibular growth and facial development in long face syndrome, juvenile rheumatoid arthritis and mandibulofacial dysostosis. *J Craniofac Genet Dev Biol*. 1985;1(suppl):127–138.
13. Behrents RG. *A Treatise on the Continuum of Growth in the Aging Craniofacial Skeleton*. Ann Arbor, MI: University of Michigan Center for Human Growth and Development; 1984.
14. Proffit WR, Phillips C, Turvey TA. Stability following superior repositioning of the maxilla. *Am J Orthod*. 1987;92:151–163.
15. Harris EF. A longitudinal study of arch size and form in untreated adults. *Am J Orthod Dentofac Orthop*. 1997;111:419–427.
16. Pecora NG, Beccetti T, McNamara JA Jr. The aging craniofacial complex: a longitudinal cephalometric study from late adolescence to late adulthood. *Am J Orthod Dentofac Orthop*. 2008;134:496–506.
17. Begg PR. Stone age man's dentition. *Am J Orthod*. 1954;40:298–312, 373–383, 462–475, 517–531.
18. Brown T, Townsend GC, Pinkerton SK, Rogers JR. *Teeth, Time and the Tanami: Dental Research at Yuendumu, Central Australia*. Univ. of Adelaide Press, 2011.
19. Corruccini RS. Australian aboriginal tooth succession, interproximal attrition and Begg's theory. *Am J Orthod Dentofac Orthop*. 1990;97:349–357.
20. Southard TE, Southard KA, Weeda LW. Mesial force from unerupted third molars. *Am J Orthod Dentofac Orthop*. 1991;99:220–225.
21. Richardson ME. Late lower arch crowding: the aetiology reviewed. *Dent Update*. 2002;29:234–238.
22. Jonsson T, Magnusson TE. Crowding and spacing in the dental arches: long-term development in treated and untreated subjects. *Am J Orthod Dentofac Orthop*. 2010;138:384.e1–384.e7, discussion 384–386.



# 5

## The Etiology of Orthodontic Problems

### CHAPTER OUTLINE

#### Specific Causes of Malocclusion

- Disturbances in Embryologic Development
- Growth Disturbances in the Fetal and Perinatal Period
- Progressive Deformities in Childhood
- Disturbances Arising in Adolescence or Early Adult Life
- Disturbances of Dental Development

#### Genetic Influences

#### Environmental Influences

- Equilibrium Considerations
- Masticatory Function
- Sucking and Other Habits
- Tongue Thrusting
- Respiratory Pattern

#### Etiology in Contemporary Perspective

Malocclusion is a developmental condition. In most instances, malocclusion and dentofacial abnormalities are caused not by some pathologic process, but by moderate (occasionally severe) distortions of normal development. Regarding various types of abnormalities, dysmorphologists (who study the developmental processes that lead to abnormal versus normal development) use the word *deformity* to describe a tissue that initially formed normally and then failed to continue normal development. The term *malformation* describes tissues that did not form normally from the beginning. Occasionally, a specific cause of a dentofacial problem is apparent—for example, in mandibular deficiency secondary to a childhood fracture of the jaw, which would be a deformity, or the characteristic malocclusion that accompanies some genetic syndromes, which with rare exceptions would be a malformation. These problems most often result from a complex interaction among multiple factors that influence growth and development, and it is impossible to describe a specific etiologic factor (Fig. 5.1).

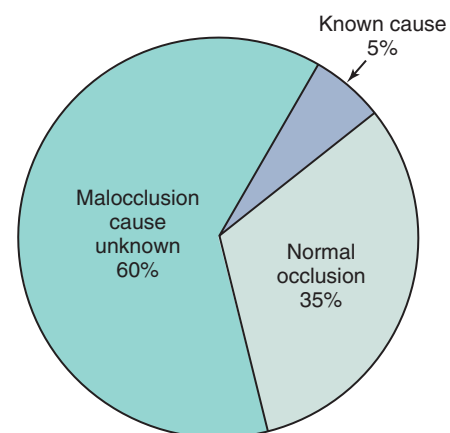
Although it is difficult to know the precise cause of most malocclusions, we do know in general what the possibilities are, and these must be considered when orthodontic problems are being evaluated. In this chapter we examine etiologic factors for malocclusion under three major headings: specific causes, hereditary influences, and environmental influences. The chapter concludes with a perspective on the interaction of hereditary and environmental influences in the development of the major types of malocclusion.

### Specific Causes of Malocclusion

#### Disturbances in Embryologic Development

Defects in embryologic development usually result in death of the embryo. As many as 20% of early pregnancies terminate because of lethal embryologic defects, often so early that the mother is not even aware of conception. Although most defects in embryos are of genetic origin, effects from the environment also are important. Chemical and other agents capable of producing embryologic defects if given at the critical time are called *teratogens*. Most drugs do not either interfere with normal development or, at high doses, kill the embryo without producing defects, and therefore are not teratogenic. Teratogens typically cause specific defects if present at low levels but, if given in higher doses, do have lethal effects. Teratogens known to produce orthodontic problems are listed in Table 5.1, with Zika virus (which causes microcephaly) being the most recent addition.

Fig. 5.2 provides an overview of a succession of stages in human embryonic development as it occurs during weeks 3 to 8 after fertilization. Over this short period, morphologic characteristics change from a disklike shape of approximately 0.5 mm in diameter (Fig. 5.2A) to an approximately 25-mm-long (crown to rump), distinctly human form (Fig. 5.2L). This change in form is characterized by formation of the neural plate (developing central nervous system), elevation of its lateral margins to form the neural tube, and subsequent neural tube closure, which occurs in the fourth week of embryonic development. Neural tube formation and



• **Fig. 5.1** From a broad perspective, only about one-third of the U.S. population has normal occlusion, whereas two-thirds have some degree of malocclusion. In the malocclusion group, only a small minority (not more than 5%) have problems attributable to a specific known cause; the remainder are the result of a complex and poorly understood combination of inherited and environmental influences.

**TABLE 5.1** Teratogens Affecting Dentofacial Development

Teratogens	Effect
Aminopterin	Anencephaly
Aspirin	Cleft lip and palate
Cigarette smoke (hypoxia)	Cleft lip and palate
Cytomegalovirus	Microcephaly, hydrocephaly, microphthalmia
Dilantin	Cleft lip and palate
Ethyl alcohol	Central midface deficiency
6-Mercaptopurine	Cleft palate
13- <i>cis</i> Retinoic acid (Accutane)	Similar to craniofacial microsomia and Treacher Collins syndrome
Rubella virus	Microphthalmia, cataracts, deafness
Thalidomide	Malformations similar to craniofacial microsomia, Treacher Collins syndrome
<i>Toxoplasma</i>	Microcephaly, hydrocephaly, microphthalmia
X-radiation	Microcephaly
Valium	Similar to craniofacial microsomia and Treacher Collins syndrome
Vitamin D excess	Premature suture closure
Zika virus	Microcephaly, brain damage

closure are accompanied by ventral and lateral folding (differential growth) that results in formation of the foregut (Fig. 5.2D); lengthening and bending of the heart tube (heart development); the appearance of the primitive oral cavity (stomodeum); and formation of the tissues that will contribute to the jaws (maxillary prominence and first arch), nose, and ears. For more detailed description of normal craniofacial embryogenesis, the reader is referred to embryology texts and websites, especially [https://embryology.med.unsw.edu.au/embryology/index.php/Main\\_Page](https://embryology.med.unsw.edu.au/embryology/index.php/Main_Page) (click on “embryologic development”), which includes scanning electron microscope (SEM) images from the K. Sulik collection that appear in this chapter.

Genetic and environmental insults (in this context, *insult* means anything that could have an adverse impact on normal development) can affect the developing face and jaws throughout the embryonic period. It usually is the case that an insult affected growth well before a specific abnormality occurred. With the help of information gained from the study of experimental animals, some abnormalities can be traced to effects that occur during narrow time windows. An example of a phenotype that arises in the third week of development is the characteristic facies of fetal alcohol syndrome (FAS; Fig. 5.3). This is due to deficiencies of midline tissue of the developing brain (neural plate) and is typically caused by exposure to very high maternal ethanol levels. Although such blood levels can be reached only in extreme intoxication in chronic alcoholics, the resulting facial deformity and developmental delay occur frequently enough to be implicated in many cases of midface

deficiency.<sup>1</sup> In these unfortunate children, the delay in dental development matches the skeletal delay.<sup>2</sup>

Many craniofacial defects are related to neural crest cell abnormalities, including cell death and migration errors. Neural crest cell migration away from the cranial neural folds occurs in the latter part of the third and the early part of the fourth week (Fig. 5.4), and this is a time of particular vulnerability to teratogens. Neural crest cells make up practically all of the mesenchyme (loose connective tissue) of the face and differentiate into much of its skeletal and connective tissue, including the bones of the jaw and the teeth.

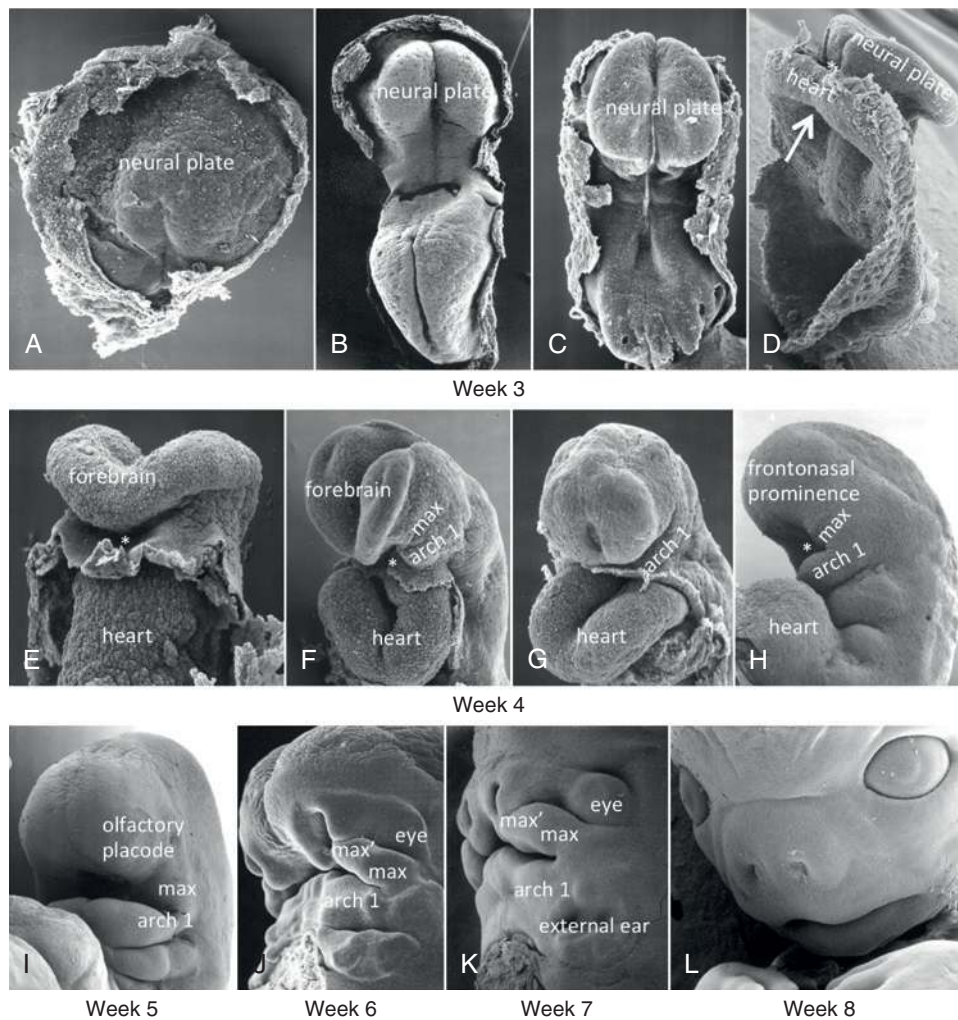
The importance of neural crest cell populations and the possibility of drug-induced cell death and/or impairment of their migration have been demonstrated clearly by unfortunate experience. In the 1960s and 1970s, exposure to thalidomide caused major congenital defects, including facial anomalies in thousands of children. In the 1980s, severe facial malformations related to the anti-acne drug isotretinoin (Accutane) were reported. The similarities in the defects make it likely that both drugs adversely affect neural crest cells. Importantly, the time of insult associated with these defects is before the mother knows she is pregnant. From 2010 to the present, Zika virus has caused thousands of cases of microcephaly due to impaired development of the brain. Exposure to Zika virus at any stage of pregnancy, not just during embryogenesis, may impair brain development. The diminished brain growth leads to both microcephaly and severe neurologic deficits.

In addition to drug-induced neural crest defects, genetic alterations also can adversely affect this cell population and produce craniofacial abnormalities. An example is Treacher Collins syndrome (Fig. 5.5), which is characterized by reduced levels of mesenchymal tissue, especially in the lateral aspects of the face. Treacher Collins syndrome now is known to be due to mutations in the *TCOF1* gene.<sup>3</sup> Malformations very similar to this syndrome may result from teratogenic effects on embryos at stages present in the fourth week.<sup>4</sup>

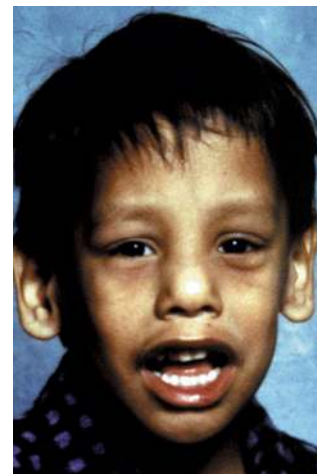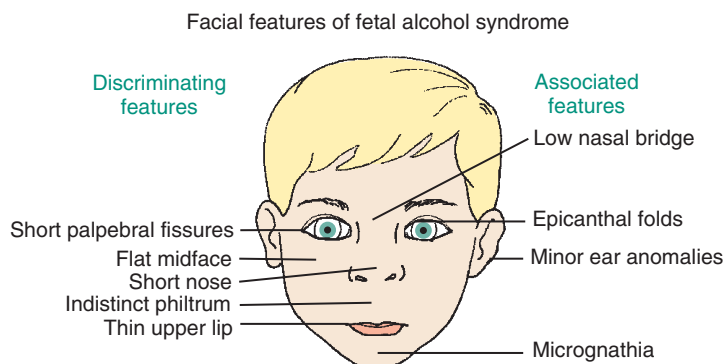
Craniofacial microsomia (often called *hemifacial microsomia*) also is characterized by deficient development in lateral facial areas. Typically, the external ear is deformed and both the ramus of the mandible and associated soft tissues (muscle, fascia) are deficient or missing (Fig. 5.6). Facial asymmetry is always seen (thus the common name), and cranial as well as facial structures are affected. The genesis of craniofacial microsomia has been extensively studied, and model systems indicate that the major cause is insult to cell populations (including but not limited to neural crest cells) that are required for proper development of the first pharyngeal (mandibular) arch.<sup>5</sup>

In addition to their importance for development of the face, neural crest cells migrate through the lower (pharyngeal) arches and play a major role in formation of the heart and great vessels. This is the basis for the common co-occurrence of craniofacial abnormalities and heart defects such as tetralogy of Fallot.

The most common congenital defects involving the face and jaws, second only to clubfoot in the entire spectrum of congenital deformities, are clefts of the lip and/or secondary palate. For dentists and orthodontists, understanding how they arise is important because children with a cleft lip and most of those with a cleft palate (a cleft of only the most posterior aspect of the hard palate and soft palate is the exception) will require extensive dental and orthodontic treatment. Fig. 5.7 shows the closure of the palate in mouse embryos (which are very similar to humans at that stage of development) from a frontal view, but understanding how this is accomplished in humans requires an appreciation

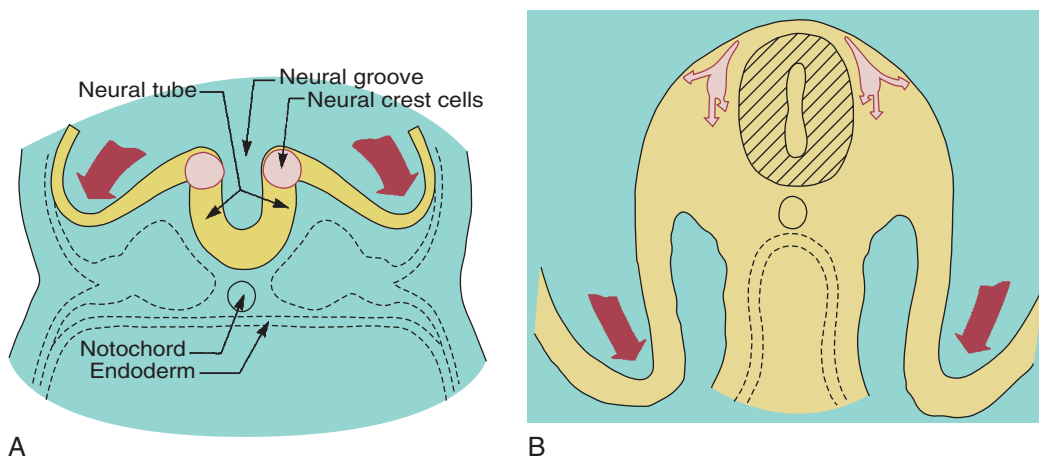


• **Fig. 5.2** This sequence of scanning electron micrographs illustrates a succession of stages of human embryonic development that occur during the third to eighth weeks after fertilization. Views shown in A to C are of the dorsal side of the embryos; D to L are ventrolateral views. Approximate postfertilization ages for each of the embryos are as follows: 17 days (A); 19 days (B); 21 days (C); 21 days (D); 23 days (E); 24 days (F); 25 days (G); 26 days (H); 32 days (I); 41 days (J); 43 days (K); 52 days (L). Notable from the earliest stage shown is the neural plate, which by the end of the fourth week has become the closed neural tube, the most rostral part of which becomes the forebrain. Tissue surrounding the forebrain of a late fourth-week and fifth-week embryo is termed the *frontonasal prominence* (growth center). This structure, along with the first pharyngeal arch and maxillary prominence (*max*, including its most medial and rostral component, *max'*), form the perimeter of the developing oral cavity (\*, stomodeum). Distinction among many of the individual facial prominences (growth centers) becomes less apparent with time, and by the end of the embryonic period, the face appears distinctly human. The arrow in D indicates the foregut. (A to I, K, and L, courtesy Dr. K. Sulik. J reprinted from Hinrichsen K. *Adv Anat Embryol Cell Biol.* 1985;98:1-79.)

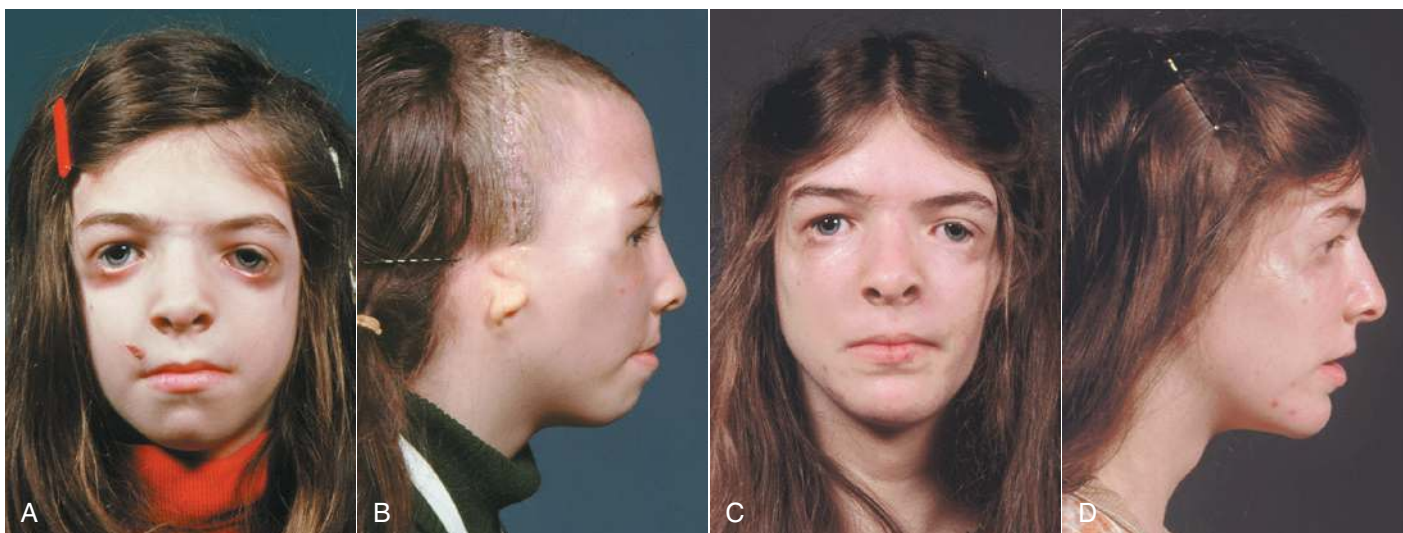

• **Fig. 5.3** The characteristic facial appearance of fetal alcohol syndrome (FAS), caused by exposure to very high blood alcohol levels during the first trimester of pregnancy.





• **Fig. 5.4** Diagrammatic lateral sections of embryos at 20 and 24 days, showing formation of the neural folds, neural groove, and neural crest. (A) At 20 days, neural crest cells (pink) can be identified at the lips of the deepening neural groove, forerunner of the central nervous system. (B) At 24 days, the neural crest cells have separated from the neural tube and are beginning their extensive migration beneath the surface ectoderm. The migration is so extensive and the role of these neural crest cells is so important in formation of structures of the head and face that they can almost be considered a fourth primary germ layer. Later stages in the migration can be seen in Fig. 5.2F–H.



• **Fig. 5.5** In the Treacher Collins syndrome (also called *mandibulofacial dysostosis*), a generalized lack of mesenchymal tissue in the lateral part of the face is the major cause of the characteristic facial appearance. Note the underdevelopment of the lateral orbital and zygomatic areas. The ears also may be affected. Patient at age 12 before (A) and immediately after (B) surgical treatment to advance the midface. Note this patient's ear deformity, which usually is concealed by hair. (C and D) Age 16. Note the change in the lateral orbital margins.

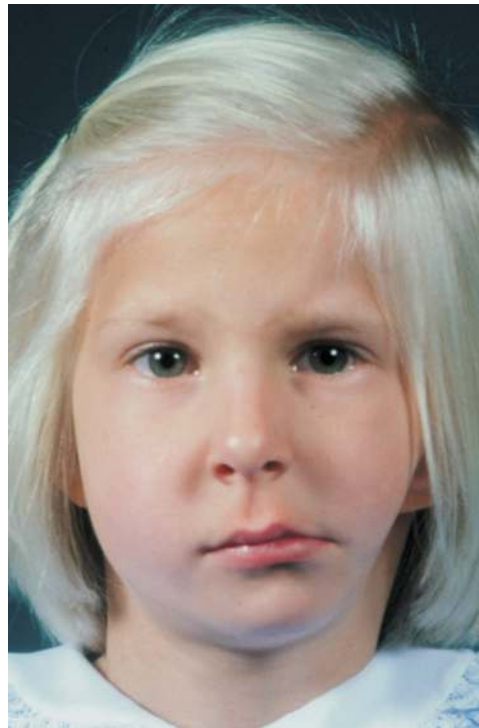of normal facial morphogenesis as it occurs before lip and palate closure.

As illustrated in Fig. 5.2 (bottom row of images) and Fig. 5.8, both of which show the developing human face between the end of the fourth week and the end of embryogenesis (eighth week), facial form changes are particularly dramatic over this approximately 1-month period. Around the forming olfactory placodes, which will become the special sensory epithelium inside the nose, elevations termed the *lateral* and *medial nasal prominences* develop (Fig. 5.8A). A portion of the medial prominence that is in closest proximity

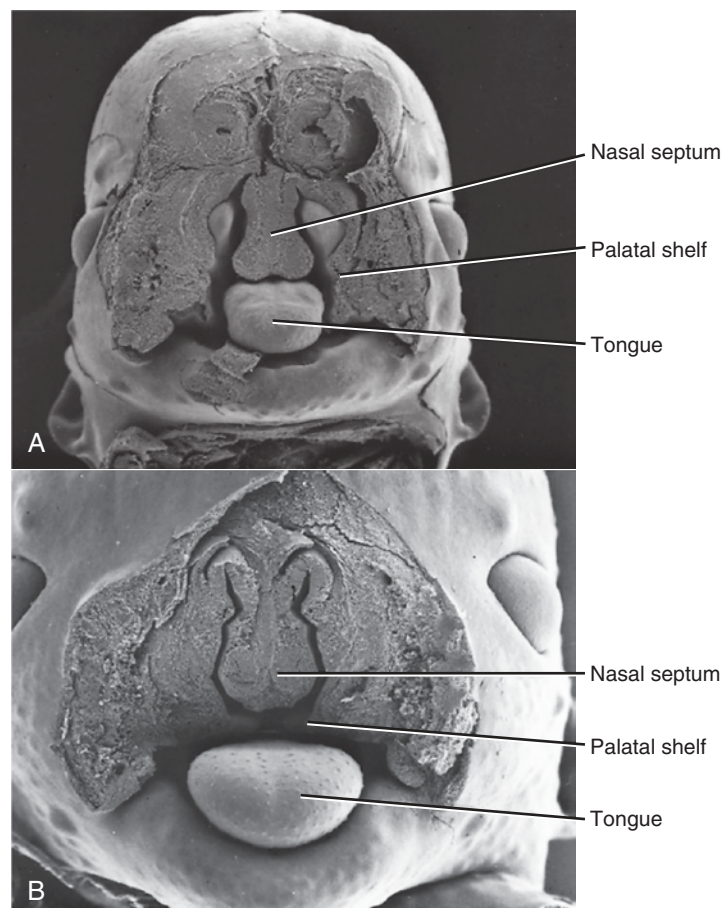
to the developing oral cavity (stomodeum) is termed the *premaxillary segment* (Fig. 5.8B). Two other structures also contribute to the margin of the stomodeum: (1) the most medial part of the maxillary prominence, which is termed *maxillary'* and is notable in Fig. 5.8B as a distinct bilateral bulge adjacent to the lateral nasal prominences and premaxillary growth centers and (2) the mandibular prominence, which makes up the majority of the first pharyngeal arch.

Union of the lateral nasal prominence and maxillary' with the premaxillary segment (Fig. 5.8C) is required for normal lip and primary palate closure. The premaxillary segment gives rise to the

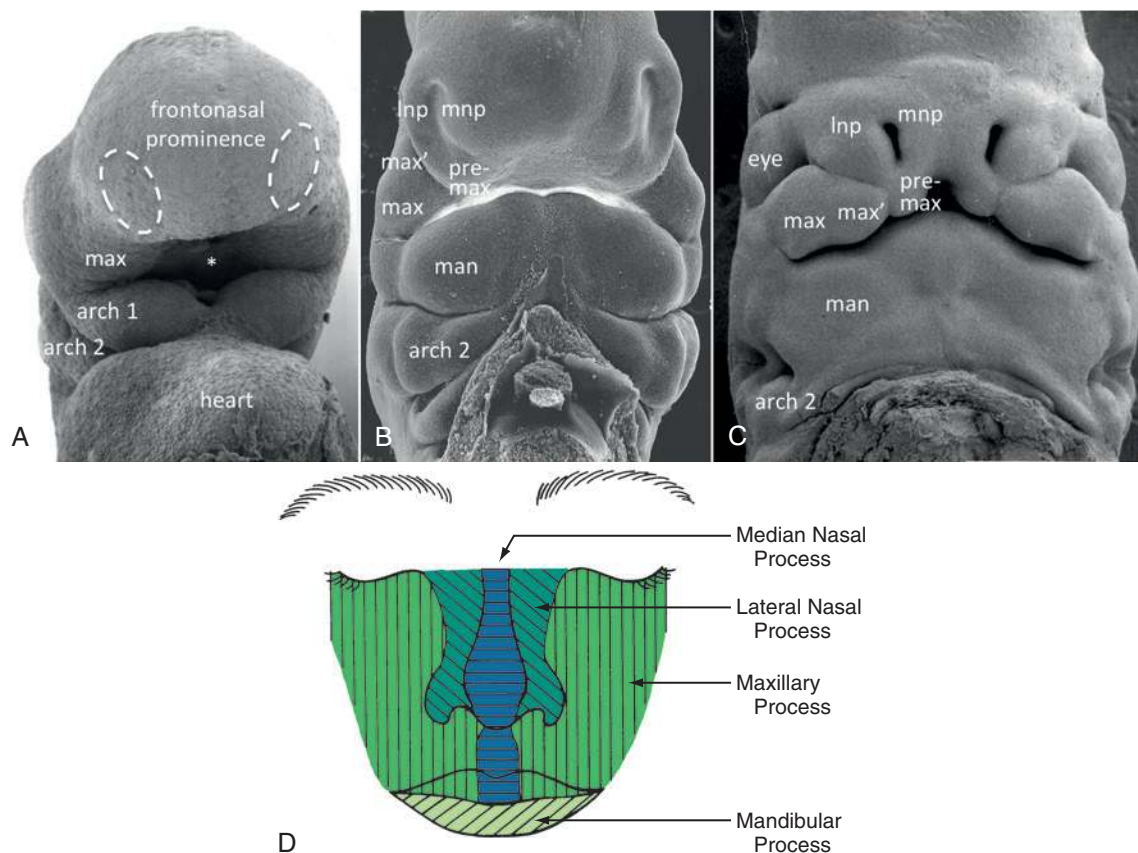




• **Fig. 5.6** In craniofacial microsomia, both the external ear and the mandibular ramus are deficient or absent on the affected side. In this patient with a relatively mild problem, note the use of the hairstyle to conceal the ear and short ramus on the affected side. (From Proffit WR, White RP, Sarver DM. *Contemporary Treatment of Dentofacial Deformity*. St. Louis: Mosby; 2003.)



• **Fig. 5.7** Scanning electron micrographs of mouse sectioned in the frontal plane. (A) Before elevation of the palatal shelves. (B) Immediately after depression of the tongue and elevation of the shelves.



• **Fig. 5.8** Frontal views of human embryos in the fourth (A), sixth (B), and seventh (C) weeks after fertilization. At the stage shown in (A) (fourth week), the olfactory placodes (*dashed circles*) are visible on the surface of the frontonasal prominence, the tissue that envelops the forebrain. By the middle of the sixth week (B), growth centers that surround the nasal pits and are termed the *medial (mnp)* and *lateral (lnp)* nasal prominences are evident, as are a premaxillary (*premax*) segment, two components of the maxillary region (*max* and *max'*) and the mandibular (*man*) portion of the first pharyngeal arch. These growth centers are also discernable in the early seventh week (43 days) in human embryos (C). \*, Stomodeum (primitive oral cavity). (D) Schematic representation of the contribution of the embryonic facial processes to the structures of the adult face. The central part of the nose and the philtrum of the lip are derived from the medial nasal process. The lateral nasal process forms the outer parts of the nose, and the maxillary process forms the bulk of the upper lip and the cheeks. (Courtesy Dr. K. Sulik.)

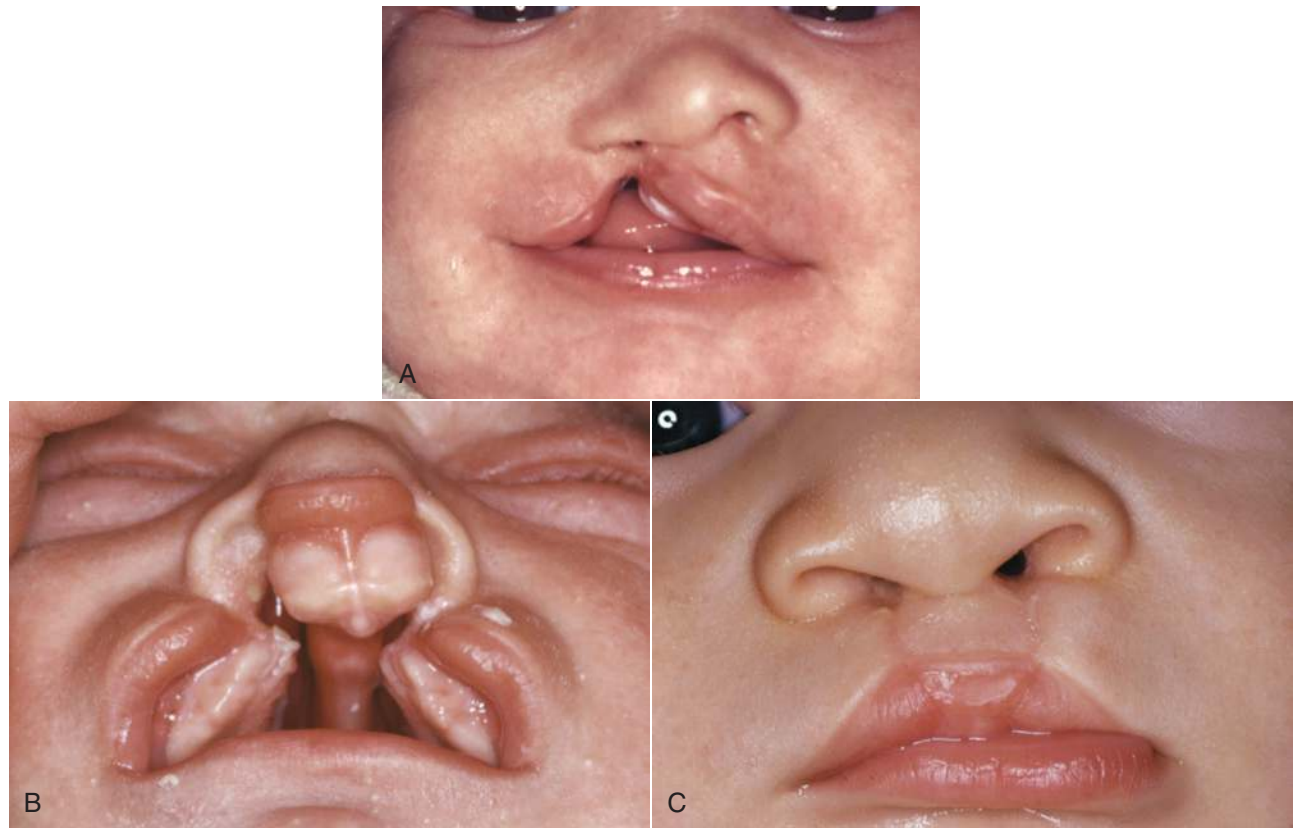
philtral part of the upper lip and also is the origin of the portion of the alveolar ridge that contains the upper central incisors and the medial (distal) portions of the upper lateral incisors.<sup>6-8</sup> The lateral (proximal) component of each of the upper lateral incisors appears to be of maxillary' tissue origin. Typical lip clefts may be unilateral, bilateral, complete, or incomplete (Fig. 5.9). Complete clefts extend through the upper lateral incisors and may manifest with deficiencies in the lateral incisor components on either or both sides of the cleft.

For the lip, closure is normally completed by the seventh week, and for the secondary palate, union occurs early in the fetal period of development (weeks 9 and 10). About 60% of individuals with a cleft lip also have a cleft palate that is due to failure of union of the maxillary prominence-derived secondary palatal shelves. This may be a result of a concurrent tissue abnormality in the lip or primary palate and the secondary palate tissue, or may result from excessive facial width that follows the lip clefting and places the secondary palatal shelves too far apart to unite in the midline. Fig. 5.10 shows human embryos at the end of the embryonic

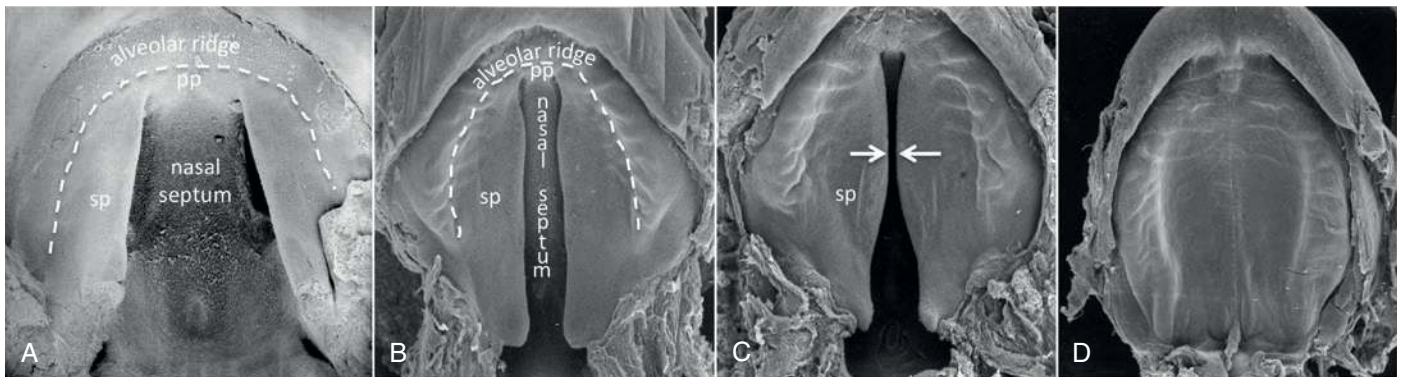
period and in the early fetal period. As you can see in Fig. 5.10A, the secondary palatal shelves initially are widely separated. Elevation of the shelves above the tongue is required for midline union. In Fig. 5.10B, note the elevation and initial contact of the palatal shelves, which is followed by completion of their midline union (Fig. 5.10C–D).

A number of possible causes of cleft lip and palate have been identified, including exposure to some teratogens. As we have noted, insults to developing tissues usually precede the steps that culminate with closure of the lip and palate, and it is interesting that maternal smoking is a definite risk factor.<sup>9</sup>

In addition to "typical" cleft lip and cleft palate, unusual facial clefts occur that also result from the failure of facial prominences to properly form or unite.<sup>10</sup> Examples include macrostomia, a defect at the junction of the maxillary and mandibular prominences that may result from a growth deficiency in either or both of these growth centers, and oblique facial clefts that occur at the junction of the maxillary' growth center with either the lateral nasal or maxillary growth center.



• **Fig. 5.9** Typical human clefts of the lip and palate. (A) Unilateral incomplete cleft lip in an infant. Note that the cleft is not in the midline but lateral to the midline, and that there is an intact band of tissue beneath the nostril. (B) Bilateral complete cleft lip and palate in an infant. The separation of the premaxilla from the remainder of the maxilla is shown clearly. (C) Same child after lip repair.



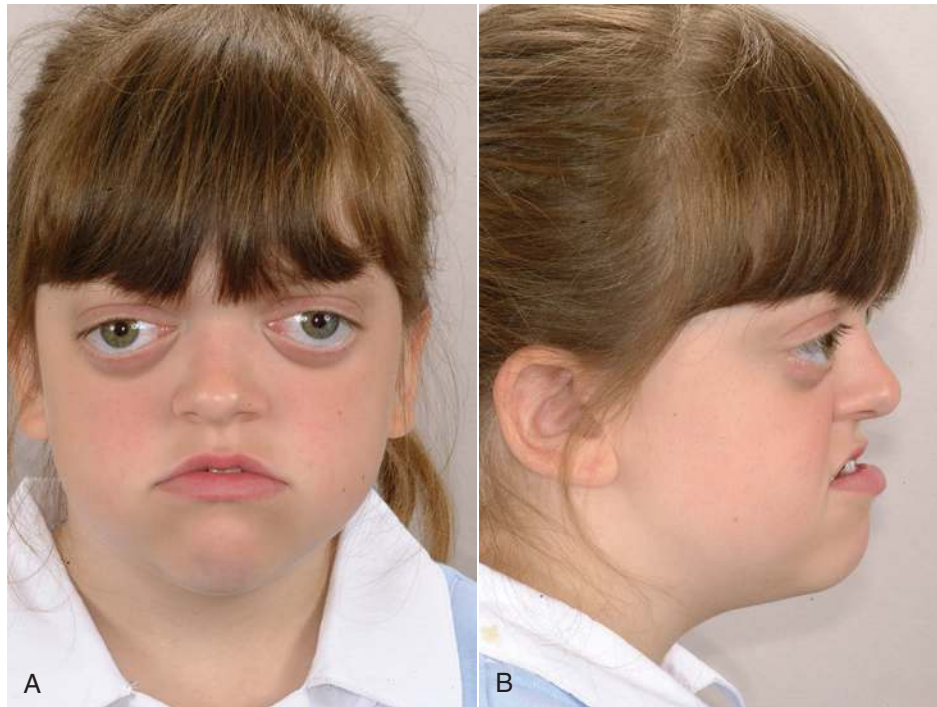
• **Fig. 5.10** The closing human palate in human embryos (A) at the end of the embryonic period (55 days) and (B) in the ninth week, which is the beginning of the fetal period (B to D). Arrows indicate approximate first site of secondary palatal fusion. *pp*, Primary palate; *sp*, secondary palatal shelf. (Courtesy Dr. K. Sulik.)

Another major group of craniofacial malformations, the craniosynostosis syndromes, involve developmental abnormalities that become evident in the fetal period.<sup>11</sup> They result from abnormally early closure of the sutures between specific bones of the craniofacial complex and can be caused by a variety of mutations involving fibroblast growth factor receptor genes. Early suture closure leads to characteristic distortions, depending on the location of the early fusion. Surgical release of the prematurely fused areas is needed to maintain normal head shape and facial

proportions.<sup>12</sup> The ideal time for surgery to release fused cranial sutures is (with a few exceptions) between 6 and 9 months of age. Fusion of sutures that attach the face to the cranial structures behind sometimes occurs, usually with, but occasionally without, fusion of cranial sutures, and this may require orbital advancement in addition to release of fused sutures.

Crouzon's syndrome is the most frequently occurring member of the group of synostosis syndromes that affect the face. It is linked to a mutation in fibroblast growth factor receptor 2 on chromosome





• **Fig. 5.11** (A) and (B) Facial appearance in Crouzon's syndrome of moderate severity, at age 8 years 8 months. Note the wide separation of the eyes (hypertelorism) and deficiency of the midfacial structures, both of which are characteristic of this syndrome. Because of premature suture fusion along the walls of the orbit, forward development of the midface is retarded, which produces the apparent protrusion of the eyes.

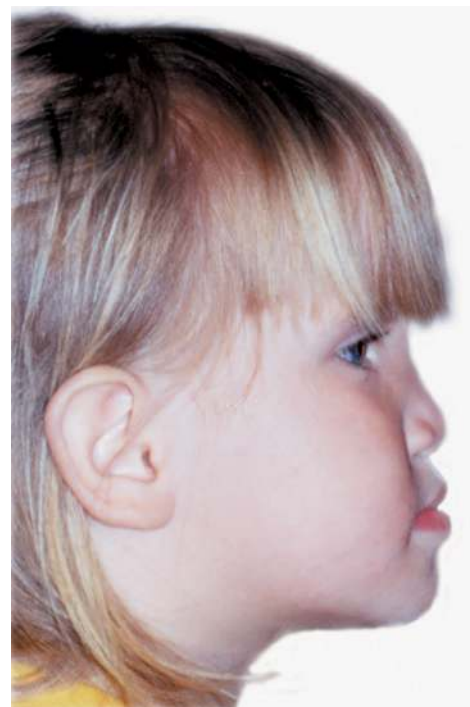10 and is characterized by underdevelopment of the midface and eyes, which seem to bulge from their sockets (Fig. 5.11). This syndrome arises because of prenatal fusion of the superior and posterior sutures of the maxilla along the wall of the orbit. The premature fusion frequently extends posteriorly into the cranium, producing distortions of the cranial vault as well. The fusion in the orbital area prevents the maxilla from translating downward and forward, and the result is severe underdevelopment of the middle third of the face. The characteristic protrusion of the eyes is largely an illusion: the eyes appear to bulge outward because the area beneath them is underdeveloped. There may be a component of true extrusion of the eyes, however, because intracranial pressure sometimes increases when cranial sutures fuse prematurely. For these children, surgery to release the sutures coupled with distraction osteogenesis to advance the orbits often is necessary.<sup>12</sup>

## Growth Disturbances in the Fetal and Perinatal Period

### Fetal Molding and Birth Injuries

Injuries apparent at birth fall into two major categories: (1) intrauterine molding and (2) trauma to the mandible during the birth process, particularly from the use of forceps during delivery.

**Intrauterine Molding.** Pressure against the developing face prenatally can lead to distortion of rapidly growing areas. Strictly speaking, this is not a birth injury, but because the effects are noted at birth, it is considered in that category. On rare occasions, an arm is pressed across the face in utero, resulting in severe maxillary deficiency at birth (Fig. 5.12).

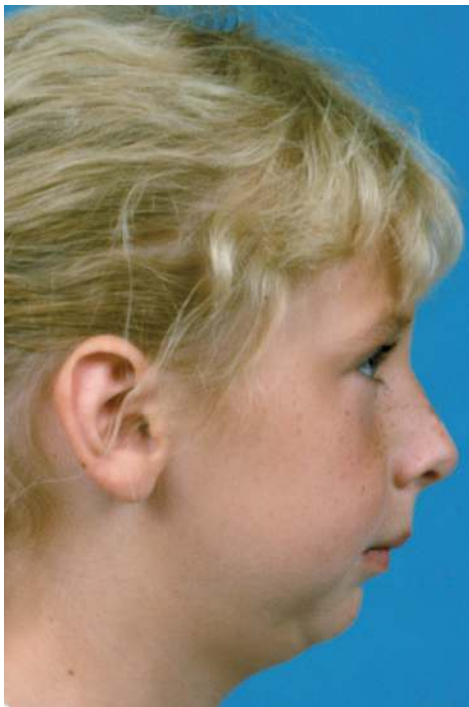

• **Fig. 5.12** Midface deficiency in a 3-year-old child still apparent, although much improved from the severe deficiency that was present at birth because of intrauterine molding. Before birth, one arm was pressed across her face. (From Proffit WR, White RP, Sarver DM. *Contemporary Treatment of Dentofacial Deformity*. St. Louis: Mosby; 2003.)



Occasionally, a fetus' head is flexed tightly against the chest in utero, preventing the mandible from growing forward normally. This is related to a decreased volume of amniotic fluid, which can occur for any of several reasons. The result is an extremely small mandible at birth, usually accompanied by a cleft palate because the restriction on displacement of the mandible forces the tongue upward and prevents normal closure of the palatal shelves. This extreme mandibular deficiency at birth is termed the *Pierre Robin sequence*. It is not a syndrome that has a defined cause; instead, multiple causes can lead to the same sequence of events that produce the deformity. The reduced volume of the oral cavity can lead to respiratory difficulty at birth, and it may be necessary to perform a tracheostomy so the infant can breathe. Early mandibular advancement via distraction osteogenesis has been used recently in these severely affected infants to bring the tongue forward and provide more space for an airway so that the tracheostomy can be closed.

Because the pressure against the face that caused the growth problem would not be present after birth, there is the possibility of normal growth thereafter and perhaps eventually a complete recovery. Some children with Pierre Robin sequence at birth do have favorable mandibular growth in childhood, but a smaller than normal mandible typically persists (Fig. 5.13), and catch-up growth during adolescence does not occur.<sup>13</sup> It has been estimated that about one-third of Pierre Robin patients have a defect in cartilage formation and can be said to have Stickler syndrome. Not surprisingly, this group has limited growth potential. Catch-up



• **Fig. 5.13** This girl was diagnosed at birth as having the Pierre Robin sequence, which results in a very small mandible, airway obstruction, and cleft palate. Some children with this condition have enough postnatal mandibular growth to largely correct the jaw deficiency, but the majority do not. At age 9, her mandibular deficiency persists. (From Proffit WR, White RP, Sarver DM. *Contemporary Treatment of Dentofacial Deformity*. St. Louis: Mosby; 2003.)

growth is most likely when the original problem was mechanical growth restriction that no longer existed after birth.

**Birth Trauma to the Mandible.** Many facial deformity patterns now known to result from other causes once were blamed on injuries during birth. Many parents, despite explanations from their doctors, will refer to their child's facial deformity as having been caused by a birth injury even if a congenital syndrome is evident. No matter what the parents say later, a recognizable syndrome obviously did not arise because of birth trauma.

In some difficult births, however, the use of forceps to the head to assist in delivery might damage either or both of the temporomandibular (TM) joints. At least in theory, heavy pressure in the area of the TM joints could cause internal hemorrhage, loss of tissue, and a subsequent underdevelopment of the mandible. At one time this was a common explanation for mandibular deficiency. If the cartilage of the mandibular condyle were an important growth center, of course, the risk from damage to a presumably critical area would seem much greater. In light of the contemporary understanding that the condylar cartilage is not critical for proper growth of the mandible, it is not as easy to blame underdevelopment of the mandible on birth injuries. Children with deformities involving the mandible are much more likely to have a congenital syndrome.

## Progressive Deformities in Childhood

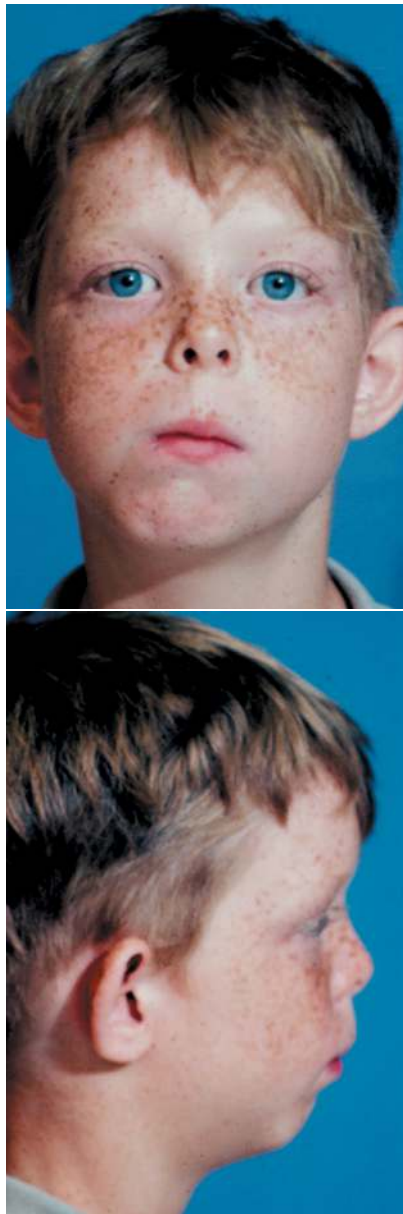A progressive deformity is one that steadily becomes worse, which, of course, indicates early treatment. These problems, fortunately, arise much less frequently than the severe but stable deformities that comprise most of the jaw problems encountered in children.

### Childhood Fractures of the Jaws

In the frequent falls and impacts of childhood, the condylar neck of the mandible is particularly vulnerable, and fractures of this area are relatively common in children. Fortunately, the condylar process tends to regenerate well after early fractures. The best human data (see Chapter 2) suggest that about 75% of children with early fractures of the mandibular condylar process have normal mandibular growth afterward and therefore do not develop malocclusions that they would not have had in the absence of such trauma.

Unilateral condylar fracture is much more frequent than bilateral fractures. It seems to be relatively common for a child to crash the bicycle, chip a tooth and fracture a condyle, cry a bit, and then continue to develop normally, complete with total regeneration of the condyle. Often, the diagnosis of condylar fracture was never made. When a problem does arise following condylar fracture, it usually is asymmetric growth deficiency, with the injured side (or, in bilateral fractures, the more severely injured side) lagging behind (Fig. 5.14). After such an injury, if there is enough scarring around the TM joint to restrict translation of the condyle, the normal soft tissues cannot pull the mandible forward on that side as much as the rest of the growing face, and subsequent growth will be restricted.

This concept is highly relevant to the management of condylar fractures in children. It suggests, and clinical experience confirms, that there would be little if any advantage from surgical open reduction of a condylar fracture in a child. The additional scarring produced by surgery could make things worse. The best therapy, therefore, is conservative management at the time of injury and early mobilization of the jaw to minimize any restriction on movement. If deficient growth is observed, however, early treatment is needed (see Chapter 14).



• **Fig. 5.14** Mandibular asymmetry in an 8-year-old boy caused by deficient growth on the affected side after fracture of the left condylar process, probably at age 2. For this patient, growth was normal despite the complete loss of the mandibular condyle until age 6, when an attachment of the condylar process to the underside of the zygomatic arch on the injured side began to restrict growth; then facial asymmetry developed rapidly. (From Proffit WR, White RP, Sarver DM. *Contemporary Treatment of Dentofacial Deformity*. St. Louis: Mosby; 2003.)

Although an old condylar fracture is the most likely cause of asymmetric mandibular deficiency in a child, other destructive processes that involve the TM joint, such as rheumatoid arthritis (Fig. 5.15), or a congenital absence of tissue as in craniofacial microsomia also can produce this problem.

### Muscle Dysfunction

The facial muscles can affect jaw growth in two ways. First, the formation of bone at the point of muscle attachments depends on the activity of the muscle; second, the musculature is an

important part of the total soft tissue matrix whose growth normally carries the jaws downward and forward. Loss of part of the musculature is most likely to result from damage to the motor nerve (muscle atrophies when its motor nerve supply is lost). The result would be underdevelopment of that part of the face, with a deficiency of both soft and hard tissues (Fig. 5.16).

Excessive muscle contraction can restrict growth in much the same way as scarring after an injury. This effect is seen most clearly in torticollis, a twisting of the head caused by excessive tonic contraction of the neck muscles on one side (primarily the sternocleidomastoid) (Fig. 5.17). The result is a facial asymmetry because of growth restriction on the affected side, which can be quite severe unless the contracted neck muscles are surgically detached at an early age.<sup>14</sup> Conversely, a major decrease in tonic muscle activity (as in muscular dystrophy, some forms of cerebral palsy, and various muscle weakness syndromes) allows the mandible to drop downward away from the rest of the facial skeleton. The result is increased anterior face height, distortion of facial proportions and mandibular form, excessive eruption of the posterior teeth, narrowing of the maxillary arch, and anterior open bite (Fig. 5.18).<sup>15</sup>

### Disturbances Arising in Adolescence or Early Adult Life

Occasionally, unilateral excessive growth of the mandible occurs in individuals who seem metabolically normal. Why this occurs is entirely unknown. It is most likely in girls between the ages of 15 and 20 but may occur as early as age 8 or as late as the early 30s in either sex. The condition formerly was called *condylar hyperplasia*, and proliferation of the condylar cartilage is a prominent aspect; however, because the body of the mandible also is affected (Fig. 5.19), *hemimandibular hypertrophy* now is considered a more accurate descriptive term.<sup>16</sup> The excessive growth may stop spontaneously, but in severe cases removal of the affected condyle and reconstruction of the area are necessary.

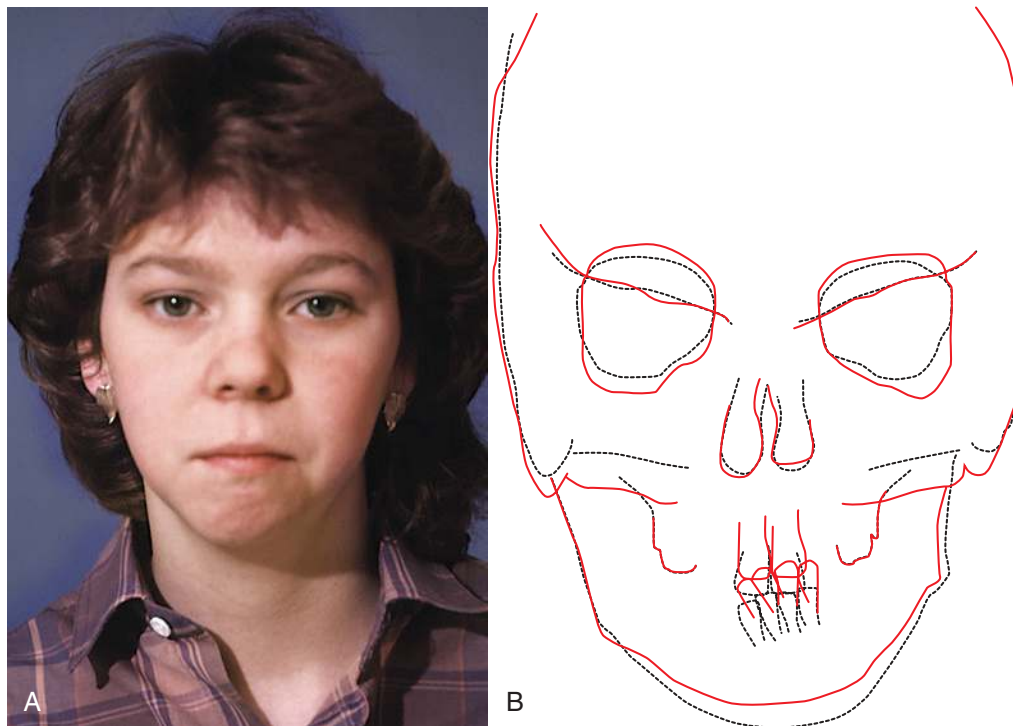
In acromegaly, which is caused by an anterior pituitary tumor that secretes excessive amounts of growth hormone, excessive growth of the mandible may occur, creating a skeletal Class III malocclusion in adult life (Fig. 5.20). Often (but not always—sometimes the mandible is unaffected while the hands and/or feet grow), mandibular growth accelerates again to the levels seen in the adolescent growth spurt, years after adolescent growth was completed.<sup>17</sup> The condylar cartilage proliferates, but it is difficult to be sure whether this is the cause of the mandibular growth or merely accompanies it. Although the excessive growth stops when the tumor is removed or irradiated, the skeletal deformity persists and orthognathic surgery to reposition the mandible is likely to be necessary (see Chapter 20).

### Disturbances of Dental Development

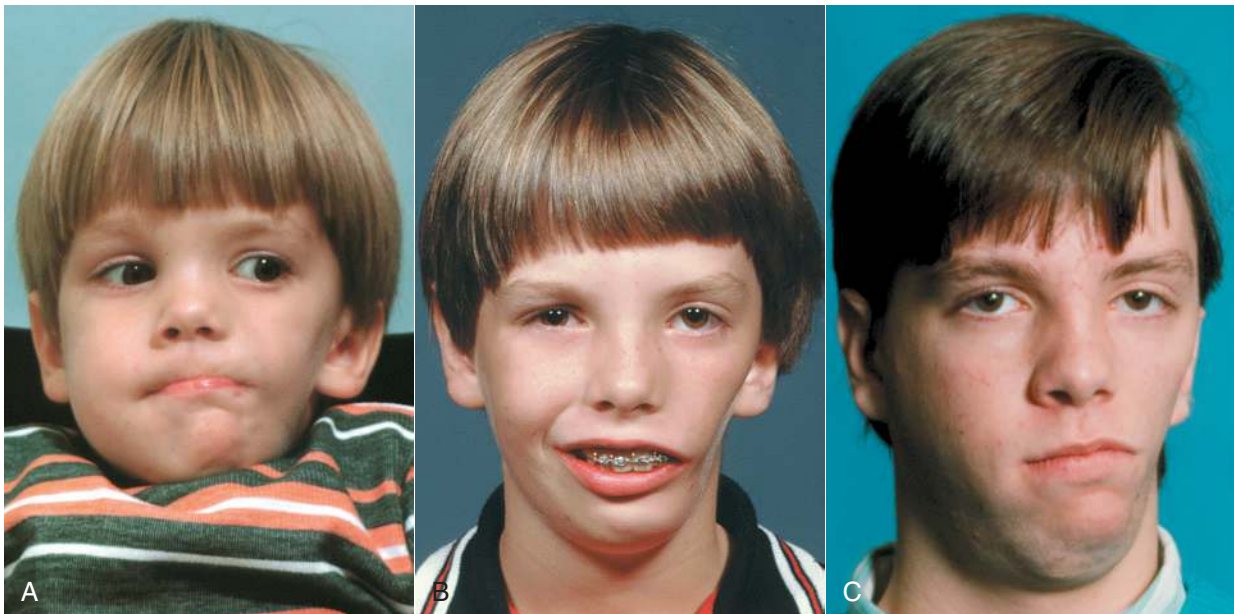Most disturbances of dental development are contributors to isolated Class I malocclusion, and these conditions (such as drift of permanent teeth after early loss of primary teeth) are discussed in Chapter 11. Dental problems that are related to larger congenital or health problems are discussed in the following sections.

#### Congenitally Missing Teeth

A genetic basis has been established for most instances of congenitally missing teeth (more formally called *tooth agenesis*), and some form of tooth agenesis appears as a phenotype in more than 150 syndromes, but it must be kept in mind that there are both



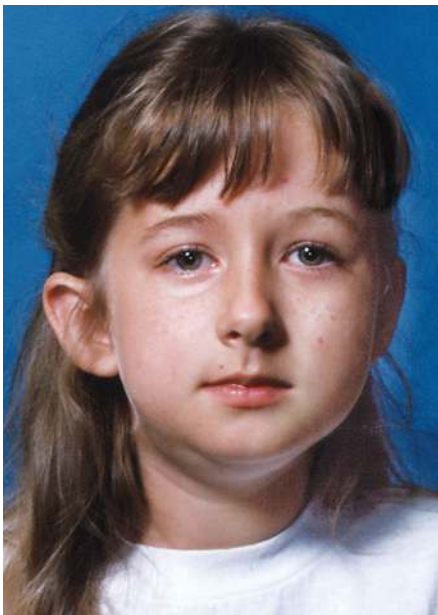• **Fig. 5.15** Rheumatoid arthritis is an uncommon cause of facial asymmetry, but in the polyarticular form of the disease (multiple joints affected), the temporomandibular joints (TMJs) often are involved, and asymmetry may develop as one side is affected more than the other. (A) Facial appearance at age 12, 2 years after the diagnosis of polyarticular rheumatoid arthritis. (B) Superimposition tracing at ages 11-8 (black) and 13-3 (red). With a decrease in ramus height on the right side over this period, the mandible rotated down and back. By age 24 the condylar processes on both sides had resorbed almost completely.



• **Fig. 5.16** Facial asymmetry in a boy whose masseter muscle was largely missing on the left side. The muscle is an important part of the total soft tissue matrix; in its absence growth of the mandible in the affected area also is deficient. (A) Age 4. (B) Age 11. (C) Age 17, after surgery to advance the mandible more on the left than the right side. The soft tissue deficiency from the missing musculature on the left side still is evident.



syndromic and nonsyndromic variants. Congenital absence of teeth results from disturbances during the initial stages of formation of a tooth: initiation and proliferation. *Anodontia*, the total absence of teeth, is the extreme form. The term *oligodontia* refers to congenital absence of many but not all teeth, whereas the rarely used term *hypodontia* implies the absence of only a few teeth. Because the primary tooth buds give rise to the permanent tooth buds, there will be no permanent tooth if its primary predecessor was missing.



• **Fig. 5.17** Facial asymmetry in a 6-year-old girl with torticollis. Excessive muscle contraction can restrict growth in a way analogous to scarring after an injury. Despite surgical release of the contracted neck muscles at age 1, moderate facial asymmetry developed in this patient, and a second surgical release of the left sternocleidomastoid muscle was performed at age 7. Note that the asymmetry reflects deficient growth of the entire left side of the face, not just the mandible.

It is possible, however, for the primary teeth to be present and for some or all the permanent teeth to be absent.

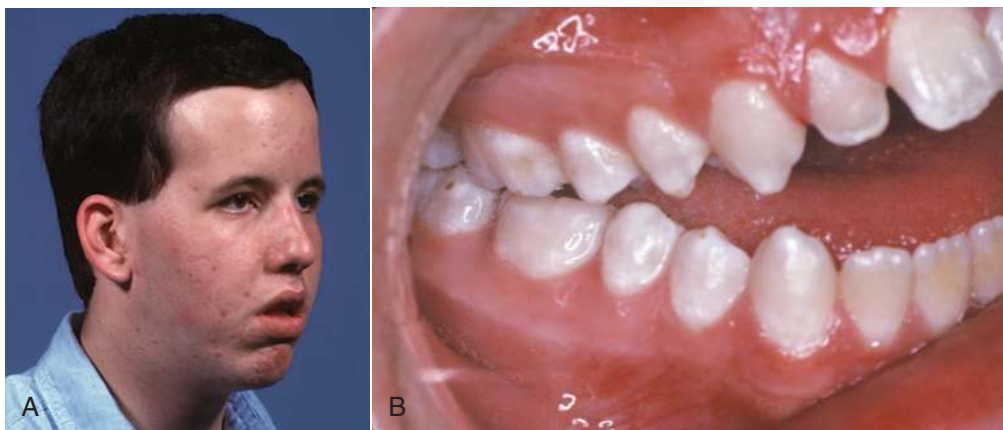
Anodontia and oligodontia are usually associated with a systemic abnormality, *ectodermal dysplasia*, which has a genetic basis. Individuals with ectodermal dysplasia have thin, sparse hair and an absence of sweat glands in addition to their characteristically missing teeth (Fig. 5.21). Occasionally, oligodontia occurs in a patient with no apparent systemic problem or congenital syndrome. In these children, it was once thought that there was a random pattern to the missing teeth, but as more data become available, patterns increasingly are being recognized.

Anodontia and oligodontia are rare, but hypodontia is a relatively common finding. It appears that a polygenic multifactorial model of etiology is the best explanation of the cause. As a general rule, if only one or a few teeth are missing, the absent tooth will be the most distal tooth of any given type. If a molar tooth is congenitally missing, it is almost always the third molar; if an incisor is missing, it is nearly always the lateral; if a premolar is missing, it almost always is the second rather than the first. Rarely is a canine the only missing tooth.

### Malformed and Supernumerary Teeth

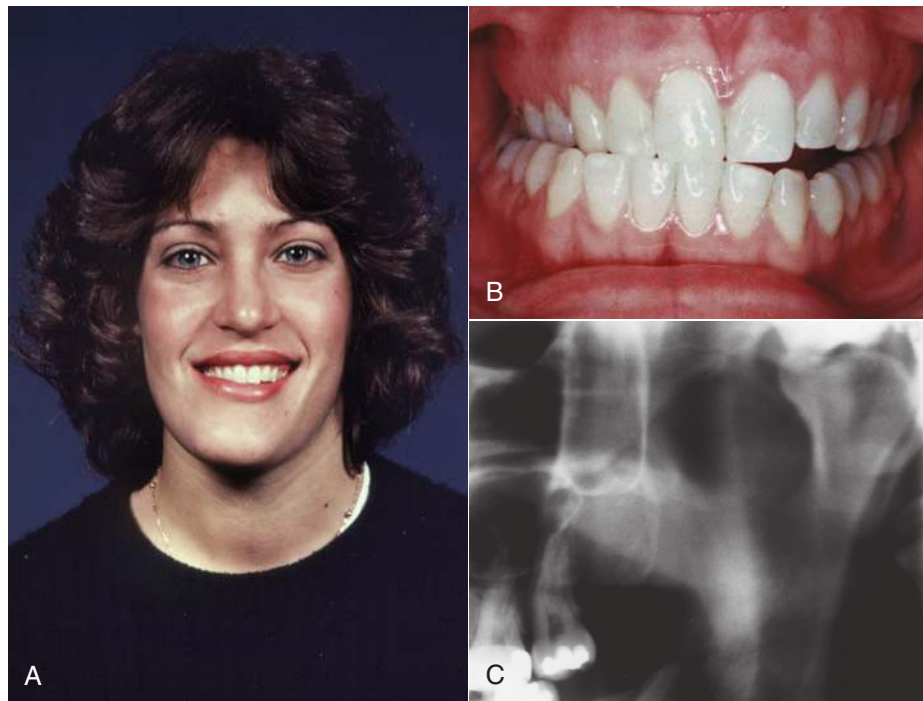Abnormalities in tooth size and shape result from disturbances during the morphodifferentiation stage of development, perhaps with some carryover from the histodifferentiation stage. The most common abnormality is a variation in size, particularly of maxillary lateral incisors (Fig. 5.22) and mandibular or maxillary second premolars. About 5% of the total population have a significant “tooth size discrepancy” because of disproportionate sizes of the upper and lower teeth. Unless the teeth are matched for size, normal occlusion is impossible. As might be expected, the most variable teeth, the maxillary lateral incisors, are the major culprits.

Supernumerary or extra teeth also result from disturbances during the initiation and proliferation stages of dental development and, like tooth agenesis, can occur as part of a larger disease process or syndrome or as an idiopathic finding. The most common supernumerary tooth appears in the maxillary midline and is called a *mesiodens*. Supernumerary lateral incisors also occur; extra premolars occasionally appear; and a few patients have fourth, in addition to third, molars. The presence of an extra tooth obviously

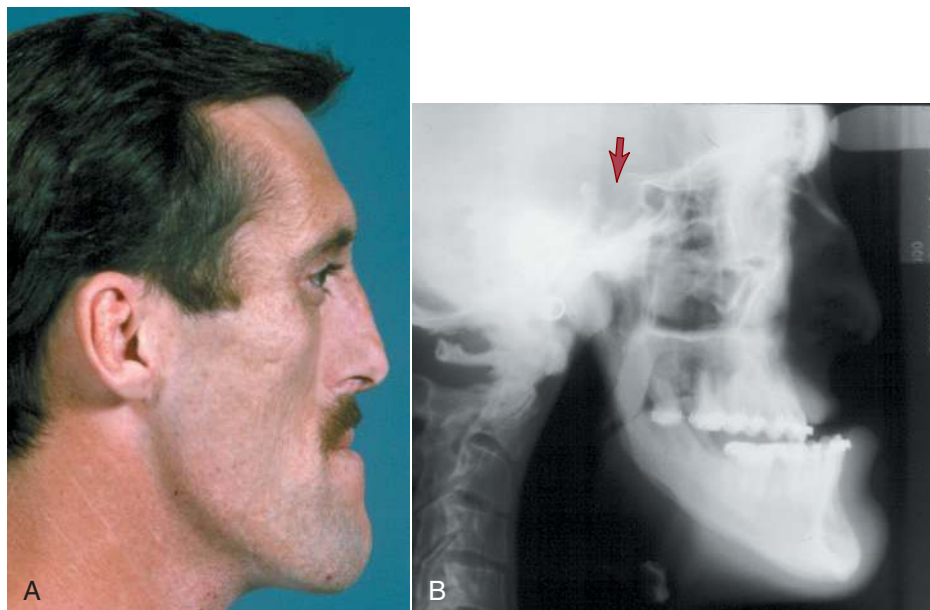


• **Fig. 5.18** (A) Lengthening of the lower face typically occurs in patients with muscle weakness syndromes, as in this 15-year-old boy with muscular dystrophy. (B) Anterior open bite, as in this patient, usually (but not always) accompanies excessive face height in patients with muscular weakness.

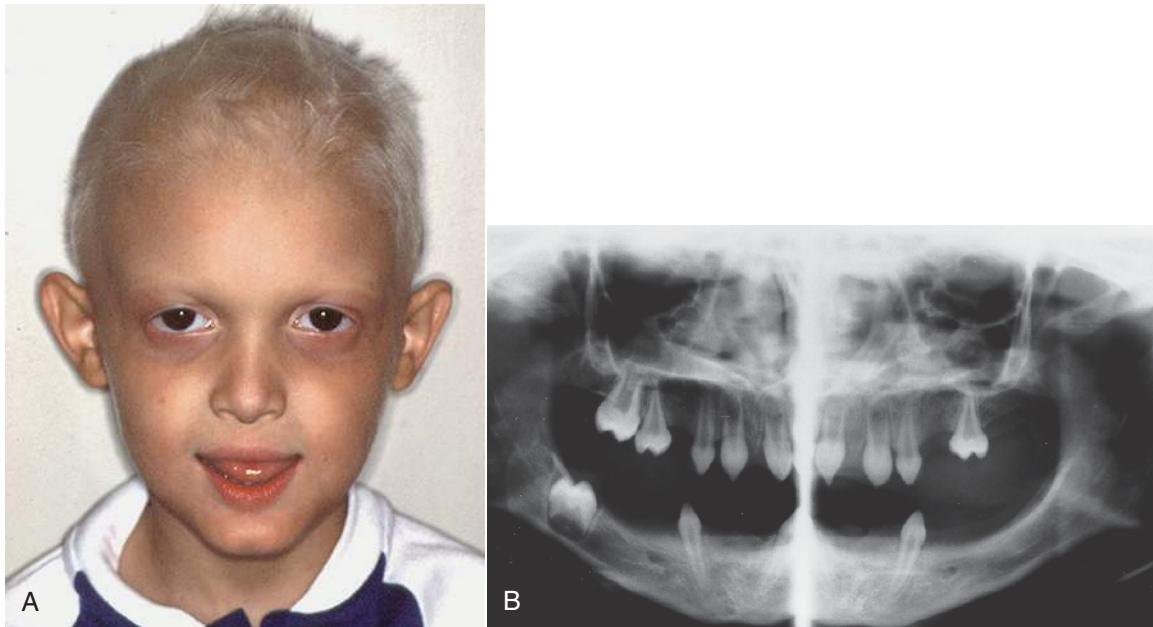




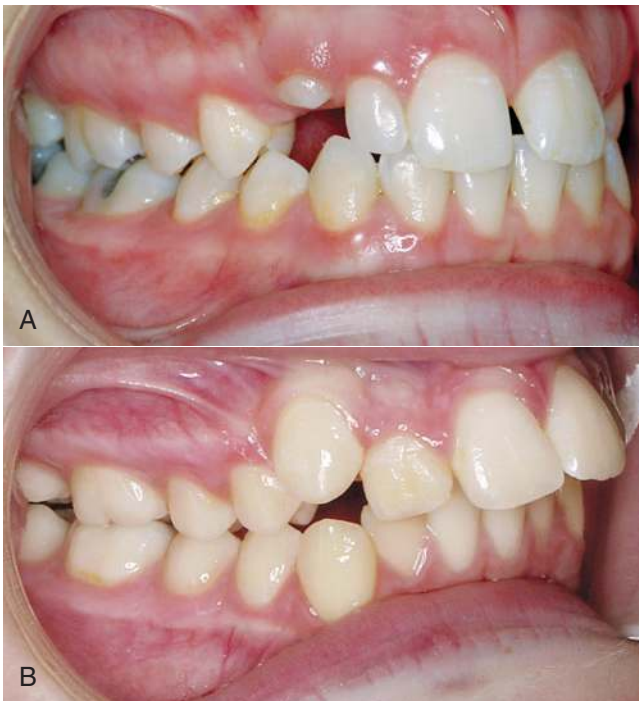• **Fig. 5.19** (A) Facial asymmetry in this 21-year-old woman developed gradually in her late teens because of excessive growth of the mandible on the left side, after orthodontic treatment for dental crowding during which there was no sign of jaw asymmetry. (B) The dental occlusion shows an open bite on the affected left side, reflecting the vertical component of the excessive growth. (C) Note the grossly enlarged mandibular condyle on the patient's left side. Why this type of excessive but histologically normal growth occurs and why it is seen predominantly in females is unknown.



• **Fig. 5.20** Profile view (A) and cephalometric radiograph (B) of a 32-year-old man with acromegaly, which had been diagnosed 3 years previously when he had gone to a dentist because his lower jaw was moving forward. After irradiation of the anterior pituitary area, growth hormone levels dropped and mandibular growth ceased. Note the enlargement of sella turcica and loss of bony definition of its bony outline, reflecting the secretory tumor in that location (arrow). (From Proffit WR, White RP, Sarver DM. *Contemporary Treatment of Dentofacial Deformity*. St. Louis: Mosby; 2003.)



• **Fig. 5.21** (A) A child with ectodermal dysplasia, in addition to the characteristic thin and light-colored hair, is likely to have an overclosed appearance because of lack of development of the alveolar processes. (B) Panoramic radiograph of the same boy, showing the multiple missing teeth. When this many teeth are congenitally missing, ectodermal dysplasia is the most likely cause.



• **Fig. 5.22** Disproportionately small (A) or large (B) maxillary lateral incisors are relatively common. This creates a tooth-size discrepancy that makes normal alignment and occlusion almost impossible. It is easier to build up small laterals than reduce the size of large ones, because dentin is likely to be exposed interproximally after more than 1 to 2 mm in width reduction.

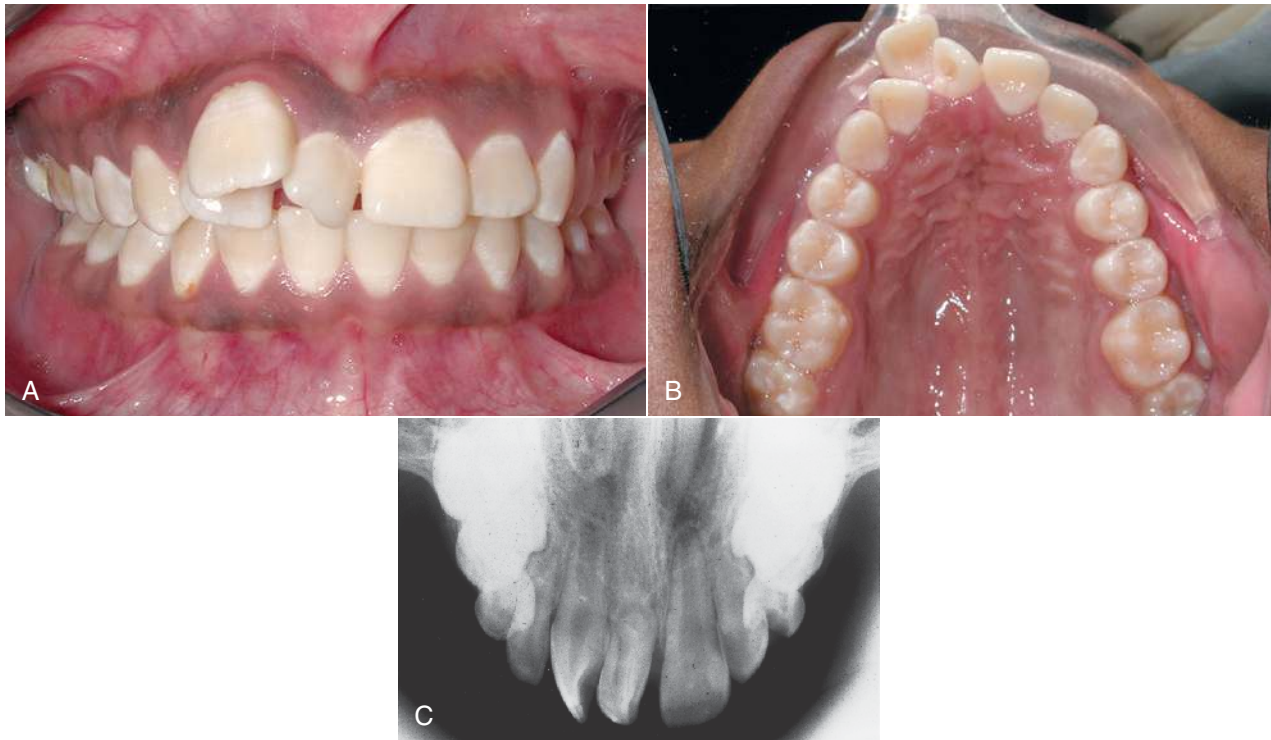
has great potential to disrupt normal occlusal development (Fig. 5.23), and early intervention to remove it is usually required to obtain reasonable alignment and occlusal relationships. Multiple supernumerary teeth are most often seen in the congenital syndrome of cleidocranial dysplasia (see Fig. 3.15), which is characterized by missing clavicles (collar bones), many supernumerary and unerupted teeth, and failure of the succedaneous teeth to erupt.

#### **Traumatic Displacement of Teeth**

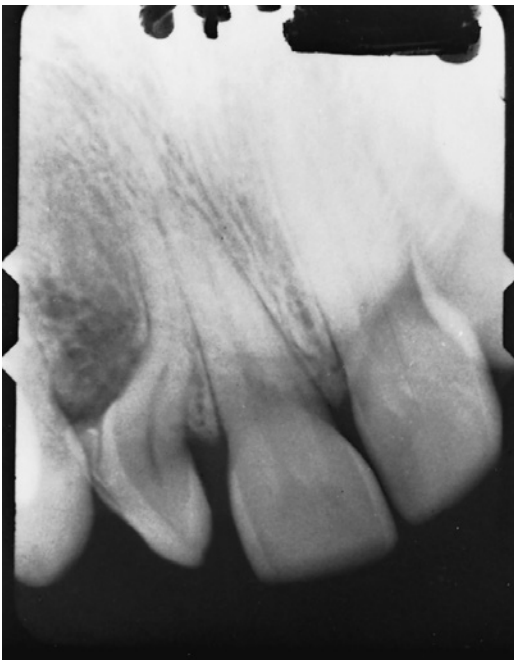Almost all children fall and hit their teeth during their formative years. When trauma to a primary tooth displaces the permanent tooth bud underlying it, there are two possible results. First, if the trauma occurs while the crown of the permanent tooth is forming, enamel formation will be disturbed and there will be a defect in the crown of the permanent tooth.

Second, if the trauma occurs after the crown is complete, the crown may be displaced relative to the root. Root formation may stop, leaving a permanently shortened root. More frequently, root formation continues, but the remaining portion of the root then forms at an angle to the traumatically displaced crown (Fig. 5.24). This distortion of root form is called *dilaceration*. If it is severe enough, it is almost impossible for the crown to assume its proper position, which might require the root to extend out through the alveolar bone. For this reason, it may be necessary to extract a severely dilacerated tooth.

Teeth that were displaced laterally by trauma usually should be repositioned as early as possible (see Chapter 12). Immediately after the accident, an intact tooth usually can be moved back to its original position rapidly and easily. After healing (which takes 2 to 3 weeks), orthodontics or surgery may be necessary to reposition the tooth, and ankylosis may make this impossible for tooth movement or difficult even with surgery.



• **Fig. 5.23** (A to C) The maxillary midline is the most common location for a supernumerary tooth, often called a *mesiodens* because of its location. It can be of almost any shape. The supernumerary tooth may block the eruption of one or both central incisors or, as in this girl, may separate them widely and also displace the lateral incisors.



• **Fig. 5.24** Distortion of the root (termed *dilaceration*) of this lateral incisor resulted from trauma at an earlier age that displaced the crown relative to the forming root. This is a more severe dilaceration than what is usually observed (see Fig. 3.17), but even in this child the tooth erupted—dilaceration does not prevent eruption.

## Genetic Influences

A strong influence of heredity on facial features is obvious at a glance: it is easy to recognize familial tendencies in the tilt of the nose, the shape of the jaw, and the look of the smile. The similarity of human faces among relatives—past and present—makes the genetic basis of human craniofacial development even more apparent. Certain types of malocclusion run in families. The Hapsburg jaw, the prognathic mandible of this European royal family, is the best known example (Fig. 5.25), but dentists routinely see repeated instances of similar malocclusions in parents and their offspring. The pertinent question for the etiology of malocclusion is not whether there are inherited influences on the jaws and teeth, because obviously there are, but whether different types of malocclusion can be directly caused by inherited characteristics.<sup>18</sup>

For much of the 20th century, thoughts about how malocclusion could be produced by inherited characteristics focused on two major possibilities. The first would be an inherited disproportion between the size of the teeth and the size of the jaws, which would produce crowding or spacing. The second would be an inherited disproportion between the size and/or shape of the upper and lower jaws, which would cause improper occlusal relationships. The more independently these characteristics are determined, the more likely that disproportions could be inherited. Could a child inherit relatively large teeth but a jaw too small to accommodate them, for instance, or a large upper jaw and a small lower one? That would be quite possible if jaw and tooth sizes were inherited independently, but if dentofacial characteristics tended to be linked, an inherited mismatch of this type would be unlikely.





• **Fig. 5.25** Mandibular prognathism in the Hapsburg family became known as the Hapsburg jaw because it recurred over multiple generations in European royalty and was recorded in many portraits. (A) Phillip II and Prince Ferdinand, 1575 (Titian). (B) Phillip IV, 1638 (Velasquez). (C) Charles IV and family, 1800 (Goya). In C, note the strong lower jaw in baby, father, and grandmother but not in mother.

Primitive human populations in which malocclusion is less frequent than in modern groups are characterized by genetic isolation and uniformity. If everyone in a group carried the same genetic information for tooth size and jaw size, there would be no possibility of a child inheriting discordant characteristics. In the absence of processed food, one would expect strong selection pressure for traits that produced good masticatory function. Genes that introduced disturbances into the masticatory system would tend to be eliminated from the population (unless they conferred some other advantage). The result should be exactly what is seen in primitive populations: individuals in whom tooth size–jaw size discrepancies are infrequent and groups in which everyone tends to have the same jaw relationship (not necessarily one that produces ideal dental occlusion). Different human groups have developed impressive variations in facial proportions and jaw relationships. What happens, then, when there is outbreeding between originally distinct human population groups?

One of the characteristics of civilization is the collection of large groups of people into urban centers, where the opportunities for mating outside one's own small population group are greatly magnified. If inherited disproportions of the functional components of the face and jaws were frequent, one would predict that modern urban populations would have a high prevalence of malocclusion and a great variety of orthodontic problems. The United States, reflecting its role as a “genetic melting pot,” should have one of the world's highest rates of malocclusion, which it does. In the 1930s and 1940s, as knowledge of the new science of genetics developed, it was tempting to conclude that the great increase in outbreeding that occurred as human populations grew and became more mobile was the major explanation for the increase in malocclusion in recent centuries.

This view of malocclusion as primarily a genetic problem was greatly strengthened by breeding experiments with animals carried out in the 1930s. By far the most influential individual in this regard was Professor Stockard, who methodically crossbred dogs and recorded the interesting effects on body structure.<sup>19</sup> Present-day dogs, of course, come in a tremendous variety of breeds and sizes.

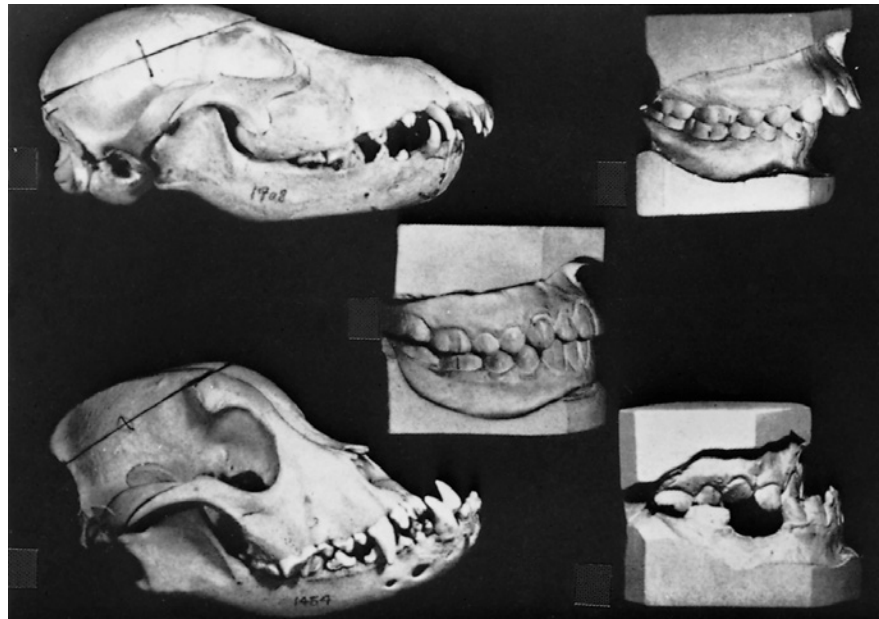
What would happen if one crossed a Boston terrier with a collie? Might the offspring have the collie's long, pointed lower jaw and the terrier's diminutive upper jaw? Could unusual crowding or spacing result because the teeth of one breed were combined in the offspring with the jaw of the other? Stockard's experiments indicated that dramatic malocclusions did occur in his crossbred dogs, more from jaw discrepancies than from tooth size–jaw size imbalances, and he published pointed comparisons with human malocclusions (Fig. 5.26). These experiments seemed to confirm that independent inheritance of facial characteristics could be a major cause of malocclusion and that the rapid increase in malocclusion accompanying urbanization was probably the result of increased outbreeding.

These dog experiments turned out to be misleading, however, because many breeds of small dogs carry the gene for achondroplasia. Animals or humans affected by this condition have deficient growth of cartilage. The result is extremely short extremities and an underdeveloped midface. The dachshund is the classic achondroplastic dog, but most terriers and bulldogs also carry this gene. Achondroplasia is an autosomal dominant trait. Like many dominant genes, the gene for achondroplasia shows variable expressivity, meaning simply that the trait will be expressed more dramatically in some individuals than in others. Most of the unusual malocclusions produced in Stockard's breeding experiments can be explained by the extent to which achondroplasia was expressed in that animal, not on the basis of inherited jaw size.

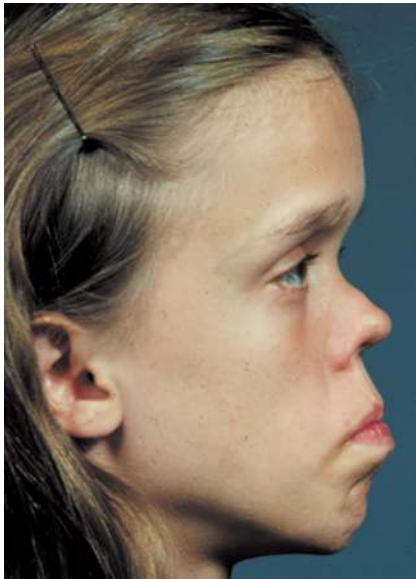Achondroplasia is rare in humans, but it does occur and produces the expected changes (Fig. 5.27). In addition to short limbs, the cranial base does not lengthen normally because of the deficient growth at the synchondroses, the maxilla is not translated forward to the normal extent, and a relative midface deficiency occurs. In a number of relatively rare genetic syndromes such as achondroplasia, influences on the form of the face, jaws, and teeth can be discerned, but those cause only a fraction of 1% of orthodontic problems.

A careful examination of the results of outbreeding in human populations also casts doubt on the hypothesis that independently inherited tooth and jaw characteristics are a major cause of





• **Fig. 5.26** In breeding experiments with dogs in the 1930s, Professor Stockard demonstrated that severe malocclusions could be developed by crossing morphologically different breeds. His analogy to human malocclusion was a powerful influence in the rejection of the prevailing belief of the 1920s that improper jaw function caused malocclusion. (From Stockard CR, Johnson AL. *Genetic and Endocrinic Basis for Differences in Form and Behavior*. Philadelphia: The Wistar Institute of Anatomy and Biology; 1941.)



• **Fig. 5.27** In this 14-year-old girl with moderately severe achondroplasia, note the deficient midface, particularly at the bridge of the nose. This results from decreased growth of cartilage in the cranial base, with a resulting lack of forward translation of the maxilla. (From Proffit WR, White RP, Sarver DM. *Contemporary Treatment of Dentofacial Deformity*. St. Louis: Mosby; 2003.)

malocclusion. The best data are from investigations carried out in Hawaii by Chung et al.<sup>20</sup> Before its discovery by the European explorers of the 18th century, Hawaii had a homogeneous Polynesian population. Large-scale migration to the islands from Europe, China, and Japan, as well as the arrival of smaller numbers of other

racial and ethnic groups, resulted in an exceptionally heterogeneous modern population. Tooth size, jaw size, and jaw proportions were all rather different for the Polynesian, Asian, and European contributors to the Hawaiian melting pot. Therefore, if tooth and jaw characteristics were inherited independently, a high prevalence of severe malocclusion would be expected in this population.

The prevalence and types of malocclusion in the current Hawaiian population, although greater than the prevalence of malocclusion in the original population, do not support this concept. The effects of interracial crosses appear to be more additive than multiplicative. For example, about 10% of the Chinese who migrated to Hawaii had Class III malocclusion, whereas about 10% of the Polynesians had crowded teeth. The offspring of this cross seem to have about a 10% prevalence of each characteristic, but there is no evidence of dramatic facial deformities like those seen in the crossbred dogs. In other words, if malocclusion or a tendency to malocclusion is inherited, the mechanism is not the independent inheritance of discrete morphologic characteristics such as tooth and jaw sizes.

The classic way to determine to what extent a characteristic is determined by inheritance is to compare monozygotic (identical) with dizygotic (fraternal) twins. Monozygotic twins occur because of the early division of a fertilized egg, so each individual has the same chromosomal DNA and the two are genetically identical. Any differences between them should be solely the result of environmental influences. Twins also occur when two eggs are released at the same time and are fertilized by different spermatozoa. These dizygotic twins are not more similar than ordinary siblings except that they have shared the same intrauterine and family environment. Through the comparison of identical twins, fraternal twins, and ordinary siblings, the proportion of the variability in that characteristic that is due to heredity can be estimated.

Studies of this type are limited in several ways. Not only is it difficult to obtain the twin pairs for study, but also it can be

difficult to establish zygoty and confirm that the environments were in fact the same for both members of a twin pair. Nevertheless, well-done twin studies are the best way to evaluate heritability. Using twins with siblings as controls, Hughes et al reported that the hereditary component for variations in spacing and tooth position within the dental arches was 69% to 89%. It was 53% for overbite, but only 28% for overjet (which therefore appears to have a greater environmental component than crowding/spacing or overbite).<sup>21</sup> Corruccini et al have argued that with appropriate corrections for unsuspected environmental differences within twin pairs, the heritability for some dental characteristics such as overjet is almost zero.<sup>22</sup>

The other classic method of estimating the influence of heredity is to study family members, observing similarities and differences between mother and child, father and child, and sibling pairs. From an examination of longitudinal cephalometric radiographs and dental casts of siblings who participated in the Bolton-Brush growth study, Harris and Johnson concluded that the heritability of craniofacial (skeletal) characteristics was relatively high but that of dental (occlusal) characteristics was low.<sup>23</sup> For skeletal characteristics, the heritability estimates increased with increasing age; for dental characteristics, the heritability estimates decreased, indicating an increasing environmental contribution to the dental variation. These findings were confirmed and extended in a follow-up study of heritability in Icelandic families.<sup>24</sup> To the extent that the facial skeleton determines the characteristics of a malocclusion, therefore, a hereditary component is likely to be present. When parent-child correlations are used to assist in predicting facial growth, errors are reduced, which in itself strongly indicates the hereditary influence on these dimensions.<sup>25</sup> Purely dental variation, however, seems to be much more environmentally determined.

As was noted in European royal families (see Fig. 5.25), the influence of inherited tendencies is particularly strong for mandibular prognathism. In a recent study of 55 families in Brazil with more than 2000 individuals, the heritability of mandibular prognathism was estimated to be 0.316. The majority of the pedigrees suggested autosomal dominant inheritance with incomplete penetration, and the investigators concluded that there is a major gene that influences the expression of mandibular prognathism.<sup>26</sup> This does not mean that a single gene is responsible, and efforts during the last decade to identify a major gene related to prognathism have not been successful. It is apparent that what we call Class III malocclusion, or even the subcategory mandibular prognathism, really is a group of different phenotypes, and identifying these phenotypes and determining their heritability is a necessary step toward unraveling the genetics of Class III problems.<sup>27</sup>

The long-face pattern of facial deformity seems to be the second most likely type of deformity to run in families. In general, similar malocclusions are likely to be seen in siblings, especially if the malocclusion is severe, perhaps because their genetically influenced facial types and growth patterns lead to similar responses to environmental factors. Knowing the type of growth associated with different genetic patterns could help greatly with both the type and timing of orthodontic and surgical treatment.

The extent to which other types of malocclusion are related to genetic influences is less clear, despite the recent advances in understanding the genetic basis of tooth agenesis and eruption failure. If dental variations that contribute to malocclusion are not tightly linked to gene expression, a condition such as open bite could be largely due to external influences—for example, sucking habits or tongue posture. Let us now examine the role of the environment in the etiology of malocclusion.

## Environmental Influences

Environmental influences during growth and development of the face, jaws, and teeth consist largely of pressures and forces related to physiologic activity. A relationship between anatomic form and physiologic function is apparent in all animals. Over evolutionary time, adaptations in the jaws and dental apparatus are prominent in the fossil record. Form-function relationships at this level are controlled genetically and, although important for a general understanding of the human condition, have little to do with any individual's deviation from the current norm.

On the other hand, there is every reason to suspect that form-function relationships during the lifetime of an individual may be significant in the development of malocclusion and dentofacial malformations. Although the changes in body form are minimal, an individual who does heavy physical work has both heavier and stronger muscles and a sturdier skeletal system than one who is sedentary. If function could affect the growth of the jaws, altered function would be a major cause of malocclusion, and it would be logical for chewing exercises and other forms of physical therapy to be an important part of orthodontic treatment. If, however, function makes little or no difference in the individual's pattern of development, altering his or her jaw function would have little if any impact, etiologically or therapeutically. Because of its importance in contemporary orthodontics, particular emphasis is placed here on evaluating potential functional contributions to both the development of dentofacial problems and to relapse after treatment.

## Equilibrium Considerations

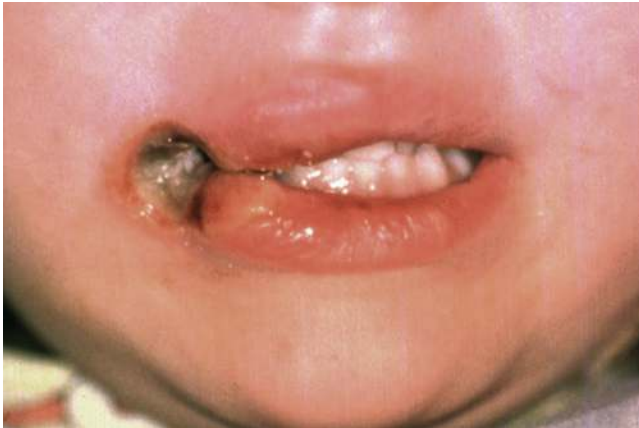
The laws of physics state that an object subjected to unequal forces will be accelerated and thereby will move to a different position in space. It follows that if any object is subjected to a set of forces but remains in the same position, any forces must be in balance or equilibrium. From this perspective, the dentition is obviously in equilibrium because the teeth are subjected to a variety of forces but do not move to a new location under usual circumstances.

The effectiveness of orthodontic treatment is itself a demonstration that forces on the dentition are normally in equilibrium. Teeth normally experience forces from masticatory effort, swallowing, and speaking but do not move. If a tooth is subjected to a continuous force from an orthodontic appliance, it does move, so the force applied by the orthodontist has altered the previous equilibrium. The nature of the forces necessary for tooth movement is discussed in detail in Chapter 8, but at this point, we must briefly preview what is known about force magnitude and force duration in producing changes in tooth position.

A key consideration is that the supporting structures of the dentition (periodontal ligament [PDL] and alveolar bone) are constructed to withstand heavy forces of short duration such as those from mastication. During mastication, the fluid in the PDL space acts as a shock absorber, so that the soft tissues in the PDL are not compressed, although bending of alveolar bone occurs. Only if pressure is maintained long enough to squeeze out the fluid (a few seconds) is there an impact on the soft tissues. Then, because that begins to hurt, the pressure is released and the fluid returns before the next chewing stroke. The result is that only light force of long duration (6 hours or so per day) is important in determining whether there is enough of an imbalance of forces to lead to tooth movement, which means that if the balance between

long-duration pressure from the tongue versus lip or cheek pressure changes, tooth movement would be expected.

It is easy to demonstrate that this is indeed the case. For example, if an injury to the soft tissue of the lip results in scarring and contracture, the adjacent incisors will be moved lingually as the lip tightens against them (Fig. 5.28). On the other hand, if restraining pressure by the lip or cheek is removed, the teeth move outward in response to unopposed pressure from the tongue (Fig. 5.29A). Pressure from the tongue, whether from an enlargement of the tongue from a tumor or other source or because its posture has



• **Fig. 5.28** Scarring of the corner of the mouth in this child will occur as the burn from biting an electrical cord heals. From equilibrium theory, one would expect a distortion in the form of the dental arch in the region of the contracting scar, and exactly this occurs after an injury of this type.

changed, will result in labial displacement of the teeth, even though the lips and cheeks are intact, because the equilibrium has been altered (Fig. 5.29B).

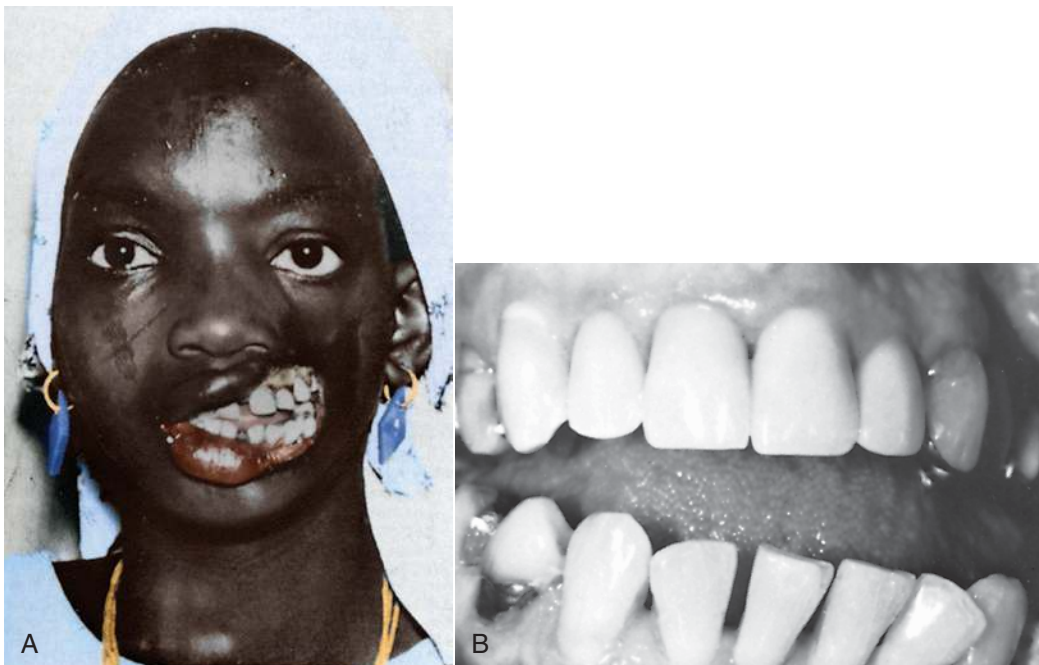These observations make it plain that, in contrast to forces from mastication, light sustained pressures from lips, cheeks, and tongue at rest are important determinants of tooth position. It seems unlikely, however, that the intermittent short-duration pressures created when the tongue and lips contact the teeth during swallowing or speaking would have any significant impact on tooth position. As with masticatory forces, the pressure magnitudes would be great enough to move a tooth, but the duration is inadequate (Table 5.2).

Equilibrium considerations also apply to the skeleton, including the facial skeleton. Skeletal alterations occur all the time in response to functional demands and are magnified under unusual experimental situations. The bony processes to which muscles attach are especially influenced by the muscles and the location of the attachments. The form of the mandible, because it is largely dictated by the shape of its functional processes, is particularly prone to alteration. The density of the facial bones, like the skeleton as a whole, increases when heavy work is done and decreases in its absence.

Let us now consider the role of function in the etiology of malocclusion and dentofacial deformity from this perspective.

### Masticatory Function

The pressures generated by chewing activity potentially could affect dentofacial development in two ways: (1) greater use of the jaws, with higher and/or more prolonged biting force, could increase the dimensions of the jaws and dental arches, or (2) less use of the jaws might lead to underdeveloped dental arches and crowded



• **Fig. 5.29** (A) In this individual, a large part of the cheek was lost because of a tropical infection. Note the outward splaying of the teeth on the affected side after the restraining force of the cheek was lost. (B) After a paralytic stroke, this patient's tongue rested against the mandibular posterior teeth. Before the stroke, the occlusion was normal; within a few months afterward, an outward splaying of the teeth occurred on the affected side because of the increase in resting tongue pressure. (A courtesy Professor J.P. Moss; B courtesy Dr. T. Wallen.)



**TABLE 5.2** Possible Equilibrium Influences: Magnitude and Duration of Force Against the Teeth During Function

Possible Equilibrium Influence	Force Magnitude	Force Duration
<b>Tooth Contacts</b>		
Mastication	Very heavy	Very short
Swallowing	Light	Very short
<b>Soft Tissue Pressures of Lip, Cheek, and Tongue</b>		
Swallowing	Moderate	Short
Speaking	Light	Very short
Resting	Very light	Long
<b>External Pressures</b>		
Habits	Moderate	Variable
Orthodontics	Moderate	Variable
<b>Intrinsic Pressures</b>		
PDL fibers	Light	Long
Gingival fibers	Variable	Long

*PDL, Periodontal ligament.*

and irregular teeth, and the resulting decreased biting force could affect how much the teeth erupt, thereby affecting lower face height and overbite and open bite relationships.

Function and Dental Arch Size

The size and shape of the muscular processes of the jaws reflect muscle size and activity. For example, enlargement of the mandibular gonial angles can be seen in humans with hypertrophy of the mandibular elevator muscles (Fig. 5.30), and changes in the form of the coronoid processes occur in children when temporalis muscle function is altered after injuries. In contrast, the heavy intermittent forces produced during mastication should have little direct effect on tooth positions, so the size of the dental arches would be affected by function only if their bony bases were widened. Does the extent of masticatory activity affect the width of the base of the dental arches? At least to some extent, yes.

It seems likely that differences in jaw size and facial proportions among human racial groups do reflect dietary differences and the accompanying masticatory effort. The characteristic craniofacial morphology of the native population of northern America, which includes broad dental arches, is best explained as an adaptation to the extreme stress they traditionally have placed on jaws and teeth, and changes in craniofacial dimensions from early to modern human civilizations have been related to the accompanying dietary changes.<sup>28</sup> A number of studies by physical anthropologists have indicated that changes in dental occlusion and an increase in malocclusion occur along with transitions from a primitive to a modern diet and lifestyle, to the point that Corruccini has labeled malocclusion a “disease of civilization.”<sup>29</sup> In the context of adaptations to changes in diet over even a few generations, it appears that dietary changes probably have played a role in the modern increase in malocclusion. During the development of a single individual, vertical jaw relationships clearly are affected by muscular activity (the effect on tooth

eruption is discussed later). Whether masticatory effort influences the size of the dental arches and the amount of space for the teeth is not so clear.

Animal experiments with soft versus hard diets have shown that morphologic changes can occur within a single generation when diet consistency is altered. When a pig, for instance, is raised on a soft rather than a normal diet, there are changes in jaw morphology, in the orientation of the jaws to the rest of the facial skeleton, and in dental arch dimensions.<sup>30</sup> In humans, if dietary consistency affects dental arch size and the amount of space for the teeth as an individual develops, it must do so early in life because dental arch dimensions are established early. Is it possible that a preadolescent child’s masticatory effort plays a major role in determining dental arch dimensions? That seems unlikely, but the precise relationship remains unknown.

Biting Force and Eruption

Patients who have excessive overbite or anterior open bite usually have posterior teeth that are infra- or supra-erupted, respectively. It seems reasonable that how much the teeth erupt should be a function of how much force is placed against them during function. Is it possible that differences in muscle strength and therefore in biting force are involved in the etiology of short- and long-face problems?

It was noted some years ago that short-face individuals have higher and long-face persons lower maximum biting forces than those with normal vertical dimensions. The difference between long- and normal-face patients is highly significant statistically for force during occlusal tooth contacts during swallow, simulated chewing, and maximum biting (Fig. 5.31).<sup>31</sup> Such an association between facial morphology and occlusal force does not prove a cause-and-effect relationship. In the rare muscle weakness syndromes discussed earlier, there is a downward and backward rotation of the mandible associated with excessive eruption of the posterior teeth, but this is almost a caricature of the more usual long-face condition, not just an extension of it. Evidence to document decreased occlusal forces in children who are showing the long-face pattern of growth would strengthen a possible causative relationship.

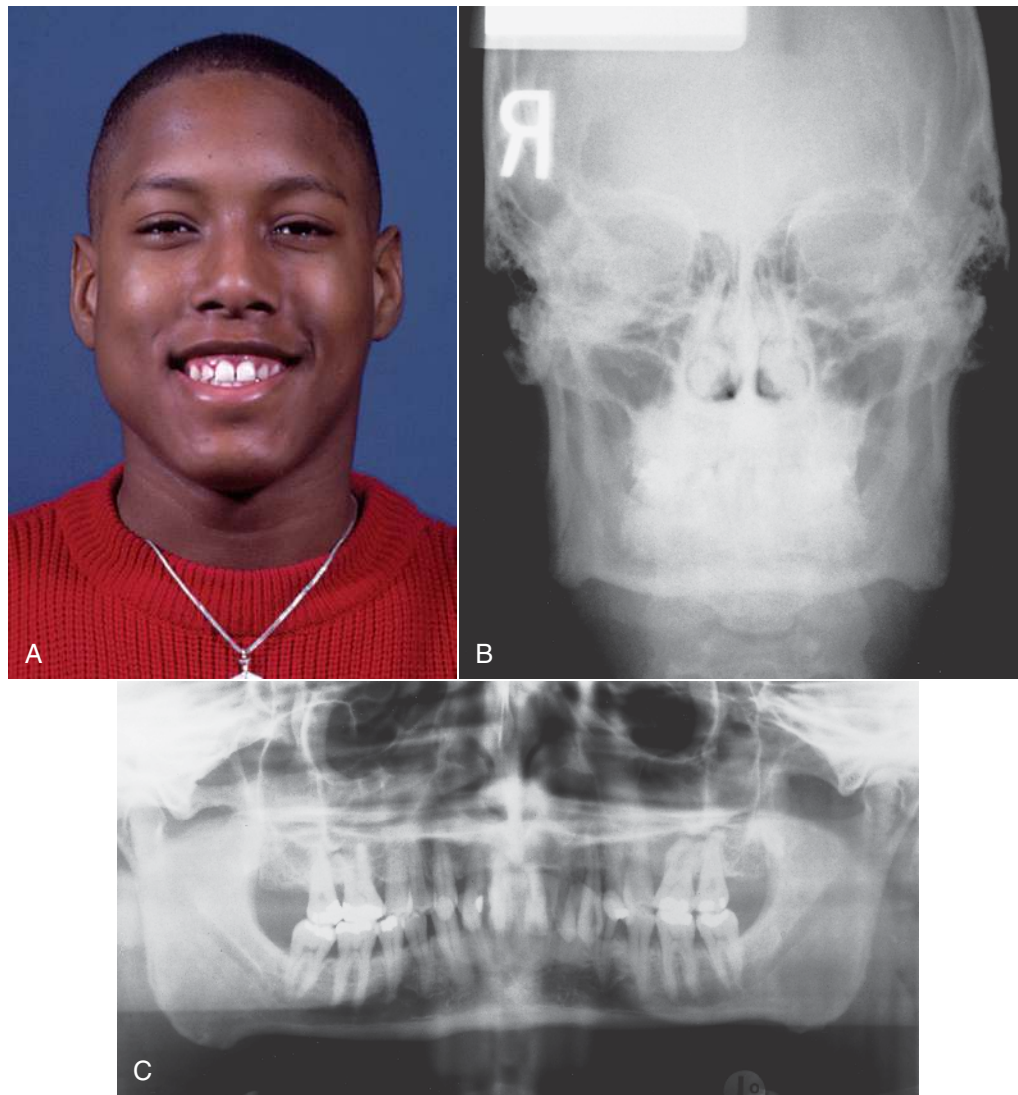
It is possible to identify a long-face pattern of growth in pre-pubescent children. Measurement of occlusal forces in this group produces a surprising result: there are no differences between children with long faces and normal faces, nor between either group of children and long-face adults.<sup>32</sup> All three groups have forces far below those of normal adults (Fig. 5.32). Therefore it appears that the differences in occlusal force arise at puberty, when the normal group gains masticatory muscle strength and the long-face group does not. Because the long-face growth pattern can be identified before the differences in occlusal force appear, it seems more likely that the different biting force is an effect rather than a cause.

These findings suggest that the force exerted by the masticatory muscles is not a major environmental factor in controlling tooth eruption and not an etiologic factor for most patients with deep bite or open bite. The effect of muscular dystrophy and related syndromes shows that there can be definite effects on growth if the musculature is abnormal, but in the absence of syndromes of this type, there is no reason to believe that how a patient bites is a major determinant of either dental arch size or vertical dimensions.

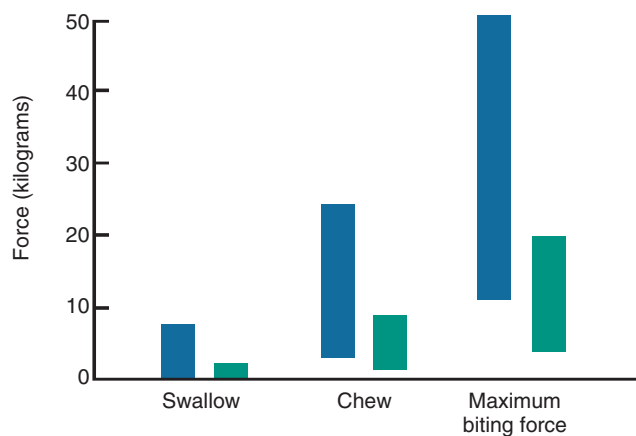
Sucking and Other Habits

Almost all normal children engage in non-nutritive sucking of a thumb or pacifier, and as a general rule, sucking habits during the primary dentition years have little if any long-term effect. If these





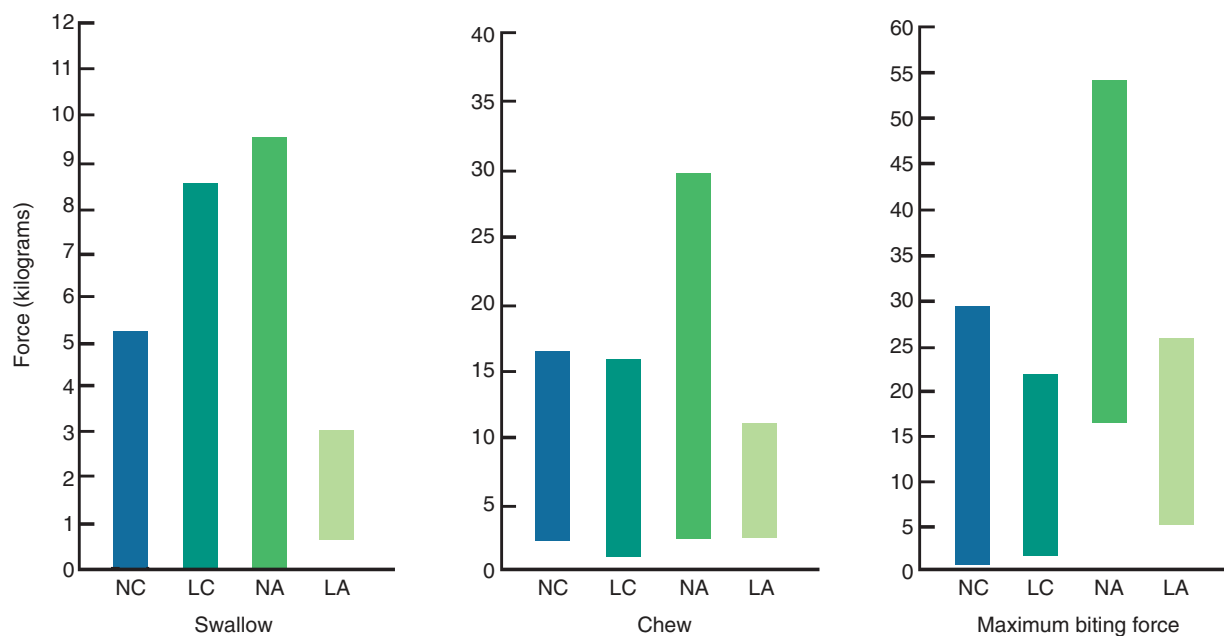
• **Fig. 5.30** Hypertrophy of the masseter muscles leads to excessive bone formation at the angles of the mandible, as would be expected in a bony area that responds to muscle attachment. Note the unusual fullness of the masseteric area, especially on the right side, in the frontal view of the face (A). Bony enlargement at the gonial angles, especially on the right, can be seen in a P-A cephalogram (B) and a panoramic radiograph (C).



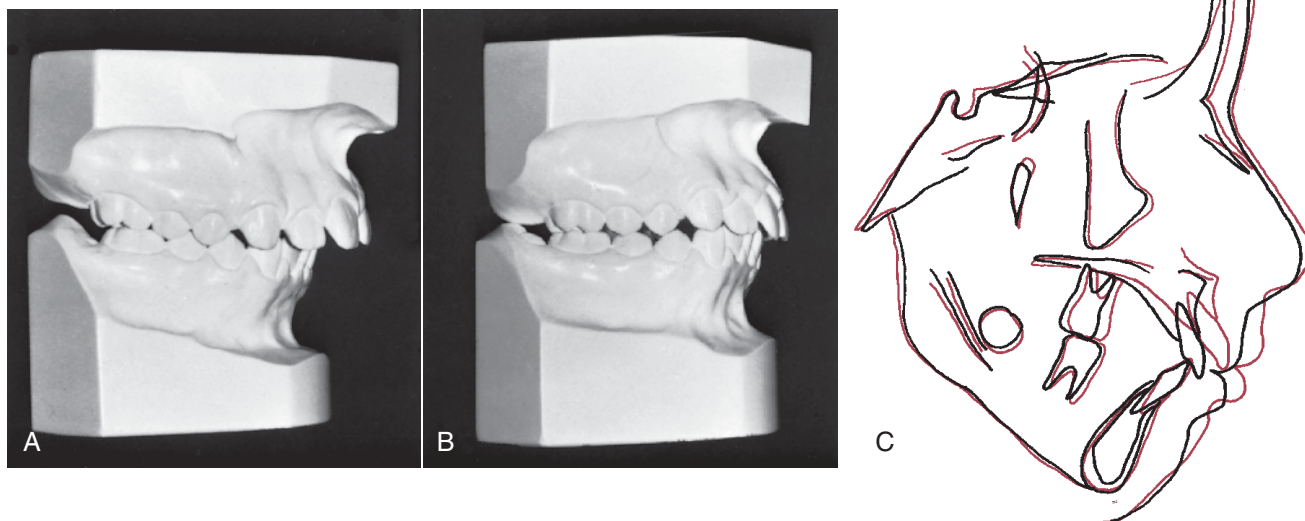
• **Fig. 5.31** Comparison of occlusal force for swallowing, simulated chewing, and maximum effort at 2.5 mm of molar separation in normal face (blue) and long face (green) adults. Note that the normal subjects have much greater occlusal force during swallowing and chewing as well as at maximum effort. The differences are highly significant statistically. (From Proffit WR, Fields HW, Nixon WL. *J Dent Res.* 1983;62:566–571.)

habits persist beyond the time that the permanent teeth begin to erupt, however, malocclusion characterized by flared and spaced maxillary incisors, lingually positioned lower incisors, anterior open bite, and a narrow upper arch is the likely result (Fig. 5.33). The characteristic malocclusion associated with sucking arises from a combination of direct pressure on the teeth and an alteration in the pattern of resting cheek and lip pressures.<sup>33</sup>

When a child places a thumb or finger between the teeth, it is usually positioned at an angle so that it presses lingually against the lower incisors and labially against the upper incisors (Fig. 5.34). There can be considerable variation in which teeth are affected and how much. From equilibrium theory, one would expect that how much the teeth are displaced would correlate better with the number of hours per day of sucking than with the magnitude of the pressure. Children who suck vigorously but intermittently may not displace the incisors much if at all, whereas others, particularly those who sleep with a thumb or finger between the teeth all night, can cause a significant malocclusion.



• **Fig. 5.32** Comparison of occlusal forces in normal-face children (NC, blue), long-face children (LC, aqua), normal-face adults (NA, green), and long-face adults (LA, light green). Values for both groups of children and the long-face adults are similar; values for normal adults are significantly higher than for any of the other three groups. The implication is that the differences in occlusal force in adults result from failure of the long-face group to gain strength during adolescence, not to the long condition itself. (From Proffit WR, Fields HW, Nixon WL. *J Dent Res*. 1983;62:566–571.)



• **Fig. 5.33** In this pair of identical twins, one sucked her thumb up to the time of orthodontic records at age 11 and the other did not. (A) Occlusal relationships in the thumb-sucking girl and (B) her non-thumb-sucking twin. Note the increased overjet and forward displacement of the dentition of the thumb-sucker. (C) Cephalometric tracings of the two girls superimposed on the cranial base of the two girls. As one would expect with identical twins, the cranial base morphology is nearly identical. Note the forward displacement of not only the maxillary dentition but also the maxilla itself. (Courtesy Dr. T. Wallen.)

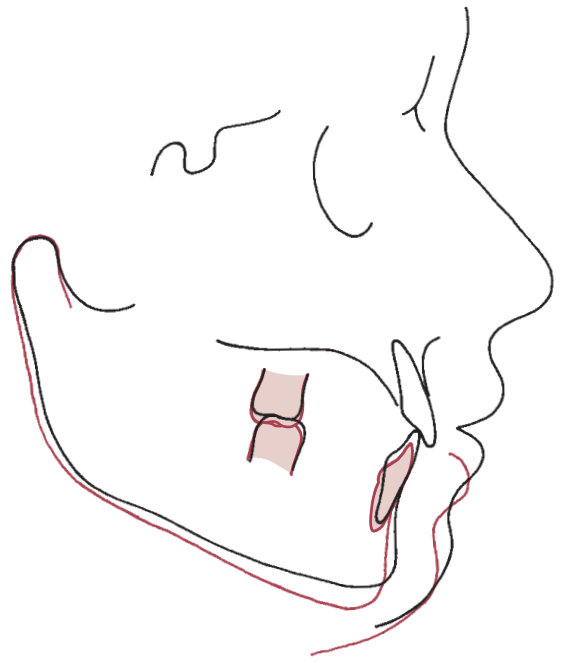


• **Fig. 5.34** A child sucking the thumb usually places it against the roof of the mouth, causing pressure that pushes the lower incisors lingually and the upper incisors labially. In addition, the jaw is positioned downward, providing additional opportunity for posterior teeth to erupt, and cheek pressure is increased while the tongue is lowered vertically away from the maxillary posterior teeth, altering the equilibrium that controls width dimensions. If the thumb is placed on one side instead of in the midline, the symmetry of the arch may be affected.

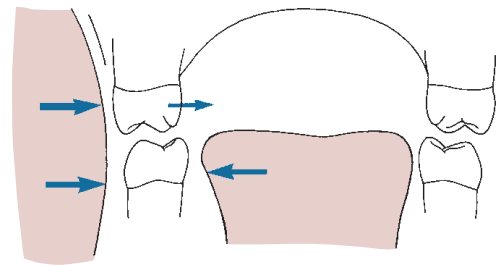
The anterior open bite associated with thumb-sucking arises by a combination of interference with normal eruption of incisors and excessive eruption of posterior teeth. When a thumb or finger is placed between the anterior teeth, the mandible must be positioned downward to accommodate it. The interposed thumb directly impedes incisor eruption. At the same time, the separation of the jaws alters the vertical equilibrium on the posterior teeth, and as a result, there is more eruption of posterior teeth than might otherwise have occurred. Because of the geometry of the jaws, 1 mm of elongation posteriorly opens the bite about 2 mm anteriorly, so this can be a powerful contributor to the development of anterior open bite (Fig. 5.35).

Although negative pressure is created within the mouth during sucking, there is no reason to believe that this is responsible for the narrowing of the maxillary arch that usually accompanies sucking habits. Instead, arch form is affected by an alteration in the balance between cheek and tongue pressures. If the thumb is placed between the teeth, the tongue must be lowered, which decreases pressure by the tongue against the lingual of upper posterior teeth. At the same time, cheek pressure against these teeth is increased as the buccinator muscle contracts during sucking (Fig. 5.36). Cheek pressures are greatest at the corners of the mouth, and this probably explains why the maxillary arch tends to become V-shaped, with more constriction across the canines than the molars. A child who sucks vigorously is more likely to have a narrow upper arch than one who just places the thumb between the teeth.

Mild displacement of the primary incisor teeth is often noted in a 3- or 4-year-old thumb-sucker, but if sucking stops at this stage, normal lip and cheek pressures soon restore the teeth to their usual positions. If the habit persists after the permanent



• **Fig. 5.35** Cephalometric tracing showing the effects of posterior eruption on the extent of anterior opening. The only difference between the red and black tracings is that the first molars have been elongated 2 mm in the red tracing. Note that the result is 4 mm of separation of the incisors because of the geometry of the jaw.



• **Fig. 5.36** Diagrammatic representation of soft tissue pressures in the molar region in a child with a sucking habit. As the tongue is lowered and the cheeks contract during sucking, the pressure balance against the upper teeth is altered, and the upper but not the lower molars are displaced lingually.

incisors have begun to erupt, orthodontic treatment may be necessary to overcome the resulting tooth displacements. It is important to realize that transverse constriction of the maxillary arch is the aspect of the malocclusion least likely to correct spontaneously. In many children with a history of thumb-sucking, if the maxillary arch is expanded transversely, both the incisor protrusion and anterior open bite will improve spontaneously (see Chapter 12). There is no point in beginning orthodontic therapy, of course, until the habit has stopped.

Whether a habit can serve in the same way as an orthodontic appliance to change the position of the teeth has been the subject of controversy since at least the first century AD, when Celsus recommended that a child with a crooked tooth be instructed to

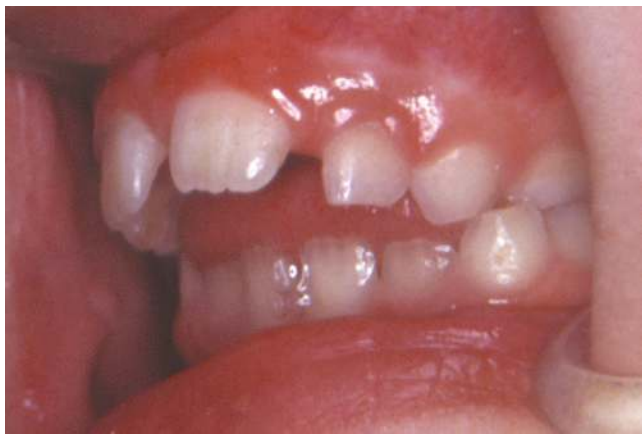apply finger pressure against it to move it to its proper position. From our present understanding of equilibrium, we would expect that this might work but only if the child kept finger pressure against the tooth for 6 hours or more per day.

This concept also makes it easier to understand how playing a musical instrument might relate to the development of a malocclusion. In the past, many clinicians have suspected that playing a wind instrument could affect the position of the anterior teeth, and some have prescribed musical instruments as part of orthodontic therapy. Playing a clarinet, for instance, might lead to increased overjet because of the way the reeds are placed between the incisors, and this instrument could be considered both a potential cause of a Class II malocclusion and a therapeutic device for treatment of Class III malocclusion. String instruments such as the violin and viola require a specific head and jaw posture that affects tongue versus lip and cheek pressures and could produce asymmetries in arch form. Although the expected types of displacement of teeth are seen in professional musicians,<sup>34,35</sup> even in this group the effects are not dramatic, and little or no effect is observed in most children. It seems quite likely that the duration of tongue and lip pressures associated with playing the instrument is too short to make any difference, except for the most devoted musician.

Can habits affect development of the jaws? In Edward Angle's era, a "sleeping habit" in which the weight of the head rested on the chin once was thought to be a major cause of Class II malocclusion. Facial asymmetries have been attributed to always sleeping on one side of the face or even to "leaning habits," as when an inattentive child leans the side of his or her face against one hand to doze without falling out of the classroom chair. It is not nearly as easy to distort the facial skeleton as these views imply. Sucking habits often exceed the time threshold necessary to produce an effect on the teeth, but even prolonged sucking has little impact on the underlying form of the jaws. On close analysis, most other habits have such a short duration that dental effects, much less skeletal effects, are unlikely.

## Tongue Thrusting

Much attention has been paid at various times to the tongue and tongue habits as possible etiologic factors in malocclusion. The possible deleterious effects of "tongue thrust swallowing" (Fig. 5.37), defined as placement of the tongue tip forward between



• **Fig. 5.37** The typical appearance of a "tongue thrust swallow" with the lip pulled back. Note the tongue tip between the incisors protruding forward toward contact with the elevated lower lip.

the incisors during swallowing, still is often thought to be a cause of malocclusion despite the number of studies that have found no such relationship. Let's review what is known now about tongue thrusting as an etiologic factor.

Laboratory studies have indicated that individuals who place the tongue tip forward when they swallow usually do not have more tongue force against the teeth than those who keep the tongue tip back; in fact, tongue pressure may be lower.<sup>36</sup> The term *tongue thrust* is therefore something of a misnomer because it implies that the tongue is forcefully thrust forward. Swallowing is not a learned behavior but is integrated and controlled physiologically at subconscious levels, so whatever the pattern of swallow, it cannot be considered a habit in the usual sense. It is true, however, that individuals with an anterior open bite malocclusion place the tongue between the anterior teeth when they swallow, whereas those who have a normal incisor relationship usually do not, and it is tempting to blame the open bite on this pattern of tongue activity.

As discussed in detail in Chapter 2, the mature or adult swallow pattern appears in some normal children as early as age 3 but is not present in the majority until about age 6 and is never achieved in 10% to 15% of a typical population. Tongue thrust swallowing in older patients superficially resembles the infantile swallow (described in Chapter 3), and sometimes children or adults who place the tongue between the anterior teeth are spoken of as having a retained infantile swallow. This is clearly incorrect. Only brain-damaged children retain a truly infantile swallow in which the posterior part of the tongue has little or no role.

Because coordinated movements of the posterior tongue and elevation of the mandible tend to develop before protrusion of the tongue tip between the incisor teeth disappears, what is called "tongue thrusting" in young children is often a normal transitional stage in swallowing. During the transition from an infantile to a mature swallow, a child can be expected to pass through a stage in which the swallow is characterized by muscular activity to bring the lips together, separation of the posterior teeth, and forward protrusion of the tongue between the teeth. This is also a description of the classic tongue thrust swallow. A delay in the normal swallow transition can be expected when a child has a sucking habit.

When there is an anterior open bite and/or upper incisor protrusion, as often occurs from sucking habits, it is more difficult to seal off the front of the mouth during swallowing to prevent food or liquids from escaping. Bringing the lips together and placing the tongue between the separated anterior teeth is a successful maneuver to close off the front of the mouth and form an anterior seal. In other words, a tongue thrust swallow is a useful physiologic adaptation if you have an open bite, which is why an individual with an open bite usually also has a tongue thrust swallow, but protruding the tongue between the anterior teeth during swallowing is often present in children with good anterior occlusion. After a sucking habit stops, the anterior open bite tends to close spontaneously, but the position of the tongue between the anterior teeth persists for a while as the open bite closes. Until the open bite disappears, an anterior seal by the tongue tip remains necessary.

The modern viewpoint is, in short, that tongue thrust swallowing is seen primarily in two circumstances: in younger children with reasonably normal occlusion, in whom it represents only a transitional stage in normal physiologic maturation; and in individuals of any age with displaced incisors, in whom it is an adaptation to the space between the teeth. The presence of a large overjet (often) and anterior open bite (nearly always) conditions a child or adult to place the tongue between the anterior teeth. A tongue thrust swallow therefore is more likely to be the result of displaced incisors,



not the cause. It follows, of course, that correcting the tooth position should cause a change in swallow pattern, and this usually happens. It is neither necessary nor desirable to try to teach the patient to swallow differently before beginning orthodontic treatment.

This is not to say that the tongue has no etiologic role in the development of open bite malocclusion. From equilibrium theory, light but sustained pressure by the tongue against the teeth would be expected to have significant effects. Tongue thrust swallowing simply has too short a duration to have an impact on tooth position. Pressure by the tongue against the teeth during a typical swallow lasts for approximately 1 second. A typical individual swallows about 800 times per day while awake but only a few times per hour while asleep. The total per day therefore is usually under 1000. One thousand seconds of pressure, of course, totals only a few minutes, not nearly enough to affect the equilibrium.

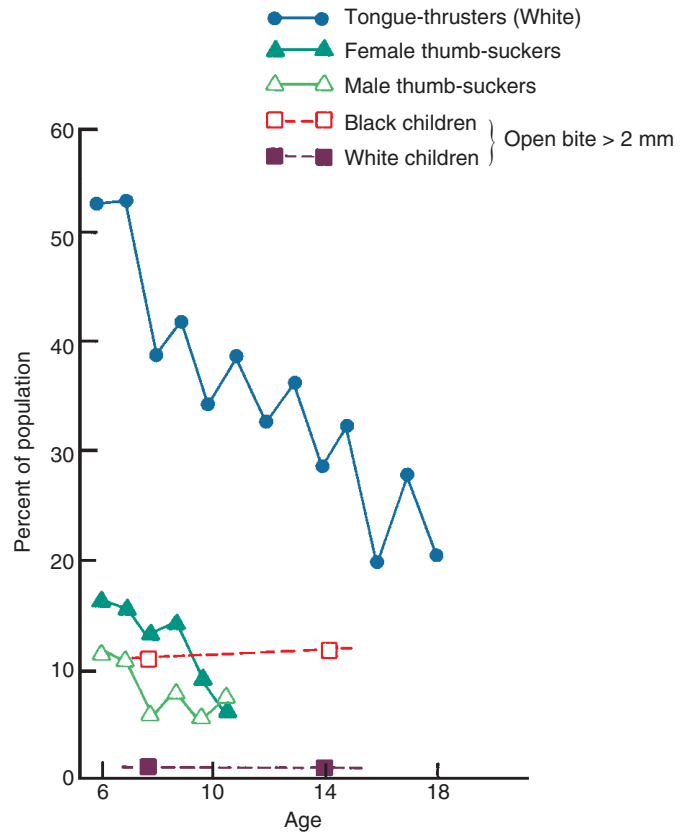
On the other hand, if a patient has a forward resting posture of the tongue, the duration of this light pressure could affect tooth position, vertically or horizontally. Tongue tip protrusion during swallowing is sometimes associated with a forward tongue posture. If the position from which tongue movements start is different from normal, so that the pattern of resting pressures is different, there is likely to be an effect on the teeth, whereas if the postural position is normal, the tongue thrust swallow has no clinical significance.

Perhaps this point can best be put in perspective by comparing the number of children who have an anterior open bite malocclusion with the number of children of the same age reported to have a tongue thrust swallow. As Fig. 5.38 shows, at every age above 6, the number of children reported to have a tongue thrust swallow is about 10 times greater than the number reported to have an anterior open bite. Thus there is no reason to believe that a tongue thrust swallow always implies an altered rest position and will lead to malocclusion. In a child who has an open bite, tongue posture may be a factor, but the swallow itself is not.

## Respiratory Pattern

Respiratory needs are the primary determinant of the posture of the jaws and tongue (and of the head itself, to a lesser extent). Therefore it seems entirely reasonable that an altered respiratory pattern, such as breathing through the mouth rather than the nose, could change the posture of the head, jaw, and tongue. This in turn could alter the equilibrium of pressures on the jaws and teeth and affect both jaw growth and tooth position. To breathe through the mouth, one must lower the mandible and tongue and extend (tip back) the head. If these postural changes were maintained, three effects on growth would be expected: (1) anterior face height would increase, and posterior teeth would super-erupt; (2) unless there was unusual vertical growth of the ramus, the mandible would rotate down and back, opening the bite anteriorly and increasing overjet; and (3) increased pressure from the stretched cheeks might cause a narrower maxillary dental arch.

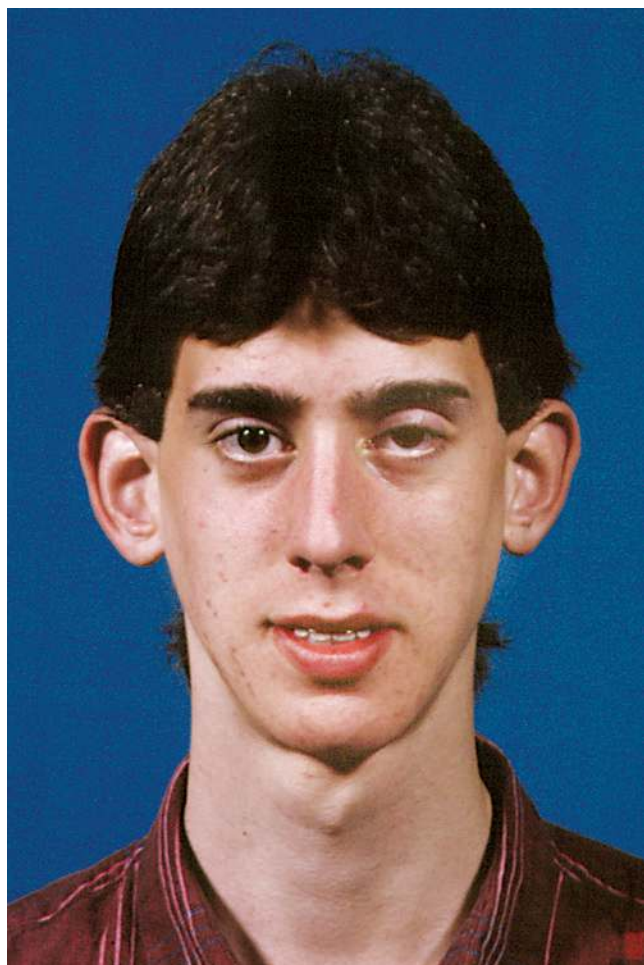Exactly this type of malocclusion often is associated with mouth breathing (note its similarity to the pattern also blamed on sucking habits and tongue thrust swallow). The association has been noted for many years: the descriptive term *adenoid facies* has appeared in the English literature for at least a century, and probably longer (Fig. 5.39). Unfortunately, the relationship among mouth breathing, altered posture, and the development of malocclusion is not so clear-cut as the theoretical outcome of shifting to oral respiration might appear at first glance.<sup>37</sup> Recent experimental studies have only partially clarified the situation.



• **Fig. 5.38** Prevalence of anterior open bite, thumb-sucking, and tongue thrust swallowing as a function of age. Open bite occurs much more frequently in blacks than in whites. Note that the prevalence of anterior open bite at any age is only a small fraction of the prevalence of tongue thrust swallowing and is also less than the prevalence of thumb-sucking. (Data from Fletcher SG, Casteel RL, Bradley DP. *J Speech Hear Disord.* 1961;26:201–208; Kelly JE, et al. DHEW Pub No [HRA] 1977;77–144.)

In analyzing this, it is important to understand first that although humans are primarily nasal breathers, everyone breathes partially through the mouth under certain physiologic conditions, the most prominent being an increased need for air during exercise. For the average individual, there is a transition to partial oral breathing when ventilatory exchange rates above 40 to 45 L/min are reached. At maximum effort, 80 or more L/min of air are needed, about half of which is obtained through the mouth. At rest, minimum airflow is 20 to 25 L/min, but heavy mental concentration or even normal conversation leads to increased airflow and a transition to partial mouth breathing.

During resting conditions, greater effort is required to breathe through the nose than through the mouth; the tortuous nasal passages introduce an element of resistance to airflow as they perform their function of warming and humidifying the inspired air. The increased work for nasal respiration is physiologically acceptable up to a point, and indeed respiration is most efficient with modest resistance present in the system. If the nose is partially obstructed, the work associated with nasal breathing increases, and at a certain level of resistance to nasal airflow, the individual switches to partial mouth breathing. This crossover point varies among individuals but is usually reached at resistance levels of about 3.5 to 4 cm H<sub>2</sub>O/L/min.<sup>38</sup> The swelling of the nasal mucosa accompanying a

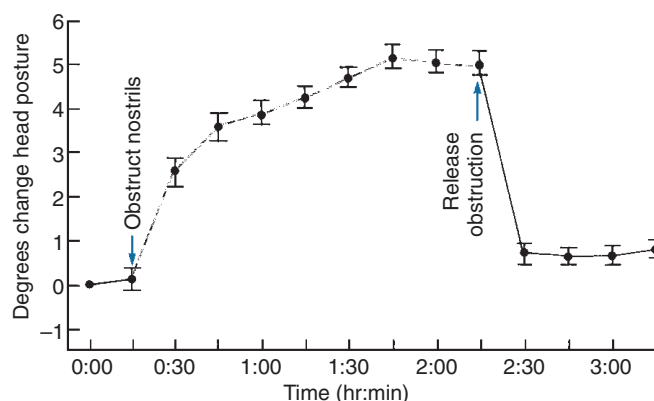


• **Fig. 5.39** The classic adenoid facies, characterized by narrow width dimensions, protruding teeth, and lips separated at rest, has often been attributed to mouth breathing because of enlarged adenoids. Because it is perfectly possible to breathe through the nose with the lips separated, simply by creating an oral seal posteriorly with the soft palate, the facial appearance is not diagnostic of the respiratory mode. On careful study, many patients with this facial type are found not to be obligatory mouth breathers.

common cold occasionally converts all of us to mouth breathing at rest by this mechanism.

Chronic respiratory obstruction can be produced by prolonged inflammation of the nasal mucosa associated with allergies or chronic infection. It can also be produced by mechanical obstruction anywhere within the nasorespiratory system, from the nares to the posterior nasal choanae. Under normal conditions, the size of the nostril is the limiting factor in nasal airflow. The pharyngeal tonsils or adenoids normally are large in children, and partial obstruction from this source may contribute to mouth breathing in children. Individuals who have had chronic nasal obstruction may continue to breathe partially through the mouth even after the obstruction has been relieved. In this sense, mouth breathing can sometimes be considered a habit.

If respiration had an effect on the jaws and teeth, it should do so by causing a change in posture that secondarily altered long-duration pressures from the soft tissues. Experiments with human subjects have shown that a change in posture does accompany nasal obstruction. For instance, when the nose is completely blocked,



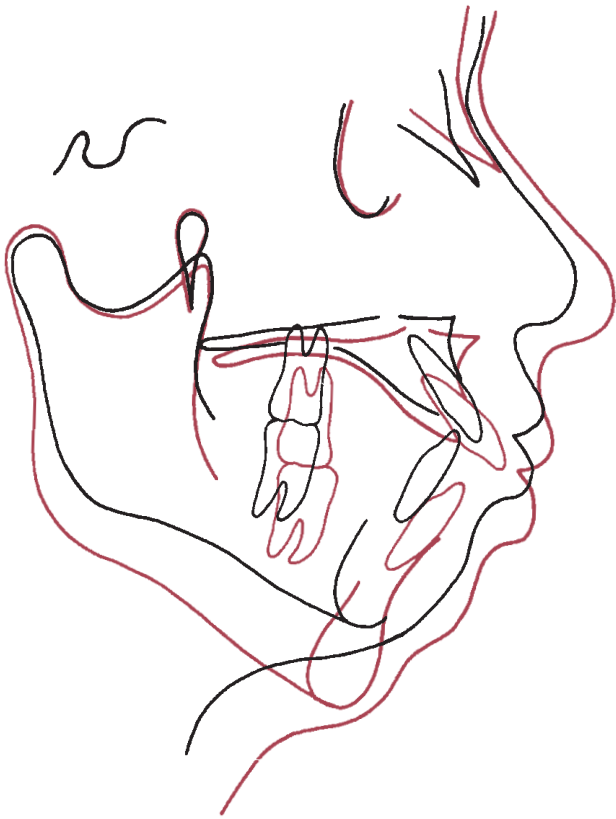
• **Fig. 5.40** Data from an experiment with dental students, showing the immediate change in head posture when the nostrils are totally blocked: The head tips back about 5 degrees, increasing the separation of the jaws. When the obstruction is relieved, head posture returns to its original position. (From Vig PS, Showfety KJ, Phillips C. *Am J Orthod.* 1980;77:258–268.)

usually there is an immediate change of about 5 degrees in the craniovertebral angle (Fig. 5.40). The jaws move apart, as much by elevation of the maxilla, because the head tips back, as by depression of the mandible. When the nasal obstruction is removed, the original posture immediately returns. This physiologic response occurs to the same extent, however, in individuals who already have some nasal obstruction, which indicates that it may not totally result from respiratory demands.

Harvold's classic experiments with growing monkeys showed that totally obstructing the nostrils for a prolonged period in this species leads to the development of malocclusion, but not the type commonly associated with mouth breathing in humans.<sup>39</sup> Instead, the monkeys tend to develop some degree of mandibular prognathism, although their response shows considerable variety. In the evaluation of these experiments, it must be kept in mind that mouth breathing of any extent is completely unnatural for monkeys, who will die if their nasal passages are obstructed abruptly. For these experiments to be carried out, it was necessary to gradually obstruct their noses, giving the animals a chance to learn how to survive as mouth breathers. The variety of responses in the monkeys suggests that the type of malocclusion is determined by the individual animal's pattern of adaptation.

Total nasal obstruction is extremely rare in humans. There are only a few well-documented cases of facial growth in children with long-term total nasal obstruction, but it appears that under these circumstances the growth pattern is altered in the way one would predict (Fig. 5.41). Because total nasal obstruction in humans is so rare, the important clinical question is whether partial nasal obstruction, of the type that occurs occasionally for a short time in everyone and chronically in some children, can lead to malocclusion; more precisely, how close to total obstruction does partial obstruction have to come before it is clinically significant?

The question is difficult to answer, primarily because it is difficult to know what the pattern of respiration really is at any given time in humans. Observers tend to equate lip separation at rest with mouth breathing (see Fig. 5.39), but this is simply not correct. It is perfectly possible for an individual to breathe through the nose while the lips are apart. To do this, the individual only needs to seal off the mouth by placing the tongue against the palate.



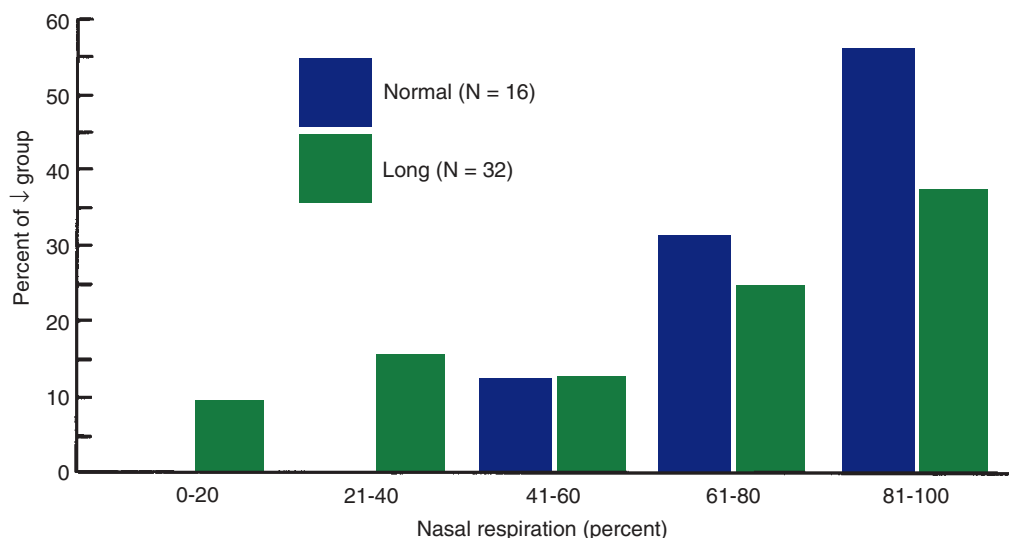
• **Fig. 5.41** Cephalometric superimposition showing the effect of total nasal obstruction produced by a pharyngeal flap operation (for cleft palate speech) that sealed off the nose posteriorly. From age 12 (black) to 16 (red), the mandible rotated downward and backward as the patient experienced considerable growth. (Redrawn from McNamara JA. *Angle Orthod.* 1981;51:269–300.)

Because some lip separation at rest (lip incompetence) is normal in children, many children who appear to be mouth breathers may not be.

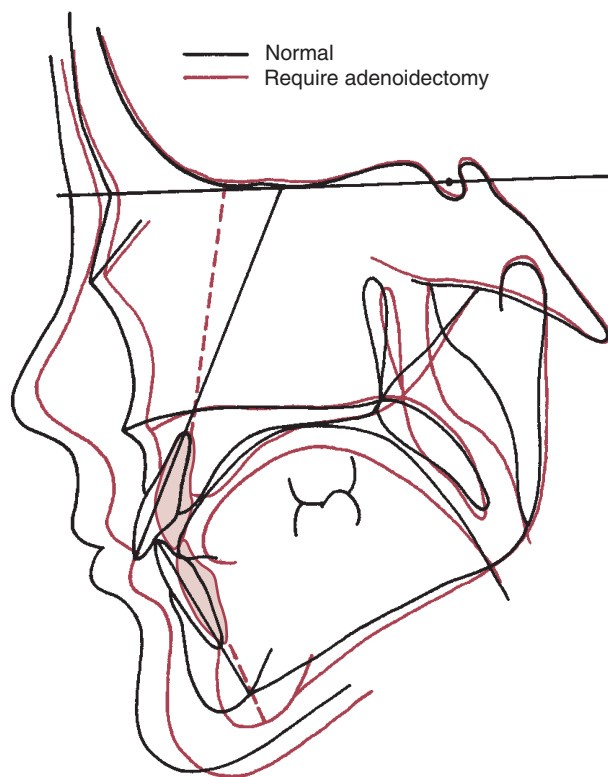
Simple clinical tests for mouth breathing can also be misleading. The highly vascular nasal mucosa undergoes cycles of engorgement with blood and shrinkage. The cycles alternate between the two nostrils: When one is clear, the other is usually somewhat obstructed. For this reason, clinical tests to determine whether the patient can breathe freely through both nostrils nearly always show that one is at least partially blocked. One partially obstructed nostril should not be interpreted as a problem with normal nasal breathing.

The only reliable way to quantify the extent of mouth breathing is to establish how much of the total airflow goes through the nose and how much through the mouth, which requires special instrumentation to simultaneously measure nasal and oral airflow. This allows the percentage of nasal or oral respiration (nasal/oral ratio) to be calculated for the length of time the subject can tolerate being continuously monitored. It seems obvious that a certain percentage of oral respiration maintained for a certain percentage of the time should be the definition of significant mouth breathing, but despite years of effort such a definition has not been produced.

The best experimental data for the relationship between malocclusion and mouth breathing were derived from studies of the nasal/oral ratio in normal versus long-face children.<sup>40</sup> The relationship is not nearly as clear-cut as theory might predict. It is useful to represent the data as in Fig. 5.42, which shows that both normal and long-face children are likely to be predominantly nasal breathers under laboratory conditions. A minority of the long-face children had less than 40% nasal breathing, but none of the normal children had such low nasal percentages. When adult long-face patients are examined, the findings are similar: the number with evidence of nasal obstruction is increased in comparison to a normal population, but the majority are not mouth breathers in the sense of predominantly oral respiration.



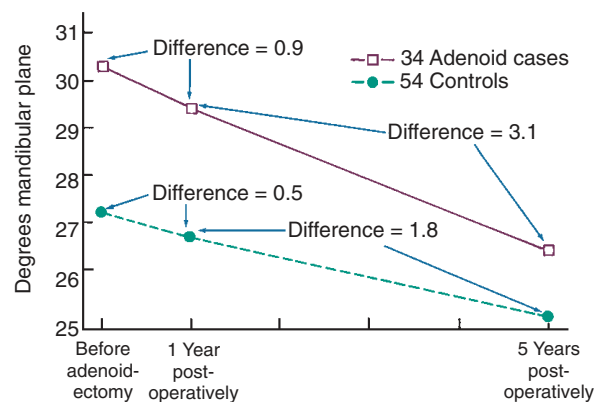
• **Fig. 5.42** Comparison of the percentage of nasal respiration in long-face versus normal-face adolescents. About one-third of the long-face group have less than 50% nasal respiration, whereas none of the normal-face group have such a low nasal percentage, but most of the long-face group are predominantly nasal breathers. The data suggest that impaired nasal respiration may contribute to the development of the long-face condition but is not the sole or even the major cause. (Data redrawn from Fields HW, Warren DW, Black K, et al. *Am J Orthod Dentofac Orthop.* 1991;99:147–154.)



• **Fig. 5.43** Composite (mean) cephalometric tracings for a group of Swedish children requiring adenoidectomy for medical purposes, compared with a group of normal controls. The adenoidectomy group had statistically significantly greater anterior face height and steeper mandibular plane angles than the controls, but the differences were quantitatively not large. The tracing is oriented with the nose to the left, as it is done routinely in Europe, because it was originally published that way. (From Linder-Aronson S. *Acta Otolaryngol Scand.* 1970;[suppl]:265.)

It seems reasonable to presume that children who require adenoidectomy and/or tonsillectomy for medical purposes, or those diagnosed as having chronic nasal allergies, would have some degree of nasal obstruction. Studies of Swedish children who underwent adenoidectomy showed that on the average, children in the adenoidectomy group had a significantly longer anterior face height than control children (Fig. 5.43). They also had a tendency toward maxillary constriction and more upright incisors.<sup>41</sup> Furthermore, when children in the adenoidectomy group were followed after their treatment, they tended to return toward the mean of the control group, although the differences persisted (Fig. 5.44). Similar differences from normal control groups were seen in other groups requiring adenoidectomy and/or tonsillectomy.<sup>42</sup>

Although the differences between normal children and those in the allergy or adenoidectomy groups were statistically significant and undoubtedly real, they were not large. Face height on the average was about 3 mm greater in the adenoidectomy group. It appears therefore that research to this point on respiration has established two opposing principles, leaving a large gray area between them: (1) total nasal obstruction is highly likely to alter the pattern of growth and lead to malocclusion in experimental animals and humans, and individuals with a high percentage of oral respiration are over-represented in the long-face population; but (2) the majority of individuals with the long-face pattern of deformity have no



• **Fig. 5.44** Comparison of mandibular plane angles in a group of post-adenoidectomy children compared with normal controls. Note that the differences existing at the time of adenoidectomy decreased in size but did not totally disappear. (From Linder-Aronson S. In: Cook JT, ed. *Transactions of the Third International Orthodontic Congress.* St. Louis: Mosby; 1975.)

evidence of nasal obstruction and must therefore have some other etiologic factor as the principal cause. Perhaps the alterations in posture associated with partial nasal obstruction and moderate increases in the percentage of oral respiration are not great enough by themselves to create a severe malocclusion. Mouth breathing, in short, may contribute to the development of orthodontic problems but is difficult to indict as a frequent etiologic agent.

It is interesting to consider the other side of this relationship: can malocclusion sometimes cause respiratory obstruction? Sleep apnea has been recognized recently as a more frequent problem than had been appreciated,<sup>43</sup> and it is apparent that mandibular deficiency can contribute to its development. Its etiology, however, is by no means determined just by orofacial morphology; obesity, age, gender, and jaw relationships seem to be important, in that order. The orthodontist's role in treatment of sleep apnea and current recommendations for types of treatment are discussed in Chapter 7.

## Etiology in Contemporary Perspective

Part of the philosophy of the early orthodontists was their belief in the perfectibility of man. Edward Angle and his contemporaries, influenced by the romanticized view of primitive peoples commonly held in the late 19th and early 20th centuries, took for granted that malocclusion was a disease of civilization and blamed it on improper function of the jaws under the "degenerate" modern conditions. Changing jaw function to produce proper growth and improve facial proportions was an important goal of treatment, which unfortunately proved difficult to achieve.

Classic (mendelian) genetics developed rapidly in the first part of the 20th century, and a different view of malocclusion gradually replaced the earlier one. This new view was that malocclusion is primarily the result of inherited dentofacial proportions, which might be altered somewhat by developmental variations, trauma, or altered function, but which are basically established at conception. If that were true, the possibilities for orthodontic treatment also would be rather limited. The orthodontist's role would be to adapt the dentition to the existing facial structures, with little hope of producing underlying changes.



In the 1980s there was a strong swing back toward the earlier view, as the failure of heredity to explain most variation in occlusion and jaw proportions was appreciated and as the new theories of growth control indicated how environmental influences could operate by altering posture. The earlier concept that jaw function is related to the development of malocclusion was revived and strengthened, both by the evidence against simple inheritance and by a more optimistic view of the extent to which the human skeleton can be altered. Clinical applications, some already recognized as unfortunate, reflected extreme optimism about arch expansion and growth modification.

As the 21st century moves ahead, a more balanced view seems to be emerging. Contemporary research has refuted the simplistic picture of malocclusion as resulting from independent inheritance of dental and facial characteristics, but the research findings consistently have shown also that there are no simple explanations for malocclusion in terms of oral function. Mouth breathing, tongue thrusting, soft diet, sleeping posture—none of these can be regarded as the sole or even the major reason for most malocclusions. Along the same lines, it is fair to say that the research has not yet clarified the precise role of heredity as an etiologic agent for malocclusion. The relatively high heritability of craniofacial dimensions and the relatively low heritability of dental arch variations now have been established, but exactly how this relates to the etiologic process of malocclusions that have both skeletal and dental components remains unknown. Conclusions about the etiology of most orthodontic problems are difficult because several interacting factors probably played a role. At least, at this point we are more aware of how much we really do not yet know about the etiology of orthodontic problems.

## References

- Suttie M, Faroud T, Wetherill L, et al. Facial dysmorphism across the fetal alcohol spectrum. *Pediatrics*. 2013;131:e779–e788.
- Naidoo S, Norval G, Swanevelder S, et al. Foetal alcohol syndrome: a dental and skeletal age analysis of patients and controls. *Eur J Orthod*. 2006;28:247–253.
- Macaya D, Katsanis SH, Hefferon TW, et al. A synonymous mutation in TCOF1 causes Treacher Collins syndrome due to mis-splicing of a constitutive exon. *Am J Med Genet A*. 2009;149:1624–1627.
- Sulik KK, Johnston MC, Smiley SJ, et al. Mandibulofacial dysostosis (Treacher Collins syndrome): a new proposal for its pathogenesis. *Am J Med Genet*. 1987;27:359–372.
- Brandstetter KA, Patel KG. Craniofacial microstomia. *Facial Plast Surg Clin North Am*. 2016;24:495–515.
- Sulik KK. Orofacial embryogenesis: a framework for understanding clefting sites. In: Fonseca RJ, Marciani RD, Turvey TA, eds. *Oral and Maxillofacial Surgery*. Vol. 3. 3rd ed. St. Louis: Elsevier; 2017 [chap 27].
- Bennun RD, Harfin JF, Sándor GK, Genecov D. *Cleft Lip and Palate Management: A Comprehensive Atlas*. Hoboken, NJ: John Wiley & Sons; 2015.
- Hovorokova M, Lesot H, Peterkova R, Peterka M. Origin of the deciduous upper lateral incisor and its clinical aspects. *J Dent Res*. 2006;85:167–171.
- Li Z, Liu J, Ye R, et al. Maternal passive smoking and risk of cleft lip with or without cleft palate. *Epidemiology*. 2010;21:240–242.
- Tessier P. Anatomical classification of facial, craniofacial and latero-facial clefts. *J Maxillofac Surg*. 1976;4:69–92.
- Uria AF, Mundlinger GS, Bellamy JJ, et al. The importance of timing in optimizing cranial vault remodeling in syndromic craniosynostosis. *Plast Reconstr Surg*. 2015;135:1077–1084.
- Helman SN, Badhey A, Kadakia S, Myers E. Revisiting Crouzon syndrome: reviewing the background and management of a multifaceted disease. *Oral Maxillofac Surg*. 2014;18:373–379.
- Suri S, Ross RB, Thompson BD. Craniofacial morphology and adolescent facial growth in Pierre Robin sequence. *Am J Orthod Dentofacial Orthop*. 2010;137:763–774.
- Yu CC, Wong FH, Lo LJ, et al. Craniofacial deformity in patients with uncorrected congenital muscular torticollis: an assessment from three-dimensional computed tomography imaging. *Plast Reconstr Surg*. 2004;113:24–33.
- Kiliaridis S, Katsaros C. The effects of myotonic dystrophy and Duchenne muscular dystrophy on the orofacial muscles and dentofacial morphology. *Acta Odontol Scand*. 1998;56:369–374.
- Obwegeser HL. *Mandibular Growth Anomalies*. Berlin: Springer-Verlag; 2000.
- Fleseriu M, Delashaw JB Jr, Cook DM. Acromegaly: a review of current medical therapy and new drugs on the horizon. *Neurosurg Focus*. 2010;29:E15.
- Carlson DS. Evolving concepts of heredity and genetics in orthodontics. *Am J Orthod Dentofacial Orthop*. 2015;148:922–938.
- Stockard CR, Johnson AL. *Genetic and Endocrine Basis for Differences in Form and Behavior*. Philadelphia: The Wistar Institute of Anatomy and Biology; 1941.
- Chung CS, Niswander JD, Runck DW, et al. Genetic and epidemiologic studies of oral characteristics in Hawaii's schoolchildren. II. Malocclusion. *Am J Hum Genet*. 1971;23:471–495.
- Hughes T, Thomas C, Richards L, et al. A study of occlusal variation in the primary dentition of Australian twins and singletons. *Arch Oral Biol*. 2001;46:857–864.
- Corruccini RS, Sharma K, Potter RH. Comparative genetic variance and heritability of dental occlusal variables in U.S. and northwest Indian twins. *Am J Phys Anthropol*. 1986;70:293–299.
- Harris EF, Johnson MG. Heritability of craniometric and occlusal variables: a longitudinal sib analysis. *Am J Orthod Dentofacial Orthop*. 1991;99:258–268.
- Johannsdottir B, Thorarinsson F, Thordarson A, et al. Heritability of craniofacial characteristics between parents and offspring estimated from lateral cephalograms. *Am J Orthod Dentofacial Orthop*. 2005;127:200–207.
- Suzuki A, Takahama Y. Parental data used to predict growth of craniofacial form. *Am J Orthod Dentofacial Orthop*. 1991;99:107–121.
- Cruz RM, Krieger H, Ferreira R, et al. Major gene and multifactorial inheritance of mandibular prognathism. *Am J Med Genet A*. 2008;146:71–77.
- Moreno-Urbe LM, Howe SC, Kummel C, et al. Phenotypic diversity in white adults with moderate to severe Class II malocclusions. *Am J Orthod Dentofacial Orthop*. 2014;145:305–316.
- Larsen CS. *Bioarchaeology: Interpreting Behavior from the Human Skeleton*. Cambridge: Cambridge University Press; 1997.
- Corruccini RS. Anthropological aspects of orofacial and occlusal variations and anomalies. In: Kelly MA, Larsen CS, eds. *Advances in Dental Anthropology*. New York: Wiley-Liss; 1991.
- Ciochon RL, Nisbett RA, Corruccini RS. Dietary consistency and craniofacial development related to masticatory function in minipigs. *J Craniofac Genet Dev Biol*. 1997;17:96–102.
- Proffit WR, Fields HW, Nixon WL. Occlusal forces in normal and long face adults. *J Dent Res*. 1983;62:566–571.
- Proffit WR, Fields HW. Occlusal forces in normal and long face children. *J Dent Res*. 1983;62:571–574.
- Dogrammaci EJ, Rossi-Fedele G. Establishing the association between non-nutritive sucking behavior and malocclusions. *J Am Dent Assn*. 2016;147:926–936.
- Grammatopoulos E, White AP, Dhoptkar A. Effects of playing a wind instrument on the occlusion. *Am J Orthod Dentofacial Orthop*. 2012;141:138–145.
- Kovero O, Kononen M, Pirinen S. The effect of professional violin and viola playing on the bony facial structures. *Eur J Orthod*. 1997;19:39–45.

36. Proffit WR. Lingual pressure patterns in the transition from tongue thrust to adult swallowing. *Arch Oral Biol.* 1972;17:555–563.
37. Vig KW. Nasal obstruction and facial growth: the strength of evidence for clinical assumptions. *Am J Orthod Dentofacial Orthop.* 1998;113:603–611.
38. Warren DW, Mayo R, Zajac DJ, et al. Dyspnea following experimentally induced increased nasal airway resistance. *Cleft Palate Craniofac J.* 1996;33:231–235.
39. Harvold EP, Tomer BS, Vargervik K, et al. Primate experiments on oral respiration. *Am J Orthod.* 1981;79:359–372.
40. Fields HW, Warren DW, Black K, Phillips C. Relationship between vertical dentofacial morphology and respiration in adolescents. *Am J Orthod Dentofacial Orthop.* 1991;99:147–154.
41. Linder-Aronson S. Adenoids: their effect on mode of breathing and nasal airflow and their relationship to characteristics of the facial skeleton and dentition. *Acta Otolaryngol Scand.* 1970;265:1–132.
42. Woodside DG, Linder-Aronson S, Lundstrom A, et al. Mandibular and maxillary growth after changed mode of breathing. *Am J Orthod Dentofacial Orthop.* 1991;100:1–18.
43. Kim KB. How has our interest in the airway changed over 100 years? *Am J Orthod Dentofacial Orthop.* 2015;148:740–747.

# Diagnosis and Treatment Planning

The process of orthodontic diagnosis and treatment planning fits very well with the contemporary problem-oriented approach to health care more generally. Diagnosis in orthodontics, as in other disciplines of dentistry and medicine, requires the collection of an adequate database of information about the patient and the distillation from that database of a comprehensive but clearly stated list of the patient's problems. It is important to recognize that both the patient's perceptions and the doctor's observations are needed in formulating the problem list. Then the task of treatment planning is to synthesize the possible solutions to these specific problems (often there are many possibilities) into a specific treatment strategy that would provide maximum benefit for this particular patient. Carrying out diagnosis and treatment planning in a series of logical steps, which are outlined in an overview of the entire process in the figure on page 139, is recommended.

Keep in mind that diagnosis and treatment planning, although part of the same process, are different procedures with fundamentally different goals. In the development of a diagnostic database and formulation of a problem list, the goal is truth—the facts about the patient's situation and problems. At this stage there is no room for opinion or judgment. Instead, a totally factual appraisal of the situation is required. On the other hand, the goal of treatment planning is not scientific truth, but wisdom—the plan that a wise and prudent clinician would follow to maximize benefit for the patient.

The first two steps shown in the figure constitute diagnosis:

1. Development of an adequate diagnostic database
2. Formulation of a problem list (the diagnosis) from the database

Both pathologic and developmental problems may be present. If so, pathologic problems should be separated from the developmental ones so that they can receive priority for treatment because pathologic conditions must be under control before treatment of developmental problems begins. The diagnostic process is outlined in detail in [Chapter 6](#).

Diagnosis must be made scientifically; treatment planning cannot involve science alone, because judgment by the clinician is required as problems are prioritized and as alternative treatment possibilities are evaluated. For this reason, treatment planning inevitably is something of an art form. Wise treatment choices, of course, are facilitated if no significant points have been overlooked previously and if it is realized that treatment planning is an interactive process requiring that the patient be given a role in the decision-making process.

As you can see in the figure, the first step in treatment planning is to put the patient's problems in a priority order, based on what is most important to him or her. Could patients with the same problem list appropriately end up with different treatment plans? *Yes*, because problem lists that are prioritized differently usually will produce different plans.

Once a patient's orthodontic problems have been identified and prioritized, four issues must be faced in determining the optimal treatment plan: (1) the timing of treatment, (2) the complexity of the treatment that would be required, (3) the predictability of success with a given treatment approach, and (4) the patient's (and parents') goals and desires. These issues are considered briefly in the next paragraphs.

## Timing

Orthodontic treatment can be carried out at any time during a patient's life and can be aimed at a specific problem or can be comprehensive. Usually, treatment is comprehensive (i.e., with a goal of the best possible occlusion, facial esthetics, and stability) and is undertaken in adolescence, as the last permanent teeth are erupting. There are good reasons for this choice. At this point, for most patients there is sufficient growth remaining to potentially improve jaw relationships, and all permanent teeth, including the second molars, can be controlled and placed in a more or less final position. From a psychosocial point of view, patients in this age group often are reaching the point of self-motivation for treatment, which is evident in their improved ability to cooperate during appointments and in appliance and oral hygiene care. A reasonably short course of treatment in early adolescence, as opposed to two stages of early and later treatment, fits well within the cooperative potential of patients and families.

Even though not all patients respond well to treatment during adolescence, treatment at this time remains the gold standard against which other approaches must be measured. For a child with obvious malocclusion, does it really make sense to start treatment early in the preadolescent years? Obviously, timing will depend on the specific problems. Issues in the timing of treatment are reviewed in detail in [Chapters 7](#) and [13](#).

## Treatment Complexity

The complexity of the treatment that would be required affects treatment planning, especially in the context of who should do the treatment. In orthodontics, as in all areas of dentistry, it makes sense that the less complex cases would be selected for treatment in general or family practice, whereas the more complex cases would be referred to a specialist. The only difference in orthodontics is that traditionally the family practitioner has referred a larger number of orthodontic cases. In family practice, an important issue is how you rationally select patients for treatment or referral. [Chapter 11](#) includes a formal scheme for separating children most appropriate for treatment in family practice from those more likely to require complex treatment. A similar scheme for adults is shown in [Chapter 18](#).

## Predictability and Success With Treatment Methods

If alternative methods of treatment are available, as usually is the case, which one should be chosen? Data gradually are accumulating

to allow choices to be based on evidence of outcomes rather than the frequently unsubstantiated claims of advocates and anecdotal case reports. The use of outcomes data as a basis for deciding what the best treatment approach might be is emphasized in [Chapter 7](#).

## Patient Interaction in Planning

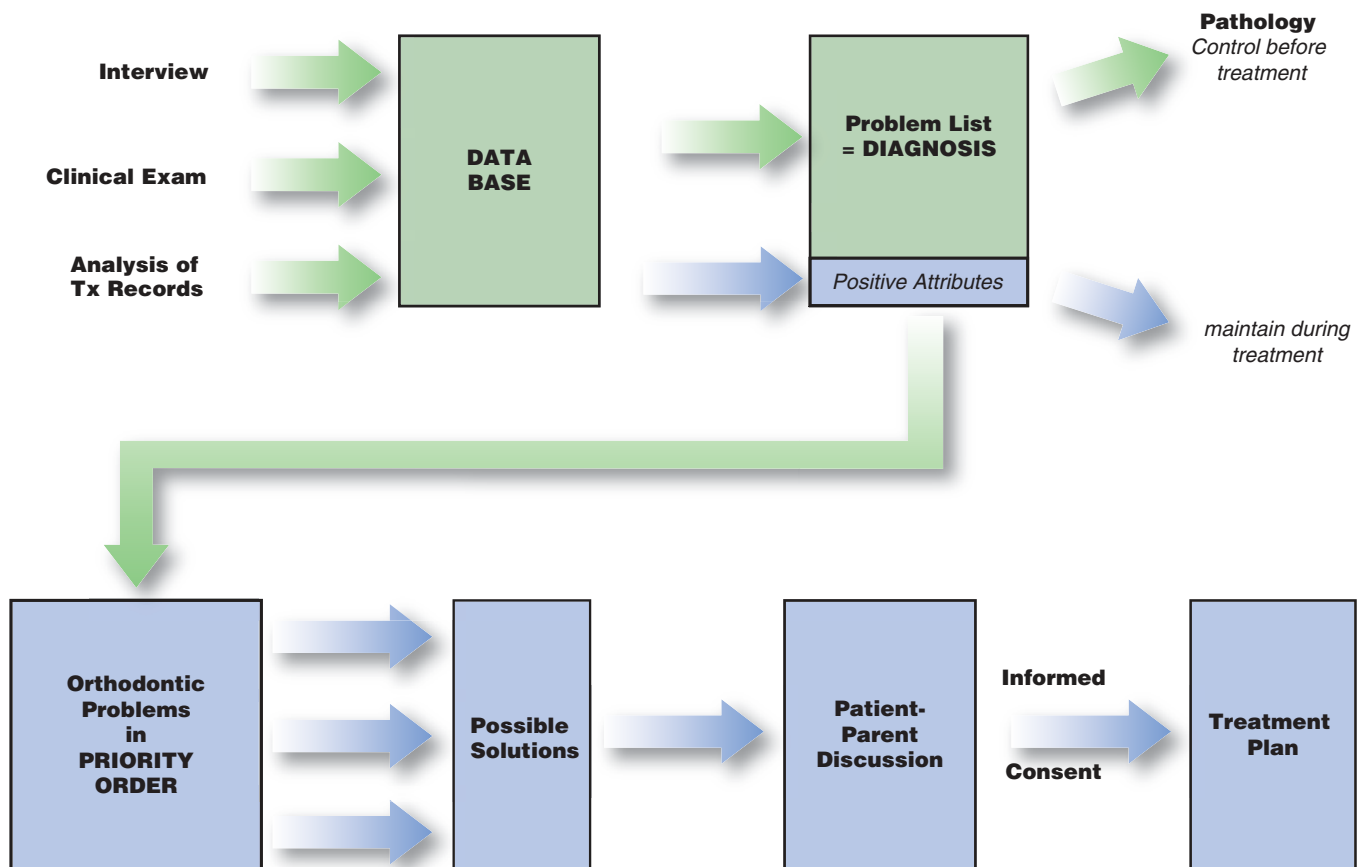
Finally, but most important, treatment planning must be an interactive process. No longer can the doctor decide, in a paternalistic way, what is best for a patient. Both ethically and practically, patients must be involved in the decision-making process. Ethically, patients have the right to control what happens to them in treatment—treatment is something done *for* them, not *to* them. Practically, the patient's compliance is likely to be a critical issue in success or failure, and there is little reason to select a mode of treatment that the patient would not support. Informed consent, in its modern form, requires involving the patient in the treatment planning process. This is emphasized in the procedure for presenting treatment recommendations to patients in [Chapter 7](#).

The logical sequence for treatment planning, with these issues in mind, is as follows:

1. Prioritization of the items on the orthodontic problem list so that the most important problem receives highest priority for treatment
2. Consideration of possible solutions to each problem, with each problem evaluated for the moment as if it were the only problem the patient had
3. Evaluation of the interactions among possible solutions to the individual problems
4. Development of alternative treatment approaches, with consideration of benefits to the patient versus risks, costs, and complexity
5. Determination of a final treatment concept, with input from the patient and parent, and selection of the specific therapeutic approach (appliance design, mechanotherapy) to be used

This process culminates in a level of patient–parent understanding of the treatment plan that allows informed consent to treatment. In most instances, after all, orthodontic treatment is elective rather than required. Rarely is there a significant health risk from no treatment, so functional and esthetic benefits must be compared with risks and costs. Interaction with the patient is required to develop the plan in this way.





# 6

## Orthodontic Diagnosis: The Problem-Oriented Approach

### CHAPTER OUTLINE

#### Questionnaire and Interview

- Chief Concern
- Medical and Dental History
- Physical Growth Evaluation
- Social and Behavioral Evaluation

#### Clinical Evaluation

- Oral Health
- Jaw and Occlusal Function
- Facial and Dental Appearance

#### Diagnostic Records

- Which Diagnostic Records Are Needed?
- Analysis of Diagnostic Records

#### Orthodontic Classification

- Development of Classification Systems
- Additions to the Five-Characteristics Classification System
- Classification by the Characteristics of Malocclusion

#### Development of a Problem List

In diagnosis, whether in orthodontics or other areas of dentistry or medicine, it is important not to concentrate so closely on one aspect of the patient's overall condition that other significant problems are overlooked. In contemporary orthodontics, this is particularly true because patients' concerns and priorities are often critical determinants of treatment plans, and it can be difficult sometimes for the orthodontist not to "rush to judgment" during the initial examination. A natural bias of any specialist (and one does not have to be a dental specialist to already take a very specialized point of view) is to characterize problems in terms of his or her own special interest. This bias must be recognized and consciously resisted.

Diagnosis, in short, must be comprehensive and not focused on only a single aspect of what in many instances can be a complex situation. Orthodontic diagnosis requires a broad overview of the patient's situation and must take into consideration both objective and subjective findings. It is important not to characterize the dental occlusion while overlooking a jaw discrepancy, developmental syndrome, systemic disease, periodontal problem, psychosocial problem, or the cultural milieu in which the patient is living.

The problem-oriented approach to diagnosis and treatment planning has been widely advocated in medicine and dentistry as

a way to overcome the tendency to concentrate on only one aspect of a patient's problems. The essence of the problem-oriented approach is to develop a comprehensive database of pertinent information so that no problems will be overlooked. For orthodontic purposes, the database may be thought of as derived from three major sources: (1) interview data from questions (written and oral) of the patient (and parents, if appropriate); (2) clinical examination of the patient; and (3) evaluation of diagnostic records, including dental casts, radiographs, and photographs. Because all possible diagnostic records will not be obtained for all patients, one of the objectives of the clinical examination is to determine what diagnostic records are needed.

At all stages of the diagnostic evaluation, a specialist may seek more detailed information than would a generalist, and this is a major reason for referring a patient to a specialist. The specialist is likely to obtain more extensive and required diagnostic records, some of which may not be readily available to a generalist. In orthodontics, cephalometric radiographs and cone beam computed tomography (CBCT) are examples. Nevertheless, the basic approach is the same for any orthodontic patient and any practitioner. For any patient, both the generalist and the specialist should want the same information and records. A competent generalist will follow the same sequence of steps in evaluating a patient as an orthodontist would and will use the same approach in planning treatment if he or she will do the orthodontics. After all, from both legal and ethical perspectives, the same standard of care is required whether the treatment is rendered by a generalist or specialist.

### Questionnaire and Interview

The goals of the interview process are to establish the patient's chief concern (major reason for seeking consultation and treatment) and to obtain further information about three major areas: (1) medical and dental history; (2) physical growth status; and (3) motivation, expectations, and other social and behavioral factors. In orthodontic specialty practice, it can be quite helpful to send the patient an interview form to fill out before the first visit to the office.

#### Chief Concern

An example of a form focused on the chief concern, which could be sent to the patient in advance or used as an outline for the interview with the patient, is shown in Fig. 6.1. Note its emphasis on learning the extent to which the child, parent, or adult patient is concerned about facial appearance. A form to elicit the medical and dental history, which should be filled out in advance, would accompany it. The medical history form becomes an outline for

Patient Name: _____	Date: _____
---------------------	-------------

**Are you interested in: (Please indicate all that apply)**

☐ Information

☐ Treatment at this time

☐ Clarification of previously received or conflicting information

**If your child's teeth were to be changed, how would you like them changed?**

☐ Upper teeth                      Forward/Backward

☐ Lower teeth                      Forward/Backward

☐ Upper teeth up because gums show too much

☐ Close spaces                      Upper/Lower

☐ Straighten crowded teeth      Upper/Lower

☐ Improve the appearance of chipped/cracked/stained/dark/pointed teeth

**Do you realize that growth has a strong influence on the success of orthodontic treatment?**

Yes \_\_\_\_\_ No \_\_\_\_\_

**Is it likely that your son or daughter will be an early maturer or late maturer?**

Early \_\_\_\_\_ Late \_\_\_\_\_

**How tall do you think this child will be when growth is completed? \_\_\_\_ ft \_\_\_\_ inches**

**Are you aware that orthodontic treatment can to some extent alter facial appearance?**

Yes \_\_\_\_\_ No \_\_\_\_\_

**If any features of the face could be changed, what would you like to see:**

☐ Upper lip                      Forward/Backward

☐ Lower lip                      Forward/Backward

☐ Upper jaw                      Forward/Backward

☐ Lower jaw                      Forward/Backward

☐ Chin                      Larger/Smaller

☐ Nose                      Larger/Smaller/Different Shape

**Would you prefer that facial appearance NOT be discussed in front of your child?**

Yes \_\_\_\_\_ No \_\_\_\_\_

**Is there any significant family history of jaw or teeth problems?**

\_\_\_\_\_

**Are you interested in improving the appearance of the teeth at this time even if more treatment will be needed later? Yes \_\_\_\_\_ No \_\_\_\_\_**

_____ Signature	_____ Relationship to Patient
--------------------	----------------------------------

• **Fig. 6.1** Finding out what patients and/or parents really want can be difficult and is often not revealed by the chief complaint on a past medical history. This type of a supplemental form that really attempts to quantify their desires can help direct the initial interview when filled out in advance. (Adapted from Dr. Alan Bloore.)

follow-up questions and discussion because so many parents and patients do not list things they think are of no relevance to orthodontics.

As we have discussed in some detail in [Chapter 1](#), there are three major reasons for patient concern about the alignment and occlusion of the teeth: impaired dentofacial appearance and a diminished sense of social well-being, impaired function, and impaired oral health. Although more than one of these reasons often may contribute to seeking orthodontic treatment, it is important to establish their relative importance to the patient. The dentist should not assume that appearance is the patient's major concern just because the teeth appear unesthetic. Nor should the dentist focus on the functional implications of, for instance, a crossbite with a lateral shift without appreciating the patient's

concern about what seems to be a trivial space between the maxillary central incisors. For an individual with reasonably normal function and appearance and reasonable psychosocial adaptation, the major reason for seeking treatment may well be a desire to enhance appearance beyond the normal, thus potentially improving quality of life (QOL). The greater orientation of modern family practice toward cosmetic dentistry increases the chance that a patient may be referred to an orthodontist for comprehensive treatment simply to enhance dental and facial appearance.

When patients inquire about whether they need orthodontic treatment, a series of leading questions should be asked, beginning with, "Do you think you need braces?" If the answer is yes, one might next inquire "What bothers you more about your teeth, your bite or your appearance?" and "What do you want treatment

to do for you?” The answer to that and follow-up questions will clarify what is most important to the patient. The dentist or orthodontist may or may not agree with the patient’s assessment; that judgment comes later. At this stage, the objective is to find out what is important to the patient.

## Medical and Dental History

Orthodontic problems are almost always the culmination of a developmental process, not the result of a pathologic condition. As the discussion in [Chapter 5](#) illustrates, often it is difficult to be certain of the etiology, but it is important to establish the cause of malocclusion if this can be done and at least rule out some of the possible causes—trauma, habits, periodontal disease, growth disturbance, and so on. A careful medical and dental history is needed for orthodontic patients, both to provide a proper background for understanding the patient’s overall situation and to evaluate specific concerns.

The outline of an appropriate medical and dental history is presented in [Fig. 6.2](#). Many of the items are annotated to explain their implications for an orthodontic patient. Three areas deserve a special comment. First, although most children with a condylar fracture of the mandible recover uneventfully, remember that a growth deficit related to an old injury is the most probable cause of true facial asymmetry ([Fig. 6.3](#)). It has become apparent in recent years that early fractures of the condyle occur more frequently than was previously thought (see [Chapter 5](#)). A mandibular fracture in a child can easily be overlooked in the aftermath of an accident that caused other injuries, so a jaw injury may not have been diagnosed at the time. Although old jaw fractures have particular significance, trauma to the teeth may also affect the development of the occlusion and treatment. Knowing when a traumatic dental

injury occurred and the type of injury can help guide your treatment recommendations, and should not be overlooked.

Second, it is important to note whether the patient is on long-term medication of any type and, if so, for what purpose. This may reveal systemic disease or metabolic problems that the patient did not report in any other way. Chronic medical problems in adults or children do not contraindicate orthodontic treatment if the medical problem is under control, but special precautions may be necessary if orthodontic treatment is to be carried out. For example, orthodontic treatment would be possible in a patient with controlled diabetes but would require especially careful monitoring because the periodontal breakdown that could accompany loss of control might be accentuated by orthodontic forces (see [Chapter 8](#)).

Third, many children and adults now survive serious illness and seek orthodontic treatment afterward. Cancer chemotherapy and radiation therapy aimed at head and neck tissues can result in morphologic impacts such as short roots or missing teeth (see [Fig. 12.3](#)). In adults being treated for arthritis or osteoporosis, and now increasingly also in children with acute and chronic disease treated with drugs (such as glucocorticoids) that can be toxic to bone, high doses of resorption-inhibiting agents such as bisphosphonates often are used. This impedes orthodontic tooth movement and may increase the chance of complications (see [Chapter 8](#)). It is necessary to ask specifically about these medications because parents or patients sometimes do not mention things they think are not related to orthodontic treatment.

## Physical Growth Evaluation

A second major area that should be explored with questions to the patient or parents is the individual’s physical growth status. This is

• **Fig. 6.2** (A) A comprehensive form for obtaining the medical and dental history for young orthodontic patients. A separate but similar form is needed for adult patients. Parents need to be told that it is important to report medical conditions and medications because many can affect orthodontic treatment. Updating these forms at least annually is also important as a follow-up. The considerations below explain the basis of some of the questions posed in this medical history form.

HAS YOUR CHILD BEEN HOSPITALIZED, RECEIVED GENERAL ANESTHESIA, OR HAD EMERGENCY DEPARTMENT VISITS: This helps establish a history of serious health problems, anesthetic complications and trauma;

ARE YOUR CHILD’S IMMUNIZATIONS UP TO DATE: In the instance of oral-facial trauma, the DPT status is critical. Soft tissue injury is increased with appliances in place;

DOES YOUR CHILD HAVE ALLERGIES: This helps identify allergies to all types of allergens. One must also consider latex used in dental treatment gloves and elastics and Nickel found in orthodontic appliances. These sensitivities appear to be increasing in the population;

HEART ISSUES: Some patients need antibiotic coverage during banding and debanding procedures;

BLOOD/INFECTIOUS DISEASE: With modern infection control procedures, these patients can be treated normally, but the treatment may need to be modified;

CANCER: This will help determine whether treatments using radiation, chemotherapy, and glucocorticoids altered dental development, jaw growth, somatic growth, or bone density, depending on the site of the lesion and the treatment type and timing;

SLEEP PROBLEMS/SNORING: This can be indicative of sleep apnea, which may limit or increase the need for certain types of treatments for jaw problems;

TONSIL/ADENOID/SINUS PROBLEMS: This can help with evaluation of respiratory problems and tooth sensitivity;

RADIATION: Radiation therapy to the jaws can greatly alter local dental and skeletal development. The risk of osteoradionecrosis is also elevated in these patients depending on the radiation dosage and the type of treatment under consideration;

GROWTH PROBLEMS: Some children with growth problems may be treated with growth hormones, which can have implications for growth modification treatment timing. In some cancer patients, growth hormones can be part of the postradiation treatment regimen. This, too, can affect treatment timing;

ATTENTION DEFICIT DISORDERS: These can be treated with numerous drugs. The effect on growth of some of these medications is unclear;

BONE OR JOINT/ARTHRITIS: This may relate to mandibular growth and development and the types of medications that can control the disease, such as glucocorticoids that can cause bone density problems as a related issue to these problems; and

CANCER treatments: Bisphosphonates are used to treat the effects of some cancer and bone treatments that slow bone resorption while at the same time inhibiting tooth movement, so that orthodontic treatment is limited.



### MEDICAL HISTORY (Child/Adolescent)

PATIENT NAME: \_\_\_\_\_ DATE: \_\_\_\_\_

BIRTH DATE: \_\_\_\_\_

Name of your child's physician: \_\_\_\_\_

Office Phone: \_\_\_\_\_

Address of your child's physician: \_\_\_\_\_

Date of last exam: \_\_\_\_\_

1. Is your child in good health? ..... Yes No Don't know
2. Does your child have a health problem? ..... Yes No Don't know  
If yes, explain: \_\_\_\_\_
3. Has your child ever been hospitalized, had general anesthesia, or emergency room visits? ..... Yes No Don't know  
If yes, explain: \_\_\_\_\_
4. Are your child's immunizations up to date? ..... Yes No Don't know
5. Does your child have allergies to medications (drugs), medical products (latex), or the environment (dust, mites, pollen, mold)? ..... Yes No Don't know  
If yes, please list: \_\_\_\_\_
6. List past medications taken by child: \_\_\_\_\_
7. List daily medications child is now taking: \_\_\_\_\_
8. Has your child ever had or been treated by a physician for: \_\_\_\_\_

Check one for each condition

Yes	No	?		Yes	No	?	
			a. Problems at birth				p. Cancer
			b. Heart murmur				q. Cerebral palsy
			c. Heart disease				r. Seizures
			d. Rheumatic fever				s. Asthma
			e. Anemia				t. Cleft lip/palate
			f. Sickle cell anemia				u. Speech or hearing problems
			g. Bleeding/hemophilia				v. Eye problems/contact lenses
			h. Blood transfusion				w. Skin problems/snoring
			i. Hepatitis				x. Tonsil/adenoid/sinus problems
			j. AIDS or HIV+				y. Sleep problems
			k. Tuberculosis				z. Emotional/behavior problems
			l. Liver disease				aa. Radiation therapy
			m. Kidney disease				bb. Growth problems
			n. Diabetes				cc. Attention deficit disorders
			o. Arthritis				dd. Osteoporosis (bisphosphonates)

9. Has your child had any recent rapid growth? \_\_\_\_\_ If so, how much? \_\_\_\_\_
10. Parents: (Father) Ht: \_\_\_\_\_ Wt: \_\_\_\_\_ (Mother) Ht: \_\_\_\_\_ Wt: \_\_\_\_\_
11. Older brothers and sisters: (1) Ht: \_\_\_\_\_ Wt: \_\_\_\_\_ (2) Ht: \_\_\_\_\_ Wt: \_\_\_\_\_ (3) Ht: \_\_\_\_\_ Wt: \_\_\_\_\_
12. Females: Has menstruation begun? \_\_\_\_\_ If yes, when? \_\_\_\_\_ Pregnant? \_\_\_\_\_  
Using birth control pills? \_\_\_\_\_
13. If yes to any above, please explain this or any other problem: \_\_\_\_\_  
\_\_\_\_\_
14. Child's grade in school: \_\_\_\_\_ Child's school: \_\_\_\_\_
15. Do you consider your child to be (check one): Advanced in learning \_\_\_\_ Progressing normally \_\_\_\_  
Slow learner \_\_\_\_

<b>DENTAL HISTORY</b>			
16.		What is your main concern about your child's dental condition? _____	
17.		Has your child been to a dentist before? No Yes If yes, date of last visit: _____	
18.		Regular dentist's name: _____	
19.		Check one for each condition:	
	Yes	No	?
			a. Has your child ever had dental x-rays? Date of last x-rays? _____
			b. Will your child be uncooperative? If yes, explain: _____
			c. Has your child experienced any complications following dental treatment? If yes, explain: _____
			d. Has your child had cavities and / or toothaches?
			e. Are your child's teeth sensitive to temperature or food?
			f. Did you or your child ever get instructions in brushing?
			g. Do your child's gums bleed when brushed?
			h. Does your child use fluoride products: rinses, drops, tabs?
			i. Does or has your child had any clicking or pain in the jaw joint?
			j. Does or has your child had any problems opening or closing their mouth?
			k. Has your child inherited any family facial or dental characteristics? If yes, explain: _____
			l. Has your child ever injured his/her teeth?
			m. Has your child ever injured his/her jaws or face?
			n. Does or did your child use a pacifier?
			o. Does or did your child suck his/her fingers or thumb?
20.		Does your child have any other dental problems we should know about? _____ Please explain: _____	
21.		Whom may we thank for referring you to our office? _____	
22.		PERSON COMPLETING THIS FORM: Signature _____	
		Relationship to patient: _____	

B

• **Fig. 6.2, cont'd** (B) Considerations in understanding the Dental History form:

**RAPID GROWTH AND PARENTS/SIBLINGS GROWTH:** This helps establish growth status and timing.

**MAIN CONCERN:** The chief complaint is critical to determine why the patient is seeking care. This must be considered carefully in the planning of the treatment.

**X-RAYS:** Reduction in unnecessary radiation is critical to the highest quality care. Many practitioners will request films as part of the examination procedures. Patients seeking second opinions often have already had some records obtained.

**BLEEDING GUMS:** Orthodontic treatment in the face of periodontal disease, either acute or chronic, is contraindicated until the disease stage is either controlled or reversed.

**OPENING/CLOSING MOUTH:** A previous history of temporomandibular joint (TMJ) problems or treatment merits pretreatment investigation. Limitations or problems with opening, closing, or translation can indicate TMJ problems.

**FAMILY FACIAL AND DENTAL CHARACTERISTICS:** Familial tendency is indicated in some skeletal patterns, and missing teeth have a documented genetic component;

**INJURY TO TEETH?** Dental trauma may have implications during tooth movement because of the increased possibility of pulpal necrosis and root resorption;

**PACIFIER/THUMB or FINGER SUCKING:** Habits may explain some aspects of the malocclusion;

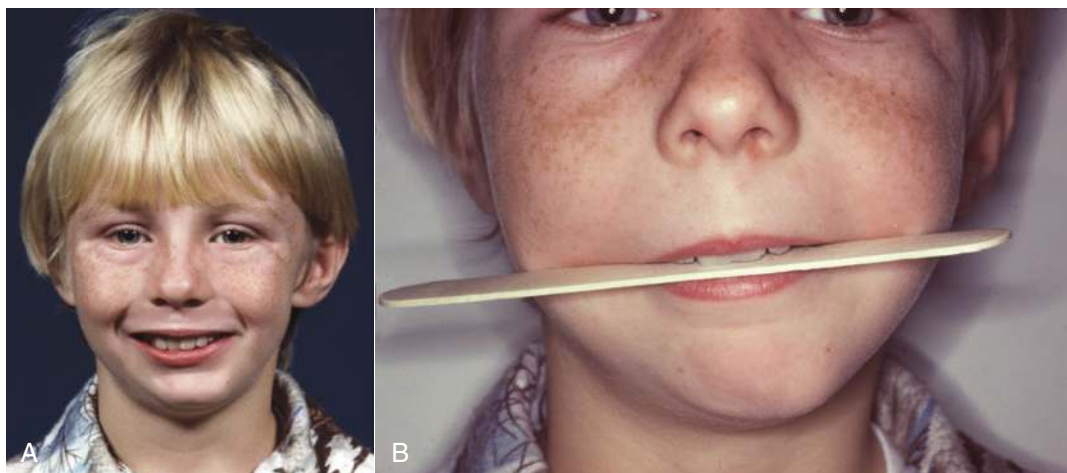
**PERSON COMPLETING FORM:** This helps establish the authenticity of the historian.

important for many reasons, not the least of which is the gradient of facial growth discussed in [Chapters 2 to 4](#). Rapid growth during the adolescent growth spurt facilitates tooth movement, but any attempt at growth modification will surely fail in a child who is beyond the peak of the adolescent growth spurt.

For normal youths who are approaching puberty, several questions usually provide the necessary information about where the child is on the growth curve: How rapidly has the child grown recently? Have clothes sizes changed recently? Are there signs of

sexual maturation? When did sexual maturation occur in older siblings? Valuable information can also be obtained from observing the stage of secondary sexual characteristics (which are described in some detail in [Chapter 4](#)).

If a child is being followed for referral to an orthodontist at the optimum time or by an orthodontist for observation of growth before beginning treatment, height and weight changes can provide insight into the patient's overall growth status and mandibular growth status, given that statural growth and mandibular growth



• **Fig. 6.3** (A) Facial asymmetry developed in this boy after fracture of the left mandibular condylar process at age 5 because scarring in the fracture area prevented normal translation of the mandible on that side during growth. See [Chapter 2](#). (B) Note the cant to the occlusal plane and the resulting roll deformity illustrated in more detail in [Fig. 6.78](#). This develops as failure of the mandible to grow vertically on the affected side restricts eruption of both maxillary and mandibular teeth. Trauma is the most frequent cause of asymmetry of this type.

are generally related (see [Fig. 2.4](#) for current charts). In many instances, height–weight records and the child’s progress on growth charts can be obtained from the pediatrician.

Another approach is to get an estimate of how much mandibular growth remains, which would be especially important for a child with a skeletal Class II problem who would benefit from orthodontic treatment to modify growth if that is possible. This can be done by determining mandibular growth timing from the vertebrae as seen in a cephalometric radiograph (see [Fig. 3.12](#)).<sup>1</sup> If vertebral maturation shows delayed skeletal development, the mandibular growth spurt probably still is in the future. The stage of dental development should *not* be used to estimate the stage of jaw growth. As we emphasized earlier (see [Fig. 3.13](#)), that correlates less well with skeletal growth than almost any other developmental index.

Unfortunately, the stage of vertebral development is less useful in establishing whether jaw growth has subsided to adult levels in a teenager with mandibular prognathism. Hand–wrist radiographs are an alternative method for evaluating skeletal maturity, but these also are not an accurate way to determine when growth is completed.<sup>2</sup> Serial cephalometric radiographs offer the most accurate way to determine whether facial growth has stopped or is continuing, because you are not inferring future facial growth changes, but measuring them.

## Social and Behavioral Evaluation

Social and behavioral evaluation should explore several related areas: the patient’s motivation for treatment, what he or she expects as a result of treatment, and how cooperative or uncooperative the patient is likely to be. Information from the preliminary form that the parent filled out in advance of the initial appointment (see [Fig. 6.1](#)) can be very helpful in evaluating this.

Motivation for seeking treatment can be classified as external or internal. External motivation is supplied by pressure from another individual, as with a reluctant child who is being brought for

orthodontic treatment by a determined mother, or with an adult who is seeking alignment of incisor teeth because her new significant other wants her teeth to look better. Internal motivation, on the other hand, comes from within the individual and is based on his or her own assessment of the situation and desire for treatment. Even quite young children can encounter difficulties in their interaction with others because of their dental and facial appearance, which sometimes produces a strong internal desire for treatment. Other children with apparently similar malocclusions do not perceive a problem, and so are less motivated internally. Older patients usually are aware of psychosocial difficulties or functional problems related to their malocclusion and so are likely to have some component of internal motivation.

Although now some preadolescent children express a desire to have “an appliance” or “braces” because many of their peers are having early treatment, it is rare to find strong internal motivation in that age group. To them, orthodontics usually is something they have to do because a parent requires it. Self-motivation for treatment often does not develop until adolescence. Nevertheless, even in preadolescents, it is important for a patient to have a component of internal motivation. Cooperation is likely to be much better if the patient genuinely wants treatment for himself or herself, rather than just putting up with it to please a parent. Children or adults who feel that the treatment is being done *for* them will be much more receptive patients than those who view the treatment as something being done *to* them.

What the patient expects from treatment is very much related to the type of motivation and should be explored carefully with adults, especially those with primarily cosmetic problems. It is one thing to undertake to correct spacing between the maxillary incisors to improve a patient’s appearance and dental function, and something else to do this because the patient expects that he or she will experience greater social or job success. If the social problems continue after treatment, as is quite likely, the orthodontic treatment may become a focus for resentment.

Cooperation is more likely to be a problem with a child than an adult. Two factors are important in determining this: (1) the extent to which the child sees the treatment as a benefit, as opposed to something else he or she is required to undergo; and (2) the degree of parental control or parenting style. The best cooperation with treatment most probably will be achieved with authoritative (not authoritarian) parents who will be demanding but responsive to their children. Resentful and rebellious adolescents, or those who do as they wish with little parental concern or involvement, are especially likely to become a problem in treatment. It is important to take the time to understand what the patient perceives his or her problems to be and, if necessary, to help the patient appreciate the reality of the situation (see the final section of [Chapter 2](#)). They also must understand their role in helping fix the problem and things associated with the treatment process such as food choices and oral hygiene.

Any patient who is under the legal age (which varies among states and countries but most often is 18) cannot legally consent to treatment. The bioethical standard is that he or she should at least assent to treatment. With child or adolescent patients of any age, ask “If your parents and I think that you would benefit from orthodontic treatment, are you willing to help with that?” Treating an unwilling child, even if the parents force an apparent assent, rarely is good judgment.

## Clinical Evaluation

There are two goals of the orthodontic clinical examination: to (1) evaluate and document oral health, jaw function, facial proportions, and smile characteristics and (2) decide which diagnostic records are required.

### Oral Health

The health of oral hard and soft tissues must be assessed for potential orthodontic patients as for any other. The general guideline is that before orthodontic treatment begins, any disease or pathologic condition must be under control. This includes medical problems,

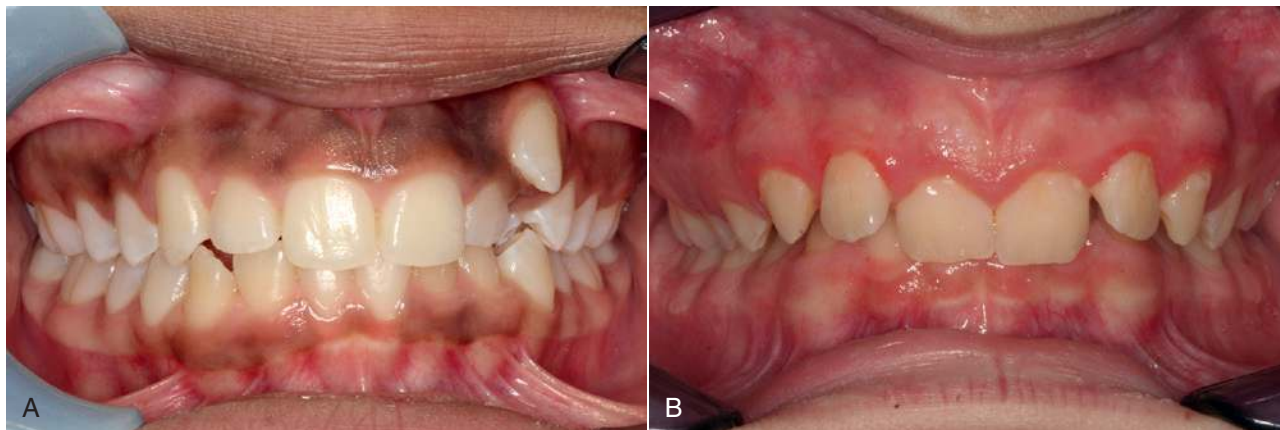
dental caries or pulpal pathologic condition, and periodontal disease. The developmental status of the patient must also be documented.

It sounds trivial to say that the dentist should not overlook the number of teeth that are present or forming, yet almost every dentist, concentrating on details rather than the big picture, has done just that on some occasion. It is particularly easy to fail to notice a missing or supernumerary lower incisor. At some point in the evaluation, count the teeth either clinically or radiographically to be sure they are all there.

In the periodontal evaluation, there are two major points of interest: indications of active periodontal disease, and potential or actual mucogingival problems. The patient's oral hygiene status should be recorded and documented by clinical photographs ([Fig. 6.4](#)). Having appliance therapy will make tooth cleaning more difficult and can lead to destruction of various amounts of the hard and soft tissues, and for a potential patient with inadequate oral hygiene, pretreatment improvement of oral hygiene should be required. Any orthodontic examination should include gentle probing through the gingival sulci, not so much to establish pocket depths as to detect any areas of bleeding. Bleeding on probing indicates inflammation that may extend into the periodontal ligament, and this must be brought under control before orthodontic treatment is undertaken.

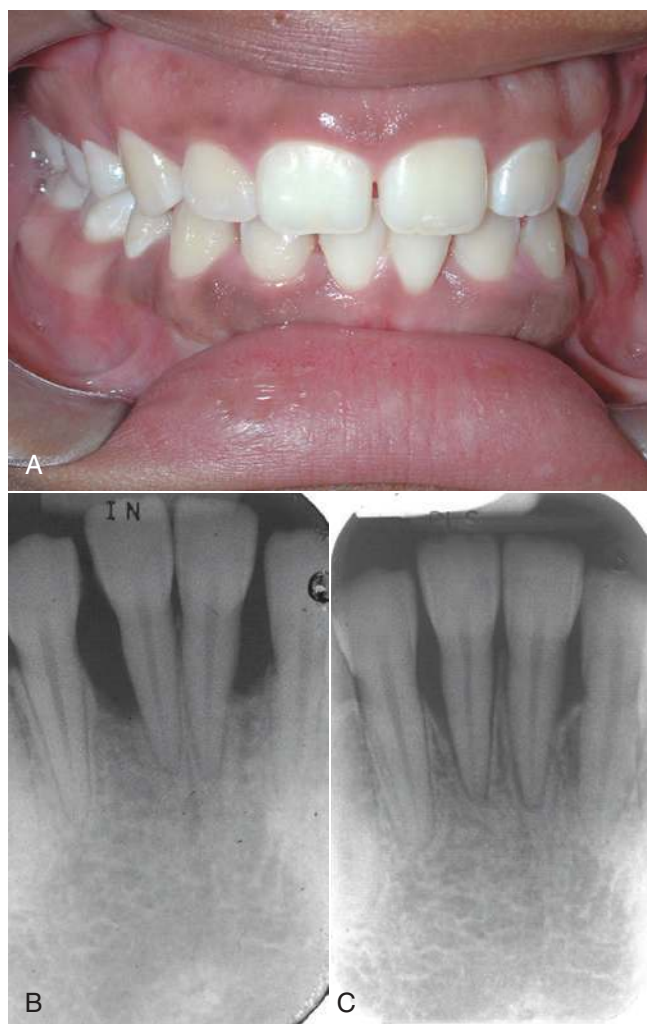Fortunately, aggressive juvenile periodontitis ([Fig. 6.5](#)) occurs rarely, but if it is present, it is critically important to note this before orthodontic treatment begins. Inadequate attached gingiva around crowded incisors may lead to stripping of the gingiva away from the teeth when the teeth are aligned, especially if the dental arch is expanded ([Fig. 6.6](#)). The interaction between periodontal and orthodontic treatment for both children and adults is discussed further in [Chapter 7](#).

The developmental status of the patient applies not only to the eruption of teeth and growth of the jaws, but also to the quality of the teeth. Teeth with developmental defects of morphology and hard tissue quality are more susceptible to decalcification and decay during treatment, which can become an esthetic issue at the end of treatment. Extraction of a defective tooth rather than a sound



• **Fig. 6.4** Two examples of variations in pretreatment oral hygiene. (A) In spite of considerable localized irregularity, this patient has good oral hygiene with excellent tissue color, crisp gingival margins, and little inflammation. (B) This patient has poor oral hygiene with plaque accumulations, rolled gingival margins, and inflamed marginal tissues. This type of patient should demonstrate improved home care before appliance placement, given the speed with which white spot lesions and soft tissue breakdown can develop.



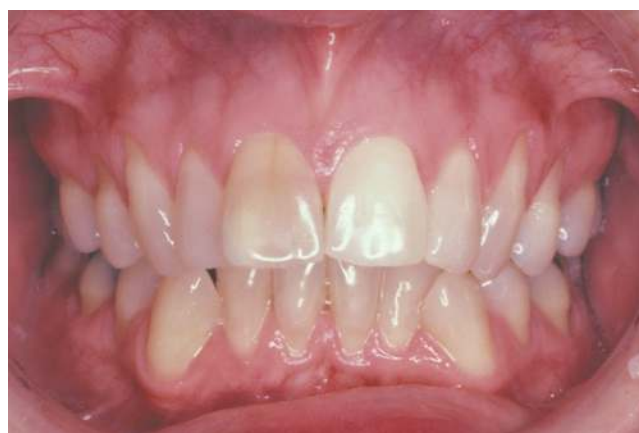

• **Fig. 6.5** Aggressive periodontitis in children and adolescents usually starts with an intensive attack on the supporting tissues around central incisors and/or first molars. (A) Intraoral appearance of a patient who sought orthodontic consultation because of congenitally missing second premolars. (B) Periapical radiograph of the lower central incisor area. (C) Follow-up periapical radiograph of the same incisor area after treatment with antibiotics and curettage and then comprehensive orthodontics. Unless periodontal probing during the orthodontist's clinical examination reveals inflammation and bone loss of this type and a periapical radiograph is ordered, the severe periodontal disease may be overlooked, and if it progresses, loss of the involved teeth is inevitable. If the periodontal problem is brought under control, orthodontic treatment is feasible.

one should be considered when extractions are part of the plan (Fig. 6.7). Photographic documentation is also important here, too. Patients and parents soon forget the pretreatment status of their teeth and gums.

### Jaw and Occlusal Function

In the evaluation of function, it is important to note in the beginning whether the patient has normal coordination and movements. If not, as in an individual with cerebral palsy or other types of severe neuromuscular disease, normal adaptation to the changes in tooth position produced by orthodontics may not occur, and the equilibrium effects discussed in Chapter 5 may lead to posttreatment



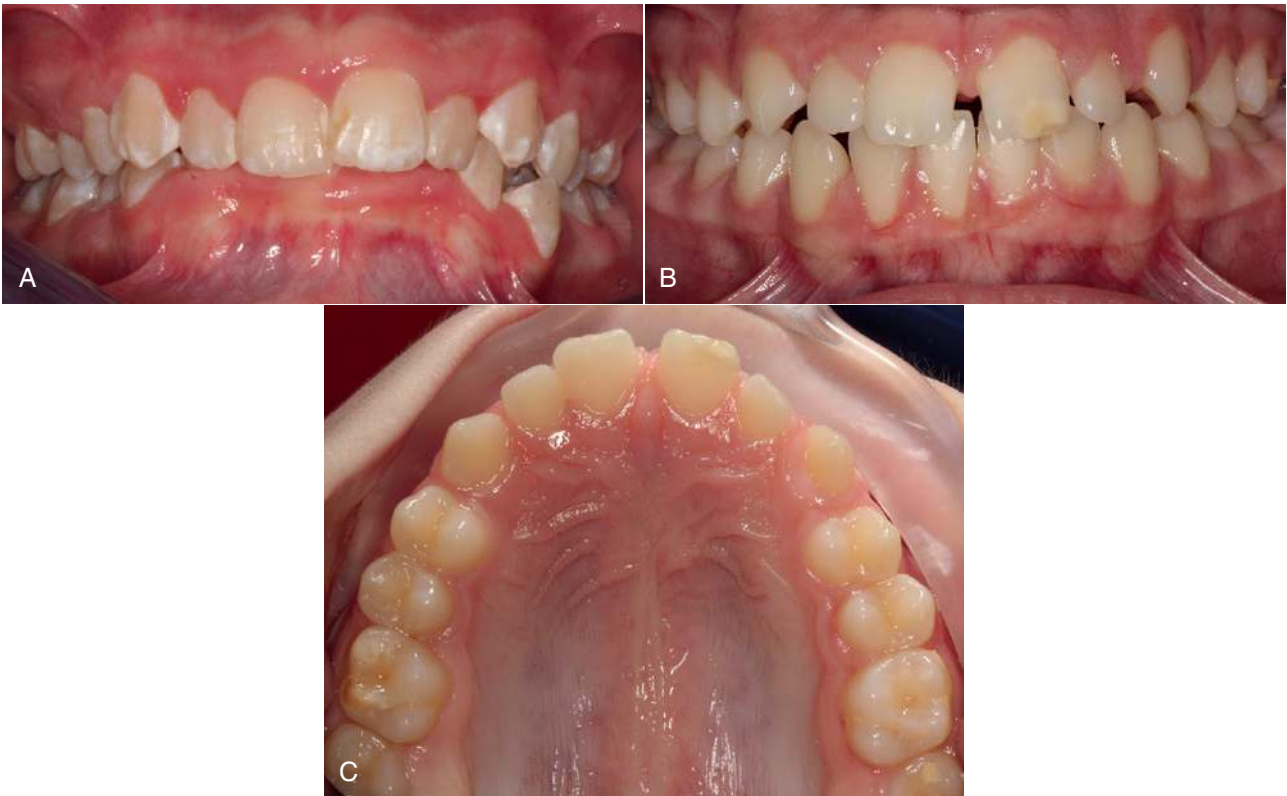• **Fig. 6.6** In this patient with minimal attached gingiva in the lower incisor region, who has enough crowding that the lower incisors will have to be advanced at least somewhat to align them, further recession of the gingiva is possible during orthodontic treatment. There is mixed evidence regarding the usefulness of pretreatment and posttreatment soft tissue grafting.

relapse. Four aspects of oral function require evaluation: mastication (including but not limited to swallowing), speech, the possibility of sleep apnea related to mandibular deficiency, and the presence or absence of temporomandibular joint (TMJ) problems.

Patients with severe malocclusion often have difficulty in normal mastication, not so much in being able to chew their food (although this may take extra effort) but in being able to do so in a socially acceptable manner. These individuals often have learned to avoid certain foods that are hard to incise and chew and may have problems with cheek and lip biting during mastication. If asked, patients report such problems and usually indicate that after orthodontic treatment they can chew better. Unfortunately, there are almost no reasonable diagnostic tests to evaluate masticatory efficiency, so it is difficult to quantify the degree of masticatory handicap and difficult to document functional improvement. Swallowing is almost never affected by malocclusion. It has been suggested that lip and tongue weakness may indicate problems in normal swallowing, but there is no evidence to support this contention (see Chapter 5). Oral gymnastic tests (such as measuring lip strength or how hard the patient can push with the tongue) therefore add little or nothing to the diagnostic evaluation.

Speech problems can be related to malocclusion, but normal speech is possible in the presence of severe anatomic distortions. Speech difficulties in a child therefore are unlikely to be solved by orthodontic treatment. Specific relationships are outlined in Table 6.1. If a child has a speech problem and the type of malocclusion related to it, a combination of speech therapy and orthodontics may help. If the speech problem is not listed as related to malocclusion, orthodontic treatment may be valuable in its own right but is unlikely to have any impact on speech.

Sleep apnea can be related to mandibular deficiency and perhaps to other jaw discrepancies,<sup>3</sup> and occasionally this functional problem is the reason for seeking orthodontic consultation. Both the diagnosis and management of sleep disorders requires an interdisciplinary team and should not be attempted without assessment, documentation, and referral from a qualified physician. Recent research suggests that oral appliances to advance the mandible can be effective, but only in patients with mild forms of sleep apnea, which must be



• **Fig. 6.7** Enamel defects of several types can be present on permanent teeth at multiple locations. Differentiating between those with local versus systemic causes can be accomplished by noting whether teeth forming during the same time are affected and the extent of the involvement. (A) This patient most likely has a form of fluorosis given the extent of the involvement and the history. This is distinguished from typical white spot lesions because the involvement is largely incisal and not primarily gingival or outlining previous bracket locations. (B) The maxillary left central incisor has a local hypoplastic incisal defect with discoloration and some defective morphology. If this is the only hypoplastic defect, then it is most likely the result of either trauma to the primary tooth that displaced it into the developing permanent tooth bud, or pulpal degeneration of one or more primary teeth that affected developing permanent teeth. Note also the narrow maxillary lateral incisors. (C) The same patient shown in (B) also has a defect on the permanent maxillary right first molar. This leads to the conclusion the patient has molar incisor hypoplasia. Although the lesions are not severe, they should be monitored for breakdown of the enamel and the need for restoration.

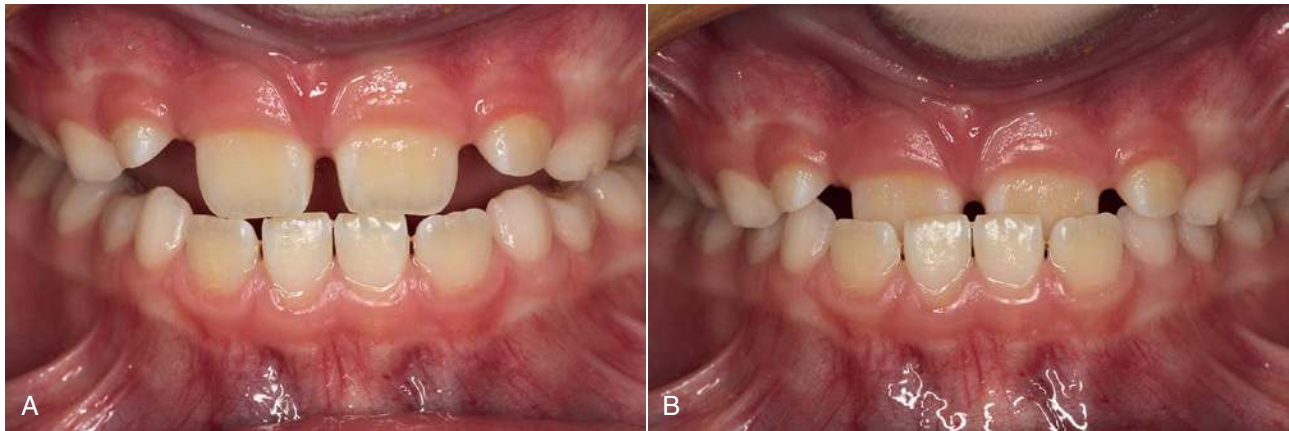
**TABLE 6.1    Speech Difficulties Related to Malocclusion**

Speech Sound	Problem	Related Malocclusion
/s/, /z/ (sibilants)	Lisp	Anterior open bite, large gap between incisors
/t/, /d/ (linguolabial stops)	Difficulty in production	Irregular incisors, especially lingual position of maxillary incisors
/f/, /v/ (labiodental fricatives)	Distortion	Skeletal Class III
th, sh, ch (linguodental fricatives [voiced or voiceless])	Distortion	Anterior open bite

established by polysomnography in a sleep laboratory before treatment in the orthodontic office begins<sup>4</sup> (see further discussion in [Chapter 7](#)).

Jaw function is more than TMJ function, but evaluation of the TMJs is an important aspect of the diagnostic workup. A form for recording routine clinical examination of TMJ function is shown in [Box 6.1](#). As a general guideline, if the mandible moves normally, its function is not severely impaired, and by the same token, restricted movement usually indicates a functional problem.<sup>5</sup> For that reason, the most important indicators of joint function are the amount of maximum opening and the ability of the mandible to translate beyond the hinge movement. Palpating the muscles of mastication and TMJs should be a routine part of any dental examination, and it is important to note any signs of TMJ problems such as joint pain, noise, limitation of opening, or deviation on opening.

Because the articular eminence is not well developed in children, it can be quite difficult to find the sort of positive “centric relation”



• **Fig. 6.8** Anterior crossbite with a forward mandibular shift. (A) When the anterior teeth contact in centric relation and cause an interference so that a natural continuation to centric occlusion is not possible, (B) the mandible shifts forward so maximum intercuspation of the posterior teeth can be achieved.

• **BOX 6.1** Screening Examination for Jaw Function (Temporomandibular Joint [TMJ])

Jaw function/TMJ complaint now:	<input type="checkbox"/> No	<input type="checkbox"/> Yes
If yes, specify: _____		
History of pain:	<input type="checkbox"/> No	<input type="checkbox"/> Yes _____ duration
History of sounds:	<input type="checkbox"/> No	<input type="checkbox"/> Yes _____ duration
TMJ tenderness to palpation:	<input type="checkbox"/> No	<input type="checkbox"/> Yes <input type="checkbox"/> Right <input type="checkbox"/> Left
Muscle tenderness to palpation:	<input type="checkbox"/> No	<input type="checkbox"/> Yes
If yes, where? _____		
Range of motion:	Maximum opening _____ mm	
	Right excursion _____ mm	
	Left excursion _____ mm	
	Protrusion _____ mm	
Deviations on opening?	Deviations on opening? R _____ L _____	
	At what point? _____ mm	

position that can be determined in adults. Nevertheless, it is important to note whether the mandible shifts laterally or anteriorly when a child bites down. Children with an apparent unilateral crossbite often have a bilateral narrowing of the maxillary arch, with a shift to the unilateral crossbite position. This is the most common cause of apparent but not true facial asymmetry. It is vitally important to verify this during the clinical examination or to rule out a shift and confirm a true unilateral crossbite, because treatment of these problems is different.

Similarly, many children and adults with a Class II malocclusion and an underlying skeletal Class II jaw relationship will position the mandible forward in a “Sunday bite,” making the occlusion look better than it really is. Sometimes an apparent Class III relationship results from a forward shift to escape incisor

interferences in what is really an end-to-end relationship (Fig. 6.8). These patients are said to have pseudo-Class III malocclusion.

Other occlusal interferences with functional mandibular movements, although of interest, are less important than they would be if treatment to alter the occlusion were not being contemplated. Balancing interferences, presence or absence of canine protection in lateral excursions, and other such factors take on greater significance if they are still present when the occlusal changes produced by orthodontic treatment are nearing completion.

## Facial and Dental Appearance

### Effect of Facial Background on Perception of Dental Esthetics

Although it is now widely recognized that the background facial appearance plays a role in the perception of the appearance of the teeth, it has been difficult to quantify these relationships. The discovery that the length of time an individual looks at features of the face (or anything else) is proportional to its importance to them provides a way to determine how the teeth and the face affect each other in quantitative terms. In recent studies, the movements of the eyes of a sample of young adults were tracked while they were looking at images of faces of young adults that were digitally combined with teeth that had different levels of facial attractiveness (quantified with the Aesthetic Component of the Index of Orthodontic Treatment Need [IOTN]—see Fig. 1.20), and the frequency and duration of gazes were recorded. This was accomplished for both sexes.

In general, eye tracking for facial images shows that the most attention is paid to the eyes. The data from these studies showed that for attractive and average females, unattractive teeth (high borderline esthetic dental need at IOTN level 7) became a focus for the viewers sooner when the female image they were observing had moderate or high background attractiveness than it did for images with unattractive background esthetics.<sup>6</sup> This attention rivaled looking at the eyes. For men, the most attention was directed at the mouth when the males were unattractive or of average attractiveness and the dental esthetics need was severe (esthetic dental need at IOTN level 10). Then it surpassed the eyes.<sup>7</sup>



These studies demonstrated that overall facial attractiveness influences how people look at teeth and that they tolerate different levels of dental attractiveness based on this. So, malalignment is more noticeable in average and attractive women and average and unattractive men. We also know that people make judgments regarding intelligence and interpersonal temperament for children and young adults based on the appearance of the teeth.<sup>8,9</sup> This information can be helpful when advising patients regarding their need for treatment and helps explain how important it is to assess the facial as well as the dental attractiveness of the patient.

Systematic Examination of Facial and Dental Appearance

A systematic examination of facial and dental appearance should be done in the following three steps:

- 1. *Facial proportions in all three planes of space (macro-esthetics).* Examples of problems that would be noted in this first step would be asymmetry, excessive or deficient face height, mandibular or maxillary deficiency or excess, and so on. In performing this evaluation, keep in mind that both the evolutionary and prenatal development of the face can provide additional insight into the origin and significance of unusual facial morphology.
- 2. *The dentition in relation to the face (mini-esthetics).* This includes the display of the teeth at rest, during speech, and on smiling. It includes such assessments as excessive gingival display, inadequate anterior tooth display, inappropriate gingival heights, and the extent of the buccal corridors (the dark spaces in the corners of the mouth beyond the teeth).
- 3. *The teeth in relation to one another (micro-esthetics).* This includes assessment of tooth proportions in height and width, gingival shape and contour, connectors and embrasures, black triangular holes, and tooth shade.

Let’s evaluate what you are looking for in each step.

**Macro-Esthetics: Facial Proportions.** The first step in evaluating facial proportions is to take a good look at the patient, examining him or her for developmental characteristics and a general impression. Humans are very adept at evaluating faces and in fact have a dedicated neural system for that purpose.<sup>10</sup> Even so, with faces as with everything else, looking too quickly at the details carries the risk of missing the big picture. It is a mistake for any dentist to focus on just the teeth after a cursory look at the face. It is a disastrous mistake for an orthodontist not to evaluate the face carefully.

**Assessment of Developmental Age.** In a step that is particularly important for children around the age of puberty, when most orthodontic treatment is carried out, the patient’s developmental age should be assessed. Everyone becomes a reasonably accurate judge of other people’s ages—we expect to come within a year or two simply by observing the other person’s facial appearance. Occasionally we are fooled, as when we say that a 12-year-old girl looks 15 or that a 15-year-old boy looks 12. With adolescents, the judgment is of physical maturity.

The attainment of recognizable secondary sexual characteristics for girls and boys and the correlation between stages of sexual maturation and facial growth are discussed in Chapter 4 and are summarized in Table 6.2. The degree of physical development is much more important than chronologic age in determining how much growth remains.

**Facial Esthetics Versus Facial Proportions.** Because a major reason for orthodontic treatment is to overcome psychosocial difficulties related to facial and dental appearance and enhance social well-being and QOL in doing so, evaluating dental and

TABLE 6.2 Adolescent Growth Stages Versus Secondary Sexual Characteristics

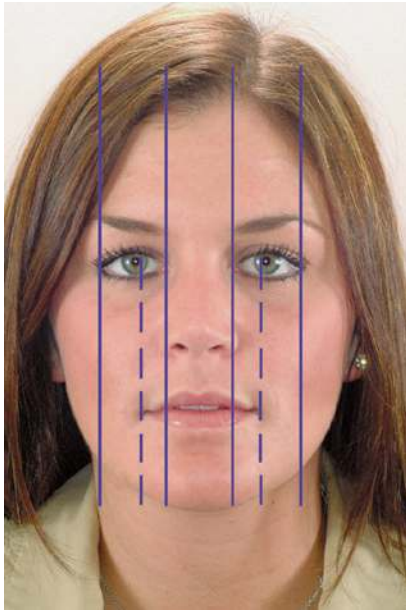
Girls	
Total Duration of Adolescent Growth: 3½ Years	
Stage 1	
Beginning of adolescent growth	Appearance of breast buds, initial pubic hair
Stage 2 (About 12 Months Later)	
Peak velocity in height	Noticeable breast development, axillary hair, darker and more abundant pubic hair
Stage 3 (12-18 Months Later)	
Growth spurt ending	Menses, broadening of hips with adult fat distribution, breasts completed
Boys	
Total Duration of Adolescent Growth: 5 Years	
Stage 1	
Beginning of adolescent growth	“Fat spurt” weight gain, feminine fat distribution
Stage 2 (About 12 Months Later)	
Height spurt beginning	Redistribution and reduction in fat, pubic hair, growth of penis
Stage 3 (8-12 Months Later)	
Peak velocity in height	Facial hair appears on upper lip only, axillary hair, muscular growth with harder, more angular body form
Stage 4 (15-24 Months Later)	
Growth spurt ending	Facial hair on chin and lip, adult distribution and color of pubic and axillary hair, adult body form

facial esthetics is an important part of the clinical examination. Judgments regarding dental esthetics are affected by the background attractiveness of the patient’s face, so this context is important. Whether a face is considered beautiful is greatly affected by cultural and ethnic factors, but whatever the culture, a severely disproportionate face becomes a psychosocial problem. For that reason, it helps to recast the purpose of this part of the clinical evaluation as an evaluation of facial proportions, not esthetics per se. Distorted and asymmetric facial features are a major contributor to facial esthetic problems, whereas proportionate features are generally acceptable even if not beautiful.

**Frontal Examination.** The first step in analyzing facial proportions is to examine the face in frontal view. Low-set ears or eyes that are unusually far apart (hypertelorism) may indicate either the presence of a syndrome or a microform of a craniofacial anomaly. If a syndrome is suspected, the patient’s hands should be examined for syndactyly, because there are several dental–digital syndromes.

In the frontal view, one looks for bilateral symmetry in the fifths of the face and for proportionality of the widths of the eyes, nose, and mouth (Fig. 6.9). A small degree of bilateral facial asymmetry exists in essentially all normal individuals. This can be appreciated most readily by comparing the real full-face photograph with composites consisting of two right or two left sides (Fig.





• **Fig. 6.9** Facial proportions and symmetry in the frontal plane. An ideally proportional face can be divided into central, medial, and lateral equal fifths. The separation of the eyes and the width of the eyes, which should be equal, determine the central and medial fifths. The nose and chin should be centered within the central fifth, with the width of the nose the same as or slightly wider than the central fifth. The interpupillary distance (*dashed line*) should equal the width of the mouth.

6.10). This “normal asymmetry,” which usually results from a small size difference between the two sides, should be distinguished from a chin or nose that deviates to one side, which can produce severe disproportion and esthetic problems (see Fig. 6.3).

Before the advent of cephalometric radiography, dentists and orthodontists often used anthropometric measurements (i.e., measurements made directly during the clinical examination) to help establish facial proportions (Fig. 6.11). Although this method was largely replaced by cephalometric analysis for many years, the recent emphasis on soft tissue proportions has brought soft tissue evaluation back into prominence. Farkas’s modern studies of Canadians of northern European origin provided the data for Tables 6.3 and 6.4.<sup>11</sup>

Note that some of the measurements in Table 6.3 could be made on a cephalometric radiograph, but many could not. When there are questions about facial proportions, it is much better to make the measurements clinically because soft tissue proportions as seen on visual examination determine facial appearance. During the clinical examination, one can record measurements and literally digitize the face rather than later digitizing a cephalometric radiograph (Fig. 6.12).

The proportional relationship of facial height to width (the facial index) establishes the overall facial type and the basic proportions of the face. It is important to remember that face height cannot be evaluated unless face width is known, and face width is not evaluated when a lateral cephalometric radiograph is analyzed.

The normal values for the facial index and other proportions that may be clinically useful are shown in Table 6.4. Differences in facial types and body types obviously must be taken into account

**TABLE 6.3 Facial Anthropometric Measurements (Young Adults)**

Parameter	Male (SD)	Female (SD)
1. Zygomatic width (zy-zy) (mm)	137 (4.3)	130 (5.3)
2. Gonial width (go-go)	97 (5.8)	91 (5.9)
3. Intercanthal distance	33 (2.7)	32 (2.4)
4. Pupil-midfacial distance	33 (2.0)	31 (1.8)
5. Nasal base width	35 (2.6)	31 (1.9)
6. Mouth width	53 (3.3)	50 (3.2)
7. Face height (N-gn)	121 (6.8)	112 (5.2)
8. Lower face height (subnasale-gn)	72 (6.0)	66 (4.5)
9. Upper lip vermillion	8.9 (1.5)	8.4 (1.3)
10. Lower lip vermillion	10.4 (1.9)	9.7 (1.6)
11. Nasolabial angle (degrees)	99 (8.0)	99 (8.7)
12. Nasofrontal angle (degrees)	131 (8.1)	134 (1.8)
13. Labiomental sulcus	Obtuse	Obtuse

Measurements are illustrated in Fig. 6.11.

SD, Standard deviation.

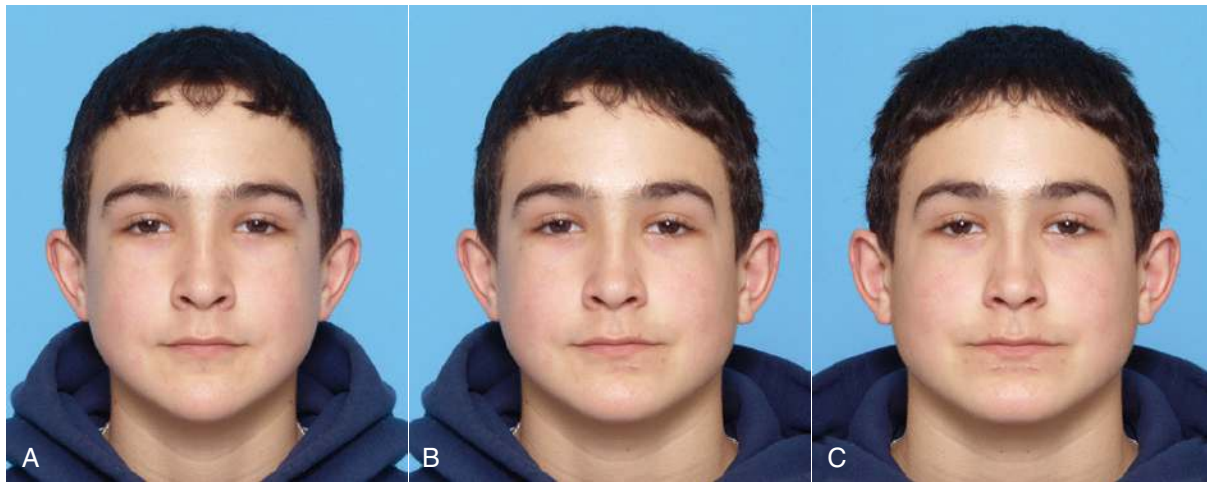
Data from Farkas LG. *Anthropometry of the Head and Face in Medicine*. New York: Elsevier Science; 1991.

**TABLE 6.4 Facial Indices (Young Adults)**

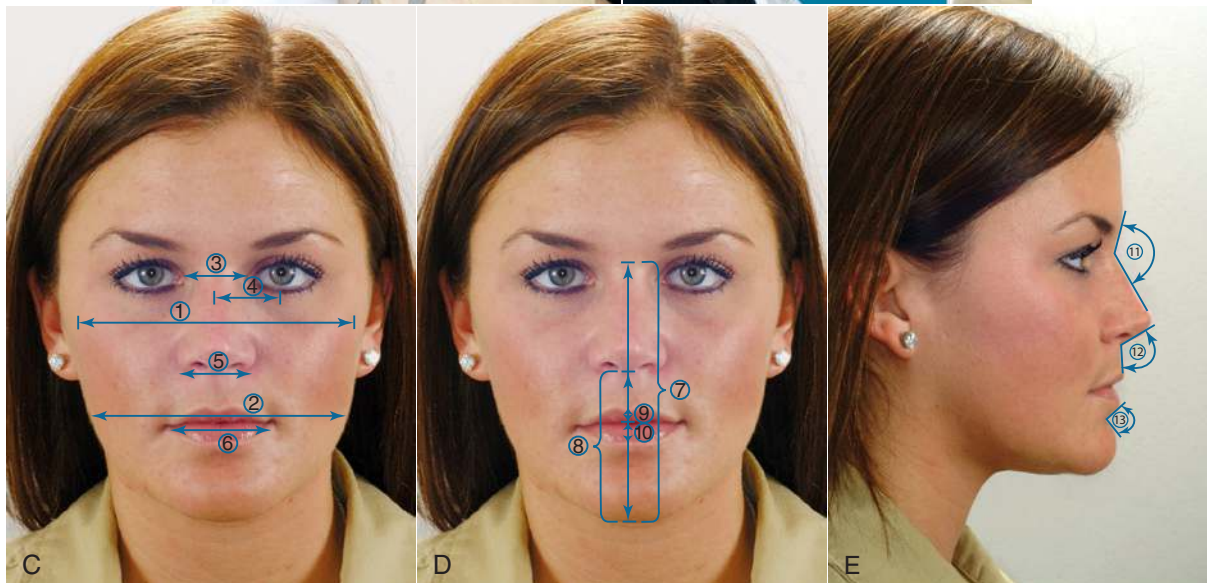
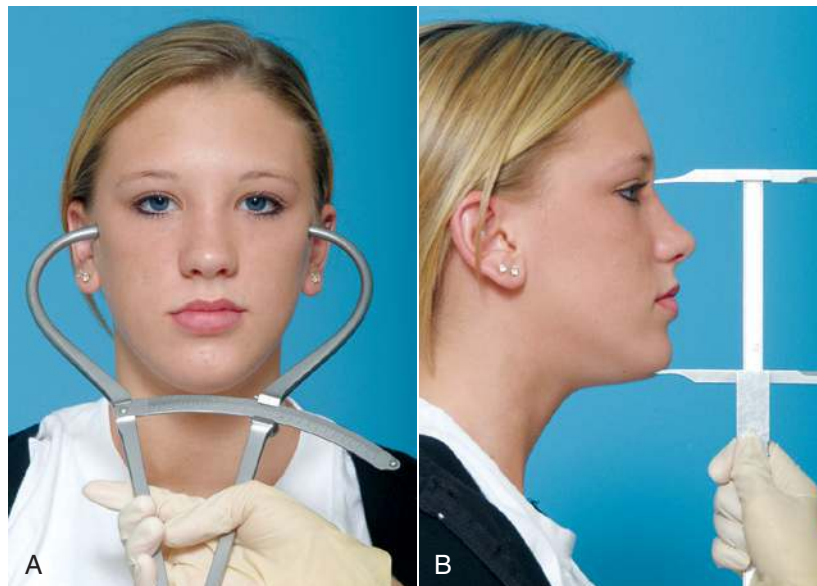
Index	Measurements	Male (SD)	Female (SD)
Facial	n-gn/zy-zy	88.5 (5.1)	86.2 (4.6)
Mandible–face width	go-go/zy-zy	70.8 (3.8)	70.1 (4.2)
Upper face	n-sto-/zy-zy	54.0 (3.1)	52.4 (3.1)
Mandibular width–face height	go-go/n-gn	80.3 (6.8)	81.7 (6.0)
Mandibular	sto-gn/go-go	51.8 (6.2)	49.8 (4.8)
Mouth–face width	ch-ch $\times$ 100/zy-zy	38.9 (2.5)	38.4 (2.5)
Lower face–face height	sn-gn/n-gn	59.2 (2.7)	58.6 (2.9)
Mandible–face height	sto-gn/n-gn	41.2 (2.3)	40.4 (2.1)
Mandible–upper face height	sto-ng/n-sto	67.7 (5.3)	66.5 (4.5)
Mandible–lower face height	sto-ng/sn-gn	69.6 (2.7)	69.1 (2.8)
Chin–face height	sl-gn $\times$ 100/sn-gn	25.0 (2.4)	25.4 (1.9)

SD, Standard deviation.

From Farkas LG, Munro JR. *Anthropometric Facial Proportions in Medicine*. Springfield, Ill.: Charles C Thomas; 1987.



• **Fig. 6.10** Composite photographs are the best way to illustrate normal facial asymmetry. For this boy, whose mild asymmetry rarely would be noticed and is not a problem, the true photograph is in the center (B). On the patient's right, (A) is a composite of the two right sides; on the left, (C) is a composite of the two left sides. This dramatically illustrates the difference in the two sides of a normal face, in which mild asymmetry is the rule rather than the exception. Usually, the right side of the face is a little larger than the left, rather than the reverse as in this individual.



• **Fig. 6.11** Facial measurements for anthropometric analysis are made with either (A) bow calipers or (B) straight calipers. (C) to (E) Frequently used facial anthropometric measurements; the numbers are keyed to [Table 6.3](#).



• **Fig. 6.12** In evaluating facial proportional relationships while looking at digital images on the computer screen, it can be helpful to put a box around the structures to be related, as in A, where the lip commissure height is being related to the central philtrum height, or as in B, where the width of the nose is being related to the interocular width. For this girl, both relationships are normal. Boxes like this can be added to the facial images during the clinical examination and become part of the record.

when facial proportions are assessed, and variations from the average ratios can be compatible with good facial esthetics. An important point, however, is to avoid treatment that would change the ratios in the wrong direction—for example, treatment with interarch elastics that could rotate the mandible downward in a patient whose face already is too long for its width.

Finally, the face in frontal view should be examined from the perspective of the vertical facial thirds. The artists of the Renaissance period, primarily da Vinci and Durer, established the proportions for drawing anatomically correct human faces (Fig. 6.13). They concluded that the distance from the hairline to the base of the nose, base of nose to bottom of nose, and bottom of nose to chin should be the same. Farkas's studies show that in modern Caucasians of European descent, the lower third is very slightly longer. The artists also saw that the lower third has a proportion of one-third above the mouth to two-thirds below, and the Farkas data show that this is still true.

It is important to note the cause of vertical problems such as excessive display of the maxillary gingiva, which is done best by examining the position of lips and teeth relative to the vertical thirds of the face (Fig. 6.14). It also is important to keep in mind that different ethnic and national groups view facial esthetics somewhat differently (there are differences even in countries as closely matched as the United States and Canada) and that both gender and overall facial attractiveness influence how people are perceived. As the examining doctor, you need to notice and evaluate disproportions, even though you know that as treatment is planned, aspects of facial appearance that would be a problem for some individuals are not a problem for others with a different ethnic background.


Dentofacial characteristics that should be noted as part of the facial examination are shown in Table 6.5. This checklist is just that: a list of things that should be noted systematically during the clinical examination. As in many other things, if you do not look for it, you will not see it. Precise measurements are not necessary, but deviations from the normal should be considered when the problem list is developed. Computer programs currently in use already allow positive findings from the digital data acquired during the clinical examination to “flow through” to the preliminary problem list.

**Profile Analysis.** A careful examination of the facial profile yields the same information, although in less detail for the underlying skeletal relationships, as that obtained from analysis of lateral cephalometric radiographs. For diagnostic purposes, particularly to identify patients with severe disproportions, careful clinical evaluation is adequate. For this reason, the technique of facial profile analysis has sometimes been called the “poor man’s cephalometric analysis.” This is a vital diagnostic technique for all dentists. It must be mastered by all those who will see patients for primary care in dentistry, not just by orthodontists.

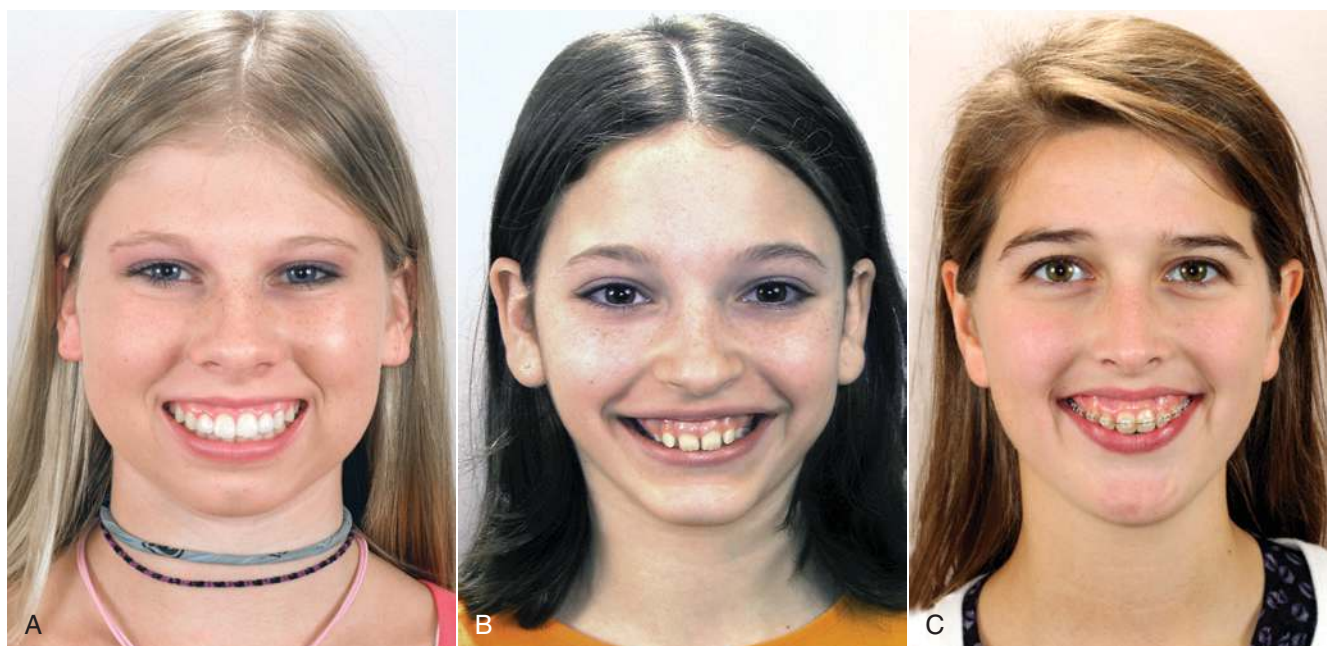The three goals of facial profile analysis are approached in three clear and distinct steps. These goals are discussed in the following paragraphs.

1. *Establishing whether the jaws are proportionately positioned in the anteroposterior (AP) plane of space.* This step requires placing the patient in the physiologic natural head position (NHP), which is the head position the individual adopts in the absence of other cues. This can be done with the patient either sitting upright or standing but not reclining in a dental chair and looking at the horizon or a distant object. With the head in this position, note





• **Fig. 6.13** Vertical facial proportions in the frontal (A) and lateral (B) views are best evaluated in the context of the facial thirds, which the Renaissance artists noted were equal in height in well-proportioned faces. In modern Caucasians, the lower facial third often is slightly longer than the central third. The lower third also includes thirds: The mouth should be one-third of the way between the base of the nose and the chin.

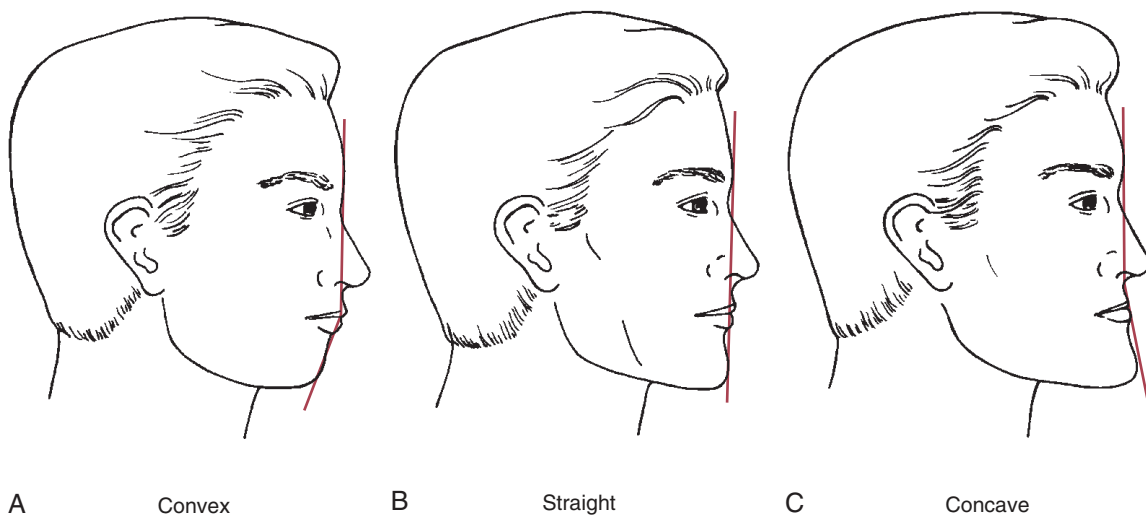


• **Fig. 6.14** The usual cause of excessive display of maxillary gingiva is a long face due to excessive downward growth of the maxilla, which moves the maxilla down below the upper lip and results in a disproportionately long lower third of the face. (A) This should not be confused with display of gingiva in childhood because the gingival recession that accompanies eruption is incomplete, or with (B) gingival display due to a combination of incomplete eruption and a short upper lip. (C) Note that for the patients in (A) and (C), the lower third of the face is long, whereas for the patient in (B), the lower third is about the same length as the middle third.



**TABLE 6.5** Checklist of Facial Dimensions to Evaluate During Clinical Examination

Frontal at Rest	Frontal Smile	Frontal Widths	Profile
<b>To Midsagittal Plane</b> <ul style="list-style-type: none"> <li>Nasal tip</li> <li>Maxillary dental midline</li> <li>Mandibular dental midline</li> <li>Chin (midsymphysis)</li> </ul>	<ul style="list-style-type: none"> <li>Maxillary incisor display</li> <li>Maxillary incisor crown height</li> <li>Gingival display</li> <li>Smile arc</li> <li>Occlusal plane cant?</li> </ul>	<ul style="list-style-type: none"> <li>Alar base</li> <li>Nasal tip</li> <li>Buccal corridor</li> </ul>	<b>Lower Face</b> <ul style="list-style-type: none"> <li>Maxillary projection</li> <li>Mandibular projection</li> <li>Chin projection</li> <li>Lower face height</li> </ul>
<b>Vertical</b> <ul style="list-style-type: none"> <li>Lip separation (lips relaxed)</li> <li>Lip vermilion display</li> <li>Maxillary incisor display (lips relaxed)</li> <li>Lower face height</li> <li>Philtrum length</li> <li>Commissure height</li> <li>Chin height</li> </ul>			<b>Nose</b> <ul style="list-style-type: none"> <li>Nasal radix</li> <li>Nasal dorsum contour</li> <li>Nasal tip projection</li> <li>Nasolabial angle</li> </ul>
			<b>Lip</b> <ul style="list-style-type: none"> <li>Lip fullness</li> <li>Labiomental sulcus</li> </ul>
			<b>Throat Form</b> <ul style="list-style-type: none"> <li>Chin–throat angle</li> <li>Throat length</li> <li>Submental contour (fat pad)</li> </ul>



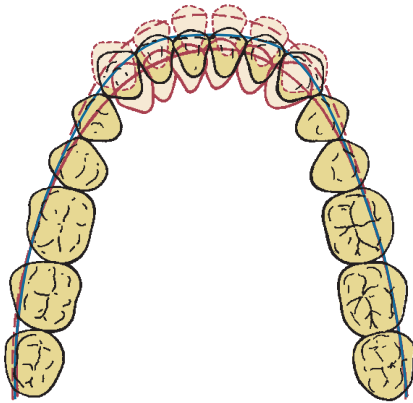
• **Fig. 6.15** Accentuated profile convexity or concavity results from a disproportion in the size of the jaws but does not by itself indicate which jaw is at fault. (A) A convex facial profile indicates a Class II jaw relationship, which can result from either a maxilla that projects too far forward or a mandible too far back. (B) A straight or slightly convex profile is normal and usually reflects a normal jaw relationship. (C) A concave profile indicates a Class III jaw relationship, which can result from either a maxilla that is too far back or a mandible that protrudes forward.

the relationship between two lines, one dropped from the bridge of the nose to the base of the upper lip, and a second one extending from that point downward to the chin (Fig. 6.15). These line segments ideally should form a nearly straight line, with only a slight inclination in either direction. A large angle between them (>10 degrees or so) indicates either profile convexity (upper jaw prominent relative to chin) or profile concavity (upper jaw behind chin). A convex profile therefore indicates a skeletal Class II jaw

relationship, whereas a concave profile indicates a skeletal Class III jaw relationship.

2. *Evaluation of lip posture and incisor prominence.* Detecting excessive incisor protrusion (which is relatively common) or retrusion (which is rare) is important because of the effect on space within the dental arches. If the incisors protrude, they align themselves on the arc of a larger circle as they lean forward, whereas if the incisors are upright or retrusive, less space is available (Fig. 6.16).

In the extreme case, incisor protrusion can produce ideal alignment of the teeth instead of severely crowded incisors, at the expense of lips that protrude and are difficult to bring into function over the protruding teeth. This is *bimaxillary dentoalveolar protrusion*, meaning simply that in both jaws the teeth protrude (Fig. 6.17). Dentists often refer to the condition as just *bimaxillary protrusion*, a simpler term but a misnomer because it is not the jaws but the

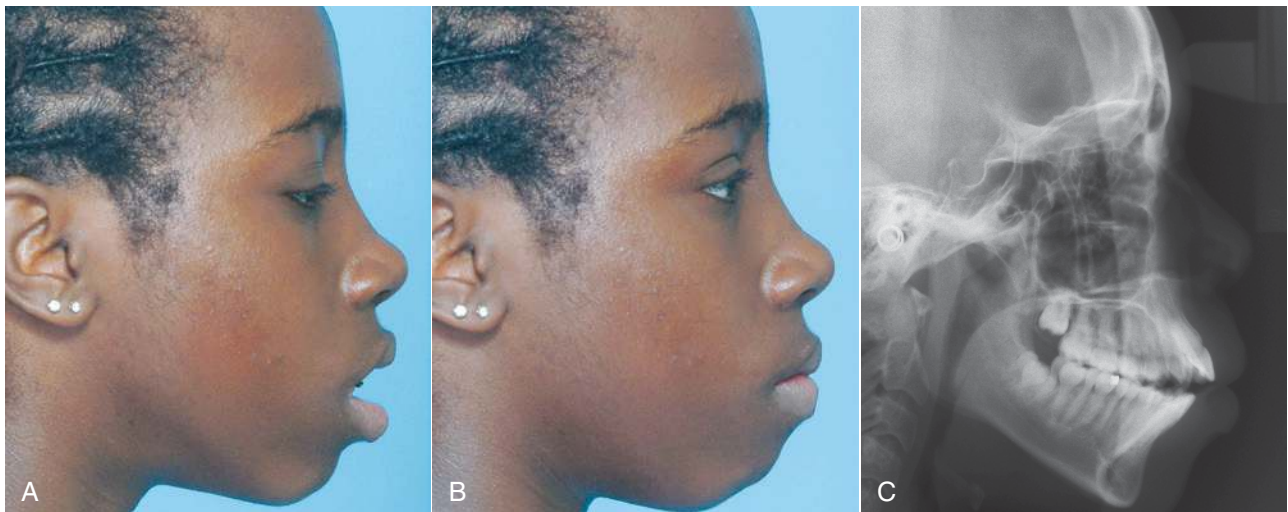


• **Fig. 6.16** If the incisors flare forward, they can align themselves along the arc of a larger circle, which provides more space to accommodate the teeth and alleviates crowding. Conversely, if the incisors move lingually, there is less space, and crowding becomes worse. For this reason, crowding and protrusion of incisors must be considered two aspects of the same thing; how crowded and irregular the incisors are reflects both how much room is available and where the incisors are positioned relative to supporting bone.

teeth that protrude. Physical anthropologists use *bimaxillary protrusion* to describe faces in which both jaws are prominent relative to the cranium, and the different terminology must be kept in mind when faces are described in the anthropology literature.

Determining how much incisor prominence is too much can be difficult, especially when changes over time in public preference for both lip and chin prominence are taken into account<sup>11</sup> and ethnic differences are considered. This is simplified by understanding the relationship between lip posture and the position of the incisors. The teeth protrude excessively if (and only if) two conditions are met: (1) The lips are prominent and everted and (2) the lips are separated at rest by more than 3 to 4 mm (which is sometimes termed *lip incompetence*). In other words, excessive protrusion of the incisors is revealed by prominent lips that are separated when they are relaxed, so that the patient must strain to bring the lips together over the protruding teeth (see Fig. 6.17). For such a patient, retracting the teeth tends to improve both lip function and facial esthetics. On the other hand, if the lips are prominent but close over the teeth without strain, the lip posture is largely independent of tooth position. For that individual, retracting the incisor teeth would have little effect on lip function or prominence.

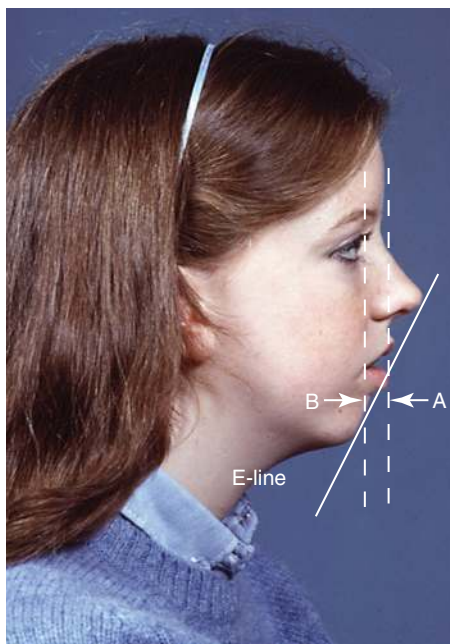
Lip prominence is strongly influenced by racial and ethnic characteristics and to a considerable extent also is age-dependent (see Chapter 2). Whites of northern European backgrounds often have relatively thin lips, with minimal lip and incisor prominence. Whites of southern European and Middle Eastern origin normally have more lip and incisor prominence than their northern counterparts. Greater degrees of lip and incisor prominence normally occur in individuals of Asian and African descent, so a lip and tooth position normal for Asians or blacks would be excessively protrusive for most whites. Although multiculturalism clearly demonstrated by multiracial individuals has begun to blur these lines of distinction, more lip prominence now is being recognized as a desired esthetic quality.<sup>12</sup>



• **Fig. 6.17** Bimaxillary dentoalveolar protrusion is seen in the facial appearance in three ways. (A) Excessive separation of the lips at rest is called *lip incompetence*. The general guideline that holds for all racial groups is that lip separation at rest should be not more than 4 mm. (B) Excessive effort to bring the lips into closure creates lip strain and prominence of lips in the profile view, as shown in both (A) and (B). Remember that all these soft tissue characteristics must be present to make the diagnosis of dental protrusion, not just protruding teeth as seen in a cephalometric radiograph of the same girl. (C) Different racial groups and individuals within those groups have different degrees of lip prominence that are independent of tooth position. As a result, excessive dental protrusion must be a clinical diagnosis. It cannot be made accurately from cephalometric radiographs.

Lip posture and incisor prominence should be evaluated by viewing the profile with the patient's lips relaxed. This is done by relating the upper lip to a true vertical line passing through the concavity at the base of the upper lip (soft tissue point A) and by relating the lower lip to a similar true vertical line through the concavity between the lower lip and chin (soft tissue point B; Fig. 6.18). If the lip is significantly forward of this line, it can be judged to be prominent; if the lip falls behind the line, it is retrusive. If the lips are both prominent and incompetent (separated by more than 3 to 4 mm), the guideline is that the anterior teeth are excessively protrusive. Is that a problem? It depends on both the patient's perception and the cultural setting, not just on the objective evaluation.

In evaluating lip protrusion, it is important to keep in mind that everything is relative, and in this case the lip relationships with the nose and chin affect the perception of lip fullness. The larger the nose, the more prominent the chin must be to balance it, and the greater the amount of lip prominence that will be esthetically acceptable. It can be helpful to look at lip prominence relative to a line from the tip of the nose to the chin (the E-line of cephalometric analysis, which can be visualized easily on clinical examination; Fig. 6.19). Another helpful guideline is to consider the nasolabial angle (the angle between the ventral surface of the nose and the labial surface of the lip). A mildly obtuse angle is considered normal.



• **Fig. 6.18** Lip prominence is evaluated by observing the distance that each lip projects forward from a true vertical line through the depth of the concavity at its base, which are soft tissue points A and B—that is, a different reference line is used for each lip, as shown here. Lip prominence of more than 2 to 3 mm in the presence of lip incompetence (as in this girl) indicates dentoalveolar protrusion. Because observers perceive lip prominence in the context of the relationship of the lips to the nose and chin, it can be helpful to draw the E-line (esthetic line) from the nose to the chin and to look at how the lips relate to this line. The guideline is that they should be on or slightly in front of the E-line, which does not change the general rule that lip separation at rest and lip strain on closure are the major indicators of excessive lip support by the dentition.

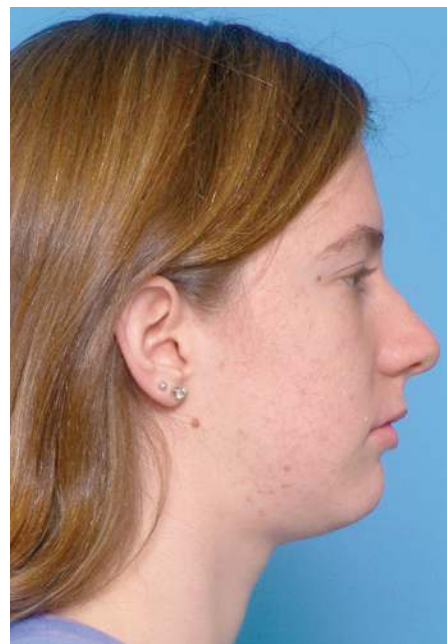Vertical facial and dental relationships also play a role here. Some patients with short lower face height have everted and protrusive lips because they are overclosed and the upper lip presses against the lower lip, not because the teeth protrude. One indicator of lip protrusion caused by overclosure is the labiomental fold angulation (the angle between the labial surface of the lower lip and the labial surface of the chin). Under normal conditions this is usually somewhat obtuse; a greatly decreased angle indicates overclosure.

Not only the prominence of the chin but also the submental soft tissue contours should be evaluated. Throat form is an important factor in establishing optimal facial esthetics, and poor throat form is a major contributor to esthetic impairment in patients with mandibular deficiency (Fig. 6.20).

3. *Reevaluation of vertical facial proportions and evaluation of mandibular plane angle.* Vertical proportions can be observed during the full-face examination (see previous section) but sometimes can be seen more clearly in profile. In the clinical examination, the inclination of the mandibular plane to the true horizontal should be noted. The mandibular plane is visualized readily by placing a finger or mirror handle along the lower border (Fig. 6.21). A steep mandibular plane angle usually accompanies long anterior facial vertical dimensions and a skeletal open bite tendency, whereas a flat mandibular plane angle often correlates with short anterior facial height and deep bite malocclusion.

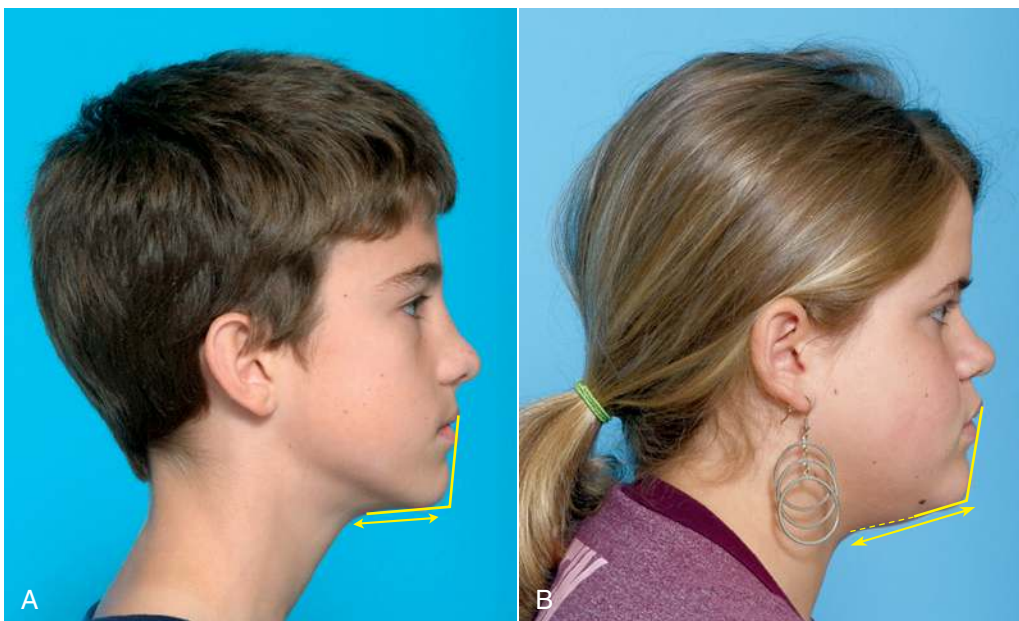Facial form analysis carried out this way takes only a couple of minutes but provides information that simply is not present from dental radiographs and casts. Such an evaluation by the primary care practitioner is an essential part of the evaluation of every prospective orthodontic patient.

During the macro-esthetic examination, and in other parts of the clinical examination discussed later, it is important to note

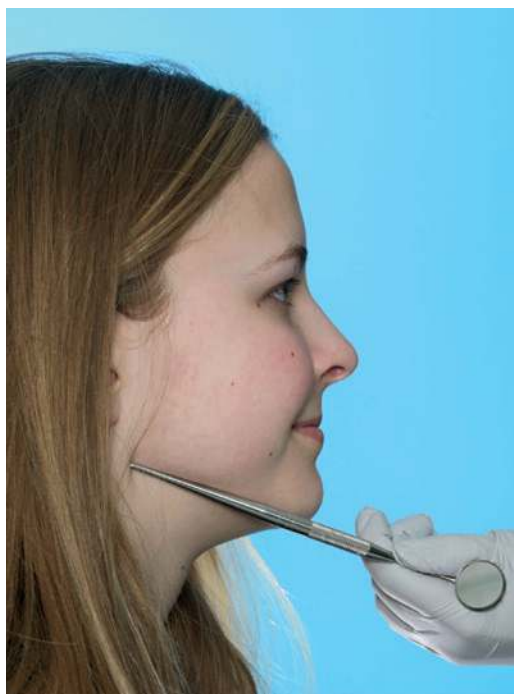


• **Fig. 6.19** For this girl with Class II malocclusion, retraction of the maxillary incisors would damage facial appearance by decreasing support for the upper lip, making the relatively large nose look even bigger. The size of the nose and chin must be considered when the position of the incisors and amount of lip support are evaluated.

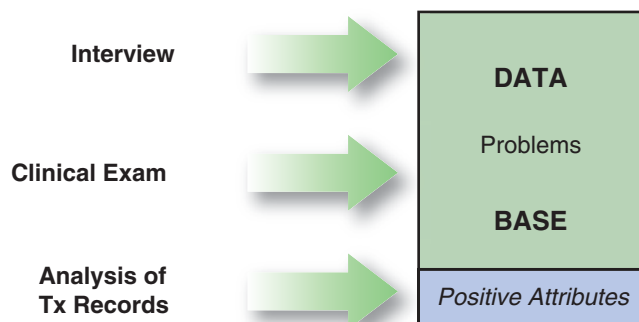




• **Fig. 6.20** Throat form is evaluated in terms of the contour of the submental tissues (straight is better), chin-throat angle (closer to 90 degrees is better), and throat length (longer is better, up to a point). Both submental fat deposition and a low tongue posture contribute to a stepped throat contour, which becomes a “double chin” when extreme. (A) For this boy who has a mild mandibular deficiency, throat contour and the chin-throat angle are good, but throat length is short, as usually is the case when the mandible is short. (B) For this girl with more chin projection, throat contour is affected by submental fat, and the chin-throat angle is somewhat obtuse, but throat length is good.



• **Fig. 6.21** The mandibular plane angle can be visualized clinically by placing a mirror handle or other instrument along the border of the mandible. For this patient, the mandibular plane angle is normal, neither too steep nor too flat.



• **Fig. 6.22** When the diagnostic database is being assembled, it is wise to note not only how the patient deviates from normal (ideal) dimensions and relationships, but what aspects are normal and should be protected during treatment. For example, if the maxillary incisors are protrusive but the vertical tooth-lip relationship is ideal, a note in the treatment plan to preserve this during treatment can prevent the elongation of the incisors that easily can occur when they are retracted.

not only what is wrong, but also what is right. After all, you don't want to damage some of the good attributes of dentofacial appearance while treating the bad ones. For instance, in a patient with a well-supported upper lip and a deficient mandible, you would want to protect the position of the upper lip, and retraction of upper incisors in a patient who does not have a prominent upper lip can damage the dentofacial appearance (Fig. 6.22).

**Mini-Esthetics: Tooth-Lip Relationships and Smile Analysis.** Evaluation of tooth-lip relationships begins with an examination of symmetry, in which it is particularly important to note the relationship of the dental midline of each arch to the skeletal



midline of that jaw (i.e., the lower incisor midline relative to the midline of the mandible, and the upper incisor midline relative to the midline of the maxilla). Dental casts, even if mounted on an articulator, will show the relationship of the midlines to each other but provide no information about the dental–skeletal midlines. This must be recorded during the clinical examination.

A second aspect of dental–soft tissue relationships is the vertical relationship of the teeth to the lips at rest and on smile. During the clinical examination, it is important to note the amount of incisor display. For patients with excessive incisor display, the usual cause is a long lower third of the face, but that is not the only possibility; a short upper lip could produce the same thing (see Fig. 6.14). Recording lip height at the philtrum and the commissures can clarify the source of the problem. Remember, however, that whatever the cause of excessive display, this tends to decrease with advancing age, so what looks like a problem at a younger age may not be as the patient gets older (see Fig. 4.30).

A third important relationship to note is whether an up–down transverse rotation of the dentition is revealed when the patient smiles or the lips are separated at rest (Fig. 6.23). This often is called a *transverse cant of the occlusal plane* but is better described as a *transverse roll of the esthetic line of the dentition* (see the section in this chapter on classification by dentofacial traits). Neither dental casts nor a photograph with lip retractors will reveal this. Dentists detect a transverse roll at 1 mm from side to side, whereas laypersons are more forgiving and see it at 2 to 3 mm—but at that point, it is a problem.<sup>13</sup>

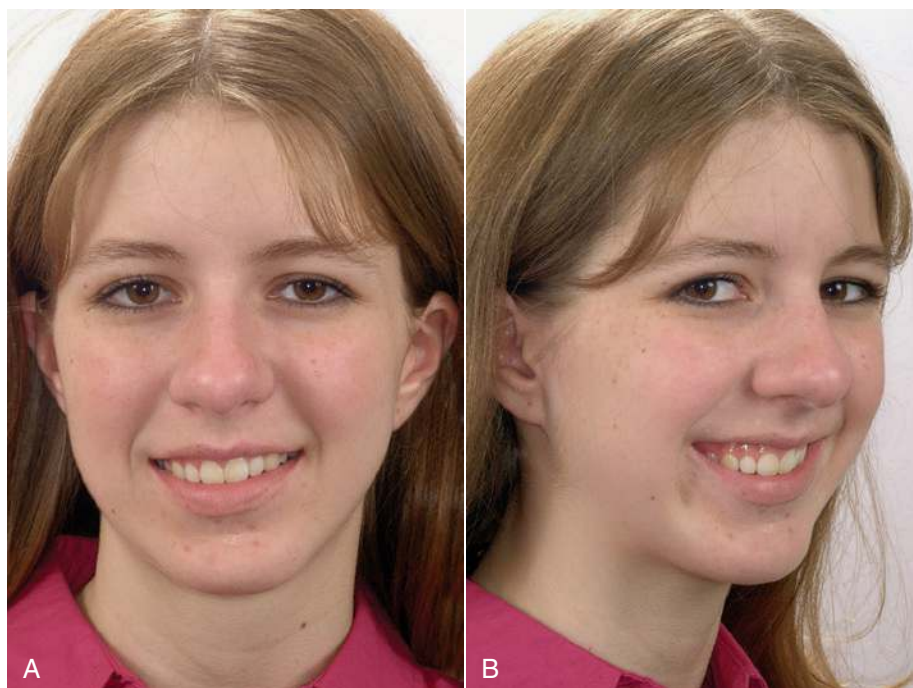
Facial attractiveness is defined more by the smile than by soft tissue relationships at rest. For this reason, it is important to

analyze the characteristics of the smile and to think about how the dentition relates to the facial soft tissues dynamically, as well as statically. There are two types of smiles: the posed or social smile and the enjoyment smile (also called the *Duchenne smile* in the research literature). The social smile is reasonably reproducible and is the one that is presented to the world routinely. The enjoyment smile varies with the emotion being displayed (for instance, the smile when you are introduced to a new colleague differs from the smile when your team just won the year's most important game). The social smile is the focus of orthodontic diagnosis.

In smile analysis, the oblique view and the frontal and profile views are important. The following variables need to be considered, while taking the viewing perspective (Table 6.6) into account.

1. *Amount of incisor and gingival display.* Using computer-altered photographs, recent research has established a range of acceptability for incisor and gingival display (Fig. 6.24).<sup>14</sup> Although some display of gingiva is acceptable and can be both esthetic and youthful appearing, the ideal elevation of the lip on smile for adolescents is slightly below the gingival margin with 2 mm of tooth coverage, so that most but not quite all of the upper incisor can be seen. More important, the acceptable range of tooth display is from minimal tooth coverage of 1 mm up to 4 mm coverage of the incisor crown. Beyond that, the smile appearance is less attractive.

It also is important to remember that the vertical relationship of the lip to the incisors will change over time, with the amount of incisor exposure decreasing (see Chapter 4).<sup>15</sup> This makes it even more important to note the vertical tooth–lip relationship during the diagnostic evaluation and to keep it in mind during treatment.



• **Fig. 6.23** A cant to the occlusal plane can be seen in both frontal (A) and oblique (B) views. This is a “roll deformity” that results from the orientation of the jaws and teeth rather than their position (roll is discussed further in the classification section of this chapter, later). It becomes an esthetic problem if it is noticeable, and lay observers do notice a cant of this degree of severity, or, in general, of 3 to 4 degrees to the horizontal.

**TABLE 6.6** Smile Variables

Variable	Ideal	Maximum	Minimum
<b>Variables Best Viewed in Full Face</b>			
Smile arc	Tracks the lower lip	0.6 mm higher at canines	Greater than flat
Buccal corridor (as % black space of intercommissure width)	16%	88%	8%
Gingival display	2.3 mm tooth coverage	0.8 mm tooth coverage	4.5 mm tooth coverage
Occlusal cant	0	2.8 degrees	
Upper to lower dental midlines	0	3.6 mm	
<b>Variables Viewed Either in Full Face or as Close-up of Lower Face</b>			
Upper dental midline to face	0 mm	2.9 to 3.2 mm	
Upper central to central incisor gingival height discrepancy	0 mm	2.0 to 2.1 mm	
Upper lateral to central incisor gingival height discrepancy	−0.4 mm	0.4 to 1.2 mm	−1.9 to −2.9 mm
Overbite	2 to 2.3 mm	5.4 to 5.7 mm	0.4 to 0.9 mm
Upper central to lateral incisal edge step	1.2 to 1.4 mm	2.0 to 2.9 mm	

Data from Ker AJ, Chan R, Fields HW, et al. *J Am Dent Assoc.* 2008;139:1318–1327, 2008; and Springer NC, Chang C, Fields HW, et al. *Am J Orthod Dentofac Orthop.* 2011;140:e171–e180.

2. *Transverse dimensions of the smile relative to the upper arch.* Depending on the facial index (i.e., the width of the face relative to its height), a broad smile may be more attractive than a narrow one—but what does that mean exactly? A dimension of interest to prosthodontists, and more recently to orthodontists, is the amount of buccal corridor that is displayed on smile—that is, the distance between the maxillary posterior teeth (especially the premolars) and the inside of the cheek (Fig. 6.25). Prosthodontists consider excessively wide buccal corridors (sometimes called “negative space”) to be unesthetic, and orthodontists have noted that widening the maxillary arch can improve the appearance of the smile if cheek drape is significantly wider than the dental arch. Although minimal buccal corridors are favored by most observers, especially in females, the transverse width of the dental arches can and should be related to the width of the face (Fig. 6.26). Too broad an upper arch, so that there is no buccal corridor, is unesthetic. The relationship of the cheeks to the posterior teeth on smile is just another way of evaluating the width of the dental arches.

3. *The smile arc.* The smile arc is defined as the contour of the incisal edges of the maxillary anterior teeth relative to the curvature of the lower lip during a social smile (Fig. 6.27). For best appearance, the contour of the incisal edges of these teeth should parallel the curvature of the lower lip. If the lip and dental contours match, they are said to be consonant.


A flattened (nonconsonant) smile arc can pose either or both of two problems: It is less attractive, and it tends to make you look older (because older individuals often have wear of the incisors that tends to flatten the arc of the teeth). The characteristics of the smile arc must be monitored during orthodontic treatment because it is surprisingly easy to flatten it in the pursuit of other treatment objectives. The data indicate that the most important factor in smile esthetics, the only one that by itself can change the rating of a smile from acceptable to unesthetic, is the smile arc.<sup>16</sup>

Another feature that draws negative attention to the smile is excessive inclination of the upper teeth as they tip toward the left or right (Fig. 6.28). Both dentists and laypersons notice an unesthetic quality of the smile when this inclination exceeds a 2-mm deviation from the normal, but tolerate a tilt less than that.

It is important to keep in mind that these features of the smile are viewed differently by patients when the full face is the context (i.e., when they are looking into a large mirror mounted so that they can see their whole face at about 2-feet distance—the normal social distance of interaction), instead of just seeing their lips and teeth (as in a hand-held mirror that shows only part of the face). With the full-face view, the smile arc is judged most attractive when the upper incisal edges and canines parallel the curvature of the lower lip. The preferred buccal corridors are small, significantly smaller than when judged using the smaller mirror. A transverse cant of the occlusal plane is less tolerated in the full-face view, but more upper to lower midline discrepancy is acceptable. When patients have complaints about these specific smile components, it is best to have them point out what concerns them while they are looking into a large mirror that lets them see their entire face—just as others will view them in real life encounters.

Because facial attractiveness and gender do make a difference for some of these features, Table 6.7 shows a range of acceptability for characteristics in which this is important. Although there are modest differences among nationalities and ethnic groups in their judgment of smile esthetics,<sup>17,18</sup> the acceptable ranges had some commonality for groups that were predominantly of European descent. Similar data for Asian and African groups are beginning to emerge.

Although smile arc, gingival display, buccal corridor, and upper midline to the face all are viewed significantly differently against a full-face background, the features described later that constitute micro-esthetics are unaffected by the size of the view. Patients can view these characteristics up-close in a hand mirror



• **Fig. 6.24** (A) Display of all the maxillary incisors and some gingiva on smiling is a youthful and appealing characteristic. (B) No gingival display is less attractive, although it is not considered objectionable at this level by lay persons. (C) There is agreement among laypersons regarding the acceptable range of gingival and tooth display during a posed smile. This girl shows 1 to 2 mm of gingiva, which is the maximum acceptable amount on a social smile. (D) Overlap by the lip of the cervical margin of the tooth by 1 to 2 mm is ideal. (E) Tooth coverage by the lip of 4 mm is considered to be the maximum acceptable amount.

or in a full-face view and make similar judgments. The facial context and attractiveness make little difference, and there are no sex differences.

**Micro-Esthetics: Close-up Dental Appearance.** Subtleties in the proportions and shape of the teeth and associated gingival contours have been emphasized in the burgeoning literature on “cosmetic dentistry” in recent years. These factors must be considered in the development of an orthodontic problem list if an optimal

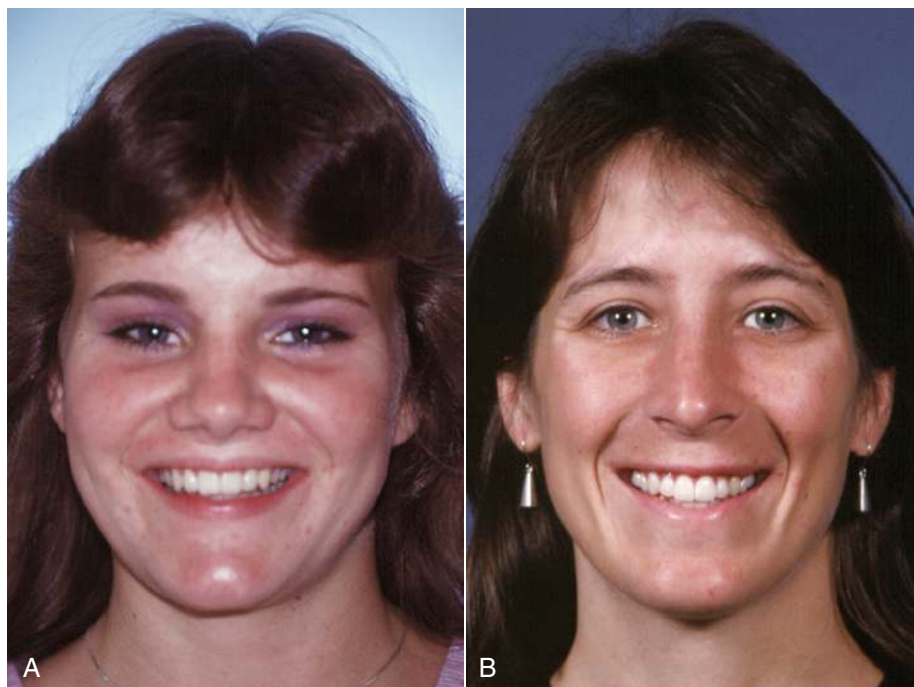esthetic result is to be obtained, and treatment planning to correct them is discussed in [Chapter 7](#) along with the orthodontic aspects of maximally esthetic treatment.

**Tooth Proportions.** The smile, of course, reveals the maxillary anterior teeth, and two aspects of proportional relationships are important components of their appearance: the tooth widths in relation to one another and the height–width proportions of the individual teeth.





• **Fig. 6.25** (A) Before treatment, this girl had a narrow maxillary arch with quite wide buccal corridors. (B) On 5-year recall, the broader smile (with narrow but not obliterated buccal corridors) is part of the esthetic improvement created by orthodontic treatment. It must be remembered that buccal corridor evaluation is subjective and that during clinical studies it has been shown to be unreliable.



• **Fig. 6.26** The width of the maxillary dental arch, as seen on smile, should be proportional to the width of the midface. (A) A broad smile is appropriate for a face with relatively large width across the zygomatic arches, but a narrower smile (B) is preferred when the face width is narrow. The patient in (B) was appropriately treated with maxillary premolar extraction to prevent overexpansion during treatment.





• **Fig. 6.27** The smile arc is the relationship of the curvature of the lower lip to the curvature of the maxillary incisors. The appearance of the smile is best when the curvatures match. (A) A flat smile arc, which is less attractive in both males and females, before treatment. (B) The same girl after treatment. The improvement in her smile was created solely by lengthening her maxillary incisors—in her case, with dental laminates rather than orthodontics.

**TABLE 6.7** Esthetic Variables: Maximum and Minimum for Esthetic Acceptability Considering Facial Attractiveness and Gender

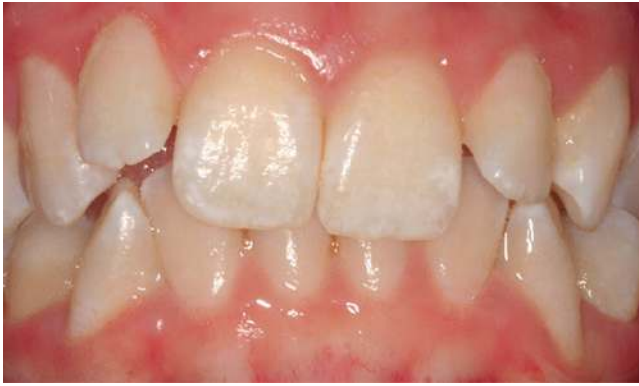Some smile variables are influenced by facial attractiveness and gender. This can be difficult to manage given the need to determine the patient's facial attractiveness. To simplify application of the information, the range of acceptability or "common ground" for all levels of facial attractiveness is noted below for each gender.

Smile Variable	Gender	Maximum	Minimum
Buccal corridor (percentage dark space of intercommissure distance)	M	24	15
	F	17	10
Gingival display (mm of tooth coverage)	M	0.5	1
	F	0.5	0.5
Smile arc (mm canine above incisal edge + or below –)	M	3.8	1.8
	F	3.8	1.8
Upper midline to face	M	2.3	0
	F	2	0

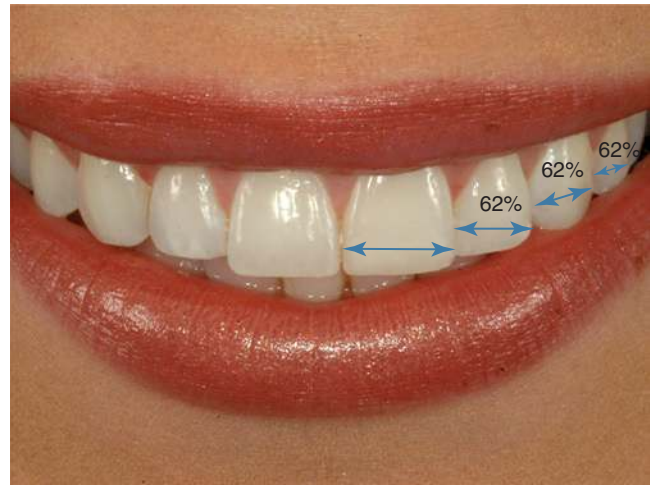
From Chang C, Springer NC, Fields HW, et al. *Am J Orthod Dentofac Orthop.* 2011;140:e171–e180.

**Width Relationships and the “Golden Proportion.”** The apparent widths of the maxillary anterior teeth on smile, and their actual mesiodistal width, differ because of the curvature of the dental arch such that not all of the lateral incisors and only a portion of the canine crowns can be seen in a frontal view. For best appearance, the apparent width of the lateral incisor (as one would perceive it from a direct frontal examination) should be 62% of the width

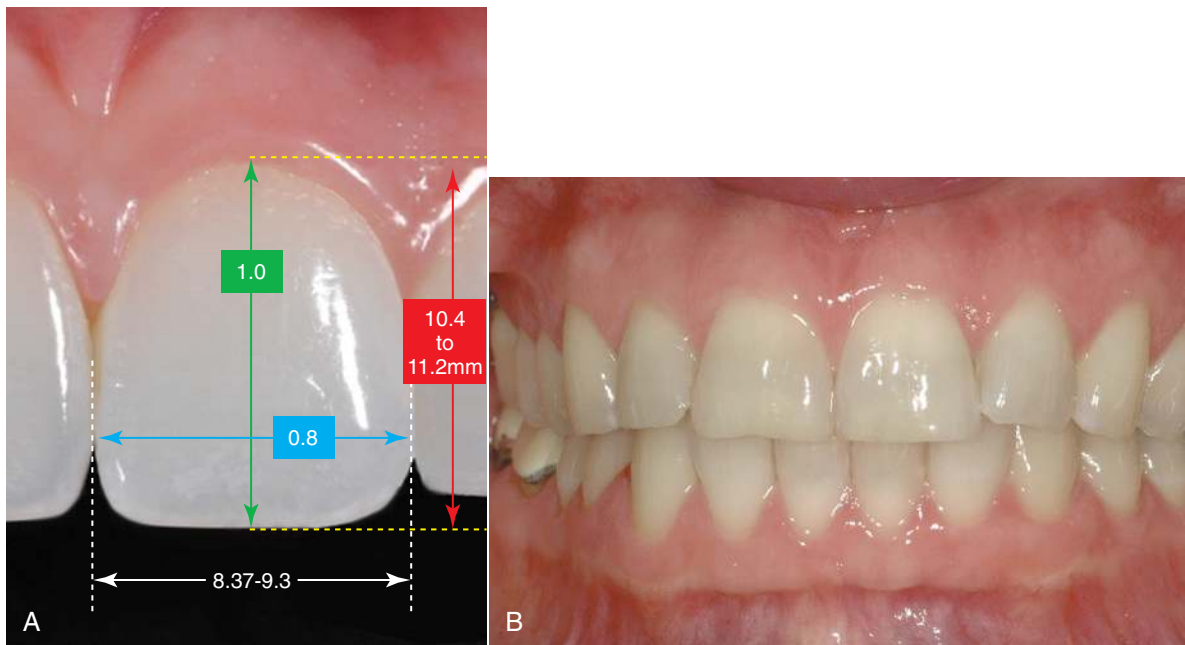
of the central incisor, the apparent width of the canine should be 62% of that of the lateral incisor, and the apparent width of the first premolar should be 62% of that of the canine (Fig. 6.29). This ratio of recurring 62% proportions appears in a number of other relationships in human anatomy and sometimes is referred to as the “golden proportion.” Whether it has any mystical significance or not, it is an excellent guideline when lateral incisors



• **Fig. 6.28** These maxillary central incisors are tipped mesiodistally. Laypersons find this objectionable esthetically when the inclination of the mesial proximal surface of an incisor exceeds a 2-mm deviation from where you would expect the normal, slightly angulated, surface to intersect the occlusal plane.



• **Fig. 6.29** Ideal tooth width proportions when viewed from the front are one of many illustrations of the “golden proportion”—1.0:0.62:0.38:0.24, and so on. In this close-up view of attractive teeth on smile, it can be seen that the width of the lateral incisor is 62% of the width of the central incisor; the apparent width of the canine is 62% of the width of the lateral incisor; and the apparent width of the first premolar is 62% of the width of the canine—which is the other way of representing the golden proportion.

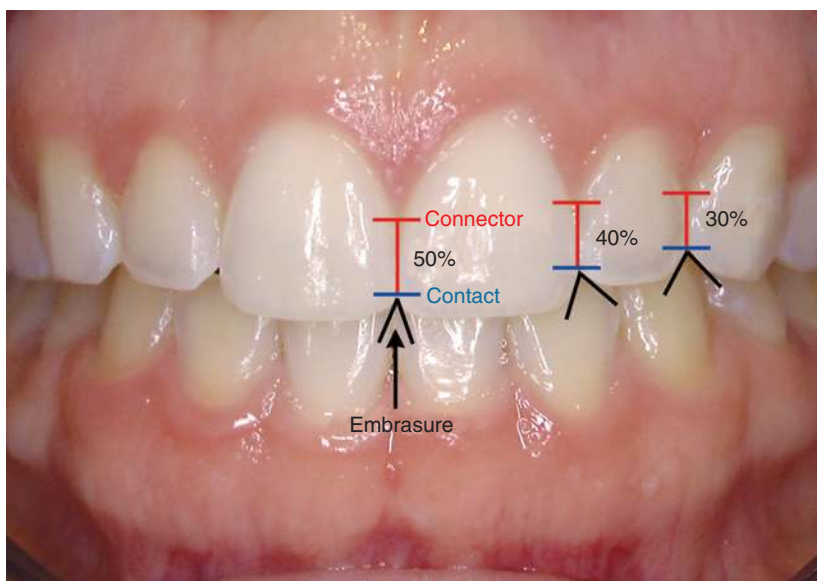


• **Fig. 6.30** (A) Height-width proportions for maxillary central incisors, with the normal range of widths and heights. The width of the tooth should be about 80% of its height. (B) This patient's central incisors look almost square, because their width is normal but their height is not. Increasing crown height would be a goal of comprehensive orthodontic treatment. How to do that would depend on mini- and macro-esthetic considerations.

are disproportionately small or (less frequently) large, and the width ratios of the central and lateral are the best way to determine what the posttreatment size of the lateral incisor should be. The same judgment is used when canines are narrowed to replace missing lateral incisors.

**Height-Width Relationships.** The range in height-width relationships for maxillary central incisors is shown in Fig. 6.30. Note

that the width of a visible tooth (i.e., incisors through premolars) should be about 80% of its height. In examining an orthodontic patient, it is important to note both height and width because if disproportions are noted, this allows a determination of which is at fault. The central incisor in Fig. 6.30B looks almost square. Its width measures 8.7 mm and its height 8.5 mm. From the table, the 8-mm width is in the middle of the normal range, and the



• **Fig. 6.31** The contact points of the maxillary teeth move progressively gingivally from the central incisors to the premolars, so there is a progressively larger incisal embrasure. The connector is the area that looks to be in contact in an unmagnified frontal view. Note that this decreases in size from the centrals posteriorly. Connectors that are too short often are part of the problem when “black triangles” appear between the teeth because the gingival embrasures are not filled with gingival papillae.

height is short. There are several possible causes: incomplete eruption in a child, which may correct itself with further development; loss of crown height from attrition in an older patient, which may indicate restoration of the missing part of the crown; excessive gingival height, which is best treated with crown lengthening; or perhaps an inherent distortion in crown form, which suggests a more extensive restoration with facial laminates or a complete crown (see [Chapter 19](#)). The disproportion and its probable cause should be included in the patient’s problem list to focus attention on doing something about it before orthodontic treatment is completed.

**Connectors and Embrasures.** These elements, illustrated in [Fig. 6.31](#), also can be of real significance in the appearance of the smile and should be noted as problems if they are incorrect. The connector (also referred to as the interdental contact area) is where adjacent teeth appear to touch and may extend apically or occlusally from the actual contact point. In other words, the actual contact point is likely to be a very small area, and the connector includes both the contact point and the areas above and below that are so close together they look as if they are touching. The normal connector height is greatest between the central incisors and diminishes from the centrals to the posterior teeth, moving apically in a progression from the central incisors to the premolars and molars. The embrasures (the triangular spaces incisal and gingival to the contact) ideally are larger in size than the connectors, and the gingival embrasures are filled by the interdental papillae.

**Embrasures: Black Triangles.** Short interdental papillae leave an open gingival embrasure above the connectors, and these “black triangles” can detract significantly from the appearance of the teeth on smile. Black triangles in adults usually arise from loss of gingival tissue related to periodontal disease, but when crowded and rotated maxillary incisors are corrected orthodontically in adults, the connector moves incisally and black triangles may appear, especially if severe crowding was present ([Fig. 6.32](#)). For that reason, both

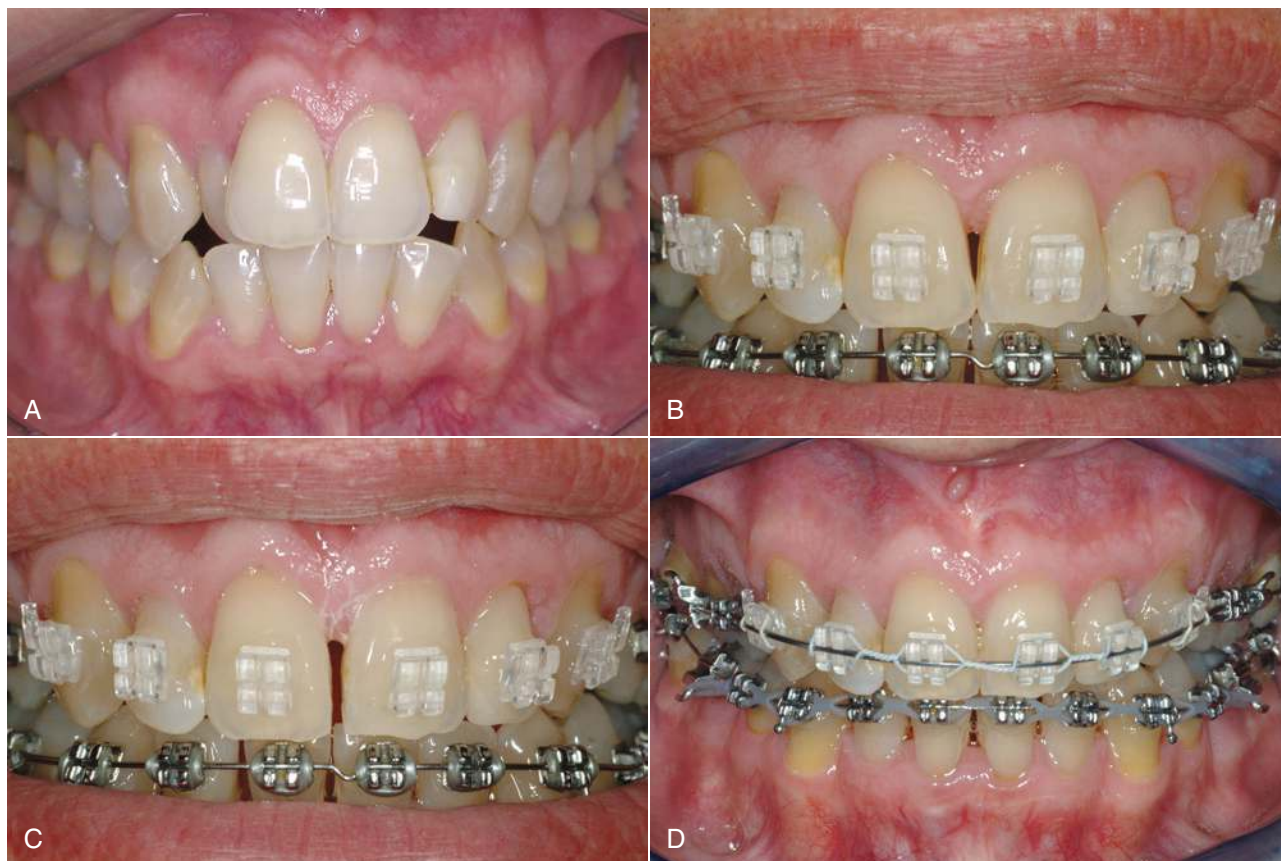actual and potential black triangles should be noted during the orthodontic examination, and the patient should be prepared for reshaping of the teeth to minimize this esthetic problem.

**Gingival Heights, Shape, and Contour.** Proportional gingival heights are needed to produce a normal and attractive dental appearance. In general, the central incisor has the highest gingival level, the lateral incisor is approximately 1.5 mm lower, and the canine gingival margin again is at the level of the central incisor. Maintaining these gingival relationships becomes particularly important when canines are used to replace missing lateral incisors or when other tooth substitutions are planned. Both laypersons and dentists readily recognize differences of more than 2 mm.

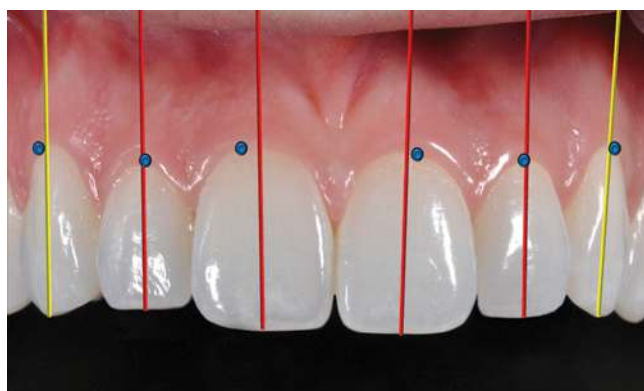
**Gingival shape** refers to the curvature of the gingiva at the margin of the tooth. For best appearance, the gingival shape of the maxillary lateral incisors should be a symmetric half-oval or half-circle. The maxillary centrals and canines should exhibit a gingival shape that is more elliptical and oriented distally to the long axis of the tooth ([Fig. 6.33](#)). The gingival zenith (the most apical point of the gingival tissue) should be located distal to the longitudinal axis of the maxillary centrals and canines; the gingival zenith of the maxillary laterals should coincide with their longitudinal axis.

**Tooth Shade and Color.** The color and shade of the teeth change with increasing age, and many patients perceive this as a problem. The teeth appear lighter and brighter at a younger age and darker and duller as aging progresses ([Fig. 6.34](#)). This is related to the formation of secondary dentin as pulp chambers decrease in size and to thinning of the facial enamel, which results in a decrease in its translucency and a greater contribution of the darker underlying dentin to the shade of the tooth. A normal progression of shade change from the midline posteriorly is an important contributor to an attractive and natural-appearing smile. The maxillary central incisors tend to be the brightest in the smile, the lateral incisors less so, and the canines the least bright. The first and





• **Fig. 6.32** (A) Crowded and rotated maxillary incisors at the beginning of orthodontic treatment in an adult. (B) After alignment of the incisors, a black triangle was present between the central incisors. (C) With the orthodontic appliance still in place, the incisors were reshaped so that when the contact point would be moved apically the midline connector would be lengthened. (D) After the space was closed the black triangle was no longer apparent.



• **Fig. 6.33** For ideal appearance, the contour of the gingiva over the maxillary central incisors and canines is a horizontal half-ellipse—that is, flattened horizontally, with the zenith the height of contour distal to the midline of the tooth. The maxillary lateral incisor, in contrast, has a gingival contour of a half-circle, with the zenith at the midline of the tooth. The canine gingival contour is a vertical half-ellipse, with the zenith just distal to the midline.

second premolars are more closely matched to the lateral incisors. They are lighter and brighter than the canines.

At present, even young patients are quite likely to be aware of the possibility of bleaching their teeth to provide a more youthful appearance and may benefit from having this done at the end of

orthodontic treatment. If color and shade of the teeth are a potential problem, this should be on the orthodontic problem list so that it is included in the final treatment plan if the patient desires it. It is important to recognize that any restorations will not be lightened by bleaching, so they may need to be replaced or modified to match the final color.

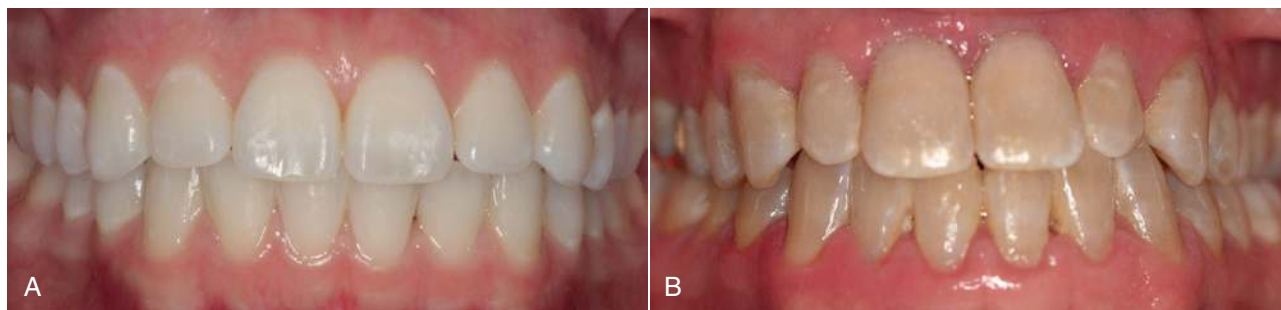## Diagnostic Records

### Which Diagnostic Records Are Needed?

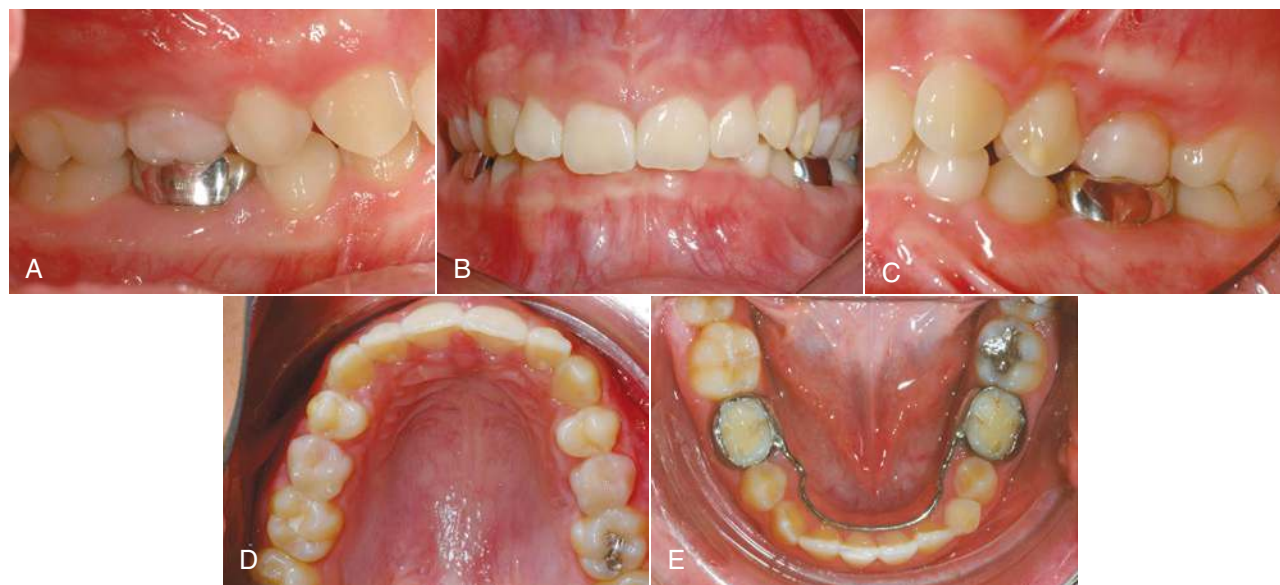
Which orthodontic records are ideal is not a clear-cut or simple judgment and depends on the problems that exist and the type of treatment anticipated.<sup>19</sup> Orthodontic diagnostic records are taken for two purposes: to document the starting point for treatment (after all, if you do not know where you started, it is hard to tell where you are going or how far you have come), and to add to the information gathered on clinical examination. It is important to remember that the records are supplements to, not replacements for, the clinical examination.

Orthodontic records fall into the same three major categories used for development of the diagnostic database: those for evaluation of the (1) health of the teeth and oral structures, (2) alignment and occlusal relationships of the teeth, and (3) facial and jaw proportions, which include both facial photographs, cephalometric radiographs, and computed tomography (CT) images. Digital





• **Fig. 6.34** (A) The teeth in younger patients show less incisal and occlusal wear and have more ideal shape because they have not been restored. Their color is also lighter even without whitening agents. (B) These teeth belong to an older patient and demonstrate extrinsic staining and likely pulpal obliteration along with more wear, decalcifications, and restoration.



• **Fig. 6.35** (A) to (E) Patient F.P., age 12-3, intraoral views before treatment. There is moderate maxillary incisor crowding, with the midline off due to displacement of the maxillary incisors. The maxillary incisors are tipped lingually, there is minimal overjet despite Class II buccal segments, and overbite is excessive. A pediatric dentist had placed a lingual arch to maintain alignment of the lower incisors.

photography now has replaced film, and digital images have done the same for radiographs.

### Records for Health of Teeth and Oral Structures

A major purpose of intraoral photographs, which should be obtained routinely for patients undergoing complex orthodontic treatment, is to document the initial condition of the hard and soft tissues. Five standard intraoral photographs are suggested: right, center, and left views with the teeth in occlusion, and maxillary and mandibular occlusal views (Fig. 6.35). Maximum retraction of the cheeks and lips is needed. If there is a special soft tissue problem (for instance, no attached gingiva in the lower anterior or palatal impingement on the maxillary lingual tissue), an additional photograph of that area is needed.

Current guidelines for radiographs developed by the American Dental Association (ADA) and the U.S. Public Health Service (USPHS) are provided in Table 6.8. We provide the context here for how they apply to orthodontics. A panoramic radiograph is

valuable for orthodontic evaluation at most ages beyond the early mixed dentition years. The panoramic image has two significant advantages over a series of intraoral radiographs: It yields a broader view and thus is more likely to show any pathologic lesions and supernumerary or impacted teeth, and the radiation exposure is much lower. It also gives a view of the mandibular condyles, which can be helpful, both in its own right and as a screening image to determine if tomography (CBCT) or magnetic resonance imaging (MRI) of the joint is needed. TMJ symptoms often are due to problems with the intraarticular disc or the ligaments that suspend it, which cannot be seen in radiographs but can be seen with MRI. Imaging of the TMJ and recommendations for current practice are covered in detail in an overview based on a multisite study.<sup>20</sup>

The panoramic radiograph should be supplemented with periapical or occlusal radiographs only when greater detail is required. In addition, for children and adolescents, periapical views of incisors are indicated if there is evidence or suspicion of root resorption or aggressive periodontal disease. The principle is that periapical

**TABLE 6.8 U.S. Public Health Service Guidelines: Dental Radiographic Examination for Pathologic Conditions**

Condition	Recommended Radiographs
Regular dental care	
No previous caries	Panoramic radiograph only
No obvious pathologic condition	
History of fluoridation	
Previous caries	Add bitewings
Obvious caries	
Deep caries	Add periapicals, affected area only
Periodontal disease	Add bitewings or periapicals, affected areas only

From the American Dental Association/U.S. Food and Drug Administration. *Guidelines for Prescribing Dental Radiographs*, revised 2009.

or other radiographs to supplement the panoramic radiograph are ordered only if there is a specific indication for doing so, in order to keep the amount of radiation to a minimum that is consistent with obtaining the necessary diagnostic information.

A frequent problem that deserves radiographic follow-up is localization of an unerupted maxillary canine that cannot be palpated in the buccal vestibule at dental age 10. Now that CBCT has become widely available, it is the preferred method for localizing canines (Fig. 6.36). Both the position of the impacted tooth and the extent of damage to the roots of other teeth can be evaluated better with true three-dimensional (3-D) images. The use of 3-D imaging, including its possible replacement of panoramic and cephalometric radiographs, is discussed further in the section of this chapter on analysis of these images.

### Dental Records

Evaluation of the occlusion requires two things: impressions for dental casts or digital scanning into computer memory, and a record of the occlusion (either a wax bite or a buccal scan) so that the casts or images can be related to each other. For some but not all patients, a facebow transfer of the dental casts to an articulator may be needed. The following paragraphs consider this in greater detail.

### Physical Versus Virtual Casts

Whether physical plaster or virtual orthodontic diagnostic casts are to be produced, an impression of the teeth that also gives maximum displacement of the lips and cheeks is desired. Being able to visualize the inclination of the teeth, not just the location of the crown, is important. If the impression is not well extended, important diagnostic information may be missing. If the impressions are to be poured in dental stone without great delay, alginate impressions are satisfactory; if virtual models will be produced, a more accurate and stable impression material (such as modified alginate or polysiloxane) should be used. At this point, direct intraoral scanning of the teeth and supporting tissues also is acceptable for obtaining virtual casts if there is adequate lip and cheek retraction.

At the minimum, a wax bite or polysiloxane record of the patient's usual interdigitation (maximum intercuspation) should be made, and a check should be made to be sure that this does not differ significantly from the initial contact position. An anterior shift of 1 to 2 mm from the retruded position is of little consequence unless it creates a pseudo-Class III relationship, but lateral shifts or anterior shifts of greater magnitude should be noted carefully and a bite registration in an approximate centric relation position should be made.

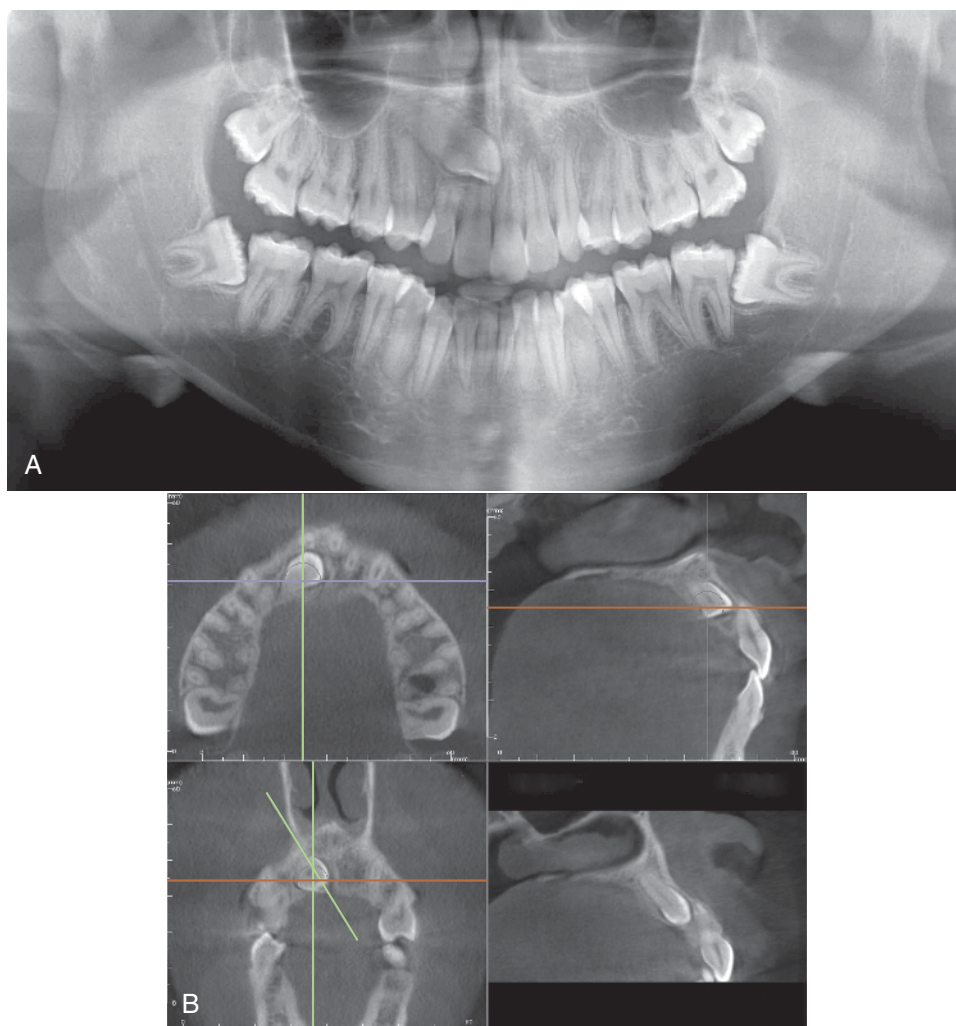
Dental casts for orthodontic purposes were usually trimmed so that the bases were symmetric and then are polished. Now that digital images often are used, they still are prepared to look like trimmed and polished casts (Fig. 6.37). There are two reasons for doing this: (1) If the casts are viewed with a symmetric base that is oriented to the midline of the palate, it is much easier to analyze arch form and detect asymmetry within the dental arches; and (2) neatly trimmed and polished casts are more acceptable for presentation to the patient, as will be necessary during any consultation about orthodontic treatment. By convention, these trimmed and polished casts are then referred to as *models*. In specialty practice, virtual models have the great advantage that they eliminate the need for storage space and can be used for computer-assisted fabrication of appliances.

There are three ways at present to generate digital casts: from laser scans of impressions, from scans of casts poured up from impressions, or from direct intraoral scans. As intraoral scanning has evolved and eliminated long scan times and reflective powder coating on the teeth, direct scanning is now the most efficient method to develop accurate digital casts and occlusal relationships.<sup>21</sup> This also eliminates impressions that are unpleasant for patients, which becomes more important when multiple scans may be needed to obtain data required for a computer-controlled wire-bending robot to fabricate archwires. Application of this technology is discussed in Chapter 10.

To relate the virtual casts to each other, one method is to use a conventional wax bite so that the poured casts from the initial impressions are indexed to each other and scanned. The other is to use three scans: the maxillary and mandibular casts separately and then a scan with the casts in occlusion, which shows only the facial surfaces. Although this method has been validated,<sup>22</sup> there is no external point as a reference for the articulated casts.

**Articulator Mounting.** Whether it is desirable to mount casts on an adjustable articulator as part of an orthodontic diagnostic evaluation is a matter of continuing debate. There are three reasons for mounting casts on articulators. The first is to record and document any discrepancy between the occlusal relations at the initial contact of the teeth and the relations at the patient's full or habitual occlusion. The second is to record the lateral and excursive paths of the mandible, documenting these and making the tooth relationships during excursions more accessible for study. A third, which increasingly is superseded by CBCT images, is to display the orientation of the occlusal plane to the face.

Knowing the centric occlusal relationship when the condyles are positioned "correctly" obviously is important for orthodontic diagnostic purposes if there is a significant difference between it and the usual intercuspation. Unfortunately, there is no current agreement as to what the "correct" centric position is, although the "muscle-guided" position (the most superior position to which a patient can bring the mandible using his or her own musculature) seems most appropriate for orthodontic purposes. It is now generally accepted that in normal individuals this neuromuscular position is anterior to the most retruded condylar position. Lateral shifts or large anterior



• **Fig. 6.36** (A) An impacted maxillary canine, seen in a panoramic radiograph and (B) in cone beam computed tomography (CBCT) sections in various planes of space. (For an overall three-dimensional view of a similar case, see Fig. 6.65). Note that it is impossible to evaluate the extent of root resorption of the lateral and central incisors from the panoramic radiograph, and it is difficult to determine whether the canine is facial or lingual to the incisors. From the CBCT slices, it is apparent that the lateral incisor root has been damaged but the central incisor root is intact, although it is very close to the crown of the canine, and the canine is on the palatal side. This information changes the treatment plan and biomechanics from what it would have been if the panoramic radiograph were supplemented with periapicals that determined the palatal canine position but not the details of its relationship to the other teeth: it will be important for the orthodontist to first move the canine palatally, away from the incisors, before beginning to bring it down toward the occlusal plane. Otherwise, the central incisor root is almost sure to be damaged during the movement of the canine.

shifts are not normal and should be recorded. Articulator-mounted casts are one way, but not the only way, to do that.

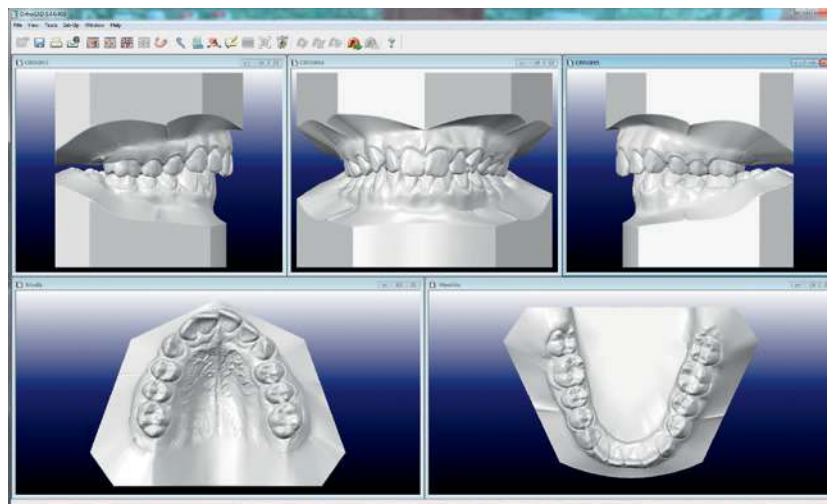
The second reason for mounting casts—to record the excursive paths—is important when restorative dentistry is being planned because the contours of the replacement or restored teeth must accommodate the path of movement. This is much less important when tooth positions and jaw relationships will change during treatment.

The current consensus is that for preadolescent and early adolescent orthodontic patients (i.e., those who have not completed their adolescent growth spurt), there is little point in an articulator mounting. In these young patients, the contours of the TMJ are not fully developed, so condylar guidance is much less prominent

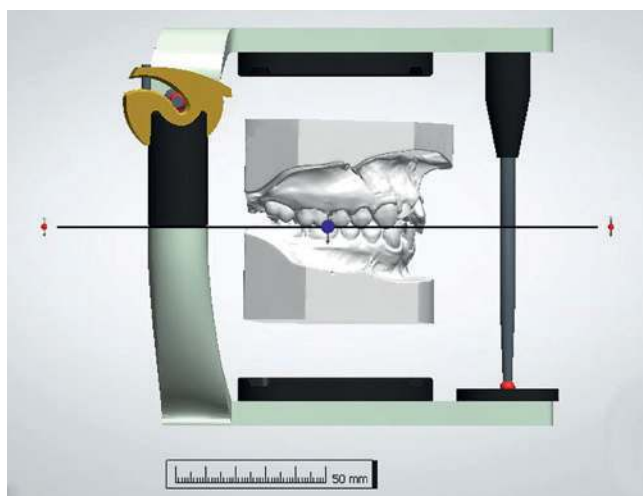
than in adults. The shape of the temporal fossa in an adult reflects function during growth. Thus, until mature canine function is reached and the chewing pattern changes from that of the child to the normal adult (see Chapter 3), completion of the articular eminence and the medial contours of the joint should not be expected. In addition, the relationships between the dentition and the joint that are recorded in articulator mountings change rapidly while skeletal growth is continuing and tend to be only of historic interest after orthodontic treatment.

The situation is different when growth is complete or largely complete. In adults with symptoms of temporomandibular dysfunction (TMD; clicking, limitation of motion, pain), articulator-mounted casts may be useful to document significant discrepancies between





• **Fig. 6.37** Digital casts, which usually are produced from intraoral scans, can be displayed with or without symmetric bases. The advantage of the bases is that they help the observer detect asymmetries within the dental arches. These six views are traditionally available for diagnostic and treatment planning purposes.



• **Fig. 6.38** The 3Shape virtual articulator (3Shape A/S, Copenhagen, Denmark) provides for some individualization of the settings for the mounted cast along with various movements and view perspectives. This technology, intended to replace physical articulators, is progressing and has shown reasonable accuracy when used in conjunction with surgical planning and splint construction.

habitual and relaxed mandibular positions. These patients often need therapy to reduce muscle spasm and splinting before the articulator mounting is done. An articulator mounting may also be needed to plan orthodontic or surgical treatment of adults with significant cants of the occlusal plane or asymmetries.

It is widely anticipated that virtual articulators will replace physical ones before long; at present they are continuing to evolve (Fig. 6.38). Software used for surgical treatment planning already has produced something like a true virtual articulator. It is possible to virtually relate casts to each other for model surgery and fabrication of bite wafers for surgery. This has proven to be equally as accurate as, if not more accurate than, manual methods.<sup>23</sup> The current limitations include the costs of these systems and the knowledge level to use and apply them. Interestingly, these systems

can also include a haptic system that introduces the feel of the articulator and restoration contact for the laboratory technician. To make them more attractive to the orthodontic community, set-up modules can be included.

That does not change the indication for articulator use in orthodontics; physical or virtual, articulators are indicated primarily for adult patients with functional problems, not for children or adolescents.

### Records for Dentofacial Proportions

For any orthodontic patient, facial and jaw proportions, not just dental occlusal relationships, must be evaluated. This is done best by a careful clinical evaluation of the patient's face (as described previously), and data from the clinical examination are an important part of the diagnostic database, but both a cephalometric radiograph and facial photographs, and sometimes CT images, are needed as records to support the clinical findings.

**Radiographs.** Like all radiographic records, cephalograms should be taken only when they are indicated. Lateral cephalometric radiographs are the standard for comprehensive orthodontic treatment. They allow analysis of the pretreatment form (positions and relationships) for diagnosis and treatment planning. In 1992, this was estimated to alter treatment in about 20% of cases,<sup>24</sup> and that proportion still is accepted. More important, they provide for evaluation of progress and the posttreatment result when follow-up cephalograms are taken. Treatment changes cannot be understood without cephalometric superimpositions. It is irresponsible to undertake growth modification treatment in a child without a pretreatment lateral cephalometric radiograph, because knowing the timing, direction, and magnitude of the pretreatment growth and subsequent changes due to treatment and growth are critical to success.

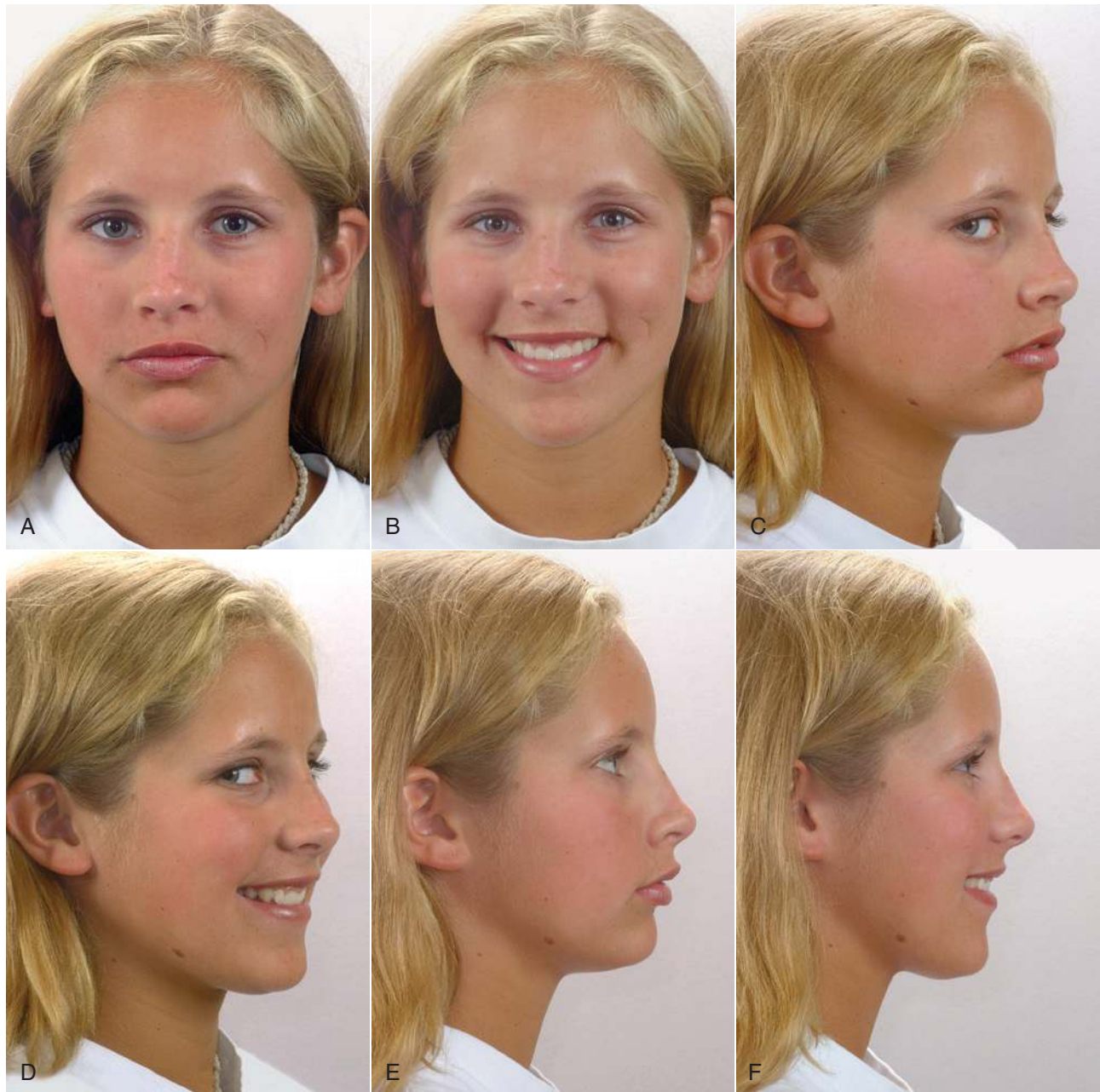The major indication for a frontal (posteroanterior [PA], not AP) cephalometric radiograph was facial asymmetry, and this now is an indication for 3-D imaging instead (see the section on analysis of 3-D images, later), so PA cephalograms are obsolete. For treatment of minor problems in children or for adjunctive treatment procedures in adults, cephalometric radiographs usually are not required, simply



because jaw relationships and incisor positions would not be changed significantly.

**Facial Photographs.** A series of facial photographs has been a standard part of orthodontic diagnostic records for many years. The minimum set is three photographs, frontal at rest, frontal smile, and profile at rest, but it can be valuable to have a record of tooth–lip relationships in other views (Fig. 6.39). The oblique smiling photo, for instance, provides an excellent view of both vertical tooth–lip relationships and the smile arc. Although 3-D photography now is available and is a valuable research tool (see Fig. 2.11), it has little to add to an orthodontic diagnostic evaluation and, despite the trend toward 3-D imaging, is unlikely to become widely used for that purpose.

With the advent of digital records, it is easy now to obtain a short segment of digital video as the patient smiles and turns from a frontal to a profile view. The resulting set of images allows analysis of facial relationships at rest and in function, and in the early 21st century it was thought this would become the preferred photographic record set when the cost of high-quality video went down. It is important to keep in mind that even the best photographs or videos are never a substitute for careful clinical evaluation—they are just a record of what was observed clinically, or what should have been observed and recorded—and the current view of digital video is that the gain in diagnostic information over careful clinical analysis simply is not worth the time and effort to obtain and analyze it.



• **Fig. 6.39** (A) to (F) Patient F.P., age 12-3, facial views before treatment. Note the mildly short anterior face height, the lack of mandibular projection, and the appearance of the maxillary incisors on smile—very upright with short clinical crowns but minimal gingival display.

### Diagnostic Records Summary

In summary, minimal diagnostic records for any orthodontic patient consist of data from the clinical examination of dentofacial characteristics, dental casts trimmed to represent the occlusal relationship (or their electronic equivalent), facial and intraoral photographs, and appropriate radiographs for that individual patient. The radiographs are the judgment call in deciding what records are needed.

The guideline for radiography is that you should obtain the images you need, while keeping the radiation dose as low as possible. With that in mind, a panoramic radiograph is needed for almost every patient and may be available from the patient's family dentist. If it is available, obtaining a lateral cephalogram is sensible unless there is severe enough facial asymmetry to indicate that full-field CBCT is indicated.

If you have the panoramic radiograph and there is a suspected localized issue, you will best serve the patient in terms of radiation by getting a cephalometric radiograph and a small-field CBCT view, because you will likely need higher resolution of the problem area.

If none of these images are available and you need a panoramic, cephalometric radiograph and a close-up view of a specific localized area, a full-field image can address all these issues, although the panoramic and cephalometric radiographs constructed from CBCT have lower resolution than individual images.

### Analysis of Diagnostic Records

Comments on the analysis of intraoral radiographs appear in the previous section on clinical evaluation, along with assessment of intraoral and facial clinical findings that were recorded photographically. In this section, the focus is on four things: (1) dental cast analysis to evaluate symmetry and space excess or deficiency within the dental arches, (2) cephalometric analysis of dentofacial relationships, (3) analysis of 3-D CBCT images, and (4) integration of information from all sources into the problem-oriented format that facilitates treatment planning.

#### Cast Analysis: Symmetry, Space, and Tooth Size

**Symmetry.** An asymmetric position of an entire arch should have been detected already in the facial and esthetic examination, but an asymmetry of arch form may be present even if the face looks symmetric. Evaluating dental casts from the occlusal view when the cast bases have been trimmed symmetrically can make it easier to see a distortion of arch form in either physical or virtual casts (see Fig. 6.37).

Asymmetry within the dental arch but with a symmetric arch form also can occur. This is due either to severe crowding or spacing or to drift of anterior or posterior teeth on one side of the arch. The primary cause of drift is premature loss of a primary canine followed by lateral movement of the incisors, or premature loss of a primary molar on one side and movement of both anterior and posterior teeth. The ruled grid also helps in seeing where drift of teeth has occurred.

**Alignment, Crowding, and Spacing: Space Analysis.** It is important to quantify the amount of space available for alignment of the teeth within the dental arches because treatment varies depending on whether the space is adequate, deficient, or excessive. In adolescents and adults, the amount of available space and the amount required to align all the teeth can be measured directly, but in the mixed dentition there is a difference between the apparent crowding at one point in time and the true ultimate crowding after the transition

from the mixed to permanent dentition. Space analysis, using the dental casts or virtual casts to measure the space available for the teeth and a prediction of the size of unerupted canines and premolars, is required for this purpose and will reveal the true ultimate crowding. The steps in mixed dentition space analysis and the assumptions that underlie it are covered in detail in Chapter 11.

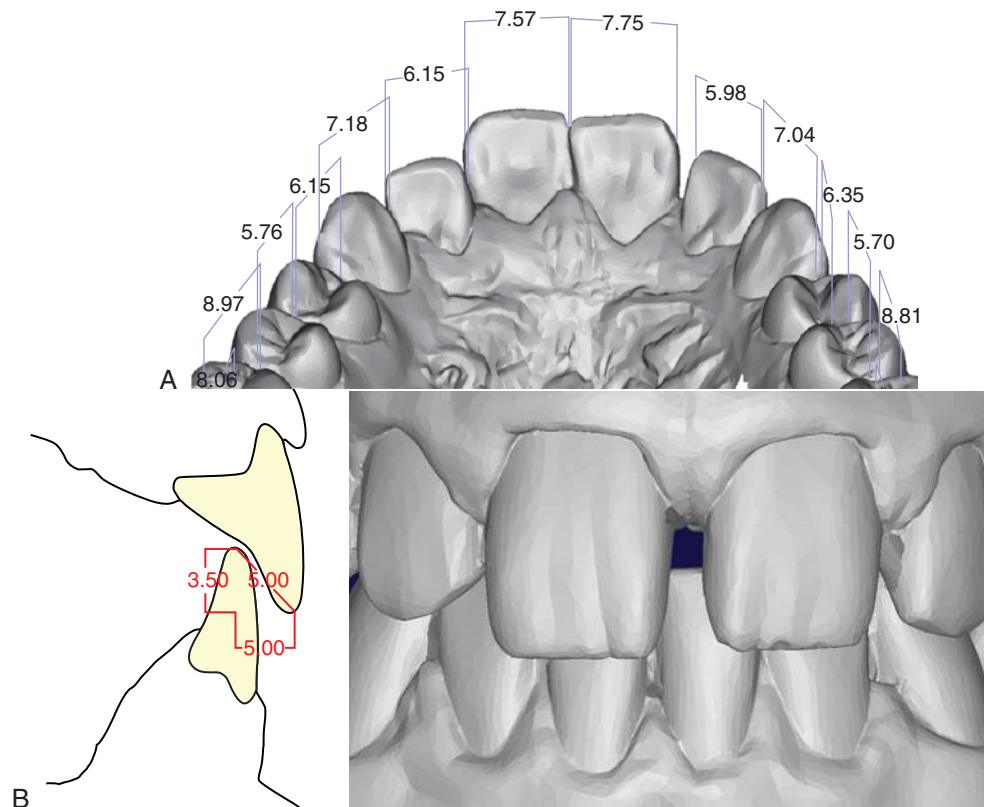
**Tooth Size Analysis.** For good occlusion, the upper and lower teeth must be proportional in size. If large upper teeth are combined with small lower teeth, as in a denture set-up with mismatched sizes, there is no way to achieve ideal occlusion. Although the natural teeth match very well in most individuals, approximately 5% of the population have some degree of disproportion among the sizes of individual teeth. This is termed *tooth size discrepancy*. Variation in the width of the upper lateral incisors or an anomaly of their size (enlarged, diminutive, or peg-shaped) is the most common cause, but variations in the size of premolars or other teeth may be present. Occasionally, all the upper teeth will be too large or too small to fit properly with the lower teeth.

Tooth size analysis, often called *Bolton analysis* after its developer,<sup>25</sup> is carried out by measuring the mesiodistal width of each permanent tooth. A standard table (Table 6.9) is then used to compare the summed widths of the maxillary to the mandibular anterior teeth (canine to canine) and the total width of all upper to lower teeth (excluding second and third molars). One advantage of measuring individual tooth widths into a computer template during space analysis is that the computer then can quickly provide individual tooth and interarch and intra-arch measurements (Fig. 6.40), and the computer can calculate a tooth size analysis (Fig. 6.41).

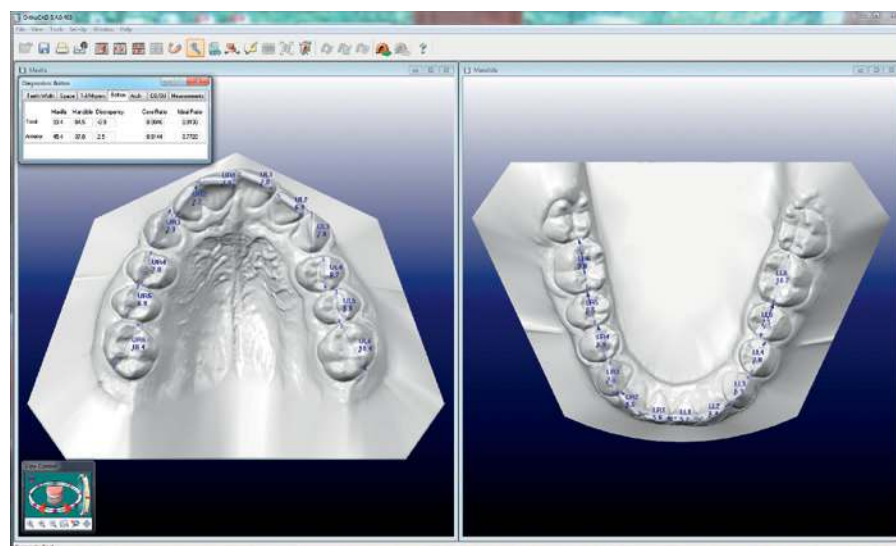
**TABLE 6.9** Tooth Size Relationships

Maxillary Anterior Sum of 3-3	Mandibular Anterior Sum of 3-3	Maxillary Total Sum of 6-6	Mandibular Total Sum of 6-6
40	30.9	86	78.5
41	31.7	88	80.3
42	32.4	90	82.1
43	33.2	92	84.0
44	34.0	94	85.8
45	34.7	96	87.6
46	35.5	98	89.5
47	36.3	100	91.3
48	37.1	102	93.1
49	37.8	104	95.0
50	38.6	106	96.8
51	39.4	108	98.6
52	40.1	110	100.4
53	40.9		
54	41.7		
55	42.5		

From Bolton WA. *Angle Orthod.* 1958;28:113–120.

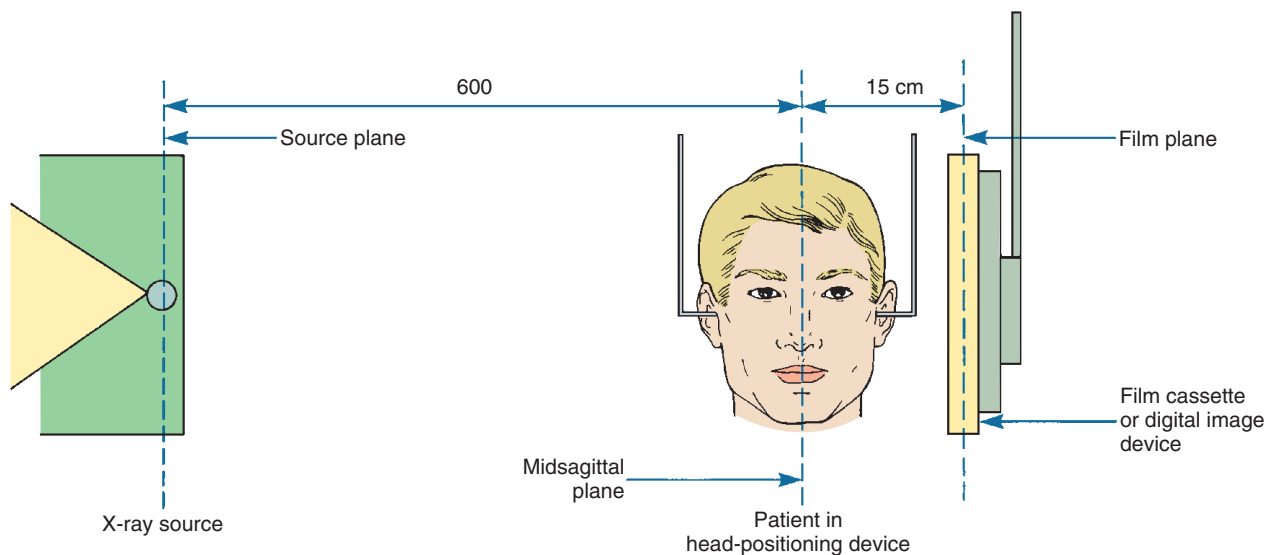


• **Fig. 6.40** (A) Accurate measurements can be achieved from digital casts derived from direct intraoral scans. Usually, virtual casts are related to each other with use of a scan of the buccal interdigitation. (B) It is possible to create sagittal representations of the digital casts and juxtapose them as shown here so that precise measurements can be made.



• **Fig. 6.41** Tooth-size analysis (Bolton analysis) also is readily available from digital casts. This requires accurate measurement of the width of each of the teeth, so that the sum of the incisor widths in each arch, and the sum of the widths of all the teeth, can be compared with these sums for the other arch (see Table 6.9).





• **Fig. 6.42** Diagrammatic representation of the American standard cephalometric arrangement. By convention, the distance from the x-ray source to the subject's midsagittal plane is 5 feet. The distance from the midsagittal plane to the cassette can vary but must be the same for any one patient every time so that magnification is the same and changes from one time to another can be measured accurately.

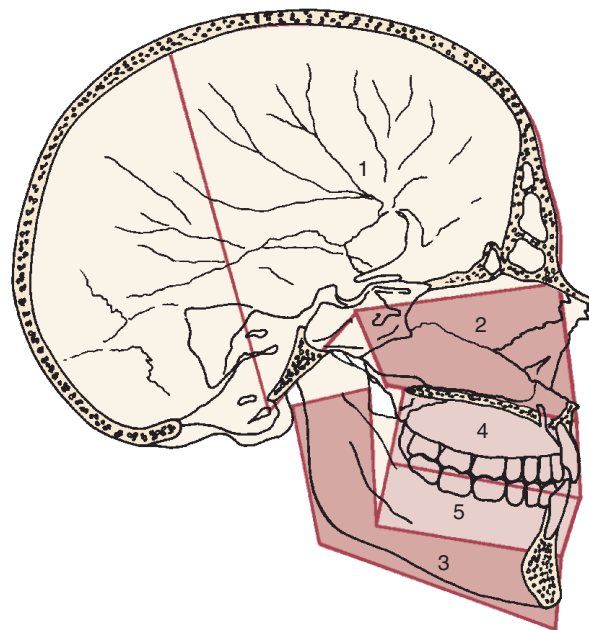
A quick check for anterior tooth size discrepancy can be done by comparing the size of upper and lower lateral incisors. Unless the upper laterals are wider, a discrepancy almost surely exists. A quick check for posterior tooth size discrepancy is to compare the size of upper and lower second premolars, which should be about equal size. A tooth size discrepancy of less than 1.5 mm is rarely significant, but larger discrepancies create treatment problems in achieving ideal interdigitation, overjet and overbite, and must be included in the orthodontic problem list.

### Cephalometric Analysis

**Early Cephalometrics: From Research to Clinical Application.** The introduction of radiographic cephalometrics in 1934 by Hofrath in Germany and Broadbent in the United States provided both a research and a clinical tool for the study of malocclusion and underlying skeletal disproportions (Fig. 6.42). The original purpose of cephalometrics was research on growth patterns in the craniofacial complex. The concepts of normal development presented in Chapters 2 and 3 were largely derived from such cephalometric studies.


It soon became clear, however, that cephalometric radiographs could be used to evaluate dentofacial proportions and clarify the anatomic basis for a malocclusion. The orthodontist needs to know how the major functional components of the face (cranial base, jaws, teeth) are related to one another (Fig. 6.43). Any malocclusion is the result of an interaction between jaw position and the position the teeth assume as they erupt, which is affected by the jaw relationships (see Chapter 4 for a discussion of dental compensation or adaptation). For this reason, apparently similar malocclusions as evaluated from the dental occlusions may turn out to be quite different when evaluated more completely (Fig. 6.44). Although careful observation of the face can provide this information, cephalometric analysis allows greater precision.

Cephalometric radiographs are not taken as a screen for pathologic problems, but the possibility of observing pathologic changes on these radiographs should not be overlooked. Occasionally,



• **Fig. 6.43** The structural components of the face, shown superimposed on the anatomic drawing. The cranium and cranial base (1), the skeletal maxilla and nasomaxillary complex (2), and the skeletal mandible (3) are parts of the face that exist whether there is or is not a dentition. The maxillary teeth and alveolar process (4) and the mandibular teeth and alveolar process (5) are independent functional units, which can be displaced relative to the supporting bone of the maxilla and mandible, respectively. The major goal of cephalometric analysis is to establish the relationship of these components in both the anteroposterior and vertical planes of space.





• **Fig. 6.44** The ideal relationships of the facial and dental components can be represented as shown in (A). Cephalometric analysis can distinguish and clarify the differing dental and skeletal contributions to malocclusions that present identical dental relationships. A Class II division 1 malocclusion, for example, could be produced by (B) protrusion of the maxillary teeth although the jaw relationship was normal, (C) mandibular deficiency with the teeth of both arches normally related to the jaw, (D) downward and backward rotation of the mandible produced by excessive vertical growth of the maxilla, or a number of other possibilities. A Class III malocclusion could be produced by (E) true mandibular prognathism with a normal maxilla, (F) maxillary anteroposterior and vertical deficiencies that make a normal-size mandible look prominent because the maxillary vertical deficiency allowed it to rotate up and forward, or any other combination of maxillary deficiency and mandibular excess. The objective of cephalometric analysis is to visualize the contribution of skeletal and dental relationships to the malocclusion in this way, not to generate a table of numbers that are estimators of relationships. Measurements and other analytic procedures are a means to the end of understanding dental and skeletal relationships for an individual patient, not ends in themselves.

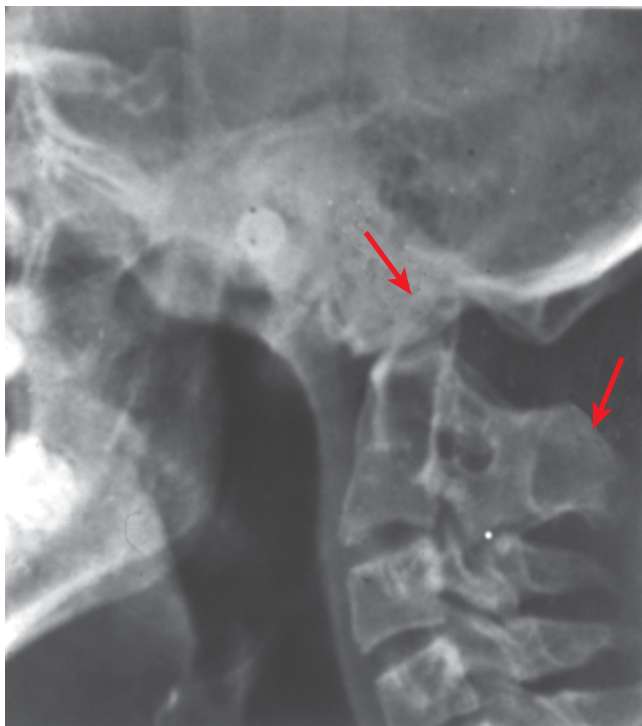previously unsuspected anomalies in the cervical spine (Fig. 6.45) or degenerative changes in the vertebrae are revealed in a cephalometric radiograph, and sometimes other pathologic changes in the skull, jaws, or cranial base can be observed.<sup>26</sup> This becomes particularly important when full-view 3-D images of the head are obtained (see later), and examination of such images by a radiologist is needed to be sure that a pathologic condition is not overlooked.

Perhaps the most important clinical use of radiographic cephalometrics is in recognizing and evaluating changes brought about by orthodontic treatment. Superimpositions taken from serial cephalometric radiographs before, during, and after treatment can be superimposed to study changes in jaw and tooth positions retrospectively (Fig. 6.46). The observed changes result from a combination of growth and treatment (except in nongrowing adults). It is all but impossible to know what is really occurring during

treatment of a growing patient without reviewing cephalometric superimpositions, which is the reason that cephalometric radiographs are required for comprehensive orthodontic treatment of children and adolescents.

For diagnostic purposes, the major use of radiographic cephalometrics is in characterizing the patient's dental and skeletal relationships. In this chapter, we focus on the use of cephalometric analysis to compare a patient to his or her ethnic and racial peers, using population standards. The use of cephalometric predictions to estimate orthodontic and surgical treatment outcomes is covered for children, adolescents, and adults later, in the clinical treatment chapters.

**Development of Cephalometric Analysis.** Cephalometric analysis is commonly carried out not on the radiograph itself, but on a tracing or digital model that emphasizes the relationship of selected points. In essence, the tracing or model is used to reduce

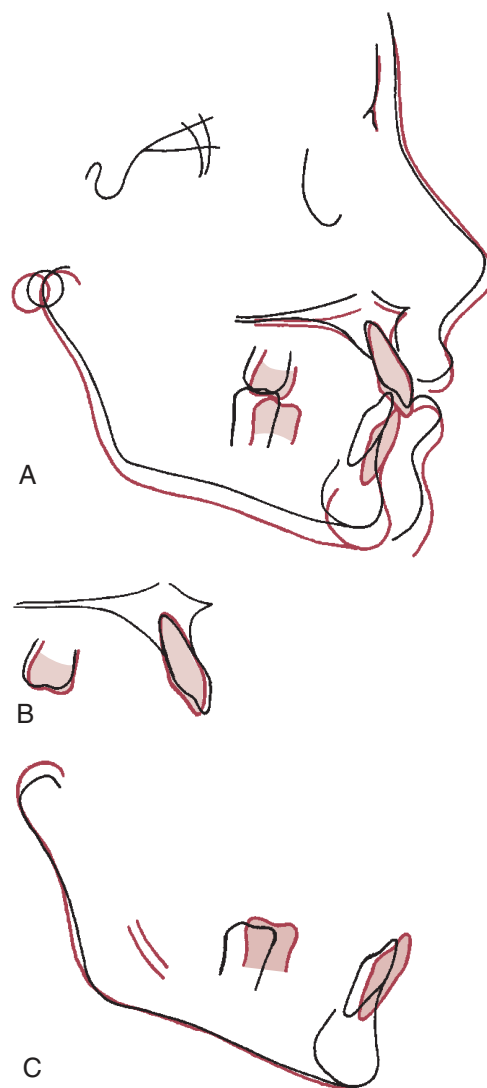


• **Fig. 6.45** Vertebral pathologic characteristics can be observed in cephalometric radiographs and sometimes is discovered by the orthodontist. This patient has fusion of the first and second cervical vertebrae (*right arrow*), with the odontoid process extending into the margin of foramen magnum (*left arrow*). This is a potentially life-threatening situation because a blow to the head or extreme positioning of the head could lead to damage to the spinal cord at the foramen level.

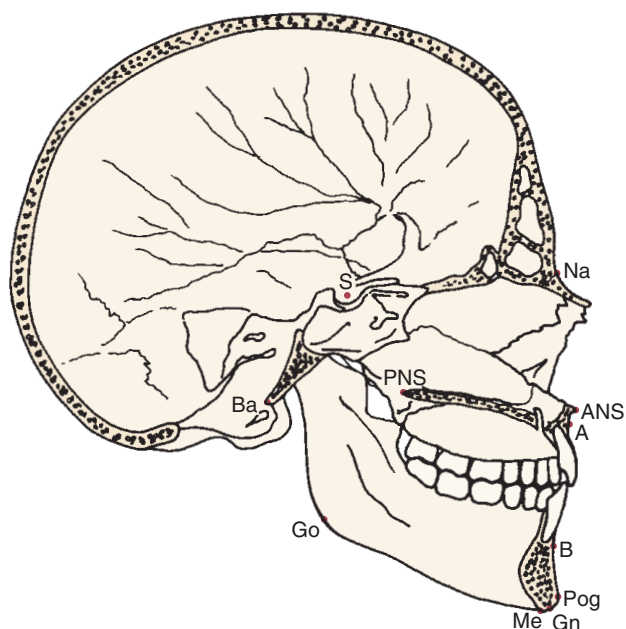
the amount of information on the radiograph to a manageable level. The common cephalometric landmarks and a typical tracing are shown in [Figs. 6.47](#) and [6.48](#).

Cephalometric landmarks are represented as a series of points, which are usually defined as locations on a physical structure (e.g., the junction of the nasal and frontal bones) but often as an extreme point (e.g., the most anterior point on the bony chin), or occasionally as constructed points such as the intersection of two planes (e.g., the intersection of the mandibular plane and a plane along the posterior margin of the ramus). The extreme points can change depending on the patient's head position so it is important that it be consistent. The  $x,y$  coordinates of these points are used to enter cephalometric data in a computer-compatible format. Computer analysis now is the usual method in almost all private offices. An adequate digital model is required, which means that 50 to 100 landmark locations should be specified ([Fig. 6.49](#)).

The principle of cephalometric analysis, however, is not different when computers are used. The goal is to determine the skeletal and dental relationships that exist in an individual patient and contribute to his or her malocclusion. How do you do that? One way is to compare the patient with a normal reference group, so that differences between the patient's actual dentofacial relationships and those expected for his or her age and racial or ethnic group are revealed. This type of cephalometric analysis was first popularized after World War II in the form of the Downs analysis, developed at the University of Illinois and based on skeletal and facial proportions of a reference group of 25 untreated adolescent whites selected because of their ideal dental occlusions.



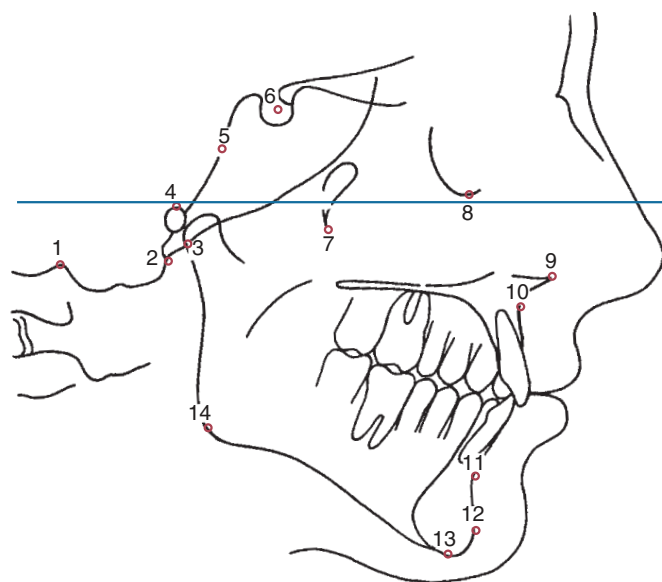
• **Fig. 6.46** The three major cephalometric superimpositions showing tracings of the same individual at an earlier (*black*) and later (*red*) time. (A) Superimposition on the anterior cranial base along the sella-nasion (SN) line. This superimposition shows the overall pattern of changes in the face, which result from a combination of growth and treatment in children receiving orthodontic therapy. Note in this patient that the lower jaw grew downward and forward, while the upper jaw moved straight down. This allowed the correction of the patient's Class II malocclusion. (B) Superimposition on the maxilla, specifically on the contour of the palate behind the incisors and along the palatal plane. This view shows changes of the maxillary teeth relative to the maxilla. In this patient's case, minimal changes occurred, the most notable being a forward movement of the upper first molar when the second primary molar was lost. (C) Superimposition on the mandible, specifically on the inner surface of the mandibular symphysis and the outline of the mandibular canal and unerupted third molar crypts. This superimposition shows both changes in the mandibular ramus and condylar process due to growth or treatment and changes in the position of the mandibular teeth relative to the mandible. Note that for this patient, the mandibular ramus increased in length posteriorly while the condyle grew upward and backward. As would be expected, the mandibular molar teeth moved forward as the transition from the mixed to the early permanent dentition occurred.



• **Fig. 6.47** Definitions of cephalometric landmarks as they would be seen in a dissected skull. *A*, The innermost point on the contour of the premaxilla between anterior nasal spine and the incisor tooth; *ANS*, anterior nasal spine, the tip of the anterior nasal spine (sometimes modified as the point on the upper or lower contour of the spine where it is 3 mm thick; see Harvold analysis); *B*, the innermost point on the contour of the mandible between the incisor tooth and the bony chin; *Ba*, basion, the lowest point on the anterior margin of foramen magnum, at the base of the clivus; *Gn*, gnathion, the most inferior and anterior point on the mandibular symphysis—that is, the point of the chin; *Go*, gonion, the midpoint of the contour connecting the ramus and body of the mandible; *Me*, menton, the most inferior point on the chin; *Na*, nasion, the anterior point of the intersection between the nasal and frontal bones; *PNS*, posterior nasal spine, the tip of the posterior spine of the palatine bone, at the junction of the hard and soft palates; *Pog*, pogonion, the most anterior point on the contour of the chin; *S*, sella, the midpoint of the cavity of sella turcica. Note that some of these points can vary depending on head position.

From the very beginning, the issue of how to establish the normal reference standards was difficult. It seems obvious that patients with severe cranial disproportions should be excluded from a normal sample. Because normal occlusion is not the usual finding in a randomly selected population group, one must make a further choice in establishing the reference group, either excluding only obviously deformed individuals while including most malocclusions, or excluding essentially all those with malocclusion to obtain an ideal sample. In the beginning, the latter approach was chosen. Comparisons were made only with patients with excellent occlusion and facial proportions, as in the 25 individuals chosen for the Downs standards. Perhaps the extreme of selectivity in establishing a reference standard was exemplified by Steiner, whose original ideal measurements were reputedly based on one Hollywood starlet. Although the story is apocryphal, if it is true, Dr. Steiner had a very good eye because recalculation of his original values based on averages from much larger samples produced only minor changes.

The standards developed for the Downs, Steiner, and Wits analyses are still useful but have largely been replaced by newer standards based on less rigidly selected groups. A major database



• **Fig. 6.48** Definitions of cephalometric landmarks (as seen in a lateral cephalometric tracing). 1, *Bo*, Bolton point, the highest point in the upward curvature of the retrocondylar fossa of the occipital bone; 2, *Ba*, basion, the lowest point on the anterior margin of the foramen magnum, at the base of the clivus; 3, *Ar*, articulare, the point of intersection between the shadow of the zygomatic arch and the posterior border of the mandibular ramus; 4, *Po*, porion, the midpoint of the upper contour of the external auditory canal (anatomic porion), or the midpoint of the upper contour of the metal ear rod of the cephalometer (machine porion); 5, *SO*, sphenoccipital synchondrosis, the junction between the occipital and basisphenoid bones (if wide, the upper margin); 6, *S*, sella, the midpoint of the cavity of sella turcica; 7, *Ptm*, pterygomaxillary fissure, the point at the base of the fissure where the anterior and posterior walls meet; 8, *Or*, orbitale, the lowest point on the inferior margin of the orbit; 9, *ANS*, anterior nasal spine, the tip of the anterior nasal spine (sometimes modified as the point on the upper or lower contour of the spine where it is 3 mm thick; see Harvold analysis); 10, *point A*, the innermost point on the contour of the premaxilla between anterior nasal spine and the incisor tooth; 11, *point B*, the innermost point on the contour of the mandible between the incisor tooth and the bony chin; 12, *Pog*, pogonion, the most anterior point on the contour of the chin; 13, *Me*, menton, the most inferior point on the mandibular symphysis—that is, the bottom of the chin; 14, *Go*, gonion, the midpoint of the contour connecting the ramus and body of the mandible.

for contemporary analysis is the Michigan growth study, carried out in Ann Arbor and involving a typical group of children, including those with mild and moderate malocclusions.<sup>27</sup> Other major sources are the Burlington (Ontario) growth study,<sup>28</sup> the Bolton study in Cleveland,<sup>29</sup> and numerous specific samples collected in university projects to develop standards for specific racial and ethnic groups that are included in texts on cephalometrics.<sup>30</sup>

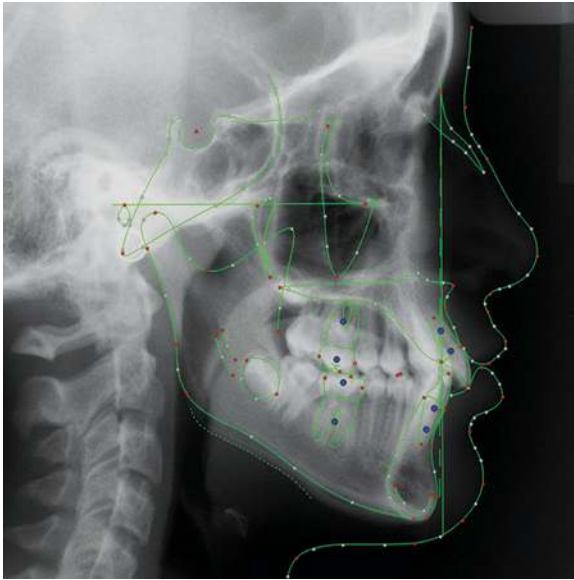
Remember, the goal of cephalometric analysis is to evaluate the relationships, both horizontally and vertically, of the five major functional components of the face (see Figs. 6.43 and 6.44): the cranium and cranial base, the skeletal maxilla (described as the portions of the maxilla that would remain if there were no teeth and alveolar processes), the skeletal mandible (similarly defined), the maxillary dentition and alveolar process, and the mandibular dentition and alveolar process. In this sense, any cephalometric

analysis is a procedure designed to yield a description of the relationships among these functional units.

There are two basic ways to approach this goal. One is the approach chosen originally in the Downs analysis and followed by most workers in the field since that time. This is the use of selected linear and angular measurements to establish the appropriate

comparisons. The other is to express the normative data graphically rather than as a series of measurements and to compare the patient's dentofacial form directly with the graphic reference (usually called a *template*). Then any differences can be observed without making measurements.

Both approaches are employed in contemporary cephalometric analysis. In the sections following, contemporary measurement approaches are discussed first, and then cephalometric analysis via direct comparison with a reference template is presented.

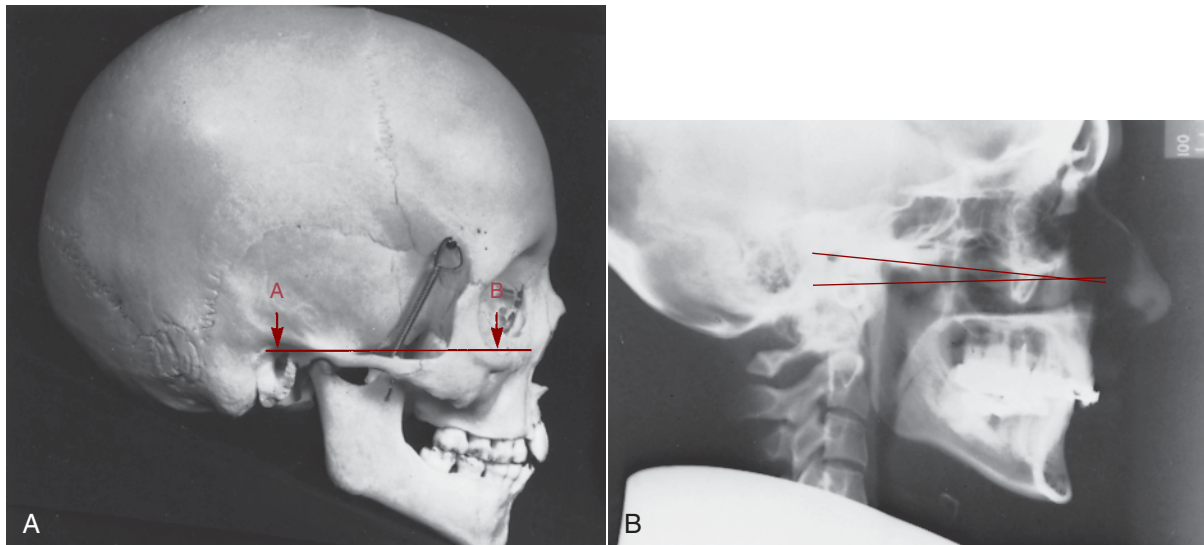


• **Fig. 6.49** The standard lateral digitization model for a current cephalometric analysis and prediction program (Dolphin Imaging, Patterson Dental, St. Paul, MN). Similar digital models, which usually can be customized to provide specific points that the clinician wants, are used in all current programs.

### Measurement Analysis

**Choice of a Horizontal (Cranial) Reference Line.** In any technique for cephalometric analysis, it is necessary to establish a reference area or reference line. The same problem was faced in the craniometric studies of the 19th century. By the late 1800s, skeletal remains of humans had been found at many locations and were under extensive study. An international congress of anatomists and physical anthropologists was held in Frankfurt, Germany, in 1882, with the choice of a horizontal reference line for orientation of skulls being an important item on the agenda. At the conference, the Frankfort plane, extending from the upper rim of the external auditory meatus (porion) to the inferior border of the orbital rim (orbitale), was adopted as the best representation of the natural orientation of the skull (**Fig. 6.50**), because it was often parallel to the true horizontal when people were standing in a relaxed position. This Frankfort plane was employed for orientation of the patient from the beginning of cephalometrics and remains commonly used for analysis.

In cephalometric use, however, the Frankfort plane has two difficulties. The first is that both its anterior and posterior landmarks, particularly porion, can be difficult to locate reliably on a cephalometric radiograph. A radiopaque marker is placed on the rod that extends into the external auditory meatus as part of the cephalometric head positioning device, and the location of this



• **Fig. 6.50** (A) The Frankfort plane as originally described for orientation of dried skulls. This plane extends from the upper border of the external auditory canal (A) (porion) anteriorly to the upper border of the lower orbital rim (B) (orbitale). (B) Use of "machine porion," the upper surface of the ear rod of the cephalometric headholder, can give a different Frankfort plane than use of "anatomic porion," the upper surface of the shadow of the bony auditory canal. Both porion and orbitale, the landmarks for the Frankfort plane, are difficult to locate accurately on cephalometric films, making it a relatively unreliable reference for cephalometric analysis.



marker, referred to as “machine porion,” is often used to locate porion. The shadow of the auditory canal can be seen on cephalometric radiographs, usually located slightly above and posterior to machine porion. The upper edge of this canal can also be used to establish “anatomic porion,” which gives a slightly different (occasionally, quite different) Frankfort plane (Fig. 6.50B).

An alternative horizontal reference line, easily and reliably detected on cephalometric radiographs, is the line from the sella turcica to the junction between the nasal and frontal bones (SN) (see Fig. 6.47). In the average individual, the SN plane is oriented at 6 to 7 degrees upward anteriorly to the Frankfort plane. Another way to obtain a Frankfort line is simply to draw it at a specific inclination to SN, usually 6 degrees. However, although this increases reliability and reproducibility, it decreases accuracy.

The second problem with the Frankfort plane is more fundamental. It was chosen as the best anatomic indicator of the true or physiologic horizontal line. Everyone orients his or her head in a characteristic position, which is established physiologically, not anatomically. As the anatomists of a century ago deduced, for most patients the true horizontal line closely approximates the Frankfort plane. Some individuals, however, show significant differences, up to 10 degrees.

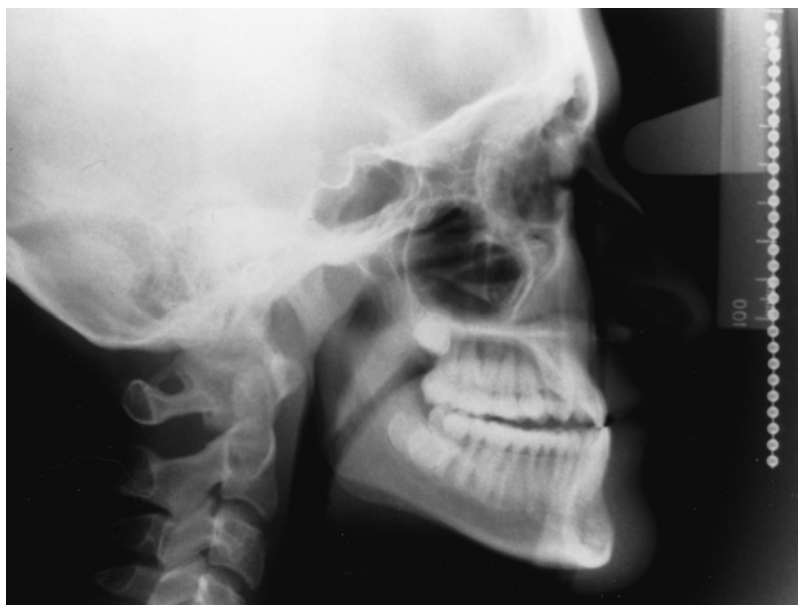For the long-dead skulls they examined, the anatomists had no choice but to use an anatomic indicator of the true horizontal. For living patients, however, it is possible to use a “true horizontal” line, established physiologically rather than anatomically, as the horizontal reference plane (Fig. 6.51). This approach requires taking cephalometric radiographs with the patient in NHP (i.e., with the patient holding the head level as determined by the patient’s own internal physiologic mechanism). This position is obtained when relaxed individuals look at a distant object or into their own eyes in a mirror and incline their heads up and down in increasingly smaller movements until they feel comfortably positioned. NHP can be reproduced within 1 or 2 degrees.<sup>31</sup>

In contemporary usage, cephalometric radiographs should be taken in NHP, so that the physiologic true horizontal plane is established. Although NHP is not as precisely reproducible as orienting the head to the Frankfort plane, the potential errors from lower reproducibility are smaller than those from inaccurate head orientation. The inclination of SN to the true horizontal plane (or to the Frankfort plane if true horizontal plane is not known) should always be noted; if the inclination of SN differs significantly from 6 degrees, any measurements based on SN should be corrected by this difference.

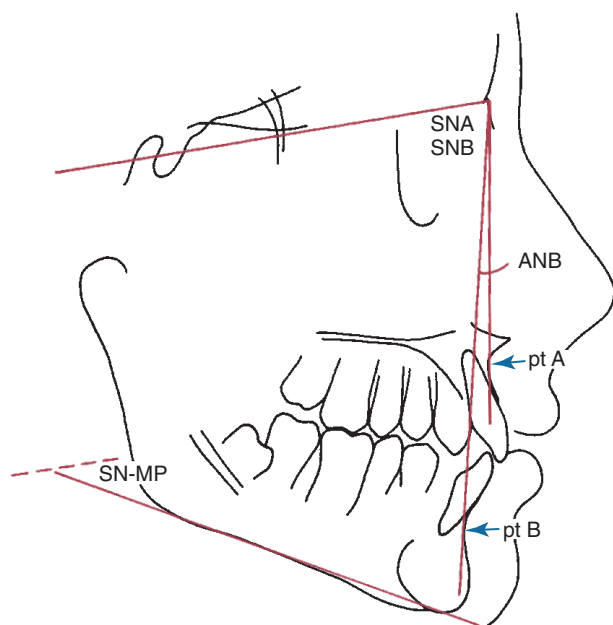
**Steiner Analysis.** Developed and promoted by Cecil Steiner in the 1950s, Steiner analysis can be considered the first of the modern cephalometric analyses for two reasons: It displayed measurements in a way that emphasized not just the individual measurements but their interrelationship in a pattern, and it offered specific guides for use of cephalometric measurements in treatment planning.<sup>33</sup> Elements of it remain useful today.

In a sense, Steiner analysis was based on evaluating the compensations necessary to compensate for the difference between SNA and SNB (angles advocated by Riedel),<sup>32</sup> which indicates the magnitude of the skeletal jaw discrepancy (Fig. 6.52). To Steiner, this difference (the ANB angle) was the measurement of real interest. One can argue, as he did, that which jaw is at fault is of mostly theoretical interest; what really matters is the magnitude of the discrepancy between the jaws that must be overcome in treatment, and this is what the ANB angle measures.

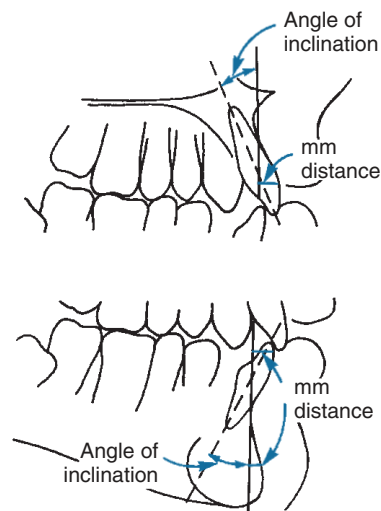
Steiner then measured the angular and millimeter relationship of the upper incisor to the NA line and both the lower incisor and the chin to the NB line, thus establishing the relative protrusion of the dentition (Fig. 6.53). The millimeter distance establishes how prominent the incisor is relative to its supporting bone, and the inclination indicates whether the tooth has been tipped to its position or has moved there bodily. The prominence of the chin (pogonion) compared with the prominence of the lower incisor



• **Fig. 6.51** If the cephalometric radiograph is taken with the patient in natural head position (NHP), a line perpendicular to the true vertical (shown by the image of the freely suspended chain that is seen on the edge of the film) is the true (physiologic) horizontal line. NHP is preferred in modern cephalometrics to anatomic head positioning.



• **Fig. 6.52** In the Steiner analysis, the angles *SNA* and *SNB* are used to establish the relationship of the maxilla and mandible to the cranial base; the *ANB* angle shows the difference between the maxilla and mandible; the *SN-MP* (mandibular plane) angle is used to establish the vertical position of the mandible.



• **Fig. 6.53** In the Steiner analysis, the relationship of the upper incisor to the NA line is used to establish the position of the maxillary dentition relative to the maxilla. Both the millimeter distance that the labial surface of the incisor is in front of the line and the inclination of the long axis of the incisor to the line are measured. The position of the lower incisor relative to the mandible is established by similar measurements to the line NB. In addition, the prominence of the chin is established by measuring the millimeter distance from the NB line to pogonion, the most prominent point on the bony chin. Remember, these angles and distances can be affected by the protrusion and retrusion of the maxilla and mandible relative to the nasion.

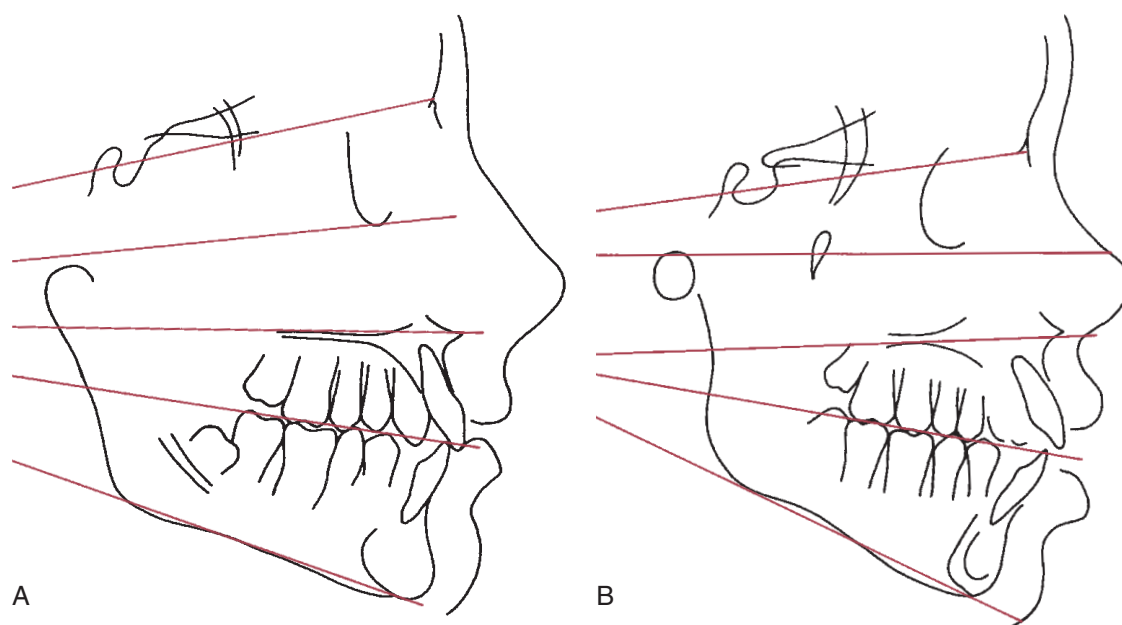
**TABLE 6.10**

**Cephalometric Values for Selected Groups (All Values in Degrees Except as Indicated)**

	American White	American Black	Chinese (Taiwan)	Israeli	Japanese
SNA	82	85	82	82	81
SNB	80	81	78	79	77
ANB	2	4	4	3	4
$\bar{1}$ -NA	4 mm 22	7 mm 23	5 mm 24	5 mm 24	6 mm 24
$\bar{1}$ -NB	4 mm 25	10 mm 34	6 mm 29	6 mm 27	8 mm 31
$\bar{1}$ to $\bar{1}$	131	119	124	126	120
GoGn-SN	32	32	35	32	34
$\bar{1}$ -MnPI	93	100	93	93	96
$\bar{1}$ -FH	62	51	57	57	57
Y-axis	61	63	61	61	62

establishes the balance between them: The more prominent the chin, the more prominent the incisor can be, and vice versa. This important relationship is often referred to as the *Holdaway ratio*. Another important measurement included in Steiner analysis is the inclination of the mandibular plane to SN, which is its only indicator of the vertical proportions of the face (see Fig. 6.52). Tabulated standard values for five racial groups are given in Table 6.10.

There were significant problems with the Steiner analysis, however, that led to its replacement. First, its reliance on ANB is problematic. The ANB angle is influenced by two factors other than the AP difference in jaw position. One is the vertical height of the face. As the vertical distance between nasion and points A and B increases, the ANB angle will decrease. The second is that if the AP position of the nasion is abnormal, the size of the angle will be affected. In addition, as SNA and SNB become



• **Fig. 6.54** Sassouni contributed the idea that if a series of horizontal planes (sella–nasion [SN], Frankfort, palatal, functional occlusal and mandibular) are drawn from the SN line at the top to the mandibular plane below, they will project toward a common meeting point in a well-proportioned face, and that if this is not the case, the orientation of the individual planes will make it easy to visualize the disproportion. (A) For this patient with mild mandibular deficiency but normal occlusion, the horizontal planes converge toward a common point not far behind the tracing, and vertical proportions are well within the range of normal. (B) Inspection of the horizontal planes for this patient makes it clear that the maxilla is rotated downward posteriorly and the mandible rotated downward anteriorly. These rotations of the jaws contribute to an open bite tendency, so the skeletal pattern revealed here is often referred to as “skeletal open bite.”

larger and the jaws are more protrusive, even if their horizontal relationship is unchanged, it will be registered as a larger ANB angle. The validity of these criticisms led to the use of different indicators of jaw discrepancy in the later analyses presented in the following sections.

Second, it should not be overlooked that relying on tooth movement alone to correct skeletal malocclusion, particularly as the skeletal discrepancies become large, is not necessarily the best approach to orthodontic treatment. It is usually better to correct skeletal discrepancies at their source than to attempt only to achieve a dental compromise or camouflage. It is fair to say that the Steiner compromises reflect the prevailing attitude of Steiner’s era, that the effects of orthodontic treatment are almost entirely limited to the alveolar process.

**Sassouni Analysis.** The Sassouni analysis was the first to emphasize vertical, as well as horizontal, relationships and the interaction between vertical and horizontal proportions.<sup>34</sup> Sassouni pointed out that the horizontal anatomic planes—the inclination of the anterior cranial base, Frankfort plane, palatal plane, occlusal plane, and mandibular plane—tend to converge toward a single point in well-proportioned faces. The inclination of these planes to each other reflects the vertical proportionality of the face (Fig. 6.54).

If the planes intersect relatively close to the face and diverge quickly as they pass anteriorly, the facial proportions are long anteriorly and short posteriorly, which predisposes the individual to an open bite malocclusion. Sassouni coined the term *skeletal*

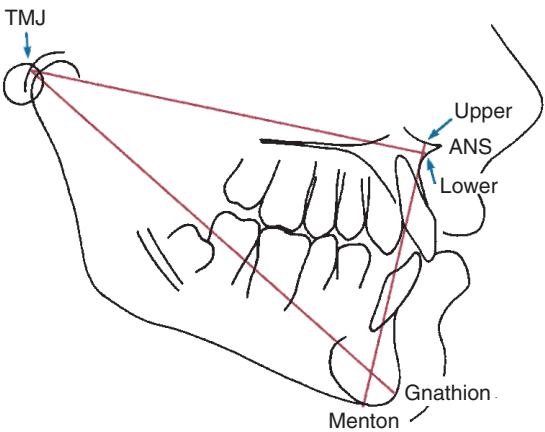
*open bite* for this anatomic relationship. If the planes are nearly parallel so that they converge far behind the face and diverge only slowly as they pass anteriorly, there is a skeletal predisposition toward anterior deep bite, and the condition is termed *skeletal deep bite*.

In addition, an unusual inclination of one of the planes stands out because it misses the general area of intersection. Rotation of the maxilla down in back and up in front may contribute to skeletal open bite, for instance. Sassouni evaluated the AP position of the face and dentition by noting the relationship of various points to arcs drawn from the area of intersection of the planes. Unfortunately, as a face becomes more disproportionate, it is more and more difficult to establish the center for the arc, and the AP evaluation becomes more and more arbitrary.

Although the total arcial analysis described by Sassouni is no longer widely used, his analysis of vertical facial proportions has become an integral part of the overall analysis of a patient. In addition to any other measurements that might be made, it is valuable in any patient to analyze the divergence of the horizontal planes and to examine whether one of the planes is clearly disproportionate to the others.

**Harvold and Wits Analyses.** Both the Harvold<sup>35</sup> and Wits<sup>36</sup> analyses are aimed solely at describing the severity or degree of jaw disharmony. Harvold, using data derived from the Burlington growth study, developed standards for the “unit length” of the maxilla and mandible. The maxillary unit length is measured from the anterior border of the mandibular condyle to the anterior nasal

spine; the mandibular unit length is measured from the same point to the anterior point of the chin (Fig. 6.55). The difference between these numbers provides an indication of the size discrepancy between the jaws. In analyzing the difference between maxillary and mandibular unit lengths, it must be kept in mind that the shorter the vertical distance between the maxilla and mandible, the more anteriorly the chin will be placed for any given unit difference, and vice versa. Harvold did quantify the lower face height to



• **Fig. 6.55** Measurements used in the Harvold analysis. Maxillary length is measured from the temporomandibular joint (TMJ), the posterior wall of the glenoid fossa, to lower anterior nasal spine (ANS), defined as the point on the lower shadow of the ANS where the projecting spine is 3 mm thick. Mandibular length is measured from TMJ to the gnathion, the most anterior and inferior point on the chin in the *lateral* views. Lower face height is measured from the upper ANS, the similar point on the upper contour of the spine where it is 3 mm thick, to menton.

account for this factor. The position of the teeth has no influence on the Harvold figures (Table 6.11).

The Wits analysis was conceived primarily as a way to overcome the limitations of ANB as an indicator of jaw discrepancy. It is based on a projection of points A and B to the occlusal plane, along which the linear difference between these points is measured. If the AP position of the jaws is normal, the projections from points A and B will intersect the occlusal plane at very nearly the same point. The magnitude of a discrepancy in the Class II direction can be estimated by how many millimeters the point A projection is in front of the point B projection, and vice versa for Class III.

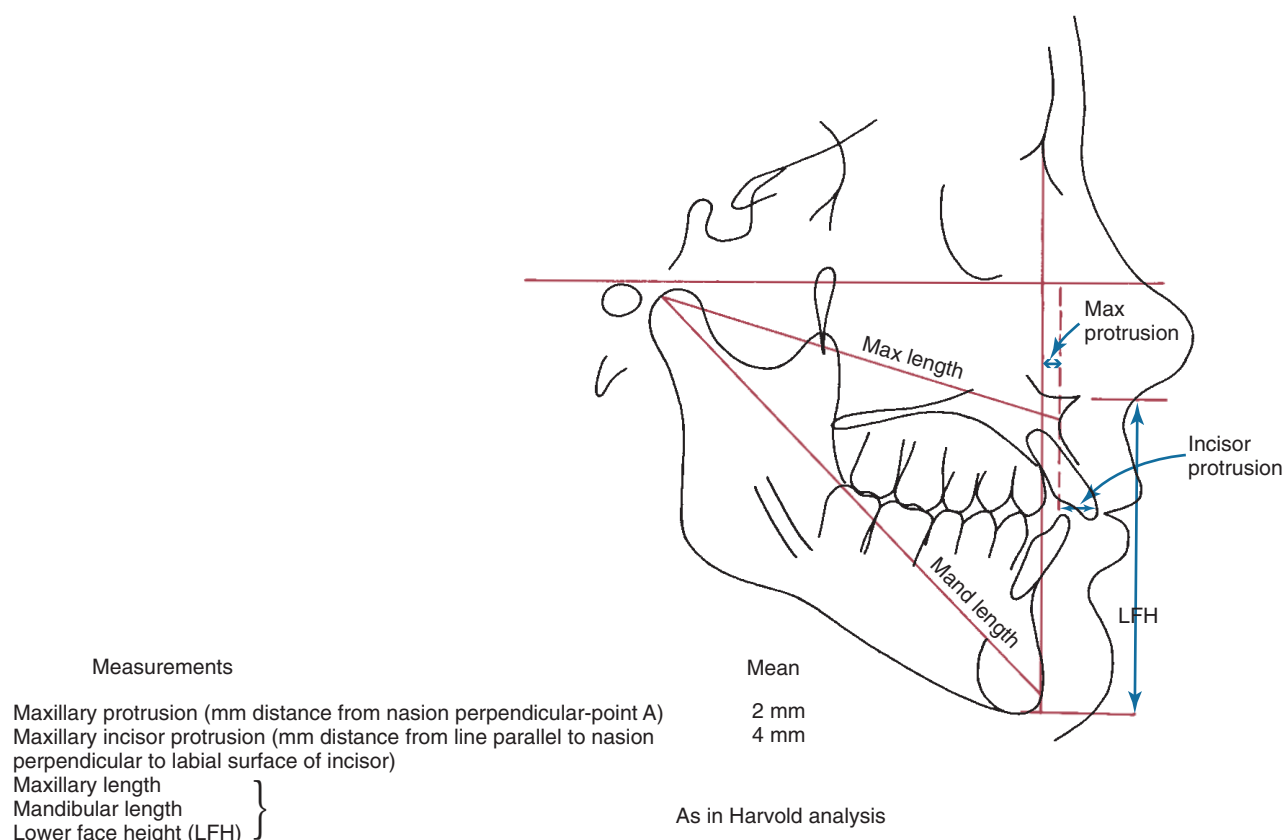
The Wits analysis, in contrast to the Harvold analysis, is influenced by the teeth both horizontally and vertically—horizontally because points A and B are somewhat influenced by the dentition and vertically because the occlusal plane is determined by the vertical position of the teeth. It is important for Wits analysis to use the functional occlusal plane, drawn along the maximum intercuspation of the posterior teeth, not the Downs analysis functional plane influenced by the vertical position of the incisors. Even so, this approach fails to distinguish skeletal discrepancies from problems caused by displacement of the dentition, and it does not specify which jaw is at fault if there is a skeletal problem. If the Wits analysis is used, these limitations must be kept in mind.

**McNamara Analysis.** The McNamara analysis, originally published in 1984,<sup>37</sup> combines elements of previous approaches (Ricketts and Harvold) with original measurements to attempt a more precise definition of jaw and tooth positions. In this method, both the anatomic Frankfort plane and the basion–nasion line are used as reference planes. The AP position of the maxilla and mandible are evaluated with regard to their position relative to the “nasion perpendicular,” a vertical line extending downward from nasion perpendicular to the Frankfort plane (Fig. 6.56). The maxilla should be on or slightly ahead of this line, the mandible slightly behind. The second step in the procedure is a comparison of maxillary and mandibular length, using Harvold’s approach.

**TABLE 6.11**    Harvold Standard Values (Millimeters)

	Age	MALE		FEMALE	
		Mean Value	Standard Deviation	Mean Value	Standard Deviation
Maxillary length (temporomandibular joint to anterior nasal spine) (see Fig. 6.55)	6	82	3.2	80	3.0
	9	87	3.4	85	3.4
	12	92	3.7	90	4.1
	14	96	4.5	92	3.7
	16	100	4.2	93	3.5
Mandibular length (temporomandibular joint to pogonion)	6	99	3.9	97	3.6
	9	107	4.4	105	3.9
	12	114	4.9	113	5.2
	14	121	6.1	117	3.6
	16	127	5.3	119	4.4
Lower face height (ANS-Me)	6	59	3.6	57	3.2
	9	62	4.3	60	3.6
	12	64	4.6	62	4.4
	14	68	5.2	64	4.4
	16	71	5.7	65	4.7





• **Fig. 6.56** Measurements used in the McNamara analysis for a mixed dentition patient: *maxillary protrusion* (millimeter distance from nasion [Na] perpendicular-point A), mean is 0 mm; *maxillary incisor protrusion* (millimeter distance from line parallel to Na perpendicular to labial surface of incisor), mean is 4 to 6 mm; *mandibular protrusion* (millimeter distance from Na perpendicular to Pog; mean is -6 to -8 mm); *maxillary length* and *mandibular length*, both measured from Co and in the lateral view, with means of approximately 86 mm and 106 mm, respectively; *lower face height* (LFH, measured from ANS to menton; mean is 60 mm). Some of these are subtle differences from the Harvold analysis but make it a different analysis.

The mandible is positioned in space with the lower anterior face height (ANS–menton). The upper incisor is related to the maxilla with a line through point A perpendicular to the Frankfort plane, similar to but slightly different from Steiner's relationship of the incisor to the NA line. The lower incisor is related as in the Ricketts analysis, primarily by using the A-pogonion line.

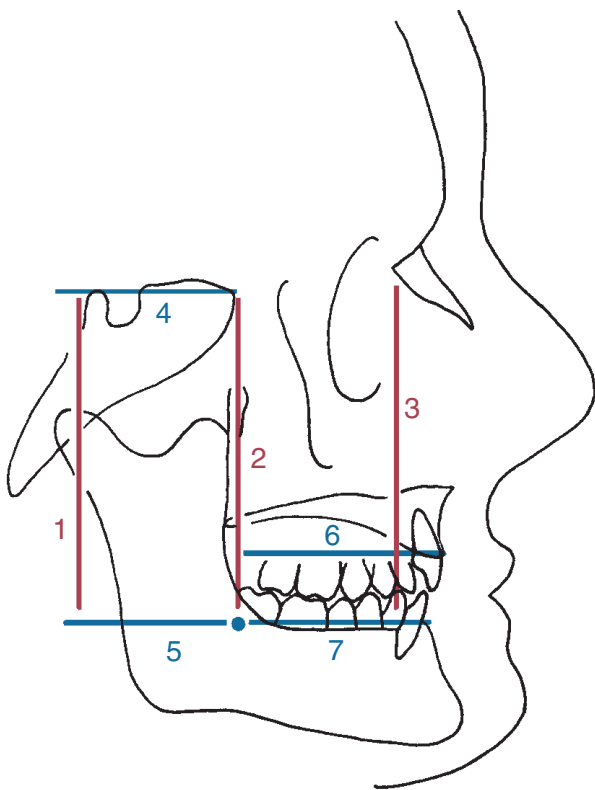
The McNamara analysis has two major strengths. first, it relates the jaws via the nasion perpendicular, in essence projecting the difference in AP position of the jaws to an approximation of the true vertical line. (Using a true vertical line, perpendicular to the true horizontal rather than anatomic Frankfort, would be better yet; the major reason for not doing so in constructing the analysis is that the cephalometric radiographs from which the normative data were derived were not taken in NHP.) This means that AP differences in jaw relationships are measured along the dimension (nearly true horizontal) in which they are visualized by both the patient and the diagnostician.

Second, the normative data are based on the well-defined Bolton sample, which is also available in template form, meaning that the McNamara measurements are highly compatible with preliminary analysis by comparison with the Bolton templates.

**Counterpart Analysis.** A major problem with any analysis based on individual measurements is that any one dimension is affected by others within the same face. Not only are the measurements not independent, but also it is quite possible for a deviation in one relationship to be compensated for wholly or partially by changes in other relationships. This applies to both skeletal and dental relationships. Compensatory changes in the dentition to make the teeth fit although the jaws do not are often the goal of orthodontic treatment. Compensatory changes in skeletal components of the face are less well known but occur frequently and can lead to incorrect conclusions from measurements if not recognized.

The basic idea of interrelated vertical and horizontal dimensions leading to an ultimately balanced or unbalanced facial pattern was first expressed well by Enlow et al in a "counterpart analysis."<sup>38</sup> If anterior face height is long, facial balance and proper proportion are preserved if posterior face height and mandibular ramus height also are relatively large (Fig. 6.57). On the other hand, short posterior face height can lead to a skeletal open bite tendency even if anterior face height is normal because the proportionality is disturbed.

The same is true for AP dimensions. If both maxillary and mandibular lengths are normal but the cranial base is long, the



• **Fig. 6.57** Enlow's counterpart analysis emphasizes the way changes in proportions in one part of the head and face can either add to increase a jaw discrepancy or compensate so that the jaws fit correctly even though there are skeletal discrepancies. For example, if the maxilla is long (measurement 6), there is no problem if the mandible (7) also is long, but malocclusion will result if the mandibular body length is merely normal. The same would be true for anterior versus posterior vertical dimensions (1 to 3). If these dimensions match each other, there is no problem, but if they do not, whether short or long, malocclusion will result.

maxilla will be carried forward relative to the mandible, and maxillary protrusion will result. By the same token, a short maxilla could compensate perfectly for a long cranial base.

One way to bring the insights of counterpart analysis into clinical practice is from examination of the patient's proportions versus those of a "normal" template (as discussed in the next section). Another method, increasingly popular in the last few years, is the use of "floating point" norms for measurements.<sup>40</sup> The idea is to use standards derived from the individual's facial type rather than relating individual cephalometric values to population means, taking advantage of the correlations among the individual values. Rather than judging normality or abnormality based on individual values, the judgment then would be based on how the values were related to one another. Some combinations would be acceptable as normal even if the individual measurements were outside the normal range. Other combinations could be judged as reflecting an abnormal pattern even though the individual measurements were within the normal range. Assessing skeletal relationships in this way is particularly valuable for patients who are candidates for growth modification therapy or orthognathic surgery.

**Template Analysis.** In the early years of cephalometric analysis, it was recognized that representing the norm in graphic form might make it easier to recognize a pattern of relationships. The "Moorrees mesh," which was developed in the 1960s and updated more

recently, presents the patient's disproportions as the distortion of a grid. In recent years, direct comparison of patients with templates derived from the various growth studies has become a reliable method of analysis, with two major advantages: Compensatory skeletal and dental deviations within an individual can be observed directly, and changes in dimensions and angles with changing ages can be evaluated by using age-appropriate templates.

Any individual cephalometric tracing easily can be represented as a series of coordinate points on an  $(x,y)$  grid, which is what is done when a radiograph is digitized for computer analysis. But cephalometric data from any group also could be represented graphically by calculating the average coordinates of each landmark point, then connecting the points. The resulting average or composite tracing often is referred to as a *template*.

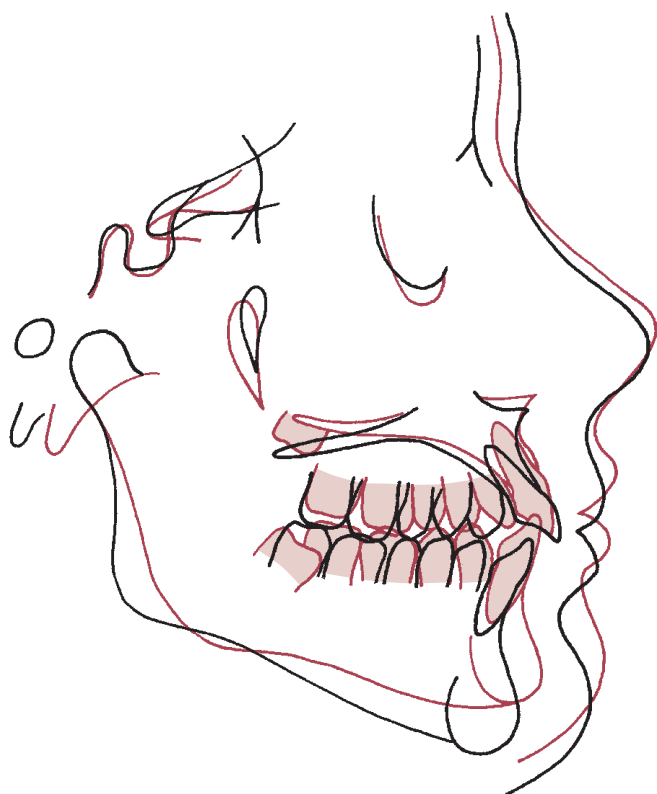
Templates of this type have been prepared by using the data from the major growth studies, showing changes in the face and jaws with age. At present, templates exist in two forms: *schematic* (Michigan, Burlington) and *anatomically complete* (Broadbent-Bolton, Alabama). The schematic templates show the changing position of selected landmarks with age on a single template. The anatomically complete templates, a different one for each age, are particularly convenient for direct visual comparison of a patient with the reference group while accounting for age. The Bolton templates, which are readily available (Department of Orthodontics, Case-Western Reserve School of Dentistry, Cleveland, Ohio), are most often used for template analysis.

The first step in template analysis, obviously, is to pick the correct template from the set of age-different ones that represent the reference data. Two things must be kept in mind: (1) the patient's physical size and (2) his or her developmental age. The best plan usually is to select the reference template initially so that the length of the anterior cranial base (of which the SN distance is a good approximation) is approximately the same for the patient and the template, and then to consider developmental age, moving forward or backward in the template age if the patient is developmentally quite advanced or retarded. In almost all instances, correcting for differences between developmental and chronologic age also leads to the selection of a template that more nearly approximates the anterior cranial base length.

Analysis using a template is based on a series of superimpositions of the template over a tracing of the patient being analyzed. The sequence of superimpositions follows.

1. *Cranial base superimposition*, which allows the relationship of the maxilla and mandible to the cranium to be evaluated (Fig. 6.58). In general, the most useful approach is to superimpose on the SN line, registering the template over the patient's tracing at the nasion rather than the sella if there is a difference in cranial base length. (For growth prediction with templates, it is important to use the posterior superimposition points described with the prediction method. For analysis, registering SN at N is usually preferable.)

With the cranial base registered, the AP and vertical position of maxilla and mandible can be observed and described. It is important at this stage to look not at the position of the teeth, but at the position of the landmarks that indicate the skeletal units (i.e., anterior nasal spine and point A for the anterior maxilla, posterior nasal spine for the posterior maxilla; point B, pogonion and gnathion for the anterior mandible, and gonion for the posterior mandible). The object is to evaluate the position of the skeletal units. The template is being used to see directly how the patient's jaw positions differ from the norm. Compensations within the individual's skeletal pattern are observed directly.



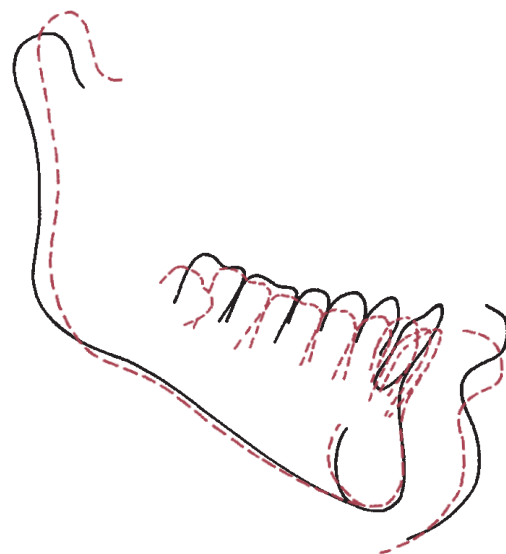• **Fig. 6.58** Cranial base superimposition of the standard Bolton template for age 14 (red) on the tracing of a 13-year-old boy. The age 14 template was chosen because it matches cranial base length. Note that from a comparison of the template with this patient, the considerable increase in the lower face height and downward rotation of the mandible can be seen clearly. It also is apparent that the patient's maxilla is rotated down posteriorly. This comparison of a patient's tracing to a template is a direct approach toward describing the relationship of functional facial units.



• **Fig. 6.59** Superimposition of the Bolton template on the maxilla (primarily on the anterior palatal contour) of the patient shown in Fig. 6.55. This superimposition clearly reveals the forward protrusion of the maxillary incisors relative to the maxilla but also shows that the vertical relationship of the maxillary teeth to the maxilla for this patient is nearly ideal.

2. *Maxillary superimposition.* The second superimposition is on the maximum contour of the maxilla to evaluate the relationship of the maxillary dentition to the maxilla (Fig. 6.59). Again, it is important to evaluate the position of the teeth both vertically and anteroposteriorly. The template makes it easy to see whether the teeth are displaced vertically, which is information often not obtained in measurement analysis techniques.

3. *Mandibular superimposition.* The third superimposition is on the symphysis of the mandible along the lower border, to evaluate



• **Fig. 6.60** Superimposition of the Bolton template on the mandible of the patient in Fig. 6.55. This superimposition indicates that the patient's mandible is longer than the ideal, but the ramus is shorter and inclined posteriorly. All the mandibular teeth have erupted more than normal, especially the incisors.

the relationship of the mandibular dentition to the mandible (Fig. 6.60). If the shadow of the mandibular canal is shown on the templates, a more accurate orientation can be obtained by registering along this rather than the lower border posteriorly. Both the vertical and the AP positions of the anterior and posterior teeth should be noted.

Template analysis in this fashion quickly provides an overall impression of the way in which the patient's dentofacial structures are related. Sometimes the reason for making measurements, which is to gain an overall understanding of the pattern of the patient's facial relationships, is overlooked in a focus on acquiring the numbers themselves. Comparing the patient's features with a template is an excellent way to overcome this hazard and be sure that one does not miss the forest while observing the trees.

Template analysis often is thought of as somehow less scientific than making a series of measurements, but really that is not so. Remember that the template contains exactly the same information as a table of measurements from the same data base (for the anatomic templates, very extensive tables). The information is just expressed in a different way. The difference is that with the template method, there is greater emphasis on the clinician's individual assessment of whatever about the patient may be abnormal, and a corresponding de-emphasis of specific criteria.

Templates easily can be used with computer analysis as well. The technique would be to store the templates in computer memory, then pull up the appropriate template for comparison to the patient's digitized tracing, and use the computer to make the series of superimpositions. The clinician, looking at the superimpositions, should be stimulated to make his own assessment of interactions among the various components of the face, incorporating the insights of counterpart analysis and floating norms at that point.

**Cephalometric Methodology in a Digital Age.** In the modern world with digital images, it is still important to follow a sequence of steps in cephalometric analysis:

1. Look carefully at the overall image for pathologic issues. The most likely indication of pathologic conditions will take the form of radiolucencies or opacities in unexpected places or to a bigger extent than expected. Sometime it is the shape of a structure, such as the sella turcica or a condyle, that signals a problem. Remember, about one cephalometric radiograph in a thousand will show significant pathologic problems—so in a practice with the current average of 250 to 300 new patients per year, you should expect to see such problems once in 3 to 4 years.
2. Look for head positioning errors if there are indications of asymmetry. The ear rods should be concentric (unless the image was deliberately taken using only one ear rod because of clinically observed asymmetry). If the structures in the upper part of the image (e.g., orbits, key ridges, greater wings of the sphenoid) are evenly spaced and those in the lower part are not (or vice versa), that usually indicates skeletal asymmetry. If all are evenly spaced, but to a greater or lesser extent than is normal, it usually indicates a positioning problem.
3. Check the landmark points. Because all the points in the template you are using were digitized, go back and check them for accuracy. Reevaluate particularly critical points such as A, B, PG, Me, Co, Or, N, Go, and Po and the occlusal plane. Errors in locating them can dramatically alter your measurements and impression of the patient's problem.
4. Look for consistency in similar types of measures. AP measures would hopefully tell consistent stories, as should vertical measures. If not, then be certain they are being affected by

commonly known shortcomings of the individual measures such as differences created by maxillary and mandibular protrusion relative to the cranial base or aberrant face height.

5. Look for facial proportionality or lack of it. This can be a key issue. For example, if the lower face is long and the mandibular plane angle is high, but the patient is large and the upper and lower face heights are proportional, this is less of a problem than it would be in a patient with disproportionate face heights and an open bite.

This method of moving from the small details to the bigger picture and making certain you can explain what you see and any inconsistencies will serve you well. It is not just the numbers, but what they mean. And remember—superimposing a normal template can help in determining exactly what's different about your patient.

### Three-Dimensional Imaging in Modern Orthodontics

Axial CT and its improved version, spiral CT, have been available for over 40 years now and quickly came to be widely used in medical applications. Neither form of CT was used to generate typical orthodontic diagnostic records because of their considerable cost and the relatively large radiation dose, which is quite acceptable for major medical problems but not for most elective treatment, including orthodontics.

The advent of CBCT for views of the head and face in the early 21st century changed this because the cost of the equipment (and therefore the cost of obtaining the images) is significantly less than for medical CT, and the radiation dose also is greatly reduced (Table 6.12). At this point, CBCT is being widely used

**TABLE 6.12 Arch Width Measurements**

Age	MALE			FEMALE		
	Canine	First Premolar	First Molar	Canine	First Premolar	First Molar
<b>Maxillary Arch</b>						
6	27.5 <sup>a</sup>	32.3 <sup>a</sup>	41.9	26.9 <sup>a</sup>	31.7 <sup>a</sup>	41.3
8	29.7 <sup>a</sup>	33.7 <sup>a</sup>	43.1	29.1 <sup>a</sup>	33.0 <sup>a</sup>	42.4
10	30.5 <sup>a</sup>	34.4 <sup>a</sup>	44.5	29.8 <sup>a</sup>	33.6 <sup>a</sup>	43.5
12	32.5	35.7	45.3	31.5	35.1	44.6
14	32.5	36.0	45.9	31.3	34.9	44.3
16	32.3	36.6	46.6	31.4	35.2	45.0
18	32.3	36.7	46.7	31.2	34.6	43.9
<b>Mandibular Arch</b>						
6	23.3 <sup>a</sup>	28.7 <sup>a</sup>	40.2	22.2 <sup>a</sup>	28.4 <sup>a</sup>	40.0
8	24.3 <sup>a</sup>	29.7 <sup>a</sup>	40.9	24.0 <sup>a</sup>	29.5 <sup>a</sup>	40.3
10	24.6 <sup>a</sup>	30.2 <sup>a</sup>	41.5	24.1 <sup>a</sup>	29.7 <sup>a</sup>	41.0
12	25.1	32.5	42.1	24.8	31.6	41.8
14	24.8	32.3	42.1	24.4	31.0	41.1
16	24.7	32.3	42.8	23.9	31.0	41.5
18	24.8	32.8	43.0	23.1	30.8	41.7

All measurements: millimeter distance between centers of teeth.

<sup>a</sup>Primary predecessor.

Data from Moyers RE, et al: *Standards of Human Occlusal Development. Monograph 5, Craniofacial Growth Series*. Ann Arbor, Mich: University of Michigan, Center for Human Growth and Development; 1976.



**TABLE 6.13****Doses and Risk Associated With Modern Radiographic Equipment**

	Effective Dose ( $\mu\text{Sv}$ )	Dose as Multiple of Average <sup>a</sup> Panoramic Dose	Days of Per Capita Background <sup>b</sup>	Probability of $x$ in a Million Fatal Cancers <sup>c</sup>
<b>Intraoral Techniques</b>				
Single PA or PBW image with digital receptor and rectangular collimation	2	0.1	6 hours	0.1
Single PA or PBW image with digital receptor and round collimation	9	0.5	2.1	0.5
FMX with digital receptors and rectangular collimation	35	2.2	4.3	2
4 PBWs with digital receptors and rectangular collimation	5	0.3	0.6	0.3
FMX with digital receptors and round cone	171	11	21	9
FMX with D Speed film and round cone <sup>d</sup> (not modern methodology)	388	24	47	21
Maxillary occlusal	8	0.5	1	0.5
<b>Extraoral Plain Projections</b>				
Panoramic: digital <sup>b</sup>	9-24	1	2	0.9
Cephalometric: digital	2-6	0.3	0.7	0.3
<b>Cone Beam Computed Tomography (FOV)</b>				
Adult (large)	212	13	26	12
Adult (medium)	177	11	22	10
Adult (medium) Galileos: adult exposure				
Adult (small)	84	5	10	4.5
10-yr-old child (large or medium)	175	11	22	10
10-yr-old child (small)	103	6.4	13	5.7

PA, Periapical; PBW, bitewing; FMX, full-mouth series; FOV, field of view.

<sup>a</sup>Average of 5 units: Sirona, Orthophos XG; Planmeca, ProMax; Kodak 9000; SOREDEX, SCANORA 3D; Instrumentarium Dental: OP200 D with VT.

<sup>b</sup>3000  $\mu\text{Sv}$  ubiquitous background radiation, NCRP Report No. 145, 2003.

<sup>c</sup>Dose in  $\mu\text{Sv} \times 5.5 \times 10^2$ .

<sup>d</sup>Calculated as F-speed film value  $\times 2.3$ .

Courtesy Drs. John Ludlow and Anita Gohel; revised May 2017.

in orthodontics. There is a consensus that it provides new information that could improve the treatment plan in certain situations, and enough enthusiasm to lead some orthodontists to advocate use of CBCT on all orthodontic patients, replacing panoramic, cephalometric, and occlusal radiographs, as well as tomograms of the TMJ. There is a significant radiation dose increase in doing this, however (Table 6.13).

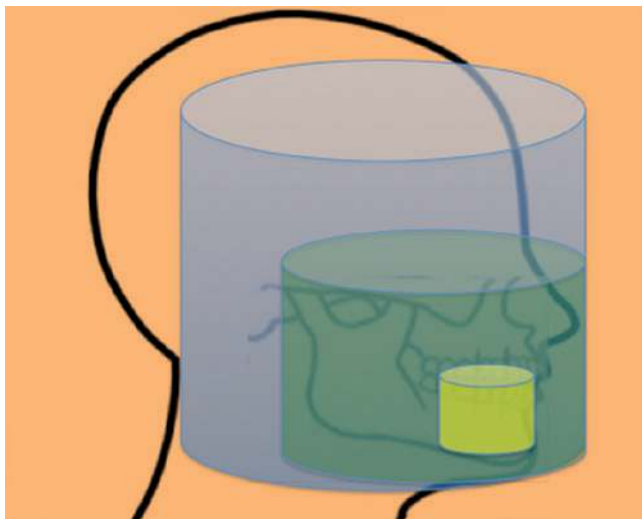
Does the additional information from CBCT translate into better treatment plans and improved treatment outcomes? Answering that question requires an understanding of the critical variables in use of CBCT, and then careful examination of its applications in orthodontic diagnosis and treatment planning. Let's start with the basic concepts in 3-D imaging.

**Basic Concepts.** A CBCT scan is derived from a cone-shaped x-ray beam that is directed through the patient's head, and information is captured on a flat two-dimensional (2-D) area detector as a series of slices as the x-ray beam rotates totally or partially around the subject and moves vertically as it does so. Each slice contains

hundreds of thousands of voxels, the 3-D equivalent of pixels in a digital camera. A darker grayscale intensity of a voxel reflects that more radiation reached it.

Two types of image resolution are important: contrast resolution, the ability to distinguish between tissues of different densities (which is somewhat limited because CBCT images have low soft tissue contrast), and spatial resolution, the ability to distinguish between separate structures that are positioned very close together. Smaller voxel size provides better spatial resolution. Because voxels are cubes, the resolution is the same for the three planes of space.

The amount of radiation exposure is determined by three things: the resolution needed for adequate diagnostic accuracy—the greater the resolution that is needed, the larger the resolution dose; the voxel size—the smaller the voxels, the greater the amount of radiation; and the field of view (FOV), which reflects the size of the irradiated area—the larger the FOV, the greater the radiation dose (Fig. 6.61). The radiation can be reduced by accepting the



• **Fig. 6.61** Different fields of view provide different areas of coverage of the head and different levels of radiation. Use of the smallest one that will yield the critical information is most important.

lower resolution that comes with larger voxels and using the smallest FOV that would be compatible with an adequate diagnosis. A recent addition to CBCT imaging is a “quick scan” feature, which minimizes radiation exposure but is adequate only for dental anomalies and impacted teeth in a small area. This does bring the radiation down to the equivalent of two digital radiographs, which is the minimum that would be needed with 2-D radiography.

**Orthodontic Applications of Cone Beam Computed Tomography.** The ability to view structures from all three planes of space without any superimposition and geometric distortions is the key advantage of CBCT over conventional images (Fig. 6.62). Synthetic cephalometric and panoramic images also can be produced (Fig. 6.63). The key disadvantage, of course, is the increased radiation exposure, and the simplest way to balance this risk against the benefits is to follow the rule that CBCT is indicated when it is the only way to get the necessary information for appropriate treatment. Four situations in which enough data now exist to support use of CBCT for orthodontic patients are as follows:

- Ectopically erupting or impacted teeth (especially maxillary canines, but other teeth as well) requiring surgical exposure and orthodontic tooth movement to bring them into the mouth
- Severe facial asymmetry, especially asymmetries involving roll and yaw (see later section)
- Syndromes, congenital deformities, and sequelae of facial trauma
- Hard tissue problems in the TMJ

Let’s consider these uses in the order of their frequency as CBCT applications.

**Ectopically Erupting or Impacted Teeth.** In evaluating ectopically erupting or impacted teeth (including supernumeraries), CBCT provides four types of information that can significantly change the treatment plan that would have resulted from 2-D radiographs: (1) presence or absence of teeth or supernumeraries (Fig. 6.64); (2) the position of the teeth relative to one another (Fig. 6.65); (3) clear demonstration of the extent of damage to the roots of adjacent permanent teeth (Fig. 6.66); and (4) definition of the path along which an unerupted tooth should be moved so that the tooth can be brought into the mouth efficiently and with the

least further damage to adjacent teeth (Fig. 6.67).<sup>40</sup> This allows adjustments such as bringing an impacted canine facially or lingually before beginning to bring it toward the occlusal plane, in order to avoid the remaining root of a damaged lateral incisor, and makes it possible for the surgeon and orthodontist to plan and apply the best treatment. For instance, the orthodontist may need to alter the anchorage appliance to include transpalatal arches with multiple attachment points so the direction of traction to the impacted canine is optimal. The surgeon can place an attachment on the tooth at the most favorable location for biomechanical advantage in moving it, and if a bone anchor is needed for anchorage, the 3-D image facilitates placing it for best advantage.

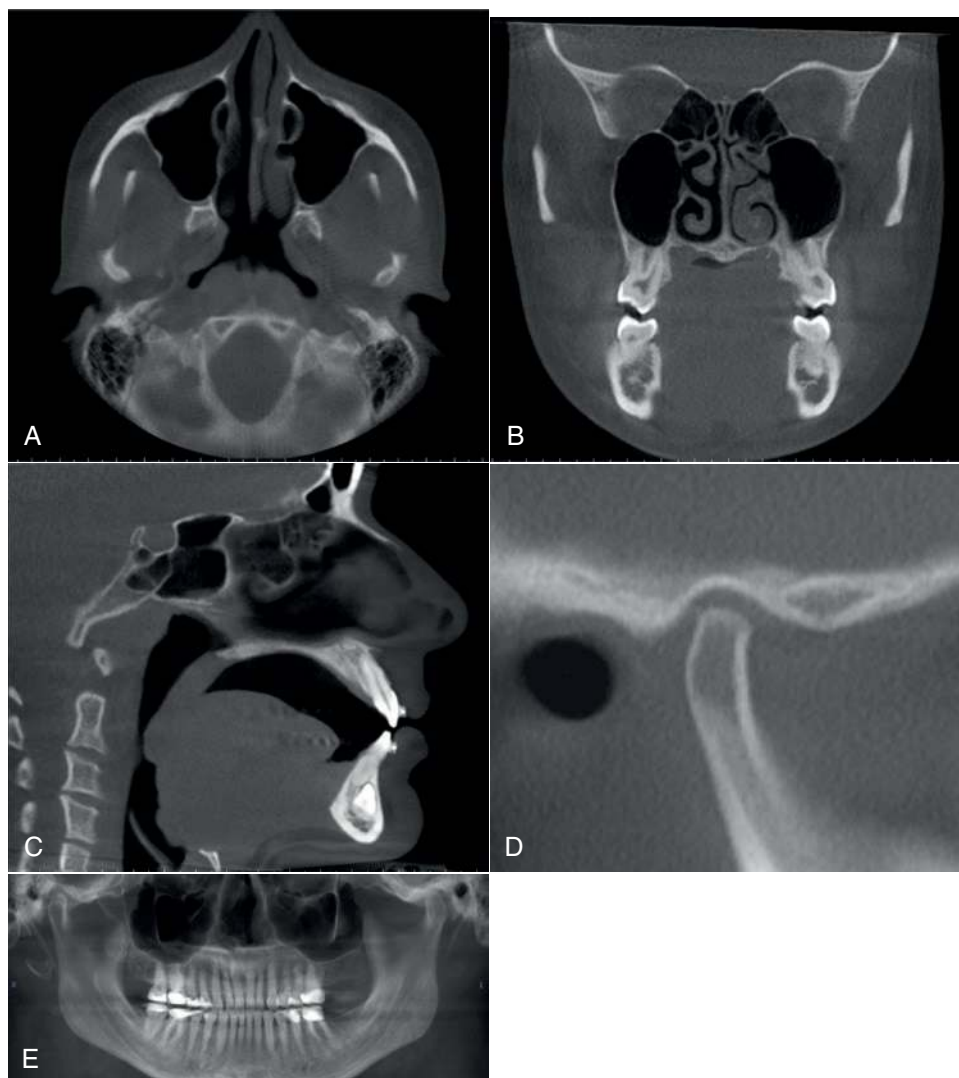
Another creative use of CBCT imaging is to use stereolithographic printing to fabricate a model of a tooth that is planned to be transplanted. At the time of the transplantation, the site is prepared by “fitting” the analogue to the receptor site before harvesting the actual donor tooth. With this method, there is little manipulation of the donor tooth and less chance of injury to the tooth or supporting periodontal tissues before the actual final surgical steps. Because intact periodontal ligament structures are critical to transplant success, this approach should improve the outcomes. Tooth transplantation is discussed in more detail in Chapter 12.

**Facial Asymmetry and Complex Orthognathic Surgery.** Until CBCT became readily available, the major indication for a frontal cephalometric radiograph was facial asymmetry. Even with the addition of this image to the standard panoramic and lateral cephalometric views, evaluating asymmetry required extrapolation among the three images and was qualitative, not quantitative. With these three radiographs of a patient with an asymmetric mandible, one could see in the lateral cephalometric view that the ramus and mandibular body are longer on one side, in the panoramic view that the ramus is longer on one side primarily because the condylar neck is longer, and in the frontal cephalometric view that the chin is off to one side—but the magnitude of the difference could be only approximated. With the multiple images and FOVs available from CBCT images (Fig. 6.68), the primary source of the asymmetry can be identified in a way that allows treatment to be targeted to it.

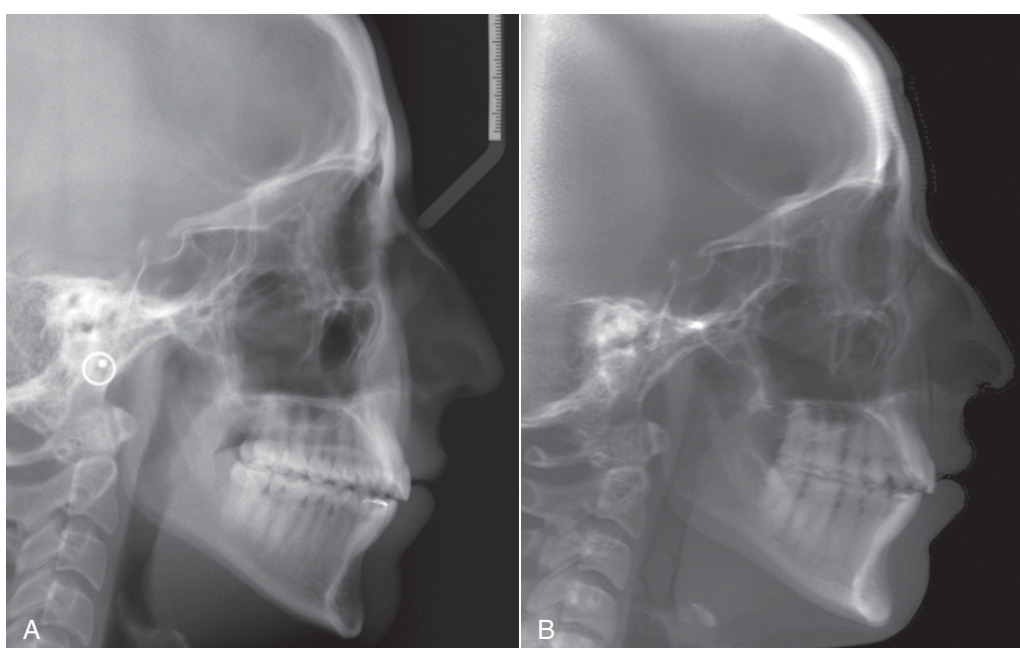
The same considerations apply to diagnosis and planning for complex orthognathic surgery, when simultaneous maxillary, mandibular, chin, and alveolar surgery may be necessary. For these patients, 3-D imaging provides more precise diagnostic evaluation, but it is even more valuable in planning the surgical cuts and making splints for intermediate and final jaw positions (see Chapter 20). Although facial asymmetry is not the major component of many of these patients’ problems, about 40% of all orthognathic surgery patients are asymmetric, and asymmetry is part of the problem for most of the complex cases.

It is possible to produce a precisely dimensioned stereolithographic model of an asymmetric facial skeleton from CT data (Fig. 6.69), so that the orthodontist and surgeon can see it in the 3-D world rather than as a series of images on a computer screen. For this application, spiral (medical) CT rather than CBCT may be advantageous because of its greater resolution. A stereolithographic model allows more precise surgical planning, including the ability to shape fixation plates in advance and determine exactly how fixation screws are to be placed. This technology is discussed in more detail in Chapter 20.

**Congenital Deformities, Syndromes, and Facial Trauma.** In a sense, because asymmetry usually is a major component of their problem list, syndromic and trauma patients also present the same



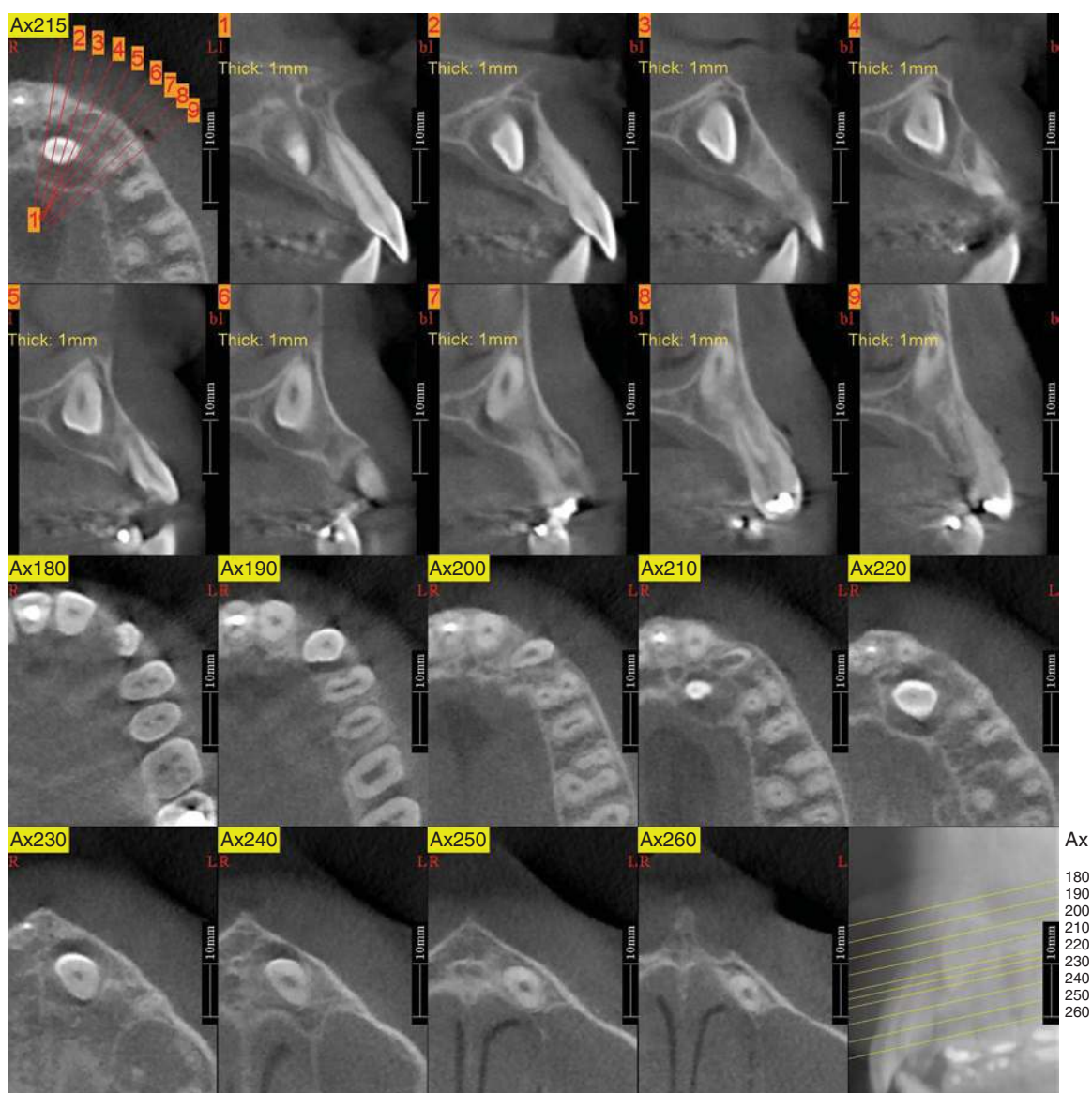
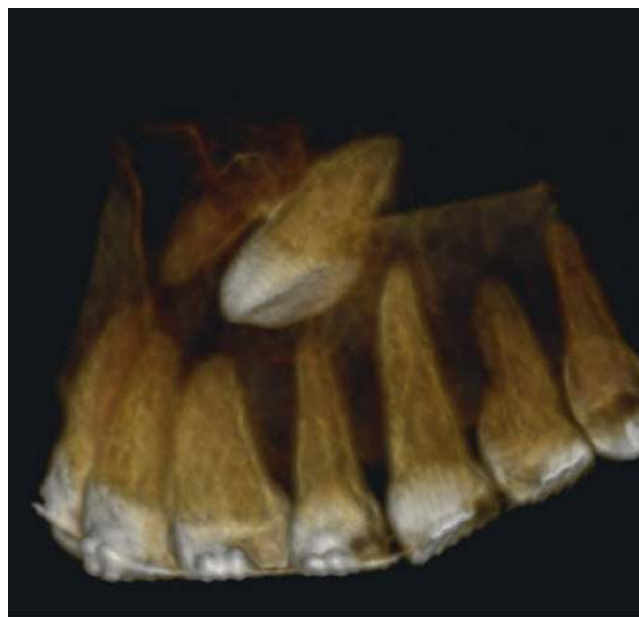
• **Fig. 6.62** Selection of cone beam computed tomography (CBCT) images demonstrating the ability to provide all three planes of space: (A) axial; (B) coronal; (C) sagittal for examination of the entire head with a large field of view (FOV). In addition, (D) the bony temporomandibular joint area can be imaged with a smaller FOV or extracted from a large FOV. (E) A synthetic panoramic radiograph can also be extracted.



• **Fig. 6.63** Comparison of (A) standard cephalometric radiograph and (B) “synthetic ceph” created from a thick slice of cone beam computed tomography (CBCT) data from the same individual. They are similar in a number of ways, and studies have shown that the same measures on both are equal, but they do not look exactly alike.

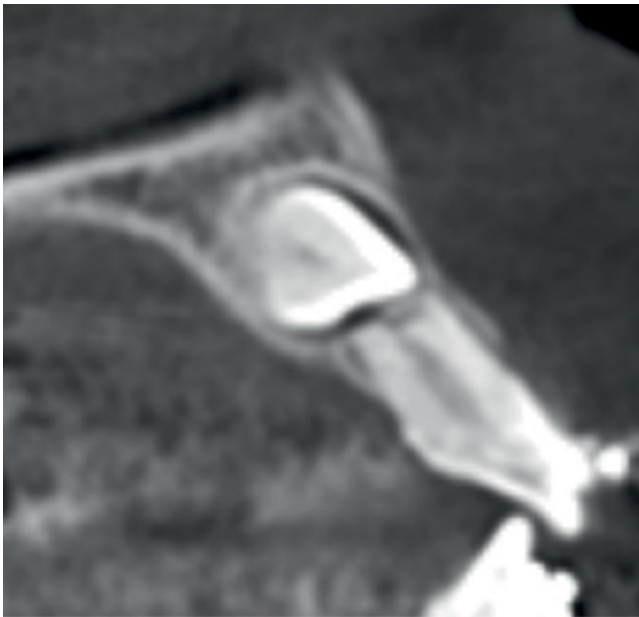


- **Fig. 6.64** Cone beam computed tomography (CBCT) images can provide added value in detecting the presence or absence of ectopic, impacted, or supernumerary teeth, as in the image. The number of supernumerary teeth is also easier to determine on a CBCT image.

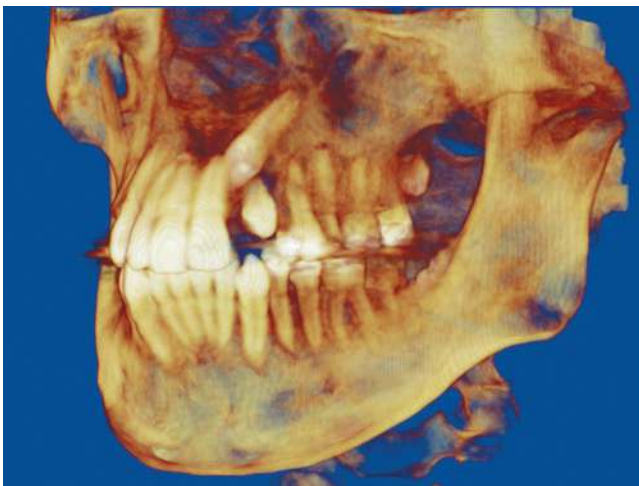


- **Fig. 6.65** The position of unerupted teeth relative to one another is best detected on a cone beam computed tomography (CBCT) image. This series of images shows the crown of an impacted canine, moving along the upper dental arch (*top two rows*) and from the occlusal plane upward (*lower two rows*). The relationship of the impacted tooth to both the bone around it and the other teeth can be seen in detail at each level.



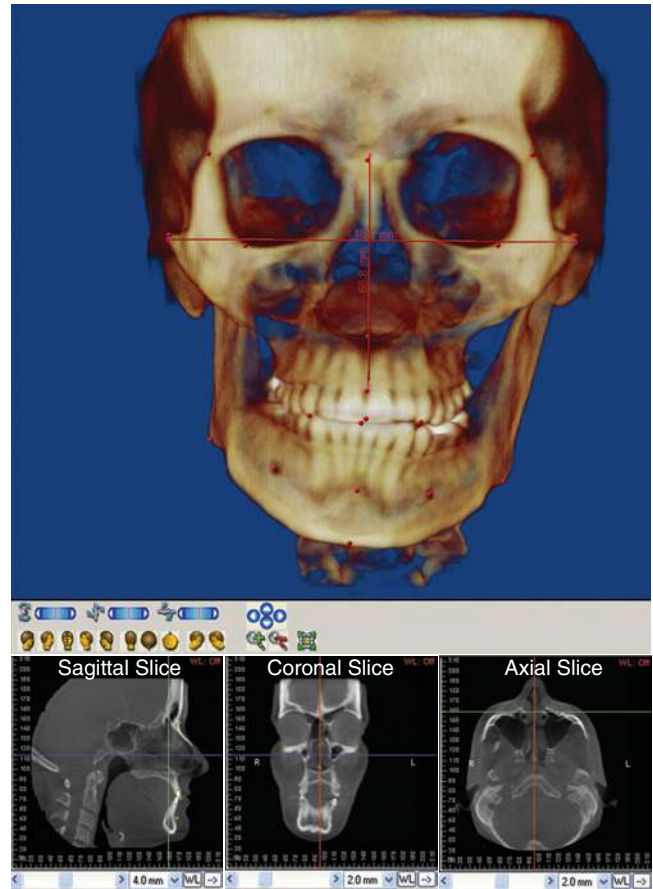


• **Fig. 6.66** The amount of damage (resorption) caused by a migrating and erupting impacted tooth is clearly demonstrated on this cone beam computed tomography (CBCT) image. This can lead to fully informed decisions as to extraction or retention of the damaged tooth, and as to the direction of moving the impacted tooth to minimize further damage to the damaged tooth if it is to be retained.



• **Fig. 6.67** An impacted canine can be seen on this medium-field-of-view cone beam computed tomography (CBCT) image. By rotating the image, different relationships of the teeth can be viewed. This type of image can help in planning the biomechanics necessary to move the impacted canine into occlusion.

diagnostic problems as asymmetry for other reasons—quantitative measurements rather than qualitative approximations are required. A major difference is that treatment at younger ages is likely to be required. For instance, in the alveolar graft surgery that cleft palate patients need at age 7 to 9, CBCT provides valuable information such as the size of the alveolar defect and the precise location of any impacted or supernumerary teeth, and allows for both linear



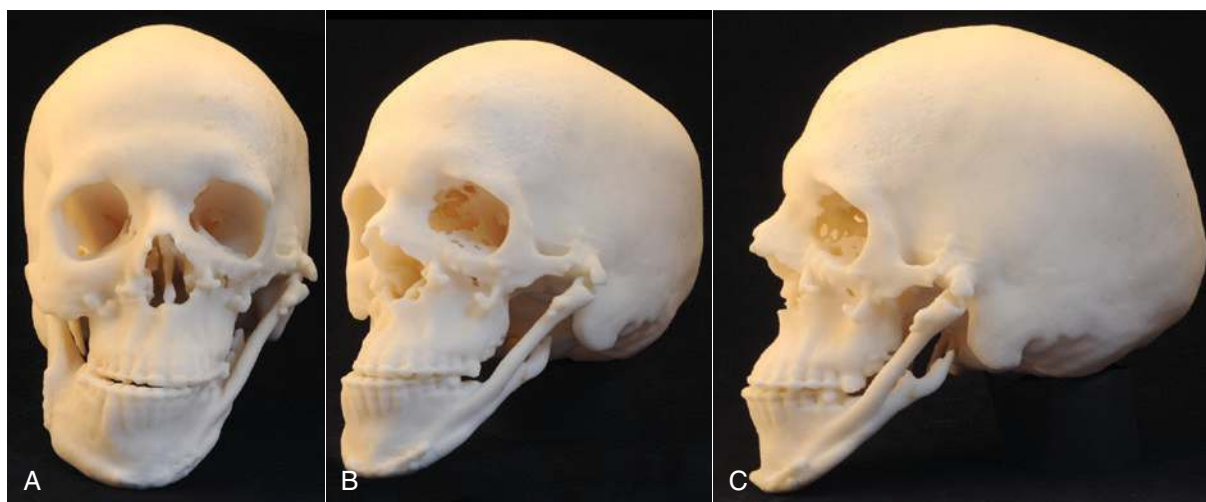
• **Fig. 6.68** Large-field cone beam computed tomography (CBCT) and the axial, coronal, and sagittal slices are useful in confirming the presence of clinically detected skeletal asymmetry. By measuring distances on the different views, the source of the problem can be identified and more readily addressed.

and volumetric measurements (Fig. 6.70). For orthodontists, cleft palate is the major condition that goes in the congenital deformity group. Treatment planning for them and other special circumstances is discussed at the end of the treatment planning chapter (Chapter 7), and appropriate use of CBCT is included there. Although orthodontists are needed as part of the team that manages such patients, their diagnostic evaluation and treatment is largely beyond the scope of this book, and the reader is referred to texts that focus on management of these cases.<sup>41,42</sup>

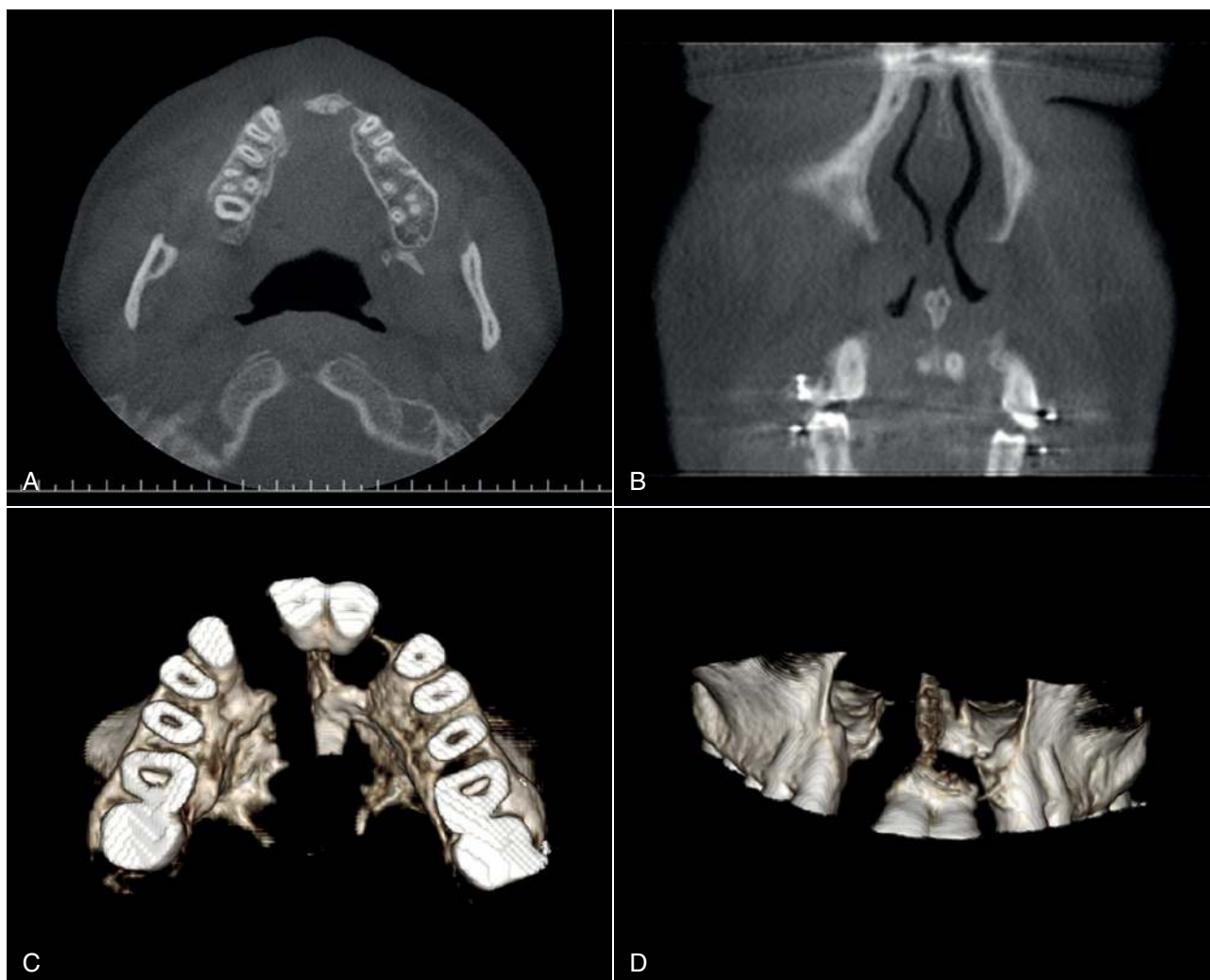
**Hard Tissue Aspects of Temporomandibular Joint Problems.** Distortion or malformation of TMJ hard tissues is relatively infrequent, but certainly can be a component of TMD, and if the mandibular condyle or the adjacent hard tissues are abnormal, CBCT can be a valuable aspect of their evaluation. It is important to keep in mind, however, that the soft tissues in the joint are more likely to be involved in TMD than the hard tissues—and if that is the case, MRI would be the appropriate diagnostic imaging, not CBCT. These issues are discussed in Chapter 19.

### Diagnostic Scope of Cone Beam Computed Tomography Imaging

**Pathologic Issues.** There are two important considerations for detection of pathologic conditions in radiographs taken for



• **Fig. 6.69** (A) to (C) Stereolithographic model of the head of a patient with grade 3 (severe) hemifacial microsomia, in which the ramus of the mandible is completely missing on the affected left side. Having undergone a previous surgery in which a rib graft was placed to connect the body of the mandible on the left side to a point of articulation with the skull, at this time she required additional surgery to improve function and gain better symmetry. A model like this is an essential part of planning complex surgical treatment. (Courtesy Dr. T.A. Turvey.)



• **Fig. 6.70** In patients with cleft lip and palate, (A–D), the cone beam computed tomography (CBCT) images can be extremely useful in determining the location and extent of the clefting, the location of teeth relative to the cleft, and the location and timing of an alveolar bone graft so that erupting teeth near the cleft site can bring new bone with them.

orthodontic diagnosis. First, orthodontic diagnosis is appropriately focused on developmental problems, but just as an orthodontist should pick up pathologic problems on cephalometric and panoramic radiographs (which he or she has been taught to do in typical specialty training), pathologic changes on CBCT images also should be detected. Is the orthodontist responsible for doing so? Should a maxillofacial radiologist with training in evaluation of CBCT images review the images created at the orthodontist's request? The answer to both questions is *yes*—either the orthodontist develops the expertise needed to detect unexpected pathologic features, or he or she must get an expert evaluation for that purpose.

Is it an advantage or a disadvantage that large-field CBCT images offer the possibility of diagnosing conditions in this FOV that would not have been diagnosed this early without the 3-D imaging? This leads to the same discussion as with other diagnostic procedures that are not focused on a specific condition or indication for their use. For some patients, the discovery of an unexpected lesion would lead to further diagnostic evaluation and perhaps more successful treatment than would have occurred with later discovery. For others, the same discovery and further diagnostic evaluation may lead to treatment that really was not needed but exposed the patient to unfortunate side effects. That is the situation with CBCT of the head: Along with the possibility of diagnosis of unsuspected pathologic conditions, there is also the risk of overtreatment of things that would never have become a problem—and that risk may be greater than the benefit. It is not yet clear what the risk–benefit ratio for detection of lesions outside the scope of orthodontic treatment is, but the risk of overdiagnosis and overtreatment is real.

As use of CBCT in orthodontics increases, as it seems clear that it will, the specific indications for using it should be kept in mind. Orthodontic specialty training will need, at the least, a focus on competency of interpretation for small-field images of the maxilla and mandible, but it seems likely that full-field images will require the expertise of a radiologist. This should be a sensible way to manage the risk of overdiagnosis or underdiagnosis for the patient and liability for the orthodontist.

The usefulness of CBCT in diagnosis of sleep apnea (little or none) and its role in planning for placement of mini-implants for skeletal anchorage (useful in special situations only) are discussed in more detail in the special section on these conditions at the end of [Chapter 7](#).

**Evaluation of Growth and Treatment Changes.** A major use of lateral cephalometrics, in many ways its most important use, is evaluation of the changes produced by growth and/or treatment. This was the purpose for which cephalometrics was developed originally. Careful clinical examination usually can produce a comprehensive problem list that cephalometric radiographs confirm, but the most skilled clinicians cannot evaluate changes over time without superimposed cephalometric tracings. In essence, we have used tracings to discard much of the information on a cephalometric radiograph so that when we superimpose the tracings, we can see more clearly the changes in which we are really interested.

Extending this method to sequential 3-D images is problematic. One possibility is to create a “synthetic ceph” from the CBCT images, which is comparable enough to conventional cephalograms to be used clinically (see [Fig. 6.63](#)),<sup>43</sup> and doing cephalometric analysis as it has been done for the last 50 years. But the major reason for CBCT imaging in the first place was to go beyond such a limited view, and that discards too much of the information. In

addition, the landmarks that are used with lateral cephalograms are not reliable as the FOV is rotated away from the AP plane of space. Efforts to define landmarks for 3-D superimposition are finding some success at present, but at best using them for superimposition provides a rather limited view of the changes occurring in a patient.

In cephalometric analysis, cranial base superimposition is on the sella turcica and the ethmoid triad, usually oriented along the SN line. Rather than superimposing on landmarks, a more successful method for 3-D images is to superimpose on the cranial base structure, using a voxel-based system. Although this method continues to use stable anatomic areas, it attempts to match voxels, not points or surfaces. This has proven to be effective when using the anterior cranial base,<sup>44</sup> and voxel-based superimposition on the mandibular symphysis recently has been introduced.<sup>45</sup>

This magnifies the problem of too much information for easy comprehension. Changes at thousands of points now can be evaluated, but thousands of measurements are orders of magnitude too many. The solution is to display changes as color maps, showing the change at the thousands of points by the intensity of color and the direction of change by the color itself, as seen in [Fig. 6.71](#).<sup>46</sup>

In the earlier growth and development chapters, the use of color maps generated from 3-D superimpositions to show growth changes already has been introduced. Now you are seeing color maps showing changes produced by treatment and will encounter more of these later in this book and in the future orthodontic literature. Using color maps to evaluate change, of course, forces the orthodontist away from the old cephalometric “numbers game” of decisions based on specific measurements, and toward looking at the overall pattern of change.

One of the early problems with this method was that the difference between surface points on two images was determined by pairing of the closest points on the two images and not the same points on the two images. For instance, this was a problem when vertical changes also occurred, and dissimilar points came close to one another because of the new orientation. For this reason, early images created with this technology may have given us the wrong impressions. Newer algorithms are attempting to use comparable points for better analyses. This methodology will continue to evolve.

As we have already pointed out, the human brain is an analog computer, and to really understand digital information, you have to do a mental digital-to-analog conversion. Color maps make that much easier.

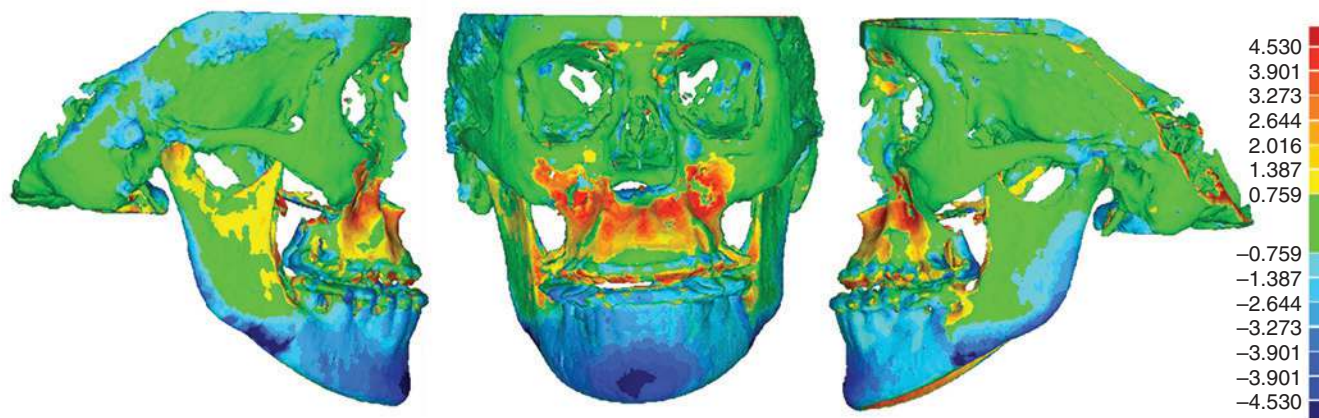
## Orthodontic Classification

Classification has traditionally been an important tool in diagnosis and treatment planning. An ideal classification of orthodontic conditions would summarize the diagnostic data and imply the treatment plan. In our concept of diagnosis, classification can be viewed as the (orderly) reduction of the database to a list of the patient's problems ([Fig. 6.72](#)).

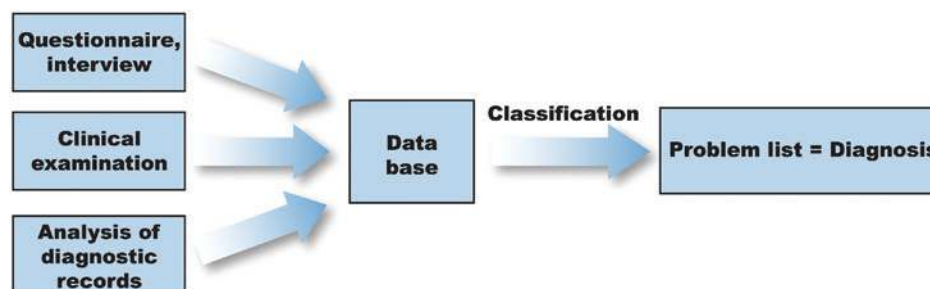
## Development of Classification Systems

The first useful orthodontic classification, still important now, was Angle's classification of malocclusion into Classes I, II, and III. The basis of the Angle classification was the relationship of the first molar teeth and the alignment (or lack of it) of the teeth relative





• **Fig. 6.71** Color map representing changes between preoperative and postoperative findings in a patient who underwent both maxillary advancement and asymmetric mandibular setback to correct Class III malocclusion. The green color is little or no change; the gradient of red and blue colors displays the amount and direction of change. Red indicates forward movement toward the viewer in the center image; the more intense the red, the greater the movement, with 4.5 mm being the maximum on the scale displayed on the right side. Blue indicates backward movement away from the viewer in the center image, with the darkest blue indicating 4.5 mm.



• **Fig. 6.72** Conceptually, classification can be viewed as an orderly way to derive a list of the patient's problems from the database.

to the line of occlusion. Angle's classification thus created the following four groups:

Normal occlusion	Normal (Class I) molar relationship, teeth on line of occlusion
Class I malocclusion	Normal (Class I) molar relationship, teeth crowded, rotated, and so on
Class II malocclusion	Lower molar distal to upper molar, relationship of other teeth to line of occlusion not specified
Class III malocclusion	Lower molar mesial to upper molar, relationship of other teeth to line of occlusion not specified

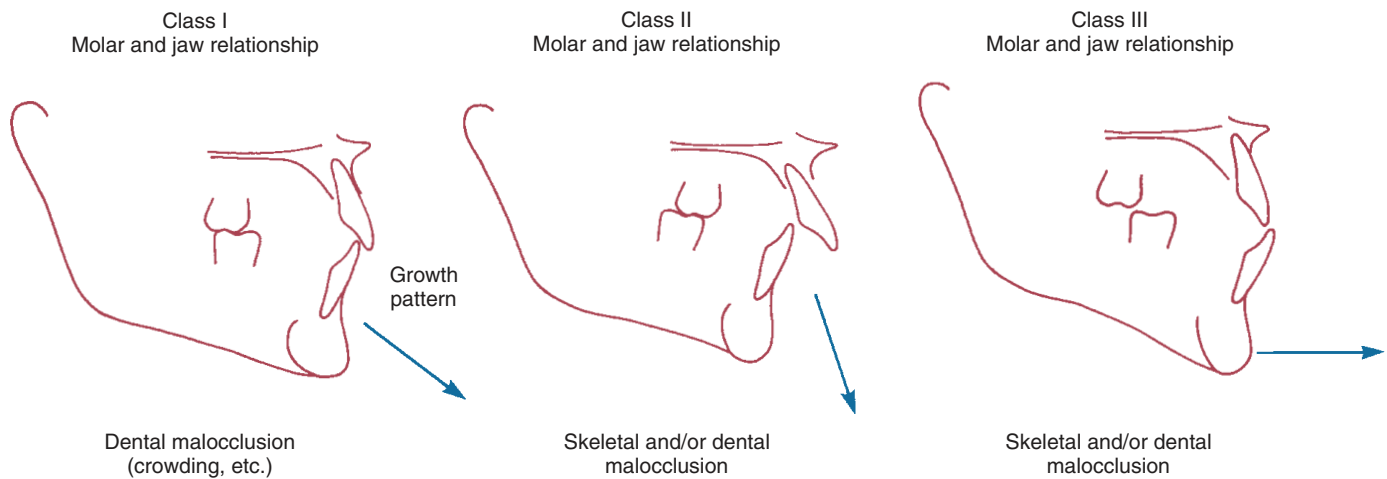
The Angle system was a tremendous step forward, not only because it provided an orderly way to classify malocclusion but also because for the first time it provided a simple definition of normal occlusion and thereby a way to distinguish normal occlusion from malocclusion.

Almost immediately, it was recognized that the Angle classification was not complete because it did not include important characteristics of the patient's problem. The deficiencies in the original Angle system led to a series of informal additions at an early stage. A series of subdivisions of Class I was proposed by Martin Dewey, initially Angle's protégé but later his rival. Gradually,

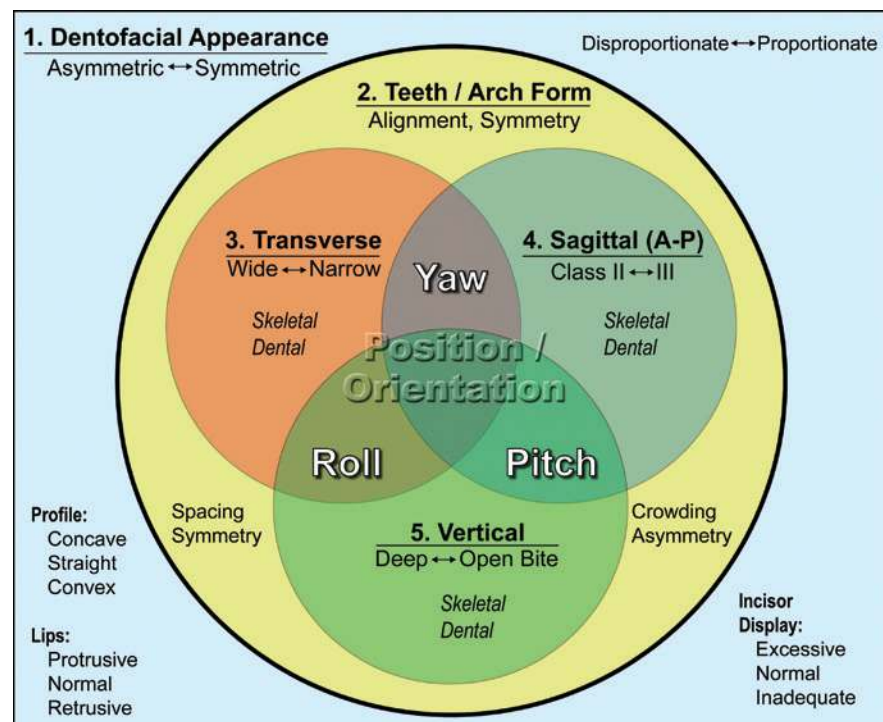
Angle's classification numbers were extended to refer to four distinct but related characteristics: the classification of malocclusion, as in the original plan; the molar relationship; the skeletal jaw relationship; and the pattern of growth (Fig. 6.73). Thus a Class II jaw relationship meant the mandible was positioned distally relative to the maxilla. This was usually found in connection with a Class II molar relationship but occasionally could be present despite a Class I molar relationship. Similarly, a Class II growth pattern was defined as a downward and backward growth direction of the mandible, which would tend to create and maintain Class II jaw and molar relationships. Class I and Class III growth patterns show balanced and disproportionate forward mandibular growth, respectively.

In the 1960s, Ackerman and Proffit formalized the system of informal additions to the Angle method by identifying five major characteristics of malocclusion to be considered and systematically described in classification (Fig. 6.74). The approach overcame the major weaknesses of the Angle scheme. Specifically, it (1) incorporated an evaluation of crowding and asymmetry within the dental arches and included an evaluation of incisor protrusion, (2) recognized the relationship between protrusion and crowding, (3) included the transverse and vertical, as well as the AP, planes





• **Fig. 6.73** The Angle classification has come to describe four different things that can be seen on clinical examination, dental casts, and/or cephalograms: the type of malocclusion, the molar relationship, the jaw relationship, and the pattern of growth, as shown here diagrammatically. Although the jaw relationship and growth pattern correlate with the molar relationship, the correlations are far from perfect. It is not unusual to observe a Class I molar relationship in a patient with a Class II jaw relationship or to find that an individual with a Class I molar and jaw relationship grows in a Class III pattern, which ultimately will produce a Class III malocclusion.



• **Fig. 6.74** Ackerman and Proffit represented the five major characteristics of malocclusion via a Venn diagram. The sequential description of the major characteristics, not their graphic representation, is the key to this classification system, but the interaction of the tooth and jaw relationships with facial appearance must be kept in mind. Note that for each characteristic, the items to be evaluated are listed within the box or circle, with a spectrum of potential problems within that area represented by opposing terms (spacing ↔ crowding, symmetry ↔ asymmetry) and items to be evaluated for dentofacial appearance appear separately in the lower part of that field. The circle for each plane of space represents not only the position but also the orientation of jaws and teeth in that plane of space, and the overlaps between the circles representing the three planes of space are labeled for the orientation problem that this interaction could represent.

of space, and (4) incorporated information about skeletal jaw proportions at the appropriate point, that is, in the description of relationships in each of the planes of space. Experience has confirmed that a minimum of five characteristics must be considered in a complete diagnostic evaluation.

Although the elements of the Ackerman-Proffit scheme now are often not combined exactly as originally proposed, classification by five major characteristics is now widely used. Like other aspects of orthodontic diagnosis, classification is affected by the major changes that have occurred recently such as the development of 3-D imaging and other advances in orthodontic technology. The most important change, however, is the greater emphasis now on evaluating facial soft tissue proportions and the relationship of the dentition to the lips and cheeks, on smile and at rest.

Recent revision of the classification scheme has focused on broadening it to incorporate these new aspects of orthodontic diagnosis. Forty years ago, most orthodontists viewed their role as correcting malocclusion by straightening teeth. At present, the goal of treatment takes into account facial and dental appearance, as well as the relationships of the teeth. Today, evaluation of dentofacial appearance includes full-face evaluation, consideration of anterior tooth display at rest and during smile, and assessment of soft tissues in the oblique (three-quarters) view, as well as in frontal and profile views. Little has changed regarding the description of crowding or spacing within the dental arches, but a clearer understanding of the line of occlusion in relationship to the goals of treatment now is required. The goal of treatment no longer is to just correct malocclusion but to correct it while also bringing the dentition and facial skeleton into normal relationships with the facial and intraoral soft tissues, which means that a more thorough analysis of dentofacial traits is required.

### Additions to the Five-Characteristics Classification System

Two things particularly help this more thorough analysis: (1) evaluating the orientation of the *esthetic line of the dentition*, which is related to but different from Angle's functional line of occlusion, and (2) supplementing the traditional 3-D description of facial and dental relationships with rotational characteristics around each plane of space. These factors will be considered in turn.

1. *Esthetic line of the dentition.* For over a century, Angle's line of occlusion has been used to characterize the positions of the teeth within the dental arch and as a reference for assessing arch form and arch symmetry. Angle's concept was that if the buccal occlusal line of the mandibular dental arch was coincident with the central fossae line of the maxillary dental arch and the teeth were well aligned, ideal occlusion would result. The line of occlusion is hidden from view when the maxillary and mandibular teeth are in contact.

In modern analysis, another curved line characterizing the appearance of the dentition is important, the one that is seen when evaluating anterior tooth display (Fig. 6.75). This line, the esthetic line of the dentition, follows the facial edges of the maxillary anterior and posterior teeth. The orientation of this line, like the orientation of the head and jaws, is best described when the rotational axes of pitch, roll, and yaw are considered in addition to transverse, AP, and vertical planes of space.

2. *Pitch, roll, and yaw in systematic description.* A key aspect of our previous classification system was its incorporation of systematic analysis of skeletal and dental relationships in all three planes of space, so that deviations in any direction would be incorporated

into the patient's problem list. A complete description, however, requires consideration of both translation (forward–backward, up–down, right–left) in 3-D space and rotation about three perpendicular axes (pitch, roll, and yaw) (Fig. 6.76).<sup>47</sup> This is exactly analogous to what would be necessary to describe the position of an airplane in space. The introduction of rotational axes into systematic description of dentofacial traits significantly improves the precision of the description and thereby facilitates development of the problem list.

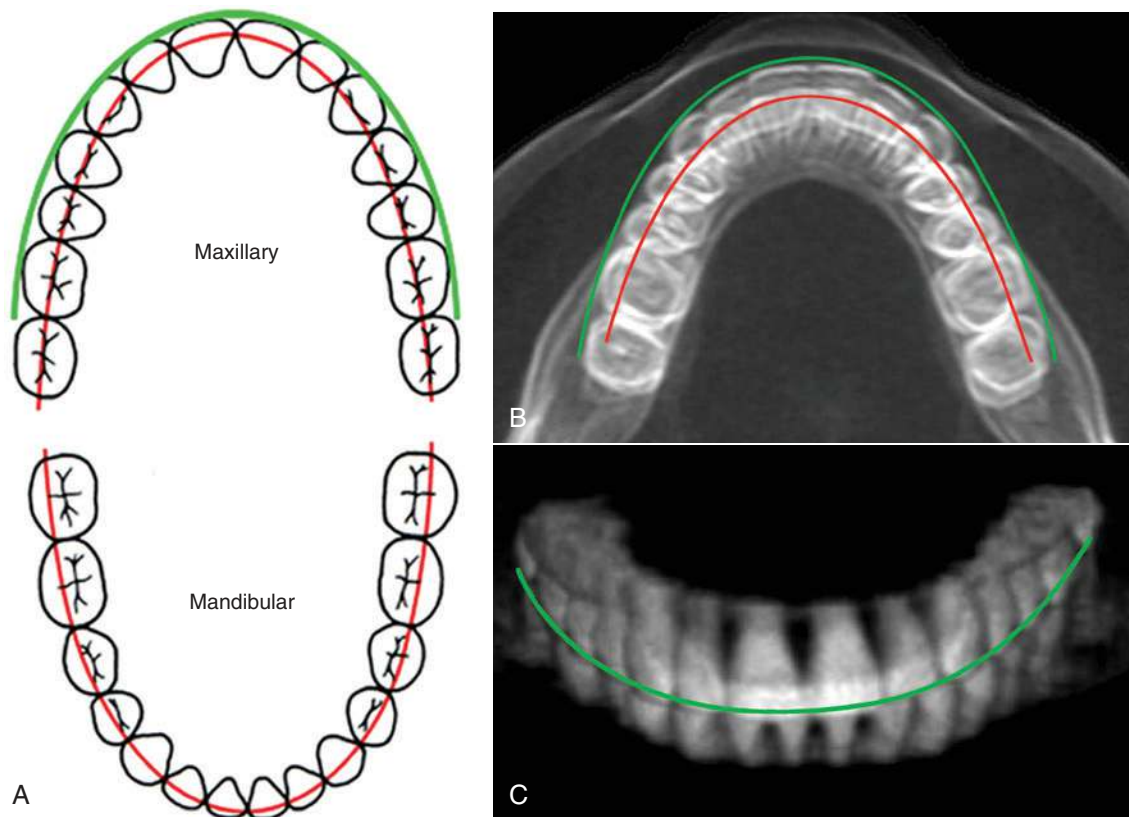
Evaluating pitch, roll, and yaw of the esthetic line of the dentition is particularly useful in determining the relationship of the teeth to the soft tissues that frame their display. From this perspective, an excessive upward–downward rotation of the dentition relative to the lips and cheeks would be noted as pitch (up or down, in front or back) (Fig. 6.77). Pitch of the dentition relative to the facial soft tissues must be evaluated on clinical examination. Pitch of the jaws and teeth relative to each other and to the facial skeleton also can and should be noted clinically, but this can be confirmed from the cephalometric radiograph in the final classification step, where pitch is revealed as the orientation of the palatal, occlusal, and mandibular planes relative to the true horizontal (see Fig. 6.54).

Roll, which is analogous to the banking of an airplane, is described as rotation up or down on one side or the other. On clinical examination, it is important to relate the transverse orientation of the dentition (the esthetic line) to both the facial soft tissues and the facial skeleton. The relationship to the facial soft tissues is evaluated clinically with the intercommissure line as a reference. Neither dental casts nor a photograph using an occlusal plane marker (Fox plane) will reveal this. It is seen with the lips relaxed and more clearly on smile, in both frontal and oblique views (Fig. 6.78; also see Fig. 6.3). The relationship to the facial skeleton is viewed relative to the interocular line. The use of a Fox plane to mark a cant of the occlusal plane may make it easier to visualize how the dentition relates to the interocular line, but with this device in place it is impossible to see how the teeth relate to the intercommissure line.

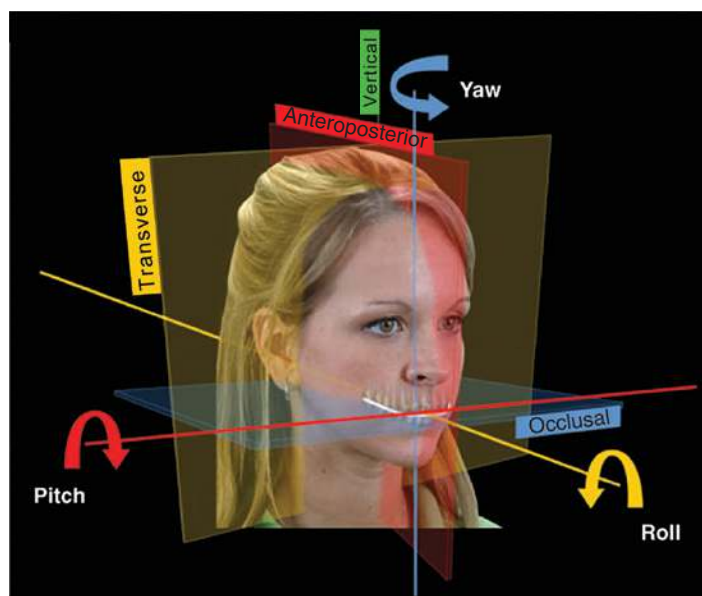
Rotation of the jaw or dentition to one side or the other, around a vertical axis, produces a skeletal or dental midline discrepancy that is best described as yaw (Fig. 6.79). Yaw of the dentition relative to the jaw, or yaw of the mandible or maxilla that takes the dentition with it, may be present. The effect of yaw, in addition to dental and/or skeletal midline deviations, typically is a unilateral Class II or Class III molar relationship. Extreme yaw is associated with asymmetric posterior crossbites, buccal on one side and lingual on the other. Yaw has been left out of all previous classifications, but characterizing transverse asymmetries in this way makes it easier to accurately describe the relationships.

Dental midline deviations can be just a reflection of displaced incisors because of crowding. This should be differentiated from a yaw discrepancy in which the whole dental arch is rotated off to one side. If a true yaw discrepancy is present, the next question is whether the jaw itself is deviated, or whether the dentition deviates relative to the jaw. A yaw deviation of the maxilla is possible but rare; an asymmetry of the mandible that often includes yaw is present in 40% of patients with deficient or excessive mandibular growth,<sup>48</sup> and in these patients the dentition is likely to be deviated in a compensatory direction relative to the jaw. All of this can be detected with a careful clinical examination—and must be because it may not be seen clearly in typical diagnostic records.

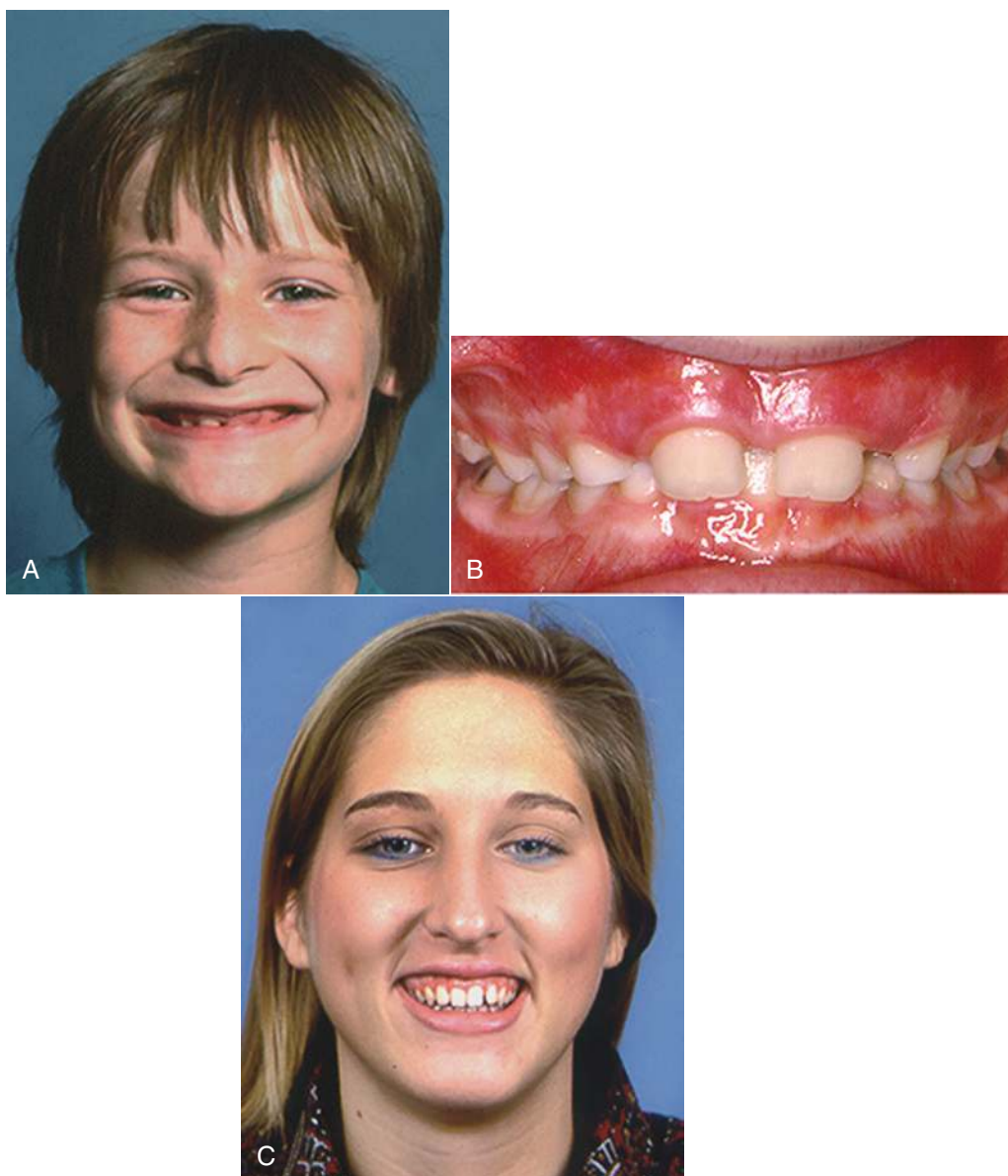
Despite these additions to the diagnostic evaluation, dentofacial traits still can be adequately delineated by five major characteristics.



• **Fig. 6.75** (A) The relationship of the teeth to Angle's line of occlusion (*red*) has long been the basis for analysis of dental arch symmetry and crowding. A curved green line along the incisal edges and cusp tips of the maxillary teeth, the esthetic line of the dentition, now is used to incorporate tooth–lip relationships into the diagnostic evaluation of tooth positions. (B) In vivo submental-vertex cone beam computed tomography (CBCT) view of an individual with normal occlusion showing the maxillary dentition superimposed on the mandibular dentition as it is in life. For this individual, the teeth are aligned and positioned so that the line of occlusion is almost ideally placed for both arches. If a patient has an asymmetry characterized by rotation of the maxilla, mandible, or dentition (any or all of the aforementioned) around the vertical axis, it can be detected in this radiographic projection. The esthetic line of the dentition (*green*) also can be seen in this projection, drawn as it was in (A). (C) A cross-sectional “block” of a CBCT image can be manipulated on the computer screen around all three rotational axes. This is simply a different perspective of the image shown in (B), in which the esthetic line of the dentition is shown in its relationship to the incisal edges and cusp tips of the upper teeth.



• **Fig. 6.76** In addition to relationships in the transverse, anteroposterior, and vertical planes of space used in traditional analysis, rotations around axes perpendicular to these planes also must be evaluated. These rotations are pitch, viewed as up–down deviations around the anteroposterior axis; roll, viewed as up–down deviations around the transverse axis; and yaw, viewed as left–right deviations around the vertical axis. The rotations should be evaluated for the jaws and for the esthetic line of the dentition.



• **Fig. 6.77** The vertical relationship of the teeth to the lips and cheeks during growth or treatment can be conveniently described as downward or upward translation with no pitch deviation, which is rare, or as pitch upward or downward anteriorly and upward or downward posteriorly. The comparison is of the esthetic line of the dentition to the intercommissure line. (A) and (B) downward pitch of the anterior teeth, so that the lower lip almost completely covers the esthetic line of the dentition on smile. Anterior deep bite usually accompanies a pitch of this type. (C) for this girl, who does not have anterior open bite despite her long-face skeletal pattern, the entire dentition is translated down, but a downward pitch posteriorly can be observed clinically. Note that the esthetic line of the dentition tilts down posteriorly relative to the intercommissure line and that there is greater exposure of gingiva posteriorly than anteriorly.

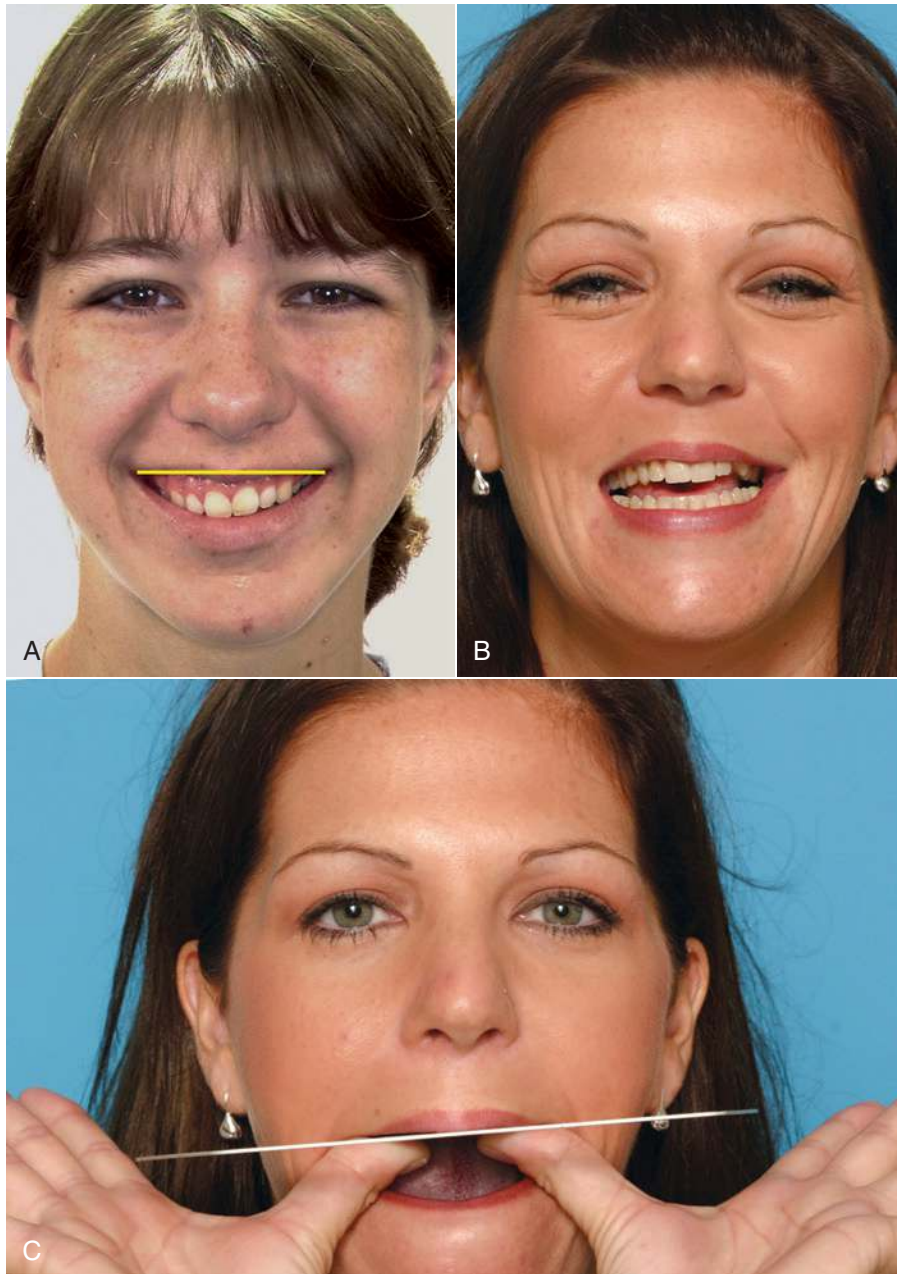The additional items that now must be included in diagnostic evaluation and classification are shown in [Box 6.2](#). Examining the five major characteristics in sequence provides a convenient way of organizing the diagnostic information to be sure that no important points are overlooked.

## Classification by the Characteristics of Malocclusion


### Step 1: Evaluation of Facial Proportions and Esthetics

Step 1 is carried out during the initial clinical examination, while facial asymmetry, AP and vertical facial proportions, and lip–tooth





- Fig. 6.78** *Roll* describes the vertical position of the teeth when this is different on the right and left sides. (A) This image shows a downward roll of the dentition on the right side relative to the intercommissure line (yellow). Note that the maxillary incisors tilt to the left. The chin deviates to the left, reflecting asymmetric mandibular growth with lengthening of the mandibular body and ramus on the right side. The vertical position of the gonial angles can be confirmed by palpation. In this case there is a skeletal component to the roll. (B) Roll of the dentition down on the right side and slightly up on the left, relative to the intercommissure line. There is no transverse displacement of the chin, but the entire right side of the face is larger; note that the interocular line rolls opposite to the esthetic line of the dentition. (C) A Fox plane device demonstrates the orientation of the occlusal plane relative to the interocular line, but the relationship of the teeth to the intercommissure line cannot be observed while one is using it.



• **Fig. 6.79** (A) Yaw of the maxillary dentition to the left side is apparent in this girl, who also has slight yaw of the mandible in the same direction. Note that the yaw of the esthetic line of the dentition is greater than the yaw of the chin. In her clinical examination, it will be important to evaluate the relationship of the midline of the mandibular dentition to the chin. A compensatory yaw of the mandibular teeth back toward the skeletal midline often is present in patients with this type of asymmetry. (B) Severe yaw of the maxillary dentition to the right in this woman, who has almost no yaw of the mandible. Note that she also has more elevation of the right commissure on smile, so relative to the intercommissure line, she has a downward roll of the dentition on the right. This should be noted in the clinical examination because it will be important to determine whether she considers it a problem.

### • BOX 6.2 Classification by the Five Characteristics of Dentofacial Traits

#### Dentofacial Appearance

Frontal and oblique facial proportions, symmetry, anterior tooth display, orientation of the esthetic line of occlusion, profile

#### Alignment

Crowding or spacing, arch form, symmetry, orientation of the functional line of occlusion

#### Anteroposterior

Angle classification, skeletal and dental

#### Transverse

Crossbites, skeletal and dental

#### Vertical

Bite depth, skeletal and dental

relationships (at rest and on smile) are evaluated. This also includes evaluating whether a cant to the dentition exists (a roll up or down one or both sides of the occlusal plane). This can only be evaluated relative to the face.

This evaluation has been covered earlier in this chapter in the context of macro- and mini-esthetic considerations. Incorporation of the data into the classification scheme, using axes of rotation in addition to the traditional three planes of space, is described

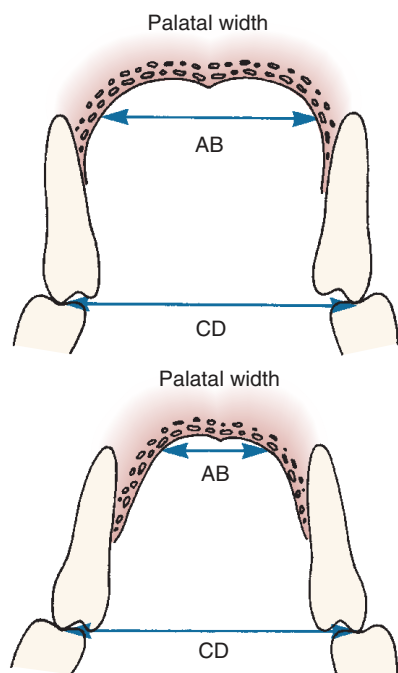
in the previous section. The results are summarized as the positive findings (problems) from this part of the examination. The clinical findings can be checked against the facial photographs and lateral cephalometric radiograph, which should confirm the clinical judgment.

#### Step 2: Evaluation of Alignment and Symmetry Within the Dental Arches

Step 2 is carried out by examining the dental arches from the occlusal view, evaluating first the symmetry within each dental arch and second the amount of crowding or spacing present. Space analysis quantifies crowding or spacing, but these figures must be interpreted in the light of other findings in the total evaluation of the patient. A major point is the presence or absence of excessive incisor protrusion, which cannot be evaluated without knowledge of lip separation at rest. For that reason, the dentofacial relationships noted in the initial clinical examination must be considered immediately along with the relationship of the teeth to the line of occlusion.

#### Step 3: Evaluation of the Transverse Plane of Space

At this stage, the casts are brought into occlusion and the occlusal relationships are examined, beginning with the transverse (posterior crossbite) plane of space. The objectives are to accurately describe the occlusion and to distinguish between skeletal and dental contributions to malocclusion. Now the evaluation is primarily of the dental casts and radiographs, but it must be kept in mind that both roll and yaw of the jaws and dentition affect dentofacial transverse relationships. These factors should have been noted in Step 1 of classification and can be confirmed in this step.



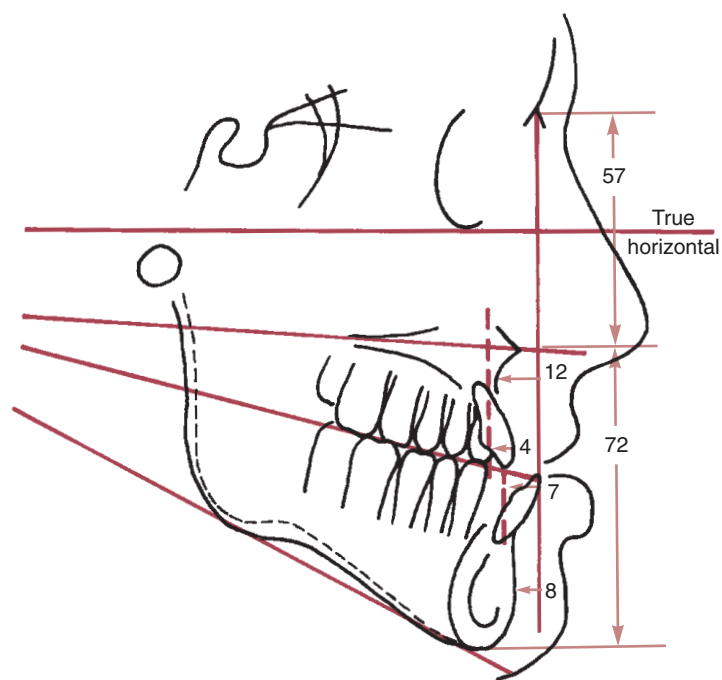
• **Fig. 6.80** Posterior crossbite can be either *dental*, as in a patient with adequate palatal width (i.e., distance AB approximately equals distance CD), or *skeletal* because of inadequate palatal width (i.e., distance CD is considerably larger than distance AB). Because it shows the palate, you can see both dental and skeletal width on a maxillary cast.

Posterior crossbite is described in terms of the position of the upper molars (Fig. 6.80). Thus a bilateral maxillary lingual (or palatal) crossbite means that the upper molars are lingual to their normal position on both sides, whereas a unilateral mandibular buccal crossbite would mean that the mandibular molars are buccally positioned on one side. This terminology specifies which teeth (maxillary or mandibular) are displaced from their normal position.

It is also important to evaluate the underlying skeletal relationships to answer the question, “Why does this crossbite exist?” in the sense of the location of the anatomic abnormality. If a bilateral maxillary palatal crossbite exists, for instance, is the basic problem that the maxilla itself is narrow, thus providing a skeletal basis for the crossbite, or is it that the dental arch has been narrowed although the skeletal width is correct?

The width of the maxillary skeletal base can be seen by the width of the palatal vault on the casts. If the base of the palatal vault is wide, but the dentoalveolar processes lean inward, the crossbite is dental in the sense that it is caused by a distortion of the dental arch. If the palatal vault is narrow and the maxillary teeth lean outward but nevertheless are in crossbite, the problem is skeletal in that it basically results from the narrow width of the maxilla. Just as there are dental compensations for skeletal deformity in the AP and vertical planes of space, the teeth can compensate for transverse skeletal problems, tipping facially or lingually if the skeletal base is narrow or wide respectively.

Transverse displacement of the lower molars on the mandible is rare, so the question of whether the mandibular arch is too wide



• **Fig. 6.81** Cephalometric analysis combining elements of the measurement approaches presented earlier. A description in words of this patient's problems would be that the maxilla is quite deficient relative to the mandible and the cranial base, but the maxillary teeth are reasonably well related to the maxilla. The mandible is fairly well related in the anteroposterior plane of space to the cranial base, but the mandibular teeth protrude relative to the mandible. Vertical proportions are good. A summary of this type, not a table of measurements, is needed for adequate diagnosis.

can be used both to answer the question of whether the mandible or maxilla is at fault in a posterior crossbite and to implicate skeletal mandibular development if the answer is positive. Tabulated data for normal molar and canine widths are shown in Table 6.12. If there is a crossbite and measurements across the arch show that the mandible is wide while the maxillary arch is normal, a skeletal mandibular discrepancy probably is present.

#### Step 4: Evaluation of the Anteroposterior Plane of Space

Examining the dental casts in occlusion will reveal any AP problems in the buccal occlusion or in the anterior relationships. The Angle classification, in its extended form, describes this well.

It is important to ask whether an end-to-end, Class II or Class III buccal segment relationship, or excessive overjet or reverse overjet of the incisors, is caused by a jaw (skeletal) discrepancy, displaced teeth on well-proportioned jaws (dental Class II or III), or a combination of skeletal and dental displacement. Deficient or excessive jaw growth almost always produces an occlusal discrepancy as well, but if the jaw discrepancy is the cause, the problem should be described as a *skeletal* Class II or Class III. The terminology simply means that the skeletal or jaw relationship is the cause of the Class II dental occlusion. The distinction between dental and skeletal is important because the treatment for a skeletal Class II relationship in a child or adult will be different from treatment for a dental Class II problem. Cephalometric analysis is needed to be precise about the nature of the problem. The object is to accurately evaluate the underlying anatomic basis of the malocclusion (Fig. 6.81).

Occasionally the molar occlusion is Class II on one side and Class I on the other. Angle called this a *Class II subdivision*, right or left, depending on which was the Class II side. In modern classification, the subdivision label rarely is useful because it does not describe the real problem. The asymmetric molar relationship reflects either an asymmetry within one or both the dental arches (typically due to loss of space when one primary second molar was lost prematurely) or a yaw discrepancy of the jaw or dentition. These must be distinguished and should already have been addressed in the first or second steps in the classification procedure.

### Step 5: Evaluation of the Vertical Plane of Space

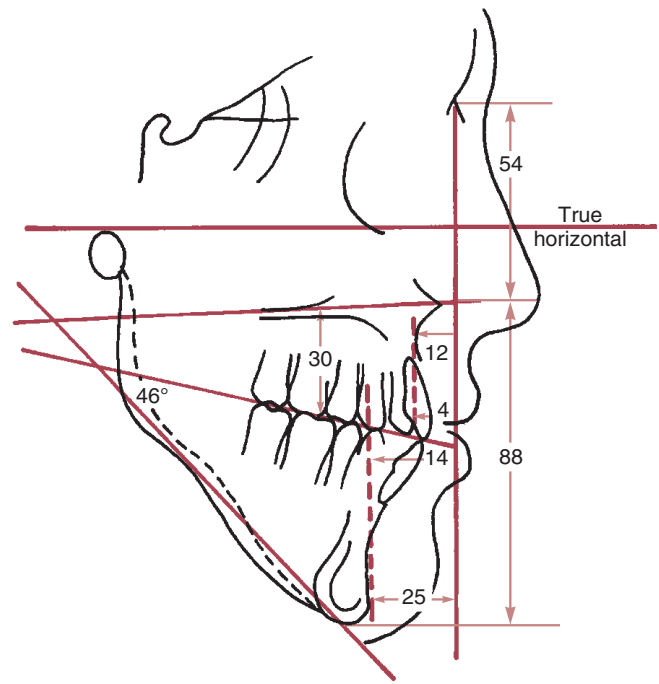
With the casts in occlusion, vertical problems can be described as anterior open bite (failure of the incisor teeth to overlap), anterior deep bite (excessive overlap of the anterior teeth), or posterior open bite (failure of the posterior teeth to occlude, unilaterally or bilaterally). As with all aspects of malocclusion, it is important to ask, “Why does the open bite (or other problem) exist?” Because vertical problems, particularly anterior open bite, can result from environmental causes or habits, the “why” in this instance has two important components: At what anatomic location is the discrepancy, and can a cause be identified?

It is obvious that if the posterior teeth erupt a normal amount but the anterior teeth do not, there will be a pitch discrepancy of the line of occlusion and the esthetic line of the dentition. This would result in two related problems: an anterior open bite and less than the normal display of the maxillary anterior teeth. Upward pitch anteriorly of the maxillary dentition is possible but rarely is the major reason for an anterior open bite. Instead, anterior open bite patients usually have at least some excessive eruption of maxillary posterior teeth. If the anterior teeth erupt a normal amount but the posterior teeth erupt too much, anterior open bite is inevitable. In this case, the relationship of the anterior teeth to the lips would be normal, and there would be excessive display of the posterior teeth. The line of occlusion and the esthetic line of the dentition then would be pitched down posteriorly.

This leads to an important but sometimes difficult concept: a patient with a *skeletal* open bite will usually have an anterior bite malocclusion that is characterized by excessive eruption of posterior teeth, downward rotation of the mandible and maxilla, and normal (or even excessive) eruption of anterior teeth (Fig. 6.82). This facial and dental pattern often is referred to as the “long-face syndrome,” and some patients with this problem do not have an anterior open bite.

The reverse is true in a short-face, skeletal deep bite relationship (Fig. 6.83). In that circumstance, one would expect to see a normal amount of eruption of incisor teeth but rotation of both jaws in the opposite direction and insufficient eruption of the posterior teeth. The skeletal component is revealed by the rotation of the jaws, reflected in the palatal and mandibular plane angles. If the angle between the mandibular and palatal planes is low, there is a skeletal deep bite tendency (i.e., a jaw relationship that predisposes to an anterior deep bite, regardless of whether one is present). Similarly, if the mandibular-palatal angle is high, there is a skeletal open bite tendency.

It is important to remember that if the mandibular plane angle is unusually flat or steep, correcting an accompanying deep bite or open bite may require an alteration in the vertical position of posterior teeth so that the mandible can rotate to a more normal inclination. Cephalometric analysis is required for evaluation of patients with skeletal vertical problems, again with the goal of



• **Fig. 6.82** Cephalometric analysis for a patient with severe vertical problems. Note that the Sassouni lines clearly indicate the skeletal open bite pattern and that the measurements confirm both long anterior facial dimensions and severe mandibular deficiency related to downward and backward rotation of the mandible. Measurement of the distance from the upper first molar mesial cusp to the palatal plane confirms that excessive eruption of the upper molar has occurred.

accurately describing skeletal and dental relationships. As the tracings in this chapter illustrate, most measurement analyses do a much better job of identifying AP than vertical problems.

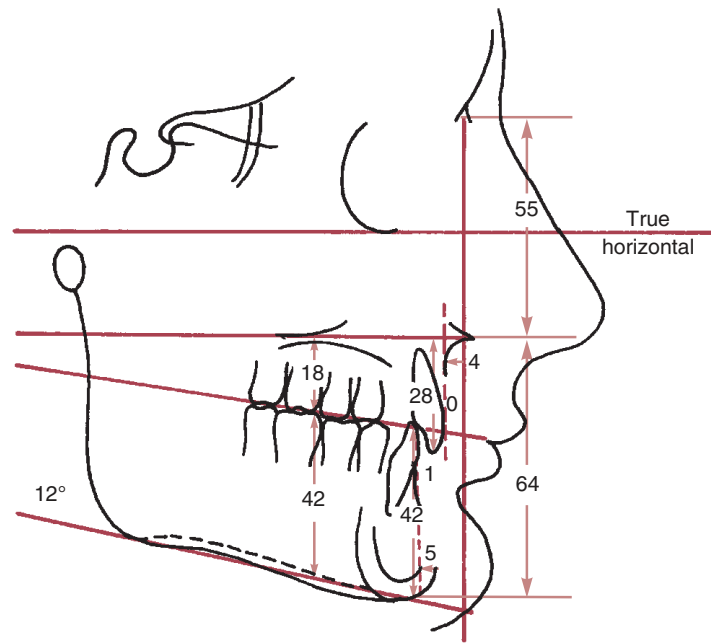
A careful clinical evaluation of the relationship of the dentition to the soft tissues also is critically important. Open bites and deep bites can result from almost any combination of skeletal and dental components, and the problem is likely to include improper tooth–lip relationships. Careful analysis is required if the approach to treatment is to be esthetic and stable.

### Development of a Problem List

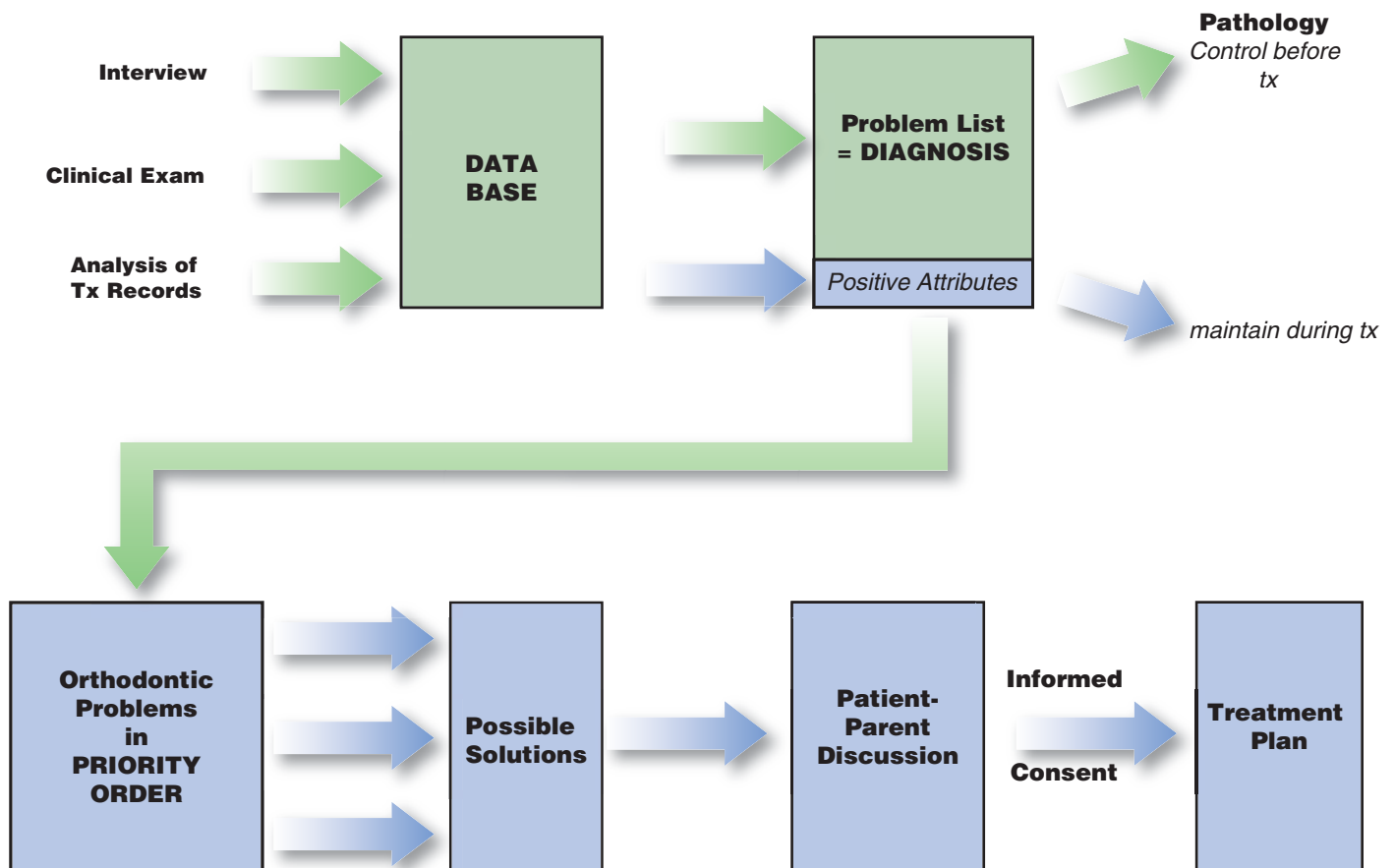
If positive findings from a systematic description of the patient are recorded (i.e., if the procedure previously described is used), the automatic and important result is a list of the patient’s problems. The step-by-step procedure is designed to ensure that the important distinctions have been made and that nothing has been overlooked.

The problem list often includes two types of problems: (1) those relating to disease or pathologic processes and (2) those relating to disturbances of development that have created the patient’s malocclusion (Fig. 6.84). The set of developmental abnormalities related to malocclusion is the orthodontic problem list. A developmental problem is just that (e.g., mandibular deficiency), not the findings that indicate its presence (e.g., weak chin, increased facial convexity, and increased ANB angle all are findings, not problems).





• **Fig. 6.83** Cephalometric analysis of a patient with short anterior vertical dimensions. The measurements show excessive eruption of the lower molar compared with the upper molar and document the distal displacement of the lower incisor relative to the mandible. Note that the Sassouni planes are almost parallel, confirming the skeletal deep bite tendency.

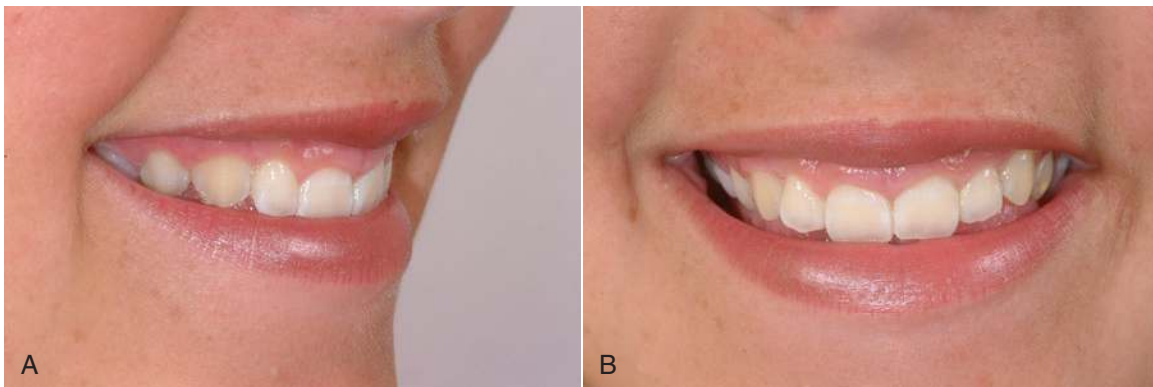


• **Fig. 6.84** As a final step in diagnosis, the patient's problems related to pathologic conditions should be separated from the developmental problems so that the pathologic issues can be brought under control before orthodontic treatment begins. The first step in treatment planning is placing the orthodontic problems in priority, and the treatment planning sequence follows (as described in more detail in [Chapter 7](#)).

For efficient clinical application of the method, it is important to group different aspects of the same thing into a single major problem area related to the Ackerman-Proffit classification. This means that it would be impossible for a patient to have more than five major developmental problems, although several subproblems within a major category would be quite possible. For instance, lingual position of the lateral incisors, labial position of the canines, and rotation of the central incisors all are problems, but they can and should be lumped under the general problem of incisor crowding and malalignment. Similarly, anterior open bite, rotation of the maxilla down posteriorly and rotation of the mandible down anteriorly, and extreme lip incompetence are all aspects of skeletal open bite. When possible, the problems should be indicated quantitatively or at least classified as mild, moderate, or severe (e.g., 5-mm mandibular incisor crowding, severe mandibular deficiency).

The initial diagnostic records for a patient with moderately severe orthodontic problems, whose primary reason for treatment was improvement of her dental and facial appearance, are shown in [Figs. 6.35, 6.39, 6.85, and 6.86](#) and the steps in developing a problem list are illustrated in [Boxes 6.3 to 6.6](#). Similar diagnostic workups for patients with more severe problems are briefly reviewed in [Chapters 19 and 20](#).

With the completion of a problem list, the diagnostic phase of diagnosis and treatment planning is completed, and the more subjective process of treatment planning begins. Thorough diagnostic evaluation means that all problems have been identified and characterized at this stage, omitting nothing of significance. The steps in treatment planning and the outcome of treatment for the patient above are presented at the end of [Chapter 7](#) in [Boxes 7.1 to 7.7](#) and [Figs. 7.23 to 7.28](#).



• **Fig. 6.85** (A) and (B) Patient F.P., age 12-3. Close-up views of the smile can be a valuable part of the diagnostic records when dental and facial appearance is an important consideration in developing a treatment plan. For this patient, the short clinical crowns coupled with almost no display of the gingiva should be noted in the problem list. Note that the oblique smile view allows an excellent view of these characteristics.

#### • BOX 6.3 Patient F.P.: Interview Data

##### Chief Concern

*"I don't like the way my teeth stick out and look ugly."*

##### Medical, Dental, Social History

- Hemangioma removed from leg at age 4
- No chronic medications
- Regular dental care, no restorations
- Lives with both parents, good progress in school, seems well adjusted without any major social problems

##### Motivation

- Largely external, mother wants treatment for a problem that she perceives as important
- Patient agrees that she needs treatment, will have to be convinced that this requires her cooperation

##### Expectation

- General improvement in appearance, seems realistic

##### Other Pertinent Information

- Older brother treated successfully previously; mother very supportive of orthodontic treatment, father much less so

#### • BOX 6.4 Patient F.P.: Clinical Examination Data

##### Dentofacial Proportions

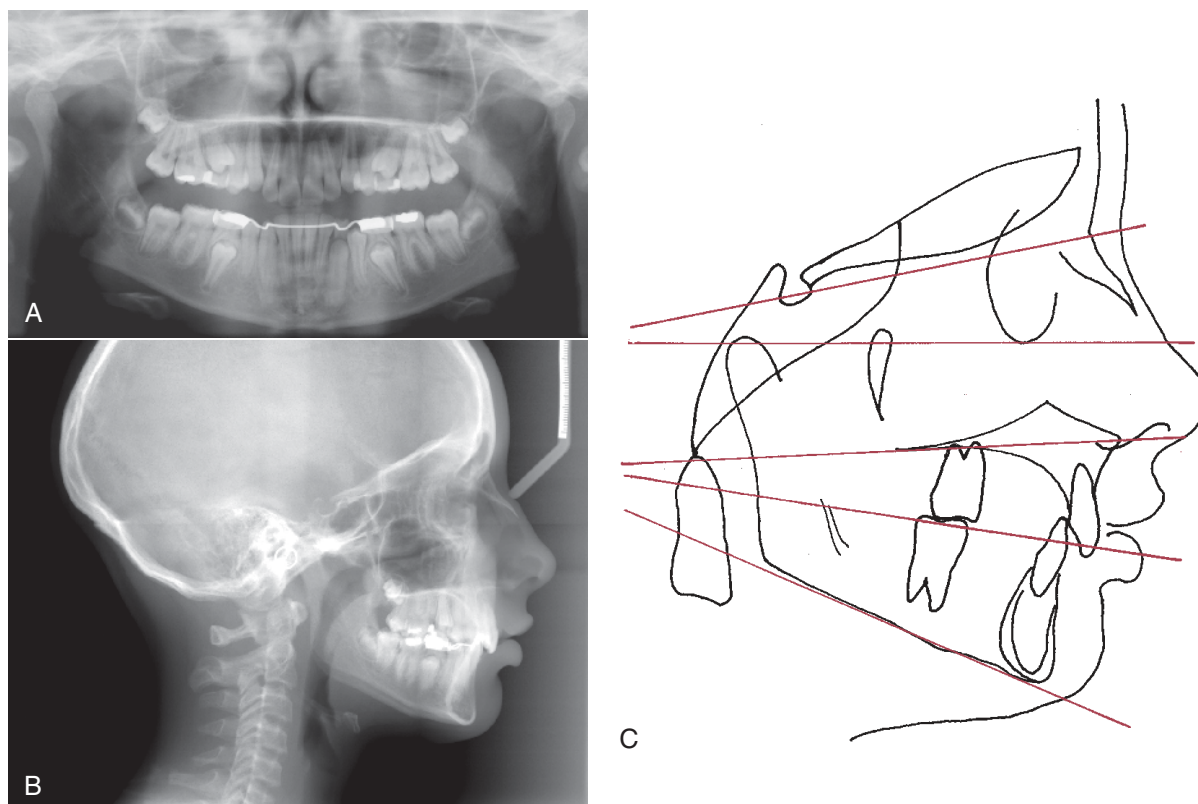
- Mildly short lower third of face
- Moderate mandibular deficiency
- Inadequate display of maxillary incisors
- Maxillary incisors as wide as they are tall: short maxillary incisor crowns
- Moderate facial and dental asymmetry: mild roll down on right and yaw to left are not severe enough to be noticed as a problem

##### Health of Hard and Soft Tissues

- Hypoplastic area, upper left first premolar
- Mild gingivitis
- Moderate overgrowth of gingiva, anterior maxilla

##### Jaw Function

- Maximum opening 45 mm
- Normal range of motion
- No joint sounds
- No pain on palpation



• **Fig. 6.86** Patient F.P., age 12-3. (A) Panoramic and (B) cephalometric radiographs before treatment. (C) Cephalometric tracing before treatment. To assist in visualization of skeletal and dental relationships, drawing this set of horizontal and vertical reference lines and evaluating relationships relative to the true horizontal line and perpendiculars to it is recommended. Note that mandibular deficiency is the major contributor to her Class II malocclusion, and that the deep overbite is primarily due to excessive eruption of the lower incisors. The maxillary incisors are tipped lingually, which is the reason that overjet is not excessive despite the skeletal Class II relationship and the Class II molar relationship.

#### • BOX 6.5 Patient F.P.: Analysis of Diagnostic Records<sup>a</sup>

##### 1. Facial Proportions and Esthetics

- Deficient chin projection, mandibular deficiency
- Mildly short lower third of face
- Maxillary incisors tipped lingually, short crowns

##### 2. Dental Alignment and Symmetry

- Moderate maxillary incisor crowding
- Dental midline off, maxillary incisor displaced

##### 3. Transverse Relationships

- Normal arch widths, no crossbite

##### 4. Anteroposterior Relationships

- Moderate mandibular deficiency
- Class II buccal segments, minimal overjet

##### 5. Vertical Relationships

- Deep bite, excessive eruption of lower incisors
- Mildly short face

<sup>a</sup>Using the Ackerman-Profitt classification to generate the initial problem list.

#### • BOX 6.6 Patient F.P.: Problem List (Diagnosis)<sup>a</sup>

##### Pathologic Problems

- Mild gingivitis, mild gingival overgrowth
- Hypoplastic area maxillary left premolar

##### Developmental Problems

- Mandibular deficiency
- Maxillary incisors tipped lingually, short crowns
- Moderate maxillary incisor crowding
- Class II buccal segments, minimal overjet
- Deep bite, excessive eruption of mandibular incisors

<sup>a</sup>In the order they appeared in the evaluation sequence.

## References

- Cericato GO, Bittencourt MA, Paranhos LR. Validity of the assessment method of skeletal maturation by cervical vertebrae: a systematic review and meta-analysis. *Dentomaxillofac Radiol.* 2015;44:201–2014.
- Deicke M, Pancherz H. Is radius-union an indicator for completed facial growth? *Angle Orthod.* 2005;75:295–299.
- Neelapu BC, Kharbada OP, Sardana HK, et al. Craniofacial and upper airway morphology in adult obstructive sleep apnea patients: a systematic review and meta-analysis of cephalometric studies. *Sleep Med Rev.* 2016;37:618–626.
- Bratton DJ, Gaisl T, Schlatz C, Kohler M. Comparison of the effects of continuous positive airway pressure and mandibular advancement devices on sleepiness in patients with obstructive sleep apnoea: a network meta-analysis. *Laryngoscope.* 2016;126:507–514.
- Okeson JP. *Management of Temporomandibular Disorders and Occlusion.* 7th ed. St. Louis: Mosby-Elsevier; 2013.
- Richards MR, Fields HW, Beck FM, Firestone AR, Bernhardt-Walther D, Rosenstiel SF, Sacksteder JM. The contribution of dental attractiveness and female facial attractiveness to smile esthetics evaluated by eye tracking. *Am J Orthod Dentofacial Orthop.* 2015;147:472–482.
- Baker RS, Fields HW, Johnson EK, et al. The contribution of dental attractiveness and male facial attractiveness to smile esthetics evaluated by eye tracking. *Am J Orthod Dentofacial Orthop.* 2018;153:523–533.
- Shaw WC. The influence of children's dentofacial appearance on their social attractiveness as judged by peers and lay adults. *Am J Orthod.* 1981;79:399–415.
- Shaw WC, Rees MD, Charles CR. The influence of dentofacial appearance on the social attractiveness of young adults. *Am J Orthod.* 1985;87:21–26.
- Rossion B, Hanseeuw B, Dricot L. Defining face perception areas in the human brain: a large scale factorial fMRI face localizer analysis. *Brain Cogn.* 2012;79:138–157.
- Farkas LG. *Anthropometry of the Head and Face in Medicine.* 2nd ed. New York: Raven Press; 1994.
- Berneburg M, Dietz K, Niederle C, et al. Changes in esthetic standards since 1940. *Am J Orthod Dentofacial Orthop.* 2010;137:450.e1–450.e9, discussion 450–451.
- Kokich VO Jr, Kiyak HA, Shapiro PA. Comparing the perception of dentists and lay people to altered dental esthetics. *J Esthet Dent.* 1999;11:311–324.
- Chang C, Springer NC, Fields HW, et al. Smile esthetics from patients' perspective for faces of varying attractiveness. *Am J Orthod Dentofacial Orthop.* 2011;140:e171–e180.
- Dickens ST, Sarver DM, Proffit WR. Changes in frontal soft tissue dimensions of the lower face by age and gender. *World J Orthod.* 2002;3:313–320.
- Parekh S, Fields HJ, Rosenstiel S, et al. Attractiveness of variations in the smile arc and buccal corridor space as judged by orthodontists and laymen. *Angle Orthod.* 2006;76:612–618.
- Sharma N, Rosenstiel SR, Fields HW, et al. Layperson's esthetics and smile characterization between Caucasian and Indian populations. *J Prosthetic Dent.* 2012;107:327–335.
- McLeod C, Fields HW, Hechter F, et al. Esthetics and smile characteristics evaluated by laypersons: a comparison of Canadian and US data. *Angle Orthod.* 2011;81:198–205.
- Rischen RJ, Breuning KH, Bronkhorst EM, Kuijpers-Jagtman AM. Records needed for orthodontic diagnosis and treatment planning: a systematic review. *PLoS ONE.* 2013;8(11):e74186.
- Hollender AM, Anderson Q, Kartha K, et al. Research diagnostic criteria for temporomandibular disorders (RDC/TMD): development of image analysis criteria and examiner reliability for image analysis. *Oral Surg Oral Med Oral Pathol Oral Radiol Endod.* 2009;107:844–860.
- Stevens DR, Flores-Mir C, Nebbe B, et al. Validity, reliability, and reproducibility of plaster vs digital study models: comparison of peer assessment rating and Bolton analysis and their constituent measurements. *Am J Orthod Dentofacial Orthop.* 2006;129:794–803.
- Grauer D, Cevdanes LH, Tyndall D, et al. Registration of orthodontic digital models. In: McNamara JA Jr, Hatch N, Kapila SD, eds. *Effective and Efficient Orthodontic Tooth Movement. Monograph 48, Craniofacial Growth Series.* Ann Arbor, MI: University of Michigan, Department of Orthodontics and Pediatric Dentistry and Center for Human Growth and Development; 2011.
- Kwon TG, Choi JW, Kyung HM, Park HS. Accuracy of maxillary repositioning in two-jaw surgery with conventional articulator model surgery versus virtual model surgery. *Int J Oral Maxillofac Surg.* 2014;732–738.
- Atchison KA, Luke LS, White SC. An algorithm for ordering pretreatment orthodontic radiographs. *Am J Orthod Dentofacial Orthop.* 1992;102:29–44.
- Bolton WA. Disharmony in tooth size and its relation to the analysis and treatment of malocclusion. *Angle Orthod.* 1958;28:113–130.
- Kantor ML, Norton LA. Normal radiographic anatomy and common anomalies seen in cephalometric films. *Am J Orthod Dentofacial Orthop.* 1987;91:414–426.
- Riolo ML, et al. *An Atlas of Craniofacial Growth, Monograph 2, Craniofacial Growth Series.* Ann Arbor, MI: University of Michigan, Center for Human Growth and Development; 1974.
- Popovich F, Thompson GW. Craniofacial templates for orthodontic case analysis. *Am J Orthod.* 1977;71:406–420.
- Broadbent BH Sr, Broadbent BH Jr, Golden WH. *Bolton Standards of Dentofacial Developmental Growth.* St. Louis: Mosby; 1975.
- Jacobson A, Jacobson RL. *Radiographic Cephalometry: From Basics to 3-D Imaging.* Chicago: Quintessence; 2006.
- Lundstrom A, Lundstrom F, Lebrecht LM, et al. Natural head position and natural head orientation: basic considerations in cephalometric analysis. *Eur J Orthod.* 1995;17:111–120.
- Steiner CC. Cephalometries in clinical practice. *Angle Orthod.* 1959;29:8–29.
- Riedel RA. An analysis of dentofacial relationships. *Am J Orthod.* 1957;43:103–119.
- Sassouni V. A classification of skeletal facial types. *Am J Orthod.* 1969;55:109–123.
- Harvold EP. *The Activator in Interceptive Orthodontics.* St. Louis: CV Mosby; 1974.
- Jacobson A. The "Wits" appraisal of jaw disharmony. *Am J Orthod.* 1975;67:125–131.
- McNamara JA. A method of cephalometric evaluation. *Am J Orthod.* 1984;86:449–469.
- Enlow DH, Kuroda T, Lewis AB. The morphologic and morphogenetic basis for craniofacial form and pattern. *Angle Orthod.* 1972;41:161–188.
- Franchi L, Baccetti T, McNamara JA Jr. Cephalometric floating norms for North American adults. *Angle Orthod.* 1998;68:497–502.
- Alqerban A, Jacobs R, Fieuws S, Willems G. Comparison of two cone beam computed tomographic systems versus panoramic imaging for localization of impacted maxillary canines and detection of root resorption. *Eur J Orthod.* 2011;33:93–102.
- Proffit WR, White RP Jr, Sarver DM. *Contemporary Treatment of Dentofacial Deformity.* St. Louis: Mosby; 2003.
- Hanson J, Hennekam RCM, Allanson JE. *Gorlin's Syndromes of the Head and Neck.* 5th ed. New York: Oxford University Press; 2010.
- Grauer D, Cevdanes LS, Styner MA, et al. Accuracy and landmark error calculation using CBCT-generated cephalograms. *Angle Orthod.* 2010;80:286–294.
- Weissheimer A, Menezes LM, Koerich L, et al. Fast three-dimensional superimposition of cone beam computed tomography for orthopaedics and orthognathic surgery evaluation. *Int J Oral Maxillofac Surg.* 2015;44:1188–1196.
- Koerich L, Weissheimer A, de Menezes LM, Lindauer SJ. Rapid 3D mandibular superimposition for growing patients. *Angle Orthod.* 2017;87:473–479.



46. Cevidanes LH, Bailey LJ, Tucker SE, et al. Three-dimensional cone-beam computed tomography for assessment of mandibular changes after orthognathic surgery. *Am J Orthod Dentofac Orthop*. 2007;131:44–50.
47. Ackerman J, Proffit WR, Sarver DM, et al. Pitch, roll and yaw: describing the spatial orientation of dentofacial traits. *Am J Orthod Dentofac Orthop*. 2007;131:305–310.
48. Severt TR, Proffit WR. The prevalence of facial asymmetry in the dentofacial deformities population at the University of North Carolina. *Int J Adult Orthod Orthogn Surg*. 1997;12:171–176.

# 7

## Orthodontic Treatment Planning: From Problem List to Specific Plan

### CHAPTER OUTLINE

#### Treatment Planning Concepts and Goals

##### Major Issues in Planning Treatment

- Patient Input
- Predictability and Complexity of Treatment

##### Treatment Possibilities

- Dental Crowding: To Expand or Extract?
- Skeletal Problems: Macro-Esthetic Considerations
- Mini-Esthetic Considerations: Improving the Smile Framework
- Micro-Esthetic Considerations: Enhancing the Appearance of the Teeth
- Interaction Between Orthodontist and Restorative Dentist
- Reshaping Gingival Contours: Applications of a Soft Tissue Laser

##### Planning Comprehensive Orthodontic Treatment

- Steps in Planning Comprehensive Treatment
- Pathologic Versus Developmental Problems
- Setting Priorities for the Orthodontic Problem List
- Factors in Evaluating Treatment Possibilities
- Informed Consent: Paternalism Versus Autonomy
- The Detailed Plan: Specifying the Treatment Procedures

##### Treatment Planning in Special Circumstances

- Dental Disease Problems
- Systemic Disease Problems
- Jaw Injuries
- Hemimandibular Hypertrophy
- Sleep Apnea
- Cleft Lip and Palate

### Treatment Planning Concepts and Goals

Orthodontic diagnosis is complete when a comprehensive list of the patient's problems has been developed and pathologic and developmental problems have been separated. At that point, the objective in treatment planning is to design the strategy that a wise and prudent clinician, using his or her best judgment, would employ to address the problems while maximizing benefit to the patient and minimizing cost and risk.

It is important to view the goal of treatment in that way. Otherwise, an inappropriate emphasis on some aspect of the case is likely, whether the proposed treatment is medical, dental, or just orthodontics. For example, consider a patient with periodontal problems who seeks orthodontics because she is concerned about mildly crowded lower incisors. For that individual, controlling periodontal disease might be more beneficial than aligning teeth that would require permanent retention, and this should be emphasized when a treatment plan is discussed with the patient, even though she initially sought only orthodontic treatment. Any treatment plan should be developed, in collaboration with the patient, to do what on balance would be best for that individual.

When a group of dentists and dental specialists meets to plan treatment for a patient with complex problems, questions for the orthodontist often are along the lines of "Could you retract the incisors enough to correct the overjet?" or "Could you develop incisal guidance for this patient?" To a question phrased as "Could you ...?" the answer often is yes, given an unlimited commitment to treatment. The more appropriate question is not "Could you ...?" but "Should you ...?" or "Would it be best for the patient to ...?" Cost-benefit and risk-benefit analyses (Fig. 7.1) are introduced appropriately when the question is rephrased that way.

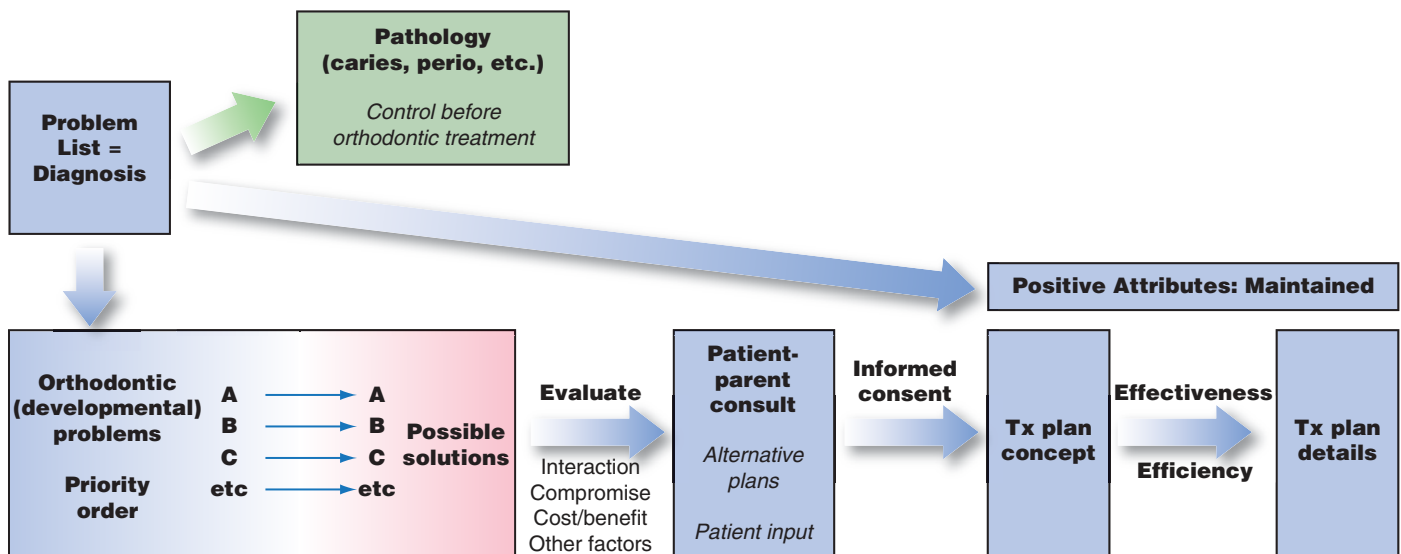
A treatment plan in orthodontics, as in any other field, may be less than optimal if it does not take full advantage of the possibilities or if it is too ambitious. There is always a temptation to jump to conclusions and proceed with a superficially obvious plan without considering all the pertinent factors. The treatment planning approach advocated here is specifically designed to avoid both missed opportunities (the false-negative or undertreatment side of treatment planning) and excessive treatment (the false-positive or overtreatment side), while appropriately involving the patient in the planning.

At this point, before we talk in detail about the steps in going from the problem list to the final treatment plan that are outlined in Fig. 7.1, let us examine some important concepts that underlie orthodontic treatment planning more generally.

### Major Issues in Planning Treatment

#### Patient Input

Modern treatment planning must be an interactive process. No longer can the doctor decide, in a paternalistic way, what is best for a patient. Both ethically and practically, patients and parents must be involved in the decision-making process. Ethically, patients have the right to control what happens to them in treatment—treatment



• **Fig. 7.1** The treatment planning sequence. In treatment planning the goal is wisdom, not scientific truth—judgment is required. Interaction with the patient and parent, so that they are involved in the decisions that lead to the final plan and understand cost and risk versus benefit, is the key to informed consent. Note the distinction between the conceptual plan that contains the treatment objectives and methods and is based on consultation with the patient and parents, and the detailed plan that the orthodontist develops to specify the treatment procedures, including their sequence and timing.

should be something done for them, not to them. Practically, the patient's compliance is likely to be a critical issue in success or failure, and there is little reason to select a mode of treatment that the patient would not support. Informed consent, in its modern form, requires involving the patient in the treatment planning process. This is emphasized in the procedure for presenting treatment recommendations that is presented later.

### Predictability and Complexity of Treatment

If alternative methods of treatment are available, as usually is the case, which one should be chosen? Data are continuing to accumulate to allow choices to be based on evidence of outcomes rather than anecdotal reports and the claims of advocates of particular approaches. This chapter, like all the chapters in this book, has been significantly updated with information that was not available when the previous edition was written. How to judge new data and evaluate the quality of evidence for clinical decisions is emphasized in [Chapter 1](#).

The complexity of the proposed treatment affects treatment planning, especially in the context of who should do the treatment. The focus of this chapter is on planning comprehensive orthodontic treatment. In orthodontics, as in all areas of dentistry, it makes sense that the less complex cases would be selected for treatment in general or family practice, and the more complex cases would be referred to a specialist. In family practice, an important issue is how you rationally select patients for treatment or referral. A formal scheme is presented in [Chapter 11](#) for separating child patients most appropriate for orthodontic treatment in family practice from those more likely to require complex treatment, and a similar scheme for adults appears in [Chapter 19](#).

### Treatment Possibilities

As further background for planning comprehensive treatment, it is important to consider two controversial aspects of current orthodontic treatment planning: the extent to which arch expansion versus extraction is indicated as a solution for crowding in the dental arches, and the extent to which growth modification versus extraction for camouflage or orthognathic surgery should be considered as solutions for skeletal problems.

#### Dental Crowding: To Expand or Extract?

Since the beginning of the specialty, orthodontists have debated the limits of expansion of the dental arches and whether the advantages of extraction of some teeth to provide space for the others outweigh the disadvantages. With extraction, the loss of a tooth or teeth is a disadvantage, greater stability and supporting tissue health are likely and are an advantage, and there may be positive or negative effects on facial esthetics. But for any individual patient the decision is a value judgment. It is not only appropriate but also necessary to discuss the pros and cons with the patient and parent before making the expansion–extraction decision.

In a rational contemporary view, the majority of orthodontic patients can and should be treated without removal of teeth, but some will require extraction to compensate for crowding and/or incisor protrusion that affects facial esthetics. For others, extraction to camouflage a jaw discrepancy will be needed. The number in both groups varies depending on the population being treated. Let's first consider dental crowding and malalignment. In such situations, facial and dental esthetics, posttreatment stability, and dental occlusion are the key factors.

### Esthetic Considerations

If the major factors in extraction decisions are stability and esthetics, it is worthwhile to review existing data that relate these factors to expansion and extraction. Consider esthetics first. The conceptual relationship between expansion–extraction and esthetics is illustrated in Fig. 7.2. All other things being equal, expansion of the arches moves the patient in the direction of more prominent teeth, but extraction tends to reduce the prominence of the teeth. Facial esthetics can become unacceptable on either the too-protrusive or too-retrusive side.

At what point have the incisors been moved too far forward so that facial appearance is compromised? The answer is found in soft tissue, not hard tissue, relationships: When the prominence of the incisors creates excessive lip separation at rest so that the patient must strain to bring the lips together, the teeth are too protrusive and retracting the incisors improves the facial appearance (Fig. 7.3). Note that this has remarkably little to do with the prominence of the teeth relative to the supporting bone as seen in a profile view. An individual with thick, full lips looks good with incisor prominence that would not be acceptable in someone with thin, tight lips. You cannot determine the esthetic limit of expansion from tooth–bone relationships on a cephalometric radiograph.

At what point are the incisors retracted to the point of adversely affecting facial esthetics? This too depends largely on the soft tissues. The size of the nose and chin has a profound effect on relative lip prominence. For a patient with a large nose and/or a large chin, if the choices are to treat without extraction and move the incisors forward or to extract and retract the incisors at least somewhat, moving the incisors forward is better, provided it does not separate

the lips too much. The upper incisors are too far lingually if the upper lip inclines backward—it should be slightly forward from its base at soft tissue point A (Fig. 7.4A). For best esthetics, the lower lip should be at least as prominent as the chin (Fig. 7.4B). Variations in chin morphology may put the proper incisor–chin relationship beyond the control of orthodontics alone, in which case surgical repositioning of the chin perhaps should be considered (see the sections in this chapter on Class II camouflage and maximizing esthetic changes in treatment, and Chapter 20).

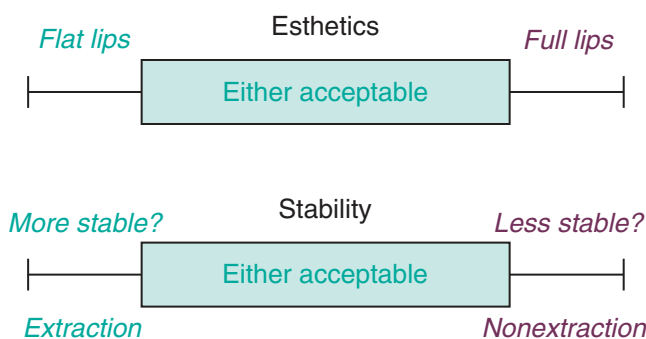
### Stability Considerations

For stable results, how much can arches be expanded? The lower arch is more constrained than the upper, and so its limitations for stable expansion may be somewhat tighter than the upper arch. Current guidelines for the limits of expansion of the lower arch, admittedly based on limited data, are presented in Fig. 7.5. The 2-mm limitation for forward movement of the lower incisors obviously is subject to considerable individual variation but makes sense in light of the observation that lip pressure increases sharply 2 mm out into space usually occupied by the lip (see Chapter 5). If lip pressure is the limiting factor in forward movement, as it probably is, the initial position of the incisors relative to the lip would be a consideration in how much movement could be tolerated. This suggests and clinical observation seems to confirm (again, limited data!) that incisors tipped lingually away from the lip can be moved farther forward than upright incisors. Incisors tipped labially and crowded probably represent the equivalent of a titrated endpoint in a chemical reaction, in that they have already become as protrusive as the facial soft tissues will allow. Moving them any further forward carries great risk of instability (see Fig. 7.2).

There also is a soft tissue limitation in how far the incisors, especially the lower incisors, can be moved facially. Fenestration of the alveolar bone and stripping of the gingiva become increasingly likely as the incisors are advanced. The amount of attached gingiva is a critical variable. Although correction of gingival stripping after it has occurred is possible (Fig. 7.6), pretreatment consultation with a periodontist often is advisable if the gingival attachment is questionable, and depending on the amount and direction of planned tooth movement, placing a gingival graft before orthodontic treatment begins may be the best option for these patients.

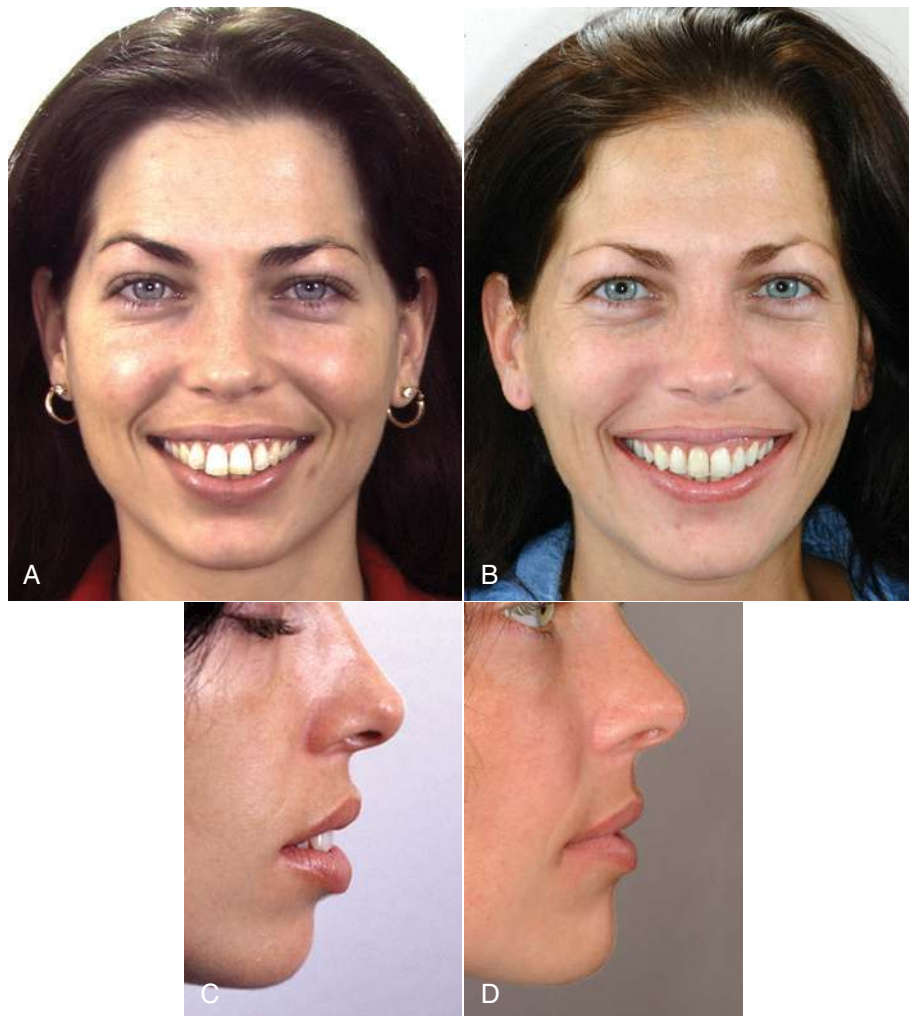As Fig. 7.5 illustrates, there is more opportunity to expand transversely than anteroposteriorly—but only posterior to the canines. Numerous reports show that transverse expansion across the canines is almost never maintained, especially in the lower arch. In fact, intercanine dimensions typically decrease as patients mature, probably because of lip pressures at the corners of the mouth, whether or not they had orthodontic treatment. Expansion across the premolars and molars is much more likely to be maintained, presumably because of the relatively low cheek pressures.

One approach to arch expansion is to expand the upper arch by opening the midpalatal suture (Fig. 7.7). If the maxillary base is narrow, this is appropriate treatment (see the later discussion of transverse maxillary deficiency). Some clinicians theorize (with no supporting evidence) that generously expanding the upper arch by opening the suture, temporarily creating a buccal crossbite, allows the lower arch then to be expanded more than otherwise would have been possible. If the limiting factor is cheek pressure, it seems unlikely that the method of expansion would make any difference. Excessive expansion carries the risk of fenestration of premolar and molar roots through the alveolar bone. There is an increasing risk of fenestration beyond 3 mm of transverse tooth movement.<sup>1</sup>

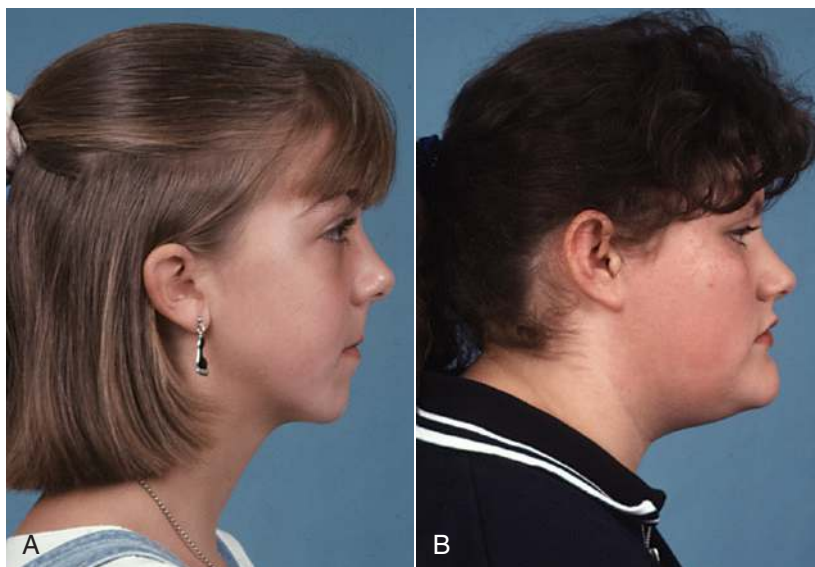


• **Fig. 7.2** Expansion of the dental arches tends to make the teeth more prominent, and extraction makes them less prominent. The choice between extraction and nonextraction (expansion) treatment is a critical esthetic decision for some patients who are toward the extremes of incisor protrusion or retrusion initially, but because there is an acceptable range of protrusion, many if not most can be treated with satisfactory esthetics either way. This is especially true if expansion is managed so as not to produce too much incisor protrusion, or if space closure after extraction is controlled so as not to produce too much incisor retraction. Similarly, expansion tends to make arches less stable and extraction favors stability, but the extraction–nonextraction decision probably is a critical factor in stability largely for patients who are toward the extremes of the protrusion–retrusion distribution. There are no data to show the percentage of patients who could be treated satisfactorily with either extraction or arch expansion versus the number for whom the extraction–nonextraction decision is critical in determining a satisfactory outcome.



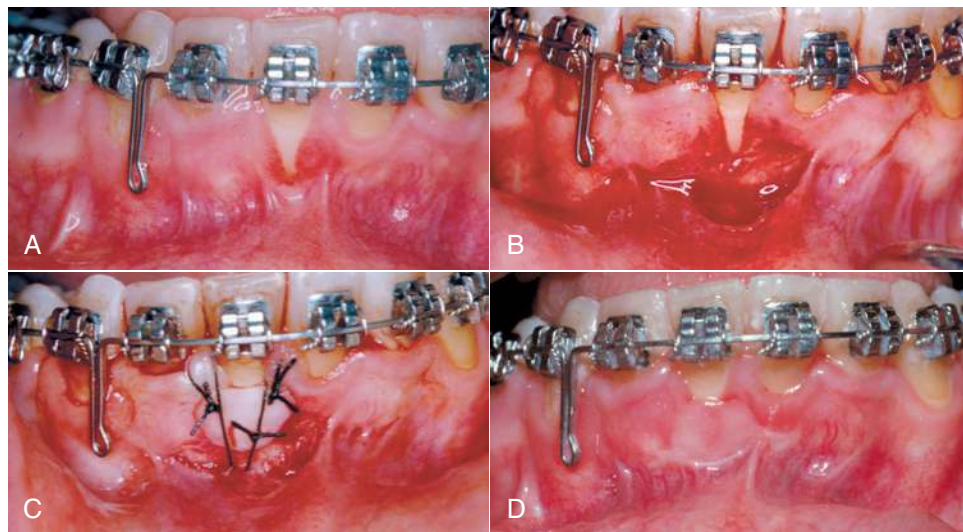
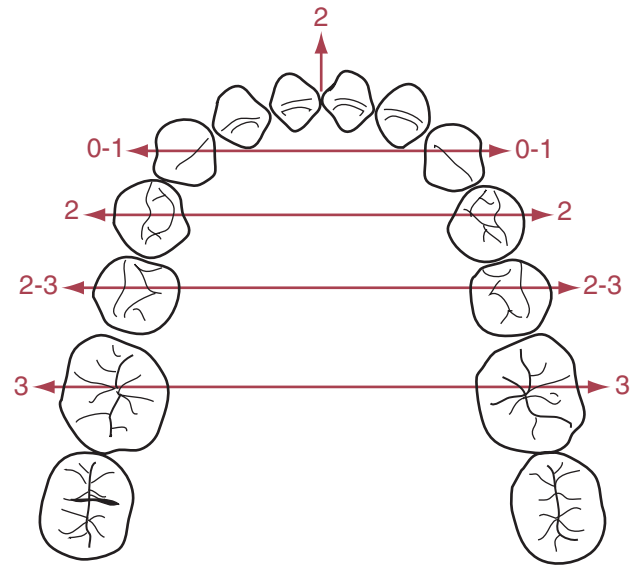


• **Fig. 7.3** In patients with excessive incisor protrusion, retracting the incisors improves facial esthetics. This young woman sought treatment because of dissatisfaction with the appearance of her teeth. After orthodontic treatment with premolar extraction and incisor retraction, dental and facial appearance were significantly improved. (A) and (B) Appearance on smile before and after treatment. (C) and (D) Profile before and after treatment. Although the idea goes back to Edward Angle and was revived in the late 20th century, it simply is not true that arch expansion always gives better facial esthetics.

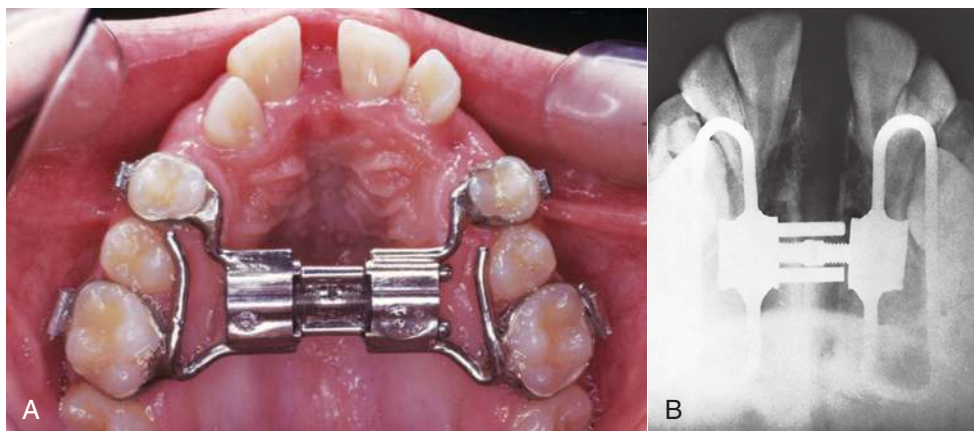


• **Fig. 7.4** (A) An upper lip that inclines backward relative to the true vertical line, which can result from retraction of upper incisors to correct excessive overjet, tends to compromise facial esthetics, as does a poorly defined labiomentral sulcus when lip strain is required to bring the lips together. (B) Retroclined mandibular incisors, as in this patient with a prominent chin and dental compensation for a skeletal Class III jaw relationship, are another cause of a poorly defined labiomentral sulcus.

• **Fig. 7.5** Because the lower arch is more constrained, the limits of expansion for stability seem to be tighter for it than the maxillary arch. The available data suggest that moving lower incisors forward more than 2 mm is problematic for stability, probably because lip pressure seems to increase sharply at about that point. A considerable body of data shows that expansion across the canines is not stable, even if the canines are retracted when they are expanded. Expansion across the premolars and molars, in contrast, can be stable if it is not overdone.



• **Fig. 7.6** (A) Gingival recession beginning to appear in a patient whose crowded lower incisors were aligned with some advancement despite premolar extraction to provide space. (B) Preparation of a bed for a free gingival graft. (C) The graft (tissue taken from the palate) sutured in position. (D) Two weeks later. (Courtesy Dr. J. Moriarty.)



• **Fig. 7.7** Transverse force across the maxilla in children and adolescents can open the midpalatal suture. (A) The expansion force is usually delivered with a jackscrew mechanism fixed to maxillary teeth, as in this Hyrax expander with metal framework and jackscrew, seen at the end of rapid expansion (0.5 mm/day). The maxilla opens as if on a hinge, with its apex at the bridge of the nose. (B) The suture also opens on a hinge anteroposteriorly, separating more anteriorly than posteriorly, as shown in this radiograph of a patient after rapid expansion.

### Contemporary Extraction Guidelines for Alignment

Contemporary guidelines for orthodontic extraction in Class I crowding cases can be summarized as follows:

- **Less than 4 mm of arch length discrepancy:** Extraction rarely indicated (only if there is severe incisor protrusion or, in a few instances, a severe vertical discrepancy). In some cases this amount of crowding can be managed without arch expansion by slightly reducing the width of selected teeth, being careful to coordinate the amount of reduction in the upper and lower arches (see further discussion in [Chapter 16](#)).
- **Arch length discrepancy of 5 to 9 mm:** Nonextraction or extraction treatment possible. The decision depends on both the hard and soft tissue characteristics of the patient and on how the final position of the incisors will be controlled; any of several different teeth could be chosen for extraction. Non-extraction treatment usually requires transverse expansion across the molars and premolars, and additional treatment time if the posterior teeth are to be moved distally, to increase arch length. As early as the 1920s, it was suggested that normal occlusion required a critical width across the maxillary first premolars (Pont's index), and other indices based on arch width have been proposed as predictors of whether extraction is necessary. The modern conclusion is that such indices are not acceptable predictors of whether extraction or expansion would be best for individual patients.<sup>2</sup> This is not surprising, because the key criterion is the amount of lip support from the anterior teeth needed for satisfactory facial appearance.
- **Arch length discrepancy of 10 mm or more:** Extraction almost always required. For these patients, the amount of crowding virtually equals the amount of tooth mass being removed, and there would be little or no effect on lip support and facial appearance. The extraction choice is four first premolars or perhaps upper first premolars and mandibular lateral incisors (which may provide better long-term stability but requires reshaping of the mandibular canines). Second premolar or molar extraction rarely is satisfactory because it does not provide enough space near crowded anterior teeth or options to correct midline discrepancies ([Table 7.1](#)).

### Dental Protrusion Plus Crowding

The presence of protrusion in addition to crowding, of course, complicates the extraction decision. Retracting the incisors to reduce lip prominence requires space within the dental arch. The effect is to increase the amount of arch length discrepancy, with about 2 mm of additional space in the arch (1 mm on each side) required for 1 mm of retraction of the central incisors. With that adjustment, the guidelines described earlier can be applied. To say it differently, if there is 6 mm of crowding in both arches and normal overjet, and the incisors need to be moved back 3 mm to correct lip protrusion and incompetence, 12 mm of space in the dental arch would be needed.

As a general rule, the lips will move about two-thirds of the distance that the incisors are retracted (i.e., 3 mm of incisor retraction will reduce lip protrusion by 2 mm), but there is a great deal of individual variation, primarily because lip retraction stops when the protruding lips come into contact at rest (i.e., when lip competence has been achieved). For that reason, a maximum of 2 to 3 mm of lip retraction is a usual outcome in Class I extraction cases even if the incisors are retracted considerably more than that.

It is often stated confidently that extraction leads to incisor retraction and narrower arches and that expansion leads to incisor protrusion and wider arches, but in the early 21st century, comparison of patients with comparable malocclusions who were treated either way showed little or no difference.<sup>3,4</sup> For both frontal and profile appearance, this has been confirmed by more recent studies.<sup>5,6</sup> The amount of change in both groups, of course, would be related to the amount of crowding and protrusion that was present initially and to the clinician's decision as to how to manage arch expansion or closure of extraction spaces.

A final set of guidelines could be as follows:

- The more you can expand without moving the incisors forward, the more patients you can treat satisfactorily (from the perspective of both esthetics and stability) without extraction.
- The more you can close extraction spaces without over-retracting the incisors, the more patients you can treat satisfactorily (again, from the perspective of both esthetics and stability) with extraction.

**TABLE 7.1** Space From Various Extractions<sup>a</sup>

Extraction	Relief of Incisor Crowding	INCISOR RETRACTION <sup>b</sup>		POSTERIOR FORWARD <sup>b</sup>	
		Maximum	Minimum	Maximum	Minimum
Central incisor	5	3	2	1	0
Lateral	5	3	2	1	0
Canine	6	5	3	2	0
First premolar	5	5	2	5	2
Second premolar	3	3	0	6	4
First molar	3	2	0	8	6
Second molar	2	1	0	—	—

Values in millimeters.

<sup>a</sup>With typical anchorage management (not skeletal anchorage).

<sup>b</sup>Anteroposterior plane of space in absence of crowding.



- For oral health, excessive expansion increases the risk of mucogingival problems.
- For masticatory function, expansion or extraction makes no difference.

Guidelines for extraction to camouflage jaw discrepancies are presented later, in the discussion of that approach to skeletal problems.

### Skeletal Problems: Macro-Esthetic Considerations

The important question in planning treatment for skeletal problems is whether orthodontic treatment, either by compensatory tooth movement and frequently extraction (camouflage) or growth modification, can bring the patient close enough to normal for esthetic social acceptability, or whether a combination of orthodontics and surgery would be required. This can be best answered by following up on the diagnostic information from the macro-esthetics part of the clinical examination and considering the possibilities for correcting facial disproportions. There are three possibilities: (1) orthodontic camouflage, (2) orthognathic and/or plastic surgery, and (3) for growing patients only, orthodontic growth modification.

#### Orthodontic Camouflage

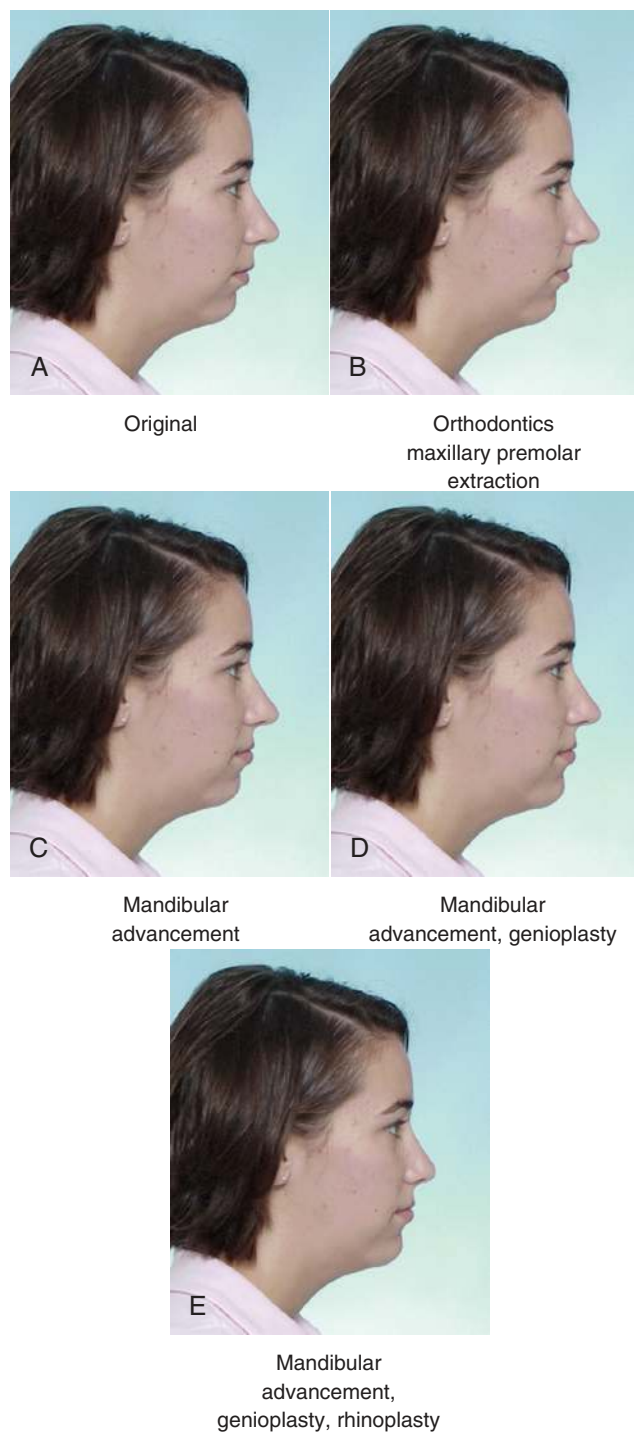
If you can make facial disproportion disappear (or at least reduce it to the point that it is no longer a problem for the patient) without changing the jaw proportions that underlie it, you have solved the patient's problem satisfactorily by camouflaging it. In this sense, the success of camouflage treatment is in the eye of the beholder. Is the facial appearance satisfactory with camouflage, or is a greater change from surgery needed to overcome the perception of deformity? In borderline situations, only the patient and family or friends can answer this question. It is not the doctor's decision.

As we have noted already, orthodontic camouflage of mandibular deficiency by retracting the upper incisors tends to be more successful in a northern European-derived population, in which most people have a convex profile with little or no chin projection. Camouflage of mandibular excess by retracting the lower incisors is rarely indicated in patients of European or African descent but can be effective in patients of Asian descent, who often have prominence of the lower lip more because of protruding incisors than a large mandible. In these situations and with other jaw discrepancies, it still is up to the patient to decide whether tooth movement alone would be successful treatment.

#### Surgery

Computer image predictions of the outcome of orthodontics alone or of orthognathic surgery are an important tool to help the patient and parents or family understand the likely effect of alternative treatments (Fig. 7.8). Because surgery is contrasted with camouflage only after growth is essentially complete, the uncertainty of growth prediction is removed, and the predictions are accurate enough for clinical use. Data from a randomized clinical trial show that surgery patients appreciate the improved communication that the computer predictions make possible and, compared with those who did not see their predictions before surgery, are more likely to be satisfied with the outcome of treatment.<sup>7</sup> Letting the patients see their prediction images now is a routine part of surgical planning (see Chapter 20).

For everyone, advancing age is indicated by increased facial wrinkles, looser skin in the cheeks and throat because of loss of



• **Fig. 7.8** Presenting a computer-generated simulation of the posttreatment profile can greatly help patients understand the differences among alternative treatment approaches. For this patient, the pretreatment profile (A) is shown alongside the probable profile outcomes for orthodontic camouflage of a skeletal Class II problem with retraction of the anterior teeth into first premolar extraction spaces (B) versus mandibular advancement to correct the jaw relationship (C) and mandibular advancement supplemented with genioplasty (D) and rhinoplasty (E). Although showing patients these simulations heightens their esthetic awareness, it does not seem to create unrealistic expectations.



tissue in the deeper layers of the skin, and decreased fullness of the lips. Until recently, face lift surgery approached these problems primarily by pulling the skin tighter. The emphasis now in improving facial appearance in adults is on “filling up the bag”—adding volume rather than decreasing it.

One of the advantages of mandibular advancement surgery, and to a lesser extent of maxillary advancement as well, is that it does add volume and makes adults look younger by doing so (Fig. 7.9). Genioplasty, the most frequently used adjunct to orthodontics, also enhances facial appearance by adding volume to the lower face, but in addition it improves the stability of the lower incisors

and decreases the chance of gingival stripping by adding bone in front of protruding lower incisors,<sup>8</sup> and so is not just a cosmetic procedure.

Orthognathic procedures that decrease volume (mandibular setback and superior repositioning of the maxilla are the best examples) improve facial proportions but can make the patient look older because of the effects on the skin. For that reason, almost all surgical Class III treatment now includes maxillary advancement, which often is combined with mandibular setback in prognathic patients. The goal is to correct the jaw discrepancy without making the patient look prematurely older.



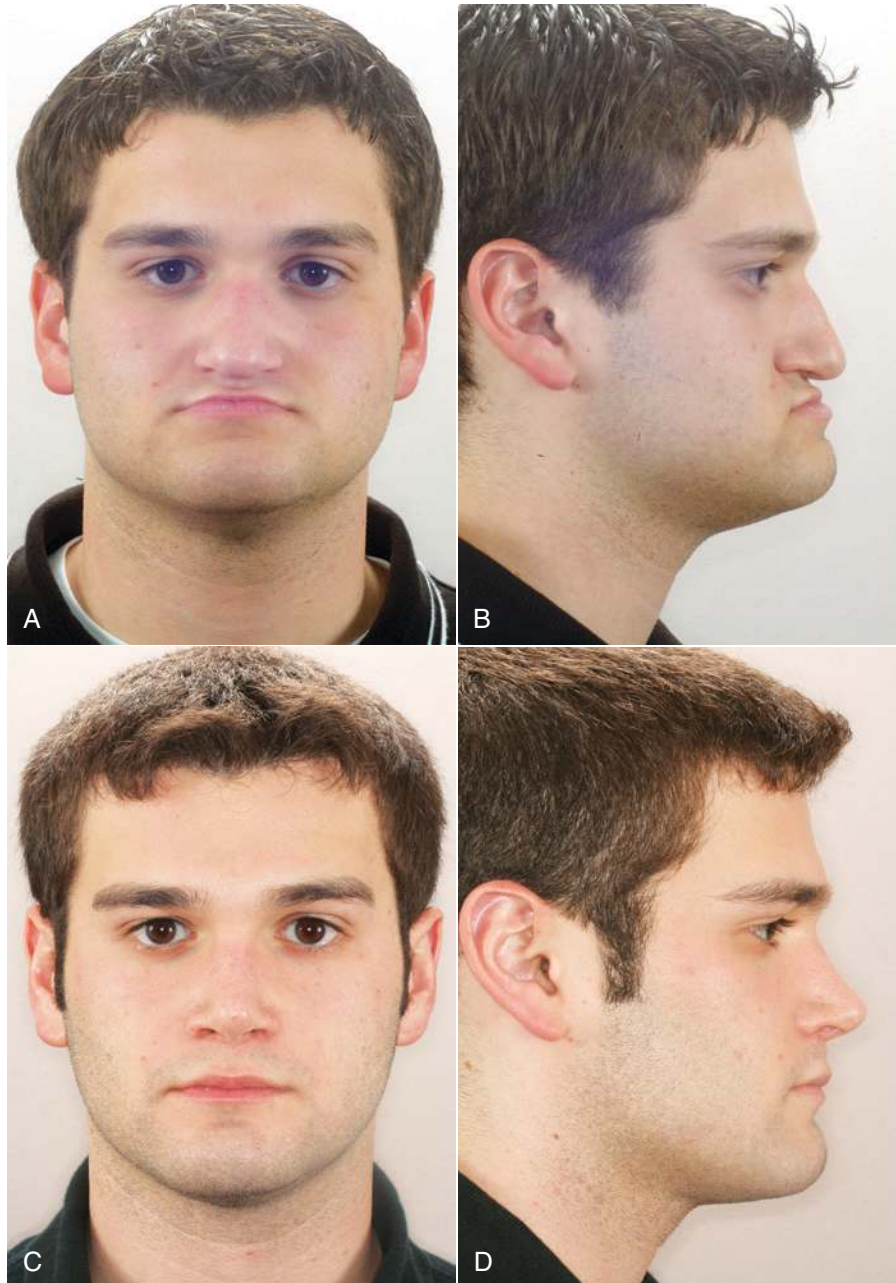• **Fig. 7.9** Surgical mandibular advancement tightens the skin around the mandible, decreasing wrinkles around and beneath the chin, which tends to make the patient look younger. (A) to (C) Patient at age 48, before treatment that involved proclining the maxillary central incisors to produce overjet, then advancing the mandible; (D) to (F) at age 51, 1 year after completion of treatment.

For some patients, maximizing the improvement of esthetics requires facial plastic surgery in addition to orthodontics or orthognathic surgery (Fig. 7.10). Rhinoplasty is particularly effective when the nose is deviated to one side, has a prominent dorsal hump, or has a bulbous or distorted tip. Deficient facial areas, such as the paranasal deficiency that often is seen in patients with maxillary deficiency, can be improved by placing grafts or alloplastic implants subperiosteally.

The interactions of orthodontists and surgeons in treatment of patients who need orthognathic and facial plastic surgery are discussed in Chapter 20.

### Growth Modification

If possible, the best way to correct a jaw discrepancy would be to get the patient to grow out of it. Because the pattern of facial growth is established early in life and rarely changes significantly,



• **Fig. 7.10** It is quite possible to combine rhinoplasty with orthognathic surgery, and correcting a nasal deformity can be a significant adjunct to the improved appearance after contemporary maxillofacial surgery. (A) and (B) Oblique and profile photographs before treatment. Note that this man's skeletal Class III problem was largely maxillary deficiency and that there was abnormal anatomy of the nasal bridge, a widened nasal base, and an enlarged and bulbous nasal tip. (C) and (D) Oblique and profile photographs after maxillary advancement and rhinoplasty. The improvement in the nose nicely complements the better projection of the maxilla.



this is unlikely without treatment. To some extent, however, jaw growth in all three planes of space can be modified, with a combination of restraint of excessive growth and stimulation of favorable growth. The attitudes of orthodontists to this have varied greatly over time, with back-and-forth enthusiasm and pessimism about making significant changes in jaw relationships. Most recently, great optimism in the late 20th century has been tempered by better outcomes data.

Modern growth modification is discussed in detail in [Chapters 13 and 14](#), in the context of how much change can be accomplished in each of the planes of space. There is an interesting contrast in success compared with camouflage; greater growth modification is possible in Class III than in Class II patients—just the reverse of the possibilities for camouflage.

### Mini-Esthetic Considerations: Improving the Smile Framework

The primary goal of mini-esthetic treatment is to enhance the smile by correcting the relationship of the teeth to the surrounding soft tissues on smiling. In the development of the problem list, the examination focuses on three aspects of the smile: the vertical relationship of the lips to the teeth, the transverse dimensions of the smile, and the smile arc. This section considers the possibilities for problems of this type.

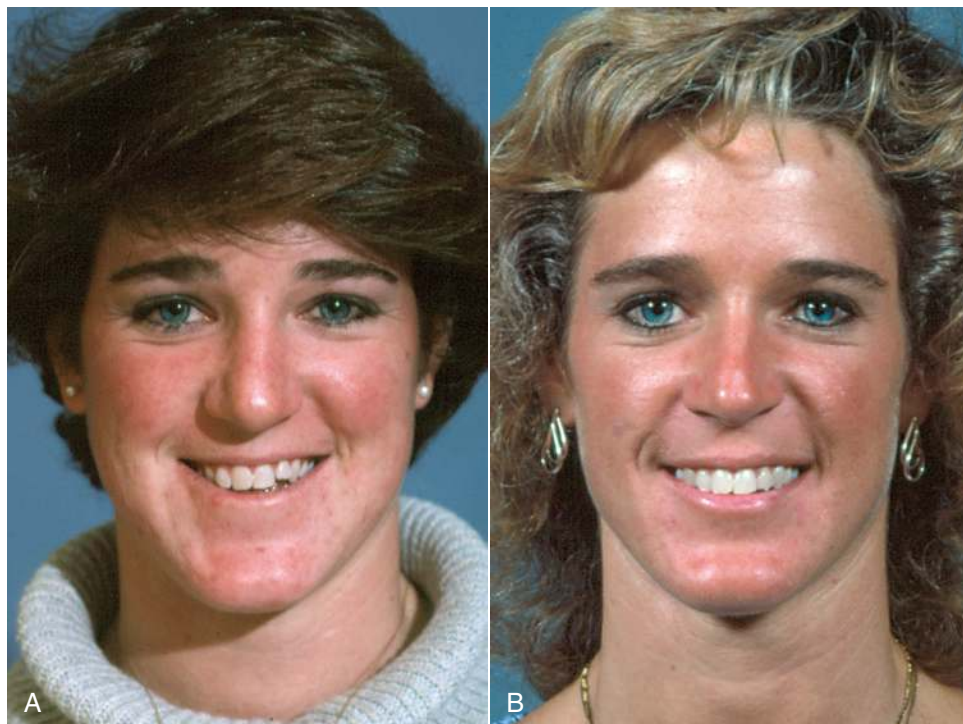#### Vertical Tooth–Lip Relationships

It is important to display most of the crowns of the maxillary anterior teeth in a social smile, and the general guideline is that

there should be at least 75% display of the central incisor.<sup>9</sup> The amount of display is a function of the age of the patient, with a peak at adolescence of an average display of 85%, little change up to about age 30, and then a gradual decrease as aging lowers the lips across the anterior teeth. Exposure of all the crown and some gingiva is both esthetically acceptable and youthful appearing (see [Fig. 6.24](#) and [Table 6.7](#)). Obviously, the goal in treatment should be to position the teeth relative to the upper lip so that they are displayed on smile within these guidelines. In applying the guidelines, it should be kept in mind that tooth display is greater in females.

If the tooth display is inadequate, elongating the upper teeth improves the smile, makes the patient look younger, and is the obvious plan. There are several possible treatment approaches to accomplish this, which would be selected on the basis of other aspects of the patient's problems. In orthodontic treatment alone, extrusive mechanics with archwires, judicious use of Class II elastics to take advantage of their tendency to rotate the occlusal plane down anteriorly, and anterior vertical elastics could be considered. Rotating the maxilla down in front as it is advanced surgically can improve smile esthetics, especially in patients with maxillary deficiency ([Fig. 7.11](#)).

Excessive display of maxillary gingiva on smile must be evaluated carefully because of the natural tendency for the upper lip to lengthen with increasing age.<sup>10</sup> What looks like too much gingival exposure in early adolescence can look almost perfect a few years later (see [Fig. 4.26](#)). There are now three possible treatment approaches to excessive gingival display due to incorrect dental and skeletal relationships: (1) intrusion of the maxillary incisors



• **Fig. 7.11** Inadequate exposure of the maxillary teeth impairs the appearance of the smile, and increasing incisor display for such a patient improves it. (A) Before treatment, the patient's chief complaint was her facial appearance. Although her problem would traditionally be described as a mild skeletal Class III problem due to maxillary deficiency, the frontal rather than the profile appearance was (appropriately) her major concern. (B) After treatment to bring the maxilla forward and rotate it down anteriorly, to increase incisor display.

using segmented arch mechanics, (2) intrusion using temporary skeletal anchorage, and (3) orthognathic surgery to move the maxilla up. With all these methods, it is possible to overdo intrusion of the anterior teeth, which, of course, makes the smile less attractive and the patient look older. In some patients, overgrowth of the gingiva may contribute to the initial excessive display, and if so, recontouring the gingiva to gain normal crown heights is an important part of correcting the problem. Laser surgery (see later) makes this much easier and more convenient than previously.

### Transverse Dimensions of the Smile


“She [or he] has a broad, welcoming smile” often is used as a compliment. Exactly what does that mean? In patients whose arch forms are narrow or collapsed, the smile may also appear narrow, which is less appealing esthetically. In the diagnostic examination of the smile framework, the width of the buccal corridors was noted. Transverse expansion of the maxillary arch, which decreases buccal corridor width, improves the appearance of the smile *if* the buccal corridor width was excessive before treatment (Fig. 7.12). Prosthodontists have learned that too wide a denture set-up, so that the buccal corridor is obliterated, is unesthetic. Too much expansion of the natural dentition can produce the same unnatural appearance of the teeth, so transverse expansion is not for everyone.

Should this be done only with dental expansion or by opening the midpalatal suture? That depends on the amount of expansion that is needed to meet the other goals of proper occlusion and long-term stability. An important consideration in widening a narrow arch form, particularly in an adult, is the axial inclination of the buccal segments. Patients in whom the posterior teeth are already flared laterally are not good candidates for dental expansion.

### The Smile Arc

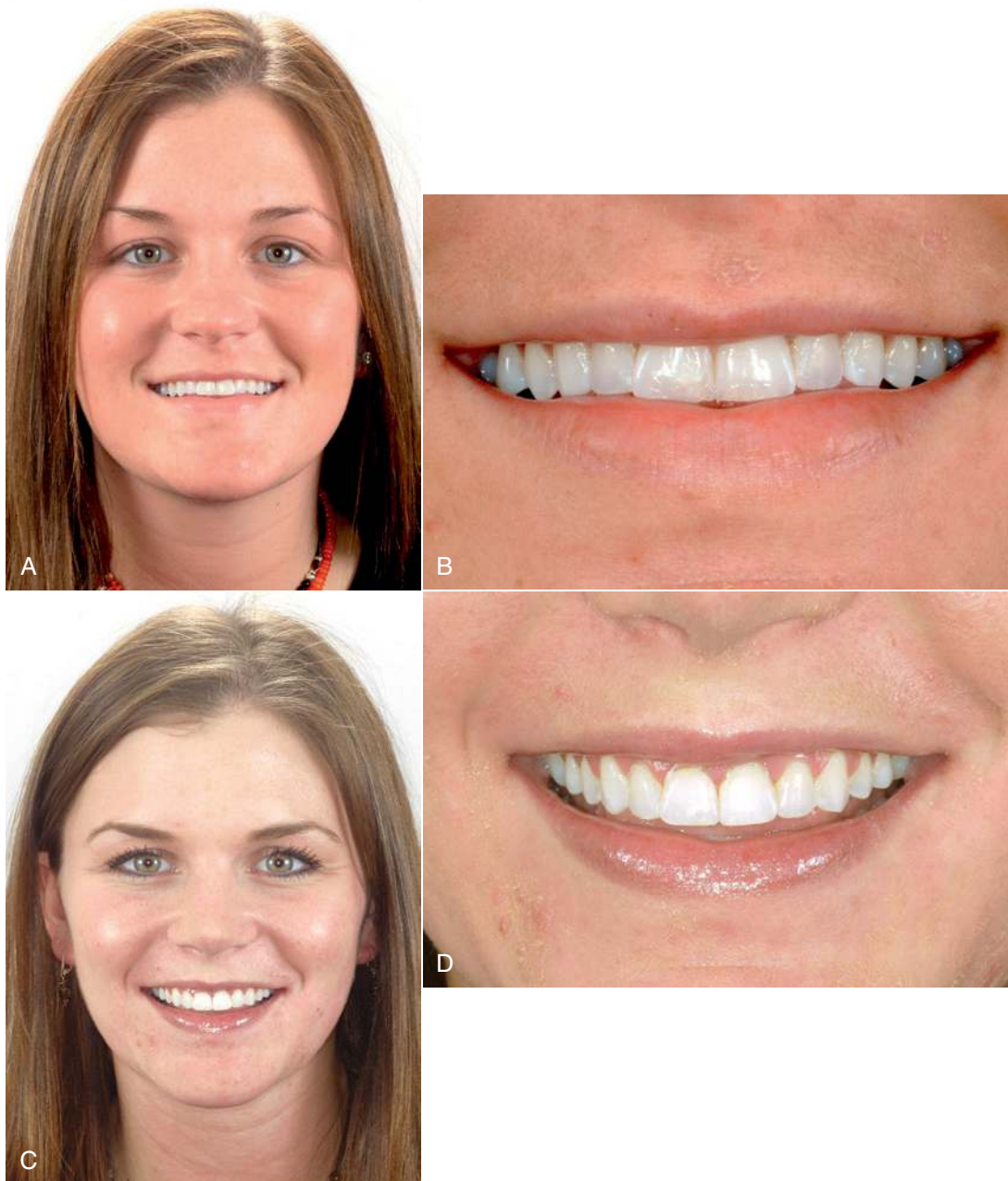
Obtaining and maintaining a proper smile arc requires taking this into account when brackets are placed on the teeth. The traditional guideline for placing brackets has been based on measurements from the incisal edge so that the central incisor bracket is placed at about the middle of the clinical crown, the lateral incisor bracket about 0.5 mm closer to the incisal edge than the central, and the canine about 0.5 mm more apically. The effect is to position the teeth very nicely in relation to one another, as they would be in a denture set-up, without taking into consideration the vertical tooth–lip relationship that the prosthodontist would emphasize. The result may not be compatible at all with the best appearance of the teeth on smile because the smile arc was not considered. Research has suggested that the smile arc is the most important determinant of the attractiveness of the smile—more important than buccal corridor space, although both play a significant role.<sup>11</sup>

What would you do differently in placing brackets to obtain the best smile arc? The usual problem is that the smile arc is too flat (Fig. 7.13; also see Fig. 6.27). If that is the case, putting the maxillary central incisor brackets more gingivally would increase the arc of the dentition, bring them closer to the lower lip, and make the smile arc more consonant with the lower lip. If the smile arc were distorted in some other way, placing the brackets to compensate for this by altering tooth positions would be the solution. Of course, if the smile arc had been flattened during treatment, step bends in the archwire would be an alternative to rebonding brackets to correct it. Repositioning incisors to obtain a better smile arc may be needed in orthognathic surgery patients, as well as in patients who are to receive orthodontic treatment only.



• **Fig. 7.12** For patients with wide buccal corridors, transverse expansion of the maxilla can improve smile esthetics. (A) Age 12, before treatment. (B) Age 15, after orthodontic treatment with widening of the maxillary arch.





• **Fig. 7.13** The smile arc is the most important single thing in smile esthetics. (A) and (B) Full-face and close-up views of the smile before treatment. Note the flat smile arc and inadequate display of maxillary incisors. (C) and (D) One year later, after orthodontic (not orthognathic surgery) treatment. The improvement in facial appearance is largely due to better lip support by the upper teeth that decreased the paranasal folds and attainment of a correct smile arc.

### Smile Symmetry

An asymmetric smile sometimes is a patient's major concern. It is possible that this is due to more eruption of the teeth or different crown heights on one side, and if so, repositioning the teeth or changing the gingival contours should be included in the treatment plan. Often, however, greater elevation of the lip on one side on smile, which is an innate characteristic that cannot be changed, gives the appearance of a cant to the maxillary dentition when it really is symmetric. For a patient who complains about smile asymmetry, this becomes an important informed consent issue; the patient must understand that the asymmetric lip movements will not be changed by treatment.

### Micro-Esthetic Considerations: Enhancing the Appearance of the Teeth

Treatment plans for problems relating directly to the appearance of the teeth fall into three major categories: (1) reshaping teeth to change tooth proportions; (2) orthodontic preparation for restorations to replace lost tooth structure and correct problems of tooth shade and color; and (3) reshaping of the gingiva.

#### Reshaping Teeth

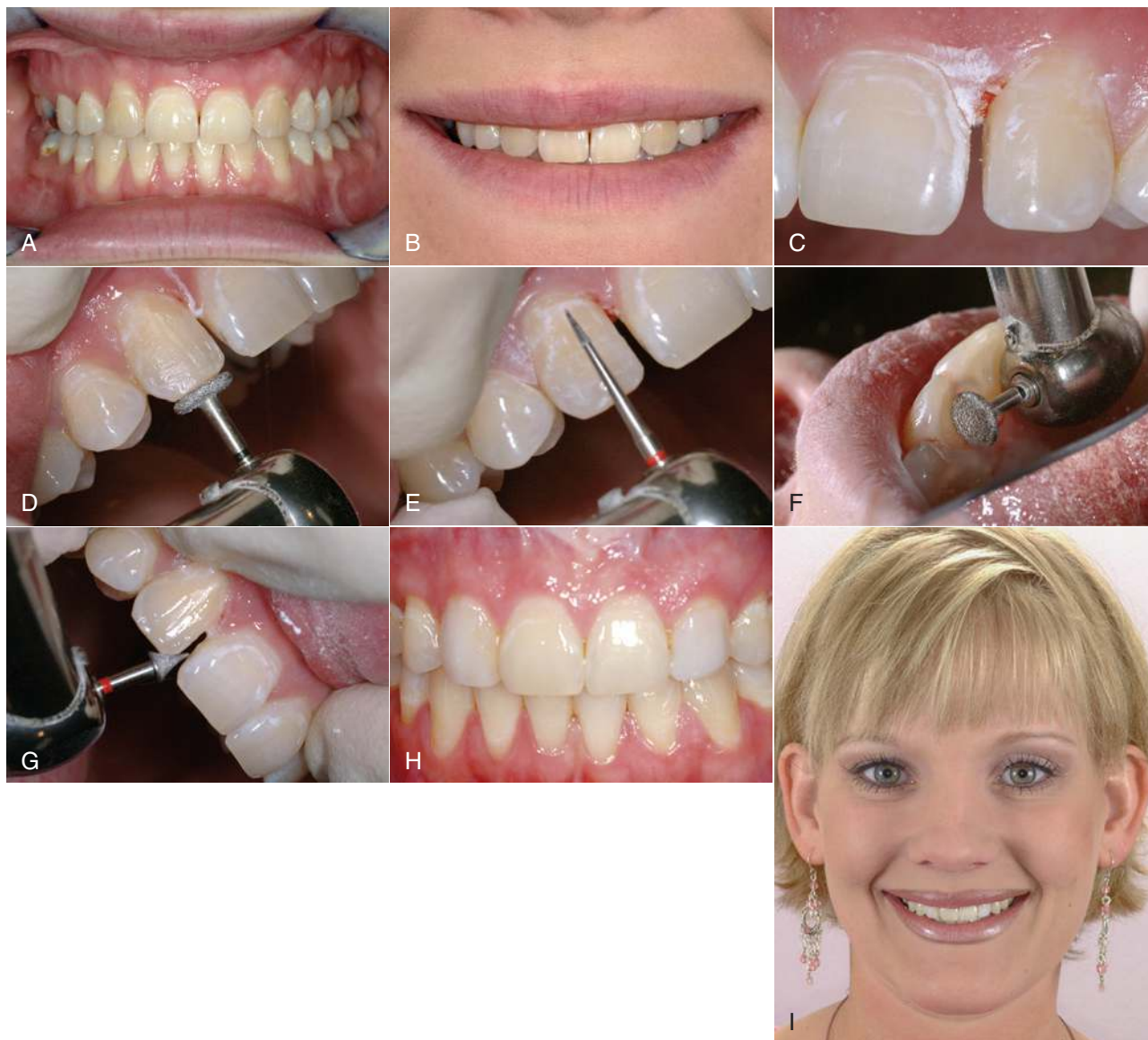Often, it is desirable to do minor reshaping of the incisal edges of anterior teeth to remove mamelons or smooth out irregular

edges from minor trauma. When minor reshaping is planned, it must be considered when brackets are placed, and it may be easier to do this before beginning fixed appliance treatment.

**Changing Tooth Proportions.** Extensive changes in tooth proportions are needed primarily when one tooth is to substitute for another, and the most frequent indication is substituting maxillary canines for congenitally missing maxillary lateral incisors. When a lateral incisor is missing, the treatment alternatives always are closing the space and substituting the canine, or prosthetic replacement of the missing tooth with a single-tooth implant or fixed bridge. The technique for reshaping a canine is illustrated in Fig. 7.14. It requires significant removal of facial, occlusal,

interproximal, and lingual enamel. The canine is normally a darker color than the lateral incisor, and removal of facial enamel to get light reflection from the facial surface as it would be from a lateral incisor can further darken the tooth. In some patients, composite buildups or ceramic laminates are needed to obtain good tooth contour and color.

Closing the space and reshaping the canine to look like a lateral incisor can provide an excellent esthetic result, perhaps superior to an implant in the long run. It is important to keep in mind, however, that canine substitution works best when the dental arch was crowded anyway. It may not be compatible with excellent occlusion and smile esthetics if closing the lateral incisor space



• **Fig. 7.14** To reshape a maxillary canine that is to substitute for a missing maxillary lateral incisor (A and B), the steps in treatment consist of interproximal reduction (C) flattening the tip (D) flattening the facial surface (E) reducing gingulum thickness (F), and rounding the corners of the flattened crown (G). At that point, a lateral bracket can be placed on the canine during orthodontic treatment. If the gingival margin of the canine is visible (which is undesirable when it is to substitute for a lateral incisor), it can be concealed by elongating the tooth and increasing the amount of gingival reduction. Recontouring the gingiva over the first premolar that becomes a substitute for the canine also enhances appearance. In (H), note that the gingival margin of the first premolar has been reshaped (with a diode laser) to make it look more like a canine. (I) Smile at completion of treatment.



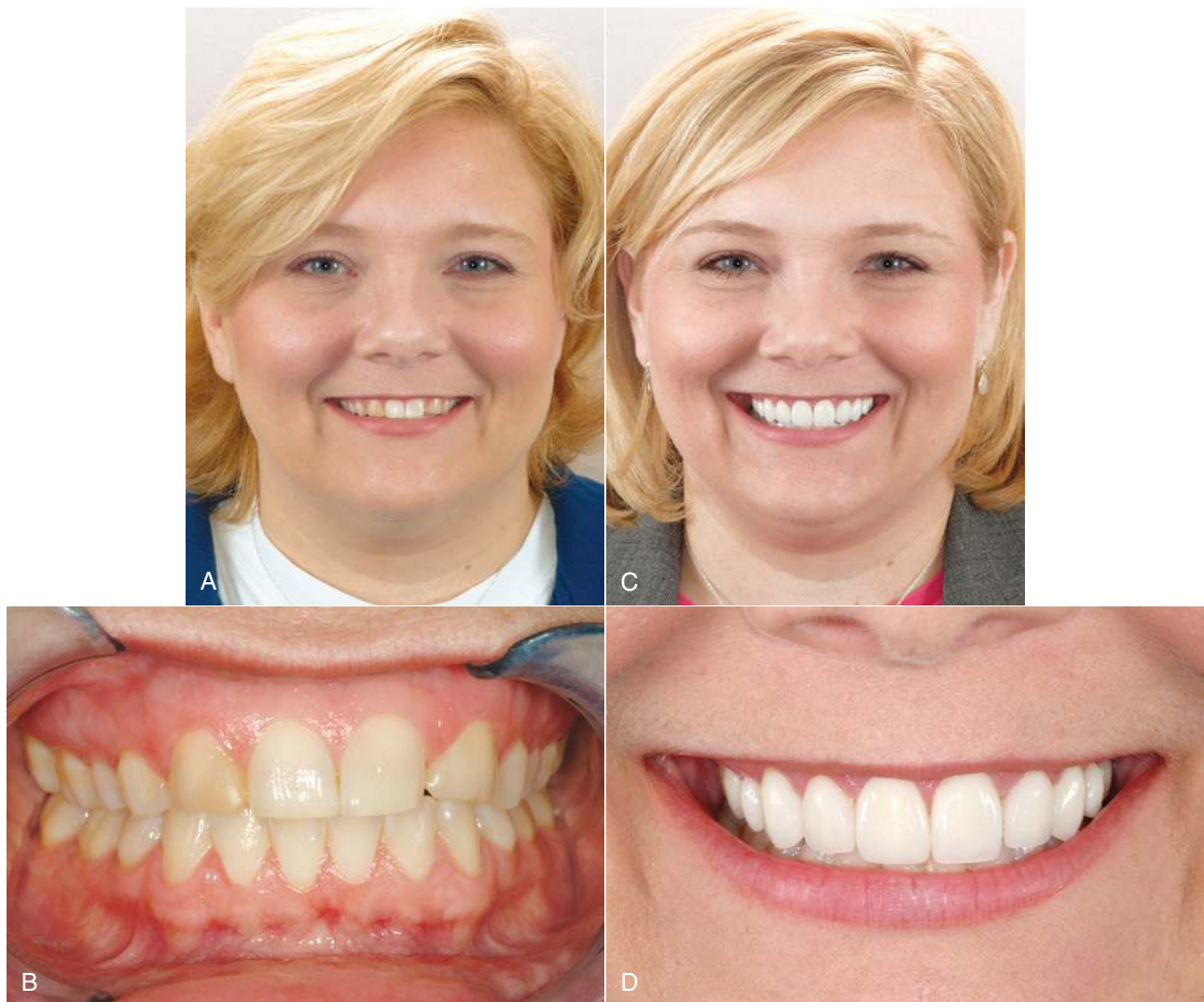would result in significant retraction of the central incisors. In that circumstance, encouraging the permanent canine to erupt into the lateral incisor position, so that alveolar bone is formed in the area of the missing tooth, and then moving the canine distally to open space is the best way to prepare for an eventual implant.<sup>12</sup> The implant should not be placed until vertical growth is essentially complete, in the late teens or early twenties, because late vertical growth will produce an apparent infra-occlusion of the crown on the implant (see [Chapter 19](#) for further discussion of this important point).

**Correcting Black Triangles.** Decreasing or eliminating spaces between teeth above the contact points, which are unsightly if they are not filled with an interdental papilla, can be accomplished most readily by removing enamel at the contact point so the teeth can be moved closer together (see [Fig. 6.32](#)). Moving the contact area apically eliminates much if not all the space. When this is done, however, care is required not to distort the proportional

relationships of the teeth to each other, and if possible the progression of connector heights (see later) should be maintained. Clinically, this means that if the central incisors are narrowed, it may be necessary also to slightly narrow the lateral incisors and move their contact area more apically to maintain a good dental appearance.

### Interaction Between Orthodontist and Restorative Dentist

When the teeth are small or if tooth color or appearance is to be improved by restorative dentistry, during orthodontic treatment it is necessary to position them so that the restorations will bring them to normal size and position. In modern practice, the restorations are either composite buildups or ceramic laminates, laminates being used particularly when it is desirable to change tooth color and shade in addition to the size of the crown ([Fig. 7.15](#)).

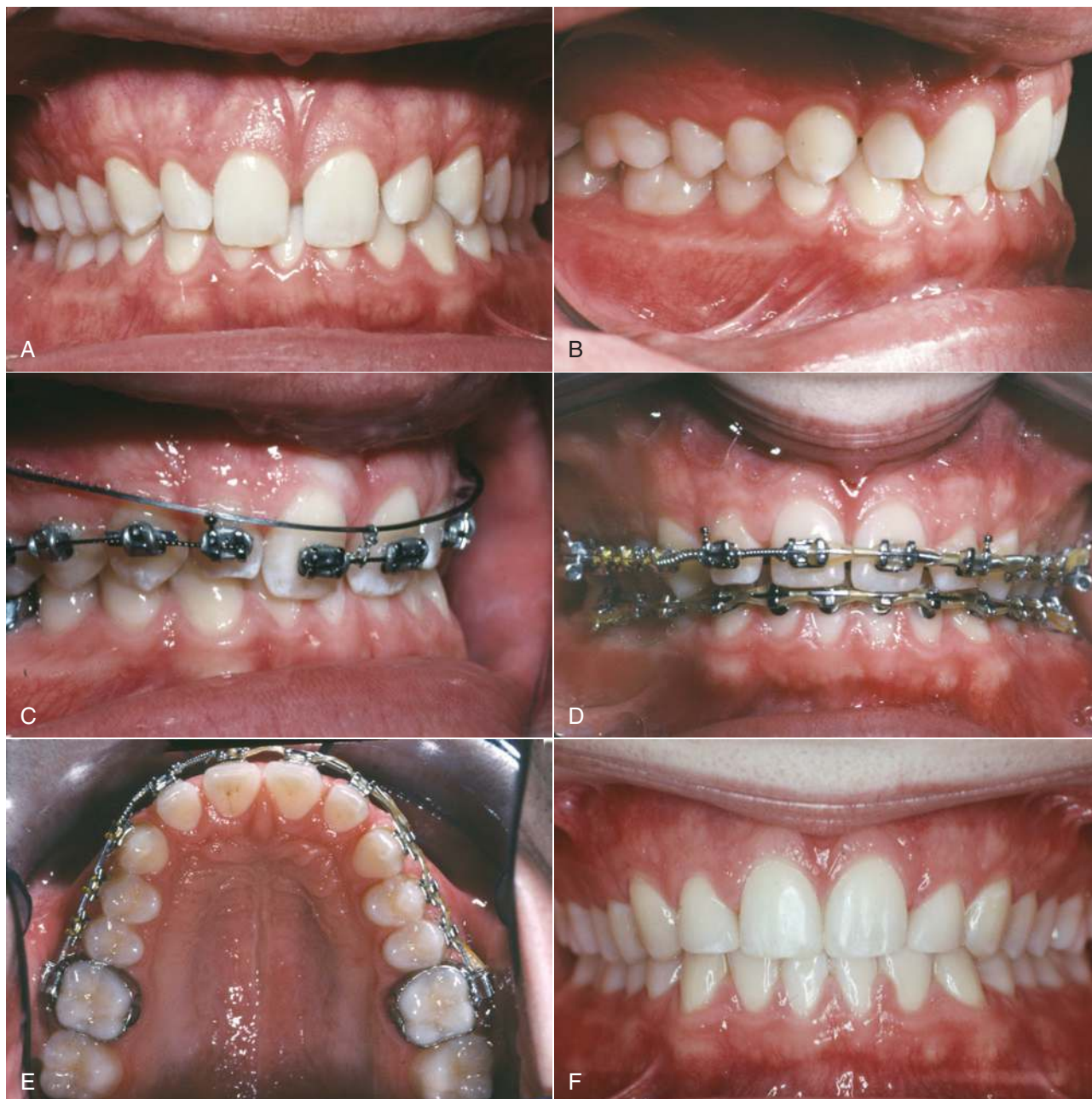


• **Fig. 7.15** Laminate veneers can be used to correct both the color and contour of teeth in canine substitution treatment. (A) and (B) Pretreatment and posttreatment appearance of teeth on full-face smile and close-up. Note the buildups on canines used after previous treatment to fill in the space of congenitally missing maxillary lateral incisors. (C) and (D) Appearance after space closure and laminate veneers for the maxillary anterior teeth. Among the things that can be corrected with laminate veneers is the length of the teeth so that there is proper display on smile as seen in the facial photographs.

There are two ways to manage the orthodontic-restorative interaction. The first is to carefully plan where the teeth are to be placed, place a vacuum-formed retainer immediately after the orthodontic appliance is removed that the patient wears full time, and send the patient to the restorative dentist for completion of the treatment. A new retainer is needed as soon as the restorations have been completed. This has two advantages: The restorative work can be scheduled at everyone's convenience after the orthodontic treatment is completed, and any gingival swelling related to the orthodontic treatment has time to resolve. It also has disadvantages: Excellent patient cooperation is required to maintain

the precise spacing needed for the best restorations, so the restorative work may be compromised by tooth movement, and the teeth are unesthetic until this is accomplished.

An alternative, which is most applicable when composite build-ups rather than laminates are planned, is for the orthodontist to deliberately provide slightly more space than the restorative dentist requires to bring the teeth to just the right size, remove the brackets from the teeth to be restored, send the patient immediately to the restorative dentist, replace the brackets the same day after the restorations are completed, and close any residual space before removing the orthodontic appliance (Fig. 7.16). This has the advantage of



• **Fig. 7.16** (A) and (B) This patient's complaint was the appearance of his upper incisors. The central incisors were elongated and quite upright; the lateral incisors were small, and the excess space was seen as a maxillary midline diastema. (C) Intrusion archwire to central incisors. (D) and (E) After intrusion and spacing of the incisors to allow buildups of the lateral incisors. (F) At completion of orthodontic and restorative treatment.



eliminating compromises in the restorative work, but the disadvantage that careful coordination of the appointments is required.

## Reshaping Gingival Contours: Applications of a Soft Tissue Laser

Appropriate display of the teeth requires removal of excessive gingiva covering the clinical crown, and is enhanced by correcting the gingival contours. Treatment of this type now can be carried out effectively with the use of a diode laser (see Fig. 7.24). A laser of this type, in comparison to the carbon dioxide (CO<sub>2</sub>) or erbium:yttrium-aluminium-garnet (Er:YAG) lasers also used now in dentistry, has two primary advantages: (1) It does not cut hard tissue, so there is no risk of damage to the teeth or alveolar bone if it is used for gingival contouring, and (2) it creates a “biologic dressing” because it coagulates, sterilizes, and seals the soft tissue as it is used. There is no bleeding, no other dressing is required, and there is no waiting period for healing.

Use of a soft tissue laser as part of finishing procedures is illustrated and discussed further in Chapter 17.

## Planning Comprehensive Orthodontic Treatment

### Steps in Planning Comprehensive Treatment

The focus of the rest of this chapter is on comprehensive treatment, in adolescence or later, when the permanent teeth are present at least for the latter part of the treatment period. Planning for mixed dentition treatment to prevent later problems or to keep existing problems from getting worse is covered in Chapter 11, and planning more complex dental treatment for a child who is likely to need later comprehensive treatment is discussed in Chapter 12. Skeletal growth modification treatments are addressed in Chapters 13 and 14.

At any stage of treatment, orthodontic diagnosis results in a comprehensive list of the patient's problems. Although any number of pathologic problems might be noted, if the five characteristics of malocclusion are used to structure the developmental problem list, there can be a maximum of five major problems. Most patients will not have that many. Of course, there can be several findings indicative of a problem with any of the characteristics, and as the problem list is developed, the findings can and should be grouped as subheadings under the appropriate characteristic. The classification scheme exists to make the treatment planning process work efficiently. Having too many overlapping findings appearing on the problem list only creates confusion.

The goal of treatment is to deal with the problems in a way that creates maximum benefit to the patient—not just to straighten the teeth. Use of a logical sequence of steps on the way from the problem list to the final plan, keeping this goal in mind, is strongly recommended. The sequence of steps is illustrated in Fig. 7.1. Let us now consider this sequence and the logic behind it as we develop the treatment plan for the patient whose diagnostic workup was illustrated in Chapter 6 (see Figs. 6.84 to 6.87). Her problem list (diagnosis) is repeated in Box 7.1.

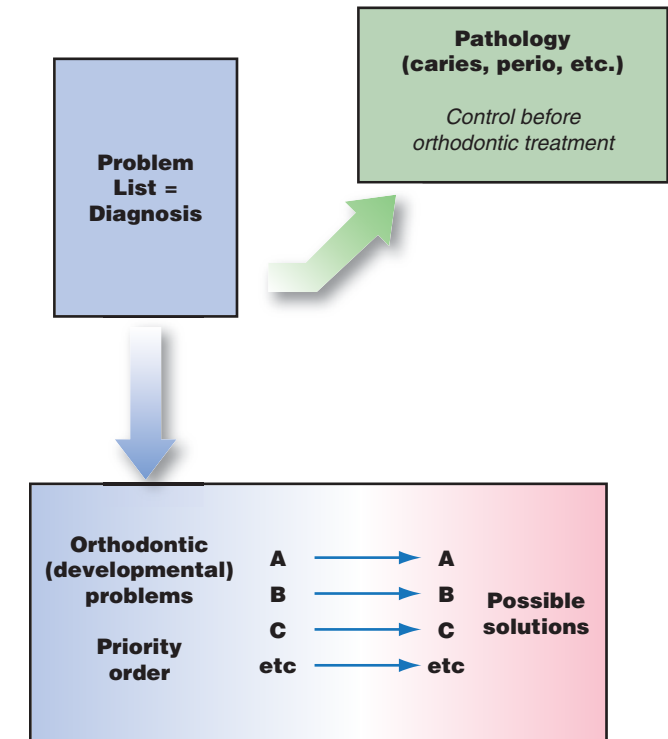
### Pathologic Versus Developmental Problems

An important principle is that a patient does not have to be in perfect health to have orthodontic treatment, but any problems related to disease and pathology must be under control (i.e., the

#### • BOX 7.1 Patient F.P.: Problem List (Diagnosis)

In the order they appeared in the evaluation sequence

- Mild gingivitis, mild gingival overgrowth
- Hypoplastic area maxillary left premolar
- Mandibular deficiency
- Maxillary incisors tipped lingually, short crowns
- Moderate maxillary incisor crowding
- Class II buccal segments, minimal overjet
- Deep bite, excessive eruption of mandibular incisors



• **Fig. 7.17** The last step in diagnostic evaluation of potential orthodontic patients is to separate pathologic from developmental problems; the first step in treatment planning is to consider the management of the pathologic problems. They must be brought under control before orthodontic treatment begins, not because they are necessarily more important, but because orthodontic treatment in the presence of active disease can accentuate the pathologic condition. After that, the first and most important step toward an orthodontic treatment plan is to put the orthodontic (developmental) problems in priority order, so that possible solutions to each problem can be considered from the perspective of what is most important for this patient.

progression of any acute or chronic conditions must be stopped). For this reason, pathologic problems must be addressed before treatment of orthodontic (developmental) problems can begin. Thus in a treatment sequence, orthodontic treatment must appear after control of systemic disease, periodontal disease, and caries.

The first step in treatment planning is to separate pathologic from developmental (orthodontic) problems (Fig. 7.17). Even when pathologic problems are mild, as one would expect them to be in the healthy adolescents who are the majority of orthodontic patients, they must not be overlooked in the treatment plan. For a typical patient of that type, the plan for the pathologic problems would include oral hygiene instruction and monitoring gingival health

during orthodontic treatment. Other items might be included for specific problems, as in our example patient (Box 7.2). For patients with more complex disease-related problems, the plan often is appropriate referral to another medical or dental clinician before orthodontic treatment begins.

Periodontal health is an important issue, especially for older patients, and interaction with a periodontist often is needed to plan and carry out appropriate orthodontic treatment. Two important points must be kept in mind: (1) orthodontic treatment in the presence of active periodontal disease is likely to accelerate the disease process, so periodontal control is essential before orthodontics begins; but (2) in the absence of active disease, even if significant bone loss has occurred previously, careful orthodontic treatment will not lead to further bone loss and can facilitate other types of dental treatment such as restorative dentistry, prosthodontics, and periodontal surgery.

### Setting Priorities for the Orthodontic Problem List

Putting the patient's orthodontic (developmental) problems in priority order (Fig. 7.18) is the most important single step in the entire treatment planning process. To maximize benefit to the patient, the most important problems must be identified, and the treatment plan must focus on what is most important for that particular patient. The patient's perception of his or her condition is important in setting these priorities.

It is always difficult for the clinician to avoid imposing his or her own feelings at this stage, and it is not totally inappropriate to reveal them; but ignoring the patient's chief complaint can lead to serious errors in planning treatment. For instance, consider the patient who complains of a protruding chin and who has a Class III malocclusion. If the clinician formulates the problem as Class III malocclusion and concentrates on bringing the teeth into correct occlusion while ignoring the chin, it is not likely that the patient will be happy with the treatment result. The plan did not deal with the patient's problem.

The doctor does not have to agree with the patient's initial thoughts as to what is most important. Indeed, often it is necessary to educate the patient about the nature of the problems. But the

#### • BOX 7.2 Patient F.P.: Pathologic Problems/Plan

- Mild gingivitis  
*Hygiene instruction*
- Hypoplastic area, upper left first premolar  
*Restore at end of orthodontic treatment*

importance of various problems must be discussed, and informed consent to treatment has not been obtained unless the patient agrees that the focus of the plan is what he or she wants. The prioritization for our example patient is shown in Box 7.3.

### Factors in Evaluating Treatment Possibilities

The next step in the planning process is to list the possibilities for treatment of each of the problems, beginning with the highest priority problem. At this stage, each problem is considered individually, and for the moment the possible solutions are examined as if this problem were the only one the patient had. Broad possibilities, not details of treatment procedures, are what is sought at this stage (Box 7.4). The more complex the total situation, the more important it is to be sure no possibilities are overlooked.

As we continue to develop the treatment plan for our illustrative patient, references to aspects of treatment that have not yet been presented in the text are inevitable. The first-time reader is urged to follow the logic rather than concentrate on details that will be discussed more fully in the following chapters.

#### Possible Solutions

First, let's consider the possible solutions to this patient's most important problem: the unattractive smile and appearance of the

#### • BOX 7.3 Patient F.P.: Prioritized Problem List

*Tentative: awaiting parent/patient interaction*

- Malaligned and unesthetic maxillary incisors
- Skeletal Class II, excess overjet—mandibular deficiency
- Anterior deep bite—excessive eruption of mandibular incisors

#### • BOX 7.4 Patient F.P.: Possible Solutions

Malaligned and unesthetic maxillary incisors:

- *Align, lingual root torque, reduce overjet and overbite*
- *Remove excess gingiva?*

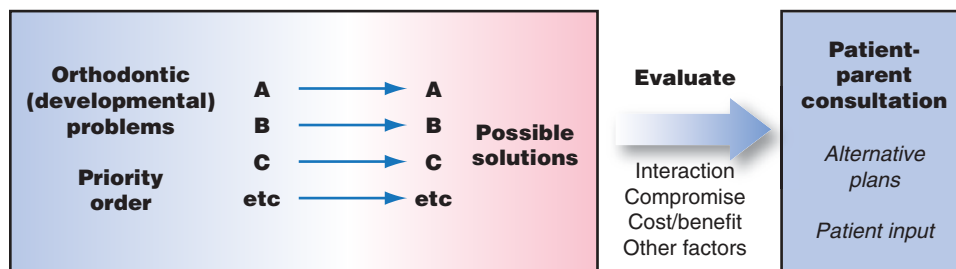
Skeletal Class II

Growth modification: Differential forward growth of mandible

- *Headgear?*
- *Herbst appliance?*
- *If unfavorable growth: Orthodontic camouflage? Orthognathic surgery?*

Anterior deep bite

- *Absolute intrusion: If needed, only for lower incisors*
- *Relative intrusion: Allow lower molar eruption as mandible grows vertically, prevent further lower incisor eruption*




• **Fig. 7.18** The possible solutions to the patient's prioritized problems must be evaluated from several important perspectives: interaction among the solutions, compromise in the sense of modifying treatment goals to best fit this patient, cost–benefit considerations, and other pertinent factors.

maxillary incisors. Correcting this will require alignment of the teeth, but proper anterior tooth relationships cannot be achieved until overjet is reduced and the deep bite is corrected—so the best solution to the first problem can be determined only after the impact of possible solutions to overjet and overbite have been considered.

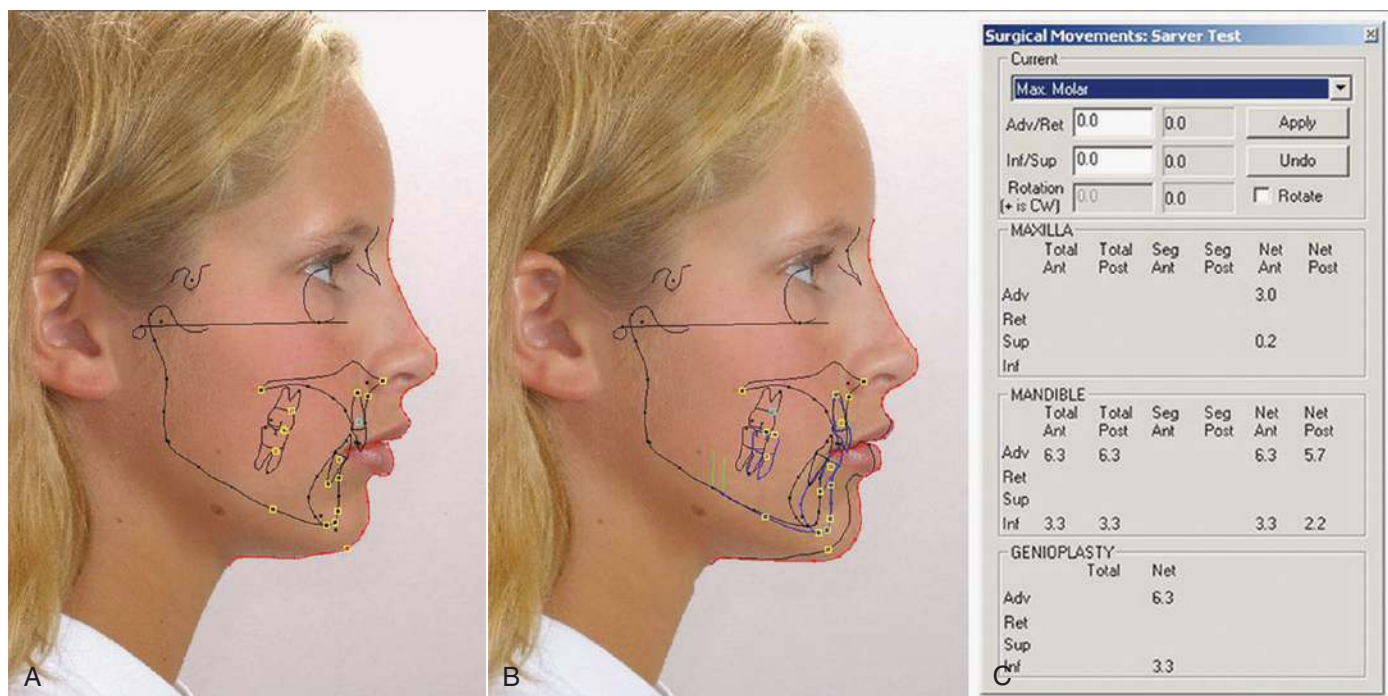
As we have noted, there are three ways that the Class II jaw relationship and overjet can be treated (Fig. 7.19): (1) differential forward growth of the mandible, which is ideal if it can be achieved; (2) orthodontic camouflage, retracting the maxillary incisors and proclining the mandibular incisors to make the teeth fit even though the jaws do not; or (3) orthognathic surgery to correct the jaw position. Because our patient has not yet reached the adolescent growth spurt, growth modification would be the primary possibility,

with camouflage and surgery as possibilities if growth modification does not succeed.

Class II growth modification can be done in several ways, which are discussed in detail in Chapter 14. For this patient, differential forward growth of the mandible while maintaining vertical control of the maxillary posterior teeth and bringing the maxillary incisors downward and facially would increase the display of the maxillary incisors and the prominence of the chin (Fig. 7.20). The two most effective ways to do that would be high-pull headgear or a fixed functional appliance such as the Herbst appliance. The functional appliance would be more likely to move the lower incisors forward, which is undesirable for this patient, so headgear would be preferred if she would agree to wear it.



• **Fig. 7.19** The possibilities for correction of a skeletal Class II problem include (A) differential forward growth of the mandible, which is the ideal method if the patient has not yet gone through the adolescent growth spurt; (B) camouflage by retraction of the maxillary incisors, which can be quite successful if the other facial features allow it; and (C) orthognathic surgery to move the mandible forward to a normal relationship. In the absence of growth, camouflage and surgery are the only possibilities.



• **Fig. 7.20** Computer predictions of growing patients often are inaccurate because of the difficulty of predicting growth but nevertheless can be used to help the patient and parents understand what is expected to occur. (A) Patient F.P., cephalometric tracing merged with facial profile image, using the Orthotrac imaging system (Carestream Dental LLC, Atlanta, GA). (B) Prediction of treatment with forward growth of the mandible while the maxilla is held in place and the upper incisors are tipped facially and elongated. (C) Computer screen showing the measured amount of change. An adolescent is more likely to cooperate with treatment if he or she understands exactly what is desired and what the benefit would be, and images of changes in your own face are easier to understand than word descriptions, pictures of a different patient, or other generalized educational materials.

There also are three ways to correct the anterior overbite (Fig. 7.21): (1) absolute intrusion of the upper and lower incisors, moving their root apices closer to the nose and lower border of the mandible, respectively; (2) relative intrusion of the incisors, keeping them where they are while the mandible grows and the posterior teeth erupt; and (3) extrusion of the posterior teeth, which would rotate the mandible downward and backward. Relative intrusion of incisors and extrusion of posterior teeth are identical in terms of the tooth movement. The difference is whether vertical growth of the ramus compensates for the increase in molar height (i.e., whether the mandibular plane angle is maintained [relative intrusion] or increases as the mandible rotates downward and backward [extrusion]).

In an immature 12-year-old like our example patient, vertical growth can be expected, so relative intrusion would be the preferred approach. It is significant that in the absence of growth, leveling the arches by extrusion of posterior teeth would cause the mandible to rotate downward and backward, accentuating a Class II tendency (Fig. 7.22), which would be highly undesirable for this patient. Controlling the vertical position of the maxillary posterior teeth so that the vertical space between the jaws created by growth could be used largely for elongation of the lower molars would facilitate leveling by relative intrusion. Thus high-pull headgear that appears to be the best approach to a skeletal Class II problem also would facilitate correction of the deep bite, if used along with a fixed appliance to level the lower arch that would elongate the mandibular molars.

Often, the same problem list prioritized differently results in a different treatment plan. For this patient, if the Class II malocclusion

was considered the most important problem and the relationship of the upper incisors to the lip and gingiva was not considered important, Class II camouflage might be chosen as the most efficient approach to treatment. Class II elastics, with or without premolar extraction, would correct the malocclusion but might harm rather than enhance the dental and facial appearance.

The objective at this stage of treatment planning is to be sure that no reasonable possibilities are overlooked. It is easy to develop the mindset that “For this problem, we always ....” Sometimes an alternative approach would be better but is overlooked unless a conscious effort is made to keep an open mind. In this patient’s case, if obtaining proper soft tissue relationships to the upper incisors were not a priority in treatment, she almost surely would not have normal incisor display after treatment, and an optimal result would not be achieved.

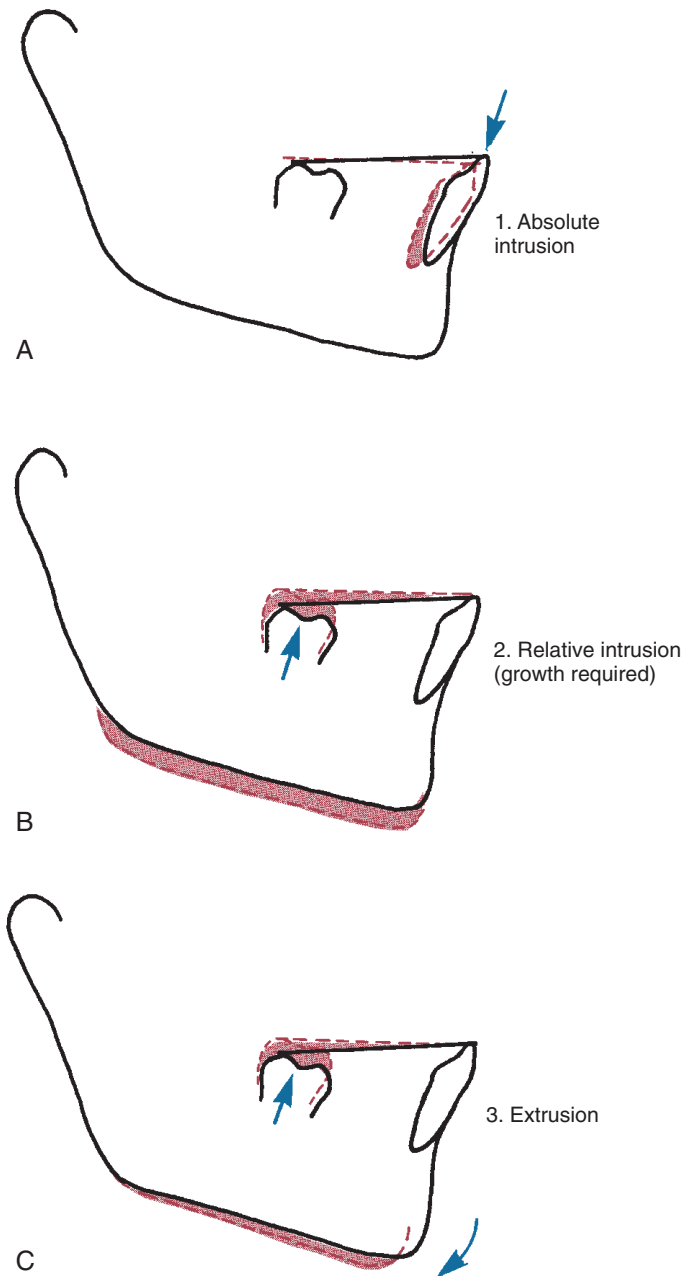
Four additional factors that are pertinent in evaluating treatment possibilities now must be considered (Fig. 7.23).

### Interaction Among Possible Solutions

The interaction among possible solutions to a patient’s various problems is much easier to see when the possibilities are listed as previously described. As in the case of the girl in the previous section, it will be clear for nearly every patient that some solutions to a high-priority problem would also solve other problems, but others would not and might even make other things worse.

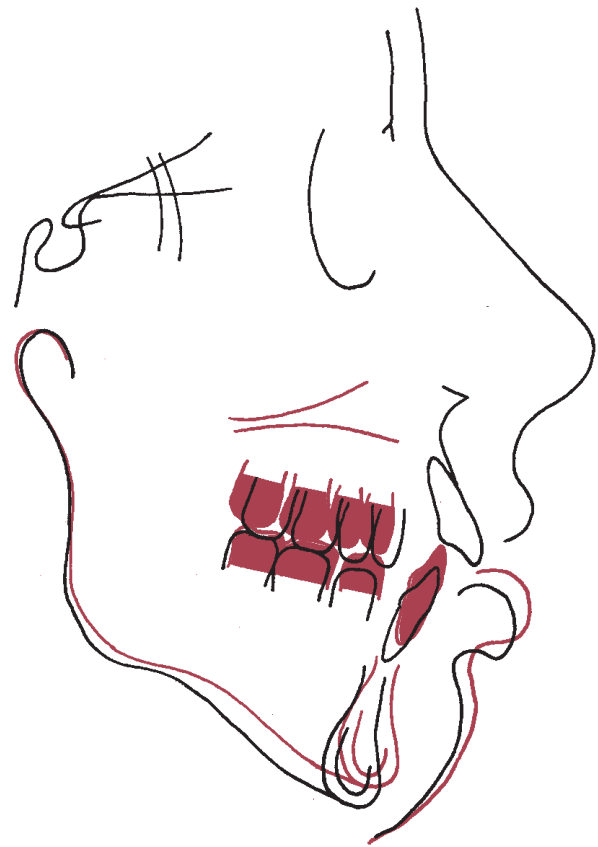
Consider the opposite situation to our example patient, a patient with an anterior open bite. Often, this problem is due not to decreased eruption of incisors but to excessive eruption of posterior





• **Fig. 7.21** There are three possible ways to level out a lower arch with an excessive curve of Spee: 1, absolute intrusion (A); 2, relative intrusion (B), achieved by preventing eruption of the incisors while growth provides vertical space into which the posterior teeth erupt; and 3, elongation of posterior teeth (C), which causes the mandible to rotate downward in the absence of growth. Note that the difference between 2 and 3 is whether the mandible rotates downward and backward, which is determined by whether the mandibular ramus grows longer while the tooth movement is occurring.

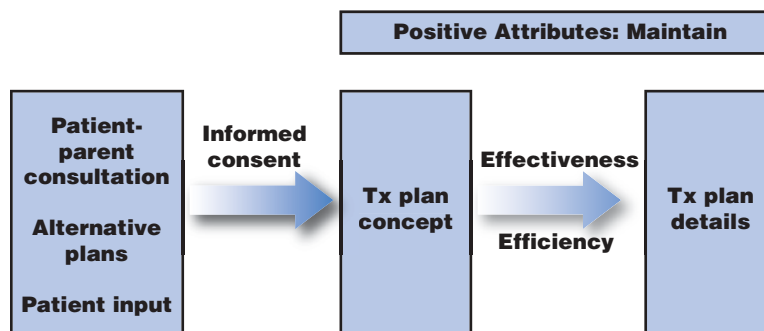
teeth and downward-backward rotation of the mandible (see Fig. 6.15). If so, using vertical elastics to elongate the anterior teeth is not a good solution. Treatment should be aimed at depressing the elongated posterior teeth, or preventing them from erupting further while everything else grows (relative intrusion). This would allow the mandible to rotate upward, bringing the incisor teeth together.



• **Fig. 7.22** There is a strong interaction between the vertical position of the maxilla and both the anteroposterior and vertical positions of the mandible, because the mandible rotates backward as it moves down and forward as it moves up unless vertical growth of the ramus matches downward movement of the maxillary posterior teeth. This superimposition (red = initial, black = progress) shows the effect on chin position of excessive vertical growth of the maxilla and excessive eruption of the maxillary posterior teeth that was not matched by vertical growth of the ramus. This is the classic long-face pattern of growth that makes the Class II jaw relationship worse, but extrusion of maxillary posterior teeth during orthodontic treatment does the same thing. Superior repositioning of the maxilla and/or intrusion of maxillary posterior teeth (see Chapters 19 and 20) would be the key to both reducing face height and correcting the Class II relationship.

But if the mandible rotates upward, it also will come forward—which would be good if the patient had a skeletal Class II malocclusion to begin with but bad if the malocclusion was Class I or Class III.

Another important interaction, which also came into play in our illustrative case (Box 7.5), is the relationship between incisor prominence and facial appearance, especially on smile. If the teeth are crowded, is expansion of the arches indicated to gain the space needed to align them? The answer depends on the relationship of the teeth to their soft tissue environment. In developing the treatment plan, it is necessary to plan the final position of the incisors and then determine what is needed to put them in the desired position. Quantifying the extent of the crowding does not tell you what to do about it. You have to look at the effect of the possible treatments on the patient's appearance.



• **Fig. 7.23** At the conference with the patient (and parents if the patient is a minor) at which alternative possible plans are discussed and patient input is sought, the outcome should be informed consent to a treatment plan concept. The doctor's role at that point is to determine the treatment plan details, considering effectiveness and efficiency of the various methods to achieve the desired outcome.

#### • BOX 7.5 Patient F.P.: Interaction of Treatment Possibilities

- Repositioning the maxillary incisors for better appearance will increase overjet and require greater use of the mechanics for Class II correction.
- Extrusive mechanics to correct the deep bite may lead to a more vertical growth direction for the mandible, compromising the Class II correction.
- Correcting the deep bite with any intrusion of the maxillary incisors would compromise the smile arc, which is excellent now.

#### Other Considerations in Planning Treatment

- Patient is immature; growth modification will be more efficient if timed with growth spurt.
- Rotating the maxilla down anteriorly will improve incisor display and smile appearance.

### Compromise

In patients with many problems, it may not be possible to solve them all. This type of compromise has nothing to do with the clinician's skill. In some cases, no plan of treatment will solve all of the patient's problems. Then, careful setting of priorities from the problem list is particularly important.

In a broad sense, the major goals of orthodontic treatment are ideal occlusion, ideal facial esthetics, and ideal stability of result. Often it is impossible to maximize all three. In fact, attempts to achieve an absolutely ideal dental occlusion, especially if that prohibits extractions, can diminish both facial esthetics and stability after treatment. In the same way, efforts to achieve the most stable result after orthodontic treatment may result in less than optimal occlusion and facial esthetics, and positioning the teeth to produce ideal facial esthetics may detract from occlusion and stability.

One way to avoid having to face compromises of this type, of course, is to emphasize one of the goals at the expense of the others. In the early 20th century, Edward Angle, the father of modern orthodontics, solved this problem by focusing solely on the occlusion and declaring that facial esthetics and stability would take care of themselves. Unfortunately, they did not. As we have noted, echoes of Angle's position are encountered occasionally even now, particularly among dentists strongly committed to avoiding extraction at all costs.

As important as dental occlusion is, it is not the most important consideration for all patients. Sometimes, ideal occlusion must be

compromised, by extraction or other changes within the dental arches, to gain acceptable esthetics and stability. Adjustments in the other goals also may be needed. It is quite possible that placing the teeth for optimal facial esthetics may require permanent retention because they are not stable in that position, or, alternatively, that placing the teeth in a position of maximum stability is likely to make the facial appearance worse, not better.

If various elements of a treatment plan are incompatible, benefit to the patient is greatest if any necessary compromises are made so that the patient understands and agrees that his or her most important problems are solved, while less important problems are deferred or left untreated. If the major goals of orthodontic treatment cannot be reached, those of greatest importance to that patient should be favored. Doing this successfully requires both judgment and thought on the part of the clinician and input from the patient and parent. For our example patient, would better stability of the result if the incisors were retracted to correct the excess overjet be worth the negative impact on her facial appearance? Given her chief complaint, almost certainly not.

### Analysis of Benefit Versus Cost and Risk

Practical considerations related to the difficulty of various treatment procedures compared with the benefit to be gained from them also must be considered in evaluating treatment possibilities. The difficulty should be considered in both risk and cost to the patient, with cost calculated not only in money but also in cooperation, discomfort, aggravation, time, and other factors that can be collectively labeled as the "burden of treatment" (see Fig. 7.18). These must be contrasted to the probable benefit from that procedure.

For instance, for a patient with anterior open bite, jaw surgery to decrease face height has greater cost and risk than elastics to elongate the incisors or occlusal reduction of the posterior teeth, which are two other possibilities for correcting the bite relationship. But if the simpler and less risky procedures would provide little real benefit to the patient, but jaw surgery would provide considerable benefit, the cost- and risk-benefit analyses might still favor the more difficult procedure. "Is it worth it?" is a question that must be answered not only from the point of view of what is involved, but also in terms of the benefit to the patient.

### Special Considerations

At this stage, it is important to consider any pertinent special considerations about the individual patient. Should the treatment time be minimized because of possible exacerbation of periodontal

disease? Should treatment options be left open as long as possible because of uncertainty of the pattern of growth? Should visible orthodontic appliances be avoided because of the patient's vanity, even if it makes treatment more difficult? Such questions must be addressed from the perspective of the individual patient. Rational answers can be obtained only when the treatment possibilities and other important factors influencing the treatment plan have been considered.

For our example patient, interactions, thoughts about necessary compromises, and other considerations (which in her case are quite minor) are shown in [Box 7.5](#). The information now has been assembled. Only at this point are treatment possibilities ready to be discussed with the patient and parents in order to finalize the treatment plan ([Box 7.6](#)).

### Informed Consent: Paternalism Versus Autonomy

Not so long ago, it was taken for granted that the doctor should analyze the patient's situation and should prescribe what he or she determined to be the best treatment—with little or no regard for whether that treatment was what the patient desired. This is best described as a paternalistic approach to patient care: the doctor, as a father figure, knows best and makes the decisions.

At present, this approach is not defensible, ethically or legally. From an ethical perspective, patients have the right to determine what is done to them in treatment, and increasingly they demand that right. It is unethical not to inform patients of the alternatives, including the likely outcome of no treatment, that are possible in their case.

The modern doctrine of informed consent has made the ethical imperative a legal one as well. Legally, the doctor now is liable for problems arising from failure to fully inform the patient about the treatment that is to be performed. Informed consent is not obtained from just a discussion of the risks of treatment. Patients must be told what their problems are, what the treatment alternatives are, and what the possible outcomes of treatment or no treatment are likely to be, in a way they can understand. Simply providing a brochure, video, or written consent form that uses complex language often does not lead the patient to really comprehend the treatment and its consequences.

This really is a matter of health literacy—being able to read, understand, and act on health information in written form. Those who did not speak English before entering school, those who had less education, and those who get their health information primarily from radio and television are most likely to not understand informed consent discussions.<sup>13</sup> For them, understanding the risks and limitations of treatment quite possibly is better with a formal audiovisual presentation than even an extensive discussion.<sup>14</sup> Recent studies have demonstrated that patient recall of information presented to them is enhanced by putting the information in layperson's terminology and by using visual presentation (images on a computer screen) instead of just words.<sup>15</sup>

The problem-oriented method of diagnosis and treatment planning lends itself very well to the patient involvement that modern treatment planning requires. A discussion with the patient and parents should begin with an outline of the patient's problems, and patient involvement begins with the prioritization of the problem list. Perhaps the doctor's single most important question in obtaining informed consent is, "Your most important problem, as I see it, is .... Do you agree?" When problems related to informed consent for orthodontic treatment arise, almost always they result

#### • BOX 7.6 Patient F.P.: Outline of Case Presentation

**Goal:** To appropriately involve the patient and parents in the treatment decisions, which is necessary to obtain informed consent. The points to be discussed (in this sequence) are as follows:

##### General and Oral Health

- Three minor problems with oral health:
  - *Mild gingivitis: Better oral hygiene is required to prevent damage to the teeth during orthodontic treatment.*
  - *Hypoplastic area in first premolar: May require restoration in the future, no treatment needed now.*
  - *Overgrowth of maxillary gingiva: May require surgical removal at the end of orthodontic treatment if it does not resolve spontaneously.*

##### Orthodontic Problems

- Appearance of upper incisors: Tipped back and not aligned properly, which partially conceals their relative protrusion.
- Lower jaw has not grown forward properly, which is the reason the upper incisors appear to protrude.
- Overbite: Lower front teeth have erupted too much, into the palate.

##### Most Important Problem

- Upper incisor protrusion and crowding (do you agree?)
  - *This is largely due to lower jaw that has not grown as much as the upper jaw.*

##### Plan to Correct the Most Important Problem

- Restrain downward and forward growth of the upper jaw during the adolescent growth spurt to maxilla so the mandible can catch up.
  - *Requires favorable growth and cooperation.*

##### Correction of Other Problems

- Alignment of teeth and correction of bite
  - *Requires braces on all the teeth.*
- Overgrowth of gums
  - *May require surgery for correction later.*

##### Benefits From Treatment

- Improved facial and dental appearance
  - *For an adult patient, this is when to show computer image predictions.*
- More normal jaw movements and incisor function

##### Risks of Treatment

- Discomfort after appliance adjustment
- Decalcification if hygiene is inadequate
- Root resorption, especially maxillary incisors
- Any other pertinent items
  - *A signed form acknowledging this discussion is strongly recommended.*

##### Treatment Schedule, Costs, and So On

- Included with the presentation of the final treatment plan (see [Box 7.7](#)).
- Schedule and costs will vary in individual practices.

from treatment that failed to address what was most important to the patient, or from treatment that focused on what was not an important problem to the patient.

The problem-oriented method requires examining the possible solutions to the patient's problems, starting with the most important one. This is exactly the way in which a discussion with the patient and parents is structured most effectively (see [Box 7.6](#)). Interactions, unavoidable compromises, and practical considerations not only must be considered by the doctor, they must be shared with the

patient as the treatment plan is developed. Under most circumstances, there are advantages and disadvantages to the possible treatment approaches. The doctor's role is to clarify this to the best of his or her ability, involving the patient in the final decision as to the treatment approach that will be used.

From a practical perspective, involving the patient and parents in decisions about treatment has important advantages. It places the responsibility where it belongs: on a patient who has been led to understand the uncertainties involved. The problems, after all, belong to the patient, not the doctor. For both adults and children, a patient who "owns" the problems and recognizes that this is the case is more likely to be cooperative and oriented toward helping with treatment than one who takes the attitude that it is all up to the doctor.<sup>16</sup>

Several specific situations in orthodontics particularly require interaction between the doctor and the patient and parent in choosing the final treatment plan. Every patient should have a discussion regarding the most frequent things that are likely to occur with patients: pain and discomfort and how to address it; root resorption (especially of incisors and first molars) and the options; the possible damage to the teeth from inadequate hygiene with resulting white spot lesions; gingival inflammation, infection and deterioration also due to inadequate tooth cleaning; and the need to have posttreatment retention appliances. Then it is necessary to have discussions about other issues unique to that patient—for instance, missing teeth, impacted teeth, or the need for temporary anchorage devices (TADs). For many patients an issue is arch expansion versus extraction in solving crowding problems (discussed earlier). A second frequent problem requiring input from the patient is whether to begin treatment for a skeletal problem before adolescence or wait until the adolescent growth spurt. In this situation, two aspects must be discussed: the efficacy of beginning treatment early versus waiting for adolescence, and if early treatment is chosen, the mode of treatment.

The patient's desire for treatment and potential cooperation also must be taken into account when treatment timing is considered. For patients with Class II problems, there is little reason to proceed with headgear or functional appliance treatment for a child who has no intention of wearing the device. Treatment results with the two methods are not precisely the same but are more similar than different, and if the patient would wear one but not the other, it would be wise to select the one he or she would prefer. For our example patient, her level of sexual maturation indicates that she is approaching the ideal time for treatment, and headgear is the preferred approach, but the patient and parent need to understand why these are the recommendations and what alternatives exist. That also is true for other types of jaw discrepancies.

When a severe skeletal problem exists, a third frequent issue for discussion with the patient and parents is whether orthodontic treatment alone would produce an acceptable result, or whether orthognathic surgery should be selected. Sometimes this difficult decision revolves around jaw function and stability. In most instances, however, it is primarily an esthetic decision. The facial appearance is likely to be better if the jaw relationship is corrected. Is that improvement worth the additional risk, cost, and morbidity of surgery? In the final analysis, only the patient and parents can—or should—make that decision. In decisions such as surgery versus orthodontic camouflage and whether to expand the dental arches or extract, a picture is worth a thousand words (see Fig. 7.20).

Sometimes, involving patients in treatment planning discussions is interpreted as allowing the patient and parent to make all the

decisions. Clearly, this is not the case. It is the doctor's responsibility to explain the options to the patient and parents and to negotiate with them the final treatment plan. It is not the doctor's responsibility to do anything the patient wants. Just as any patient has the right to refuse to accept treatment, the doctor has the right to refuse to carry out treatment that he or she considers not in the patient's best interest. At one time, the doctor decided what was to be done and that was that. Now, establishing the concept of the final treatment plan is and must be an interactive process between the doctor and the patient.

In our example case, the patient and her parents understood the importance of correcting the Class II malocclusion and deep bite if a better facial appearance was to be achieved, accepted the suggestion that headgear during the adolescent growth spurt would be the best approach, and acknowledged that a change in the treatment plan to include extraction or even orthognathic surgery might be needed if the patient did not respond well to the more conservative initial treatment plan. They also reviewed the anticipated risks of treatment specific to her case, the primary concern being cooperation and the consequences of a lack of it. The result was both informed consent in the broad (and correct) sense and approval of the treatment plan concept (Box 7.7).

## The Detailed Plan: Specifying the Treatment Procedures

Note that for this patient, the conceptual plan leads directly to the therapy plan, which usually is the case. For any patient, the selected treatment procedures must meet two criteria: *effectiveness* in producing the desired result and *efficiency* in doing so without wasting either doctor or patient time. Progress and completion of this case are shown in Figs. 7.24 to 7.28.

For a relatively simple treatment plan, the associated treatment procedures are also reasonably simple or at least straightforward. Nevertheless, choices must be made and clearly specified in the treatment plan. For example, if the plan is to expand a narrow maxillary arch, it would be possible to do this with an expansion lingual arch, an expansion labial arch, or a banded or bonded maxillary palatal expander. The treatment plan must specify which,

### • BOX 7.7 Patient F.P.: Final Treatment Plan

#### Treatment Concept

- During adolescent growth, headgear to correct skeletal Class II, reduce overjet.
- Align maxillary incisors and correct their inclination without increasing overjet.
- Correct anterior deep bite by controlling lower incisor eruption as vertical growth occurs.
- Adjunctive gingival surgery if needed.
- Observe asymmetry to be sure it is not getting worse.

#### Treatment Details

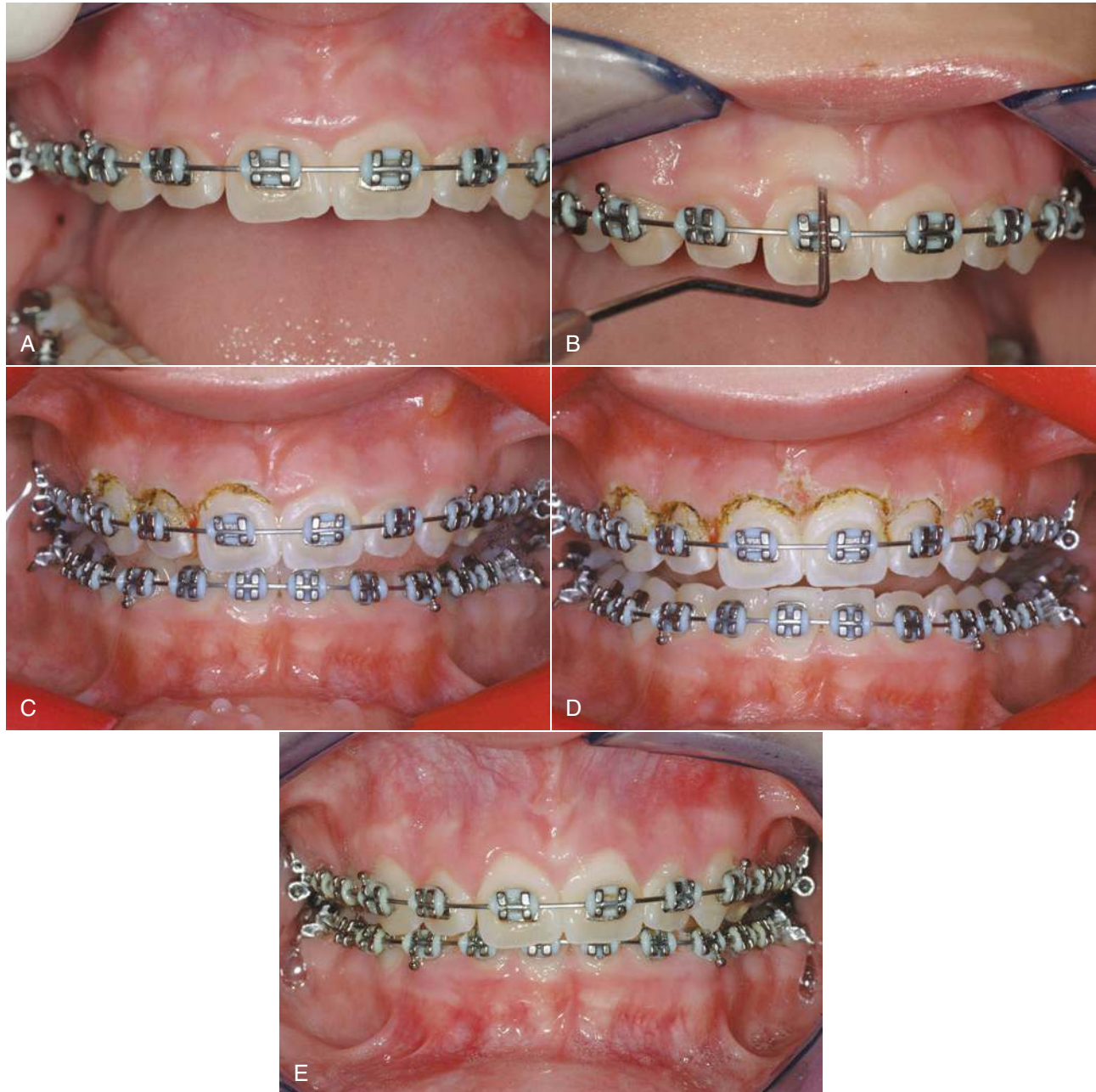- Delay start of treatment until level of maturation indicates onset of adolescent growth.
- High-pull headgear.
- Level mandibular arch with reverse curve archwires.
- Torque to maxillary incisors.
- Class II elastics as needed.
- Gingival surgery, if needed, before appliances are removed.



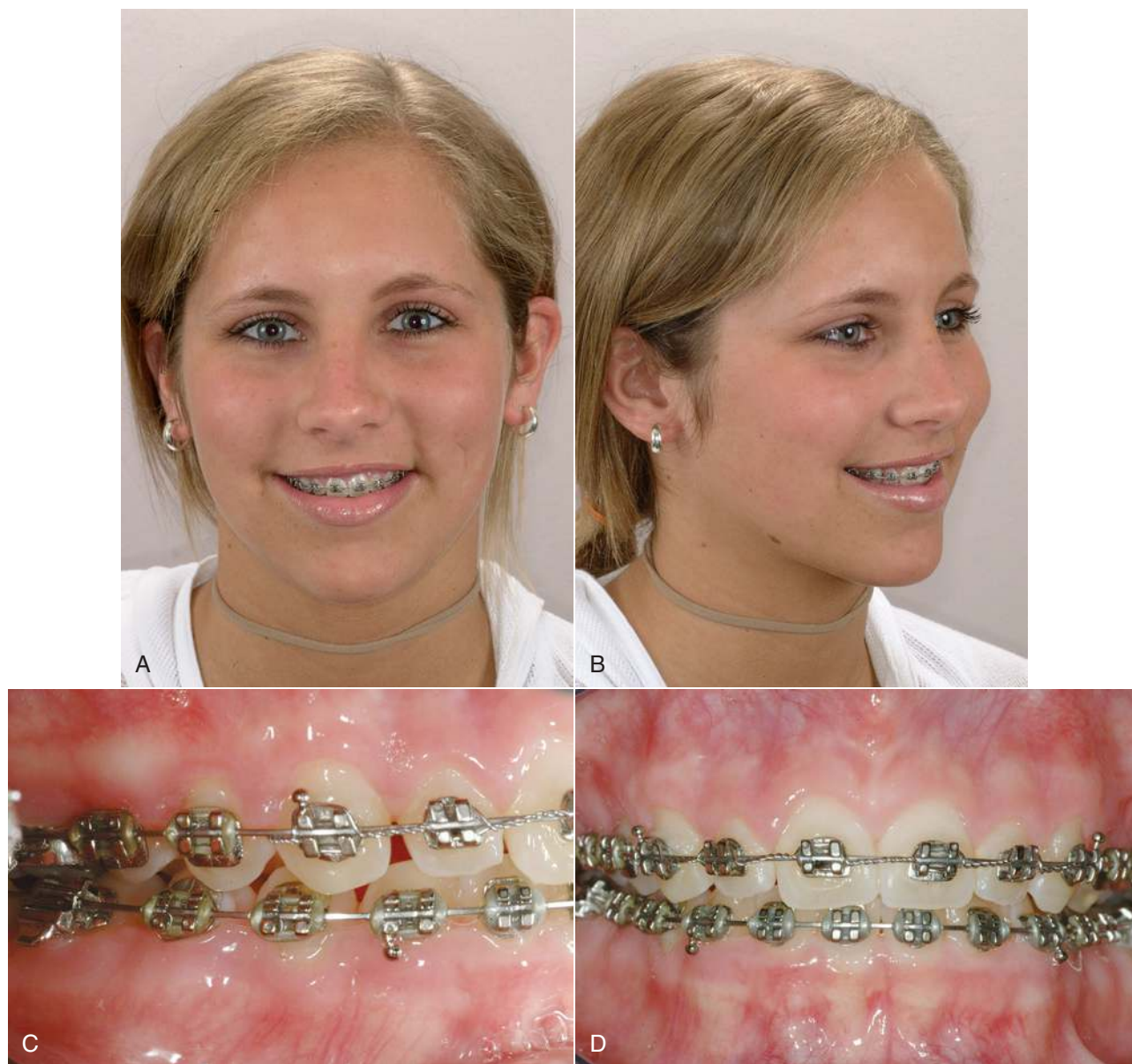
and the effectiveness and efficiency of the various possibilities must be considered. There is a time and a place for everything, and this last step is the place for the practical considerations of which treatment method and what orthodontic therapy to use.

The most serious errors in orthodontic treatment planning are those that result from first thinking of which appliance to use,

not what the appliance is supposed to accomplish. The treatment mechanics should not be allowed to determine the treatment result. It is an error to establish the treatment mechanics before establishing the broader goal of treatment. The treatment procedures should be manipulated to produce the desired result, not the other way around.

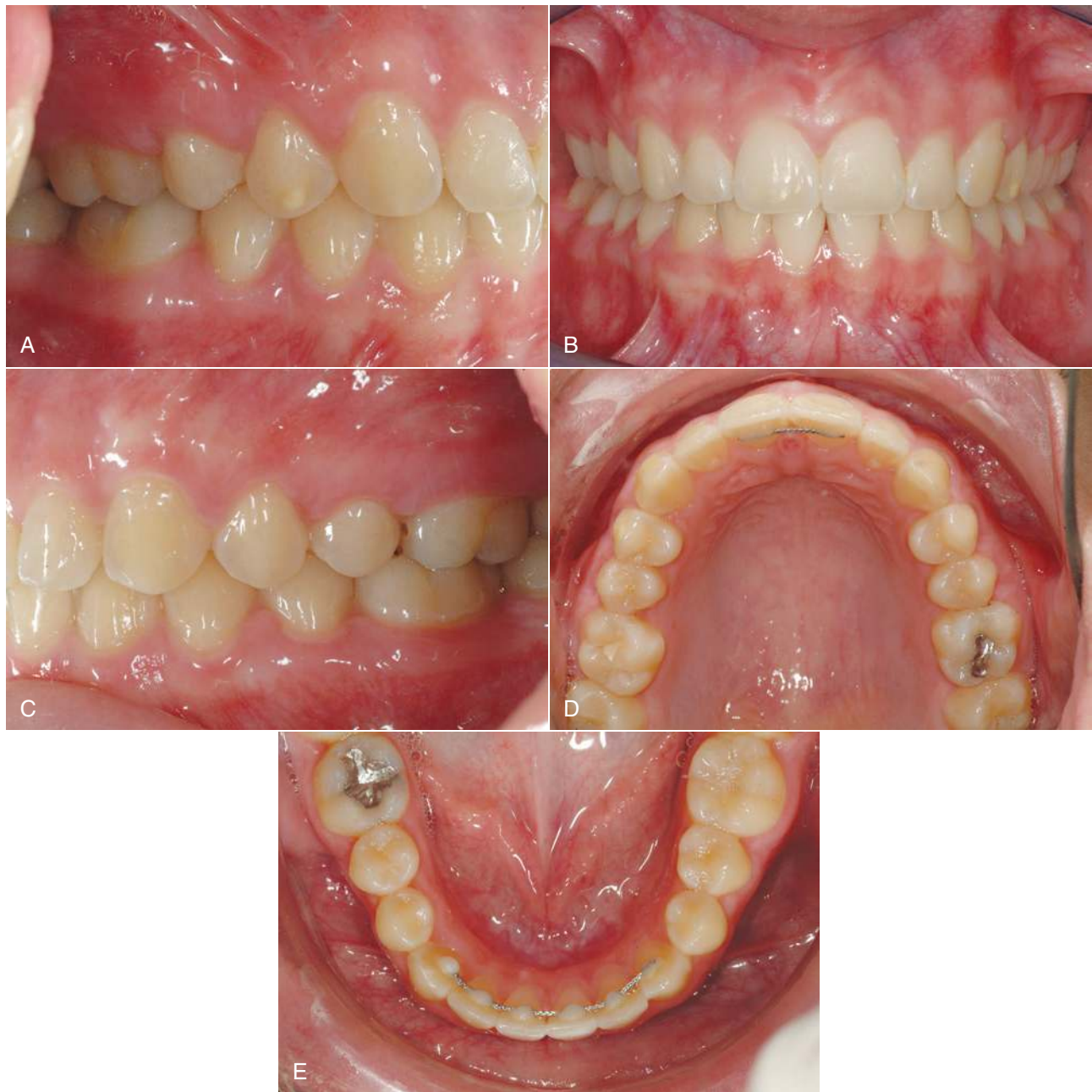

• **Fig. 7.24** For patient F.P., whose diagnostic workup is illustrated in [Figs. 6.84 to 6.87](#), treatment was deferred until she was entering her adolescent growth spurt. A fixed appliance was placed at age 12-5, and high-pull headgear was started at age 12-10. Dentally and skeletally, she responded well to treatment, but the gingival overgrowth of the maxillary incisors worsened rather than improved (A). A diode laser now offers a painless and efficient way to manage problems of this type, and she was scheduled for gingival recontouring at age 13-11. A periodontal probe was used to establish the depth of the gingival sulcus (B), and the laser was used to recontour the tissue (C, one side done; D, gingival recontouring completed). Because the tissue is ablated (vaporized) and the heat of the laser seals the ablation site, no bleeding occurs and no periodontal dressing is needed. Healing occurs within a few days. (E) The greatly improved tissue contours 4 weeks later.

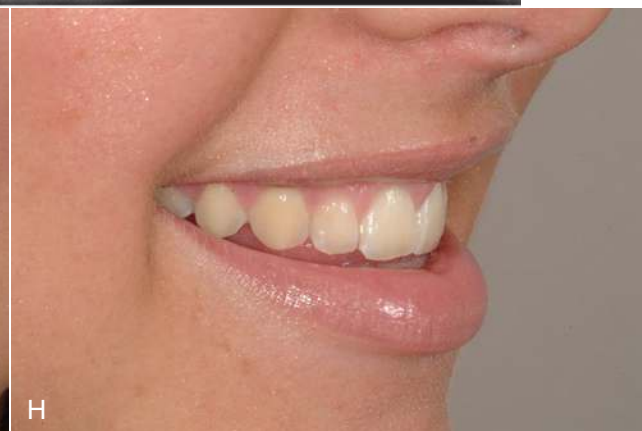
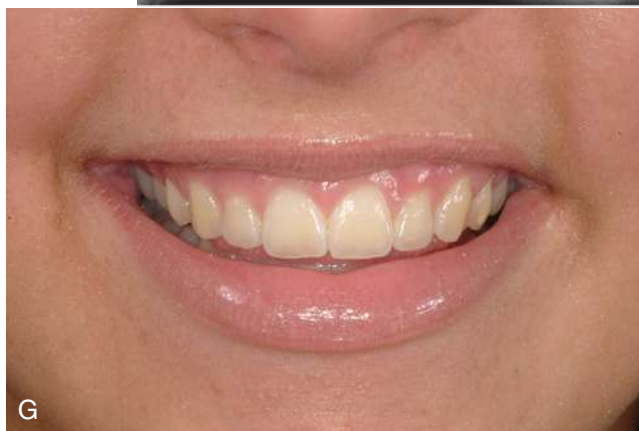
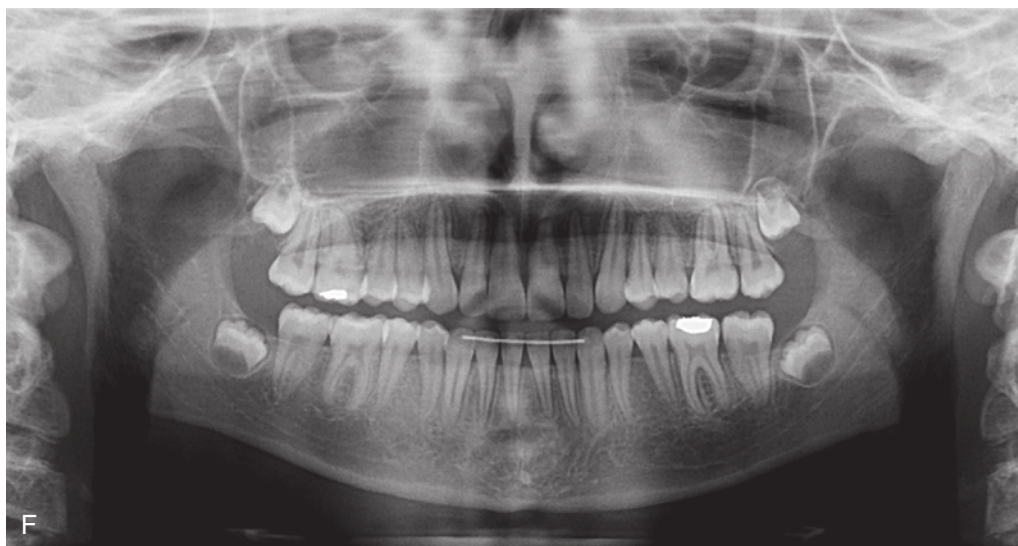• **Fig. 7.25** For patient F.P., fixed appliance treatment and high-pull headgear were continued following the gingival surgery, with an effort to elongate the maxillary incisors for better display on smile while maintaining the overbite correction. (A) and (B) Progress records at age 14-5 showed good incisor display; and (C) and (D) a nearly corrected malocclusion.





• **Fig. 7.26** Patient F.P. The orthodontic appliance was removed at age 14-9, 23 months after treatment began. The intraoral views and panoramic radiograph (A to F) show excellent alignment and occlusion, with normal gingival contours. Note (D) the bonded maxillary retainer to maintain the rotation correction and space closure for the maxillary central incisors and (E) the bonded canine-to-canine retainer for the lower arch. In the close-up smile images (G and H), note the consonant smile arc and improved maxillary incisor display. *Continued*

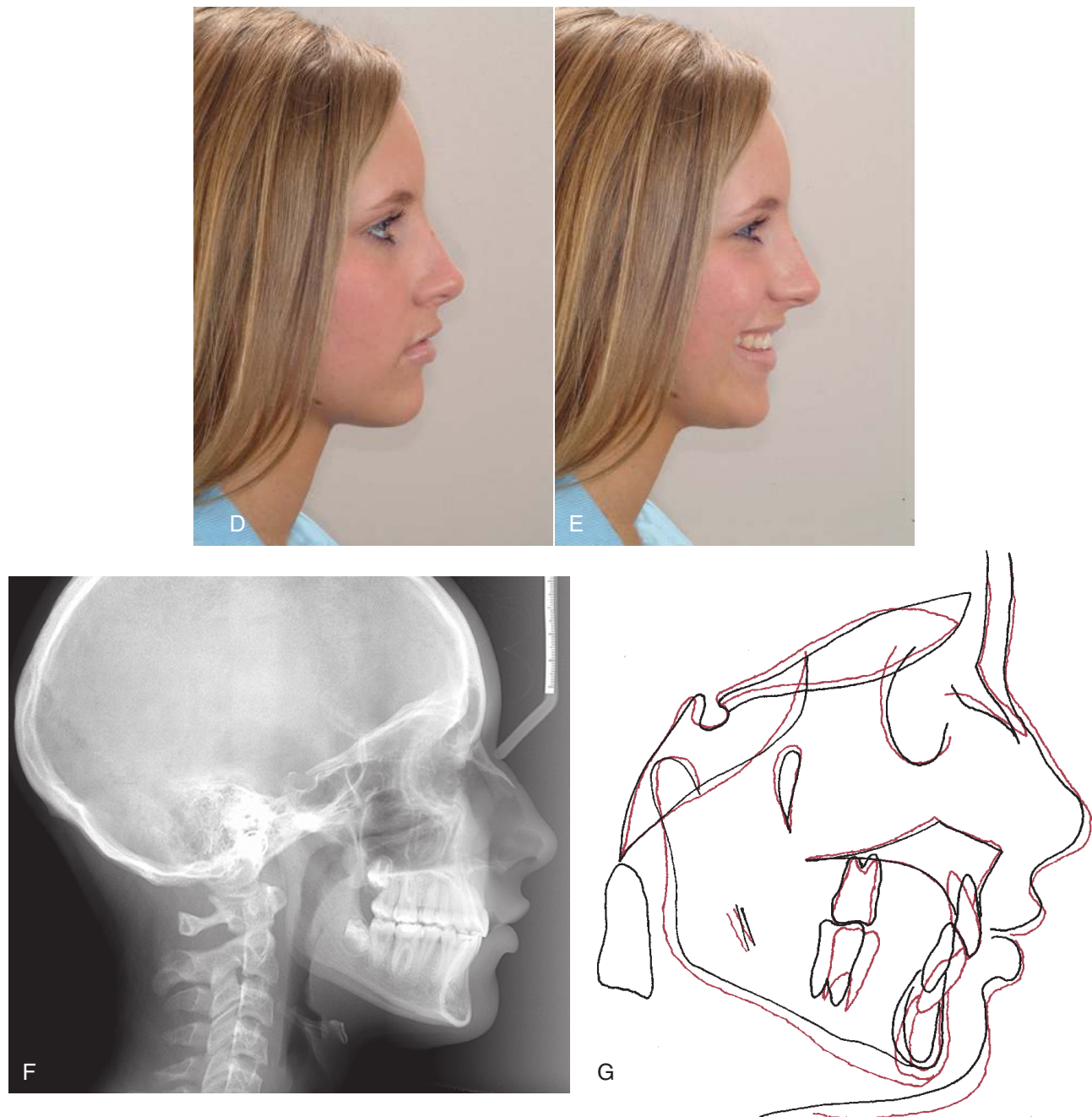


• Fig. 7.26, cont'd

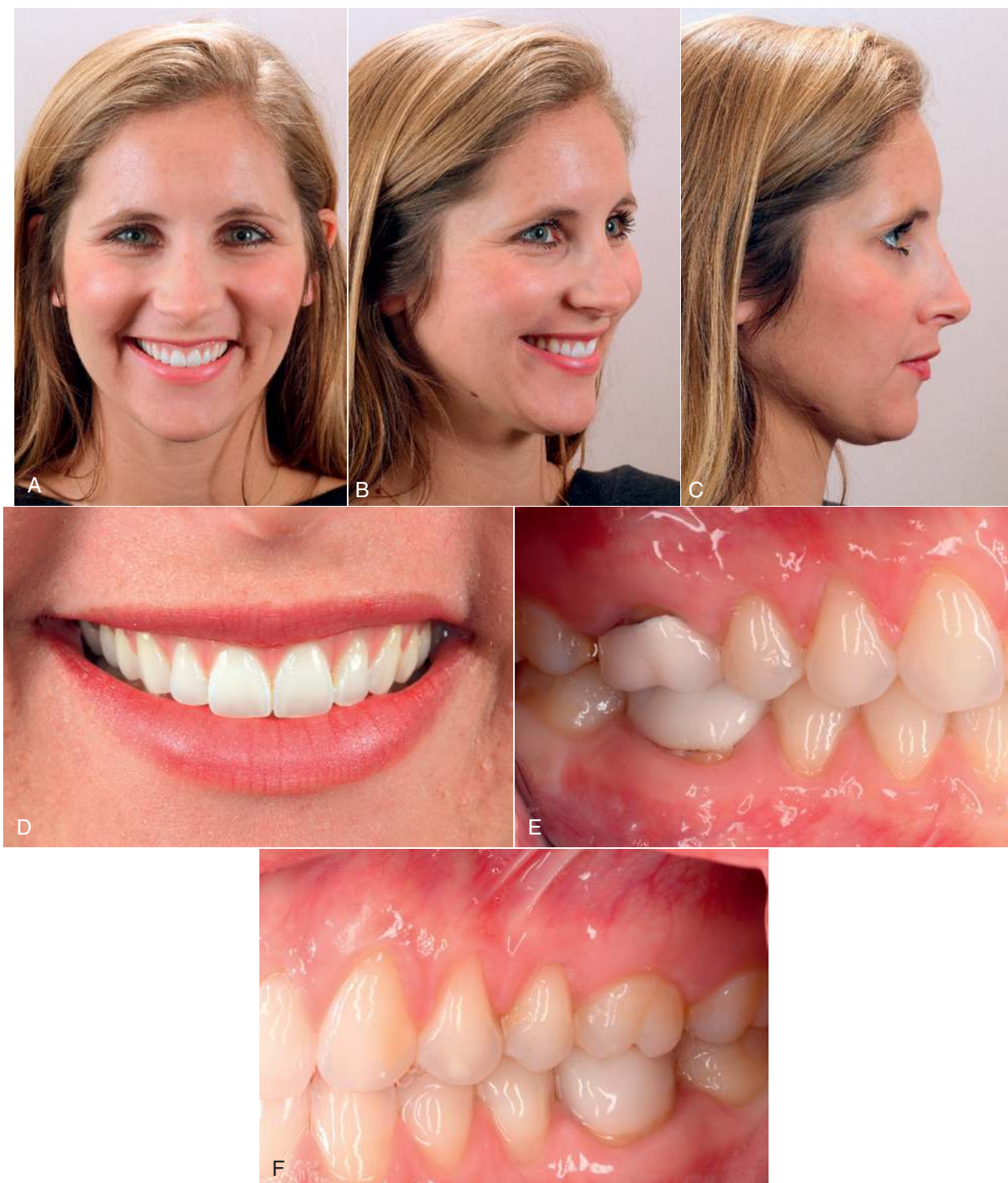

• Fig. 7.27 Patient F.P. (A) to (C) The posttreatment facial appearance.





• **Fig. 7.27, cont'd** (D) and (E) Posttreatment facial appearance. (F) The posttreatment cephalometric radiograph and (G) a cephalometric superimposition showing the changes during treatment. In the superimposition tracing, note the improvement in upper incisor angulation through palatal root torque, without intrusion or facial tipping of the incisors that would have elevated their incisal edges. One potential solution to a “gummy smile” is intrusion of the maxillary incisors, but in this case that would have flattened the smile arc and decreased incisor display, both of which were undesirable. Downward and forward growth of the mandible relative to the maxilla, while the vertical position of the maxillary molars was maintained, was the desired result from use of high-pull headgear. Proclination of the lower incisors contributed to the improved support of the lower lip and reduced the depth of the labial sulcus, which also were desirable—but long-term retention would be required.



• **Fig. 7.28** Patient F.P., age 21, 6-year follow-up. (A) to (C) Facial photos. (D) Smile arc. (E) and (F) Dental occlusion. She had almost no growth after completion of treatment, cooperated with wearing retainers at night to age 18, and had a stable result.

## Treatment Planning in Special Circumstances

### Dental Disease Problems

Until the late 20th century, there was concern that endodontically treated teeth could not be moved. It is now clear that if the

periodontal ligament remains normal, endodontically treated teeth respond to orthodontic force in the same way as teeth with vital pulps. Although some investigators have suggested that root-filled teeth are more subject to root resorption, the current consensus is that this is not a major concern.<sup>17</sup> Occasionally, hemisection of a posterior tooth, with removal of one root and endodontic treatment of the remaining root, is desirable. It is perfectly feasible to

orthodontically reposition the remaining root of a posterior tooth, should this be necessary, after the endodontics is completed. In general, prior endodontic treatment does not contraindicate orthodontic tooth movement, but teeth with a history of severe trauma may be at greater risk of root resorption, whether they have received endodontic treatment or not.

Essentially all periodontal treatment procedures may be used in bringing a pre-orthodontic patient to the point of satisfactory maintenance, with the exception of osseous surgery. Scaling, curettage, flap procedures, and gingival grafts should be employed as appropriate, so that progression of periodontal problems during orthodontic treatment can be avoided. Children or adults with a lack of adequate attached gingiva in the mandibular anterior region should have free gingival grafts to create attached gingiva before the beginning of orthodontics. This is especially true if tooth movement would place the teeth in a more facial position.

Further details in the sequencing of treatment for adults with multiple problems are provided in [Chapter 19](#).

### Systemic Disease Problems

Patients with systemic disease are at greater risk for complications during orthodontic treatment but can have successful orthodontic treatment as long as the systemic problems are under control.

In adults or children, the most common systemic problem that may complicate orthodontic treatment is diabetes or a prediabetic state. If the diabetes is under good control, periodontal responses to orthodontic force are essentially normal, and successful orthodontic treatment, particularly the adjunctive procedures most often desired for adult diabetics, can be carried out successfully. The rapid progression of alveolar bone loss in patients with diabetes is well recognized, however, and if diabetes is not under good control, there is a real risk of accelerated periodontal breakdown ([Fig. 7.29](#)). For this reason, careful monitoring of a diabetic patient's compliance with medical therapy is essential during any phase of orthodontic treatment. Prolonged comprehensive orthodontic treatment should be avoided in these patients.

Arthritic degeneration may also be a factor in orthodontic planning. Juvenile rheumatoid arthritis (JRA) can produce severe skeletal mandibular deficiency, and adult-onset rheumatoid arthritis can destroy the condylar process and create a deformity ([Fig. 7.30](#)). Reduced mandibular growth has been reported after steroid

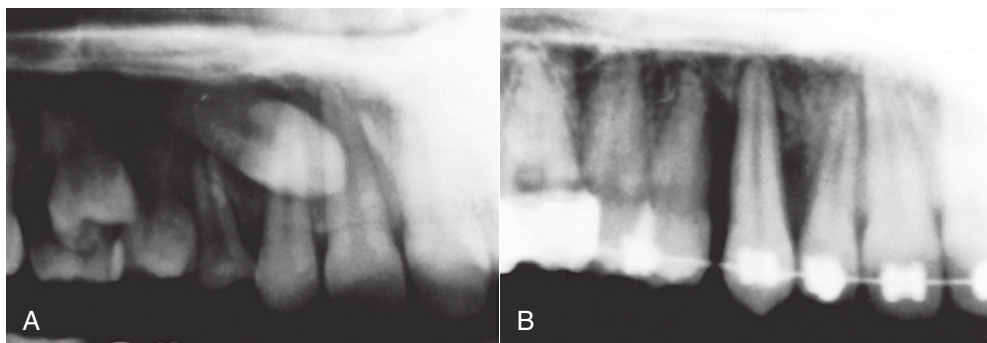
injections into the temporomandibular joint in JRA treatment,<sup>18</sup> and long-term administration of steroids as part of the medical treatment may increase the possibility of periodontal problems during orthodontics. Keep in mind that children on steroids may also be taking bisphosphonates, which make orthodontic tooth movement almost impossible. Prolonged orthodontic treatment should be avoided in patients with either type of rheumatoid arthritis because the potential for harm is at least as great as the potential benefit.

Comprehensive orthodontic treatment for children with other systemic diseases also is possible if the disease is controlled, but requires careful judgment about whether the benefit to the patient warrants the orthodontic treatment. It is not uncommon for the parents of a child with a severe systemic problem (for instance, cystic fibrosis) to seek orthodontic consultation in their bid to do everything possible for their child. With the increasing long-term survival after childhood malignancies and other major problems, parents now are increasingly likely to view children with complex medical backgrounds (such as radiation therapy, long-term steroid use, and drugs to prevent loss of bone mass) as potential orthodontic patients. Although treatment for patients with a poor long-term prognosis is technically feasible, it is usually good judgment to limit the scope of treatment plans, accepting some compromise in occlusion to limit treatment time and intensity.

Finally, although orthodontic treatment can be carried out during pregnancy, there are risks involved. Gingival hyperplasia is likely to be a problem, and the hormonal variations in pregnancy sometimes can lead to surprising results from otherwise predictable treatment procedures. Because of bone turnover issues during pregnancy and lactation, an orthodontist theoretically should be vigilant about loss of alveolar bone and root resorption during pregnancy, but radiographs to check on the status of bone and tooth roots are not permissible then. Treatment for a potential patient who is already pregnant should be deferred until the pregnancy is completed. If a patient becomes pregnant during treatment, the possible problems should be discussed, and it is wise to place her in a holding pattern during the last trimester, limiting the amount of active tooth movement.

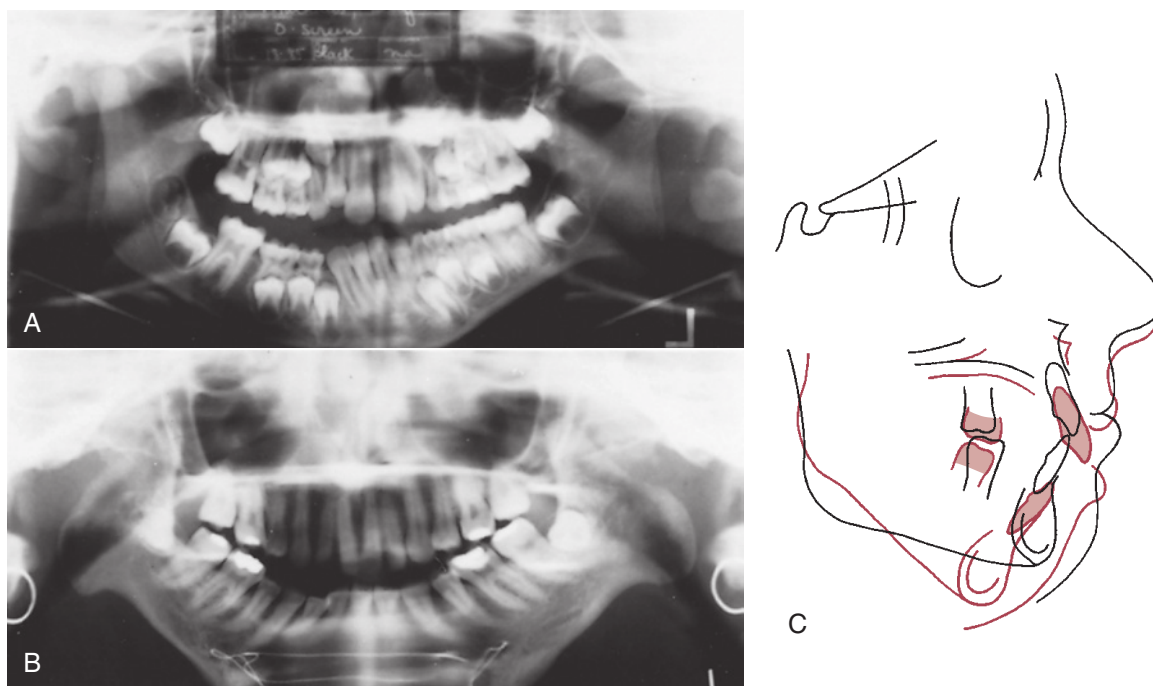
### Jaw Injuries

Fortunately, injuries to the maxilla in children are rare, because their consequences are difficult to manage. If the maxilla is



• **Fig. 7.29** Patients with uncontrolled diabetes may experience rapid bone loss during orthodontic tooth movement. (A) Impacted canine in a 13-year-old girl. (B) One year later. Note the extent of bone loss around the tooth as it was being moved. During the year of active treatment, the patient had great difficulty in controlling her diabetes and was hospitalized for related problems on two occasions. (Courtesy Dr. G. Jacobs.)





• **Fig. 7.30** Rheumatoid arthritis can affect the condylar process and in the worst case can lead to loss of the entire condylar process. (A) Panoramic radiograph of a child with rheumatoid arthritis. Note the early degenerative changes in the condyle on the left side (compare the left with the as yet unaffected right side). (B) Panoramic radiograph of a young adult with complete destruction of the condylar processes. (C) Cephalometric superimpositions for a patient with severe degeneration of the condylar process of the mandible because of rheumatoid arthritis. Age 18, after uneventful orthodontic treatment (*black*); age 29 (*red*), by which time the condylar processes had been destroyed. Note the downward-backward rotation of the mandible. (B courtesy Dr. M. Goonewardene; C courtesy Dr. J. R. Greer.)

displaced by trauma, it should be repositioned immediately if this is possible. When immediate attention to a displaced maxilla is impossible because of other injuries, protraction force from a facemask before fractures have completely healed can successfully reposition it.

The causes of asymmetric mandibular deficiency are discussed in [Chapter 14](#), and the information on hemifacial microsomia versus condylar injury should be reviewed at this point. In planning treatment, it is important to evaluate whether the affected condyle can translate normally. If it can, as one would expect in a mild-to-moderate form of hemifacial microsomia or after a condylar fracture, a functional appliance could be helpful and should be tried first. If translation of the condyle is severely restricted by posttraumatic scarring, a functional appliance will be ineffective and should not be attempted until the restriction on growth has been removed.

Mandibular asymmetry with deficient growth but some translation on that side is a particular indication for custom-designed “hybrid” functional appliances (see [Fig. 10.9](#)) because requirements for the deficient side will be different from those for the normal or more normal side. Often, it is desirable to incorporate a bite block between the teeth on the normal side while providing space for eruption on the deficient side so that the vertical component of the asymmetry can be addressed. In the construction bite, the mandible would be advanced more on the deficient side than on the normal side.

The severe restriction of growth that accompanies little or no translation of the condyle can lead to a progressively more severe

deformity as growth of other parts of the face continues. Progressive deformity of this type is an indication for early surgical intervention. There is nothing to be gained by waiting for such a deformity to become worse. The goal of surgery is to create an environment in which growth is possible, and orthodontic treatment with a hybrid functional appliance usually is needed after surgery to release ankylosis to guide the subsequent growth.

### Hemimandibular Hypertrophy

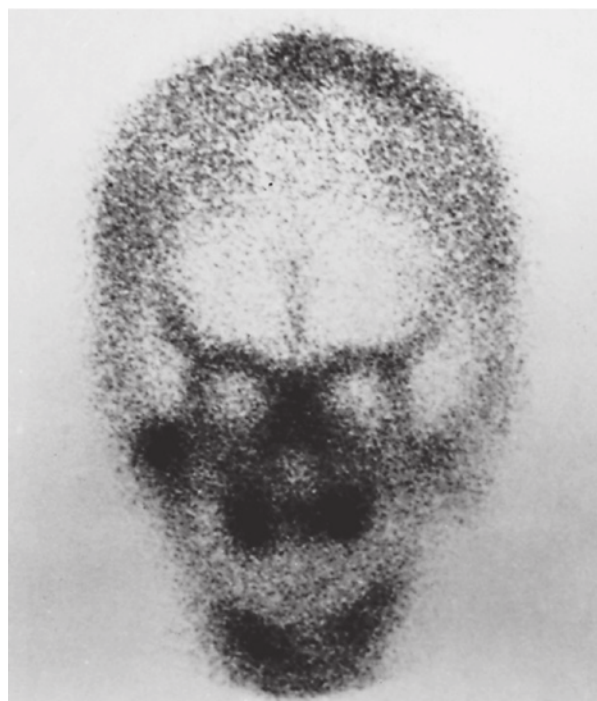
Mandibular and facial asymmetry can also be caused by excessive growth of a mandibular condyle or lengthening of the condylar neck. Growth problems of this type are never symmetric, and in most patients one condyle is normal or nearly so. The excessive growth is not a tumor in which the growing cells are abnormal—it is simply excessive growth on one side of normal condylar tissue, with no histologic difference from normal condyles.<sup>19</sup> The mechanism by which that could happen is not understood. The condition typically appears in the late teens, most frequently in girls, but may begin at an earlier age. Because the body of the mandible is distorted by the excessive growth (usually by bowing downward on the affected side), the condition is appropriately described as hemimandibular hypertrophy; however, because excessive growth at the condyle appears to be the primary cause, the old name for this condition, condylar hyperplasia, was not totally wrong.

There are two possible modes of treatment, both surgical: (1) a ramus osteotomy to correct the asymmetry resulting from unilateral overgrowth, after the excessive growth has ceased; and

(2) condylectomy to remove the excessively growing condyle and reconstruct the joint. The reconstruction usually is done with a section of rib incorporating the costochondral junction area but occasionally can be accomplished just by recontouring the condylar head (“condylar shave”). Because surgical involvement of the temporomandibular joint should be avoided if possible, the asymmetric ramus osteotomy is preferable. This implies, however, that the abnormal growth has stopped or, in a younger patient, will stop within reasonable limits. As a practical matter, removal of the condyle is likely to be necessary in the more severe and more rapidly growing cases, whereas a ramus osteotomy is preferred for the less severe problems.

The bone-seeking isotope technetium 99m ( $^{99m}\text{Tc}$ ) can be used to distinguish an active rapidly growing condyle from an enlarged condyle that has ceased growing. This short-lived gamma-emitting isotope is concentrated in areas of active bone deposition.  $^{99m}\text{Tc}$  imaging of the oral structures typically shows high activity in areas around the alveolar ridge, particularly in areas where teeth are erupting. The condyles are not normally areas of intense imaging, and a “hot” condyle is evidence of active growth at that site (Fig. 7.31).

Unfortunately, although false-positive images are rare, false-negative images are not, so a negative bone scan of the condyles cannot be taken as evidence that hyperplastic growth of one condyle is not occurring. A positive unilateral condylar response on a bone scan indicates that condylectomy will probably be required, whereas a negative response means that further observation for continuing growth is indicated before the surgical procedure is selected.



• **Fig. 7.31** Bone scan with technetium 99m ( $^{99m}\text{Tc}$ ; Towne's view with the mouth open) in a 10-year-old boy with suspected hyperplasia of the right mandibular condyle. Note the “hot spot” in the area of the right condyle and the difference in uptake of the isotope between the right and left sides. Eruption of teeth and apposition of bone at the alveolar processes normally create heavy imaging along the dental arches.

## Sleep Apnea

Sleep apnea has been recognized recently as a more frequent problem than had been appreciated previously, and there is major interest now in the possibility of using jaw-repositioning appliances, essentially the same as removable orthodontic functional appliances, in its treatment.

Sleep apnea carries that name because affected individuals stop breathing while asleep, typically missing several cycles of respiratory movement before waking up abruptly, gasping for breath. The problem is a blockage or severe narrowing of the airway, which can occur at any point between the nostrils and lungs but usually is found in the upper pharynx to midpharynx, where the tongue can intermittently block the pharyngeal airway when muscle relaxation during sleep allows the mandible to drop backward.

It seems apparent that mandibular deficiency would be a risk factor for this type of sleep apnea, because tongue posture is affected by the position of the mandible. The pharyngeal airway can be seen on lateral cephalometric radiographs (Fig. 7.32), and to naïve viewers, the likely location of airway obstruction can be visualized. But the depth of the airway is not shown in cephalograms, and therefore the location of the minimum dimension of the airway cannot be located. Even with three-dimensional images, one gets only a snapshot of the airway, which undergoes small changes minute to minute and larger changes between upright and supine body positions and between being awake and being asleep.

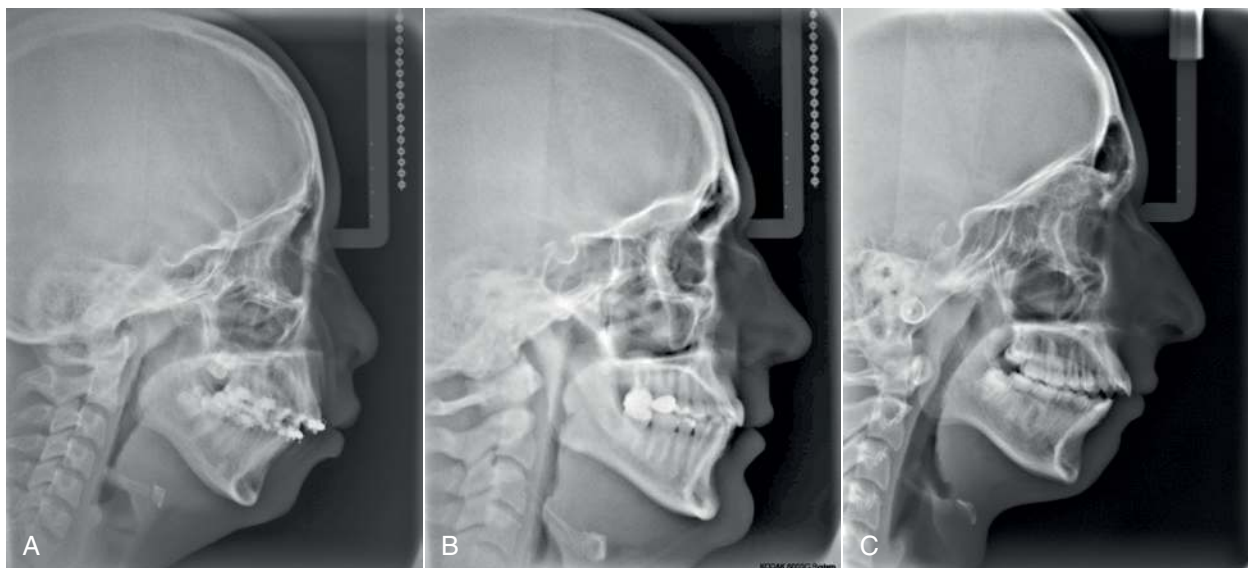
Mandibular deficiency is by no means the major risk factor for sleep apnea. Obesity and increasing age are major contributing factors. As a person gets fatter, fat deposits in the neck tend to compress the airway, and as one gets older, muscle tone decreases so that maintaining tongue position during sleep is more difficult. Loss of muscle tone is inevitable with aging; obesity is not, but body weight often increases with advancing age. So even if mandibular deficiency played a secondary role in the etiology of sleep apnea, correcting it could be an important aspect of treatment.

Would holding the mandible forward with an intraoral appliance correct or at least decrease the severity of sleep apnea? In fact, such an appliance can be effective for some patients with low or moderately severe sleep apnea. It should be designed to minimize tooth movement, which can occur easily if the appliance puts prolonged pressure on the teeth during sleep.<sup>20</sup> Managing appliance therapy for sleep apnea is discussed in some detail in Chapter 19.

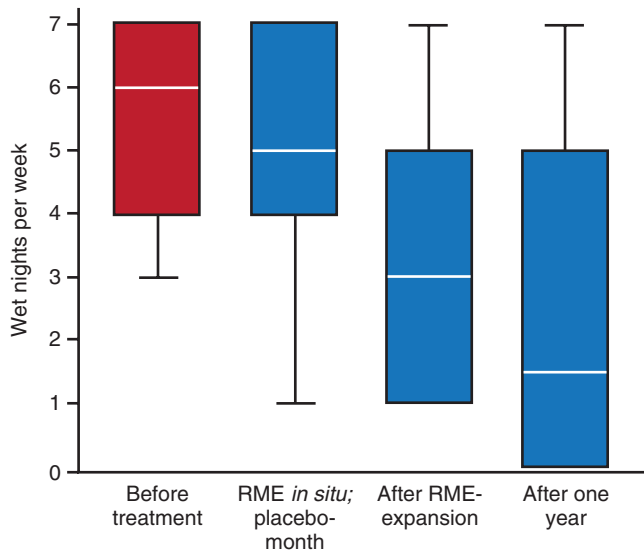
Orthognathic surgery to advance the mandible and maxilla to provide more room for the tongue is important in treating severely affected patients, and for these patients the improved respiratory function outweighs the detrimental effects on facial appearance and dental occlusion that probably would occur. Considerations in planning and providing this treatment are discussed in Chapter 20.

Could a narrow maxilla be a contributor to sleep apnea, or even the primary cause? That would be the case if great respiratory effort was required when awake. Then muscle relaxation during sleep would make the respiratory movements inadequate. If so, would widening the palate, which is the base of the nasal cavity, be effective treatment? That would be the case if obstruction within the nose was part of the respiratory problem. Opening the midpalatal suture orthodontically does help some children with sleep apnea.<sup>21</sup>

It was observed 20 years ago that in some children, maxillary expansion by opening the midpalatal suture also stopped nocturnal enuresis (“bed-wetting”), presumably because it enlarged the nasal cavity and improved respiration. A series of case reports followed, but until recently there were no data for success rates and mechanism



• **Fig. 7.32** Pharyngeal airway as seen in lateral cephalometric radiographs. (A) Typical view of the pharyngeal airway in a severely mandibular individual who has normal sleep despite an apparently restricted airway. (B) The airway for this patient without mandibular deficiency appears to be some constricted, but she has normal sleep. (C) For this mandibular deficient patient with severe sleep apnea, the airway appears remarkably wide open. These two-dimensional views are almost caricatures of the spectrum of pharyngeal dimensions, however, because of the great variation in apparent airway dimensions in people with no respiratory problems. They cannot be used for sleep apnea diagnosis. Even three-dimensional views of the airway are not diagnostic because the airway contours change between degrees of alertness, upright and prone posture, and waking and sleeping.



• **Fig. 7.33** The antineuritic effect of maxillary expansion in a group of 32 Swedish children with severe bed-wetting that did not respond to the first line of treatment, a vasopressin analogue, shown here as the number of wet nights per week. At 1-year recall, 60% of these patients no longer had enuresis. (Redrawn from Bazargani F, et al. *Angle Orthod.* 86:481-486, 2016.)

for success. In 2016 Bazargani et al reported that in a group of 32 Swedish children with primary enuresis who had not responded to standard antineuritic treatment with a vasopressin analogue, rapid maxillary expansion followed by 6 months of retention with a transpalatal arch produced a 60% cure rate at 1 year (Fig. 7.33).<sup>22</sup>

Before expansion, these children did not have classic sleep apnea but did have greater resistance to nasal air flow than normal controls, so the extent to which improving respiration was the major mechanism for improvement still is not clear.

There is some evidence from three-dimensional studies that surgical maxillary expansion in adults with sleep apnea both opens the nasal passage and widens the upper pharyngeal area.<sup>23</sup> Although one would think that surgery to move the maxilla up, which decreases the size of the nasal chamber, would compromise air flow through the nose, it has been shown that almost all these patients have decreased resistance to nasal airflow after treatment.<sup>24</sup> The explanation is that the nostril is the nasal valve under normal conditions. Superior repositioning of the maxilla is accompanied by widening of the nostrils. Surgical widening of the maxilla also affects the nostrils, so the bony change may not be the important one in sleep apnea.

As of mid-2017, a period of overenthusiasm for dental treatment of sleep apnea, especially among family dentists, appears to be waning. Orthognathic surgery is definitive treatment for adults, intraoral appliances in many instances are not, and the sleep apnea appliances in children mimic what they would have done in orthodontic patients with normal breathing. Without pretreatment and posttreatment cephalometric or cone beam computed tomography (CBCT) radiographs and sleep studies to show the skeletal and dental changes that occur with this treatment, it is impossible to know how the dental and hard tissue changes really relate to the effect on sleep apnea and the extent of undesired tooth movement. As better information for treatment outcomes becomes available, it will be easier to determine the characteristics of sleep apnea patients who would benefit significantly.



## Cleft Lip and Palate

Patients with cleft lip and palate routinely require extensive and prolonged orthodontic treatment.<sup>25</sup> Orthodontic treatment may be involved at any or all of four separate stages: (1) in infancy before the initial surgical repair of the lip, (2) during the late primary and early mixed dentition, (3) during the late mixed and early permanent dentition, and (4) in the late teens after the completion of facial growth, in conjunction with orthognathic surgery. The typical sequence of treatment is outlined in Table 7.2, and the treatment procedures are discussed in more detail in the following sections.

### Infant Orthopedics

An infant with a cleft lip and palate will have a distorted maxillary arch at birth in nearly every instance. In patients with a bilateral cleft, the premaxillary segment is often displaced anteriorly while the posterior maxillary segments are lingually collapsed behind it (Fig. 7.34). Less severe distortions occur in infants with unilateral palatal clefts (Fig. 7.35A–B). If the distortion of arch form is extremely severe, surgical closure of the lip, which is normally carried out in the early weeks of life, can be extremely difficult. Orthodontic intervention to reposition the segments and to bring the protruding premaxillary segment back into the arch may be needed to obtain a good surgical repair of the lip.<sup>26</sup> This “infant

orthopedics” is one of the few instances in which orthodontic treatment for a newborn infant, before eruption of any teeth, may be indicated.

In a child with a bilateral cleft, two types of movement of the maxillary segments may be needed. First, the collapsed maxillary posterior segments must be expanded laterally; then pressure against the premaxilla can reposition it posteriorly into its approximately correct position in the arch. This can be accomplished by a light elastic strap across the anterior segment, by an orthodontic appliance pinned to the segments that applies a contraction force, or even by pressure from the repaired lip if lip repair is done after the lateral expansion. In patients with extremely severe protrusion, an appliance held to the maxillary segments by pins might be required, while an elastic strap or the pressure of the lip itself would be adequate with less severe problems.

In infants the segments can be repositioned surprisingly quickly and easily, so that the period of active treatment is a few weeks at most. If presurgical movement of maxillary segments is indicated, this typically would be done beginning at 3 to 6 weeks of age so that the lip closure can be carried out at approximately 10 weeks. A passive plate, similar to an orthodontic retainer, is then used for a few months after lip closure (Fig. 7.35C–D).

Soon after this treatment, the infants who had presurgical orthopedics look much better than those who did not. With each passing year, however, it becomes more difficult to tell which patients had segments repositioned in infancy and which did not.<sup>27</sup> The short-term benefit is more impressive than the long-term benefit. For some infants with extremely malpositioned segments, which occur almost exclusively in bilateral cleft lip and palate, presurgical infant orthopedics remains useful. For most patients with cleft lip or palate, however, the orthodontist is no longer called on to reposition segments in infants. Instead, if the segments protrude, the lip repair may be carried out in two stages, first with a lip adhesion to provide an elastic force from the lip itself, followed at a somewhat later stage by definitive lip repair.

At some centers, bone grafts to stabilize the position of the segments were placed across the cleft alveolus soon after infant orthopedics. Although a few clinicians still advocate this procedure, the consensus is that early grafting of the alveolar process is contraindicated because it tends to interfere with later growth. Alveolar bone grafts are better deferred until the early mixed dentition.<sup>28</sup>

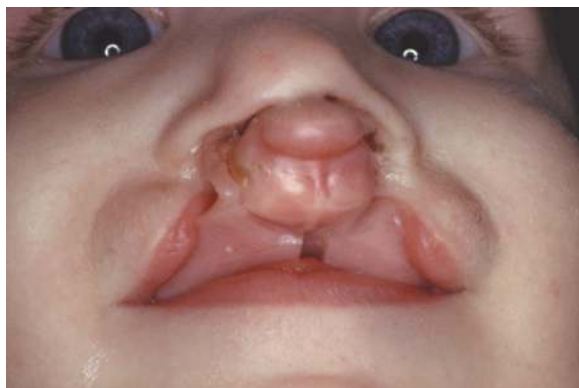### Late Primary and Early Mixed Dentition Treatment

Many of the orthodontic problems of children with cleft palate in the late and early mixed dentition result not from the cleft itself but from the effects of surgical repair. Although the techniques for repair of cleft lip and palate have improved tremendously in recent years, closure of the lip inevitably creates some constriction across the anterior part of the maxillary arch, and closure of a cleft palate causes at least some degree of lateral constriction. As a result, surgically treated cleft palate patients have a tendency toward both anterior and lateral crossbite, which is not seen in patients with untreated clefts. This result is not an argument against surgical repair of the lip and palate, which is necessary for esthetic and functional (speech) reasons. It simply means that orthodontic treatment must be considered a necessary part of the habilitation of such patients.

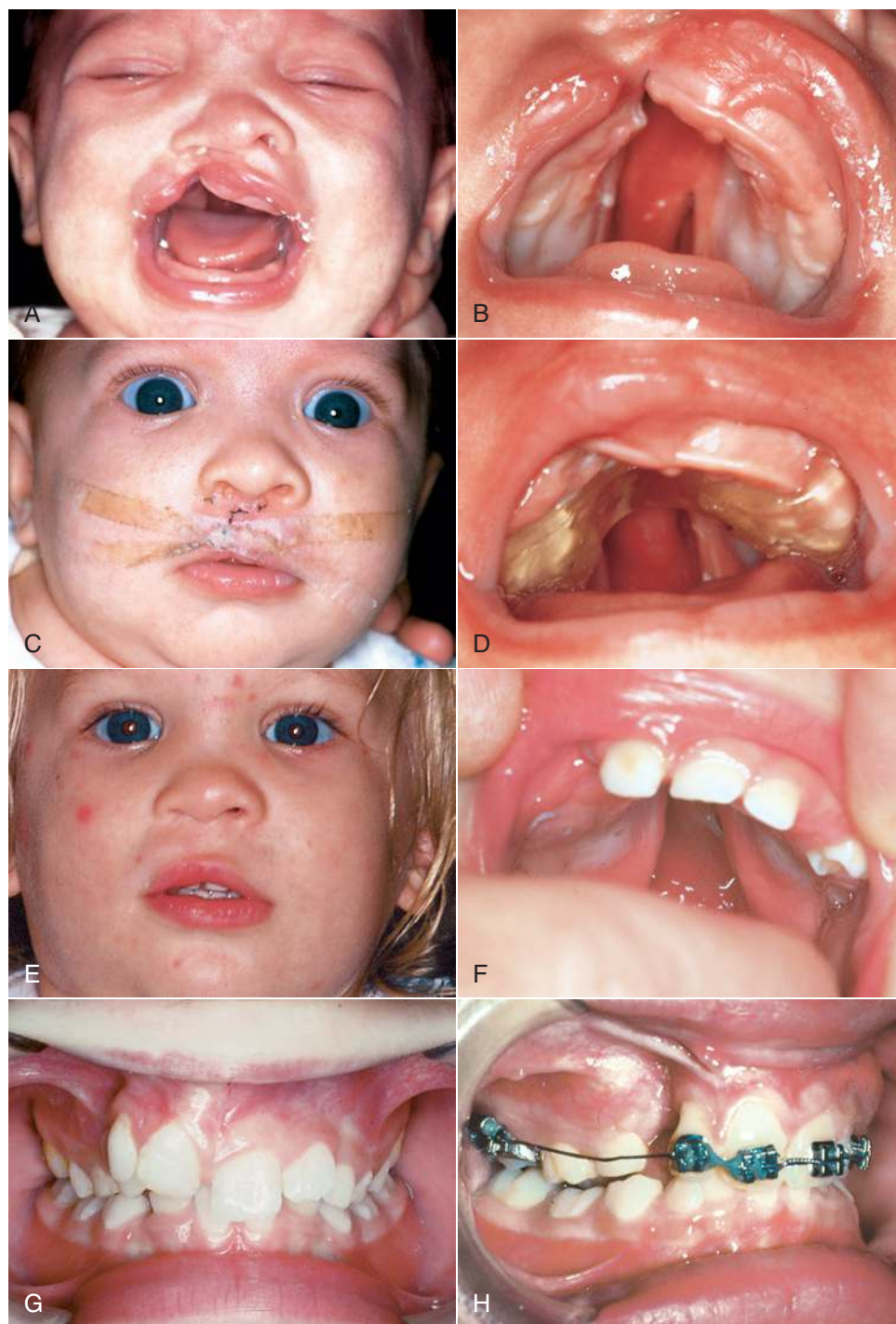Orthodontic intervention is often unnecessary until the permanent incisor teeth begin to erupt but is usually imperative at that point (Fig. 7.35E–J). As the permanent teeth come in, there is a strong tendency for the maxillary incisors to erupt rotated and often in crossbite. The major goal of orthodontic treatment

**TABLE 7.2** Sequence of Treatment for Cleft Palate Patients

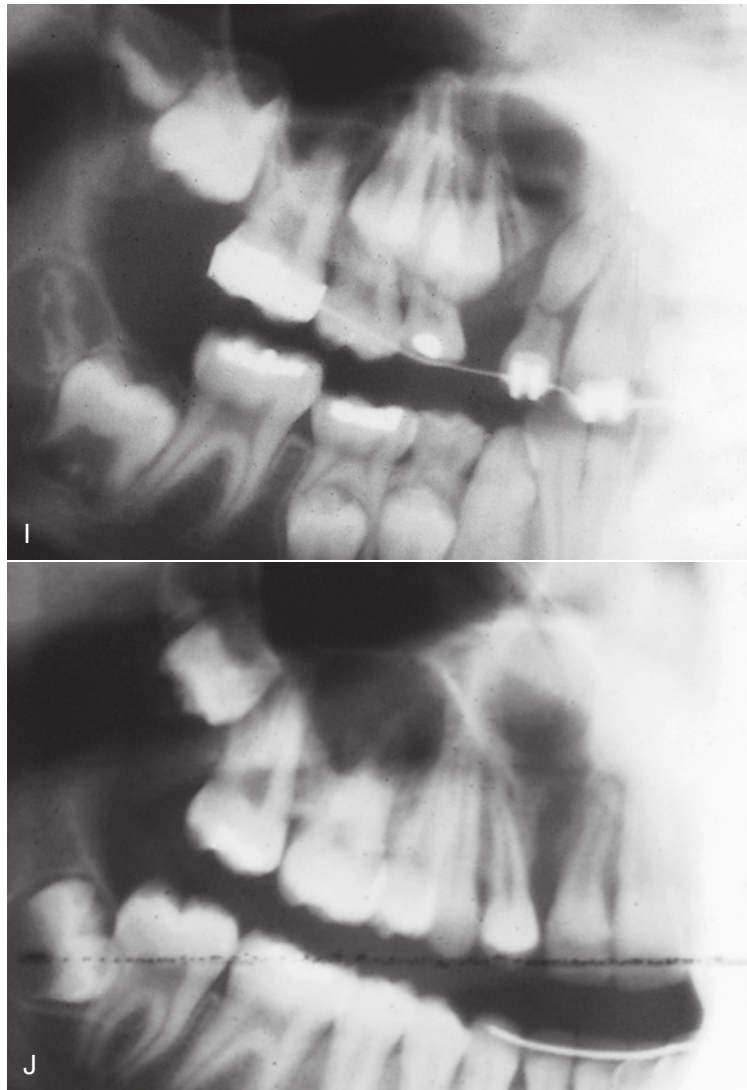
2-4 weeks	Lip closure (infant orthopedics?)
12-18 months	Palate closure
7-8 years	Alignment of maxillary incisors
7-9 years	Alveolar bone graft ( <i>before eruption of lateral incisor, if present, or canine</i> )
Adolescence	Comprehensive orthodontics Lip/nose revision?
Late adolescence	Orthognathic surgery?



• **Fig. 7.34** In this photograph of an infant with a bilateral cleft of the lip and palate, note the forward displacement of the premaxillary segment and medial collapse of the lateral maxillary segments. This displacement of the segments nearly always is seen in infants with a bilateral cleft. An expansion appliance, to create space for retraction of the premaxilla, can be seen in the child's mouth.



• **Fig. 7.35** Long-term observation of treatment of a girl with unilateral cleft lip and palate (see Fig. 7.34). (A) and (B) Age 8 weeks before lip repair. Note the displacement of the alveolar segments at the cleft site. (C) and (D) Age 9 weeks after lip closure. A palatal plate has been pinned into position to control the alveolar segments, while lip pressure molds them into position. (E) and (F) Age 2, prior to palate closure. (G) Age 8, after eruption of maxillary incisors. (H) Age 9, incisor alignment in preparation for alveolar bone graft.



• **Fig. 7.35, cont'd** (I) Panoramic radiograph, age 9, just before bone graft. (J) Panoramic radiograph, age 12, at completion of orthodontic treatment, showing bone fill-in at the cleft site.

then is to correct incisor position and prepare the patient for an alveolar bone graft.

The objective is to have a permanent tooth erupt through the grafted area so that the cleft is obliterated. An erupting tooth brings bone with it, creating new bone beyond the limits of the previous graft. If the permanent lateral incisors are present, the graft should be placed at about age 7, before they erupt. If the laterals are missing, the graft can be delayed but should be done before the permanent canines erupt. Any necessary alignment of incisors or expansion of posterior segments should be completed before the alveolar grafting. For bilateral cleft patients, an expander that expands more anteriorly than posteriorly has been shown to be more effective.<sup>29</sup> The alveolar graft now is a routine part of contemporary treatment, and doing it at the right time is critically important.

#### **Early Permanent Dentition Treatment**

As the canine and premolar teeth erupt, posterior crossbite is likely to develop, particularly on the cleft side in a unilateral cleft patient, and the teeth are likely to be malaligned (Fig. 7.36). The more

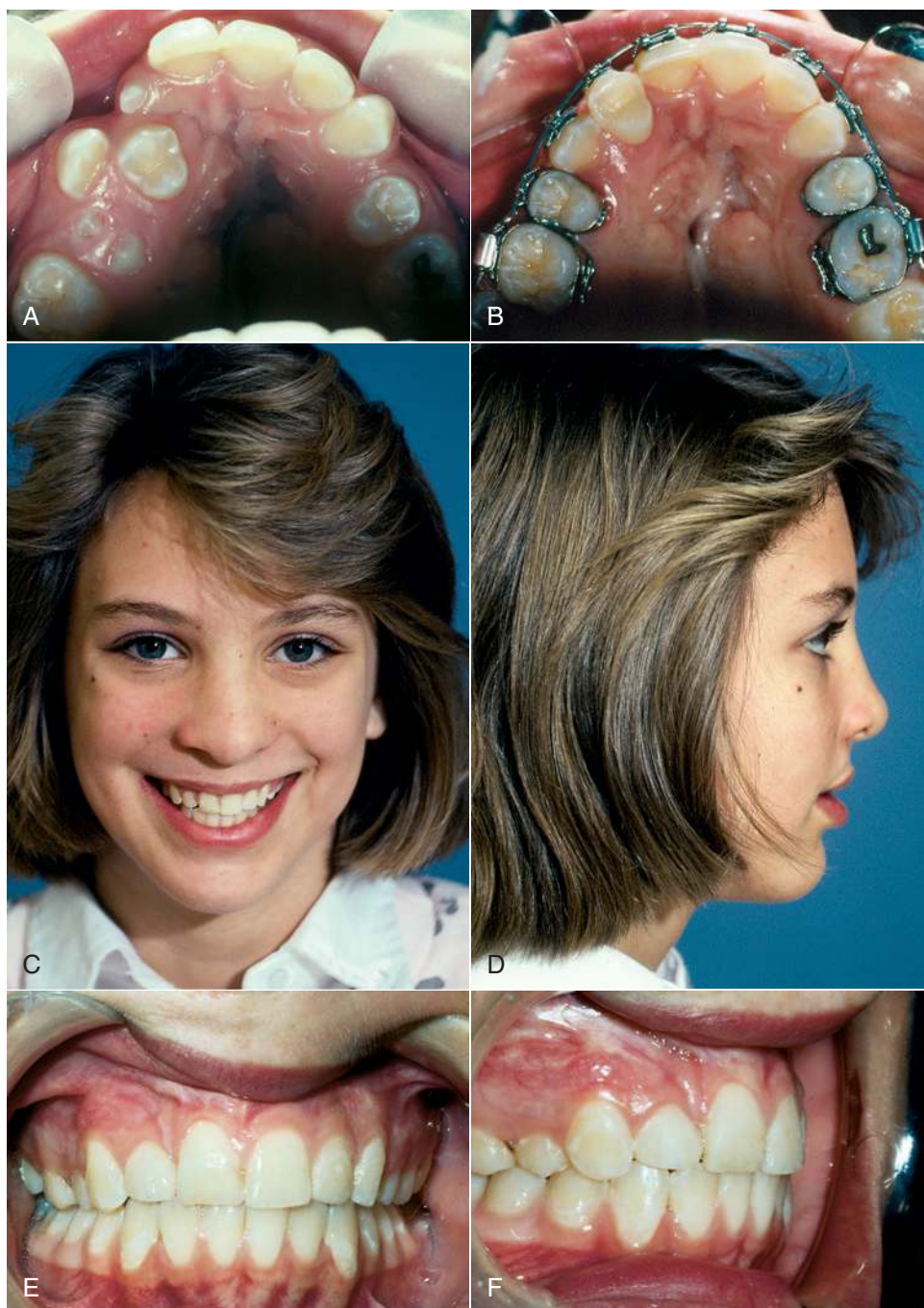
successful the surgery, the fewer the problems, but in essentially every instance, fixed appliance orthodontic treatment is necessary in the late mixed or early permanent dentition. New bone fills in the grafted cleft as the canine erupts, which makes it possible to close spaces due to missing teeth, and this now is a major objective of this phase of treatment (Fig. 7.36I–J).

If space closure is not possible, orthodontic tooth movement may be needed to position teeth as abutments for eventual fixed prosthodontics. In that circumstance, a resin-bonded bridge that provides a semipermanent replacement for missing teeth can be extremely helpful. Orthodontic treatment is often completed at age 14, but a permanent bridge in many instances cannot be placed until age 17 or 18. The semipermanent fixed bridge is preferable to prolonged use of a removable retainer with a replacement tooth. Dental implants are not appropriate for cleft areas.

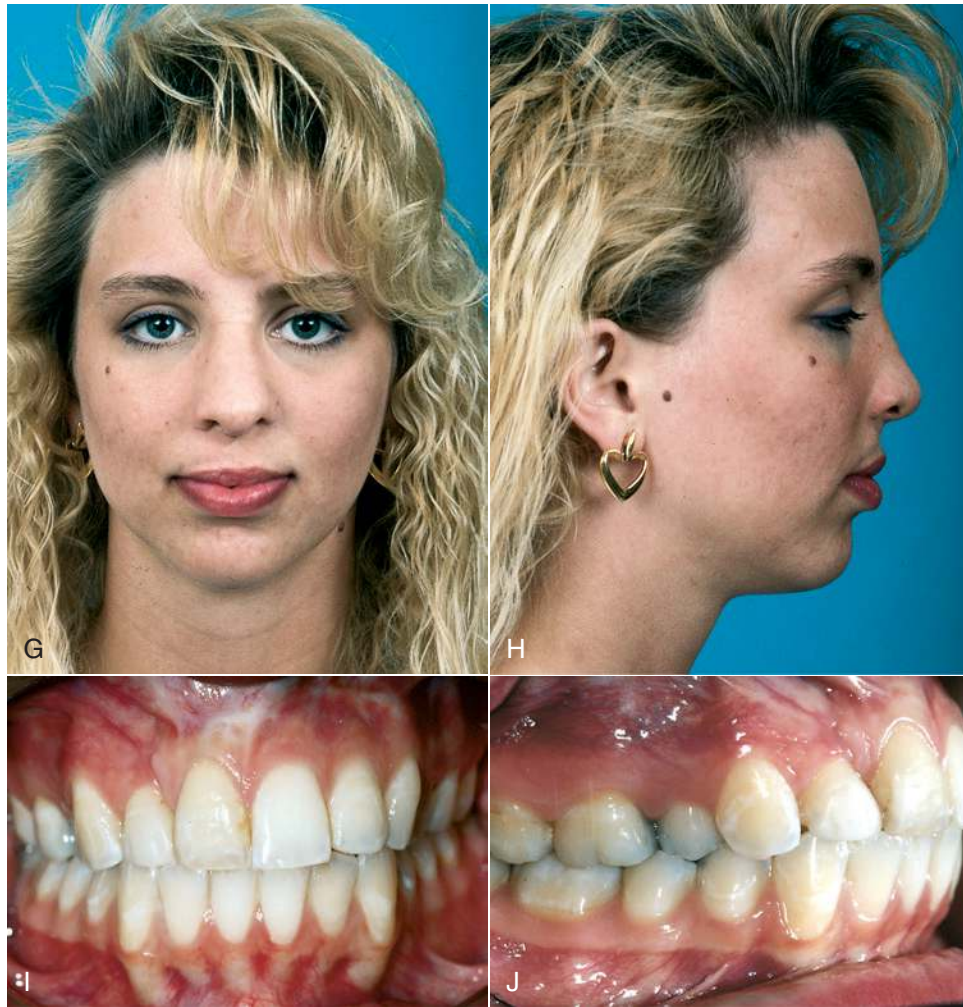#### **Orthognathic Surgery for Patients With Cleft Lip and Palate**

In some patients with cleft lip and palate, more often in males than females, continued mandibular growth after the completion





• **Fig. 7.36** (A) Age 11, transposed first premolar erupting in the grafted area. (B) First premolar in lateral incisor position toward the end of active orthodontics, age 12. A tooth that erupts in a grafted area or that is moved orthodontically into the area stimulates formation of new bone that eliminates the cleft. Because teeth bring alveolar bone with them and this bone is lost in the absence of teeth, this is the only way to completely repair an alveolar cleft. (C) and (D) Facial and (E) and (F) intraoral photos, age 12.



• **Fig. 7.36, cont'd** (G) and (H) Facial and (I) and (J) intraoral photographs, age 21. At this point the occlusion is stable and both the facial and alveolar cleft can hardly be discerned. Although the palate repair is obvious on intraoral examination, it does not affect appearance or function.

of active orthodontic treatment leads to the return of anterior and lateral crossbites. This result is not so much from excessive mandibular growth as from deficient maxillary growth, both anteroposteriorly and vertically, and it is seen less frequently now because of the improvements in cleft lip and palate surgery in recent years. Orthognathic surgery to bring the deficient maxilla downward and forward may be a necessary last stage in treatment of a patient with cleft lip or palate, typically at about age 18 if required. Occasionally, surgical mandibular setback also may be needed. After this, the definitive restorative work to replace any missing teeth can be carried out. A pharyngeal flap to control leakage of air through the nose often is needed after maxillary advancement in cleft patients.

There has been a striking decrease in recent years in the number of teenage cleft patients needing either prosthodontic replacement of missing teeth or orthognathic surgery to correct maxillary deficiency. The standard of care now is atraumatic palatal surgery that minimizes interferences with growth, and closure of the space where teeth are missing, made possible by alveolar grafts in the early mixed dentition. Improvements in the United States have been promoted by and documented in the Americleft

program, an organized way to gather data from multiple sites of cleft care so that superior procedures can be selected.<sup>30,31</sup> This program is an excellent example of the way in which good data from treatment outcomes can be used to improve the quality of treatment.

## References

1. Betts NJ, Vanarsdall RJ, Barber HD, et al. Diagnosis and treatment of transverse maxillary deficiency. *Int J Adult Orthodon Orthognath Surg.* 1995;10:75–96.
2. Nimkarn Y, Miles PG, O'Reilly MT, et al. The validity of maxillary expansion indices. *Angle Orthod.* 1995;65:321–326.
3. Bowman SJ, Johnston LE. The esthetic impact of extraction and non-extraction treatments on Caucasian patients. *Angle Orthod.* 2000;70:3–10.
4. Kim E, Gianelly AA. Extraction vs non-extraction: arch widths and smile esthetics. *Angle Orthod.* 2003;73:354–358.
5. Meyer AH, Woods MG, Manton DJ. Maxillary arch width and buccal corridor changes with orthodontic treatment. Part 2: attractiveness of the frontal facial smile in extraction and nonextraction outcomes. *Am J Orthod Dentofacial Orthop.* 2014;145:296–304.

6. Iared W, Koga da Silva EM, Iared WG, Macedo CM. Esthetic perception of changes in facial profile resulting from orthodontic treatment with extraction of premolars: a systematic review. *J Am Dent Assoc.* 2017;148:9–16.
7. Phillips C, Hill BJ, Cannac C. The influence of video imaging on patients' perceptions and expectations. *Angle Orthod.* 1995;65:263–270.
8. Chamberland S, Proffit WR, Chamberland PE. Genioplasty in growing patients. *Angle Orthod.* 2015;85:360–373.
9. Springer NC, Chang C, Fields HW, et al. Smile esthetics from the patients' perspective. *Am J Orthod Dentofacial Orthop.* 2011;139:e91–e101.
10. Dickens S, Sarver DM, Proffit WR. The dynamics of the maxillary incisor and the upper lip: a cross-sectional study of resting and smile hard tissue characteristics. *World J Orthod.* 2002;3:313–320.
11. Ker AJ, Chan R, Fields HW, et al. Esthetic and smile characteristics from the layperson's perspective: a computer-based survey study. *J Am Dent Assoc.* 2008;139:1318–1327.
12. Kokich VO, Kinzer GA. Managing congenitally missing lateral incisors. Part I. Canine substitution. *J Esthet Restor Dent.* 2005;17:5–10.
13. Kutner M, Greenberg E, Jin Y, et al. The health literacy of America's adults: results from the 2003 National Assessment of Adult Literacy. US Department of Education, National Center for Education Statistics. NCES 2006-483.
14. Carr KM, Fields HW Jr, Beck FM, et al. Impact of verbal explanation and modified consent materials on orthodontic informed consent. *Am J Orthod Dentofacial Orthop.* 2012;141:174–186.
15. Carr KM, Fields HW, Beck FM, et al. Improving orthodontic informed consent: a new approach. *Am J Orthod Dentofacial Orthop.* In press.
16. Bandura A, Barbaranelli C, Capara GV, et al. Self-efficacy beliefs as shapers of children's aspirations and career trajectories. *Child Dev.* 2001;72:187–206.
17. Llamas-Carreras JM, Amarilla A, Solano E, et al. Study of external root resorption during orthodontic treatment in root filled teeth compared with their contralateral teeth with vital pulps. *Int Endod J.* 2010;43:654–662.
18. Ststrup P, Kristensen KD, Kuseler A, et al. Reduced mandibular growth in experimental arthritis in the TM joint treated with intra-articular corticosteroids. *Eur J Orthod.* 2008;30:111–119.
19. Eslami B, Behnia H, Javadi H, et al. Histopathologic comparison of normal and hyperplastic condyles. *Oral Surg Oral Med Oral Pathol Oral Radiol Endod.* 2003;96:711–717.
20. Wang X, Gong X, Yu Z, et al. Follow-up study of dental and skeletal changes in patients with obstructive sleep apnea and hypopnea syndrome with long-term treatment with the Silensor appliance. *Am J Orthod Dentofacial Orthop.* 2015;147:559–565.
21. Katyal V, Pamula Y, Daynes C, et al. Craniofacial and upper airway morphology in pediatric sleep-disordered breathing and changes in quality of life with rapid maxillary expansion. *Am J Orthod Dentofacial Orthop.* 2013;144:860–871.
22. Bazargani F, Jonson-Ring I, Neveus T. Rapid maxillary expansion in therapy-resistant enuretic children: an orthodontic perspective. *Angle Orthod.* 2016;86:481–486.
23. Vinha PB, Faria AC, Xavier SP, et al. Enlargement of the pharynx resulting from surgically assisted rapid maxillary expansion. *J Oral Maxillofac Surg.* 2016;74:369–379.
24. Turvey TA, Hall DJ, Warren DW. Alteration in nasal airway resistance following superior repositioning of the maxilla. *Am J Orthod.* 1984;85:109–114.
25. Bennun RD, Harfin JF, Sándor GKB, Genecov D. *Cleft Lip and Palate Management: A Comprehensive Atlas.* Hoboken, NJ: John Wiley & Sons; 2015.
26. Bongaarts CAM, Prah-Andersen B, Bronkhorst EW, et al. Infant orthopedics and facial growth in complete unilateral cleft lip and palate until six years of age (Dutchcleft). *Cleft Palate Craniofac J.* 2009;46:654–663.
27. Vig KWL, Mercado AM. Overview of orthodontic care for children with cleft lip and palate, 1915–2015. *Am J Orthod Dentofacial Orthop.* 2015;148:543–556.
28. Weissler EH, Paine KM, Ahmed MK, Taub PJ. Alveolar bone grafting and cleft lip and palate: a review. *Plast Reconstr Surg.* 2016;138:1287–1295.
29. Garib D, Lauris RC, Calil LR, et al. Dentoskeletal outcomes of a rapid maxillary expander with differential opening in patients with bilateral cleft lip and palate: a prospective clinical trial. *Am J Orthod Dentofacial Orthop.* 2016;150:564–574.
30. Long RE Jr, Hathaway R, Daskalogiannakis J, et al. The Americleft study: an inter-center study of treatment outcomes with unilateral cleft and palate, part 5. General discussion and conclusions. *Cleft Palate Craniofac J.* 2011;48:265–270.
31. Ruppel K, Long RE Jr, Oliver DR, et al. The Americleft project: a comparison of short- and longer-term secondary bone graft outcomes in two centers using the standardized way to assess grafts scale. *Cleft Palate Craniofac J.* 2016;53:508–515.



# Biomechanics, Mechanics, and Contemporary Orthodontic Appliances

Orthodontic therapy depends on the reaction of the teeth, and more generally the facial structures, to gentle but persistent force. In an orthodontic context, *biomechanics* is commonly used in discussions of the reaction of the dental and facial structures to orthodontic force, whereas *mechanics* is reserved for the properties of the strictly mechanical components of the appliance system. In this section, the biologic responses to orthodontic force that underlie biomechanics are discussed in [Chapter 8](#), and new possibilities for accelerating the rate of tooth movement are reviewed and evaluated. [Chapter 9](#), which is concerned with the design and application of orthodontic appliances, is largely devoted to mechanics but also includes some biomechanical considerations and introduces the application of temporary skeletal anchorage, which is discussed in more detail in [Chapter 10](#).

Contemporary orthodontic treatment involves the use of both fixed and removable appliances. The first part of [Chapter 10](#) describes all types of removables that are useful at present, with emphasis on the components approach to designing functional appliances for individual patients, and on the considerations that are important in clear aligner therapy.

In the early decades of the 21st century there have been major changes in fixed appliances, and these are reviewed in the second part of [Chapter 10](#). The principle of the edgewise appliance, control of tooth movement via rectangular archwires in a rectangular slot, remains the basis of contemporary fixed appliance therapy, but changes in brackets and archwire fabrication are occurring as computer-aided design/computer-aided manufacturing (CAD/CAM) design and production become more and more important. The major problems that limited the use of fixed lingual appliances have largely been overcome. Skeletal anchorage, based on both multiscrew miniplates and alveolar bone screws, has quickly become an important part of contemporary treatment. A major goal of [Chapter 10](#) and the subsequent chapters on comprehensive treatment is to evaluate these changes in appliances in the context of data for clinical outcomes with their use.

# 8

## The Biologic Basis of Orthodontic Therapy

### CHAPTER OUTLINE

#### Periodontal and Bone Response to Normal Function

- Periodontal Ligament Structure and Function

- Response to Normal Function

- Role of the Periodontal Ligament in Eruption and Stabilization of the Teeth

#### Periodontal Ligament and Bone Response to Sustained Force

- Biologic Control of Tooth Movement

- Effects on the Response to Orthodontic Force

- Drug Effects on the Response to Orthodontic Force

- Local Injury to Accelerate Tooth Movement

#### Anchorage and Its Control

- Anchorage: Resistance to Unwanted Tooth Movement

- Control of Anchorage

- Skeletal Effects of Orthodontic Force: Growth Modification

#### Deleterious Effects of Orthodontic Force

- Mobility and Pain Related to Orthodontic Treatment

- Effects on the Dental Pulp

- Root resorption

- Effects of Treatment on Alveolar Bone Height

- Enamel Demineralization

### Periodontal and Bone Response to Normal Function

Orthodontic movement of teeth is based on the observation that if prolonged light pressure is applied to a tooth, tooth movement will occur as the bone around the tooth remodels. Bone is selectively removed in some areas and added in others. In essence, the tooth moves through the bone carrying its attachment apparatus with it, as the socket of the tooth migrates. Because the bony response is mediated by the periodontal ligament (PDL), tooth movement is primarily a PDL phenomenon.

Forces applied to the teeth can also affect the pattern of bone apposition and resorption at sites distant from the teeth, particularly the sutures of the maxilla and bony surfaces on both sides of the temporomandibular joint. In addition, it is possible now to apply force to implants in the maxilla or mandible to influence growth at maxillary sutures and at the mandibular condyle, affecting skeletal growth with minimal or no tooth movement. Thus the biologic response to orthodontic therapy includes not only the response

of the PDL but also the response of growing areas distant from the dentition. It is not possible to move bones in the same way teeth are moved, because pressure against sutures, synchondroses or joints does not stimulate similar remodeling of adjacent bone, but it is possible to generate formation of new bone by distraction osteogenesis, and the pattern of skeletal growth can be modified.

In this chapter, the focus is on the response of periodontal structures to orthodontic force, with consideration of deleterious effects including enamel decalcification. Growth modification of skeletal areas distant from the dentition as a component of orthodontic treatment is discussed in detail in [Chapters 13 and 14](#), drawing on the background of normal growth provided in [Chapters 2 through 4](#) and [etiologic considerations in Chapter 5](#). Applications of distraction osteogenesis to generate new bone are described in the clinical chapters for children, adolescents, and adults.

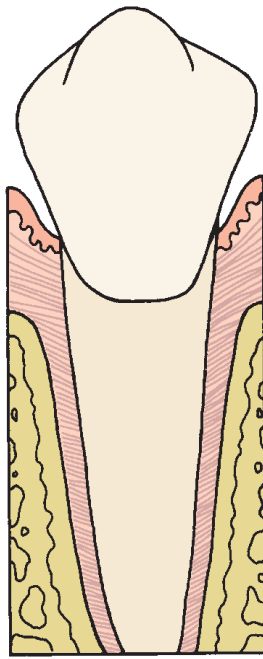
### Periodontal Ligament Structure and Function

Each tooth is attached to and separated from the adjacent alveolar bone by a heavy collagenous supporting structure, the PDL. Under normal circumstances, the PDL occupies a space approximately 0.5 mm in width around all parts of the root. By far the major component of the ligament is a network of parallel collagenous fibers, inserting into cementum of the root surface on one side and into a relatively dense bony plate, the lamina dura, on the other side. These supporting fibers run at an angle, attaching farther apically on the tooth than on the adjacent alveolar bone. This arrangement, of course, resists the displacement of the tooth expected during normal function ([Fig. 8.1](#)).

Although most of the PDL space is taken up with the collagenous fiber bundles that constitute the ligamentous attachment, two other major components of the ligament must be considered. These are (1) the cellular elements, including mesenchymal cells of various types along with vascular and neural elements, and (2) the tissue fluids. Both play an important role in normal function and in making orthodontic tooth movement possible.

The principal cellular elements in the PDL are undifferentiated mesenchymal cells and their progeny in the form of fibroblasts and osteoblasts. The collagen of the ligament is constantly being remodeled and renewed during normal function. The same cells can serve both as fibroblasts, producing new collagenous matrix materials, and fibroclasts, destroying previously produced collagen.<sup>1</sup> Remodeling and recontouring of the bony socket and the cementum of the root is also constantly being carried out, although on a smaller scale, as a response to normal function.

Fibroblasts in the PDL have properties similar to those of osteoblasts, and new alveolar bone probably is formed by osteoblasts



• **Fig. 8.1** Diagrammatic representation of periodontal structures (*pale red*). Note the angulation of the periodontal ligament fibers.

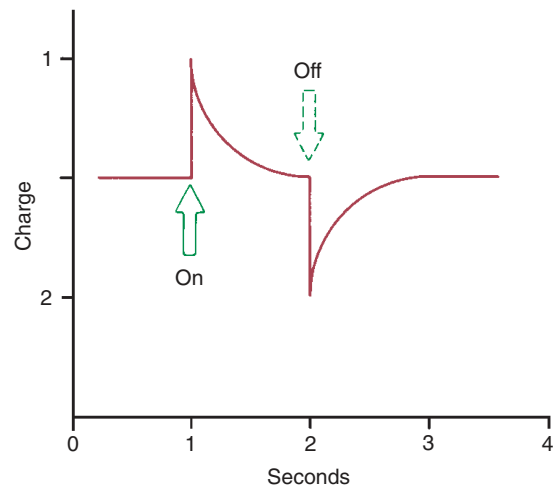
that differentiated from the local cellular population. Recent research indicates that differentiation of PDL fibroblasts is dependent on the amount of mechanical strain, and that calcitonin induces this differentiation.<sup>2</sup> Bone and cementum are removed by specialized osteoclasts and cementoclasts, respectively. These multinucleated giant cells are quite different from the osteoblasts and cementoblasts that produce bone and cementum. Despite years of investigation, their origin remains controversial. Most are of hematogenous origin, differentiating within the PDL space from circulating precursor cells; some may be derived from stem cells found in the local area.<sup>3</sup>

Although the PDL is not highly vascular, it does contain blood vessels and cells from the vascular system. Nerve endings are also found within the ligament, both the unmyelinated free endings associated with perception of pain and the more complex receptors associated with pressure and positional information (proprioception).

Finally, it is important to recognize that the PDL space is filled with fluid. This fluid is the same as that found in all other tissues, ultimately derived from the vascular system. A fluid-filled chamber with retentive but porous walls is a description of a shock absorber, and in normal function the fluid allows the PDL space to play just this role.

### Response to Normal Function

During masticatory function, the teeth and periodontal structures are subjected to intermittent heavy forces. Tooth contacts last for 1 second or less; forces are quite heavy, ranging from 1 or 2 kg while soft substances are being chewed to as much as 50 kg against a more resistant object. When a tooth is subjected to heavy loads of this type, quick displacement of the tooth within the PDL space is prevented by the incompressible tissue fluid. Instead, the force is transmitted to the alveolar bone, which bends in response.



• **Fig. 8.2** Piezoelectricity: When a force is applied to a crystalline structure such as bone or collagen, a flow of current is produced that quickly dies away. When the force is released, an opposite current flow is observed. This piezoelectric effect results from migration of electrons within the crystal lattice as it is distorted by applied force and then returns to its original form when the force is removed.

The extent of bone bending during normal function of the jaws (and other skeletal elements of the body) is often not appreciated. The body of the mandible bends as the mouth is opened and closed, even without heavy masticatory loads. On wide opening, the distance between the mandibular molars decreases by 2 to 3 mm. In heavy function, individual teeth are slightly displaced as the bone of the alveolar process bends to allow this to occur, and bending stresses are transmitted over considerable distances. Bone bending in response to normal function generates piezoelectric currents (Fig. 8.2) that appear to be an important stimulus to skeletal regeneration and repair (see further discussion later in this chapter). This is the mechanism by which bony architecture is adapted to functional demands.

Very little of the fluid within the PDL space is squeezed out during the first second of pressure application. If pressure against a tooth is maintained, however, the fluid is rapidly expressed, and the tooth displaces within the PDL space, compressing the ligament itself against adjacent bone. Not surprisingly, this hurts. Pain is normally felt after 3 to 5 seconds of heavy force application, indicating that the fluids are expressed and crushing pressure is applied against the PDL in this amount of time (Table 8.1). The resistance provided by tissue fluids allows normal mastication, with its force applications of 1 second or less, to occur without pain.

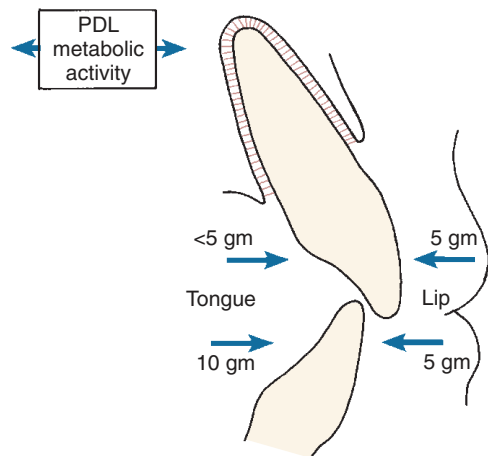
Although the PDL is beautifully adapted to resist forces of short duration, it rapidly loses its adaptive capability as the tissue fluids are squeezed out of its confined area. Prolonged force, even of low magnitude, produces a different physiologic response—remodeling of the adjacent bone. Orthodontic tooth movement is made possible by the application of prolonged forces. In addition, light prolonged forces in the natural environment—forces from the lips, cheeks, or tongue resting against the teeth—have the same potential as orthodontic forces to cause the teeth to move to a different location (see the discussion of equilibrium factors in Chapter 5).



**TABLE 8.1** Physiologic Response to Heavy Pressure Against a Tooth

Time (seconds)	Event
<1	PDL fluid incompressible, alveolar bone bends, piezoelectric signal generated
1-2	PDL fluid expressed, tooth moves within PDL space
3-5	PDL fluid squeezed out, tissues compressed; immediate pain if pressure is heavy

*PDL*, Periodontal ligament.



• **Fig. 8.3** Resting pressures from the lips or cheeks and tongue are usually not balanced. In some areas, as in the mandibular anterior, tongue pressure is greater than lip pressure. In other areas, as in the maxillary incisor region, lip pressure is greater. Active stabilization produced by metabolic effects in the periodontal ligament (*PDL*) probably explains why teeth are stable in the presence of imbalanced pressures that would otherwise cause tooth movement.

**Role of the Periodontal Ligament in Eruption and Stabilization of the Teeth**

The phenomenon of tooth eruption makes it plain that forces generated within the PDL itself can produce tooth movement. After a tooth emerges into the mouth, further eruption depends on metabolic events within the PDL, including but perhaps not limited to formation, cross-linkage, and maturational shortening of collagen fibers (see Chapter 3). This process continues, although at a reduced rate, into adult life. A tooth whose antagonist has been extracted will often begin to erupt again after many years of apparent quiescence.

The continuing presence of this mechanism indicates that it may produce not only eruption of the teeth under appropriate circumstances but also active stabilization of the teeth against prolonged forces of light magnitude. It is commonly observed that light prolonged pressures against the teeth are not in perfect balance, as would seem to be required if tooth movement were not to occur (Fig. 8.3). The ability of the PDL to generate a force and thereby contribute to the set of forces that determine the equilibrium situation probably explains this.

Active stabilization also implies a threshold for orthodontic force, because forces below the stabilization level would be expected to be ineffective. The threshold, of course, would vary depending on the extent to which existing soft tissue pressures were already being resisted by the stabilization mechanism. In some experiments, the threshold for orthodontic force, if one was found at all, appeared to be extremely low. In other circumstances, a somewhat higher threshold, but still one of only a few grams, seems to exist. The current concept is that active stabilization can overcome prolonged forces of a few grams at most, perhaps up to the 5 to 10 gm/cm<sup>2</sup> often observed as the magnitude of unbalanced soft tissue resting pressures.

**Periodontal Ligament and Bone Response to Sustained Force**

The response to sustained force against the teeth is a function of force magnitude: heavy forces lead to rapidly developing pain, necrosis of cellular elements within the PDL, and the phenomenon (discussed in more detail later) of “undermining resorption” of alveolar bone near the affected tooth. Lighter forces are compatible with survival of cells within the PDL and a remodeling of the tooth socket by a relatively painless “frontal resorption” of the tooth socket. In orthodontic practice, the objective is to produce tooth movement as much as possible by frontal resorption, recognizing that some areas of PDL necrosis and undermining resorption will probably occur despite efforts to prevent this.

**Biologic Control of Tooth Movement**

Before discussing in detail the response to orthodontic force, it is necessary to consider the biologic control mechanisms that lead from the stimulus of sustained light force to the response of alveolar bone remodeling that allows tooth movement. Two possible control elements, biologic electricity and pressure–tension in the PDL that affects blood flow, are contrasted in the two major theories of orthodontic tooth movement. The bioelectric theory relates tooth movement at least in part to changes in bone metabolism controlled by biologic electricity that are produced by light pressure against the teeth. The pressure–tension theory relates tooth movement to cellular changes produced by chemical messengers, traditionally thought to be generated by alterations in blood flow through the PDL and/or release of chemical messengers from damaged cells in the PDL. Pressure and tension within the PDL, by reducing (pressure) or increasing (tension) the diameter of blood vessels in the ligament space, could certainly alter blood flow, and disruption of cells occurs when soft tissues are stressed. The electricity and chemical messenger theories are neither incompatible nor mutually exclusive, and it appears that both mechanisms may play a part in the biologic control of tooth movement, but chemical messengers play a dominant role.

**Biologic Electricity**

Electric signals that might initiate tooth movement initially were thought to be piezoelectric. Piezoelectricity is a phenomenon observed in many crystalline materials in which a deformation of the crystal structure created by external force produces a flow of electric current as electrons are displaced from one part of the crystal lattice to another. The piezoelectricity of many inorganic crystals, including those in bone, has been recognized for many years. Organic crystals also can be piezoelectric, and collagen crystals in the PDL have this property.

Piezoelectric signals have two unusual characteristics: (1) a quick decay rate (i.e., when a force is applied, a piezoelectric signal is created in response that quickly dies away to zero even though the force is maintained) and (2) the production of an equivalent signal, opposite in direction, when the force is released (see Fig. 8.2).

Both of these characteristics are explained by the migration of electrons within the crystal lattice as it is distorted by pressure. When the crystal structure is deformed, electrons migrate from one location to another and an electric current flow is observed. As long as the force is maintained, the crystal structure is stable and no further electric events are observed. When the force is released, however, the crystal returns to its original shape, and a reverse flow of electrons is seen. With this arrangement, rhythmic activity would produce a constant interplay of current flows in one direction and then the other that would be measured as amperes, whereas occasional application and release of force would produce only occasional signal of this type.

Ions in the fluids that bathe living bone interact with the complex electric field generated when the bone bends, causing electric signals in the form of volts as well as temperature changes. As a result, both convection and conduction currents can be detected in the extracellular fluids, and the currents are affected by the nature of the fluids. The small voltages that are observed are called the “streaming potential.” These voltages, although different from piezoelectric current flows, have in common their rapid onset and alteration as changing stresses are placed on the bone.

There is also a reverse piezoelectric effect. Not only will the application of force cause distortion of crystalline structure and with it an electric signal, but also application of an electric field can cause a crystal to deform and produce force in doing so. Reverse piezoelectricity has no place in natural control systems, at least as far as is presently known, but there are intriguing possibilities for use of external electric fields to promote bone healing and regeneration after injury.<sup>4</sup>

There is no longer any doubt that piezoelectricity is important in the general maintenance of the skeleton. Without such signals, bone mineral is lost and general skeletal atrophy ensues—a situation that has proved troublesome for astronauts, whose bones no longer flex in a weightless environment as they would under normal gravity. Signals generated by the bending of alveolar bone during normal chewing almost surely are important for maintenance of the bone around the teeth.

On the other hand, sustained force of the type used to induce orthodontic tooth movement does not produce piezoelectric or other types of stress-generated signals. As long as the force is sustained, nothing happens. If stress-generated signals were important in producing the bone remodeling associated with orthodontic tooth movement, a vibrating application of pressure would be advantageous. Although earlier experiments indicated little or no advantage in using vibration to generate piezoelectric signals over sustained force for the movement of teeth,<sup>5</sup> this idea was revived in the early 21st century and has been heavily promoted in recent years. It is discussed later in the section of this chapter on possibilities for accelerating tooth movement, where the conclusion still is that vibratory signals have little if anything to do with the response to orthodontic force and the rate of tooth movement.

Electromagnetic fields also can affect cell membrane potentials and permeability and thereby trigger changes in cellular activity. In animal experiments, a pulsed electromagnetic field increased the rate of tooth movement, apparently by shortening the initial “lag phase” before tooth movement begins,<sup>6</sup> but this has not been demonstrated in human subjects. It was hoped 25 years ago that

the fields generated by small magnets attached to the teeth could change the basic biology of the response to force. It is clear now that is not the case. The idea that moving teeth with magnetic force reduces pain and mobility is not supported by evidence and is no longer taken seriously.

### **Pressure–Tension Effects in the Periodontal Ligament Space**

Chemical messengers are known to be important in the cascade of events that lead to remodeling of alveolar bone and tooth movement, and both mechanical compression of tissues and changes in blood flow can cause their release. Because the sequence of chemical changes after orthodontic force is applied does explain the course of events in tooth movement reasonably well, it remains the basis of the following discussion.

There is no doubt that sustained pressure against a tooth causes the tooth to shift position within the PDL space, compressing the ligament in some areas while stretching it in others. The mechanical effects on cells within the ligament cause the release of cytokines, prostaglandins, and other chemical messengers. In addition, blood flow is decreased where the PDL is compressed (Fig. 8.4), while it is maintained or increased where the PDL is under tension (Fig. 8.5). These alterations in blood flow also quickly create changes in the chemical environment. For instance, oxygen levels decrease on the compressed area and carbon dioxide (CO<sub>2</sub>) levels increase, while the reverse occurs on the tension side. These chemical changes, acting either directly or by stimulating the release of other biologically active agents, then would stimulate cellular differentiation and activity. In essence, this view of tooth movement shows three stages: (1) initial compression of tissues and alterations in blood flow associated with pressure within the PDL, (2) the formation and/or release of chemical messengers, and (3) activation of osteoblasts and osteoclasts, leading to remodeling of alveolar bone.

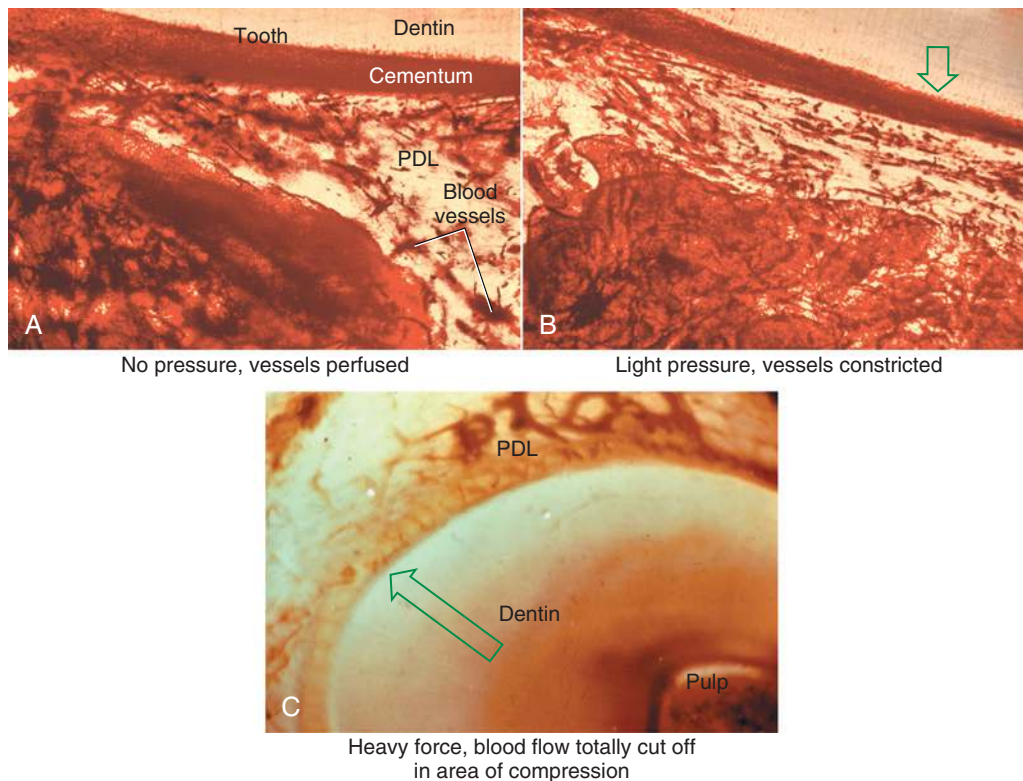
## **Effects on the Response to Orthodontic Force**

### **Sequence of Events**

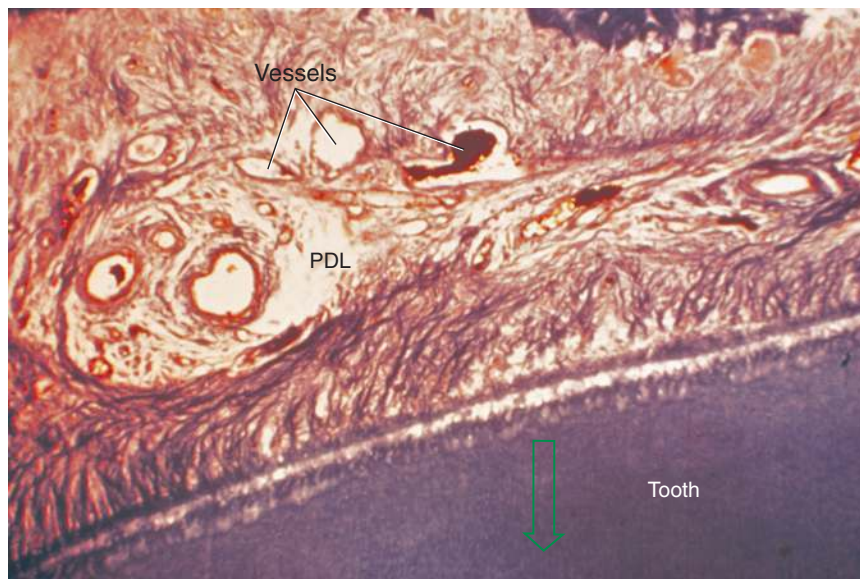
The heavier the sustained pressure, the greater should be the reduction in blood flow through compressed areas of the PDL, up to the point that the vessels are totally collapsed and no further blood flows (Fig. 8.6). That this theoretical sequence actually occurs has been demonstrated in animal experiments, in which increasing the force against a tooth causes decreasing perfusion of the PDL on the compression side (see Figs. 8.4 and 8.5).<sup>7</sup> Let us consider the time course of events after application of orthodontic force, contrasting what happens with heavy versus light force (Table 8.2).

When light but prolonged force is applied to a tooth, blood flow through the partially compressed PDL decreases as soon as fluids are expressed from the PDL space and the tooth moves in its socket (i.e., in a few seconds). Within a few hours at most, the resulting change in the chemical environment produces a different pattern of cellular activity. Animal experiments have shown that increased levels of cyclic adenosine monophosphate (cAMP), the “second messenger” for many important cellular functions and cell differentiation, appear after about 4 hours of sustained pressure. This amount of time to produce a response correlates rather well with the human response to removable appliances. If a removable appliance is worn less than 4 to 6 hours per day, it will produce no orthodontic effects. Above this duration threshold, tooth movement does occur.

What happens in the first hours after sustained force is placed against a tooth, between the onset of pressure and tension in the



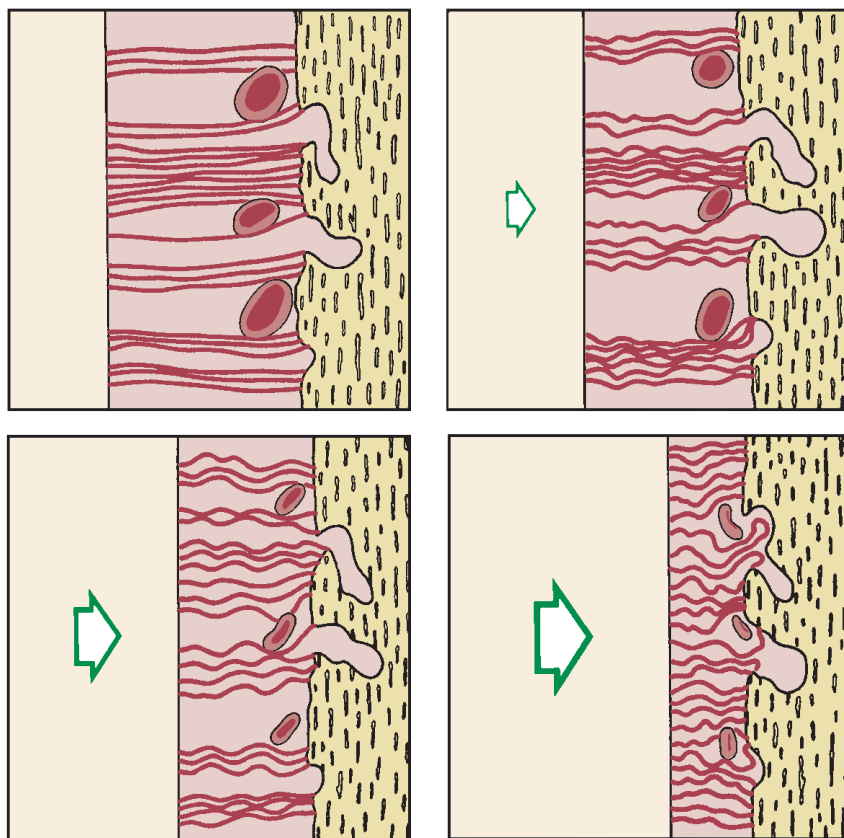
• **Fig. 8.4** In experimental animals, changes in blood flow in the periodontal ligament (PDL) can be observed by perfusing India ink into the vascular system while the animal is killed. The vessels are filled with India ink, so their size can be seen easily. (A) Normal perfusion of the PDL. Note the dark areas indicating blood flow. (B) A 50-gm force is compressing the PDL. Note the decreased amount of perfusion, but there still is blood flow through the compressed area. (C) Heavy force with almost complete obliteration of blood flow in the compressed area. This specimen is seen in horizontal section, with the tooth root on the left and the pulp chamber just visible in the upper left. The PDL is below and to the right. Cells disappear in the compressed areas, and the area is sometimes said to be hyalinized because of its resemblance to hyaline cartilage. (Courtesy Dr. F.E. Khouw.)



Tension side: fibers stretched, vessels open wide

• **Fig. 8.5** On the side away from the direction of tooth movement, the periodontal ligament (PDL) space is enlarged and blood vessels dilate. Expanded vessels that are only partially filled can be seen on the tension side of the PDL. (Courtesy Dr. F.E. Khouw.)





• **Fig. 8.6** Diagrammatic representation of the increasing compression of blood vessels as pressure increases in the periodontal ligament. At a certain magnitude of continuous pressure, blood vessels are totally occluded and a sterile necrosis of periodontal ligament tissue ensues.

**TABLE 8.2**

**Physiologic Response to Sustained Pressure Against a Tooth**

TIME		Event
Light Pressure	Heavy Pressure	
	<1 second	PDL fluid incompressible, alveolar bone bends, piezoelectric signal generated
	1-2 seconds	PDL fluid expressed, tooth moves within PDL space
	3-5 seconds	Blood vessels within PDL partially compressed on pressure side, dilated on tension side; PDL fibers and cells mechanically distorted
	Minutes	Blood flow altered, oxygen tension begins to change; prostaglandins and cytokines released
	Hours	Metabolic changes occurring: chemical messengers affect cellular activity, enzyme levels change
	~4 hours	Increased cAMP levels detectable, cellular differentiation begins within PDL
	~2 days	Tooth movement beginning as osteoclasts and osteoblasts remodel bony socket
	3-5 seconds	Blood vessels within PDL occluded on pressure side
	Minutes	Blood flow cut off to compressed PDL area
	Hours	Cell death in compressed area
	3-5 days	Cell differentiation in adjacent narrow spaces, undermining resorption begins
	7-14 days	Undermining resorption removes lamina dura adjacent to compressed PDL, tooth movement occurs

cAMP, Cyclic adenosine monophosphate; PDL, periodontal ligament.

PDL and the appearance of second messengers a few hours later? Experiments have shown that prostaglandin and interleukin-1 beta levels increase within the PDL within a short time after the application of pressure, and it is clear now that both are important mediators of the cellular response. Because prostaglandins are released when cells are mechanically deformed, it appears that prostaglandin release is a primary rather than a secondary response to pressure. At the molecular level, we are beginning to understand how these effects are created. Focal adhesion kinase (FAK) appears to be the mechanoreceptor in PDL cells, and its compression is at least part of the reason that prostaglandin  $E_2$  ( $PGE_2$ ) is released.<sup>8</sup> Experiments have shown that concentrations of the receptor activator of nuclear factor kappa-B ligand (RANKL) and osteoprotegerin (OPG) in gingival crevicular fluid increase during orthodontic tooth movement, which suggests that PDL cells under stress may induce the formation of osteoclasts through upregulation of RANKL.<sup>9</sup> Other chemical messengers, particularly members of the cytokine family but also nitric oxide (NO) and other regulators of cellular activity, also are involved. Because drugs of various types can affect both prostaglandin levels and other potential chemical messengers, pharmacologic modification of the response to orthodontic force is more than just a theoretical possibility (see further discussion later).

For a tooth to move, osteoclasts must be formed so that they can remove bone from the area adjacent to the compressed part of the PDL. Osteoblasts also are needed to form new bone on the tension side and remodel resorbed areas on the pressure side. Prostaglandins have the interesting property of stimulating both osteoclastic and osteoblastic activity, making them particularly suitable as a mediator of tooth movement. If parathyroid hormone is injected, osteoclasts can be induced in only a few hours, but the response is much slower when mechanical deformation of the PDL is the stimulus, and it can be up to 48 hours before the first osteoclasts appear within and adjacent to the compressed PDL. Studies of cellular kinetics indicate that they arrive in two waves, implying that some (the first wave) may be derived from a local cell population, whereas others (the larger second wave) are brought in from distant areas via blood flow.<sup>10</sup> These cells attack the lamina dura, the layer of dense bone on the outer wall of the tooth socket, removing bone in the process of “frontal resorption,” and tooth movement begins soon thereafter. At the same time, but lagging somewhat behind so that the PDL space becomes enlarged, osteoblasts (recruited locally from progenitor cells in the PDL) form bone on the tension side and begin remodeling activity on the pressure side.<sup>11</sup>

The course of events is different if the sustained force against the tooth is great enough to totally occlude blood vessels and cut off the blood supply to an area within the PDL. When this happens, rather than cells within the compressed area of the PDL being stimulated, a sterile necrosis ensues within the compressed area. In clinical orthodontics it is difficult to avoid pressure that produces at least some avascular areas in the PDL, and it has been suggested that releasing pressure against a tooth at intervals, while maintaining the pressure for enough hours to produce the biologic response, could help in maintaining tissue vitality. This seems to be the mechanism by which chewing on a plastic wafer or chewing gum after orthodontic force is applied reduces pain—chewing force briefly displaces the tooth and allows a spurt of blood into compressed areas, thereby reducing the size of necrotic areas in the PDL.

Because of its histologic appearance as the cells disappear, an avascular area in the PDL traditionally has been referred to as

*hyalinized* (see Fig. 8.4). Despite the name, the process has nothing to do with the formation of hyaline connective tissue. It represents the inevitable loss of all cells when the blood supply is totally cut off. When this happens, remodeling of bone bordering the necrotic area of the PDL must be accomplished by cells derived from adjacent undamaged areas.

After a delay of several days, cellular elements begin to invade the necrotic (hyalinized) area. More importantly, osteoclasts appear within the adjacent bone marrow spaces and begin an attack on the underside of the bone immediately adjacent to the necrotic PDL area (Fig. 8.7). This process is appropriately described as *undermining resorption*, because the attack is from the underside of the lamina dura. When hyalinization and undermining resorption occur, an inevitable delay in tooth movement results. This is caused first by a delay in stimulating differentiation of cells within the marrow spaces, and second because a considerable thickness of bone must be removed from the underside before any tooth movement can take place. The different time course of tooth movement when frontal resorption is compared with undermining resorption is shown graphically in Fig. 8.8.


Not only is tooth movement more efficient when areas of PDL necrosis are avoided, but pain is also lessened. However, even with light forces, small avascular areas are likely to develop in the PDL, and tooth movement will be delayed until these can be removed by undermining resorption. The smooth progression of tooth movement with light force shown in Fig. 8.8 may be an unattainable ideal when continuous force is used. In clinical practice, tooth movement usually proceeds in a more stepwise fashion because of the inevitable areas of undermining resorption.

### Effects of Force Distribution

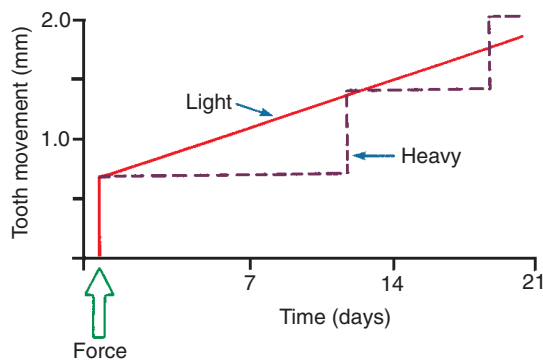
From the previous discussion, it is apparent that the optimum force levels for orthodontic tooth movement should be just high enough to stimulate cellular activity without completely occluding blood vessels in the PDL. Both the amount of force delivered to a tooth and the area of the PDL over which that force is distributed are important in determining the biologic effect. The PDL response is determined not by force alone, but by force per unit area, or pressure. Because the distribution of force within the PDL, and therefore the pressure, differs with different types of tooth movement, it is necessary to specify the type of tooth movement as well as the amount of force in discussing optimum force levels for orthodontic purposes.

The simplest form of orthodontic movement is tipping. Tipping movements are produced when a single force (e.g., a spring extending from a removable appliance) is applied against the crown of a tooth. When this is done, a tipping moment is created, and the tooth rotates around its *center of resistance*, a point located about halfway down the root. (A further discussion of the center of resistance and its control follows in Chapter 9.) When the tooth rotates in this fashion, the PDL is compressed near the root apex on the same side as the spring and at the crest of the alveolar bone on the opposite side from the spring (Fig. 8.9). Maximum pressure in the PDL is created at the alveolar crest and at the root apex. Progressively less pressure is created as the center of resistance is approached, and there is minimum pressure at that point.

In tipping, only one-half of the PDL area that could be loaded actually is. As shown in Fig. 8.9, the “loading diagram” consists of two triangles, covering half of the total PDL area. On the other hand, pressure in the two areas where it is concentrated is high in relation to the force applied to the crown. For this reason, forces used to tip teeth must be kept quite low. Both experiments with



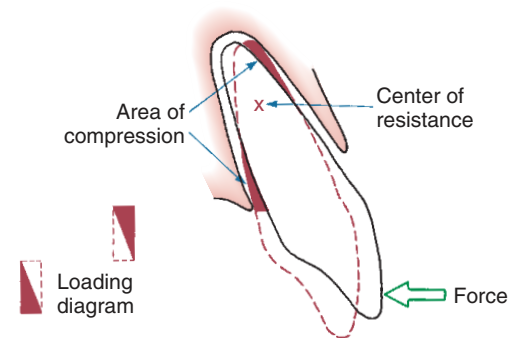
• **Fig. 8.7** Histologic specimen of compressed periodontal ligament (PDL) area after several days. When the PDL is compressed to the point that blood flow is totally cut off, differentiation of osteoclasts within the PDL space is not possible. After a delay of several days, osteoclasts within adjacent marrow spaces attack the underside of the lamina dura in the process called *undermining resorption*. The scalloped underside seen in this image indicates active osteoclast activity against that area. (Courtesy Dr. F.E. Khouw.)



• **Fig. 8.8** Diagrammatic representation of the time course of tooth movement with frontal resorption versus undermining resorption. With frontal resorption, a steady attack on the outer surface of the lamina dura results in smooth continuous tooth movement. With undermining resorption, there is a delay until the bone adjacent to the tooth can be removed. At that point, the tooth “jumps” to a new position, and if heavy force is maintained, there will again be a delay until a second round of undermining resorption can occur.

animals and clinical experience with humans suggest that tipping forces for a single-rooted tooth should not exceed approximately 50 gm, and lighter forces are better for smaller teeth (which have a smaller PDL).

If two forces are applied simultaneously to the crown of a tooth so that there is no net tipping moment, the tooth can be moved bodily (translated)—that is, the root apex and crown move in the same direction the same amount. In this case, the total PDL area is loaded uniformly (Fig. 8.10). It is apparent that to produce the same pressure in the PDL and therefore the same biologic response, twice as much force would be required for bodily movement as



• **Fig. 8.9** Application of a single force to the crown of a tooth creates rotation around a point approximately halfway down the root. Heavy pressure is felt at the root apex and at the crest of the alveolar bone, but pressure decreases to zero at the center of resistance. The loading diagram therefore consists of two triangles as shown.

for tipping. To move a tooth so that it is partially tipped and partially translated would require forces intermediate between those needed for pure tipping and bodily movement (Table 8.3).

In theory, forces to produce rotation of a tooth around its long axis could be much larger than those to produce other tooth movements, because the force could be distributed over the entire PDL rather than over a narrow vertical strip. In fact, however, it is essentially impossible to apply a rotational force so that the tooth does not also tip in its socket, and when this happens, an area of compression is created just as in any other tipping movement. For this reason, appropriate forces for rotation are similar to those for tipping.

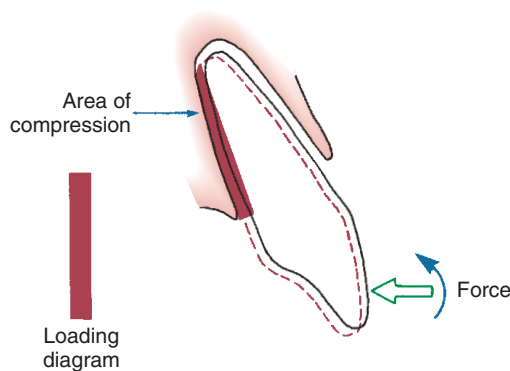
Extrusion and intrusion are also special cases. Extrusive movements ideally would produce no areas of compression within the



**TABLE 8.3 Optimum Forces for Orthodontic Tooth Movement**

Type of Movement	Force <sup>a</sup> (gm)
Tipping	35-60
Bodily movement (translation)	70-120
Root uprighting	50-100
Rotation	35-60
Extrusion	35-60
Intrusion	10-20

<sup>a</sup>Values depend in part on the size of the tooth: smaller values are appropriate for incisors, higher values for multirooted posterior teeth.



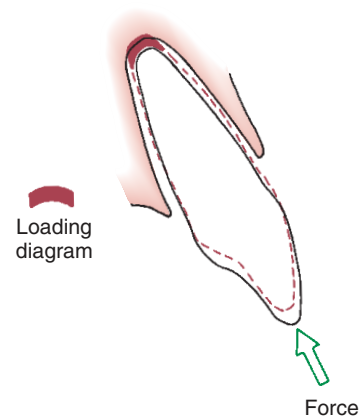
• **Fig. 8.10** Translation or bodily movement of a tooth requires that the periodontal ligament space be loaded uniformly from alveolar crest to apex, creating a rectangular loading diagram. Twice as much force applied to the crown of the tooth would be required to produce the same pressure within the periodontal ligament for bodily movement as compared with tipping.

PDL, only tension. Like rotation, this is more a theoretical than a practical possibility, because if the tooth tipped at all while being extruded, areas of compression would be created. Even if compressed areas could be avoided, heavy forces in pure tension would be undesirable unless the goal was to extract the tooth rather than to bring alveolar bone along with the tooth. Extrusive forces, such as rotation, should be about the same magnitude as those for tipping.

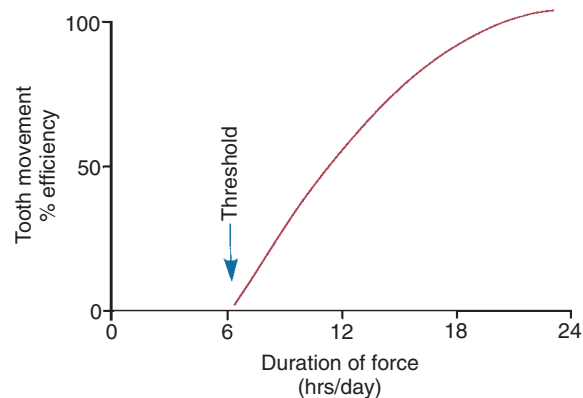
For many years, it was considered essentially impossible to produce orthodontic intrusion of teeth. Now it is clear that clinically successful intrusion can be accomplished, but only if very light forces are applied to the teeth. Light force is required for intrusion because the force will be concentrated in a small area at the tooth apex (Fig. 8.11). As with extrusion, the tooth probably will tip somewhat as it is intruded, but the force still will be concentrated at the apex. Only if the force is kept very light can intrusion be expected.

**Effects of Force Duration and Force Decay**

The key to producing orthodontic tooth movement is the application of sustained force, which does not mean that the force must be absolutely continuous. It does mean that the force must be present



• **Fig. 8.11** When a tooth is intruded, the force is concentrated over a small area at the apex. For this reason, extremely light forces are needed to produce appropriate pressure within the periodontal ligament during intrusion.



• **Fig. 8.12** Theoretical plot of tooth movement efficiency versus duration of force in hours per day. Continuous force, 24 hours per day, produces the most efficient tooth movement, but successful tooth movement can be produced by shorter durations, with a threshold at about 6 hours.

for a considerable percentage of the time, certainly hours rather than minutes per day. As we have noted previously, animal experiments suggest that only after force is maintained for approximately 4 hours do cyclic nucleotide levels in the PDL increase, indicating that this duration of pressure is required to produce the “second messengers” needed to stimulate cellular differentiation.

Clinical experience suggests that there is a threshold for force duration in humans in the 4- to 8-hour range and that increasingly effective tooth movement is produced if force is maintained for longer durations. Although no firm experimental data are available, a plot of efficiency of tooth movement as a function of force duration would probably look like Fig. 8.12. Continuous forces, produced by fixed appliances that are not affected by what the patient does, produce more tooth movement than removable appliances unless the removable appliance is present almost all the time. Removable appliances worn for decreasing fractions of time produce decreasing amounts of tooth movement.

Duration of force has another aspect, related to how force magnitude changes as the tooth responds by moving. Only in theory is it possible to make a perfect spring, one that would deliver the same force day after day, no matter how much or how

little the tooth moved in response to that force. In reality, some decline in force magnitude (i.e., force decay) is noted with even the springiest device after the tooth has moved a short distance (although with the superelastic nickel–titanium materials discussed in Chapter 9, the decrease is amazingly small). With many orthodontic devices, the force may drop all the way to zero. From this perspective, orthodontic force duration is classified (Fig. 8.13) by the rate of decay as:

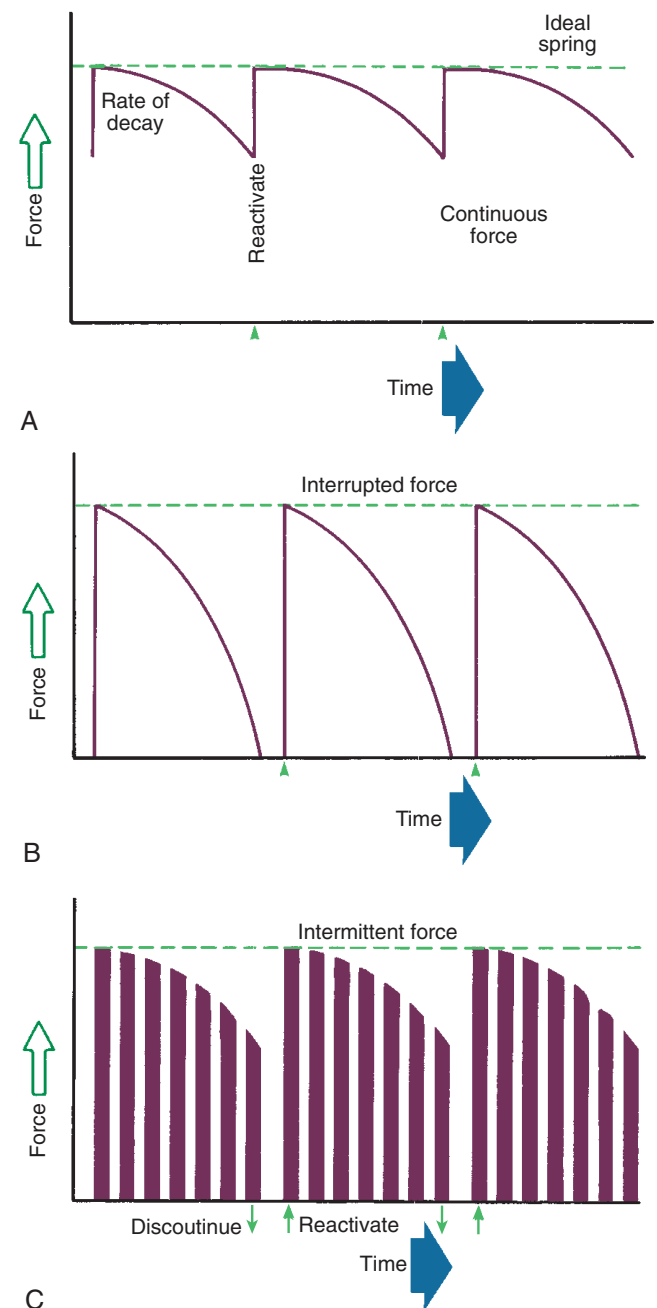
- Continuous—force maintained at some appreciable fraction of the original from one patient visit to the next
- Interrupted—force levels decline to zero between activations
- Intermittent—force levels decline abruptly to zero intermittently, when a removable orthodontic appliance or elastic traction to a fixed appliance is removed by the patient, and then return to the original level some time later when the appliance is reinserted or the elastics are replaced. When tooth movement occurs, force levels with a removable appliance will decrease as they would with a fixed appliance (i.e., force decay occurs, often all the way to zero before the removable appliance is reactivated). It is quite possible, therefore that intermittent force can also be interrupted.

Intermittent forces are produced by all patient-activated appliances such as removable plates, functional appliances, headgear, and elastics. Forces generated during normal function (e.g., chewing, swallowing, speaking) can be viewed as a special case of intermittently applied forces, most of which are not maintained for enough hours per day to have significant effects on the position of the teeth.

There is an important interaction between force magnitude and how rapidly the force declines as the tooth responds. Consider first the effect of a nearly continuous force. If this force is quite light, a relatively smooth progression of tooth movement will result from frontal resorption. If the continuous force is heavy, however, tooth movement will be delayed until undermining resorption can remove the bone necessary to allow the tooth movement. At that time, the tooth will change its position rapidly, and the constant force will again compress the tissues, preventing repair of the PDL and creating the need for further undermining resorption and so on. Such a heavy continuous force can be quite destructive to both the periodontal structures and the tooth itself.

Consider now the effect of forces that decay fairly rapidly, so that the force declines to zero after the tooth moves only a short distance. If the initial force level is relatively light, the tooth will move a small amount by frontal resorption and then will remain in that position until the appliance is activated again. If the force level is heavy enough to produce undermining resorption, the tooth will move when the undermining resorption is complete. Then, because the force has dropped to zero at that point, it will remain in that position until the next activation. Although the original force is heavy, after the tooth moves there is a period for regeneration and repair of the PDL before force is applied again.

Theoretically, there is no doubt that light continuous forces produce the most efficient tooth movement. Despite the clinician's best efforts to keep forces light enough to produce only frontal resorption, some areas of undermining resorption are probably produced in every clinical patient. The heavier forces that produce this response are physiologically acceptable only if the force level quickly drops to zero so that there is a period of repair and regeneration before the next activation or if the force decreases at least to the point that no second and third rounds of undermining resorption occur.



• **Fig. 8.13** Diagrammatic representation of force decay. (A) An ideal spring would maintain the same amount of force regardless of distance a tooth had moved, but with real springs the force decays at least somewhat as tooth movement occurs. Forces that are maintained between activations of an orthodontic appliance, even though the force declines, are defined as continuous. (B) In contrast, interrupted forces drop to zero between activations. (C) Intermittent forces fall to zero when a removable appliance is taken out, only to resume when the appliance is reinserted into the mouth. These forces also decay as tooth movement occurs.

The bottom line: heavy continuous forces are to be avoided; heavy intermittent forces, although less efficient, can be clinically acceptable. To say it another way: the more perfect the spring in the sense of its ability to provide continuous force, the more careful the clinician must be that only light force is applied. Some of the cruder springs used in orthodontic treatment have the paradoxical

virtue of producing forces that rapidly decline to zero and are thus incapable of inflicting the biologic damage that can occur from heavy continuous forces. Several clinical studies have indicated that heavy force applications may produce more tooth movement than lighter force, which can be understood only from consideration of force decay characteristics.

Experience has shown that orthodontic appliances should not be reactivated more frequently than at 3-week intervals. A 4- to 6- or 8-week appointment cycle is the usual minimum in clinical practice, and now a 6- or 8-week cycle is more typical. Undermining resorption requires 7 to 14 days (longer on the initial application of force, shorter thereafter). When this is the mode of tooth movement and when force levels decline rapidly, tooth movement is essentially complete in this length of time. The wisdom of the interval between adjustments now becomes clear. If the appliance is springy and light forces produce continuous frontal resorption, there is no need for further activation for 6 to 8 weeks. If the appliance is stiffer and undermining resorption occurs, but then the force drops to zero, the tooth movement occurs in the first 10 days or so, and there is an equal or longer period for PDL regeneration and repair before force is applied again. This repair phase is highly desirable and needed with many appliances. Activating an appliance too frequently, short-circuiting the repair process, can produce damage to the teeth or bone that a longer appointment cycle would have prevented or at least minimized.

### Drug Effects on the Response to Orthodontic Force

At present, drugs that stimulate tooth movement are unlikely to be encountered, although efforts to produce them continue. A major problem is how they would be applied to the local area where an effect on tooth movement is desired. Direct injection of prostaglandin into the PDL has been shown to increase the rate of tooth movement, but this is quite painful (a bee sting is essentially an injection of prostaglandin) and not very practical. Relaxin, a “pregnancy hormone” discovered in the 1980s, facilitates birth by causing a softening and lengthening of the cervix and pubic symphysis. It works by simultaneously reducing collagen synthesis and increasing collagen breakdown. Preliminary data in rats showed faster tooth movement with relaxin treatment, but a well-done, double-blinded clinical trial at the University of Florida, in which relaxin or just physiologic saline was injected adjacent to a tooth to be moved, did not show a consistent positive effect,<sup>12</sup> and further clinical trials were abandoned.

In the future, it is possible that drugs to facilitate tooth movement will become clinically useful—but there is no way to know how long it will take to develop them. Drugs aimed at increasing brain levels of acetylcholine (ACH), the key neurotransmitter in the brain, now are widely used to maintain neural function in patients with cognitive decline. Such drugs (e.g., donepezil [Aricept]) have widespread effects on other bodily functions, and perhaps might accelerate tooth movement by affecting circulating hormone levels. There is no solid information as to the effect of these powerful drugs on PDL activity, but given their effect on brain activity, using them to affect tooth movement would be hard to justify. The problem, of course, is to find something that primarily works locally.

Drugs that inhibit tooth movement as a side effect of their use for other problems, however, already are encountered frequently, although not yet prescribed for their tooth-stabilizing effect. Two types of drugs are known to depress the response to orthodontic force and may influence current treatment: prostaglandin inhibitors

for pain control (especially the more potent members of this group that are used in treatment of arthritis, such as indomethacin), and the bisphosphonates used in treatment of osteoporosis (e.g., alendronate [Fosamax], ibandronate [Boniva], risedronate [Actonel]).

### Prostaglandin Inhibitors

If PgE plays an important role in the cascade of signals that leads to tooth movement, one would expect inhibitors of its activity to affect tooth movement. Drugs that affect prostaglandin activity fall into two categories: (1) corticosteroids and nonsteroidal antiinflammatory drugs (NSAIDs) that interfere with prostaglandin synthesis and (2) other agents that have mixed agonistic and antagonistic effects on various prostaglandins.

In the body, prostaglandins are formed from arachidonic acid, which in turn is derived from phospholipids. Corticosteroids reduce prostaglandin synthesis by inhibiting the formation of arachidonic acid; NSAIDs inhibit the conversion of arachidonic acid to prostaglandins. Most over-the-counter analgesics are NSAIDs and therefore are prostaglandin inhibitors (aspirin, ibuprofen, naproxen [Aleve], and many others). The major exception is acetaminophen (Tylenol), which acts centrally rather than peripherally. This raises the interesting possibility that the medication used by many patients to control pain after orthodontic appointments could interfere with tooth movement. Fortunately, with the low doses and short durations of analgesic therapy in orthodontic patients, this does not occur, but it can become a problem in adults or children being treated chronically for arthritis pain. Control of pain related to orthodontic treatment is discussed later in more detail.

Several other classes of drugs can decrease prostaglandin levels and therefore could slow the response to orthodontic force. Tricyclic antidepressants (doxepin, amitriptyline, imipramine), antiarrhythmic agents (procaine), antimalarial drugs (quinine, quinidine, chloroquine), and methylxanthines fall into this category. In addition, the anticonvulsant drug phenytoin has been reported to decrease tooth movement in rats, and some tetracyclines (e.g., doxycycline) inhibit osteoclast recruitment, an effect similar to that of bisphosphonates.<sup>13</sup> It is possible that an unusual lack of response to orthodontic force could be encountered in patients taking any of these medications, and as mentioned earlier, there could also be an increased response with some drugs that affect neurotransmitters.

### Bisphosphonates

Osteoporosis is a problem particularly in postmenopausal women but is associated with aging in both sexes and now also is being observed in children who require long-term steroids after cancer therapy or other medical treatment. Estrogen therapy, which was used frequently in the past to prevent loss of bone in older women, now has been shown to carry significant risks and is not widely used. Estrogens have little or no effect on orthodontic treatment, but pharmacologic agents that inhibit bone resorption are a potential problem. At present, bisphosphonates, synthetic analogues of pyrophosphate that bind to hydroxyapatite in bone, are the major class of drugs for control of osteoporosis. They act as specific inhibitors of osteoclast-mediated bone resorption, so it is not surprising that the bone remodeling necessary for tooth movement is slower in patients who are taking this medication.

Bisphosphonates are a special concern for two reasons:

1. Their use has been associated with an unusual necrosis of mandibular bone. This typically occurs after extraction of a tooth or other injury to the bone, which fails to heal and becomes the center of an expanding necrotic area. Fortunately, this is rare and occurs most often in patients with metastatic

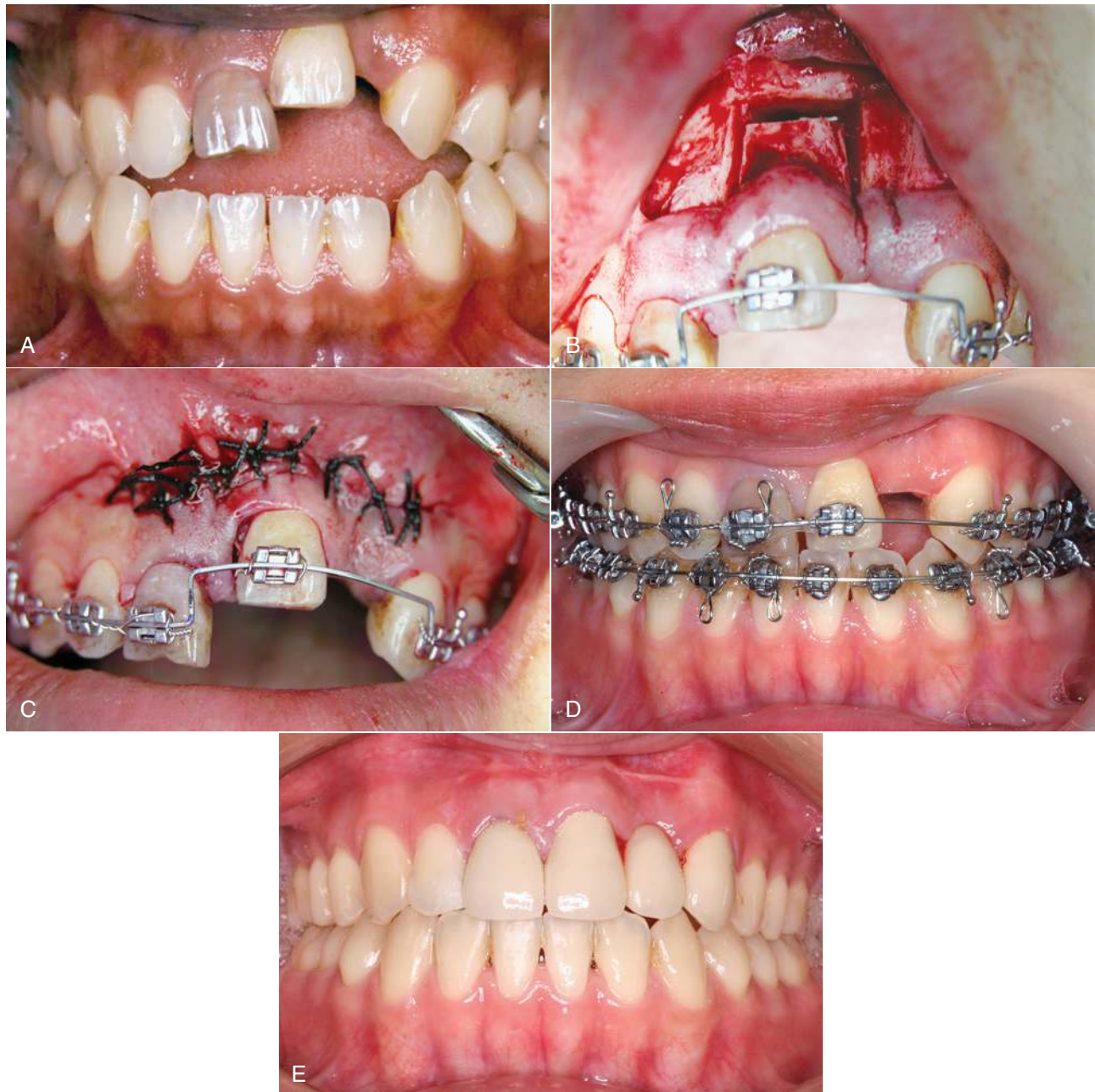

bone cancer who receive high doses of potent bisphosphonates, but elective extractions for orthodontic purposes should be avoided for a patient who has been taking any of these drugs.

2. They are incorporated into the structure of bone, then slowly eliminated over a period of years—so stopping the drug does not eliminate all of its effects. It appears that there are two elimination rates: a fast elimination from the surface of the bones within some weeks, and slower elimination from bone structure. Fortunately, most of the drug is only on the surface, which makes orthodontic treatment possible after about 3

months with no further bisphosphonate therapy.<sup>14</sup> Obviously, treatment would be possible only if the physician were willing for the patient to have a drug holiday or if the patient could be switched to raloxifene (Evista; the estrogen analogue with the greatest effect on bone), at least temporarily.

Could distraction osteogenesis (discussed in detail later) be used to move teeth in a patient who had been taking bisphosphonates for a long time? The situation then would be similar to ankylosis of all the teeth, and presumably could be approached by moving alveolar bone segments as shown in Fig. 8.14 in a



• **Fig. 8.14** An ankylosed tooth can be moved only by moving the bone to which it is attached. Distraction osteogenesis allows that to be done. (A) Age 21, maxillary central incisor that ankylosed after an accident at age 8 (the lateral incisor was lost at that time). (B) Creation of the bony segment to be moved. (C) Closure of the wound. A period of initial healing, usually 5 to 7 days, is allowed before the archwire is activated to begin movement of the segment. (D) The tooth nearly in final position, 3 weeks later. (E) Treatment completed, with prosthetic replacement of the missing lateral incisor. (Courtesy Dr. H. Chen; reprinted with permission from *Am J Orthod Dentofacial Orthop.* 2019;138:829–838.)

patient with ankylosis of a central incisor after trauma. But bone healing in patients taking bisphosphonates is problematic, and distraction osteogenesis would be a risky procedure, probably unacceptably so. Distraction also could be considered in a patient with primary failure of eruption (PFE; see Chapter 3), but this is feasible only if PFE developed after a tooth had erupted at least partially and is difficult to impossible when several posterior teeth in a quadrant are involved. In short, distraction osteogenesis to reposition an isolated ankylosed tooth or teeth is acceptable; when all or many of the teeth are affected by bisphosphonates or a syndrome, it rarely would be useful.

## Local Injury to Accelerate Tooth Movement

Because remodeling of alveolar bone is the key component of orthodontic tooth movement and bone remodeling is accelerated during wound healing (via the regional acceleratory phenomenon described by Frost),<sup>15</sup> the idea that teeth could be moved faster after local injury to the alveolar process first appeared early in the history of orthodontics. The pioneer American oral surgeon Hurler is said to have experimented with moving teeth after making cuts in alveolar bone in the late 19th century, and sporadic experiments with this continued into the early 20th century. The approach was not widely adopted, however, for several reasons that included concerns about infections and bone loss in this pre-antibiotic era.

### Corticotomy

In the mid-20th century, the German surgeon K  le revived the idea that cuts between teeth could produce faster tooth movement and introduced the term *corticotomy* to describe the technique.<sup>16</sup> After flap surgery to reflect the gingiva all the way around the arch, vertical cuts were made facially and lingually between the teeth. A banded orthodontic appliance (placed before the surgery) was activated as soon as possible, using relatively stiff archwires and wire ties to generate enough force to create greenstick fractures of the bone around the root apex and bring the teeth into alignment almost instantly. The root apex did not move, so the teeth were tipped into position, not moved bodily. The time for alignment was minutes and hours, not days and weeks. It was not used widely because many surgeons and most orthodontists thought it was too invasive, and it did not allow precise positioning of the teeth.

More recently, corticotomy was revived and reconsidered as a stimulus to a regional acceleration of bone remodeling that allows faster tooth movement, rather than movement of blocks of bone that contain a tooth. The surgical technique, with a large flap to fully expose the alveolar bone and cuts between the teeth, still is similar to K  le's, but now lighter force to move teeth more physiologically is recommended, and the surgical approach has been broadened into "accelerated osteogenic orthodontics" (AOO) by adding decortication of the facial surfaces of alveolar bone. The exposed bone is then covered with demineralized freeze-dried bone or a mixture of this with bovine bone or allograft bone; Fig. 8.15.<sup>17</sup> One of the risks of expansion of the dental arches, of course, is fenestration of the alveolar bone, and the AOO approach is said to generate new bone that allows facial movement of teeth without this risk. No data to support this claim have been presented.

In order to evaluate the outcomes of corticotomy-assisted orthodontics, as with any other type of treatment, an analysis of benefit versus cost and risk is needed. The primary benefit claimed for corticotomy is a reduction in treatment time, with facilitation of arch expansion via AOO as a secondary benefit.

After a fracture, enough bone healing to allow release of fixation takes about 6 weeks and maturation of the bone is largely completed in another 2 months. Similarly, bone remodeling after corticotomy would be accelerated for 2 to 4 months, as the regional acceleratory phenomenon declined and then disappeared. A key question, therefore, would be the extent to which the bone injury would shorten total treatment time.

Reduction of treatment time with corticotomy has been presented primarily from case reports that show a reduction in time to alignment for selected patients. The amount of time needed for alignment of crowded teeth obviously depends on the extent of crowding, but with superelastic archwires, even severe crowding rarely requires more than 5 to 6 months. If corticotomy cuts that time in half, as selected case reports suggest is the case, the 2- to 3-month reduction in total treatment time would not mean that total treatment time would be twice as fast, because only the initial alignment phase would be faster.

A second possibility for more rapid tooth movement is closure of an extraction space. For that also, faster retraction of a canine into a premolar extraction space with corticotomy cuts around the extraction site and removal of some of the bone has been reported, but the reduction in time for that phase of treatment also would not carry over into later treatment. It has been suggested that a special indication for corticotomy that included bone cuts above the root apices is intrusion, which requires remodeling of the denser bone that lies beneath the tooth roots and often takes several months. No evidence to support this claim has been presented in a peer-reviewed journal.

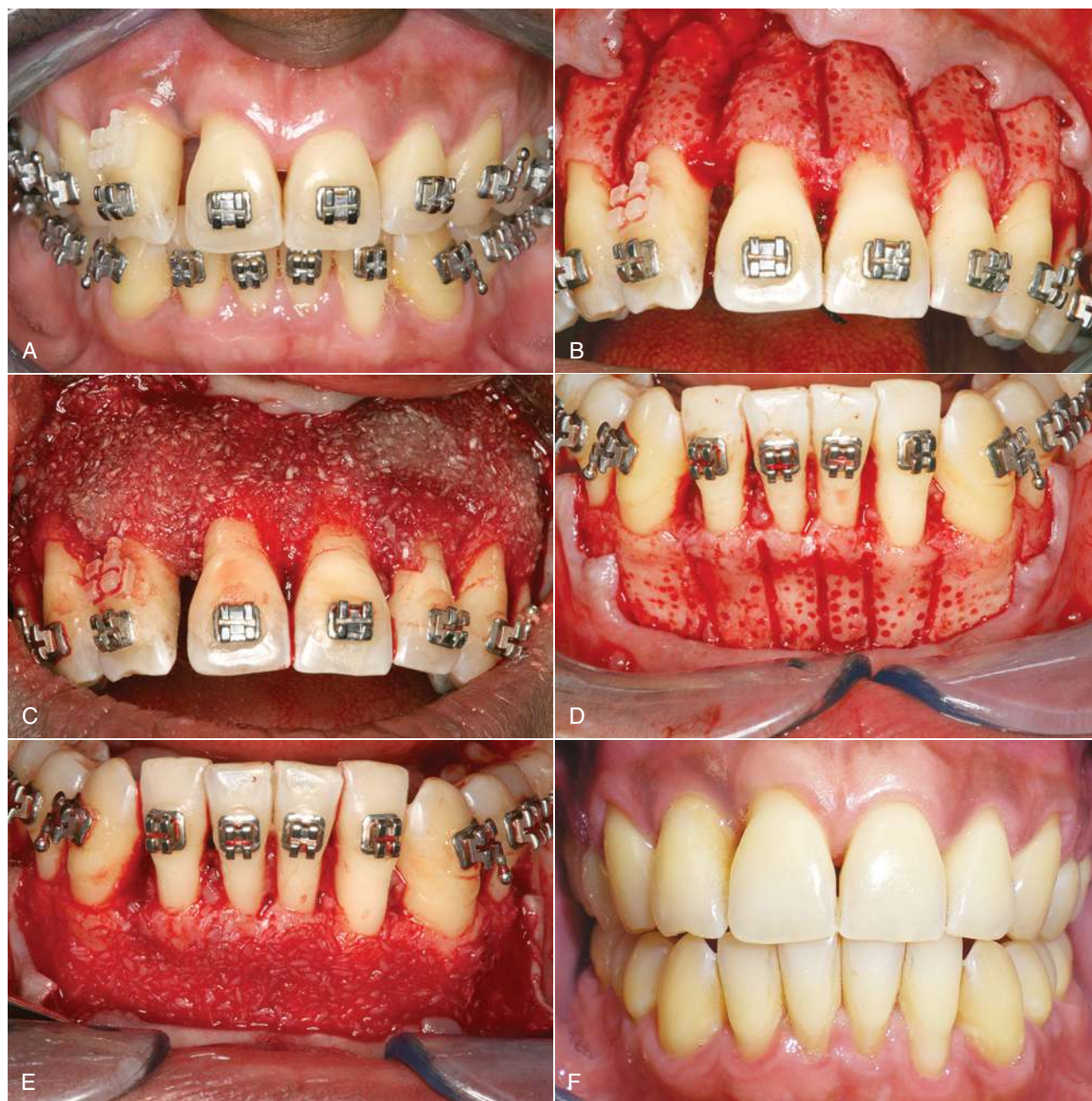In short, the benefit of AOO and corticotomy is primarily in reduction of the time to align crowded teeth without extractions. As with any procedure, that benefit must be evaluated relative to the cost and risk of the treatment. Cost, of course, includes all aspects of the "burden of treatment." In addition to the economic cost of the surgery (which can require several hours), morbidity and inconvenience of all types must be considered. Risk includes the possibility of loss of alveolar bone height, which occurs when corticotomy is done without bone grafting<sup>18</sup>; unsightly facial bruising; unfavorable changes in the appearance of the gingiva after the extensive flaps; and the possibility of gingival stripping (Fig. 8.16). What is needed but simply has not been provided is a well-documented consecutive series of patients in whom time to alignment and total treatment time are given, along with data for patient pain and what is needed for its control, and the nature and prevalence of complications.

### Modified Corticotomy: Piezocision

Given the extensive surgery and flap reflection needed for corticotomy, a reasonable question is whether less invasive surgery could be equally effective in producing faster tooth movement. In 2009 Dibart, a periodontist at Boston University, introduced a technique he called *piezocision*. In this technique, gingival incisions between crowded incisors are used only on the facial side and injury to the bone in that area is performed with a vibrating piezoelectric knife (Fig. 8.17).<sup>19</sup> Tunneling beneath the gingiva allows placement of a slurry bone graft.

In a recent randomized clinical trial (RCT) with a small sample of patients treated with the sequence of archwires in the standard Damon technique (see Chapter 10), Charavet et al documented a statistically significant shortening of treatment time (Fig. 8.18)<sup>20</sup> and concluded that replacing corticotomy with this approach can be recommended for adults. Because the reduction in treatment time they noted compares favorably with corticotomy, that seems





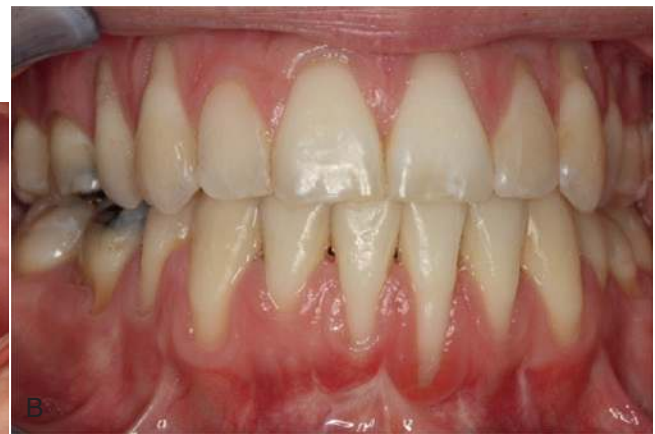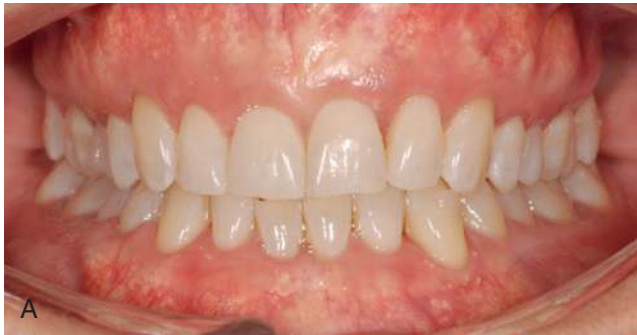• **Fig. 8.15** (A) For this adult with an upper incisor that was brought down into position and crowding in the lower incisor region, corticotomy and bone grafting on the facial surface (accelerated osteogenic orthodontics [AOO]) was planned. (B) After reflection of a flap, corticotomy cuts between the teeth were made and small circular depressions were placed in the facial surface of the bone over the maxillary anterior teeth. (C) Bone graft material in the form of a slurry of demineralized freeze-dried bone was placed over the facial surface. (D) Corticotomy and preparation of the bone over the lower incisor was done at the same time, and (E) bone graft material was placed to reduce the chance of bone loss as the lower incisors were advanced. (F) Eleven months later, after completion of treatment that required 6 months, with good healing of the alveolar bone. (Courtesy Dr. S. Dibart.)

reasonable—but only under the specific circumstances of this trial. How generalizable is this trial? More extensive data are needed to document that.

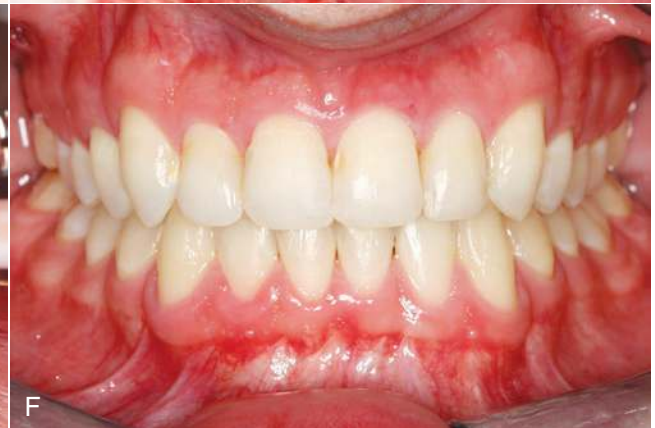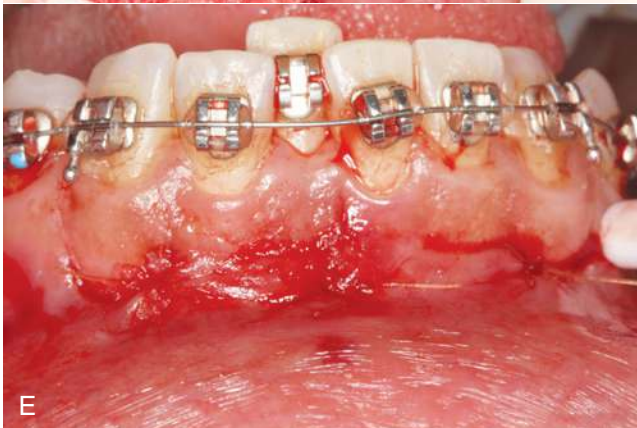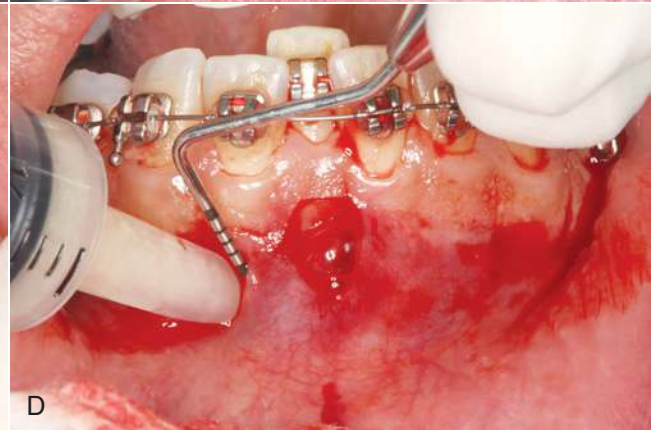
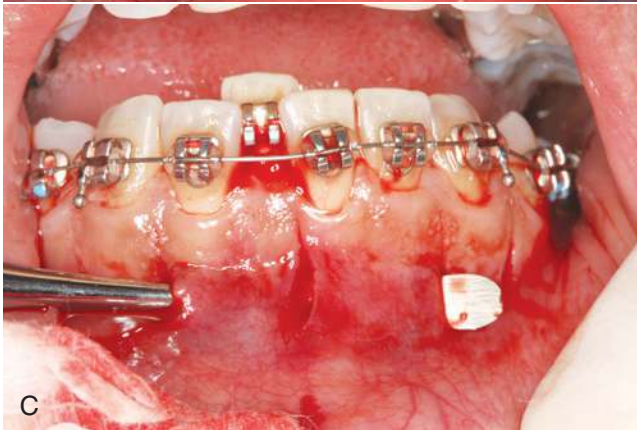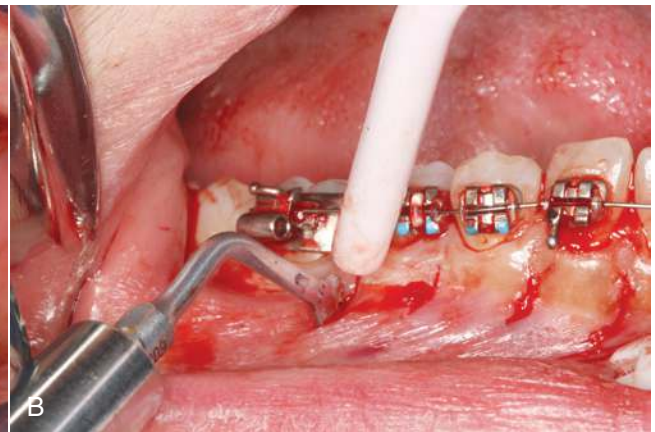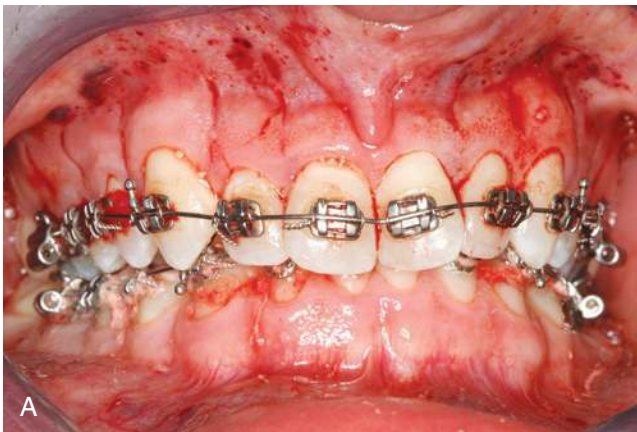It also is true that there is remarkably little information about possible complications with piezocision. A 2017 report from Australian investigators noted that in 5 of 14 patients in a split-mouth

study in whom premolars were extracted for examination with microcomputed tomography after 4 weeks of buccal tipping, root damage from contact with the piezoelectric knife was evident, and there was greater tooth remodeling in the piezocision group.<sup>21</sup> Being better than corticotomy does not necessarily qualify piezocision as an acceptable tool for accelerated tooth movement.

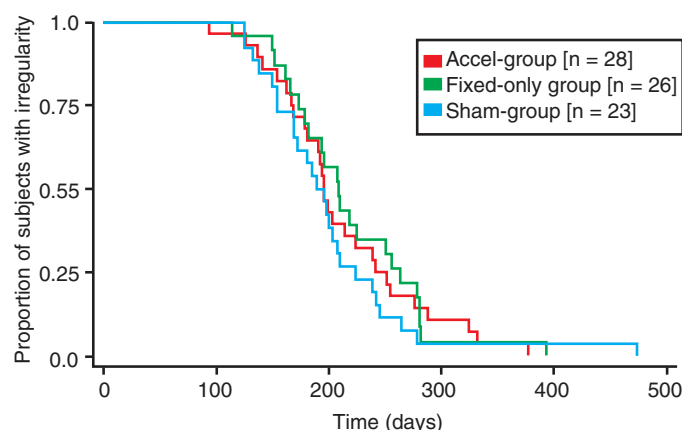




• **Fig. 8.16** Corticotomy complications include (A) whitening of the gingiva after reflection of the large flap and (B) fenestration of incisor roots after labial movement of these teeth, which can happen even after placing particulate bone grafts. (Courtesy Dr. S. Dibart.)



• **Fig. 8.17** (A) Modified corticotomy avoids reflecting a flap, using thin micro-incisions through the facial tissue. (B) A piezoelectric knife is used to penetrate the cortical bone and extend into the medullary bone between the teeth. (C) If a bone graft is desired, a tunnel under the soft tissue is established, and (D) the graft slurry is placed into the area with a syringe. (E) Appearance at the end of the procedure, with the graft material in place. (F) Ten months later. (Courtesy Dr. S. Dibart.)



• **Fig. 8.18** Time to alignment with no vibration (green); sham device with no device (blue); and AcceleDent vibration (red). (Redrawn from Woodhouse et al. *J Dent Res.* 2015;94:682–689.)

### Microperforation

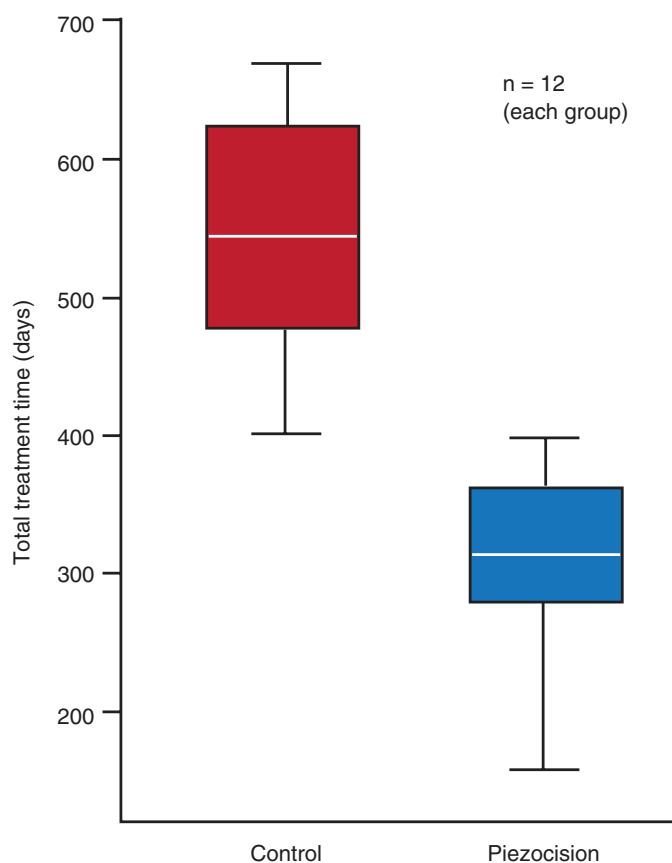
A third injury method, “microperforation”, differs from the previous two in that it was developed by a commercial company (Propel, Alveologic LLC, Briarcliff Manor, NY). It has the advantage that it does not require periodontal surgery and can be implemented by orthodontists. In this method, special screws supplied by the company are placed through the gingiva into interproximal alveolar bone and then removed. It is said that three such perforations in each interproximal area between teeth are enough to generate a regional acceleration of bone remodeling and thereby produce faster tooth movement. Although this method has been highly advertised for the past several years, as of mid-2017 no data to document its effectiveness had been published.

For the injury methods, perhaps a fair conclusion is that for some but certainly not all patients, the cost–benefit and risk–benefit ratios are favorable, and controlled injury would be a valuable adjunct to orthodontic treatment. The extent of injury with modified corticotomy is less, and it seems to be as effective as and more efficient than the original method, but caution in recommending it still seems prudent. Microperforation, if it is effective, would appear to be limited to specific areas rather than a whole arch or even all the anterior teeth because of the increasing effort to place so many screw holes.

### Other Physical Effects to Accelerate Tooth Movement

Three other methods intended to accelerate tooth movement have been marketed since the onset of the 21st century: vibration of the teeth, application of light to the alveolar process, and application of therapeutic ultrasound to the teeth and adjacent bone. Vibration may or may not really be another way to injure alveolar bone; penetrating light and therapeutic ultrasound are not injurious (at least as far as we know at present), but the mechanism by which they work is not understood. That is also true of vibration if its mechanism is not injury.

**Vibration: AcceleDent and Competitors.** The AcceleDent vibratory system (OrthoAccel Technologies, Houston, TX), unlike the efforts 40 years ago to induce piezoelectric currents with vibration that we have already discussed, is based on delivery of high-frequency vibration (30 Hz) to the teeth for approximately 20 minutes per day. The rationale is that this stimulates cell differentiation and maturation so that the bone remodeling necessary for tooth movement occurs more quickly.




• **Fig. 8.19** Total treatment time for similar patients treated without and with piezocision. (Redrawn from Charavet et al. *J Dent Res.* 2016;95:1003–1009.)

The important consideration, of course, is whether this produces a clinically significant decrease in treatment time. Case reports and several retrospective studies to support this have appeared, along with three RCTs. The first, published in 2015, was an evaluation of the rate of closure of a maxillary first premolar extraction site with sliding mechanics and anchorage with a temporary anchorage device (TAD). The researchers reported an average rate of 1.16 mm/month with AcceleDent, and 0.79 mm/month without it.<sup>22</sup> The second trial was a three-arm RCT to evaluate the rate of alignment of crowded lower incisors in lower first premolar extraction cases with a fixed orthodontic appliance alone, with a sham device with no vibration, or with an AcceleDent device. The result, shown graphically in Fig. 8.19, was “no evidence that supplemental vibrational force can significantly increase the rate of initial tooth movement or reduce the amount of time required to achieve final alignment when used in conjunction with a preadjusted edgewise fixed appliance.”<sup>23</sup> Faster alignment would be the presumed benefit for most orthodontic cases.

The third and fourth trials, published in 2018, evaluated the rate of closure of maxillary premolar extraction sites with and without the newer AcceleDent Aura device AcceleDent.<sup>24,24a</sup> Both found no difference in space closure rates or occlusal outcomes, and one also noted no difference in the time to alignment of the maxillary incisors before space closure.<sup>24</sup> Based on the later three trials, the effectiveness of AcceleDent is highly questionable.





• **Fig. 8.20** (A) and (B) The intraoral Biolux device delivers light at an infrared frequency that penetrates the soft tissue over the alveolar bone and, in theory, delivers energy to the bone that increases the rate of remodeling.

In late 2016, a higher frequency vibration device for use with aligners was marketed by the company that developed Propel, with advertisements that its recommended use of 5 minutes per day made it both more efficient than AcceleDent and that the higher energy made it more effective. No data have been presented to support either of these claims.

**Tissue-Penetrating Light: Biolux.** Based on the observation that healing of dental extraction sites seemed to occur more quickly when the sites were exposed to light, a patent application for the use of tissue-penetrating light to speed tooth movement was filed in late 2010, and an intraoral device (Biolux [Biolux Research Ltd, Vancouver, Canada]) was marketed 3 years later. It provides light with an 800- to 850-nanometer wave length (just above the visible spectrum) adjacent to the alveolar bone. Light in this spectrum does penetrate soft tissue, and the idea is that it “infuses light energy directly into the bone tissue” (Fig. 8.20). This is said to excite intracellular enzymes and increase cellular activity in the PDL and bone, increasing the rate of bone remodeling and tooth movement—but there has been no demonstration of how that would work, and little in the way of evidence of faster tooth movement. At present, as with vibrating devices, the major focus for Biolux is on improving the performance of removable aligners, with no data as of 2017 to document its effectiveness.

Could visible light affect tooth movement? A number of reports, largely outside the peer-reviewed literature, have suggested that low-level laser light could not only make teeth move faster but also decrease orthodontic pain, but about as many similar reports have shown no effect. The conclusion: neither faster tooth movement nor decreased pain has been credibly demonstrated.

**Therapeutic Ultrasound: SmileSonica Aevo.** The most recent entry into the tooth acceleration market is low-intensity therapeutic ultrasound—the Aevo device, now being marketed by SmileSonica of Canada (Fig. 8.21). It is known that therapeutic ultrasound (which is different from diagnostic ultrasound) increases blood flow in treated areas; indeed, it is used routinely in physical therapy to increase blood flow in muscles. The theory is that increased blood flow in the PDL would increase the rate of bone remodeling and tooth movement and also could decrease root resorption. This



• **Fig. 8.21** The Aevo device has four components: maxillary and mandibular mouthpieces with facial and lingual emitters and five treatment zones, a coupling gel for use in the mouthpieces, and a battery-powered energy source. It is used with an interface that allows selection of which treatment zones are activated and monitors patient compliance so that the doctor knows whether it is being used and how much.

is plausible, especially because an important aspect of injury to bone is an increase in blood flow to the healing area. Perhaps ultrasound could provide the major effect of injury to alveolar bone without surgical intervention. As of mid-2017, however, there had been no convincing demonstration of effectiveness or efficiency in accelerating tooth movement.



## Anchorage and Its Control

### Anchorage: Resistance to Unwanted Tooth Movement

The term *anchorage*, in its orthodontic application, is defined in an unusual way: the definition as “resistance to unwanted tooth movement” includes a statement of what the dentist desires. The usage, although unusual, is clearest when presented this way. The dentist or orthodontist always constructs an appliance to produce certain desired tooth movements. For every (desired) action, there is an equal and opposite reaction. Inevitably, reaction forces can move other teeth as well if the appliance contacts them. Anchorage, then, is the resistance to reaction forces that is provided usually by other teeth, occasionally by the palate, sometimes by the head or neck (via extraoral force), and more and more often by anchors screwed into the jaws.

At this point, let us focus first on controlling unwanted tooth movement when some teeth are to serve as anchors. In planning orthodontic therapy, it is simply not possible to consider only the teeth whose movement is desired. Reciprocal effects throughout the dental arches must be carefully analyzed, evaluated, and controlled. An important aspect of treatment is maximizing the tooth movement that is desired, while minimizing undesirable side effects.

An obvious strategy for anchorage control would be to concentrate the force needed to produce tooth movement where it is desired, and then to dissipate the reaction force over as many other teeth as possible, keeping the pressure in the PDL of anchor teeth as low as possible. A threshold, below which pressure would produce no reaction, could provide perfect anchorage control, because it would only be necessary to be certain that the threshold for tooth movement was not reached for teeth in the anchorage unit. A differential response to pressure, so that heavier pressure produced more tooth movement than lighter pressure, would make it possible to move some teeth more than others, even though some undesired tooth movement occurred.

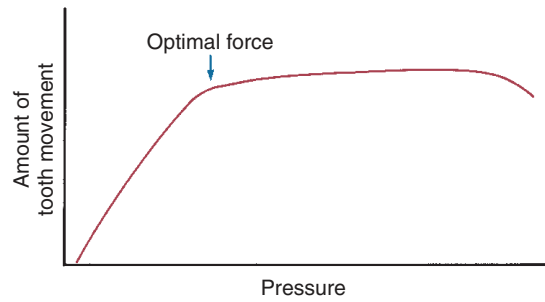
In fact, the threshold for tooth movement appears to be quite low, but there is a differential response to pressure, so this strategy of “divide and conquer” is reasonably effective. As Fig. 8.22 indicates, teeth behave as if orthodontic movement is proportional to the magnitude of the pressure, up to a point. When that point is reached, the amount of tooth movement becomes more or less independent of the magnitude of the pressure, so that a broad plateau of orthodontically effective pressure is created.<sup>25</sup> The optimum force level for orthodontic movement is the lightest force and resulting pressure that produces a near-maximum response (i.e., it is found at the edge of the plateau). Forces greater than that, although equally effective in producing tooth movement, would be unnecessarily traumatic and, as we will see, unnecessarily stressful to anchorage.

## Control of Anchorage

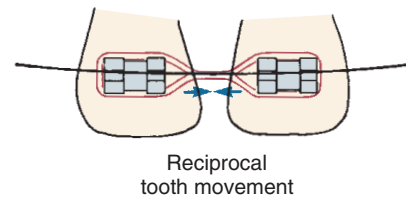
### Anchorage Situations

From this background, we can now define several anchorage situations.

**Reciprocal Tooth Movement.** In a reciprocal situation, the forces applied to teeth and to arch segments are equal, and so is the force distribution in the PDL. A simple example is what would occur if two maxillary central incisors separated by a diastema were connected by an active spring (Fig. 8.23). The essentially identical teeth would feel the same force distributed in the same



• **Fig. 8.22** Theoretical representation of the relationship of pressure within the periodontal ligament (PDL) to the amount of tooth movement. Pressure in the PDL is determined by the force applied to a tooth divided by the area of the PDL over which that force is distributed. The threshold for tooth movement is very small. Tooth movement increases as pressure increases up to a point, remains at about the same level over a broad range, and then may actually decline with extremely heavy pressure. The best definition of the optimum force for orthodontic purposes is the lightest force that produces a maximum or near-maximum response (i.e., that brings pressure in the PDL to the edge of the nearly constant portion of the response curve). The magnitude of the optimum force will vary, depending on the way it is distributed in the PDL (i.e., it is different for different types of tooth movement [tipping, bodily movement, intrusion, and so on]).



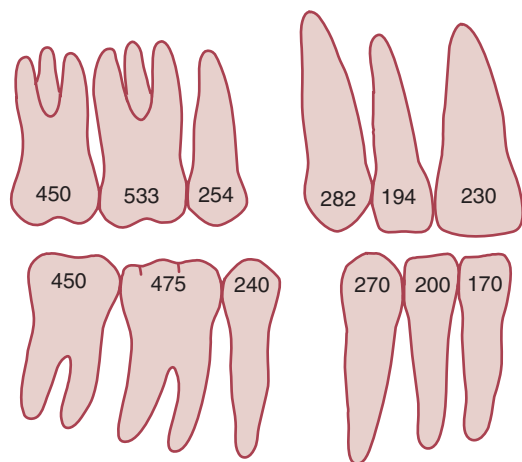
• **Fig. 8.23** Reciprocal tooth movement is produced when two teeth or resistance units of equal size pull against each other, as in this example of the reciprocal closure of a maxillary midline diastema.

way through the PDL and would move toward each other by the same amount.

A somewhat similar situation would arise if a spring were placed across a first premolar extraction site, pitting the central incisor, lateral incisor, and canine in the anterior arch segment against the second premolar and first molar posteriorly. Whether this would really produce reciprocal tooth movement requires some thought. The same force would be felt by the three anterior teeth and the two posterior teeth, because the action of the spring on one segment has an equal and opposite reaction on the other. Reciprocal movement would require the same total PDL area over which the force was distributed.

Conceptually, the “anchorage value” of a tooth, that is, its resistance to movement, can be thought of as a function of its root surface area, which is the same as its PDL area. The larger the root, the greater the area over which a force can be distributed, and vice versa. As Fig. 8.24 shows, the PDL area for the two posterior teeth in this example is slightly larger than the total anterior PDL area. Therefore, with a simple spring connecting the segments, the anterior teeth would move slightly more than the posterior teeth. The movement would not be truly reciprocal but would be close to it.

**Reinforced Anchorage.** Continuing with the extraction site example, if it is desired to differentially retract the anterior teeth,



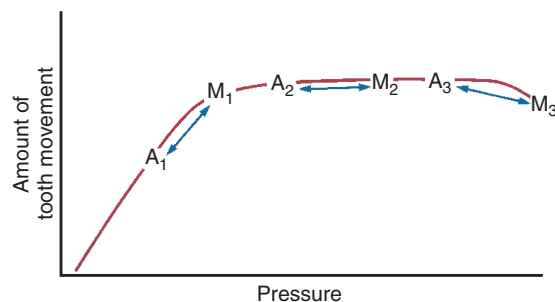
• **Fig. 8.24** The “anchorage value” of any tooth is roughly equivalent to its root surface area. As this diagram shows, the first molar and second premolar in each arch are approximately equal in surface area to the canine and two incisors. (Modified from Freeman DC. [Master’s thesis.] University of Tennessee Department of Orthodontics; 1965.)

the anchorage of the posterior teeth could be reinforced by adding the second molar to the posterior unit (see Fig. 8.24). This would change the ratio of the root surface areas so that there would be relatively more pressure in the PDL of the anterior teeth and therefore relatively more retraction of the anterior segment than forward movement of the posterior segment.

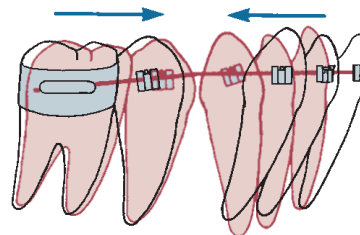
Note that reinforcing anchorage by adding more resistance units is effective because with more teeth (or extraoral structures) in the anchorage, the reaction force is distributed over a larger area. This reduces the pressure on the anchor teeth, moving them down the slope of the pressure–response curve. Now the shape of the pressure–response curve becomes important. Keeping the force light has two virtues. Not only does this minimize trauma and pain, but it also makes it possible to create anchorage by taking advantage of different PDL areas in the anchor segments. As Fig. 8.25 illustrates, too much force destroys the effectiveness of reinforced anchorage by pulling the anchor teeth up onto the flatter portion of the pressure–response curve. Then the clinician is said to have slipped, burned, or blown the anchorage by moving the anchor teeth too much.

**Stationary Anchorage.** The term *stationary anchorage*, traditionally used although inherently less descriptive than the term *reinforced anchorage*, refers to the advantage that can be obtained by pitting bodily movement of one group of teeth against tipping of another (Fig. 8.26). Using our same example of a premolar extraction site, if the appliance were arranged so that the anterior teeth could tip lingually while the posterior teeth could only move bodily, the optimum pressure for the anterior segment would be produced by about half as much force as if the anterior teeth were to be retracted bodily. This would mean that the reaction force distributed over the posterior teeth would be reduced by half, and these teeth would move half as much.

If PDL areas were equal, tipping the anterior segment while holding the posterior segment for bodily movement would have the effect of doubling the amount of anterior retraction compared with posterior forward movement. It is important to note again, however, that successful implementation of this strategy requires light force. If the force were large enough to bring the posterior



• **Fig. 8.25** Consider the response of anchor teeth (A on the chart) and teeth to be moved (M) in three circumstances. In each case, the pressure in the periodontal ligament (PDL) of the anchor teeth is less than the pressure in the PDL of the teeth to be moved because there are more teeth in the anchor unit. In the first case ( $A_1$ – $M_1$ ), the pressure for the teeth to be moved is optimal, whereas the pressure in the anchor unit is suboptimal, and the anchor teeth move less (anchorage is preserved). In the second case ( $A_2$ – $M_2$ ), although the pressure for the anchor teeth is less than for the teeth to be moved, both are on the plateau of the pressure–response curve, and the anchor teeth can be expected to move as much as the teeth that are desired to move (anchorage is lost). With extremely high force ( $A_3$ – $M_3$ ), the anchor teeth might move more than the teeth it was desired to move. Although the third possibility is theoretical and may not be encountered clinically, both the first and second situations are seen in clinical orthodontics. This principle explains the efficacy of light forces in controlling anchorage, and why heavy force destroys anchorage.



• **Fig. 8.26** Displacement of anchor teeth can be minimized by arranging the force system so that the anchor teeth must move bodily if they move at all, while movement teeth are allowed to tip, as in this example of retracting incisors by tipping them posteriorly. The crowns of the incisors moved back much more than the posterior teeth moved forward because the lighter force for tipping the incisors decreased the periodontal ligament pressure for the anchor teeth. The approach is called stationary anchorage. In this example, treatment is not complete because the roots of the lingually tipped incisors will have to be uprighted at a later stage, but two-stage treatment with tipping followed by uprighting can be used as a means of controlling anchorage.

teeth into their optimum movement range, it would no longer matter whether the anterior segment tipped or was moved bodily. Using too much force would disastrously undermine this method of anchorage control.

If tooth movement were actually impeded by very high levels of pressure, it might be possible to structure an anchorage situation so that there was more movement of the arch segment with the larger PDL area. This result could happen, of course, if such high force were used that the smaller segment was placed beyond the greatest tooth movement range, while the larger segment was still in it (see Fig. 8.25). Because the effect would be highly traumatic, it would be an undesirable way to deliberately manage anchorage.

In fact, it is not certain that the amount of tooth movement in response to applied force really decreases with very high force levels in any circumstance, and so this type of differential movement may not really exist. By using too much force, however, it is certainly possible to produce more movement of the anchor segment than was expected, even if the mechanism is merely a differential movement of the anchor segment up the slope of the pressure–response curve rather than a decline in the response of the movement segment. Differential force is understood best in terms of the plateau portion of the curve in [Figs. 8.22](#) and [8.25](#), not the questionable decline at the far right.

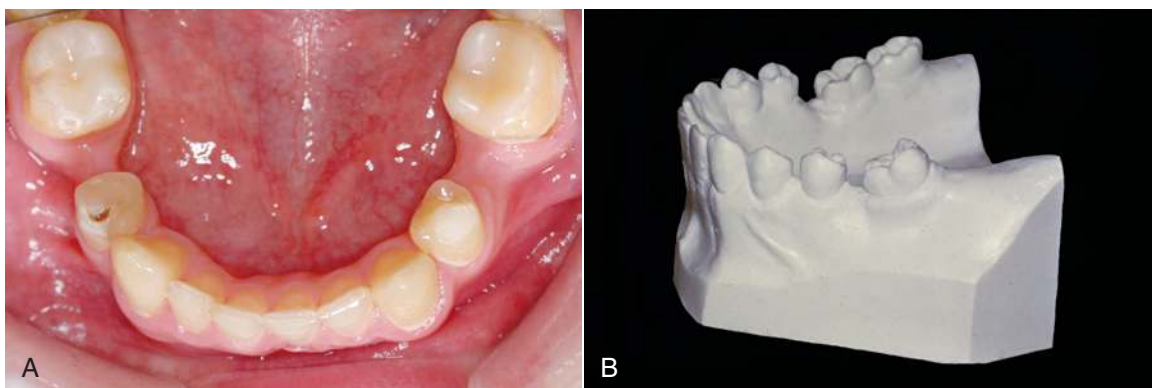
**Cortical and Skeletal Anchorage.** Another consideration in anchorage control is the different response of cortical compared with medullary bone. Cortical bone is more resistant to resorption, and tooth movement is slowed when a root contacts it. A layer of dense cortical bone that has formed within the alveolar process can certainly affect tooth movement. This situation may be encountered at an old extraction site—for example, in an adult in whom a molar or premolar was lost many years previously ([Fig. 8.27](#)). Another frequent example is an area in which a permanent tooth never erupted, as when a mandibular second premolar was congenitally missing. It can be very difficult to close such a space in the dental arch because tooth movement is slowed to a minimum as the roots encounter cortical bone along the resorbed alveolar ridge.

As a general rule, torquing movements are limited by the facial and lingual cortical plates. If a root is persistently forced against either of these cortical plates, tooth movement is greatly slowed and root resorption is likely. A common example is the difficulty in obtaining an ideal inclination of maxillary incisors when there is little space between their roots and cortical bone of the palate. At one time, deliberately creating root contact of lower molars against the buccal cortical plate was suggested as a way to increase their resistance to forward movement when Class II elastics were employed. Like excessive torquing of maxillary incisors, this is now recognized more as a prescription for root resorption than as a good way to reinforce anchorage.

It has long been realized that if structures other than the teeth could be made to serve as anchorage, it would be possible to produce tooth movement or growth modification without unwanted side effects. Until the turn of the 21st century, extraoral force (headgear) and to a lesser extent the anterior palate were the only ways to obtain anchorage that was not from the teeth. Although headgear can be used to augment anchorage, there are two problems: (1) it is impossible for a patient to wear headgear all the time, and most wear it half the time at best, and (2) when headgear is worn, the force against the teeth is greater than optimal. The result is a force system that is far from ideal. Heavy intermittent force from headgear is simply not a good way to counterbalance the effect of light continuous force from the orthodontic appliance. It is not surprising that headgear to the anchor segment of a dental arch usually does not control its movement very well. In theory, additional anchorage can be obtained from the rugae area of the palate; in fact, this is not very effective (see [Chapter 16](#)).

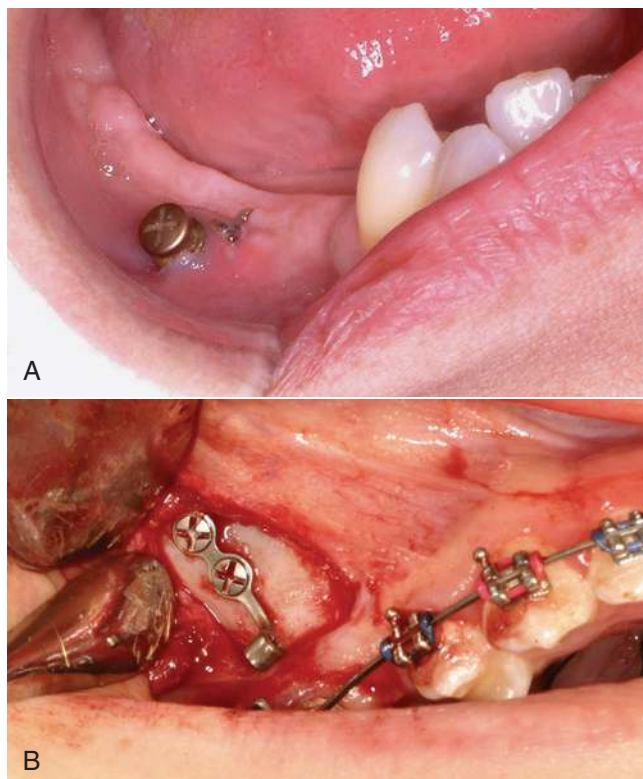
With the development of successful bone implant techniques to replace missing teeth, it was quickly realized that implants also could be used for orthodontic anchorage. A successful implant is like an ankylosed tooth: it does not move unless pathologic degeneration of the bone around it develops. It has become apparent that the osseointegration needed for long-term implant success is not necessary, and perhaps not desirable, for temporary attachments to bone to provide orthodontic anchorage. A number of options for skeletal anchorage exist at present, the principal ones being titanium screws that penetrate through the gingiva into alveolar bone ([Fig. 8.28A](#)) and bone plates held by multiple screws that are placed beneath the soft tissue, usually in the zygomatic buttress area of the maxilla ([Fig. 8.28B](#)).

At this point, application of bone screws or plates for skeletal anchorage has become a routine aspect of clinical orthodontics, and in many ways has superseded extraoral devices for control of anchorage. These devices are discussed further in [Chapters 9](#) and [10](#), and their current applications are illustrated in most of the clinical chapters that follow.



• **Fig. 8.27** Loss of alveolar bone at an old extraction site can create an area of cortical bone between adjacent teeth, as the alveolar process resorbs and narrows. (A) This child lost second primary molars early and was congenitally missing the second premolars. The greater ridge resorption on the right than the left side indicates that the right second primary molar was lost first. This is one situation in which “cortical anchorage” definitely can be a factor. Closing such an extraction site is extremely difficult because of the resistance of cortical bone to remodeling, and the result often is as much retraction of the anterior teeth as forward movement of the posterior teeth. (B) In adults who had a permanent first molar extracted during childhood or adolescence, the second molar tips mesially, but resorption of alveolar bone at the extraction site narrows the ridge. Closing these spaces also is difficult and slow because remodeling of cortical bone is required.





• **Fig. 8.28** Skeletal (absolute) anchorage can be provided in two major ways: (A) screws placed through the gingiva into the alveolar bone, as in this patient in whom the screw will be used for anchorage so that the lower incisors can be aligned before prosthodontic replacement of the missing teeth; or (B) bone anchors placed beneath the soft tissue, usually at the base of the zygomatic arch, so that the posterior teeth can be intruded or the anterior teeth retracted. After soft tissues are sutured back over the plate and screws, only the tube for attachment of springs will extend into the oral cavity.

### Skeletal Effects of Orthodontic Force: Growth Modification

Orthodontic force directly affects the teeth and alveolar bone, but it also can have indirect effects on the jaws more generally. Force against maxillary teeth is greatly attenuated before it reaches the sutures above and behind the maxilla that are sites of maxillary growth, but sustained light force can inhibit or enhance the maxilla's normal downward and forward growth. Force against mandibular teeth similarly can affect the direction, and perhaps the amount, of growth at the mandibular condyles (see [Chapter 4](#)). It is possible now to place force directly against the maxilla or mandible by using implants in the bone, and as one might have predicted, heavy force is not needed to affect growth.

Growth modification is the subject of [Chapters 13](#) and [14](#), and the skeletal effects of force against the jaws is discussed there in detail.

### Deleterious Effects of Orthodontic Force

#### Mobility and Pain Related to Orthodontic Treatment

Orthodontic tooth movement requires not only a remodeling of bone adjacent to the teeth but also a reorganization of the PDL

itself. Collagen fibers become detached from the bone and cementum, then reattach at a later time. Radiographically, it can be observed that the PDL space widens during orthodontic tooth movement. The combination of a wider ligament space and a somewhat disorganized ligament means that some increase in mobility will be observed in every patient.

A moderate increase in mobility is an expected response to orthodontic treatment. The heavier the force, however, the greater the amount of undermining resorption expected, and the greater the mobility that will develop. Excessive mobility is an indication that excessive forces are being encountered. This may occur because the patient is clenching or grinding against a tooth that has moved into a position of traumatic occlusion. If a tooth becomes extremely mobile during orthodontic treatment, it should be taken out of occlusion and all force should be discontinued until the mobility decreases to moderate levels. Unlike root resorption, excessive mobility will usually correct itself without permanent damage.

If heavy pressure is applied to a tooth, pain develops almost immediately as the PDL is literally crushed. There is no excuse for using force levels for orthodontic tooth movement that produce immediate pain of this type. If appropriate orthodontic force is applied, the patient feels little or nothing immediately. Several hours later, however, pain usually appears. The patient feels a mild aching sensation, and the teeth are quite sensitive to pressure, so that biting a hard object hurts. The pain typically lasts for 2 to 4 days, then disappears until the orthodontic appliance is reactivated. At that point, a similar cycle may recur, but for almost all patients, the pain associated with the initial activation of the appliance is the most severe. It is commonly noted that there is a great deal of individual variation in any pain experience, and this is certainly true of orthodontic pain. Some patients report little or no pain even with relatively heavy forces, whereas others experience considerable discomfort with quite light forces.

The pain associated with orthodontic treatment is related to the development of ischemic (hyalinized) areas in the PDL that will undergo sterile necrosis. The increased tenderness to pressure suggests inflammation at the apex, and the mild pulpitis that usually appears soon after orthodontic force is applied probably also contributes to the pain. There does seem to be a relationship between the amount of force used and the amount of pain: all other factors being equal, the greater the force, the greater the pain. This is consistent with the concept that ischemic areas in the PDL are the major pain source, because greater force would produce larger areas of ischemia.

If the source of pain is the development of ischemic areas, strategies to temporarily relieve pressure and allow blood flow through compressed areas should help. In fact, if light forces are used, the amount of pain experienced by patients can be decreased by having them engage in repetitive chewing (of sugarless gum, a plastic wafer placed between the teeth, and so on) during the first 8 hours after the orthodontic appliance has been activated. Presumably this works by temporarily displacing the teeth enough to allow some blood flow through compressed areas, thereby preventing buildup of metabolic products that stimulate pain receptors. Light forces, however, are the key to minimizing pain as a concomitant feature of orthodontic treatment.

As we have noted previously, many drugs used to control pain have the potential to affect tooth movement because of their effects on prostaglandins. It has been suggested that acetaminophen (Tylenol) should be a better analgesic for orthodontic patients than aspirin, ibuprofen, naproxen, and similar prostaglandin

inhibitors because it acts centrally rather than as a prostaglandin inhibitor. There are two counterarguments against acetaminophen. First, inflammation in the PDL contributes to the pain. Acetaminophen does not reduce inflammation, but the peripherally acting agents such as ibuprofen do, so they may offer more effective pain control (i.e., lower doses would suffice). Second, prolonged use of acetaminophen now has been shown to have the potential to cause serious damage to renal function. Based on clinical studies, it now is widely accepted that acetaminophen and the over-the-counter NSAIDs are equally acceptable for controlling pain over the 3 to 4 days after an orthodontic appliance has been activated. Given the recently discovered potential for liver damage from acetaminophen, the choice for orthodontic pain now has swung toward the prostaglandin inhibitors, although neither type of drug would be used for orthodontic pain in large enough quantities or long enough to create problems.

It also is of interest that there is a strong placebo effect: reassuring patients and calling them at home the evening after appliances were placed was as effective in reducing pain as either type of drug in a recent and well-done study.<sup>26</sup> Physicians now often make an end-of-the-day phone call after surgery, and many orthodontic practice management consultants now recommend a personal phone call after appliance placement.

It is rare but not impossible for orthodontic patients to develop pain and inflammation of soft tissues, not because of the orthodontic force, but because of an allergic reaction. There are two major culprits when this occurs: a reaction to the latex in gloves or elastics and a reaction to the nickel in stainless steel bands, brackets, and wires. Latex allergies can become so severe as to be life-threatening. Extreme care should be taken to avoid using latex products in patients reporting a latex allergy.

Nickel is allergenic, and nearly 20% of the U.S. population show some skin reaction to nickel-containing materials (such as cheap jewelry and earrings). Fortunately, most children with a skin allergy to nickel have no mucosal response to stainless steel orthodontic appliances (which are about 8% nickel) and tolerate treatment perfectly well, but some do not. The typical symptoms of nickel allergy in an orthodontic patient are widespread erythema and swelling of oral tissues, developing 1 to 2 days after a stainless steel appliance is placed. For such patients (see further discussion in [Chapter 10](#)), titanium brackets and tubes can be substituted for stainless steel, and beta-titanium archwires can be used instead of nickel–titanium (NiTi) or steel wires.<sup>27</sup>

If there is doubt about how a patient with a known nickel allergy will react to an orthodontic appliance, it is wise to bond one or two steel brackets and wait for a week or two to see if there will be an allergic response before placing a complete appliance. A true mucosal allergy is rare enough that in most such patients, there will be no response and a completely titanium appliance would not be necessary.

## Effects on the Dental Pulp

Although pulpal reactions to orthodontic treatment are minimal, there is probably a modest and transient inflammatory response within the pulp, at least at the beginning of treatment. As we have noted previously, this may contribute to the discomfort that patients often experience for a few days after appliances are placed, but the mild pulpitis has no long-term significance.

There are occasional reports of loss of tooth vitality during orthodontic treatment. Usually there is a history of previous trauma to the tooth, but poor control of orthodontic force also can be

the culprit. If a tooth is subjected to heavy continuous force, a sequence of abrupt movements occurs, as undermining resorption allows increasingly large increments of change. A large enough abrupt movement of the root apex could sever the blood vessels as they enter. Loss of vitality has also been observed when incisor teeth were tipped distally to such an extent that the root apex, moving in the opposite direction, was moved outside the alveolar process. This also can happen with excess torque ([Fig. 8.29](#)). Again, such movements probably would sever the blood vessels entering the pulp canal.

Because the response of the PDL, not the pulp, is the key element in orthodontic tooth movement, moving endodontically treated teeth is perfectly feasible. Endodontic treatment may be necessary before orthodontics after trauma at any age or in adults receiving adjunctive orthodontic treatment (see [Chapter 18](#)). There is no contraindication to going ahead with orthodontics soon after the pulp therapy, and severe root resorption would not be expected. One special circumstance is a tooth that experienced severe intrusive trauma and required pulp therapy for that reason. If such a tooth must be repositioned orthodontically, resorption seems less likely if a calcium hydroxide fill is maintained until the tooth movement is completed, and then the definitive root canal filling is placed.<sup>28</sup>

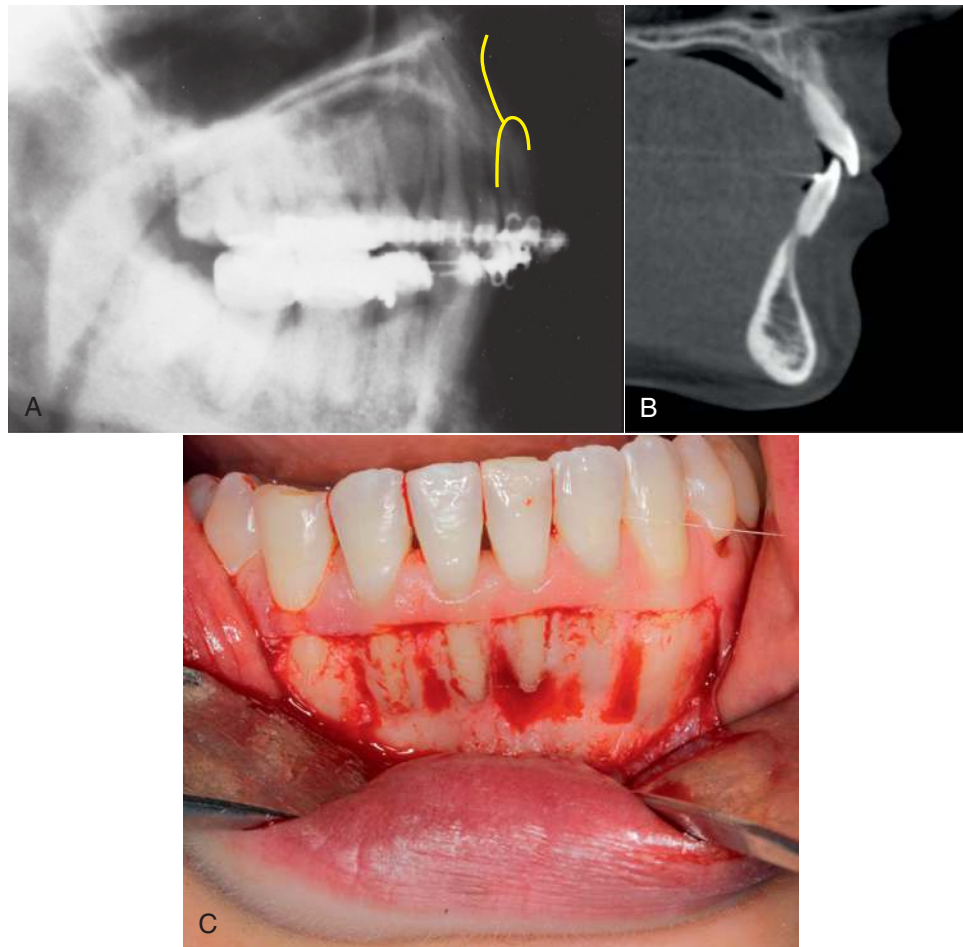
## Root Resorption

Orthodontic treatment requires remodeling of bone adjacent to the tooth roots. For many years, it was thought that the roots were not remodeled in the same way as bone. More recent research has made it plain that when orthodontic forces are applied, there usually is some remodeling of the cementum on the root surface as well as the adjacent bone.

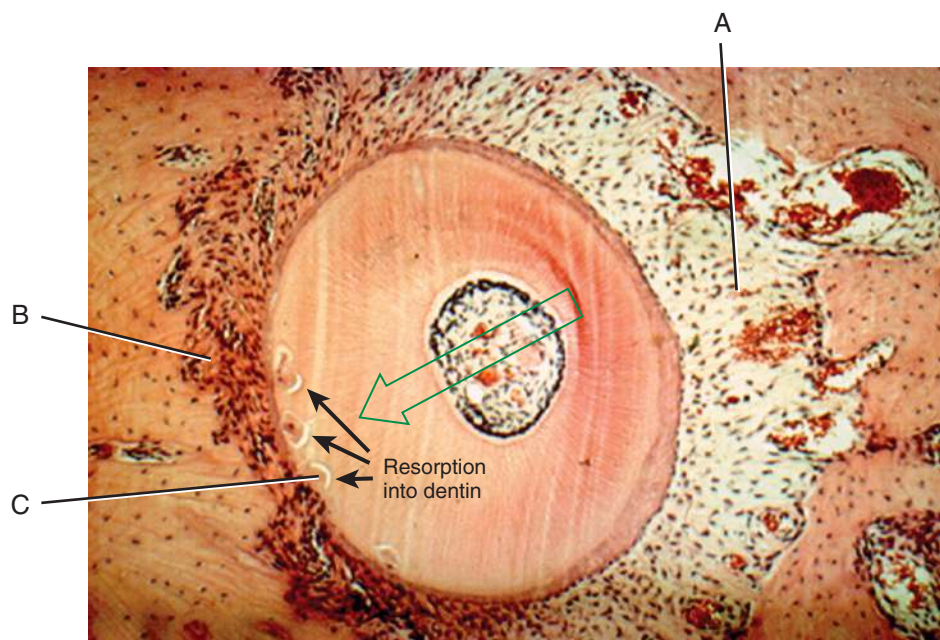
Brudvik and Rygh have shown that cementum adjacent to hyalinized (necrotic) areas of the PDL is “marked” by this contact and that clast cells attack this marked cementum when the PDL area is repaired.<sup>28</sup> This observation helps explain why heavy continuous orthodontic force can lead to severe root resorption. Even with the most careful control of orthodontic force, however, it is difficult to avoid creating some hyalinized areas in the PDL. It is not surprising, therefore, that careful examination of the root surfaces of teeth that have been moved reveals repaired areas of resorption of both cementum and dentin of the root ([Fig. 8.30](#)). It appears that cementum (and dentin, if resorption penetrates through the cementum) is removed from the root surface, then cementum is restored in the same way that alveolar bone is removed and then replaced. Root remodeling, in other words, is a constant feature of orthodontic tooth movement, but permanent loss of root structure would occur only if repair did not replace the initially resorbed cementum.

Repair of the damaged root restores its original contours, unless the attack on the root surface produces large defects at the apex that eventually become separated from the root surface ([Fig. 8.31](#)). Once an island of cementum or dentin has been cut totally free from the root surface, it will be resorbed and will not be replaced. On the other hand, even deep defects in the form of craters into the root surface will be filled in again with cementum once orthodontic movement stops, so permanent loss of root structure related to orthodontic treatment occurs primarily at the apex.

Apical root resorption (loss of root length) during orthodontic treatment occurs in three distinct forms that must be distinguished when its etiology is considered.



• **Fig. 8.29** (A) Extreme tipping of maxillary incisor teeth from excessive and poorly controlled orthodontic forces. In this patient, the apices of all four maxillary incisors were carried through the labial cortical plate, and pulp vitality was lost. Mandibular incisor root shown out of bone in cone beam computed tomography image (B) and clinical photograph (C).



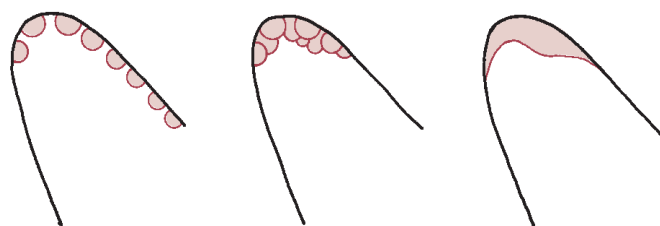• **Fig. 8.30** Coronal section of alveolar bone through the root of a premolar being moved to the left (arrow). Note the zone of periodontal ligament (PDL) compression to the left and tension to the right. Dilatation of blood vessels and osteoblastic activity (A) can be seen on the right. Osteoclasts removing bone are present on the left (B). Areas of beginning root resorption that will be repaired by later deposition of cementum also can be seen on the left (C). If resorption penetrates through the cementum and into the dentin, the result will be cementum repair that fills in craters in the dentin. (Courtesy Professor B. Melsen.)



**TABLE 8.4** Average Root Length Change

	MAXILLARY		MANDIBULAR	
	Serial Ext Plus	Late Ext	Serial Ext Plus	Late Ext
Central incisor	−1.5	−2.0	−1.0	−1.5
Lateral incisor	−2.0	−2.5	−1.0	−1.0
Canine	−1.0	−1.5	−0.5	−1.0
Second premolar	−0.5	−1.5	−0.5	−1.5
First molar (mesial)	−0.5	−1.0	−0.5	−1.5

ext, Extraction.

Data from Kennedy DB, Joondeph DR, Osterburg SK, et al. *Am J Orthod.* 1983;84:183.

• **Fig. 8.31** During tooth movement, clast cells attack cementum, as well as bone, creating defects in surface of the roots. During the repair phase, these defects fill back in with cementum. Shortening of the root occurs when cavities coalesce at the apex, so that peninsulas of root structure are cut off as islands. These islands resorb, and although the repair process places new cementum over the residual root surface, a net loss of root length occurs. This is why, although both the sides and the apex of the root experience resorption, roots become shorter but not thinner as a result of orthodontic tooth movement.

### 1. Moderate Generalized Resorption

Despite the potential for repair, careful radiographic examination of individuals who have undergone comprehensive orthodontic treatment shows that most of the teeth have some loss of root length, and this is greater in patients whose treatment duration was longer (Table 8.4). The average shortening of root length of maxillary incisors is somewhat greater than for other teeth, but all teeth included in the typical fixed orthodontic appliance show slight average shortening. In the Seattle study from which the data of Table 8.4 were derived, all teeth except upper second molars were banded. Note that these were the only unaffected teeth. Although 90% of maxillary incisors and over half of all teeth show some loss of root length during treatment, for the great majority of the patients, this modest shortening is almost imperceptible and is clinically insignificant (Fig. 8.32A–B).

Occasionally, however, loss of one-third or one-half or more of the root structure is observed in patients who received what seemed to be only routine orthodontic therapy. To understand this, it is important to distinguish between two forms of severe resorption.

### 2. Severe Generalized Resorption

Severe root resorption of all the teeth, fortunately, is rare. Some individuals are prone to root resorption, even without orthodontic

treatment—severe generalized resorption has been observed many times in individuals who never were orthodontic patients. If there is evidence of root resorption before orthodontic treatment, the patient is at considerable risk of further resorption during orthodontic treatment, much more so than a patient with no pretreatment resorption. Although hormonal imbalances and other metabolic derangements have been suspected in these susceptible patients, little evidence supports these theories.

Various reports have suggested that above-average resorption can be anticipated if the teeth have conical roots with pointed apices, distorted tooth form (dilaceration), or a history of trauma (with or without endodontic treatment). These characteristics, however, are best considered indicators of possible moderate resorption than as risk factors for severe resorption.

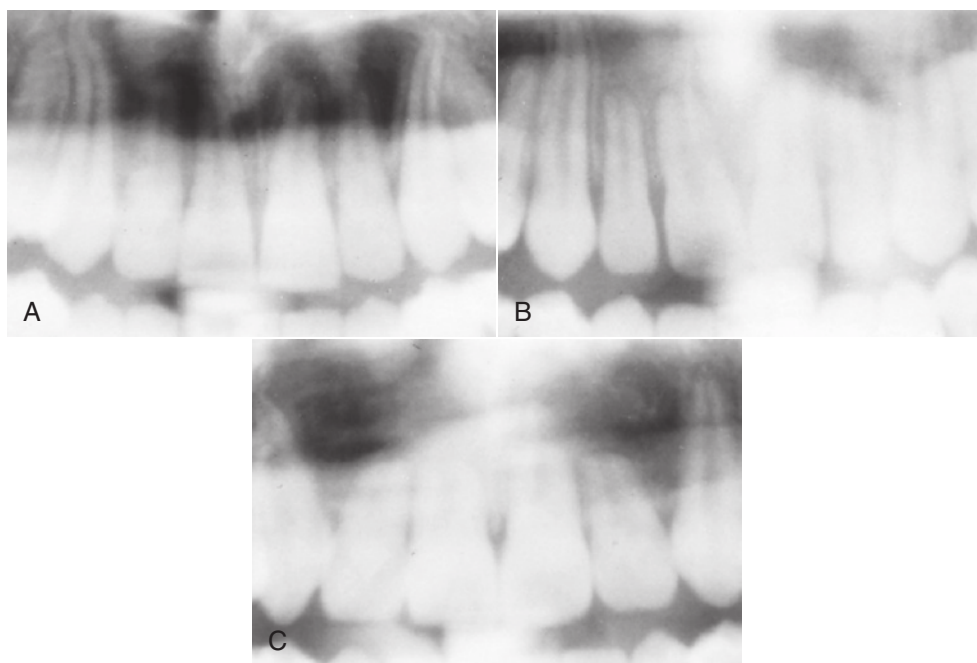
At this point the etiology of severe generalized resorption must be considered entirely unknown—but at least we know that it is not a complication of orthodontic treatment.

### 3. Severe Localized Resorption

In contrast to severe generalized resorption, severe localized resorption (i.e., severe resorption of a few teeth) (see Fig. 8.32C) usually is caused by orthodontic treatment. It has been known for many years that excessive force during orthodontic treatment increases the risk of root resorption, particularly if heavy continuous forces are used. Prolonged duration of orthodontic treatment also increases the amount of resorption.

It is increasingly apparent that some individuals are more susceptible to root resorption. It seems reasonable to presume that the large individual differences relate to genetic factors, although there is not yet any way to use genetic testing to evaluate resorption risk.<sup>30</sup> Perhaps the best way to detect those who are likely to experience unusually large amounts of resorption is to take a panoramic radiograph 6 to 9 months into treatment and evaluate the amount of resorption during this time. Patients who show significant resorption in the initial stage of treatment are likely to have greater resorption at the end of treatment.<sup>30</sup>

The risk of severe localized resorption is much greater for maxillary incisors (3% affected versus <1% for all other teeth; Table 8.5). Kaley and Phillips reported a 20-fold increase in the risk of severe resorption for maxillary incisors if the roots were forced against the lingual cortical plate during treatment (Table 8.6).<sup>31</sup> This is likely to occur during camouflage treatment for skeletal problems, when the maxillary incisors are torqued (as in



• **Fig. 8.32** Root resorption accompanying orthodontic treatment can be placed into three categories as illustrated here for maxillary central and lateral incisors: (A) category 1, slight blunting; (B) category 2, moderate resorption, up to  $\frac{1}{4}$  of root length; (C) category 3, severe resorption, greater than  $\frac{1}{4}$  of root length. See Table 8.5 for data for prevalence of these levels of resorption. (From Kaley JD, Phillips C. *Angle Orthod.* 1991;61:125–131.)

**TABLE 8.5** Percentage of Patients With Root Resorption by Degree of Resorption (200 Consecutive Full-Treatment Patients)

Tooth	RESORPTION CATEGORY <sup>a</sup>			
	0	1	2	3
<b>Maxillary</b>				
Central incisor	8	45	44	3
Lateral incisor	14	47	37	3
Second premolar	51	45	4	0.5
<b>Mandibular</b>				
Central incisor	16	63	20	0.5
Second premolar	55	38	6	0.5

<sup>a</sup>Values are for the right tooth in each instance (no significant right–left differences): 0 = no apical root resorption; 1 = slight blunting of the root apex; 2 = moderate resorption, up to of root length; 3 = severe resorption, greater than of root length. (See Fig. 8.32.)

Data from Kaley JD, Phillips C. *Angle Orthod.* 1991;61:125–131.

Class II patients) or tipped (as in Class III treatment) so that the root apices are thrust against the lingual cortical plate. Contact with the cortical plates also can explain other patterns of localized root resorption, such as resorption of lower molar roots when buccal root torque is used in an effort to augment anchorage.

### Effects of Treatment on Alveolar Bone Height

Pressure in the PDL space is at its peak, except when tipping of the tooth is perfectly controlled, at the root apex and the alveolar

**TABLE 8.6** Risk Factors for Severe Root Resorption, Maxillary Incisors

Factor	Probability	Odds Ratio
Lingual plate approximation	.001	20
Maxillary surgery	.002	8
Torque	.01	4.5
Extraction	.01	.5
Mandibular surgery	.05	3.6

Lingual plate approximation largely explains the other risk factors. Data from Kaley JD, Phillips C. *Angle Orthod.* 1991;61:125–131.

bone crest. For that reason alone, it would seem logical to suspect that another side effect of orthodontic treatment might be loss of alveolar bone height. In addition, there are two other potential risk factors: the blood supply at the bone crest is diminished relative to the thicker bone beneath it, and the presence of orthodontic appliances increases the amount of gingival inflammation, even with good hygiene.

Fortunately, excessive loss of crestal bone height is almost never seen as a complication of orthodontic treatment. Loss of alveolar crest height in one large series of patients averaged less than 0.5 mm and almost never exceeded 1 mm, with the greatest changes occurring at extraction sites.<sup>32</sup> Minimal effects on crestal alveolar bone levels also are observed on long-term follow-up of orthodontic patients. The reason is that the position of the teeth determines the position of the alveolar bone. When teeth erupt or are moved, they bring alveolar bone with them. The only exception is tooth

movement in the presence of active periodontal disease, and even adults who have had bone loss from periodontal disease can have orthodontic treatment with good bone responses if the periodontal disease is well controlled.

The relationship between the position of a tooth and alveolar bone height can be seen clearly when teeth erupt too much or too little. In the absence of pathologic factors, a tooth that erupts too much simply carries alveolar bone with it, often for considerable distances. It does not erupt out of the bone. But unless a tooth erupts into an area of the dental arch, alveolar bone will not form there. If a tooth is congenitally absent or extracted at an early age, a permanent defect in the alveolar bone will occur unless another tooth is moved into the area relatively rapidly. This is an argument against very early extraction, as in, for instance, the enucleation of an unerupted premolar. Early removal of teeth poses a risk of creating an alveolar bone defect that cannot be overcome by later orthodontic treatment.

Because an erupting tooth brings alveolar bone with it, orthodontic tooth movement can be used to create the alveolar bone needed to support an implant to replace a congenitally missing tooth. For instance, if a maxillary lateral incisor is missing and a prosthetic replacement is planned, it is advantageous to have the permanent canine erupt mesially, into the area of the missing lateral incisor, and then to move it back into its proper position toward the end of the growth period. This stimulates the formation of alveolar bone in the lateral incisor region that otherwise would have not formed.

The same effects on alveolar bone height are seen with orthodontic extrusion as with eruption: as long as the orthodontic treatment is carried out with reasonable force levels and reasonable speed of tooth movement, a tooth brought into the dental arch by extrusive orthodontic forces will bring alveolar bone with it. The height of the bone attachment along the root will be about the same at the conclusion of movement as at the beginning. In some circumstances, it is possible to induce bone formation where an implant will be required, by extruding the root of an otherwise hopelessly damaged tooth, so that new hard and soft tissue forms in the area. If a tooth is intruded, bone height tends to be lost at the alveolar crest, so that about the same percentage of the root remains embedded in bone as before, even if the intrusion was over a considerable distance.

In most circumstances, this tendency for alveolar bone height to stay at the same level is a therapeutic plus. Occasionally, it would be desirable to change the amount of tooth embedded in bone, either to expose more of the crown to facilitate restoration after an injury, or to create better bone support after bone loss due to periodontal disease. In theory, very rapid orthodontic extrusion to expose more of the crown would not be followed by alveolar bone. The effect, however, is greater trauma for an already compromised tooth, and it is better to extrude more slowly and then recontour the alveolar bone.

For a patient who had lost alveolar bone height because of periodontal disease, if it were possible to intrude teeth without compensatory changes in alveolar height, pocket depths would decrease and bony support for the teeth would be improved as the roots moved deeper into the bone. Otherwise, intrusion would just create additional loss of bone height, which is what usually happens. There are reports of therapeutic benefit from intruding periodontally involved teeth,<sup>33</sup> and that can be an important part of comprehensive treatment for a patient with severe periodontal problems (see Chapter 19). But when reduced pocketing occurs in those patients, it relates to the formation of a long junctional

epithelium, not to reattachment of the PDL or more extensive bony support.

## Enamel Demineralization

Enamel demineralization around the gingival edge of bands was a well-known problem when most teeth were banded, but banding only molar teeth and using glass ionomer rather than zinc phosphate cement largely solved this problem. Unfortunately, bonding brackets has made it worse. Although bonded brackets do not directly damage the teeth, the contours of a bracket make it a trap for food debris and more difficult to clean—which increases the risk of unsightly white lesions around the areas where brackets were.

Maxillary incisors, particularly lateral incisors, have the greatest likelihood of obvious demineralization. In a group of 338 patients treated in a university orthodontic clinic, clinical examinations revealed that 36% had at least one clearly visible lesion on a maxillary incisor tooth at the end of treatment despite preventive efforts. Risk factors were young age at the beginning of treatment, poor hygiene before the start of treatment, and citations for poor hygiene during treatment.<sup>34</sup> Light-induced fluorescence reveals less completely decalcified areas, and with this method Boersma et al found that all but 2 of 62 patients (97%) examined immediately after comprehensive orthodontic treatment had evidence of demineralization around or adjacent to bracket sites.<sup>35</sup> A recent study pointed out a less obvious but also quite prevalent problem: demineralization beneath the occlusal-coverage portion of a bonded maxillary expander, in which the cusp tips of nearly all the teeth were affected.<sup>36</sup>

The lesions can be carious or noncarious. Carious lesions are rough and porous, noncarious ones are smooth and shiny white spots. Some natural remineralization occurs, and the carious lesions have a better prognosis for this because the surface is porous. Nevertheless, the lesions are not likely to completely correct themselves. One 14-year follow-up study showed that most of the white spot lesions noted at the end of treatment were still there.<sup>37</sup>

Fluoridated water and a fluoride-containing toothpaste are effective as caries-controlling measures in the general population and should be considered an essential part of a program to prevent white spot lesions. There is some evidence that a daily 0.05% neutral sodium fluoride rinse is effective in preventing white spots. The major problem with the toothpaste and rinse, of course, is sporadic or no compliance. Optimal prevention requires a constant fluoride application to the area around the bracket. For caries-prone patients in general, a fluoride varnish application at 6-month intervals is recommended; for noncompliant orthodontic patients who are developing lesions, more frequent fluoride varnish applications may be helpful, although the evidence to support this is weak. A short-term daily chlorhexidine rinse program (usually 14 days) could be a last resort approach to a noncompliant patient with persistent plaque accumulation, despite the staining of teeth that occurs.

A number of fluoride-releasing bonding materials (usually composite resins impregnated with sodium fluoride) have been offered commercially in the hope that they would control demineralization around brackets, but a 2013 review of the published data concluded that there was no good evidence that any were effective against white spot formation around brackets.<sup>38</sup> The problem is that the fluoride release is large initially, then dwindles to little or nothing long before a typical 18- to 24-month orthodontic treatment is completed.

One way to control obvious white spot lesions is to put brackets on the lingual, not the labial, surface of the teeth. Although



demineralization does occur on the lingual surface, there is good evidence that it is significantly less than on the labial surface, probably because of greater saliva flow on the lingual side of the teeth.<sup>39</sup> A German study found that in lingual orthodontics for children and adolescents, the addition of a layer of hydrophilic resin decreased the number of white spot lesions by 70% and the remaining lesions were minor,<sup>40</sup> so this change can be recommended.

Fluoride release from the glass-ionomer cements that now are the standard material for band cementation (see Chapter 10) is more sustained over time than release from fluoride-impregnated bonding resins, because the glass-ionomer cement absorbs fluoride when it is provided, and then gradually discharges it. This incoming fluoride is primarily from dentifrices and oral rinses, but also to some extent comes from fluoridated drinking water. Bonding with glass ionomers, therefore, would be a way to obtain satisfactory fluoride release around brackets.

Unfortunately, glass ionomer cements are simply not strong enough for satisfactory bracket bonding. Glass ionomer cements with a small component of adhesive resin added increased the bond strength, but it was still unsatisfactory until a different surface preparation method developed by Justus and coworkers allowed a more retentive enamel surface after etching.<sup>41</sup>

This potentially useful method for decreasing or even eliminating enamel demineralization is presented in the section on bonding in Chapter 10.

## References

- Jacobs C, Grimm S, Ziebart T, et al. Osteogenic differentiation of periodontal fibroblasts is dependent on the strength of mechanical strain. *Arch Oral Biol.* 2013;58:896–904.
- Wei Y, Ye Q, Tang Z, et al. Calcitonin induces collagen synthesis and osteoblastic differentiation in human periodontal ligament fibroblasts. *Arch Oral Biol.* 2017;74:114–122.
- Thilander B. Tissue reactions in orthodontics. In: Graber LW, Vanarsdall R, Vig KWL, Huang GJ, eds. *Orthodontics: Current Principles and Techniques*. 6th ed. St. Louis: Elsevier; 2017.
- Pilla AA. Low-intensity electromagnetic and mechanical modulation of bone growth and repair: are they equivalent? *J Orthop Sci.* 2002;7:420–428.
- Shapiro E. Orthodontic movement using pulsating force-induced piezoelectricity. *Am J Orthod.* 1979;73:59–66.
- Darendeliler MA, Zea A, Shen G, et al. Effects of pulsed electromagnetic field vibration on tooth movement induced by magnetic and mechanical forces: a preliminary study. *Aust Dent J.* 2007;52:282–287.
- Khouw FE, Goldhaber P. Changes in vasculature of the periodontium associated with tooth movement in the rhesus monkey and dog. *Arch Oral Biol.* 1970;15:1125–1132.
- Kang YG, Nam JH, Kim KH, et al. FAK pathway regulates PGE<sub>2</sub> production in compressed periodontal ligament cells. *J Dent Res.* 2010;89:1444–1449.
- Yamaguchi M. RANK/RANKL/OPG during orthodontic tooth movement. *Orthod Craniofac Res.* 2009;12:113–119.
- Chen YW, Wang HC, Gao LH, et al. Osteoclastogenesis in local alveolar bone in early decortication-facilitated orthodontic tooth movement. *PLoS ONE.* 2016;11(4):e0153937.
- Roberts WE. Bone physiology, metabolism, and biomechanics in orthodontic practice. In: Graber LW, Vanarsdall RL, Vig KWL, Huang GH, eds. *Orthodontics: Current Principles and Techniques*. 6th ed. St. Louis: Elsevier; 2017.
- McGorray SP, Dolce C, Kramer S, et al. A randomized, placebo-controlled clinical trial on the effects of recombinant human relaxin on tooth movement and retention. *Am J Orthod Dentofacial Orthop.* 2012;141:196–203.
- Bartzela T, Turp JC, Motschall E, et al. Medication effects on the rate of orthodontic tooth movement: a systematic literature review. *Am J Orthod Dentofacial Orthop.* 2009;135:16–26.
- Zahrowski JJ. Optimizing orthodontic treatment in patients taking bisphosphonates for osteoporosis. *Am J Orthod Dentofacial Orthop.* 2009;135:361–374.
- Frost HM. Wolff's Law and bone's structural adaptations to mechanical usage: an overview for clinicians. *Angle Orthod.* 1994;64:175–188.
- Köle H. Surgical operations of the alveolar ridge to correct occlusal abnormalities. *Oral Surg Oral Med Oral Pathol.* 1959;12:515–529.
- Patterson BM, Dalci O, Darendeliler MA, Papadopolou AK. Corticotomies and orthodontic tooth movement: a systematic review. *J Oral Maxillofac Surg.* 2016;74:453–473.
- Yang C, Wang B, Deng F, et al. Biomechanical effects of corticotomy approaches on dentoalveolar structures during canine retraction: a 3-dimensional finite element analysis. *Am J Orthod Dentofacial Orthop.* 2015;148:457–465.
- Keser EI, Dibart S. Sequential piezocision: a novel approach to accelerated orthodontic treatment. *Am J Orthod Dentofacial Orthop.* 2013;144:879–889.
- Charavet C, Lecloux G, Bruwier A, et al. Localized piezoelectric decortication for orthodontic treatment in adults: a randomized controlled clinical trial. *J Dent Res.* 2016;95:1003–1009.
- Patterson BM, Dalci O, Papadopolou AK, et al. Effect of piezocision on root resorption associated with orthodontic force: a microcomputer tomography study. *Am J Orthod Dentofacial Orthop.* 2017;151:53–62.
- Pavlin D, Anthony R, Raj V, Gakunga PT. Cyclic loading (vibration) accelerates tooth movement in orthodontic patients: a double-blind, randomized controlled trial. *Semin Orthod.* 2015;21:187–194.
- Woodhouse NR, DiBiase AT, Johnson N, et al. Supplemental vibrational force during orthodontic alignment: a randomized clinical trial. *J Dent Res.* 2015;94:682–689.
- Miles P, Fisher E, Pandis N. Assessment of the rate of premolar extraction site space closure in the maxillary arch with the AcceleDent Aura appliance vs no appliance in adolescents: a single-blind randomized clinical trial. *Am J Orthod Dentofacial Orthop.* 2018;153:8–14, 25.
- DiBiase AT, Woodhouse NR, Papageorgiou SN, et al. Effects of supplemental vibrational force on space closure, treatment duration, and occlusal outcome: a multicenter randomized clinical trial. *Am J Orthod Dentofacial Orthop.* 2018;153:469–480.
- Quinn RS, Yoshikawa DK. A reassessment of force magnitude in orthodontics. *Am J Orthod.* 1985;88:252–260.
- Murdock S, Phillips C, Khondker Z, et al. Treatment of pain after initial arch wire placement: a noninferiority randomized clinical trial comparing over-the-counter analgesics and bite-wafer use. *Am J Orthod Dentofacial Orthop.* 2010;137:316–323.
- Pazzini CA, Pereira LJ, Marques LS, Ramos-Jorge J, Aparecida da Silva T, Paiva SM. Nickel-free vs conventional braces for patients allergic to nickel: gingival and blood parameters during and after treatment. *Am J Orthod Dentofacial Orthop.* 2016;150:1014–1019.
- Brudvik P, Rygh P. Transition and determinants of orthodontic root resorption-repair sequence. *Eur J Orthod.* 1995;17:177–188.
- Llamas-Carreras JM, Amarilla A, Solano E, et al. Study of external root resorption during orthodontic treatment in root filled teeth compared with their contralateral teeth with vital pulps. *Int Endod J.* 2010;43:654–662.
- Artun J, Van t'Hullenaar R, Doppel D, et al. Identification of orthodontic patients at risk of severe apical root resorption. *Am J Orthod Dentofacial Orthop.* 2009;135:448–455.
- Kaley JD, Phillips C. Factors related to root resorption in edgewise practice. *Angle Orthod.* 1991;61:125–131.
- Kennedy DB, Joondoph DR, Osterburg SK, et al. The effect of extraction and orthodontic treatment on dentoalveolar support. *Am J Orthod.* 1983;84:183–190.
- Melsen B, Agerbaek N, Markenstam G. Intrusion of incisors in adult patients with marginal bone loss. *Am J Orthod Dentofacial Orthop.* 1989;96:232–241.

34. Chapman JA, Roberts WE, Eckert GJ, et al. Risk factors and severity of white spot lesions during treatment with fixed orthodontic appliances. *Am J Orthod Dentofacial Orthop.* 2010;138:188–194.
35. Boersma JG, van der Veen MH, Lagerweij MD, et al. Caries prevalence measured with quantitative light-induced fluorescence after treatment with fixed orthodontic appliances: influencing factors. *Caries Res.* 2005;39:41–47.
36. Yagci A, Korkmaz YN, Buyuk SK, et al. White spot lesion formation after treatment with full-coverage maxillary expanders. *Am J Orthod Dentofacial Orthop.* 2016;149:331–338.
37. Shungin D, Olsson DI, Persson M. Orthodontic treatment-related white spot lesions: a 14-year prospective quantitative follow-up, including bonding material assessment. *Am J Orthod Dentofacial Orthop.* 2010;138:136e1–136e8, discussion 136–137.
38. Benson PE, Parkin N, Dyer F, et al. Fluorides for prevention of early tooth decay (demineralized white lesions) during fixed brace treatment. *Cochrane Database Syst Rev.* 2013;doi:10.1002/14651858.
39. Wiechmann D, Klang E, Helms HJ, Knosel M. Lingual appliances reduce the incidence of white spot lesions during orthodontic multi-bracket treatment. *Am J Orthod Dentofacial Orthop.* 2015;148:414–422.
40. Beyling F, Schwestka-Polly R, Wiechmann D. Lingual orthodontics for children and adolescents: improvement of the indirect bonding protocol. *Head Face Med.* 2013;9:27.
41. Justus R, Cubero T, Ondarza R, et al. A new technique with sodium hypochlorite to increase bracket shear bond strength of fluoride-releasing resin-modified glass ionomer cements: comparing shear bond strength of two adhesive systems with enamel surface deproteinization before etching. *Semin Orthod.* 2010;16:66–75.

# 9

## Mechanical Principles in Orthodontic Force Control

### CHAPTER OUTLINE

#### Elastic Materials and the Production of Orthodontic Force

- The Basic Properties of Elastic Materials
- Orthodontic Archwire Materials
- Effects on Elastic Properties of Beams
- Other Sources of Elastic Force

#### Design Factors in Orthodontic Appliances

- Two-Point Contact for Control of Root Position
- Narrow Versus Wide Brackets in Fixed Appliance Systems
- Effect of Bracket Slot Size in the Edgewise System

#### Mechanical Aspects of Anchorage Control

- Friction Versus Binding in Resistance to Sliding
- Methods to Control Anchorage

#### Determinate Versus Indeterminate Force Systems

- One-Couple Systems
- Two-Couple Systems
- Segmented Arch Mechanics
- Continuous Arch Mechanics

Optimum orthodontic tooth movement is produced by light, continuous force. The challenge in designing and using an orthodontic appliance is to produce a force system with these characteristics, creating forces that are neither too great nor too variable over time. It is particularly important that light forces do not decrease rapidly, decaying away either because the material itself loses its elasticity or because a small amount of tooth movement causes a larger change in the amount of force delivered. Both the behavior of elastic materials and mechanical factors in the response of the teeth must be considered in the design of an orthodontic appliance system through which mechanotherapy is delivered.

### Elastic Materials and the Production of Orthodontic Force

#### The Basic Properties of Elastic Materials

The elastic behavior of any material is defined in terms of its stress–strain response to an external load. Both *stress* and *strain* refer to the internal state of the material being studied: stress is

the internal distribution of the load, defined as force per unit area, whereas strain is the internal distortion produced by the load, defined as deflection per unit length.

For analysis, orthodontic archwires and springs can be considered as beams, supported either only on one end (e.g., a spring projecting from a removable appliance) or on both ends (the segment of an archwire spanning between attachments on adjacent teeth) (Fig. 9.1). If a force is applied to such a beam, its response can be measured as the deflection (bending or twisting) produced by the force (Fig. 9.2). Force and deflection are external measurements. Internal stress and strain can be calculated from force and deflection by considering the cross-sectional area and length of the beam.

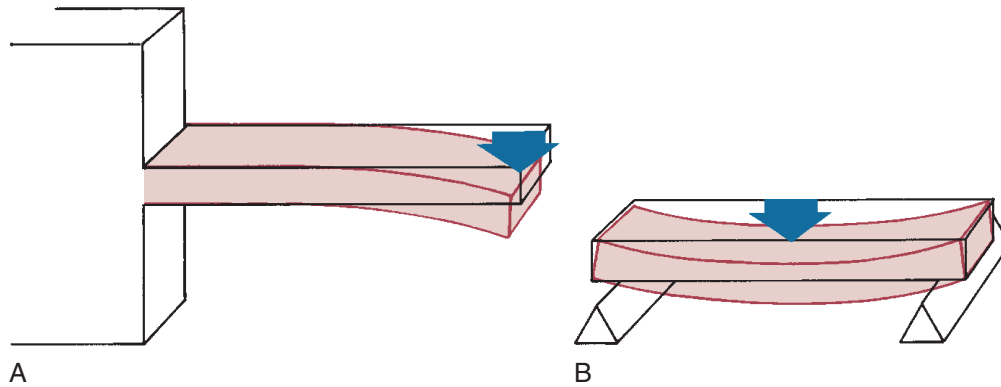
For orthodontic purposes, three major properties of beam materials are critical in defining their clinical usefulness: strength, stiffness, and range. Each can be defined by appropriate reference to a force–deflection or stress–strain diagram (Figs. 9.2 and 9.3).

Three different points on a stress–strain diagram can be taken as representative of the strength of a material (see Fig. 9.3). Each represents, in a somewhat different way, the maximum load that the material can resist. The first two points attempt to describe the elastic limit of the material, the point at which any permanent deformation is first observed. The most conservative measure is the *proportional limit*, the highest point where stress and strain still have a linear relationship (this linear relationship is known as *Hooke's law*). Precisely determining this point can be difficult, so a more practical indicator is the *yield strength*—the intersection of the stress–strain curve with a parallel line offset at 0.1% strain. Typically, the true *elastic limit* lies between these two points, but both serve as good clinical estimates of how much force or deflection a wire can withstand before permanent deformation occurs. The maximum load the wire can sustain—the *ultimate tensile strength*—is reached after some permanent deformation and is greater than the yield strength. This ultimate strength determines the maximum force the wire can deliver if used as a spring, so it also is important clinically, especially because yield strength and ultimate strength differ much more for the newer titanium alloys than for steel wires.

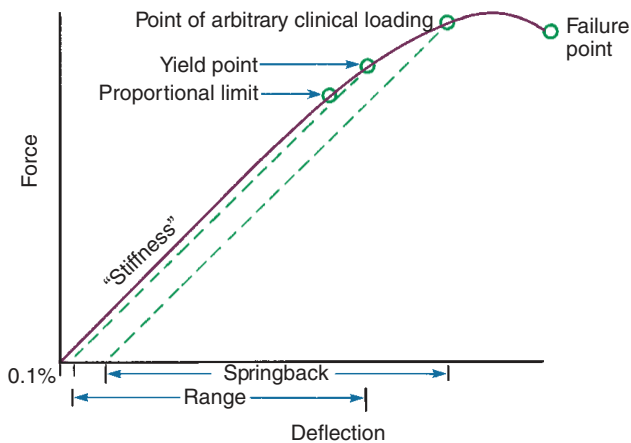
*Strength* is measured in units of stress—the SI (International System of Units) unit is the pascal (Pa), but English units such as gm/cm<sup>2</sup> are still frequently encountered. Data in megapascals (MPa) now appear frequently in orthodontic journals, and MPa will be used in the rest of this text. Other commonly encountered units of stress are gm/cm<sup>2</sup> and psi (1 MPa = 10,197 gm/cm<sup>2</sup> = 145 psi).

*Stiffness* is proportional to the slope of the elastic portion of the force–deflection curve (see Fig. 9.2). The more vertical the slope, the stiffer the wire, the more horizontal the slope, the more flexible the wire.

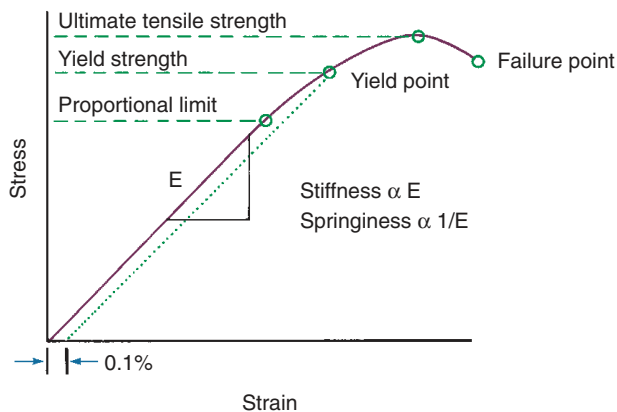




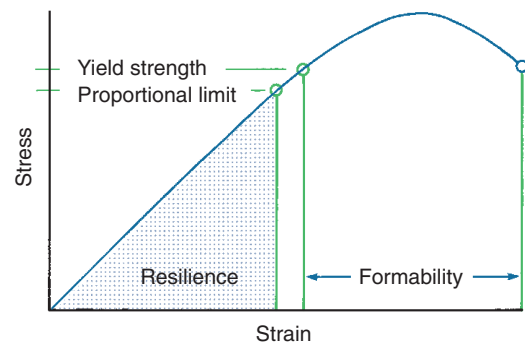
• **Fig. 9.1** Cantilever (A) and supported beams (B).



• **Fig. 9.2** A typical force–deflection curve for an elastic material like an orthodontic archwire. The stiffness of the material is given by the slope of the linear portion of the curve. The range is the distance along the x-axis to the point at which permanent deformation occurs (usually taken as the yield point, at which 0.1% permanent deformation has occurred). Clinically useful springback occurs if the wire is deflected beyond the yield point (as to the point indicated here as “arbitrary clinical loading”), but it no longer returns to its original shape. At the failure point, the wire breaks.



• **Fig. 9.3** Stress and strain are internal characteristics that can be calculated from measurements of force and deflection, so the general shapes of force–deflection and stress–strain curves are similar. Three different points, as noted here on a stress–strain diagram, can be taken as representing the strength. The slope of the stress–strain curve ( $E$ ) is the modulus of elasticity, to which stiffness and springiness are proportional.



• **Fig. 9.4** Resilience and formability are defined as an area under the stress–strain curve and a distance along the x-axis, respectively, as shown here. Because the plastic deformation that makes a material formable also may be thought of as cold work, formability alternatively can be interpreted as the area under that part of the stress–strain curve.

*Range* is defined as the distance that the wire will bend elastically before permanent deformation occurs. For orthodontics, this distance is measured in millimeters (see Fig. 9.2). If the wire is deflected beyond this point, it will not return to its original shape, but clinically useful springback will still occur unless the failure point is reached. This springback is measured along the horizontal axis as shown in Fig. 9.2. Orthodontic wires often are deformed beyond their elastic limit, so springback properties are important in determining clinical performance.

These three major properties have an important relationship:

$$\text{Strength} = \text{Stiffness} \times \text{Range}$$

Two other characteristics of some clinical importance also can be illustrated with a stress–strain diagram: resilience and formability (Fig. 9.4). *Resilience* is the area under the stress–strain curve out to the proportional limit. It represents the energy storage capacity of the wire, which is a combination of strength and springiness. *Formability* is the amount of permanent deformation that a wire can withstand before failing. It represents the amount of permanent bending the wire will tolerate (while being formed into a clinically useful spring, for instance) before it breaks.

The properties of an ideal wire material for orthodontic purposes can be described largely in terms of these criteria: it should possess (1) high strength, (2) low stiffness (in most applications), (3) high range, and (4) high formability. In addition, the material should

be weldable or solderable, so that hooks or stops can be attached to the wire. It should also be reasonable in cost. In contemporary practice, no one archwire material meets all these requirements, and the best results are obtained by using specific archwire materials for specific purposes.

In the United States, orthodontic appliance dimensions, including wire sizes, are specified in thousandths of an inch. For simplicity in this text, they are given in mils (i.e., 0.016 inch = 16 mil). In Europe and many other areas of the world, appliance dimensions are specified in millimeters. For the range of orthodontic sizes, a close approximation of sizes in millimeters can be obtained by dividing the dimensions in mils by 4 and moving the decimal point one place to the left (i.e., 16 mil = 0.4 mm; 40 mil = 1.0 mm).

## Orthodontic Archwire Materials

### Precious Metal Alloys

In the first half of the 20th century, precious metal alloys were used routinely for orthodontic purposes, primarily because nothing else would tolerate intraoral conditions. Gold itself is too soft for nearly all dental purposes, but alloys (which often included platinum and palladium along with gold and copper) could be useful orthodontically. The introduction of stainless steel made precious metal alloys obsolete for orthodontic purposes even before precious metals became prohibitively expensive. Currently, the only considerable advantage to gold is the ease of fabricating cast appliances, such as custom-fit bonding pads used with fixed lingual appliances (see [Chapter 10](#)).

### Stainless Steel and Cobalt–Chromium Alloys

Stainless steel, or a cobalt–chromium alloy (Elgiloy; Rocky Mountain Co.) with similar properties, replaced precious metal in orthodontics because of considerably better strength and springiness with equivalent corrosion resistance. Stainless steel's rust resistance results from a relatively high chromium content. A typical formulation for orthodontic use has 18% chromium and 8% nickel (thus the material is often referred to as an 18-8 stainless steel).

The properties of these steel wires can be controlled over a reasonably wide range by varying the amount of cold working and annealing during manufacture. Steel is softened by annealing and hardened by cold working. Fully annealed stainless steel wires are soft and highly formable. The steel ligatures used to tie orthodontic archwires into brackets on the teeth are made from such “dead soft” wire. Steel archwire materials are offered in a range of partially annealed states, in which yield strength is progressively enhanced at the cost of formability. The steel wires with the most impressive yield strength (“super” grades) are almost brittle and will break if bent sharply. The “regular” grade of orthodontic steel wire can be bent to almost any desired shape without breaking. If sharp bends are not needed, the super wires can be useful, but it is difficult to show improved clinical performance that justifies either their higher cost or limited formability.

Elgiloy, the cobalt–chromium alloy, has the advantage that it can be supplied in a softer and therefore more formable state, and the wires can be hardened by heat treatment after being shaped. The heat treatment increases strength significantly. After heat treatment, the softest Elgiloy becomes equivalent to regular stainless steel, while harder initial grades are equivalent to the “super” steels. This material, however, had almost disappeared by the end of the 20th century because of its additional cost relative to stainless steel and the extra step of heat treatment to obtain optimal properties, and it is used only rarely at present.

## Nickel–Titanium Alloys

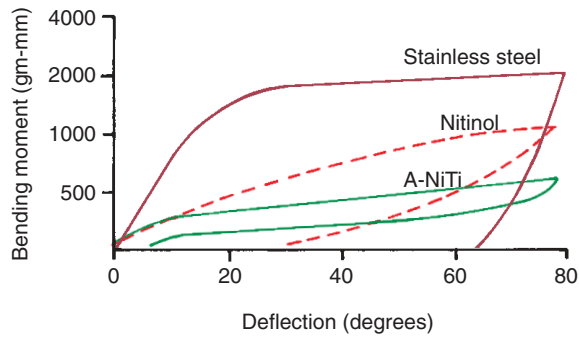
**Properties of Nickel–Titanium Alloys.** Nickel–titanium alloys have an exceptional ability to deliver light force over a large range of activation, making these archwires the material of choice during initial alignment in modern orthodontics. The first nickel–titanium alloy was developed for the space program and named *Nitinol* (Ni, nickel; Ti, titanium; NOL, Naval Ordnance Laboratory). In this book, the term *NiTi* is used subsequently to refer to the family of nickel–titanium wire materials (*nitinol*, with the word not capitalized, is used in the same way in some other publications). Reference to a specific material is by its trademark (capitalized) name.

The properties of NiTi alloys cannot be discussed without first understanding that these alloys can exist in more than one crystal structure at intraoral temperature. At higher temperatures and lower stress, the alloy exists in a simple cubic structure called *austenite*. At lower temperatures and higher stress, the alloy is more stable in a monoclinic phase called *martensite*. Although many metal alloys exist in different crystal structures, the uniqueness of NiTi is that the transition between the two structures is fully reversible and may occur at an intraoral temperature. This phase transition allows certain NiTi alloys to exhibit two remarkable properties found in no other archwire materials—heat-activation and superelasticity.

*Heat-activation* refers to the ability of the material to go from a martensitic state to an austenitic state when its temperature is increased. This temperature-induced change in crystal structure (called *thermoelasticity*) was important to the original Nitinol used in the space program but proved difficult to exploit in orthodontic applications. Many companies still heavily promote heat-activation properties of their wires, but keep in mind that clinicians do not add slow, controlled temperature change during this initial alignment stage to incrementally move the material to its austenitic phase. These wires typically express other desirable properties and are still highly useful, but the most clinically applicable property is not the thermoelastic phase transformation.

One unique property of some alloys that go through a heat-activated phase transformation is shape memory. *Shape memory* refers to the ability of the material to “remember” its original shape after being plastically deformed while in the martensitic form. In a typical application, a certain shape is set while the alloy is maintained at an elevated temperature, above the martensite–austenite transition temperature. When the alloy is cooled below the transition temperature, it can be plastically deformed in the martensitic state, but the original shape is restored when it is heated enough to regain an austenitic structure.

*Superelasticity* refers to the very large reversible strains that certain NiTi wires can withstand due to the martensite–austenite phase transition. This reversible deformation can be over 10 times greater than similar dimension archwires in other materials. In engineering applications, it also is frequently described as pseudoelasticity, owing to the nonlinear stress–strain curve ([Fig. 9.5](#)), which is not typical elastic behavior obeying the linear stress–strain relationship of Hooke's Law. Materials displaying superelasticity are austenitic alloys that undergo a transition to martensite in response to stress—a mechanical analogue to the thermally induced shape memory effect. This is possible because the transition temperature is very close to room temperature. Most archwire materials can be reversibly deformed only by stretching interatomic bonds (which creates the linear region of the stress–strain curve), while superelastic materials can undergo a reversible change in internal structure after a certain amount of deformation. This stress-induced martensitic



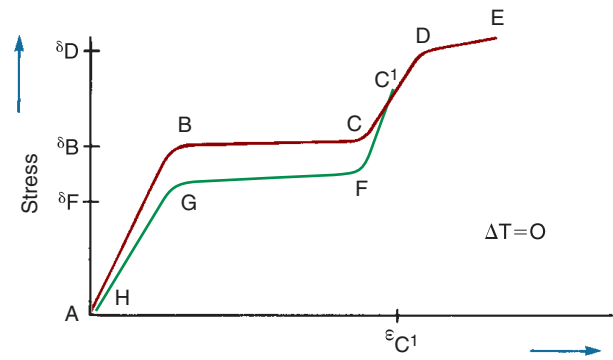
• **Fig. 9.5** Bending moment versus deflection plotted for 16-mil orthodontic wires (solid red, stainless steel; dashed red, stabilized martensitic nickel–titanium [M-NiTi]; green, austenitic NiTi [A-NiTi]). Note that after an initial force level is reached, A-NiTi has a considerably flatter load–deflection curve and greater springback than M-NiTi, which in turn has much more springback than steel. (Redrawn from Burstone CJ, Qin B, Morton JY. *Am J Orthod.* 1985;87:445–452.)

transformation manifests in the almost flat section of the load–deflection curve. This means that an initial archwire can exert about the same force whether it was deflected a relatively small or large distance, which is a unique and extremely desirable characteristic (Fig. 9.6). For a change, superelasticity is not just another advertising term.

Although shape memory is a thermal reaction and superelasticity is a mechanical one, they are inherently linked. Superelastic materials must exhibit a reversible phase change at a close transition temperature, which must be lower than intraoral temperature for the austenite phase to exist clinically once placed in the mouth. Shape memory alloys only have exceptional range clinically if stress-induced transformation also occurs. Otherwise, in order to keep the force light, the temperature would have to be slowly increased as the teeth come closer to alignment—which, again, does not occur clinically. Because of the close interaction of these properties, wires displaying martensite–austenite transitions are subsequently referred to as *austenitic nickel–titanium* (A-NiTi). All other NiTi wires are stabilized in the martensitic form without undergoing intraoral phase transformations and are subsequently referred to as *martensitic nickel–titanium* (M-NiTi).

**Nickel–Titanium Wires in Clinical Orthodontics.** The original Nitinol wires marketed under that name in the late 1970s by Unitek were M-NiTi wires, with no application of phase transition effects. As supplied for orthodontic use, Nitinol is exceptionally springy and quite strong but has poor formability (Table 9.1). In the late 1980s, new nickel–titanium wires with an austenitic grain structure (A-NiTi) appeared. These wires (Sentinol, GAC; Copper NiTi,Ormco/Sybron; and several other trade names from other suppliers) exhibit superelasticity and/or shape memory in various degrees. Without laboratory data, however, it is dangerous to assume that wires advertised as superelastic really are,<sup>1</sup> so care in purchasing is advised. Data for performance under controlled conditions, not testimonials from prominent clinicians, should be the basis for choosing a specific wire.

Part of the unusual nature of a superelastic material such as A-NiTi is that its unloading curve differs from its loading curve (i.e., the reversibility has an energy loss associated with it [hysteresis]) (Fig. 9.7). This means the force that it delivers is not the same as



• **Fig. 9.6** A stress–strain curve illustrating superelasticity due to the stress-induced transformation from the austenitic to the martensitic phase, as in an austenitic nickel–titanium (A-NiTi) archwire. Section A–B represents purely elastic deformation of the austenitic phase (note in Fig. 9.5 that in this phase A-NiTi is stiffer than martensitic nickel–titanium [M-NiTi]). The stress corresponding to point B is the minimum stress at which transformation to the martensitic phase starts to occur. At point C, the transformation is completed. The difference between the slopes of A–B and B–C indicates the ease with which transformation occurs. After the transformation is completed, the martensitic structure deforms elastically, represented by section C–D (but orthodontic archwires are almost never stressed into this region, and this part of the graph usually is not seen in illustrations of the response of orthodontic archwires). At point D, the yield stress of the martensitic phase is reached, and the material deforms plastically until failure occurs at E. If the stress is released before reaching point D (as at point C' in the diagram), elastic unloading of the martensitic structure occurs along the line C'–F. Point F indicates the maximum stress on which the stress-induced martensitic structure on unloading can exist, and at that point the reverse transformation to austenite begins, continuing to point G, where the austenitic structure is completely restored. G–H represents the elastic unloading of the austenite phase. A small portion of the total strain may not be recovered because of irreversible changes during loading or unloading.

the force applied to activate it. The different loading and unloading curves produce the even more remarkable effect that the force delivered by an A-NiTi wire can be changed during clinical use merely by releasing and retying it (Fig. 9.8).

For the orthodontist, wire bending in the classic sense is all but impossible with A-NiTi wires because they do not undergo plastic deformation until remarkably deformed (see Fig. 9.5). The wires can be shaped and their properties can be altered, however, by heat treatment. This can be done in the orthodontic office by passing an electric current between electrodes attached to the wire or a segment of it. Miura et al were the first to show that it is possible to reposition the teeth on a dental cast to the desired posttreatment occlusion, bond brackets to the set-up, force an A-NiTi wire into the brackets, and then heat-treat the wire so that it “memorizes” its shape with the teeth in the desired position.<sup>2</sup> The wire then incorporates all of what would otherwise be the “finishing bends” usually required in the last stages of treatment.

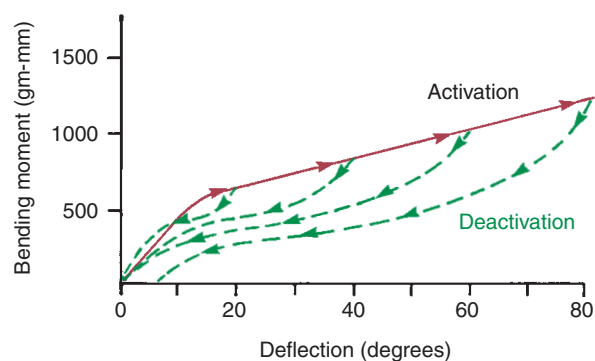
In theory at least, this allows certain types of treatment to be accomplished with a single wire, progressively bringing the teeth toward their predetermined position. The concept is exactly the same as Edward Angle's original approach to arch expansion, which implies that the same limitations would be encountered. At present, however, this approach is used primarily in computer-assisted fabrication of the initial archwires for lingual orthodontics (see



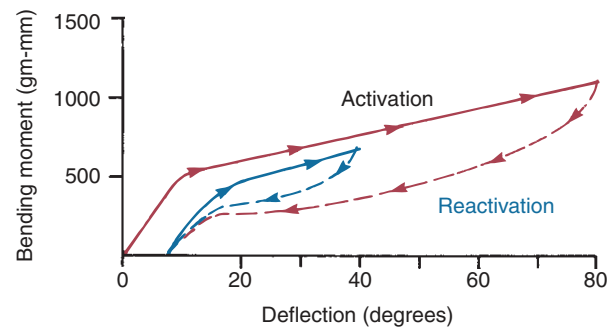
TABLE 9.1 Comparative Properties of Orthodontic Wires

	Modules of Elasticity (GPa)	Material Stiffness Relative to Steel	Set Angle (Degrees) <sup>a</sup>
Gold (heat-treated)	83	0.41	12
Stainless steel <i>Truchrome</i> —Rocky Mountain	200	1.00	NA
Australian stainless steel <i>Australian</i> —TP Labs	193	0.97	12
Cobalt–chromium <i>Elgiloy</i> —Rocky Mountain	193	0.97	16
Cobalt–chromium (heat-treated) <i>Elgiloy</i> —Rocky Mountain	200	1.00	35
Beta-titanium <i>TMA</i> —Ormco	72	0.36	87
A–NiTi <i>Nitinol SE</i> —Unitek	83 <sup>b</sup>	0.41	NA
M–NiTi <i>Nitinol</i> —Unitek	33	0.17	42
Triple strand 9 mil <i>Triple-flex</i> —Ormco	27 <sup>c</sup>	0.13	62
Coaxial 6 strand <i>Respond</i> —Ormco	8.6 <sup>c</sup>	0.04	49
Braided rectangular 9 strand <i>Force 9</i> —Ormco	10 <sup>c</sup>	0.05	56
Braided rectangular 8 strand <i>D-Rect</i> —Ormco	8.6 <sup>c</sup>	0.04	88
Braided rectangular A–NiTi <i>Turbo</i> —Ormco	3.4 <sup>c</sup>	0.02	88

<sup>a</sup>Degrees of bending around 1-inch radius before permanent deformation.  
<sup>b</sup>From initial elastic part of force–deflection curve.  
<sup>c</sup>Apparent modulus, calculated.  
A–NiTi, Austenitic nickel–titanium; M–NiTi, martensitic nickel–titanium.



• **Fig. 9.7** Activation (*solid*) and deactivation (*dashed*) curves for austenitic nickel–titanium (A–NiTi) wire. Note that the unloading curves change at different activations (i.e., the unloading stiffness is affected by the degree of activation). In contrast, the unloading stiffness for steel, beta-titanium (beta-Ti), and martensitic nickel–titanium (M–NiTi) wires is the same for all activations. (Redrawn from Burstone CJ, Qin B, Morton JY. *Am J Orthod.* 1985;87:445–452.)



• **Fig. 9.8** Red lines, activation to 80 degrees (*solid line*) and deactivation (*dashed line*) for superelastic nickel–titanium (NiTi) wire; blue lines, reactivation of the wire to 40 degrees. In each case, the deactivation (unloading) curve indicates the force that would be delivered to a tooth. Note that the amount of force exerted by a piece of austenitic nickel–titanium (A–NiTi) wire that had previously been activated to 80 degrees (shown by the upper deactivation curve) could be considerably increased by untying it from a bracket and then retying it—again, a unique property of this alloy. (Redrawn from Burstone CJ, Qin B, Morton JY. *Am J Orthod.* 1985;87:445–452.)

later section in this chapter), and there is no attempt to do everything with one archwire.

The properties of A-NiTi have quickly made it the preferred material for orthodontic applications in which a long range of activation with relatively constant force is needed (i.e., for initial archwires and coil springs). M-NiTi remains useful, primarily in the later stages of treatment when flexible but larger and somewhat stiffer wires are needed. At this point, small round nickel–titanium wires usually should be A-NiTi to take advantage of its large range. Rectangular A-NiTi wires, however, do not have enough torsional stiffness to be effective torquing arches, so larger rectangular wires used for more detailed positioning of teeth perform better if made from another archwire material.

**Beta-Titanium.** In the early 1980s, after Nitinol but before A-NiTi, a quite different titanium alloy, beta-titanium (beta-Ti), was introduced into orthodontics. This beta-Ti material (TMA, Ormco/Sybron [the name is an acronym for *titanium-molybdenum alloy*]), was developed primarily for orthodontic use. It offers a highly desirable combination of strength and springiness (i.e., excellent resilience), as well as reasonably good formability. This makes it an excellent choice for auxiliary springs and for intermediate and finishing archwires, especially rectangular wires for the late stages of edgewise treatment.

**Composite Plastics.** The new orthodontic materials of recent years have been adapted from those used in aerospace technology. The high-performance aircraft of the 1980s and 1990s were titanium-based, but their replacements are being built (with some difficulty) of composite plastics (e.g., Boeing's 787 or the U.S. military's Lockheed Martin F-35). Orthodontic technology tends to trail aerospace technology by 15 to 20 years, and orthodontic "wires" of composite materials were shown in the laboratory 10 years ago to have desirable properties<sup>3</sup> but have not yet come into clinical use because of problems with stability and performance under intraoral conditions.<sup>4,5</sup> It was more than a decade before the first NiTi wires went from clinical curiosity to regular use, and a similar time period may be needed to bring the composite plastics into routine clinical orthodontics.

### Comparison of Contemporary Archwires

Strength, stiffness, and range for stainless steel, beta-Ti, and M-NiTi wires are compared in Fig. 9.9 (also see Table 9.1 for other comparative data). Note that in many ways the properties of beta-Ti are intermediate between stainless steel and M-NiTi, and all three archwire materials are important in contemporary orthodontic practice. Their comparative properties explain why specific wires are preferred for specific clinical applications (which are discussed further in Chapters 15 through 19). Hooke's law (which defines the linear elastic behavior of materials illustrated in Figs. 9.2, 9.3, and 9.4) applies to all orthodontic wires except superelastic A-NiTi. For everything else, a useful method for comparing two archwires of various materials, sizes, and dimensions is the use of ratios of the major properties (strength, stiffness, and range):

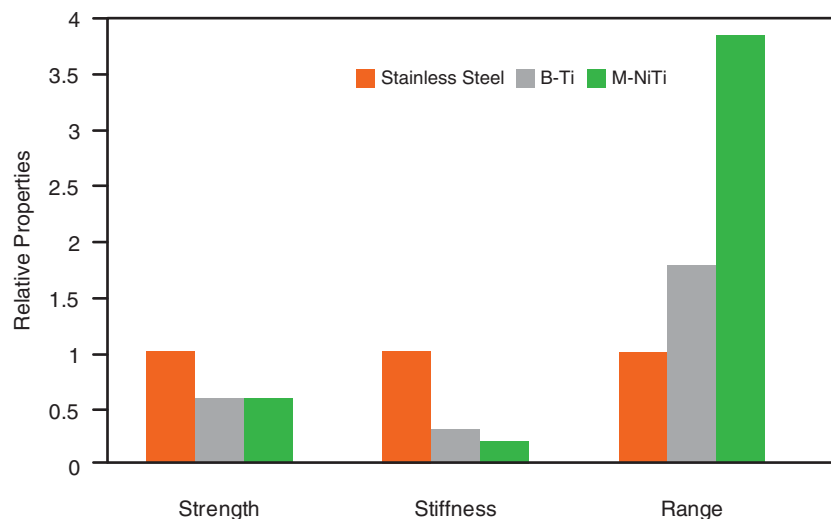
$$\text{Strength A/Strength B} = \text{Strength ratio}$$

$$\text{Stiffness A/Stiffness B} = \text{Stiffness ratio}$$

$$\text{Range A/Range B} = \text{Range ratio}$$

These ratios were calculated for many different wires by the late Robert Kusy,<sup>6</sup> and the data presented here are taken from his work. When the comparative properties of wires are considered, it is important to keep two things in mind:

1. Bending describes round wires reasonably completely in orthodontic applications, but both bending and torsional stresses are encountered when rectangular wires are placed into rectangular attachments on teeth. The fundamental relationships for torsion are analogous to those in bending but are not the same. Appropriate use of the equations for torsion, however, allows torsion ratios to be computed in the same way as bending ratios.
2. The ratios apply to the linear portion of the load-deflection curve and thus do not accurately describe the behavior of wires that are stressed beyond their elastic limit but still have useful springback. This is an increasingly significant limitation as consideration passes from steel or chromium–cobalt to beta-Ti



• **Fig. 9.9** The relative strength, stiffness, and range for stainless steel, B-Ti, and martensitic nickel–titanium (M-NiTi) wires (which would be the same for any wire size). Note that both B-Ti and M-NiTi have half the strength of steel; M-NiTi has slightly less stiffness but much more range than B-Ti.

to M-NiTi. The nonlinear response of A-NiTi makes calculation of ratios for it all but impossible. Nevertheless, the ratios offer an initial understanding of the properties of traditional steel wires as compared with the newer titanium alloys, and they can be quite helpful in appreciating the effects of changing wire size and geometry in a typical archwire sequence.

An efficient method for comparing different wire materials and sizes (within the limitations described earlier) is the use of bar charts such as Fig. 9.10 that show the strength, stiffness, and range of stainless steel, M-NiTi, and beta-Ti relative to a common reference, in this case 12-mil stainless steel. Note that because all wire types and sizes are compared with the same reference, wires of different materials, as well as different sizes, can be compared. Fig. 9.11 gives comparative information for torsion in a similar way.

These bar charts are particularly helpful in allowing one to assess at a glance a set of relationships that would require pages of tables. For example, let's use Fig. 9.11 to compare  $21 \times 25$  M-NiTi with  $21 \times 25$  beta-Ti in torsion (the appropriate comparison if the wires would be used to produce a torquing movement of the root of a tooth).

- The  $21 \times 25$  beta-Ti has a torsional stiffness value of 6, whereas  $21 \times 25$  M-NiTi has a value of 3, so the beta-Ti wire would deliver twice the force at a given deflection.
- The strength value for  $21 \times 25$  beta-Ti wire is 4, whereas the value for this size M-NiTi wire is 6, so the NiTi wire is less likely to become permanently distorted if twisted into a bracket.
- The range value for  $21 \times 25$  beta-Ti is 0.7, whereas the same size M-NiTi has a range value of 1.9, so the NiTi could be twisted nearly three times as far.

The bar charts contain the information to allow a similar comparison of any one of the wire sizes listed versus any other wire shown on the chart, in bending (see Fig. 9.10) or torsion (see Fig. 9.11).

## Effects on Elastic Properties of Beams

Each of the major elastic properties—strength, stiffness, and range—is substantially affected by the geometry of a beam. Both the cross-section (whether the beam is circular, rectangular, or square) and the length of a beam are of great significance in determining its properties.

### Geometry: Size and Shape

Changes related to size and shape are independent of the material. In other words, decreasing the diameter of a steel beam by 50% would reduce its strength to a specific percentage of what it had been previously (the exact reduction would depend on how the beam was supported, as we discuss later). Decreasing the diameter of a similarly supported TMA beam by 50% would reduce its strength by exactly the same percentage as the steel beam. But keep in mind that the performance of a beam, whether beneath a highway bridge or between two teeth in an orthodontic appliance, is determined by the combination of material properties and geometric factors.

**Cantilever Beams.** Let us begin by considering a cantilever beam supported on only one end. In orthodontic applications, this is the type of spring often used in removable appliances, in which a wire extends from the plastic body of the removable appliance as a fingerspring. When a round wire is used as a fingerspring, doubling the diameter of the wire increases its strength eight times (i.e., the larger wire can resist eight times as much

force before permanently deforming or can deliver eight times as much force). Doubling the diameter, however, increases stiffness by a factor of 16 and decreases range by a factor of 2.

More generally, for a round cantilever beam, the strength of the beam changes as the third power of the ratio of the larger to the smaller beam; stiffness changes as the fourth power of the ratio of the larger to the smaller; and range changes directly as the ratio of the smaller to the larger (Fig. 9.12).

**Supported Beams.** The situation is somewhat more complex for a beam supported on both ends, as is the case for a segment of archwire between two teeth. Supporting both ends makes the beam stronger and less flexible, particularly if the ends are tightly anchored as opposed to being free to slide. If a rectangular beam is evaluated, its dimension in the direction of bending is the primary determinant of its properties. The principle with any supported beam, however, is the same as with a cantilever beam: as the beam size increases, strength increases as a cubic function, whereas stiffness increases as a fourth power function and range decreases proportionately, not exponentially.

Although round beams can be placed in torsion in engineering applications, torsion is of practical importance in orthodontics only for rectangular wires that can be twisted into rectangular slots. In torsion, the analytic approach is basically similar to that in bending, but shear stress rather than bending stress is encountered, and the appropriate equations are all different. The overall effect is the same, however: Decreasing the size of a wire decreases its strength and stiffness in torsion while increasing its range, just as in bending.

As the diameter of a wire decreases, its strength decreases so rapidly that a point is reached at which the strength is no longer adequate for orthodontic purposes. As the diameter increases, its stiffness increases so rapidly that a point is reached at which the wire is simply too stiff to be useful. These upper and lower limits establish the wire sizes useful in orthodontics. The phenomenon is the same for any material, but the useful sizes vary considerably from one material to another. As Table 9.2 indicates, useful steel wires are considerably smaller than the gold wires they replaced. The titanium wires are much springier than steel wires of equal sizes but not as strong. Their useful sizes therefore are larger than steel and quite close to the sizes for gold.

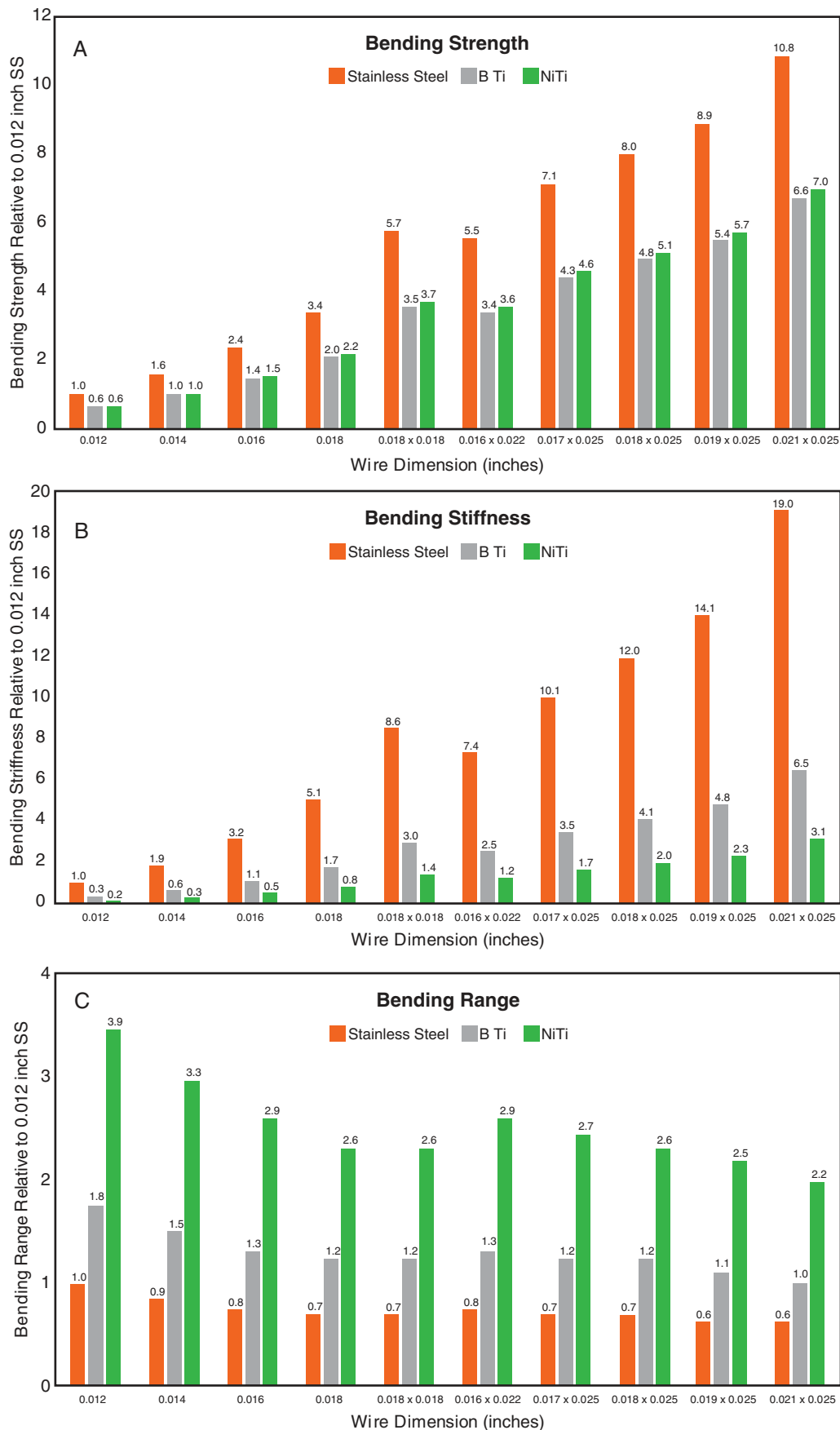
### Geometry: Length and Attachment

Changing the length of a beam, whatever its size or the material from which it is made, also dramatically affects its properties (Fig. 9.13). If the length of a cantilever beam is doubled, its bending strength is cut in half, its springiness decreases eight times, and its range increases four times. More generally, when the length of a cantilever beam increases, its strength decreases proportionately, its stiffness decreases as the cubic function of the ratio of the length, and its range increases as the square of the ratio of the length. Length changes affect torsion quite differently from bending: stiffness decreases and range increases proportionally with length, whereas torsional strength is not affected by length.

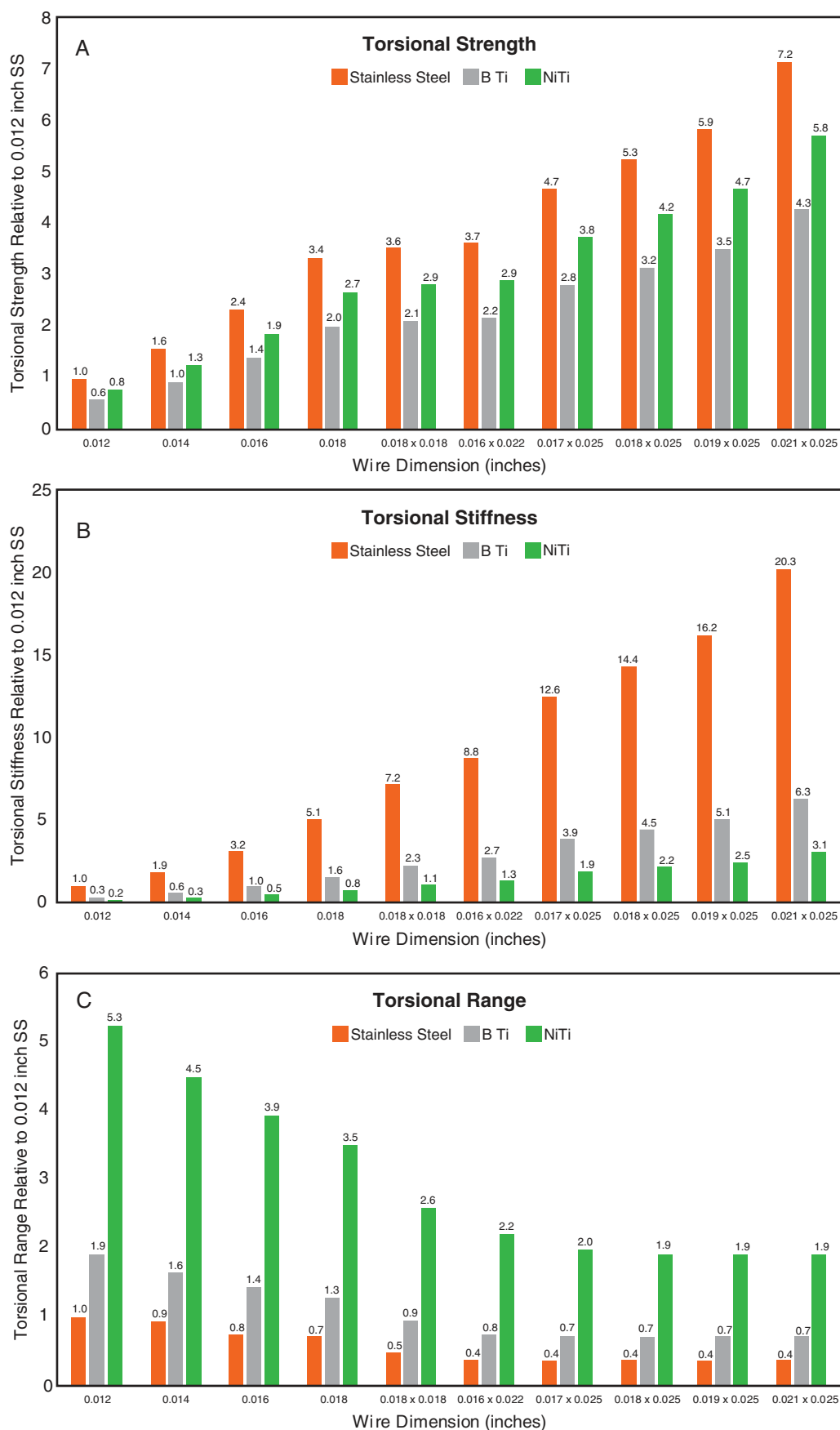
Changing from a cantilever to a supported beam, although it complicates the mathematics, does not affect the big picture: as beam length increases, there are proportional decreases in strength, exponential decreases in stiffness, and exponential increases in range.

The way in which a beam is attached also affects its properties. An archwire can be tied tightly or loosely, and the point of loading can be any point along the span. As Fig. 9.12 shows, a supported beam such as an archwire is four times less stiff if it can slide over





• **Fig. 9.10** Strength (A), stiffness (B), and range (C) comparisons in bending for stainless steel, martensitic nickel-titanium (M-NiTi; Nitinol), and beta-titanium (TMA; B Ti) wires. The index for all three comparisons, with an assigned value of 1, is 12 mil steel, so all values are comparable.

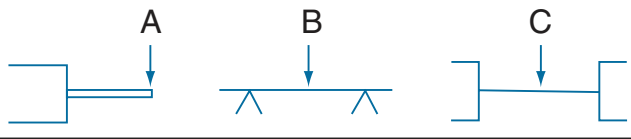


• **Fig. 9.11** Strength (A), stiffness (B), and range (C) comparisons in torsion for stainless steel, martensitic nickel–titanium (M–NiTi; Nitinol), and beta–titanium (TMA; B Ti) wires. For all three comparisons, the index wire is the same, making all values comparable.

**TABLE 9.2** Useful Wire Sizes in Various Materials (Dimensions in Mil)

	Gold	Steel	Cobalt–Chromium	Beta-Ti	M-NiTi	A-NiTi
Stranded archwire		6 to 9				
Archwire						
Round	20 to 22	12 to 20	12 to 20	16 to 20	16 to 20	14 to 20
Rectangular	22 × 28	16 × 16 to 19 × 25	16 × 16 to 19 × 25	16 × 22 to 21 × 25	16 × 22 to 21 × 25	16 × 22 to 21 × 25
Removable appliance	30 to 40	22 to 30	22 to 30			
Lingual arch	40	30, 36, 32 × 32	30, 36	32 × 32		
Headgear		45, 51				
Auxiliary expansion arch		36, 40				

*A-NiTi*, Austenitic nickel–titanium; *beta-Ti*, beta-titanium; *M-NiTi*, martensitic nickel–titanium.



Example For Beam type A

$$\begin{aligned}
 \text{Strength } d &\rightarrow 2d = 8 & \left(\frac{2d}{d}\right)^3 \\
 \text{Stiffness } d &\rightarrow 2d = 16 & \left(\frac{2d}{d}\right)^4 \\
 \text{Range } d &\rightarrow 2d = 1/2 & \left(\frac{d}{2d}\right)
 \end{aligned}$$

• **Fig. 9.12** Changing the diameter ( $d$ ) of a beam, no matter how it is supported, greatly affects its properties. As the figures below the drawing indicate, doubling the diameter of a cantilever beam makes it 8 times as strong and 16 times as stiff and reduces the range by half. More generally, when beams of any type made from two sizes of wire are compared, strength changes as a cubic function of the ratio of the two cross-sections; springiness changes as the fourth power of the ratios; range changes as a direct proportion (but the precise ratios are different from those for cantilever beams).

the abutments (in clinical use, through a bracket into which it is loosely tied) rather than if the beam is firmly attached (tied tightly). With multiple attachments, as with an archwire tied to several teeth, the gain in springiness from loose ties of an initial archwire is less dramatic but still significant.<sup>7</sup>

### Controlling Orthodontic Force by Varying Materials and Size and Shape of Archwires

Obtaining enough orthodontic force is never a problem. The difficulty is in obtaining light but sustained force. A spring or archwire strong enough to resist permanent deformation may be too stiff, which creates two problems: the force is likely to be too heavy initially and then will decay rapidly when the tooth begins to move. A very flexible wire with excellent range may nevertheless fail to provide a sustained force if it distorts from inadequate

Beam				
Strength	1/2	1/4	1	2
Stiffness	1	1/8	1	4
Range	1	4	1	1/2

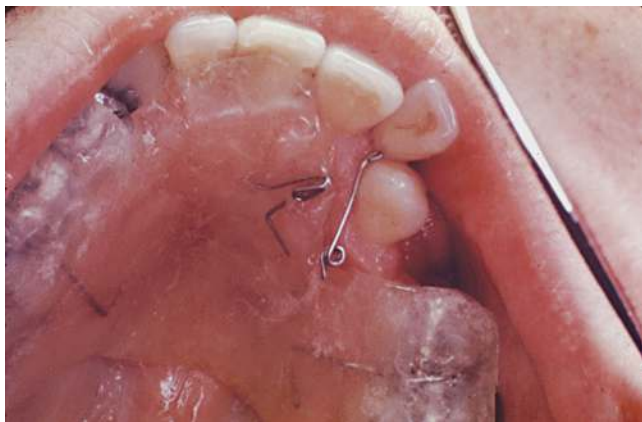• **Fig. 9.13** Changing either the length of a beam or the way in which it is attached dramatically affects its properties. Doubling the length of a cantilever beam cuts its strength in half, reduces its stiffness by 8 times, and gives it 4 times the range. More generally, strength varies inversely with length, whereas stiffness varies as a cubic function of the length ratios and range as a second power function. Supporting a beam on both ends makes it much stronger but also much stiffer than supporting it on only one end. Note that if a beam is rigidly attached on both ends, it is twice as strong and 4 times as stiff as a beam of the same material and length that can slide over the abutments. For this reason, the elastic properties of an orthodontic archwire are affected by whether it is tied tightly or held loosely in a bracket.

strength the first time the patient has lunch. The best balance of strength, stiffness, and range must be sought among the almost innumerable possible combinations of beam materials, diameters, and lengths.

The first consideration in spring design is adequate strength: the wire that is selected must not deform permanently in use. As a general rule, fingersprings for removable appliances are best constructed using steel wire. Great advantage can be taken of the fact that fingersprings behave like cantilever beams: springiness increases as a cubic function of the increase in length of the beam, whereas strength decreases only in direct proportion. Thus a relatively large wire, selected for its strength, can be given the desired spring qualities by increasing its length.

In practice, this lengthening often means doubling the wire back on itself or winding a helix into it to gain length while keeping the spring within a confined intraoral area (Fig. 9.14). The same technique can be used with archwires, of course; the effective length of a beam is measured along the wire from one support to the other, and this does not have to be in a straight line

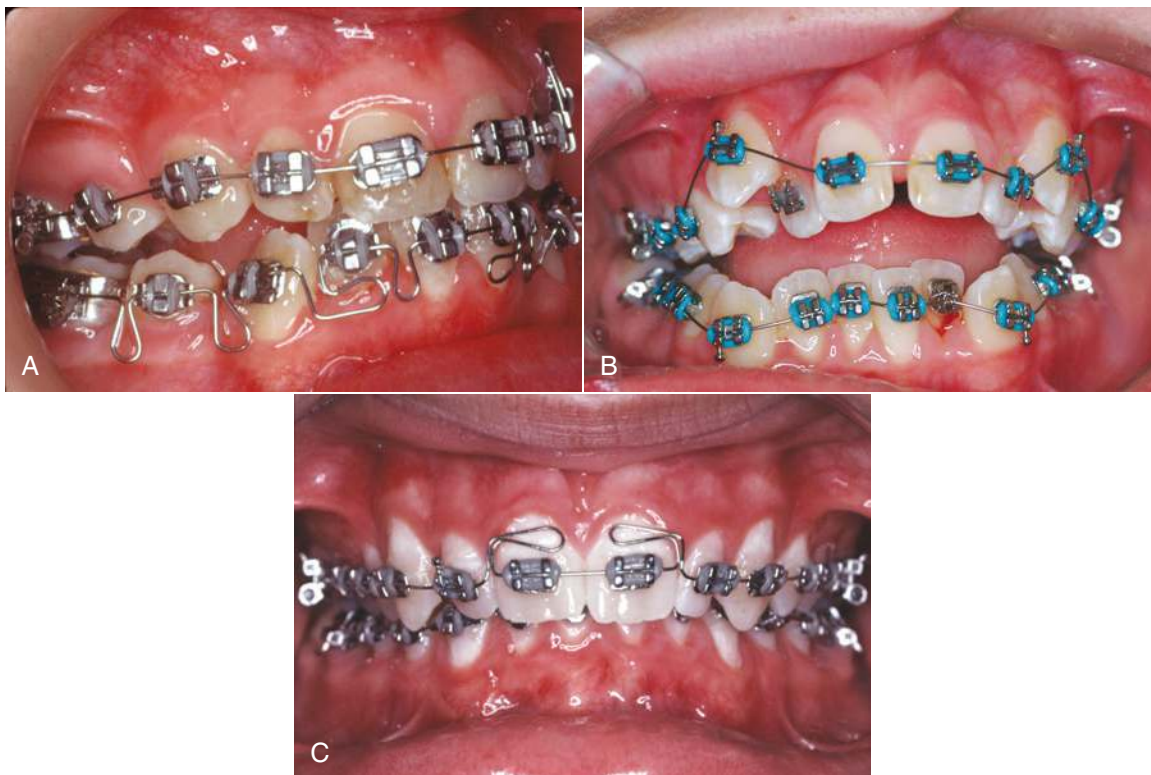




• **Fig. 9.14** A removable appliance incorporating a cantilever spring for initial tipping of a maxillary canine toward a premolar extraction site. Note that a helix has been bent into the base of the cantilever spring, effectively increasing its length to obtain more desirable mechanical properties.

(Fig. 9.15). Bending loops in archwires can be a time-consuming chairside procedure, which is the major disadvantage.

Another way to obtain a better combination of stiffness and strength is to combine two or more strands of a small and therefore more flexible wire. Two 10-mil steel wires in tandem, for instance, could withstand twice the load as a single strand before permanently deforming, but if each strand could bend without being restrained by the other, the reduced stiffness is maintained. The genesis of the “twin wire” appliance system (see Chapter 10) was just this observation: that a pair of 10-mil steel wires offered proper stiffness and range for aligning teeth and that two wires gave adequate strength, although a single wire did not. Later, three or more strands of smaller steel wires, twisted into a cable, came into common use. The properties of the multistrand wire depend both on the characteristics of the individual wire strands and on how tightly they have been woven together. Multistrand steel wires offer an impressive combination of strength and spring qualities but now have been displaced for most applications by NiTi wires.



• **Fig. 9.15** (A) Improved springiness and range with steel archwires can be obtained by either of two strategies: bending loops into the archwire, as shown in the lower arch here, to increase the length of the beam segments between adjacent teeth; or using multistranded or small-diameter steel wires, as shown in the upper arch. (B) The exceptional range and flat force–deflection curve of modern superelastic austenitic nickel–titanium (A-NiTi) wire make it possible to use a single strand of 14- or 16-mil wire for initial alignment. Using these wires is more efficient than using multistrand steel wires because of the greater range of A-NiTi and takes less clinical time than bending loops, so A-NiTi has almost totally replaced both the steel alternatives. (C) A round steel wire can be used advantageously to change the axial inclination of incisors if this is needed at the initial stage of treatment (as it may be in patients with Class II division 2 malocclusion), by bending loops that contact the gingival area of the teeth when the wire is tied in place. If the end of the wire is free to slide forward, the result is facial tipping of the incisors; if the end of the wire is bent over behind the molar tube, the incisor crowns cannot tip facially and the result is lingual root torque.

The exceptional flexibility of A-NiTi makes it a particularly attractive alternative to steel wires in the initial phases of treatment when the teeth are severely malaligned. A continuous NiTi archwire of either type will have better properties than multistrand steel wires and properties similar to a steel archwire with loops. TMA, as an intermediate between NiTi and steel, is less useful than either in the first stage of full-appliance treatment. Its excellent overall properties, however, make it quite useful in the later stages of treatment. It is possible and frequently desirable to carry out orthodontic treatment with a series of wires of approximately the same size, using a sequence from NiTi to TMA to steel. Archwire selection in varying circumstances is discussed in more detail later in this chapter and in [Chapters 15 to 17](#).

## Other Sources of Elastic Force

### Plastic Materials: Clear Aligners

The increased use of clear aligners for orthodontic treatment has made it important to understand the elastic properties of the materials that are delivering the orthodontic force. A variety of thermoplastic polymers including polyethylene, polypropylene, and polyurethane have been used to fabricate clear aligners designed to move teeth. These materials generally are 0.4 to 0.5 mm in thickness before being thermoformed over a modified plaster cast or three-dimensional (3-D) printed model. The process of thermoforming stretches the material over the cast or model and thins it to a variable degree that may affect the force delivery characteristics of the aligner.

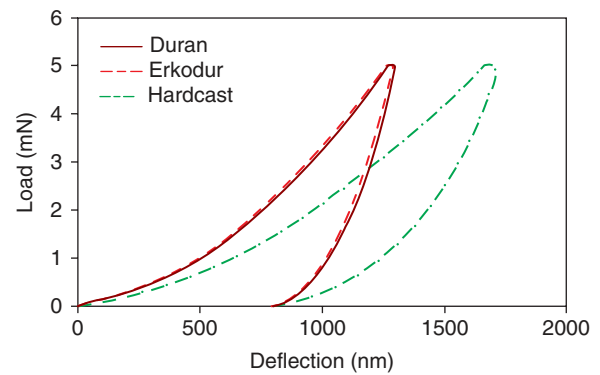
Just as for the archwire materials discussed earlier, it is possible to develop a force-deflection curve for these clear aligner materials, and this has been done for some of the available materials as shown in [Fig. 9.16](#). From this, it is possible to determine an elastic modulus from the slope of the curve. The modulus values, however, are not directly comparable to archwire properties because aligners are not delivered in a standardized geometric configuration such as a wire. But it is clear that these materials can store enough elastic energy to create tooth movement.

A large difference exists between the elastic range of the aligner materials and NiTi wires. A NiTi wire has an effective force-delivering range of several millimeters, whereas the range of a plastic aligner is generally limited to about 0.2 mm. What this means practically is that an incisor displaced 3 mm from its ideal position in the arch would require a minimum of five aligner trays for each millimeter it needs to travel, in this case 15 trays (3 mm  $\times$  5 trays/mm), plus any additional trays needed to create space for the moving tooth or to help with root movement. This explains why a single NiTi wire can be used with brackets to align irregular incisors, whereas doing this with aligners could take up to 20 individual trays.

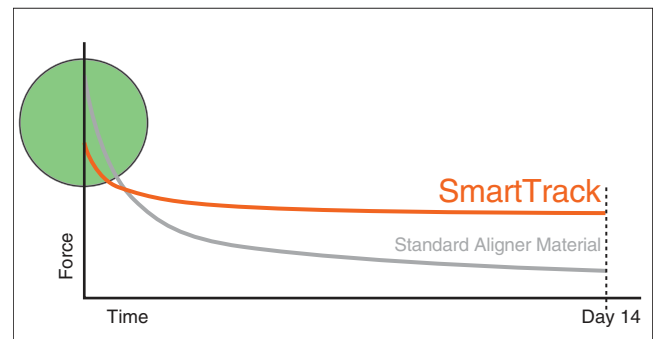
Plastics for aligners also are subject to stress relaxation and water absorption that may affect their ability to deliver tooth moving forces over time. The Align corporation has developed a proprietary material that demonstrates less stress relaxation and relatively constant force delivery over a 14-day period ([Fig. 9.17](#)). Shaping aligners so that they deliver the desired force for the next movement in the sequence of aligners remains a not-yet-achieved goal.

### Rubber and Elastomeric Materials

From the beginning, rubber bands were used in orthodontics to transmit force from the upper arch to the lower. Rubber has the particularly valuable quality of a great elastic range, so the extreme stretching produced when a patient opens the mouth while wearing



• **Fig. 9.16** Representative loading-unloading curves for three thermoplastic materials: Duran, continuous line; Erkodur, dashed line; and Hardcast, dashed-dotted line. (From Kohda N, et al. *Angle Orthod.* 2013;83:476–483.)



• **Fig. 9.17** Diagram showing the improved stress relaxation properties demonstrated by the SmartTrack material developed for use with the Invisalign system, compared with traditional aligner material. This proprietary material demonstrates a relatively constant force delivery over a 14-day period. (SmartTrack @figure. Courtesy Align Technology, Inc., San Jose, CA.)

rubber bands can be tolerated without destroying the appliance. Rubber bands are also easier for a patient to remove and replace than, for instance, a heavy coil spring.

The greatest problem with orthodontic use of all types of rubber is that they absorb water and deteriorate under intraoral conditions. Gum rubber, which is used to make the rubber bands commonly used in households and offices, begins to deteriorate in the mouth within a couple of hours, and much of its elasticity is lost in 12 to 24 hours. Although orthodontic elastics once were made from this material, they have been superseded by latex elastics, which have a useful performance life four to six times as long. In contemporary orthodontics, only latex rubber elastics or a suitable nonlatex substitute should be used.

Elastomeric plastics for orthodontic purposes are marketed under a variety of trade names, A-lastic being the best known. Small elastomeric modules replace wire ligation ties to hold archwires in the brackets in many applications (see [Fig. 9.15B](#)), and also can be used to apply a force to close spaces within the arches. Like rubber, however, these elastomers tend to deteriorate in elastic performance after a relatively short time in the mouth. This does not prevent them from performing quite well in holding archwires in place, nor does it contraindicate their use to close small spaces. It simply

must be kept in mind that when elastomers are used to move teeth, the forces decay rapidly and so can be characterized better as interrupted rather than continuous (see Fig. 8.13).<sup>8</sup> Although larger spaces within the dental arch can be closed by sliding teeth with rubber bands or elastomeric chains, the same tooth movement can be done much more efficiently with A-NiTi springs, which provide a nearly constant force over quite a large range.

### Magnets

Rare earth magnets developed in the 1980s were promoted for orthodontic force delivery because they could generate forces of the magnitude needed to move teeth and it was believed they would have a biologic effect that would speed tooth movement and reduce pain. These biologic effects have proven not to be true,<sup>9</sup> so the dramatic changes in force as the distance between magnets in attraction or repulsion changes have all but eliminated them from contemporary treatment.<sup>10</sup>

## Design Factors in Orthodontic Appliances

### Two-Point Contact for Control of Root Position

#### Definition of Terms

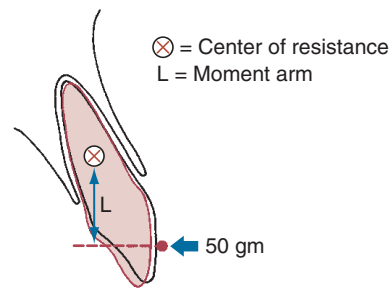
Before beginning to discuss control of root position, it is necessary to understand some basic physical terms that must be used in the discussion:

**Force**—a load applied to an object that will tend to move it to a different position in space. Force, though rigidly defined in units of newtons (mass  $\times$  the acceleration of gravity), is usually measured clinically in weight units of grams or ounces. In this context, for all practical purposes,  $1.0 \text{ N} \cong 100 \text{ gm}$

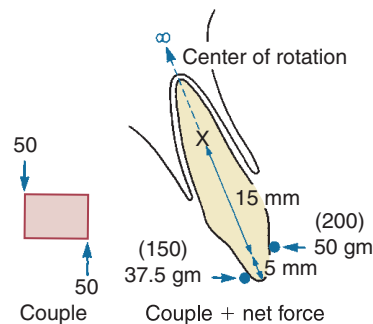
**Center of resistance**—a point at which resistance to movement can be concentrated for mathematical analysis. For an object in free space, the center of resistance is the same as the center of mass. If the object is partially restrained, as is the case for a fence post extending into the earth or a tooth root embedded in bone, the center of resistance will be determined by the nature of the external constraints. The center of resistance for a tooth is at the approximate midpoint of the embedded portion of the root (i.e., about halfway between the root apex and the crest of the alveolar bone; Fig. 9.18).

**Moment**—a measure of the tendency to rotate an object around some point. A moment is generated by a force acting at a distance. Quantitatively, it is the product of the force times the perpendicular distance from the point of force application to the center of resistance and thus is measured in units of gram-millimeters (or equivalent). If the line of action of an applied force does not pass through the center of resistance, a moment is necessarily created. Not only will the force tend to translate the object, moving it to a different position, it also will tend to rotate the object around the center of resistance. This, of course, is precisely the situation when a force is applied to the crown of a tooth (see Fig. 9.18). Not only is the tooth displaced in the direction of the force, it also rotates around the center of resistance—thus the tooth tips as it moves.

**Couple**—two forces equal in magnitude and opposite in direction but not on the same line. The result of applying two forces in this way is a pure moment, because the translatory effect of the forces cancels out. A couple will produce pure rotation, spinning the object around its center of resistance; the



• **Fig. 9.18** The center of resistance ( $C_R$ ) for any tooth is at the approximate midpoint of the embedded portion of the root. If a single force is applied to the crown of a tooth, the tooth will not only translate but also rotate around  $C_R$  because a moment is created by applying a force at a distance from  $C_R$ . The perpendicular distance from the point of force application to the center of resistance is the moment arm ( $L$ ). Pressure in the periodontal ligament will be greatest at the alveolar crest and opposite the root apex (see Fig. 8.9).

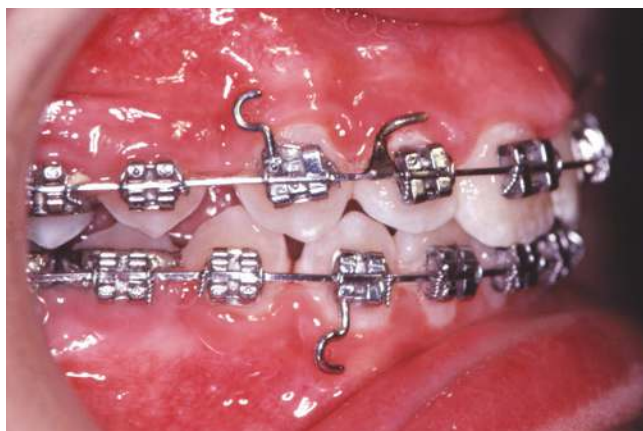

• **Fig. 9.19** A couple, as shown on the left, is defined as two forces equal in magnitude and opposite in direction. The application of a couple produces pure rotation. In clinical application, two unequal forces applied to the crown of a tooth to control root position can be resolved into a couple and a net force to move the tooth. If a 50-gm force were applied to a point on the labial surface of an incisor tooth 15 mm from the center of resistance, a 750 gm-mm moment (the moment of the force, or  $M_F$ ) would be produced, tipping the tooth. To obtain bodily movement, it is necessary to apply a couple to create a moment (the moment of the couple, or  $M_C$ ) equal in magnitude and opposite in direction to the original moment. One way to do this would be to apply a force of 37.5 gm pushing the incisal edge labially at a point 20 mm from the center of resistance. This creates a 750 gm-mm moment in the opposite direction, so the force system is equivalent to a couple with a 12.5-gm net force to move the tooth lingually. With this force system, the tooth would not tip, but with so light a net force, there would be only a small amount of movement. To achieve a net 50 gm for effective movement, it would be necessary to use 200 gm against the labial surface and 150 gm in the opposite direction against the incisal edge. Controlling forces of this magnitude with a removable appliance is very difficult, almost impossible—effective root movement is much more feasible with a fixed appliance.

combination of a force and a couple can change the way an object rotates while it is being moved (Fig. 9.19).

**Center of rotation**—the point around which rotation actually occurs when an object is being moved. When two forces are applied simultaneously to an object, the center of rotation can be controlled and made to have any desired location. The application of a force and a couple to the crown of a tooth, in fact, is the





• **Fig. 9.20** Attachments extending toward the center of resistance, seen here as hooks integrated into the canine brackets, can be used to shorten the moment arm and thereby decrease the amount of tipping when elastics or springs are used to slide teeth mesiodistally along an archwire. This idea from the 1920s was reintroduced as part of the early straight-wire appliance. Unfortunately, the longer the hook, the more effective it is mechanically but the greater the chance of oral hygiene problems leading to gingival irritation and/or decalcification. Other methods for controlling tipping are more practical.

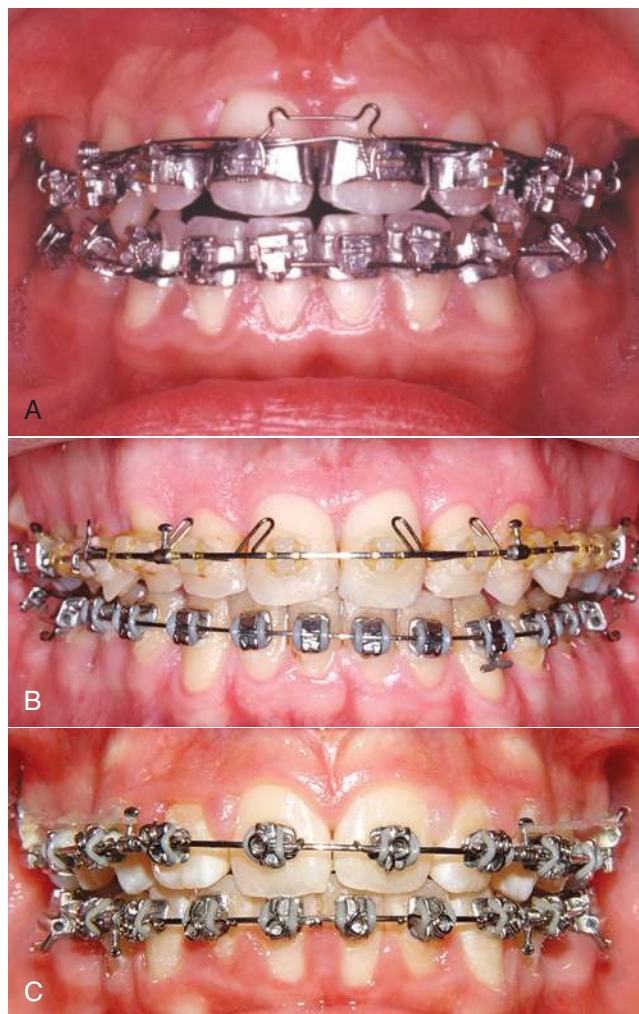
mechanism by which bodily movement of a tooth, or even greater movement of the root than the crown, can be produced.

### Forces, Moments, and Couples in Tooth Movement

Consider the clinical problem posed by a protruding maxillary central incisor. If a single force of 50 gm is applied against the crown of this tooth, as might happen with a spring on a maxillary removable appliance, a force system will be created that includes a 750 gm-mm moment (see Fig. 9.18). The result will be that the crown will be retracted more than the root apex, which might actually move slightly in the opposite direction. (Remember that a force will tend to displace the entire object, despite the fact that its orientation will change via simultaneous rotation around the center of resistance.) If it is desired to maintain the inclination of the tooth while retracting it, it will be necessary to overcome the moment created when the force was applied to the crown.

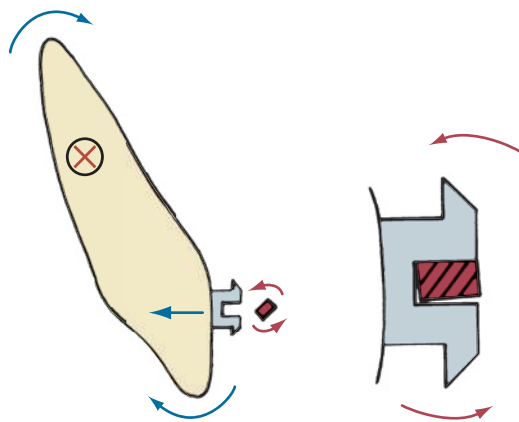
One way to decrease the magnitude of the moment is to apply the force closer to the center of resistance. In orthodontics, it is impractical to apply the force directly to the root, but a similar effect could be achieved by constructing a rigid attachment that projected upward from the crown. Then the force could be applied to the attachment such that its line of action passed near or through the center of resistance. If the attachment were perfectly rigid, the effect would be to reduce or eliminate the moment arm and thereby the tipping (Fig. 9.20). Because it is difficult to make the arms long enough to totally eliminate tipping, this procedure is only a partial solution at best, and it creates problems with oral hygiene.

Another way to control or eliminate tipping is to create a second moment opposite in direction to the first one. If a second counterbalancing moment could be created equal in magnitude to the moment produced by the first force application, the tooth would remain upright and move bodily. A moment can be created only by application of a force at a distance, however, so this would require that a second force be applied to the crown of the tooth.



• **Fig. 9.21** (A) Auxiliary root positioning springs and auxiliary torquing springs were used routinely with the Begg appliance, and both can be seen in the maxillary arch of this patient being treated with an early (1980s) Begg-edgewise combination appliance. The torquing spring contacts the facial surface of the central incisors; uprighting springs are present bilaterally on the canines. Note that the base wires are pinned in the Begg slot, and the edgewise slot is not used at this point in treatment. (B) An auxiliary torquing spring in use with the Tip-Edge appliance, the current version of a combination Begg-edgewise appliance. (C) Root positioning (side-winder) springs used with the Tip-Edge appliance (TP Orthodontics, La Porte, IN). (A, Courtesy Dr. W.J. Thompson; B and C, courtesy Dr. D. Grauer.)

In our example of the protruding central incisor, the tendency for the incisor to tip when it was being retracted could be controlled by applying a second force to the lingual surface of this tooth, perhaps with a spring in a removable appliance pushing outward from the lingual near the incisal edge (see Fig. 9.18). As a practical matter, it can be difficult to maintain removable appliances in place against the displacing effects of a pair of springs with heavy activation. The usual orthodontic solution is a fixed attachment on the tooth, constructed so that forces can be applied at two points. With round wires in bracket slots, an auxiliary spring is needed to produce a torquing couple (Fig. 9.21). A rectangular archwire fitting into a rectangular bracket slot on the tooth is most widely used because the entire force system can be produced with a single wire (Fig. 9.22).



• **Fig. 9.22** A rectangular archwire fitting into a rectangular slot can generate the moment of a couple ( $M_C$ ) necessary to control root position. The wire is twisted (placed into torsion) as it is put into the bracket slot. The two points of contact are at the edge of the wire, where it contacts the bracket. The moment arm therefore is quite small, and forces must be large to generate the necessary  $M_C$ . Using the same tooth dimensions indicated in Fig. 9.19, a 50-gm net lingual force would generate a 750 gm-mm moment. To balance it by creating an opposite 750 gm-mm moment within a bracket with a 0.5 mm slot depth, a torsional force of 1500 gm is required.

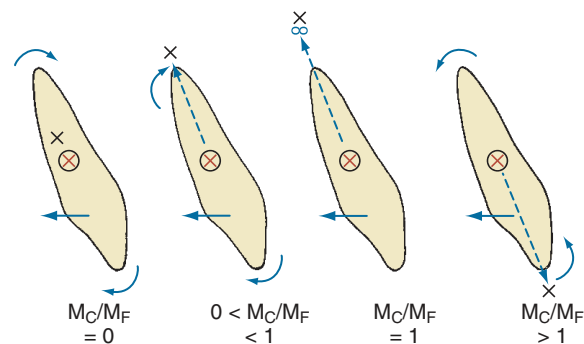
It should be noted that with this approach, the two points of contact are the opposite edges of the rectangular wire. The moment arms of the couple therefore are quite small, which means that the forces at the bracket necessary to create a countervailing moment are quite large. If a rectangular archwire is to be used to retract a central incisor bodily, the net retraction force should be small, but the twisting forces on the bracket must be large in order to generate the moment.

**$M_C/M_F$  Ratios and Control of Root Position.** The previous analysis demonstrates that control of root position during movement requires both a force to move the tooth in the desired direction and a couple to produce the necessary counterbalancing moment for control of root position. The heavier the force, the larger the counterbalancing movement must be to prevent tipping, and vice versa.

Perhaps the simplest way to determine how a tooth will move is to consider the ratio between the moment created when a force is applied to the crown of a tooth (the moment of the force [ $M_F$ ]), and the counterbalancing moment generated by a couple within the bracket (the moment of the couple [ $M_C$ ]). Then it can be seen (Fig. 9.23) that the following possibilities exist:

$M_C/M_F = 0$	Pure tipping (tooth rotates around center of resistance)
$0 < M_C/M_F < 1$	Controlled tipping (inclination of tooth changes but the center of rotation is displaced away from the center of resistance, and the root and crown move in the same direction)
$M_C/M_F = 1$	Bodily movement (equal movement of crown and root)
$M_C/M_F > 1$	Torque (root apex moves further than crown)

The moment of the force is determined by the magnitude of the force and the distance from the point of force application to the center of resistance. For most teeth, this distance is 8 to 10 mm, so  $M_F$  will be 8 to 10 times the force. In other words, if a 100-gm net force were used to move such a tooth, a balancing moment of 800 to 1000 gm-mm would be needed to obtain bodily movement. In



• **Fig. 9.23** The ratio between the moment produced by the force applied to move a tooth ( $M_F$ ) and the counterbalancing moment produced by the couple used to control root position ( $M_C$ ) determines the type of tooth movement. With no  $M_C$  ( $M_C/M_F = 0$ ), the tooth rotates around the center of resistance (pure tipping). As the moment-to-force ratio increases ( $0 < M_C/M_F < 1$ ), the center of rotation is displaced further and further away from the center of resistance, producing what is called *controlled tipping*. When  $M_C/M_F = 1$ , the center of rotation is displaced to infinity and bodily movement (translation) occurs. If  $M_C/M_F > 1$ , the center of rotation is displaced incisally and the root apex will move more than the crown, producing root torque.

the orthodontic literature, the relationship between the force and the counterbalancing couple often has been expressed in this way, as the “moment-to-force” ratio. In those terms, moment-to-force ratios of 1 to 7 would produce controlled tipping, ratios of 8 to 10 (depending on the length of the root) would produce bodily movement, and ratios greater than that would produce torque. Because the distance from the point of force application to the center of resistance can and does vary, moment-to-force ratios must be adjusted if root length, amount of alveolar bone support, or point of force application differs from the usual condition.  $M_C/M_F$  ratios more precisely describe how a tooth will respond.

Remember that when a force is applied to a bracket to slide it along an archwire, as often is the case in clinical orthodontics, the force felt by the tooth will be less than the force applied to the bracket because of resistance to sliding within the bracket (see later discussion). The *net* force (after resistance to sliding is subtracted) and the moment associated with the net force are what is important. In contrast, when a couple is created within a bracket, friction rarely is a factor.

It is easy to underestimate the magnitude of the forces needed to create the balancing couple. In the example presented previously, if a 50-gm net force was used to retract a central incisor, a 500 gm-mm moment would be needed to keep it from tipping as the crown moved lingually. To produce a moment of this magnitude within the confines of an 18-mil (0.45-mm) bracket would require opposite forces of 1100 gm, derived from twisting the archwire. These forces within the bracket produce only a pure moment, so the periodontal ligament (PDL) does not feel heavy force, but the necessary magnitude can come as a considerable surprise. The wire must literally snap into the bracket.

**Root Control With Clear Aligners.** The increased use of clear aligner treatment in orthodontics has led to innovations to increase their application to a greater range of malocclusions. The designers of these innovations have recognized that teeth don't just follow plastic, but that the plastic must exert tooth-moving forces just as

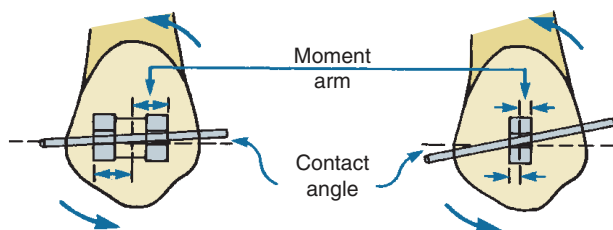
fixed appliances do. In an attempt to control root position, Invisalign has developed a system that creates two-point contact for mesiodistal and buccolingual root movement, which is mechanically the same as what we previously saw with the use of two springs in contact with the crown of a tooth (see Fig. 9.18). In a modified aligner, to provide a moment for lingual root movement of an upper incisor, a plastic ridge provides a lingual force on the facial surface near the gingival margin while a facial force is applied on the lingual surface near the incisal edge. For distal root movement of a premolar, two attachments are placed on the facial surface of the tooth, which exerts a distal force near the gingival margin and a mesial force closer to the cusp tip. Although these two-point force systems can theoretically provide better root control with aligners, the extent to which they are clinically effective in doing so is still not clear.

### Narrow Versus Wide Brackets in Fixed Appliance Systems

Control of root position with an orthodontic appliance is especially needed in two circumstances: when the root of a tooth needs to be torqued facially or lingually (as in the previous example) and when mesiodistal root movement is needed for proper paralleling of teeth when spaces are closed (as at extraction sites). In the former instance, the necessary moment is generated within the bracket, and the key dimensions are those of the archwire; in the latter circumstance, the moment is generated across the bracket, and bracket width determines the length of the moment arm.

The wider the bracket, all other things being equal, the easier it will be to generate the moments needed to bring roots together at extraction sites or to control mesiodistal position of roots in general. Consider retracting the root of a canine tooth into a first premolar extraction site (Fig. 9.24). With a retraction force of 100 gm and a 10-mm distance from the bracket to the center of resistance, a 1000 gm-mm counterbalancing moment will be needed. If the bracket on this tooth is 1 mm wide, 1000 gm of force will be needed at each corner of the bracket, but if the bracket is 4 mm wide, only 250 gm of force at each corner will be necessary.

This assumes even greater practical significance when the extraction site is to be closed by sliding teeth along an archwire, and binding between the wire and bracket is encountered. Binding of the wire against the corners of the bracket is affected by the force with which the bracket contacts the archwire and the contact angle between the wire and the bracket (see Fig. 9.24). The wider the bracket reduces both the force needed to generate the moment and the contact angle and is thus advantageous for space closure by sliding.



• **Fig. 9.24** The width of the bracket determines the length of the moment arm (half the width of the bracket) for control of mesiodistal root position. Bracket width also influences the contact angle at which the corner of the bracket meets the archwire. The wider the bracket, the smaller the contact angle.

Despite their advantage when spaces are to be closed by sliding teeth on an archwire, wide brackets have a partially offsetting disadvantage. The wider the bracket on a tooth, the smaller the interbracket span between adjacent teeth, and therefore the shorter the effective length of the archwire segments between supports. Reducing the span of the wire segments in this way (reducing the length of the beam, in the terminology of our previous discussion) greatly increases the stiffness of the archwire and decreases its range of action. For this reason, the use of extremely wide brackets is contraindicated. The maximum practical width of a wide bracket is about half the width of a tooth, and narrower brackets have an advantage when teeth are malaligned because the greater interbracket span reduces stiffness of any type of wire.

### Effect of Bracket Slot Size in the Edgewise System

The use of rectangular archwires in rectangular bracket slots was introduced by Edward Angle in the late 1920s with his edgewise arch mechanism (see Chapter 10). The original appliance was designed for use with gold archwires, and the 22 × 28 mil bracket slot size was designed to accommodate rectangular archwires of approximately the same dimension. In Angle's concept of treatment, sliding teeth along archwires to close extraction sites was unnecessary because extractions for orthodontic purposes simply were not done. Torquing movements, on the other hand, were important, and a major goal of the appliance design was efficient torque. The appliance was engineered to produce appropriate force and a reasonable range of action in torsion when gold archwires of 22 × 28 dimension were used with narrow brackets.

When steel archwires replaced gold, Angle's original engineering calculations were no longer valid because steel wire of the same size was so much stiffer. An alternative was to redesign the edgewise appliance, optimizing the bracket slot size for steel. A reduction in slot size from 22 to 18 mil was advocated for this purpose. Even with this smaller slot size, full-dimension steel wires still produce slightly greater forces than the original edgewise system did, but the properties of the appliance system are close to the original. Good torque is possible with steel wires and 18-mil edgewise brackets.

On the other hand, using undersized archwires in edgewise brackets is a way to reduce the frictional component of resistance to sliding teeth along an archwire, which was an important consideration by the time steel wire replaced gold. As a practical matter, sliding teeth along an archwire requires at least 2 mil of clearance to minimize friction, and even more clearance may be desirable. The greater strength of an 18-mil archwire compared with a 16-mil wire can be an advantage in sliding teeth. The 18-mil wire would, of course, offer excellent clearance in a 22-slot bracket but fit tightly in an 18-slot bracket. The original 22-slot bracket therefore would have some advantage during space closure but would be a definite disadvantage when torque was needed later.

With steel archwires of 21 mil as the smaller dimension (close enough to the original 22-mil bracket slot size to give a good fit), springiness and range in torsion are so limited that effective torque with the archwire is essentially impossible. Using wide brackets to help with space closure would make the torque problem worse. Exaggerated inclinations of smaller rectangular wires (e.g., 19 × 25) are one alternative, but torquing auxiliaries (see Fig. 9.21) are often necessary with undersized steel wires in 22-slot edgewise brackets.

In this situation, a role for the new titanium archwires becomes clearer. If only steel wires are to be used, the 18-mil slot system



has considerable advantage over the larger bracket slot size. With their excellent springback and resistance to permanent deformation, A-NiTi wires overcome some of the alignment limitations of steel wires in wide 22-mil slot brackets; rectangular NiTi and beta-Ti wires offer advantages over steel for the finishing phases of treatment and torque control. In short, titanium archwires greatly help overcome the major problems associated with continued use of the original edgewise slot size.

## Mechanical Aspects of Anchorage Control

### Friction Versus Binding in Resistance to Sliding

When teeth slide along an archwire, force is needed for two purposes: to overcome resistance created by contact of the wire with the bracket and to create the bone remodeling needed for tooth movement. As we pointed out in [Chapter 8](#), controlling the position of anchor teeth is accomplished best by minimizing the reaction force that reaches them. It is tempting for the clinician to use heavier force when moving a tooth along an archwire to overcome the friction and binding of the wire in the bracket. The prudent decision when anchorage control is critical is to err on the side of lighter force so that differential anchorage is possible (see [Fig. 8.22](#)) or to use an approach, such as closing loops, that does not require sliding a bracket along the wire.

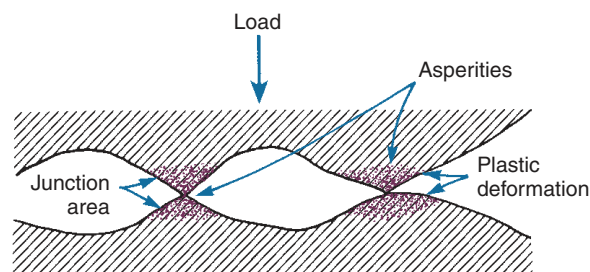
Because of the increasing use of passive self-ligating brackets and other techniques designed to reduce friction (which are discussed in detail in [Chapter 10](#)), it has become important to clearly distinguish between the contributions of friction and binding to resistance to sliding.

#### Friction in Fixed Appliance Treatment

When one object moves relative to another, friction at their interface produces resistance to the direction of movement. Friction ultimately is derived from electromagnetic forces between atoms—it is not a fundamental force that can be defined independently of local conditions. It is proportional to the force with which the contacting surfaces are pressed together and is affected by the nature of the surface at the interface (e.g., rough or smooth, chemically reactive or passive, modified by lubricants). It is interesting to note that friction is independent of the apparent area of contact. This is because all surfaces, no matter how smooth, have irregularities that are large on a molecular scale, and real contact occurs only at a limited number of small spots at the peaks of the surface irregularities ([Fig. 9.25](#)). These spots, called *asperities*, carry all the load between the two surfaces. Even under light loads, local pressure at the asperities may cause appreciable plastic deformation of those small areas. Because of this, the true contact area is to a considerable extent determined by the applied load and is directly proportional to it.<sup>11</sup>

When a tangential force is applied to cause one material to slide past the other, the junctions begin to shear. The coefficient of friction then is proportional to the shear strength of the junctions and is inversely proportional to the yield strength of the materials (because this determines the extent of plastic deformation at the asperities). At low sliding speeds, a “stick-slip” phenomenon may occur as enough force builds up to shear the junctions and a jump occurs, then the surfaces stick again until enough force again builds to break them.

Two other factors affect friction: the interlocking of surface irregularities, which obviously becomes more important when the asperities are large or pointed, and the extent to which asperities



• **Fig. 9.25** When two solid surfaces are pressed together or one slides over the other, real contact occurs only at a limited number of small spots, called *asperities*, that represent the peaks of surface irregularities. These junctions shear as sliding occurs, and the force to produce this plastic deformation of the surface irregularities is the frictional resistance. (Redrawn from Jastrzebski ZD. *The Nature and Properties of Engineering Materials*. 3rd ed. New York: Wiley; 1987.)


on a harder material plow into the surface of a softer one. Thus the total frictional resistance will be the sum of three components: (1) the force necessary to shear all junctions, (2) the resistance caused by the interlocking of roughness, and (3) the plowing component of the total friction force.<sup>12</sup> In practice, if the two materials are relatively smooth and not greatly dissimilar in hardness, friction is largely determined by the shearing component.

The concept that surface qualities are an important variable in determining friction has been emphasized by experience in recent years with both titanium wires and ceramic or plastic brackets. Stainless steel brackets slide reasonably well on steel wires, but the situation is not so fortunate with some other possible combinations.

**Friction Related to Surface Qualities of Wires.** When NiTi wires were first introduced, manufacturers claimed that they had an inherently slick surface compared with stainless steel, so that all other factors being equal, there would be less interlocking of asperities and thereby less frictional resistance to sliding a tooth along a NiTi wire than a stainless steel one. This is erroneous—the surface of NiTi is rougher (because of surface defects, not the quality of polishing) than that of beta-Ti, which in turn is rougher than steel. More important, however, is that there is little or no correlation for orthodontic wires between the coefficients of friction and surface roughness<sup>13</sup> (i.e., interlocking and plowing are not significant components of the total frictional resistance). Although NiTi has greater surface roughness, beta-Ti has greater frictional resistance. It turns out that as the titanium content of an alloy increases, its surface reactivity increases, and the surface chemistry is a major influence. Thus beta-Ti, at 80% titanium, has a higher coefficient of friction than NiTi at 50% titanium, and there is greater frictional resistance to sliding with either than with steel. With beta-Ti, there is enough titanium reactivity for the wire to “cold-weld” itself to a steel bracket under some circumstances, making sliding all but impossible.

A possible solution to this problem is alteration of the surface of the titanium wires by implantation of ions into the surface. Ion implantation (with nitrogen, carbon, and other materials) has been done successfully with beta-Ti and has been shown to improve the characteristics of beta-Ti hip implants. In clinical orthodontics, however, implanted NiTi and beta-Ti wires failed to show improved performance in initial alignment or sliding space closure respectively, and are no longer marketed.

**Friction Related to Surface Qualities of Brackets.** Bracket surfaces also are important in friction. Most modern orthodontic



• **Fig. 9.26** (A) It is possible in the laboratory to orient a small wire within a bracket (or tube) so that it does not touch any of the walls, and therefore there would be no frictional resistance to moving the wire relative to the bracket. (B) In the mouth, a curved archwire passing through a series of brackets will inevitably contact the bottom of the bracket, so there will be some friction.

brackets are either cast or milled from stainless steel and, if properly polished, have relatively smooth surfaces comparable with steel wires. Titanium brackets now are promoted as particularly needed for patients who have a nickel allergy, but are rarely needed for that reason (see [Chapter 8](#)). At best, the surface properties of titanium brackets are like those of titanium wires, and polishing the interior of bracket slots is difficult enough that these critical areas may be rougher than wires. Sliding with titanium brackets therefore may be problematic, particularly if titanium archwires also are used.

Ceramic brackets became quite popular in the 1990s because of their improved esthetics, but their surface properties are far from ideal. The ones made from polycrystalline ceramics have considerably rougher surfaces than steel brackets. The rough but hard ceramic material is likely to penetrate the surface of even a steel wire during sliding, creating considerable resistance, and of course, this is worse with titanium wires. Although single crystal brackets are quite smooth, these brackets also can damage wires during sliding, and so they also have increased resistance to sliding.<sup>14</sup> As a result, ceramic brackets with metal slots and with rounded corners in the slot have been introduced, a rather explicit recognition of the problems created by friction against ceramic surfaces (see further discussion of esthetic appliances in [Chapter 10](#)).

It is possible that composite plastic brackets will begin to be used in orthodontics within the next few years. They have the advantages of being tooth colored and nonallergenic, and at least in theory should have surface properties that would not be as troublesome as ceramics. As with composite plastic wires, however, their fabrication is difficult and their advantages relative to metal may not be worth the additional expense.

### **Elastic and Inelastic Binding in Resistance to Sliding**

The amount of force between the wire and the bracket strongly influences the amount of resistance to sliding. This resistance is determined primarily by two things: friction as the wire contacts

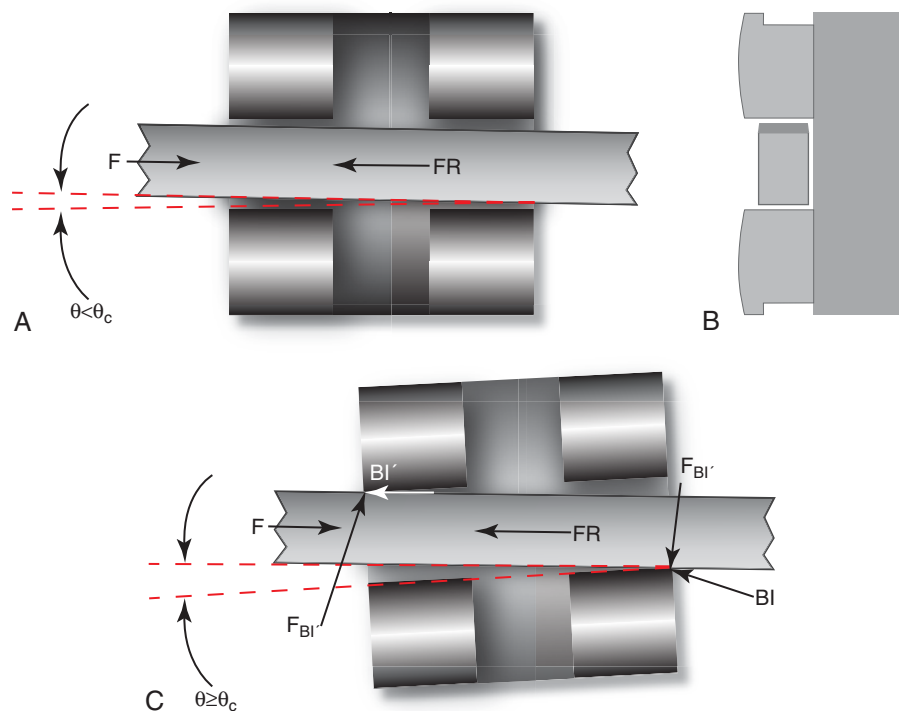
the walls or bottom of the bracket and elastic or inelastic binding as the wire contacts the corners of the bracket. As we will see, binding, not friction, is the major component of resistance to sliding.

In theory, a wire could move through a bracket or tube with no friction whatever, if it were small relative to the bracket and did not contact any part of the bracket ([Fig. 9.26A](#)). Even in the laboratory, this is very difficult—unless everything is aligned perfectly, the wire will contact the bottom of the bracket or some other area, but friction will be small if nothing forces the wire against the bracket.

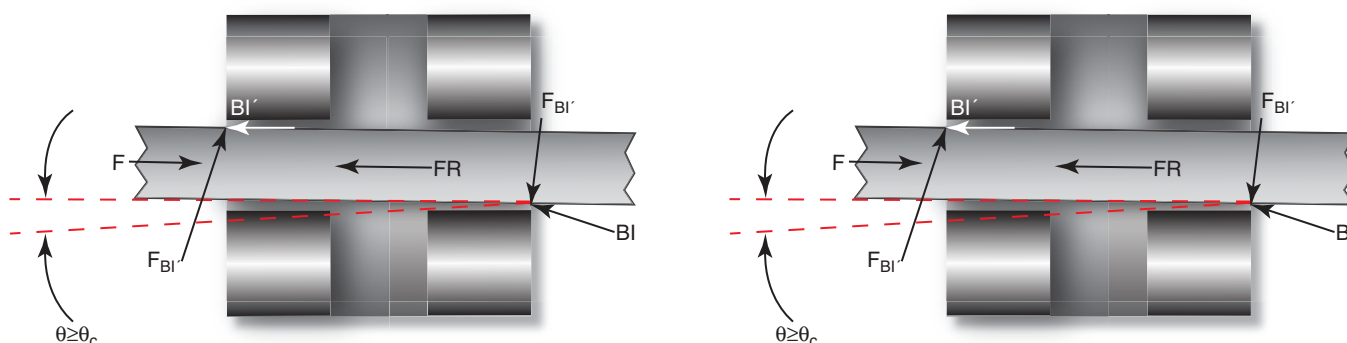
This, however, has no resemblance to what happens in the mouth. In fact, contact of the wire against the bracket is necessary to control rotation and root position by generating couples to offset the moments created by the forces to move the teeth. When a wire shaped to arch form fits through multiple brackets, contact with the base of the bracket and/or bracket walls is inevitable ([Fig. 9.26B](#)). If a tooth is pulled along an archwire, the resistance to sliding will be only friction until the tooth tips enough to bring the corners of the bracket into contact with the wire. The tooth tips, of course, because the force is applied to a bracket on its crown, and the center of resistance is halfway down the root. As soon as the corners of the bracket engage the wire, which happens after a very small movement of the tooth, a moment is generated that opposes further tipping ([Fig. 9.27](#)). This generates elastic binding between the bracket and the wire, which is different from friction.

The greater the angle at which the wire contacts the corners of the bracket, the greater the force between the wire and bracket—so, as we noted previously, there is greater resistance to sliding with narrow than wide brackets. As can be seen from [Fig. 9.28](#), resistance to sliding includes elastic binding almost immediately when tooth movement begins and goes up rapidly as the angle between the bracket and the wire increases.<sup>15</sup>

A series of experiments in Kusy's laboratory help to put into perspective the importance of binding versus friction as components of resistance to sliding.<sup>16</sup> In the experiments,  $21 \times 25$  M-NiTi and



• **Fig. 9.27** (A) and (B) The force ( $F$ ) to move a bracket along an archwire initially will be resisted only by friction ( $FR$ ) because of contact of the wire with the bottom or sides of the bracket slot. (C) Because the root of a tooth resists movement, the tooth tips until the corners of the bracket contact the wire, and at that point, elastic binding ( $BI$ ) of the wire against the corner of the bracket adds to the resistance to sliding.



Very early alignment:  $RS = FR + BI$   
Almost immediately:  $RS = BI$


• **Fig. 9.28** Because binding creates most of the resistance to sliding ( $RS$ ) as the angle of contact between the wire and the corner of the bracket increases, resistance to sliding in very early alignment is the sum of elastic binding ( $BI$ ) and friction ( $FR$ ), but almost immediately the proportion of resistance from binding exceeds friction by so much that the frictional component can be disregarded—for all practical purposes, the resistance to sliding is due just to binding (see Fig. 9.29).

steel wires were tied into a 22-slot steel twin bracket with 200-gm ligature force, so there was a lot of friction. Then the resistance to sliding was evaluated as a function of the angle of contact between the wire and the bracket. As Fig. 9.29 shows, with a 3-degree contact angle, most of the resistance to sliding was binding with a steel wire, and nearly half was binding with an M-NiTi wire. At

Steel Wire	NiTi Wire
3° RS = 73% BI	3° RS = 45% BI
7° RS = 94% BI	7° RS = 93% BI
11° RS = 97% BI	11° RS = 95% BI

• **Fig. 9.29** Laboratory studies in which the bracket was allowed to tip relative to the wire along which it was being moved have shown that with a  $21 \times 25$  steel wire that was tied into a steel bracket with a 200-gm force (so there was a lot of friction), 73% of the resistance to sliding ( $RS$ ) was due to binding ( $BI$ ) at a contact angle of 3 degrees, and over 90% was due to binding at 7 degrees or higher angles. With a martensitic nickel-titanium (M-NiTi) wire of the same size, there was less binding at 3 degrees but similar binding at higher angles. The component of resistance attributed to friction can be seen to be negligible at contact angles that are reached quickly in sliding a tooth along a wire. (From Articulo LC, Kusy RP. *Am J Orthod Dentofac Orthop*. 1999;115:39–51.)





• **Fig. 9.30** Scanning electron microscope images show that sliding a bracket along a wire (or a wire through a bracket) causes surprising amounts of distortion of the wire surface. (A) A 16-mil steel wire after sliding through a bracket. Note the significant tear in the wire. (B) A 21 × 25 steel wire after sliding. Note the series of indentations. When the corner of the bracket catches on damaged areas such as these, tooth movement stops until the notching is released by masticatory function. (Courtesy Dr. Robert Kusy.)

a 7-degree or greater angle, almost all the resistance was due to binding with both wires.

The conclusion: For very early alignment of teeth, resistance to sliding is due to a combination of friction and binding, but almost immediately, unless the tooth is allowed to tip to keep the contact angle low, the frictional component becomes so low that it is negligible, and resistance to sliding is due almost totally to elastic binding.

During orthodontic tooth movement, inelastic binding also is likely to be encountered. This occurs when notching of the edge of the wire occurs (Fig. 9.30). When a notch encounters the edge of the bracket, tooth movement stops until displacement of the tooth during function releases the notch (remember, teeth move during function as alveolar bone bends under the heavy loads and return to their original position as the bone springs back when the heavy loading is released). Given the presence of both types of binding, it is not surprising that observations of tooth movement show that it happens almost entirely in a series of steps, not in a smooth flow.

### Magnitude of Resistance to Sliding

Perhaps the most important information to be gained from a consideration of resistance to sliding is an appreciation of its magnitude, even under the best of circumstances. If a canine tooth is to slide along an archwire as part of the closure of an extraction space, and a 100-gm net force is needed for tooth movement, approximately another 100 gm will be needed to overcome the effects of binding and friction. The total force needed to slide the tooth therefore is twice as great as might have been expected. Because this resistance is due mostly to binding, replacing a conventional edgewise bracket and elastomeric ligature tie with a self-ligating bracket so that the wire is not forced against the bottom of the bracket does not lead to faster space closure.<sup>17</sup>

In terms of the effect on orthodontic anchorage, the problem created by resistance to sliding is not so much its presence as the

difficulty of knowing its magnitude. To slide a tooth or teeth along an archwire, the clinician must apply enough force to overcome the resistance and produce the biologic response. As mentioned earlier, it is difficult to avoid the temptation to estimate the resistance to sliding generously and add additional force to be certain that tooth movement will occur. The effect of any force beyond what was really needed to overcome resistance to sliding is to bring the anchor teeth up onto the plateau of the tooth movement curve (see Fig. 8.22). Then either unnecessary movement of the anchor teeth occurs or additional steps to maintain anchorage are necessary (such as headgear or bone screws).

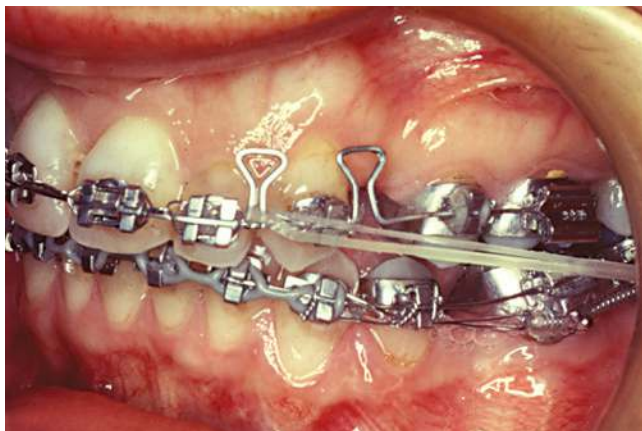
If a springy loop is bent into the archwire, activated to produce tooth movement, and then tied tightly, archwire segments move, taking the teeth with them instead of the teeth moving relative to the wire. Springs of this type are called *retraction springs* if they attach to only one tooth or *closing loops* if they connect two archwire segments (Fig. 9.31). Incorporating springs into the archwire makes the appliance more complex to fabricate and use clinically but eliminates the difficulty in predicting resistance to sliding.

### Methods to Control Anchorage

From the previous discussion of the biologic aspects of anchorage in Chapter 8 and the earlier review in this chapter of the effects of friction and binding, it is apparent that several potential strategies could be used to control anchorage. Nearly all the possible approaches are actually used in clinical orthodontics, and all are affected by whether resistance to sliding will be encountered and, if so, how much. Let us consider these strategies in more detail.

#### Anchorage Types

**Reinforcement.** The extent to which anchorage should be reinforced (by adding teeth to the anchorage unit) depends on the tooth movement that is desired. In practice, this means that anchorage requirements must be established individually in each



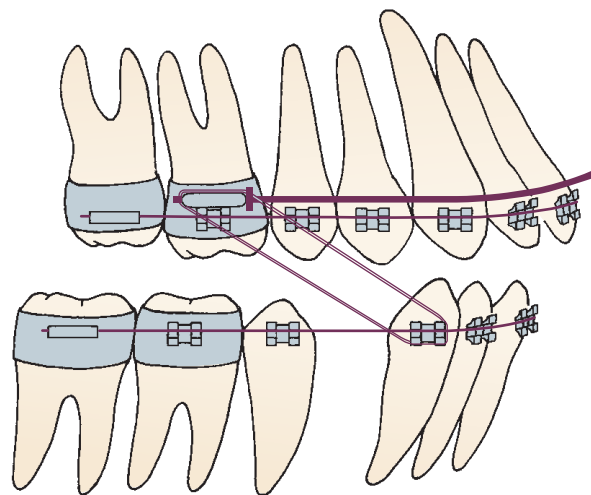
• **Fig. 9.31** A closing loop is being used to retract the maxillary incisors, while a spring to slide the lower teeth along the archwire is being used in the lower arch. In this patient with Class II malocclusion, the closing loop eliminates resistance to sliding as a factor in maintaining the position of the maxillary posterior teeth, while the sliding space closure in the lower arch and the light Class II elastic both serve to move the lower posterior teeth forward as part of the correction of the molar relationship.

clinical situation. Once it has been determined that reinforcement is desirable, however, this typically involves including as many teeth as possible in the anchorage. For significant differential tooth movement, the ratio of PDL area in the anchorage unit to PDL area in the tooth movement unit should be at least 2 to 1 without sliding and 4 to 1 with it. Anything less produces something close to reciprocal movement, especially if force levels are not well controlled.

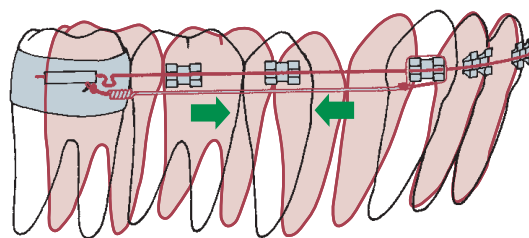
Satisfactory reinforcement of anchorage may require the addition of teeth from the opposite dental arch to the anchor unit. For example, to close a mandibular premolar extraction site, it would be possible to stabilize all the teeth in the maxillary arch so that they could only move bodily as a group and then to run an elastic from the upper posterior to the lower anterior, thus pitting forward movement of the entire upper arch against distal movement of the lower anterior segment (Fig. 9.32). This addition of the entire upper arch would greatly alter the balance between retraction of the lower anterior teeth and forward slippage of the lower posterior teeth.

This anchorage could be reinforced even further by having the patient wear an extraoral appliance (headgear) placing backward force against the upper arch. The reaction force from the headgear is dissipated against the bones of the cranial vault, thus adding the resistance of these structures to the anchorage unit. The only problem with reinforcement outside the dental arch is that springs within an arch provide constant forces, whereas elastics from one arch to the other tend to be intermittent, and extraoral force is likely to be even more intermittent. Although this time factor can significantly decrease the value of cross-arch and extraoral reinforcement, both can be quite useful clinically.

**Subdivision of Desired Movement.** A common way to improve anchorage control is to pit the resistance of a group of teeth against the movement of a single tooth, rather than dividing the arch into more or less equal segments. In our same extraction site example, it would be perfectly possible to reduce the strain on posterior anchorage by retracting the canine individually, pitting its distal movement against mesial movement of all other teeth within the arch (Fig. 9.33). After the canine tooth had been retracted, one



• **Fig. 9.32** Reinforcement of anchorage can be obtained by adding additional teeth within the same arch to the anchor unit, or by using elastics from the opposite arch to help produce desired tooth movement, as with the interarch elastic shown here. Additional reinforcement can be obtained with extraoral force, as with addition of a facebow to the upper molar to resist the forward pull of the elastic.

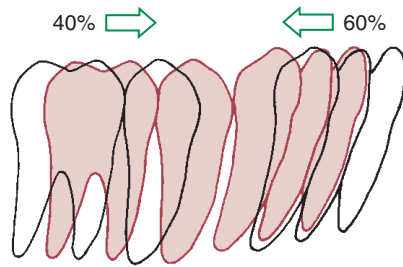


• **Fig. 9.33** Retraction of the canine by itself, as the first step in a two-stage space closure, often is used to conserve anchorage, particularly when sliding teeth along an archwire.

could then add it to the posterior anchorage unit and retract the incisors. This approach has the advantage of dissipating the reaction force over a large PDL area in the anchor unit—but only if the retraction force is kept light, as discussed in Chapter 8. Its disadvantage is that closing the space in two steps rather than one takes nearly twice as long.

Subdivision of tooth movement improves the anchorage situation regardless of whether sliding is involved and where a space in the arch is located. If it is desired to slip all the posterior teeth forward (in which case the anterior teeth are the anchor unit), bringing them forward one at a time is the most conservative way to proceed. Again, keeping the force levels light is the key to producing the differential tooth movement.

**Tipping and Uprighting.** Another possible strategy for anchorage control is to tip the teeth and then upright them, rather than moving them bodily. In our familiar extraction site example, this would again require two steps in treatment. First, the anterior teeth would be tipped distally by being pitted against mesial bodily movement of the posterior segment (see Fig. 8.23). Using a bracket that allows the teeth to tip as they slide along an archwire



• **Fig. 9.34** Closure of a premolar extraction site often is desired in a ratio of 60% retraction of incisors, 40% forward movement of molar and second premolar. This result can be obtained straightforwardly in three ways: (1) one-step space closure with no sliding (closing loop); (2) two-step space closure with sliding mechanics, retracting the canine individually, and then retracting the four incisors in a second step (the classic Tweed approach); or (3) two-step sliding with distal tipping of the canine and incisors initially, followed by uprighting of these teeth (the classic Begg approach). Good clinical results can be obtained with all three methods. The cost of resistance to sliding in space closure, with well-managed orthodontic appliances, is paid more in increased treatment time than in decreased quality of result.

reduces binding and therefore keeps resistance to sliding small. As a second step, the tipped teeth would be uprighted, moving the canine roots distally and torquing the incisor roots lingually, again with stationary anchorage in the posterior segments. It would be extremely important to keep forces as light as possible during both steps, so that the teeth in the posterior segment were always below the optimum force range, while the anterior teeth received optimum force.

### Anchorage Control in Space Closure

At this point, let's begin by considering a relatively typical extraction situation, in which it is desirable to close the extraction space 60% by retraction of the anterior teeth and 40% by forward movement of the posterior segments (Fig. 9.34). This outcome would be expected from any of three possible approaches: (1) one-step space closure with no sliding (via closing loops so that segments of wire are moved with the teeth attached, rather than sliding); (2) a two-step closure sliding the canine bodily along the archwire, then retracting the incisors (as in the original Tweed technique); or (3) two-step space closure, tipping the anterior segment with some friction, then uprighting the tipped teeth (as in the Begg technique). (See Chapter 16 for a detailed discussion of these techniques.)

This example makes the cost of binding and friction in a clinical setting more apparent: the greater strain on anchorage when brackets slide along an archwire must be compensated for by a more conservative approach to anchorage control. The price therefore is paid in increased treatment time. The closing loop approach, although more difficult to fabricate and manipulate, will result in the same space closure significantly more quickly.

Note that strategies for anchorage control are associated with particular orthodontic appliances; indeed, they are literally built into the appliance in many instances. The approach to anchorage control that is implicit in the appliance design is sometimes called the *appliance philosophy*, not quite so strange a term when viewed in this way.

**Skeletal Anchorage.** Skeletal anchorage is derived from bone screws, which differ from implants to support replacement teeth

in that osseointegration with the screw is not desired, simply because it is to be removed when it is no longer needed as an orthodontic anchor. They can be used either as single screws or, when greater anchorage is needed for more complex tooth movement, as miniplates attached with screws to basal bone of the maxilla or mandible (Fig. 9.35). Collectively, these devices are referred to as *temporary anchorage devices* (TADs). They make tooth movement possible now that simply could not be accomplished without them. With properly designed skeletal anchorage, there is no concern about moving teeth that were not intended to be moved, but the amount of force to teeth that are to be moved still must be determined with resistance to sliding in mind, and the desired treatment outcome must be determined with some precision before bone anchors are placed so that they can be positioned to provide the proper force directions.

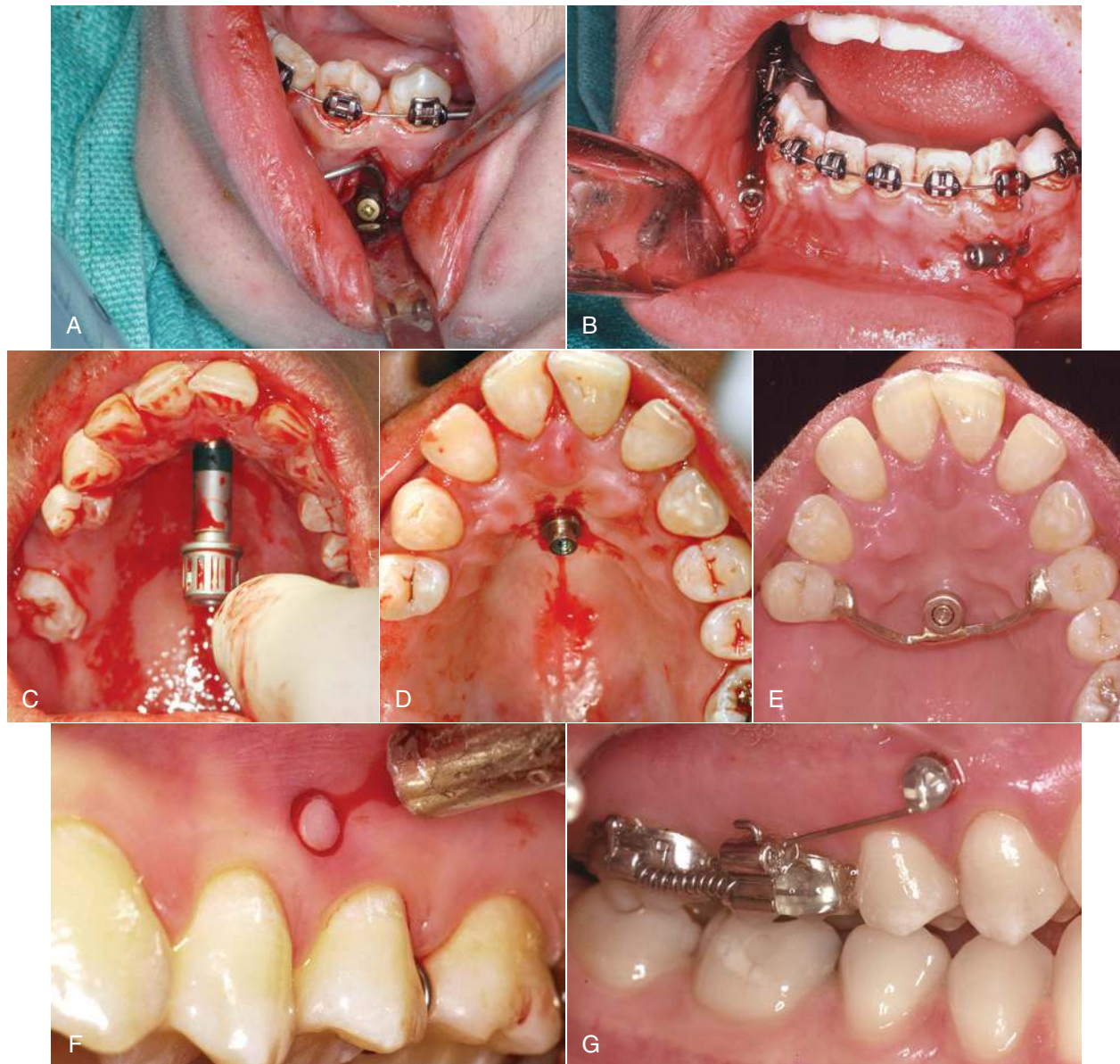From a broad perspective, the indication for skeletal anchorage is inadequate intraoral and extraoral anchorage to obtain the desired tooth movement. At that point, the key consideration is whether individual bone screws that the orthodontist can place would be satisfactory, or whether miniplates that require raising a flap for placement (more surgery than many orthodontists would wish to perform) would be required. The relative advantages and disadvantages of screws alone versus miniplates have been the subject of some controversy,<sup>18,19</sup> but it seems clear that the more anchorage that would be needed, the greater the indication for miniplates and their multiple screws.

For missing teeth that eliminate the usual dental anchorage possibility, impacted teeth, and other problems that require movement of only a few teeth, alveolar bone screws are adequate and indicated. It is interesting that single bone screws also can be satisfactory for intrusion of multiple teeth, as when maxillary posterior teeth are to be intruded to close an anterior open bite, because a requirement for intrusion is light force. For more complex tooth movement—for example, moving the entire maxillary arch distally for Class II camouflage—or when the desired force direction cannot be obtained with alveolar screws, miniplates that are attached with 2 or 3 screws and can be placed above or below tooth apices are needed.

Skeletal anchorage is used in two ways: direct or indirect. Direct anchorage is when the tooth or teeth to be moved are attached directly to the bone anchor; indirect anchorage is when another tooth or teeth are attached to the bone anchor to hold them in position while they serve as anchorage. With indirect anchorage there is nothing different from what has been discussed previously. With direct anchorage the location of the bone anchor must be carefully considered, because the line of force from it almost always is above or below the line of force from anchorage teeth. Miniplates are better for direct anchorage, even though they are likely to be even further from the teeth than isolated bone screws, because attachments to miniplates usually allow placing a wire through the attachment so that the line of force can be varied.

In many areas around the dentition, the bone where skeletal anchors might be placed is not nearly as thick or dense as one might think. Such areas are not good sites for single screws, although they might be satisfactory if a miniplate in that area were placed with multiple screws. The bone above the maxillary posterior teeth, where miniplates are preferred, is the best example, but this also applies more generally if heavy force would be used—the heavier the force, the greater the need for bone density if a single screw is to be satisfactory. The bone of the palate is more dense than alveolar bone, which makes it a favored site for screws rather than plates.





• **Fig. 9.35** Bone anchors retained by screws or screws with a head that extends into the mouth can be placed in both the mandibular and maxillary arches to provide skeletal anchorage for tooth movement. This makes it possible to produce tooth movement that otherwise would be impossible. (A) Placement of screws to hold a bone anchor in the mandible. (B) Anchors in place bilaterally. (C) Surgical placement of a palatal anchor. (D) Anchor (Straumann Orthosystem) in position. (E) Stabilizing lingual arch attached to the anchor, in preparation for retraction of the protruding maxillary incisors. (F) Removal of a small area of mucosa over the site where a bone screw is to be placed in the maxillary alveolar process. (G) Tomas screw (Dentaurum) with a stabilizing wire attached from a channel in the screw head to the molar headgear tube being used to prevent movement of the maxillary first molar as the second molar is moved distally. (C to E, courtesy Drs. S. Cunningham and P. Thomas; F and G, courtesy Professor A. Bumann.)

Age also is a factor in the use of skeletal anchorage: adequate bone density for most orthodontic procedures is not attained until early adolescence, so bone anchors cannot be used for most mixed dentition treatment.

The skeletal anchorage devices themselves are discussed and illustrated in [Chapter 10](#), and their use to accomplish tooth movement that was very difficult or impossible previously is described in detail in [Chapters 15 to 17 and 19](#).

## Determinate Versus Indeterminate Force Systems

The laws of equilibrium require not only that for every force there is an equal and opposite reactive force, but also that the sum of the moments around any arbitrary point is equal to zero. In other words, the moments, as well as the forces, generated by an orthodontic appliance system must be balanced, in all three planes of

space. It can be very difficult to visualize the total force system when multiple teeth are involved, but unexpected and unwanted tooth movement easily can result when an important component of the system is overlooked.

Force systems can be defined as statically *determinate*, meaning that the moments and forces can readily be discerned, measured, and evaluated, or as *indeterminate*. Statically indeterminate systems are too complex for precisely calculating all forces and moments involved in the equilibrium. Typically, only the direction of net moments and approximate net force levels can be determined.

This is more of a problem in orthodontics than in most engineering applications because the eventual action of an orthodontic appliance is affected by the biologic response. For instance, the amount of tooth movement will be determined largely by the magnitude of the forces felt by anchor teeth and teeth whose movement is intended, not just by the differential between those forces. If the force applied to the anchor teeth is high enough to pull them up onto the plateau of the pressure-response curve, reciprocal tooth movement will occur despite a difference in PDL pressures (see Fig. 8.22). Similarly, whether intrusion of incisor teeth or extrusion of posterior teeth occurs is almost totally a function of the magnitude of intrusive versus extrusive forces, not their direction or the difference between them. Determinate force systems therefore are particularly advantageous in orthodontics when control of force magnitudes is necessary to produce the desired biologic response.

For all practical purposes, determinate systems in orthodontics are those in which a couple is created at one end of an attachment, with only a force (no couple) at the other (i.e., a one-couple system). This means that a wire that will serve as a spring can be inserted into a tube or bracket at one end but must be tied so that there is only one point of contact on the other (Fig. 9.36). When

the wire is tied into a bracket on both ends, a statically indeterminate two-couple system has been created.

## One-Couple Systems

In orthodontic applications, one-couple systems are found when two conditions are met: (1) a cantilever spring or auxiliary archwire is placed into a bracket or tube(s) and typically attaches to a tooth or teeth that are part of a stabilized segment (i.e., reinforced anchorage is being used), and (2) the other end of the cantilever spring or auxiliary archwire is tied to a tooth or group of teeth that are to be moved, with a single point of force application.<sup>20</sup>

For analysis, the teeth in the anchor unit are considered as if stabilization had created a single large multirooted tooth, with a single center of resistance. It is important to tie teeth in an anchor unit tightly together with as rigid a stabilizing wire segment as possible. Often the posterior teeth on both sides are tied together with a rigid lingual/palatal arch, so that a single posterior stabilizing segment is created. If the goal is to move more than one tooth, the tooth movement segment similarly must be tied so the teeth become a single unit.

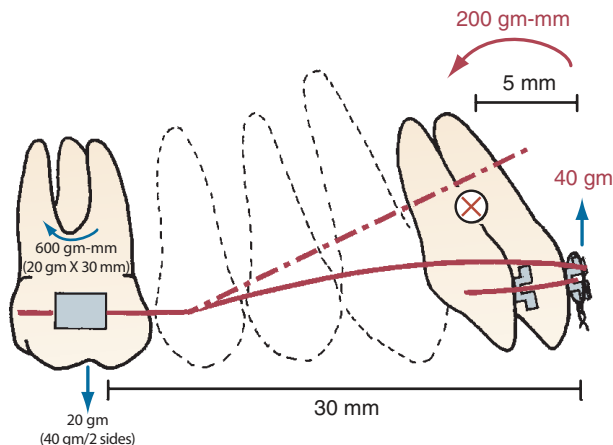
### Cantilever Spring Applications

Cantilever springs are used most frequently to bring severely displaced (impacted) teeth into the arch (Fig. 9.37). These springs have the advantage of a long range of action, with a minimal decrease in force as tooth movement proceeds and excellent control of force magnitude. There are two disadvantages: (1) as with most devices with a long range of action, cantilever springs do not fail safely—if they are distorted by the patient, significant tooth movement in the wrong direction is quite possible—and (2) the moment of the force on an unerupted tooth rotates the crown lingually as the tooth is brought toward the occlusal plane, which is undesirable if the tooth is already lingual to its proper position (as most unerupted teeth are). Although an additional force can be added to overcome this, the system rapidly becomes extremely complex, making it hard to know what forces and couples exist. If the cantilever spring is tied into a bracket on the unerupted tooth so that a couple can be created for better control, the force system becomes statically indeterminate and force magnitudes are no longer known with certainty.

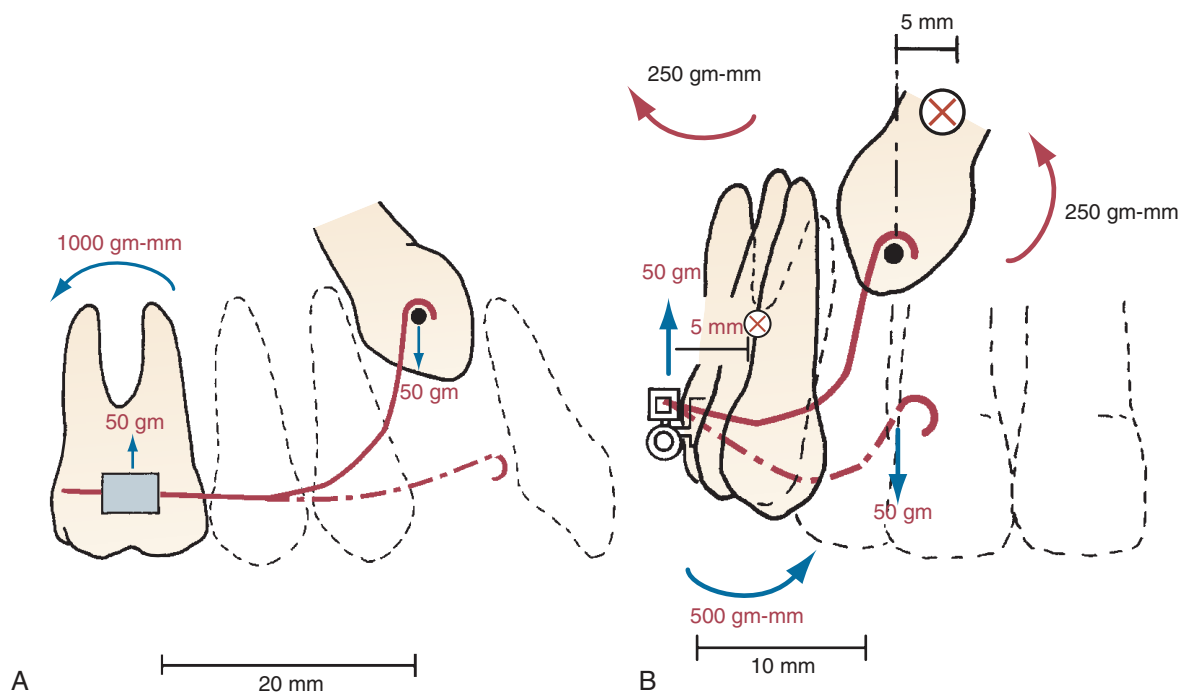
### Auxiliary Intrusion or Extrusion Arches

The major use of one-couple systems is for intrusion, typically of incisors that have erupted too much. For this purpose, light force against the teeth to be intruded is critical. An intrusion arch typically employs posterior (molar) anchorage against two or four incisors (Fig. 9.38). Because the intrusive force must be light, the reaction force against the anchor teeth also is light, well below the force levels needed for extrusion and tipping that would be the reactive movements of the anchor teeth. Tying the molar teeth together with a rigid lingual/palatal arch prevents buccal tipping of the molars. In adults, usually the premolar teeth also are added to the anchor unit.

It would be easy enough to activate an auxiliary archwire to produce extrusion of incisors rather than intrusion. This is rarely done clinically, however. The force needed for extrusion is four to five times higher than for intrusion, so the reactive force against the anchor teeth also would be higher and the anchor teeth would not be as stable. Perhaps more important, the precise control of force magnitude that is the major advantage of a one-couple system



• **Fig. 9.36** An intrusion arch made from rectangular wire, which fits into a rectangular tube on the molars and is tied to one point of contact on the incisor segment, is an example of a determinate one-couple system. If the archwire is activated by pulling it down and tying it to the incisor segment so that it delivers 40 gm of intrusion force (10 gm per incisor, 20 gm per side), and if the distance from the molar tube to the point of attachment is 30 mm, each molar will feel a 20-gm extrusive force in reaction and a 600 gm-mm moment to tip the crown distally. At the incisor segment, the force will create a 200 gm-mm moment to rotate the incisor crowns facially. At each molar, the extrusive force also would create a moment to roll the crown lingually. If the buccal tube were 4 mm buccal to the center of resistance, the magnitude of this moment would be 80 gm-mm.



• **Fig. 9.37** A cantilever spring, made from a rectangular wire that fits into a rectangular tube (or bracket) on one end and is tied to one point of contact on the other, produces a determinate one-couple system in which the forces and moments can be known precisely. (A) Lateral view of the force system created by a cantilever spring to extrude an impacted maxillary canine. If the distance between the molar tube and a button on the canine to which the spring is tied is 20 mm, placing a 50-gm extrusive force on the canine creates a 50-gm intrusive force on the molar and also a 1000 gm-mm moment to rotate the molar crown forward around its center of resistance. (B) Frontal view of the same force system. Consider the buccolingual (torque) moments created by the force on the molar and canine. If the center of resistance of the canine is 5 mm lingual to the button on its crown, a 50-gm extrusive force creates a 250 gm-mm moment to rotate the crown lingually (which usually is not desired; *red arrow*). At the molar, if the center of resistance is 5 mm lingual to the tube on the buccal surface, the 50-gm intrusive force creates a 250 gm-mm moment to rotate the crown facially (*red arrow*). But if the impacted canine is 10 mm lingual to the buccal surface of the molar, activating the spring also twists it, creating a 500 gm-mm torquing moment to rotate the molar crown lingually (*blue arrow*). The result at the molar is a net 250 gm-mm moment to torque the molar crown lingually and roots buccally. If the rectangular spring were tied into a bracket on the canine, a moment to torque its root facially could be generated, but the resulting two-couple system would be indeterminate—it would no longer be possible to know the forces and moments with certainty.

is less critical when extrusion is desired. The additional complexity of stabilizing segments and an auxiliary archwire may not be cost-effective if extrusion is the goal.

## Two-Couple Systems

### Utility Arches for Intrusion

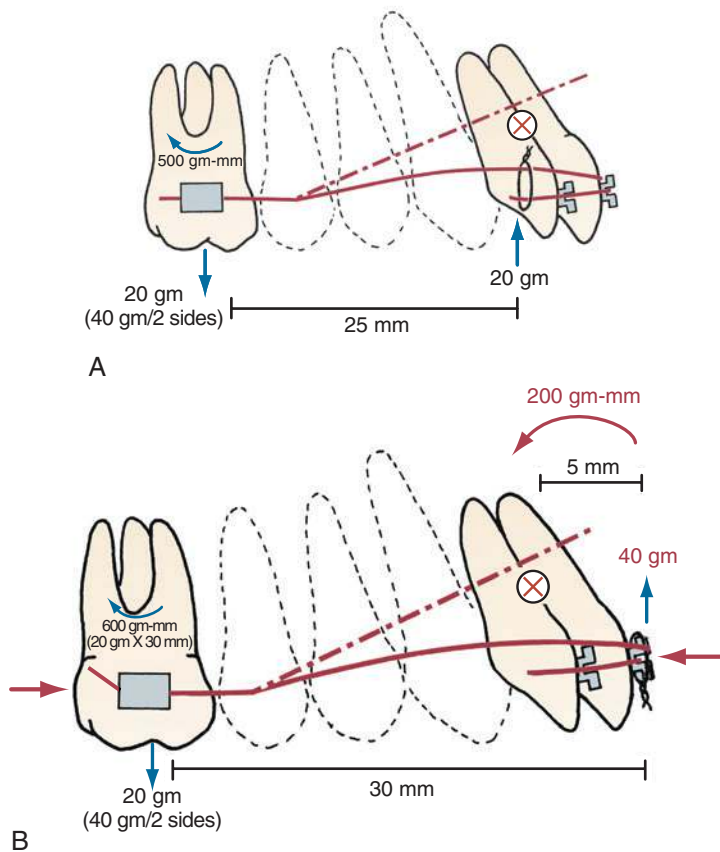
An easy way to see the effect of changing from a determinate one-couple to an indeterminate two-couple system is to observe the effect of tying an intrusion arch into brackets on incisor teeth, rather than tying it with one-point contact.<sup>21</sup> The utility arch, popularized by Ricketts and recommended for incisor intrusion, makes just this change. It is formed from rectangular wire so that it will not roll in the molar tubes, bypasses the canine and premolar teeth, and (unlike a one-couple intrusion arch) is tied into the incisor brackets (i.e., it is a  $2 \times 4$  archwire attached to two molars and four incisors). The resulting long span provides excellent load deflection properties, so the light force necessary for intrusion can

be created. One-couple intrusion arches can look quite similar. The difference comes when the utility arch is tied into the incisor brackets, creating a two-couple system.

When the utility arch is activated for intrusion, the moment of the intrusive force tips the crowns facially (Fig. 9.39). One way to prevent the facial tipping is to apply a force to retract the incisors, which would create a moment in the opposite direction. This could be done by cinching or tying back the intrusion utility arch. Although the retraction force could be light, any force to bring the anchor teeth mesially is likely to be undesirable.

Another strategy to control the facial tipping is immediately apparent: place a twist in the anterior segment of the utility arch, to torque the incisors lingually, and accentuate the torque by cinching the end of the wire at the molar tube. Let us examine the effect of doing this (see Fig. 9.39B–C). An effect of the couple within the bracket is to increase the intrusive force on the incisors and also the reactive extrusive force on the molars. Although one can be sure that the magnitude of the intrusive force would increase,





• **Fig. 9.38** Two factors in the action of an intrusion arch are the relationship of the point of force application relative to the center of resistance of the incisor segment and whether the incisor teeth are free to tip facially as they intrude or whether the arch is cinched back to produce lingual root torque. (A) An intrusion arch can be tied at any point along the incisor segment. If it is tied behind the lateral incisor bracket, the force is applied in line with the center of resistance, and there is no moment to rotate the incisors faciolingually. The effect on the anchor molar would be slightly less than if the intrusion arch were tied in the midline (see Fig. 9.36). (B) If the intrusion arch were tied in the midline and cinched back so it could not slide forward in the molar tube, the effect would be lingual root torque on the incisors as they intruded. Equilibrium requires that both moments and forces be balanced, so any lingual force exerted by the wire to restrain the incisors would be balanced by a mesial force on the molar (red arrows).

it is impossible to know how much. An increase in the magnitude of the intrusive force often is not anticipated from such an apparently unrelated change in the archwire. In addition, now the magnitude of the reactive forces is not known with certainty, which makes it impossible to accurately adjust the archwire even if you do anticipate the increase. Both effects help explain why utility arches often produce disappointing amounts of incisor intrusion relative to molar extrusion.

### Symmetric and Asymmetric Bends

When a wire is placed into two brackets, the forces of the equilibrium always act at both brackets. For analysis, two groups of teeth that have been tied together to create the equivalent of a single multirrooted tooth can be treated as if there were just one bracket for each group. There are three possibilities for placing a bend in the wire to activate it:

- *Symmetric V-bend*, which creates equal and opposite couples at the brackets (Fig. 9.40). The associated equilibrium forces at each bracket also are equal and opposite, and therefore cancel each other out. A symmetric V-bend is not necessarily halfway between two teeth or two groups of teeth; the important quality is that it generates equivalent couples at both ends. These couples are affected by both bracket width and bracket alignment, so care must be taken if placing symmetric V-bends before the teeth are well aligned. In addition, if a symmetric V-bend is to be placed between posterior and anterior teeth, studies have shown that the bend must be placed closer to the posterior segment owing to the curve of the archwire. Finally, equal and opposite couples have the benefit of no net reaction forces, but these equal couples will not generate equivalent tooth movement if the anchorage of one section is much greater.
- *Asymmetric V-bend*, which creates unequal and opposite couples, and net equilibrium forces that would intrude one unit and extrude the other (Fig. 9.41). Although the absolute magnitude of the forces involved cannot be known with certainty (this is, after all, an indeterminate system), the relative magnitude of the moments and the direction of the associated equilibrium forces can be determined. The bracket with the larger moment will have a greater tendency to rotate than the bracket with the smaller moment, and this will indicate the direction of the equilibrium forces. Placing the short segment of the wire in the bracket is a good way to visualize the direction of the equilibrium forces. As the bend moves closer to one of two equal units, the moment increases on the closer unit and decreases on the distant one, while equilibrium forces increase.

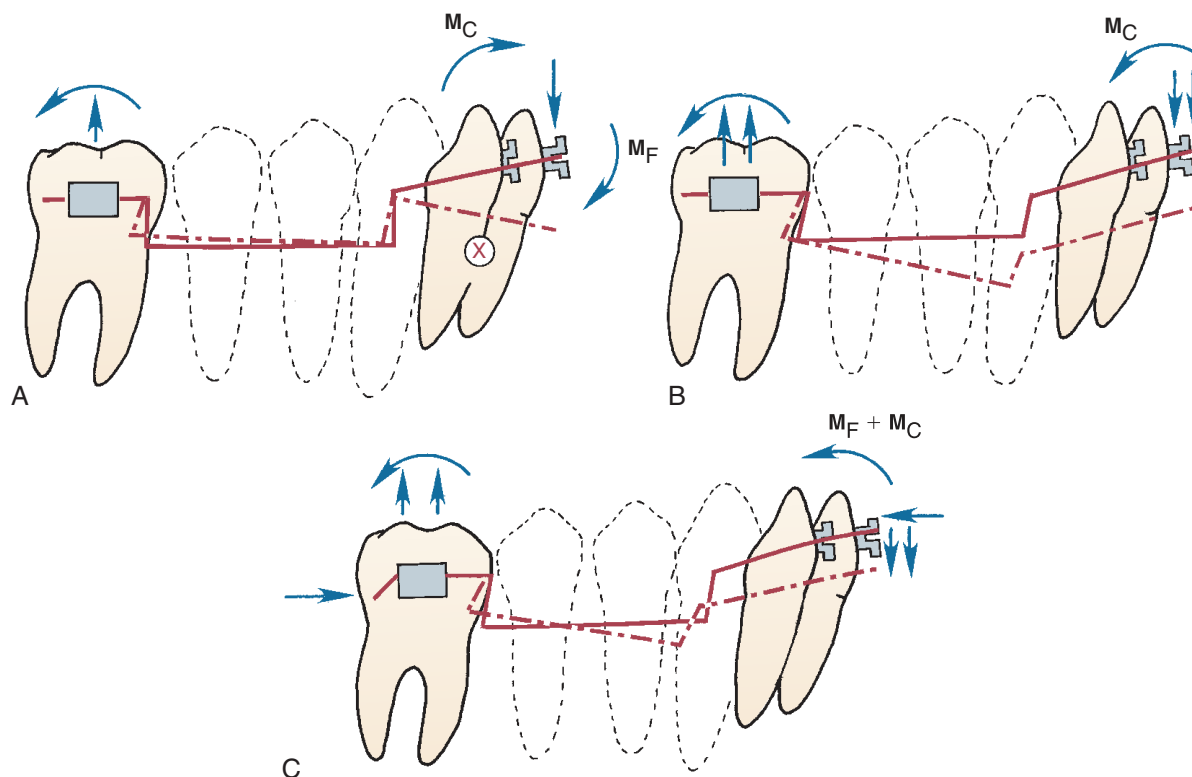
In most studies of asymmetric V-bends, a location is found where no moment is felt at the distant bracket, only a single force. When the bend moves closer than this to one bracket, moments at both brackets are in the same direction, and equilibrium forces increase further. The location of this point, however, varies in different studies, ranging from one-third of the distance along the wire to not being found even when the bend is placed right by one anchor unit. The difficulty of locating this point and therefore of confidently predicting the effect of placement of the bend is another illustration of why it is important to watch clinically for undesired side effects.

- *Step bend*, which creates two couples in the same direction regardless of its location between the brackets (Fig. 9.42). The location of a V-bend is a critical variable in determining its effect, but the location of a step bend has little or no effect on either the magnitude of the moments or the equilibrium forces.

The general relationship between bend location and the forces and moments that are produced is shown in Table 9.3. Note that for V-bends, the force increases steadily as the beam moves off-center. For step bends, because both couples are in the same direction, the force is increased over what an asymmetric V-bend would produce.

### Forces and Couples Created by Interbracket Bends

Under laboratory conditions, the forces and couples created in a two-couple system by interbracket bends can be evaluated experimentally.<sup>22</sup> With a 16-mil steel wire and an interbracket distance of 7 mm (about what would be found between central incisors with twin brackets or between narrow canine and premolar brackets), a step bend of only 0.35 mm would produce intrusive and extrusive forces of 347 gm and 1210 gm-mm couples in the same direction (see Table 9.3). Permanent distortion of the wire would occur with



• **Fig. 9.39** A utility arch often is an intrusion arch in a two-couple configuration, created by tying the rectangular intrusion arch into the brackets on the incisors. When this is done, the precise magnitude of forces and couples cannot be known, but the initial activation of the arch should be to provide about 40 gm to the incisor segment for intrusion. (A) Activating the utility arch by placing it in the brackets creates the intrusion force, with a reactive force of the same magnitude on the anchor molar and a couple to tip its crown distally. At the incisors, a moment to tip the crowns facially ( $M_F$ ) is created by distance of the brackets forward from the center of resistance, and an additional moment in the same direction is created by the couple within the bracket ( $M_C$ ) as the inclination of the wire is changed when it is brought to the brackets. The moment of this couple cannot be known, but it is clinically important because it affects the magnitude of the intrusion force. (B) Placing a torque bend in the utility arch creates a moment to bring the crown lingually, controlling the tendency for the teeth to tip facially as they intrude, but it also increases the magnitude of the intrusive force on the incisor segment and the extrusive force and couple on the molar. (C) Cinching back the utility arch creates a force to bring the incisors lingually, and a moment of this force opposes the moment of the intrusion force. At the molar, a force to bring the molar mesially is created, along with a moment to tip the molar mesially. Especially if a torque bend still is present, it is difficult to be certain which of the moments will prevail or whether the intrusion force is appropriate. With this two-couple system, the vertical forces easily can be heavier than desired, changing the balance between intrusion of the incisors and extrusion of the molars. (Redrawn from Davidovitch M, Rebellato J. *Semin Orthod.* 1995;1:25–30.)

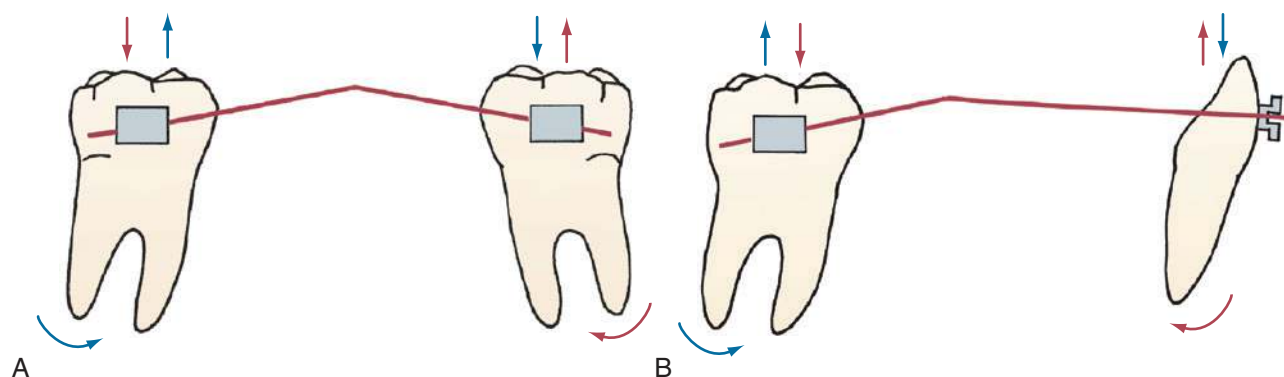
a step bend of 0.8 mm. Because this force magnitude is far too great for intrusion, it is clear that extrusion would prevail.

The heavy vertical forces produced by what orthodontists would consider modest bends in a light archwire such as 16-mil steel explain why extrusion is the response to step bends in continuous archwires. An asymmetric V-bend that places the apex of the bend 0.35 mm above the plane of the brackets produces 803 gm-mm couples with no net intrusive or extrusive forces at the one-third position. At the one-sixth position, intrusive and extrusive forces over 900 gm occur, with very large moments (see Table 9.3), so the result here also would be extrusion in addition to root movement.

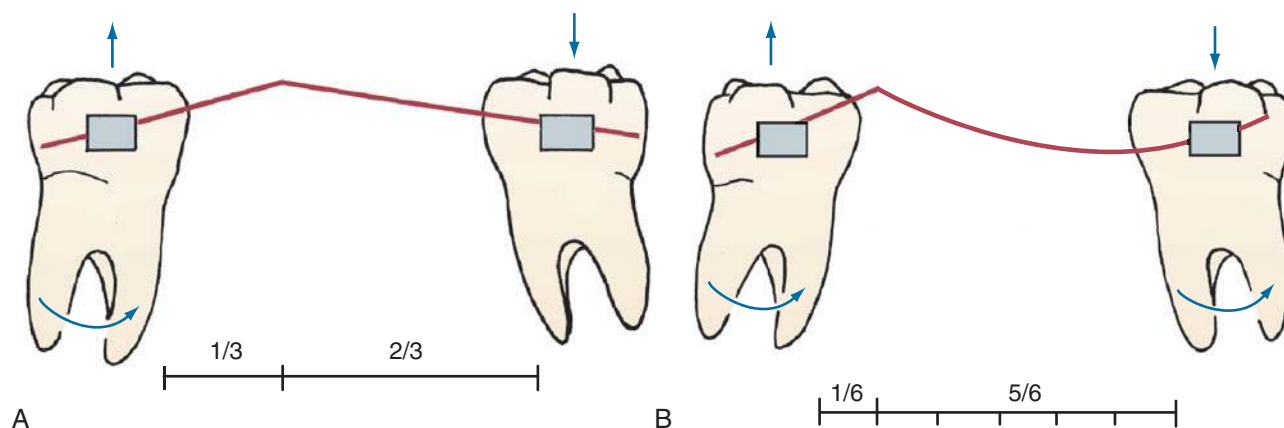
The moments and forces are greatly reduced as interbracket distances increase. For instance, the same 0.35-mm step bend that produced 347 gm with a 7-mm interbracket span produces only

43 gm with a 14-mm span (which is still too high for intrusion). Even with flexible archwires, an interbracket span equivalent to the distance from the first molar to the lateral incisor usually is needed to obtain the light force necessary for intrusion (which is why intrusion arches are designed to bypass the premolars and canines).

Longer spans also make the location of V-bends less critical. With a 7-mm interbracket span, moving a V-bend only 1.2 mm from a centered position would put it at the one-third position that totally eliminates the moment on the distant bracket. With a 21-mm span, the same error would be almost negligible. It is much easier therefore to control two-couple systems when the distances between attachments are relatively large, as they are when wires connect only to molars and incisors in a  $2 \times 4$  arrangement, or to anterior and posterior segments.



• **Fig. 9.40** (A) When a symmetric V-bend is placed halfway between two units with equal resistance to movement, it creates equal and opposite moments (red and blue curved arrows), and the intrusive–extrusive forces indicated by the red and blue vertical arrows cancel each other. (B) To create equal and opposite couples between two units with unequal resistance to movement, a V-bend must be displaced toward the unit with greater resistance, so a symmetric V-bend between an incisor and molar would be offset toward the molar. One must know the approximate anchorage value of teeth or units of the dental arch to calculate the appropriate location of symmetric or asymmetric V-bends.



• **Fig. 9.41** (A) An asymmetric V-bend creates a greater moment on one tooth or unit than the other. As the bend moves toward one tooth, the moment on it increases and the moment on the distant tooth decreases. When the bend is one-third of the way along the interbracket span, the distant tooth (on the right in this drawing) receives only a vertical force, with no moment. (B) If the V-bend moves closer than the one-third point to one of the teeth, a moment in the same direction is created on both teeth, instead of opposite moments. A V-bend placed to parallel the roots of the adjacent teeth would not do so if the bend were too close to one of the teeth.

Still another level of complexity exists for a  $2 \times 4$  two-couple wire, because 3-D effects are produced when the wire goes around the arch from the molars to the incisors. This makes the analysis of torque bends particularly difficult. Using finite analysis modeling, Isaacson et al have shown that the general principles of two-dimensional (2-D) analysis remain valid when 3-D analysis is done.<sup>23</sup> In a long-span wire such as a utility arch, however, a V-bend at the molar produces significantly less moment and associated equilibrium forces than the same V-bend located at the same distance from the incisor segment. In addition, the reversal of moments so that the moment is in the same direction on the molar and the incisor does not occur in the 3-D analysis when the V-bend moves closer than one-third of the distance to the molar or incisors. This makes the effect of utility arches with complex bends even less predictable.

### Two-Couple Archwires to Change Incisor Inclination

A two-couple system to change the inclination of incisors can be arranged to produce either tipping or torque.<sup>24</sup> The change in inclination is the same for tipping or torque; the difference is crown movement or root movement. If a wire spanning from the molars to the incisors is activated to rotate incisors around their center of resistance, the crowns will move facially when the wire is free to slide through the molar tube (Fig. 9.43A). Occasionally, this provides a convenient way to tip maxillary incisors facially to correct anterior crossbite in the mixed dentition (see Chapters 15 to 17 and 19).

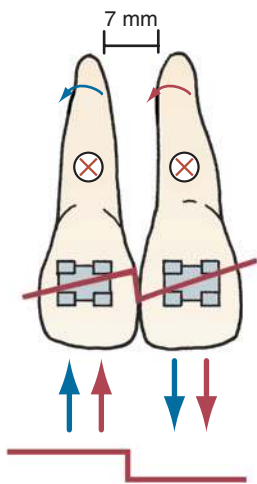
If the wire is cinched back (Fig. 9.43B), the effect will be to torque the incisor roots lingually, and a reaction force to bring the molar mesially is created. The incisors also will extrude, while the molars will intrude and roll facially. For incisor root torque,



**TABLE 9.3** Force Systems From Step and V-Bends

Percentage of Total Span to Closest Bracket	Moment Far Tooth/ Moment Near Tooth	Force General Condition	DATA FROM EXPERIMENT 16 STEEL, 7-MM SPAN, 0.35-MM BEND	
			Force (gm)	Moment (gm-mm)
Step Bend				
Any	1.0	XX	347	1210/1210
V-Bend				
0.5	−1.0	None	0	803/803
0.4	−0.3	X		
0.33	0	XX		
0.29			353	2210/262
0.2	0.3	XXX		
0.14			937	4840/1720
0.1	0.4	XXXX		

X, XX, XXX, XXXX indicate relative force levels generated at the various V-bend locations.  
From Burstone CJ, Koenig HA. *Am J Orthod Dentofac Orthop.* 1988;93:59–67.

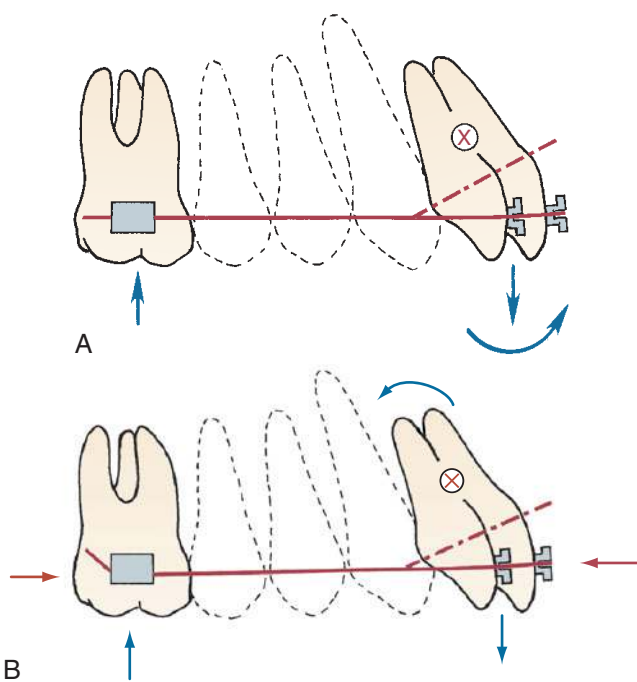


• **Fig. 9.42** A step bend between two teeth produces intrusive force on one tooth and extrusive force on the other, and creates couples in the same direction. In contrast to V-bends, there is little effect on either the force or the couples when the step bend is moved off-center.

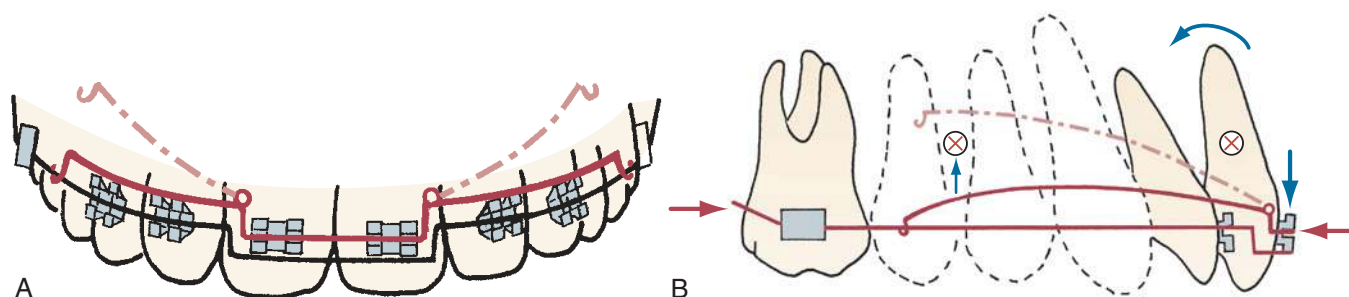
the long range of action provided by a 2 × 4 two-couple system is not necessarily an advantage, particularly when there is nothing to control the vertical side effects on the incisors. In patients with severely upright maxillary central incisors (as in Class II division 2 malocclusion), a one-couple torquing arch with all the other teeth as anchorage can be used to advantage (Fig. 9.44).

**Posterior Crossbite Correction: Transverse Movement of Posterior Teeth**

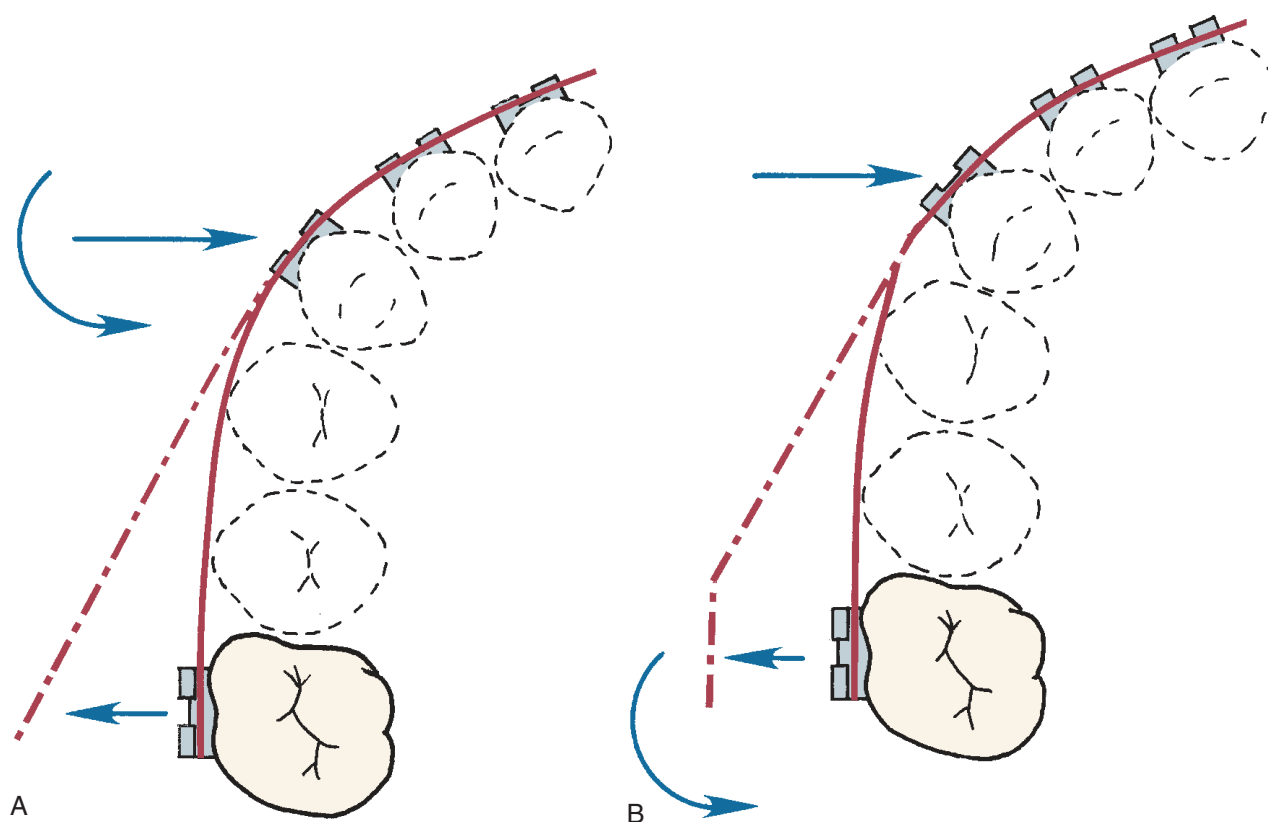
Dental posterior crossbite, requiring expansion or constriction of molars, can be approached with two-couple archwires.<sup>25</sup> Then the anterior segment becomes the anchorage and movement of



• **Fig. 9.43** An asymmetric V-bend in a rectangular wire spanning from the first molars to the incisor segment produces a moment to rotate the incisors faciolingually, with an intrusive force but no moment on the molars and an extrusive force on the incisors. (A) If the archwire is free to slide forward through the molar tube, the result is anterior tipping and extrusion of the incisors. Occasionally, this is desirable in the correction of anterior crossbite in the mixed dentition. (B) If the archwire is cinched behind the molar so that it cannot slide, the effect is lingual root torque and extrusion for the incisors. As noted in Fig. 9.38B, any lingual force exerted by the wire to restrain the incisors would be balanced by a mesial force on the molar (red arrows).



• **Fig. 9.44** For torque of very upright maxillary central incisors (as in Class II division 2 malocclusion), a one-couple torquing arch designed by Burstone can be very effective. (A) A heavy stabilizing arch is placed in all the teeth but the central incisors, contoured so that it steps below the brackets on the central incisors and contacts the facial surface of these teeth, and tied back against the molars. A wire tied into the central incisor brackets and activated by bending it down and hooking it between the first molar and second premolar then produces the desired moment. (B) Because the stabilizing archwire resists facial tipping and extrusion of the central incisors, the result is lingual root torque with optimum force over a long range. The reaction force to intrude the remaining teeth and bring them anteriorly is distributed over all the other teeth, minimizing the reaction.



• **Fig. 9.45** A 2 × 6 appliance can be used to produce transverse movement of first permanent molars. In this circumstance, the anterior segment becomes the anchorage and it is important to add the canines to the anchor unit, but the premolars cannot be tied to the archwire without destroying its effectiveness. The long span between the canine and molar is needed to produce the desired forces and moments in this two-couple system. (A) An outward bend a few millimeters behind the canine bracket results primarily in expansion of the molar, with little or no rotation (with the unequal segments, this approximates the one-third position between the units of the two-couple system). (B) An outward bend combined with a toe-in bend at the molar results in expansion and mesial-out rotation of the molar. (Redrawn from Rebellato J. *Semin Orthod.* 1995;1:37–43.)

one or both first molars is desired (Fig. 9.45). Incorporating the canines into the anchor segment is a necessity (i.e., this requires a  $2 \times 6$  rather than a  $2 \times 4$  appliance). A long span bypassing the premolars still is needed for appropriate force levels and control of moments. Asymmetric expansion or constriction to correct unilateral crossbite is quite feasible and often is the indication for using this method. As with other applications of two-couple systems, the large range of the appliance means that teeth can be moved a considerable distance with a single activation of the appliance. The corresponding disadvantage, of course, is that the system has poor fail-safe properties.

### Lingual Arches as Two-Couple Systems

Still another example of a two-couple appliance system is a transpalatal lingual arch (or a mandibular lingual arch that does not contact the anterior teeth).<sup>26</sup> Lingual arches often are employed to prevent tooth movement rather than create it. The need for a lingual arch to stabilize posterior segments in many situations has been noted previously. When a lingual arch is used to move teeth, spring properties are required, which means that either a different wire size or different material is needed for an active rather than a stabilizing lingual arch. Whatever a lingual arch is made of and however it is attached, its two-couple design predicts the effect of symmetric V, asymmetric V, and step bends. Often, it is desirable to rotate maxillary first molars so that the mesiobuccal cusp moves facially. This can be accomplished bilaterally with symmetric bends or unilaterally with an asymmetric bend (Fig. 9.46). An asymmetric activation tends to rotate the molar on the side closest to the bend and move it mesially, while the molar on the other side is displaced distally.

It is tempting to think that net distal movement of an upper molar can be accomplished routinely with this type of activation

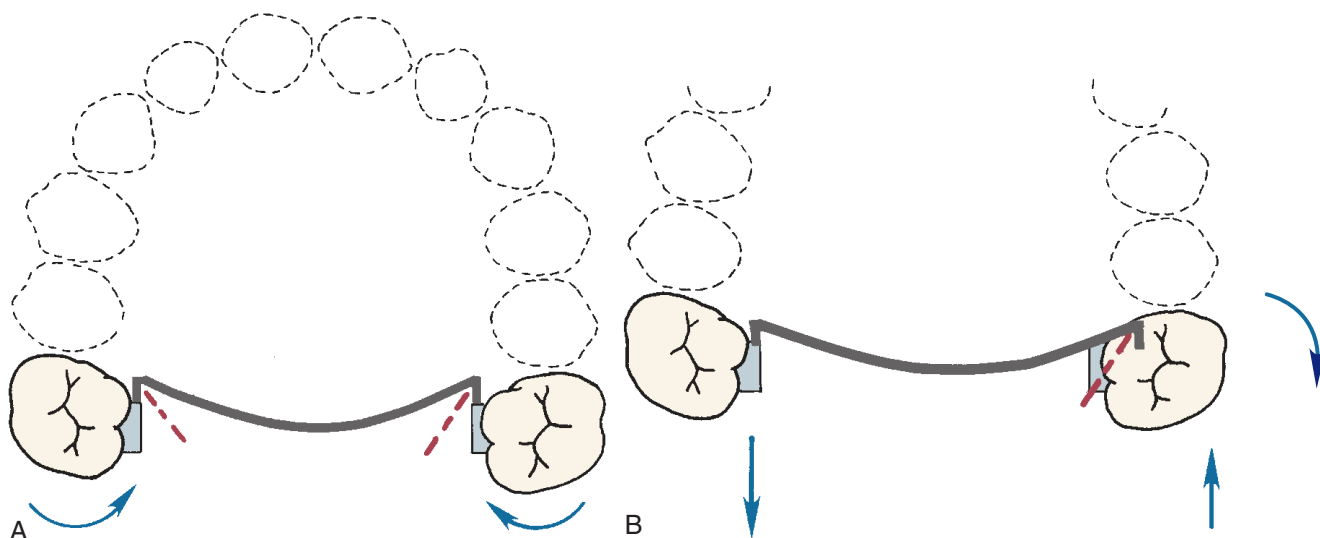
of a transpalatal lingual arch, and it has been suggested that a clinician can distalize one molar while rotating the other, then reverse the process, moving both of them back. However, the evidence indicates that significant distal movement beyond rotation of the buccal cusps is unlikely—mesial movement of the anchor molar is entirely possible and indeed quite likely.<sup>27</sup>

A lingual arch also can be activated to torque roots facially or lingually (Fig. 9.47). Symmetric torque when molars are expanded provides bodily movement rather than tipping. An interesting approach to unilateral crossbite is the use of a lingual arch with buccal root torque (lingual crown torque) on one side pitted against buccal tipping on the other side. As Ingervall and coworkers have shown quite convincingly, significant expansion on the tipping side can be produced, perhaps more effectively if the appliance is converted to a one-couple device by placing a round rather than rectangular wire in the bracket on the tipping side.<sup>28</sup>

A somewhat unusual application of a lingual arch would be to tip one molar distally, uprighting it. The reciprocal, of course, would be mesial tipping of the opposite molar. This activation would require a twist in the lingual wire. The location of this twist bend is not critical. The relative moments on the molar teeth will be equal and opposite, wherever the twist bend is placed.

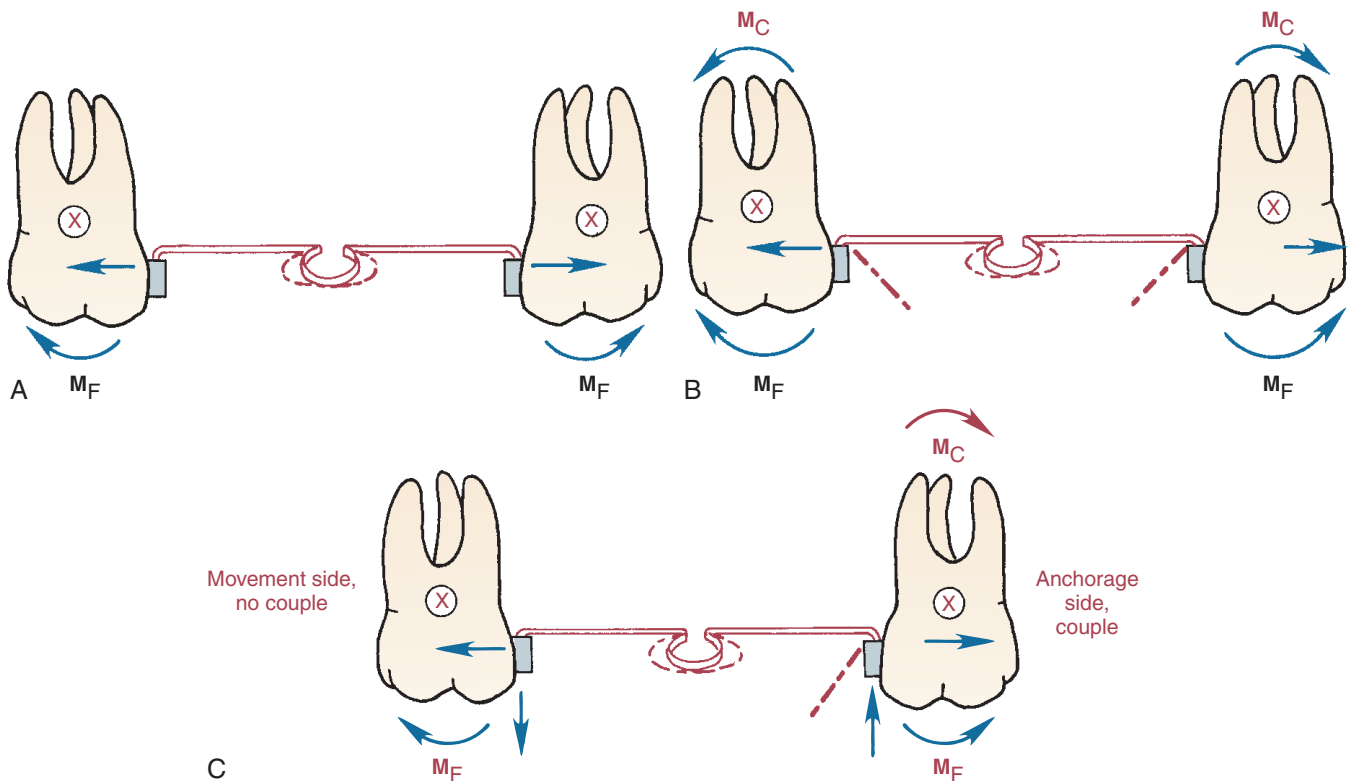
### Segmented Arch Mechanics

What is often called *segmented arch mechanics* is best considered an organized approach to using one-couple and two-couple systems for most tooth movements, so that an engineering analysis can provide an approximation of both forces and moments. This would allow use of more favorable force levels and potentially provide better control. The essence of the segmented arch system is the establishment of units of teeth, so that anchorage and movement



• **Fig. 9.46** (A) Bilateral toe-in bends at the first molars create equal and opposite couples, so the mesio-distal forces cancel and the teeth are rotated to bring the mesiobuccal cusp facially. When space has been lost in the maxillary arch or when a Class II molar relationship exists, this type of rotation often is desired, but a flexible rather than a rigid lingual arch is needed to obtain it. (B) A unilateral toe-in bend rotates the molar on the side of the bend, and creates a force to move the other molar distally. Although mesial movement of the molar on the side of the bend is limited by contact with the other teeth, mesial movement may occur. Although net distalization of both molars has been claimed by bends of this type on first one side, then the other, significant distal movement of both teeth is unlikely.





• **Fig. 9.47** (A) Bilateral expansion of molars can be created by expansion of a transpalatal arch, which typically is achieved by opening a loop in the middle. The moment of the expansion force tips the crowns facially. (B) Placing a twist in the wire creates a moment to torque the roots facially. The moment of the couple must be greater than the moment of the force for this to occur. Unless a flexible wire is used for the lingual arch, it can be difficult to insert the activated lingual arch with enough twist to produce the desired torque. (C) A twist in the wire on one side can be used to create stationary anchorage to tip the opposite molar facially. This is particularly effective if the wire is rounded on the movement side, so that a one-couple rather than two-couple system exists in the faciolingual plane of space. (A and B redrawn from Rebello J. *Semin Orthod.* 1995;1:44–54; C modified from Ingervall B, et al. *Am J Orthod Dentofac Orthop.* 1995;107:418–425.)

segments are clearly defined. The desired tooth movement is accomplished with cantilever springs where possible, so that the precision of the one-couple approach is available, or with the use of two-couple systems through which at least net moments and the direction of equilibrium forces can be known (as they cannot be with the multicouple force system created by a continuous rectangular archwire tied into brackets on all teeth in a dental arch).

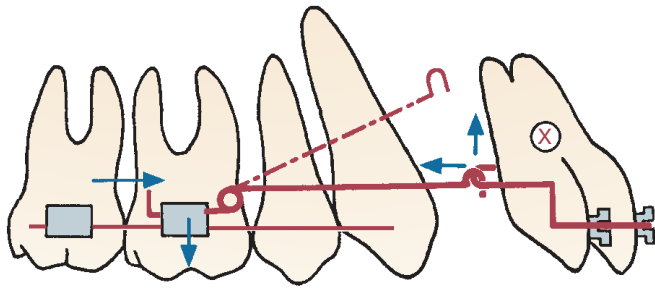
In segmented arch treatment, lingual arches are used for stabilization in a majority of the patients, and stabilizing wire segments in the brackets of teeth in anchor units also are used routinely. The requirements for stabilization, of course, are just the opposite of those for tooth movement: the heaviest and most rigid available wires are desired. For this reason, the 22-slot edgewise appliance is favored for segmented arch treatment. The wires used for stabilizing segments usually are  $21 \times 25$  steel, which is far too stiff for tooth movement. The stabilizing lingual arches usually are 36 steel, soldered to the molar bands or with doubled-over ends that fit into rectangular sheaths.

Typical segmented arch treatment would call for initial alignment within anterior and posterior segments, the creation of appropriate anchorage and tooth movement segments, vertical leveling using

intrusion or extrusion as needed, space closure with differential movement of anterior and posterior segments, and perhaps the use of auxiliary torquing arches. Sliding archwires through brackets almost always is avoided in this technique because resistance to sliding hampers efforts to control anchorage and introduces uncertainties into the calculation of appropriate force levels. Continuous archwires, particularly rectangular wires, would be reserved for the final stages of treatment when quite small but precise movements are required.

The advantages of the segmented arch approach are the control that is available and the possibility of tooth movements that would be impossible with continuous archwires. The disadvantages are the greater complexity of the orthodontic appliance and the greater amount of the doctor's time needed to install, adjust, and maintain it. It is an interesting paradox that simplifying the engineering analysis of the appliance, by dealing insofar as possible with identifiable one- and two-couple systems, complicates the appliance rather than making it simpler.

An excellent example of the segmented arch approach is the design of an appliance to simultaneously retract and intrude protruding maxillary central incisors. This is difficult to accomplish because lingual tipping of the incisors tends to move the crown downward



• **Fig. 9.48** A segmented arch approach allows simultaneous retraction and intrusion of an anterior segment. A rigid bar in the anterior segment can be extended posteriorly so that the point of application of an intrusive force is at or distal to the center of resistance of the incisor segment. If a cantilever spring is used to apply an intrusive force at that point, the tendency of a retraction force to elongate the anterior segment can be overcome. (Redrawn from Shroff B, et al. *Angle Orthod.* 1997;67:455–462.)

as the tooth rotates around its center of resistance. Intrusion of the root apex is necessary to keep the crown at the same vertical level relative to the lip and other teeth. This problem can be solved by creating anterior and posterior segments, using a rigid bar to move the point of force application distal to the center of resistance of the incisor segment, and applying separate intrusion and retraction forces (Fig. 9.48).<sup>29</sup> This could be done much more easily now, however, by using TADs as illustrated in Chapter 15. Skeletal anchorage has the potential to replace many of the more complex applications of segmented arch treatment.

Complex segmented arch treatment carries with it two other potential disadvantages that must be kept in mind. First, even with the most careful engineering analysis, it can turn out that something was overlooked in the determination of the likely outcome. The application of engineering theory to orthodontics is imperfect enough that a unique force system for an individual patient may not produce the expected outcome. Second, most segmented arch mechanisms contain little or nothing to control the distance that teeth can be displaced if something goes wrong. If precisely calibrated springs with a long range of action encounter something that distorts them (such as a sticky candy bar), major problems can occur. The mechanical efficiency of a segmented appliance can be both an advantage and a disadvantage.

## Continuous Arch Mechanics

Engineering analysis of the effects of a continuous archwire, one that is tied into the brackets on all the teeth, is essentially impossible. All that can be said is that an extremely complex multicouple force system is established when the wire is tied into place. The initial result is a small movement of one tooth. As soon as that occurs, the force system is changed, and the new system causes a small movement of another tooth (or a different movement of the first tooth). Either way, the result is still another complex force system, which causes another movement, leading to another change in the system, and so on.

Sometimes, orthodontic tooth movement is conceived as a slow, smooth transition of the teeth from one arrangement to another, but the force systems involved, particularly those with continuous arch mechanics, make it plain that this is far from the case. If it were possible to take time-lapse photographs of teeth

being moved into position, we undoubtedly would see “the dance of the teeth,” as the complex force systems formed and changed, producing varied effects in sequence, and Hayashi et al have shown just this sort of movement.<sup>30</sup> It is a saving grace that a continuous archwire usually does not allow the teeth to move very far from the desired endpoint.

The advantages and disadvantages of the continuous arch approach are just the reverse of those with the segmented arch approach. Continuous arch treatment is not as well defined in terms of the forces and moments that will be generated at any one time and certainly is less elegant from an engineering perspective. But continuous archwires often take less chair time because they are simpler to make and install, and they have excellent failsafe properties in most applications. In modern orthodontics, often the clinician must evaluate the trade-off between segmented and continuous arch approaches to specific problems. For those who use primarily the segmented approach, some use of continuous archwires simplifies life. For those who use primarily continuous archwires, some use of the segmented approach is necessary to meet specific objectives. Quite literally, you consider the benefits versus the cost (time) and risks, and make your choice.

The development of contemporary fixed appliances and their characteristics are discussed in the next chapter (Chapter 10). Clinical applications of the mechanical principles reviewed in this chapter and further information about the use of specific treatment methods are provided in some detail in Chapters 14 to 18.

## References

- Gurgel J, Kerr S, Powers JM, et al. Force-deflection properties of superelastic nickel-titanium archwires. *Am J Orthod Dentofacial Orthop.* 2001;120:378–382.
- Miura F, Mogi M, Okamoto Y. New application of superelastic NiTi rectangular wire. *J Clin Orthod.* 1990;24:544–548.
- Cacciafesta V, Sfondrini MF, Scribante LA, et al. Force levels of fiber-reinforced composites and orthodontic stainless steel wires: a 3-point bending test. *Am J Orthod Dentofacial Orthop.* 2008;133:410–413.
- Spendlove J, Berzins DW, Pruszyński JE, Ballard RW. Investigation of force decay in aesthetic, fibre-reinforced composite orthodontic archwires. *Eur J Orthod.* 2015;37:43–48.
- Chang JH, Berzins DW, Pruszyński JE, Ballard RW. The effect of water storage on the bending properties of esthetic, fiber-reinforced composite orthodontic archwires. *Angle Orthod.* 2014;84:417–423.
- Kusy RP. On the use of nomograms to determine the elastic property ratios of orthodontic archwires. *Am J Orthod.* 1983;83:374–381.
- Adams DM, Powers JM, Asgar K. Effects of brackets and ties on stiffness of an arch wire. *Am J Orthod Dentofacial Orthop.* 1987;91:131–136.
- Masoud AI, Tsay TP, BeGole E, Bedran-Russo AK. Force decay evaluation of thermoplastic and thermoset elastomeric chains: a mechanical design comparison. *Angle Orthod.* 2014;84:1026–1033.
- Linder-Aronson A, Lindsog S, Rygh P. Orthodontic magnets: effects on gingival epithelium and alveolar bone in monkeys. *Eur J Orthod.* 1992;14:255–263.
- Darendeliler MA, Darendeliler A, Mandurino M. Clinical application of magnets in orthodontics and biological implications: a review. *Eur J Orthod.* 1997;19:431–442.
- Jastrzebski ZD. *The Nature and Properties of Engineering Materials.* 3rd ed. New York: Wiley; 1987.
- Kusy RP, Whitley JQ. Effects of surface roughness on the coefficients of friction in model orthodontic systems. *J Biomech.* 1990;23:913–925.
- Kusy RP, Whitley JQ, Gurgel J. Comparisons of surface roughnesses and sliding resistances of 6 titanium-based or TMA-type archwires. *Am J Orthod Dentofacial Orthop.* 2004;126:589–603.

14. Saunders CR, Kusy RP. Surface topography and frictional characteristics of ceramic brackets. *Am J Orthod Dentofacial Orthop.* 1994;106:76–87.
15. Kusy RP, Whitley JQ. Assessment of second-order clearances between orthodontic archwires and bracket slots via the critical contact angle for binding. *Angle Orthod.* 1999;69:71–80.
16. Articulo LC, Kusy RP. Influence of angulation on the resistance to sliding in fixed appliances. *Am J Orthod Dentofacial Orthop.* 1999;115:39–51.
17. Burrow SJ. Canine retraction rate with self-ligating brackets vs conventional edgewise brackets. *Angle Orthod.* 2010;80:438–445.
18. Baumgaertel S. Temporary skeletal anchorage devices: the case for miniscrews. *Am J Orthod Dentofacial Orthop.* 2014;145:558–564.
19. Sugawara J. Temporary skeletal anchorage devices: the case for miniplates. *Am J Orthod Dentofacial Orthop.* 2014;145:559–565.
20. Lindauer SJ, Isaacson RJ. One-couple systems. *Semin Orthod.* 1995;1:12–24.
21. Davidovitch M, Rebellato J. Utility arches: a two-couple intrusion system. *Semin Orthod.* 1995;1:25–30.
22. Burstone CJ, Koenig HA. Creative wire bending—the force system from step and V bends. *Am J Orthod Dentofacial Orthop.* 1988;93:59–67.
23. Isaacson RJ, Lindauer SJ, Conley P. Responses of 3-dimensional archwires to vertical V-bends: comparisons with existing 2-dimensional data in the lateral view. *Semin Orthod.* 1995;1:57–63.
24. Isaacson RJ, Rebellato J. Two-couple orthodontic appliance systems: torquing arches. *Semin Orthod.* 1995;1:31–36.
25. Rebellato J. Two-couple orthodontic appliance systems: activations in the transverse dimension. *Semin Orthod.* 1995;1:37–43.
26. Rebellato J. Two-couple orthodontic appliance systems: transpalatal arches. *Semin Orthod.* 1995;1:44–54.
27. Dahlquist A, Gebauer U, Ingervall B. The effect of a transpalatal arch for correction of first molar rotation. *Eur J Orthod.* 1996;18:257–267.
28. Ingervall B, Gollner P, Gebauer U, et al. A clinical investigation of the correction of unilateral molar crossbite with a transpalatal arch. *Am J Orthod Dentofacial Orthop.* 1995;107:418–425.
29. Davoody AR, Posada L, Utreja A, et al. A prospective comparative study between differential moments and miniscrews in anchorage control. *Eur J Orthod.* 2013;35:568–576.
30. Hayashi K, DeLong R, Mizoguchi I. Comparison of the finite helical axis and the rectangular coordinate system in representing orthodontic tooth movement. *J Biomech.* 2006;39:2925–2933.



# 10

## Contemporary Orthodontic Appliances

### CHAPTER OUTLINE

#### Removable Appliances

- Development of Active Aligners
- Functional Appliances for Growth Modification
- Clear Aligner Therapy

#### Fixed Appliances

- The Development of Contemporary Fixed Appliances
- Bands for Attachments
- Bonded Attachments
- Characteristics of Contemporary Fixed Appliances
- Temporary Anchorage Devices

Orthodontic appliances have evolved steadily since the development of the specialty, but the pace of change has accelerated significantly in recent years. Technologic advances have brought both changes and some improvements in existing appliance systems (for instance, new brackets and wires for the edgewise appliance) and new ways of correcting malocclusion (such as clear aligners formed on stereolithographic models and temporary skeletal anchorage). The improved technology has greatly increased the productivity of orthodontists. Charles Tweed suggested in the 1950s that an orthodontist should not start treatment for more than 50 patients per year because there would not be enough time to manage more than that and achieve high-quality results. This number has greatly increased since then, but so has average treatment quality—and comprehensive orthodontic treatment that cost about the same as a new car at that time now costs far less.

Although at this point an orthodontist could use one fixed appliance system to treat all of his or her patients, it is better to select among appliance systems to fit the needs of individual patients. Modern removable appliances can do some things better than fixed appliances, and variants within fixed appliance systems do some things better than others. The purpose of this chapter is to provide an overview of modern appliances and put them in perspective in a way that helps in choosing the best appliance for specific situations—a goal that extends into the clinical chapters that follow.

### Removable Appliances

Removable orthodontic appliances have two immediately apparent advantages: (1) They are fabricated in the laboratory and adjusted extraorally rather than directly in the patient's mouth, reducing the dentist's chair time, and (2) they can be removed on socially

sensitive occasions if wires on the facial part of the teeth would be visible, or can be made almost invisible if fabricated from clear plastic materials. This makes them (at least initially) more acceptable to adult patients. In addition, removables allow some types of growth guidance treatment to be carried out more readily than is possible with fixed appliances. These advantages for both the patient and the dentist have ensured a continuing interest in removable appliances for both children and adults.

There are also two significant disadvantages: (1) The response to treatment is heavily dependent on patient compliance, because the appliance can be effective only when the patient chooses to wear it, and (2) it is difficult to obtain the two-point contacts on teeth necessary to produce complex tooth movements, which means that the appliance itself may limit the possibilities for treatment. Because of these limitations, fixed appliances dominate modern treatment.

Modern removable appliance therapy consists largely of the use of:

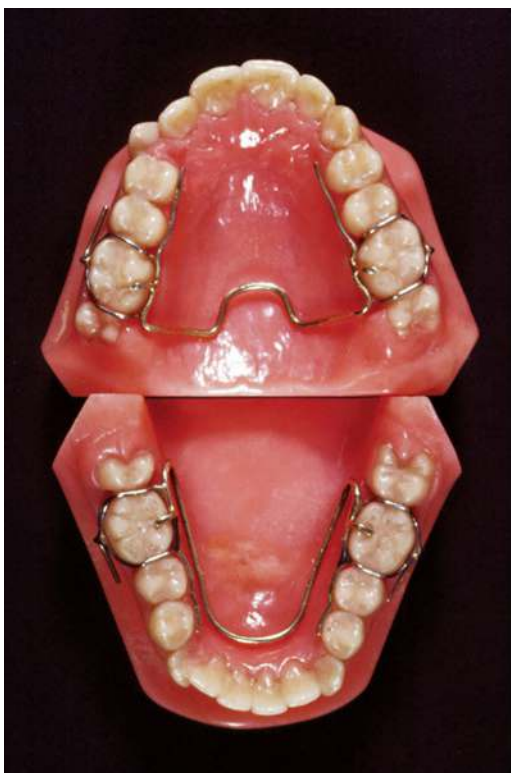
1. Active aligners with springs for tooth movement, used primarily in preadolescents (they have been largely replaced by clear aligners in adult treatment).
2. Various types of functional appliances for growth guidance in adolescents and, less frequently, in children.
3. Clear plastic aligners for tooth movement in adults.

The focus of this part of the chapter, accordingly, is on the characteristics of the appliances used for these purposes.

### Development of Active Aligners

In the United States, the original removable appliances were rather clumsy combinations of vulcanite bases and precious metal or nickel–silver wires. In the early 1900s, George Crozat developed a removable appliance fabricated entirely of precious metal that consisted of an effective clasp for first molar teeth, heavy gold wires as a framework, and lighter gold fingersprings to produce the desired tooth movement (Fig. 10.1). The Crozat appliance attracted a small but devoted following and was still being used in the late 20th century for comprehensive treatment by a few practitioners. Its limitation was that, like almost all removables, it produced mostly tipping of teeth. It had little impact on the mainstream of U.S. orthodontic thought and practice, however, which from the beginning was focused on fixed appliances.

Development of removable appliances for tooth movement continued in Europe despite their neglect in the United States. There were three interesting reasons for this trend: (1) Angle's dogmatic approach to occlusion, with its emphasis on precise positioning of each tooth, had less impact in Europe than in the United States; (2) social welfare systems developed much more rapidly in Europe, which tended to place the emphasis on limited orthodontic treatment for large numbers of people,

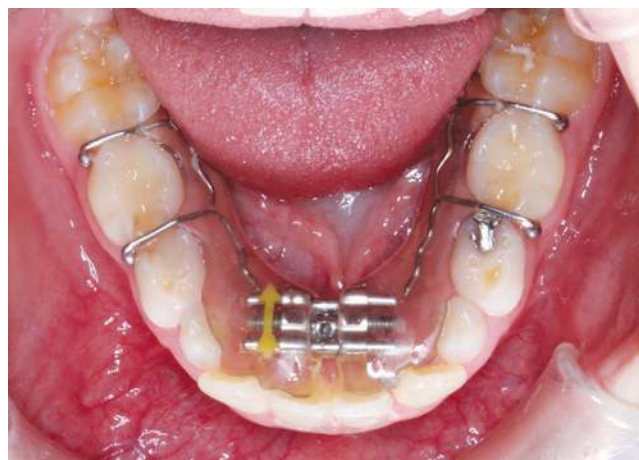

• **Fig. 10.1** Crozat appliances for the upper and lower arch, showing the transverse connectors that allow lateral expansion. The Crozat clasps on the molars use fingers that extend into the mesiobuccal and distobuccal undercuts.

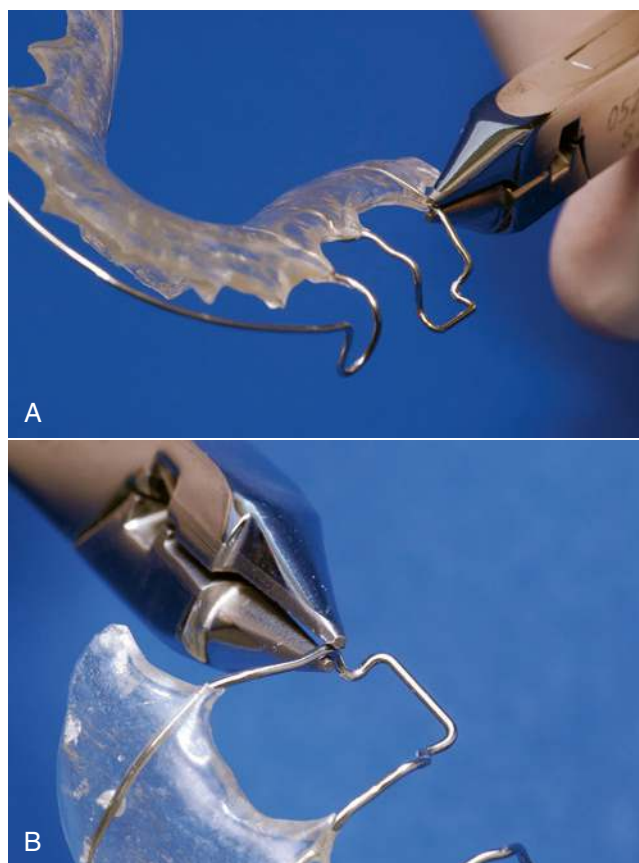
often delivered by general practitioners rather than orthodontic specialists; and (3) precious metal for fixed appliances was less available in Europe, both as a consequence of the social systems and because the use of precious metal in dentistry was banned in Nazi Germany in the early 1930s. This forced German orthodontists to focus on removable appliances that could be made with available materials, primarily acrylic plastics for baseplates and brass (later, stainless steel) wires for springs.

The result was that in the 1925 to 1965 era, U.S. orthodontics was based almost exclusively on the use of fixed appliances (partial or complete banding), whereas fixed appliances were essentially unknown in Europe and all treatment was done with removables. Two European orthodontists deserve special mention for their contributions to removable appliance techniques for moving teeth. Martin Schwarz in Vienna developed and publicized a variety of “split plate” appliances, which were effective for expanding the dental arches (Fig. 10.2). Philip Adams in Belfast modified the arrowhead clasp favored by Schwarz into the Adams crib (Fig. 10.3), which is still the most effective clasp to keep a removable appliance in position when springs are used to move teeth.

Tooth movement with removable appliances in children almost always falls into one of two major categories: (1) arch expansion, in which groups of teeth are moved to expand the arch perimeter, and (2) repositioning of individual teeth within the arch.



• **Fig. 10.2** A removable appliance of the “Schwarz plate” type used a jackscrew to separate the parts of the acrylic plate and expand the dental arch. They were used in the maxillary or mandibular dental arch—this one was designed to expand across the lower incisors to provide more space for the crowded teeth. The force system created by turning a screw is far from ideal, and plates of this type are now obsolete, but they can create small amounts of tooth movement.



• **Fig. 10.3** Clinical adjustments of an Adams clasp. (A) Tightening the clasp by bending it gingivally at the point where the wire emerges from the baseplate. This is the usual adjustment for a clasp that has become loose after repeated insertions and removals of an appliance. (B) Adjustment of the clasp by bending the retentive points inward. This alternative method of tightening a clasp is particularly useful during the initial fitting of an appliance. This bend also can be made with the plier positioned slightly closer to the appliance body.

### Active Plates for Arch Expansion

The framework of an active plate is a baseplate that serves as a base in which screws or springs are embedded and to which clasps are attached. The active element sometimes is a jackscrew placed so that it holds the parts of the plate together (see Fig. 10.2). Opening the screw with a key then separates the sections of the plate. The screw offers the advantage that the amount of movement can be controlled, and the baseplate remains rigid despite being cut into two parts. The disadvantage is that the force system is very different from the ideal one for moving teeth. Rather than providing a light but continuous force, activation of the screw produces a heavy force that decays rapidly. This is acceptable for arch expansion if the activation is slow, but not for moving individual teeth. Activating the screw too rapidly results in the appliance being progressively displaced away from the teeth rather than the arch being expanded as desired.

### Removable Acrylic Appliances With Springs for Tooth Movement

In contrast to the heavy, rapidly decaying forces produced by a screw, nearly optimum light continuous forces can be produced by springs in a removable appliance. Like the edges of an active plate, however, these springs contact the tooth surface at only one point, and it is difficult to use them for anything but tipping tooth movements. The guideline for tooth movement with a spring from a removable appliance therefore is that this approach should be used only when a few millimeters of tipping movement are acceptable.

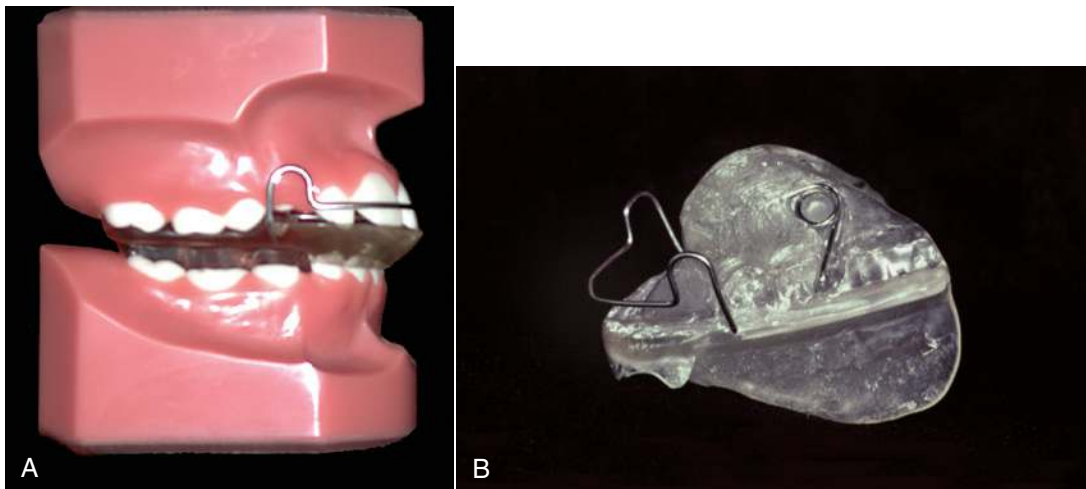
Because these appliances are used primarily for minor tooth movement in children, they are discussed in more detail in Chapters 11 and 12.

## Functional Appliances for Growth Modification

By definition, a functional appliance is one that changes the posture of the mandible, holding it open or open and forward. Pressures created by stretch of the muscles and soft tissues are transmitted to the dental and skeletal structures, moving teeth and modifying growth. The monobloc developed by Robin in the early 1900s is generally considered the forerunner of all functional appliances, but the activator developed in Norway by Andresen in the 1920s (Fig. 10.4) was the first to be widely accepted.

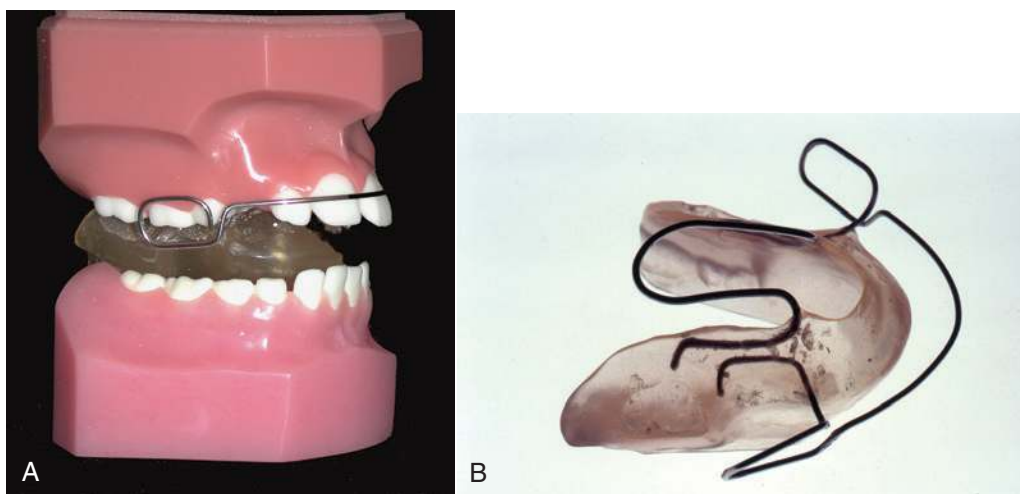
Andresen's activator became the basis of the "Norwegian system" of treatment. Both the appliance system and its theoretical underpinnings were improved and extended elsewhere in Europe, particularly by the German school led by Haupl, who believed that the only stable tooth movement was produced by natural forces and that alterations in function produced by these appliances would give stable corrections of malocclusion. This philosophic approach was diametrically opposite to that espoused by Angle and his followers in the United States, who emphasized fixed appliances to precisely position the teeth and presumed that if they were in ideal occlusion, that would keep them there. These opposing beliefs contributed to the great differences between European and U.S. orthodontics at mid-20th century.

Functional appliances were introduced into U.S. orthodontics in the 1960s through the influence of orthodontic faculty members with a background in Europe (of whom Egil Harvold was prominent) and later from personal contact by U.S. orthodontists with their European counterparts. (Fixed appliances spread to Europe at the same time through similar personal contacts.) A major boost to functional appliance treatment in the United States came from the publication of animal experiment results in the 1970s showing that skeletal changes really could be produced by posturing the



• **Fig. 10.4** (A) The activator, a tooth-borne passive appliance, was the first widely used functional appliance. It opens the bite, and the mandible is advanced for Class II correction as the patient is forced to move it forward to avoid contact of the lingual flanges with the lingual soft tissues. (B) The design of the original Andresen activator reflects the concept that stimulating activity of the jaw muscles was the key to altering mandibular growth; the large spring in the palate is to keep the appliance from staying in place except when the patient is biting against it. Whenever the patient relaxes, the appliance drops down and the patient has to bite against it, so the muscles are activated repeatedly while it is being worn. As that concept disappeared, so did the displacement springs (which often were replaced with clasps to help hold the activator in position), but complete coverage of the palate continued.





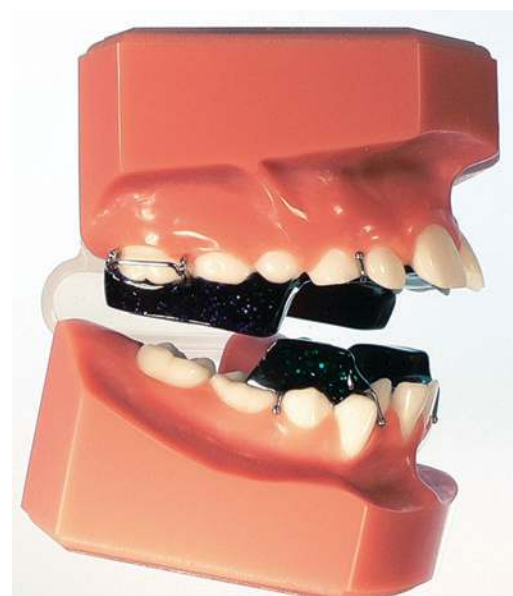• **Fig. 10.5** (A) The Bionator design, which removes much of the bulk of the activator and is more comfortable for the patient to wear, also uses lingual flanges to force the patient to hold the mandible forward. (B) It can include posterior facets or acrylic occlusal stops to control the amount or direction of tooth eruption and still is used occasionally, although it has largely been displaced by the twin block appliance or other more modern removable functional appliances.

mandible to a new position and holding out the possibility that true stimulation of mandibular growth could be achieved (see Chapter 14).

Some of the enthusiasm for functional appliance treatment resulting from the favorable animal experiments has faded in the light of less impressive results from clinical trials and retrospective clinical studies, but functional appliances have achieved a major place in contemporary growth modification treatment. In modern use, primarily because the patient has no choice but to wear them full-time, fixed functional appliances now are more widely used than the removable alternatives. These include the Herbst appliance, which became quite popular after Pancherz documented in the 1970s that it could be quite effective,<sup>1</sup> and variants introduced more recently. They are grouped here with the removable functionals because they are quite different from traditional fixed appliances but have much in common with the removables. Both fixed and removable functionals are fabricated from identical construction bites. This advances the mandible in patients with Class II malocclusion and rotates it downward in those with Class III malocclusion. In addition, vertical stops or bite blocks are used to control the vertical dimension in both.

Functional appliances are understood best when viewed as falling into one of four broad categories:

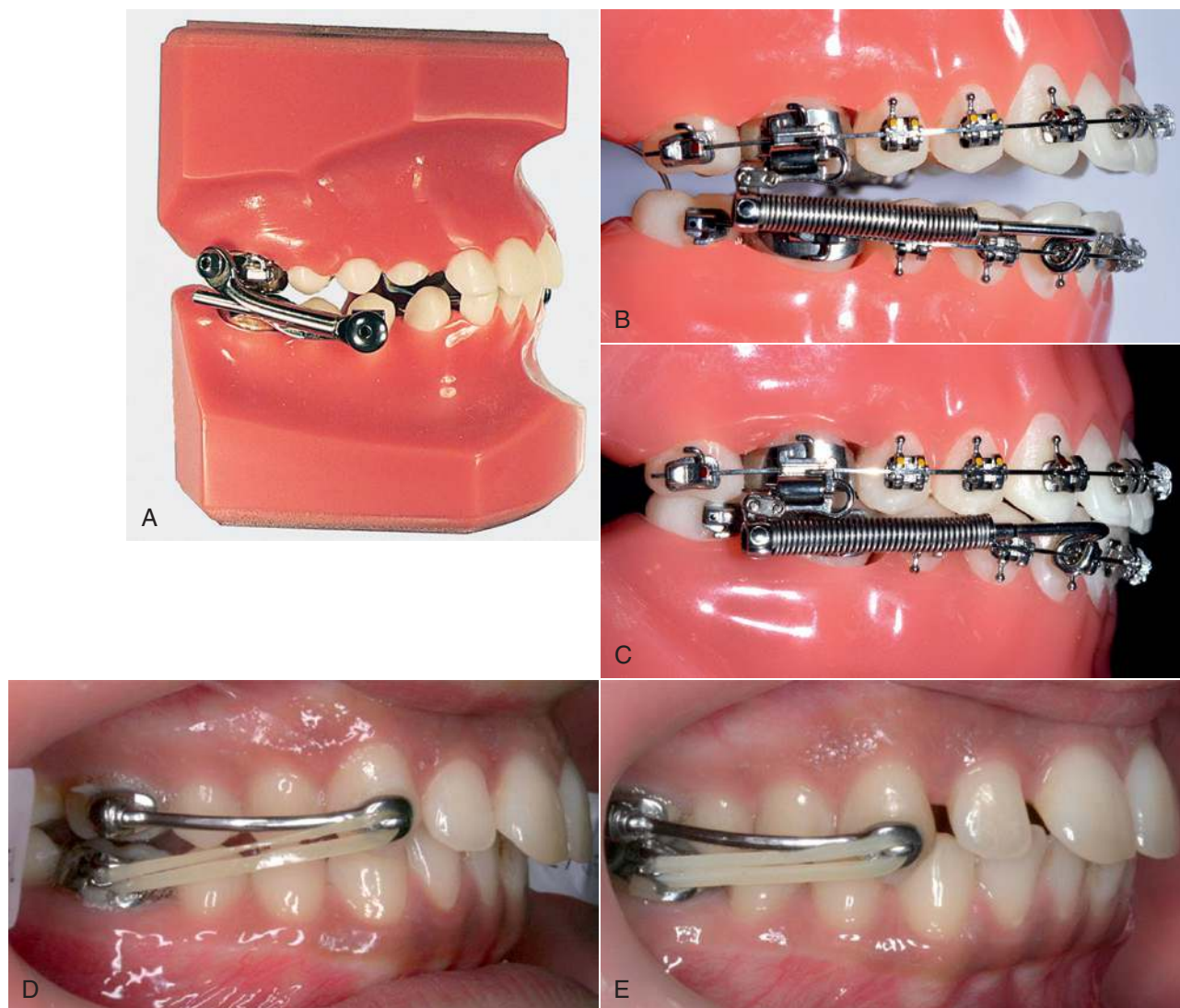
- **Passive tooth-borne.** These appliances have no intrinsic force-generating capacity from springs or screws and depend only on soft tissue stretch and muscular activity to produce treatment effects. In current use, the Bionator (Fig. 10.5), twin block (Fig. 10.6), and Herbst appliance (Fig. 10.7A) are examples of passive tooth-borne appliances. The Bionator is always removable, the twin block usually is removable but can be fixed, and the Herbst appliance usually is fixed but can be constructed to be removable.
- **Active tooth-borne.** In removable form, these are largely modifications of activator and Bionator designs that include expansion screws or springs to move teeth. Some current fixed functionals have evolved in this same direction in that, like their removable predecessors, they produce tooth movement that often replaces



• **Fig. 10.6** The twin-block appliance consists of individual maxillary and mandibular plates with ramps that guide the mandible forward when the patient closes down. The maxillary plate incorporates tubes for attachment of a headgear and often includes an expansion screw to increase posterior arch width. (Courtesy AOA Laboratories, Sturtevant, WI.)

jaw growth modification with camouflage tooth movement. For that reason, although removables of this type were once the mainstay of European orthodontics, they now are rarely used. It seems likely that fixed functionals with active springs will have the same fate.

- **Tissue-borne.** The Frankel appliance (which Frankel called the *function regulator*) is the only tissue-borne functional appliance (Fig. 10.8). Insofar as possible, contact of the appliance with the teeth is avoided, reflecting the goal of inducing tooth



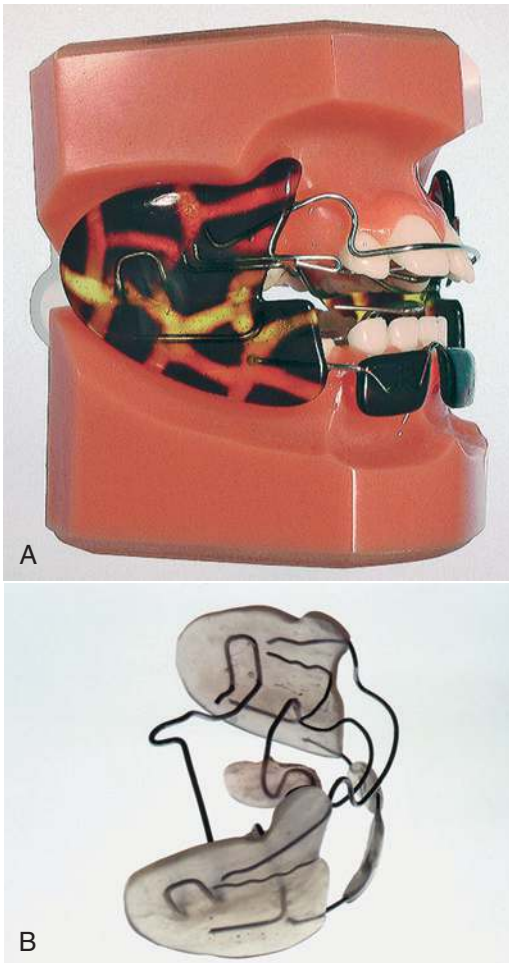
• **Fig. 10.7** (A) The Herbst appliance, introduced by Herbst in the 1920s, was the original fixed functional appliance, but it was not widely used until it was reintroduced in the 1970s. It uses a pin and tube apparatus to hold the mandible in an advanced position and is quite compatible with the presence of a fixed appliance on anterior teeth (but also can be used with bonded or removable splints). Note that for this patient the pin and tube attaches to steel crowns on the molars, which are sturdier than molar bands, and the extensions forward from the lower crowns are bonded to the lower premolars. In current use, there are many variations in the precise design of the appliance. (B) and (C) The Forsus appliance, offered as a modern alternative to the Herbst appliance, uses springs to maintain the mandible (and mandibular teeth) forward; the reaction is a distal force on the maxilla. In theory, the effect would be similar to that of the Herbst appliance; in fact, studies have shown that it has a greater skeletal effect on maxillary growth than the Herbst and produces more forward movement of the mandibular dentition but less skeletal mandibular advancement. (D) The Carriere motion appliance similarly creates a distal force against the maxilla while pushing the mandible forward so that (E) the molar relationship is corrected. Then the maxillary incisors are retracted. It has the advantage of minimal restriction of lateral excursions of the mandible. In theory, it also is creating forces similar to the Herbst appliance that would create similar effects; in its case, no data beyond selected case reports are available to show what it really does skeletally and dentally. The same can be said of a number of other currently advertised appliances to correct Class II malocclusion. (D and E, courtesy Henry Schein Co., Carlsbad, CA.)

movement from soft tissue pressures rather than physically moving the teeth. Much of the appliance is located in the vestibule, holding the lips and cheeks away from the dentition. This makes it an arch expansion appliance in addition to its effects on jaw growth because the arches tend to expand when lip and cheek pressure is removed.

- *Hybrid.* Hybrid functionals are composed of components that are common to functional appliances but are combined to meet a specific need, and are used primarily in the treatment of jaw asymmetry (Fig. 10.9).

The components of functional appliances are shown in Table 10.1. They can be combined as needed for individual patients.





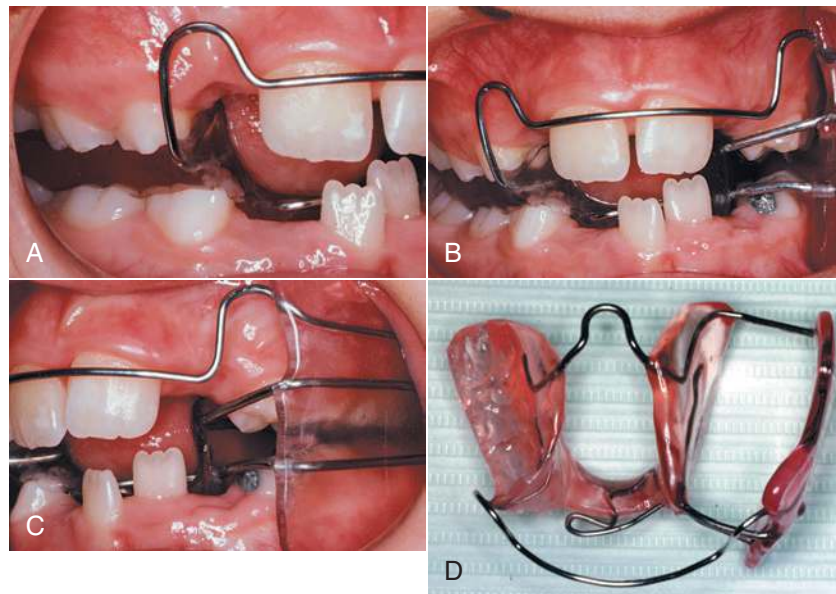
Functional appliances are used primarily in late preadolescent children and during the adolescent growth spurt. They are discussed in more detail in [Chapter 14](#).

## Clear Aligner Therapy

### Development of Clear Aligners

The use of a sequence of clear aligners in orthodontic treatment for adults became possible as vacuum-formed clear thermoplastic sheets were introduced into orthodontics in the 1980s. These “suck-down” materials were used initially as retainers and still are important for this purpose (see [Chapter 18](#)). It became apparent rather quickly, however, that if teeth were reset slightly and the vacuum-formed sheet was made to fit the reset teeth, a tooth moving device rather than a retainer would be the result.<sup>2</sup> The

• **Fig. 10.8** (A) The Frankel appliance on dental casts and (B) as it would look before being placed in the mouth. It is the only functional appliance that is primarily tissue-borne rather than tooth-borne, and is the expression of the German theory that the only stable tooth movement was produced by changing the soft tissue environment of the jaws. It was offered in Class II, Class III, and open bite versions, but its primary use was Class II treatment with the Frankel-II design shown here. Its active components are the large buccal shields and lip pads that reduce cheek and lip pressure on the dentition and provide the expansion of the maxillary arch that usually is needed as part of Class II correction; the small lower lingual pad behind the lower incisors that holds the mandible forward, and the facial pad in front of the lower incisors that holds the lower lip forward. The appliance looks bulky, but for the most part, it is restricted to the buccal vestibule, and therefore it interferes less with speech and is more compatible with 24-hour wear than other removable functional designs. (Courtesy AOA Laboratories, Sturtevant, WI.)



• **Fig. 10.9** A hybrid functional appliance consists of the components of one type of functional on one side and components of another type on the other. For a child with a facial asymmetry, an appliance of the type shown here can be effective in improving both the vertical and anteroposterior aspects of the problem. Note that (A) a bite block blocks eruption of teeth on the left side, while (B and C) the teeth are free to erupt on the left side, where (D) a lingual, as well as a buccal, side is required to keep the patient's tongue out of the space where eruption is required. The bite is taken to bring the jaw to the midline, advancing the deficient side (here, the left) more than the other. (From Proffit WR, White RP, Sarver DM. *Contemporary Treatment of Dentofacial Deformity*. St. Louis: Mosby; 2003.)



**TABLE 10.1** Functional Appliance Components

Component	Comment
<b>Functional Components</b>	
Lingual flanges	Contact with mucosa; most effective
Lingual pad	Contact with mucosa; less effective
Sliding pin and tube	Contact with teeth; variable tooth displacement
Tooth-supported ramps	Contact with teeth; tooth displacement likely
Lip pads	Secondary effect only on mandibular position
<b>Tooth-Controlling Components</b>	
<b>Arch Expansion</b>	
Buccal shields	Passive, effective
Buccinator bow, other wire shield	Passive, less effective
Expansion screws and/or springs	Must activate slowly; questionable stability
<b>Vertical Control</b>	
Occlusal or incisal stops	Prevent eruption in discrete area
Bite blocks	Prevent eruption of all posterior teeth
Lingual shield	Facilitate eruption
<b>Stabilizing Components</b>	
Clasps	No effect on growth modification
Labial bow	Keep away from incisors, lingual tipping undesirable
Anterior torquing springs	Needed to control lingual tipping, especially with headgear-activator combination

device now could be, and quickly was, called a “clear aligner” because the typical use was to bring mildly displaced teeth back into alignment, as, for instance, when mild irregularity of maxillary or mandibular incisors occurred in an orthodontic patient after retainers were discontinued.

Only small amounts of tooth movement are possible with a single aligner, however, because of the stiffness of the plastic material. It became clear that a sequence of several aligners, made on a series of casts with some teeth reset in small increments (not more than 1 mm), would be needed to correct even mild malalignment. Although a sequence of modified dental casts can be produced by hand and a short sequence of two to five aligners made from these casts works for minor tooth movement, this is prohibitively time-consuming and difficult if more than a few aligners are required.

In the late 1990s, a new company, Align Technology, obtained venture capital to computerize the process of producing a sequence of casts with incremental changes on which aligners could be fabricated. With careful planning, this would result in a sequence of aligners that could correct more complex problems. Because growth changes could not be predicted, the method would be useful primarily for treatment of adults or late adolescents, but

these are the patients most interested in an invisible or minimally visible orthodontic appliance.

The early days of Invisalign treatment were fraught with problems because staging of treatment, optimal rates of tooth movement, and indications for use of attachments on the teeth had not been worked out, and initial professional acceptance of the method was spotty. The technique has matured, however, as clinical evaluation has clarified the best sequence of steps in treatment and the amount of tooth movement in steps that should be attempted, and as the use of tooth-colored shapes bonded to the teeth has improved the appliance’s grip on the teeth and ability to move them. It is clear now that even complex malocclusions can be successfully treated in this way.<sup>3</sup> Now that patents are expiring or are challenged successfully, competitive companies are offering sequenced aligners based on modifications of the current techniques, and orthodontists are beginning to use digital models on their own computers and three-dimensional (3-D) printing in their own labs to produce clear aligners.<sup>4</sup>

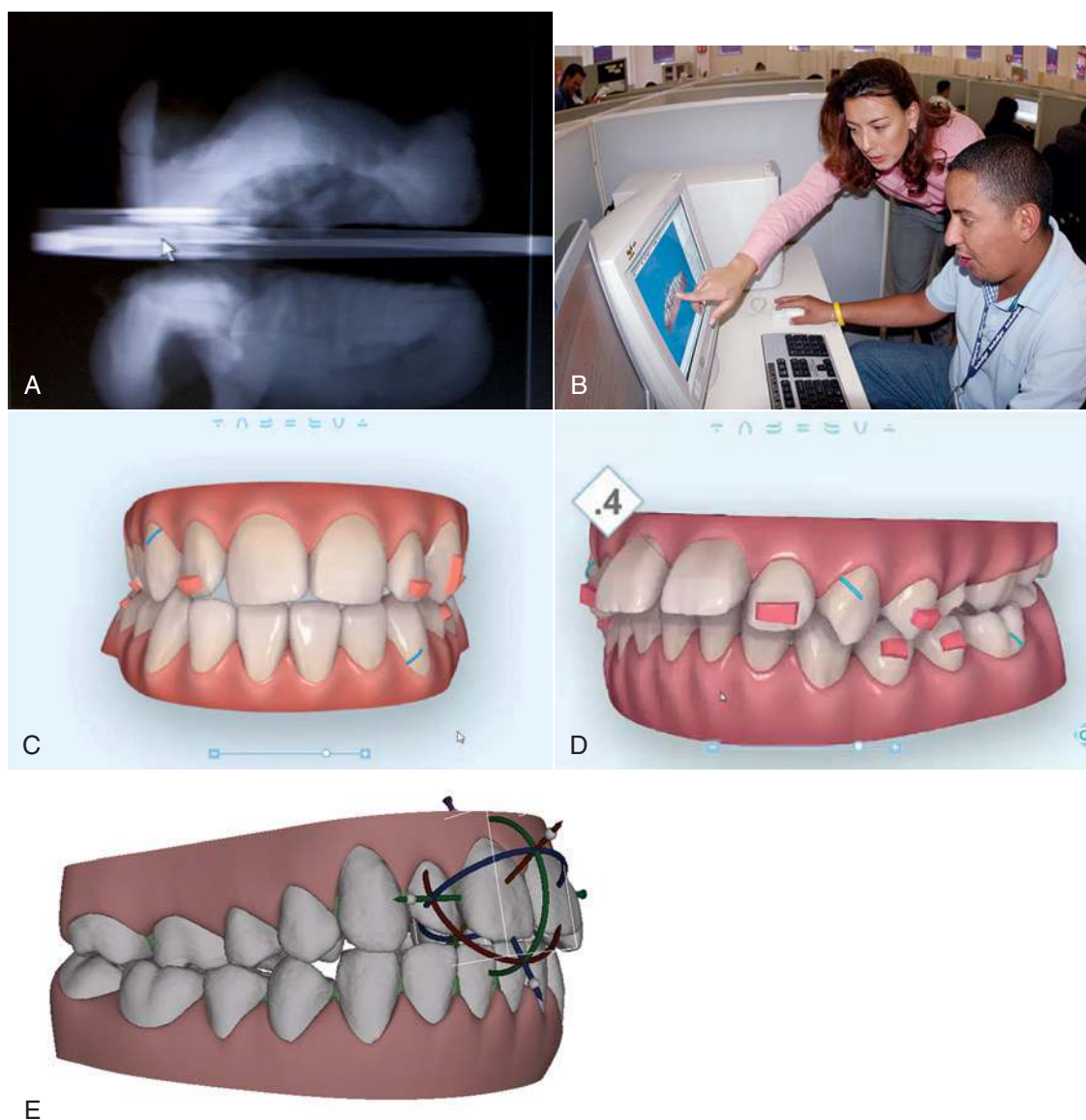
### *Invisalign Production Process*

**Steps in Preparing the Aligners.** Diagnostic records for aligner treatment are the same photographs, radiographs, and dental casts as for any other type of orthodontic treatment. For Invisalign sequenced aligners, either an intraoral optical scan (which also records the initial occlusion) or siloxane impressions and a bite registration (maximum intercuspation) are obtained. The scan or impressions, photographs, and radiographs are submitted to the company along with the doctor’s initial instructions. The production process begins when the intraoral scan or impressions are used to create an accurate 3-D digital model of each dental arch (Fig. 10.10). These records are transferred electronically to a digital treatment facility (presently in Costa Rica).

At the digital treatment facility, technicians virtually segment the individual teeth and clean up obvious artifacts. Then the dental arches are related to each other, gingiva is added, movement is staged following the doctor’s instructions, and this preliminary plan is placed online for the doctor’s review as a “ClinCheck.” After the doctor is satisfied with the planned sequence of aligners, the set of digital models for a patient is transferred to a cast production facility, where a stereolithographic model for each step is fabricated (Fig. 10.11). A clear plastic aligner is formed over each model, using a recently developed proprietary material that has much improved physical properties (see Chapter 9), and the set of aligners is sent directly to the doctor.

There is increasing interest now in the possibility of doing aligner production in the doctor’s own office, using computer software to create the sequence of models, a 3-D printer to make the models for each stage, and a vacuum-forming unit to make the aligners (Fig. 10.12). At this point the available software is much less advanced than Invisalign’s, printing the models for each stage is time-consuming, and the improved aligner material is not available—but for simpler cases this already is quite feasible and much less expensive. Will this become a common procedure in the future? That remains unknown at present.

**Clinician’s Role in ClinCheck.** With experience, doctors tend to be more specific in their initial prescription of what they want, or do all the sequencing of steps themselves to set things up for a better result, but the sequence of steps and the amount of movement between steps is specified by algorithms built into the Treat software if this is not spelled out in detail in the prescription. In essence, when the ClinCheck is posted for the doctor to examine, the computer technician has sent a draft treatment plan for review.



• **Fig. 10.10** (A) The first step in the production of a series of aligners using Invisalign's computer technology is submission of a three-dimensionally accurate digital image of the patient's dentition to a technology facility consisting entirely of computer workstations and technicians. The image can be obtained from a direct scan of the patient's dentition, or from a scan of dental casts. (B) In this view, the seated technician is conferring with one of the orthodontic advisors as the digital dental arches are displayed on the computer screen. (C) On the computer screen, attachments to be bonded to the teeth can be positioned as desired, and areas of special modification of the aligners are marked, shown here as blue stripes on the canines where power ridges will be placed to assist in correction of the dental midlines. (D) Lateral view of the same case. The images on the screen can be rotated as desired. (E) The teeth are repositioned in a sequence of steps, here moving the maxillary anterior teeth to the left and the mandibular anterior teeth to the right for midline correction, before repositioning them in further steps to gain the desired dental occlusion.

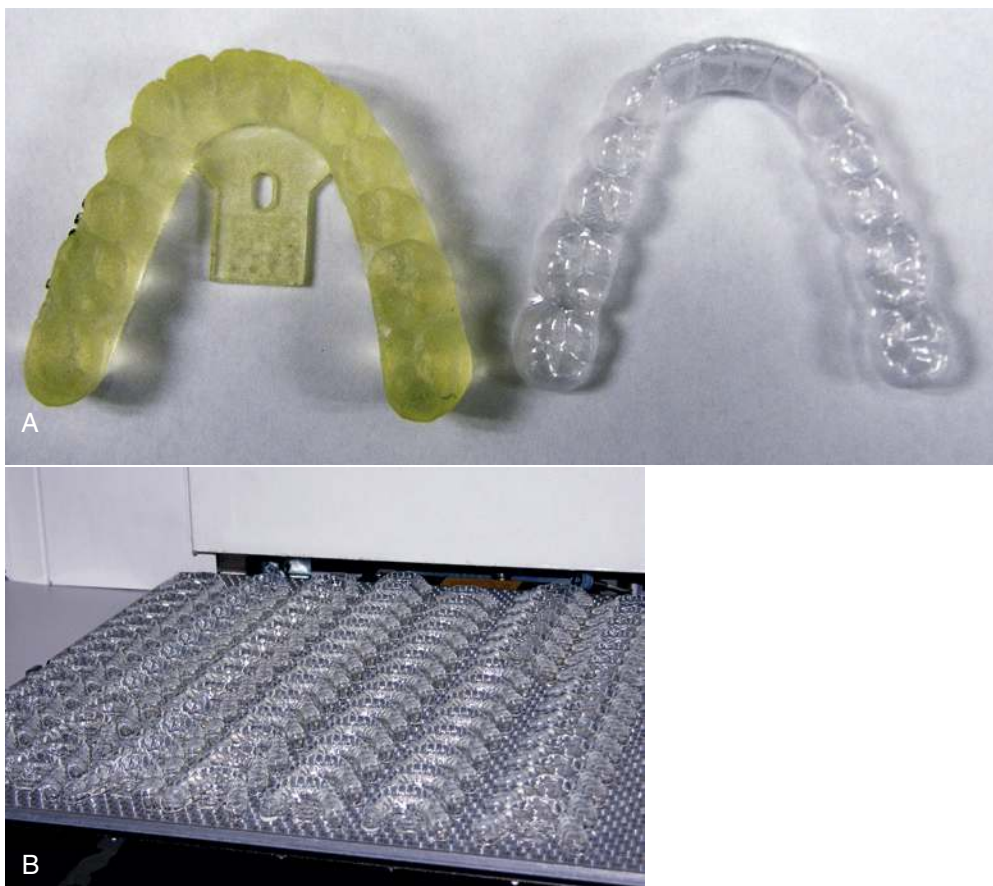
The software used by the computer technicians has default scenarios for different types of malocclusions and default rates of tooth movement. These defaults are satisfactory for simpler cases but not for the more complex ones.

For complex treatment, the doctor must customize the plan in terms of the extent to which bonded attachments are to be used to increase the aligner's grip on the teeth, the rate of tooth movement with each subsequent aligner (often reducing the amount of movement at critical points), any special components

of aligners that need to be added, and the amount and location of interproximal reduction of teeth (if any) that is to be done. These modifications to the original ClinCheck then are used to produce the aligners for that patient.

### Current Considerations in Clinical Use of Clear Aligners

It is clear now that Invisalign (and clear aligners more generally) can perform well for many but not all malocclusions ([Box 10.1](#)), and that fixed appliances tend to provide more improvement in



• **Fig. 10.11** After the sequence of treatment steps has been adjusted as desired and approved by the doctor, who can access the digital models electronically after the preliminary treatment sequence has been put together, the models are used to fabricate a sequence of stereolithographic (SL) casts and a sequence of aligners are formed over the casts. (A) An SL cast and the aligner formed from it. (B) SL casts emerging from the production machine, in which hundreds of aligners can be produced in a single cycle.

complex cases.<sup>3</sup> As the box indicates, some things that aligners now can do require bonded attachments to the teeth and modifications built into the aligners.

The limitations should be kept in mind when clear aligner treatment is considered. Several other considerations in the use of sequential aligners are as follows:

- There is an increasing trend toward a combination approach to complex treatment, using a short phase of partial fixed appliances or auxiliaries in addition to the sequence of aligners. The use of attachments bonded to selected teeth greatly extends the possible tooth movement with aligners, but even with attachments, significant torque and correction of molar relationships is difficult. New adjuncts to aligners (Fig. 10.13) now are being offered to improve performance in these areas. One of the innovations is an aligner with bite blocks between the posterior teeth to close open bites by intruding these teeth instead of elongating the incisors—but elongation of the incisors can occur with aligners of this type (Fig. 10.14).
- Interproximal enamel reduction (IPR) to obtain space for aligning crowded teeth often is part of the treatment plan. If IPR is planned, removal of interproximal enamel in the canine and premolar region to provide space can be used in addition to reduction in the width of incisors. The amount of interproximal reduction is an important part of the doctor's prescription (Fig. 10.15).

#### • BOX 10.1 Clear Aligner Therapy (CAT) Applicability

##### CAT Performs Well

- Mild-to-moderate crowding
  - With arch expansion
  - With interproximal reduction (IPR)
- Posterior dental expansion
- Close mild-to-moderate spacing
- Intrusion of incisors (one or two tooth segments)
- Lower incisor extraction for severe crowding
- Tip molar distally

##### Requires Bonded Attachments

- Extrusion of incisors
- Incisor or canine rotation correction
- Translation of molars


##### Requires Attachments and Modified Aligners

- Premolar extraction space closure
- Molar relationship correction
- Deep bite correction
- Open bite correction (?)

##### CAT Does Not Perform Well

- Prolonged treatment in children
- High canines
- Severe rotations (especially rounded teeth)





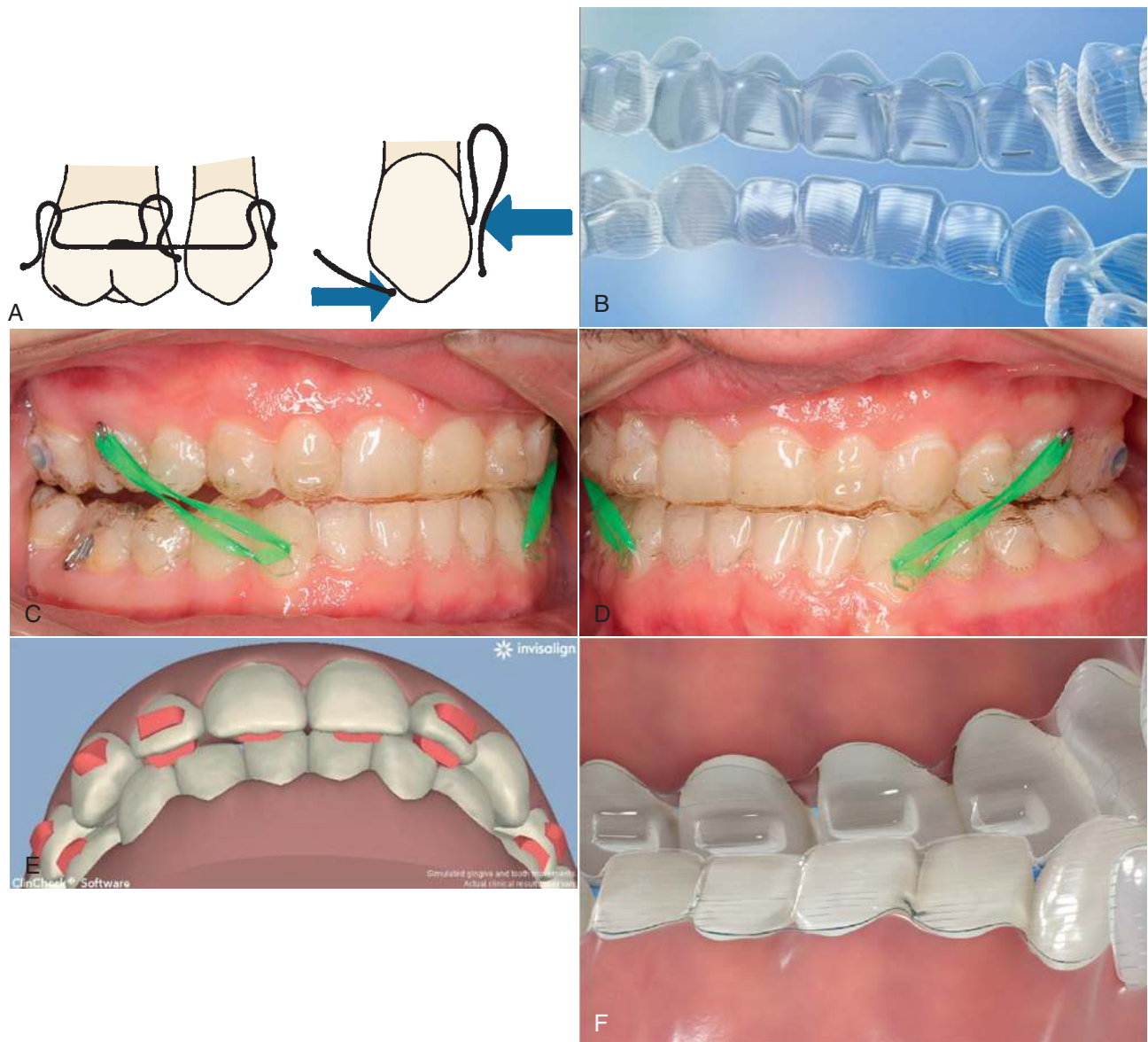
• **Fig. 10.12** In-office production of aligners requires a program to run on the office computer that allows repositioning of virtual teeth (available but not yet well developed) and (A) an in-office 3-D printer that can make (B) a set of accurate models with sequential changes. The printer in this private office (in late 2017) can print six models at a time. (C) The vertical height of the tallest model determines the print time with this type of printer, which is about 25 minutes. (D) Then a vacuum-forming device is used to produce the six aligners—so it would be possible to provide same day delivery. (Courtesy Dr. W. Gierie.)

- Patients must be monitored carefully to verify that tooth movement is tracking with the series of aligners (i.e., that all teeth are seated completely in the aligner after it has been worn for the specified period of time). If the teeth are not tracking, there are several possibilities: not enough wear of the aligners by the patient, insufficient interproximal reduction, insufficient crown height or shape to allow a grip on the tooth or teeth to be moved, wrong type or position of bonded attachments, or movement created in ClinCheck that is too fast to be biologically possible. A refinement or midcourse correction, with a new intraoral scan or polyvinyl siloxane (PVS) impressions and revision of the treatment plan, often is necessary when tracking deviates significantly from the plan. This is likely to be

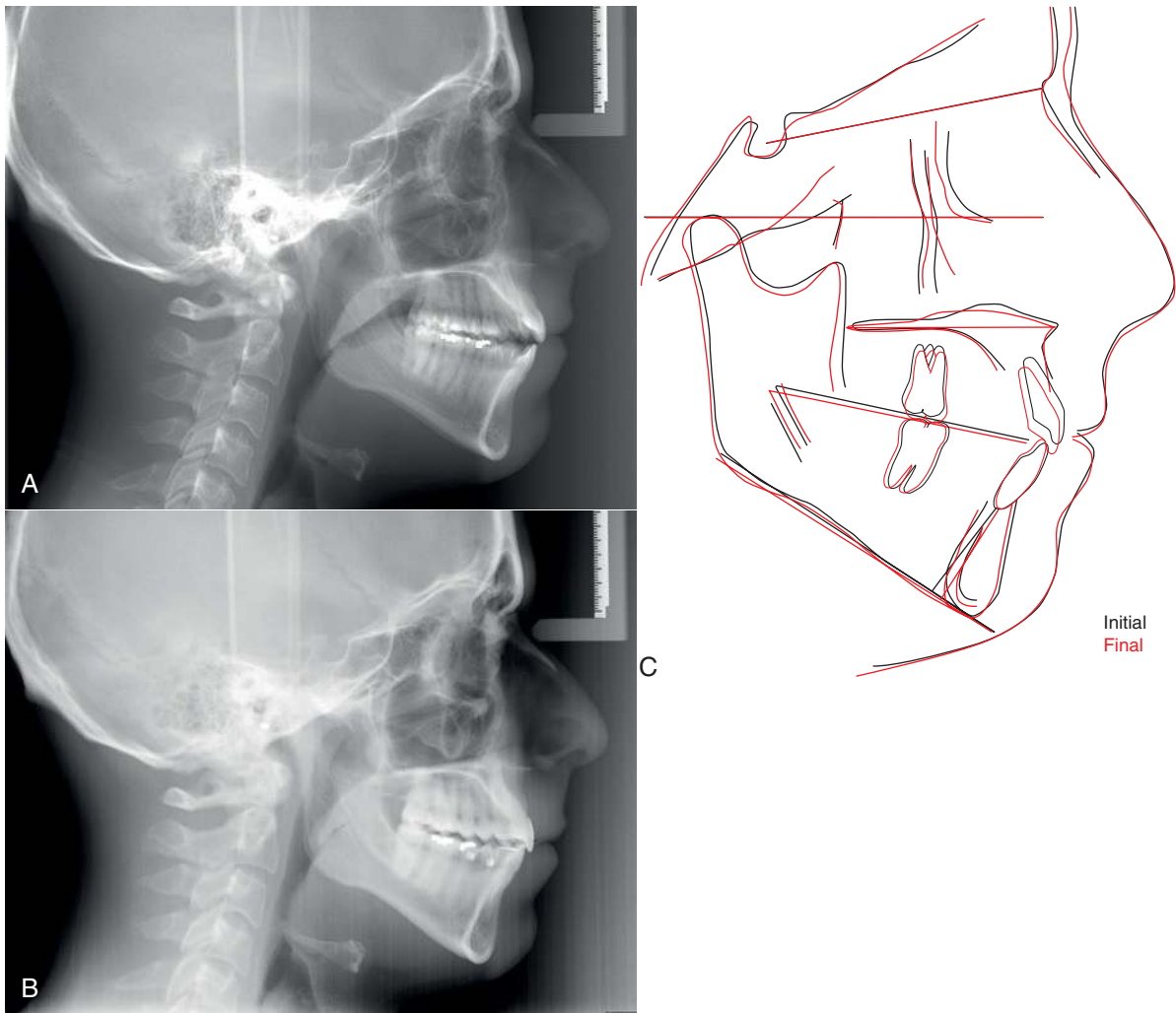
encountered in the treatment of complex problems even with good patient cooperation.

- Aligners cover the teeth like a bleaching tray, and they can be used to bleach during treatment (unless the patient has bonded attachments on the anterior teeth). If this is done, it is important to remember that tooth movement causes transient pulpitis and so does bleaching. The combination of the two procedures can lead to significant tooth sensitivity. This can be controlled by increasing the intervals between bleaching sessions, but bleaching usually is better deferred until the retention stage.

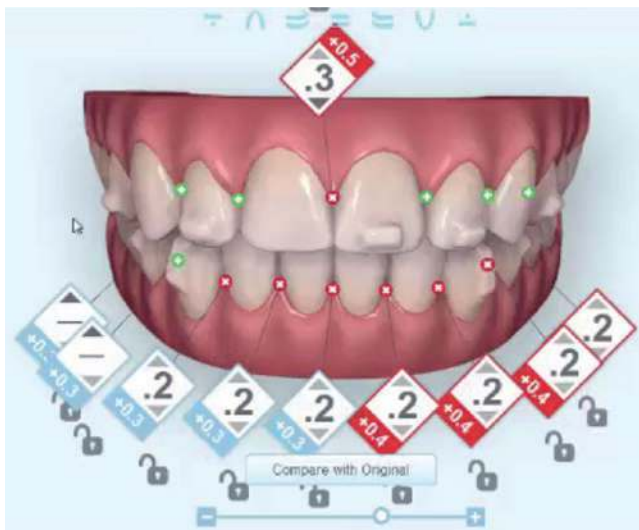The clinical use of clear aligners in adjunctive and comprehensive treatment is discussed in greater detail in [Chapters 19](#).



• **Fig. 10.13** New features in Invisalign. (A) Two-point contact on the crown of a tooth is required to obtain a moment to parallel roots when closing an extraction site, or to torque roots lingually or facially. As shown here, this was possible (although difficult) with traditional removable appliances, using a pair of springs to create a net moment. For example, for bodily retraction of a canine with a removable appliance, the spring on the mesial aspect of the canine generates a larger moment than the distal spring, leaving a net force to move the canine distally, and the couple necessary for control of root position is created by the opposing action of the two springs. (B) With clear aligners, the same principle is used: power ridges (thickened ridges in a modified aligner) are used to create a larger lingual moment on the upper facial surface of an incisor and a smaller labial moment near the incisal edge when lingual root torque is desired. This creates a net moment to move the tooth root more than the crown. Root paralleling with aligners could be created similarly with power ridges arranged like the springs in (A). (C) and (D) Class II or Class III elastics from lower to upper trays now can be used with specially designed hooks incorporated into the aligners. (E) Bite ramps to disclude posterior teeth can prevent transient posterior intrusion as arches are leveled and (F) can be automatically varied within an aligner sequence to maintain anterior contact during treatment. (Courtesy Dr. W. Gierie.)



• **Fig. 10.14** Bite blocks between posterior teeth can be incorporated into aligners to facilitate closure of anterior open bite by posterior intrusion, but historically bite blocks have not been effective in doing this, and much of the bite closure is likely to be incisor elongation—as it was in this patient whose open bite was closed successfully. (A) Pretreatment lateral cephalometric radiograph; (B) posttreatment cephalometric radiograph; (C) cranial base superimposition. (Courtesy Drs. S. Chamberland and L. Dorval.)



• **Fig. 10.15** The Invisalign ClinCheck form now includes the planned interproximal reduction and the stage at which it is to be done, as well as the steps in tooth movement. (Courtesy Dr. W. Gierie.)

## Fixed Appliances

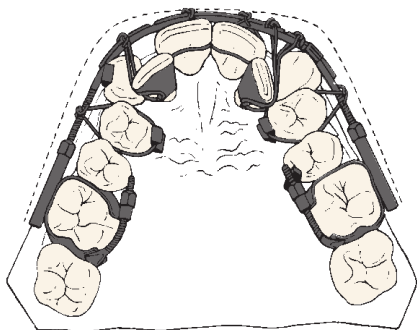
Contemporary fixed appliances are almost totally variations of the edgewise appliance system, using rectangular archwires for precise positioning of the teeth after initial treatment with round wires. The Begg appliance, which used only round wires and auxiliary springs, morphed into the Tip-Edge appliance in the early 21st century so that rectangular wires could easily be used in finishing. Although Tip-Edge treatment stages are shown in [Chapters 16](#) and [17](#), the focus in this and the succeeding chapters is almost entirely on the contemporary edgewise appliance, which continues to evolve as computer-assisted design and manufacturing take over.

## The Development of Contemporary Fixed Appliances

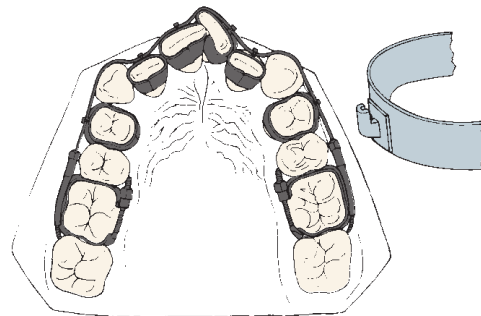
### Angle's Progression to the Edgewise Appliance

Edward Angle's position as the “father of modern orthodontics” is based not only on his contributions to classification and diagnosis but also on his creativity in developing new orthodontic appliances.





• **Fig. 10.16** Edward Angle's E-arch from the early 1900s. Ligatures from a heavy labial arch were used to bring malposed teeth to the line of occlusion.



• **Fig. 10.17** Angle's ribbon arch appliance, introduced about 1910, was well adapted to bring teeth into alignment but was too flexible to allow precise positioning of roots.

With few exceptions, the fixed appliances used in contemporary orthodontics are based on Angle's designs from the early 20th century. Angle developed four major appliance systems:

- **E-arch.** In the late 1800s, a typical orthodontic appliance depended on some sort of rigid framework to which the teeth were tied so that they could be expanded to the arch form dictated by the appliance. Angle's first appliance, the E-arch, was an improvement on this basic design (Fig. 10.16). Bands were placed on molar teeth, and a heavy labial archwire extended around the arch. The end of the wire was threaded, and a small nut placed on the threaded portion of the arch allowed the archwire to be advanced so that the arch perimeter increased. Individual teeth were simply ligated to this expansion arch. This appliance still could be found in the catalogs of some mail-order orthodontic laboratories as late as the 1980s, perhaps because of its simplicity, and despite the fact that it can deliver only heavy interrupted force.
- **Pin and tube.** The E-arch was capable only of tipping teeth to a new position. It was not able to precisely position any individual tooth. To overcome this difficulty, Angle began placing bands on other teeth and used a vertical tube on each tooth into which a soldered pin from a smaller archwire was placed. With this appliance, tooth movement was accomplished by repositioning the individual pins at each appointment.

An incredible degree of craftsmanship was involved in constructing and adjusting this pin and tube appliance, and although it was theoretically capable of great precision in tooth movement, it proved impractical in clinical use. It is said that only Angle himself and one of his students ever mastered the appliance. The relatively heavy base arch meant that spring qualities were poor, and the problem therefore was compounded because many small adjustments were needed.

- **Ribbon arch.** Angle's next appliance modified the tube on each tooth to provide a vertically positioned rectangular slot behind the tube. A ribbon archwire of 10 × 20 gold wire was placed into the vertical slot and held with pins (Fig. 10.17). The ribbon arch was an immediate success, primarily because the archwire, unlike any of its predecessors, was small enough to have good spring qualities and therefore was quite efficient in aligning malpositioned teeth. Although the ribbon arch could be twisted as it was inserted into its slot, the major weakness of the appliance was that it provided relatively poor control of root position. The resiliency of the ribbon archwire simply did not allow generation of the moments necessary to torque roots to a new position.

- **Edgewise.** To overcome the deficiencies of the ribbon arch, Angle reoriented the slot from vertical to horizontal and inserted a rectangular wire rotated 90 degrees to the orientation it had with the ribbon arch, thus the name "edgewise" (Fig. 10.18). The dimensions of the slot were altered to 22 × 28 mil, and a 22 × 28 precious metal wire was used. These dimensions, arrived at after extensive experimentation, did allow excellent control of crown and root position in all three planes of space.

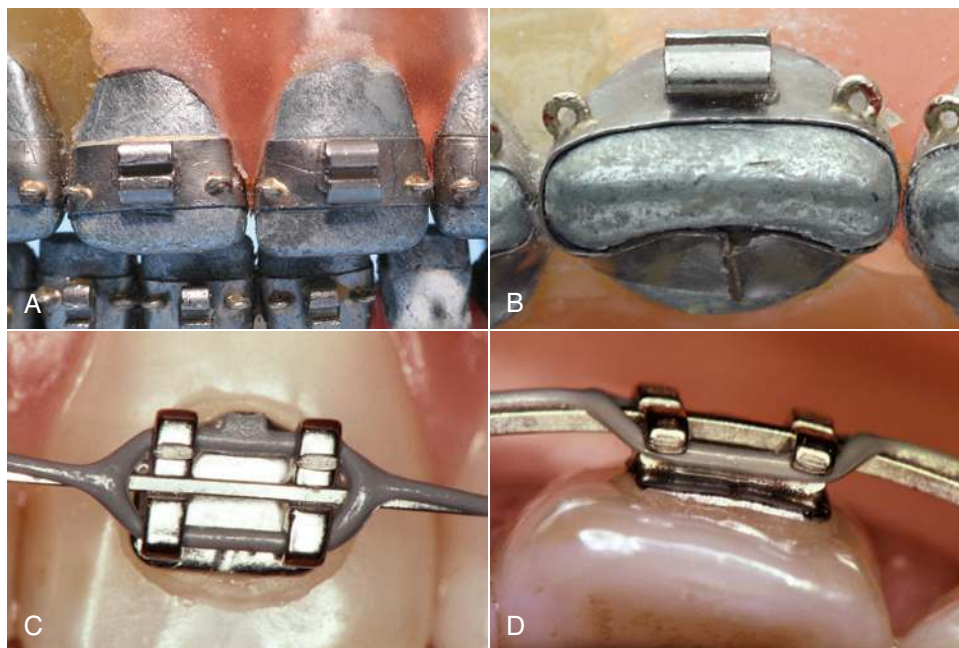
After its introduction in 1928, this appliance became the mainstay of multibanded fixed appliance therapy, although the ribbon arch continued in common use for another decade.

### Other Early Fixed Appliance Systems

**Labiolingual, Twin Wire.** Before Angle, placing attachments on individual teeth simply had not been done, and Angle's concern about precisely positioning each tooth was not widely shared during his lifetime. In addition to a variety of removable appliances using fingersprings for repositioning teeth, there were two major competing appliance systems in the first half of the 20th century. The labiolingual appliance used bands on first molars and a combination of heavy lingual and labial archwires to which fingersprings were soldered to move individual teeth. The twin-wire appliance used bands on incisors as well as molars and featured twin 10-mil steel archwires for alignment of the incisor teeth. These delicate wires were protected by long tubes that extended forward from the molars to the vicinity of the canines. Neither of these appliances, however, was capable of more than tipping movements except with special and unusual modifications. They have disappeared from contemporary use.

**Begg Appliance.** Given Angle's insistence on expansion of the arches rather than extraction to deal with crowding problems, it is ironic that his appliances finally provided the control of root position necessary for successful extraction treatment. The edgewise appliance was being used for this purpose within a few years of its introduction. Charles Tweed, one of Angle's last students, was the leader in the United States in adapting the edgewise appliance for extraction treatment. In fact, little adaptation of the appliance was needed. Tweed moved the teeth bodily and used the subdivision approach for anchorage control, first sliding the canines distally along the archwire, then retracting the incisors (see Fig. 9.33).

Raymond Begg had been taught use of the ribbon arch appliance at the Angle school before his return to Australia in the 1920s. Working independently in Adelaide, Begg also concluded that extraction of teeth was often necessary, and set out to adapt the



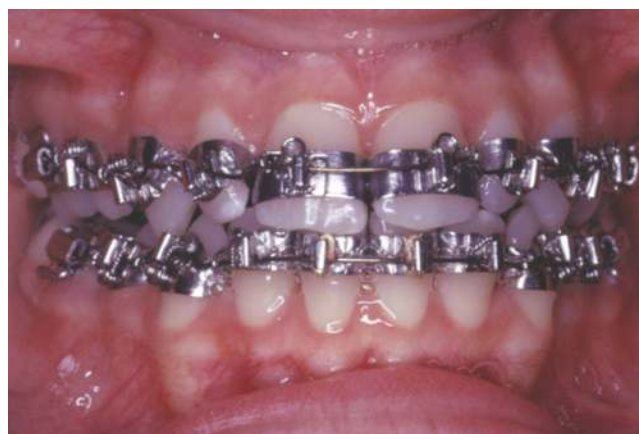• **Fig. 10.18** (A) and (B) Angle's edgewise appliance received its name because the archwire was inserted at a 90-degree angle to the plane of insertion of the ribbon arch, which made it wider than it was tall. The rectangular wire could be twisted to create torque (see Fig. 10.30). It was tied into a rectangular slot with wire ligatures, making excellent control of root position possible. The original appliance is seen here on a typodont. Note the narrow brackets (double width on the maxillary centrals, which are wider teeth), which were soldered to gold bands. Also note the eyelets soldered on the corners of the bands. These were used for ligature ties to the archwire as needed for rotational control. (C) and (D) Close-up views of a modern edgewise twin bracket with a rectangular archwire in place. The wire is held in the bracket by an elastomeric ligature, here part of a chain of ligatures that also keep spaces closed between the teeth.

ribbon arch appliance so that it could be used for better control of root position.

Begg's adaptation took three forms: (1) He replaced the precious metal ribbon arch with high-strength 16-mil round stainless steel wire when this became available from an Australian company in the late 1930s; (2) he retained the original ribbon arch bracket, but turned it upside down so that the bracket slot pointed gingivally rather than occlusally; and (3) he added auxiliary springs to the appliance for control of root position. In the resulting Begg appliance (Fig. 10.19),<sup>5</sup> friction was minimized because the area of contact between the narrow ribbon arch bracket and the archwire was very small and the force of the wire against the bracket was also small. Binding was minimized because Begg's strategy for anchorage control was tipping and uprighting (see Fig. 8.26), and tipping minimizes the angle of contact between the wire and corner of the bracket.

Although the progress records with his approach looked vastly different, it is not surprising that Begg's overall result in anchorage control was similar to Tweed's, because both used two steps to compensate for resistance to sliding. The Begg appliance is rarely seen now in contemporary use, although as we noted earlier, it still appears now in the hybrid Tip-Edge appliance, with brackets that allow the use of rectangular wires in finishing (Fig. 10.20).<sup>6</sup> Unlike labiolingual, twin-wire, and other partially banded fixed appliances, the Begg appliance was a complete treatment system in the sense that it allowed good control of crown and root position in all three planes of space.

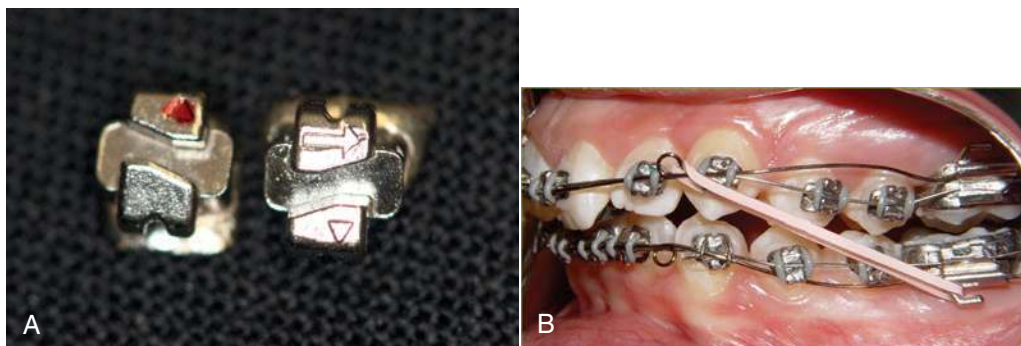**Contemporary Edgewise.** The Begg appliance became widely popular in the 1960s because it was more efficient than the edgewise



• **Fig. 10.19** The Begg appliance uses a modification of the ribbon arch attachment, into which round archwires are pinned. A variety of auxiliary archwires are used in this system to obtain control of root position. For this patient late in treatment, the mandibular archwire is held in place in the central incisors with brass pins, and auxiliary springs (placed in the vertical slot and also serving as pins to retain the archwire) are being used to position the roots of several teeth (they are seen clearly in the maxillary central incisors, activated to move the roots distally).

appliance of that era, in the sense that equivalent results could be produced with less investment of the clinician's time. Developments since then have reversed the balance. The contemporary edgewise appliance has evolved far beyond the original design while retaining the basic principle of a rectangular wire in a rectangular slot, and





• **Fig. 10.20** The Begg appliance now is rarely used in the form in which Dr. Begg developed it, but his ideas survive in the Tip-Edge bracket (A), which has a rectangular slot cut away on one side to allow crown tipping in that direction with no incisal deflection of the archwire. This allows a tooth to be tipped during space closure and uprighted afterward with auxiliary springs, but a rectangular wire can be used for torque in finishing. (B) Tip-Edge brackets in the initial stage of treatment, with small-diameter steel archwires. (Courtesy Dr. D. Grauer.)

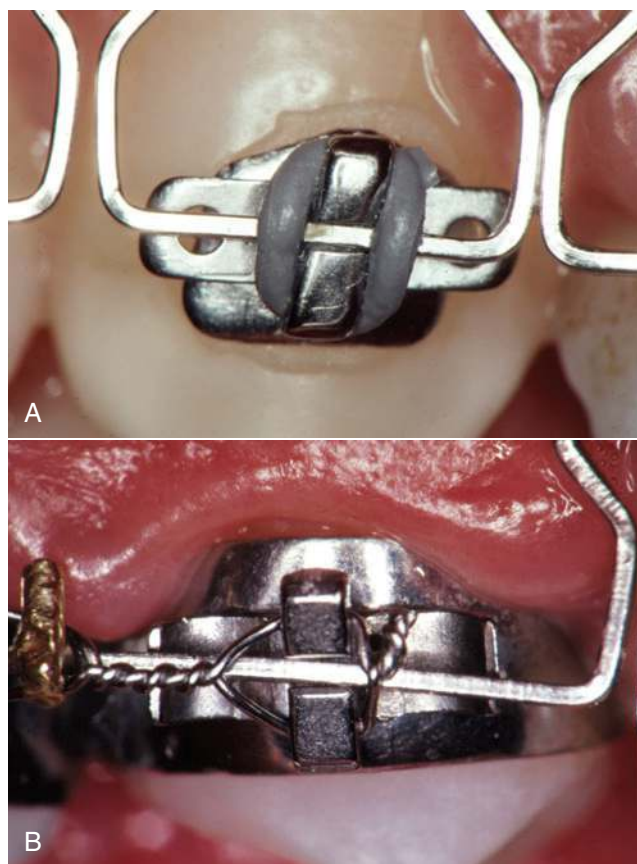
now is more efficient than the Begg appliance, which is the reason for its almost universal use now.

Major steps in the evolution of the edgewise appliance include:

- *Automatic rotational control.* In the original appliance, Angle soldered eyelets to the corners of the bands, so a separate ligature tie could be used as needed to correct or control rotations as a tooth was moved (see Fig. 10.18). Now rotation control is achieved without the necessity for an additional ligature, by using either twin brackets or single brackets with extension wings that contact the underside of the archwire (Lewis or Lang brackets) (Fig. 10.21). Both types of brackets to make it easier to obtain the necessary moment in the rotational plane of space.
- *Alteration in bracket slot dimensions.* The significance of reducing Angle's original slot size from 22 to 18 mil and the implications of using the larger slot with undersize steel wires have been discussed in Chapter 9. There are now two modern edgewise appliances, because the 18- and 22-slot appliances are used rather differently. The introduction of a 20-slot appliance with greater precision than the existing ones has been discussed but has not yet occurred. Chapters 15 to 17 discuss the differences in using the 18- and 22-slot appliances in detail.
- *Straight-wire bracket prescriptions.* Angle used the same bracket on all teeth, as did the other appliance systems. In the 1980s, bonding made it much easier to have different brackets for each tooth, and Andrews developed bracket modifications for specific teeth to eliminate the many repetitive bends in archwires that were necessary to compensate for differences in tooth anatomy. The result was the "straight-wire" appliance.<sup>7</sup> This was the key step in improving the efficiency of the edgewise appliance.

In the original edgewise appliance, faciolingual bends in the archwires (*first-order*, or *in-out*, bends) were necessary to compensate for variations in the contour of labial surfaces of individual teeth. In the contemporary appliance, this compensation is built into the base of the bracket itself, by varying the thickness of the base depending on which tooth it will be attached to. This reduces the need for compensating bends but does not eliminate them because of individual variations in tooth thickness.

Angulation of brackets relative to the long axis of the tooth is necessary to achieve proper positioning of the roots of most teeth. Originally, this mesiodistal root positioning required angled bends in the archwire, called *second-order*, or *tip*, bends. Angulating



• **Fig. 10.21** In contemporary edgewise appliances, the alternative methods for rotation control are twin brackets (as seen in Fig. 10.18C and D) or single brackets with antirotation wings. (A) Bonded single-wing (Lang) bracket with antirotation arms. (B) Single-wing (Lewis) bracket welded to a premolar band. In both (A) and (B), note that the end of an antirotation arm would contact the back of the archwire if the tooth began to rotate, creating the needed antirotation couple. Note also that the slightly undersized rectangular wire crosses the bracket at an angle, creating a moment to control the position of the roots.



the bracket or bracket slot decreases or removes the necessity for these bends.

Because the facial surface of individual teeth varies markedly in inclination to the true vertical, in the original edgewise appliance it was necessary to place a varying twist (referred to as *third-order*, or *torque*, bends) in segments of each rectangular archwire, to make the wire fit passively. Torque bends were required for every patient in every rectangular archwire, not just when roots needed to be moved facially or lingually, to avoid inadvertent movements of properly positioned teeth. The bracket slots in the contemporary edgewise appliance are inclined to compensate for the inclination of the facial surface, so that third-order bends are less necessary.

The angulation and torque values built into the bracket are often referred to as the *appliance prescription*. Obviously, any prescription based on a group average would precisely position only the average tooth and would not be correct for outliers in a normal population.

The edgewise appliance continues to evolve. Current commercially available edgewise appliances are reviewed in some detail at the end of this chapter, along with the possibilities of custom prescriptions for every bracket and using wire-bending robots to produce complex rectangular archwires. Before getting to this, let us examine banding versus bonding as the means for positioning the appliance on the teeth.

## Bands for Attachments

### Indications for Banding

Until the 1980s, the only practical way to place a fixed attachment was to put it on a band that could be cemented to a tooth. The pioneer orthodontists of the early 1900s used clamp bands, which were tightened around molar teeth by screw attachments. Only with the advent of custom-fitted gold bands that were fabricated with special pliers was it practical to place fixed attachments on more than a few teeth. Preformed steel bands came into widespread use during the 1960s but are used now primarily for molar teeth.

There are many advantages to bonding brackets, so it is no longer appropriate to routinely place bands on all teeth. However, indications still exist for use of a band rather than a bonded attachment, including:

- *Heavy intermittent forces against the attachments.* This is the primary indication for banding. An excellent example is an upper first molar against which extraoral force will be placed via a headgear. The twisting and shearing forces often encountered when the facebow is placed or removed are better resisted by a steel band than by a bonded attachment.
- *Teeth that will need both labial and lingual attachments*, such as a molar with both headgear and lingual arch tubes. Isolated bonded lingual attachments that are not tied to some other part of the appliance can be swallowed or aspirated if something comes loose.
- *Teeth with short clinical crowns*, so that bonded brackets are difficult to place correctly. If attached to a band, a tube or bracket can slightly displace the gingiva as it is carried into proper position. It is much more difficult to do this with bonded attachments. The decision to band rather than bond second premolars in adolescents is often based on the length of the clinical crown.

Although there are exceptions, the rule in contemporary orthodontics is that bonded attachments are almost always preferred for anterior teeth and premolars. Bands usually are preferred for first molars, especially if both buccal and lingual attachments are

needed. Second molars are bonded if exposure of the crown allows it, and banded if not.

### Steps in Banding

**Separation.** Tight interproximal contacts make it impossible to properly fit a band, which means that some device to separate the teeth usually must be used before banding. Although there are many types of separators, the principle is the same for all of them: A device to force or wedge the teeth apart is left in place long enough for initial tooth movement to occur, so that the teeth are slightly separated when bands are to be fitted.

Two main methods of separation are used for posterior teeth: (1) separating springs (Fig. 10.22), which exert a scissors action above and below the contact, typically opening enough space for banding in approximately 1 week; and (2) elastomeric separators (“doughnuts”), applied as shown in Fig. 10.23, which surround the contact point and squeeze the teeth apart over a period of several days.

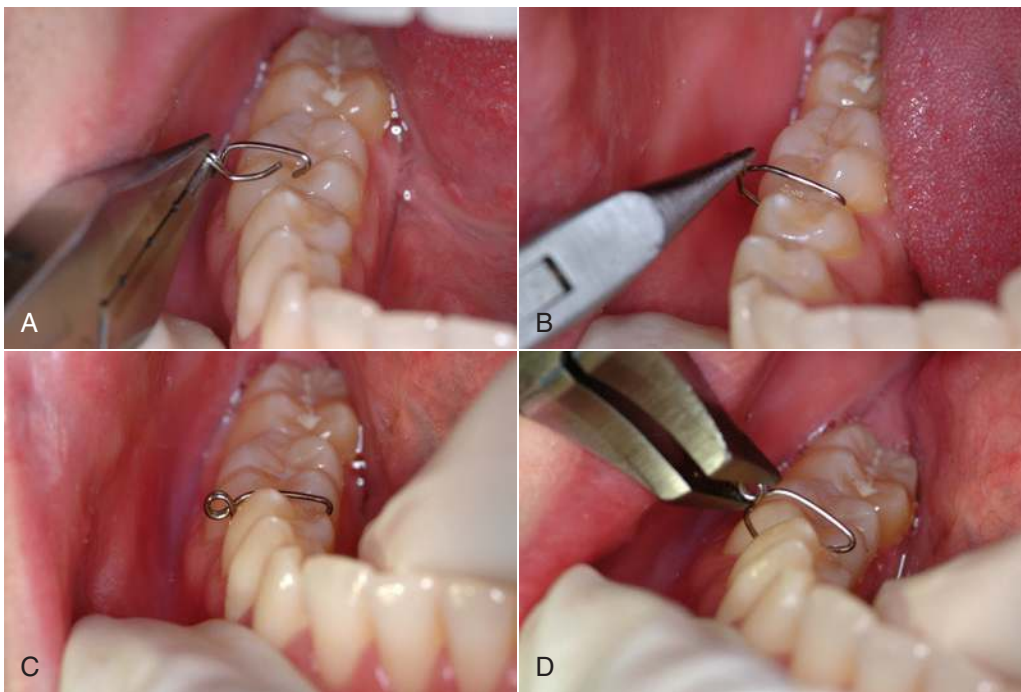
From the patient’s perspective, separation of teeth before banding is the worst part of orthodontics—it hurts, especially if multiple teeth are to be banded. Steel spring separators are easier to tolerate, both when they are being placed and removed, and as they separate the teeth. These separators tend to come loose and may fall out as they accomplish their purpose, which is their main disadvantage and the reason for leaving them in place only a few days, and not for more than a week.

Elastomeric separators are more difficult to insert but are usually retained well when they are around the contact and so may be left in position for somewhat longer periods. They exert heavy force initially that declines quickly, but pain medication is required for at least the first 24 to 36 hours. Because elastomeric separators are radiolucent, a serious problem can arise if one is lost into the interproximal space or gingival crevice. It is wise to use a brightly colored elastomeric material to make a displaced separator more visible, and these separators should not be left in place for more than 2 weeks.

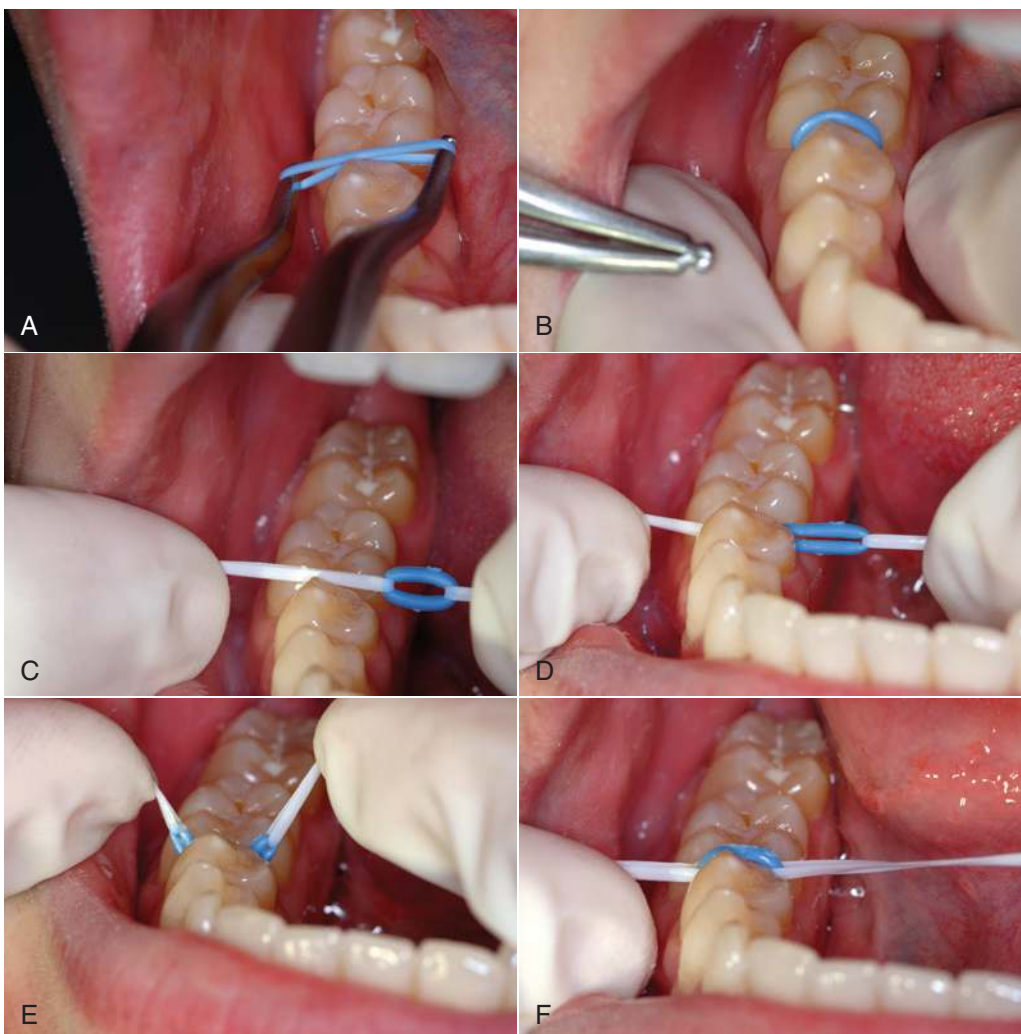
**Fitting Bands.** With the wide availability of preformed bands now, forming bands clinically is too inefficient. Almost all bands are supplied with prewelded attachments. This saves clinical time and allows the use of templates to ensure accurate placement of the attachment.

Fitting a preformed band involves stretching the stainless steel material over the tooth surface. This simultaneously contours and work-hardens the initially rather soft band material. It follows that heavy force is needed to seat a preformed band. This force should be supplied by the masticatory muscles of the patient, not by the arm strength of the dentist or dental assistant. Patients can bite harder and with much greater control, a fact best appreciated on the rare occasions when a patient is unable to bite bands to place and the orthodontist has to do it with hand pressure.

Preformed bands are designed to be fitted in a certain sequence, and it is important to follow the manufacturer’s instructions. A typical maxillary molar band is designed to be placed initially by hand pressure on an instrument placed on the mesial and distal surfaces. This brings the band down close to the height of the marginal ridges. Then it is driven to place by biting pressure on the mesiobuccal and distolingual surfaces. The final seating is with heavy biting force on the distolingual corner. Lower molar bands are designed to be seated initially with hand pressure on the proximal surfaces and then with heavy biting force along the buccal but not the lingual margins. Maxillary premolar bands are usually seated with alternate pressure on the buccal and lingual surfaces;



• **Fig. 10.22** Separation with steel separating springs. (A) The spring is grasped at the base. (B) The bent-over end of the longer leg is placed in the lingual embrasure, and the spring is pulled open so the shorter leg can slip beneath the contact. (C) The spring in place, with the helix to the buccal. (D) The spring can be removed most easily by squeezing the helix, forcing the legs apart.



• **Fig. 10.23** Separation with an elastomeric ring or "doughnut." (A) The elastomeric ring is placed over the beaks of a special pliers and stretched, then (B) one side is snapped through the contact and the pliers slipped out so that the doughnut now surrounds the contact; (C) an alternative to the special pliers is two loops of dental floss, placed so they can be used to stretch the ring. (D) The dental floss is snapped through the contact and the doughnut is pulled underneath the contact; (E) the doughnut is pulled upward, and (F) the doughnut is snapped into position. At that point, the dental floss is removed.

mandibular premolar bands, like mandibular molars, are designed for heavy pressure on the buccal surface only.

**Cementation.** New cements specifically designed for orthodontic use have supplanted the zinc phosphate and early glass ionomer cements used in the 20th century. The newer ones are a composite of glass ionomer and resin materials and usually are light-cured. Their use has greatly reduced problems with leakage beneath bands that previously was a risk for demineralization of banded teeth (see discussion in [Chapter 8](#)).

All interior surfaces of an orthodontic band must be coated with cement before it is placed, so that there is no bare metal. As the band is carried to place, the occlusal surface should be covered so that cement is expressed from the gingival as well as the occlusal margins of the band ([Fig. 10.24](#)). Bands are largely retained by the elasticity of the band material as it fits around the tooth. This is augmented by the cement that seals between the band and the tooth, but a band retained only by cement was not fitted tightly enough. It is good judgment to replace a band that comes loose for the second time with a smaller preformed one.

## Bonded Attachments

### The Basis of Bonding

Bonding of attachments, eliminating the need for bands, was a dream for many years before rather abruptly becoming a routine clinical procedure in the 1980s. Bonding is based on the mechanical locking of an adhesive to irregularities in the enamel surface of the tooth and to mechanical locks formed in the base of the orthodontic attachment. Successful bonding therefore requires careful attention to three components of the system: the attachment base, the tooth surface and its preparation, and the bonding material itself.

The base of a metal bonded bracket or tube is manufactured so that a mechanical interlock between the bonding material and the attachment surface is achieved. The objective is to obtain a stronger attachment of the bonding material to the bracket than to the tooth surface, so that on debonding the bonding material breaks away from the tooth rather than the bracket. This is not necessary with most ceramic brackets because an unpolished ceramic surface has enough irregularity.

Before bonding of an orthodontic attachment, it is desirable to remove the enamel pellicle (the thin layer of protein material that coats the teeth) and then create irregularities in the enamel surface. In the standard technique that still is widely used, this is



• **Fig. 10.24** Molar band ready to cement. The cement must cover all the interior surface of the band. We recommend placing a gloved finger over the top of the band when it is carried to place, to help in keeping cement on the gingival aspect of the band.

accomplished by gently cleaning and drying the enamel surface (avoiding heavy pumicing), then treating it with an etching agent, usually 37% unbuffered phosphoric acid ( $H_3PO_4$ ) for 20 to 30 seconds.<sup>8</sup> The effect is to remove a small amount of the softer interprismatic enamel and open pores between the enamel prisms, so the adhesive can penetrate into the enamel surface ([Fig. 10.25](#)).

A successful bonding material must meet a set of formidable criteria: it must be dimensionally stable; it must be fluid enough to penetrate into the prepared enamel surface, while tacky enough to stay where it was placed; it must have excellent inherent strength, as documented by laboratory testing<sup>9,10</sup>; and it must be easy to use clinically. The most widely used bonding material at present is a light-activated composite resin, although chemically activated resins still are widely available.

Especially in treatment of adults, it occasionally is necessary to bond to a porcelain veneer or crown, or to gold or amalgam restorations. Techniques for bonding to these restorative materials have been developed,<sup>11</sup> and are described in [Chapter 19](#).

### Direct Bonding

During direct bonding, bracket position is determined intraorally by the clinician during the bonding procedure. This technique can be used quite successfully as a routine clinical procedure. Even when most attachments are bonded indirectly (as described later), direct bonding is much more efficient whenever a single bracket must be repositioned. The major difficulty with direct bonding is that the dentist must be able to judge the proper position for the attachment and must carry it to place rapidly and accurately. There is less opportunity for precise measurements of bracket position or detailed adjustments than there would be at the laboratory bench. For this reason, it is generally conceded that direct bonding does not provide as accurate a placement of brackets as indirect bonding. On the other hand, direct bonding is easier, faster (especially if only a few teeth are to be bonded), and less expensive (because the laboratory fabrication steps are eliminated).

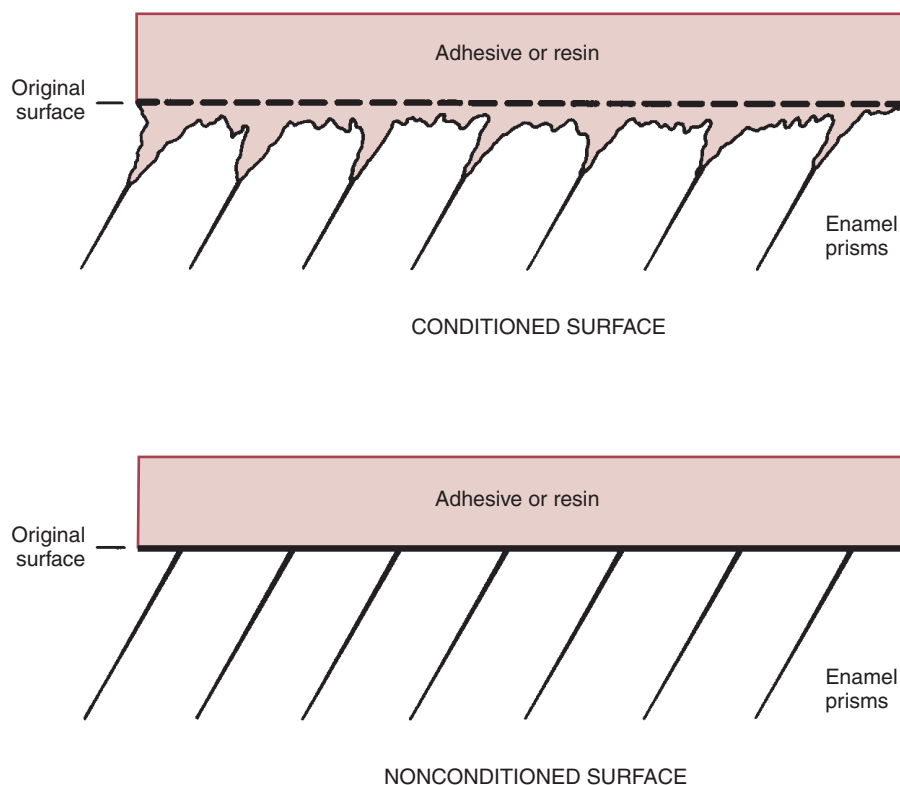
Steps in the direct bonding technique when using a light-activated resin for each bracket are illustrated in [Fig. 10.26](#). Light-cured resins now are used more frequently than chemically activated resins because the newer light-cured materials have more flexibility in working time and usually have higher bond strengths.

As we have noted in [Chapter 8](#), demineralization around brackets is a significant problem in fixed appliance treatment at present, and glass ionomer materials offer the possibility of enough sustained fluoride release to protect the enamel around the edges of brackets (see [Chapter 8](#)). Trials with modified glass ionomers for bonding showed that even when some composite resin was included in the bonding material, the bond strength still was not adequate. Justus and coworkers have advocated a way to improve the bond strength of a modified glass ionomer to the point that it should be adequate for bonding.<sup>12</sup>

The key to bonding with a largely glass ionomer material has turned out to be deproteinization of the enamel surface with 5% NaOCl (sodium hypochlorite, widely sold as Clorox), and then a 15- to 20-second etch time—slightly shorter than the usual 25 to 30 seconds—with 35%  $H_3PO_4$ . This increases the percentage of etch patterns 1 and 2 in the enamel surface ([Fig. 10.27](#)), and significantly increases the bond strength of the resin-modified glass ionomer (Fuji Ortho LC).

A light nickel–titanium (NiTi) wire without initial full bracket engagement in severely malpositioned teeth should be used because the glass ionomer part of the adhesive takes 24 hours to set. With





• **Fig. 10.25** Diagrammatic representation of the effect of preparation of the enamel surface before bonding. Pretreatment with phosphoric acid creates minute irregularities in the enamel surface, allowing the bonding material to form penetrating “tags” that mechanically interlock with the enamel surface.

that approach, the debonding rate is said to be about 5%, roughly comparable to rates with composite resin bonding materials.

Does this use of resin-modified glass ionomer cement really reduce the incidence of demineralization and white spots? The ideal evidence would be outcomes from a randomized clinical trial, which has not been done, but the clinical data presented by Justus are impressive. It appears that the improved fluoride release from the resin-modified glass ionomer can provide useful protection against demineralization, and the glass ionomer component allows the ability to “recharge” the fluoride content of the resin by in-office fluoride treatment.

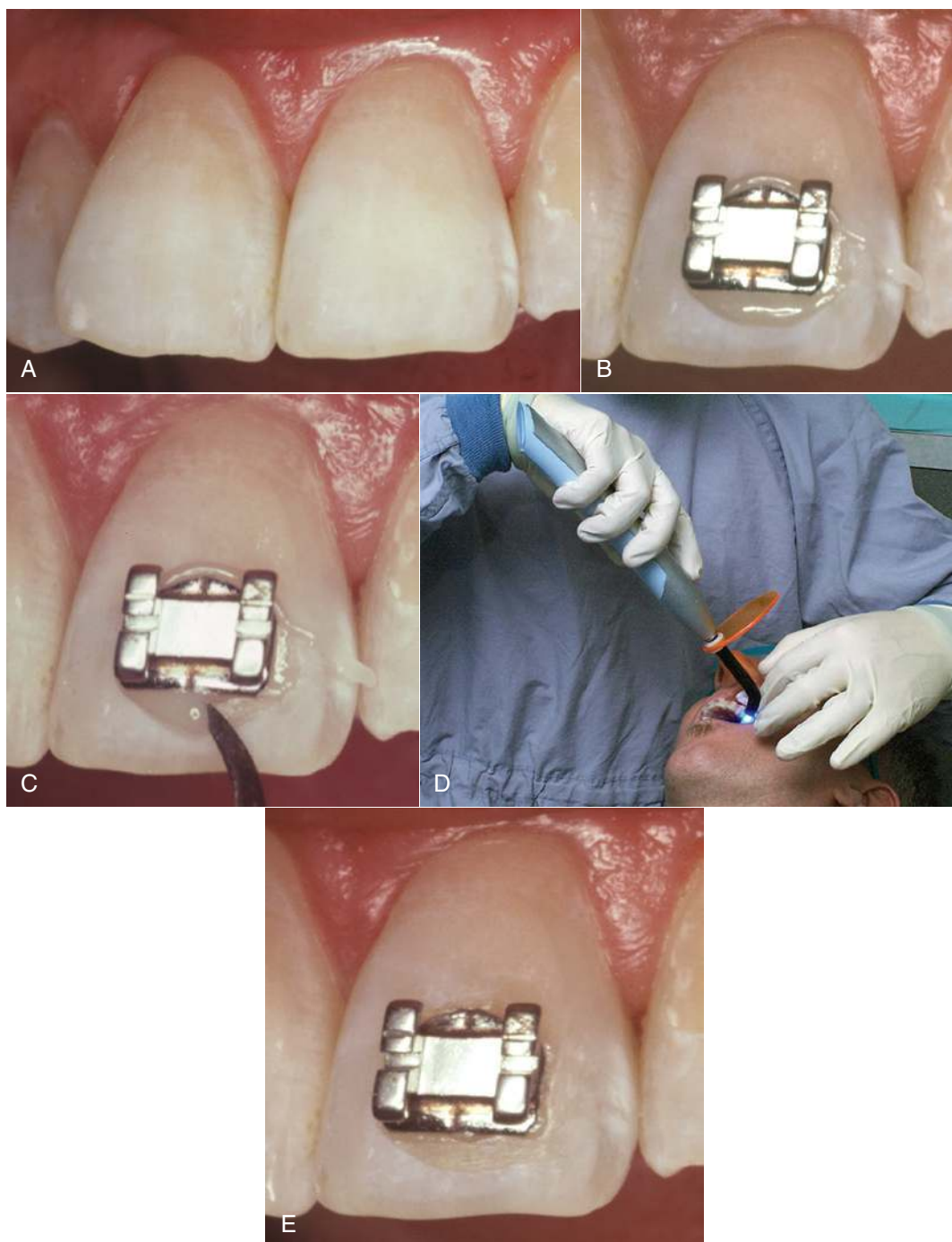
### Indirect Bonding

Indirect bonding is done by accurately placing the brackets on dental casts in a laboratory or in virtual space, then using a template or tray to transfer this bracket position to the patient. The result is more precise location of brackets because the limitations of cheeks that partially obstruct the view of the teeth are removed, salivary contamination of prepared surfaces is easier to control, and direct transfer to a tooth location determined from virtual bonding in a computer system is straightforward.<sup>13</sup>

Indirect set-ups can be completed by the clinician in the office laboratory by creating a stone cast from an impression or by printing a 3-D model from an intraoral scan. Indirect bracket set-ups can also be done by a service laboratory by using a stable impression material suitable for digital scanning at a distant site or, more likely in today’s digital world, by sending a direct intraoral scan directly from the office scanner to the lab. Laboratory and clinical steps in indirect bonding are illustrated in Fig. 10.28.

Producing indirect bonding bracket set-ups and transfer trays in the office remains a rapid and cost-effective method. After producing an accurate stone cast, a layer of separator is placed on the cast. The brackets are then placed on the cast by using a light-activated composite resin in the desired location and are checked by the orthodontist for positioning accuracy. Once the brackets are in position, any excess flash is removed and they are secured in this location by exposing them to an appropriate curing light in a light box (such as the Triad unit [Dentsply Sirona, York, PA]). Less efficiently, this also can be done with a hand-held curing light. This process creates a custom composite base for each bracket that fits each tooth surface precisely. A transfer tray is then made using a PVS putty that covers the brackets and provides occlusal/incisal stops. The tray is trimmed to remove excess tray material and sectioned into quadrants. This makes it easier to insert and to see clearly that the trays are fully seated during the clinical bonding procedure. A frequently used but more time-consuming alternative (because of the greater effort to trim these trays) is to vacuum-form them from an aligner-type material.


The trays are clinically used by placing a lightly filled sealant on the patient’s teeth and on the bracket backs and then seating the trays in the patient’s mouth. The lightly filled sealant used for bonding can be a chemical-cured resin, a “no-mix” resin, or a light-activated resin. A chemical cure resin that is mixed before application to the brackets and teeth is efficient because all brackets cure simultaneously, but care must be taken to minimize excess resin to avoid flash after tray removal. A “no-mix” resin has an advantage in minimizing flash; a composite resin is placed on the tooth surface in unpolymerized form, and the polymerization



• **Fig. 10.26** Steps in direct bonding. (A) After etching, the tooth surface has a somewhat chalky or frosted appearance if dried (drying is no longer necessary with modern tooth preparation materials, but the tooth surface must be etched). (B) A small amount of the bonding agent is squeezed into the mesh on the back of the bracket, and it is pressed to place on the tooth surface. (C) Excess bonding material is removed from around the bracket. (D) For light-cured materials, a cordless light now is the most convenient way to activate the adhesive bonding process. (E) The bracket bonded in place.

catalyst is placed on the back of the brackets. When the tray carrying the brackets is placed against the tooth surface, the resin immediately beneath the bracket is activated and polymerizes, but excess resin around the margins of the brackets does not polymerize and can easily be scaled away when the bracket tray is removed. Some studies, however, have found increased bond failures with

this technique because it relies on diffusion for proper polymerization. Finally, a flowable light-cured material can be used with a translucent tray, but polymerizing the resin at each bracket through or around the tray takes more time than using a chemical cure. With any of these techniques, proper isolation to prevent saliva contamination is critical for obtaining adequate bond strength.



• **Fig. 10.27** After deproteinization of the enamel surface with NaOCl (Clorox or a special formulation for orthodontic bonding) and then a reduced etch time with 35% phosphoric acid, it is possible to obtain a more favorable enamel surface pattern that allows successful bonding with a glass ionomer cement. Etch patterns 1 and 2 ([A] and [B]) work with a glass ionomer; etch pattern 3 (C), the typical result without deproteinization, does not. (Courtesy Dr. R. Justus.)

There are now several laboratory services that will produce indirect bonding trays for the clinician. Some of these simply duplicate the in-office process described earlier. Others provide a value-added service by producing transfer trays based on bracket position determined from a digital treatment simulation. This is meant to ensure that the bracket position will provide optimal alignment. In this case the digital models are segmented into movable teeth and virtually aligned following the arch form prescribed by the orthodontist. Virtual brackets are then placed on the teeth in such a position that a straight wire of the proper arch form will engage all the bracket slots. This “ideal” bracket position is then digitally transferred back to the original cast and a tray is fabricated to produce this bracket position in the patient. Some of these trays are directly 3-D printed so the brackets can be snapped into place. To gain the benefits of indirect bonding, the transfer process itself must be accurate, and we now have some evidence that this is the case.<sup>14</sup>

At present, indirect bonding is the preferred technique for placement of a complete fixed appliance. Custom brackets that were manufactured for an individual patient require precise placement that can be achieved only by indirect bonding. More generally, the poorer the visibility, the more difficult direct bonding becomes and the greater the indication for an indirect approach. For this reason, indirect bonding is a necessity for lingual attachments. Bonding an isolated lingual hook or button is not difficult, but

precisely positioning the attachments for a lingual appliance is, and even the placement of a fixed lingual retainer is easier with indirect technique and a transfer tray.

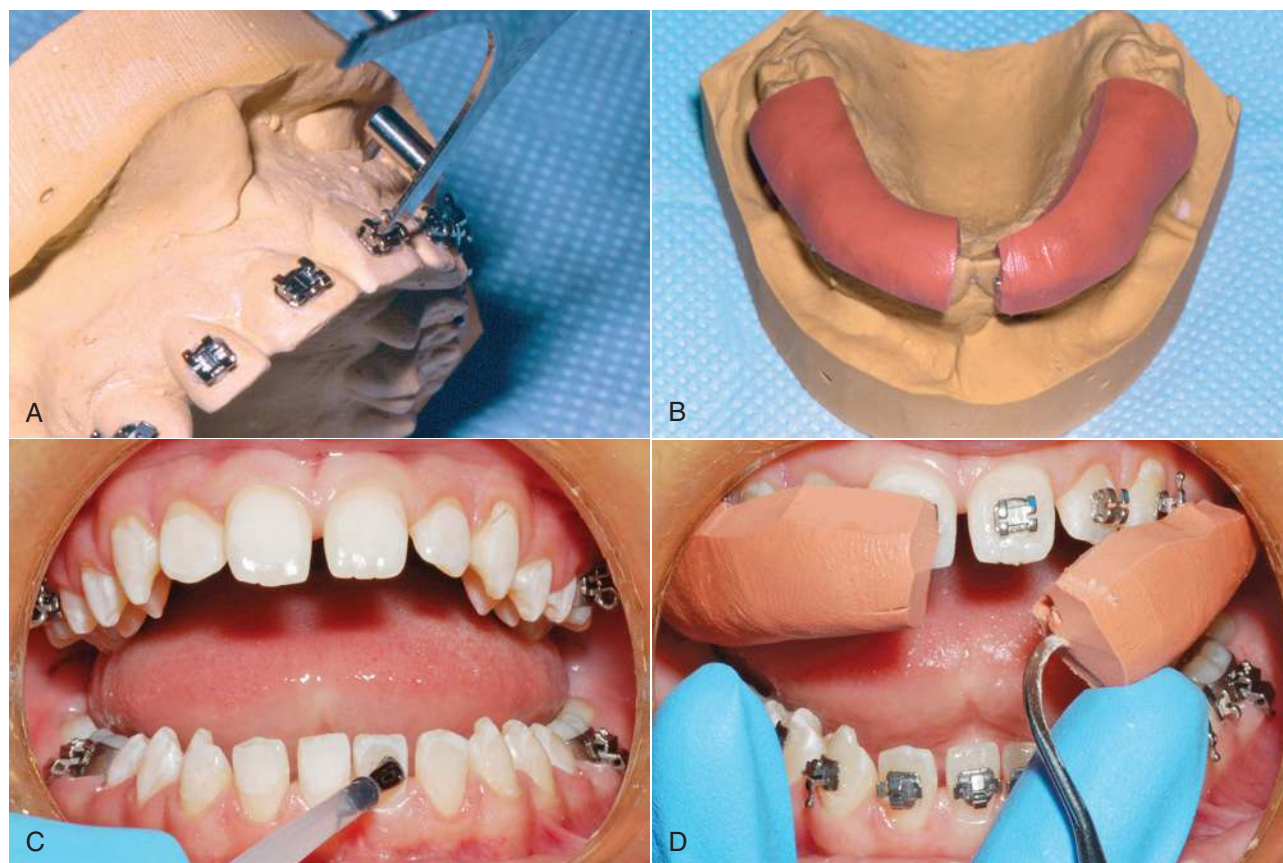
## Characteristics of Contemporary Fixed Appliances

### Appliance Materials

**Stainless Steel Brackets.** The brackets and tubes for an edgewise appliance must be precisely manufactured so that the internal slot dimensions are accurate to at least  $\pm 1$  mil. Until the recent introduction of ceramic and titanium brackets, fixed appliances had been fabricated entirely from stainless steel for many years, and stainless steel remains the standard material for appliance components.

There are now three contemporary ways to produce edgewise brackets and tubes: by metal-injection molding (MIM), casting, or 3-D printing (which is possible with metals as well as plastics). Most of the brackets and tubes for contemporary appliances still are produced by MIM, but an increasing percentage are cast. Better precision of bracket slot size is achieved by milling the slot of a cast bracket, which corrects errors introduced by shrinkage of the casting as it cools. The use of 3-D printing offers the possibility of significantly better bracket slot precision, and the first 3-D brackets printed in metal now are available for the newest lingual appliance system (see later). It is likely that 3-D printing, probably





• **Fig. 10.28** Steps in indirect bonding. (A) Brackets are placed precisely as desired on a cast of the teeth and held in place with a filled resin. (B) After the brackets are cured in the ideal position, a transfer tray is formed from a vinyl polysiloxane putty. The trays are removed from the working cast after soaking in warm water and trimmed. (C) The teeth are isolated and etched, and a chemically cured two-paste resin is painted on the etched enamel and the brackets; alternatively, a light-cured resin can be used, but only with translucent trays. Then the transfer trays are inserted. (D) After the resin has completely set, the trays are carefully removed, leaving the brackets bonded to the teeth.

using different alloys than stainless steel or composite plastics, will largely replace the older technology for bracket production.

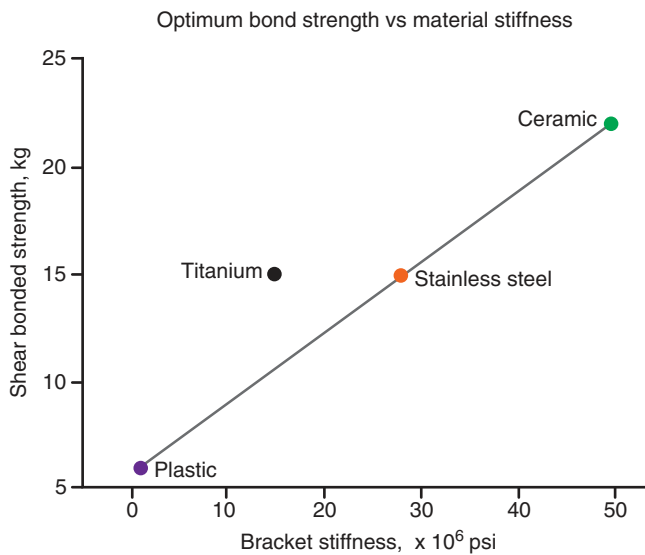
**Titanium as an Alternative to Stainless Steel.** Titanium edgewise brackets have been commercially available for some years now and can be used for comprehensive treatment. A major indication for titanium brackets and wires is to eliminate the possibility of an allergic response to the 8% nickel content in stainless steel (see [Chapter 8](#)). In addition to their greater safety in an increasingly allergic population, titanium brackets have an important advantage over steel brackets—and also a potentially important disadvantage.

The major advantage is better bond reliability—that is, a lower chance that a bonded bracket will be lost during active treatment. A lost bracket disrupts patient flow on the day it has to be replaced and tends to lengthen treatment time, so bracket reliability is an important aspect of efficient treatment. The greater reliability of titanium brackets is primarily because titanium has the same strength as stainless steel, but is half as stiff. This means that a titanium bracket can absorb 50% more impact energy than a steel bracket, reducing the load on the bond during function ([Fig. 10.29](#)). The effect is a lower bond failure rate—although this has not been well documented in the peer-reviewed literature. In a private practice with excellent practice metrics, the bond failure rate dropped from

between 5% and 10% to less than 1% after replacement of steel with titanium brackets. A reasonable consensus rate for steel brackets is about 3%.

Titanium also has an inherently rougher surface than stainless steel, and all other things being equal, that means potentially greater resistance to sliding a tooth along an archwire if the wire or the bracket is titanium. The area of contact of an archwire against a bracket slot is quite small under most circumstances, and a titanium bracket is not a problem when small round wires are used. Titanium also has a chemically active surface, and this can contribute to difficulty in sliding, especially with a TMA wire in a titanium bracket. Clinically, that means that when titanium brackets are used, small spaces should be closed by sliding along undersized steel wires, and extraction sites preferably would be closed with closing loops in steel or TMA wires.

**Nonmetallic Appliance Materials: Plastics, Ceramics, and Composite Plastics.** Recurring efforts have been made to make fixed appliances more esthetic by eliminating their metallic appearance. A major impetus to the development of bonding for orthodontic attachments was elimination of the unsightly metal band. Tooth-colored or clear brackets for anterior teeth ([Fig. 10.30](#)) became practical when successful systems for direct bonding were developed. Although plastic brackets were introduced



• **Fig. 10.29** This graph illustrates the comparable bond strengths with titanium and stainless steel brackets and the lesser stiffness of a titanium bracket. This allows it to absorb more of an impact against the bracket, and makes it more resistant to inadvertent debonding. (Data from Sachdeva R. Redefining bracket engineering with titanium data. *Orthos*. 2016:10–13.)

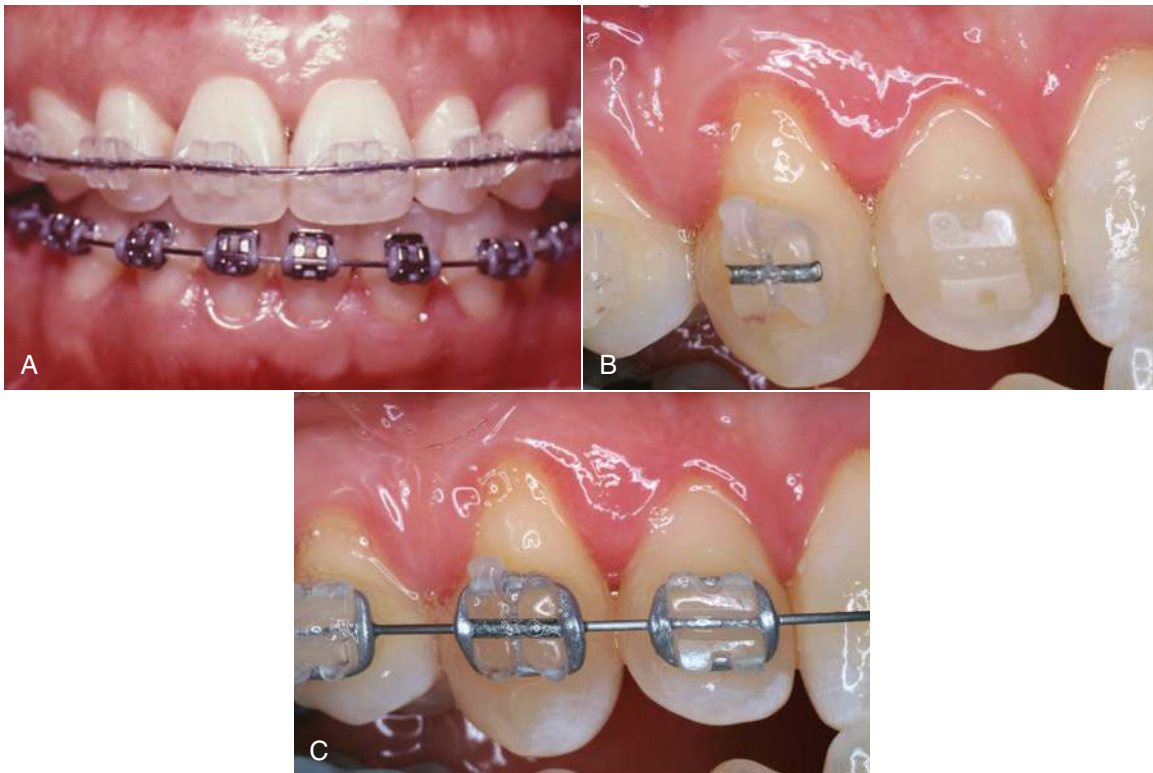
with considerable enthusiasm in the 1980s and have retained a small market share ever since, they have four largely unresolved problems:

- Staining and discoloration, particularly in patients who smoke or drink coffee
- Poor strength (see Fig. 10.29), so that brackets are likely to break when large archwires are used
- Poor dimensional stability, so that it is not possible to provide precise bracket slots or build in all the straight-wire features
- Friction and binding between the plastic bracket and metal archwires that makes it very difficult to slide teeth to a new position

Using a metal slot in the plastic bracket helps with the last three problems, but even with this modification, plastic brackets are useful only when complex tooth movements are not required.

Ceramic brackets, which became available in the late 1980s, largely overcome the esthetic limitations of plastic brackets in that they are quite durable and resist staining (see Fig. 10.30). In addition, they can be custom-molded to fit individual teeth and are dimensionally stable, so the precise bracket angulations and slots of the straight-wire appliance can be incorporated. Several different types of ceramic brackets currently are available (Table 10.2). They all are comparable esthetically.

Ceramic brackets were received enthusiastically and immediately achieved widespread use, but problems with fractures, friction



• **Fig. 10.30** (A) Ceramic twin brackets on the maxillary anterior teeth, with steel brackets on all teeth that are not highly visible. Using ceramic brackets in this way eliminates the possibility of enamel abrasion when teeth contact ceramic brackets in function while maintaining the esthetic benefit of using brackets of this type. (B) Ceramic brackets with and without a metal slot, wire out. (C) Same brackets with wire in place. Note the similarity of appearance when an archwire is present.


**TABLE 10.2** Ceramic Brackets

Material	Manufacturer	Name
Polycrystalline alumina (PCA)	American	20/40 Virage
	Dentaurum	Fascination 2
	GAC	Allure
	Ormco	Mystique
	Rocky Mountain and many others	Innovation-C
		Damon Clear
		Signature
PCA with metal slot	Unitek	Clarity
	Rocky Mountain	Luxi II
Monocrystalline alumina	American	Radiance
	Ormco	Inspire Ice
	Ortho Technology	PURE

within bracket slots, wear on teeth contacting a bracket, and enamel damage from bracket removal soon became apparent. Fractures of ceramic brackets occur in two ways: (1) loss of part of the brackets (e.g., tie wings) during archwire changes or eating and (2) cracking of the bracket when torque forces are applied. Ceramics are a form of glass, and like glass, ceramic brackets tend to be brittle. Because the fracture toughness of steel is much greater, ceramic brackets must be bulkier than stainless steel brackets, and the ceramic design is much closer to a wide single bracket than is usual in steel.

Most currently available ceramic brackets are produced from alumina, either as single-crystal or polycrystalline units. In theory, single-crystal brackets should offer greater strength, which is true until the bracket surface is scratched. At that point, the small surface crack tends to spread, and fracture resistance is reduced to or below the level of the polycrystalline materials. Scratches, of course, are likely to occur during treatment.

Although ceramic brackets are better in this regard than plastics, resistance to sliding has proved to be greater with ceramic than with steel brackets. Because of the multiple crystals, polycrystalline alumina brackets have relatively rough surfaces in the bracket slots (Fig. 10.31). Even though monocrystalline alumina is as smooth



• **Fig. 10.31** Scanning electron microscope views of brackets. (A) Stainless bracket (Uni-Twin, 3M-Unitek). (B) Commercially pure titanium (Rematitan, Dentaurum). (C) Polycrystalline alumina (Transcend, 3M-Unitek). (D) Monocrystalline alumina (Starfire, A Co.). Note the smooth surfaces of the monocrystalline alumina and steel brackets compared with the rougher surface of the polycrystalline alumina. The titanium bracket slot is smooth but not quite as smooth as steel. (Courtesy Dr. R. Kusy.)



as steel, these brackets also do not allow good sliding, perhaps because of a chemical interaction between the wire and bracket material. For this reason, many second-generation ceramic brackets were supplied with an integrated metal slot. Most current brackets now have eliminated the metal slot, using corner-rounding and surface-smoothing techniques instead to reduce binding, but with limited evidence that these alterations are effective.

Many patients bite against a bracket or tube at some point in treatment. Contact against a steel or titanium bracket causes little or no wear of enamel, but contact of an opposing tooth against a ceramic bracket can abrade enamel quite rapidly. This risk is largely avoided if ceramic brackets are placed only on the upper anterior teeth, where improved esthetics is most important. Most patients who want the esthetic effect will accept steel or titanium brackets elsewhere if ceramic brackets are used on the most visible teeth.

Debonding ceramic brackets also can be a problem when it comes time for bracket removal. Most manufacturers now offer debonding pliers designed to fracture the bracket along a feature engineered into the bracket. An alternative is to use a diode laser or thermal instrument to weaken the adhesive by heating it. This is quite effective in reducing the chance of enamel damage.<sup>15</sup> Unfortunately, it introduces the chance of damaging the tooth pulp if the heat application is not controlled quite precisely, and for that reason has not been widely adopted. Debonding techniques are discussed in greater detail in [Chapter 17](#).

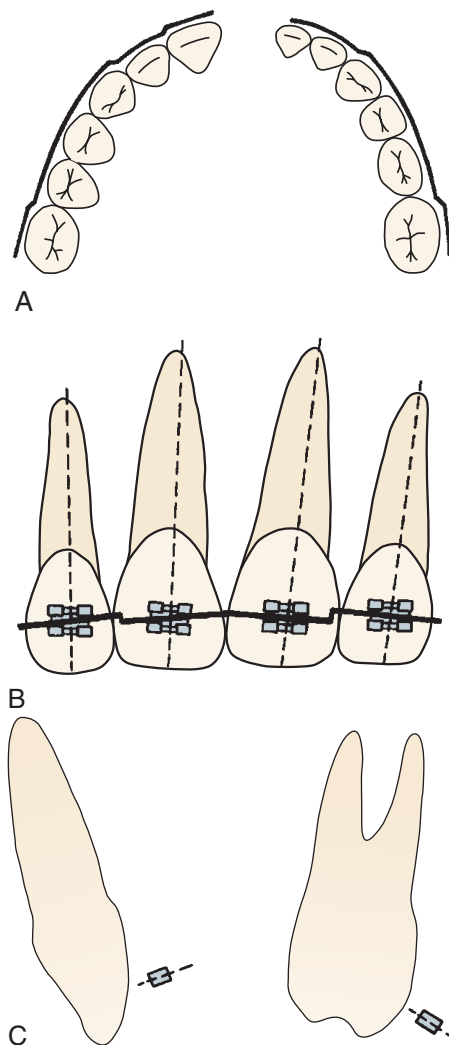
Composite plastic brackets are likely to become the next advance in brackets. Composite plastics with better physical properties than any metal already exist and could be used for both brackets and archwires. It is just a matter of overcoming the engineering problems to produce competitively priced brackets with better mechanical properties. Because composite plastics can be almost any color, a better appearance is likely to be an additional benefit.

### Straight-Wire Concept in Bracket and Tube Design

Modern edgewise appliances use brackets or tubes that are custom-made for each tooth, with the goal of minimizing the number of bends in archwires needed to produce an ideal arrangement of the teeth, hence the “straight-wire” name. In Angle’s terminology for his appliance, first-order bends were used to compensate for differences in tooth thickness, second-order bends to position roots correctly in a mesiodistal direction, and third-order (torque) bends to position roots in a faciolingual direction ([Fig. 10.32](#)). Let’s view these bracket and tube compensations for bends in archwires in more detail.

**Compensations for First-Order Bends.** For anterior teeth and premolars, varying the bracket thickness eliminates in–out bends in the anterior portions of each archwire, but an offset position of molar tubes is necessary to provide correct molar rotation ([Fig. 10.33](#)). For good occlusion, the buccal surface must sit at an angle to the line of occlusion, with the mesiobuccal cusp more prominent than the distobuccal cusp. For this reason, the tube or bracket specified for the upper molar should have at least a 10-degree offset, as should the tube for the upper second molar. The offset for the lower first molar should be 5 to 7 degrees, about half as much as for the upper molar. The offset for the lower second molar should be at least as large as for the first molar.

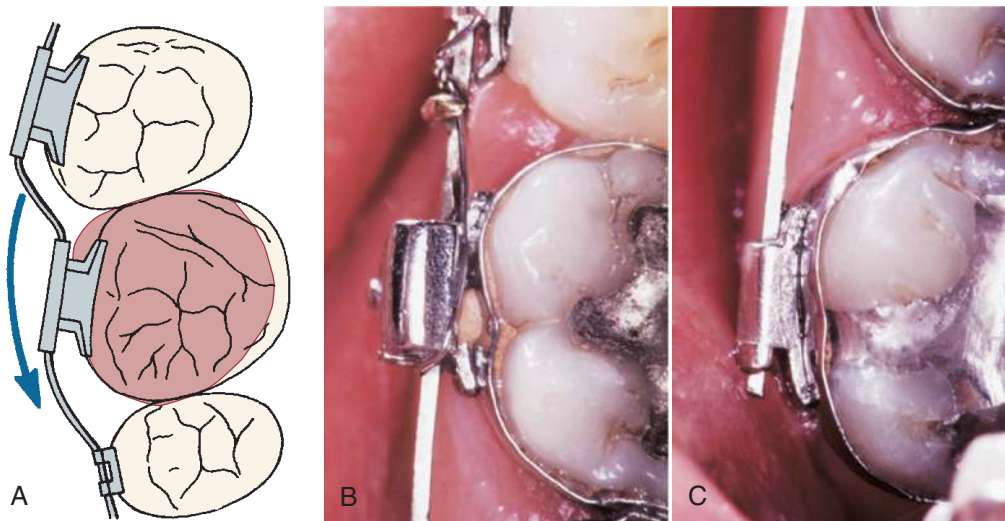
**Compensations for Second-Order Bends.** In the original edgewise appliance, second-order bends, sometimes called *artistic positioning bends*, were an important part of the finishing phase of treatment. These bends were necessary because the long axis of



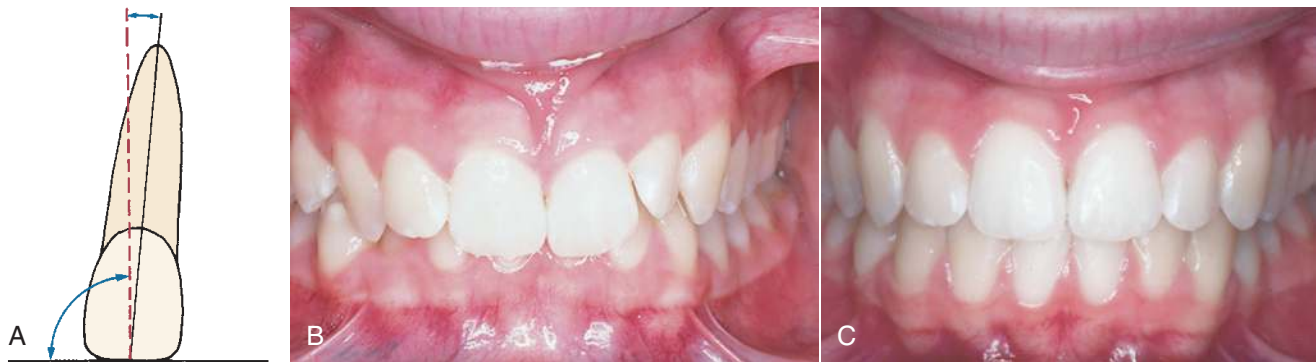• **Fig. 10.32** First-, second-, and third-order bends in edgewise wires. (A) First-order bends in a maxillary (*left*) and mandibular (*right*) archwire. Note the lateral inset required in the maxillary archwire and the canine and molar offset bends that are required in both. (B) Second-order bends in the maxillary incisor segment to compensate for the inclination of the incisal edge of these teeth relative to the long axis of the tooth. (C) Third-order bends for the maxillary central incisors and maxillary first molars showing the twist in the archwire to provide a passive fit in a bracket or tube on these teeth. Twist in an archwire provides torque in a bracket; the torque is positive for the incisor, negative for the molar.

each tooth is inclined relative to the plane of a continuous archwire ([Fig. 10.34](#)). Contemporary edgewise brackets have a built-in tip for maxillary incisor teeth, which varies among the appliances that are now available. A distal tip of the upper first molar is also needed to obtain good interdigitation of the posterior teeth. If the upper molars are too vertically upright, even though a proper Class I relationship apparently exists, good interdigitation cannot be achieved. Tipping upper molars distally brings their distal cusps into occlusion and creates the space needed for proper relationships of the premolars ([Fig. 10.35](#)).

**Compensations for Third-Order Bends.** If the bracket for a rectangular archwire is placed flat against the labial or buccal surface of any tooth, the plane of the bracket slot will twist away from



• **Fig. 10.33** (A) The rhomboidal surface of the upper, and to a lesser extent the lower, molars means that placing a springy archwire through attachments that were flat against the facial surface would produce a mesiolingual rotation of these teeth, causing them to take up too much space in the arch. Compensation requires a bend in the archwire, or placing the tube at an angle offset to the facial surface. (B) Rectangular and headgear tubes for the upper first molar and (C) rectangular tube for the lower second molar in a contemporary appliance. Note the offset position of the tubes so that a first-order bend in the wire is unnecessary.

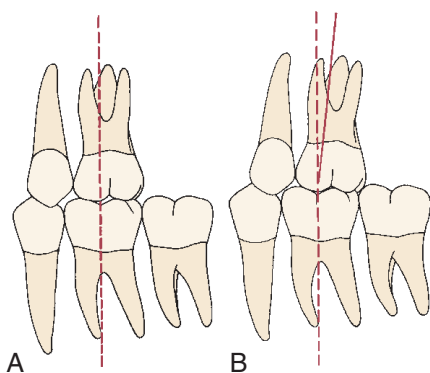


• **Fig. 10.34** (A) A second-order bend, or an inclination of the bracket slot to produce the same effect, is necessary for the maxillary incisors because the long axes of these teeth are inclined relative to the incisal edge. The angle between the dotted red line and the long axis of the tooth is the bracket angulation. The term “bracket tip” refers to the same angle. (B) and (C) Malaligned maxillary incisors before and after treatment using straight-wire brackets to facilitate both mesiodistal (tip) and faciolingual (torque) root positioning. (A redrawn from Andrews LF. *J Clin Orthod.* 1976;10:174–195.)

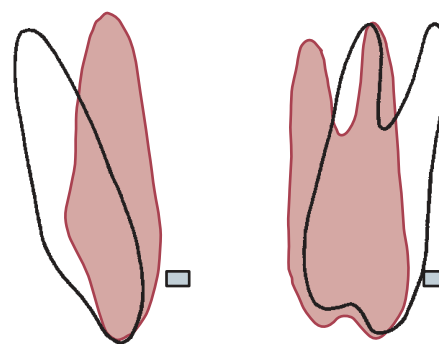
the horizontal, often to a considerable extent. With the original edgewise appliance, it was necessary to place a twist in each rectangular archwire to compensate for this. Failure to place third-order bends meant that in the anterior region, the teeth would become too upright, while posteriorly the buccal cusps of molars would be depressed and the lingual cusps elevated (Fig. 10.36). Compensation for this can be done by cutting the bracket slot into the bracket at an angle or forming the base so that the face of the bracket is at an angle. This is called placing torque in the bracket or torque in the base, respectively. It allows a horizontally flat rectangular archwire to be placed into the bracket slots without incorporating twist bends.

The amount of torque recommended in the various appliance prescriptions varies more than any other feature of contemporary edgewise appliances. Although a number of factors are important in establishing the appropriate torque, four are particularly germane to how much torque is used for any particular bracket:

- The value that the developer of the appliance chose as the average normal inclination of the tooth surface. (This varies considerably among individuals and therefore can be different in “normal” samples.)
- Where on the labial surface (i.e., how far from the incisal edge) the bracket is intended to be placed. The inclination of the tooth surface varies depending on where the measurement is



• **Fig. 10.35** A distal inclination or tip of the maxillary first molar is important for proper posterior occlusal interdigitation. If the mesiobuccal cusp occludes in the mesial groove of the mandibular first molar, creating an apparently ideal Class I relationship, proper interdigitation of the premolars still cannot be obtained if the molar is positioned too upright (A). Tipping the molar distally (B) allows the premolars to interdigitate properly. (Redrawn from Andrews LF. *Am J Orthod.* 1972;62:296.)



• **Fig. 10.36** The plane of a flat rectangular archwire relative to a maxillary incisor and molar is shown in red. To produce the proper faciolingual position of both anterior and posterior teeth, either a rectangular archwire must be twisted (torqued), or the bracket slot must be cut at an angle to produce the same torque effect. Otherwise, the improper inclination shown in red will be produced. Proper torque is necessary not to move teeth but to prevent undesired movement.

**TABLE 10.3**

**Bracket/Tube Prescription: Incisors Through Premolars, Bracket Prescription**

	CENTRAL		LATERAL		CANINE		FIRST PREMOLAR		SECOND PREMOLAR	
	Torque	Tip	Torque	Tip	Torque	Tip	Torque	Tip	Torque	Tip
<b>Maxillary</b>										
Alexander	15	5	9	9	-3	10	-6	0	-8	4
Andrews	7	5	3	9	-7	11	-7	2	-7	2
Damon (standard torque)	15	5	6	9	7	5	-11	2	-11	2
MBT	17	4	10	8	-7	8	-7	0	-7	0
Ricketts	22	0	14	8	7	5	0	0	0	0
Roth	12	5	8	9	-2	9	-7	0	-7	0
<b>Mandibular</b>										
Alexander	-5	2	5	6	-7	6	-7	0	-9	0
Andrews	-1	2	-1	2	-11	5	-17	2	-22	2
Damon (standard torque)	-3	2	-3	4	7	5	-12	4	-17	4
MBT	-6	0	-6	0	-6	3	-12	2	-17	2
Ricketts	0	0	0	0	7	5	0	0	0	0
Roth	0	0	0	0	-11	7	-17	0	-22	0

made, so an appliance meant to be placed more gingivally would require different torque values than would one placed more incisally.

- The expected “play” between the wire and the bracket slot, which is determined by the difference between the wire size and the slot size. As Tables 10.3 and 10.4 demonstrate, the effective torque produced by undersized rectangular wires is far less than the bracket slot prescription might lead one to expect.<sup>16</sup>

- The resistance to unwanted movements, such as a negative torque prescribed for lower incisors to resist the expected proclination from nonextraction alignment.

### Contemporary Straight-Wire Brackets and Tubes

**Self-Ligating Brackets.** Placing wire ligatures around tie wings on brackets to hold archwires in the bracket slot is a time-consuming procedure. The elastomeric modules introduced in the 1970s largely replaced wire ligatures for two reasons: They are quicker and easier



**TABLE 10.4** Molar Tube/Bracket Prescriptions

	FIRST MOLAR			SECOND MOLAR		
	Torque	Tip	Rotation	Torque	Tip	Rotation
<b>Maxillary</b>						
Alexander	−10	0	13	−10	0	10
Andrews	−9	5	10	−9	0	10
Damon (standard torque)	−18	0	12	−27	0	6
MBT	−14	0	10	−14	0	10
Ricketts	0	0	0	0	0	0
Roth	−14	0	14	−14	0	14
<b>Mandibular</b>						
Alexander	−10	0	0	0	0	5
Andrews	−25	2	0	−30	0	0
Damon (standard torque)	−28	2	2	−10	0	5
MBT	−20	0	0	−10	0	0
Ricketts	0	0	0	0	0	0
Roth	−30	1	4	−30	0	4

to place, and they can be used in chains to close small spaces within the arch or prevent spaces from opening. At present, brackets with a built-in ligating mechanism are widely used. They are called “self-ligating” but most really aren’t, because manually opening or closing the mechanism still is required (Fig. 10.37).

A variety of claims have been made as advantages of self-ligating brackets, but it is clear now that almost all have been proved incorrect when clinical outcomes are reviewed. A definitive review of claims versus evidence concluded that self-ligating brackets save a little time in ligation but do not produce a saving of treatment time or better results.<sup>17</sup>

That should not be taken to mean that there is anything wrong with these brackets. The problem has been the advertising, not the product. As a group, the self-ligating brackets perform as well as conventional ones, with no evidence that their latching mechanism makes any positive or negative difference in the outcome of treatment. All three of the ligation types shown in Fig. 10.27 perform well and remarkably similarly. It is important, however, that a self-ligating bracket is made so that an archwire can be tied tightly in place with an external steel ligature when needed. This is needed when stabilization rather than tooth movement is needed, as with a stabilizing wire for orthognathic surgery patients. It is needed even more frequently when the latching mechanism has difficulty in holding a rectangular torquing wire in place.

**Individually Customized Brackets.** Because of individual variations in the contours of the teeth, no appliance prescription can be optimal for all patients, and compensatory bends in finishing archwires often are necessary. Custom brackets for the facial surface of teeth offer the prospect of eliminating almost all archwire bending (i.e., they could provide the perfect straight-wire appliance). The Insignia system now marketed by Ormco uses custom brackets on

each tooth (Fig. 10.38) and is the only commercial product at present that focuses on eliminating wire bending to make the appliance more time-efficient for the doctor and patient.

The first step in producing the Insignia customized bracket is a 3-D scan of the dentition to produce an STL file (now the most frequent input), or a scan of an impression with high-accuracy impression material, or a scan of dental casts from such an impression. Whatever the source, the virtual teeth need to be accurate to least 50-micron resolution.

If a cone beam computed tomography (CBCT) radiograph is available, Ormco processes the crown and root with a proprietary “build up” process, following the contours of the 3-D image to generate a crown and root as a single unit. It is not yet possible to accurately put the alveolar bone into the same set of images, but this is anticipated soon. If a CBCT image is not available, a software calculation of ideal arch form is used to place the roots in the center of the cancellous bone of the jaw.

Based on this “anatomically correct” arch form, the software then aligns the virtual teeth and places them in occlusion, with each tooth position determined from the best-fit buccal cusp orientation. The doctor can adjust the tooth positions at this point, and would need to be aware of the software assumptions as this is done.

This digital information then is used to precisely cut each bracket by using computer-aided design/computer-aided manufacturing (CAD/CAM) technology, so that the slot for each bracket has the appropriate thickness, inclination, and torque needed for ideal positioning of that tooth, and archwires with an arch form established for that patient are supplied. The result is “the ultimate straight-wire appliance,” with wire bending reduced to a minimum if not totally avoided. In a study at the University of North Carolina (UNC), this did result in a significant decrease in both treatment



• **Fig. 10.37** Self-ligating brackets have either a rigid clip (Damon, others), spring clip (Innovation, Speed), or retaining springs (SmartClip) to hold an archwire in the bracket slot. Demonstration of an bracket with a rigid clip that is closed ([A] Damon-Q) and the clip open in a ceramic bracket of the same design ([B] Damon Clear). Esthetic nonmetal brackets are available now in most self-ligating bracket designs. (C) The Innovation-X bracket, which has a latching clip that does not put pressure on small round wires but does tightly hold rectangular wires in place. (D) The Speed bracket, which is less than half the width of the other brackets shown here, uses a nickel–titanium (NiTi) spring clip. Both these provide additional springiness, which is especially useful when steel archwires are used. (A and B, courtesy Ormco Corporation, Monrovia, CA; C, courtesy Dentsply-Sirona, Cupertino, CA; D, courtesy Speed System Orthodontics, Cambridge, Ontario, Canada.)

time and the number of archwire changes compared with directly or indirectly bonded conventional brackets, but more of the decrease was attributed to indirect bonding than the custom brackets.<sup>18</sup> That leads to the interesting thought that careful indirect bonding has an excellent cost–benefit ratio, and that custom brackets add to the efficiency of treatment, but perhaps with a less favorable cost–benefit ratio.

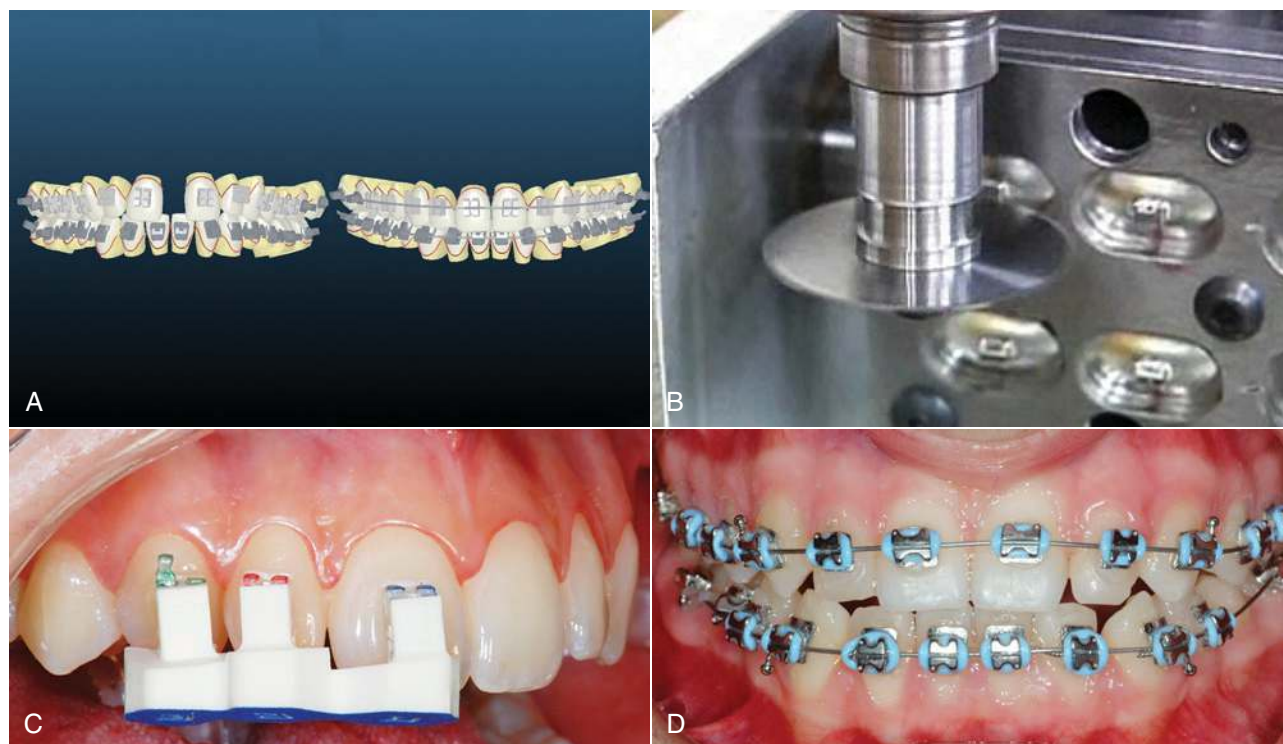What happens when one of the custom brackets is lost and requires replacement and rebonding, or is loose and requires rebonding? Because the specifications for each bracket can be maintained in computer memory, it is possible to obtain a replacement bracket and bonding template within 2 to 3 weeks. Rebonding a loose bracket is done most efficiently by using the original bonding template, which should be kept with the patient's records for this possible reuse. In its absence, if alignment of the teeth has been completed, the archwire can be used to position the bracket.

At present, however, that is not the biggest problem. Even a set of modern CAD/CAM brackets formed on individual dental casts is still focused largely on dental intra-arch relationships, and so, for example, the patient with Class II malocclusion who requires

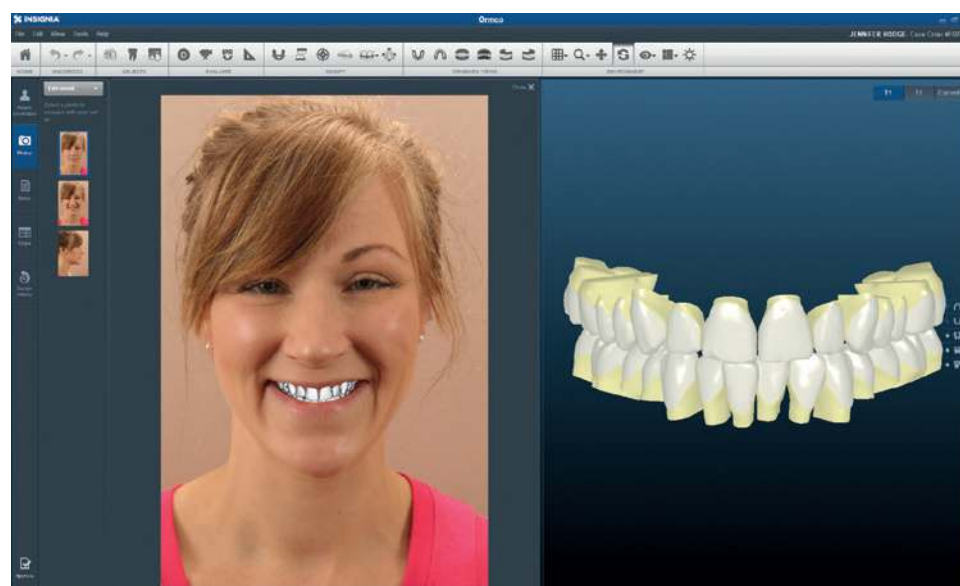
slightly more upright maxillary incisors and more proclined lower incisors would still receive brackets with “ideal” incisor inclinations. It remains important to introduce coordination with the patient's individual skeletal and soft tissue pattern into this type of design.

Attempts are being made now to integrate images of tooth–lip relationships into the database for Insignia, so that tooth display on smile is built into where the brackets are placed on the anterior teeth (Fig. 10.39), and moving the brackets automatically changes the tooth display. It is likely that at the point of approving the set-up for making the brackets, it soon will be possible for the orthodontist to check not only on whether the arch form assumptions are correct, but also to adjust where the bracket is to be placed on the teeth to obtain the best incisor display. It is not possible to get this just by adjusting the bracket slot angulation and prescription; instead, the bracket must be placed properly on the teeth relative to the lips.

Even at that point, the custom brackets and archwires do not make the dental arches fit together. That relies on interarch relationships, which usually are provided by interarch elastics and are mostly under the control of the patient.



• **Fig. 10.38** The Insignia system is built around the use of a custom prescription bracket for each individual tooth, coupled with custom archwires with that patient's individual arch form, to produce the "ultimate straight-wire appliance." A polyvinyl siloxane (PVS) impression is used to obtain accurate dental casts, which are scanned into computer memory. (A) This data set is used to place virtual brackets on each tooth and develop a template of the change needed to obtain ideal occlusion. (B) The digital data are used to mill a custom prescription slot for each bracket that incorporates the in-out, tip, and torque needed to position each tooth. (C) Then bonding jigs are fabricated so that each bracket can be placed in the planned location. (D) The appliance in the mouth with an archwire in place. The Insignia brackets are now available in a self-ligating form. (CourtesyOrmco Corporation, Orange, CA.)



• **Fig. 10.39** In the planning screens for Insignia, a view of the display of teeth on smile now appears alongside the view of the dentition, so that the effect on the smile of a change in the position of the teeth can be seen immediately. This is the first system that includes the appearance of the teeth in a computerized treatment planning system.



### Lingual Appliances

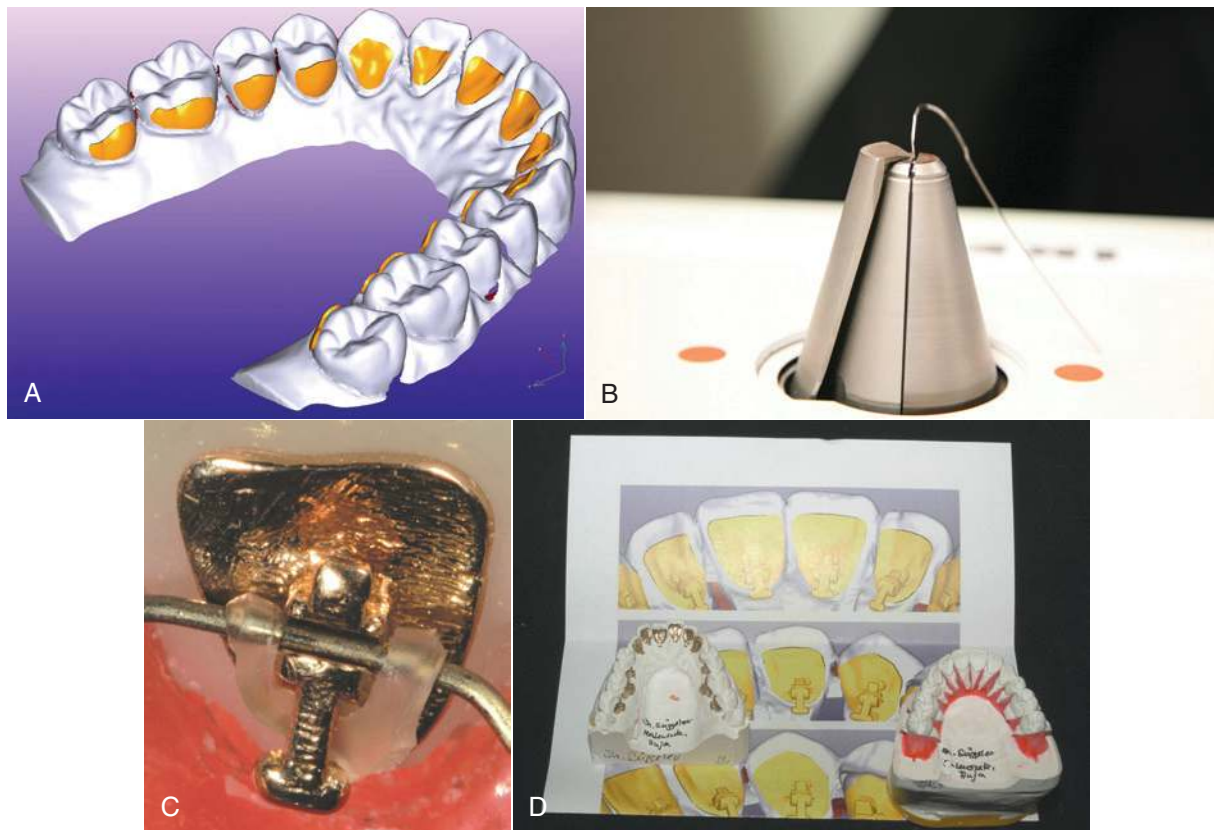
A major objection to fixed orthodontic appliances always has been their visible placement on the facial surface of the teeth. This is one reason for using removable appliances and is the major reason for the current popularity of clear aligners. The introduction of bonding in the 1970s made it possible to place fixed attachments on the lingual surface of teeth to provide an invisible fixed appliance, and brackets designed for the lingual surface were first offered soon after bonding was introduced. There were multiple problems in producing a bracket that intruded only minimally into tongue space and was at least reasonably easy to use. In the United States, most orthodontists who experimented with the U.S.-designed lingual appliances available in the 1980s abandoned this approach as more trouble than it was worth, and lingual appliance treatment all but disappeared until newer versions were brought in from Europe and Asia.

One successful German appliance design, Incognito, was purchased by 3M-Unitek in 2012 and widely marketed. It uses a custom precious metal pad for each tooth that covers a large area on the lingual surface. Low-profile brackets designed so the archwire can be inserted from the top are attached to the pad (Fig. 10.40).

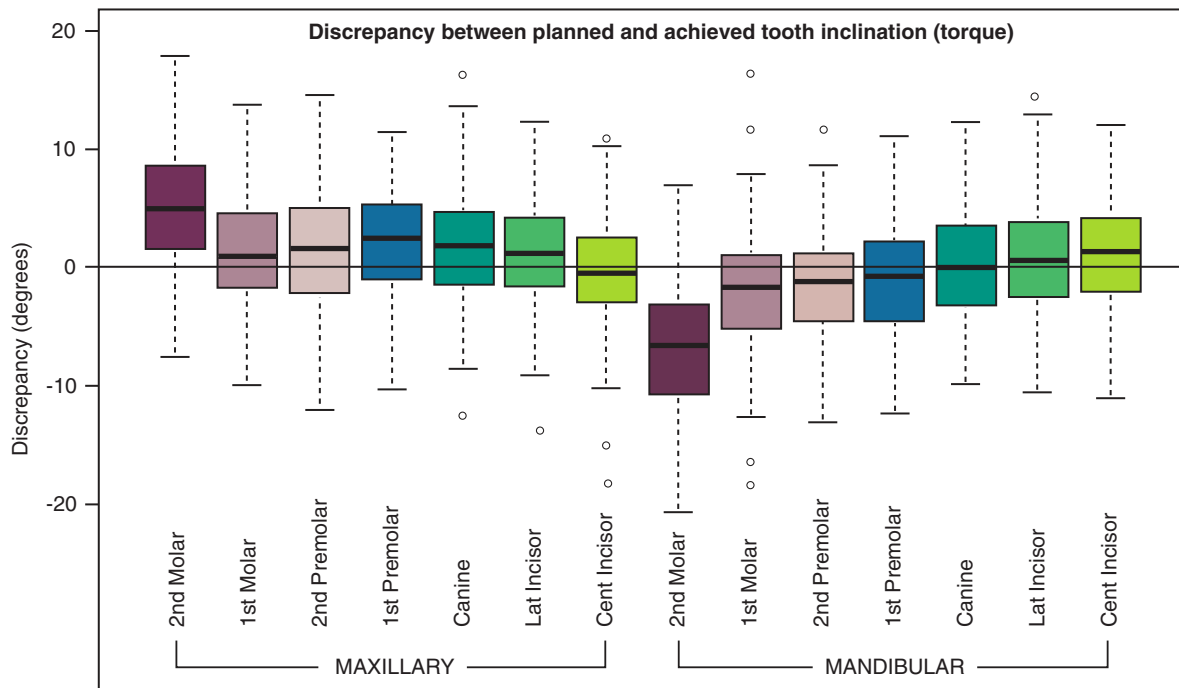
Wire bending is eliminated by using wire-bending robots to form the archwires.

A major test for any of the computer-assisted appliance systems is the accuracy with which the planned outcome (established during manufacture of the customized appliance) actually is achieved. A 2011 study, using a new method for analyzing the difference between the computer template and the actual result, showed that Incognito outcomes were quite accurate representations of the template, except that second molars were not positioned as precisely as the other teeth (Fig. 10.41).<sup>19</sup> That led to algorithm changes to improve second molar positions. Feedback of that type is needed for all the computer-assisted appliances, both to improve the accuracy of the system and to allow better evaluation of the method.

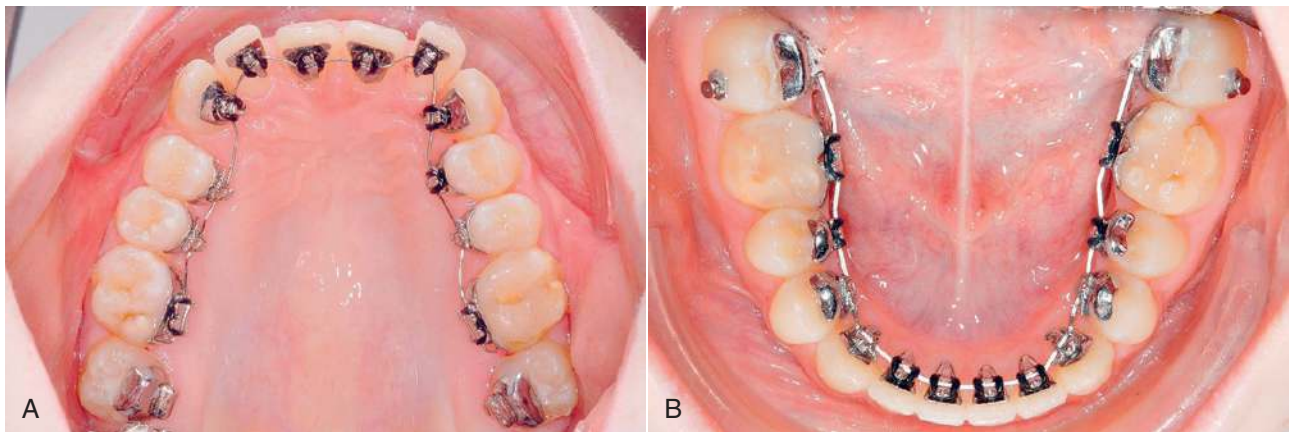
A German successor to Incognito (Fig. 10.42), which uses a different bracket design, 3-D printing for production of brackets with precise slots (its first commercial use in orthodontics), and computer-formed archwires, now is becoming available. It has been shown to significantly decrease treatment time compared with Incognito,<sup>20</sup> and to compare favorably with Incognito in producing the planned outcomes.<sup>21</sup> At present, lingual appliances are much more popular in Europe and Asia than in the United



• **Fig. 10.40** (A) The approach for one successful custom lingual appliance (Incognito, 3M-Unitek, Monrovia, CA) is based on laser scans of casts after the teeth are separated and set in ideal position. The location of the custom bracket pad for each tooth is established, and wax patterns are made for (B) gold castings of custom bracket pads for each tooth. The use of these custom pads greatly improves retention of the bonded lingual brackets. A standard bracket (not individualized for each tooth) that allows vertical insertion of archwires and the use of elastomeric or wire ligatures (C) is attached to the custom pads, and the completed appliance (D) is supplied ready for indirect bonding. Note that extraction of maxillary first premolars is planned for this patient.



• **Fig. 10.41** Box plots depicting the difference between the planned and achieved inclination (torque) by tooth type in a sample of 94 patients treated using the Incognito lingual appliance (from TopService GMBH, Bad Essen, Germany). Each box shows the median difference from the plan (*dark line*) and the amount of deviation for the median 50% of the patients. Range and extreme outliers are shown by the whiskers and small circles, respectively. Note that for most of the sample and for all teeth except second molars, mean inclination differences were very small and differences of greater than 6 degrees of inclination were rare. (Courtesy Dr. D. Grauer.)



• **Fig. 10.42** The WIN appliance, a successor to Incognito from its designer, uses low-profile metal brackets produced by three-dimensional printing with a proprietary alloy. The greater precision of this technique allows smaller tolerances in bracket slot size. (A) Maxillary arch with a computer-formed nickel-titanium (NiTi) archwire for initial alignment. (B) Mandibular arch with a computer-formed steel archwire toward the end of treatment. Note the bonded attachments on the second molars for Class II attachments and the partial occlusal coverage for better bonding of the molar tube. (Courtesy Dr. D. Wiechmann.)

States. That seems likely to change, but how much and in which direction remains unpredictable.

### Making Appliance Choices Based on Patient Preference

There are considerable differences in what patients feel is the most attractive appliance, the one they would prefer to have.<sup>22</sup> Most notably, this is related to patient age, but there are some minor

gender differences. For 9- to 11-year-olds, the preference is either shaped brackets such as WildSmiles (WildSmiles Braces, Omaha, NE) with or without colored elastomeric ties, or mini-twin brackets with colored elastomeric ties. Inconspicuous esthetic brackets are not a high priority for this group. In the 12- to 14-year age group, clear aligners and esthetic brackets are more highly prized, but mini-twin brackets with colored ties and the shaped brackets all

are rated similarly. Clear aligners rarely are compatible with partially erupted teeth and continuing growth.

For 15- to 17-year-olds, clear aligners or esthetic brackets with a clear wire (see discussion later) are considered most attractive. For this group, clear aligners can make sense because the permanent teeth are fully erupted and rapid growth is completed. Adults prefer lingual appliances, clear aligners, or esthetic brackets, especially when combined with a clear wire. The spectrum changes from unique and colorful for children to esthetic appliances with older adolescents and adults. With this combination of acceptable alternatives, it is possible to meet esthetic demands and accomplish the biomechanics for almost every patient.

### Arch Form and Archwire Fabrication

#### Selection of Arch Form for Individual Patients

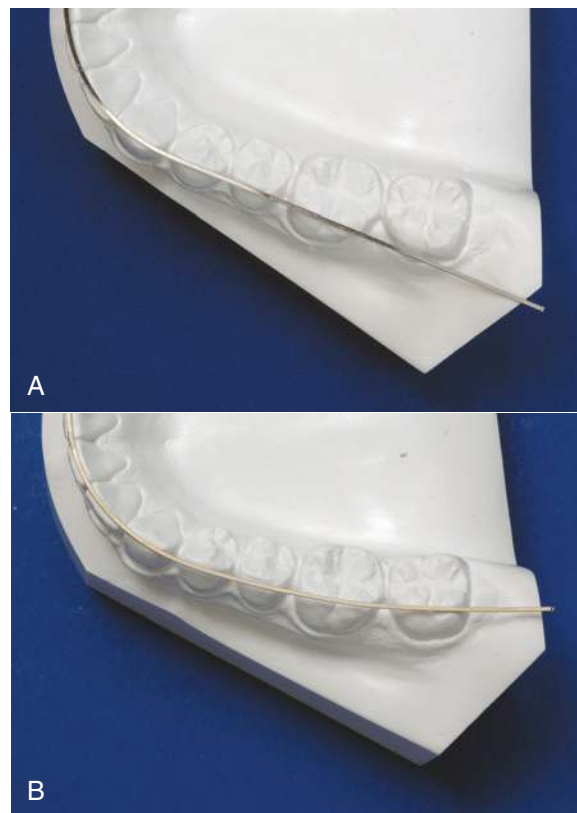
**Preformed Arch Wires.** As another contributor to increased efficiency, preformed archwires are an important part of the modern edgewise appliance, whether individualized custom brackets are used or not. When NiTi and beta-titanium (beta-Ti, sold commercially as TMA) wires are needed, there is no choice but to use preformed archwires because these wires are almost impossible to shape to arch form without special tools. What arch form should be employed?

The concept that dental arch form varies among individuals is driven home to most dentists in full-denture prosthodontics, where it is taught that the dimensions and shape of the dental arches are correlated with the dimensions and shape of the face. The same variations in arch form and dimensions of course exist in the natural dentition, and it is not the goal of orthodontic treatment to produce dental arches of a single ideal size and shape for everyone.

The basic principle of arch form in orthodontic treatment is that within reason, the patient's original arch form should be preserved. Most thoughtful orthodontists have assumed that this would place the teeth in a position of maximum stability, and long-term retention studies support the view that posttreatment changes are greater when arch form is altered than when it is maintained (see [Chapter 18](#)).

As a more general guideline, if the maxillary and mandibular arch forms are incompatible at the beginning of treatment, the mandibular arch form should be used as a basic guide. In many patients with Class II malocclusion, the maxillary arch is narrow across the canines and premolars and should be expanded to match the lower arch as overjet is reduced. Obviously, this guideline would not apply when mandibular arch form is distorted. That can happen in many ways, the most common being lingual displacement of the mandibular incisors by habits or heavy lip pressures. Although some judgment is required, the arch form desired at the end of orthodontic treatment should be determined at the beginning, and the patient's occlusal relationships should be established in the context of this arch form.

An excellent mathematical description of the natural dental arch form is provided by a catenary curve, which is the shape that a loop of chain would take if it were suspended from two hooks. The length of the chain and the width between the supports determine the precise shape of the curve. When the width across the first molars is used to establish the posterior attachments, a catenary curve fits the dental arch form of the premolar–canine–incisor segment of the arch very nicely for most individuals. For all patients, the fit is not as good if the catenary curve is extended posteriorly from the first molars, because the dental arch normally curves slightly lingually in the second and third molar region ([Fig. 10.43A](#)). When they were first offered,



• **Fig. 10.43** (A) Preformed archwire with catenary arch form on a lower dental cast from an untreated patient. Note the good correspondence between the arch form and the line of occlusion, except for the second molars. (B) The Brader arch form for preformed archwires is based on a trifocal ellipse, which slightly rounds the arch in the premolar region compared with a catenary curve and constricts it posteriorly. An archwire formed to the Brader curve fits much better in the second molar region for this untreated patient than a catenary curve.

most preformed archwires were based on a catenary curve, with average intermolar dimensions. With this arch form, modifications by the orthodontist to accommodate for a generally more tapering or squarer morphology are appropriate, and the second molars must be “tucked in” slightly.

Another mathematical model of dental arch form, originally advocated by Brader and often called the *Brader arch form*, is based on a trifocal ellipse. Its anterior segment closely approximates the anterior segment of a catenary curve, but the trifocal ellipse gradually constricts posteriorly in a way that the catenary curve does not ([Fig. 10.43B](#)). The Brader arch form therefore will more closely approximate the normal position of the second and third molars. It also differs from a catenary curve in producing somewhat greater width across the premolars.

Recently, several manufacturers have offered preformed archwires that appear to be variations of the Brader arch, with advertisements that suggest these wires are more compatible with arch expansion therapy. Expansion across the premolars often is thought to have esthetic advantages; whether the modified arch form to produce this has any effect on stability is unknown. More refined mathematical descriptions of typical human arch forms have been proposed,<sup>23</sup> and it is likely that better mathematical models will improve the arch forms for preformed archwires in the future.



It is important to keep in mind that neither the ligation method nor the prescription adjustments placed in straight-wire brackets have anything to do with arch form, which is still established by the shape of the archwires. Arch form is particularly important during the finishing stage of treatment, when heavy rectangular archwires are employed. Preformed archwires are best considered as “arch blanks” and sometimes are listed in the catalogs in that way. The name is appropriate, because this properly implies that a degree of individualization of their shape will be required to accommodate the needs of patients.

**Wire-Bending Robots.** Another approach to the goal of reducing the amount of clinical time spent bending archwires is to use a computer-controlled machine to shape the archwire as desired. If the effort to fabricate a complex archwire were eliminated, inexpensive “plain vanilla” brackets could be used instead of going to the trouble of producing custom brackets with a specific prescription for every tooth. A less complex bracket also could be smaller and have a lower profile.

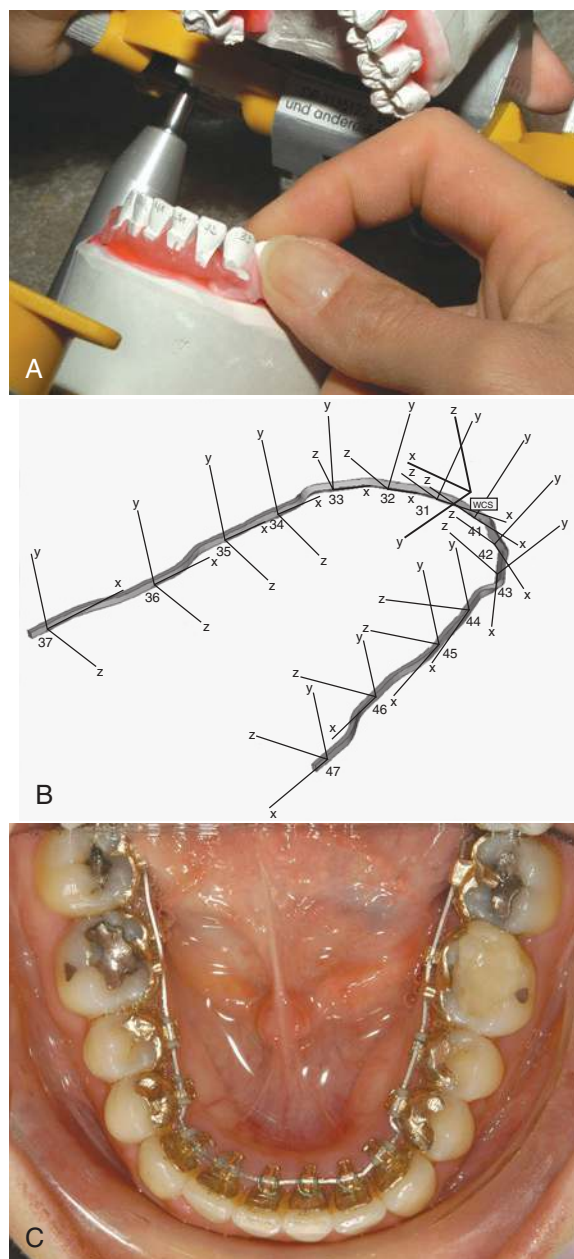
In lingual orthodontics, the scanned casts needed for fabrication of custom bracket pads also provide the data needed to generate computer-fabricated archwires (Fig. 10.44). For labial orthodontics, SureSmile (OraMetrix, Richardson, TX) uses data acquired via a direct intraoral scan or CBCT to shape finishing archwires to the desired arch form and adjust it at each bracket to provide correct in–out, angulation, and torque bends.

In the SureSmile technique, it is recommended to obtain an initial intraoral scan or CBCT to provide a diagnostic model in order to produce a treatment simulation (digital set-up) to help in making initial treatment decisions. The orthodontist can view and modify this as an aid in planning treatment. If assistance in diagnosis and treatment planned is not desired, the diagnostic model step can be omitted.

The first step in treatment is to bond brackets either directly or indirectly—the only requirement is that the characteristics of the brackets be known. At that point, or if desired, somewhat later in the initial stage of treatment, a new intraoral scan or CBCT is obtained that now incorporates the precise position of each bracket, and a set-up is produced by the SureSmile technicians for review and modification by the orthodontist. Once the position of each bracket is known and the final desired position of all teeth is prescribed with the set-up, a robot forms rectangular archwires (usually superelastic NiTi, but other archwire materials can be specified by the doctor) that are sent to the orthodontist. These wires bring the teeth to their final positions (Fig. 10.45).

In a study carried out at the University of Indiana, the first to provide good data for SureSmile outcomes in nonextraction treatment,<sup>24</sup> a group of 63 conventionally finished patients were compared with 69 SureSmile patients treated in the same office by the same clinician. The SureSmile group had a significantly shorter time in fixed appliances (mean of 23 versus 32 months). Although the SureSmile group had better scores for alignment and rotation correction and fewer interproximal spaces, the conventional group had better scores for both faciolingual (torque) and mesiodistal (tip) root angulation. The study concluded that the shorter treatment time with SureSmile was due at least in part to less severe malocclusions and less detailed finishing and that a randomized clinical trial would be needed to determine whether the use of computer-formed finishing wires really reduced treatment time for comparable outcomes.

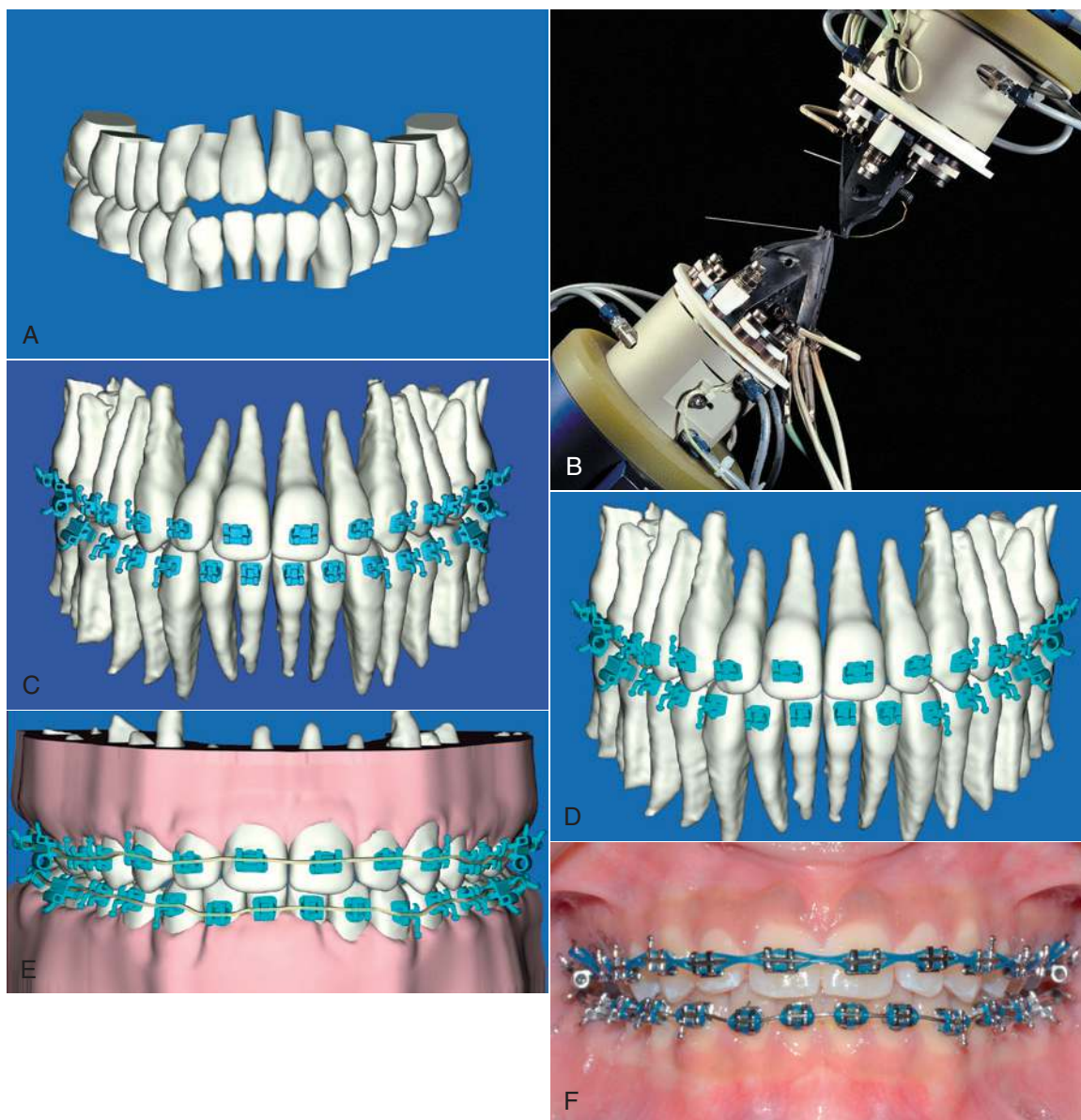A study done at the University of Minnesota used digital superimposition techniques to carefully compare the actual final tooth position obtained by using the robotically formed archwires



• **Fig. 10.44** Archwires for the Incognito lingual appliance are formed with a wire-bending robot, using an ideal set-up of the teeth that were scanned in preparation of the bracket pads. (A) Ideal set-up in preparation on an articulator. (B) Archwire coordinates for using a wire-bending robot to form an archwire. (C) Archwire in place after robotic fabrication. (Courtesy Dr. D. Wiechmann.)

versus the predicted and desired position. In general, the final tooth position was remarkably close to what had been prescribed, but there tended to be a lack of full expression of arch form and torque on second molars. As we have noted previously, rectangular superelastic archwires provide lower moments within brackets than are ideal for both tip and torque, and they have less stiffness for arch form control, so it is not surprising that full expression of arch form and terminal torque may not be realized.<sup>25</sup>

**Clear Polymer Archwires.** Orthodontic archwires formed from clear polymers offer two potential advantages over stainless steel or titanium: better esthetics because the wire can be clear or the



• **Fig. 10.45** Various stages of the SureSmile system, which uses digital technologies for treatment simulation and treatment assist. (A) A SureSmile diagnostic model, produced from an intraoral scan, which can be used for treatment simulation when making initial planning decisions. No roots are visible at this stage. (B) A wire-bending robot making the precise bends in a custom wire designed as shown in the following images. (C) A SureSmile therapeutic model constructed from a cone beam computed tomography (CBCT) scan so that the roots are visible. The exact bracket position and prescription are captured at this stage for use in designing the custom arch wire. (D) The final SureSmile plan in which the teeth are virtually moved into the desired finished position to obtain ideal alignment, root position, and occlusion. Note the change in root position compared with (C). (E) The custom wire designed to achieve the final tooth position in the plan (D). (F) The wire designed in (E) and fabricated by the robot, after placement in the patient's mouth.

same color as the teeth, so the wire becomes almost invisible when used with ceramic brackets, and physical properties that may equal or exceed those of metal archwires. From 2010 to 2012 they were marketed enthusiastically—and then problems with wire stability and discoloration diminished the enthusiasm to the point that further progress will be needed to make them an acceptable choice in clinical treatment.<sup>26,27</sup>

**Coated Archwires.** Another option for esthetics is archwires coated with white or more tooth-colored materials. White wires are rated as highly as clear wires by adults. Initially, these coatings were easily lost. More recently the coatings have become better, but their esthetic value still is at risk over time.

At this point, it seems likely that most fixed orthodontic appliances of the not-too-distant future will be individualized with scans of



• **Fig. 10.46** Bone screw types for use as orthodontic temporary anchorage devices (TADs). Note the differences in the shape of the head and collar, the shape (form) of the screw and the screw threads, and the pitch (separation) of the screw threads. Each of these screws requires a special driver that fits the base of the head, and the method for attaching a wire or spring to the screw is different in each case. The optimum characteristics of a bone screw for orthodontic applications depends primarily on where it is to be placed and the amount of force it will have to withstand, and secondarily on its difficulty or ease of use.

the tooth surfaces and computer technology. It is still too soon to tell which of the competing technologies will prevail. Will it be custom brackets that allow the use of preformed archwires with little or no manual wire bending, custom archwires formed by a wire-bending robot, or a sequence of nonadjustable custom wires produced for that patient? Or something we haven't even thought of yet?

## Temporary Anchorage Devices

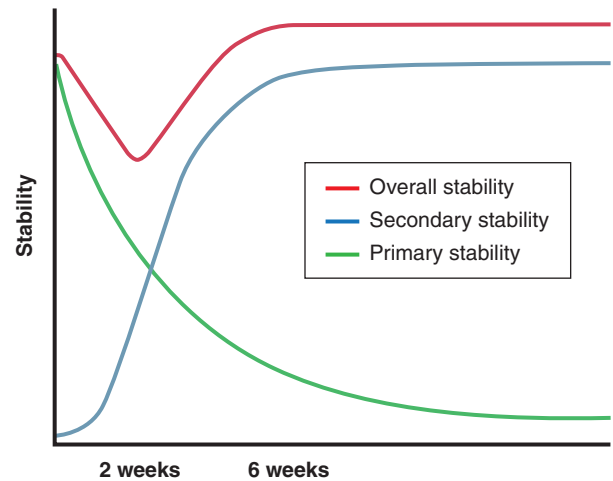
With the rapid development and commercialization of bone screws and miniplates for orthodontic anchorage devices, there is now a remarkable diversity in these items. The key characteristics of any orthodontic temporary anchorage device (TAD) are (1) its short- and long-term stability, the major indicator of success or failure, and (2) its ease of use, which includes both its placement and the features of the attachment that extends into the oral cavity. The goal here is to discuss what has been learned about desirable and undesirable features of this increasingly important part of the orthodontist's armamentarium.

### Bone Screws

A wide variety of bone screws for use as intraoral TADs now are available. It is interesting that use of bone screws now has somewhat declined as clinicians have become more aware of the situations in which they perform well and no longer try to solve almost all problems with them.

Three reasonably typical screws for use as TADs are shown in Fig. 10.46, and desirable characteristics are summarized in Box 10.1. Although stainless steel screws were marketed initially, most screws now are formed from titanium (purity grades I to IV) to take advantage of its greater biocompatibility. From the perspective of both stability and ease of use, it is clear now that screws for alveolar bone should have different characteristics than screws for the denser bone of the palate or mandible.

**Stability.** *Short-term or primary stability* is determined by mechanical retention of the screw in bone, which depends on bone properties, the engineering design of the screw, and placement



• **Fig. 10.47** Primary stability, which is created by mechanical retention of a bone screw in bone, is maximal immediately after the screw has been placed and declines rapidly as bone remodeling occurs around the screw. Secondary stability, created by a biologic union between the screw and bone, increases over time. Clinical stability is the sum of primary and secondary stability. Note that clinical stability declines to a minimum at about 2 weeks after insertion, then (if all goes well) stabilizes at a somewhat larger value than the initial primary stability at about 6 weeks.

technique. *Long-term or secondary stability* is defined by the biologic union of the screw to the surrounding bone. It is determined by the implant surface, bone characteristics, and bone turnover (especially in the context of cortical versus medullary bone) and is affected by the implant surface and the mechanical system used. To obtain good secondary stability it is important to limit micro-movements that could lead to bone resorption and formation of a fibrous capsule. Over time, primary stability decreases while secondary stability increases; clinical stability is the sum of primary and secondary stability and is the major factor in clinical success (Fig. 10.47).

Factors in stability-related success that have been shown to be important are:

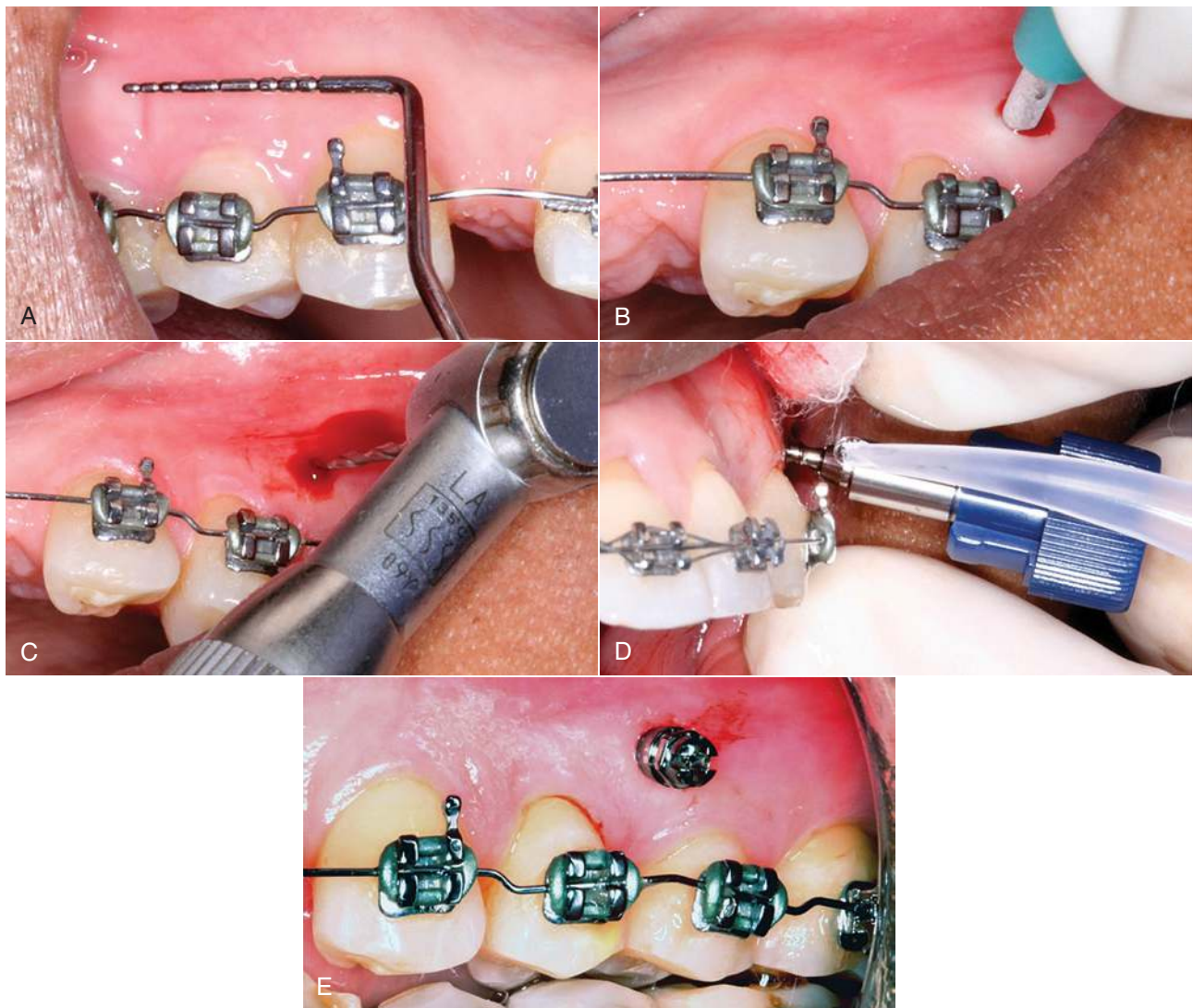- *The pitch of the screw threads* (i.e., how close the threads are to one another). A tight pitch means the threads are close, a loose pitch means they are farther apart. The denser the bone, the closer the threads should be. It has become apparent that most of a screw's resistance to being dislodged comes from contact with cortical bone and relatively little from medullary bone. Because the layer of cortical bone is thin in the dental alveolus, a tighter pitch of the threads near the head of the screw gives greater contact with the cortical bone, higher pull-out strength, and better primary stability.<sup>28</sup>
- *The length of the screw.* If the amount of contact with cortical bone is the major factor in stability, and the amount of contact with medullary bone makes little difference, it seems apparent that short screws should perform as well as longer ones. But the amount of soft tissue overlying the bone is an important consideration; screws extending into the base of the zygomatic process need to be longer to reach some cortical bone. A long screw that passes all the way through the alveolus to reach cortical bone on the other side (called a *bicortical screw*) does provide greater stability,<sup>29</sup> but for most applications this is not worth the greater invasiveness.



- *The diameter of the screw.* A screw that is to be placed into the alveolar process must be narrow enough to fit between the teeth. Bone screw TADs currently on the market can be as narrow as 1.3 mm and as wide as 2 mm. The success rate drops when the screw is narrower than 1.3 mm. Within the 1.3- to 2.0-mm diameter range, stability and survival are much more strongly related to the amount of cortical bone contact rather than the screw diameter, but a larger diameter screw does show better primary stability when heavy force is applied. At this point, the data suggest that root proximity is not a major factor in long-term stability of the screw<sup>30</sup> and that, at least in dogs, penetration of the periodontal ligament does not lead to ankylosis.<sup>31</sup> If an alveolar bone screw is less than 0.5 mm from

the periodontal ligament, however, the success rate drops significantly.<sup>32</sup> In humans, the possibility of ankylosis as the screw socket heals cannot be ruled out, so avoiding contact with tooth roots probably is important for adolescent patients.

- *The form of the tip.* All orthodontic miniscrews are self-tapping (i.e., they create their own thread as they advance). There are two self-tapping designs: thread-forming and thread-cutting. The difference is the presence of a cutting flute on the tip of the thread-cutting screw. A thread-forming screw compresses the bone around the thread as the screw advances, obtains better bone-to-screw contact, and is better adapted for use with alveolar bone. The flutes on a thread-cutting screw improve penetration into denser bone. It appears that thread-cutting



• **Fig. 10.48** The sequence of steps in insertion of an alveolar bone screw. (A) Marking the location for the screw, which should be in gingiva rather than mucosa if possible but must be high enough to accommodate any vertical changes in tooth position. Note the bends in the archwire that were used to create some root separation in the area where the screw is to be placed. (B) Use of a tissue punch, which is needed if a hole is to be drilled into the bone or if the screw is placed through mucosa, but may not be needed for a screw placed through gingiva. (C) Drilling a pilot hole through the cortical plate (which is needed only if the cortical bone is relatively thick). (D) Placing the screw, which will then be screwed into position using a special driver shaped to fit the screw head. (E) The screw in position, ready for use.

screws perform better in the mandibular ramus, mandibular buccal shelf, zygomatic buttress, and palate.<sup>33</sup>

For a more detailed review of the factors that influence clinical stability and success rates in major tooth movement, see Lee et al.<sup>34</sup>

**Ease of Use.** For bone screws, ease of use has two components: how easy or difficult it is to place the screw (Fig. 10.48) and how easy it is to use the exposed screw head as an attachment for springs or wires.

Factors in ease of screw placement include:

- *Whether a pilot hole is needed.* Self-drilling screws do not need a pilot hole beyond the cortical plate and can penetrate the cortical plate if it is thin.<sup>35</sup> Screws of this type now have largely replaced screws that require a pilot hole because they can be used either way, with the decision being made at the time of insertion. If the cortical plate is difficult to penetrate, a pilot hole can decrease insertion torque and potential for screw fracture.
- *Whether a tissue punch is needed.* A tissue punch through the gingiva is rarely needed unless a pilot hole is to be drilled but frequently is needed in unattached tissue to keep gingival tissue from wrapping around the screw thread.
- *The ease or difficulty of turning the screw as it is inserted, while keeping pressure on it.* Once the screw threads engage, pressure on it is no longer needed, but strong resistance to turning the screw at that point reflects high insertion torque. This increases primary stability, but it can lead to fracture of the screw, increased microdamage to the bone, and decreased secondary stability. Moderate insertion torque provides enough primary stability without causing excessive bone compression and subsequent remodeling. A driver made to fit around the head of the specific screw type is needed for insertion, and some systems offer a torque-controlled instrument for placement of their bone screws.
- *The design of the area of the head to which a wire, spring, or elastomeric will be attached.* It is desirable to have an attachment that locks this force delivery device in place. A slot in the head that would allow insertion of a heavy wire would make it possible to change the direction of force, but the resulting moment is likely to twist or otherwise loosen the screw.

In summary, bone screws can be used readily as either direct or indirect anchorage (Fig. 10.49). The desirable characteristics of a bone screw TAD are listed in Box 10.2. This serves as a guide in selecting the screw for a specific area and use, and suggests that

efficient practice requires having more than one type of bone screw available.

**Linked Screws in Palatal Anchorage.** As we have noted previously, the dense bone of the palate is an excellent place for bone screws, with the greatest bone density found anteriorly and lateral to the midline.<sup>36</sup> Screws in the palate almost always are used in pairs and often are linked together to stabilize a small plate that has attachments to reach the dentition (Fig. 10.50). This linkage of screws offers the same advantage of greater resistance to force as two or more screws holding a miniplate. Linking palatal screws differs from the miniplates discussed hereafter in that the linked attachment usually does not offer the ability to change the direction of force by adding an extension. With palatal anchorage, direct anchorage usually is employed for intrusion of posterior teeth. For repositioning teeth along the line of the arch (as in the maximum retraction space closure shown here), indirect anchorage is the usual choice.

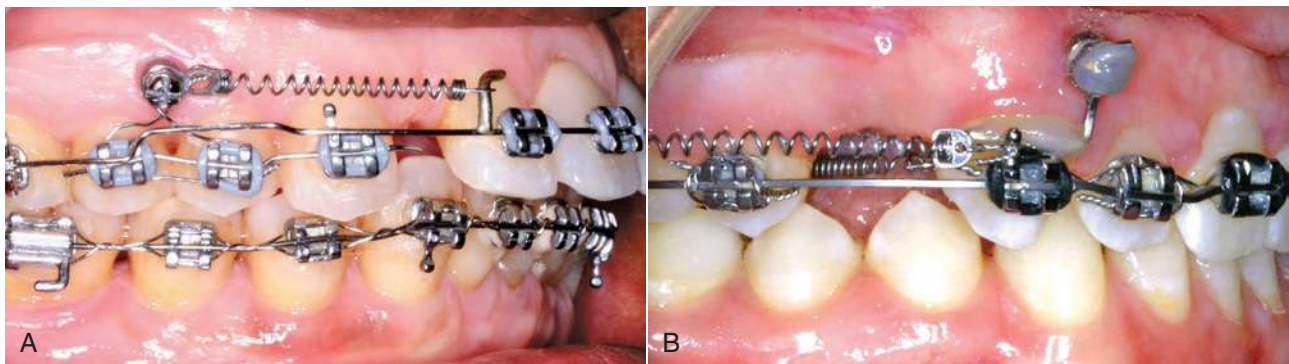
### • BOX 10.2 Design Factors for Bone Screws

#### Related to Stability and Success

- Pitch of screw threads: tight, not loose
- Length of screw
  - Alveolar bone, approximately 6 mm
  - Palatal or mandibular bone, approximately 4 mm
  - Base of zygomatic bone, 6 to 8 mm
- Diameter of screw
  - Minimum 1.3 mm
  - Maximum 2.0 mm
- Shape of screw: conical preferred
- Form of tip: thread-cutting preferred
- Bicortical versus monocortical: monocortical preferred
  - Minimal stability advantage for bicortical
  - Decreased ease of use

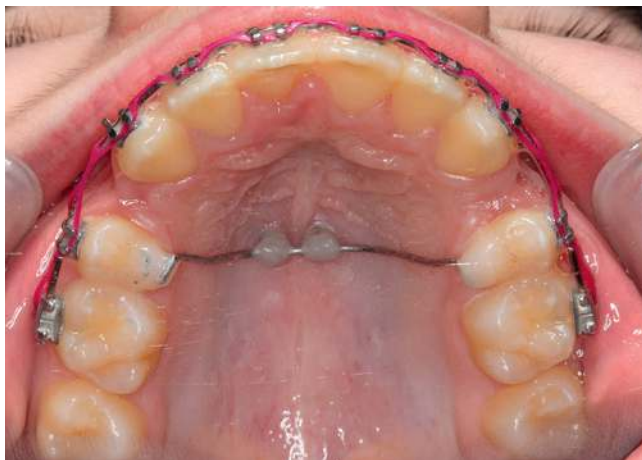#### Related to Ease of Use

- Pilot hole: better if not necessary
- Soft tissue punch: better if not necessary
- Insertion torque: better if low
- Insertion device: better if simple
- Direct versus indirect anchorage: both acceptable



• **Fig. 10.49** (A) An alveolar bone screw used for direct anchorage usually serves as the attachment point for a superelastic nickel–titanium (NiTi) spring, as in this use to retract protruding maxillary incisors. (B) Alveolar bone screws also work well for indirect anchorage, when a rigid attachment from the screw is used to prevent movement of anchor teeth, as in this patient in whom the maxillary posterior teeth are being moved forward via a spring to the stabilized canine.





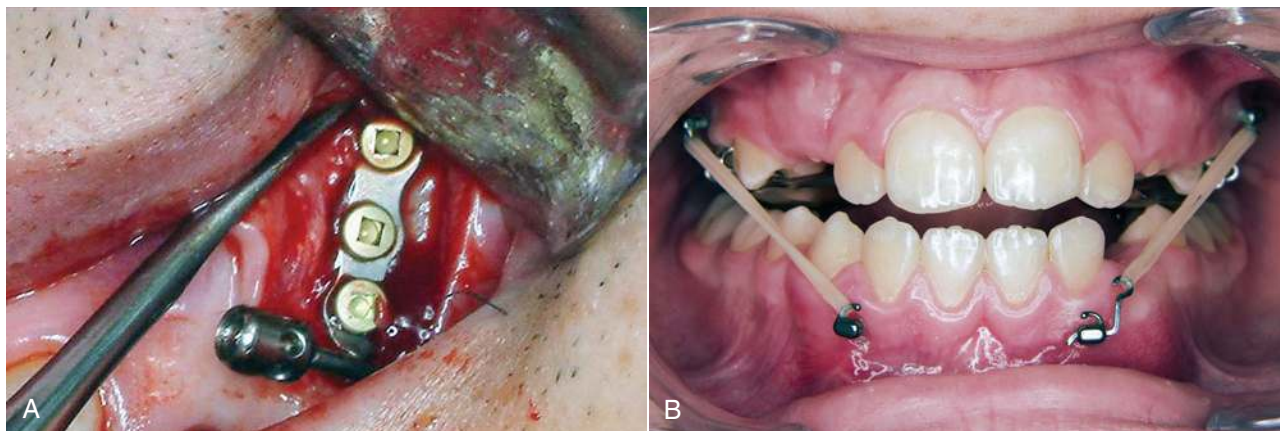
• **Fig. 10.50** Screws in the palate usually are in pairs that are linked by a plate or heavy wire, as shown here. The advantage over using a single screw on each side is that neither screw can rotate when they are tied together, but single screws can rotate, and this greatly increases the chance that the screw will loosen and be lost.

### Miniplates

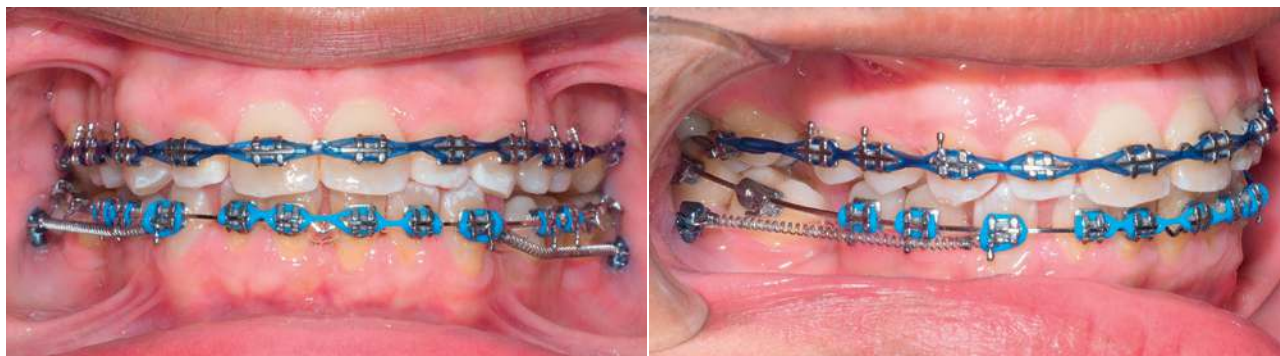Miniplates have two major components: the plate itself, which is contoured to fit on the surface of the bone where it attached, and a connector that penetrates into the mouth. Ideally, this is at the junction of the fixed gingival tissue and alveolar mucosa, but the location of the connector is not a critical variable. The connector is designed so that superelastic NiTi springs (or less desirable elastomers) can be attached to it for direct anchorage, or wires can be attached for indirect anchorage.

The most frequent location for miniplates as anchorage for repositioning maxillary teeth vertically or sagittally is at the base of the zygomatic arch (but the linked screws in the palate are used even more often for the same purpose). Anchors in this area combined with anchors on the anterior surface of the mandible below the incisors (Fig. 10.51) also are used for Class III growth modification (as discussed in Chapter 13).

For repositioning multiple mandibular teeth, either bone screws or miniplates are most often placed on the buccal shelf of bone below the lower molars (Fig. 10.52), although the anterior surface







• **Fig. 10.51** (A) A miniplate placed at the base of the zygomatic arch requires creating a flap to expose the bone and must be contoured so it fits closely to the bone surface. In this location it is above the roots of the teeth and is ideally positioned as an anchor for mesiodistal movement of the maxillary teeth. (B) A miniplate on the mandible to serve as an attachment for Class III elastics. Note that a segment of wire has been used on one side to move the attachment point so that the elastic will not impinge on the gingiva. Being able to move the attachment point is a major advantage of using miniplates rather than single screws. (Courtesy Dr. H. DeClerck.)



• **Fig. 10.52** A bone screw into the buccal shelf of bone below the mandibular molars provides excellent anchorage for moving or stabilizing mandibular posterior teeth and is easier to use than the anterior surface of the ramus.



					
Screw Number	2	3	2	3	4
Success Rate	23/26 88%	11/11 100%	25/26 96%	69/69 100%	20/20 100%

• **Fig. 10.53** Success rates for plates of different designs and number of screws placed at the base of the zygomatic arch by the same clinician. Note that success rates were quite high in all these applications, but failures were more likely with three screws than with two, and no better with four screws than with three—so three screws are preferred. (Courtesy Dr. T. Wu.)

of the ramus is an alternate possibility. Miniplates designed for this area are notched so that the vertical component of force direction can be varied.

As with single bone screws, the key characteristics for miniplates are stability and ease of use. The major determinants of stability are:

- The number of screws with which the plate is attached, which really is determined by the bone thickness and density in that area. The success rate for plates of four designs placed by the same clinician at the base of the zygomatic arch is shown in Fig. 10.53. With these designs and with a straight-line plate for that area, it appears that three screws provide more stability than two, but nothing additional is gained with four screws. For the palate, two linked screws usually are adequate.
- The age of the patient. As Table 10.5 shows, the number of failures with miniplates at the base of the zygomatic arch or on the anterior mandible in both North Carolina and Belgium was much greater in young patients who had not yet entered puberty. This determines when to use Class III elastics to maxillary and mandibular miniplates (see Chapter 13): bone maturity does not reach the level for good retention of the screws before approximately age 11 (obviously, maturational rather than chronologic age). The denser bone of the mandible and palate is available at somewhat younger ages, but age still is a limitation.

Because it is necessary to reflect a flap to place miniplates and then suture the soft tissue incision, their surgical placement is significantly more difficult than placement of screws. It is important to contour the miniplates to fit closely against the bone of the base of the zygoma and maintain bone contact at the point of emergence to prevent excessive moments against the proximal screw. As a general rule, orthodontists can place bone screws into alveolar bone quite satisfactorily, but miniplates are better done by those with more extensive surgical training. From the surgeon's perspective, this is a relatively short surgical procedure that can be performed under local anesthesia without significant complications.<sup>37</sup>

**TABLE 10.5** Miniplate Failure Rate

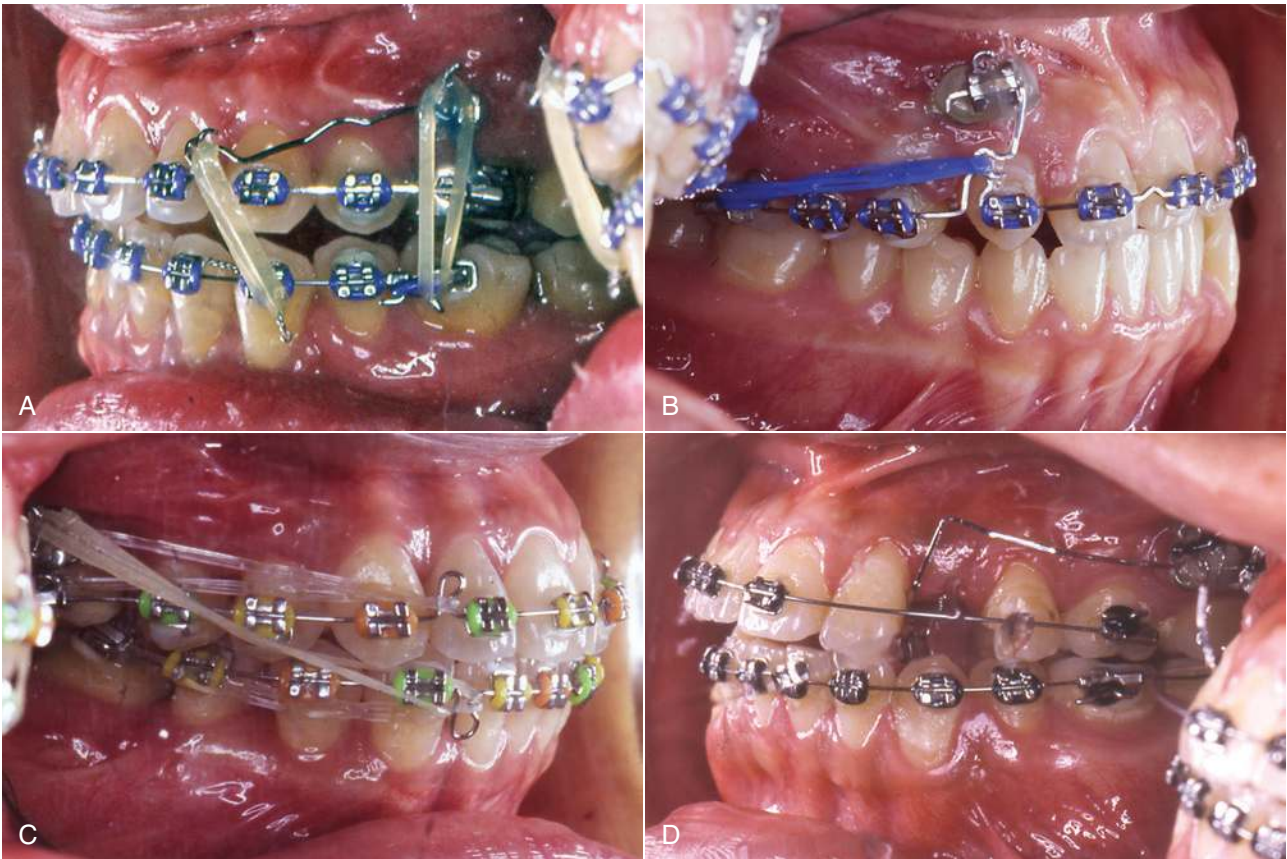	University of North Carolina (UNC)	Université de Catholique de Louvain (UCL)
Number of miniplates	59	141
Number of failures	4 (7%)	11 (8%)
Due to mobility	2	5
Soft tissue ulceration	0	4
Anchor breakage	1	2
Poor location	1	0
In growing patients	3 (75%)	8 (73%)
In adults	1 (25%)	3 (27%)
In mandible	NA	6 (56%)

Adapted from Cornelis MA, Scheffler NR, Nyssen-Behets C, et al. *Am J Orthod Dentofac Orthop.* 2008;133:8–14.

Once the plates are in place, however, they are well accepted by patients and providers and are a safe and effective adjunct for complex orthodontic treatment.<sup>38</sup> They are as easy for the orthodontist to use as alveolar TADs. Compared with individual alveolar screws, miniplates have three major advantages:

- The amount of force that the miniplate can tolerate is significantly larger because the plate is held by multiple screws and usually is placed in an area with thicker cortical bone.
- If the miniplate connector has a locking mechanism (as it should), the direction of pull can be changed readily and the source of the force can be moved a considerable distance by extending wire hooks from end of the connector (Fig. 10.54; also see Fig. 10.51). With the vertical posts that are part of the mandibular buccal shelf plate, the angle of force can be changed just by using a higher or lower notch to tie the spring. This also can be done with individual screws that have a slot for a wire extension, but as we noted earlier, putting a force on the extension introduces a moment that can overtighten or loosen the screw, greatly increasing the chance of screw failure. With multiple screws holding the miniplate, this is not a problem.
- The miniplates can be placed well above the roots of the maxillary teeth, so an interdental screw does not become a barrier to moving all the teeth mesially or distally.

In comparing alveolar bone screws with miniplates (Table 10.6), a reasonable conclusion is that individual screws are less invasive and are indicated wherever they can provide adequate anchorage. This is the case when a few teeth need to be repositioned. A long screw at the base of the alveolar arch can be used if intrusion of maxillary posterior teeth (which requires light force) is desired (see Chapter 19), and shorter screws in the palate also can be used for maxillary posterior intrusion. For more complex and extensive movement of multiple teeth, with distalization of an entire dental arch being the best example, miniplates offer better control and are less likely to loosen or need to be replaced.



• **Fig. 10.54** (A) to (D) A variety of attachment points can be created with wire extensions from miniplate connectors, as illustrated in this series of variations in force directions using miniplates in the same location at the base of the zygoma. (Courtesy Dr. T. Wu.)

**TABLE 10.6** Bone Screws Versus Miniplates

Single Alveolar Screws	Palatal Screws Linked by Plate	Maxillary or Mandibular Miniplates
<b>Advantages</b>		
Less invasive, lower cost	Excellent stability and resistance	Excellent stability and resistance
Orthodontist can place and remove	Orthodontist can place and remove	Can be placed above and below roots to allow en masse movement
Multiple sites for placement	Useful for vertical and anteroposterior movements	Useful for vertical and anteroposterior movements Easy to activate unilaterally well tolerated during therapy
<b>Disadvantages</b>		
Limited anchorage amount, move one or two teeth but not more	Framework in palate can be difficult for patient to tolerate	Experienced surgeon needed, not for typical orthodontist
No way to alter force direction without risk of losing screw	Bilateral screws needed	Surgery to place and remove
Vertical movement limited	Moderately difficult placement	Cost of surgery and device
<b>Major Indications for Use</b>		
Repositioning or rotating single teeth	Indirect anchorage primarily, for retracting protrusive incisors	Direct anchorage primarily, for retraction and/or intrusion of incisors
Bringing impacted canine(s) into the arch while preserving arch form	Indirect anchorage for intrusion of posterior teeth Indirect anchorage to bring posterior teeth forward	Direct anchorage for intrusion of posterior teeth Direct anchorage for skeletal Class III growth modification

## References

- Pancherz H. Treatment of Class II malocclusions by jumping the bite with the Herbst appliance: a cephalometric investigation. *Am J Orthod.* 1979;76:423–442.
- Sheridan JJ, Armbruster P, Nguyen P, et al. Tooth movement with Essix molding. *J Clin Orthod.* 2004;38:435–441.
- Gu J, Tang JS, Skulski B, Fields HW Jr, et al. Evaluation of Invisalign treatment effectiveness and efficiency compared with conventional fixed appliances using the Peer Assessment Rating Index. *Am J Orthod Dentofacial Orthop.* 2017;151:259–266.
- Chen YJ, Chan LY, Chung-Chen JY. Clear aligner treatment with “in-office” virtual model set-up and 3D printing. *J Dent Oral Care.* 2017;3:1–5.
- Begg PR, Kesling PC. *Begg Orthodontic Theory and Technique*. 3rd ed. Philadelphia: WB Saunders; 1977.
- Parkhouse RC. Current products and practice: Tip-Edge Plus. *Int J Orthod.* 2008;19:17–24.
- Andrews LF. *Straight Wire: The Concept and Appliance*. San Diego: LA Wells; 1989.
- Hobson RS, Rugg-Gunn AJ, Booth TA. Acid etch patterns on the buccal surface of human permanent teeth. *Arch Oral Biol.* 2002;47:407–412.
- Finnema KJ, Ozcan M, Post WJ, et al. In vitro orthodontic bond strength testing: a systematic review and meta-analysis. *Am J Orthod Dentofacial Orthop.* 2010;137:615–622.
- Al-Saleh M, El-Mowafy O. Bond strength of orthodontic brackets with new self-adhesive resin cements. *Am J Orthod Dentofacial Orthop.* 2010;137:528–533.
- Maryanchik I, Brendlinger EJ, Fallis DW, Vandewalle KS. Shear bond strength of orthodontic brackets bonded to various esthetic pontic materials. *Am J Orthod Dentofacial Orthop.* 2010;137:684–689.
- Justus R, Cubero T, Ondarza R, et al. A new technique with sodium hypochlorite to increase bracket shear bond strength of fluoride-releasing resin-modified glass ionomer cements: comparing shear bond strength of two adhesive systems with enamel surface deproteinization before etching. *Semin Orthod.* 2010;16:66–75.
- Nichols DA, Gardner G, Carballeyra AD. Reproducibility of bracket positioning in the indirect bonding technique. *Am J Orthod Dentofacial Orthop.* 2013;144:770–776.
- Grunheid T, Lee M, Larson BE. Transfer accuracy of vinyl polysiloxane trays for indirect bonding. *Angle Orthod.* 2016;86:468–474.
- Feldon PJ, Murray PE, Burch JG, et al. Diode laser debonding of ceramic brackets. *Am J Orthod Dentofacial Orthop.* 2010;138:458–462.
- Lombardo L, Arreghini A, Bratti E, et al. Comparative analysis of real and ideal wire-slot play in square and rectangular archwires. *Angle Orthod.* 2015;85:848–858.
- Marshall SD, Currier GF, Hatch NE, et al. Self-ligating bracket claims. *Am J Orthod Dentofacial Orthop.* 2010;138:128–131.
- Brown MW, Koroluk L, Ko C-C, et al. Effectiveness and efficiency of a CAD/CAM orthodontic bracket system. *Am J Orthod Dentofacial Orthop.* 2015;148:1067–1074.
- Grauer D, Proffit WR. Accuracy in tooth positioning with fully customized lingual orthodontic appliances. *Am J Orthod Dentofacial Orthop.* 2011;140:433–443.
- Knosel M, Klang E, Helms H-J, Wiechmann D. Lingual orthodontic treatment duration: performance of two different completely customized multi-bracket appliances (Incognito and WIN) in groups with different treatment complexities. *Head Face Med.* 2014;10:46. <http://www.head-face-med.com/content/10/1/46>.
- Pauls A, Nienkemper M, Schweska-Polly R, Wiechmann D. Therapeutic accuracy of the completely customized lingual appliance WIN: a retrospective cohort study. *J Orofac Orthop.* 2017;78:52–61.
- Walton D, Fields HW, Johnston WM, et al. Orthodontic appliance preferences of children and adolescents. *Am J Orthod Dentofacial Orthop.* 2010;138:698.e1–698.e12.
- Braun S, Hnat WH, Fender WE, et al. The form of the human dental arch. *Angle Orthod.* 1998;68:29–36.
- Alford TJ, Roberts WE, Hartsfield JK, et al. Clinical outcomes for patients finished with the SureSmile method compared to conventional fixed orthodontic therapy. *Angle Orthod.* 2011;81:383–388.
- Larson BE, Vaubel CJ, Grunheid T. Effectiveness of computer-assisted orthodontic treatment technology to achieve predicted outcomes. *Angle Orthod.* 2013;83:557–562.
- Chang J-H, Berzins DW, Pruszynski JE, Ballard RW. The effect of water storage on the bending properties of esthetic, fiber-reinforced composite orthodontic archwires. *Angle Orthod.* 2014;84:417–423.
- da Silva DL, Mattos CT, de Araujo MCA, et al. Color stability and fluorescence of different orthodontic esthetic archwires. *Angle Orthod.* 2013;83:127–132.
- Brinley CL, Behrents R, Kim KB, et al. Pitch and longitudinal fluting effects on the primary stability of miniscrew implants. *Angle Orthod.* 2009;79:1156–1161.
- Chatzigianni A, Keilig L, Reimann S, et al. Effect of mini-implant length and diameter on primary stability under loading with two force levels. *Eur J Orthod.* 2011;33:381–387.
- Kim H, Kim TW. Histologic evaluation of root-surface healing after root contact or approximation during placement of mini-implants. *Am J Orthod Dentofacial Orthop.* 2011;139:752–760.
- Ahmed VKS, Rooban T, Krishnaswamy NR, et al. Root damage and repair with temporary skeletal anchorage devices. *Am J Orthod Dentofacial Orthop.* 2012;141:547–555.
- Kuroda S, Yamada K, Deguchi T, et al. Root proximity is a major factor for screw failure in orthodontic anchorage. *Am J Orthod Dentofacial Orthop.* 2007;131:68–73.
- Rodriguez JC, Suarez F, Chan H, et al. Implants for orthodontic anchorage: success rates and reasons for failures. *Implant Dent.* 2014;23:155–161.
- Lee JS, Kim JK, Park YC. Biomechanical considerations with temporary anchorage devices. In: Graber LW, Vanarsdall RL, Vig KWL, Huang GJ, eds. *Orthodontics: Current Principles and Techniques*. 6th ed. St Louis: Elsevier; 2016:511–568, [Chapter 20].
- Baumgaertel S. Predrilling of the implant site: is it necessary for orthodontic mini-implants? *Am J Orthod Dentofacial Orthop.* 2010;137:825–829.
- Holm M, Jost-Brinkmann P-G, Mah J, Bumann A. Bone thickness of the anterior palate for orthodontic miniscrews. *Angle Orthod.* 2016;86:826–831.
- Cornelis MA, Scheffler NR, Nyssen-Behets C, et al. Patients’ and orthodontists’ perceptions of miniplates used for temporary skeletal anchorage: a prospective study. *Am J Orthod Dentofacial Orthop.* 2008;133:18–24.
- Cornelis MA, Scheffler NR, Mahy P, et al. Modified miniplates for temporary skeletal anchorage in orthodontics: placement and removal surgeries. *J Oral Maxillofac Surg.* 2008;66:1439–1445.



## SECTION IV

# Treatment in Preadolescent Children: What Is Different?

Orthodontic treatment rarely is done in the primary dentition, for three reasons: (1) Movement of primary incisors and canines is likely to lead to accelerated root resorption and premature loss of primary teeth; (2) movement of any of the primary teeth has little effect on where the permanent teeth erupt; and (3) growth modification effects in young children are lost to a resumption of growth in the original pattern. That means there usually is little benefit and some risk from primary dentition treatment, usually called *very early treatment*.

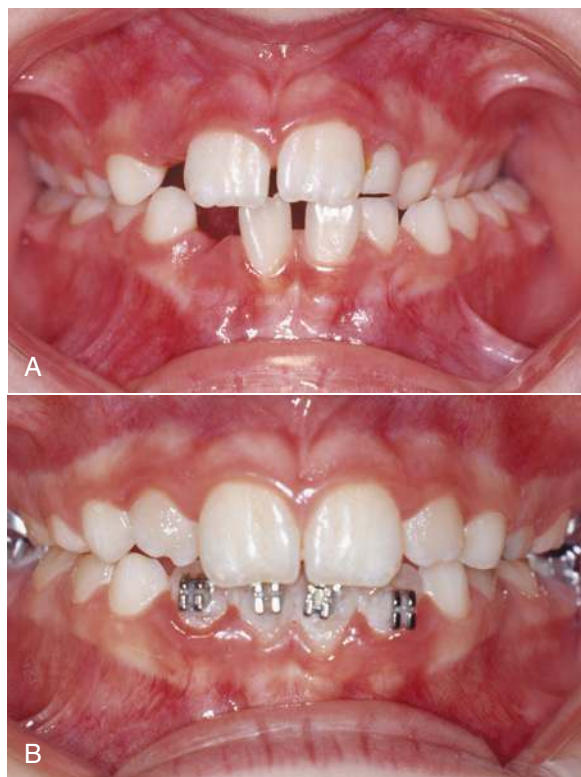That changes as the permanent incisors erupt and the patient enters the mixed dentition, when a first phase of what usually is called *early treatment* definitely should be done in some situations, and often can be beneficial even though a second phase of comprehensive treatment that will be completed during adolescence usually is needed. Among the important points when early treatment is considered are the following.

**Focus on “should be done” and obvious treatment.** Early treatment will be truly beneficial to the patient when the treatment changes are known and proven. For instance, patients who are in the mid or late mixed dentition with unerupted incisors have an obvious esthetic and dental development problem and clearly fall into the “should be done” category because good data show that delaying treatment is likely to make things worse. On the other hand, 10 mm of crowding will not resolve itself whether or not a lingual arch is placed in the mixed dentition, and requires more definitive decision making with long-term consequences. Given a mixed dentition child with dental and facial problems, is it wise to start treatment now for this patient? The child’s age and behavior, the family and social situation, and the time commitment and cost must be factored into the decision. The treatment must meet the patient’s needs in many dimensions.

**The goals of early treatment must be clearly outlined and understood.** For a child with a complex problem, it is highly likely that a second stage of treatment in the early permanent dentition will be required even if early treatment is carried out effectively and properly (Fig. IV.1). There is a limit to the time and cooperation that patients and parents are willing to devote to orthodontics. Unless appropriate endpoints are set in advance, it is easy for mixed dentition treatment to extend over several years and result in an extremely long period of treatment instead of defined treatment segments that are more advantageous. If mixed dentition treatment takes too long, there are two problems: (1) Patients can be “burned out” by the time they are ready for comprehensive treatment in the early permanent dentition and (2) the chance of damage to the teeth and supporting structures increases as treatment time increases.

This means that diagnosis and treatment planning are just as demanding and important as in comprehensive treatment. If the treatment goals are not clear, setting appropriate endpoints will be impossible. In early treatment, all aspects of the occlusion usually are not modified to ideal or near ideal. Final tooth and root positions are not required in most cases unless this is all the treatment the child will ever encounter—a prediction that is hard to make.

**In mixed dentition treatment with a partial fixed appliance, there simply are fewer options available.** This is mostly due to the transition of the teeth from the primary to permanent dentition—primary molars with resorbing roots are not good candidates for banding or bonding. Patient compliance can complicate the problems related to a partial appliance. It is true that numerous fixed correctors are now available that appear to reduce some of the patient compliance variables. If a patient will not or does not want to wear a headgear, other appliances can be used, but it is still mandatory that certain teeth are available for appliance placement and anchorage, and changing to a different appliance may also change what outcomes can be attained.

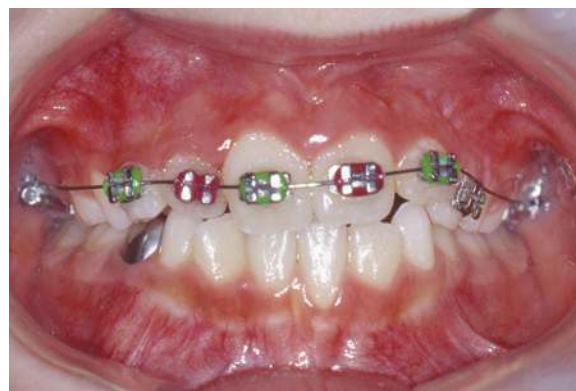

• **Fig. IV.1** Limited treatment in the mixed dentition requires specific objectives, but does not require comprehensive objectives. (A) This patient has lower incisor spacing and a posterior crossbite. Both were addressed in the first phase of treatment, but (B) detailed tooth positioning was not attempted (and generally is not required in mixed dentition treatment) because additional teeth will erupt and cause potential problems.

In the permanent dentition, full appliances allow more flexibility, and temporary anchorage devices (TADs) can provide more substantial skeletal anchorage. Although some of these options also require cooperation, they often allow immediate adjustment of the treatment approach so it can be completed in an acceptable manner. With a partial appliance and potential compliance problems, the full range of options is just not there.

**There are important biomechanical differences between complete and partial appliances.** The typical fixed appliance for mixed dentition treatment is a “2 × 4” or “2 × 6” arrangement (2 molar bands, 4 or 6 bonded anterior teeth; Fig. IV.2). When a fixed appliance includes only some of the teeth, archwire spans are longer, large moments are easy to create, and the wires themselves are less stiff and less strong. This can lead to displaced, or broken, appliances or to appliances that irritate the soft tissue.

On the other hand, this can provide some biomechanical advantages. For example, intrusion of teeth is easier with long spans of wire that keep forces light and allow the appropriate moments to be generated. There is little indication for use of the newer superelastic wires when long unsupported spans exist. Wires with intermediate flexibility and looped configurations or the use of a heavy base wire and a “piggyback” flexible wire are easier to control. Because the available permanent teeth are grouped in anterior (incisor) and posterior (molar) segments, a segmented arch approach to mechanics often is required. The apparently simple



• **Fig. IV.2** This patient has a “2 × 6” appliance in place that includes 2 molars and 6 anterior teeth. The “2 × 4” appliance includes 2 molars and 4 anterior teeth. This is a typical appliance for the mixed dentition and can include both primary and permanent teeth.

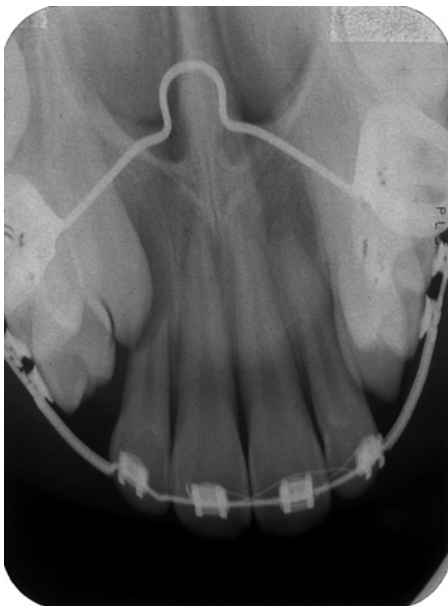
fixed appliances used in the mixed dentition can be quite complex to use appropriately. They are better described as deceptively simple.

**Anchorage control is both more difficult and more critical.** With only the first molars available as anchorage in the posterior segment of the arch, there are limits to the amount of tooth movement that should be attempted in the mixed dentition. Extraoral support from headgear or facemasks can be used, but implant-supported anchorage usually is not practical because of the presence of unerupted teeth and immature bone. The reciprocal effects of an intrusion arch or molar distalizing appliance are accentuated by this reduced anchorage. In addition, stabilizing maxillary and mandibular lingual arches are more likely to be necessary as an adjunct to anchorage.

**Beware of unerupted teeth.** Although radiographic images of the developing dentition are obtained routinely when early treatment is considered, the effect of tooth movement on unerupted teeth often escapes continued consideration. This is a particular risk when moving lateral incisors that are adjacent to unerupted canines. Care must be taken so that the roots of the lateral incisors are not inadvertently tipped into the path of the erupting canines. Failure to pay attention to this can lead to resorption of considerable portions of the lateral incisor root (Fig. IV.3). It is also wise to make certain that unerupted teeth are present. Discovering their absence at a later time can dramatically alter the course and direction of treatment.

**Space closure must be managed with particular care.** Otherwise, when all teeth are not banded or bonded, the teeth without attachments will tend to be displaced and squeezed out of the arch. Teeth without attachments may move facially or lingually, or in some instances occlusally. Unanticipated side effects of space closure that would not be encountered with a complete fixed appliance often are a problem in mixed dentition treatment.

**Interarch mechanics must be used sparingly if at all.** The side effects of Class II, Class III, or vertical elastics, such as widening or constriction of the dental arches and alteration of the occlusal plane, make them risky with partial fixed appliances and lighter wires such as the typical mixed dentition 2 × 4 arrangement. Interarch forces are not recommended under most circumstances



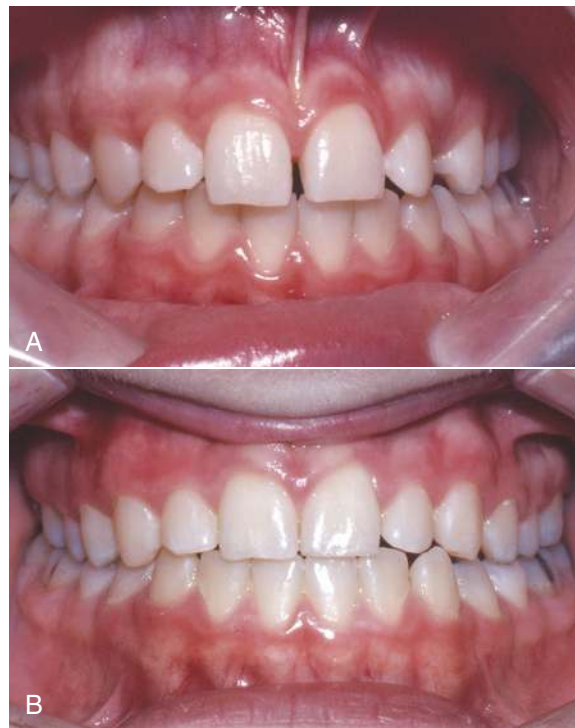• **Fig. IV.3** This patient has resorption of the maxillary right lateral incisor before eruption of the maxillary right canine with appliances in place. This can occur if the canine position is more mesial than normal or, less frequently, the lateral incisor has excessive distal root tip. Early treatment definitely is indicated because the root resorption will get worse if the canine is not repositioned.

unless a complete fixed appliance or heavy stabilizing lingual or buccal wire is present, with one exception: Cross-elastics can be used in the mixed dentition in the treatment of unilateral crossbite. This also subjects the treatment result to the limitations of not using interarch mechanics (Fig. IV.4).

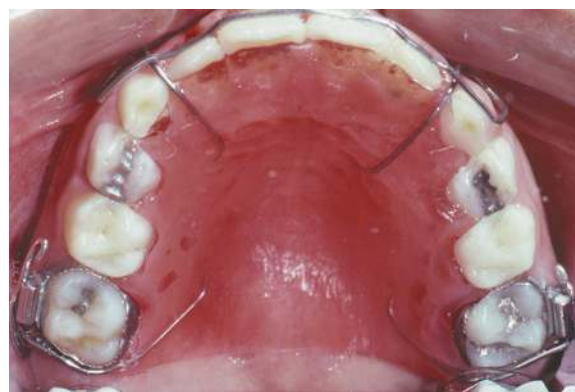**If early treatment is carried out in only one dental arch, the final result is dictated by the untreated teeth and arch.** For instance, if the lower arch is not ideally aligned, it will be difficult to ideally align the upper arch and have proper coordination of the teeth without interferences. Likewise, if there is a substantial curve of Spee in the lower arch and only the upper arch is leveled, the overbite and overjet will be excessive. Despite this, early treatment in only one arch, and the interim nonideal tooth positions, can be quite acceptable if the remainder of the total correction is to be accomplished later.

**Retention often is needed between mixed dentition treatment and eruption of the permanent teeth.** After any significant tooth movement or skeletal change, it is important to maintain the teeth or bone in their new position until a condition of stability is reached. This is as true in the mixed dentition as later. In fact, overcorrection and careful retention may be even more necessary after early treatment. The final stage of transition from the mixed to the permanent dentition is a particularly unstable time. For instance, mesial drift of molars that shortens arch length normally occurs then, but this must be prevented if arch expansion was the goal. Facemask or palatal expansion correction should tend toward overcorrection.

In mixed dentition patients, retention must be planned with two things in mind: the patient's current versus initial condition, and subsequent changes in the dentition and occlusion that will occur as the child matures (Fig. IV.5). With removable retainers,



• **Fig. IV.4** This shows the limitations of not using interarch mechanics for limited treatment. (A) This patient had limited overbite on the left side where an impacted canine was located, and (B) still has limited overbite after extrusion of the canine because appliances were used only on the maxillary arch, so no interarch vertical elastics could be used.



• **Fig. IV.5** When retention is used between early (phase 1) and later (phase 2) treatment, creative planning of bow and clasp positions is required to avoid interference with erupting teeth and maintain the effectiveness of clasps. Note that the labial bow crosses the occlusion distal to the lateral incisors rather than in the area where the canines will erupt, and the molar clasps adapt to the bands and headgear tubes.

the location of clasps, wires, and labial bows should be chosen carefully, and they should be either modifiable or removable. Wires through edentulous areas can interfere with eruption of the permanent teeth in that area, and clasps on primary teeth will be of limited use because these teeth will be lost. Preadolescent children, even those who were quite cooperative with active treatment, may



not be reliable patients for removable retainers, but the greater control provided by fixed retainers must be balanced against their greater hygiene risk and lower modifiability as teeth erupt. A prolonged period of retention before comprehensive treatment begins also increases the chance of patient burnout.

In the chapters in this section, our goal is to present the spectrum of early (preadolescent) treatment in the context of this background.

[Chapter 11](#) focuses on two things: (1) separating child patients with important but less complex orthodontic problems, who are appropriately treated in a family practice setting, from those with more complex problems who are likely to need treatment by a specialist, and (2) the treatment procedures needed to manage these less complex cases. [Chapter 12](#) is a discussion of more complex treatment in children with nonskeletal problems.

# 11

## Moderate Nonskeletal Problems in Preadolescent Children: Preventive and Interceptive Treatment in Family Practice

### CHAPTER OUTLINE

---

#### Orthodontic Triage: Distinguishing Moderate From Complex Treatment Problems

- Step 1: Syndromes and Developmental Abnormalities
- Step 2: Facial Profile Analysis
- Step 3: Dental Development
- Step 4: Space Problems
- Step 5: Other Occlusal Discrepancies

#### Management of Occlusal Relationship Problems

- Posterior Crossbite
- Anterior Crossbite
- Anterior Open Bite
- Deep Bite

#### Management of Eruption Problems

- Overretained Primary Teeth
- Ectopic Eruption

#### Space Analysis: Quantification of Space Problems

- Principles of Space Analysis
- Estimating the Size of Unerupted Permanent Teeth

#### Treatment of Space Problems

- Premature Tooth Loss With Adequate Space: Space Maintenance
- Localized Space Loss (3 mm or Less): Space Regaining
- Mild-to-Moderate Crowding of Incisors With Adequate Space
- Space Deficiency Largely Due to Allowance for Molar Shift: Space Management
- Generalized Moderate Crowding
- Other Tooth Displacements

### Orthodontic Triage: Distinguishing Moderate From Complex Treatment Problems

---

For a dentist seeing a young patient with a malocclusion, just as with all patients, it is important to begin with the parent or patient's chief concern. Then the initial consultation should seek answers to the key questions: Is early or limited orthodontic treatment needed? If so, when should it be done? Finally, who should do it? Does this patient need referral to a specialist?

In military and emergency medicine, triage is the process used to separate casualties by the severity of their injuries. Its purpose is twofold: to separate patients who can be treated at the scene of the injury from those who need transportation to specialized facilities, and to develop a sequence for handling patients so that

those most likely to benefit from immediate treatment will be treated first. Because orthodontic problems almost never are an emergency, the process of sorting orthodontic problems by their severity is analogous to medical triage in only one sense of the word. On the other hand, it is very important for the primary care dentist to be able to distinguish problems that generally need to be treated soon, as opposed to more routine problems that can wait for later comprehensive care. Along the same lines, sorting out moderate from complex problems is essential because this process determines which patients are appropriately treated within family practice and which are most appropriately referred to a specialist.

As with all components of dental practice, a generalist's decision of whether to include orthodontic treatment as a component of his or her services is an individual one, best based on education, experience, and ability. The principle that the less severe problems

are handled within the context of general practice and the more severe problems are referred should remain the same, however, regardless of the practitioner's interest in orthodontics. Only the individual practitioner's cutoff points for treating a patient in the general practice or referral should change.

This section presents a logical scheme for orthodontic triage for children. It is based on the diagnostic approach developed in Chapter 6 and incorporates the principles of determining treatment need that have been discussed. An adequate database and a thorough problem list, of course, are necessary to carry out the triage process. A cephalometric radiograph is not required for triage because a facial form analysis is more appropriate in the generalist's office, but appropriate dental radiographs are needed (usually a panoramic radiograph; occasionally, bitewings supplemented with anterior occlusal radiographs are needed, as are dental casts and photographs). A space analysis (see later in this chapter) is essential.

A flowchart illustrating the steps in the triage sequence accompanies this section.

### Step 1: Syndromes and Developmental Abnormalities

The first step in the triage process is to separate out patients with facial syndromes or similarly complex problems (Fig. 11.1) so they can be treated by specialists or teams of specialists. From physical appearance, the medical and dental histories, and an evaluation of developmental status, nearly all such patients are easily recognized. These malformations are described and illustrated in Chapter 3.

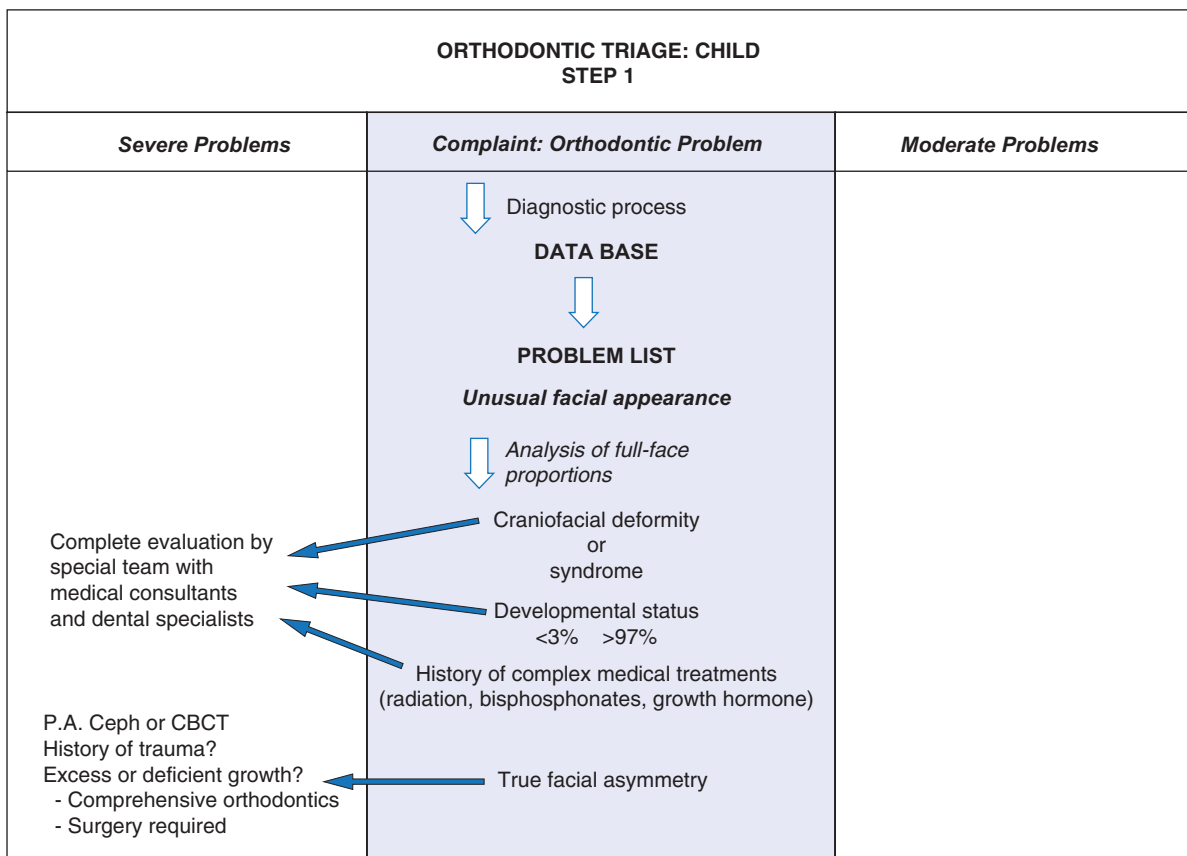
Complex medical treatments, such as radiation, bisphosphonates, and growth hormones, can affect dentofacial development and responses to treatment. Patients who appear to be developing either above the 97th or below the 3rd percentiles on standard growth charts require special evaluation. Growth disorders may demand that any orthodontic treatment be carried out in conjunction with endocrine, nutritional, or psychologic therapy. For these patients and those with diseases that affect growth, such as juvenile rheumatoid arthritis, the proper orthodontic therapy must be combined with identification and control of the disease process.

Patients with significant skeletal asymmetry (not necessarily those whose asymmetry results from only a functional shift of the mandible due to dental interferences) always fall into the severe problem category (Fig. 11.2). These patients could have a developmental problem or the growth anomaly could be the result of an injury. Treatment is likely to involve growth modification and/or surgery, in addition to comprehensive orthodontics. Timing of intervention is affected by whether the cause of the asymmetry is deficient or excessive growth, but early comprehensive evaluation by a specialist is always indicated.

### Step 2: Facial Profile Analysis (Fig. 11.3)

#### Anteroposterior and Vertical Problems

Skeletal Class II and Class III problems and vertical deformities of the long-face and short-face types, regardless of their cause, require thorough cephalometric evaluation to plan appropriate treatment and its timing, and must be considered complex problems

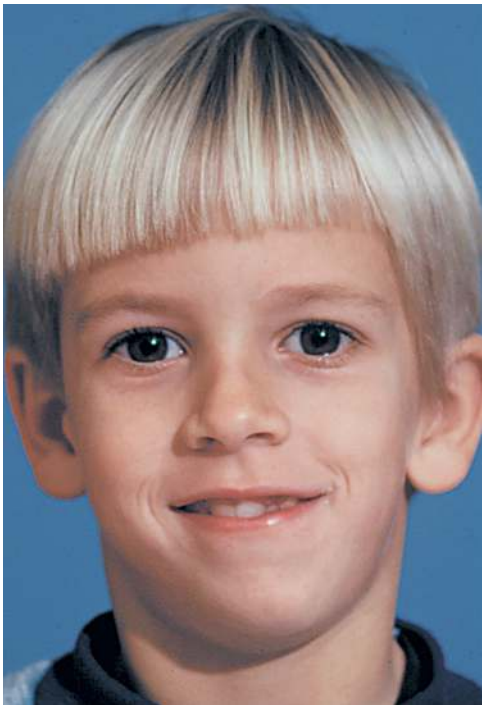

• Fig. 11.1 Orthodontic Triage, Step 1.



(Fig. 11.4). Issues in treatment planning for growth modification are discussed in Chapter 13 and 14.

- As a general rule:
- Class II treatment can be deferred until near adolescence because treatment then is equally as effective as earlier treatment, but Class III treatment for maxillary deficiencies should be addressed earlier.
  - Class III treatment for protrusive mandibles requires either Class III elastics to skeletal anchors during adolescence (the



• **Fig. 11.2** At age 8, this boy has a noticeable mandibular asymmetry with the chin several millimeters off to the left. A problem of this type is likely to become progressively worse and is an indication for referral for comprehensive evaluation by a facial deformities team. (From Proffit WR, White RP, Sarver DM. *Contemporary Treatment of Dentofacial Deformity*. St. Louis: Mosby; 2003.)

- less severe cases) or orthognathic surgery after growth has essentially stopped (see Chapter 20).
- Treatment of both long- and short-face problems usually can be deferred until adolescence because:
    - Long-face or open bite problems can improve during pre-adolescent growth but can be aggravated by growth that persists until the late teens and can outstrip early focused intervention.
    - Short-face problems usually can be managed well with comprehensive treatment during adolescence, unless there is maxillary palatal gingival damage due to a deep bite.
- As with asymmetry, early evaluation for all of these skeletal problems is indicated even if treatment is deferred, so early referral is appropriate.


Excessive Dental Protrusion or Retrusion

Severe dental protrusion or retrusion, which also are complex treatment problems, should be recognized during the facial profile analysis. The urgency for treating these problems usually depends on the esthetic impact or, in the case of protrusion, the potential for traumatic injury. Otherwise, they should be treated as noted earlier.

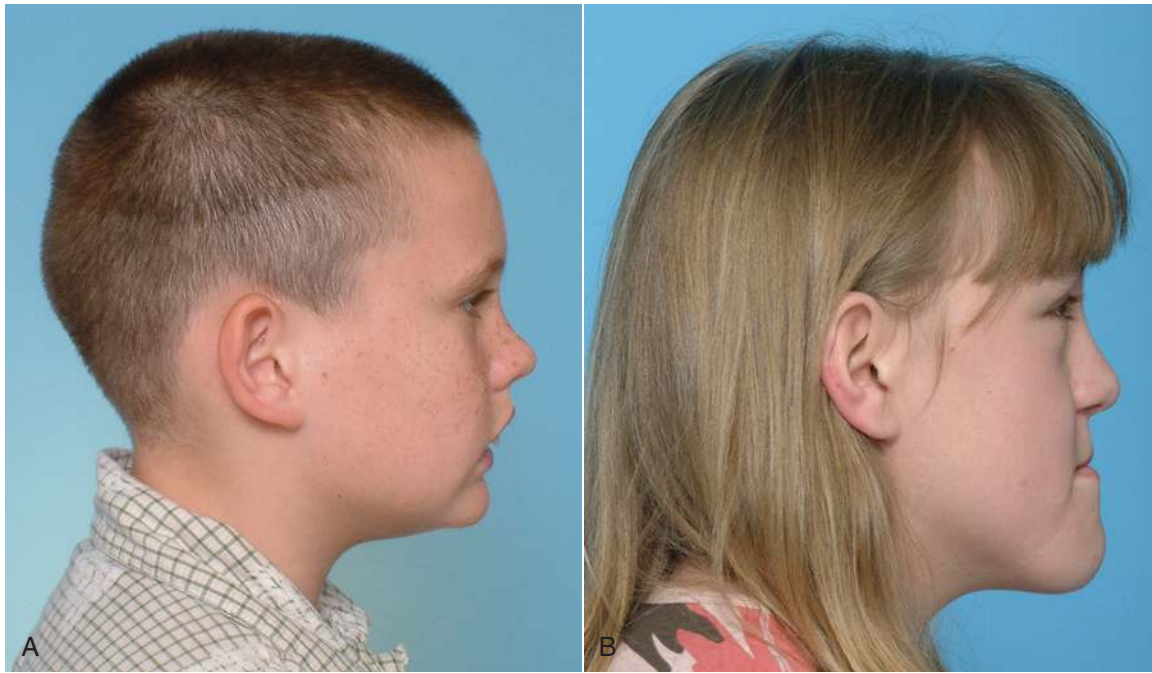Some individuals with good skeletal proportions have protrusion of incisor teeth rather than crowding (Fig. 11.5). When this occurs, the space analysis will show a small or nonexistent discrepancy because the incisor protrusion has compensated for the potential crowding. Excessive protrusion of incisors (bimaxillary protrusion, not excessive overjet) usually is an indication for premolar extraction and retraction of the protruding incisors. This is complex and prolonged treatment. Because of the profile changes produced by adolescent growth, it is better for most children to defer extraction to correct protrusion until late in the mixed dentition or early in the permanent dentition. Techniques for controlling the amount of incisor retraction are described in Chapter 15.

Step 3: Dental Development

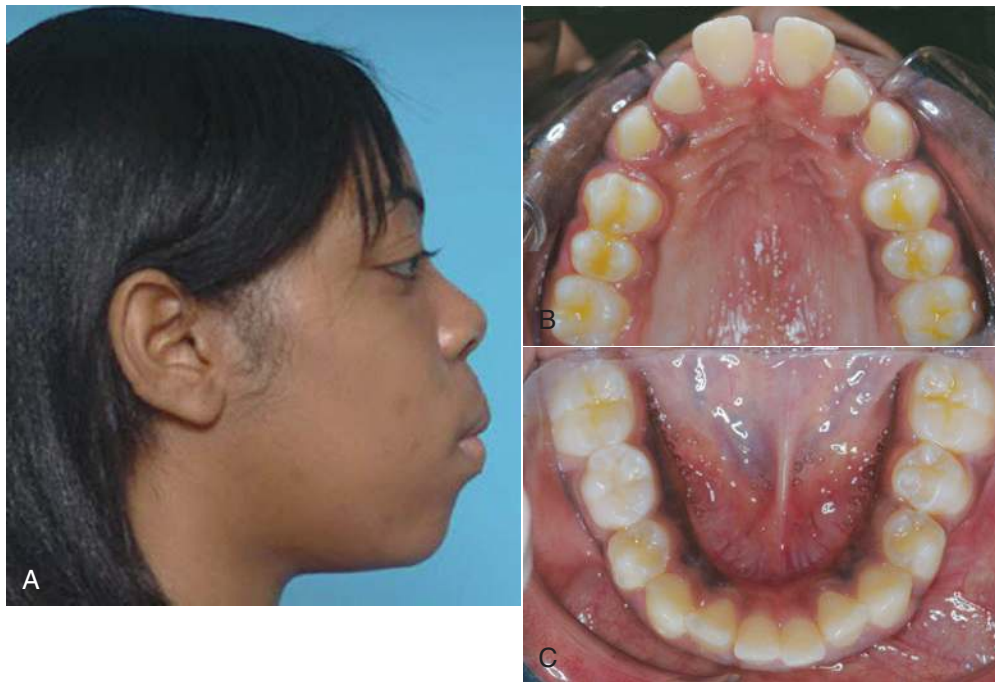Unlike the more complex skeletal problems and problems related to protruding incisors, problems involving dental development often need treatment as soon as they are discovered, typically during the early mixed dentition, and often can be handled in family practice. Considerations in making that decision are outlined in



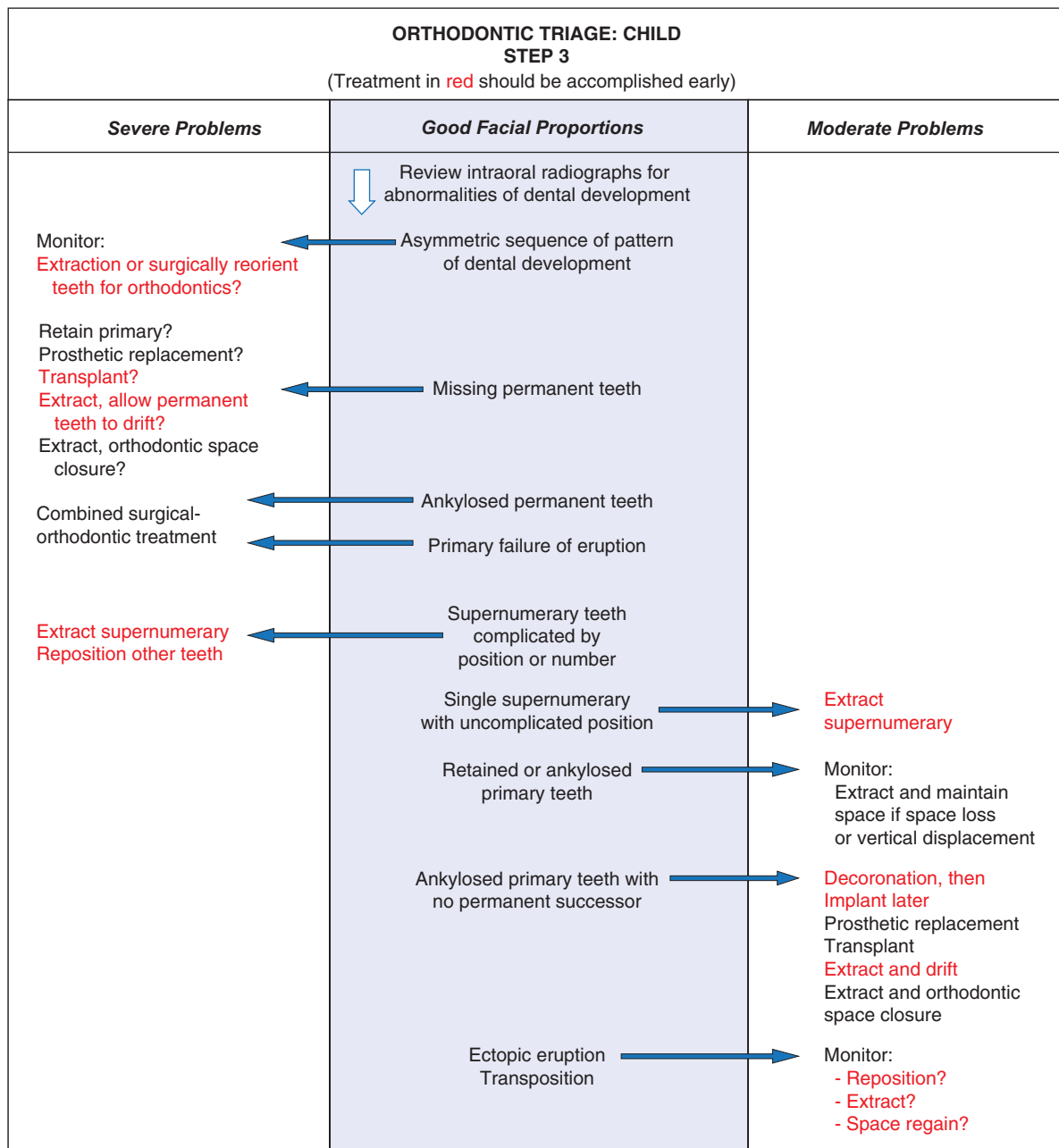
• **Fig. 11.3** Orthodontic Triage, Step 2. AP, Anteroposterior.



• **Fig. 11.4** A skeletal problem of even moderate severity can easily be picked up from examination of the profile, and a cephalometric radiograph is not necessary. (A) Skeletal Class II malocclusion due to mandibular deficiency. (B) Skeletal Class III malocclusion with a component of both maxillary deficiency and mandibular excess.



• **Fig. 11.5** (A) Bimaxillary dentoalveolar protrusion. Note the lip strain to bring the lips together over the teeth. The lips were separated at rest by the protruding incisors. (B) and (C) Occlusal views show the spacing in the upper arch and very mild crowding in the lower arch. For this girl, potential crowding of the teeth is expressed almost completely as protrusion.



• Fig. 11.6 Orthodontic Triage, Step 3.

Fig. 11.6, and treatment of the less severe problems of this type is presented in detail in this chapter.

### Asymmetric Dental Development

Treatment for an abnormal sequence of dental development should be planned only after a careful determination of the underlying cause. Asymmetric eruption (one side ahead of the other by 6 months or more) is significant. It requires careful monitoring of the situation, and in the absence of outright pathologic conditions, often requires early treatment such as selective extraction of primary or permanent teeth. A few patients with asymmetric dental development have a history of childhood radiation therapy to the head and neck or traumatic injury. Surgical and orthodontic treatment for these patients must be planned and timed carefully and may require tooth removal or tooth reorientation. Some of these teeth

have severely dilacerated roots and will not be candidates for orthodontics. These situations definitely fall into the complex category and usually require early intervention.

### Missing Permanent Teeth

The permanent teeth most likely to be congenitally missing are the maxillary lateral incisors and the mandibular second premolars. Maxillary central and lateral incisors are the teeth most likely to be lost to trauma.

The treatment possibilities differ slightly for anterior and posterior teeth. For missing posterior teeth, it is possible to (1) maintain the primary tooth or teeth, (2) extract the overlying primary teeth and then allow the adjacent permanent teeth to drift, (3) extract the primary teeth followed by immediate orthodontic treatment, (4) decoronate the ankylosed primary tooth



and replace with a later implant, or (5) replace the missing teeth prosthetically or perhaps by transplantation or an implant later. For anterior teeth, maintaining the primary teeth is often less of an option because of the esthetics and the spontaneous eruption of adjacent permanent teeth into the space of the missing tooth. Also, extraction and drift of the adjacent teeth are possible, but less appealing because of the immediate esthetic problems with the missing teeth. Although the anterior edentulous ridges can deteriorate quickly when teeth are missing, subsequent eruption of the drifted permanent teeth will reestablish the bone. As with other growth problems, early evaluation and planning are essential. Treatment of problems related to missing teeth in children with mixed dentition is discussed in more detail in [Chapter 12](#).

For all practical purposes, ankylosed permanent teeth at an early age or teeth that fail to erupt for other reasons (such as primary failure of eruption) fall into the same category as missing teeth. These severe problems often require a combination of surgery (for extraction or decoronation) and orthodontics, if indeed the condition can be treated satisfactorily at all. After surgical intervention, the ultimate choices are orthodontic space closure, transplantation into the affected area, or prosthetic replacement.

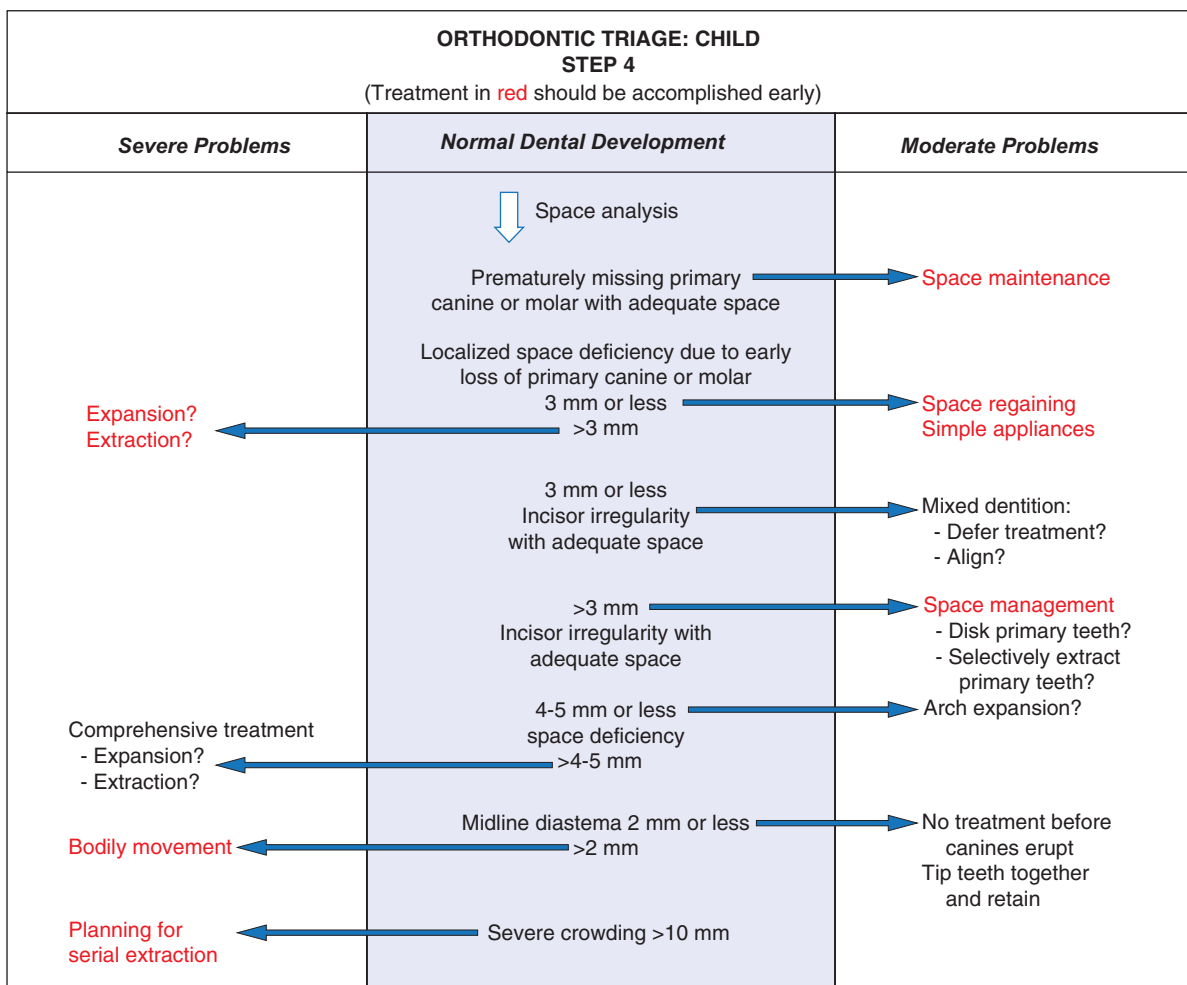
### Supernumerary Teeth

Ninety percent of all supernumerary teeth are found in the anterior part of the maxilla. Multiple or inverted supernumeraries and those that are malformed often displace adjacent teeth and cause problems in their eruption. The presence of multiple supernumerary teeth indicates a complex problem and perhaps a syndrome or congenital abnormality such as cleidocranial dysplasia. Early removal of the supernumeraries is indicated, but this must be done carefully to minimize damage to adjacent teeth. If the permanent teeth have been displaced or severely delayed, surgical exposure, adjunctive periodontal surgery, and possibly mechanical traction are likely to be required to bring them into the arch after the supernumerary has been removed.

Single supernumeraries that are not malformed often erupt spontaneously, causing crowding problems. If these teeth can be removed before they cause distortions of arch form, extraction may be all that is needed.

### Other Eruption Problems

Ectopic eruption (eruption of a tooth in the wrong place or along the wrong eruption path) often leads to early loss of a primary



• Fig. 11.7 Orthodontic Triage, Step 4.

tooth, but in severe cases resorption of permanent teeth can result. Repositioning of the ectopically erupting tooth may be indicated, either surgically or by exposing the problem tooth, placing an attachment on it, and applying traction. A dramatic variation of ectopic eruption is transposition of teeth. Early intervention can reduce the extent to which teeth are malpositioned in some cases. These severe problems often require a combination of surgery and orthodontics and may be genetically linked to other anomalies. They are discussed in [Chapter 12](#).

### Step 4: Space Problems

Orthodontic problems in a child with good facial proportions involve spacing, crowding, irregularity, or malposition of the teeth ([Fig. 11.7](#)). At this stage, regardless of whether crowding is apparent, the results of space analysis are essential for planning treatment. The presence or absence of adequate space for the teeth must be taken into account when other treatment is planned.

In interpreting the results of space analysis for patients of any age, remember that if space to align the teeth is inadequate, either of two conditions may develop. One possibility is for the incisor teeth to remain upright and well positioned over the basal bone of the maxilla or mandible and then rotate or tip labially or lingually. In this instance, the potential crowding is expressed as actual crowding and is difficult to miss ([Fig. 11.8](#)). The other possibility is for the crowded teeth to align themselves completely or partially at the expense of the lips, displacing the lips forward and separating them at rest (see [Fig. 11.5](#)). Even if the potential for crowding is extreme, the teeth can align themselves at the expense of the lip, interfering with lip closure. This must be detected on profile examination. If there is already a degree of protrusion in addition to the crowding, it is safe to assume that the natural limits of anterior displacement of incisors have been reached.

Depending on the circumstances, the appropriate response to space deficiencies varies. For localized space loss of 3 mm or less, lost space can be regained. For total arch space shortage of 5 mm or less or crowding with adequate space, repositioning incisors labially or space management, respectively, during the transition is appropriate. Of these procedures, only treatment to regain space and manage transitional space is critical in terms of timing. Treatment planning for these moderate problems is outlined later in this chapter.

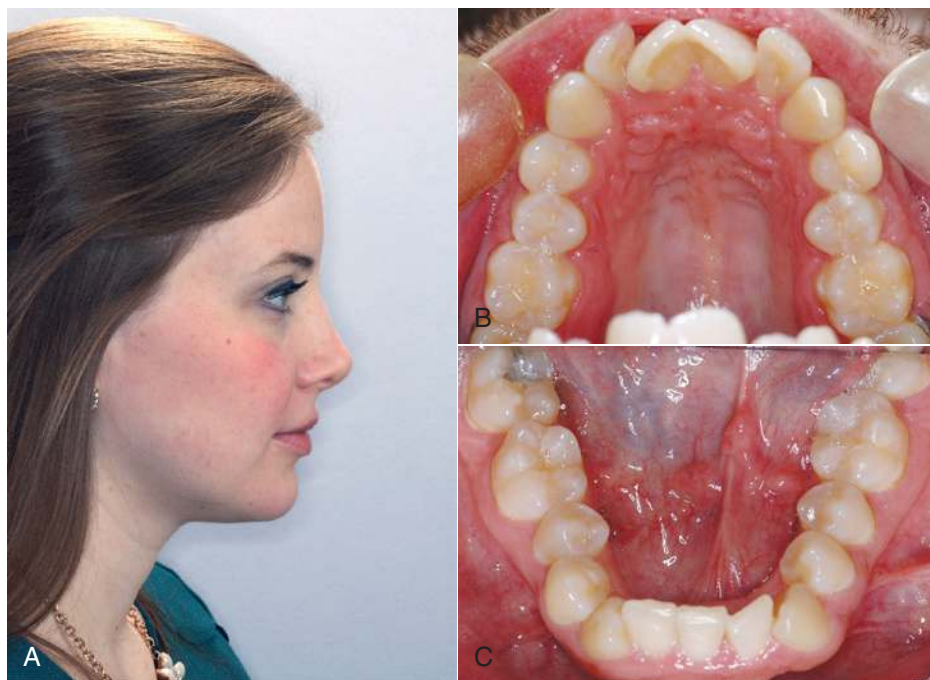
Space discrepancies of approximately 6 mm or more, with or without incisor protrusion, constitute complex treatment problems. In these children, if teeth are not extracted, robust mechanics must be employed to align the teeth, and if teeth are extracted, the anchorage considerations are critical. Severe crowding of 10 mm or more also requires careful and complex planning and often early intervention so that permanent teeth are not impacted or deflected into eruption paths that affect other permanent teeth or bring them into the oral cavity through nonkeratinized tissue.

In general, minor midline diastemas will close and cause little esthetic or developmental problems. Large diastemas, over 2 mm, can be esthetic concerns and inhibit adjacent teeth from erupting properly. They are cause for heightened concern and early treatment.

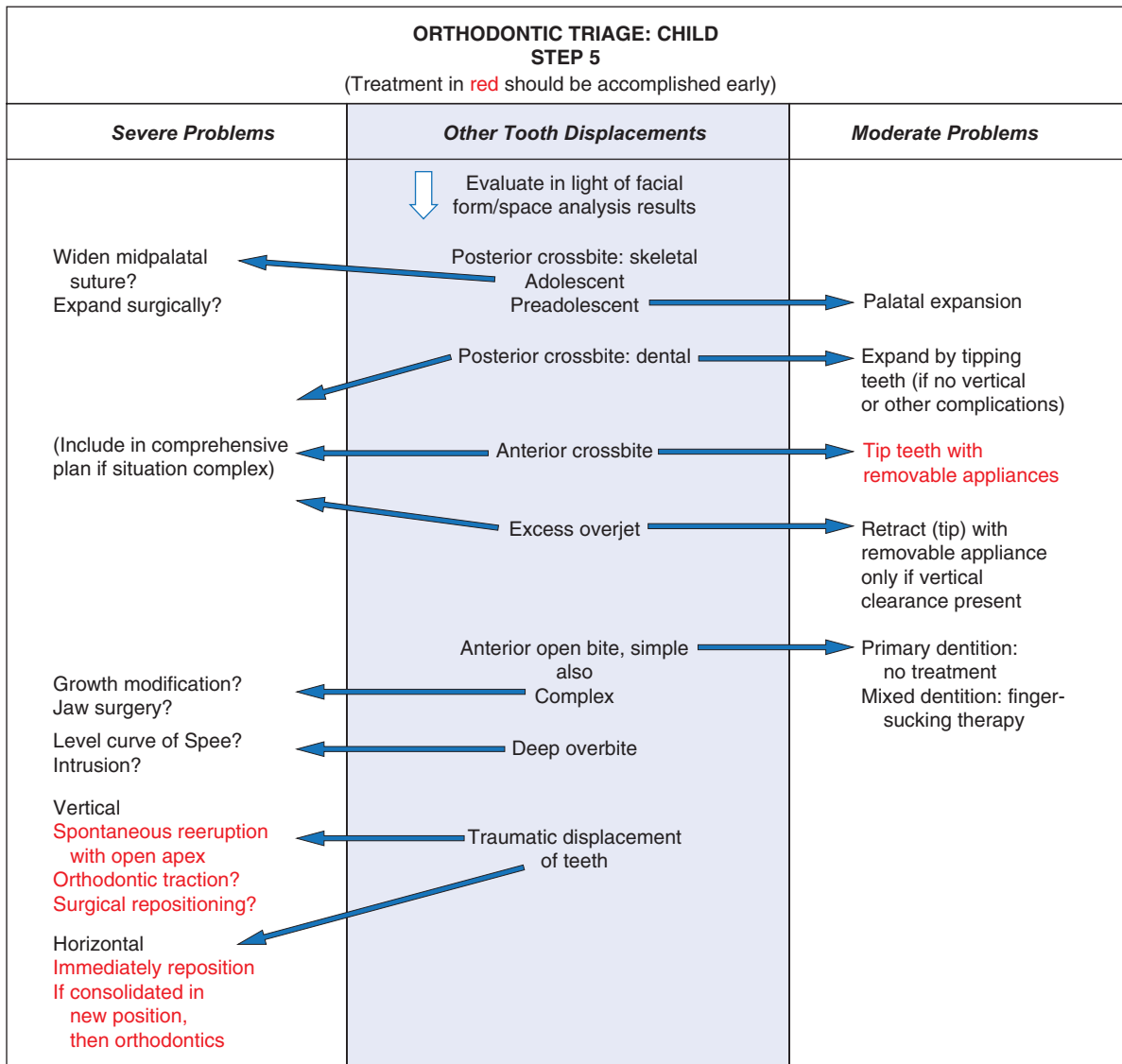
### Step 5: Other Occlusal Discrepancies

Whether crossbite and overbite or open bite should be classified as moderate or severe is determined for most children from their facial form ([Fig. 11.9](#)). Mixed dentition treatment for all these problems must be discussed in the context of “should be treated” versus “can be treated.”

As a general guideline, posterior crossbite in a preadolescent child falls into the moderate category if no other complicating factors (such as severe crowding) are present. It should be treated



• **Fig. 11.8** In some patients, as in this girl (A) with good lip position, potential crowding is expressed completely as actual crowding (B and C), with no compensation in the form of dental and lip protrusion. In others (see [Fig. 11.5](#)), potential crowding is expressed as protrusion. The teeth end up in a position of equilibrium between the tongue and lip forces against them (see [Chapter 5](#))



• Fig. 11.9 Orthodontic Triage, Step 5.

early if the child shifts laterally from the initial dental contact position (a centric relation-to-centric occlusion [CR-CO] shift). If there is no shift but space in the arch is borderline, early mixed dentition treatment sometimes is recommended, but usually it is better to delay until the late mixed dentition so that more teeth can be guided into position. If a skeletal posterior crossbite is treated in adolescence, it will require heavier forces and more complex appliances.

Anterior crossbite usually reflects a Class III jaw discrepancy but can arise from lingual tipping of the upper incisors or crowding as they erupt. Treatment planning for the use of removable versus fixed appliances to correct these simple crossbites early is discussed later.

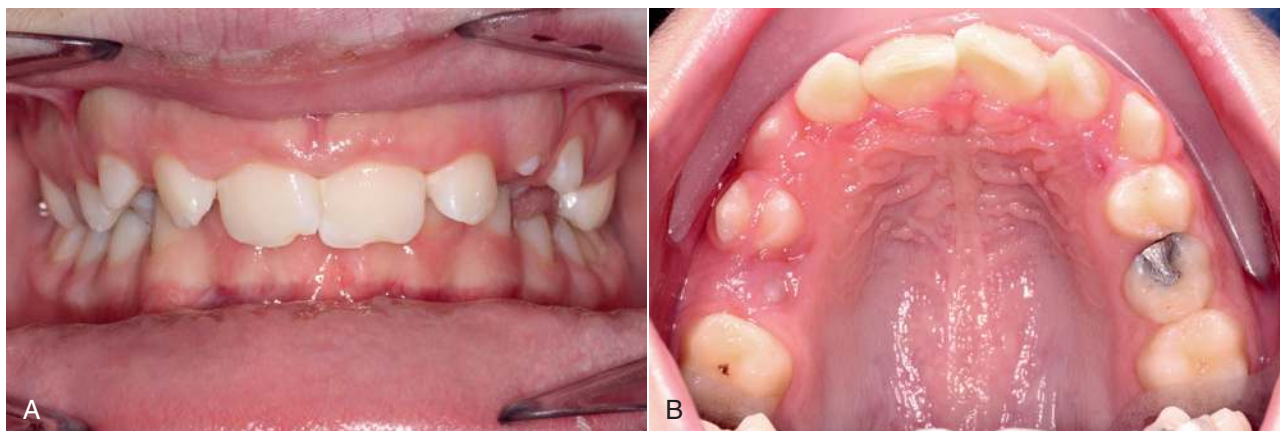
Excessive overjet, with the upper incisors flared and spaced, often reflects a Class II skeletal problem but also can develop in patients with good jaw proportions. If adequate vertical clearance is present, the upper teeth can be tipped lingually and brought together with a simple removable appliance when the child is almost any age. The timing of treatment often depends on child and parent preference and the risk of trauma.

Anterior open bite in a young child with good facial proportions usually needs no treatment because there is a good chance of

spontaneous correction with additional incisor eruption, especially if the open bite is related to an oral habit such as finger-sucking. A complex open bite (one with skeletal involvement or posterior dental manifestations) or any open bite in an older patient whose teeth have erupted is a severe problem. A deep overbite can develop in several ways (see Chapter 6) but often is caused by or made worse by short anterior face height. This is seldom treated in the mixed dentition unless the lower anterior teeth are damaging the upper palatal tissue (Fig. 11.10).

Traumatically displaced erupted incisors at any age pose a special problem because of the resulting occlusal interference problems. There is a risk of ankylosis after healing has occurred, especially after traumatic intrusion, which can lead to a serious problem as all the other teeth erupt while the ankylosed one(s) do not. If the apex is open and root development is incomplete in a young child, waiting for spontaneous re-eruption is warranted. If the injuries are in older patients and involve less than 4 mm of intrusion, a short period of observation also is suggested. If the teeth fail to erupt or the intrusion is greater, either immediate orthodontic or surgical treatment is needed, and the long-term prognosis must be guarded.





• **Fig. 11.10** This patient has an obvious deep bite, with (A) severe overbite and (B), resulting damage to the palatal tissue adjacent to the maxillary incisors.

This triage scheme is oriented toward helping the family practitioner decide which children with orthodontic problems to treat and which to refer. Treatment for children with moderate nonskeletal problems, those selected for treatment in family practice using the triage scheme, is discussed later in this chapter. Early (preadolescent) treatment of more severe and complex nonskeletal problems is discussed in [Chapter 12](#), and growth modification treatment for skeletal problems is discussed in [Chapters 13](#) and [14](#).

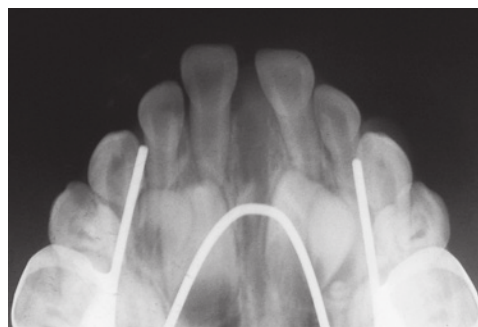
## Management of Occlusal Relationship Problems

### Posterior Crossbite

Posterior crossbite in mixed dentition children is reasonably common. In the Third National Health and Nutrition Examination Survey (NHANES III) in 1992, it was noted in 7.1% of U.S. children aged 8 to 11,<sup>1</sup> and the incidence does not seem to have changed significantly since then. It usually results from a narrowing of the maxillary arch and often is present in children who have had prolonged sucking habits. The crossbite can be due to a narrow maxilla (i.e., to skeletal dimensions) or due only to lingual tipping of the maxillary teeth. If the child shifts on closure or if the constriction is severe enough to significantly reduce the space within the arch, early correction is indicated. If not, treatment can be deferred as long as it is corrected before midpalatal suture bridging so lighter forces and simpler, lingual arch-type appliances can be used, especially if other problems suggest that comprehensive orthodontics will be needed later.

It is also important to determine whether any associated mandibular asymmetry is the result of a shift of the lower jaw due to dental interferences or is due to a true maxillary or mandibular asymmetry. Another critical question is whether the posterior crossbite is related to skeletal maxillary retrusion or mandibular protrusion. In these cases, the anteroposterior position of the maxilla or mandible is contributing to the crossbite, and the actual transverse dimension of the palate may be normal.

Correcting posterior crossbites in the mixed dentition increases arch circumference and provides more room for the permanent teeth. On the average, a 1-mm increase in the inter-premolar width increases arch perimeter values by 0.7 mm.<sup>2</sup> Total relapse into crossbite is unlikely in the absence of a skeletal problem, and mixed



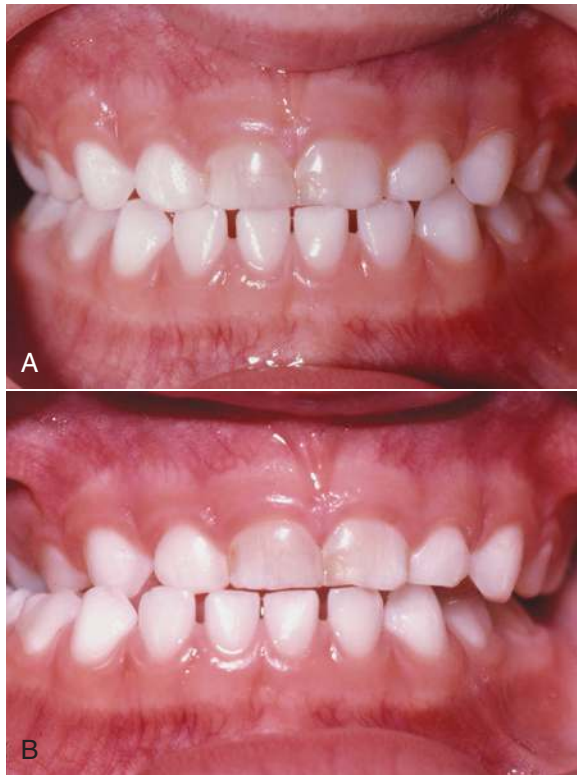• **Fig. 11.11** In young children, lingual arch maxillary expansion devices (W-arches and quad helices) deliver enough force to open the midpalatal suture, as demonstrated in this maxillary occlusal radiograph.

dentition expansion reduces the incidence of posterior crossbite in the permanent dentition, so early correction also simplifies future diagnosis and treatment by eliminating at least that problem from the list.

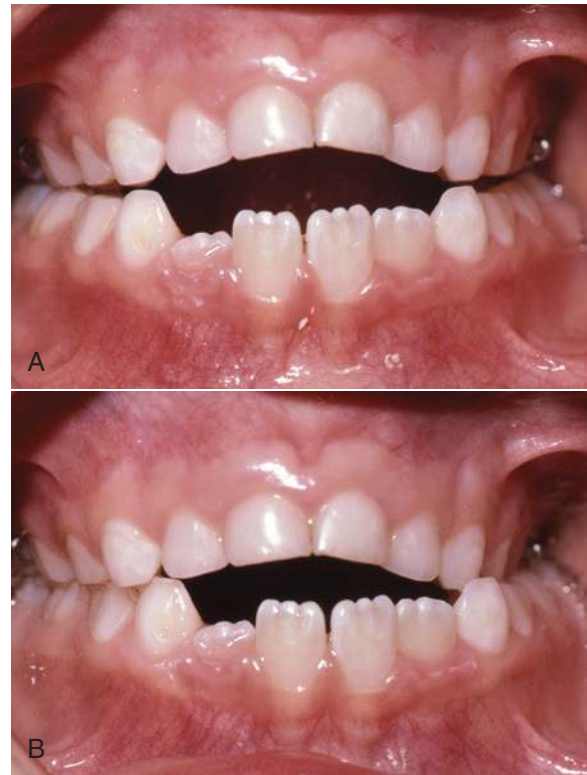Although it is important to determine whether the crossbite is skeletal or dental, in the early mixed dentition years the treatment is usually the same because relatively light forces will move teeth and bones. An expansion lingual arch is the best choice at this age; heavy force from a jackscrew device is needed only when the midpalatal suture has become significantly interdigitated during adolescence ([Fig. 11.11](#); also see further discussion in [Chapter 13](#)). Heavy force and rapid expansion are not indicated in the primary or early mixed dentition. There is a significant risk of distortion of the nose if this is done in younger children (see [Fig. 13.3](#)).

There are three basic approaches to the treatment of moderate posterior crossbites in children:

1. *Equilibration to eliminate mandibular shift.* In a few cases, mostly observed in the primary or early mixed dentition, a shift into posterior crossbite will be due solely to occlusal interference caused by the primary canines or (less frequently) primary molars. These patients can be diagnosed by carefully positioning the mandible in centric occlusion; then it can be seen that the width of the maxilla is adequate and that there would be no crossbite without the shift ([Fig. 11.12](#)). In this case, a child requires only limited equilibration of the primary teeth (often,



• **Fig. 11.12** Minor canine interferences leading to a mandibular shift. (A) Initial contact; (B) shift into centric occlusion. The slight lingual position of the primary canines can lead to occlusal interferences and an apparent posterior crossbite. This sole cause of posterior crossbite is infrequent and is best treated by occlusal adjustment of the primary canines.



• **Fig. 11.13** Moderate bilateral maxillary constriction. (A) Initial contact; (B) shift into centric occlusion. Moderate bilateral maxillary constriction often leads to posterior interferences on closure and a lateral shift of the mandible into an apparent unilateral posterior crossbite. This problem also is best treated by bilateral maxillary expansion.

just reduction of the primary canines) to eliminate the interference and the resulting lateral shift into crossbite.<sup>3</sup>

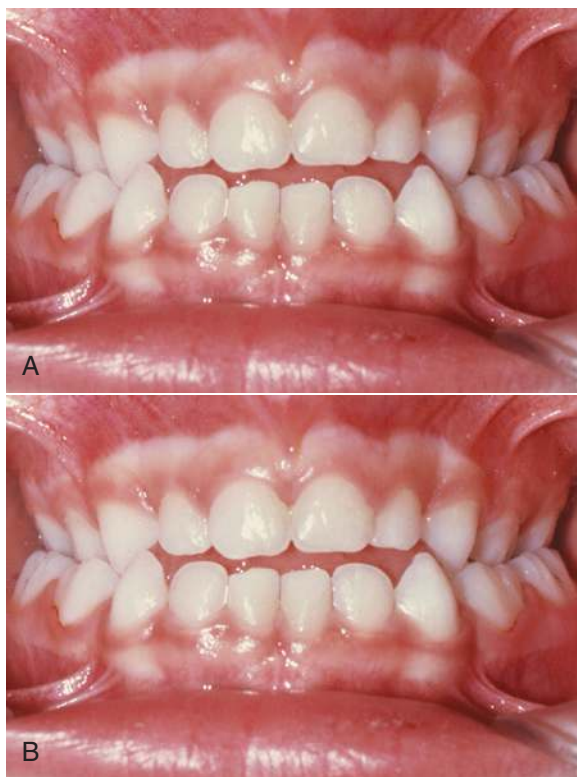2. *Expansion of a constricted maxillary arch.* More commonly, a lateral shift into crossbite is caused by constriction of the maxillary arch. Even a small constriction creates dental interferences that force the mandible to shift to a new position for maximum intercuspation (Fig. 11.13), and moderate expansion of the maxillary dental arch is needed for correction. The general guideline is to expand to prevent the shift when it is diagnosed, but there is an exception: if the permanent first molars are expected to erupt in less than 6 months, it is better to wait for their eruption so that correction can include these teeth, if necessary. A greater maxillary constriction may allow the maxillary teeth to fit inside the mandibular teeth—if so, there will not be a shift on closure (Fig. 11.14), and there is less reason to provide early correction of the crossbite on this basis, but patients with this amount of constriction generally have a space problem that expansion and correction of the crossbite can still be beneficial.

Although it is possible to treat posterior crossbite with a split-plate type of removable appliance, there are three problems: This relies on patient compliance for success, treatment time is longer, and it is more costly than an expansion lingual arch.<sup>4</sup> The preferred appliance for a preadolescent child is an adjustable lingual arch that requires little patient cooperation. Both the W-arch and the quad helix are reliable and easy to use. The W-arch is a fixed appliance constructed of 36-mil steel wire

soldered to molar bands (Fig. 11.15). It is activated simply by opening the apices of the W and is easily adjusted to provide more anterior than posterior expansion, or vice versa, if this is desired. The appliance delivers proper force levels when opened 4 to 6 mm wider than the passive width and should be adjusted to this dimension before being cemented. It is not uncommon for the teeth and maxilla to move more on one side than the other, so precise bilateral expansion is the exception rather than the rule, but acceptable correction and tooth position are almost always achieved.

The quad helix (Fig. 11.16) is a more flexible version of the W-arch, although it is made with 38-mil steel wire. The helices in the anterior palate are bulky, which can effectively serve as a reminder to aid in stopping a finger habit. The combination of a posterior crossbite and a finger-sucking habit is the best indication for this appliance. The extra wire incorporated in it gives it a slightly greater range of action than the W-arch, but the forces are equivalent. Soft tissue irritation can become a problem with the quad helix. Both the W-arch and the quad helix leave an imprint on the tongue. Both the parents and the child should be warned about this (Fig. 11.17). The imprint will disappear when the appliance is removed but can take up to a year to totally do so. With both types of expansion lingual arches, some opening of the midpalatal suture can be expected in a child with primary or mixed dentition, so the expansion is not solely dental. Data show an average palatal expansion of 3.9 mm and an average intermolar expansion of 6.5 mm. As



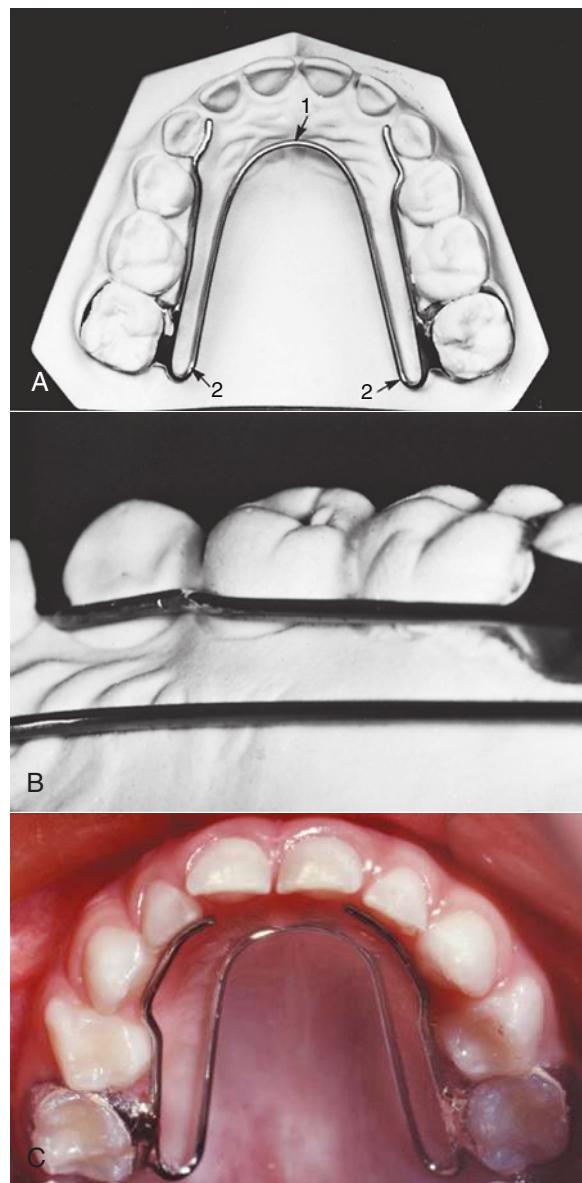


• **Fig. 11.14** Marked bilateral maxillary constriction. (A) Initial contact; (B) centric occlusion (no shift). Severe constriction often produces no interferences on closure, and the patient has a bilateral posterior crossbite in centric relation. This problem is best treated by bilateral maxillary expansion and, unlike with a unilateral crossbite with a mandibular shift, treatment can be delayed until the early permanent dentition.

with rapid or slow expansion using a jackscrew device, the skeletal change was about 50% of the total change.<sup>5</sup>

Expansion should continue at the rate of 2 mm per month (1 mm on each side) until the crossbite is slightly overcorrected. In other words, the lingual cusps of the maxillary teeth should occlude on the lingual inclines of the buccal cusps of the mandibular molars at the end of active treatment (Fig. 11.18). Intraoral appliance adjustment is possible but may lead to unexpected changes. For this reason, removal and re-cementation are recommended at each active treatment visit. Most posterior crossbites require 2 to 3 months of active treatment (with the patients seen each month for adjustments) and 3 months of retention (during which the lingual arch is left passively in place). This mixed dentition correction appears to be stable in the long term.<sup>6</sup>

3. **Unilateral repositioning of teeth.** Some children do have a true unilateral crossbite because of unilateral maxillary constriction of the upper arch (Fig. 11.19). In these children the ideal treatment is to move selected teeth on the constricted side. To a limited extent, this goal of asymmetric movement can be achieved by using different length arms on a W-arch or quad helix (Fig. 11.20), but some bilateral expansion must be expected. An alternative is to use a mandibular lingual arch to stabilize the lower teeth and attach cross-elastics to the maxillary teeth that are at fault. This is more complicated and requires cooperation to be successful but is more unilateral in its effect. Both these approaches are preferred to bilateral

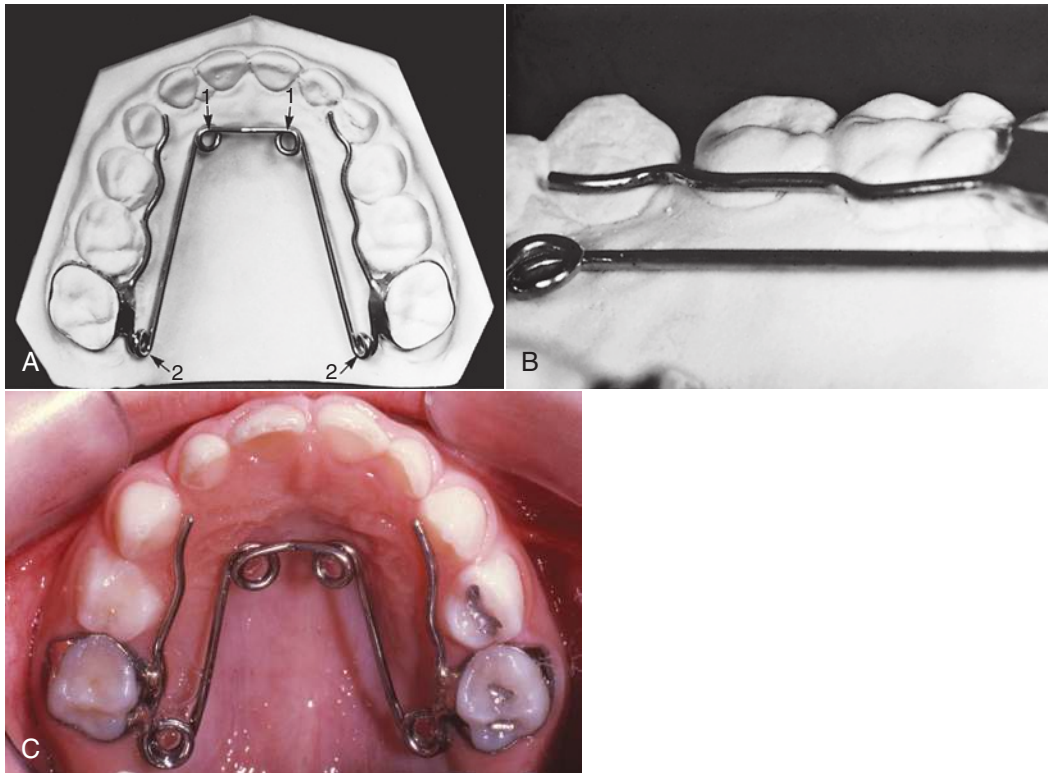


• **Fig. 11.15** The W-arch appliance is ideal for bilateral maxillary expansion. (A) The appliance is fabricated from 36-mil wire and soldered to the bands. The lingual wire should contact the teeth involved in the crossbite and should not extend than 1 to 2 mm distal to the banded molars to eliminate soft tissue irritation. Activation at point 1 produces posterior expansion and activation at point 2 produces anterior expansion. (B) The lingual wire should remain 1 to 1.5 mm away from the marginal gingiva and the palatal tissue. (C) This W-arch is being used to correct a bilateral constriction in the primary dentition.

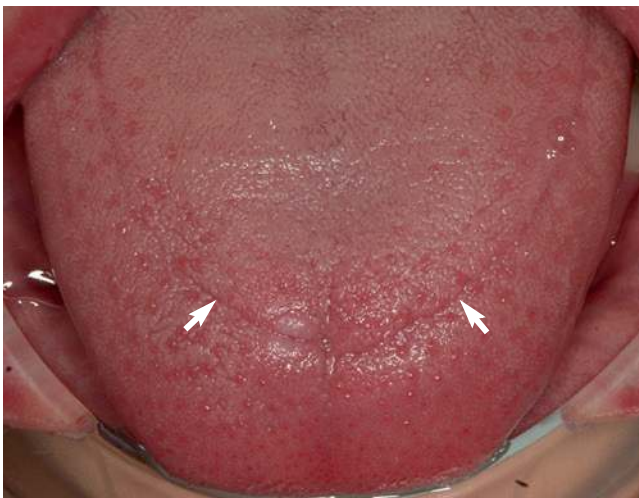maxillary expansion and then hoping for unilateral relapse into a normal occlusion.

All the appliances described earlier are aimed at correction of teeth in the maxillary arch, which is usually where the problem is located. If teeth in both arches contribute to the problem, cross-elastics between banded or bonded attachments in both arches (Fig. 11.21) can reposition both upper and lower teeth. The best choice is a latex elastic (unless the patient has a latex allergy, which is an indication for polymer elastics) with a  $\frac{3}{16}$ -inch (5-mm) lumen generating 6 ounces (170 gm) of force. The force from the elastics

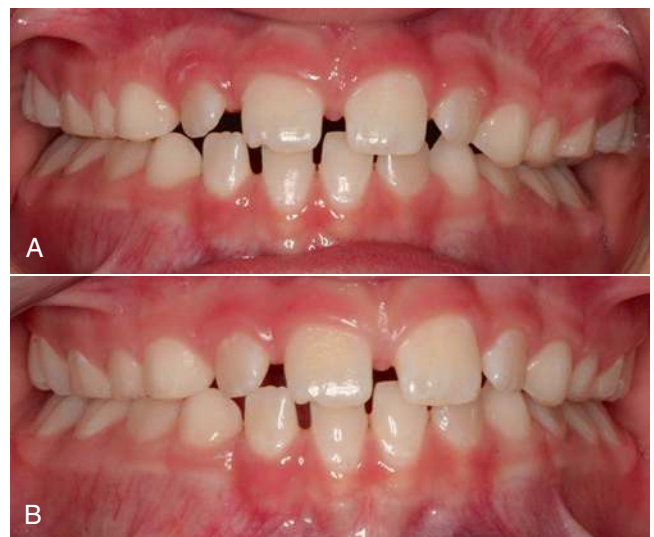



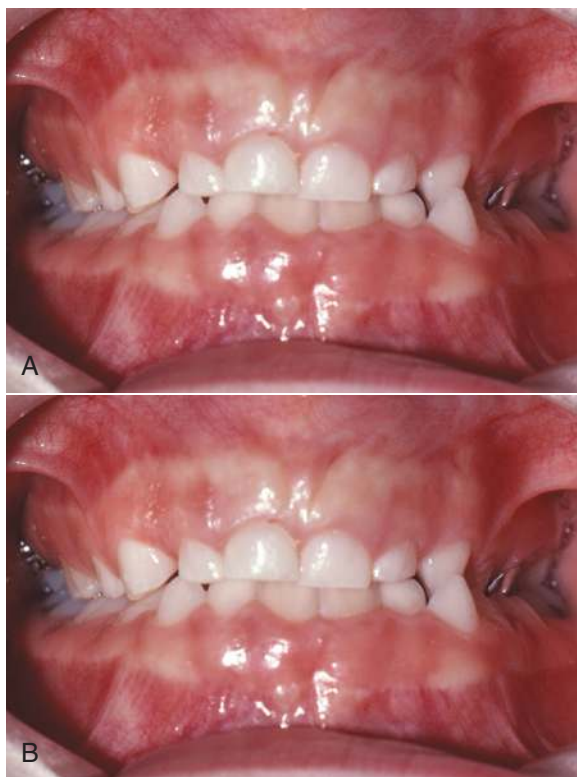• **Fig. 11.16** A quad helix used to correct bilateral maxillary constriction. (A) The appliance is fabricated from 38-mil wire and soldered to the bands. The lingual wire should contact the teeth involved in the crossbite and extend no more than 1 to 2 mm distal to the banded molars to eliminate soft tissue irritation. Activation at point 1 produces posterior expansion, whereas activation at point 2 produces anterior expansion. (B) The lingual wire should remain 1 to 1.5 mm away from the marginal gingiva and palatal tissue. (C) This quad helix is being used to correct a bilateral maxillary constriction in the primary dentition.



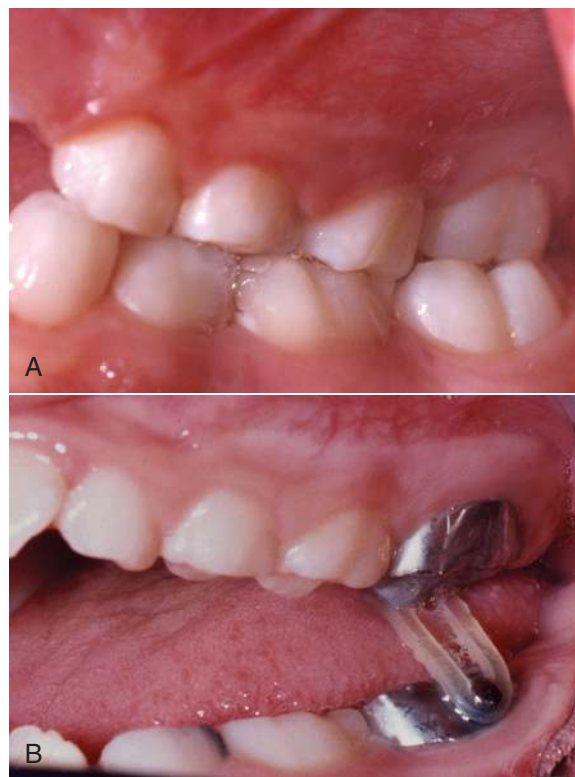• **Fig. 11.17** W-arches, quad helixes, and habit appliances often leave indentations in the superior surface of the tongue (arrows). These often remain after appliance removal for up to 1 year. No treatment is recommended, but patients and parents should be warned of this possibility.



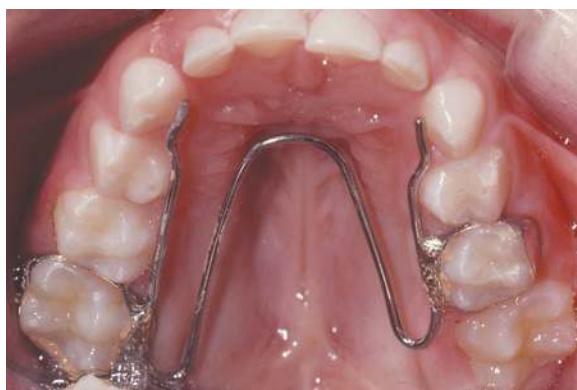• **Fig. 11.18** (A) Posterior crossbites should be overcorrected until the maxillary posterior lingual cusps occlude with the lingual inclines of the mandibular buccal cusps, as shown here, and then retained for approximately 3 months. (B) After retention, slight lingual movement of the maxillary teeth results in stability.



• **Fig. 11.19** True unilateral maxillary posterior constriction. (A) Initial contact. (B) Full occlusion (no shift). True unilateral constriction has a unilateral posterior crossbite in centric relation and in centric occlusion, without a lateral shift. This problem is best treated with asymmetric posterior expansion.



• **Fig. 11.21** (A) This patient's permanent maxillary left first molar is displaced lingually and the permanent mandibular left first molar is displaced facially, which resulted in a posterior crossbite between these teeth. (B) A short and relatively heavy cross-elastic is placed between the buttons welded on the bands. The elastic can be challenging for some children to place, but should be worn full-time, except for eating, and changed frequently.



• **Fig. 11.20** An unequal and asymmetric W-arch used to correct a true unilateral maxillary constriction. The side of the arch to be expanded has fewer teeth against the lingual wire than the anchorage unit. Even with this arrangement, both sides can be expected to show some expansion movement, and the extent cannot be predicted.

is directed vertically as well as faciolingually, which will extrude the posterior teeth and reduce the overbite. Therefore cross-elastics should be used with caution in children with increased lower face height or limited overbite.

Crossbites treated with elastics should be overcorrected, and the bands or bonds left in place immediately after active treatment.

If there is too much relapse, the elastics can be reinstated without rebanding or rebonding. When the occlusion is stable after several weeks without elastic force, the attachments can be removed. The most frequent problem with this form of crossbite correction is lack of cooperation from the child.

A flowchart is provided to help guide decision making for posterior crossbites ([Fig. 11.22](#)).

## Anterior Crossbite

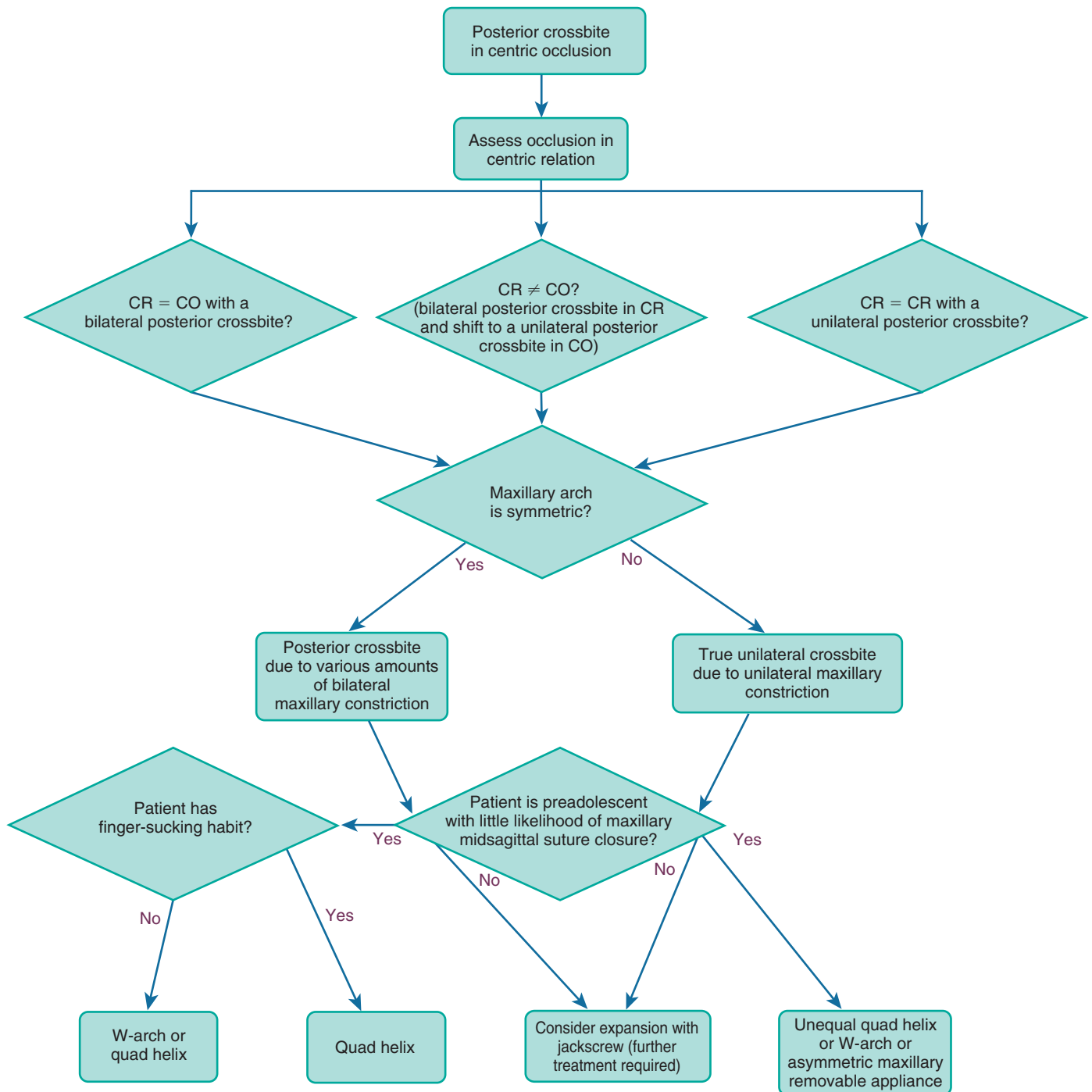
### Etiology

Anterior crossbite, particularly crossbite of all of the incisors, is rarely found in children who do not have a skeletal Class III jaw relationship. A crossbite relationship of one or two anterior teeth, however, may develop in a child who has good facial proportions. When racial or ethnic groups in the U.S. population are combined, about 3% of children have an anterior crossbite in the mixed dentition (see [Fig. 1.12](#)).

In planning treatment for anterior crossbites, it is critically important to differentiate skeletal problems of deficient maxillary or excessive mandibular growth from crossbites due only to displacement of teeth.<sup>7</sup> If the problem is truly skeletal, simply changing the incisor position is inadequate treatment, especially in more severe cases (see [Chapter 13](#)).

Anterior crossbite affecting only one or two teeth almost always is due to lingually displaced maxillary central or lateral

## Posterior Crossbite—Pathways of Care



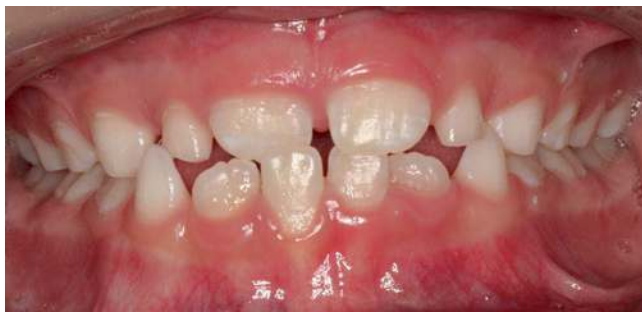• **Fig. 11.22** This flowchart can be used to aid decision making regarding possible options for posterior crossbite correction in the primary and mixed dentitions. Answers to the questions posed in the chart should lead to successful treatment pathways. The approaches to skeletal correction of posterior crossbites are described in [Chapter 13](#). CO, Centric occlusion; CR, centric relation.

incisors. These teeth tend to erupt to the lingual because of the lingual position of the developing tooth buds and may be trapped in that location, especially if there is not enough space ([Fig. 11.23](#)). Sometimes, central incisors are involved because they were deflected toward a lingual eruption path by supernumerary

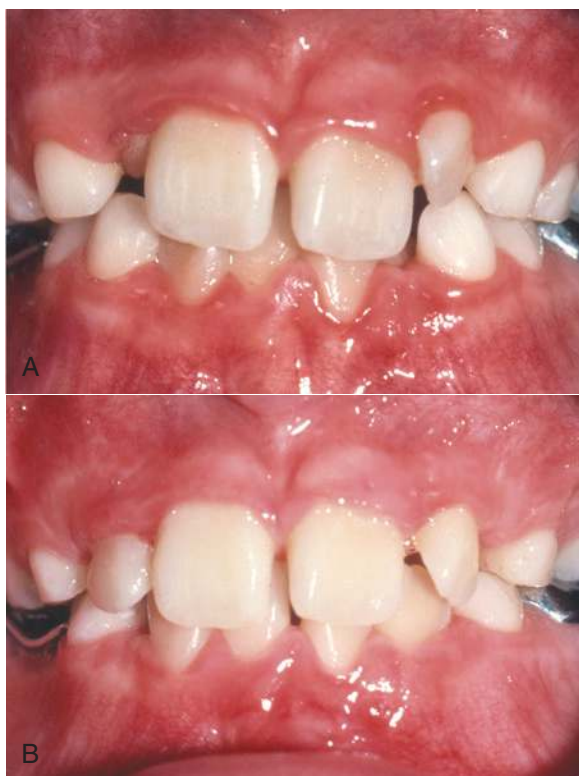anterior teeth or overretained primary incisors. More rarely, trauma to maxillary primary teeth reorients a permanent tooth bud or buds lingually.

The most common etiologic factor for nonskeletal anterior crossbites is lack of space for the permanent incisors, and it is





• **Fig. 11.23** Although there was adequate space, this permanent maxillary right central incisor erupted into crossbite. Most likely this was caused by the lingual position of the tooth bud.



• **Fig. 11.24** An anterior crossbite that is developing as erupting permanent incisors are deflected lingually can be treated by extracting adjacent primary teeth if space is not available for the erupting permanent teeth. (A) The permanent maxillary right lateral incisor is beginning to erupt lingual to the other anterior teeth. (B) Extraction of both primary maxillary canines has allowed spontaneous correction of the crossbite although all the irregularity has not been resolved.

important to focus the treatment plan on management of the total space situation, not just the crossbite. If the developing crossbite is discovered before eruption is complete and overbite has not been established, the adjacent primary teeth can be extracted to provide the necessary space for facial migration of the erupting tooth (Fig. 11.24).

Occasionally, mandibular anterior crowding will force a lower anterior tooth facially and into crossbite. This position, especially if there is incisal interference in centric relation, will lead to tooth mobility and possible gingival recession of the affected tooth.

### Treatment of Nonskeletal Anterior Crossbite

In the early mixed dentition, correction of dental anterior crossbites is recommended for two reasons: (1) Lingually positioned maxillary incisors limit lateral jaw movements, and these teeth or their mandibular counterparts sometimes sustain significant incisal abrasion, and (2) gingival recession is a risk for anterior teeth in crossbite, especially for the lower incisors, when oral hygiene is less than ideal and gingival inflammation occurs.

Only occasionally, however, is it indicated to correct this type of crossbite in the primary dentition, because crowding severe enough to cause it is rare at that stage and the primary incisors often exfoliate before they can be successfully moved.

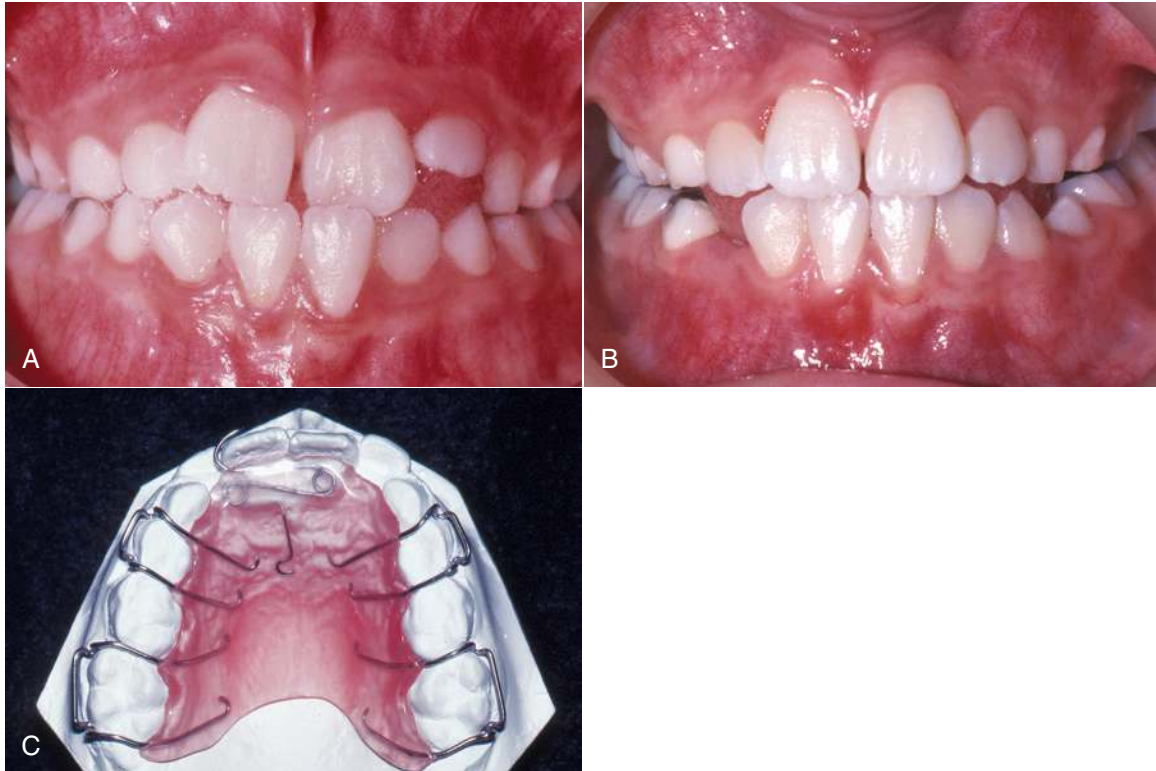
The first concern in this treatment is adequate space for tooth movement, which usually requires reducing the width of some primary teeth, extraction of the adjacent primary teeth, or opening space orthodontically. The diagnostic evaluation should determine whether tipping will provide appropriate correction. Often it will because the problem arose as eruption paths were deflected. If teeth are tipped when bodily movement is required, stability of the result is questionable.

**Removable Appliance Therapy.** In a young child, one way to tip the maxillary anterior teeth out of crossbite is with a removable appliance, using fingersprings for facial movement of the maxillary incisors (Fig. 11.25) or, less frequently, an active labial bow for lingual movement of mandibular incisors. Two maxillary anterior teeth can be moved facially with one 22-mil double-helical cantilever spring. The appliance should have multiple clasps for retention, but a labial bow is contraindicated because it can interfere with facial movement of the incisors and would add little or no retention.

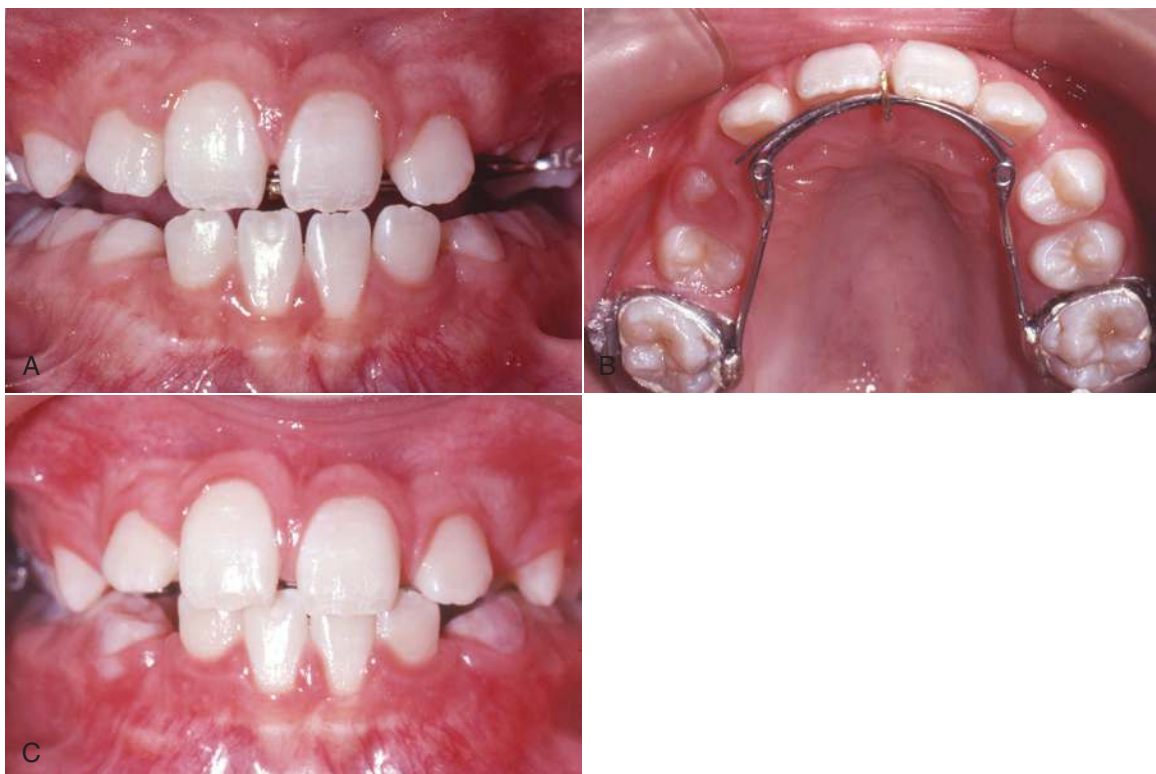In correction of a dental anterior crossbite in a child, it usually is not necessary to open the bite to prevent incisor interferences that keep the patient in crossbite. Unless the overbite is exceptionally deep, a biteplate would be needed only in a child with a clenching or grinding habit. In the early mixed dentition, the preferred approach is to place the removable appliance without a biteplate and attempt tooth movement. If after 2 months the teeth in the opposing arch are moving in the same direction as the teeth to which the force is being applied, the bite can be opened by adding orthodontic banding cement to the occlusal surfaces of the lower posterior molars. When the crossbite is corrected, the cement can be removed relatively easily, and it does not require alteration of the appliance. Using a biteplate risks the chance that teeth not in contact with the appliance or the opposing arch will erupt excessively.

A removable appliance of this type requires nearly full-time wear to be effective and efficient. If the lingual fingersprings are activated 1.5 to 2 mm, they will produce approximately 1 mm of tooth movement in a month. The offending teeth should be slightly overcorrected and retained until overbite is adequate to retain the corrected tooth positions. One or 2 months of retention with a passive appliance is usually sufficient.

The most common problems associated with these simple removable appliances are lack of patient cooperation, poor design leading to lack of retention, and improper activation. In children asked to wear removable appliances 12 to 15 hours, half of the patients achieved a wear time of 9 hours or more when wearing a monitoring device embedded in the appliance. The wear behaviors showed great variability. Only 15% of the patients wore the appliances every day. Some patients skipped days and then tried to compensate with periods of greater wear time. It is possible that irregular wear can jeopardize the treatment success.<sup>8</sup>

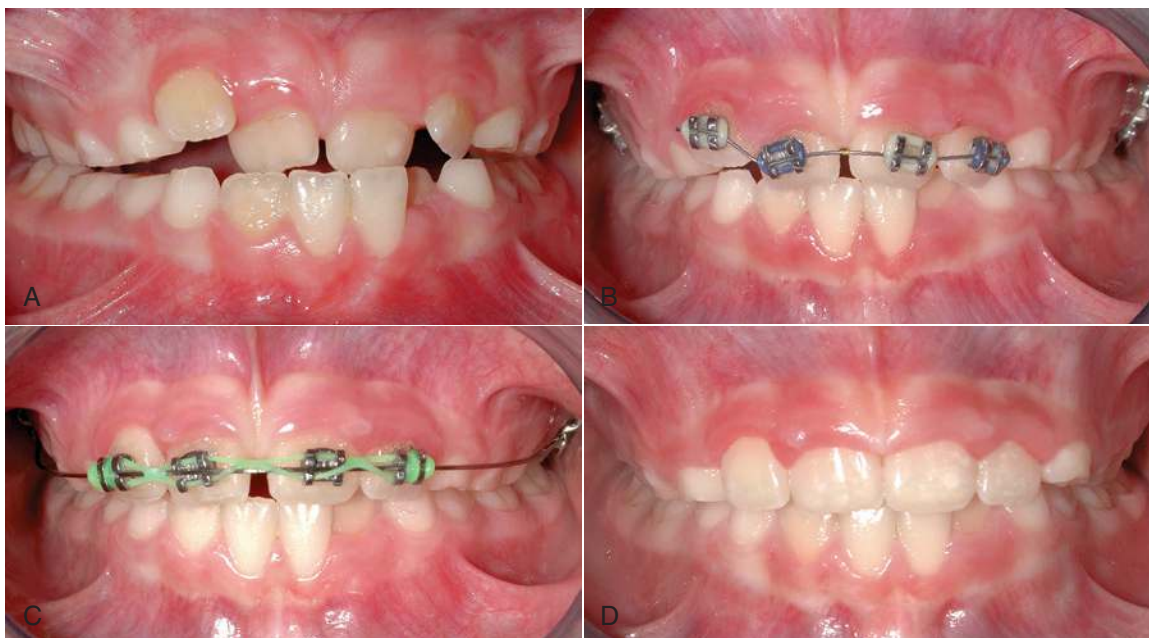


• **Fig. 11.25** Anterior crossbite correction with a removable appliance to tip teeth. (A) The permanent maxillary left central incisor has erupted into crossbite and (B) has been corrected with a removable appliance. (C) This appliance is used to tip both central incisors facially with a 22-mil double helical fingerspring activated 2 mm per month to produce 1 mm per month of tooth movement. Note that plastic baseplate material extends over the spring to maintain its vertical position (see [Chapter 10](#)). The appliance is retained with multiple Adams clasps.



• **Fig. 11.26** (A) An anterior crossbite caused by lingual position of the maxillary incisors can be corrected by using (B) a 36-mil lingual arch with soldered 22-mil fingersprings. A guidewire can be placed between the incisors as shown here to keep the springs from moving incisally. (C) After correction, the appliance can be modified to serve as a retainer by soldering the free ends of the springs to the lingual arch.





• **Fig. 11.27** (A) This patient has an anterior crossbite and irregular maxillary anterior teeth. (B) A 14-mil segmental nickel–titanium (NiTi) archwire was used from maxillary lateral to lateral incisors to take advantage of the archwire’s extreme flexibility for alignment. (C) This was followed by a heavier stainless steel archwire that extended to the molars for more control and stability for diastema space closure with an elastomeric chain as well as (D) final alignment.

**Fixed Appliance Therapy.** One of the simplest fixed appliances for correction of maxillary incisors with a moderate anterior crossbite is a maxillary lingual arch with fingersprings (sometimes referred to as whip springs). This appliance (Fig. 11.26) is indicated for a child with whom compliance problems are anticipated. The springs usually are soldered on the opposite side of the arch from the tooth to be corrected, in order to increase their length. They are most effective if they are approximately 15 mm long. When these springs are activated properly at each monthly visit (advancing the spring about 3 mm), they produce tooth movement at the optimum rate of 1 mm per month. The greatest problems are distortion and breakage from poor patient cooperation and poor oral hygiene, which can lead to decalcification and decay.

It also is possible to tip the maxillary incisors forward with a  $2 \times 4$  fixed appliance (2 molar bands, 4 bonded incisor brackets). In the rare instance in which there is no skeletal component to the anterior crossbite, this is the best choice for a patient with mixed dentition with crowding, rotations, the need for bodily movement, and more permanent teeth in crossbite (Fig. 11.27). When the anterior teeth are bonded and moved before permanent canine eruption, it is best to place the lateral incisor brackets with some increased mesial root tip so that the roots of the lateral incisors are not repositioned into the canine path of eruption, with resultant resorption of the lateral incisor roots. If torque or bodily repositioning is needed for these teeth, finishing with a rectangular wire is required even in early mixed dentition treatment. Otherwise, the teeth will tip back into crossbite again.

See Fig. 11.28 for a flowchart to help guide decision making for anterior crossbites.

## Anterior Open Bite

### Oral Habits and Open Bites

An open bite in a preadolescent child with normal vertical facial proportions is most likely caused by a habit such as thumb- or finger-sucking. Deviation from the usual pattern in transition from the primary to the permanent dentition may also be an etiologic factor, but this is less likely. A disproportionately large lower anterior face height with a severe anterior open bite indicates a skeletal problem (excessive vertical growth and rotation of the jaws). All told, these problems affect less than 4% of the mixed dentition population (see Fig. 1.13).

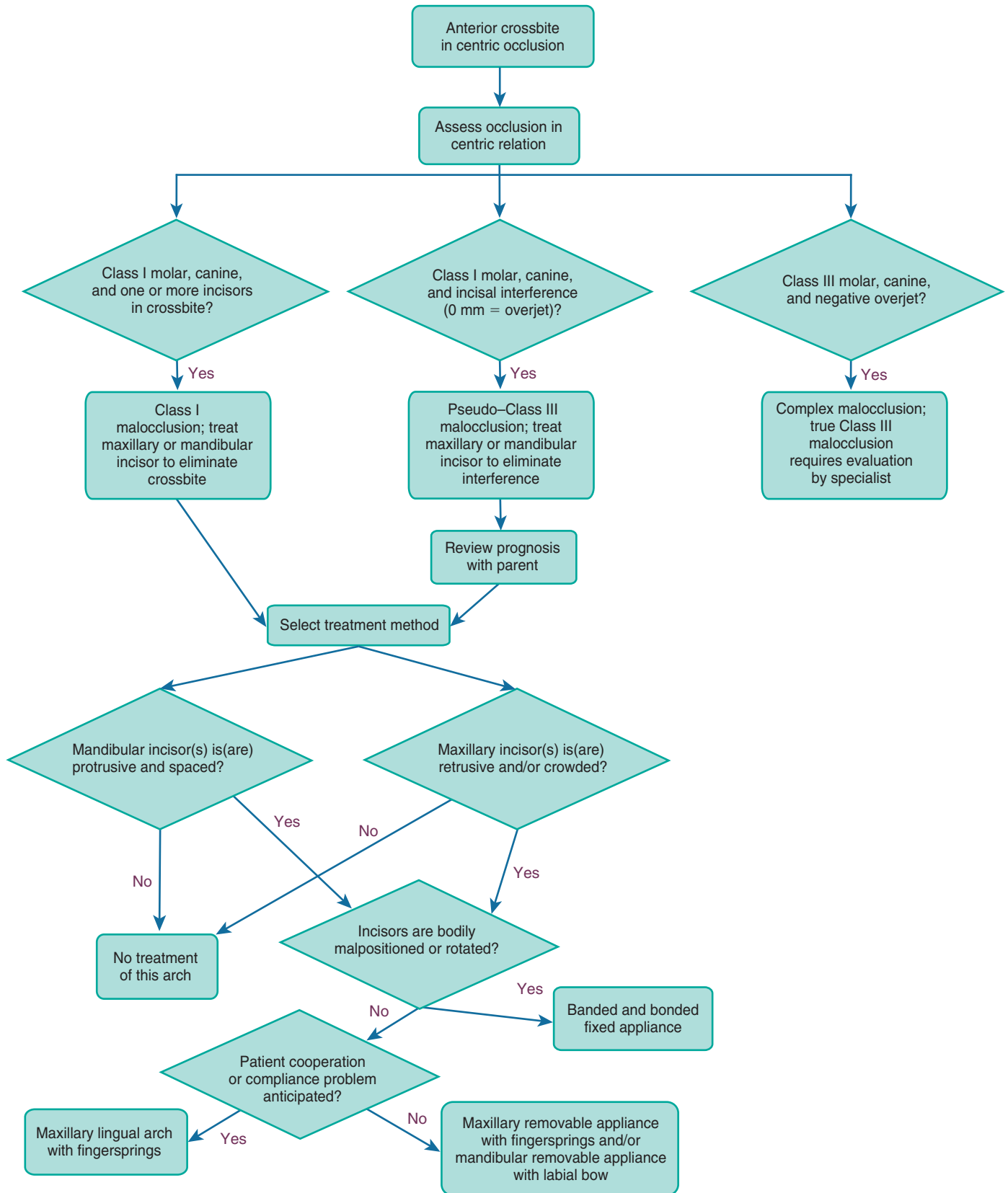
Many of the transitional and habit problems resolve with either time or cessation of the sucking habit. Open bites that persist until adolescence, except those related to habits, almost always have a significant skeletal component, and careful diagnosis of the contributing factors is required.<sup>9</sup> These are termed *complex open bites* and require advanced treatment methods (see Chapter 14).

**Effects of Sucking Habits.** First, let us consider breastfeeding. Advocates include a reduced prevalence of malocclusion among its benefits, but in the long run there appears to be no difference in prevalence of malocclusion between breastfed and non-breastfed children.<sup>10</sup> It is apparent that longer breastfeeding leads to fewer non-nutritive sucking habits.<sup>11</sup>

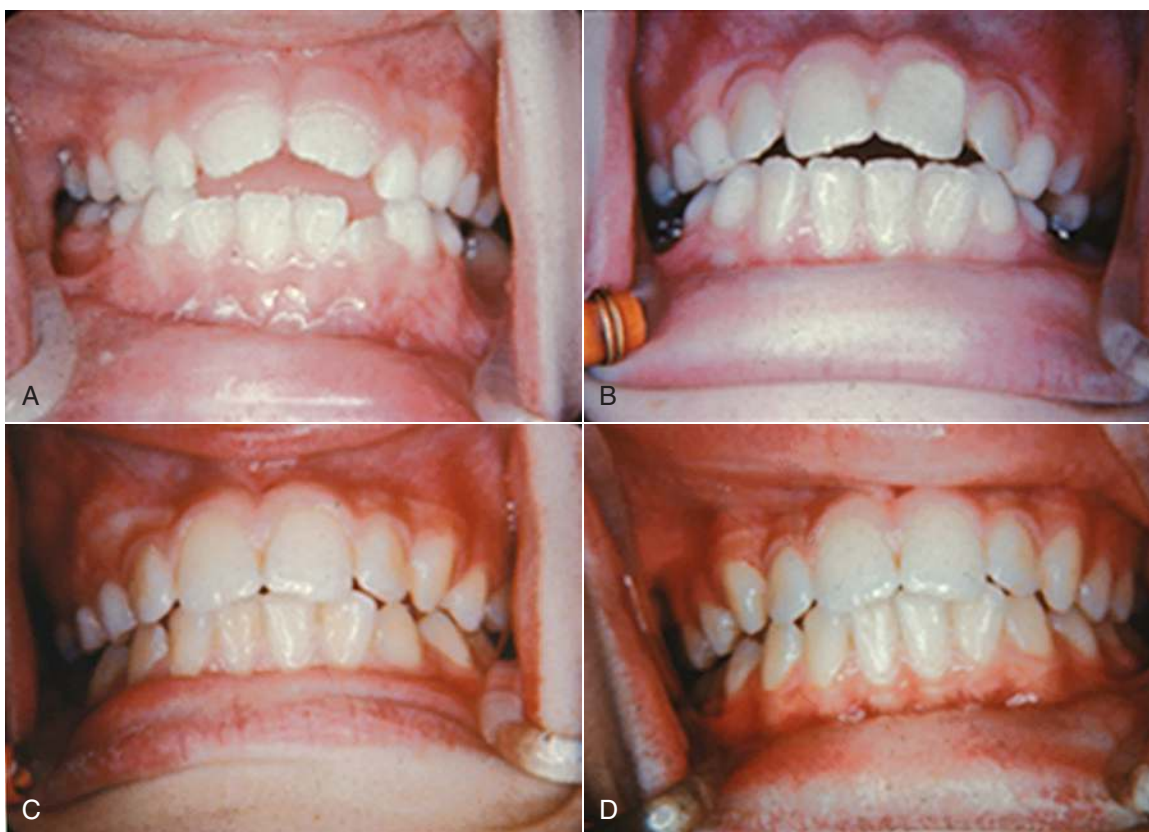During the primary dentition and early mixed dentition years, many children engage in digit- and pacifier-sucking, with these behaviors being more prevalent in girls and non-breastfed children. Although it is possible to deform the alveolus and displace the teeth during the primary dentition years with a prolonged and



## Anterior Crossbite—Pathways of Care



• **Fig. 11.28** This flowchart can be used to aid decision making regarding possible options for anterior crossbites in the primary and mixed dentitions. Answers to the questions posed in the chart should lead to successful treatment pathways.



• **Fig. 11.29** (A) to (D) Photos at 1-year intervals of a child who stopped sucking his thumb at the time of the first photo. Gradual closure of the open bite, without a need for further intervention, usually occurs in patients with normal facial proportions after habits stop.

intense habit, much of the effect is on eruption of the permanent anterior teeth. The extent to which such a habit affects eruption depends on its frequency (hours per day) and duration (months or years) (see [Chapter 5](#)). With frequent and prolonged sucking, maxillary incisors are tipped facially, mandibular incisors are tipped lingually, and eruption of some incisors is impeded. As one would expect, overjet increases and overbite decreases. In many children, maxillary intercanine and intermolar width is narrowed, resulting in a posterior crossbite with a V-shaped arch form.

When the effect of digit-sucking is compared with the effect of pacifier use, there is some evidence for increased prevalence of posterior crossbites with pacifiers, and especially with pacifier use for more than 18 months. Pacifier shapes that are designed to produce a more physiologic sucking pattern have not been proven to be beneficial when compared with other pacifiers or to finger-sucking.<sup>12</sup> Most children have a non-nutritive sucking habit at 24 months, but only 40% have one at 36 months.<sup>13</sup> These habits decrease with age, and pacifier habits are observed less often with older children than digit habits. The social pressures of school are a strong deterrent.

As long as the habit stops before the eruption of the permanent incisors, most of the changes resolve spontaneously with the exception of posterior crossbite ([Fig. 11.29](#)).<sup>14</sup> By that time, the majority of children have stopped their sucking habit. Another group still suck but want to stop, and yet another small group do not want to stop and appear to be immune to social pressure. If

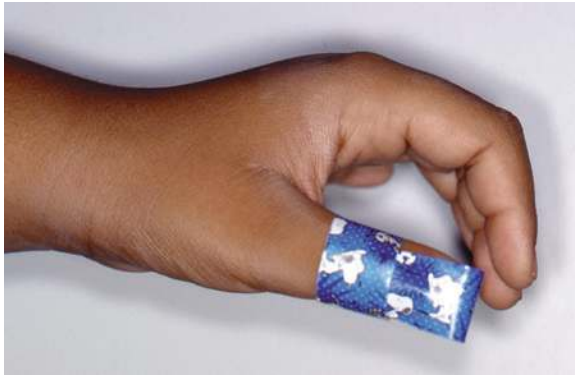
a child does not want to quit sucking, habit therapy (especially appliance therapy) is not indicated.

**Nondental Intervention.** As the time of eruption of the permanent incisors approaches, the simplest approach to habit therapy is a straightforward discussion between the child and the dentist that expresses concern and includes an explanation by the dentist of the problems caused by a prolonged finger habit. This “adult” approach (and restraint from intervention by the parents) may be enough to terminate the habit during this first part of the transition to the permanent dentition, but is most effective with older children.

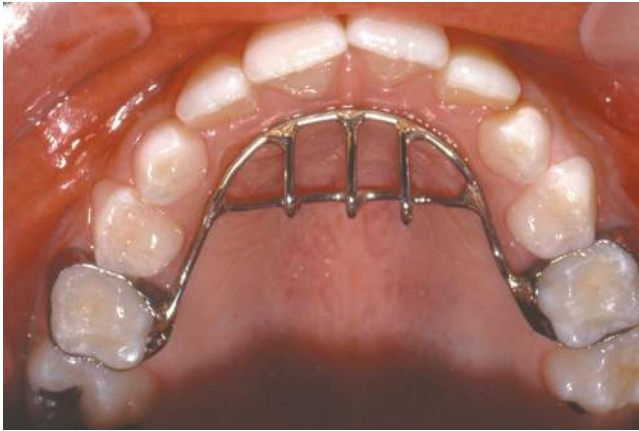Another level of intervention is reminder therapy. This is for the child who wants to quit but needs help. Any one of several reminders that are introduced with an explanation to the child can be useful. One of the simplest approaches is to secure an adhesive bandage with waterproof tape on the finger that is sucked ([Fig. 11.30](#)). The anterior portion of the quad helix appliance also can be quite useful as a reminder when it is placed in the appropriate position in the palate (see [Fig. 11.16](#)).

If the reminder approach fails, a reward system can be implemented that provides a small tangible daily reward for not engaging in the habit. In some cases, a large reward must be negotiated for complete cessation of the habit.

If all these approaches fail and the child really wants to quit, an elastic bandage loosely wrapped around the elbow prevents the arm from flexing and the fingers from being sucked. If this is used, wearing it only at night and 6 to 8 weeks of intervention



• **Fig. 11.30** An adhesive bandage can be applied over the end of the finger to remind the child not to suck and to reduce the enjoyment. The bandage should be anchored at its base for retention with waterproof tape, so that it will stay in place if sucking is still attempted. (Courtesy Dr. B. Joo.)



• **Fig. 11.31** A cemented habit crib made of 38- to 40-mil wire can be used as a reminder to interrupt a finger-sucking habit. The appliance can be cemented to either primary or permanent molars and should be extended anteriorly to interfere with the finger position during sucking. The amount of overbite will also help determine the appliance position. A crib is most effective in a child who wants to stop the thumb or finger habit and accepts the crib as a reminder.

should be sufficient. The child should understand that this is not punishment.

**Appliance Therapy.** If the previous methods have not succeeded in eliminating the habit, a removable reminder appliance is contraindicated because lack of compliance is part of the problem. The child who wants to stop can be fitted with a cemented reminder appliance that impedes sucking (Fig. 11.31). These appliances can be deformed and removed by children who are not compliant and do not truly wish to stop the habit, so cooperation still is important. If this is understood by the child as a “helping hand” rather than punishment, the treatment will be successful and psychologic problems will not result.<sup>15</sup> The preferred method is a maxillary lingual arch with an anterior crib device, making it extremely difficult for the child to place the thumb or other object in the mouth.

In about half of the children for whom such a crib is made, thumb-sucking stops immediately and the anterior open bite usually begins to close relatively rapidly thereafter. In the remaining children,

thumb-sucking persists for a few weeks, but the crib device is eventually effective in extinguishing thumb-sucking in 85% to 90% of patients.<sup>16</sup> It is a good idea to leave the crib in place for 6 months after the habit has apparently been eliminated. Commonly, these cemented reminders, like lingual arch expanders, leave an imprint on the tongue (see Fig. 11.17) that will resolve some time after the appliance is removed. The appliances also trap food and can lead to mouth odor, so excellent oral hygiene is important.

The open bites associated with sucking in children with normal jaw relationships often resolve after sucking stops and the remaining permanent teeth erupt (see Fig. 11.29). An appliance to laterally expand a constricted maxillary arch will be required, and flared and spaced incisors may need retraction, but the open bite should require no other treatment in children with good skeletal proportions.

A flowchart is provided to help guide decision making for open bite problems related to oral habits (Fig. 11.32).

## Deep Bite

Before treating an overbite problem, it is necessary to establish its cause. Significant deep bites affect approximately 20% of patients with mixed dentition (see Fig. 1.13). The problem may result from reduced lower face height, lack of eruption of posterior teeth, or overeruption of the anterior teeth. The possible treatments are quite different and mutually exclusive.

True reduced lower face height is a skeletal problem and requires more complex treatment (see Chapter 14). Undereruption of posterior teeth or overeruption of anterior teeth also are complex problems that are addressed during comprehensive treatment. They are rarely treated during the mixed dentition years unless there is developing tissue damage (see Fig. 11.10). In those instances, as an interim measure a removable appliance with an anterior bite plane to encourage eruption of the posterior teeth may also provide protection of the affected tissue. This type of appliance can be modified to also impede further eruption of the lower anterior teeth. Treatment like this is only a temporary solution, and the child will require comprehensive treatment in the permanent dentition.

## Management of Eruption Problems

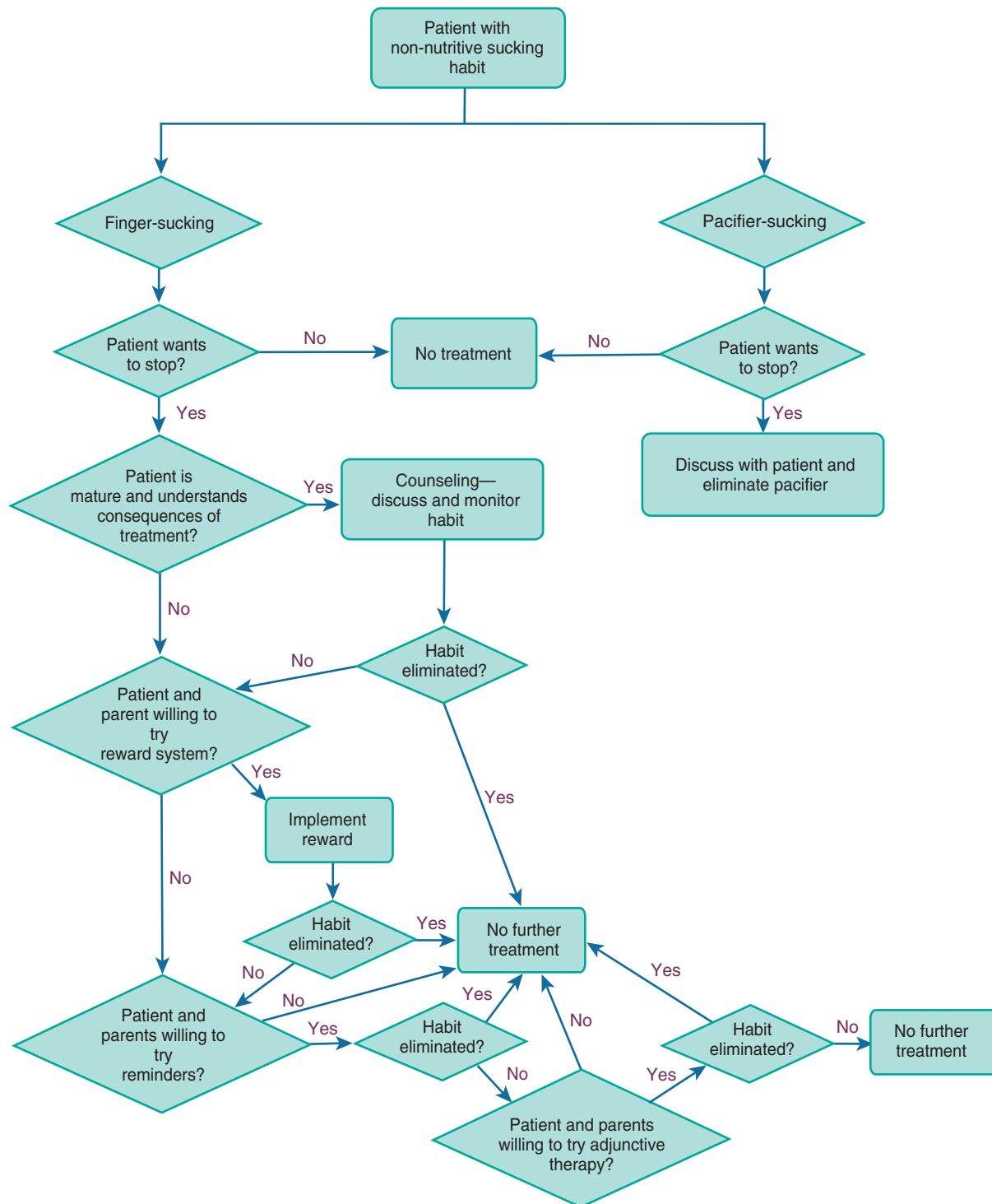
### Overretained Primary Teeth

A permanent tooth should replace its primary predecessor when approximately three-fourths of the root of the permanent tooth has formed, whether resorption of the primary roots is or is not to the point of spontaneous exfoliation. Given enough time, the primary tooth will exfoliate, but a primary tooth that is retained beyond this point should be removed because it often leads to gingival inflammation and hyperplasia that cause pain and bleeding and sets the stage for deflected eruption paths of the permanent teeth that can result in irregularity, crowding, and crossbite. If a portion of the permanent tooth crown is visible and the primary tooth is mobile to the extent that the crown will move 1 mm in the facial and lingual direction, it is probably advisable to encourage the child to “wiggle” the tooth out. If that cannot be accomplished in a few days, extraction is indicated. Most overretained primary maxillary molars have either the buccal roots or the large lingual root intact; most overretained primary mandibular molars have either the mesial or distal root still intact and hindering exfoliation.

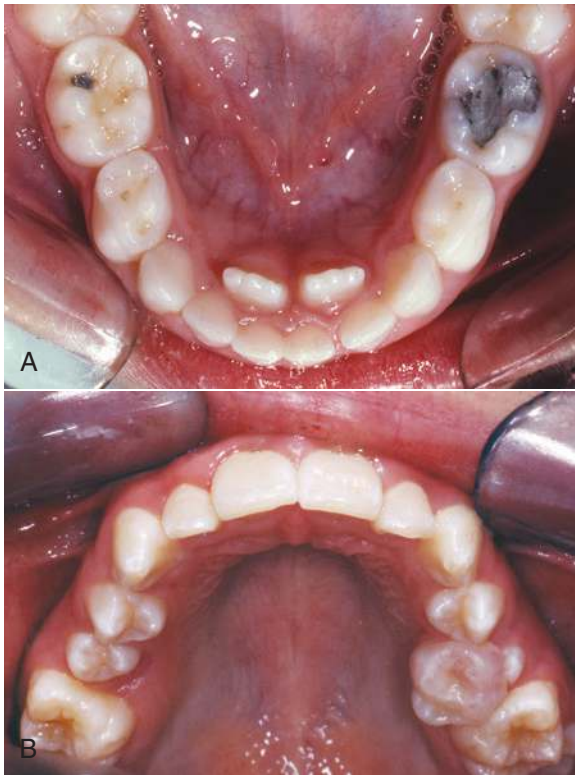
Once the primary tooth is out, if space is adequate, moderately abnormal facial or lingual positioning will usually be corrected by



### Oral Habits—Pathways of Care



• **Fig. 11.32** This flowchart can be used to aid decision making regarding possible options for non-nutritive sucking habits during the primary and mixed dentitions. Answers to the questions posed in the chart should lead to successful treatment pathways.



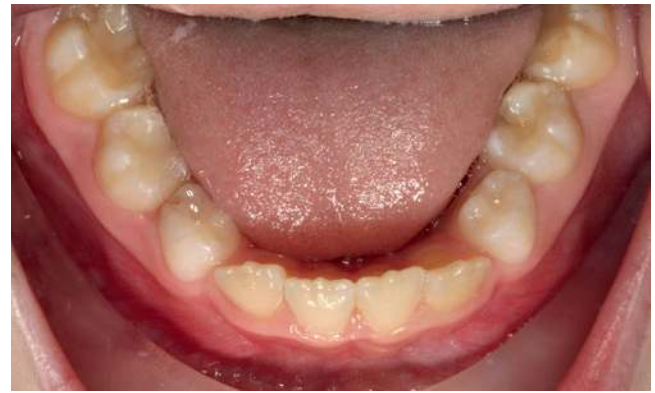• **Fig. 11.33** Permanent teeth often erupt in abnormal positions as a result of retained primary teeth. (A) These lower central incisors erupted lingually because the permanent incisors have not been lost and their tooth buds are positioned lingual to the primary incisors. This is a common occurrence in this area and is the main reason lingual arches should not be placed until after lower incisors erupt. (B) This maxillary left second premolar has been deflected facially because of the retained primary molar. In both the circumstances shown here, removal of the retained primary tooth or teeth will allow some spontaneous alignment.

the equilibrium forces of the lip, cheeks, and tongue. In general, incisors will erupt lingually and then move facially when over-retained primary incisors exfoliate or are removed (Fig. 11.33). If spontaneous correction has not occurred when overbite is achieved, however, further alignment is unlikely in either the anterior or posterior quadrants, and active tooth movement will be required to correct the crossbite.

## Ectopic Eruption

The term *ectopic eruption* is used to describe the situation in which a permanent tooth erupts on a deviant eruption path, so it emerges into the mouth at a different point than it should have or becomes totally blocked, and often causes damage to the roots of other teeth. As we have noted previously, osteoclasts above the crown of an erupting tooth resorb tooth roots as readily as bone.

Any permanent tooth can erupt ectopically, and examples are shown in several locations in this book, starting with the discussion in Chapter 6. Three patterns of deviant eruption, however, are both reasonably frequent and clinically significant, and deserve consideration during the mixed dentition: lateral incisors in both arches, maxillary first molars, and maxillary canines.



• **Fig. 11.34** This patient lost two primary canines during the eruption of the permanent lower incisors. This usually indicates either a large incisor liability or a substantial shortage of lower arch perimeter.

## Lateral Incisors

When the permanent lateral incisors erupt in both arches, some degree of root resorption of the primary canines is common, and less frequently, one or both these teeth are lost. In some patients, this is just a symptom of the temporary incisor crowding that is normal in the early mixed dentition (see Chapter 4) and not an indication of long-term crowding. More often, loss of one or both primary canines indicates a significant lack of enough space for all the permanent teeth, so either major arch expansion or premolar extraction ultimately will be required. Space analysis, including an assessment of the anteroposterior incisor position and the facial profile, is needed to determine whether space maintenance, space management, or space regaining is needed, or whether more complex treatment to deal with major space problems that are better managed by referral to specialty practices will be required.

Early loss of one or both *maxillary* primary canines almost never requires immediate treatment; indeed, as you will see later, early extraction of maxillary primary canines is important in preventing impaction of the permanent canines, because closure of the space rarely occurs.

In contrast, early loss of one or both mandibular primary canines can be a more complex problem that is best managed in specialty practice but is discussed here.

When both mandibular primary canines are lost as the lateral incisors erupt, either there is a substantial “incisor liability” (the difference in the size of the primary and permanent incisors) that can still be accommodated by space management with a lingual arch during the transition and the available leeway space (see later in this chapter) or there is a true arch length shortage (Fig. 11.34). If there is a moderate shortage and the incisor position can tolerate expansion, that is an option. If the crowding is more severe, extraction of permanent teeth is a more reasonable option (see Chapter 12 for details on both these topics). Guidance for these decisions comes from doing a space analysis and assessing the incisor position.

An early decision as to how to manage patients with early loss of one mandibular primary canine also is required (Fig. 11.35). In that situation, the predominant thinking has been that the remaining retained primary canine should be extracted to prevent a shift of the midline, a lingual arch placed to keep the incisors from tipping lingually, and a fixed appliance used to correct a developing midline asymmetry if that was occurring. This has

recently been shown not to be the usual result of the loss of one primary canine more than a year before the loss of the contralateral primary canine. Using data from the Iowa and Burlington growth studies, Christensen et al<sup>17</sup> showed that the prevalence of a clinically significant midline shift after premature loss of one primary canine was not statistically or clinically greater than what was seen in patients with normal eruption (1.3 and 1.0 mm, respectively).

With this in mind, the clinician faced with early loss of one mandibular primary canine now can choose among several approaches. A passive lingual arch to prevent lingual tipping only could still be used, but the new data suggest that it is not necessary to hold the midline or extract the contralateral tooth. An early phase of  $2 \times 4$  or  $2 \times 6$  treatment to correct minor midline changes also could be deferred.

### Maxillary First Molars

Ectopic eruption of a permanent first molar presents an interesting problem that is usually diagnosed from routine bitewing radiographs rather than clinically because it is painless. When only small amounts of resorption ( $<1$  to 1.5 mm) are observed (Fig. 11.36), a period of watchful waiting is indicated because self-correction is possible and occurs in about two-thirds of the cases. If the blockage of

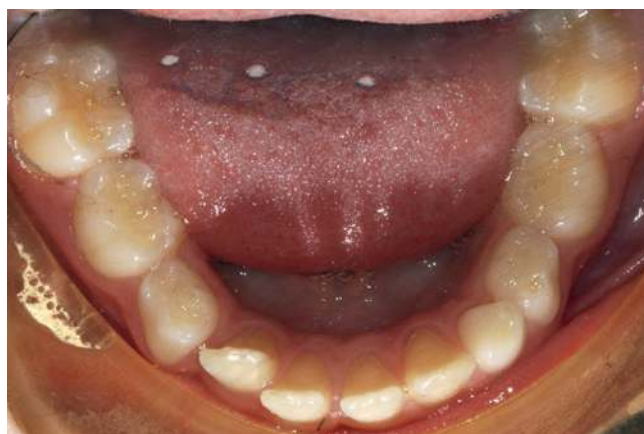eruption persists for 6 months or if resorption continues to increase, treatment is indicated. Lack of timely intervention may cause loss of the primary molar and space loss as the permanent molar erupts mesially and rotates mesiolingually.

Several methods can be helpful when intervention is necessary.<sup>18</sup> The basic approach is to move the ectopically erupting tooth away from the primary molar it is resorbing. If a limited amount of movement is needed but little or none of the permanent first molar is visible clinically, a 22-mil brass wire looped and tightened around the contact between the primary second molar and the permanent molar is suggested (Fig. 11.37). It may be necessary to anesthetize the soft tissue to place the brass wire, and depending on the tooth position and depth of the contact between the permanent and primary molars, it can be difficult to successfully direct the brass wire subgingivally. The brass wire should be tightened at each adjustment visit, approximately every 2 weeks, so that it will not move in relation to the teeth. If the wire is not tightened to the point that the patient feels some discomfort, it has not been appropriately adjusted. Treatment is slow but reliable when used with limited resorption.

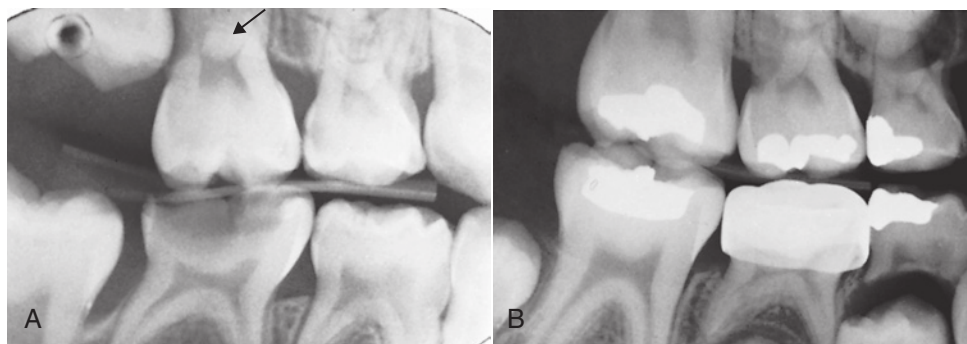
A steel spring clip separator, available commercially, may work if only a small amount of resorption of the primary molar roots exists. These clips are difficult to place if the point of contact between the permanent and primary molars is much below the cemento-enamel junction of the primary molar, although some are available that have greater vertical distances for just these situations (Fig. 11.38). They can be activated on a biweekly basis.

Elastomeric separators wedged mesial to the first molar also can be used to push it distally so it can erupt but are not recommended. The current elastomeric separators are large. They are well retained for normally positioned teeth, but they require substantial force to place them below the contact of an impacted molar. They have the potential to become dislodged in an apical direction and cause periodontal irritation. If this occurs, the separators are hard to locate and retrieve, especially if the material is not radiopaque.

If resorption on the distal roots of the primary second molars is severe and more distal movement is required than can be provided by the brass wire or metal separators, the situation becomes more complicated. If access can be gained to the occlusal surface of the molar, a simple fixed appliance can be fabricated to move the molar distally. The appliance consists of a band on the primary molar (which can be further stabilized with a transpalatal arch)

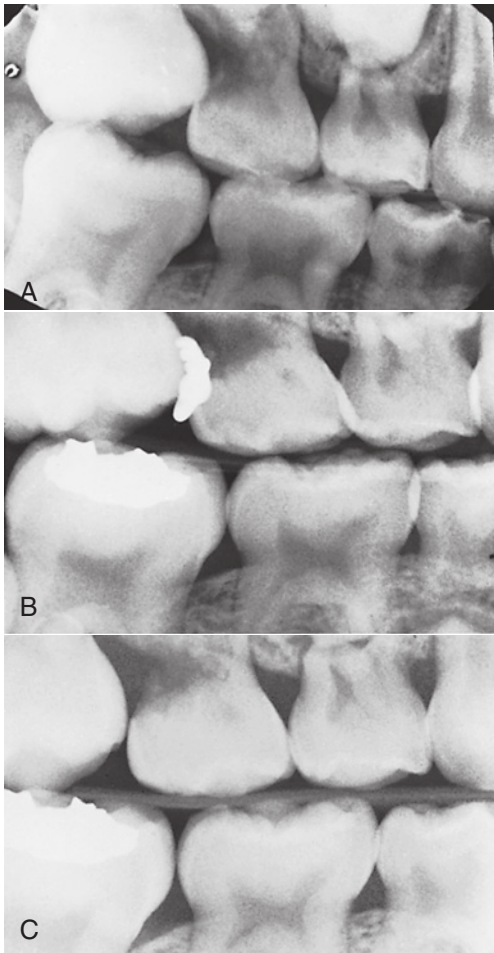


• **Fig. 11.35** This patient lost one primary canine when the lower incisors erupted and had a shift of the midline to the right. Shifts of this magnitude are, on average, rare.



• **Fig. 11.36** Ectopic eruption of the permanent first molar is usually diagnosed from routine bitewing radiographs. If the resorption is limited, immediate treatment is not required. (A) The distal root of the primary maxillary second molar shows minor resorption from ectopic eruption. (B) This radiograph taken approximately 18 months later illustrates that the permanent molar was able to erupt without treatment.

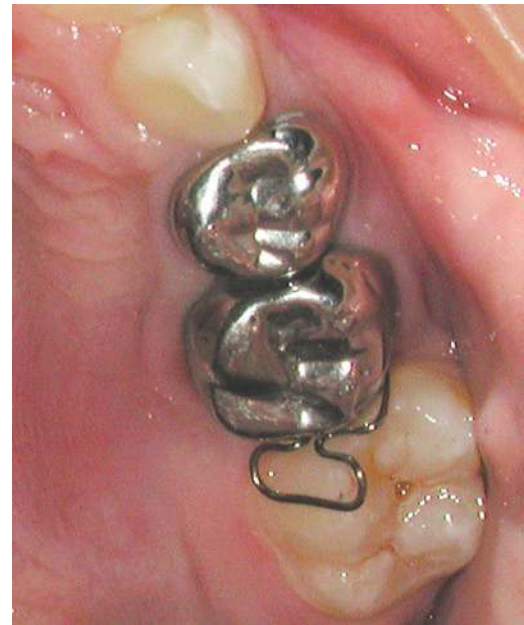



• **Fig. 11.37** Moderately advanced resorption from ectopic eruption of the permanent maxillary first molar requires active intervention. (A) This distal root of the primary maxillary second molar shows enough resorption that self-correction is highly unlikely. (B) A 22-mil dead soft brass wire is guided under the contact (starting from either the facial or lingual surface and proceeding with the most advantageous approach) and then looped around the contact between the teeth and tightened at approximately 2-week intervals; (C) the permanent tooth is dislodged distally and erupts past the primary tooth that is retained.

with a soldered spring that is bonded to the permanent molar (Fig. 11.39). In lieu of using a soldered appliance that must be fabricated in the laboratory, a similar but alternative appliance can be fabricated intraorally with either a band and looped spring (Fig. 11.40A) or two bonded brackets (a first molar bracket on the primary molar and a second molar bracket on the first molar) and a looped spring (Fig. 11.40B). With either appliance, if the movement is not sufficient in 2 weeks, the loop can be reactivated.

If the permanent molar has caused extensive resorption of the primary molar, there may be no choice but to extract the primary tooth, which allows the permanent molar to continue to move mesially and shorten the arch length. Unless the second premolar is missing and the arch length is purposefully to be reduced or unless considerable mesial molar movement is tolerable and later premolar extraction is planned, a distal shoe that guides the erupting molar should be placed after the extraction (see later in this chapter). Even if this technique is used, some space has already been lost and the permanent molar will have to be repositioned distally after



• **Fig. 11.38** An Arkansas spring (Arkansas Dental Products Co, West Plains, MO), a scissors-like spring that extends below the contact point, can be effective in tipping a permanent first molar distally so that it can erupt. The posterior bow is crimped to bring the subgingival legs together and apply pressure to separate the teeth.

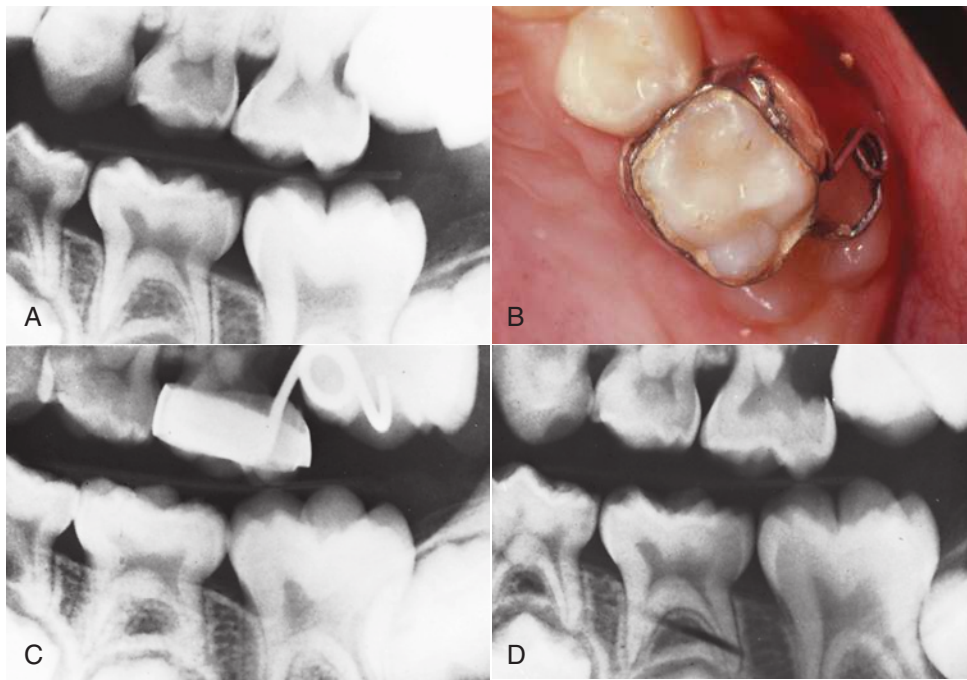
it fully erupts by using another type of space-regaining appliance described in this chapter or Chapter 12.

A flowchart summarizes the decision making for ectopic eruption of permanent first molars (Fig. 11.41).

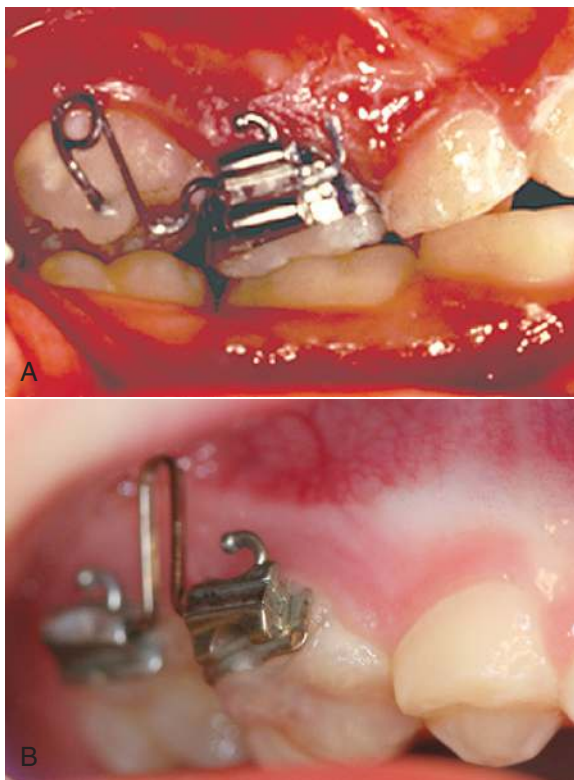
### Maxillary Canines

At approximately age 10, if a maxillary primary canine is not mobile and there is no observable or palpable facial canine bulge, ectopic eruption of maxillary canines should be considered because it is a relatively frequent occurrence (the incidence of ectopic eruption and impaction of canines is in the 1% to 2% range).<sup>19</sup> This can lead to either or both of two problems: (1) impaction of the canine and/or (2) resorption of permanent lateral and/or central incisor roots.<sup>20</sup> There appears to be a genetic basis for this eruption phenomenon, and in some cases it is related to small or missing maxillary lateral incisors and missing second premolars.<sup>21</sup> Root resorption of the permanent incisors is significantly more likely to occur when no space is available for the canine.<sup>22</sup>

Although multiple studies now have shown that cone beam computed tomography (CBCT) images are superior to two-dimensional (2-D) images for both localization of impacted canines and evaluation of resorption of roots of other teeth,<sup>23</sup> it is probably better to get a full view of the status of the patient first with a digital panoramic radiograph because dental anomalies are genetically related, and other anomalies may well be present (peg or missing lateral incisors, missing premolars, and transposed teeth). Then, depending on the findings, it is sensible to obtain detailed information on root resorption and position of the canine eruption from a small field-of-view (FOV) CBCT (Fig. 11.42). These views can be supplemented with a traditional cephalometric digital image if required for limited or comprehensive orthodontic care. This is less radiation than to initially obtain a full-field CBCT (see Table 6.13).



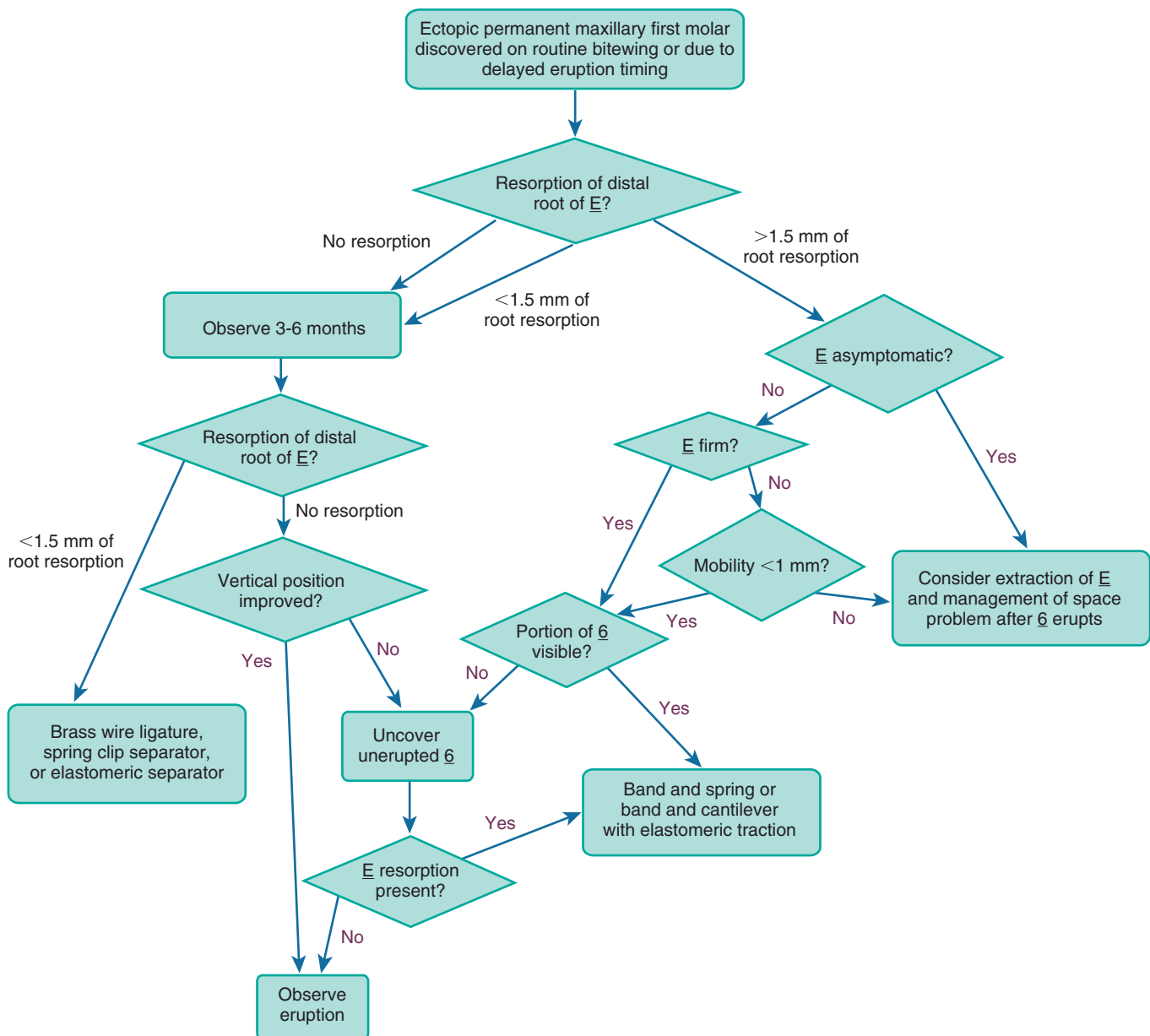
• **Fig. 11.39** Ectopic eruption with severe resorption may require appliance therapy. (A) This primary maxillary second molar shows severe resorption. (B) If the occlusal surface of the permanent molar is accessible, the primary molar can be banded and a 20-mil spring soldered to the band. (C) The permanent molar is tipped distally out of the resorption defect and (D) once disengaged, is free to erupt.



• **Fig. 11.40** (A) A band and spring appliance can be fabricated intraorally with a savings of time and laboratory expense. A band with an attachment having a buccal tube is cemented on the primary second molar. Next a large omega-shaped loop and a helical loop are bent distal to the primary molar. The spring is activated, and the wire is inserted into the primary molar tube from the distal surface and secured with a bend anterior to the molar tube. The helical loop is compressed during bonding to the occlusal surface of the permanent first molar. The appliance is reactivated intraorally by opening the omega loop with loop-forming pliers with the round beak positioned superior to the wire. (B) Another option for repositioning an ectopically erupting first molar is to bond archwire tubes on both the primary second molar and the permanent first molar. Then, bend an opening loop from either rectangular beta-titanium or stainless steel wire, and compress it to seat from the distal into the primary molar tube and from the mesial into the permanent molar tube. The force from the activated loop will retain the rectangular wire, which can be carefully positioned adjacent to the soft tissue. This avoids banding and laboratory procedures.

Given the potential complications of continued ectopic canine eruption, early diagnosis and intervention are warranted to either prevent or limit root resorption. When a mesial position of the erupting permanent canine is detected and incisor root resorption is threatened but has not yet occurred, extraction of the primary canine is indicated (Fig. 11.43). Ericson and Kurol found that if the permanent canine crown was overlapping less than half of the root of the lateral incisor as seen in a panoramic radiograph, there was an excellent chance (91%) of normalization of the path of

## Ectopic Eruption of Permanent Maxillary First Molar—Pathways of Care



• **Fig. 11.41** This flowchart can be used to aid decision making regarding possible options when a permanent molar is ectopically erupting during the mixed dentition. Answers to the questions posed in the chart should lead to successful treatment pathways. E, The primary maxillary second molar; 6, the permanent maxillary first molar. (Modified from Kennedy D, Turley P. *Am J Orthod Dentofac Orthop*. 1987;92:336–345.)

eruption. When more than half of the lateral incisor root was overlapped, early extraction of the primary tooth resulted in a 64% chance of normal eruption and likely improvement in the position of the canine even if it was not totally corrected.<sup>24</sup> A recent systematic review confirms this effect.<sup>25</sup> Extraction of the primary canine with maxillary expansion appears to encourage improved permanent canine eruption even more.<sup>26</sup>

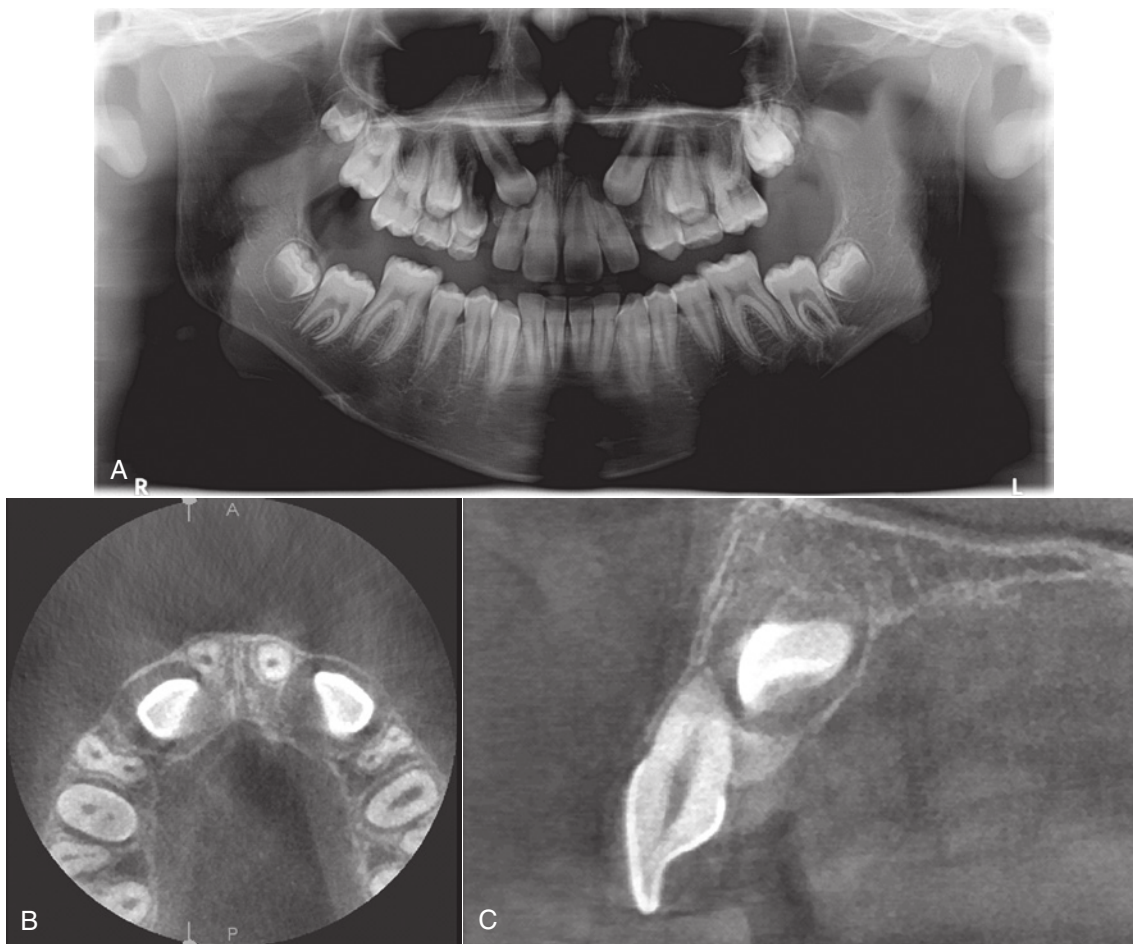
If resorption of the permanent lateral or central incisor roots is occurring, usually it is necessary to surgically expose the permanent canine and use orthodontic traction to bring it to

its correct position (Fig. 11.44). This will stop the resorption caused by the ectopic tooth, but some continued resorption and blunting of the roots may continue when further tooth movement of the affected tooth occurs. This comprehensive treatment will extend into the early permanent dentition period (see Chapter 15).

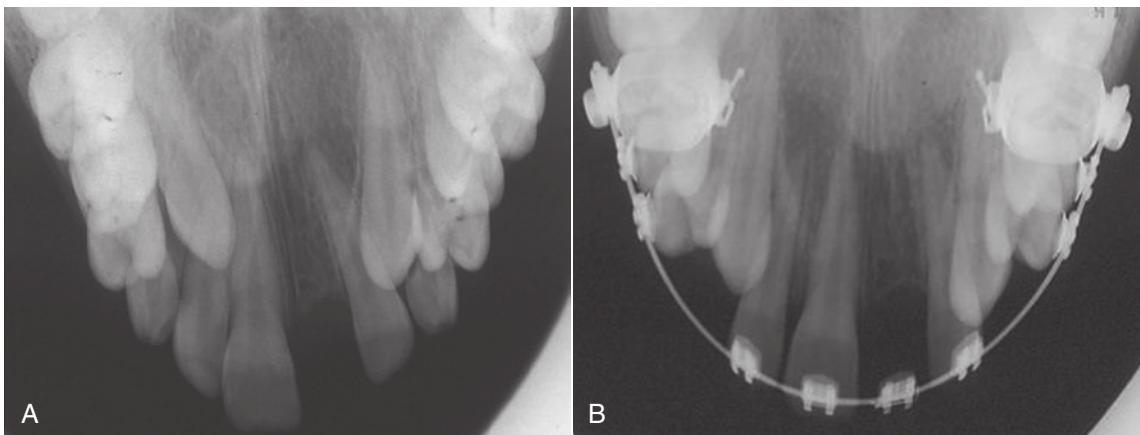
### Supernumerary Teeth

Supernumerary teeth can disrupt the normal eruption of other teeth and cause crowding or spacing. Treatment is aimed at extracting

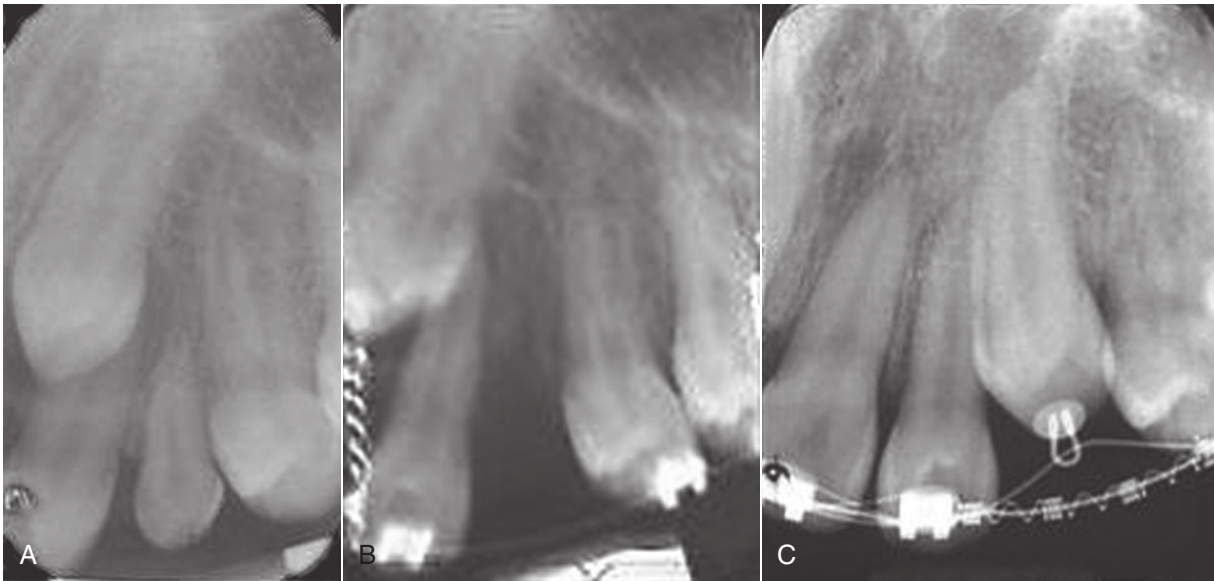




• **Fig. 11.42** (A) Panoramic radiograph showing damage to the maxillary lateral incisor roots from ectopically erupting canines. (B) and (C) Three-dimensional images from small-field-of-view cone beam computed tomography (CBCT), which clarify the position of the unerupted canines and establish the initial direction of movement of the canines that will be needed to prevent further damage to the laterals. The radiation exposure for a CBCT of this type is about the same as with a digital panoramic radiograph, and the CBCT is needed because of its potential to change the treatment plan.



• **Fig. 11.43** (A) This patient has a maxillary right canine positioned over the root of the maxillary right lateral incisor with more than 50% overlap. The left permanent canine overlapped less than 50% of the permanent lateral incisor root. This positioning is associated with an increased risk of resorption of the incisor roots. The adjacent primary canines were extracted and (B) improvement was observed as the right canine nearly totally corrected while the left one made only minor changes in lateral position. These changes probably would not have occurred without the intervention.



• **Fig. 11.44** (A) The maxillary left canine is positioned over the root of the adjacent lateral incisor and causing some initial root resorption. (B) Because of the resorption, the permanent canine was exposed surgically, the primary canine was extracted, and an attachment and metal chain were bonded to the crown of the permanent canine and ligated to the archwire. Attachments sometimes are difficult to bond because of contamination of the tooth surface by saliva and hemorrhage, but the alternative approach of looping a wire around the cervical part of the crown is no longer recommended. That approach requires more extensive bone removal and increases the risk of ankylosis and potential reduced gingival attachment. Using an acid etch as opposed to a combination etch/sealant usually will stop hemorrhage for a short time to enable the bonding. (C) Subsequently, the canine was repositioned distally away from the lateral incisor and into its correct position. This limited the continued resorption of the lateral incisor.

the supernumeraries before problems arise or at minimizing the effect if other teeth have already been displaced.

The most common location for supernumerary teeth is the anterior maxilla. These teeth are often discovered on a panoramic or occlusal radiograph when a child is about 6 to 7 years of age, either during a routine examination or when permanent incisors fail to erupt. The simple cases are those in which a single supernumerary tooth is present and superficially located. If the tooth is not inverted, it will often erupt before or along with the normal tooth and can be extracted before it interferes with the adjacent teeth.

The choice of which tooth to retain and which one is the supernumerary can be difficult, but it really makes no difference. The tooth that should be retained is the one with the best size, color, morphologic characteristics, and position related to the other teeth. All other things being equal, the tooth that is nearest to the ultimate final position should be retained. These decisions are difficult to make from conventional radiographs when the teeth are unerupted, and supernumerary teeth can be missed or continue to develop. Small-FOV CBCT can be helpful and is indicated now for evaluation of most of these patients.

When multiple supernumerary teeth are discovered or suspected, the difficulty of diagnosis and treatment is amplified. This is covered in [Chapter 12](#).

### Delayed Incisor Eruption

When an incisor has failed to erupt more than a year past the normal eruption time and adjacent teeth have erupted, there is no excuse for delaying treatment. The esthetic and social consequences along with the impact on ultimate eruption and development of the dentition are bound to be significant. A retained

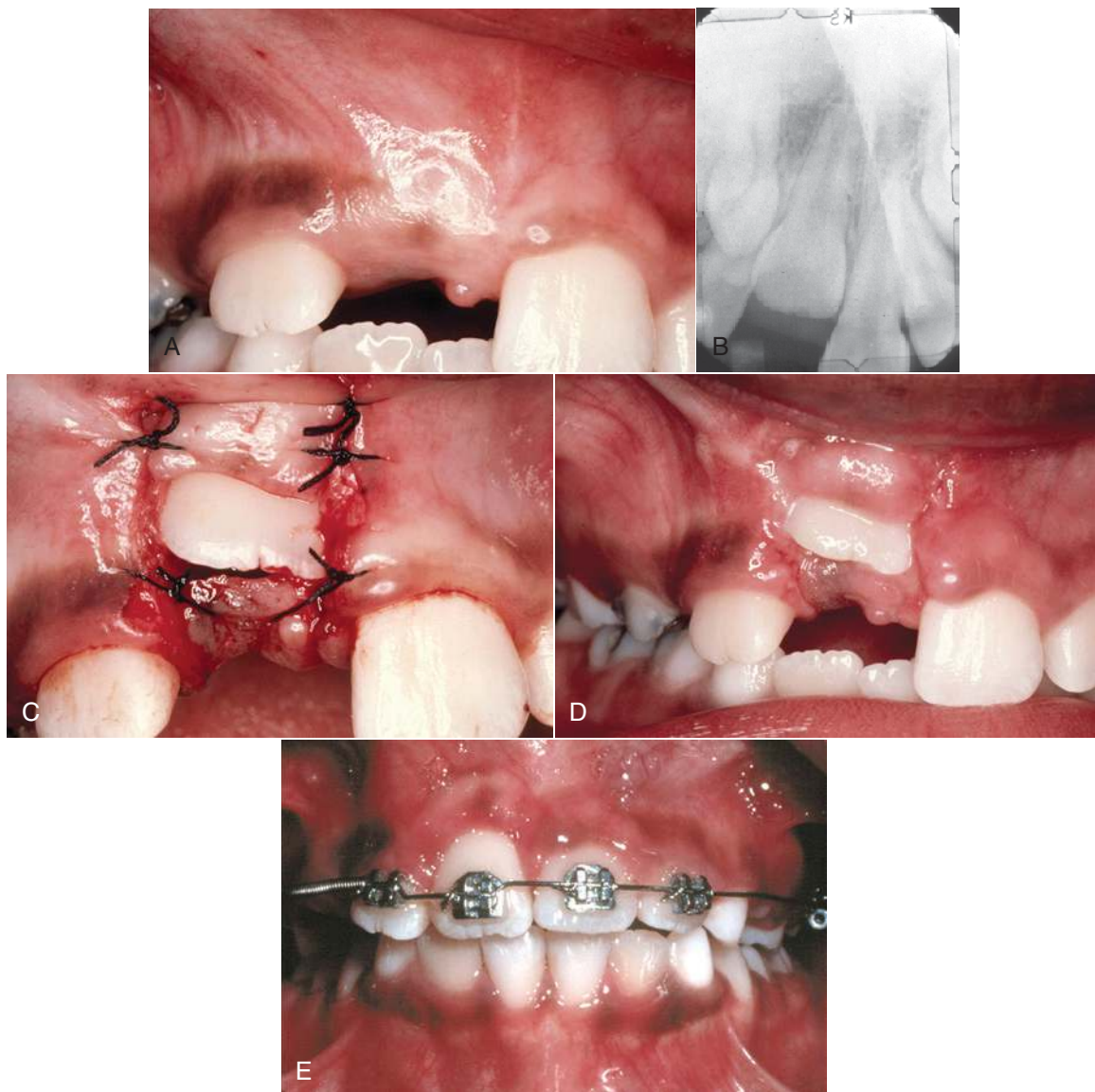
primary tooth, supernumerary tooth, or some type of pathologic condition is most commonly associated with delayed incisor eruption. The best advice is to count the teeth and pay close attention to departures from normal eruption timing.

The first consideration in evaluating this situation is the morphologic features (usability) of the unerupted tooth and its position. If the tooth is not malformed and is located superficially under the keratinized tissue, it can be exposed with a simple soft tissue excision and usually will erupt rapidly ([Fig. 11.45](#)). If the tooth is more deeply positioned, it is likely to need fixed appliance treatment to bring it into proper position. This is discussed in [Chapter 12](#).

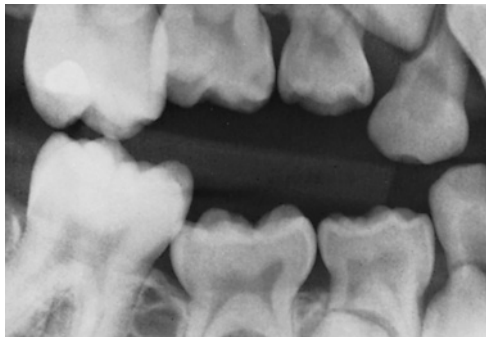
### Ankylosed Primary Teeth

Ankylosed primary teeth with permanent successors, especially ankylosed primary molars, constitute a potential alignment problem for the permanent teeth. Although these teeth usually resorb without creating long-term problems, occasionally they fail to resorb or are retained by a bony attachment in the cervical region. This delays the erupting permanent tooth and can deflect it from the normal eruption path. Appropriate management of an ankylosed primary molar consists of maintaining it until an interference with eruption or drift of other teeth begins to occur ([Fig. 11.46](#)), then extracting it and placing a lingual arch or other appropriate fixed appliance if needed. If adjacent teeth have tipped over the ankylosed tooth, they will need to be repositioned to regain space. Vertical bony discrepancies will be eradicated when the permanent tooth brings bone with it during eruption.

The situation is completely different when an ankylosed primary tooth has no permanent successor. Then, to avoid long-term



• **Fig. 11.45** (A) This patient had a superficially positioned permanent maxillary right central incisor that was unerupted and substantially delayed. (B) The radiograph shows the tooth at the crestal bone level. (C) The flap has been released on both sides, repositioned apically, and sutured in place with adequate exposed tooth structure. (D) One week after surgery, the tissue is healing well. (E) Appliances in place for the final positioning. Note the uneven gingival borders of the two central incisors, which will become more similar with age as the left central incisor's attachment migrates apically.

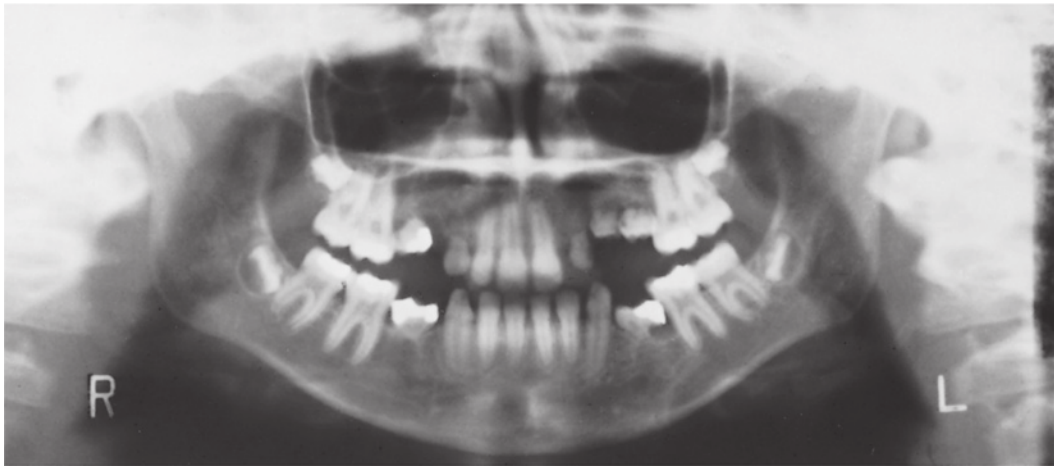


• **Fig. 11.46** This radiograph demonstrates both anterior and posterior teeth tipping over adjacent ankylosed primary molars. The ankylosed teeth should be removed if significant tipping and space loss are occurring.

periodontal problems, there are two approaches. Either the ankylosed primary molar should be extracted before a large vertical occlusal discrepancy develops (Fig. 11.47)<sup>27</sup> or the tooth can be decoronated. This procedure is more complex and is described in Chapter 12.

Because erupting teeth bring alveolar bone with them, in planning and executing treatment it is best to move teeth at least partially into the edentulous space so that new bone is created there, even if the long-range plan is prosthetic replacement of the missing tooth. Space maintenance, therefore, is contraindicated. The longer the ankylosed primary tooth is left in place, the greater the chance of a long-term defect because alveolar bone has not formed in that area. Although extraction of the primary tooth without a successor will result in some loss of alveolar bone, this is preferable to a long-term periodontal





• **Fig. 11.47** If they have no successors, ankylosed primary teeth can be carefully removed when vertical discrepancies begin to develop. It is better to allow permanent teeth to drift into the edentulous space and bring bone with them, and then reposition the teeth before implant or prosthetic replacement, so that large periodontal defects such as those adjacent to the primary molars in this patient do not develop. Another approach is to decoronate the primary molar.

problem due to reduced attachment and exposed cementum on the adjacent teeth.

It is advisable to have an experienced clinician remove these teeth. Unless the extraction is managed carefully, an even worse periodontal defect may occur.

## Space Analysis: Quantification of Space Problems

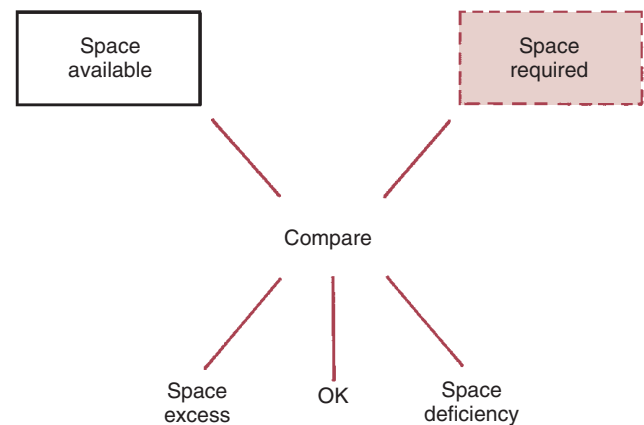
Space problems must be considered from the viewpoint of the space available, which is quantified by the space analysis. The space analysis results must be considered in the context of the profile because reducing protrusion reduces the amount of available space. Conversely, when teeth are retroclined and then moved facially to the correct position, more space is available. The vertical dimension also has an impact on space. It is generally contraindicated to expand when there is limited overbite because tipping teeth facially usually moves them vertically as well and an anterior open bite may develop. In a child with a deep overbite and an accentuated curve of Spee, leveling the arch will make teeth more protrusive.

It is important to quantify the amount of crowding within the arches because treatment varies, depending on the severity of the crowding. Space analysis, using the dental casts, is required for this purpose. Such an analysis is particularly valuable in evaluating the likely degree of crowding for a child with a mixed dentition when the permanent teeth are erupting and real or transitional crowding is evident, and in that case it must include prediction of the size of unerupted permanent teeth.

### Principles of Space Analysis

Space analysis requires a comparison between the amount of *space available* for the alignment of the teeth and the amount of *space required* to align them properly in the dental arches (Fig. 11.48). The analysis can be done either manually on plaster dental casts or with a computer system by using virtual digital casts.

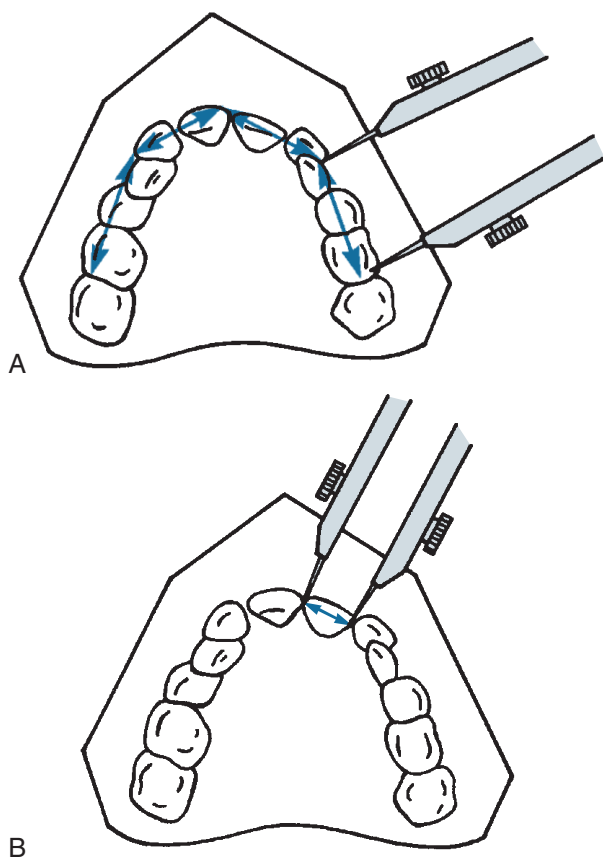
Whether the space analysis is done manually or virtually, the first step is calculation of space available. This is accomplished by measuring arch perimeter from the mesial of one first molar to



• **Fig. 11.48** A comparison of space available versus space required establishes whether a deficiency of space within the arch will ultimately lead to crowding, whether the correct amount of room is available to accommodate the teeth, or whether excess space will result in gaps between the teeth.

the other, over the contact points of posterior teeth and the incisal edge of the anteriors. There are two basic ways to accomplish this manually: (1) by dividing the dental arch into segments that can be measured as straight-line approximations of the arch (Fig. 11.49A) or (2) by contouring a piece of wire (or a curved line on the computer screen) to the line of occlusion and then straightening it out for measurement. The first method is preferred for manual calculation because of its greater reliability. Either method can be used with an appropriate computer program.

The second step is to calculate the amount of space required for alignment of the teeth. This is done by measuring the mesiodistal width of each erupted tooth from contact point to contact point, estimating the size of unerupted permanent teeth, and then summing the widths of the individual teeth (see Fig. 11.49B). If the sum of the widths of the permanent teeth is greater than the amount of space available, there is a space deficiency and crowding would occur. If available space is larger than the space required (excess space), gaps between some teeth would be expected.



• **Fig. 11.49** (A) Space available can be measured most easily by dividing the dental arch into four straight segments as shown. Each segment is measured individually with a divider or sharpened Boley gauge. (B) Space required is the measured sum of the mesiodistal widths of all individual erupted permanent teeth plus the estimated sizes of the unerupted permanent teeth.

Space analysis carried out in this way is based on three important assumptions: (1) The anteroposterior position of the incisors is correct (i.e., the incisors are neither excessively protrusive nor retrusive), (2) the space available will not change because of growth and dental compensatory tipping, and (3) all the teeth are present and reasonably normal in size. None of these assumptions can be taken for granted. All of them must be kept in mind when space analysis is done.

With regard to the first assumption, it must be remembered that incisor protrusion is relatively common and that retrusion, though uncommon, does occur. There is an interaction between crowding of the teeth and protrusion or retrusion: if the incisors are positioned lingually (retruded), this accentuates any crowding; but if the incisors protrude, the potential crowding will not be fully expressed. Crowding and protrusion are really different aspects of the same phenomenon. If there is not enough room to properly align the teeth, the result can be crowding, protrusion, or (most likely) some combination of the two. For this reason, information about how much the incisors protrude must be available from clinical examination to evaluate the results of space analysis. This information comes from facial form analysis (or from cephalometric analysis, if available).

The second assumption, that space available will not change during growth, is valid for most but not all children. In a child with a well-proportioned face, there is little or no tendency for

#### • BOX 11.1 Tanaka and Johnston Prediction Values

One half of the mesiodistal width of the four lower incisors

+10.5 mm = estimated width of mandibular canine and premolars in one quadrant  
+11.0 mm = estimated width of maxillary canine and premolars in one quadrant

the dentition to be displaced relative to the jaw during growth, but the teeth often shift anteriorly or posteriorly in a child with a jaw discrepancy. For this reason, space analysis is less accurate and less useful for children with skeletal problems (Class II, Class III, long face, short face) than in those with good facial proportions.

Even in children with well-proportioned faces, the position of the permanent molars changes when primary molars are replaced by the premolars (see Chapter 3 for a detailed review). If space analysis is done in the mixed dentition and depending on the molar relationships, it may be necessary to adjust the space available measurement to reflect the shift in molar position that can be anticipated.


The third assumption can (and must) be checked by clinical and radiographic examination, looking at the teeth as a set rather than as individual units. Anomalies in tooth size have significant implications for space in the dental arches (see Fig. 5.22).

### Estimating the Size of Unerupted Permanent Teeth

There are two basic approaches to doing this:

1. *Measurement of the teeth on radiographs.* This requires an undistorted radiographic image, which is achieved with individual periapical radiographs. Even with individual radiographs, it is often difficult to obtain an undistorted view of the canines, and this inevitably reduces the accuracy. With any type of radiograph, it is necessary to compensate for enlargement of the radiographic image. This can be done by measuring an object that can be seen both in the radiograph and on the casts, usually a primary molar tooth. A simple proportional relationship can then be set up. Accuracy is fair to good, depending on the quality of the radiographs and their position in the arch. The technique can be used in maxillary and mandibular arches for all ethnic groups, but the radiation burden is justified only in unusual cases.
2. *Estimation from proportionality tables.* There is a reasonably good correlation between the size of the erupted permanent incisors and the unerupted canines and premolars. By using the mesiodistal width of the *lower* incisors, the size of *both* the lower and upper unerupted canines and premolars can be predicted. The size of the lower incisors correlates better with the size of the upper canines and premolars than does the size of the upper incisors because upper lateral incisors are extremely variable teeth. No radiographs are required, and it can be used for the upper or lower arch.

Tanaka and Johnston developed a simple variation of the proportionality method, using a single equation and the width of the lower incisors to predict the size of unerupted canines and premolars (Box 11.1).<sup>28</sup> For children from a European population group, the method has good accuracy despite a small bias toward overestimating the unerupted tooth sizes. It requires neither radiographs nor reference tables (once the equation is memorized), which makes it very convenient, but two specific problems now are recognized: It tends to overestimate the required space for

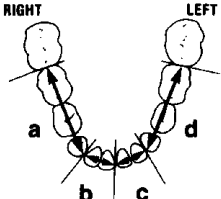


UNIVERSITY OF NORTH CAROLINA AT CHAPEL HILL  
SCHOOL OF DENTISTRY  
**SPACE ANALYSIS FORM**

Patient's Name: \_\_\_\_\_ Date: \_\_\_\_\_

---

**SECTION 1**  
**AVAILABLE MANDIBULAR SPACE**



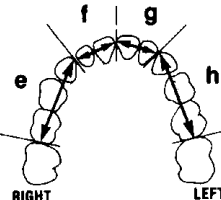
Arch Segment Lengths

a: \_\_\_\_\_ mm  
b: \_\_\_\_\_ mm  
c: \_\_\_\_\_ mm  
d: \_\_\_\_\_ mm  
TOTAL: \_\_\_\_\_ mm

**SECTION 2**  
**MANDIBULAR INCISOR WIDTH**

#23: \_\_\_\_\_ mm  
#24: \_\_\_\_\_ mm  
#25: \_\_\_\_\_ mm  
#26: \_\_\_\_\_ mm  
TOTAL: \_\_\_\_\_ mm

**SECTION 3**  
**AVAILABLE MAXILLARY SPACE**



Arch Segment Lengths

e: \_\_\_\_\_ mm  
f: \_\_\_\_\_ mm  
g: \_\_\_\_\_ mm  
h: \_\_\_\_\_ mm  
TOTAL: \_\_\_\_\_ mm

**SECTION 4**  
**MAXILLARY INCISOR WIDTH**

#7: \_\_\_\_\_ mm  
#8: \_\_\_\_\_ mm  
#9: \_\_\_\_\_ mm  
#10: \_\_\_\_\_ mm  
TOTAL: \_\_\_\_\_ mm

**SECTION 5**  
**MANDIBULAR SPACE ANALYSIS**

a. TOTAL SPACE AVAILABLE (from Section 1) \_\_\_\_\_  
b. SUM OF MAND. INCISOR WIDTHS (from Section 2) \_\_\_\_\_  
c. SUM OF LEFT CANINE & PREMOLARS (estimated below from mand. incisors) \_\_\_\_\_  
d. SUM OF RIGHT CANINE & PREMOLARS (estimated below from mand. incisors) \_\_\_\_\_  
e. TOTAL SPACE REQUIRED (b + c + d) \_\_\_\_\_  
f. DISCREPANCY (a - e) \_\_\_\_\_

**SECTION 6**  
**MAXILLARY SPACE ANALYSIS**

a. TOTAL SPACE AVAILABLE (from Section 3) \_\_\_\_\_  
b. SUM OF MAX. INCISOR WIDTHS (from Section 4) \_\_\_\_\_  
c. SUM OF RIGHT CANINE & PREMOLARS (estimated below from mand. incisors) \_\_\_\_\_  
d. SUM OF LEFT CANINE & PREMOLARS (estimated below from mand. incisors) \_\_\_\_\_  
e. TOTAL SPACE REQUIRED (b + c + d) \_\_\_\_\_  
f. DISCREPANCY (a - e) \_\_\_\_\_

**SECTION 7**  
**SKELETAL JAW RELATIONSHIP**  
(from Facial Profile Analysis)  
( ) CLASS I; ( ) CLASS II; ( ) CLASS III

**SECTION 8**  
**OCCCLUSION OF PERMANENT FIRST MOLARS**

RIGHT SIDE ( ) ANGLE CLASS I ( ) LEFT SIDE  
( ) END-TO-END  
( ) ANGLE CLASS II  
( ) ANGLE CLASS III

**SECTION 9**  
**MOLAR SHIFT** (From end-to-end to Class I)  
For Skeletal Class I only  
RIGHT SIDE + LEFT SIDE = TOTAL SHIFT  
\_\_\_\_\_ mm + \_\_\_\_\_ mm = \_\_\_\_\_ mm TOTAL

**SECTION 10**  
**LIP POSTURE** (from Facial Profile Analysis)  
( ) ACCEPTABLE; ( ) PROTRUSIVE; ( ) RETRUSIVE  
**MANDIBULAR INCISOR POSITION**  
(from Facial Profile Analysis and casts)  
( ) ACCEPTABLE; ( ) PROTRUSIVE; ( ) RETRUSIVE

**INTERPRETATION OF NUMERICAL RESULTS** (based on observations in Sections 7 - 10)

To estimate the size of the unerupted canine and premolars in each quadrant [method of Tanaka and Johnston, *J Am Dent Assn* 88:798, 1974]:

**Mandibular quadrant:**  $\frac{1}{2}$  the sum of the widths of the mandibular incisors, plus 10.5 mm.

**Maxillary quadrant:**  $\frac{1}{2}$  the sum of the widths of the mandibular incisors, plus 11.0 mm.

[ENTER ON LINE 5c and 5d ABOVE]

[ENTER ON LINE 6c and 6d ABOVE]

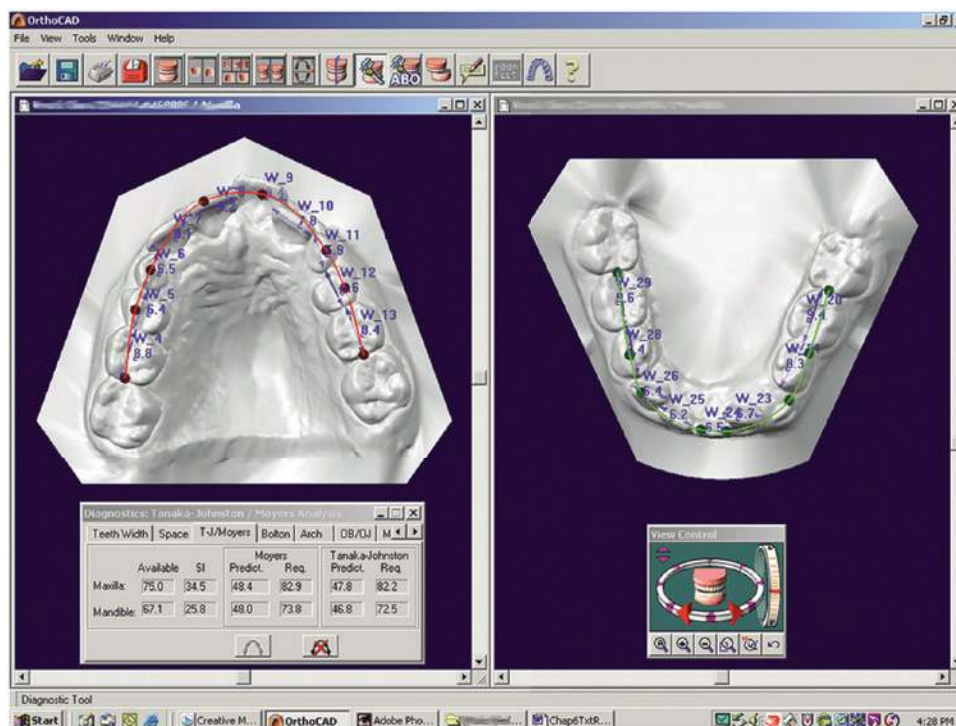
• Fig. 11.50 Space analysis form.

Caucasian females in both arches and underestimate the space required in the lower arch for African-American males.

Most computer algorithms for space analysis are based on correlations of tooth sizes and should be used with caution if the radiographs show anything unusual (unless the computer program allows for introduction of radiographic information).

Which of these methods is best for an individual patient depends on the circumstances. The prediction tables work surprisingly well when applied to the population group from which they were developed: white schoolchildren of northern European descent. On balance, the Tanaka-Johnston method probably is most practical for manual calculation because no radiographs are required and





• **Fig. 11.51** Space analysis can be accomplished by a computer algorithm. The data for the arch dimensions and tooth widths can be entered by digitizing the already present digital casts. Then the computer does the calculations.

the simple ratio can be printed right on the space analysis form or memorized, so no reference tables must be consulted.

A contemporary form for mixed dentition space analysis is shown in Fig. 11.50. Note that (1) a correction for mesial movement of the lower molars following the exchange of the dentition is included, (2) the Tanaka-Johnston method for predicting the size of unerupted canines and premolars is used, and (3) the result from facial form analysis is requested to check for appropriateness of the analysis and for interpretation of the results. A screen capture from a commercial computer analysis is shown in Fig. 11.51. Computer analysis is faster and easier, but it is important to remember that its accuracy will depend on the accuracy of the digitized input and how well the patient meets the assumptions that underlie a correlation approach.

## Treatment of Space Problems

In the section of the chapter that follows, you will recognize that the problems become increasingly more complex but are still within reach of many general practitioners. Other space problems, more complex still, usually would be addressed in a specialty practice and are discussed in Chapter 12.

### Premature Tooth Loss With Adequate Space: Space Maintenance

Early loss of a primary tooth presents a potential alignment problem because drift of permanent or other primary teeth is likely unless it is prevented. Space maintenance is appropriate only when adequate space is available, and when all unerupted teeth are present and at the normal stage of development. If a permanent successor will erupt within 6 months (i.e., if more than one-half to two-thirds of its root has formed), a space maintainer is unnecessary. If there

is not enough space for the permanent tooth or if it is missing, space maintenance alone is inadequate or inappropriate, and the other treatment approaches discussed here will be needed.

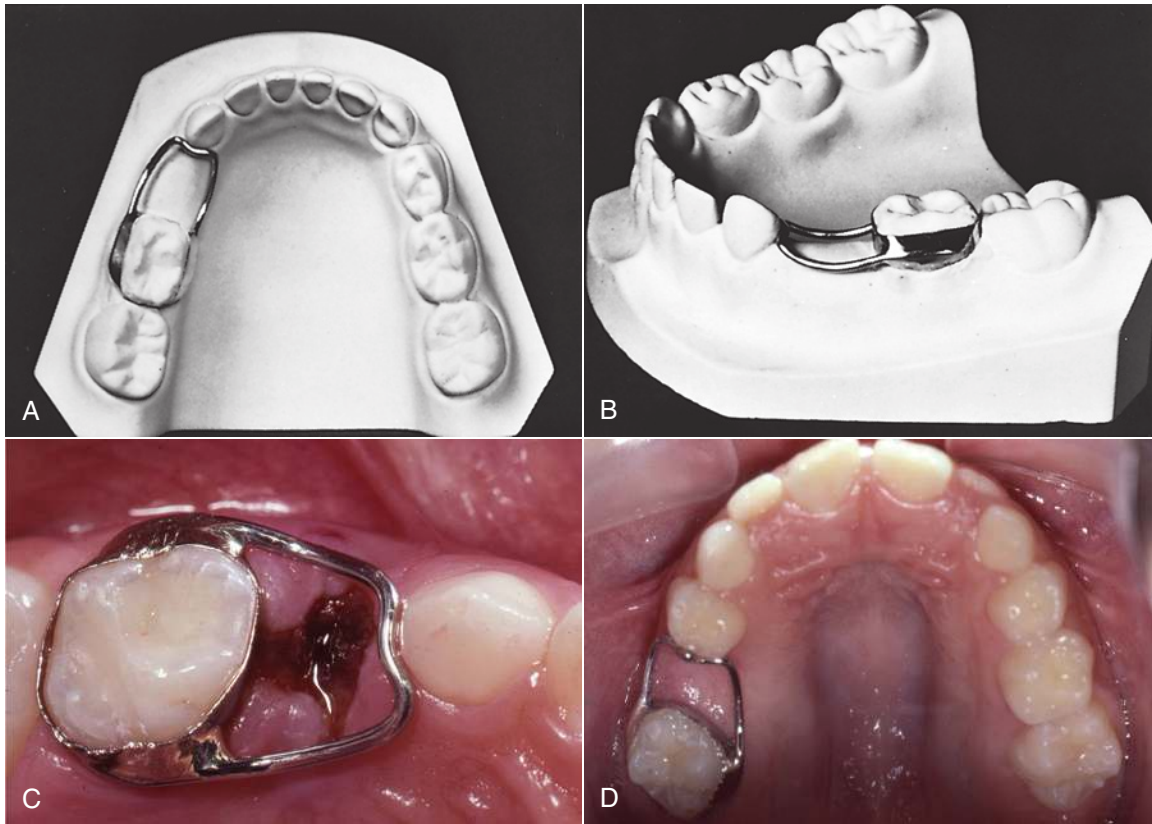
Several treatment techniques can be used successfully for space maintenance, depending on the specific situation. Because these appliances are at risk for breakage and loss, they must be monitored carefully, probably at 3- to 6-month intervals, to be successful.

### Band-and-Loop Space Maintainers

The band and loop is a unilateral fixed appliance indicated for space maintenance in the posterior segments. The simple cantilever design makes it ideal for isolated unilateral space maintenance (Fig. 11.52). Because the loop has limited strength, this appliance must be restricted to holding the space of one tooth and is not expected to accept functional forces of chewing. Although bonding a rigid or flexible wire across the edentulous space has been advocated as an alternative, this has not proved satisfactory clinically. It also is no longer considered advisable to solder the loop portion to a stainless steel crown because this precludes simple appliance removal and replacement. Teeth with stainless steel crowns should be banded like natural teeth.

If a primary second molar has been lost, the band can be placed on either the primary first molar or the erupted permanent first molar. Some clinicians prefer to band the primary tooth in this situation because of the risk of decalcification around any band, but primary first molars are challenging to band because of their morphologic features, which converge occlusally and make band retention difficult. A more important consideration is the eruption sequence of the succedaneous teeth. The primary first molar should not be banded if the first premolar is developing more rapidly than the second premolar because loss of the banded abutment tooth would require replacement of the appliance.

Before eruption of the permanent incisors, if a single primary molar has been lost bilaterally, a pair of band-and-loop space



• **Fig. 11.52** A band-and-loop space maintainer is typically used in the mixed dentition to save the space of a single prematurely lost primary molar. It consists of a band on either a primary or permanent molar and a wire loop to maintain space. (A) The loop portion made from 36-mil wire is carefully contoured to the abutment tooth without restricting lateral movement of the primary canine, and (B) the loop is also contoured to within 1.5 mm of the alveolar ridge. The solder joints should fill the angle between the band and wire to avoid food and debris accumulation. (C) A completed band and loop maintainer in place after extraction of a primary first molar; (D) an occlusal rest, shown here on the primary first molar, can be added to the loop portion to prevent the banded teeth from tipping mesially.

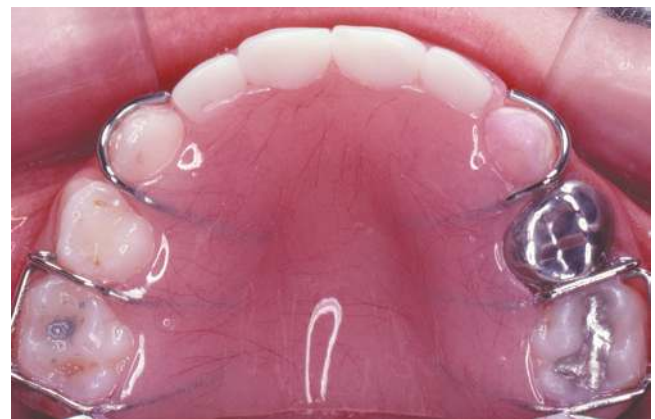maintainers is recommended instead of the lingual arch that would be used if the patient were older. This is advisable because the permanent incisor tooth buds are lingual to the primary incisors and often erupt lingually. The bilateral band and loops enable the permanent incisors to erupt without interference from a lingual wire. At a later time, the two band-and-loop appliances can be replaced with a single lingual arch if necessary.

The survival of band and loops is not impressive. It has been judged to be approximately 18 months, with cement failure cited as the most frequent problem.<sup>29</sup> This speaks to the need to evaluate these space maintainers at routine recall visits or more frequently.

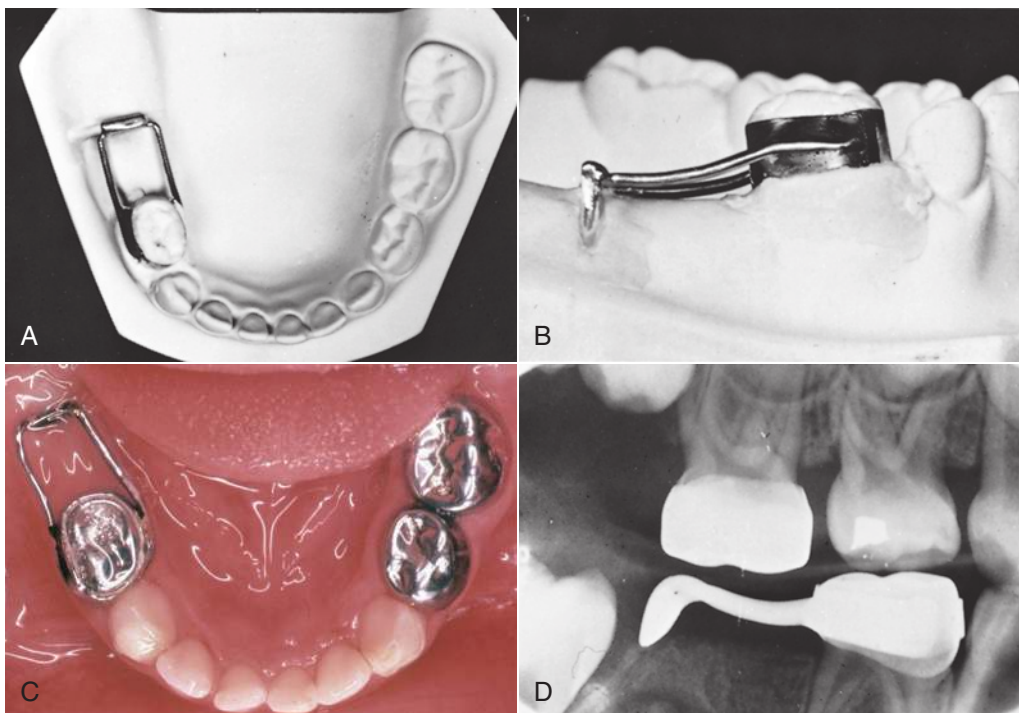
### Partial Denture Space Maintainers

A partial denture is most useful for bilateral posterior space maintenance when more than one tooth has been lost per segment and the permanent incisors have not yet erupted. In these cases, because of the length of the edentulous space, band-and-loop space maintainers are contraindicated, and the likely lingual position of the permanent incisors at initial eruption makes the lingual arch a poor choice. The partial denture also has the advantage of replacing some occlusal function.

Another indication for this appliance is posterior space maintenance in conjunction with replacement of a missing primary incisor or delayed permanent incisor eruption (Fig. 11.53). Anterior



• **Fig. 11.53** In a young child, a removable partial denture is used to replace anterior teeth for esthetics. At the same time, it can maintain the space of one or more prematurely lost primary molars. For this patient, the four incisors are replaced by the partial denture. Multiple clasps, preferably Adams clasps, are necessary for good retention. Both the clasps and the acrylic need frequent adjustment to prevent interference with physiologic adjustment of primary teeth during eruption of permanent teeth. The C-clasps on the primary canines provide limited retention and are good examples of clasps that need continued careful attention.



• **Fig. 11.54** The distal shoe space maintainer is indicated when a primary second molar is lost before eruption of the permanent first molar and is usually placed at or very soon after the extraction of the primary molar. (A) The loop portion, made of 36-mil stainless steel wire, and the intraalveolar blade are soldered to a band so that the whole appliance can be removed and replaced with another space maintainer after the permanent molar erupts. (B) The loop portion must be contoured closely to the ridge because the appliance cannot resist excessive occlusal forces from the opposing teeth. (C) This distal shoe space maintainer was placed at the time of extraction of the primary second molar. (D) The blade portion must be positioned so that it extends approximately 1 mm below the mesial marginal ridge of the erupting permanent tooth to guide its eruption. This position can be measured from pretreatment radiographs and verified by a radiograph taken at try-in or after cementation. An additional occlusal radiograph can be obtained if the faciolingual position is in doubt.

space maintenance is unnecessary because arch circumference generally is not lost even if the teeth drift and redistribute the space. Primary anterior teeth are not required for nutrition or speech development, and children adapt readily to missing teeth in most cases, so replacement of missing anterior teeth is done solely to improve appearance. This may have social advantages, however, even for young children.

### Distal Shoe Space Maintainers

The distal shoe has a unique application and is the appliance of choice when a primary second molar is lost before eruption of the permanent first molar. This appliance consists of a metal or plastic guide plane along which the permanent molar erupts. The guide plane is attached to a fixed or removable retaining device (Fig. 11.54). When fixed, the distal shoe is usually retained with a band instead of a stainless steel crown so that it can be replaced by another type of space maintainer after the permanent first molar erupts. Unfortunately, this design limits the strength of the appliance and provides no functional replacement for the missing tooth. If primary first and second molars are missing, the appliance must be removable and the guide plane is incorporated into a partial denture because of the length of the edentulous span. This type of appliance can provide some occlusal function.

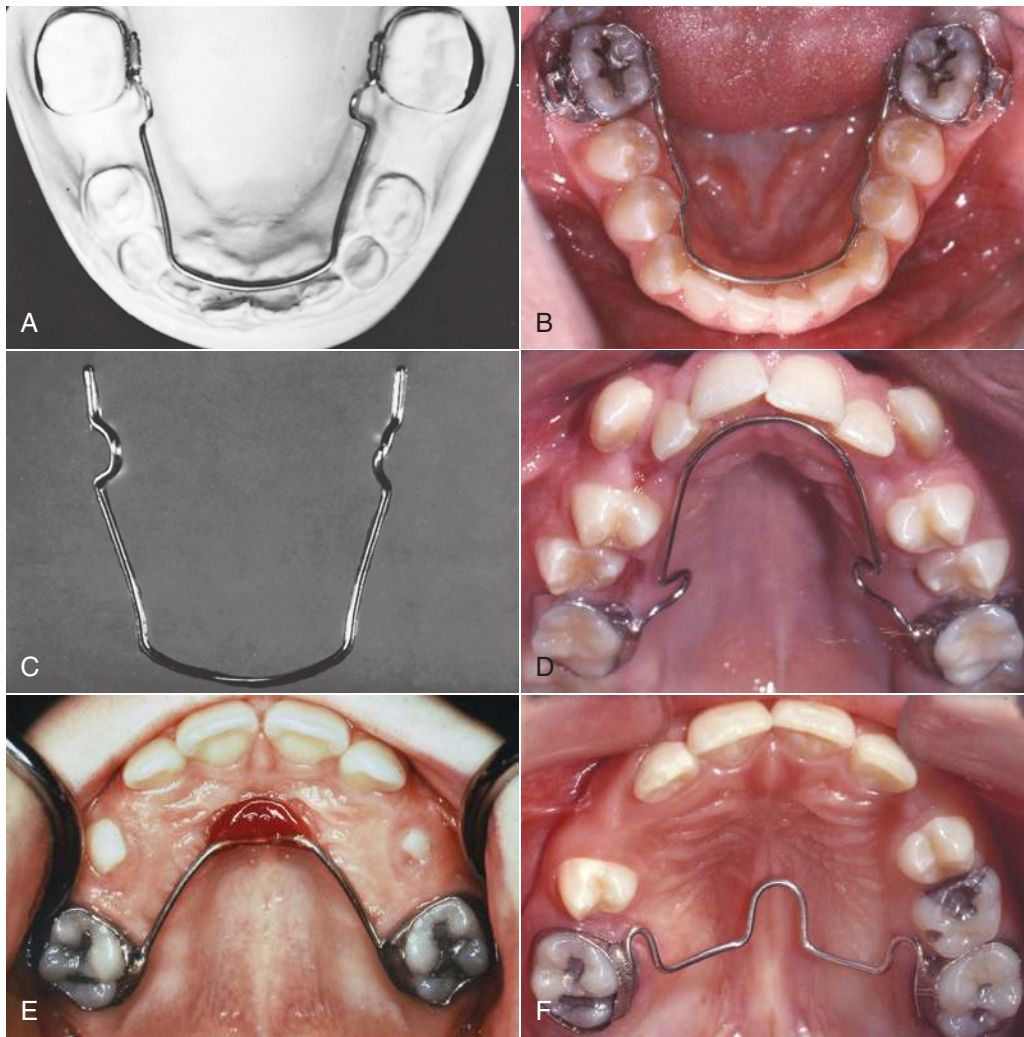
To be effective, the guide plane must extend into the alveolar process so that it is located approximately 1 mm below the mesial marginal ridge of the permanent first molar, at or before its emergence from the bone. An appliance of this type is tolerated well by most children but is contraindicated in patients who are at risk for subacute bacterial endocarditis or are immunocompromised because complete epithelialization around the intraalveolar portion has not been demonstrated.<sup>30</sup> Careful measurement and positioning are necessary to ensure that the blade will ultimately guide the permanent molar. Faulty positioning and loss of the appliance are the most common problems with this appliance.

### Lingual Arch Space Maintainers

A lingual arch is indicated for space maintenance when multiple primary posterior teeth are missing and the permanent incisors have erupted (Fig. 11.55A–B). A conventional lingual arch, attached to bands on the primary second or permanent first molars and contacting the maxillary or mandibular incisors, prevents anterior movement of the posterior teeth and posterior movement of the anterior teeth.

A lingual arch space maintainer is usually soldered to the molar bands but can be fabricated to be removable by the doctor. Removable lingual arches (e.g., those that fit into attachments welded onto the bands) are more prone to breakage and loss.





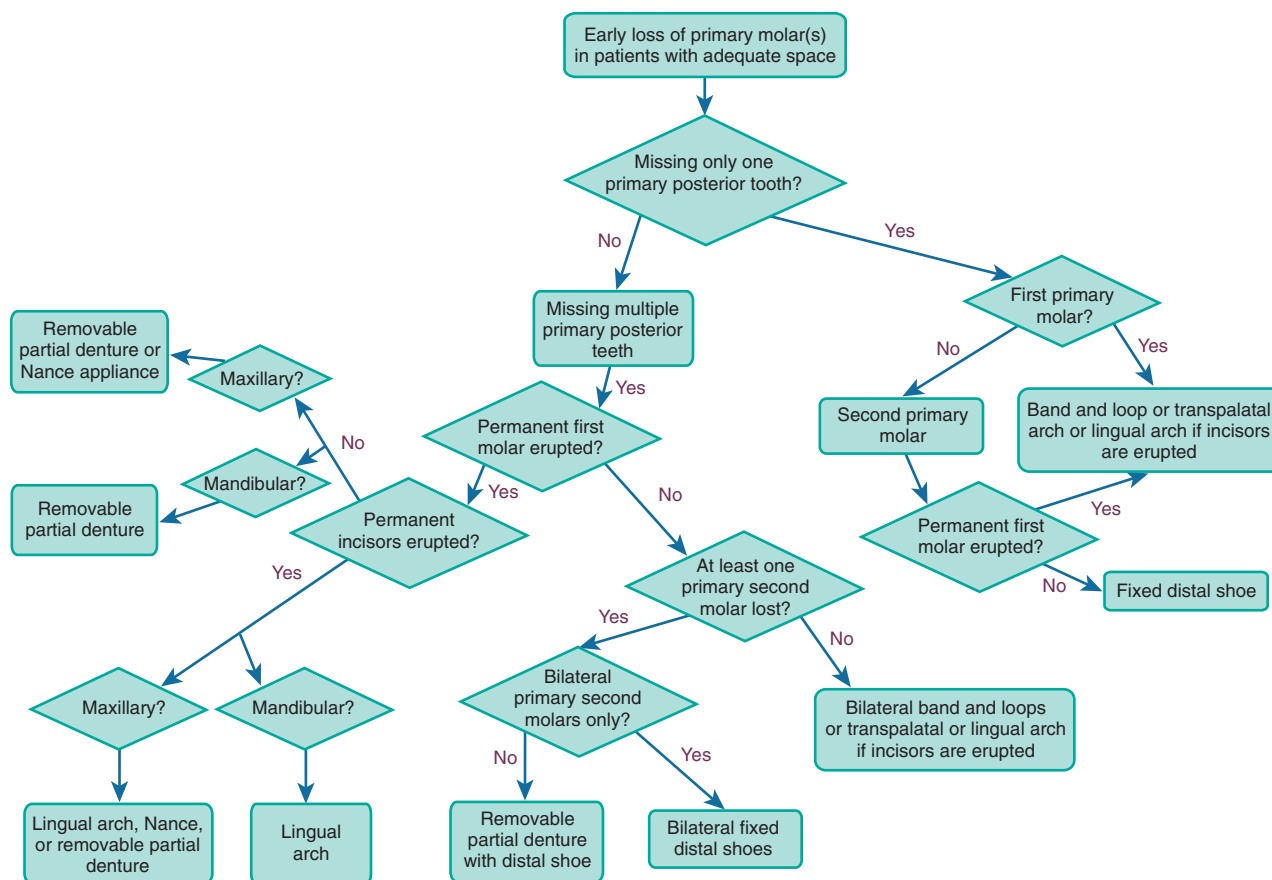
• **Fig. 11.55** A lingual holding arch usually is the best choice to maintain space for premolars after premature loss of the primary molars when the permanent incisors have erupted. (A) The lingual arch is made of 36-mil wire with adjustment loops mesial to the permanent first molars. (B) This soldered lingual arch successfully maintained the space for the premolars. (C) The lingual arch is stepped away from the premolars starting in the canine area to allow their eruption without interference, which results in a keyhole design. The wire is also 1.5 mm away from the soft tissue at all points. (D) A maxillary lingual arch is used when the overbite is not excessive, or (E) a Nance arch with an acrylic button in the palatal vault is indicated if the overbite is excessive. The palatal button must be monitored because it may cause soft tissue irritation. (F) The transpalatal arch prevents a molar from rotating mesially into a primary molar extraction space, and this largely prevents its mesial migration. Several adjacent teeth should be present on at least one side of the arch when a transpalatal design is employed as a sole space maintainer to resist drift of the teeth.

Regardless of whether it is removable, the lingual arch should be positioned to rest on the cingula of the incisors, approximately 1 to 1.5 mm off the soft tissue, and should be stepped to the lingual in the canine region to remain away from the primary molars and unerupted premolars so that there is no interference with their eruption (Fig. 11.55C). Lingual arches should have ideal arch form so the teeth can align if they have space. Making the arch conform to dental irregularities is not appropriate. Approximately 25% to 30% of lingual arch type appliances fail, usually because of cement loss and solder joint breakage. Their survival time is estimated at less than 24 months.<sup>31</sup> Careful instructions to

parents and patients can reduce these problems, but regular recall is advisable.

Maxillary lingual arches as space maintainers are not familiar to many clinicians, but are contraindicated only in patients whose bite depth causes the lower incisors to contact the archwire on the lingual aspect of the maxillary incisors (Fig. 11.55D). When bite depth does not allow use of a conventional design, either the Nance lingual arch (Fig. 11.55E) or a transpalatal arch (Fig. 11.55F) can be used. The Nance arch is an effective space maintainer, but soft tissue irritation can be a problem. The best indication for a transpalatal arch is when one side of the arch is intact and more

## Posterior Space Maintenance—Pathways of Care



• **Fig. 11.56** This flowchart can be used to aid decision making regarding possible options for space maintenance in the primary and mixed dentitions.

than one primary tooth is missing on the other side. In this situation, the rigid attachment to the intact side usually provides adequate stability for space maintenance. When primary molars have been lost bilaterally, however, both permanent molars can tip mesially despite the transpalatal arch, and a conventional lingual arch or Nance arch is preferred.

A flowchart is provided to help guide decision making for space maintenance (Fig. 11.56).

### Localized Space Loss (3 mm or Less): Space Regaining

Potential space problems can be created by drift of permanent incisors or molars after early extraction of primary canines or molars, which usually begins during the first 6 months after extraction. Then, repositioning the teeth to regain space and reduce the space discrepancy to zero, followed by a space maintainer, is necessary to prevent further drift and space loss until the succedaneous teeth have erupted. A space maintainer alone is not adequate treatment for a space deficiency.

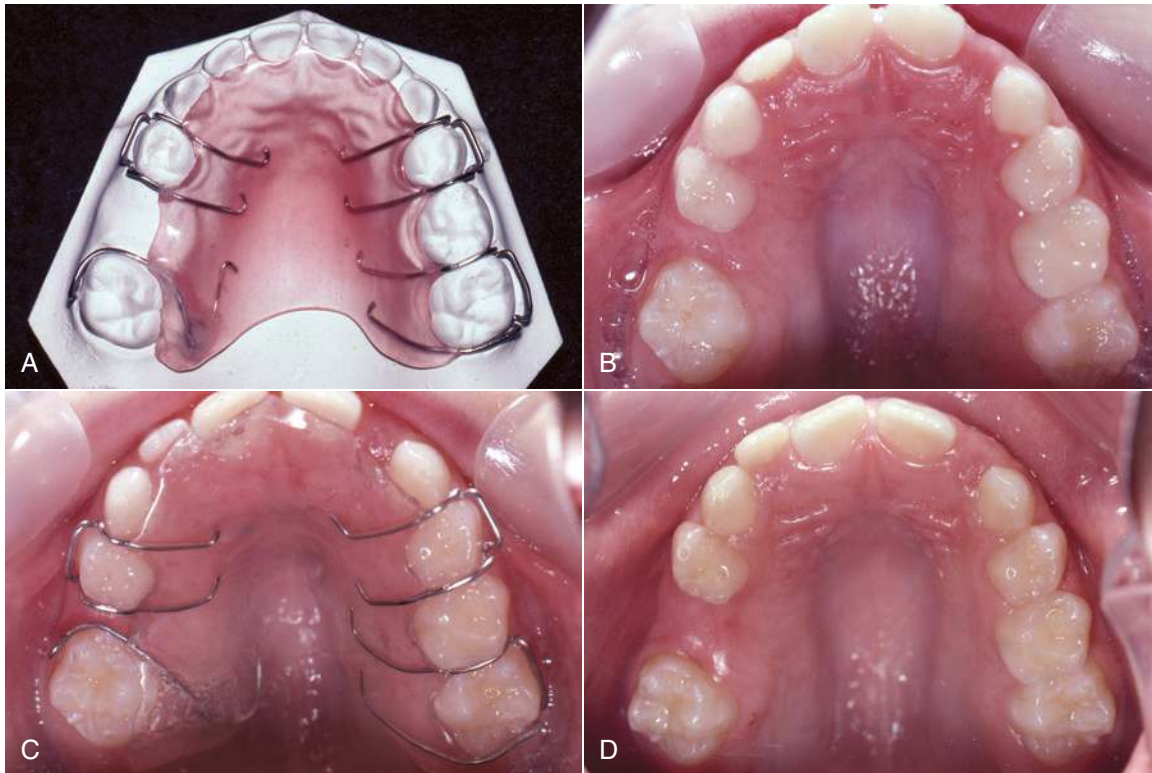
Up to 3 mm of space can be reestablished in a localized area with relatively simple appliances and a good prognosis. Space loss

greater than that constitutes a severe problem and usually requires comprehensive treatment to achieve acceptable results. The methods to regain major space loss are considered in Chapter 12. The treatment necessary to regain the space during the mixed dentition, especially if a second stage of treatment will be required in any event, may be more than is reasonable when one analyzes the cost-benefit ratio. Extraction with space closure often is a better choice. In that circumstance, often the crowding can be accepted during the mixed dentition so that the ultimate space closure occurs under control when complete fixed appliances are present.

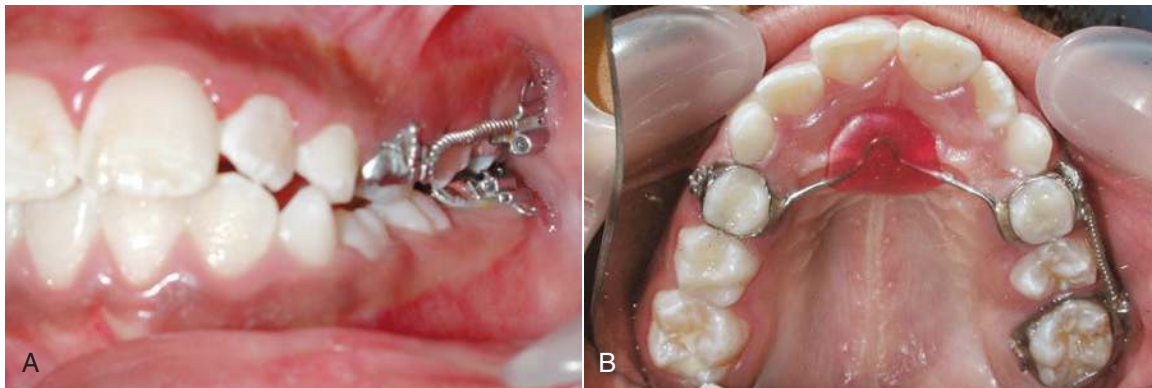
### Maxillary Space Regaining

In general, space is easier to regain in the maxillary than in the mandibular arch because of the increased anchorage for removable appliances afforded by the palatal vault and the possibility for use of extraoral force (headgear). Permanent maxillary first molars can be tipped distally to regain space with either a fixed or removable appliance, but bodily movement requires a fixed appliance. Because the molars tend to tip forward and rotate mesiolingually, distal tipping and de-rotation often are satisfactory to regain 2 to 3 mm.

A removable appliance retained with Adams clasps and incorporating a helical fingerspring adjacent to the tooth to be moved



• **Fig. 11.57** A removable appliance with a fingerspring can be used to regain space by tipping a permanent first molar distally. (A) The appliance incorporates multiple Adams clasps and a 28-mil helical spring that is activated 2 to 3 mm per month. (B) Premature loss of the primary second molar has led to mesial drift and rotation of the permanent first molar. (C) This removable appliance can be used to regain up to 3 mm of space. (D) After space regaining, the space should be maintained with a band and loop or lingual arch if the permanent incisors have erupted.



• **Fig. 11.58** (A) A fixed appliance also can be used to regain space in the maxillary posterior regions, with a coil spring generating the distalizing force. (B) Palatal anchorage was gained using a Nance arch and the erupted teeth.

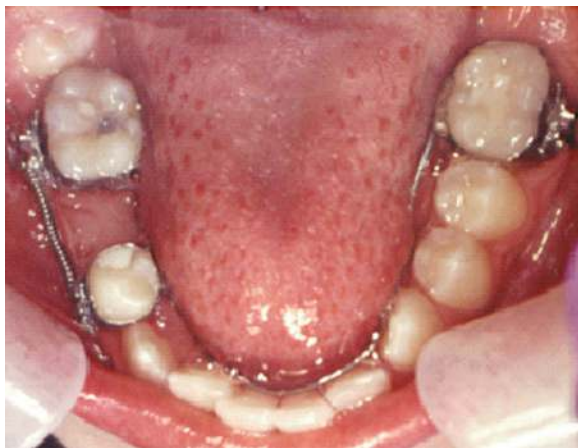is very effective. This appliance is the ideal design for distally tipping one molar (Fig. 11.57). One posterior tooth can be moved up to 3 mm distally during 3 to 4 months of full-time appliance wear. The spring is activated approximately 2 mm to produce 1 mm of movement per month. The molar typically will de-rotate spontaneously as it is tipped distally.

For unilateral space regaining with bodily movement of the permanent first molar, a fixed appliance is preferred. The anchorage

provided by the remaining teeth can support the forces generated by a coil spring on a segmental archwire, with good success (Fig. 11.58), but to be effective, the support of a modified Nance arch usually is needed.

Regardless of the method used to regain space, a space maintainer is required when adequate space has been restored. A fixed space maintainer is recommended, rather than trying to maintain the space with the removable appliance that was used for space





• **Fig. 11.59** Moving molars distally in the mandibular arch, especially unilaterally, is quite challenging and requires support from a number of teeth. Use of a lingual arch, to incorporate anchorage from the permanent and primary molars as well as the incisors, and force from a coil spring on a segmental archwire can be effective.

regaining, because it may become distorted and allow inadvertent space loss.

Regaining bilateral localized space loss of any amount is more complex and is discussed in [Chapter 12](#).

### Mandibular Space Regaining

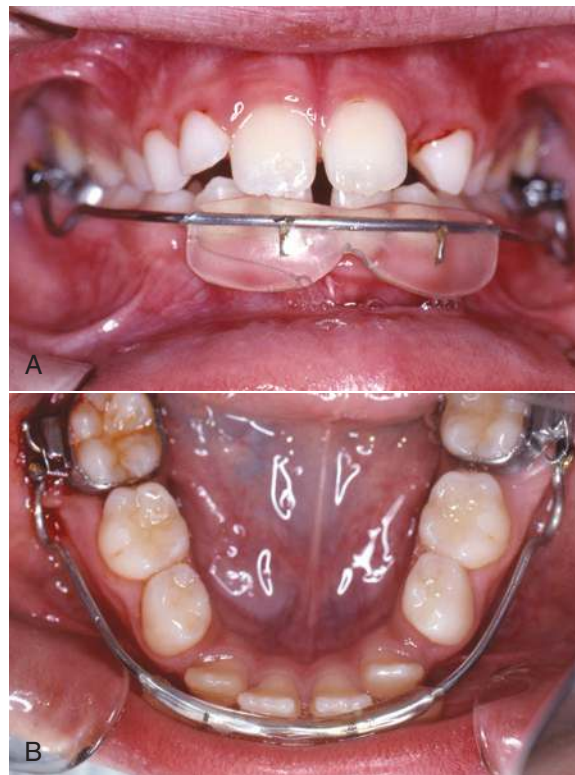For moderate amounts of space regaining, removable appliances can be used in the mandibular arch just as they are in the maxillary arch, but as a rule they are less satisfactory because they are more fragile and prone to breakage. They do not fit as well and lack the palatal anchorage support. Problems with tissue irritation frequently are encountered, and patient acceptance tends to be poorer than with maxillary removable appliances.

For unilateral mandibular space regaining, the best choice is a fixed appliance. A lingual arch can be used to support the tooth movement and provide anchorage when used in conjunction with a segmental archwire and coil spring ([Fig. 11.59](#)).

If space has been lost bilaterally because of lingual incisor tipping, there are two choices short of bands and brackets: a lip bumper or an adjustable lingual arch. With the lip bumper, which is a labial appliance fitted to tubes on the molar teeth ([Fig. 11.60](#)), the idea is that the appliance presses against the lip, which creates a distal force to tip the molars posteriorly without affecting the incisors. Although some posterior movement of the molars can be observed when a lip bumper is used, the appliance also alters the equilibrium of forces against the incisors, removing any restraint from the lip on these teeth. The result is forward movement of the incisors.<sup>32</sup> Depending on the type of lip bumper used and its clinical manipulation, transverse widening also may occur.

When an active lingual arch pits posterior movement of both molars against the anchorage offered by the incisors, significant forward displacement of the incisors must be expected ([Fig. 11.61](#)). The expansion can be accomplished by slightly opening the loops located mesial to the banded molars. Small steps in activation are necessary because the wire is large and capable of delivering heavy forces. The appliance can then serve as a passive retainer or be replaced with a soldered lingual arch.

On balance, the effects of an active lingual arch and a lip bumper are similar. A lingual arch can be left in place as a space maintainer after space has been regained. A lip bumper is not a



• **Fig. 11.60** (A) A lip bumper constructed of a 36-mil wire bow with an acrylic pad, which fits into tubes on the permanent first molars, is sometimes used to increase arch length. This occurs when the appliance stretches the lower lip and transmits force to move the molars back. The appliance also disrupts the equilibrium between the lip and tongue and allows the anterior teeth to move facially. The result is nearly equal molar and incisor change. This appliance can be used for either minor space regaining or for moderate arch expansion. (B) The lip bumper is ligated in place so that it remains in the proper position during treatment and to increase compliance. Periodically, it needs to be advanced a couple of millimeters facial to the incisors so they can migrate facially.

good space maintainer and should be replaced with a lingual arch when long-term maintenance of the regained space is needed.

Bilateral molar distalization to regain space or moving the mandibular midline to resolve an asymmetry are both considered complex problems and are addressed in [Chapter 12](#).

## Mild-to-Moderate Crowding of Incisors With Adequate Space

### Irregular Incisors, Minimal Space Discrepancy

In some children, space analysis shows that enough space for all the permanent teeth ultimately will be available, but relatively large permanent incisors and the clinical reality of the “incisor liability” (see [Chapter 4](#)) cause transient crowding of the permanent incisors. This crowding is usually expressed as mild faciolingual displacement or rotation of individual anterior teeth.

Studies of children with normal occlusion indicate that when they go through the transition from the primary to the mixed dentition, up to 2 mm of incisor crowding may resolve spontaneously without treatment. From this perspective, there is no need for treatment when mild incisor crowding is observed during the mixed dentition. Not only is correction of this small amount of

crowding probably not warranted, but also there is no evidence that long-term stability will be greater. The only reason for treatment may be temporary esthetic improvement.

If exaggerated parental concern makes mild or moderate crowding a problem, one could consider disking the interproximal enamel

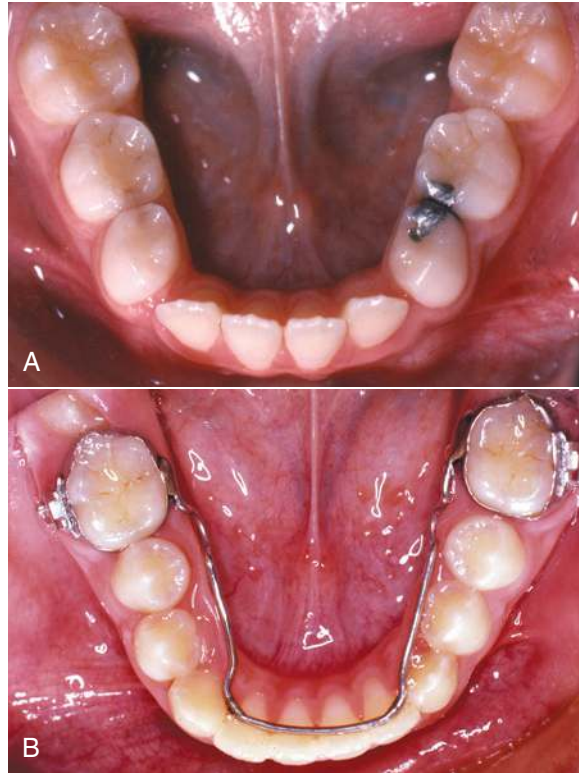surfaces of the remaining *primary* canines and first primary molars (Fig. 11.62) as the anterior teeth erupt. This can help with faciolingual discrepancies but not rotations. It is possible to gain as much as 3 to 4 mm of anterior space through this procedure, but the teeth may align in a more lingual position and actually make the space problem worse. Remember, at this point in the transitional dentition no disking or interproximal stripping should be attempted on *permanent* teeth. This could create a tooth-size discrepancy that later will be difficult to resolve. Permanent tooth stripping should not be undertaken until all the permanent teeth have erupted and their interarch size relationships can be evaluated.

Correction of incisor rotations caused by this transitional crowding requires space and controlled movement to align and de-rotate them, using an archwire and bonded attachments on the incisors. It is rare that a child who needs this type of treatment in the mixed dentition does not require further treatment after all permanent teeth have erupted, so extensive early treatment is usually not indicated.

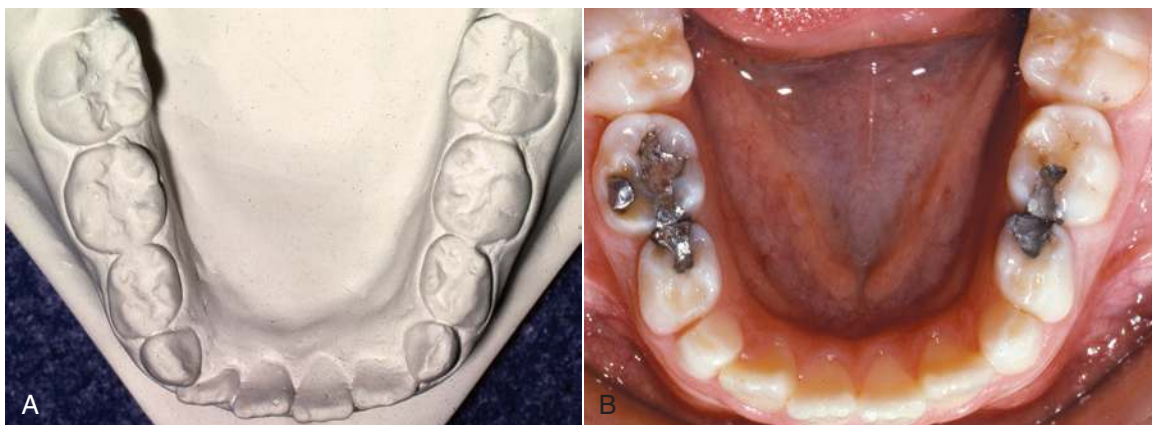### Space Deficiency Largely Due to Allowance for Molar Shift: Space Management

In some children, more severe transitional crowding occurs when the incisors erupt. Space analysis often shows that the space available is adequate or nearly so. A major component of the projected space deficiency is the allowance for mesial movement of the permanent first molars to a Class I relationship when the second primary molars are lost. For these patients, if the loss of leeway space could be prevented, there would be little or no space deficiency. Gianelly reported that in patients seeking treatment at Boston University, 75% would have approximately enough space to align the teeth if molar drift were prevented.<sup>33</sup> One can look at these children from either of two perspectives: (1) There is minimal benefit from early treatment unless there are major esthetic concerns, and therefore little or no reason to intervene, or alternatively (2) this group does not need much treatment, it should be relatively easy to provide, and there is always the possibility that if early treatment is done, later treatment might not be necessary.

Rather than beginning treatment in the early mixed dentition, the current recommendation for children with moderate crowding but little or no space discrepancy is to begin intervention with a

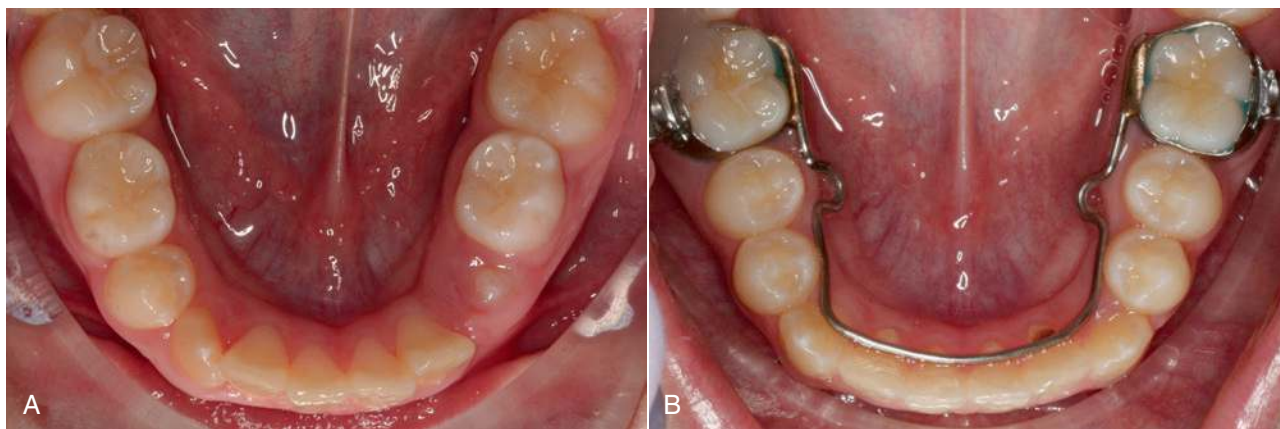


• **Fig. 11.61** (A) Limited space regaining or moderate lower arch expansion can be accomplished by using a lingual arch when the incisors have good alignment and little spacing, as in this patient who requires additional arch length to accommodate the unerupted premolars and canines. (B) When the lingual arch is in place and active, it will rest high on the lingual surface of the incisors and should exert a downward tipping force. Two or three 1- to 1.5-mm activations at 4- to 6-week intervals will achieve the desired movement.

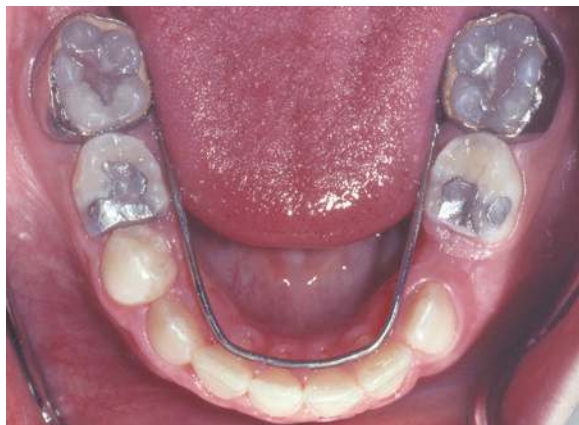

• **Fig. 11.62** Disking can be used on multiple surfaces of primary teeth—especially the primary canines—when limited transitional crowding is apparent. (A) This pretreatment cast shows minor anterior crowding. (B) Disking of the mesial and distal surfaces of the primary canines allowed spontaneous alignment to occur without appliance therapy.





• **Fig. 11.63** A lingual arch in conjunction with primary tooth extraction or exfoliation can be an effective way to take advantage of the leeway space and reduce crowding. (A) The primary second molars are in place, and there is some anterior crowding that is within the range of the leeway space. (B) With the lingual arch in place to take advantage of the leeway space, the second premolars erupted and incisor and canine alignment improved spontaneously.



• **Fig. 11.64** Disking primary posterior teeth in conjunction with space maintenance is an effective method to use the leeway space and all available arch length. Note that the diskings must be completed perpendicular to the occlusal plane so that the height of contour of the tooth is reduced. Occlusally convergent slices that do not reduce the mesiodistal width of the tooth are not helpful.

lingual arch in the late mixed dentition, just before the second primary molars exfoliate. The transitional incisor crowding would simply be tolerated up to that time, on the theory that it could be corrected along with other crowding in the arch when the space occupied by the large second primary molars became available. In these patients, beginning comprehensive treatment earlier is judged not to be cost-effective—it takes longer for both patient and doctor, without producing a better long-term result.

A primary indication does exist, however, for starting treatment earlier in some of these patients who have overall adequate space but various amounts of transitional crowding. Loss of both primary canines or delayed eruption due to crowding is an indication for earlier space management with a lingual arch. Placement of a lingual arch may prevent distal movement of the incisors that shortens arch length (Fig. 11.63).<sup>34</sup> The lingual arch should be left in position until the second premolars erupt, so the start of comprehensive treatment can be delayed. With this approach to

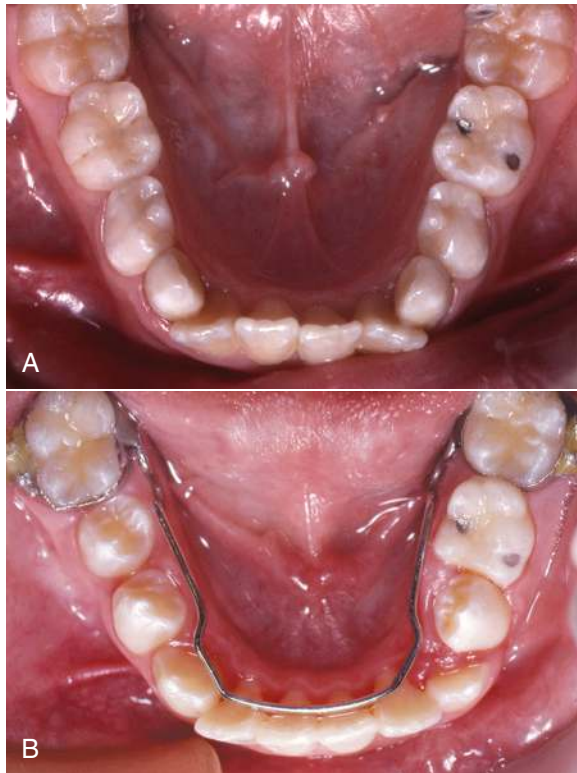
space management, there also is some evidence for better long term stability.<sup>35</sup>

In the absence of early loss of primary teeth, the major reason for early intervention in a child who has transitional crowding is esthetic concern because of the obvious crowding. If the parents insist on doing something sooner rather than later, a combination of early extraction of primary canines and diskings to reduce the width of primary molars can provide space to allow the permanent incisors and canines to erupt and align. This can be carried further posteriorly in the arch by diskings the second primary molar to allow the first premolars to erupt (Fig. 11.64). The minimum orthodontic appliance therapy is a lingual arch that will support the incisor teeth and control the molar position and arch perimeter by preventing any mesial shift. If necessary, the lingual arch can be activated slightly to tip molars distally and incisors facially to obtain a modest increase in arch length (see Fig. 11.61). A lip bumper also can be used in the lower arch to maintain the position of the molars or perhaps tip them slightly distally, while removing lip pressure and allowing the incisors to move facially.

When space is created in this way, the incisors often align spontaneously if the irregularity is from faciolingual tipping, but rotations are less likely to resolve. An exception is the child whose incisor segment is straight, without anterior arch curvature. In these children, extraction of primary canines usually leads to spacing of the incisors or maintenance of essentially the same arch form. Alignment does not improve even when the space is available and a lingual arch is in place to serve as a template for tooth position (Fig. 11.65). Correction of incisor rotations or residual irregularity in incisor position requires a fixed appliance, using an archwire and bonded attachments on the incisors. Accepting some incisor crowding and deferring treatment until as late as possible—when the premolars are erupting—usually is the best judgment.

Because the molars have not been allowed to shift forward into the leeway space when space management is employed, they often are maintained in the end-to-end relationship that is normal before the premolars erupt, instead of moving into a Class I relationship. For that reason, correction of the molar relationship also must become a goal of treatment. Doing this during the second phase of treatment, when a complete fixed appliance is available, is the





• **Fig. 11.65** (A) Anterior crowding combined with a straight anterior incisor segment. (B) Straight incisor segments with lateral incisors that overlap the mesial surface of the primary canine usually do not align into ideal arch form when the primary canines are extracted, even if a lingual arch is used.

most efficient approach. The techniques used for molar correction are discussed in detail in [Chapter 15](#).

### Generalized Moderate Crowding

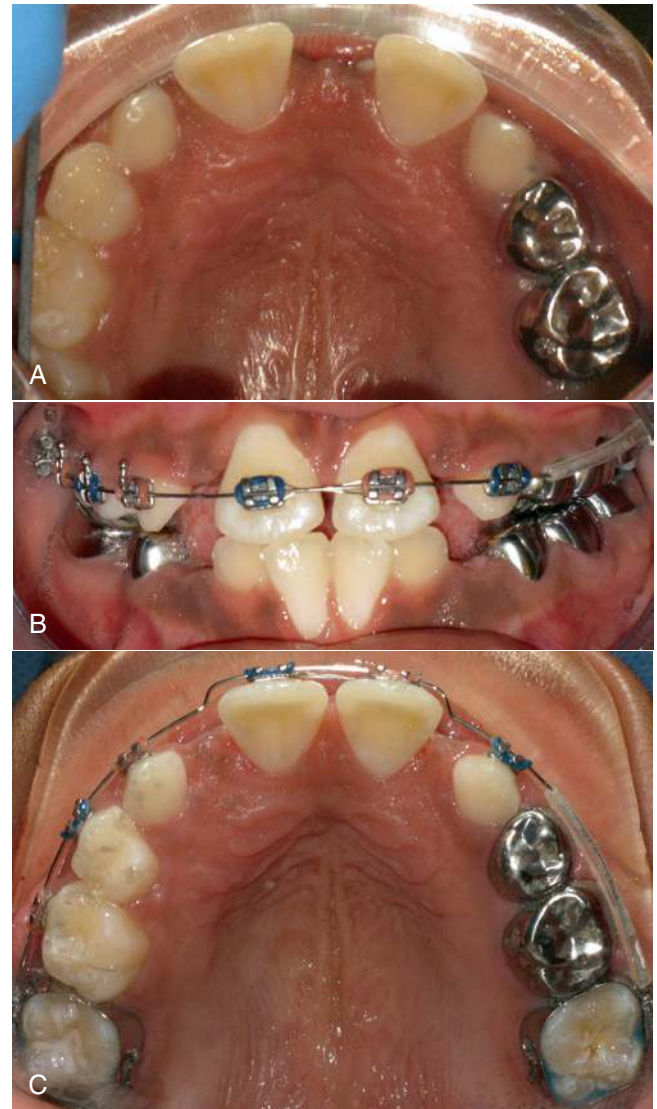
A child with a generalized arch length discrepancy of 2 to 4 mm and no prematurely missing primary teeth can be expected to have moderately crowded incisors. This occurs in about 25% of each ethnic group in the United States (see [Fig. 1.11](#)). Unless the incisors are severely protrusive, the long-term plan would be generalized expansion of the arch to align the teeth. The major advantage of doing this in the mixed dentition is improved dentofacial esthetics, and the benefit is largely for the parents, not the child.

If the parents strongly desire early treatment for moderate crowding, in the mandibular arch an adjustable lingual arch is the appliance of choice for simple expansion by tipping tooth movement. In the maxilla, either a removable or fixed appliance can be employed ([Fig. 11.66](#)). Keep in mind that rotated incisors usually will not correct spontaneously even if space is provided, so early correction would require bonded attachments for these teeth.

### Other Tooth Displacements

#### Spaced and Flared Maxillary Incisors

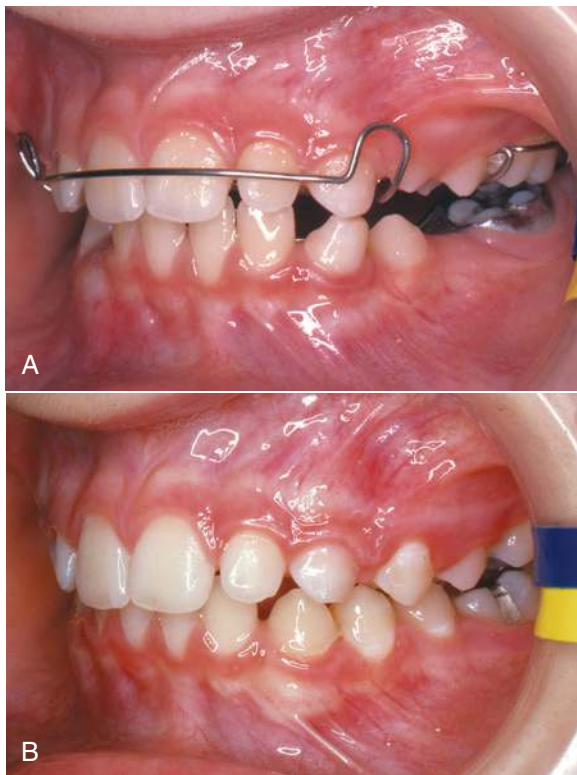
In children with spaced and flared maxillary incisors who have Class I molar relationships and good facial proportions, space analysis should show that the space available is excessive rather than



• **Fig. 11.66** Limited maxillary appliances can be used in the mixed dentition to align teeth and distribute space. (A) This patient had unerupted maxillary lateral incisors as a result of the large midline diastema. (B) and (C) The teeth were aligned and the diastema closed. Note the tubing that protects the patient's lip from the expanse of continuous wire on the patient's left side.

deficient. This condition often is found in the mixed dentition after prolonged thumb-sucking and frequently occurs in connection with some narrowing of the maxillary arch. A thumb or finger habit should be eliminated before attempts are made to retract the incisors. Physiologic adaptation to the space between the anterior teeth requires placing the tongue in this area to seal off the gap for successful swallowing and speech. This “tongue thrust” is not the cause of the protrusion or open bite and should not be the focus of therapy. If the teeth are retracted, the tongue thrust will disappear as the tongue adapts to the new morphologic characteristics.

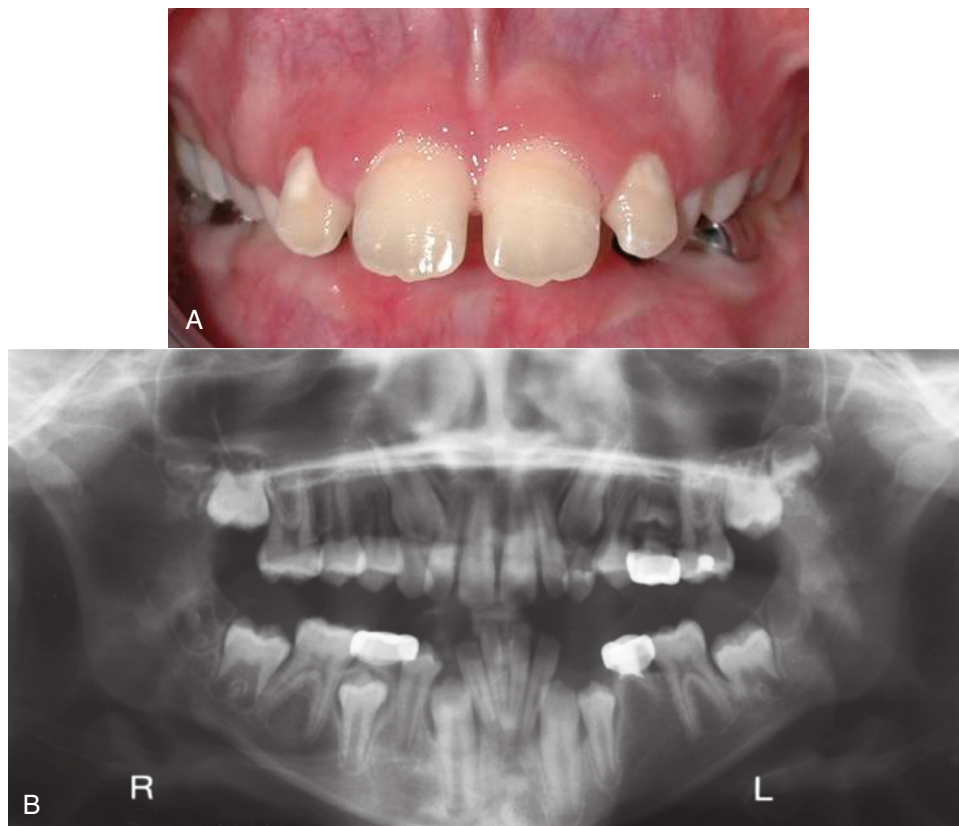
If the upper incisors are flared forward and there is no contact with the lower incisors, the protruding upper incisors can be retracted quite satisfactorily with a removable appliance. A Hawley-type appliance using multiple clasps and a labial bow can be effective



for this purpose (Fig. 11.67). Of course, the patient must be cooperative in wearing the appliance, and it must be constructed with adequate retention and a flexible labial bow (28-mil wire). Incorporating loops in the bow can aid the flexibility. During the course of treatment, the appliance is adjusted approximately 2 mm per month to achieve 1 mm of lingual tipping of the incisors and space closure. The palate-covering plastic lingual to the incisors must be removed to provide space for posterior movement of the teeth and gingiva. After space closure, the teeth need to be retained with the existing removable appliance.

On the other hand, if there is a deep overbite, protruding upper incisor teeth cannot be retracted until the overbite is corrected. The lower incisors biting against the lingual of the upper incisors prevent the upper teeth from being moved lingually. Even if anteroposterior jaw relationships are Class I, a skeletal vertical problem may be present, and complex treatment is likely to be required.

• **Fig. 11.67** A removable appliance can be used in the mixed dentition to retract spaced and protruding anterior teeth. (A) The labial bow is activated 1.5 to 2 mm and will achieve approximately 1 mm of retraction per month as the maxillary anterior teeth tip lingually. At each appointment, the labial bow should be adjusted and lingual acrylic removed to provide space for the tooth movement. (B) A near-normal occlusion in the late mixed dentition.



• **Fig. 11.68** The “ugly duckling” phase of dental development. (A) Spacing and mesial root position of the maxillary incisors result from the position of the unerupted permanent canines. (B) This panoramic radiograph shows that the canines are erupting and in close proximity to the roots of the lateral incisors. The spaces between the incisors, including the midline diastema, decrease and often completely disappear when the canines erupt.



Teeth that are flared and rotated or that require bodily movement during retraction are more difficult to move and control. This is a complex problem and discussed in [Chapter 12](#).

### Maxillary Midline Diastema

A small maxillary midline diastema, which is present in many children, is not necessarily an indication for orthodontic treatment. The unerupted permanent canines often lie superior and distal to the lateral incisor roots, which forces the lateral and central incisor roots toward the midline while their crowns diverge distally ([Fig. 11.68](#)). In its extreme form, this condition of flared and spaced incisors is called the “ugly duckling” stage of development (see [Chapter 4](#)). These spaces tend to close spontaneously or at least reduce in size when the canines erupt and the incisor root and crown positions change—the prevalence of a midline diastema drops from about 25% in the early mixed dentition to approximately 7% at ages 12 to 17.<sup>1</sup> Until the permanent canines erupt, it is difficult to be certain whether the diastema will close completely or only partially.

A small but unesthetic diastema (2 mm or less) can be closed in the early mixed dentition by tipping the central incisors together. A maxillary removable appliance with clasps, fingersprings, and possibly an anterior bow can successfully complete this type of treatment ([Fig. 11.69](#)). Under no circumstances should an unsupported rubber band be looped around the central incisors; there

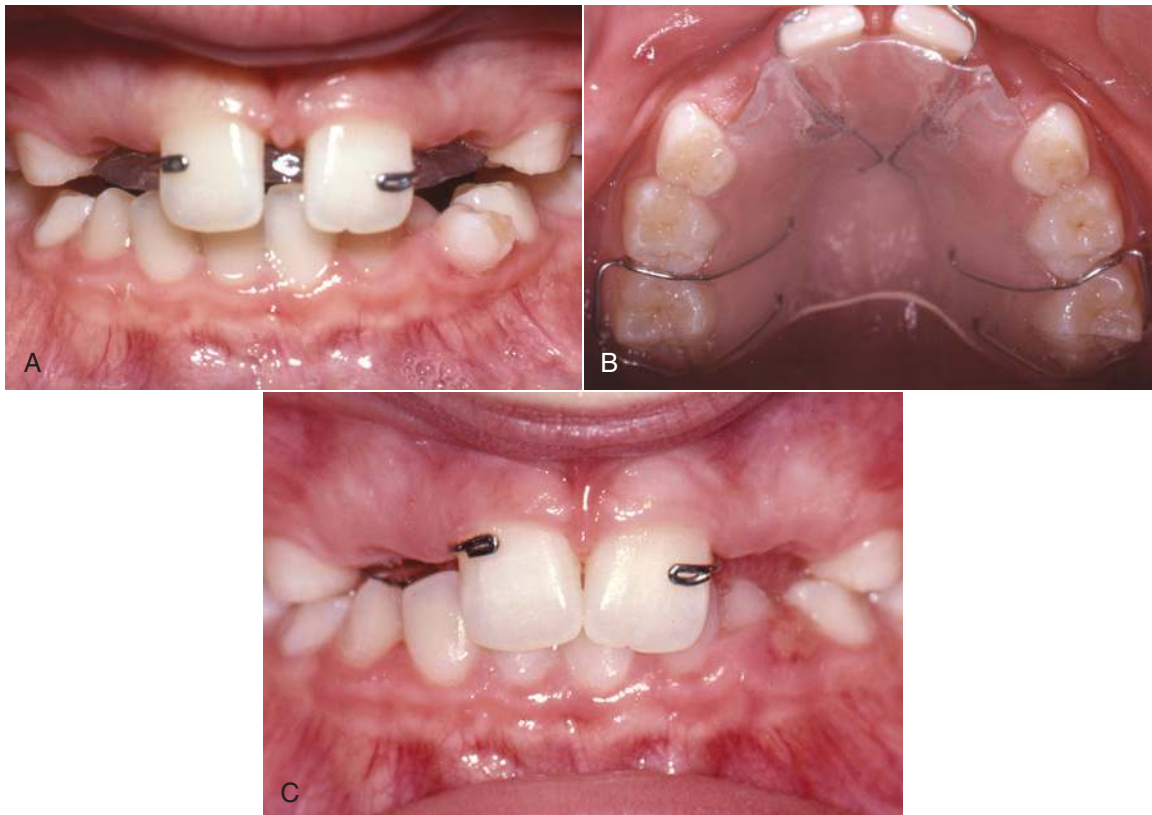is a high probability that it will slip apically and destroy the periodontal attachment. The elastic can become an effective way to extract both teeth.

When a larger diastema (>2 mm) is present, a midline supernumerary tooth or intrabony lesion must always be suspected ([Fig. 11.70](#)), and complete spontaneous closure is unlikely. A diastema this large is disproportionately prevalent in the African-American population. Depending on what radiographs are already available, one of several images may be appropriate—a panoramic radiograph, a maxillary occlusal radiograph, or a maxillary anterior CBCT image with a small FOV. Missing permanent lateral incisors also can lead to a large space between the central incisors because the permanent central incisors frequently move distally into the available space. Some digit-sucking habits can lead to diastemas and spacing.

Whatever its cause, a diastema greater than 2 mm is unlikely to close spontaneously.<sup>36</sup>

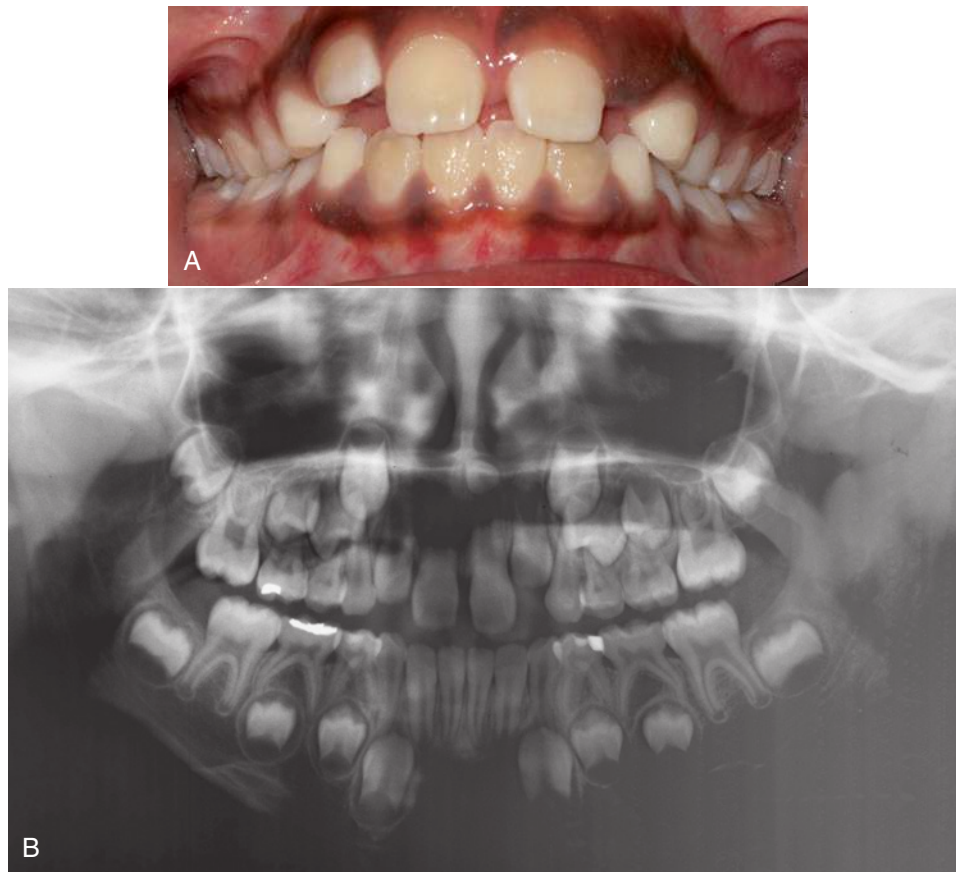This type of treatment will usually require bodily tooth movement and retention<sup>37</sup> and is addressed in [Chapter 12](#).

Sometimes the soft tissue of the midline frenum attachment is blamed for the space between the central incisors, but it is hard to be sure whether this is the case. Usually it is advisable to proceed with the tooth movement and determine if there are further problems with retention. If there are, then a frenectomy can be considered if there is excessive tissue bunched up in the midline. Early frenectomy should be avoided.



• **Fig. 11.69** (A) Closure of a midline diastema can be accomplished with a removable appliance and fingersprings to tip the teeth mesially. (B) The 28-mil helical fingersprings are activated to tip the incisors together. (C) The final position can be maintained with the same appliance.





• **Fig. 11.70** In the mixed dentition, sizable diastemas should be investigated to determine if they are the result of a supernumerary tooth, pathologic conditions, or missing permanent lateral incisors. (A) In this case, at least one lateral incisor is present along with the diastema, but (B) the accompanying radiograph shows that a midline supernumerary near the apex of the maxillary left central incisor is present. Clearly, the cause of the diastema dictates the treatment response.

## References

1. Brunelle JA, Bhat M, Lipton JA. Prevalence and distribution of selected occlusal characteristics in the US population, 1988-91. *J Dent Res.* 1996;75:706-713.
2. Adkins MD, Nanda RS, Currier GF. Arch perimeter changes on rapid palatal expansion. *Am J Orthod.* 1990;97:10-19.
3. Agostino P, Ugolini A, Signori A, et al. Orthodontic treatment for posterior crossbites. *Cochrane Database Syst Rev.* 2014;CD000979.
4. Godoy F, Godoy-Bezerra J, Rosenblatt A. Treatment of posterior crossbite comparing 2 appliances: a community-based trial. *Am J Orthod Dentofacial Orthop.* 2011;139:e45-e52.
5. Corbridge JK, et al. Transverse dentoalveolar changes after slow maxillary expansion. *Am J Orthod Dentofacial Orthop.* 2011;140:317-325.
6. Petré S, Björklund K, Bondemark L. Stability of unilateral posterior crossbite correction in the mixed dentition: a randomized clinical trial with a 3-year follow-up. *Am J Orthod Dentofacial Orthop.* 2011;139:e73-e81.
7. Ngan P, Hu AM, Fields HW. Treatment of Class III problems begins with differential diagnosis of anterior crossbites. *Pediatr Dent.* 1997;19:386-395.
8. Schott TC, Ludwig B. Microelectronic wear-time documentation of removable orthodontic devices detects heterogeneous wear behavior and individualizes treatment planning. *Am J Orthod Dentofacial Orthop.* 2014;146:155-160.
9. Lentini-Oliveira DA, Carvalho FR, Rodrigues CG, et al. Orthodontic and orthopaedic treatment for anterior open bite in children. *Cochrane Database Syst Rev.* 2014;CD005515.
10. Abreu LG, Paiva SM, Pordeus IA, Martins CC. Breastfeeding, bottle feeding and risk of malocclusion in mixed and permanent dentitions: a systematic review. *Braz Oral Res.* 2016;30:[Epub 2016 Mar 28].
11. Scavone H Jr, Guimarães CH Jr, Ferreira RI, et al. Association between breastfeeding duration and non-nutritive sucking habits. *Am J Orthod Dentofacial Orthop.* 2010;137:54-58.
12. Melink S, Vagner MV, Hocevar-Boltezar I, et al. Posterior crossbite in the deciduous dentition period: its relation with sucking habits, irregular orofacial functions, and otolaryngological findings. *Am J Orthod Dentofacial Orthop.* 2010;138:32-40.
13. Duncan K, McNamara C, Ireland AJ, et al. Sucking habits in childhood and the effects on the primary dentition: findings of the Avon Longitudinal Study of Pregnancy and Childhood. *Int J Paediatr Dent.* 2006;18:178-188.
14. Warren JJ, Slayton RL, Bishara SE, et al. Effects of non-nutritive sucking habits on occlusal characteristics in the mixed dentition. *Pediatr Dent.* 2005;27:445-450.
15. Haryett R, Hansen R, Davidson P, et al. Chronic thumbsucking: the psychological effects and the relative effectiveness of the various methods of treatment. *Am J Orthod.* 1967;53:559-585.
16. Villa NL, Cisneros GJ. Changes in the dentition secondary to palatal crib therapy in digit-suckers. *Pediatr Dent.* 1997;19:323-326.

17. Christensen RT, Fields HW, Christensen JR, Beck FM, Casamassimo PS, McTigue DJ. The effects of primary canine loss on permanent lower dental midline stability. *Pediatr Dent*. 2018;40(4):279–284.
18. Kennedy DB, Turley PK. The clinical management of ectopically erupting first permanent molars. *Am J Orthod Dentofacial Orthop*. 1987;92:336–345.
19. Aydin U, Yilmaz HH, Yildirim D. Incidence of canine impaction and transmigration in a patient population. *Dentomaxillofac Radiol*. 2004;33:164–169.
20. Naoumova J, Kurol J, Kjellbert H. A systematic review of the interceptive treatment of palatally displaced maxillary canines. *Eur J Orthod*. 2011;33:143–149.
21. Garib DG, Alencar BM, Lauris JR, et al. Agenesis of maxillary lateral incisors and associated dental anomalies. *Am J Orthod Dentofacial Orthop*. 2010;137(732):e1–e6.
22. Cernochova P, Krupa P, Izakovicova-Holla LA. Root resorption associated with ectopically erupting maxillary permanent canines: a computed tomography study. *Eur J Orthod*. 2011;33:483–491.
23. Alqerban A, Jacobs R, Fieuws S, et al. Comparison of two cone-beam computed tomographic systems versus panoramic imaging for localization of impacted maxillary canines and detection of root resorption. *Eur J Orthod*. 2011;33:93–102.
24. Ericson S, Kurol J. Early treatment of palatally erupting maxillary canines by extraction of the primary canines. *Eur J Orthod*. 1988;10:283–295.
25. Almasoud NN. Extraction of primary canines for interceptive orthodontic treatment of palatally displaced permanent canines: a systematic review. *Angle Orthod*. 2017;87:878–885.
26. Sigler LM, Baccetti T, McNamara JA Jr. Effect of rapid maxillary expansion and transpalatal arch treatment associated with deciduous canine extraction on the eruption of palatally displaced canines: a 2-center prospective study. *Am J Orthod Dentofacial Orthop*. 2011;139:e235–e244.
27. Kurol J, Thilander B. Infraocclusion of primary molars with aplasia of the permanent successor: a longitudinal study. *Angle Orthod*. 1984;54:283–294.
28. Tanaka MM, Johnston LE. The prediction of the size of unerupted canines and premolars in a contemporary orthodontic population. *J Am Dent Assoc*. 1974;88:798–801.
29. Tunc ES, Bayrak S, Tuloglu N, et al. Evaluation of survival of 3 different fixed space maintainers. *Pediatr Dent*. 2012;34:e97–e102.
30. Mayhew M, Dilley G, Dilley D, et al. Tissue response to intralingival appliances in monkeys. *Pediatr Dent*. 1984;6:148–152.
31. Moore TR, Kennedy DB. Bilateral space maintainers: a 7-year retrospective study from private practice. *Pediatr Dent*. 2006;28:499–505.
32. Hashish DI, Mostafa YA. Effect of lip bumpers on mandibular arch dimensions. *Am J Orthod Dentofacial Orthop*. 2009;135:106–109.
33. Gianelly AA. Crowding: timing of treatment. *Angle Orthod*. 1994;64:415–418.
34. Brennan M, Gianelly AA. The use of the lingual arch in the mixed dentition to resolve crowding. *Am J Orthod Dentofacial Orthop*. 2000;117:81–85.
35. Little RM. Stability and relapse: early treatment of arch length deficiency. *Am J Orthod Dentofacial Orthop*. 2002;121(6):578–581.
36. Huang WJ, Creath CJ. The midline diastema: a review of its etiology and treatment. *Pediatr Dent*. 1995;17:171–179.
37. Moffitt AH, Raina J. Long-term bonded retention after closure of maxillary midline diastema. *Am J Orthod Dentofacial Orthop*. 2015;148:238–244.

# 12

## Complex Nonskeletal Problems in Preadolescent Children: Preventive and Interceptive Treatment

### CHAPTER OUTLINE

#### Eruption Problems

- Delayed Incisor Eruption
- Transposition
- Primary Failure of Eruption
- Impact of Radiation Therapy and Bisphosphonates

#### Traumatic Displacement of Teeth

- Ankylosed Primary Molars Without Successors

#### Space-Related Problems

- Excess Space
- Maxillary Dental Protrusion and Spacing
- Missing Permanent Teeth
- Localized Moderate-to-Severe Crowding
- Generalized Moderate and Severe Crowding
- Early (Serial) Extraction
- The Borderline Crowding Case: What Do You Do?

### Eruption Problems

#### Delayed Incisor Eruption

When an incisor has delayed eruption and there is no impediment such as a supernumerary tooth or other pathology, simple excision of the overlying soft tissue is recommended (see [Chapter 11](#)). This usually leads to normal eruption.

If there is *any* doubt regarding the potential for eruption or whether there has been adequate exposure of the crown, the tooth should have an attachment bonded to it (a bracket or button, depending on access). A metal chain (*not* a wire ligature around the cervical portion of the tooth) is attached to the bracket or button and extended out of the tissue so traction can be applied using a fixed appliance if necessary ([Fig. 12.1](#)). If space is not adequate, preoperative space opening should have been accomplished so the sequence of treatment is seamless.

In general, the force against the unerupted tooth is applied by using either elastomeric chain or (better) a nickel–titanium (NiTi) overlay wire supported by a heavy base wire with bonded brackets on several teeth for anchorage. The chain is adequate for initial movement because it is not as irritating to the soft tissue. As the

tooth erupts, often the bracket placed initially requires repositioning because the initial bonding during the surgical procedure was less than ideal. Final root positioning can be left until a second stage of treatment during the permanent dentition if one is anticipated.

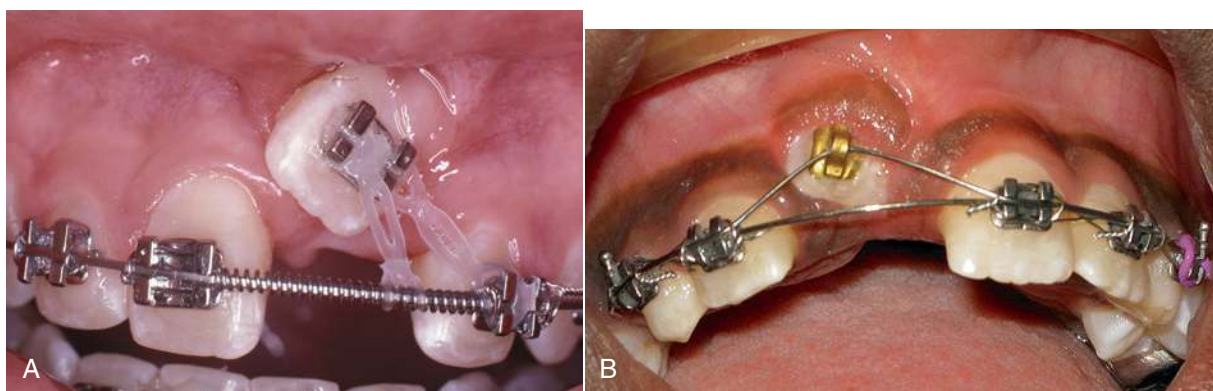
#### Transposition

Transposition is a rare positional interchange of two adjacent teeth. It occurs with a prevalence of approximately 0.3% and equally affects males and females.<sup>1</sup> The teeth most likely to be transposed are mandibular incisors and maxillary premolars, and this usually occurs as a consequence of ectopic eruption (discussed in [Chapter 11](#)). There appears to be a genetic component to this problem.<sup>2</sup>

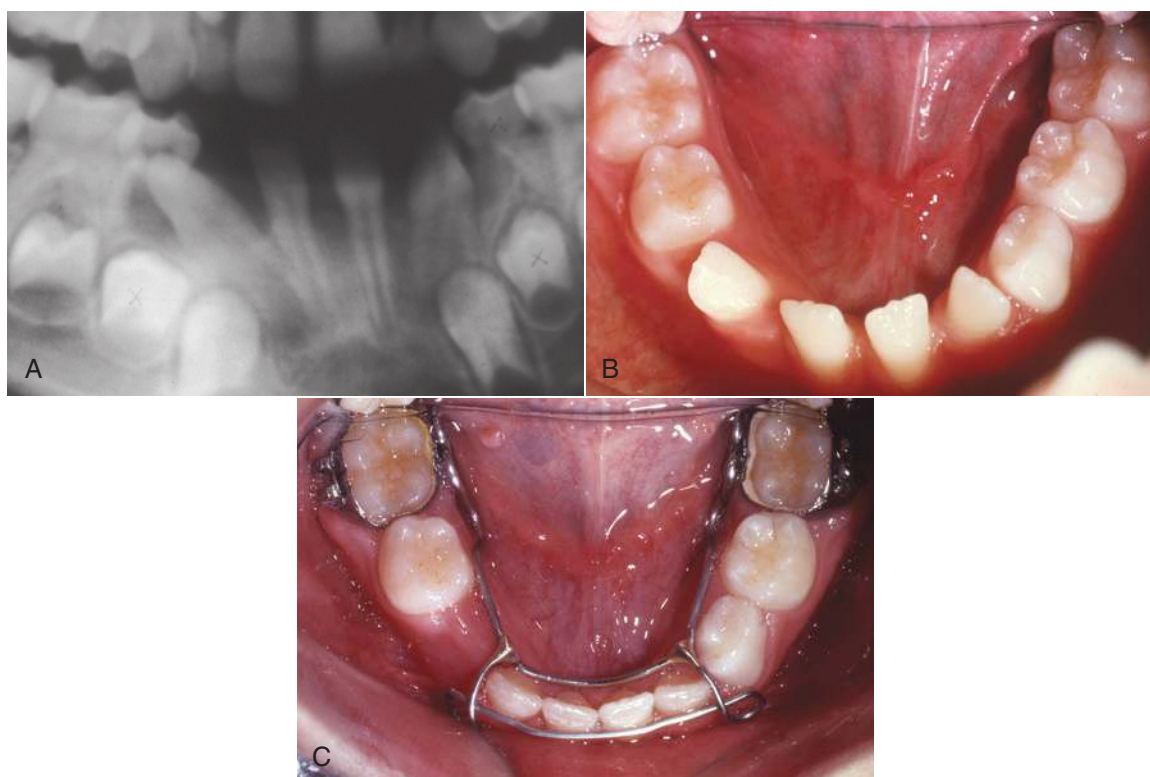In the early mixed dentition years, transposition can develop when distally directed eruption of the permanent mandibular lateral incisor leads to loss of the primary mandibular canine and primary first molar ([Fig. 12.2](#)). If left untreated, this can result in a true transposition of the permanent lateral incisor and canine. Interceptive treatment requires repositioning the lateral incisor mesially ([Fig. 12.2C](#)), which eliminates the possibility of the complete transposition with the canine. This means either bonding the tooth or gaining surgical access to the tooth and applying traction to tip the tooth back to its natural position. In addition to a labial fixed appliance, a lingual arch usually is required for supplemental anchorage. The benefit of this type of early intervention is that simple tipping movement usually can reposition the tooth. Left until later, bodily movement of the erupted teeth is required. One adverse consequence of this early repositioning is potential resorption of the lateral incisor root because it may be brought into contact with the unerupted canine. This is unlikely because of the usual facial position of the unerupted canine but should be discussed with the patient and parents before treatment. Beginning treatment before the canine is actively erupting is important.

Later in the mixed dentition, the more prevalent transposition is of the maxillary canine and first premolar or maxillary canine and lateral incisor.<sup>3</sup> Treatment of transpositions involving the maxillary canine if not addressed early is quite challenging. Moving the teeth to their natural positions can be difficult because this requires bodily repositioning, translating the canine facially or lingually past the other tooth. Careful consideration of alveolar width and the integrity of the attached supporting tissue is required. Often, the best approach is to move a partially transposed tooth to a total transposed position or to leave fully transposed teeth in





• **Fig. 12.1** (A) For initial traction to an unerupted incisor, it is acceptable to use a heavy base archwire and elastomeric chain to the teeth. Although this places relatively heavy forces on the teeth and has limited range, the limited invasiveness and bulk make it a sensible starting method. (B) A simple and more efficient option is to use the flexibility of a superelastic auxiliary archwire (austenitic nickel–titanium [A–NiTi]) while stabilizing with another stiffer wire to control the reciprocal forces. This is accomplished by tying the superelastic wire over the base archwire except in the area of the unerupted tooth, and deflecting it gingivally to provide the traction. The overlay wire should be tied loosely with steel ligatures to further reduce friction and released at adjustment appointments so the wire regains its superelastic properties. As the tooth erupts, it can be incorporated in a continuous flexible wire or the base wire will have to be offset to allow for the bracket to pass it.

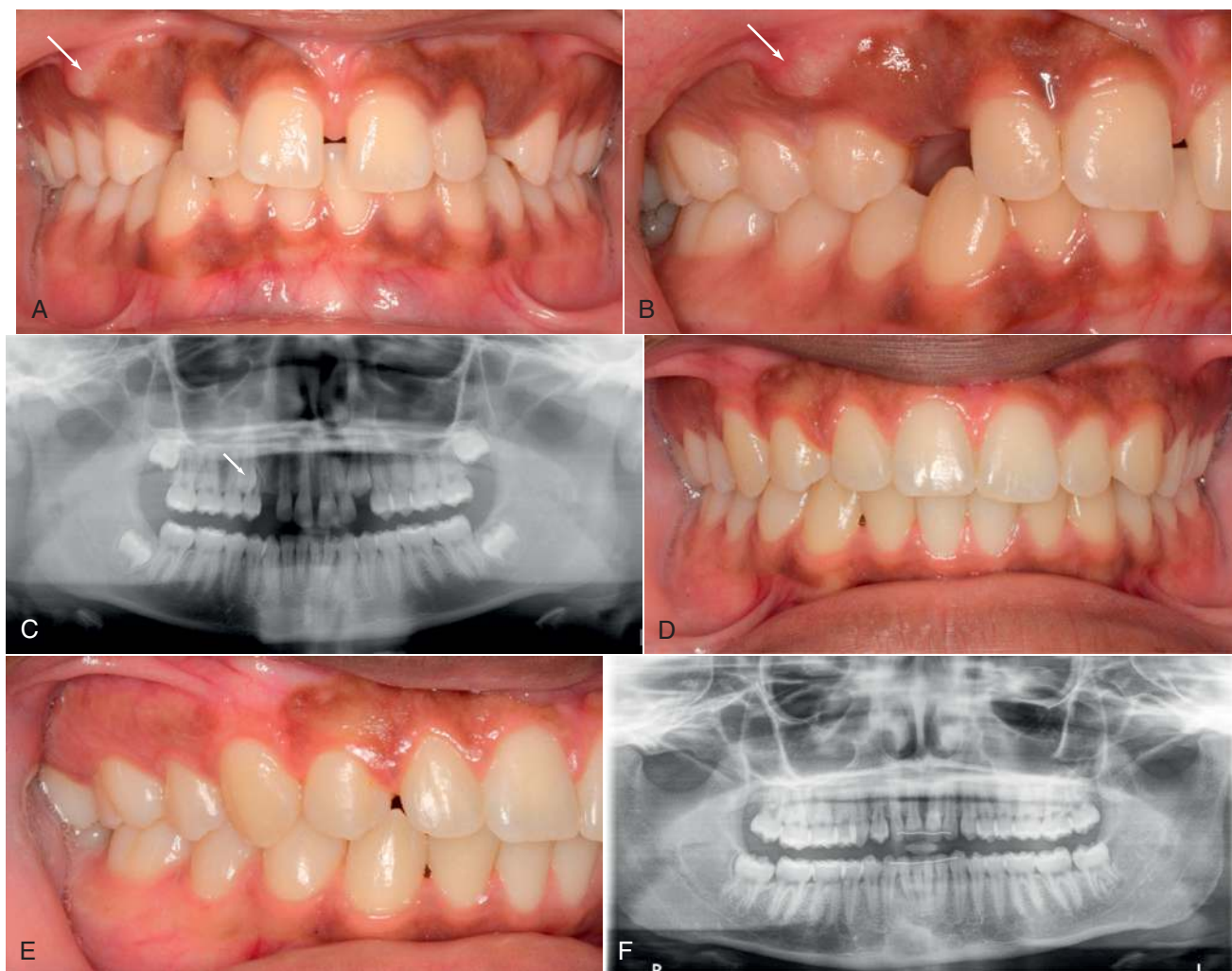

• **Fig. 12.2** (A) This radiograph shows that the right mandibular lateral incisor is erupting ectopically and has resorbed the roots of the primary canine and first molar. (B) Failure to reposition the right lateral incisor will lead to true transposition of the permanent lateral and canine. (C) The lateral incisors have been repositioned with fixed appliances and are now retained.

that position (Fig. 12.3). This requires careful finishing with reshaping of the transposed tooth both to improve its appearance and fit it within the dental arch. Although this can be difficult, the time and difficulty in correcting the transposition make it even more challenging.

### Primary Failure of Eruption

Primary failure of eruption (PFE) is characterized by failure of eruption of permanent posterior teeth when there is no mechanical interference, and now is known to have a genetic etiology (see Chapter 3).<sup>4</sup> This usually is noted in the late mixed dentition when



• **Fig. 12.3** (A) and (B) This patient has a transposed permanent maxillary canine in the mixed dentition that is visible under the tissue between the first and second premolars. (C) This preoperative radiograph confirms its position. (D) and (E) The canine was left in the transposed position and brought into the arch between the premolars. (F) This postoperative radiograph confirms its position.

some or all the permanent first molars still have not erupted and eruption of other posterior teeth appears abnormal (Fig. 12.4). The affected teeth are not ankylosed but do not erupt and do not respond normally to orthodontic force, so they cannot be pulled into occlusion. If tooth movement is attempted, usually the affected teeth will ankylose after little or no movement in any direction, and only what were supposed to be the anchor teeth will move.

Table 12.1 contrasts the diagnostic characteristics of PFE with the much more frequent situation of mechanical obstruction.<sup>5</sup> Obtaining a genetic analysis to confirm the diagnosis (which can be done using just a saliva sample) can help guide the patient and parents in accepting the reality of the problem, and circumvent treatment attempts that will not be successful. As the table points out, the most difficult diagnosis is whether a single unerupted molar is due to isolated ankylosis or PFE, and the table explains why doing nothing is not appropriate treatment.

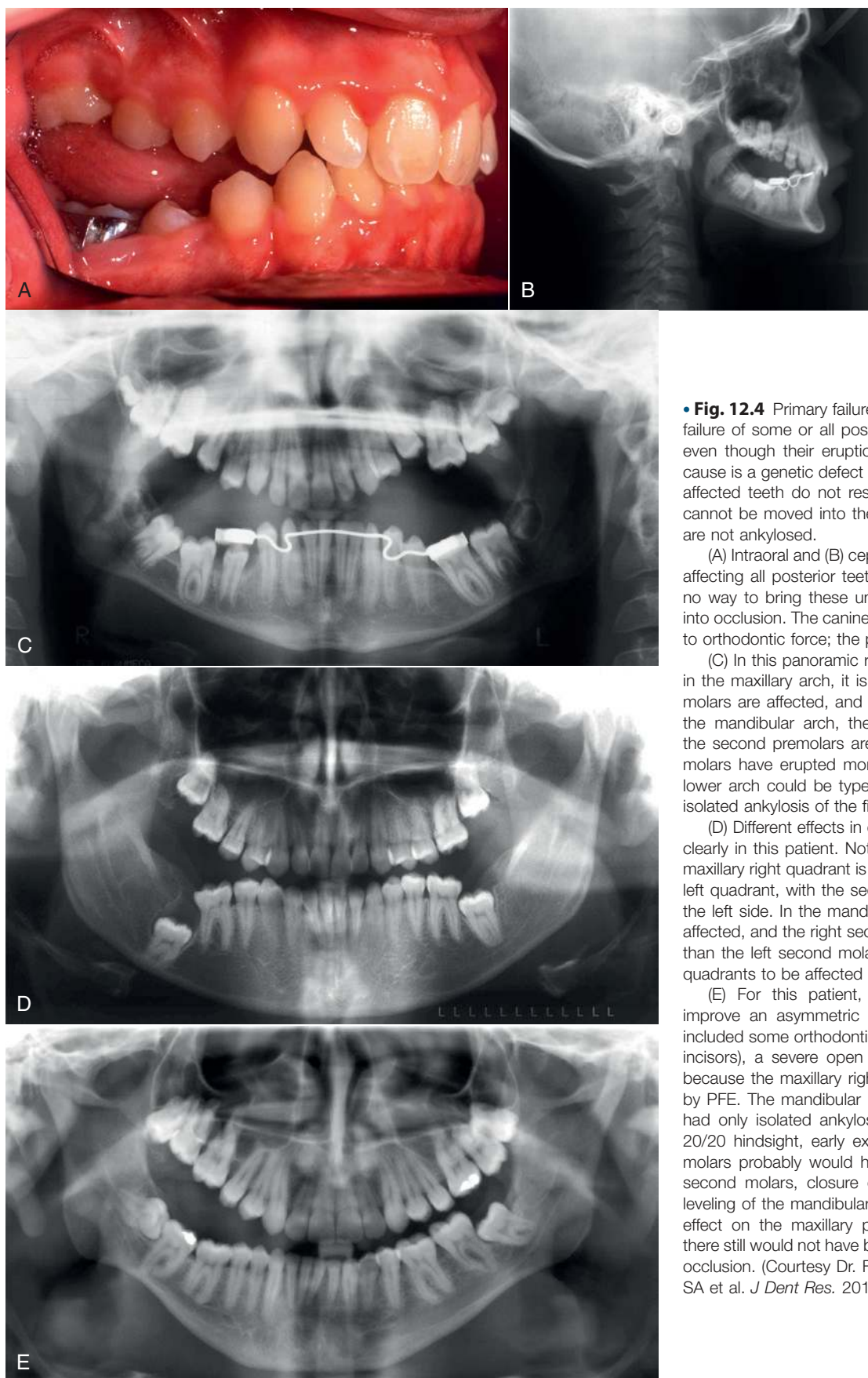
Because this is the unusual case in which orthodontics simply doesn't work, acceptance of premolar occlusion in affected quadrants usually is the best long-term option. Prosthetic replacement of the

teeth that failed to erupt, or possibly segmental osteotomies or distraction osteogenesis, is almost the only treatment possibility—and such treatment is indicated only in mild cases. It is somewhat distressing, but very useful, to know what you can't do as well as what you can.

### Impact of Radiation Therapy and Bisphosphonates

Because of the increased prevalence of successful stem cell transplantation (SCT) and total body irradiation (TBI) for treatment of childhood cancers, more patients with missing teeth and altered tooth morphology are being observed. Early age at SCT (younger than 5 years old) is more of a risk factor than TBI.<sup>6</sup> Shortened roots are the result of high-dose chemotherapy and TBI, especially when treatment is in the 3- to 5-years age group.<sup>7</sup> Because these patients have high survival rates, they now seek orthodontic treatment. Some of the irradiated teeth fail to develop, others fail to erupt, and some may erupt even though they have extremely limited root development. Although the roots are short, light forces can





• **Fig. 12.4** Primary failure of eruption is characterized by failure of some or all posterior permanent teeth to erupt even though their eruption path has been cleared. The cause is a genetic defect in the eruption mechanism. The affected teeth do not respond to orthodontic force and cannot be moved into the dental arch even though they are not ankylosed.

(A) Intraoral and (B) cephalometric views of severe PFE affecting all posterior teeth in both jaws. There is simply no way to bring these unerupted premolars and molars into occlusion. The canines and incisors respond normally to orthodontic force; the posterior teeth do not.

(C) In this panoramic radiograph of a mid-adolescent, in the maxillary arch, it is apparent that the second premolars are affected, and the first premolars might be. In the mandibular arch, the first molars are affected and the second premolars are questionable, but the second molars have erupted more than the first molars, so the lower arch could be type 2 PFE but also could be only isolated ankylosis of the first molars.

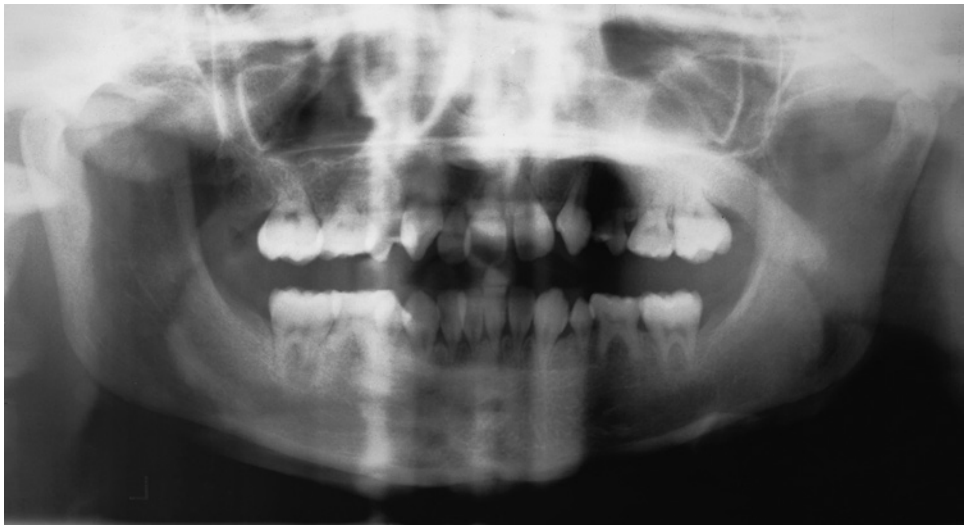(D) Different effects in different quadrants can be seen clearly in this patient. Note in the maxillary arch that the maxillary right quadrant is more severely affected than the left quadrant, with the second premolar affected only on the left side. In the mandibular arch, only the molars are affected, and the right second molar was affected sooner than the left second molar. It is not unusual for different quadrants to be affected differently.

(E) For this patient, after orthognathic surgery to improve an asymmetric skeletal Class III problem that included some orthodontics (primarily repositioning of the incisors), a severe open bite persists on the right side because the maxillary right quadrant is severely affected by PFE. The mandibular right quadrant appears to have had only isolated ankylosis of the first molar, and with 20/20 hindsight, early extraction of the mandibular first molars probably would have allowed mesial drift of the second molars, closure of the first molar spaces, and leveling of the mandibular arch. Given the severity of the effect on the maxillary premolars and molars, though, there still would not have been any way to obtain posterior occlusion. (Courtesy Dr. F. Del Toro; from Frazier-Bowers SA et al. *J Dent Res.* 2014;93:134–139.)



**TABLE 12.1** Distinguishing Primary Failure of Eruption (PFE) From Other Eruption Disorders

PFE	Other Disorder
Affects posterior teeth only Molars: always Second premolars: sometimes First premolars: rarely	Affects some or all anterior teeth also Canines Lateral incisors Central incisors
Eruption pathway clear (no mechanical obstruction)	Mechanical obstruction of eruption (ankylosis, eruption pathway blocked)
Affected teeth do not respond to orthodontic force	Teeth respond normally after eruption path is cleared (ankylosis is permanent)
Family history (some, not all)	History of pathologic condition or trauma
<i>PTHR1</i> mutation is diagnostic (but not all have this)	No or unknown genetic cause
The biggest diagnostic problem: One affected first molar (usually mandibular)—is it isolated ankylosis or PFE? <ul style="list-style-type: none"><li>• If it's PFE, the second molar also will be affected and will not erupt normally.</li><li>• If it's isolated ankylosis, the second molar will erupt normally (including mesial drift).</li></ul>	
What do you do? <i>Extract the unerupted first molar as early as possible.</i> <ul style="list-style-type: none"><li>• If it was isolated ankylosis, the second molar will drift forward, bringing bone with it.</li><li>• And if it was PFE, the second molar will be abnormal and also a candidate for extraction.</li></ul>	
<i>Bottom line:</i> You have nothing to lose with early extraction, and often something to gain.	



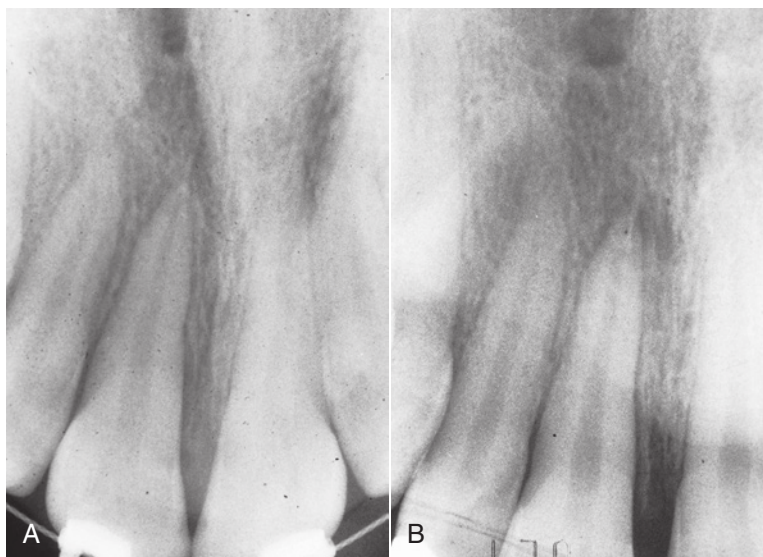
• **Fig. 12.5** This patient's panoramic radiograph shows shortening of the roots of multiple permanent teeth following radiation therapy. These teeth can be moved orthodontically, if necessary, with limited objectives and light forces. (Courtesy Dr. D. Grosshandler.)

be used to reposition these teeth and achieve better occlusion without fear of tooth loss (Fig. 12.5). Children are increasingly receiving bisphosphonates in conjunction with other therapies, especially for steroid-induced osteoporosis or osteogenesis imperfecta. This drug class has known implications for dentistry and makes orthodontic tooth movement almost impossible (see Chapter 8).<sup>8,9</sup> Orthodontic treatment should not be attempted while bisphosphonates are actively being used. Currently, as children who previously underwent bisphosphonate treatment reach the age at which orthodontic tooth movement will be a possibility, it is important to assess the impact of this

therapy. Intravenous treatments appear to produce more long-term impact than oral medication, as does the length of treatment and the number of intervening years since treatment.

Traumatic Displacement of Teeth

Treating traumatically injured teeth is complicated, and recommendations continue to change and evolve. Here we will provide a summary of the current (2017) knowledge in selected areas. In order to remain current, clinicians are encouraged to consult The Dental Trauma Guide.<sup>10</sup>



• **Fig. 12.6** Multiple vertically positioned radiographs are required for an adequate diagnosis of previously traumatized teeth. (A) This radiograph displays no periapical pathology 2 weeks after the trauma to the central incisors, but a radiograph (B) exposed at the same time from a different vertical position shows a periapical radiolucency at the apex of the maxillary right central incisor.

Immediately after a traumatic injury, teeth that have not been irreparably damaged usually are repositioned with finger pressure to a near normal position and out of occlusal interference. They are then stabilized (with a light wire or nylon filament) for approximately 3 to 5 weeks depending on the extent of the injury. At this point, the teeth usually exhibit physiologic mobility. If the alveolus has been fractured, then the teeth should be stabilized with a heavy wire for approximately 6 weeks.

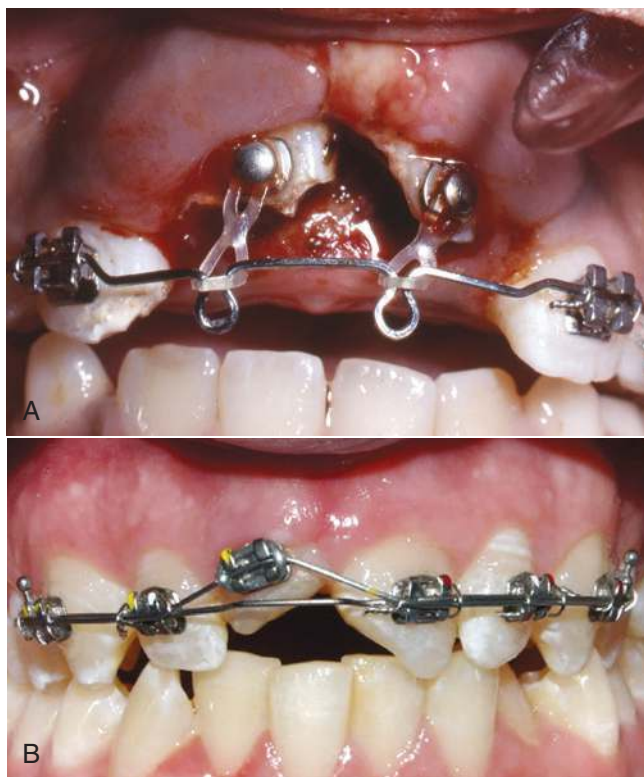Following either of these initial treatments, if the teeth are not in ideal positions, orthodontic treatment to reposition them is indicated. For most patients it is advised to wait 3 to 4 months to begin active treatment, but for more severe periodontal-type injuries (luxation, intrusion, extrusion, or avulsion), some clinicians recommend longer waiting times (of up to 1 year).<sup>11</sup> On the other hand, if after an injury the teeth have consolidated in a position that causes an occlusal interference, tooth movement should be started earlier to remove the interference (although final positioning of the teeth probably should be delayed after that). In either scenario, light force should be used. In orthodontic treatment that begins after significant trauma, even tipping forces can lead to loss of vitality and root resorption for previously traumatized teeth,<sup>12</sup> and patients who had partial obliteration of the pulp as a result of trauma are at particular risk.<sup>13</sup>

This increased risk of devitalization also applies to patients injured during orthodontic treatment, even though the orthodontic appliance often prevents extreme displacement of the teeth. Devitalization is still quite likely for those who have severe periodontal trauma (more extensive than crown fracture and especially luxation, intrusion, and extrusion injuries).<sup>14</sup>

Until recently, traumatized teeth were evaluated initially with multiple radiographs at numerous vertical and horizontal angulations to rule out vertical and horizontal root fractures that could make it impossible to save the tooth or teeth (Fig. 12.6); now cone beam computed tomography (CBCT) with a small field of view usually is an option. During orthodontic treatment, it is reasonable to follow the teeth clinically by observing clinical mobility, sensitivity

to percussion and cold, and electric pulp testing. The patients should immediately report tooth discoloration, pain, swelling, and any discharge from the surrounding tissues. Radiographically, periapical radiographs at 2 to 3 weeks, 6 to 8 weeks, and 1 year are indicated to determine periapical pathology. If the apex is complete at the time of the injury, it is more likely that the tooth will become nonvital from luxation injuries. If that happens, pulpal extirpation and treatment are recommended. External root resorption can jeopardize the tooth quite rapidly. When this is observed, immediate pulpal extirpation and antiresorptive treatment are recommended as the best approach.

Traumatic vertical displacement of teeth can be managed either by surgical repositioning of the traumatized teeth or orthodontic tooth movement. Teeth with an incomplete apex that have been intruded more than 7 mm and those with complete roots intruded more than 3 mm are unlikely to achieve complete correction with orthodontics alone, and surgical repositioning of the teeth can be considered before healing from the trauma is complete. For teeth with less severe intrusion, orthodontics provides better supporting tissue outcomes than surgical repositioning,<sup>15</sup> and to keep this option open, the intruded teeth should be observed for about 3 weeks before any treatment. If they do begin to actively re-erupt, they can simply be observed; if they don't show any re-eruption, orthodontics still is an option even for those with complete roots intruded up to 7 mm, but may be impractical in terms of treatment time and appointments required (Fig. 12.7). Remember, periodontal injury can lead to ankylosis that makes orthodontics impossible, but although nearly all severely displaced teeth with complete roots will have pulpal necrosis that requires endodontics,<sup>16</sup> nonvital teeth can be moved orthodontically after endodontic treatment. So here is the dilemma. Even though the goal is to preserve pulpal vitality with intruded teeth and this is enhanced by re-eruption, repositioning is critical to improve access for endodontics and to complete the diagnosis. Crown and root fractures can remain undiagnosed even with extensive radiographs. If we wait a full 3 weeks, we will not be able to ensure endodontic access to reduce the possibility

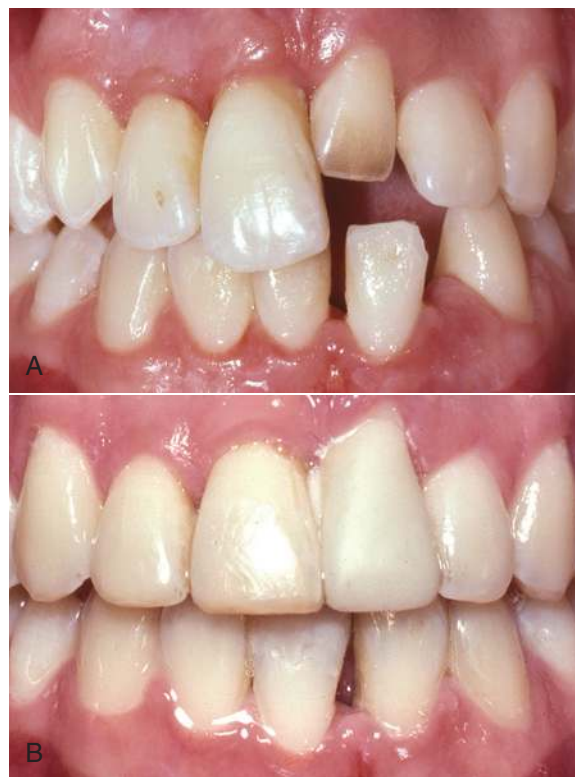

• **Fig. 12.7** (A) For teeth without open apices, traction following intrusion of permanent teeth can ensure adequate endodontic access if necessary. To begin, elastomeric chain can be used. (B) A more efficient method is to use a heavy base archwire complemented by a nickel–titanium (NiTi) overlay wire for rapid tooth movement. Note that the base archwire has been stepped facially to allow the bracketed tooth to pass on its lingual side.

and extent of resorption. Practically, the approach is that we wait the 3 weeks only if the teeth with immature or mature apices are actively re-erupting. Otherwise, we intervene with orthodontics or surgical repositioning sooner. If access still cannot be obtained, a gingivectomy should be performed to facilitate access. Fortunately, an endodontically treated tooth that will need orthodontics can be successfully moved without much fear of resorption.<sup>17</sup>

Traumatically extruded teeth also are at increased risk for losing pulp vitality. Those that were not immediately repositioned with finger pressure and have stabilized in their posttrauma position pose a difficult problem after complete healing. These teeth have reduced bony support and a poor crown–root ratio. Attempts to intrude them result in bony defects between the teeth, and loss of pulp vitality is a major risk (especially for lateral incisors), so orthodontic intrusion is not a good plan.<sup>18</sup> When the discrepancy is minor to moderate, reshaping the elongated tooth by crown reduction may be the best plan (Fig. 12.8). On the other hand, avulsed teeth that were not completely seated in the socket during initial injury treatment and are extruded as a result can be successfully orthodontically repositioned if treatment begins immediately.

Another consideration for patients with traumatically injured anterior teeth that cannot be restored is decoronation, removing the clinical crown of the compromised tooth and root structure to below the soft tissue level and removing vital pulp tissue until vertical growth is largely completed and an implant can be placed



• **Fig. 12.8** (A) This patient had extrusive displacement injuries to the maxillary permanent right incisors. (Also note that the permanent mandibular left central incisor was reimplanted as the lost permanent maxillary left central incisor.) (B) Because it is difficult to intrude these maxillary incisors and there is a risk of a subsequent bony defect, the crowns of these teeth were reduced to provide a better crown–root ratio and improve the appearance.

into the area.<sup>19</sup> This adjunctive procedure reduces the chance of ridge resorption and the need for later bone grafting. If the tooth is compromised and can still be moved orthodontically, it can be repositioned and the root buried at the optimal place. The root can subsequently be removed or the implant placed through it (Fig. 12.9).

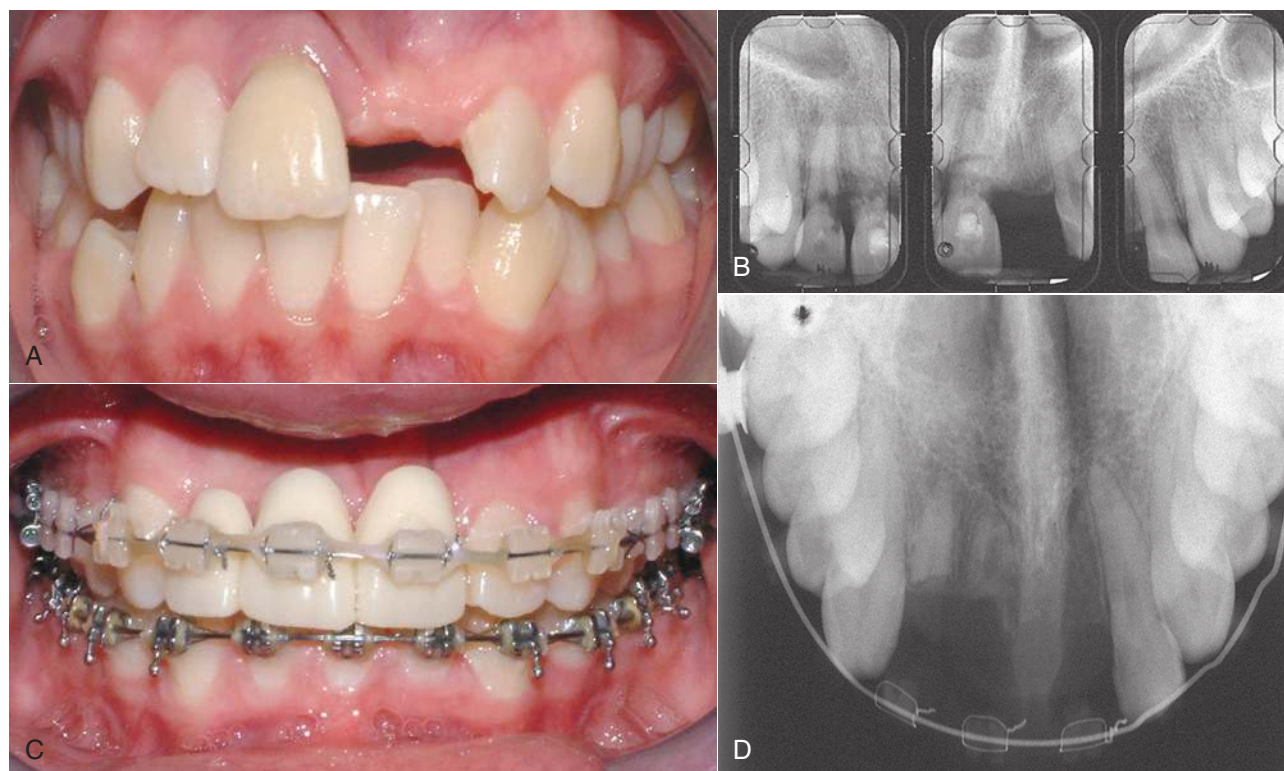
### Ankylosed Primary Molars Without Successors

Ankylosed primary molars are common (remember, this is the second most frequent congenitally missing tooth, behind only maxillary lateral incisors). Most have successors and will exfoliate in reasonable time. If the premolar is blocked by the retained crown of an ankylosed primary molar, the remainder of the crown should be extracted.

The teeth that are problematic are ankylosed primary second molars without successors that are *not* planned for extraction and drift or space closure (addressed later in this chapter). As other teeth erupt and the ankylosed ones do not, large vertical occlusal discrepancies and vertical periodontal defects on the adjacent permanent teeth can develop. If this occurs and the ankylosed teeth are extracted, a great deal of bone will be lost and the cementum of the adjacent permanent teeth will be exposed—compromising these teeth.

One solution is early extraction of the ankylosed second primary molar before any vertical defect advances too far, and *not* placing





• **Fig. 12.9** This patient had root burial to retain the maxillary anterior alveolar bone. (A) The maxillary left central incisor was avulsed. (B) The maxillary radiograph shows severe resorption of the roots of the maxillary right central and lateral incisors. Instead of extracting these two teeth, they were decoronated (crowns removed and roots covered with soft tissue) to maintain the ridge. (C) The pontics are in place during orthodontic treatment for space control and esthetics; the roots maintain the ridge as seen on the radiograph (D).

a space maintainer. Letting the first permanent molar drift mesially is desirable for two reasons: It reduces the size of the implant to closer to the size of a second premolar, and the first molar brings bone with it as it moves forward. Certainly, after the extraction, the bony ridge will deteriorate, but the periodontal attachments will have limited compromise.

The other possibility is decoronation, as described earlier, which is increasingly indicated for patients who still have the growth spurt remaining but for some reason (potentially unsupported posterior teeth, incisor retrusion or other spacing in the arch) are not going to have space closure but later implants for the missing teeth (Fig. 12.10). For these patients, the vertical defect at the time of implant placement is reduced and bone grafting may not be necessary. It is possible that new bone will form coronal to the buried root structure (Fig. 12.11), and an implant in late adolescence with good bony support should be possible.

## Space-Related Problems

The most frequent cause of irregular and malaligned teeth in the early mixed dentition is a lack of adequate space for alignment of permanent incisors, but loss of space due to mesial drift of permanent molars after early loss of primary second molars is the major indication for treatment in the early mixed dentition beyond the interferences with eruption that we have discussed. Early treatment to align crowded incisors may or may not be indicated. The decision as to whether this should be done in the mixed dentition and how it will be accomplished depends on the impact

on esthetics as judged by the child and parents, as well as the location and magnitude of the problem.

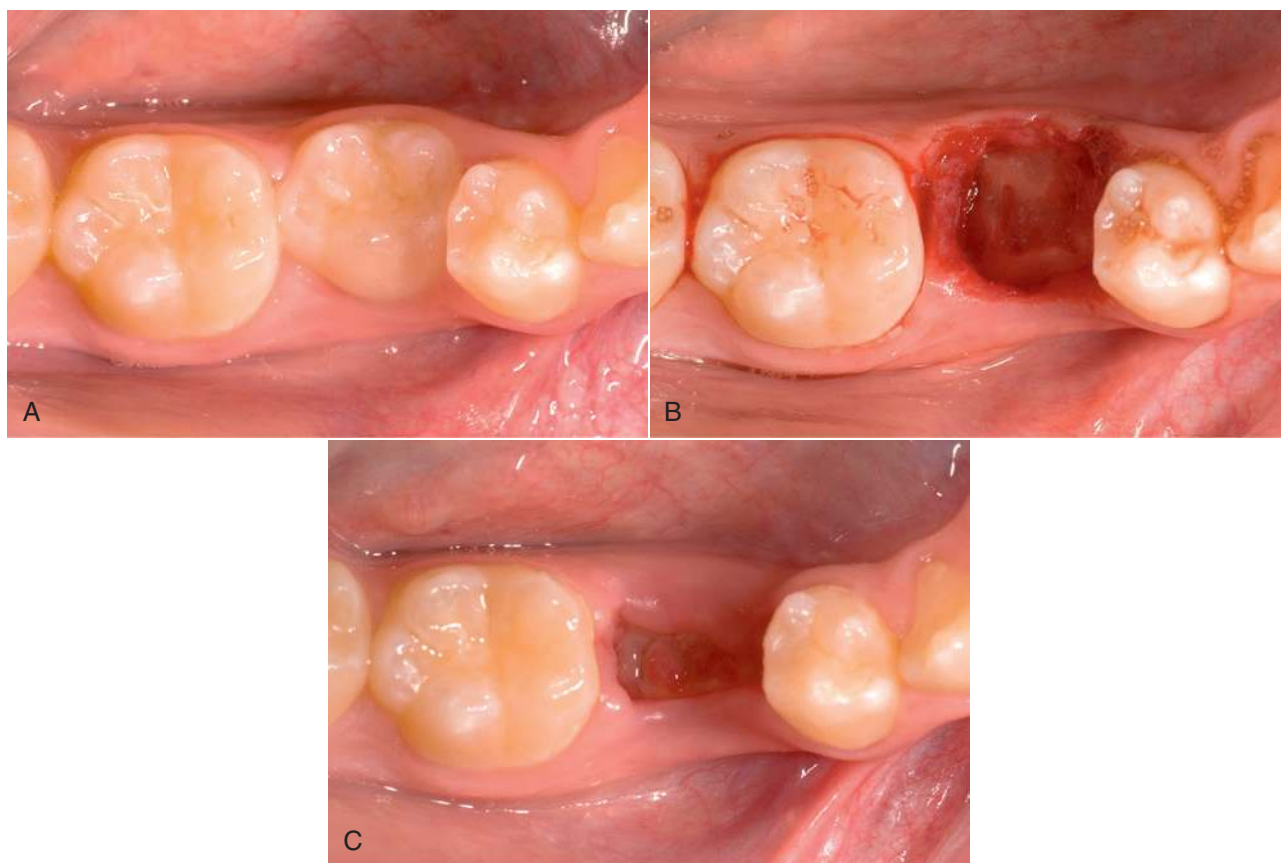
The goal should be to keep as many sensible options open as possible but to refrain from treatment when either the problem is too minor or later treatment obviously will be needed. The following section focuses on more complex space problems that require more expertise in diagnosis, treatment planning, and biomechanics in order to achieve a useful and timely treatment. These treatments must be truly beneficial to the patient in the long run to be justified.

## Excess Space

### Spacing of Permanent Teeth

In the absence of incisor protrusion, generalized excess space is not a frequent finding in the mixed dentition. It can result from either small teeth in normal-sized arches or normal-sized teeth in large arches. Unless the space presents an esthetic problem, it is reasonable to allow eruption of the remaining permanent teeth before closing the space with fixed appliances as part of comprehensive treatment (see Chapter 16). There is little or no advantage to early treatment unless it is for compelling esthetic reasons.<sup>20</sup>

A midline diastema often is a localized excess space problem (if not complicated by pathologic conditions, supernumerary teeth, or missing adjacent teeth). Tipping anterior teeth to close a small diastema was addressed in Chapter 11, but closing a large unesthetic diastema that may also be inhibiting eruption of adjacent teeth requires bodily repositioning of the central incisors to maintain



• **Fig. 12.10** When an ankylosed tooth without a successor, like this second primary molar, is retained and the aim is to maintain bone for a later implant, decoronation of the primary molar is a treatment option. (A) The primary molar before decoronation with a developing vertical discrepancy. (B) The crown removed 2 mm below the gingival level with all pulpal vital tissue removed, and (C) the tooth 1 week postoperatively.

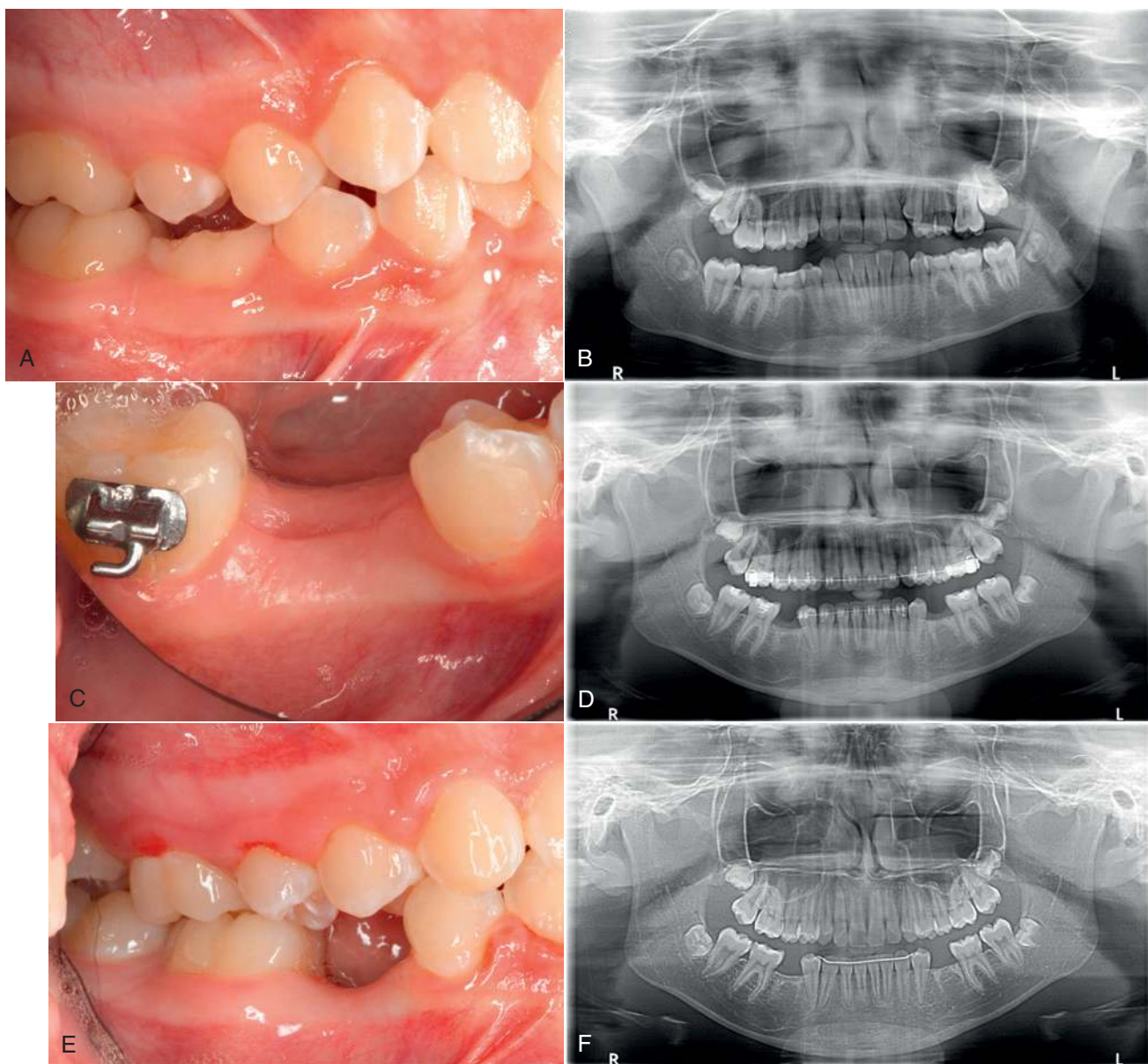
proper inclinations of the teeth. Mesial crown and root movement provides more space for the eruption of the lateral incisors and canines. When the situation demands bodily mesiodistal movement and no retraction of the teeth, an anterior segmental archwire from central to central incisor or a segmental archwire including more anterior teeth is needed. Initial alignment of the incisors with a flexible wire is required. Then a stiffer archwire can be employed as the teeth slide together (with 22-slot brackets, 18-mil round or 16- × 22-mil rectangular steel is a good choice; [Fig. 12.12](#)). The force to move the incisors together can be provided by an elastomeric chain. Diastema closure is more predictable if only mesiodistal movement is required. If protruding incisors are part of the problem and need to be retracted to close the space, then careful attention to the posterior anchorage, overbite, and type of needed incisor tooth movement (tipping versus bodily retraction) is required (see later).

In a few instances, multiple supernumerary teeth are located superficially, and uncomplicated extractions can be performed without interfering appreciably with the normal teeth. The guideline is that the more supernumeraries there are, the more abnormal their shape, and the higher their position, the harder it will be to manage the situation. Multiple abnormal supernumeraries are likely to have disturbed the position and eruption timing of the normal teeth before their discovery, and tubercle teeth are unlikely to erupt. Extractions should be completed as soon as the supernumerary

teeth can be removed without harming the developing normal teeth ([Fig. 12.13](#)). The surgeon may wish to delay extraction until continued growth has improved both access and the child's ability to tolerate surgery and until further root development has improved the prognosis for the teeth that will remain. This is reasonable, but the earlier the supernumeraries can be removed, the more likely that the normal teeth will erupt without further intervention. Conversely, the later the extractions, the more likely it is that the remaining unerupted normal teeth will need surgical exposure, orthodontic traction, or both to bring them into the arch. Usually banding and bonding multiple primary and permanent teeth will be required to close spacer and bodily reposition the permanent teeth so that the adjacent teeth can erupt in normal positions. This can involve more advanced biomechanics and rectangular wires for root torquing movements.

The experienced clinician's desire to close diastemas at an early age is tempered by knowledge of how difficult it can be to keep the space closed as the other permanent teeth erupt. If the lateral incisors and canines have not erupted when the diastema is closed, a removable retainer will require constant modification. If the overbite is not prohibitively deep, a better alternative approach for retention is to bond a 17.5-mil multistrand archwire to the linguocervical portion of the incisors ([Fig. 12.14](#)). This provides excellent retention with less maintenance. If the centrals and laterals have erupted, a removable appliance instead of a lingual bonded





• **Fig. 12.11** This patient had a vertical discrepancy developing with the ankylosed primary second molars without successors. (A) The preoperative intraoral and (B) panoramic radiographs. (C) The healed primary second molar decoronation site and (D) panoramic radiograph showing the extent of crown removal and retained root structure. (E) The postorthodontic intraoral view with the healed decoronation site and space for an implant. (F) Postorthodontic panoramic radiograph showing the maintained bone levels and root structure that will serve as the ultimate implant sites.

retainer is best. The removable appliance will allow the adjustment of the lateral incisal roots when the canines erupt along their distal root surfaces. A bonded retainer will not allow that and may potentially contribute to lateral incisor root resorption.

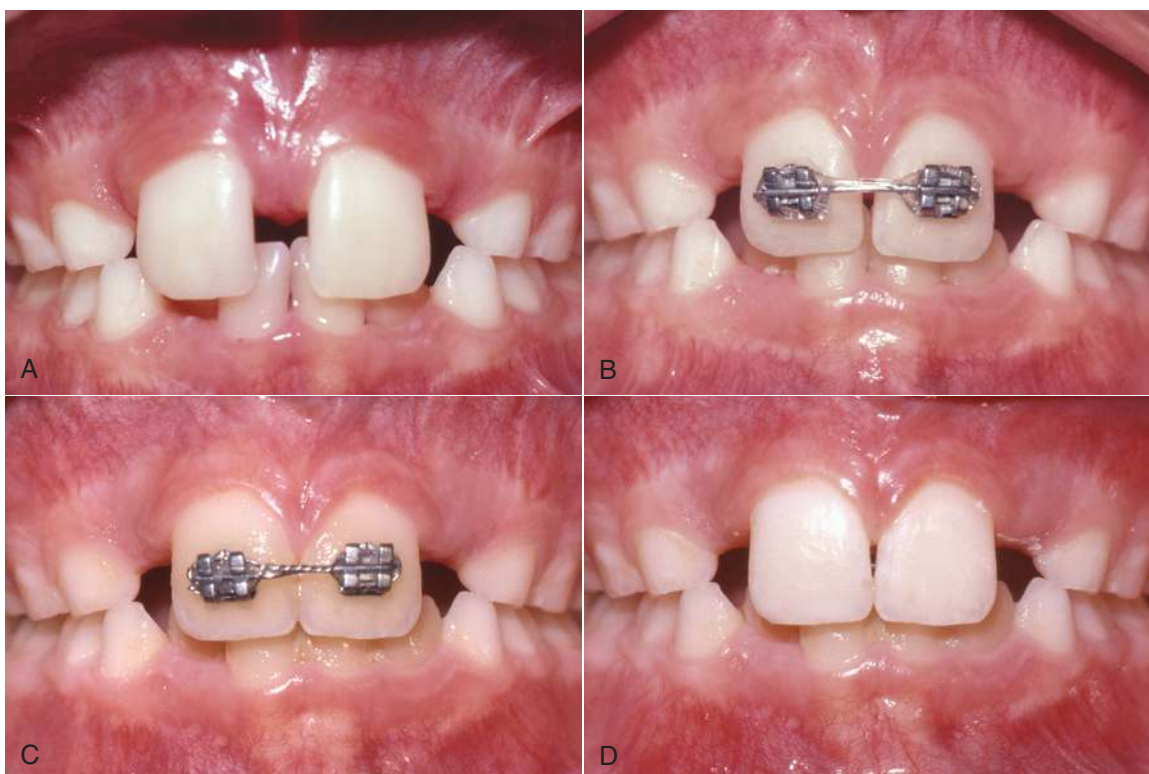
The difficulty in keeping a midline diastema closed is due primarily to failure of the gingival elastic fibers to cross the midline when a large diastema is present, but may be aggravated by the presence of a large or inferiorly attached labial frenum. A frenectomy after space closure and retention may be necessary in some cases, but it is difficult to determine the potential contribution of the frenum to retention problems from its pretreatment morphology. Therefore a frenectomy before treatment is contraindicated, and a posttreatment frenectomy should be done only

if unresolved bunching of tissue between the teeth shows that it is necessary.

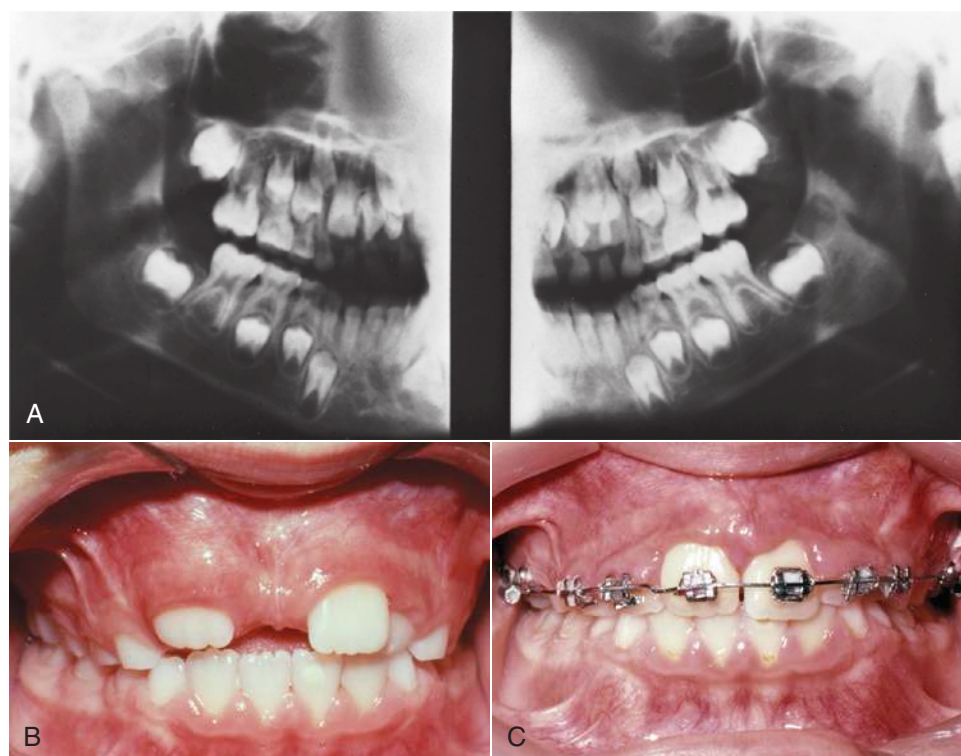
### Maxillary Dental Protrusion and Spacing

Treatment for maxillary dental protrusion during the early mixed dentition is indicated only when the maxillary incisors protrude with spaces between them and are esthetically objectionable or in danger of traumatic dental injury (TDI). When this occurs in a child who has no skeletal discrepancies, it is often a sequel to a prolonged finger-sucking habit. Eliminating the finger habit before tooth movement is necessary (see [Chapter 11](#)). The more common cause for maxillary incisor protrusion is a Class II malocclusion

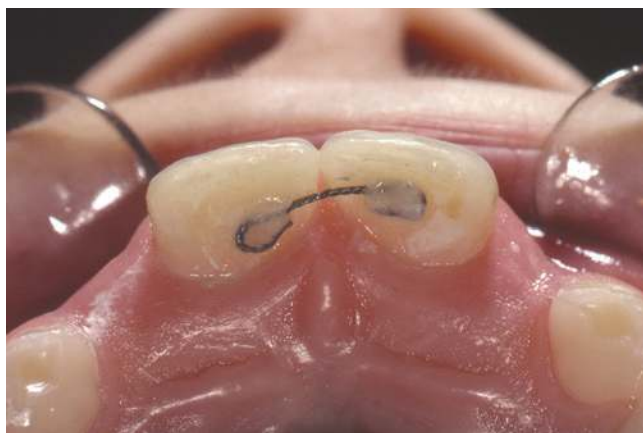



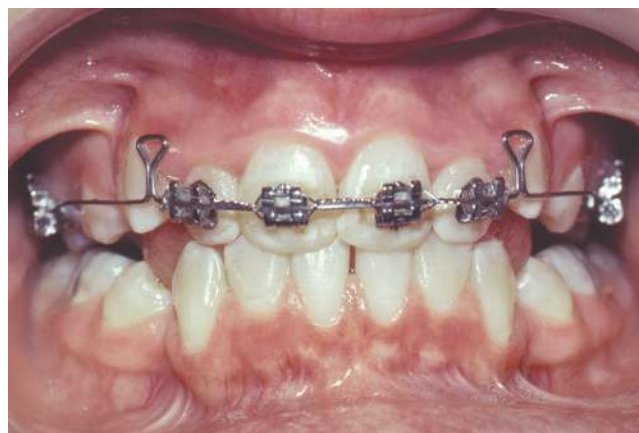• **Fig. 12.12** Closure of a diastema with a fixed appliance. (A) This diastema requires closure by moving the crowns and roots of the central incisors. (B) The bonded attachments and rectangular wire control the teeth in three planes of space while the elastomeric chain provides the force to slide the teeth along the wire. (C) Immediately after space closure, the teeth are retained, preferably with (D) a fixed lingual retainer (see Fig. 18.12), at least until the permanent canines erupt.



• **Fig. 12.13** Multiple supernumerary teeth in the anterior maxilla are often the cause of spacing and delayed eruption of anterior teeth. (A) This patient has an exceptionally wide diastema and delayed eruption of the maxillary lateral incisors. (B) The panoramic radiograph reveals three supernumeraries of various shapes and orientations. Conical and noninverted supernumeraries usually erupt, whereas tubercle-shaped and inverted ones do not. (C) The supernumeraries were removed, the diastema was closed, and the incisors were aligned with fixed appliances after they erupted.



• **Fig. 12.14** A fixed retainer to maintain diastema closure. A bonded 17.5-mil multistrand wire with loops bent into the ends is bonded to the lingual surfaces of anterior teeth to serve as a permanent retainer. This flexible wire allows physiologic mobility of the teeth and reduces bond failure but can be used only when the overbite is not excessive.



• **Fig. 12.15** This closing loop archwire was used to retract protrusive maxillary incisors and close space. Each loop was activated approximately 1 mm per month, and the posterior anchorage was reinforced with headgear.

that often has a skeletal component, and, in that case, treatment must address the larger problem (see [Chapter 14](#)).

There are relationships between malocclusion and TDI. It is clear that children with protruding teeth, increased overjet, incompetent lips, and a history of previous dental injury in the primary dentition or before age 9 in the permanent dentition are at risk for dental trauma.<sup>21–23</sup> Although it might seem this is a reason to treat many patients with Class II malocclusion early, this is not supported by longitudinal data and the benefits of early treatment.<sup>24</sup> This is especially true if we recognize that most TDIs are enamel and dentin fractures with moderate long-term sequelae, not periodontal injuries that have significant long-term consequences. Predicting who is most at risk for significant injury is not easy.

Early orthodontic treatment for those who have increased overjet, incompetent lips, and a history of permanent dentition TDI before age 9 years makes some sense if the treatment is limited to retraction of the incisors (not early Class II growth modification). This, combined with a good mouth guard for sports, can greatly reduce TDIs.

If there is adequate vertical clearance (not a deep bite) and space within the arch, maxillary incisors that are proclined or have been tipped facially by a sucking habit can be tipped lingually with a removable appliance as described in [Chapter 11](#). When the teeth require bodily movement or correction of rotations, a fixed appliance is required ([Fig. 12.15](#)). In these cases, an archwire should be used with bands on permanent first molars and bonded brackets on incisors. This appliance must provide a retracting and space-closing force, which can be obtained from closing loops incorporated into the archwire or from a section of elastomeric chain. To ensure bodily movement, a rectangular archwire must be used so that the crown and root movement are controlled (as described in [Chapter 9](#)), and undue tipping does not occur and leave the patient with upright or “rabbited” teeth. Bodily incisor retraction places a large strain on the posterior teeth, which tends to pull them forward. Depending on the amount of incisor retraction and space closure, a headgear or Nance appliance, with consideration for vertical facial and dental characteristics, may be necessary for supplemental anchorage support.

If the overbite is deep, it will bring the upper and lower incisors into vertical contact before the upper incisors can be retracted

enough to close spaces between them and eliminate the excess overjet. In some properly selected patients this can be addressed with a biteplate that allows eruption of posterior teeth and reduces the overbite, but it is rare that skeletal Class II malocclusion is not part of the total picture when excessive overjet and overbite both are present. This presents a much more complex treatment problem that requires skeletal change and most likely comprehensive orthodontic treatment.

## Missing Permanent Teeth

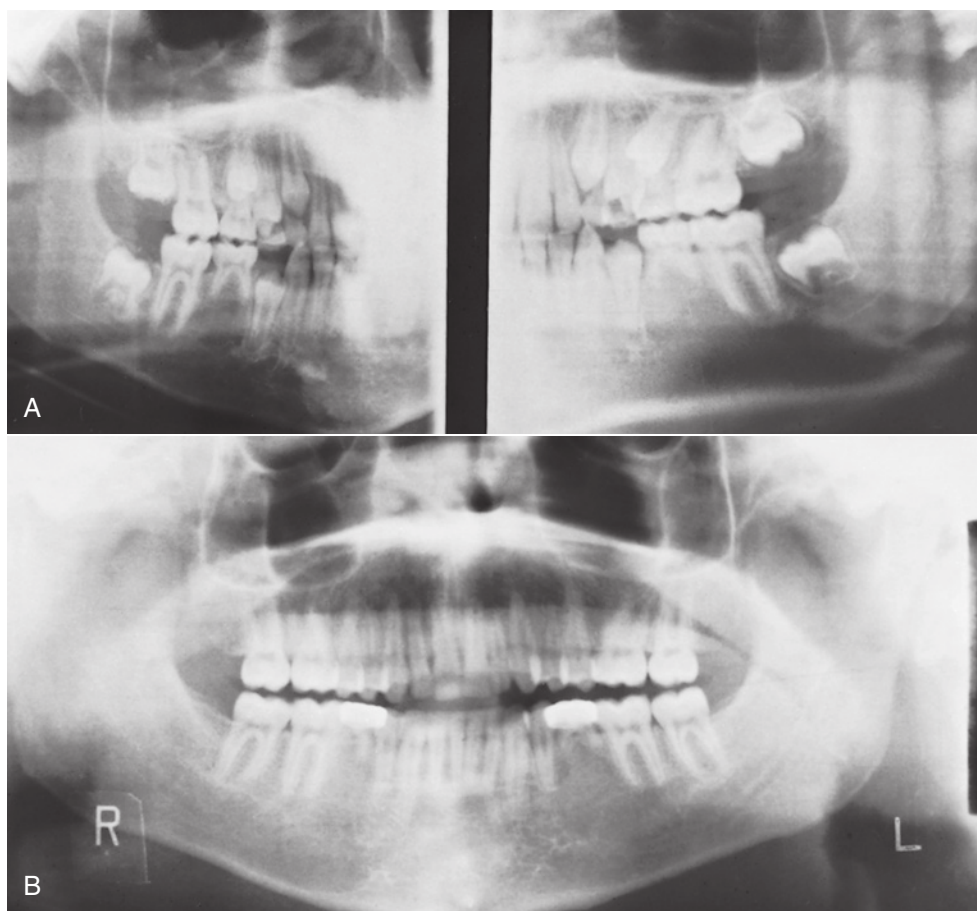
When permanent teeth are congenitally missing, a thorough evaluation of the patient must be performed to determine the correct treatment because any of the diagnostic variables of profile, incisor position, tooth color and shape, skeletal and dental development or position, and space availability or deficiency can be crucial in treatment planning. The most commonly missing permanent teeth are second premolars (especially mandibular) and maxillary lateral incisors. These two conditions pose different problems.

### Missing Second Premolars

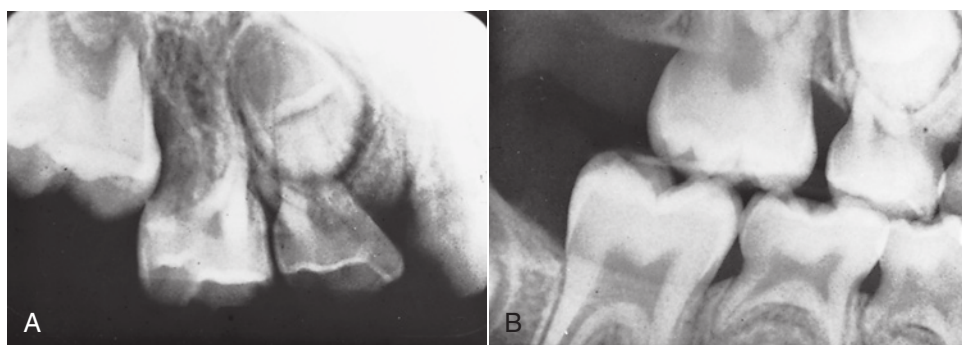
Second premolars have a tendency to form late and may be thought to be missing, only to be discovered to be forming at a subsequent visit. A premolar that begins formation very late is likely to be very late in erupting, and may be abnormal in other ways, so careful observation and caution are required. Good premolars seldom form after the child is 8 years of age.

If the patient has an acceptable occlusion, maintaining the primary second molars is a reasonable plan, because many can be retained at least until the patient reaches the early 20s or beyond ([Fig. 12.16](#)). Many reports exist of primary molars surviving until the patient is 40 to 60 years of age. Some reduction of their mesiodistal width often is needed to improve the interdigitation of the posterior teeth, but if this is done, there is a risk of resorption of the mesiodistal diverging roots of the primary molar when they contact the adjacent permanent tooth roots. Even if eventual replacement of the primary molar with an implant or bridge is required, keeping the primary molar as long as possible is an excellent way to maintain alveolar bone in that area.





• **Fig. 12.16** Primary mandibular second molars can be retained when the second premolars are missing. (A) This patient was identified before orthodontic treatment as having missing mandibular second premolars. (B) The decision was to retain the primary mandibular second molars because of the lack of crowding in the mandibular arch and their excellent root structure. These teeth were reduced mesiodistally and restored with stainless steel crowns during the finishing stages of orthodontic treatment to provide good occlusion.

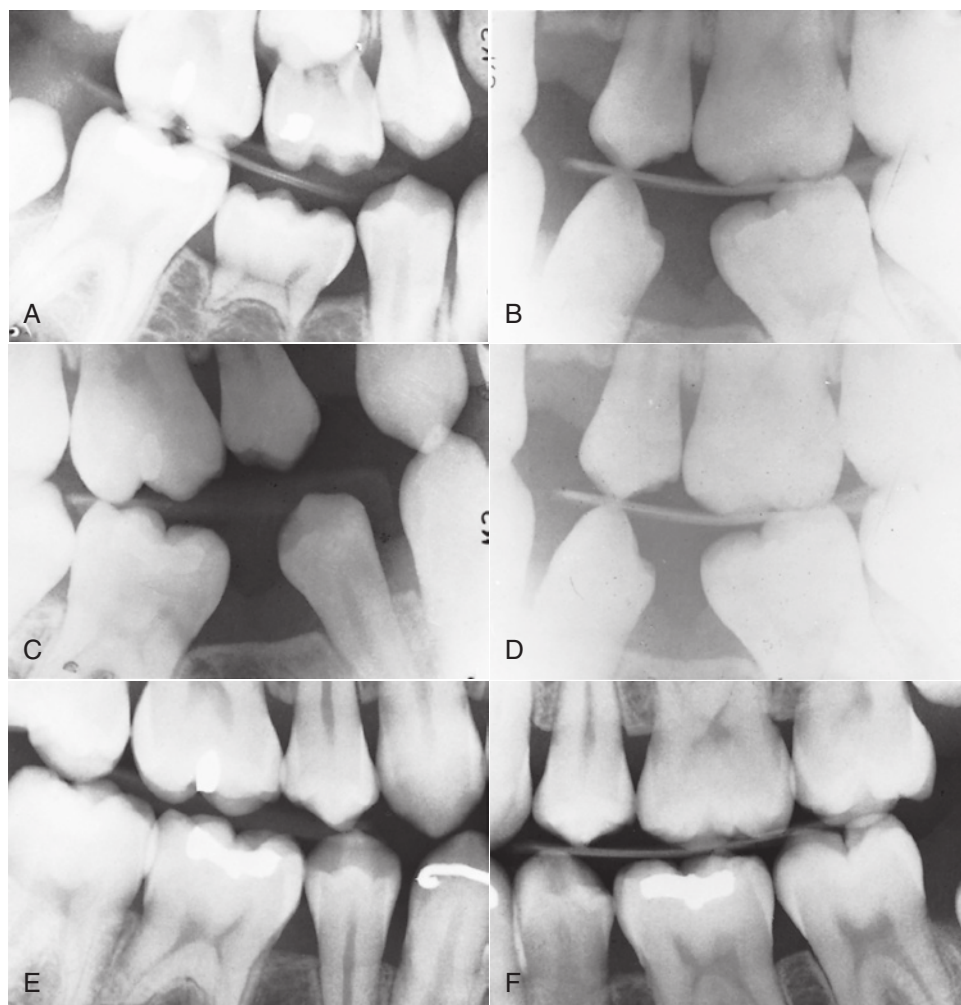


• **Fig. 12.17** Missing second premolars can be treated by extraction of primary second molars to allow drifting of the permanent teeth and spontaneous space closure. (A) This patient has ectopic eruption of the permanent maxillary first molar and a missing permanent maxillary second premolar. Since there was no other evidence of a malocclusion, the primary molar was extracted and (B) the permanent molar drifted anteriorly and closed the space during eruption. This eliminates the need for a prosthesis at a later date.

If the space, profile, and jaw relationships are good or somewhat protrusive, it can be advantageous to extract primary second molars that have no successor at age 7 to 9 and allow the first molars to drift mesially (Fig. 12.17). This can produce partial or even complete space closure. Unfortunately, the amount and

direction of mesial drift varies (Fig. 12.18). Unless the second premolars are missing in all quadrants, it may be necessary to extract teeth in the opposing arch to reach a near-ideal Class I occlusion. Otherwise, space closure will result in a Class II or Class III molar relationship. The molar relationship itself is not a





• **Fig. 12.18** (A) and (B) In this patient with bilaterally missing permanent mandibular second premolars, the decision was made to extract the retained primary molars to allow as much spontaneous drift and space closure as possible before full appliance therapy. (C) and (D) Although posterior teeth did drift anteriorly and the anterior teeth distally, the space did not completely close. The pattern of drift to close the space of congenitally missing mandibular second premolars is highly variable and unpredictable. (E) and (F) The residual space was closed and the roots paralleled with full appliances.

problem, but later overeruption of unopposed second molars may become one.

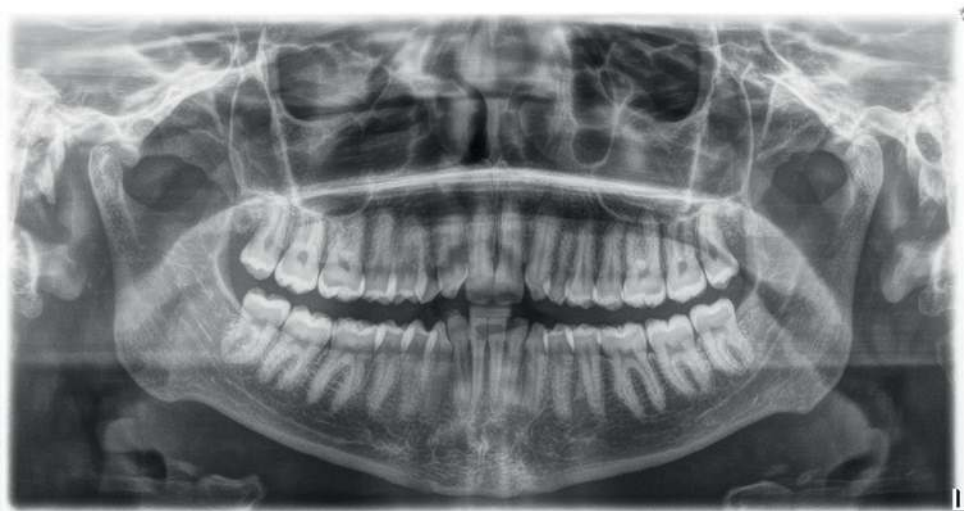Early extraction can reduce the treatment time when the space of missing second premolars is to be closed, but later comprehensive orthodontic treatment usually is needed. If only one primary molar is missing, unless there has been true unilateral space loss or there is considerable crowding on the contralateral side, restorative rather than conventional orthodontic resolution of the problem is usually indicated. It is nearly impossible to close space unilaterally in the mixed dentition without affecting the midlines and other anterior interarch relationships. Remember that temporary anchorage devices (TADs) to facilitate unilateral space closure are not indicated before about 12 years of age because of bone density, so unilateral space closure would have to be reserved for a later time period.

Another solution to missing second premolars is to combine hemisectioning of the primary tooth and pulp therapy so that the first permanent molar is protracted into the primary molar space without loss of alveolar bone from a more long-standing extraction. This treatment is described in more detail in [Chapter 16](#).

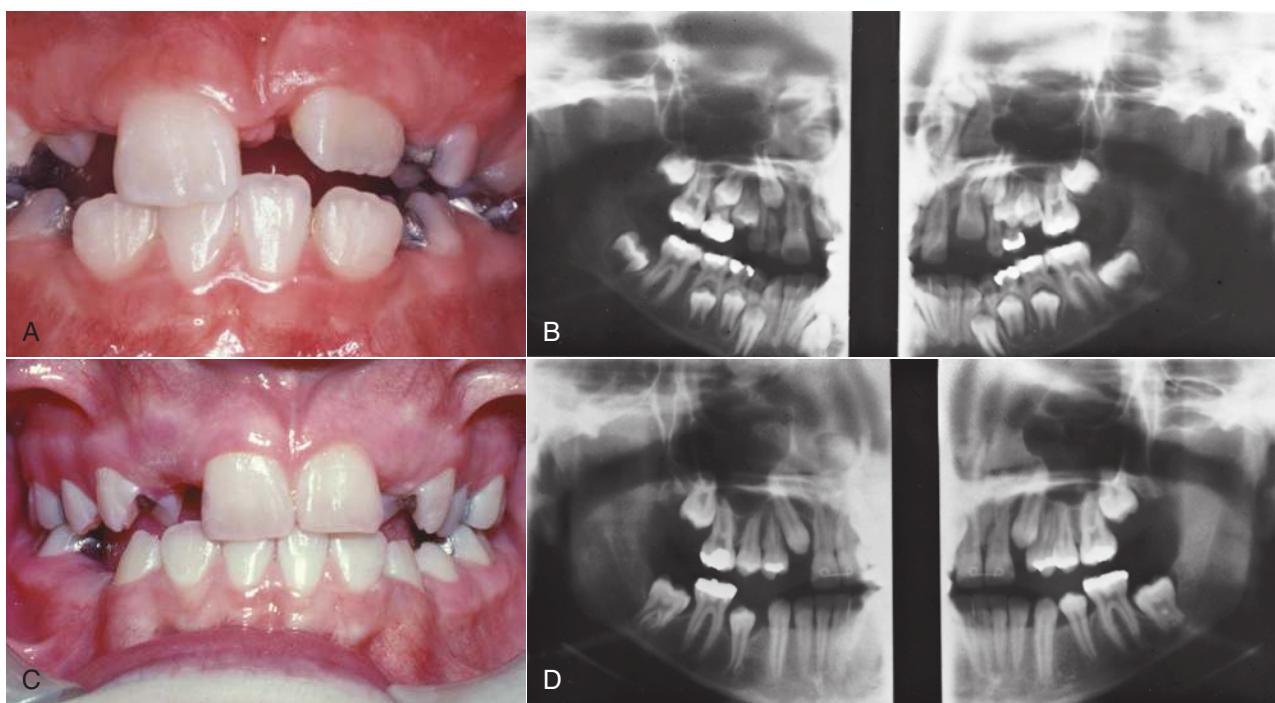
### Missing Maxillary Lateral Incisors

Long-term retention of primary laterals, in contrast to primary molars, is almost never an acceptable plan. When the lateral incisors are missing, there are two possible sequelae. In some patients, the erupting permanent canine resorbs the primary lateral incisor and spontaneously substitutes for the missing lateral incisor, which means that the primary canine has no successor and is sometimes retained ([Fig. 12.19](#)). This is seen occasionally in adults, but most primary canines are lost by the end of adolescence even if they were retained after their successors erupted mesially into the lateral incisor space. Less often, the primary lateral is retained when the permanent canine erupts in its normal position. This usually means that the lateral incisor space is reduced to the size of the primary lateral incisor and the remaining primary incisor is unesthetic.

Having the permanent canine erupt in the position of a congenitally missing lateral incisor is advantageous, whether or not the ultimate treatment is substitution of the canine for the lateral or opening space for a prosthetic lateral replacement, because its eruption in that area generates the formation of alveolar bone. In



• **Fig. 12.19** Missing permanent maxillary lateral incisors are often replaced spontaneously by permanent canines. This phenomenon occurs without intervention, but the resorption noted on the retained primary canines probably will continue to progress. If implants to eventually replace the missing laterals are planned, it is desirable for the canines to erupt mesially so that alveolar bone forms in the area of the future implant. The canines can be moved into their final position just before the implant surgery. (Courtesy Dr. M. Larson.)

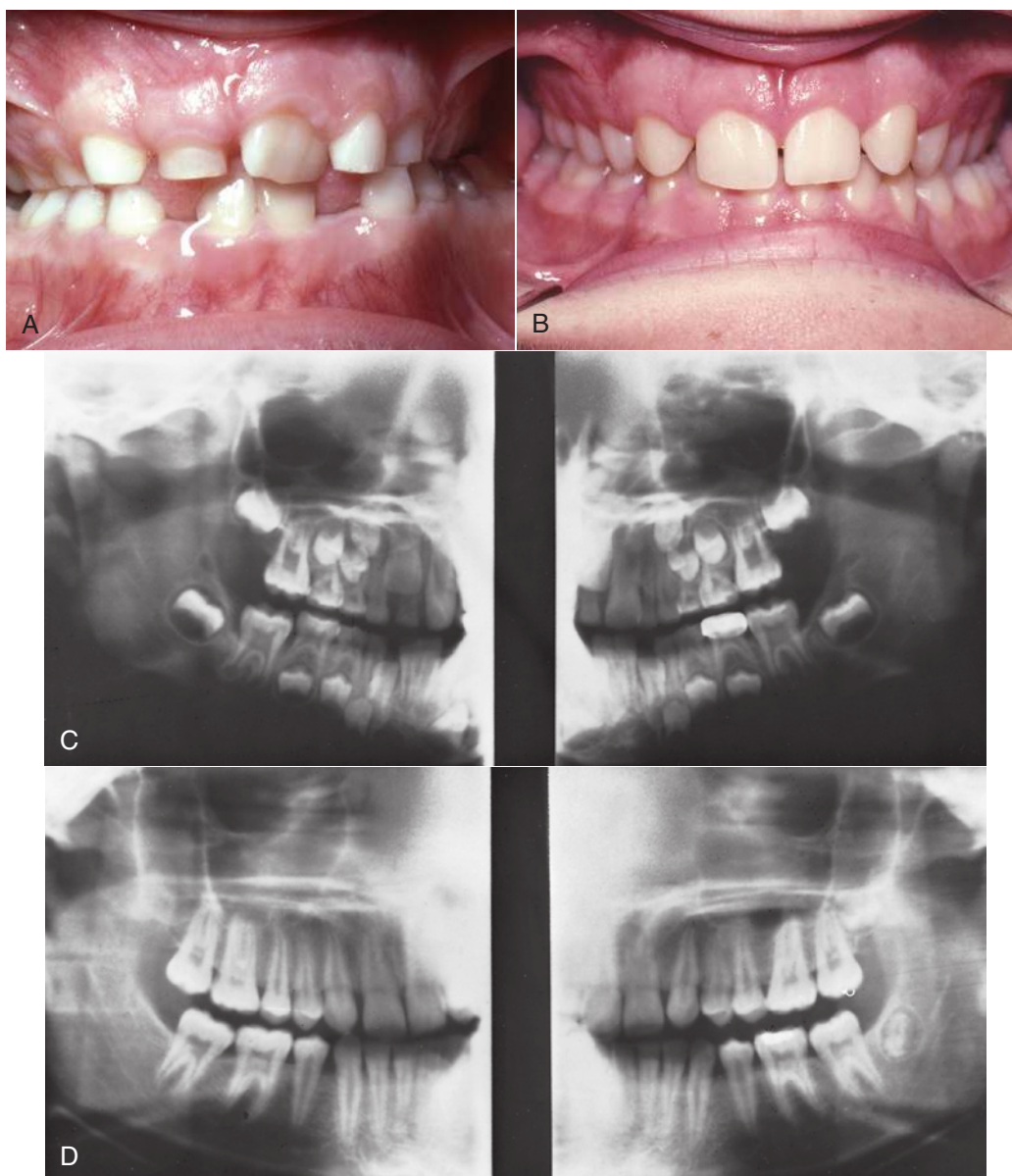


• **Fig. 12.20** When permanent lateral incisors are congenitally missing, often a large diastema develops between the permanent central incisors. (A) This patient has that type of diastema, and the unerupted permanent canines will be substituted for the missing lateral incisors. (B) This radiograph shows the unerupted canines in an excellent position for substitution for the lateral incisors. (C) The diastema has been closed to obtain maximum mesial drift of the canines. (D) This technique enables the canines to erupt closer to their final position and eliminates unnecessary tooth movement during full appliance therapy.

addition, the canine shape and color can be determined, which may have some influence on whether they are retracted and implants placed or substituted for the lateral incisors. Both solutions require comprehensive orthodontic treatment in adolescence, and this also is discussed in more detail in [Chapter 16](#).

If space closure is the goal and the primary lateral incisors are replaced by the permanent canines as they erupt, little immediate

attention in the mixed dentition is necessary. Sometimes the absence of lateral incisors causes a large diastema to develop between the permanent central incisors. To maximize mesial drift of the erupting permanent canines, this diastema can be closed and retained ([Fig. 12.20](#)). Later in the transition to the permanent dentition, the primary canines should be extracted if they are not resorbing, so that some spontaneous closure of the canine space can occur



• **Fig. 12.21** Selective removal of primary teeth when permanent maxillary lateral incisors are missing can lead to a shortened second phase of fully banded treatment. (A) and (B) This patient had primary canines and primary first molars extracted to maximize the mesial drift of the permanent posterior teeth. (C) and (D) This intervention resulted in good tooth position that will require little fixed appliance therapy to complete.

(Fig. 12.21). This space closure option is best when the incisors are slightly protrusive and the molars are tending toward Class II in the posterior so that reciprocal space closure can be employed between the anterior and posterior teeth. Space closure is usually avoided when the patients have a Class III tendency, because of the possibility of inadvertently creating an anterior crossbite. Once again, TADs can help in these less than ideal situations. These are intricacies of comprehensive treatment.

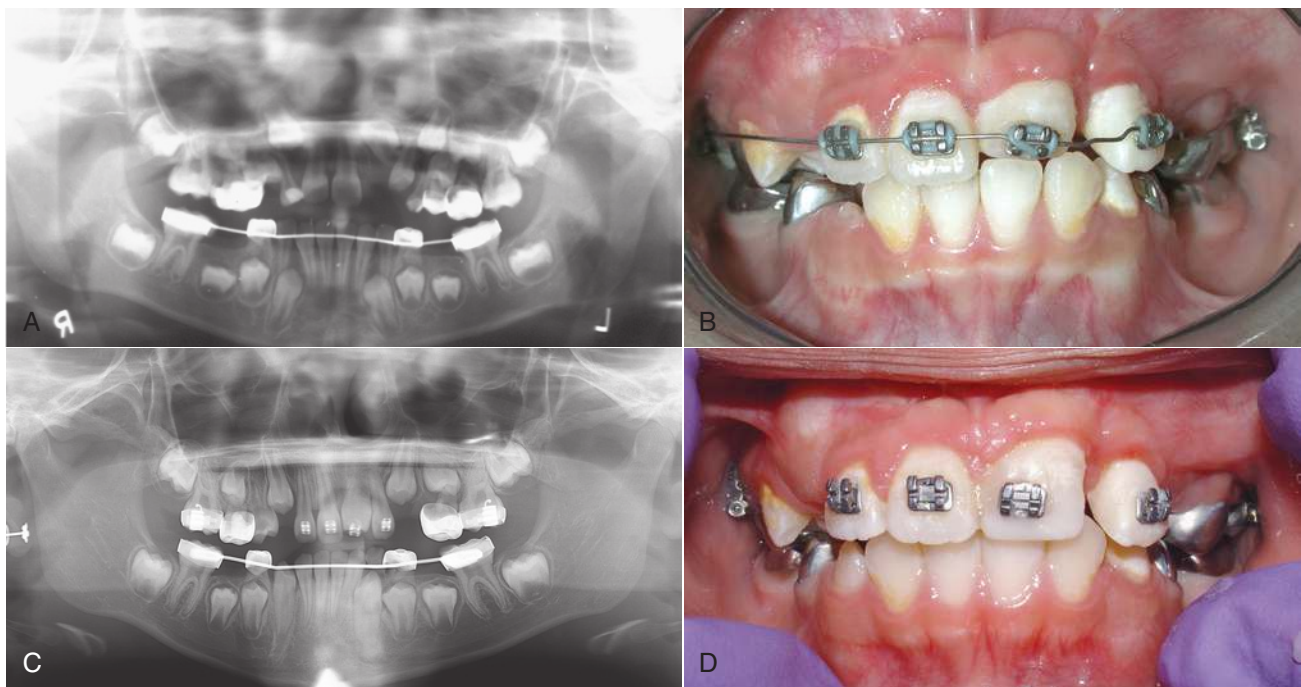
### Autotransplantation

In patients with a congenitally missing tooth or teeth in one area but crowding in another, autotransplantation is a possible solution. Teeth can be transplanted from one position to another in the same mouth with a good prognosis for long-term success, if this

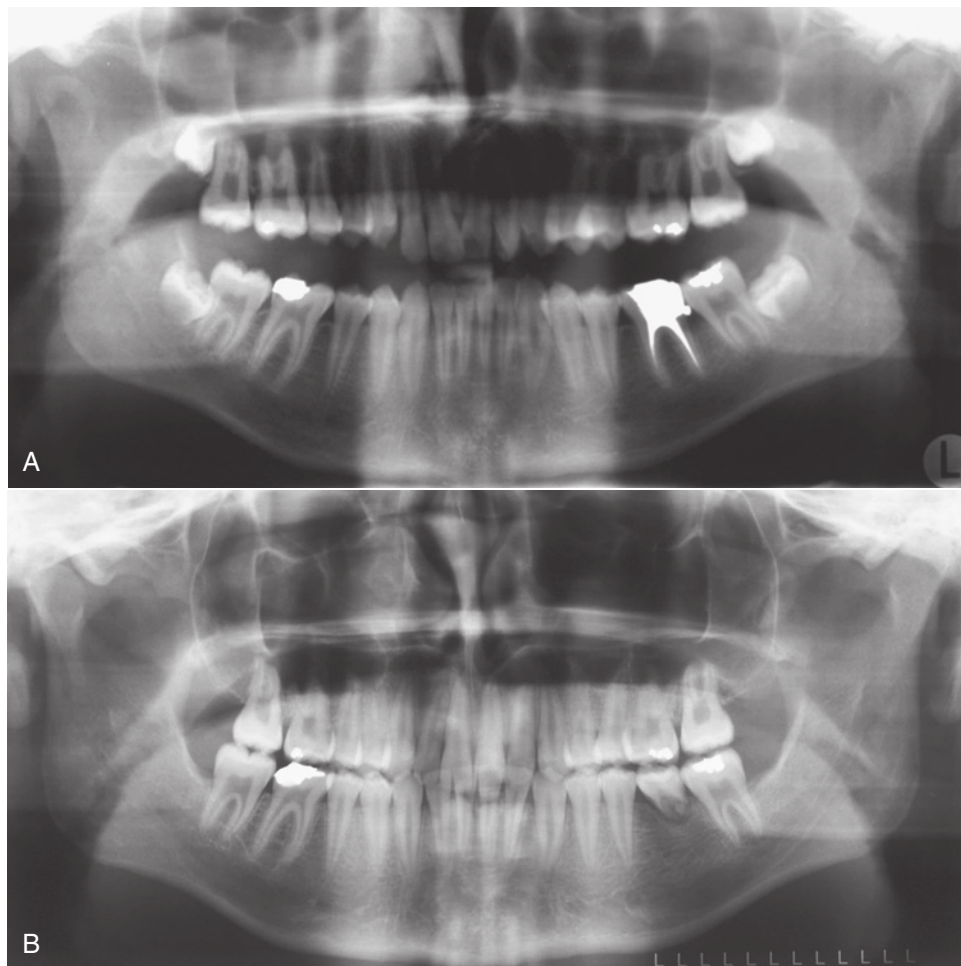
is done when the transplanted tooth has approximately two-thirds to three-fourths of its root formed. This means that the decision for autotransplantation must be made during the mixed dentition (Fig. 12.22).

Transplantation is most commonly used to move premolars into the location of missing maxillary incisors. For replacement of a maxillary lateral incisor, the mandibular first premolar has the best crown and root form and often is preferred if it is available.<sup>25</sup> Autotransplantation also can be used to replace missing first molars with third molars, a decision that can be made a little later (Fig. 12.23).<sup>26</sup> A combination of careful surgical intervention and positioning of the transplant, 3 months of healing, followed by light orthodontic forces to achieve final tooth position, and restorative treatment to recontour the crown of the transplanted





• **Fig. 12.22** (A) This patient has an unerupted permanent maxillary left central incisor with a dilacerated root, possibly due to previous trauma. It was determined that it could not be repositioned surgically or moved orthodontically. (B) To relieve crowding, premolar extraction was indicated, and the maxillary left first premolar was transplanted to the maxillary left central incisor position and moved after a short healing period. (C) Root development and healing have continued and indicate a vital tooth. (D) The tooth will continue to be recontoured and restored with resin before definitive restorative treatment.



• **Fig. 12.23** (A) The mandibular permanent first molar was restoratively compromised. With the developing third molar in the maxillary left quadrant available (B), it was decided to transplant it into the first molar position when the root development was appropriate, rather than plan a restoration for the first molar. The transplanted third molar was subsequently repositioned during orthodontic treatment and served well as a replacement.

tooth can result in long-term functional and esthetic success. The success rate with this type of treatment is high and predictable.

### Localized Moderate-to-Severe Crowding

In some children, there is moderate-to-severe localized crowding ( $>3$  mm). In a posterior quadrant of the dental arches, this is most likely the result of severe space loss after early loss of a primary molar or ectopic eruption. Typically this prevents eruption of a succedaneous tooth, usually a second premolar.

If there is enough space in other areas of the dental arches and no indication that comprehensive orthodontics will be needed in the near future, it is often sensible to extract the impacted tooth and close the space. This typically takes less time than regaining space and encouraging eruption of the impacted tooth or teeth. If space regaining is the goal after careful weighing of the options, the biomechanical issues are sizable and include unilateral space opening without disruption of the rest of the arch or occlusion. Sometimes the space loss may be bilateral. Distal molar movement is often part of the equations for correction of the problem. Reciprocal forces, which are the easiest and most predictable for orthodontics, cannot be employed. These types of treatment are covered later in this chapter under distal molar movement.

In the anterior portion of the arch, the most common localized problem of this type is a shift of the mandibular dental midline. Tooth movement is more often used to solve this problem than simple single tooth extraction. If the midline has moved and no

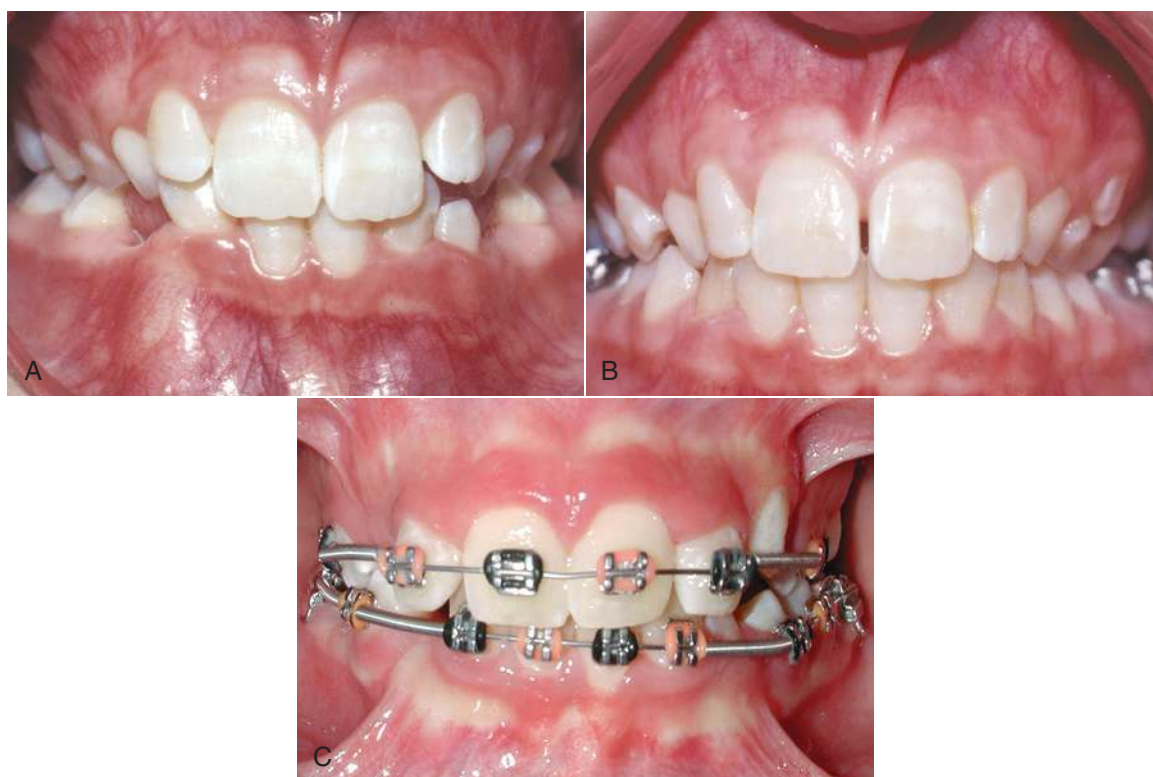permanent teeth will be extracted, midline correction is needed before the remaining permanent teeth erupt in asymmetric positions and localized crowding becomes worse. If the midline has moved and the space is inadequate, both the space and midline problems need to be addressed before the canines erupt. This is most successfully accomplished by using a supportive lingual arch to maintain molar symmetry and control, bonding of the incisors, and correction of the midline with a coil spring (Fig. 12.24). In some cases, disking or extraction of a primary canine or molar will be required to provide the necessary room to reestablish the midlines and space. A lingual arch can then be used as a retainer to maintain the correction.

If both mandibular primary canines are lost and the permanent incisors tip lingually, which reduces the arch circumference and increases the apparent crowding, an active lingual arch to tip them facially may be indicated. In some of these children, however, space analysis will reveal that the crowding would still be severe enough after the incisors are repositioned to require comprehensive treatment later. If so, the expansion lingual arch would be optional.

### Generalized Moderate and Severe Crowding

#### *Expansion Versus Extraction in Mixed Dentition Treatment*

For children with a moderate space deficiency, usually there is generalized but not severe crowding of the incisors, but sometimes the primary canines are lost as the lateral incisors



• **Fig. 12.24** Some midline shifts require bodily tooth movement. (A) The midline of the mandibular arch has bodily shifted to the patient's right because of premature loss of a primary canine. (B) The teeth were moved back to their proper position by using a fixed appliance and are supported until eruption of the canines with a lingual holding arch. (C) This type of movement is best achieved with an archwire and coil springs to generate the tooth moving forces. Active coil springs can be replaced with passive coils to gain stability prior to retention.



erupt, and the severe crowding that will develop goes largely unrecognized. Children with the largest arch length discrepancies often have reasonably well-aligned incisors in the early mixed dentition because both primary canines were lost when the lateral incisors erupted.

Potentially severe crowding usually is obvious in the primary dentition, even before a space analysis can be completed. These children have little developmental spacing between primary incisors and occasionally some crowding in the primary dentition. The two major symptoms of severe crowding in the early mixed dentition are severe irregularity of the erupting permanent incisors and early loss of primary canines caused by eruption of the permanent lateral incisors. After a definitive analysis of the profile and incisor position, these patients face the same decisions as those with moderate crowding: whether to expand the arches or extract permanent teeth and when this should be done (see [Chapter 7](#) for a review of factors influencing this decision). In the presence of severe crowding, limited mixed dentition treatment will not be sufficient and extraction has to be considered.

### Expansion for Treatment of Crowding in the Early Mixed Dentition

For most children with crowding and inadequate space in the early mixed dentition, some facial movement of the incisors and expansion can be accommodated, especially if:

- The lower incisor position is normal or somewhat retrusive.
- Lips are normal or retrusive.
- Overjet is adequate.
- Overbite is not excessive.
- There is good keratinized tissue facial to the lower incisors.

If facial movement is anticipated and the amount and quality of gingival tissue is questionable, a periodontal consultation regarding a gingival graft is appropriate. Surgical or nonsurgical management of the soft tissue may be required before or following tooth movement.

A key question is whether early expansion of the arches (before all permanent teeth erupt) gives more stable results than later expansion (in the early permanent dentition). Partly in response to the realization that recurrent crowding occurs in many patients who were treated with premolar extractions (see [Chapter 7](#)), early arch expansion recently has gained some popularity in spite of a lack of data to document its effectiveness. This early expansion can involve any combination of several possibilities:

- Maxillary dental or skeletal expansion, moving the teeth facially and/or opening the midpalatal suture
- Mandibular buccal segment expansion by facial movement of the teeth
- Advancement of the incisors and distal movement of the molars in either arch

The most aggressive approach to early expansion, in terms of timing, uses maxillary and mandibular lingual arches in the complete primary dentition. This produces an increase in both arch perimeter and width, which must be maintained for variable periods during the mixed dentition years. The ability of expansion in the primary dentition to meet the challenge of anterior crowding is highly questionable and unsubstantiated.<sup>27</sup>

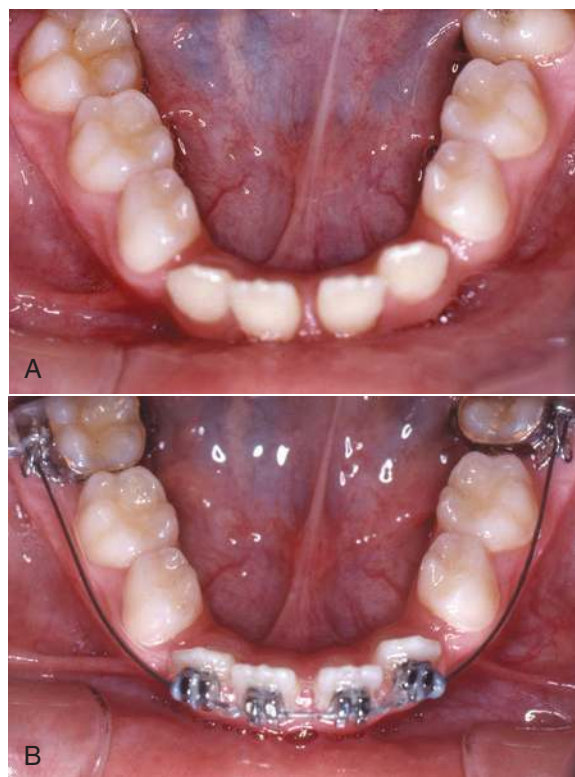
A sensible approach to moderate crowding in the early mixed dentition is to perform a space analysis when the incisors erupt and then begin to work toward arch expansion or extraction with the eruption of the remaining permanent teeth (canines and premolars). Long-term holding of inadequate space is hard on the teeth and soft tissues and is not merited.

To execute the expansion decision, placing a lingual arch after the extraction of the primary canines and ultimately using the lingual arch or another appliance to increase the arch length is a solution. Alternatively, timely extractions can be done.

Clinical experience indicates that a considerable degree of faciolingual irregularity will resolve if space is available, but rotational irregularity will not. If the incisors are rotated, severely irregular, or spaced, and early correction is felt to be important, a fixed appliance will be needed for treatment, either in the mixed or early permanent dentition ([Fig. 12.25](#)).

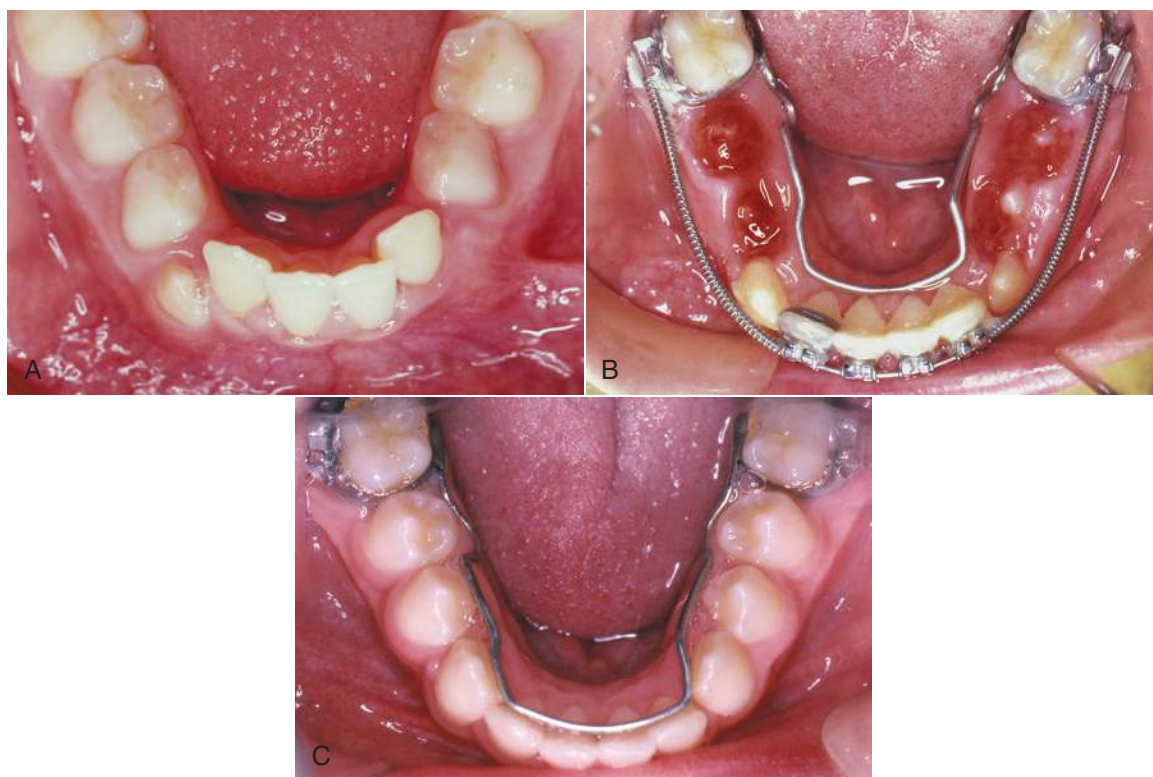
Lower incisor teeth usually can be tipped 1 to 2 mm facially without much difficulty, which creates up to 4 mm of additional arch length, but only if overbite is not excessive and overjet is adequate. To create substantial space and control the tooth movement, it is best to band the permanent molars, bond brackets on the incisors, and use a compressed coil spring on a labial archwire to gain the additional space ([Fig. 12.26](#)). The multiple band and bond technique is usually followed with a lingual arch for retention. The advantage of the bonded and banded appliance is to provide rotational and mesiodistal space control and bodily movement if necessary. Some expansion of the buccal segments can be included in addition to incisor movement.

A somewhat more aggressive approach is to expand the upper arch transversely in the early mixed dentition, not to correct posterior crossbite but specifically to gain more space in the dental arch. This is accomplished by using a lingual arch or jackscrew expander to produce dental and skeletal changes ([Fig. 12.27](#)), but jackscrew

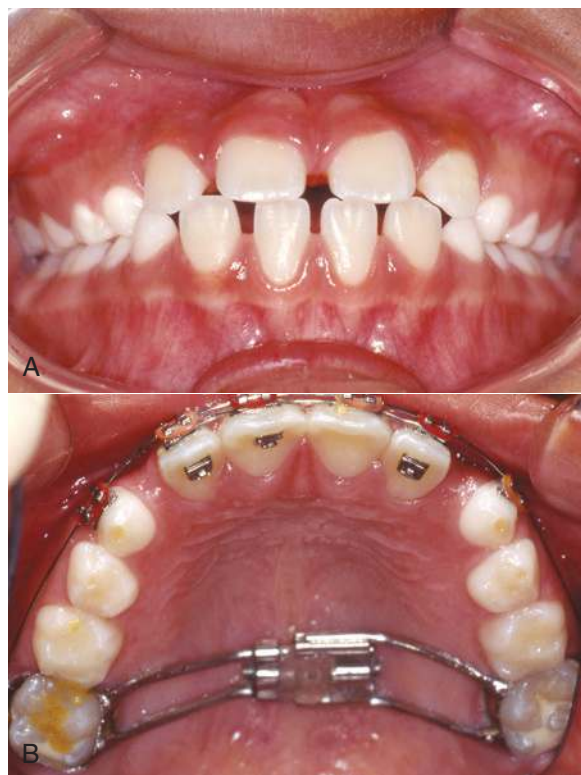

• **Fig. 12.25** (A) In this patient who had lower anterior teeth that were lingually tipped and spaced, lower arch expansion with a fixed appliance was required because the spacing could not be adequately controlled with a lingual arch or lip bumper. (B) The fixed appliance in place during alignment and before space closure in the incisor area. After space closure, the incisors can be further proclined if necessary.





• **Fig. 12.26** Moderate arch-length increases can be accomplished by using a multiple bonded and banded appliance and a mechanism for expansion. (A) This patient has moderate lower arch irregularity and space shortage. (B) The appliance is in place with the tooth movement completed. In this case, coil springs served to generate the tooth moving force, but other methods using loops and flexible archwires are available. Note the lingual arch used to control transverse molar dimensions. (C) The lingual arch is adjusted by opening the loops and advancing the arch so it can serve as a retainer following removal of the archwire and bonded brackets.



• **Fig. 12.27** (A) and (B) Some practitioners advocate early expansion by opening the midpalatal suture, usually using a jackscrew-type appliance as in this patient, even in the absence of a posterior crossbite or an apparent arch length shortage, on the theory that this will improve the long-term stability of arch expansion. Little or no data exist to support this contention.

expansion must be done carefully and slowly if it is used in the early mixed dentition. The theory is that this would ensure more space at a later time.<sup>28</sup> To date, there is no credible long-term postretention evidence that early intervention to “prepare,” “develop,” “balance,” or expand arches by any other name has any efficacy in providing a less crowded permanent dentition later. Unfortunately, even in children who had mild crowding initially, incisor irregularity can recur soon after early treatment if retention is not managed carefully. Parents and patients should know the issues and uncertainties associated with this type of treatment.

It has been suggested that this type of early expansion not only provides more space and better esthetics, but also can reduce occlusal disharmonies between the arches that are present in Class II malocclusions.<sup>29</sup> Data supporting the long-term effectiveness of this technique are unavailable. It seems unlikely that the soft tissues, which establish the limits for arch expansion, would react quite differently to transverse expansion at different ages (see

the discussion of equilibrium influences in Chapter 5) or that jaw growth in other planes of space would be greatly affected by transverse expansion.

### **Expansion for Crowding in the Late Mixed Dentition: Molar Distalization**

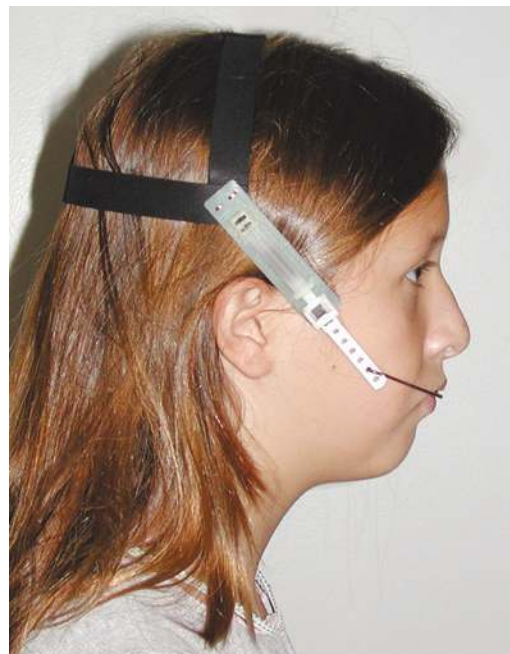Transverse expansion to gain additional space can be used in the late as well as the early mixed dentition, and the previous comments also apply to the late mixed dentition. An additional approach in the late mixed dentition is to obtain additional space by repositioning molars distally. Unless TADs are used, which is not recommended before age 12 because of inadequate bone density, intraoral appliances for distal molar movement will be accompanied by facial incisor movement. With this knowledge, there are some indications for this type of treatment:

- Less than 4 to 5 mm of space per side, with some tipping of the molars acceptable.
- Erupted maxillary anterior teeth and ideally, first premolars for anchorage.
- Normal or retrusive lip and maxillary dental position, because about one-third of the movement will be experienced as facial incisor movement.
- Likewise, overjet should be limited.
- The vertical facial dimensions should be normal or with a short-face tendency because the distal movement of the molars can open the bite.
- Similarly, the overbite should be somewhat greater than normal owing to the bite opening mechanics.

Until relatively recently, headgear to move maxillary molars distally was the preferred approach. It has the advantage of simplicity and the major disadvantage that good patient compliance is needed. To tip or bodily move molars distally, extraoral force via a facebow to the molars is a straightforward method. The force is directed specifically to the teeth that need to be moved, and reciprocal forces are not distributed on the other teeth (the incisors) that are in the correct positions. The force should be as nearly constant as possible to provide effective tooth movement and should be moderate because it is concentrated against only two teeth. The more the child wears the headgear, the better; 12 to 14 hours per day is minimal. Approximately 400 gm of force per side is appropriate but not particularly friendly to the teeth. The teeth should move at the rate of 1 mm per month, so a cooperative child would need to wear the appliance for 3 to 5 months to obtain the 3 mm of correction that would be a typical requirement in this type of treatment with good cooperation.

For the short-term duration of this type of treatment, either cervical or high-pull headgear can be chosen, but high-pull headgear is an excellent option (Fig. 12.28). Baumrind et al reported that this approach is particularly effective in producing distal molar movement.<sup>30</sup>

If bodily distal movement of one or both permanent maxillary first molars is needed to adjust molar relationships and gain space, if there are adequate anterior teeth for anchorage, if some anterior incisor movement can be tolerated, and if the overbite is adequate, several other appliances can be considered. All are built around the use of a heavy lingual arch, usually with an acrylic pad against the anterior palate to provide anchorage (Fig. 12.29). Often, the anterior teeth also are bonded and stabilized with an archwire. Then a force to move the molar distally is generated by a palate-covering appliance with helical springs (the pendulum appliance), steel or superelastic coil springs, or other device (see Fig. 16.19).<sup>31</sup>



• **Fig. 12.28** A high-pull headgear has been demonstrated to be the most effective extraoral appliance to move molars distally. Of course, compliance is required, but no reciprocal incisor protrusion occurs.

In the mandibular arch, appliances that change arch dimensions (not passive lingual holding arches to hold the dimensions) can cause problems with lower second molar eruption.<sup>32</sup> Erupted upper second molars make distalization of the first molars even more difficult, and use of a fixed appliance to bring the lower incisors forward may be more acceptable (Fig. 12.30).

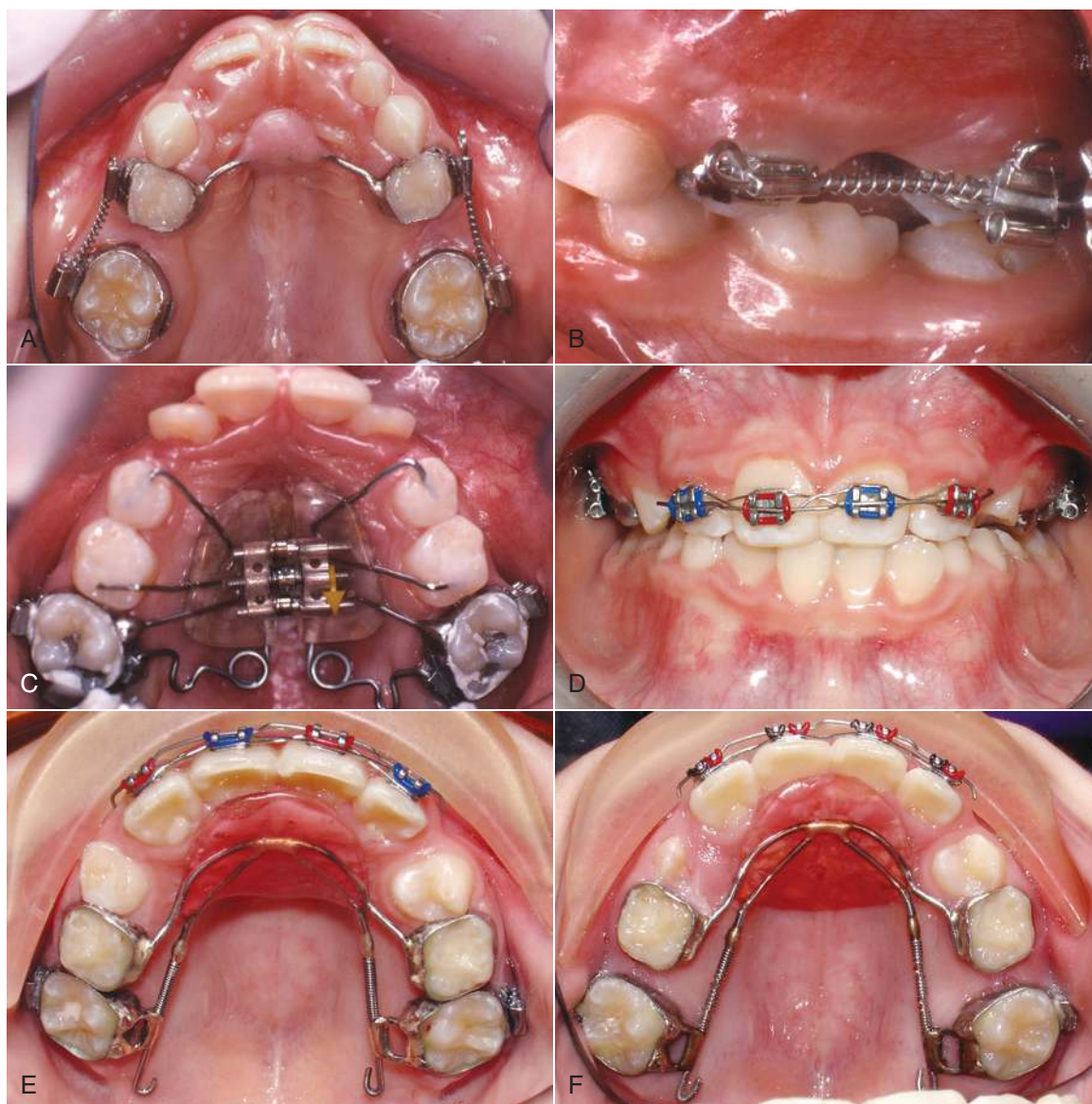
The primary method now for distalization of molars, which can be used with children 12 years of age and older, is the use of TAD-supported molar-distalizing appliances (Fig. 12.31).<sup>33</sup> These appliances can distalize molars in both arches without creating forward movement of the incisors because of the nearly absolute anchorage. There are three major limitations to this approach: (1) the surgery to place and remove the TADs, which is quite acceptable to patients but can have complications, (2) the long duration of treatment to move and retain the teeth from the mixed dentition through the eruption of the permanent teeth, which is not shorter with TADs, and (3) the uncertain stability of the long-term result. The question is not whether the tooth movement is possible—it is. Rather, the question is the wisdom of major expansion of the arches or distal movement, especially in the mixed dentition.

No matter how molars were moved distally, if the time before eruption of the premolars will be longer than a few months, it will be necessary to hold them back after they are repositioned. Maxillary and mandibular lingual arch space maintainers (see Fig. 11.55) are the best insurance to guard against space loss. Remember, too, that this new posterior molar position has to be maintained if incisors are to be retracted. This is a difficult task without TADs to reinforce the anchorage.

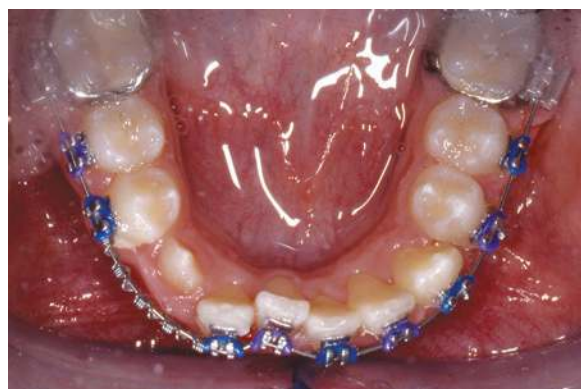### **Early (Serial) Extraction**

In many children with severe crowding, a decision can be made during the early mixed dentition period that expansion is not





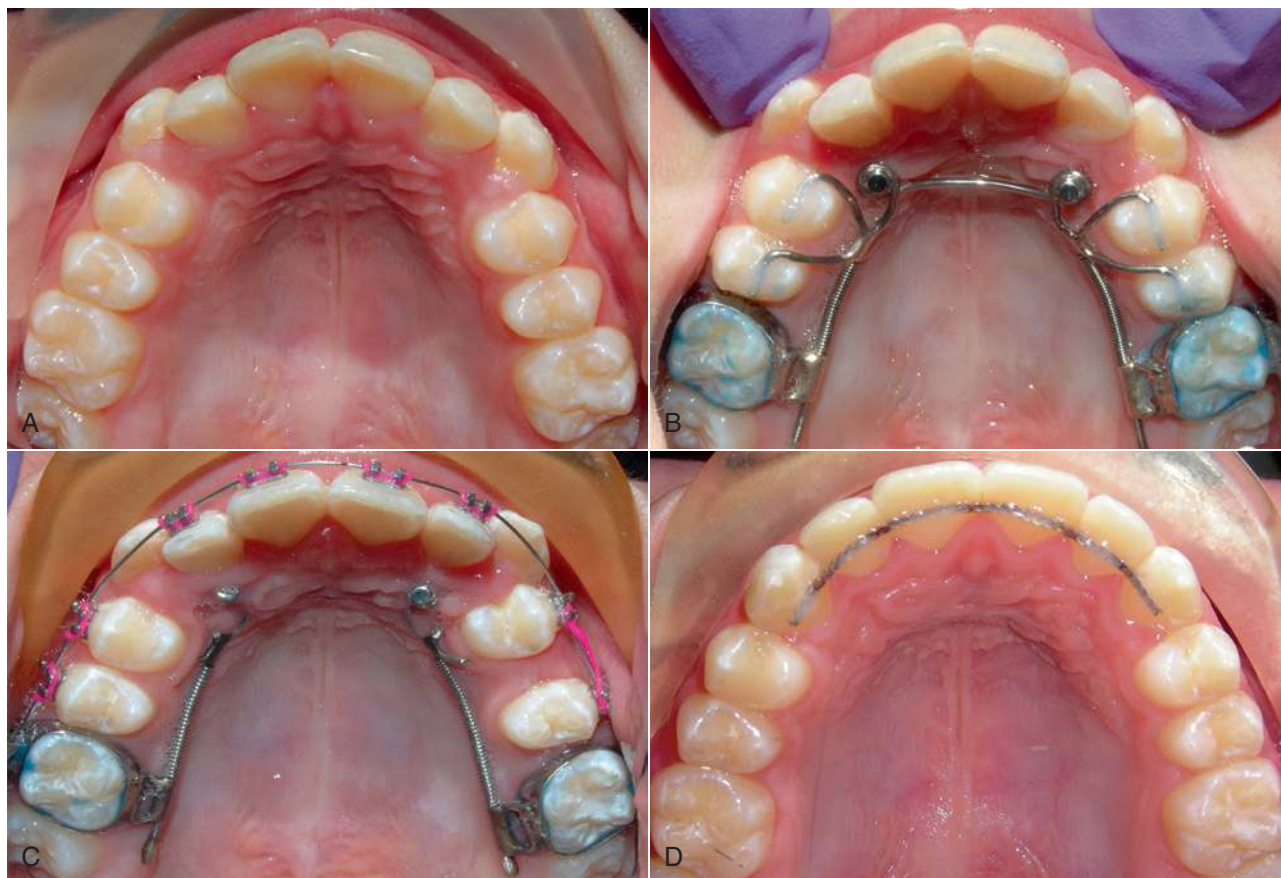• **Fig. 12.29** Several approaches can be taken to increasing arch circumference by distalizing molars, if the correct diagnosis is made and the incisor protrusion that usually results can be accepted. (A) and (B) Bilateral coil springs provide the force that is resisted by the anchorage of the primary molars and the palate using a Nance arch. (C) Alternatively, a pendulum appliance can be used that also gains anchorage from the palate but uses helical springs to supply the force. (D) to (F) This fixed appliance also uses palatal and dental anchorage and nickel–titanium (NiTi) coil springs to slide the molars along heavy lingual wires. Once placed, the appliance can be monitored until the desired tooth movement is achieved and then it can be modified to serve as a retainer. ([A] to [C] courtesy Dr. M. Mayhew.)



• **Fig. 12.30** For mixed dentition treatment of significant lower crowding and irregularity, banded and bonded attachments and an archwire provide the most efficient approach. This patient has crowding and irregularity that indicates fixed appliance treatment. Note the use of a superelastic coil spring to create space for the erupting mandibular right canine.

advisable and that some permanent teeth will have to be extracted to make room for the others. A planned sequence of tooth removal can reduce crowding and irregularity during the transition from the primary to the permanent dentition.<sup>34</sup> It will also allow the teeth to erupt over the alveolus and through keratinized tissue,





• **Fig. 12.31** (A) This patient had temporary anchorage device (TAD)-supported molar distalization in the late mixed dentition to accommodate the initial crowding and a nonextraction treatment plan. This is not recommended for patients much younger than 12 years because of inadequate bone density and resulting TAD instability. (B) The wire framework supports the TADs in the anterior palate with the distal force provided by the coil springs. No anchorage is provided by the anterior teeth. (C) Good tooth movement with intact TADs at the end of active distalization, even with the second molars erupted. (D) The final arch in retention.

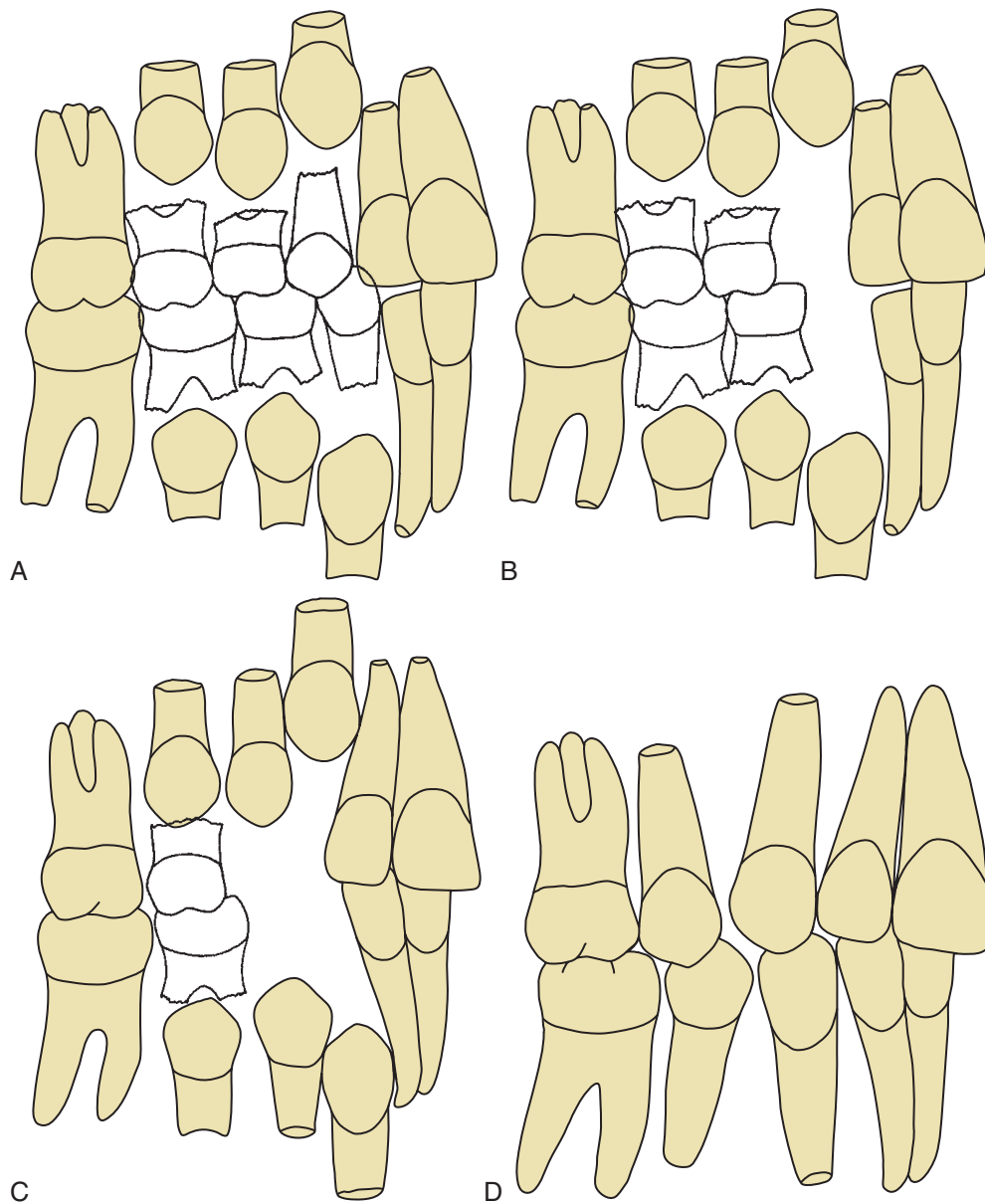
rather than being displaced buccally or lingually. This sequence, often termed *serial extraction*, simply involves the timed extraction of primary and, ultimately, permanent teeth to relieve severe crowding. It was advocated originally as a method to treat severe crowding without or with only minimal use of appliance therapy but is now viewed as an adjunct to later comprehensive treatment instead of a substitute for it.

Although serial extraction makes later comprehensive treatment easier and often quicker, by itself it almost never results in ideal tooth position or closure of excess space. Serial extraction is directed toward severe dental crowding. For this reason, it is best used when no skeletal problem exists and the space discrepancy is large—greater than 10 mm per arch. If the crowding is severe, little space will remain after the teeth are aligned, which means there will be little tipping and uncontrolled movement of the adjacent teeth into the extraction sites. If the initial space discrepancy is smaller, more residual space must be anticipated. Although it is possible to use serial extraction to compensate for minor and moderate skeletal Class II and Class III problems (with a usual extraction sequence of only upper teeth in Class II and only lower teeth in Class III problems),<sup>35</sup> this type of treatment is much more complex. The residual space closure probably needs to be

selectively directional (i.e., all from the front or all from the back) and requires a much better command of biomechanics than most nonspecialists have.

Serial extraction treatment begins in the early mixed dentition period with extraction of primary incisors if necessary, followed by extraction of the primary canines to allow eruption and alignment of the permanent incisors (Fig. 12.32). As the permanent teeth align without any appliances in place, there is usually some lingual tipping of the lower incisors, and overbite often increases during this stage. Labiolingual displacements resolve better than rotational irregularity. After extraction of the primary canines, crowding problems are usually under control for 1 to 2 years, but foresight is necessary. The goal is to influence the permanent first premolars to erupt ahead of the canines so that they can be extracted and the canines can move distally into this space.

The maxillary premolars usually erupt before the canines, so the eruption sequence is rarely a problem in the upper arch. In the lower arch, however, the canines often erupt before the first premolars, which causes the canines to be displaced facially. To avoid this result, the lower primary first molar should be extracted when there is one-half to two-thirds root formation of the first premolar. This usually will speed up the premolar eruption and



• **Fig. 12.32** Serial extraction is used to relieve severe arch length discrepancies. (A) The initial diagnosis is made when a severe space deficiency is documented and there is marked incisor crowding. (B) The primary canines are extracted to provide space for alignment of the incisors. (C) The primary first molars are extracted when one-half to two-thirds of the first premolar root is formed, to speed eruption of the first premolars. (D) When the first premolars have erupted they are extracted and the canines erupt into the remaining extraction space. The residual space is closed by drifting and tipping of the posterior teeth unless full appliance therapy is implemented.

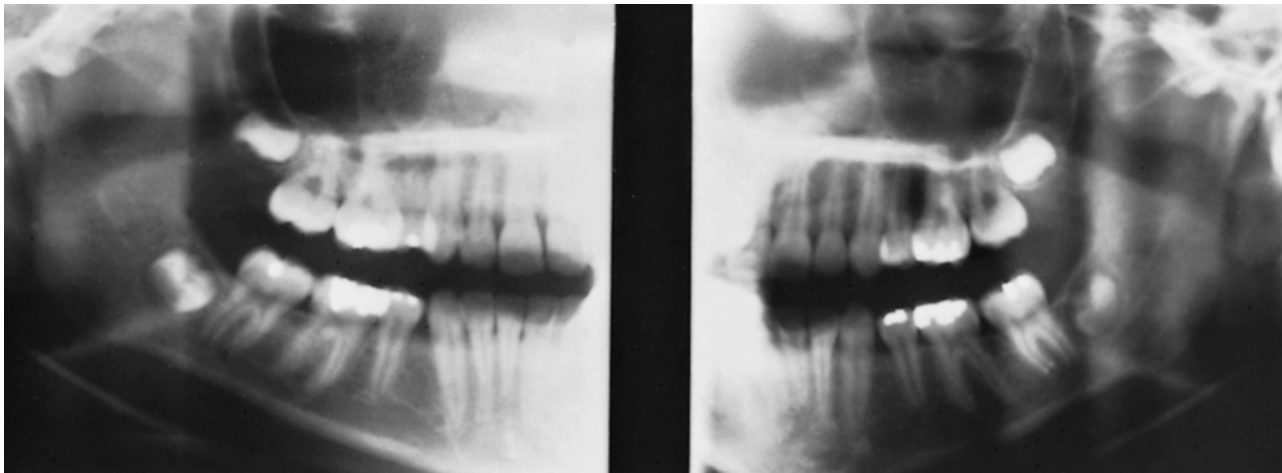
cause it to enter the arch before the canine (Fig. 12.32C). The result is easy access for extraction of the first premolar before the canine erupts (Fig. 12.32D).

A complication can occur if the primary first molar is extracted early and the first premolar still does not erupt before the canine. This can lead to impaction of the premolar that requires later surgical removal. When the primary first molar is being removed, it may be obvious that the canine will erupt before the premolar. In this case the underlying premolar can also be extracted at the same time—a procedure termed *enucleation*. If possible, however, enucleation should be avoided because the erupting premolar brings

alveolar bone with it. Early enucleation can leave a bone defect that persists.

After the first premolar has been extracted, the second primary molars should exfoliate normally. The premolar extraction spaces close partially by mesial drift of the second premolars and permanent first molars but largely by distal eruption of the canines. If serial extraction is not followed by mechanotherapy, ideal alignment, root positioning, correct rather than deep overbite, and space closure usually are not achieved (Fig. 12.33).

Serial extraction was used much more frequently 25 to 30 years ago than now. It was overused then and perhaps is underused now.



• **Fig. 12.33** This patient had serial extraction that was not followed by fixed appliance treatment, with an excellent result. Properly timed serial extraction usually results in incomplete space closure. Teeth drift together by tipping, which results in nonparallel roots between the canine and second premolar. Lack of root parallelism, residual space, and other irregularities can be addressed with subsequent fixed appliance therapy.

It can be a useful adjunct to treatment, shortening the time of comprehensive treatment if it is used correctly, but the patients must be chosen and supervised carefully as they develop. It is far from a panacea for treatment of crowding.

### The Borderline Crowding Case: What Do You Do?

If early extraction is only for the few patients with extremely severe crowding, and early expansion offers little advantage over expansion during later comprehensive treatment, what is the best approach to moderately crowded and irregular teeth during the mixed dentition? The wisest course of action, in most cases, is simply to keep the options open for the later comprehensive treatment that these children will need. Unless crowding is severe, maintaining leeway space during the last part of the transition to the permanent dentition increases the chance of successful nonextraction treatment. Early extraction of primary canines often can provide space for some spontaneous alignment of permanent incisors and decrease the chance of canine impaction, but a lower lingual arch to maintain space is needed to keep the nonextraction option open when this is done. Beyond that, the advantages of early appliance therapy are questionable and must be viewed in the context of an increased burden of treatment versus little or no additional benefit.

### References

- Papadopoulos MA, Chatzoudi M, Kaklamanos EG. Prevalence of tooth transposition. A meta-analysis. *Angle Orthod.* 2010;80:275–285.
- Garib DG, Peck S, Gomes SC. Increased occurrence of dental anomalies associated with second-premolar agenesis. *Angle Orthod.* 2009;79:436–441.
- Peck S, Peck L. Classification of maxillary tooth transpositions. *Am J Orthod Dent Orthop.* 1995;107:505–517.
- Frazier-Bowers SA, Simmons D, Wright JT, et al. Primary failure of eruption and PTH1R: the importance of a genetic diagnosis for orthodontic treatment planning. *Am J Orthod Dentofacial Orthop.* 2010;137:160.e1–160.e7, discussion 160–1.
- Rhoads SG, Hendricks HM, Frazier-Bowers SA. Establishing the diagnostic criteria for eruption disorders based on genetic and clinical data. *Am J Orthod Dentofacial Orthop.* 2013;144:194–202.
- Hölttä P, Alaluusua S, Saarinen-Pihkala UM, et al. Agenesis and microdontia of permanent teeth as late adverse effects after stem cell transplantation in young children. *Cancer.* 2005;103:181–190.
- Hölttä P, Hovi L, Saarinen-Pihkala UM, et al. Disturbed root development of permanent teeth after pediatric stem cell transplantation. Dental root development after SCT. *Cancer.* 2005;103:1484–1493.
- Iglesias-Linares A, Yáñez-Vico RM, Solano-Reina E, et al. Influence of bisphosphonates in orthodontic therapy: systematic review. *J Dent Res.* 2010;38:603–611.
- Hellstein JW, Adler RA, Edwards B, et al. Managing the care of patients receiving antiresorptive therapy for prevention and treatment of osteoporosis. Recommendations from the American Dental Association Council on Scientific Affairs. *J Am Dent Assoc.* 2011;142:1243–1251.
- International Association of Dental Traumatology. The Dental Trauma Guide. <https://dentaltraumaguide.org/>. Accessed June 11, 2017.
- Kindelan SA, Day PE, Kindelan JD, et al. Dental trauma: an overview of its influence on the management of orthodontic treatment; part 1. *J Orthod.* 2008;35:68–78.
- Brin I, Ben-Bassat Y, Heling I, Engelberg A. The influence of orthodontic treatment on previously traumatized permanent incisors. *Eur J Orthod.* 1991;13:372–377.
- Bauss O, Röhling J, Meyer K, Kiliaridis S. Pulp vitality in teeth suffering trauma during orthodontic therapy. *Angle Orthod.* 2009;79:166–171.
- Bauss O, Röhling J, Rahman A, Kiliaridis S. The effect of pulp obliteration on pulpal vitality of orthodontically intruded traumatized teeth. *J Endodont.* 2008;34:417–420.
- Diangelis AJ, Andreasen JO, Ebeleseder KA, et al. International Association of Dental Traumatology guidelines for the management of traumatic dental injuries: 1. Fractures and luxations of permanent teeth. *Dent Traumatol.* 2012;28:2–12.
- Tsilingaridis G, Malmgren B, Andreasen JO, et al. Scandinavian multicenter study on the treatment of 168 patients with 230 intruded permanent teeth—a retrospective cohort study. *Dent Traumatol.* 2016;32:353–360.
- Esteves T, Ramos AL, Pereira CM, Hidalgo MM. Orthodontic root resorption of endodontically treated teeth. *J Endodont.* 2007;33:119–122.



18. Bauss O, Röhling J, Sadat-Khonsari R, Kiliaridis S. Influence of orthodontic intrusion on pulpal vitality of previously traumatized maxillary permanent incisors. *Am J Orthod Dentofac Orthop*. 2008;134:12–17.
19. Malmgren B, Tsilingaridis G, Malmgren O. Long-term follow up of 103 ankylosed permanent incisors surgically treated with decoronation—a retrospective cohort study. *Dent Traumatol*. 2015;31:184–189.
20. Little R, Riedel R. Postretention evaluation of stability and relapse—mandibular arches with generalized spacing. *Am J Orthod*. 1989;95:37–41.
21. Bauss O, Freitag S, Rohling J, Rahman A. Influence of overjet and lip coverage on the prevalence and severity of incisor trauma. *J Orofac Orthop*. 2008;69:402–410.
22. Goettems ML, Brancher LC, da Costa CT, et al. Does dental trauma in the primary dentition increases the likelihood of trauma in the permanent dentition? A longitudinal study. *Clin Oral Investig*. 2017;21:2415–2420.
23. Glendor U, Koucheiki B, Halling A. Risk evaluation and type of treatment of multiple dental trauma episodes to permanent teeth. *Endod Dent Traumatol*. 2000;16:205–210.
24. Thiruvengkatachari B, Harrison JE, Worthington HV, O'Brien KD. Orthodontic treatment for prominent upper front teeth (Class II malocclusion) in children. *Cochrane Database Syst Rev*. 2013;(11):Art. No. CD003452.
25. Paulsen HU, Andreasen JO, Schwartz O. Tooth loss treatment in the anterior region: autotransplantation of premolars and cryopreservation. *World J Orthod*. 2006;7:27–34.
26. Zachrisson BU, Stenvik A, Haanaes HR. Management of missing maxillary anterior teeth with emphasis on autotransplantation. *Am J Orthod Dent Orthop*. 2004;126:284–288.
27. Bauss O, Sadat-Khonsari R, Engelke W, Kahl-Nieke B. Results of transplanting developing third molars as part of orthodontics space management. Part 2: results following the orthodontic treatment of transplanted developing third molars in cases of aplasia and premature loss of teeth with atrophy of the alveolar process. *J Orofac Orthop*. 2003;64:40–47.
28. Lutz HD, Poulton D. Stability of dental arch expansion in the deciduous dentition. *Angle Orthod*. 1985;55:299–315.
29. O'Grady PW, McNamara JA Jr, Baccetti T, Franchi LA. Long-term evaluation of the mandibular Schwarz appliance and the acrylic splint expander in early mixed dentition patients. *Am J Orthod Dentofac Orthop*. 2006;130:202–213.
30. McNamara JA Jr, Sigler LM, Franchi L, et al. Changes in occlusal relationships in mixed dentition patients treated with rapid maxillary expansion. A prospective clinical study. *Angle Orthod*. 2010;80:230–238.
31. Baumrind S, Korn EL, Isaacson RJ, et al. Quantitative analysis of orthodontic and orthopedic effects of maxillary traction. *Am J Orthod*. 1983;84:384–398.
32. Fontana M, Cozzani M, Caprioglio A. Non-compliance maxillary molar distalizing appliances: an overview of the last decade. *Prog Orthod*. 2012;13:173–184.
33. Rubin RL, Baccetti T, McNamara JA Jr. Mandibular second molar eruption difficulties related to the maintenance of arch perimeter in the mixed dentition. *Am J Orthod Dentofacial Orthop*. 2012;141:146–152.
34. Grec RH, Janson G, Branco NC, et al. Intraoral distalizer effects with conventional and skeletal anchorage: a meta-analysis. *Am J Orthod Dentofac Orthop*. 2013;143:602–615.
35. Hotz RP. Guidance of eruption versus serial extraction. *Am J Orthod*. 1970;58:1–20.

# SECTION V

## Growth Modification

If it were possible, the best way to correct a jaw discrepancy would be to get the patient to grow out of it. That requires inducing differential growth of one jaw relative to the other, either stimulating one to grow faster or restraining it so the other jaw can catch up. Because the pattern of facial growth is established early in life and rarely changes significantly (see [Chapter 2](#)), this is unlikely without treatment.

Three important principles must be kept in mind when growth modification is considered for a preadolescent or adolescent child: (1) if you start growth modification too late, it doesn't work, but if you start too soon, it takes too long; (2) growth occurs on a different timetable for the three planes of space; and (3) children's compliance with treatment is affected by both their stage of maturation and the difficulty of doing what the doctor wants.

### Timing in Relation to the Amount of Growth Remaining

This section of the book appropriately fits between the discussion of treatment for preadolescent children and adolescents, because some growth modification procedures must be done before adolescence whereas others are much more effective and efficient if done in adolescents. Whatever the type of appliance that is used or the kind of growth effect that is desired, if growth is to be modified, the patient must be growing. That means growth modification has to be done before the adolescent growth spurt ends. In theory, it could be done at any point up to that time.

Because of the rapid growth exhibited by children during the primary dentition years, one might think that treatment of jaw discrepancies by growth modification should be successful at a very early age. The rationale for very early treatment at ages 4 to 6 would be that because of the rapid rate of growth and the smaller and more plastic skeletal components, significant amounts of skeletal discrepancy could be overcome in a short time. This has been tested and does occur. The further rationale is that once discrepancies in jaw relationships have been corrected, proper function will cause harmonious growth thereafter without further treatment.

If this were the case, very early treatment in the primary dentition would be indicated for many skeletal discrepancies. Unfortunately, that is not correct. Although most anteroposterior and vertical jaw discrepancies can be corrected during the primary dentition years, relapse occurs because of continued growth in the original disproportionate pattern. If children are treated very early, they will need further treatment during the mixed dentition and again in the early permanent dentition periods to maintain the correction. For all practical purposes, early orthodontic treatment for skeletal problems now is restricted to the mixed dentition years, with a second phase of treatment required during adolescence.

The opposite point of view would be that because treatment in the permanent dentition will be required anyway, there is no point in starting treatment until then. Delaying treatment that long has two potential problems: (1) by the time the canines, premolars, and second molars erupt, there may not be enough growth remaining for effective modification, especially in girls, and (2) some children who would benefit from early treatment would be denied the psychosocial benefits of treatment during an important period of development.

This particularly applies to children with a skeletal Class II problem, which—as we will discuss in detail later—is otherwise better delayed until the adolescent growth spurt. Another indication for preadolescent Class II treatment is a dental and skeletal profile highly susceptible to trauma, such as the increased overjet and protrusive incisors that often accompany Class II relationships. The data are clear that these individuals encounter more dental trauma (see [Chapter 1](#) and [Fig. 1.18](#)). The type and extent of trauma are highly variable. It makes the most sense to treat the trauma-prone Class II children (those who experienced trauma to the incisors before 9 years of age) only by retracting the protruding incisors instead of performing early growth

modification, which would be more productive during the growth spurt. More generally, for each patient the benefits of early treatment must be considered against the risk and cost of prolonging the total treatment period.

## Different Timing for Different Planes of Space

The timing of maturation and the potential to effect a change in the different facial planes of space are not uniform. Maxillary growth in the transverse plane of space, the first to cease growing, stops when the first bridging of the midpalatal suture begins, not at final complete fusion. This means that for most children, palatal width increases would normally end by early adolescence, and to alter this later with appliance therapy would require heavier force to open the midpalatal suture. Transverse maxillary expansion therefore is more physiologic if done before adolescence.

Anteroposterior facial growth is most obvious in Class II and III malocclusions as the maxilla and mandible both move forward. For Class III maxillary deficiencies, skeletal protraction using the dentition as anchorage is easiest before age 11, but with skeletal anchorage it also is possible during adolescence. In the mandible, compressive forces against the condyle have not demonstrated long-term potential to restrict growth. But compressive force at the sutures above and behind the maxilla during adolescence can redirect and restrain maxillary growth while the mandible grows forward. It also means that anteroposterior growth modification treatment must be continued until growth is essentially complete,

to prevent uncontrolled late growth from ruining retention of what was thought to be completed treatment.

Vertical facial growth is the last to stop. It often continues into the late teens in girls and early 20s in boys, and prolonged retention is needed for both long-face and short-face patients. Recurrence of deep overbite can be controlled relatively easily, but starting early requires prolonged retention. Excessive vertical growth is difficult to control, and early attempts to do this would have to extend for inordinately long periods to outlast growth.

So, different timing for different problems is important. Palatal expansion and maxillary protraction are seemingly more urgent in earlier years, anteroposterior mandibular growth modification is more a midgrowth activity, and vertical control requires a later approach if it can be accomplished.

## Timing in Relation to Patient Compliance

Patient compliance is affected by both the patient's relative maturity and the burden of treatment from the patient's perspective. Timing of treatment interventions must be viewed relative to their effectiveness and the practical weighing of likely patient tolerance and compliance. This evaluation is not one of whether a change can be made, but whether the change is worth it in terms of time, financial and behavioral impact, and alternative treatment approaches such as surgery.

In the discussion of growth modification treatment techniques that follows, we will review the evidence that supports the timing that is advocated for different methods, along with management of the treatment procedures.



# 13

## Treatment of Skeletal Transverse and Class III Problems

### CHAPTER OUTLINE

#### Growth Modification in the Transverse Plane of Space

- Palatal Expansion in the Primary and Early Mixed Dentition
- Palatal Expansion in Preadolescents (Late Mixed Dentition)
- Palatal Expansion in Adolescents (Early Permanent Dentition)
- Rapid Palatal Expansion—the Details
- Slow Palatal Expansion—the Details
- Maxillary Expansion and Sleep-Disordered Breathing
- Clinical Management of Palatal Expansion Devices
- Treatment of Transverse Mandibular Constriction
- Restriction of Excessive Transverse Growth

#### Class III Growth Modification

- Concepts of Class III Treatment
- Anteroposterior and Vertical Maxillary Deficiency
- Mandibular Excess

### Growth Modification in the Transverse Plane of Space

It is appropriate to address maxillary transverse deficiency at the beginning of this discussion of skeletal problems because this is the first dentofacial dimension to cease growing. Like all craniofacial sutures, the midpalatal suture becomes more tortuous and interdigitated with increasing age, so there is some demand to be timely with treatment.

Patients with maxillary transverse deficiency usually have a narrow palate and a posterior crossbite (see [Fig. 6.80](#)). If the maxilla is narrow relative to the rest of the face, a diagnosis of transverse maxillary deficiency is justified. Both the width of the maxillary premolar teeth (via Pont's index, an old and now-discredited approach)<sup>1</sup> and the width of the palate compared with population norms have been advocated as methods to diagnose maxillary deficiency. As we have emphasized in [Chapter 6](#), the appropriate comparison of maxillary width should be to other transverse proportions in the same patient (e.g., bizygomatic width), not to population averages. Remember, a narrow maxilla accompanied by a narrow mandible and normal occlusion should not be considered a problem just because the jaw widths are below the population mean. Finally, transverse deficiencies can be mistakenly diagnosed because there is really an anteroposterior maxillary deficiency and

not really a transverse deficiency. Accurate diagnoses can avoid unnecessary treatment.

A narrow maxillary arch is related to the extraction–nonextraction decision in that a child with crowded teeth and deficient maxillary width can have transverse expansion to provide space to align the teeth.<sup>2</sup> Many of these patients have some distortion of the arches, tooth abrasion from interferences of anterior teeth, and either anterior or lateral mandibular shifts that can lead to the possibility of mandibular skeletal asymmetry.<sup>3</sup> Customarily, treatment occurs by opening the midpalatal suture, which widens the roof of the mouth and the floor of the nose ([Fig. 13.1](#)). The maxilla opens as if on a hinge superiorly at the base of the nose and also opens more anteriorly than posteriorly. This transverse expansion corrects the posterior crossbite that almost always is present. The expansion sometimes moves the maxilla forward a little (but is about as likely to lead to backward movement),<sup>4</sup> increases space in the arch, and repositions underlying permanent tooth buds as they move along with the bone in which they are embedded. Adequate expansion that coordinates the arches will also eliminate mandibular shifts and interferences.

Palatal expansion can be done at any time before the end of the adolescent growth spurt, but the technique varies with the patient's age, with different procedures for preadolescents, early and late adolescents, and adults. Let's begin with treatment for children in the primary and early mixed dentition.

### Palatal Expansion in the Primary and Early Mixed Dentition

Skeletal expansion is easiest when the midpalatal suture has not fused or has only minor initial bridging, so that heavy force and extensive microfracturing are not needed to separate the palatal halves. Almost any expansion device will tend to separate the midpalatal suture in addition to moving the molar teeth in a child up to age 9 or 10.

Three methods can be used for palatal expansion in children: (1) a split removable plate with a jackscrew or heavy midline spring, (2) a lingual arch, often of the W-arch or quad-helix design, or (3) a fixed palatal expander with a jackscrew, which can be either attached to bands or incorporated into a bonded appliance. Despite that, the three approaches are *not* equally sensible to use.

With a split removable plate (see [Fig. 13.11](#)), the rate of expansion must be quite slow, and the force employed during the process must be low because faster expansion produces higher forces that create problems with retention of the appliance. Multiple clasps that are well adjusted are mandatory. Because of the instability of the teeth during the expansion process, failure to wear the appliance

even for 1 day requires adjustment of the jackscrew, usually by the practitioner, to constrict the appliance until it again fits and expansion can be resumed. Compliance in activation and wear time are always issues with these appliances. Successful expansion with a removable appliance can take considerable time, which makes it less cost effective.

Lingual arches of the W-arch and quad-helix designs have been demonstrated to open the midpalatal suture in young patients (Fig. 13.1). These appliances generally deliver a few hundred grams of force and provide slow expansion. They are relatively clean and reasonably effective, producing a mix of skeletal and dental change that approximates one-third skeletal and two-thirds dental change.<sup>4</sup> There is some evidence that these appliances are more effective than removable appliances<sup>5</sup> as well as more comfortable for the patient and more efficient.

Fixed jackscrew appliances attached to bands or bonded splints also can be used in the early treatment of maxillary constriction (Fig. 13.2), but in comparison with an expansion lingual arch, there are two major disadvantages. First, a jackscrew appliance bulky and more difficult to place and remove. The patient inevitably

has problems cleaning it, which leads to soft tissue irritation, and either the patient or parent must activate the appliance. Banding permanent molars and primary second molars is relatively simple, but banding primary first molars can be challenging. Use of a bonded jackscrew appliance in the mixed dentition is relatively straightforward, but it can be difficult to remove if conventional bonding techniques are used.

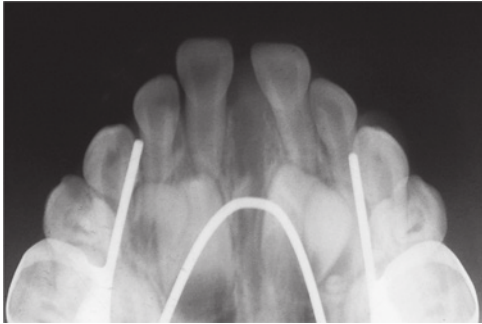
Second, an appliance of this type can be activated rapidly, which in young children is a disadvantage, not an advantage, and can cause facial distortion (Fig. 13.3). There is no evidence of any advantage of rapid movement and high forces in children, and ample evidence that this can be dangerous.

On balance, slow expansion with an active lingual arch is the preferred approach to maxillary constriction in children with primary and early mixed dentitions. A fixed jackscrew appliance (see Fig. 13.1) is an acceptable alternative if activated carefully and slowly. In fact, 10 years after treatment, both rapid and slow palatal expansion, although sometimes used for different magnitudes of constriction, have been found to be stable.<sup>6</sup> It also appears that anteroposterior dental changes in terms of overjet are not consistently correlated with maxillary expansion.<sup>7</sup>

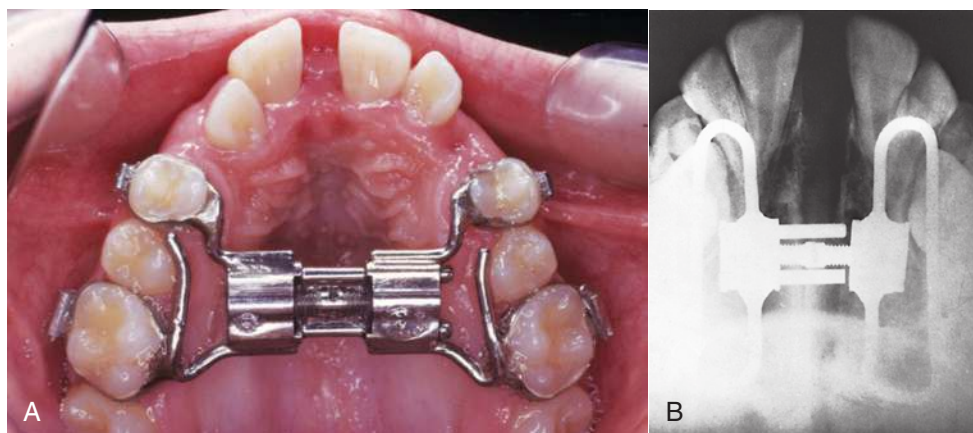
### Palatal Expansion in Preadolescents (Late Mixed Dentition)

With increasing age, the midpalatal suture becomes more and more tightly interdigitated. By the late mixed dentition period, sutural expansion often necessitates placement of a relatively heavy force directed across the suture, which microfractures the interdigitated bone spicules so that the halves of the maxilla can be moved apart. A fixed jackscrew appliance (either banded or bonded) is necessary (Fig. 13.4). As many teeth as possible should be included in the anchorage unit. In the late mixed dentition, root resorption of primary molars may have reached the point at which these teeth offer little resistance, and it may be wise to wait for eruption of the first premolars before beginning expansion.

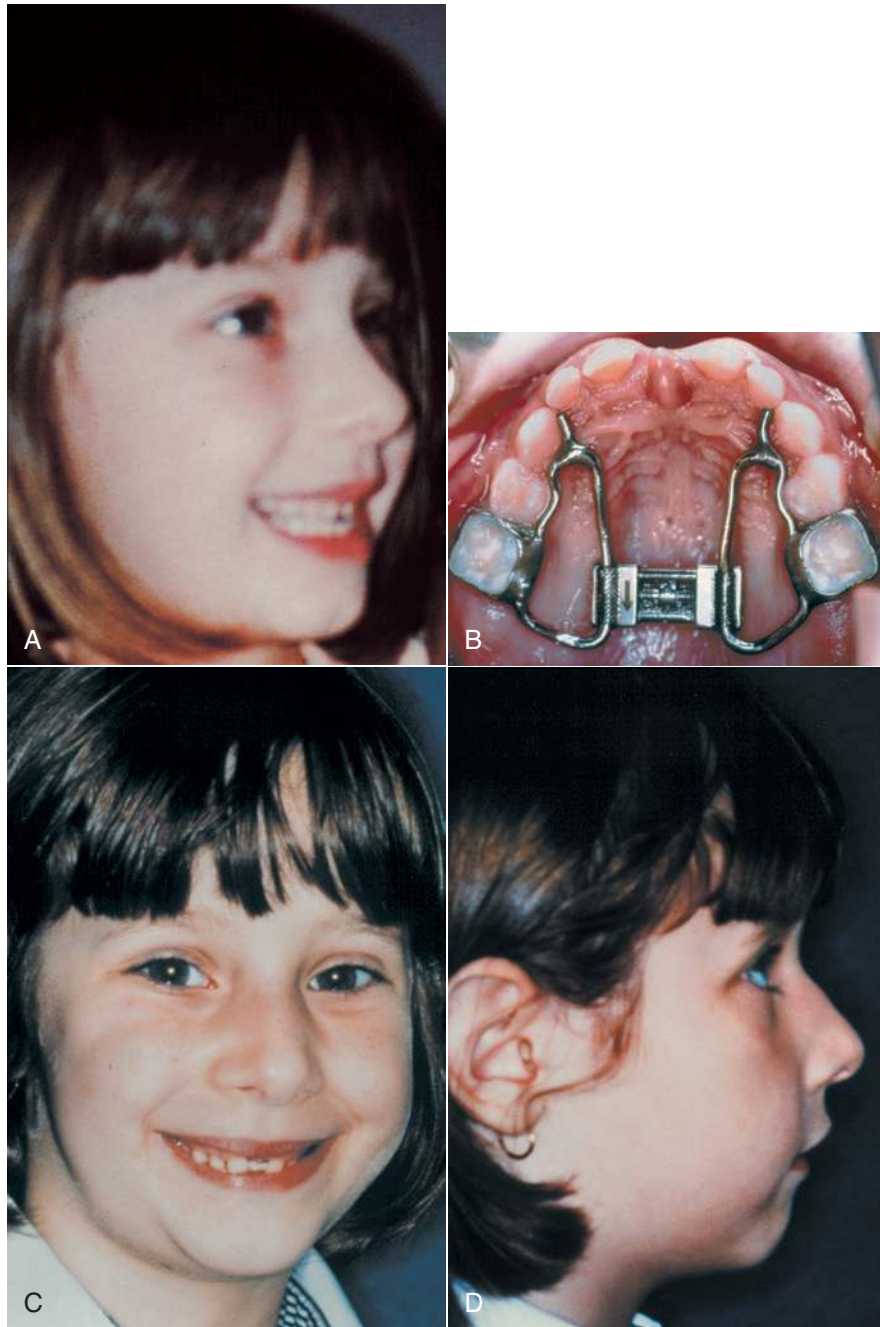
Many functional appliances for Class II treatment (discussed in Chapter 14) incorporate some components to expand the



• **Fig. 13.1** Before adolescence, the midpalatal suture can be opened during maxillary expansion by using a number of methods. This occlusal radiograph taken during the primary dentition years illustrates sutural opening in response to the W-arch appliance.



• **Fig. 13.2** Transverse force across the maxilla in children and adolescents can open the midpalatal suture. (A) The expansion force is usually delivered with a jackscrew mechanism fixed to maxillary teeth, as in this Hyrax expander with metal framework, seen at the end of rapid expansion (0.5 mm per day). The maxilla opens as if on a hinge, with its apex at the bridge of the nose. (B) The suture also opens on a hinge anteroposteriorly, separating more anteriorly than posteriorly, as shown in this radiograph of a patient after rapid expansion.



• **Fig. 13.3** Rapid palatal expansion in young children can lead to undesirable changes in the nose, as in this 5-year-old who had expansion at the rate of 0.5 mm per day (two quarter turns of the jackscrew per day). (A) Nasal contours before treatment. (B) Jackscrew appliance after activation over a 10-day period. (C) and (D) Nasal hump and paranasal swelling, which developed after the child complained of discomfort related to the expansion. (Courtesy Dr. D. Patti.)

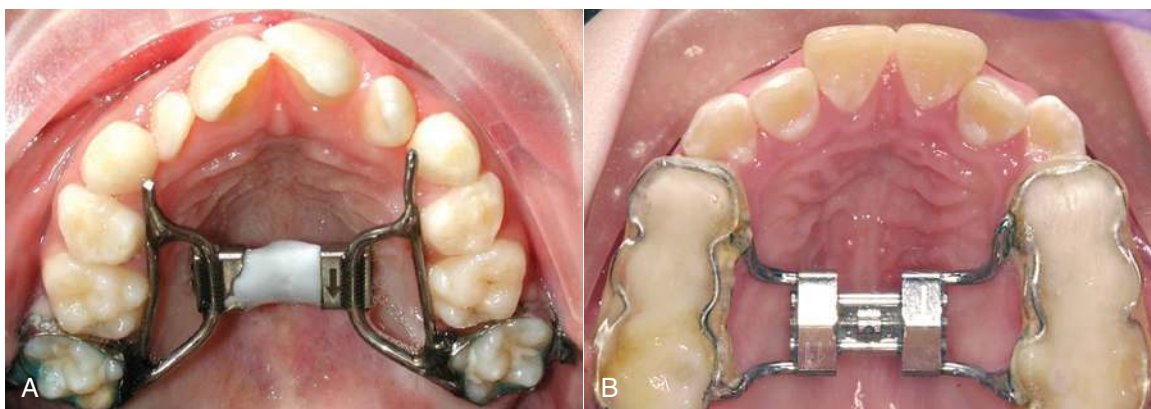maxillary arch, either intrinsic force-generating mechanisms such as springs and jackscrews or buccal shields that reduce cheek pressure against the dentition. When arch expansion occurs during functional appliance treatment, it is possible that some opening of the midpalatal suture contributes to it, but the precise mix of skeletal and dental change is not well documented.

Although some studies have reported increases in vertical facial height with maxillary expansion, long-term evidence indicates this change is transitory.<sup>8</sup> A bonded appliance that covers the

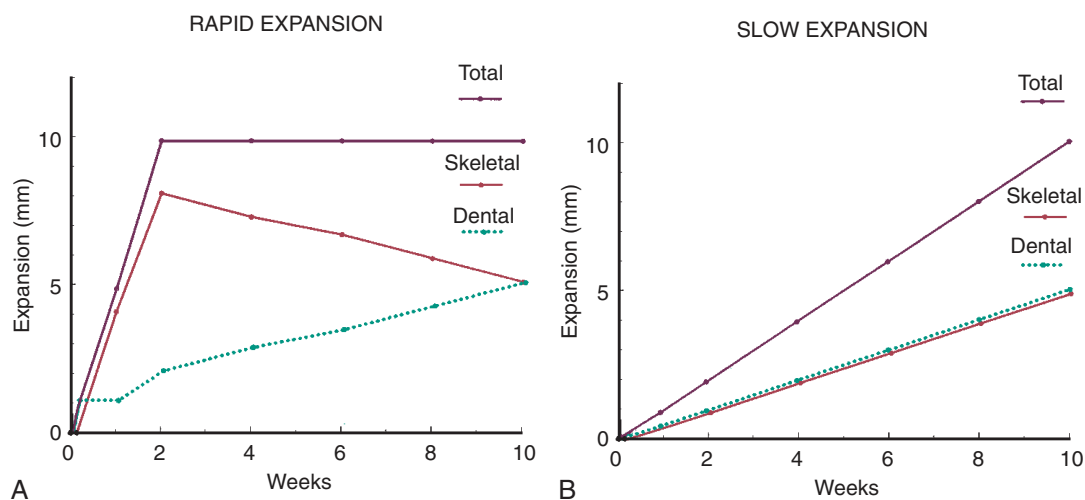
occlusal surface of the posterior teeth may be a better choice for a preadolescent child with a long-face tendency because it produces less mandibular rotation than a banded appliance, but in the long term, this is not totally clear.<sup>9</sup> Perhaps the best summary is that the older the patient when maxillary expansion is done, the less likely it is that vertical changes will be recovered by subsequent growth.

An important consideration in skeletal expansion is the rate of activation of the expander, so that rapid or slow expansion is obtained. In the late mixed dentition, either rapid or slow expansion





• **Fig. 13.4** (A) This banded palatal expander, attached only to the first molars in a patient in the mid mixed dentition, has been stabilized after expansion by using cold-cure acrylic so it will not relapse. This will remain in place for 3 months. (B) For a bonded palatal expander, during fabrication the plastic base is extended over the occlusal, facial, and lingual surfaces of the posterior teeth. In general, a composite bonding agent is used to retain the appliance, with only the facial and lingual surfaces of the posterior teeth etched. Etching the occlusal surface is not recommended; bonding there is unnecessary for retention and can greatly complicate appliance removal.



• **Fig. 13.5** (A) With rapid expansion, 10-mm expansion would be obtained in 1 to 2 weeks and at that point about 80% of it would be skeletal. If the expander were removed immediately after the expansion, there would be rapid total relapse, because there had not been time for new bone to form along the sides of the widened suture—so the expander is left in place for 10 to 12 weeks or so. During that time the stretched palatal tissue creates a lingual force against the molars and premolars, and the resulting tooth movement allows the halves of the maxilla to move back toward each other even though the teeth remain separated. (B) With slow expansion and dental anchorage, about 50% of the dental arch expansion is skeletal, owing to opening of the suture, and 50% is tooth movement from the beginning. For 10-mm expansion across the first molars, about 5 mm would be skeletal and 5 mm would be dental. New bone forms along the edges of the suture at the rate of about 0.5 mm per week, so with 10-mm expansion and a 50% skeletal component, the width of the suture itself would be about normal at 10 weeks.

is clinically acceptable, but simplicity and consideration for tissue irritation probably favors slow expansion. It now appears that slower activation of the expansion appliance (at the rate of <2 mm per week) provides approximately the same ultimate result over a 10- to 12-week period as rapid expansion, with less trauma to the teeth and bones. Essentially, as Fig. 13.5 shows, there are different paths to the same outcome. These are discussed in detail in the following sections.

### Palatal Expansion in Adolescents (Early Permanent Dentition)

In mid-adolescence, there is a near-100% probability of opening the midpalatal suture with a banded or bonded expansion device, but as the adolescent growth spurt ends, interdigitation of the suture reaches the point that opening it may no longer be possible. Guidance for decision making regarding the state of the midpalatal

suture could be gained from chronologic age or dental developmental age as we have generally described earlier. Or, it could be provided by one of several developmental staging methods that have been proposed. One method is to extend cervical vertebra maturation staging (CVMS), which is used to estimate mandibular growth potential,<sup>10</sup> to evaluate midpalatal suture maturation. This is appealing because the information for CVMS is readily available from any cephalometric radiograph. This extension, however, has not been evaluated for validity.

Another option is to use the five-stage midpalatal suture maturation method.<sup>11</sup> This, too, has not been validated.

Recently, Grünheid et al tested several methods including those mentioned earlier and a novel one called the “midpalatal suture density ratio” (MSDR).<sup>12</sup> The calculation used gray levels (really substitutes for bone density levels) from cone beam computed tomography (CBCT) images of defined palatal regions. The ratio values were 0 to 1, with 0 indicating less calcification and gray levels closer to soft tissue and 1 indicating a more calcified suture with gray levels closer to palatal bone. The values for MSDR, chronologic age, CVM, and stage of midpalatal suture maturation were correlated with actual measurements of skeletal expansion to determine which was a good predictor of the potential and desired expansion. The results showed that only MSDR was significantly correlated and at a high enough level to provide clinical value (by explaining about half the variability). As CBCT images become more common as diagnostic aids in orthodontics, this method may prove helpful in determining whether rapid, slow, or surgical expansion is recommended.

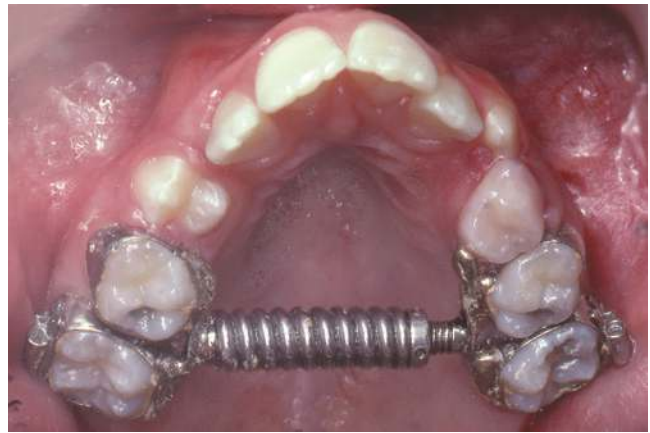Skeletal anchorage for expansion is more likely to be successful in adolescents, because retention of bone screws and plates requires a level of bone maturation that is not reached until mid-adolescence. Presumably, objective measures of bone maturation such as MSDR could be used to decide whether skeletal anchorage in the form of bone screws on each side of the palate would be feasible.

The later years of adolescence are when decisions regarding maxillary expansion become most difficult. By the end of adolescence, for some patients, there is no expansion for 1 or 2 days as each turn of the screw increases the amount of force, until the patient hears and feels suture fracture. For others, increasing pain from the amount of force against the teeth leads to giving up on expansion after that amount of time.

For these late adolescents, rapid expansion does make some sense, because force builds up rapidly to the point at which either the suture fractures or the treatment is discontinued. Slow expansion would be likely to just move the teeth, not open the suture. A modern view would be that for patients of this type, tooth-supported expansion should not be attempted. Instead, micro-implant assisted palatal expansion (MARPE) should be used, with one activation of the screw (0.25 mm) per day, rather than using heavy force against the teeth. This approach along with surgically assisted palatal expansion (SARPE) and segmental osteotomy of the maxilla are the possibilities for the more mature patients in whom tooth-supported expanders will not work. These techniques are discussed in detail in [Chapters 19](#) and [20](#).

## Rapid Palatal Expansion—the Details

Major goals of growth modification always are to maximize the skeletal changes and minimize the dental changes produced by treatment. The object of maxillary expansion is to widen the maxilla, not just expand the dental arch by moving the teeth relative to the bone. Originally, rapid palatal expansion (RPE) was



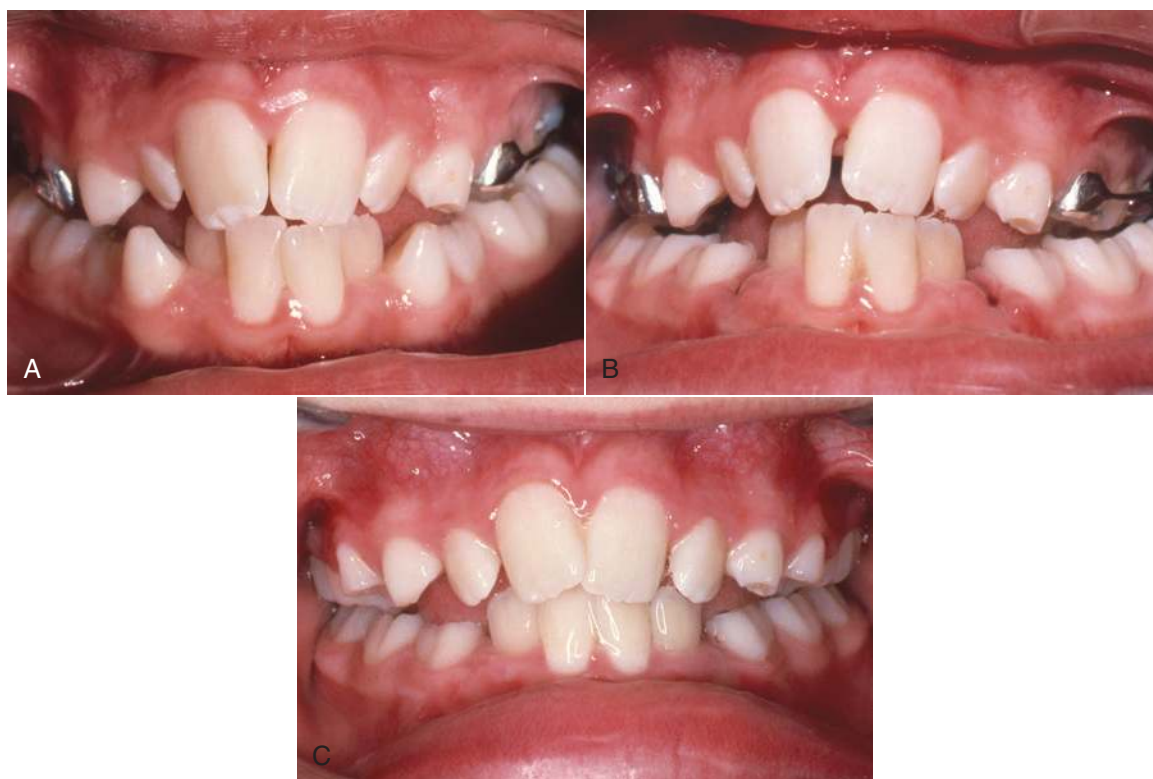• **Fig. 13.6** This expander uses a coil spring to provide the force as the stop on the threaded connector is turned to compress the spring. It can be calibrated to determine and monitor the force that is active. This prevents delivery of either low or excessive forces during the expansion.

recommended to help meet this goal. The theory was that with rapid force application to the posterior teeth, there would not be enough time for tooth movement, the force would be transferred to the suture, and the suture would open up while the teeth moved only minimally relative to their supporting bone. In other words, rapid activation was conceived as a way to maximize skeletal change and minimize dental change. As we have noted earlier, that is true in the first couple of weeks, but not thereafter (see [Fig. 13.5](#)).

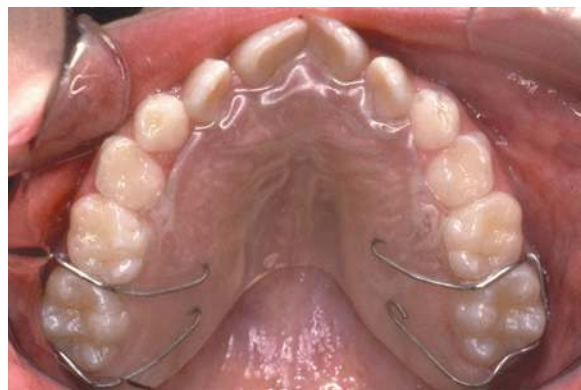With RPE at a rate of 0.5 mm per day (two quarter turns of the screw), a centimeter or more of expansion is obtained in 2 to 3 weeks, with 10 to 20 pounds of pressure across the suture. Sometimes a large coil spring is incorporated along with the screw, which modulates the amount of force, depending on the length and stiffness of the spring ([Fig. 13.6](#)). Most of the movement is separation of the two halves of the maxilla, but force also is transmitted to adjacent posterior structures.<sup>13</sup> A space between the central incisors develops because the suture opens wider and faster anteriorly and suture closure begins in the posterior area of the midpalatal suture ([Fig. 13.7](#)).

The space created at the midpalatal suture is filled initially by tissue fluids and hemorrhage, and at this point the expansion is highly unstable. The expansion device must be stabilized so that it cannot screw itself back shut and is left in place for 3 to 4 months. By then, new bone has filled in the space at the suture, and the skeletal expansion is stable. The midline diastema decreases and may disappear during this time. The diastema closes from a combination of skeletal relapse and tooth movement created by stretched gingival fibers, not from tooth movement alone.

The aspect of rapid expansion that was not appreciated initially was that orthodontic tooth movement continues after the expansion is completed, until bone stability is achieved. In most orthodontic treatment, the teeth move relative to a stable bony base. It is possible, of course, for tooth movement to allow bony segments to reposition themselves while the teeth are held in the same relationship to each other, and this is what occurs during the approximately 3 months required for bony fill-in at the suture after rapid expansion. During this time, the dental expansion is maintained, but the two halves of the maxilla move back toward each other as a result of soft tissue forces, which is possible because at the same time the teeth move laterally on their supporting bone.



• **Fig. 13.7** Usually spaces develop between the central incisors during rapid maxillary expansion. (A) When the appliance is placed and treatment begins, there is only a tiny diastema. (B) After 1 week of expansion, the teeth have moved laterally with the skeletal structures. (C) After retention, a combination of skeletal relapse and pull of the gingival fibers has brought the incisors together and closed the diastema. Note that the expansion was continued until the maxillary lingual cusps occlude with the lingual inclines of the buccal cusps of the mandibular molars.



• **Fig. 13.8** Following palatal expansion, even after 3 months of retention with the passive expander, an acrylic retainer that covers the palate is advisable to control relapse and stabilize the skeletal components.

After the 3-month retention period, the fixed appliance can be removed, but a removable retainer that covers the palate is often needed as further insurance against early relapse (**Fig. 13.8**). A relatively heavy, expanded maxillary archwire provides retention and support if further treatment is being accomplished immediately. If not, a transpalatal lingual arch or a large expanded auxiliary wire (36 or 40 mil) in the headgear tubes will help maintain expansion while a more flexible wire is used in the brackets.

If the changes were represented graphically, the plot for rapid expansion would look like **Fig. 13.5A**. Note that when the expansion was completed, 10 mm of total expansion would have been produced by 8 mm of skeletal expansion and only 2 mm of tooth movement. At 4 months, the same 10 mm of dental expansion would still be present, but at that point there would be only 5 mm of skeletal expansion, and tooth movement would account for the other 5 mm of the total expansion. Rapid activation of the jackscrew, therefore, is not an effective way to minimize tooth movement. The net effect is approximately equal skeletal and dental expansion.

### Slow Palatal Expansion—the Details

Slow activation of the expansion appliance at the rate of less than 2 mm per week, which produces about 2 pounds of pressure in a child with mixed dentition, opens the suture at a rate that is close to the maximum speed of bone formation. The suture can show some opening on radiographs, but no midline diastema appears. Even so, both skeletal and dental changes occur (see **Fig. 13.5B**). After 10 to 12 weeks, approximately the same amounts of skeletal and dental expansion are present as were seen at the same time with rapid expansion. When bonded slow and rapid palatal expanders in early adolescents were compared, the major difference was greater expansion across the canines in the rapid expansion group. This translated to a predicted greater arch perimeter change but similar opening of the suture posteriorly.<sup>14</sup> So with use of slow palatal expansion (one turn per day or every other day) in a typical



fixed expansion appliance or with use of a spring, effective expansion with minimal disruption of the suture can be achieved for a child with late mixed dentition.

This really brings us to the question of early slower expansion or later rapid expansion as choices. Two studies that demonstrate age-appropriate approaches are instructive. One, with patients who averaged 8 years 10 months of age at the start, used a bonded acrylic splint and a semirapid approach of 0.25 mm of expansion per day.<sup>15</sup> The other, with patients averaging 12 years 2 months of age at the start, used a Haas-type RPE device turned twice for 0.5 mm of expansion per day of treatment.<sup>16</sup> Both followed the expansion with retention, and ultimately the patients underwent full treatment without further purposeful expansion. At the long-term evaluation points (19 years 9 months and 20 years 5 months, respectively), the expansion across the molars and canines and the increase in arch perimeter were quite similar, which indicates equivalent long-term results.

### Alternative Expansion Approaches

Another expansion protocol with alternate rapid maxillary expansion and constriction (Alt-RAMEC) was initially devised by Liou for treatment of patients with Class III cleft palate with maxillary transverse and anteroposterior deficiency. It requires the patient to alternatively expand and constrict the maxilla on a weekly basis by 1 mm per day (two turns in the morning and two turns in the evening for a weekly total of 7 mm) by using a double-hinged expander. This is done for 7 to 9 weeks,<sup>17</sup> then the patient wears a facemask for maxillary protraction. The goal is to disrupt not only the midpalatal suture but also the lateral and posterior sutures. As we point out in the discussion of maxillary protraction later in this chapter, ALT-RAMEC for protraction cannot be recommended now.

What makes this of interest in our discussion of maxillary expansion is whether this protocol has any application to expansion without protraction. It appears from data obtained by using the Alt-RAMEC protocol with noncleft children over a 9-week period that there was statistically significant transverse change to the maxilla, adjacent sutures, and soft tissues, along with approximately 1 mm of forward and downward movement at A point, but not clinically different transverse changes from what one would see

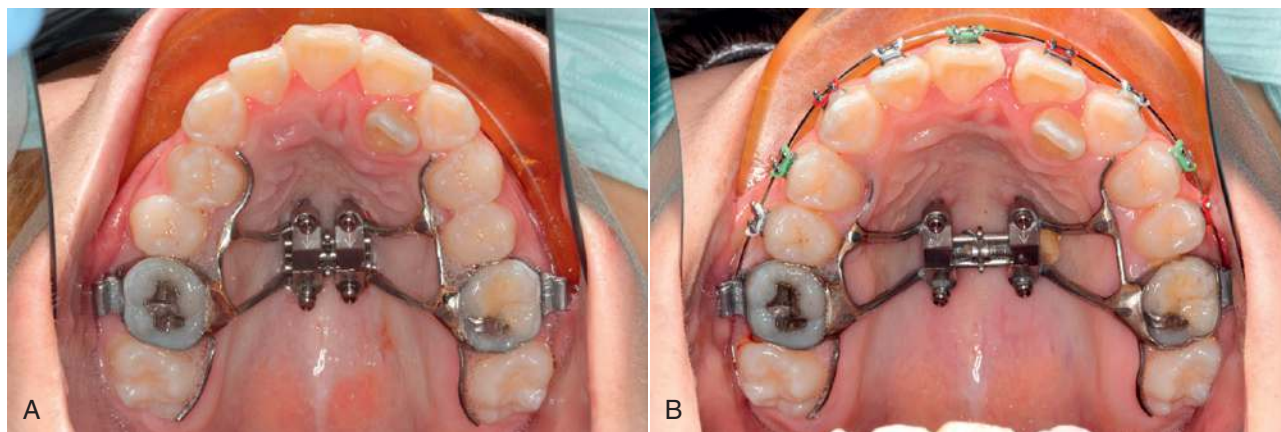
with routine maxillary expansion.<sup>18</sup> So, as a singular approach to maxillary expansion treatment alone, this is a much more aggressive approach than is necessary, and it carries with it the risks that are described later in the discussion of maxillary protraction.

### Implant-Supported Expansion

For older (more mature) adolescents, heavier force is needed to fracture the suture. The chance that opening of the suture will occur with moderate force declines with increasing bone maturity, and the chance increases that even with heavier force, tooth-supported expanders will just move teeth rather than open the suture. For these patients, initially rapid activation quickly leads to one of two possible responses: The desired fracture occurs, or the patient is experiencing significant pain. At that point the expansion screw should be backed off and surgical assistance or very slow activation of an implant-supported expander should be considered. From the perspective of patient management, it would be better to consider a skeletally anchored expander from the beginning rather than go through the aforementioned scenario.

The location of the skeletal anchors for palatal expansion is important. A randomized clinical trial at the University of Alberta in 2009 and 2010 compared the percentage of skeletal versus dental change with bone screws at the base of the alveolar process versus conventional expansion. The surprising and discouraging result was no significant difference between the two groups, because the alveolar process bent outward in the skeletal anchorage group.<sup>19</sup> Since then, research has shown that bone screws in the palate provide better anchorage and significantly less tooth movement, with a significant difference between the palatally anchored and tooth-borne expanders.<sup>20,21</sup> It must be kept in mind, however, the teeth do move apart as the suture expands, and that the possibility of tooth movement allowing skeletal relapse still exists—so the implant anchorage needs to remain in place for 2 to 3 months after the expansion is completed.

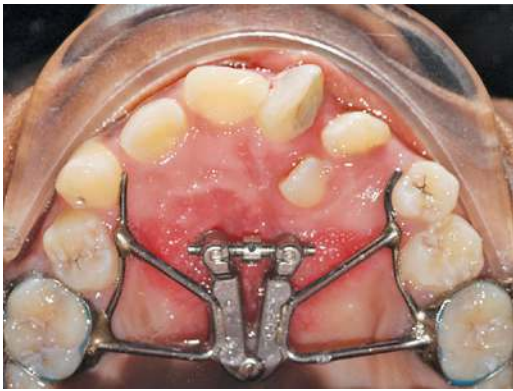
At this point, the goal of treatment with skeletally anchored expanders is not so much to provide heavy force as to apply the force directly against the bone so that there is little or no pressure against the teeth (Fig. 13.9). This provides a way to expand the maxilla in a patient with anodontia or severe hypodontia, and would maximize skeletal change and minimize tooth movement



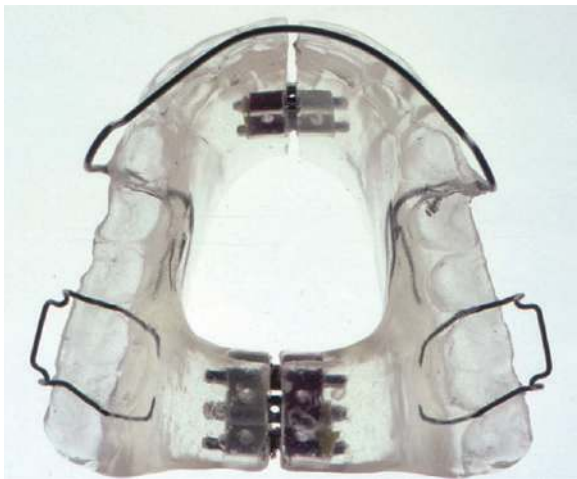
• **Fig. 13.9** (A) The preferred configuration now for bone-anchored expanders, particularly with the MARPE technique that uses semi-slow expansion (0.25 mm per day), is a pair of linked bone screws at the base of the palate. (B) End of expansion for this patient, with opening of space between the central incisors. Repositioning the central incisors to correct the midline should allow bringing the lingually positioned lateral incisor into the arch. (Courtesy Drs. D. Grauer and G. Sameshima.)

in patients with a normal dentition. Bone screws in the palate now are routinely used for expansion. With a jackscrew attached to skeletal anchors, rapid disruption of the suture would be a disadvantage, so slow ( $<2$  mm per week) rather than rapid expansion is indicated. There are a number of designs for expanders, including hinged ones that expand more anteriorly than posteriorly (Fig. 13.10), and these can be adapted for skeletal anchorage if desired.

Following midpalatal expansion, a retainer is needed even after bone fill-in seems complete. Even with skeletal anchorage, the expansion increases the light but constant pressure against the teeth from the stretched palatal mucosa and soft tissues of the cheeks. Placing a blocking material to prevent the screw from turning (see Fig. 13.4A) helps to retain the skeletal expansion, but dental relapse still could occur. With no retention at all, both skeletal and dental relapse would be expected. Exactly that result has been reported after expansion in children to help in management of enuresis: The intermolar expansion in these children, who had normal posterior occlusion before treatment and underwent expansion into a buccal crossbite, disappeared completely when no retainer was used.<sup>22</sup>



• **Fig. 13.10** Many configurations of maxillary expanders are available. This one has a hinge in the posterior and the expansion screw in the anterior. This design holds the posterior teeth and their transverse dimension stable and expands only the anterior part of the arch.



• **Fig. 13.11** This removable maxillary expander has two expansion screws, but all it can do is produce a small amount of tooth movement, and it has to be activated very slowly in order to do that. This design now is obsolete.

The general guideline is that after any type of maxillary expansion, the fixed expansion device should remain in place until the new bone formed in the midline suture has had time to calcify and at least partially mature, and that a tooth-supported retainer is needed for another 6 to 12 months after that. With RPE, the consensus is that a tooth-supported expansion appliance should remain in place for 3 to 4 months and then can be replaced with a removable retainer or other retention device. After slow expansion, the expansion device is not replaced with a tooth-supported retainer for another 12 weeks after expansion is completed. With implant-supported expansion, the guideline is about the same as with tooth-supported expansion. Note that the time a fixed appliance is kept in place is about the same with RPE and slow expansion.

### Maxillary Expansion and Sleep-Disordered Breathing

There is little doubt that nasal airway and nasopharynx volume are increased by RPE (sometimes by an order of 2 when measured with CBCT in children and adolescents).<sup>23,24</sup> There are no data for airway effects with slow expansion, but no reason to think that it would not have the same effect. The issue is whether the expansion provides better respiration, especially for those with sleep apnea. There is evidence that nasal resistance usually decreases when minimum cross-sectional area and nasal volume are improved following expansion.<sup>25</sup> For patients with sleep-disturbed breathing and no adenotonsillar hypertrophy, RPE appears to reduce Apnea-Hypopnea Index (AHI) and arousal index scores.<sup>26</sup> Even in children with mild or severe tonsillar hypertrophy who showed symptoms of sleep-disordered breathing,<sup>27</sup> RPE produced a decreased AHI that was sustained at 36 months.<sup>27,28</sup> At this point, using true measures of respiration, RPE appears to have a therapeutic effect for children and adolescents with sleep apnea. Does that justify routinely expanding those with normal palatal dimensions into buccal crossbite? For those with demonstrated resistance to nasal airflow, the answer is *yes*. Without that, exactly how RPE would accomplish improved breathing is not clear, and routine expansion is questionable.

### Clinical Management of Palatal Expansion Devices

Most traditional palatal expansion devices use bands for retention on permanent first molars and first premolars if possible. During the late mixed dentition years, the first premolars often are not fully erupted and are difficult to band. If the primary second molars are firm, they can be banded along with the permanent first molars. Alternatively, only the permanent first molars can be banded and the supporting framework extended anteriorly, contacting the other posterior primary and erupting permanent teeth near their gingival margins (see Fig. 13.4A). A comparison of four-band (see Fig. 13.2) versus two-band devices showed that the four-band devices provided more transverse expansion and arch perimeter, especially after 12 years of age when the suture was more calcified.<sup>29</sup> If first premolars are available, they should be banded.

Expanders with hinged designs can differentially expand the anterior or posterior portions of the arch. For some patients, this may be an advantage (see Fig. 13.10). After crossbite correction is completed, band removal can be difficult because the teeth are mobile and sensitive. In those patients, sectioning the bands is appropriate.



An alternative approach is to use a bonded palatal expander (see Fig. 13.4B). Because there is no band fitting, the appliance is easier to place for both the patient and doctor, and during treatment it is manipulated like any other RPE appliance. Removal of this appliance also can be difficult. It is accomplished with a band remover engaged under a facial or lingual margin to flex the appliance and break the bond. In addition, the appliance usually needs to be sectioned or portions of the occlusal plastic removed for a direct purchase on the teeth so the band remover can effectively lift and separate the plastic from the teeth. Complete removal of the bonding agent (typically a filled resin that will adhere to etched tooth surfaces and to the appliance) can be laborious, so use of only an adequate amount is crucial, but insufficient resin will lead to excessive leakage onto the nonbonded surfaces, which can result in decalcification or appliance loss. For these reasons, some clinicians use a resin-modified glass ionomer cement that will bond to both the plastic appliance and the teeth for retention. The strength of the material usually is adequate, and the short-term fluoride release may be beneficial (see Chapter 10).

A factor in the decision between a bonded and banded expander is the vertical effect of maxillary expansion. Regardless of the skeletal effect, expansion creates dental interferences as soon as the posterior teeth begin to move laterally, and the effect is to rotate the mandible downward and backward. Almost always there is a permanent increase in face height after expansion because of eruption of both maxillary and mandibular posterior teeth before a solid cusp–fossa relationship of the teeth is established.

For a patient who had a deep bite as well as a posterior crossbite, this is good. For one who had an open bite, this makes the open bite worse. In theory, the splint on top of the teeth with a bonded expander would interfere with eruption of the posterior teeth in both arches, and there is some (weak) evidence that this is the case in the short term. It may be reasonable to use a bonded expander in long-face or open bite patients who need expansion rather than a banded one. For patients with a deep bite, it seems to make no difference in the vertical effects of expansion which type of expander is used.

## Treatment of Transverse Mandibular Constriction

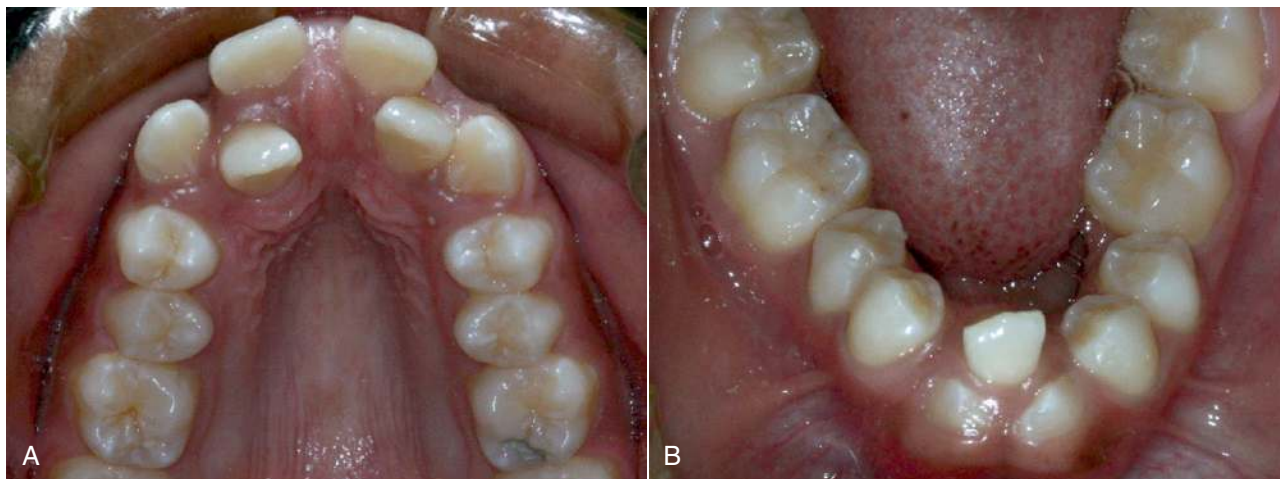
Unlike the maxilla, the mandible has no midline suture. It started as two halves, but they fused early in fetal life, and the midline is solid bone. Although removable appliances that look like midpalatal expanders can be used (see Fig. 13.11), they can only move the teeth (and do not do that very well). Mandibular transverse expansion was impossible until distraction osteogenesis became available. The first step in distraction, of course, is to cut through the bone; then it is possible to manipulate the healing callus and generate new bone (Fig. 13.12). There still is a limitation: The expansion is much greater anteriorly than in the molar region, and the condyles rotate slightly but do not move laterally. Fortunately, this amount of condylar rotation is tolerated without creating any problems.

## Restriction of Excessive Transverse Growth

Restriction of transverse growth in both jaws is exceptionally difficult, almost impossible. In the maxillary arch a transpalatal lingual arch during the preadolescent period would maintain molar width but does not affect skeletal growth or arch width across the premolars and canines. In the mandibular arch the length of a lingual arch makes it flexible enough that some increase in intermolar width probably would occur despite its presence, and there would be the same lack of effect on both jaw width and the other teeth.

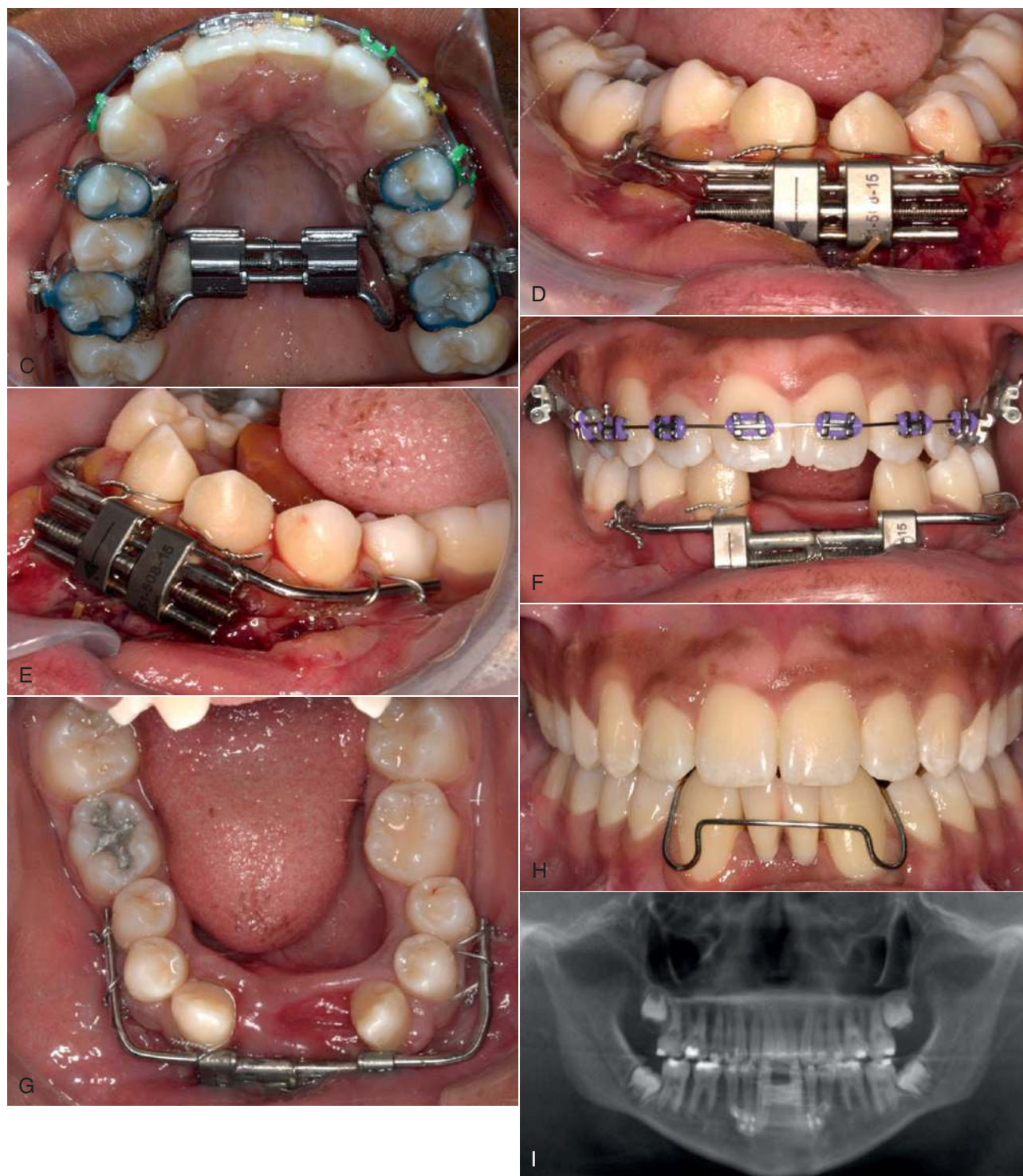The major problem this creates is posterior crossbite in a patient with normal maxillary arch width and very large mandibular arch width. Patients of that type usually have a wide tongue. Even heroic efforts to decrease the mandibular intermolar width (for instance, wearing an elastic across the arch, running it over the top of the tongue), rarely succeed, and immediate relapse is likely. That leaves the orthodontist with two options: expand the maxillary arch to match the wide lower arch, or tolerate the crossbite.

As we have illustrated earlier, sutural expansion increases maxillary width more anteriorly than posteriorly, just the reverse of what



• **Fig. 13.12** (A) and (B) This patient had both a narrow maxillary arch with crowded-out lateral incisors and the unusual condition of a mandible with an imperfect union of the two halves of the mandible early in fetal life. Note that the mandibular canines were almost in contact in the midline. Three lower incisors were congenitally missing; one was only in soft tissue in the midline.





• **Fig. 13.12, cont'd** (C) The maxillary arch was expanded at the rate of 1 mm per day with a banded jackscrew device. At the time of the photo the expansion was complete and was being retained (note the wire ligature to prevent further movement of the jackscrew). (D) and (E) The screw-retained expander for mandibular symphysis distraction osteogenesis, after removal of the lone incisor, immediately after cuts through the cortical bone. Expansion at the rate of 1 mm per day was done after a 7-day latency period. (F) and (G) The expander was stabilized when the desired expansion had been obtained and left in place for 4 months for maturation and remodeling of the new bone. (H) Nearly 1 year later, with orthodontic alignment of both arches completed and a temporary retainer in place. (I) Panoramic radiograph at the time distractor was removed. Note the fill in mature bone in the distraction area. Symphysis distraction is the only way to deal with problems created by missing areas of the anterior maxilla. (Courtesy Drs. D. Grauer and D. Hall.)

is needed to match a mandibular arch that widens posteriorly, and dental expansion risks fenestration of the molar roots. Patients with posterior crossbite have a problem only when it forces a mandibular shift on closure, and without that, there are neither functional nor esthetic reasons for correcting it. A segmental maxillary osteotomy (see [Chapter 20](#)) can provide more expansion posteriorly than anteriorly. That simply is not indicated for a condition that really is not a problem for the patient. The best option: Take that type of posterior crossbite off the problem list and tolerate it.

## Class III Growth Modification

### Concepts of Class III Treatment

We have emphasized in the diagnosis and treatment planning chapters that it is critically important to recognize the skeletal versus dental components of problems in all three planes of space, and the focus of the following discussion is on treatment of Class III jaw discrepancies, due to some combination of deficient growth of the maxilla and excessive growth of the mandible. Treatment of the milder and largely dental Class III problems that can be managed by altering the dental occlusion in adolescents and adults is discussed in [Chapters 15 to 17 and 19](#).

This distinction between dental and skeletal problems, of course, was not made by the pioneers of orthodontics. Edward Angle's concept was that Class III malocclusion was due almost exclusively to excessive mandibular growth and that Class III elastics could control this excessive growth in all but the most severely prognathic patients. This was shown to be incorrect in the first studies using cephalometric radiographs. In fact, almost any combination of deficient maxillary growth and excessive mandibular growth can be found in patients with Class III malocclusion, and in a broad view maxillary deficiency and mandibular excess are about equally likely.

The realization that maxillary deficiency is so frequently a component of skeletal Class III malocclusion, and the discovery 50 years ago that extraoral force could pull the growing maxilla forward if done in the early mixed dentition period, led to a great increase in treatment aimed at promoting maxillary growth. Fortunately, although few data from randomized clinical trials exist, data from well-documented retrospective studies now provide a clear picture of both the best time for facemask protraction and the amount of short- and long-term change that can be expected.

In contrast, extraoral force via a chin cup anchored against the cranium has been shown to produce more downward and backward rotation of the mandible than true growth restraint. A large mandible cannot be rotated to decrease chin prominence without creating a long-face deformity except in patients who also have short anterior face height. That Class III phenotype is most prevalent in those of Asian descent, but is rarely seen in Europeans or Americans. Not surprisingly, this has led to a great decrease in chin cup therapy, especially in Europe and the Americas.

A more recent discovery is that Class III elastics between bone anchors above the posterior maxilla and in the anterior mandible are more effective than facemask protraction in bringing the maxilla forward, and that alterations in mandibular growth also occur. This is now the most effective and invasive growth-modifying method orthodontists have ever had, but there are still many unanswered questions that are discussed in detail in the following sections.

In evaluating current growth modification possibilities for skeletal Class III problems, focusing on what they do and how they do it, let's begin with maxillary deficiency.

## Anteroposterior and Vertical Maxillary Deficiency

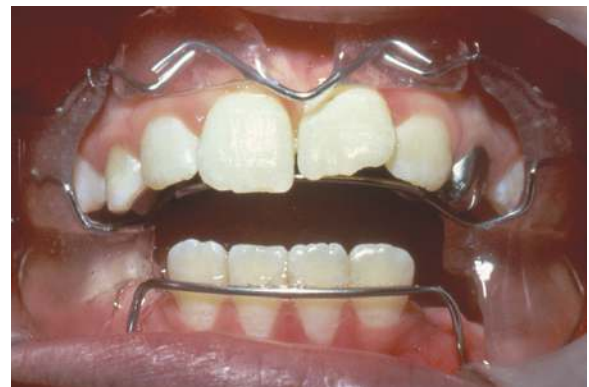Both anteroposterior and vertical maxillary deficiency can contribute to Class III malocclusion. If the maxilla is small or positioned posteriorly, the effect is direct; if it does not grow vertically, there is an indirect effect on the mandible, which then rotates upward and forward as it grows, producing an appearance of mandibular prognathism that may be due more to the position of the mandible than its size.

In order of their effectiveness, there are three possible approaches to growth modification to correct maxillary deficiency: Frankel's FR-III functional appliance, reverse-pull headgear (facemask) to a maxillary splint or skeletal anchors, and Class III elastics to skeletal anchors.

### FR-III Functional Appliance

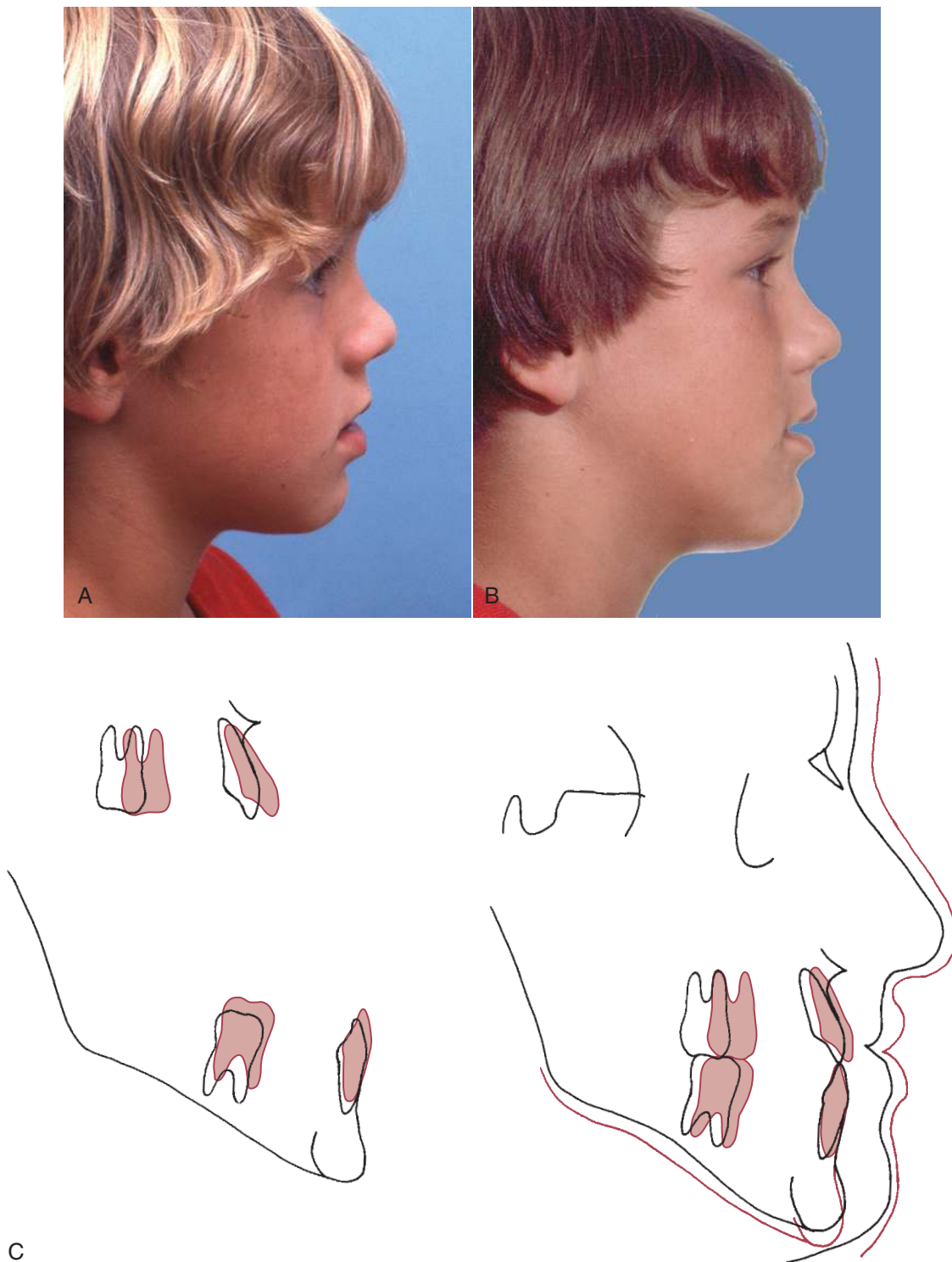
The FR-III appliance ([Fig. 13.13](#)) is made with the mandible positioned posteriorly and rotated open and with pads to stretch the upper lip forward. In theory, the lip pads stretch the periosteum in a way that stimulates forward growth of the maxilla. In a review of cases selected from Frankel's archives, Levin et al reported that in patients with Class III skeletal and dental relationships and good compliance who wore the FR-III appliance full-time for an average of 2.5 years and then part-time in retention for 3 years, there was significantly enhanced change over controls in maxillary size and position. There was improved mandibular position combined with more lingual lower incisor bodily position, so the patients had more overjet. This held up at the long-term follow-up over 6 years after active treatment.<sup>30</sup>

The available data from most other studies, however, indicate little true forward movement of the upper jaw.<sup>31</sup> Instead, most of the improvement is from dental changes. The appliance allows the maxillary molars to erupt and move mesially while holding the lower molars in place vertically and anteroposteriorly. The appliance tips the maxillary anterior teeth facially and retracts the mandibular anterior teeth ([Fig. 13.14](#)). Rotation of the occlusal plane as the upper molars erupt more than the lowers also contributes to a change from a Class III to a Class I molar relationship ([Fig. 13.15](#)). In addition, if a functional appliance of any type rotates the chin down and back, the Class III relationship will improve



• **Fig. 13.13** The FR-III appliance stretches the soft tissue at the base of the upper lip, attempting to stimulate forward growth of the maxilla by stretching the maxillary periosteum while maintaining the mandible in its most retruded position. The vertical opening is used to enhance downward and forward eruption of maxillary posterior teeth.





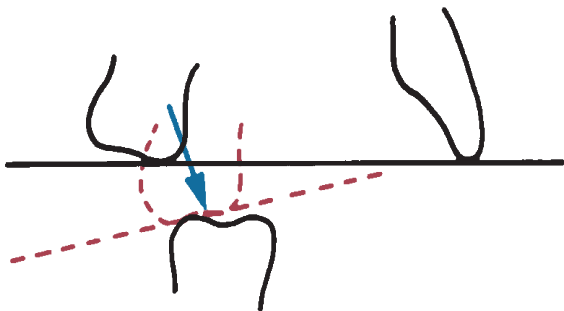
• **Fig. 13.14** Response to a FR-III functional appliance. (A) Pretreatment profile. (B) Posttreatment profile. (C) Cephalometric superimpositions. Note in the cranial base superimposition that the mandible rotated inferiorly and posteriorly to a less prominent position. The maxillary incisors moved facially while there was lower incisor eruption, but there was little if any differential forward growth of the maxilla. In essence, the treatment traded increased face height for decreased chin prominence.



because of the mandibular rotation, not an effect on the maxilla. In short, functional appliance treatment, even with the use of upper lip pads, has little or no effect on maxillary deficiency and, if considered, should be used only in mild cases. If this appliance is used, there are long treatment and retention periods that require excellent compliance to maintain limited changes.

### Reverse-Pull Headgear (Facemask)

**Dental Anchorage.** After Delaire's demonstration that at an early age, a facemask attached to a maxillary splint could move the maxilla forward by inducing growth at the maxillary sutures,



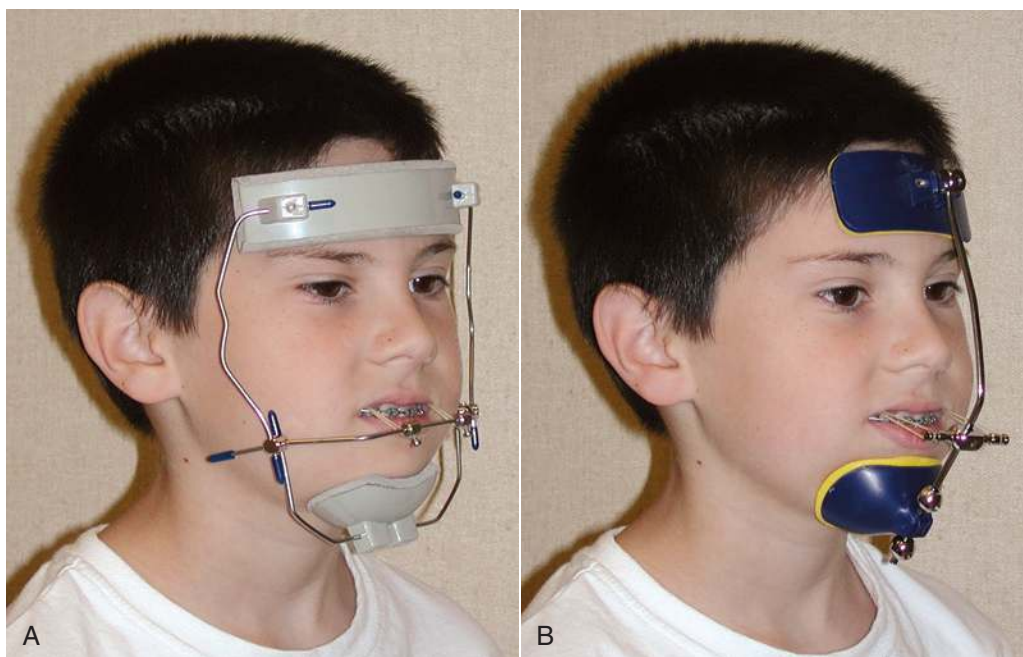
• **Fig. 13.15** To facilitate Class III correction, the mesial and vertical eruption of the maxillary molar can be emphasized so that the occlusal plane rotates down posteriorly. This facilitates normal interdigitation of the molars in a Class III patient.

this approach to maxillary deficiency became popular in the late 20th century (Fig. 13.16). The age of the patient is a critical variable. It is easier and more effective to move the maxilla forward at younger ages. Although some recent reports indicate that anteroposterior changes can be produced up to the beginning of adolescence, the chance of true skeletal change appears to decline beyond age 8, and the chance of clinical success begins to decline at age 10 to 11.<sup>32</sup>

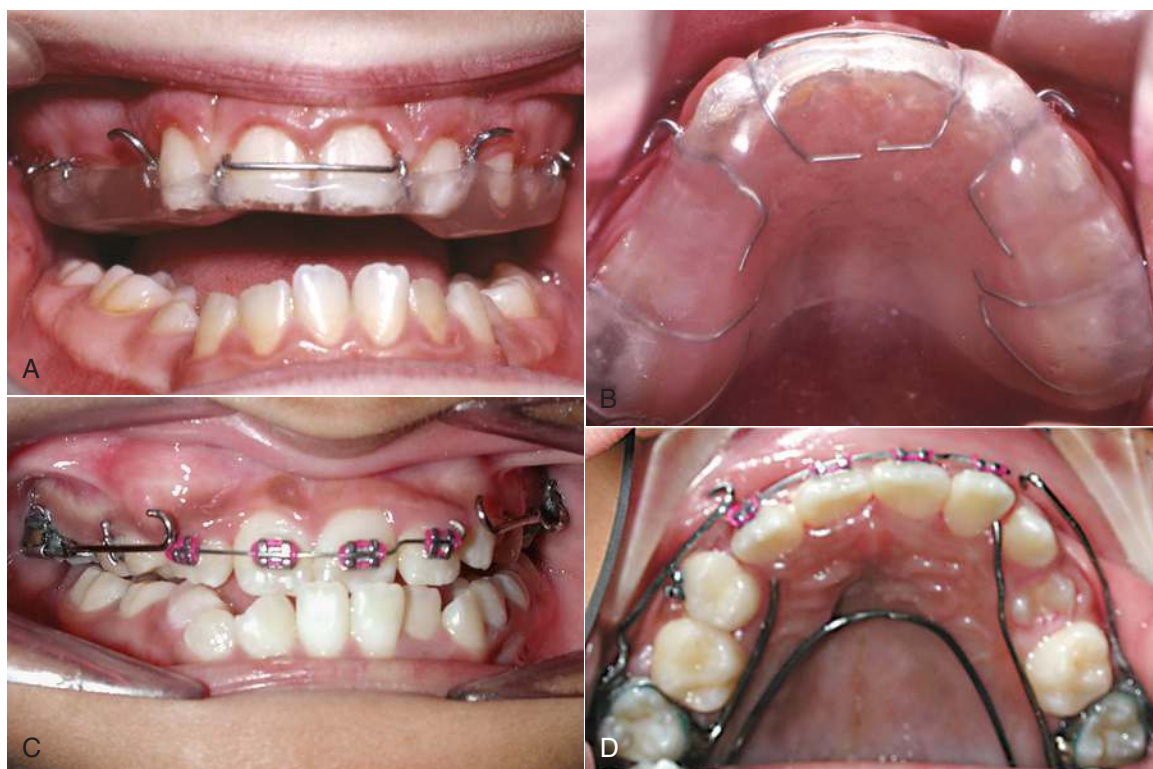When force is applied to the teeth for transmission to the sutures, tooth movement in addition to skeletal change is inevitable. Whatever the method of attachment to the teeth (Fig. 13.17), the appliance must have hooks for attachment to the facemask that are located in the canine–primary molar area above the occlusal plane. This places the force vector nearer the purported center of resistance of the maxilla and limits maxillary rotation (Fig. 13.18).

Facemask treatment is most suited for children with minor-to-moderate skeletal problems, so that the teeth are within several millimeters of one another when they have the correct axial inclination. This type of treatment also is best used in children who have true maxillary problems, but some evidence indicates that the effects on mandibular growth during treatment go beyond changes caused by clockwise rotation of the mandible.

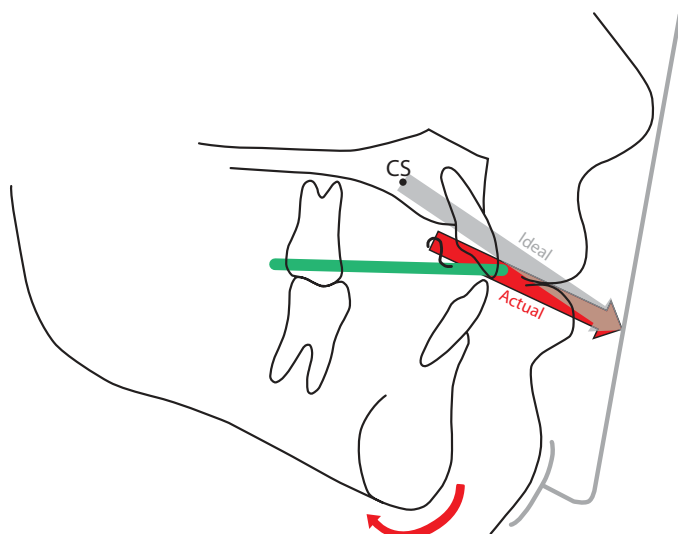
In general, it is better to defer maxillary protraction until the permanent first molars and incisors have erupted. The molars can be included in the anchorage unit and the inclination of the incisors can be controlled to affect the overjet. Many clinicians use protraction with a facemask following or simultaneously with palatal expansion, on the theory that this increases the responsiveness



• **Fig. 13.16** (A) This Delaire-type facemask (sometimes called *reverse headgear*) offers good stability when used for maxillary protraction. It is rather bulky and can cause problems with sleeping and wearing eyeglasses. With even modest facial asymmetry, it can appear to be ill-fitted on the face. Note the downward and forward direction of the pull of the elastics. (B) This rail-style facemask provides more comfort during sleeping and is less difficult to adjust. It also can be adjusted to accommodate some vertical mandibular movement. Both types can lead to skin irritation caused by the plastic forehead and chin pads. These occasionally require relining with an adhesive-backed fabric lining for an ideal fit or to reduce soft tissue irritation. Clinical experience indicates that some children will prefer one type over the other, and changing to the other type of facemask can improve cooperation if the child complains.



• **Fig. 13.17** A maxillary removable splint is sometimes used to make the upper arch a single unit for maxillary protraction. (A) The splint incorporates hooks in the canine and premolar region for attachment of elastics and should cover the anterior and posterior teeth and occlusal surfaces for best retention (B). Note that the hooks extend gingivally, so the line of force comes closer to the center of resistance of the maxilla. Multiple clasps also aid in retention. If necessary, the splint can be bonded in place, but this causes hygiene problems and should be avoided if possible for long-term use. (C) and (D) A banded expander or wire splint also can be used for delivery of protraction force. It consists of bands on primary and permanent molars or just permanent molars connected by a palatal wire for expansion or transverse stability and hooks on the facial aspect for facemask attachments.



• **Fig. 13.18** With the splint attached to the maxillary arch, the ideal line of force would be directed at the center of resistance (CS) of the maxilla, so the hooks on the splint should be above the occlusal plane. Even so, the actual line of force is likely to be below the center of resistance, so some downward movement of the posterior maxilla and opening of the bite anteriorly can be anticipated.

of the sutures above and behind the maxilla to the protraction force—but that is not correct. A randomized clinical trial showed that simultaneous palatal expansion made no difference in the amount of anteroposterior skeletal change,<sup>33</sup> and this has also been shown by a recent retrospective study.<sup>34</sup> If the maxilla is narrow, palatal expansion is quite compatible with maxillary protraction and the expansion device is an effective splint; there is no benefit, however, from expanding the maxilla just to improve the protraction.

It is claimed by some clinicians that aggressive maxillary expansion (Alt-RAMEC) to create greater maxillary mobility significantly facilitates forward movement with traction from a facemask. This procedure consists of rapid expansion for a week at 1 mm per day, followed by turning the screw in the opposite direction to constrict for another week, and continuing this over a 7- or 9-week period. It certainly creates maxillary mobility, sometimes extreme mobility, and there seems to have been little consideration of possible adverse effects and risks. A recent clinical trial showed a statistically significant further forward movement with facemask therapy after Alt-RAMEC, but the investigators noted that the greater change was so small (1 mm) that it probably was not clinically significant.<sup>35</sup>

There also are concerns about the effects of compression of the facial sutures during back-and-forth opening and closure of

the suture, which are particularly pertinent in view of the recent demonstration that Gli1+ cells within the craniofacial sutures are critical for formation of all craniofacial bones and are activated during injury repair.<sup>36</sup> Their loss is associated with craniosynostosis. Given the minimal if any benefit and the possibility of injury to multiple sutures (which, given the excessive mobility that sometimes occurs, may not be trivial), Alt-RAMEC cannot be recommended.

For most young children, a facemask is as acceptable as conventional headgear. Contouring an adjustable facemask for a comfortable fit on the forehead is not difficult for most children, with either of the primary designs (see Fig. 13.16). Approximately 350 to 450 gm of force per side is applied for 12 to 14 hours per day. Most children with maxillary deficiency are deficient vertically, as well as anteroposteriorly, which means that a slight downward direction of elastic traction between the intraoral attachment and the facemask frame often is desirable, and some downward and backward mandibular rotation improves the jaw relationship. A downward pull would be contraindicated if lower face height is already large.

A maxillary-deficient child who cooperates with facemask treatment usually shows a noticeable improvement in facial esthetics as the maxilla moves forward more than the mandible (Fig. 13.19), but cephalometric superimposition tracings show that backward displacement of the mandibular incisors and forward displacement of the maxillary teeth also typically occur in response to this type of treatment, and afterward the maxilla may change minimally while the mandible appears to show catch-up growth. Usually some of the Class III correction is lost as the mandible outgrows the maxilla. As children come closer to adolescence, mandibular rotation and displacement of maxillary teeth—not forward movement of the maxilla—are the major components of the treatment result.

A key question is how much of the effect is retained after the adolescent growth spurt. If the mandible grows forward during adolescence and the maxilla doesn't keep pace, orthognathic surgery might still be necessary although the jaw discrepancy was largely corrected before adolescence. Three studies have looked at long-term outcomes of facemask therapy, and all three came to a remarkably similar conclusion: In patients who initially responded well, there is a 25% to 33% chance 8 years later of recurrence of anterior crossbite because of excessive mandibular growth, not because the maxilla relapsed, and most of the patients who experienced this needed orthognathic surgery.<sup>32</sup> Knowing that, how do you deal with informed consent for preadolescent facemask therapy? The message is straightforward: "If we do this treatment, your child is very likely to have a short-term improvement, and there is about a 75% chance of long-term success; but that also means there is about one chance in four that surgery still will be needed later." The parents need to understand that, and if you are the doctor, you want a signed and witnessed copy in your records.

**Facemask Traction to Skeletal Anchorage.** Clearly, a major negative side effect of conventional maxillary protraction is tooth movement that detracts from the skeletal change. With bone screws and miniplates now readily available as temporary implants, skeletal anchorage for maxillary protraction is straightforward. Single alveolar bone screws are not adequate, but a facemask can be attached to miniplates on the anterior maxilla (Fig. 13.20). Although varying results have been reported, three acceptable randomized clinical trials show that greater skeletal change can be obtained with facemasks to skeletal rather than dental anchorage, with 4 to 5 mm of advancement about the limit.<sup>37</sup> The greatest difficulty with this approach is that miniplate placement on the anterior surface of

the maxilla is invasive and bone maturity is not adequate until around age 11, well after the preferred time window for facemask therapy (age 8 to 10).

### **Class III Elastics to Maxillary and Mandibular Miniplates**

The most effective approach to protraction of the maxilla is Class III elastics between bone-supported miniplates at the base of the zygoma above the maxillary molars and the anterolateral surface of the mandible, so that light force is delivered to the jaws rather than the teeth. This method was introduced by De Clerck and coworkers in 2010<sup>38</sup> and has been studied extensively since then.

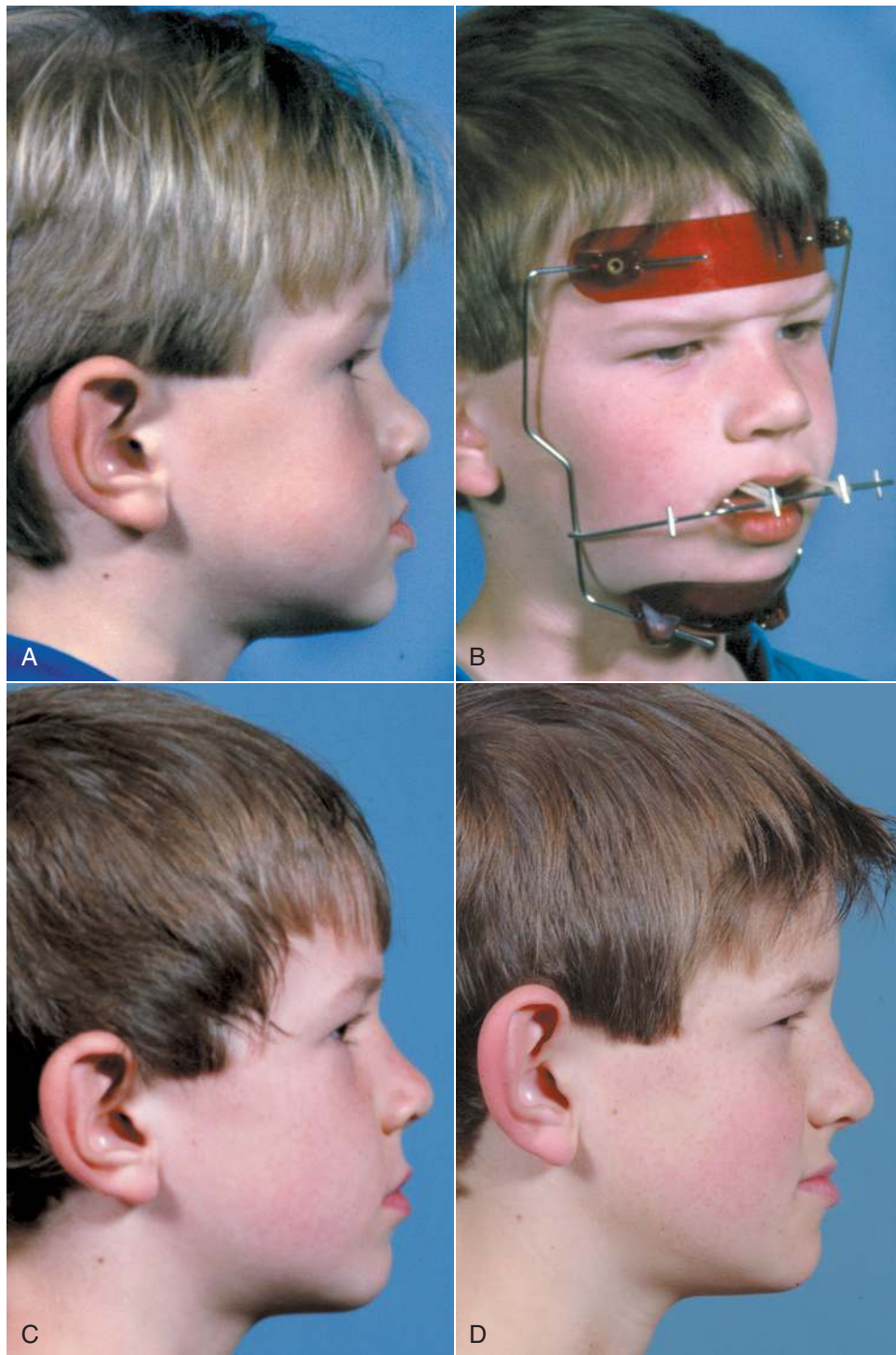
**Sequence and Timing of Treatment.** The first step is placement of the bone anchors, with a three-screw plate at the base of the zygomatic arch and a two-screw plate on the anterolateral surface of the mandible (Fig. 13.21). This requires reflection of a flap and, especially in the maxilla, careful contouring of the surface of the miniplate to follow the curving surface of the bone. It is technique-sensitive and is best done by a surgeon with training and experience in doing this.<sup>39</sup> To reduce the risk of infection at the implant site, it is important to bring the intraoral connector into the mouth just below the upper extent of attached gingiva rather than through mucosa, and the connector should be both smooth and round to minimize soft tissue irritation.

In the timing of treatment, two related factors are important. First, adequate bone density to retain the screws does not develop until approximately age 11; second, the mandibular bone plates should not be inserted until the permanent mandibular canines have erupted, which should not be a problem because they usually erupt at approximately 9 years of age. This means treatment with this method cannot begin until the patient is already too old for a good response to facemask therapy—but it also means that now there is a way to obtain excellent maxillary protraction for patients who are too old to hope for a good response to facemask therapy. With the skeletally anchored Class III elastics, a favorable growth response can be obtained throughout the adolescent growth spurt, so treatment for about 1 year between the ages 12 and 14 is the best plan.

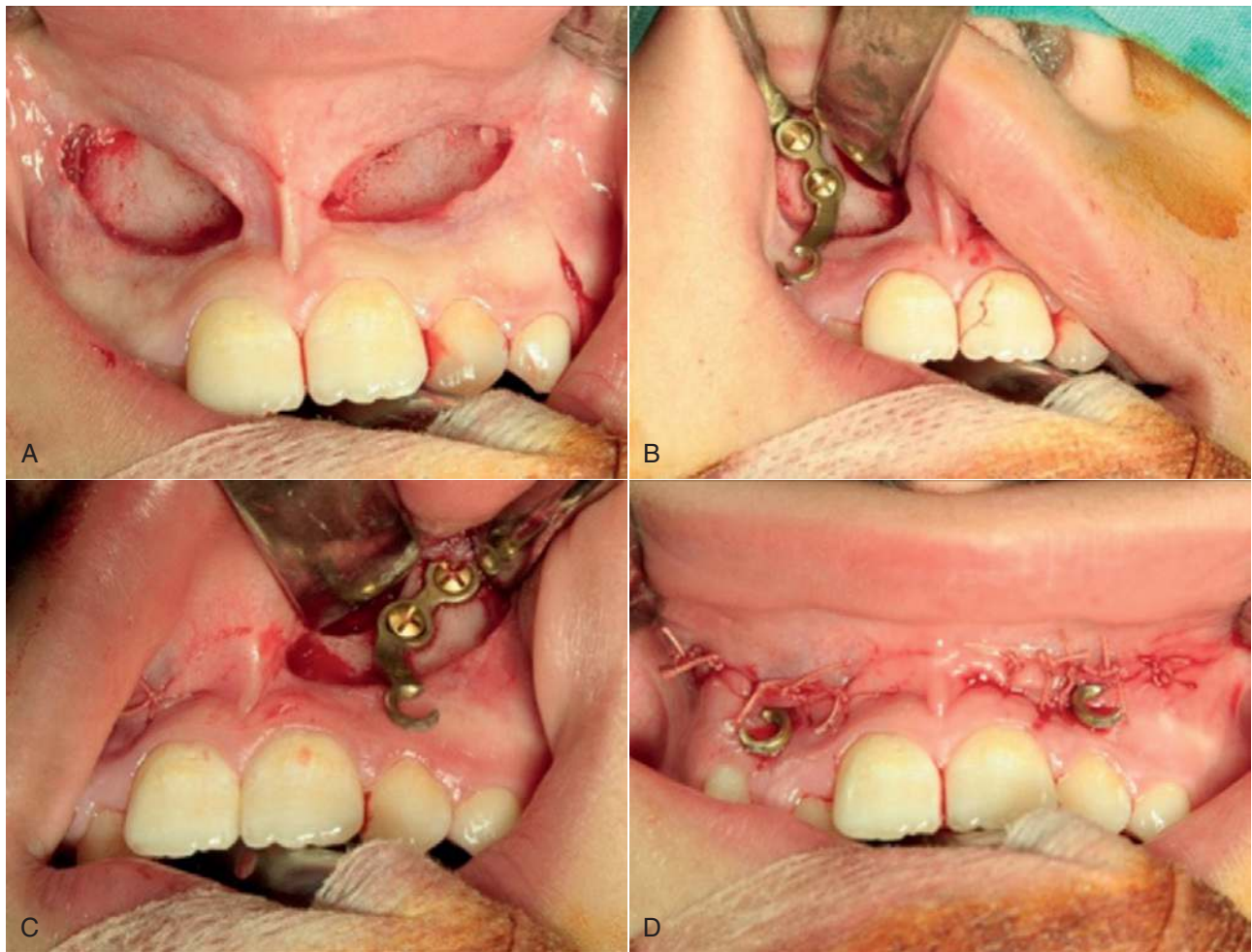
It was once thought that higher force would be needed for moving bones than for moving teeth, but with the nearly continuous Class III elastics, this is not correct. Only light force is needed to obtain the desired growth modification (not more than 250 gm per side; often 150 gm is adequate). With the miniplate anchorage, stability is better if elastic wear begins the day after placement of miniplates. Steady force against the anchors is tolerated better than heavier discontinuous force, so patients should avoid intermittent finger or tongue pressure against the miniplates.

In typical treatment with this method, intermaxillary traction is maintained for about 12 months, which is almost always enough time to correct the jaw discrepancy, and then a second phase of treatment with a fixed orthodontic appliance follows. In these maxillary-deficient patients, often there is insufficient space for the maxillary canines, and because of the forward growth of the maxilla, a Class III or Class I molar occlusion is likely to be transformed into a near-Class II or Class II relationship. The same zygomatic anchors used for growth modification can be used to distalize the maxillary posterior teeth, opening space for the canines and completing nonextraction treatment (Fig. 13.22).<sup>40</sup> It is possible that after debonding, even if this is toward the end of adolescence, some additional growth in the Class III pattern can occur. For that reason, it is wise not to remove the miniplates for another 6 to 12 months (or longer if mandibular growth continues) so that additional elastic wear can be used if needed.

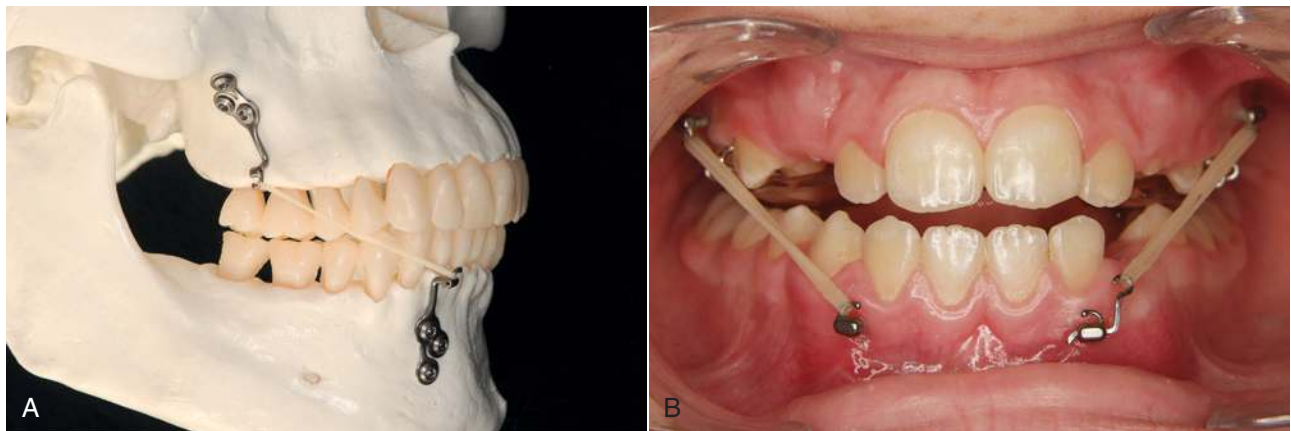




• **Fig. 13.19** If forward traction is applied at an early age, it is possible to produce forward displacement of the maxilla rather than just displacement of teeth. (A) Age 5 years, 2 months before treatment. (B) Age 5-2, wearing a Delaire-type facemask. (C) Age 7-10, at the time facemask treatment was discontinued. Note the increased fullness of the midface. (D) Age 11-3, at the beginning of phase 2 treatment. When facemask treatment is discontinued, there is usually a rebound of mandibular growth similar to what occurred for this patient. Whether surgery eventually will be required will be determined by mandibular growth during and after adolescence. (From Proffit WR, White RP, Sarver DM. *Contemporary Treatment of Dentofacial Deformity*. St. Louis: Mosby; 2003.)

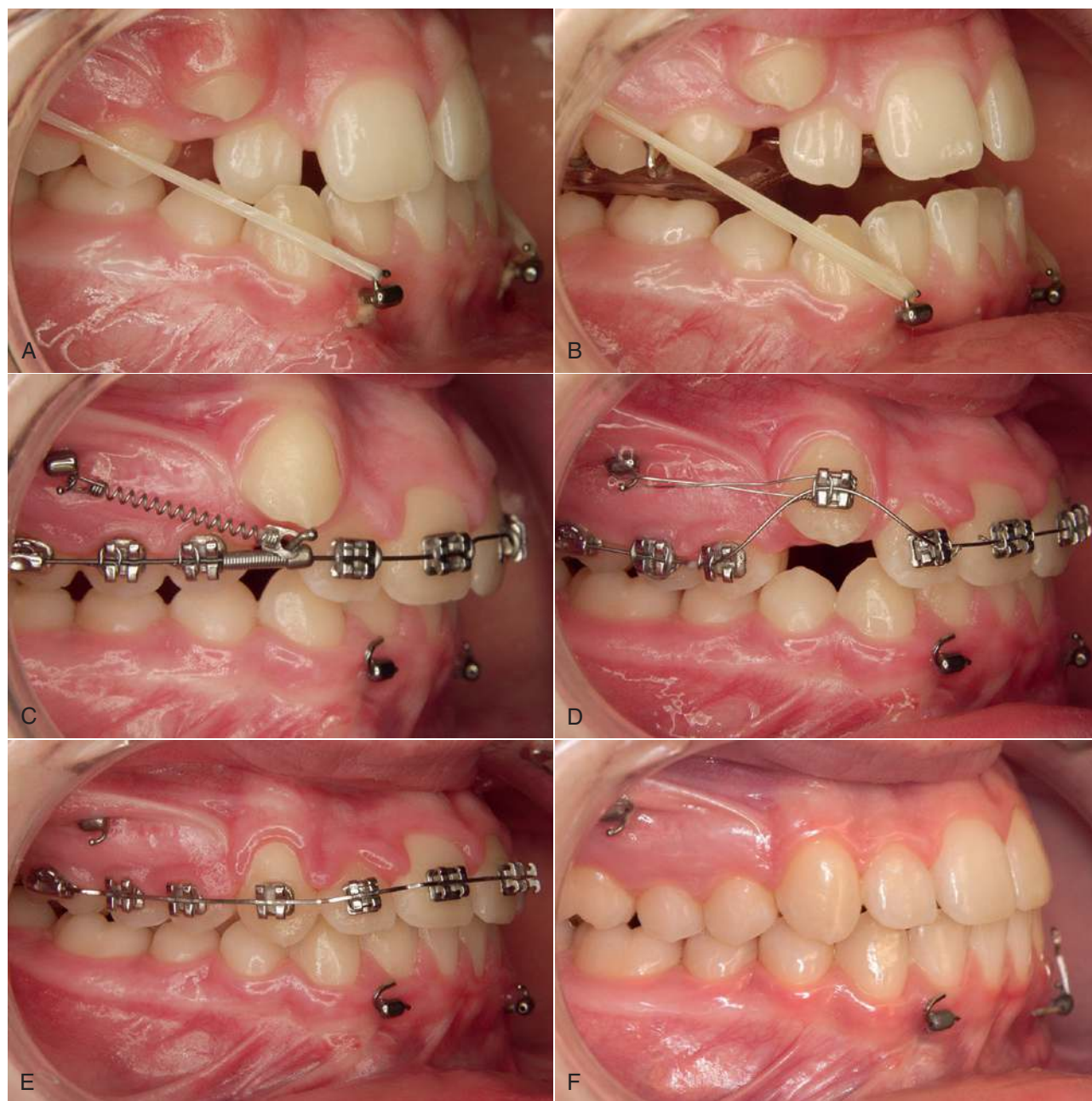

• **Fig. 13.20** Skeletal anchorage for attachment of a facemask for maxillary protraction. (A) Exposure of the anterior surface of the maxilla. (B) and (C) Placement of a miniplate held by with two screws. (D) Attachments for the facemask extending into the anterior vestibule. (From Sar C, Sahinoğlu Z, Özçirpici AA, Uçkan S. *Am J Orthod Dentofac Orthop.* 2014;145:41–54.)



• **Fig. 13.21** (A) Y-shaped miniplates on a skull, to show where they are placed high on the posterior maxilla at the base of the zygomatic arch and on the mandible mesial to the mandibular canines. (B) A maxillary-deficient child wearing Class III elastics to an earlier version of the mandibular miniplates that did not have an upward projection for the elastic hook. An auxiliary 21 × 25 archwire in the tube that penetrated the gingiva allowed adjustment of the position of the attachment for the elastic on the left side so that it did not press against the soft tissue. Being able to move the point to which force is applied, of course, is one of the advantages of miniplates.





• **Fig. 13.22** In typical treatment of Class III problems with a major component of skeletal maxillary deficiency, anterior crossbite is likely to be present initially, even in children in whom some compensatory lingual tipping of mandibular incisors has occurred, and blocked-out maxillary canines also are present. (A) Start of treatment: Note the lateral incisor in crossbite and position of the maxillary canine. (B) Use of a biteplate to unlock the incisors, with use of about 6 ounces (180 gm) of elastic force full-time. (C) to (F) Force from the maxillary implant being used for distalization of the maxillary posterior teeth, making room for the canine and bringing it posteriorly into the occlusion, and end of treatment. This method avoids premolar extraction and places the first molars in normal occlusion, but requires extraction of the maxillary third (or sometimes) second molars. (From DeClerck and Proffit.<sup>40</sup>)

**Comparison With Facemask.** How do these results compare with facemask treatment? In a comparison of facemask patients treated at the University of Michigan using dental anchorage with a group treated with Class III elastics and miniplates in Brussels and at the University of North Carolina,<sup>41</sup> the data were as follows:

- Facemask patients were younger; mean age at start of treatment was 8 years 3 months versus 11 years 10 months for Class III elastics and miniplates.
- Force with facemask was twice as large: 300 to 500 gm versus 150 to 200 gm.



- On average, there was 2.5 to 3 mm more movement of the maxilla with Class III elastics and miniplates.
- Midface changes were not seen with facemask treatment but occurred in 32% of the elastics group (discussed in detail later). In a comparison of skeletally anchored facemask treatment (data from Sar et al)<sup>42</sup> versus the same group of patients with Class III elastics and miniplates:
  - The facemask patients were younger, but the mean age at start of treatment was 10 years 9 months, more than a year older than the Michigan group who had dental anchorage. That reflects the necessity to wait for adequate bone density before beginning traction against the maxillary anterior bone plates, and more recent patients from the same group were 11 years 9 months at the beginning.
  - The data showed that on average there was about twice as much change with the elastics, and about the same amount of change with the skeletally anchored facemask as with the dentally anchored Michigan group.

In a later report,<sup>43</sup> the Sar group reported about 4 mm of advancement with facemask to skeletal anchorage, about the same as they achieved with Class III elastics from stabilized maxillary molars to mandibular miniplates. Both were less than the change with the much higher attachment used by De Clerck.

**Facial Outcomes.** The facial changes that accompany this treatment are far beyond anything seen previously in growth modification in both the amount of change and its extension into the mid-face—but there was considerable variation in the response.

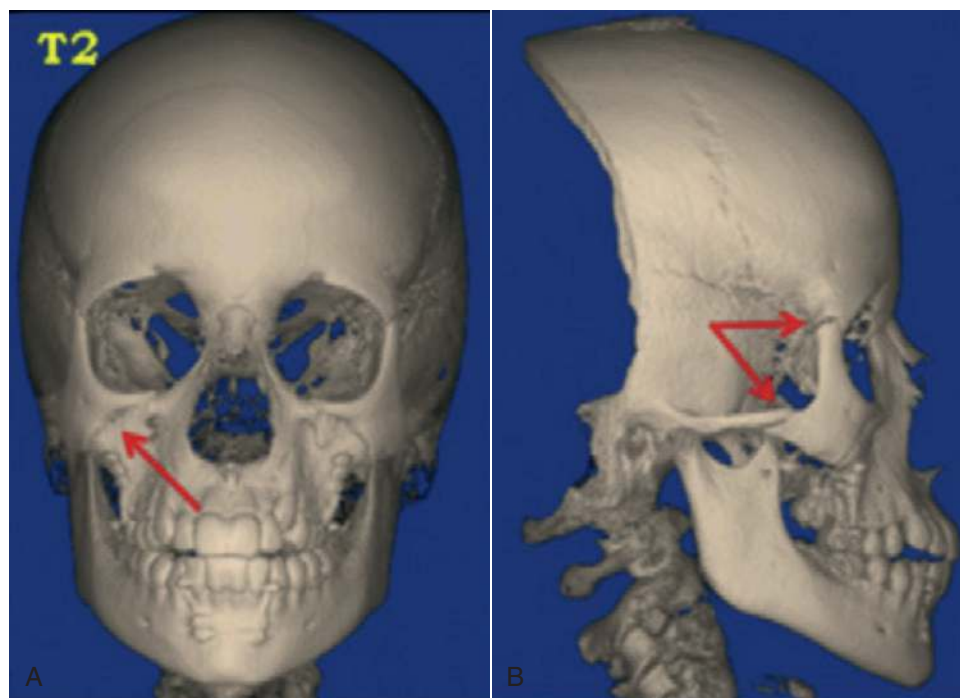
The best way to appreciate this is to view Fig. 13.23, with three-dimensional (3-D) superimpositions showing the treatment change in 25 consecutive patients treated by De Clerck in Brussels.<sup>44</sup> Measurements of changes in various dimensions can be used for statistical analysis, and these changes are statistically significant from changes in untreated patients—but it is much easier to understand the likelihood of significant clinical change when there is variability in the response to treatment by looking at the percentage of patients with each variation.

In Fig. 13.23, the direction of change is shown by the color of various areas, and the amount of change is shown by the intensity of the color. Begin your examination of this figure by looking at the maxillary and midface changes. Note that of the 25 patients, eight (32%) showed more than 4 mm of forward movement of the midface as well as maxillary change (just count the images with dark red that includes the zygomatic arches). That's highly clinically significant. How can that happen? Because sutures above and behind the maxilla are affected by the light consistent force (Fig. 13.24). Note the opening of the zygomaticomaxillary and zygomaticofrontal sutures. These sutures were affected in all the patients who showed midface advancement.

Now note how many other patients had smaller amounts of movement of the maxilla and midface, some of just the maxilla but others with a smaller amount of midface change as well. That's another 12 patients (48%). In contrast, five of the patients (20%) had little or no maxillary change (shown by the green color). (You can also see that four of the five patients with no forward movement



• **Fig. 13.23** Color map cranial base superimposition of 25 consecutive patients treated in Brussels by De Clerck and analyzed at the University of North Carolina by using the method developed by Cevindanes. The red and blue colors show the direction of movement (*red* = forward, out of the screen toward you; *blue* = backward), and the intensity of the color indicates the amount of movement (*dark red or blue* = >4 mm, *lighter red or blue* = 2 to 4 mm).



• **Fig. 13.24** Forward movement of the midface had not been seen previously with Class III traction. The mechanism is opening of the zygomaticomaxillary (A) and zygomaticofrontal (B) sutures, which occurs in about one-third of patients with Class III elastics to miniplates.

of the maxilla showed backward movement of the mandible—that’s discussed later.) The conclusion is that 80% of this group of patients, who would be reasonably representative of northern Europeans and Americans of European descent, had a favorable response, and 32% had a highly favorable response.

Finally, note the number of patients whose mandible grew forward during treatment. These are growing children, and you would expect at least some forward mandibular growth along with the enhanced maxillary growth. But forward movement of the chin happened in only five patients, two of whom showed more than 4 mm of forward growth; and eight showed some backward movement of the chin. In short, what did not happen to the position of the chin in most of those with maxillary growth also is significant.

One thing that isn’t seen in the 3-D aforementioned superimpositions is likely to be noted clinically: When the maxilla is moved forward, a wider part of the maxillary arch comes into occlusion with the mandibular arch, so just the change in the jaw relationship reduces the magnitude of a posterior crossbite. This increases the chance that a posterior crossbite can be managed with archwire expansion. If the crossbite is severe enough that skeletal expansion by opening the midpalatal suture will be required, this should be deferred until the a-p jaw relationship is corrected.

Several other reports of growth changes with posterior maxillary miniplates to mandibular anterior miniplates have appeared, many of which used a lower attachment to the maxilla. With a similar protocol to De Clerck’s, the reported outcomes also are similar.<sup>45</sup>

Given the current emphasis on a possible role for orthodontics in prevention or management of obstructive sleep apnea (see [Chapter 7](#)), could orthopedic forward movement of the maxilla facilitate air flow through the pharyngeal airway? The answer seems to be *no*. Nguyen et al reported that patients who had responded to miniplates and Class III elastics showed no difference in airway

diameter at the “choke point” that determines air flow. The conclusion: Maxillary protraction does no harm to the airway, but sleep apnea is not an indication for it.<sup>46</sup>

**Summary of Maxillary Protraction Experience.** The only Class III functional appliance that attempts to overcome maxillary deficiency is the Frankel FR-III, and its ability to do that is limited.

Maxillary protraction with a facemask at an early age (8 to 10, after first molars and incisors have erupted but before adolescence) usually produces clinical improvement in a patient with Class III malocclusion—but the more the growth pattern is excessive mandibular growth, the greater the chance of long-term recurrence of the problem. After age 10 to 11, facemask therapy largely produces tooth movement and down-back mandibular rotation. We know there are at least six different Class III growth patterns (see [Chapter 4](#)), and probably there are more than that. When current selection criteria are used, follow-up after adolescent growth indicates about a 25% chance of recurrence of anterior crossbite, and many of these patients require orthognathic surgery.

Class III elastics between bone anchors at the base of the zygoma and the anterior surface of the mandible are clearly more effective in protracting the maxilla than facemask therapy, even when the facemask traction is to bone anchors on the maxilla. The miniplates and Class III treatment cannot be done as early as conventional facemask therapy but is effective during adolescent growth. That is a disadvantage if preadolescent treatment is desired, but an advantage if treatment was not sought until early adolescence. The first patients treated during adolescence now are reaching their late teens, but no substantial data for long-term outcomes are available yet. Will some of the patients experience a recurrence because of late mandibular growth? Almost surely. How many? We simply do not know—but the preliminary data are encouraging, and with this method mandibular as well as maxillary growth is affected, as we will see later.

## Mandibular Excess

Children who have Class III malocclusion because of excessive growth of the mandible are extremely difficult to treat. There are three possible treatment approaches: Class III functional appliances, extraoral force to a chin cup, and Class III elastics to skeletal anchors.

### Functional Appliances in Treatment of Excessive Mandibular Growth

Functional appliances for patients with excessive mandibular growth make no pretense of restraining mandibular growth. They are designed to rotate the mandible down and back and guide the eruption of the teeth so that the upper posterior teeth erupt down and forward while eruption of lower teeth is restrained. This rotates the occlusal plane in the direction that favors correction of a Class III molar relationship (see Fig. 13.15). These appliances also tip the mandibular incisors lingually and the maxillary incisors facially, introducing an element of dental camouflage for the skeletal discrepancy.

To produce the working bite for a Class III functional appliance, the steps in preparation of the wax bite, practice for the patient, and use of a guide to determine the correct vertical position are identical to the procedure for patients with Class II problems (discussed in detail in Chapter 14). However, the working bite itself is significantly different: The mandible is rotated open on its hinge axis but is not advanced. This type of bite is easy to obtain because light force can be placed on each side of the mandible to guide the mandible and retrude it.

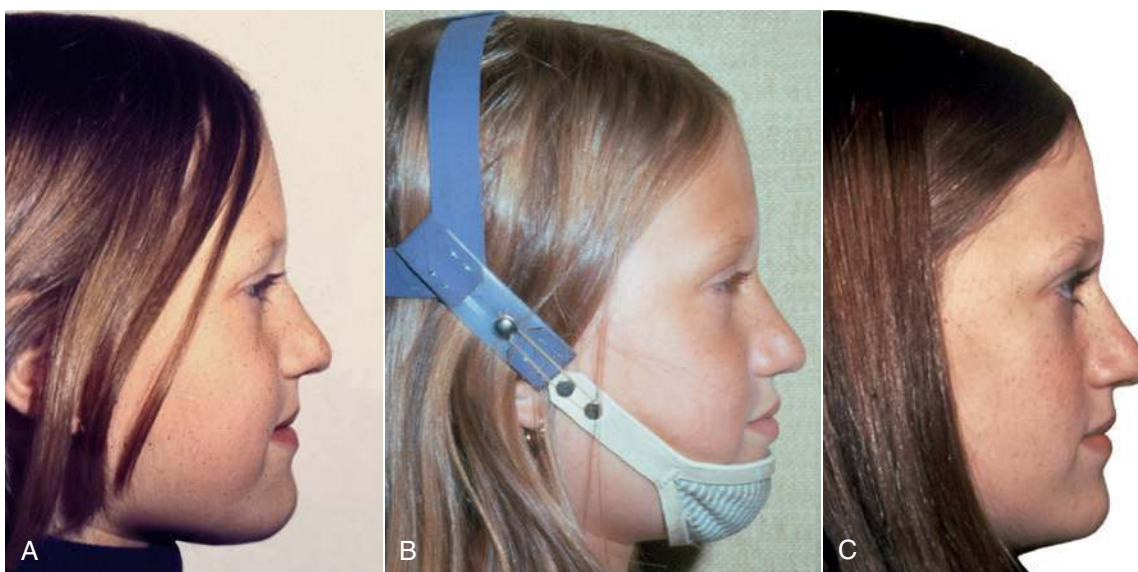
How far the mandible is rotated open depends on the type of appliance and the need to interpose bite blocks and occlusal stops between the teeth to limit eruption. The general guideline is that the mandible should be rotated at least 3 and not more than 5 to 6 mm beyond its postural rest position. If this is not enough or would produce excessive anterior face height, the problem is too severe for functional appliance treatment. As we have noted

previously, Class III functional appliance treatment is applicable only to patients in whom a large and prominent mandible is combined with vertical maxillary deficiency, so that they have both mandibular excess and short anterior face height.

### Chin-Cup Appliances: Restraint of Mandibular Growth?

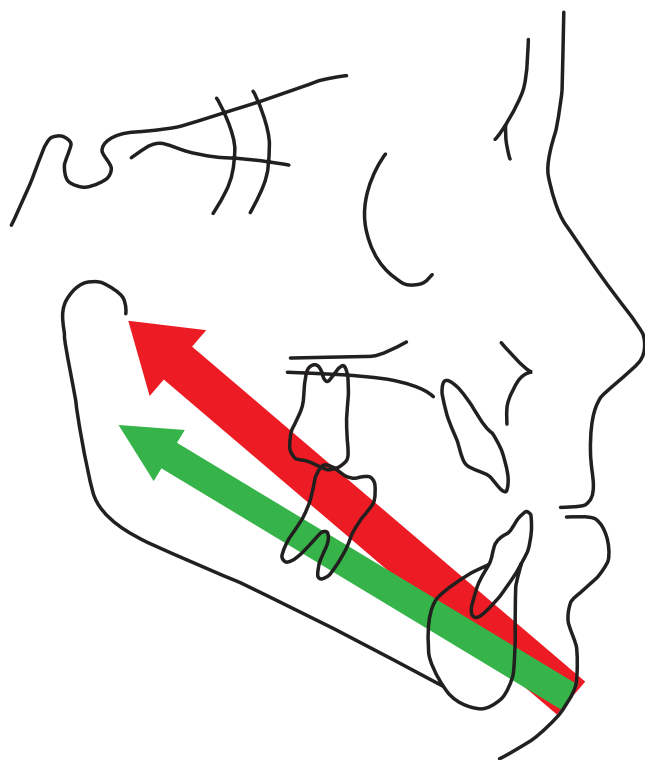
In theory, extraoral force directed against the mandibular condyle would restrain growth at that location, but there is little evidence that this occurs in humans (see Chapter 7). What chin-cup therapy does accomplish is a change in the direction of mandibular growth, rotating the chin down and back, which makes it less prominent but increases anterior face height. The data seem to indicate a transitory restraint of growth that is likely to be overwhelmed by subsequent growth. In essence, the treatment becomes a trade-off between decreasing the anteroposterior prominence of the chin and increasing face height. In addition, lingual tipping of the lower incisors often occurs because the appliance presses on the lower lip and dentition (Fig. 13.25), which often is undesirable.

For chin-cup treatment, a hard plastic cup fitted to a cast of the patient's chin or a soft cup made from an athletic helmet chinstrap can be used. The more the chin cup or strap migrates up toward the lower lip during appliance wear, the more lingual movement of the lower incisors will be produced, so soft cups produce more incisor uprighting than hard ones. The headcap that includes the spring mechanism can be the same one used for high-pull headgear. It is adjusted in the same manner as the headgear. A persistent recommendation through the years has been a force of approximately 16 ounces per side aimed directly at the head of the condyle, on the theory that this would reduce growth. Once it is accepted that mandibular rotation, not growth inhibition, is the major treatment effect, lighter force oriented to produce greater rotation makes more sense (Fig. 13.26). One concern about chin cup treatment always has been the possibility that it could create temporomandibular dysfunction problems. A recent systematic review of the literature indicates that this is not a problem, especially if very heavy force is avoided.<sup>47</sup>



• **Fig. 13.25** A typical response to chin-cup treatment. (A) Pretreatment profile, (B) chin-cup placement, (C) posttreatment profile. This treatment reduces mandibular protrusion primarily by increasing anterior face height, very similar to the effect of Class III functional appliances.





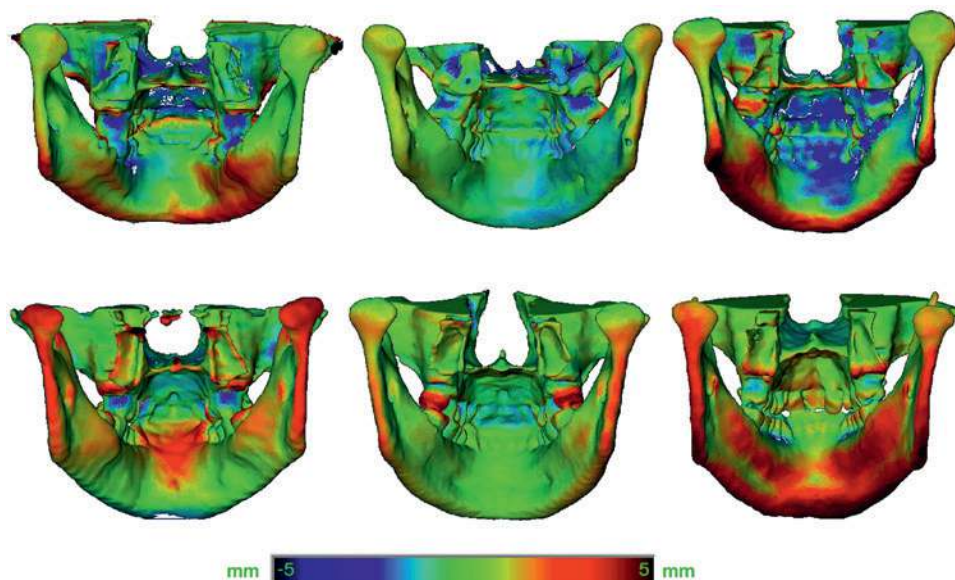
• **Fig. 13.26** The traditional view of chin cup treatment was that heavy force aimed directly at the condyles (*red line*) would correct excessive mandibular growth by inhibiting condylar growth. Now that downward and backward rotation of the mandible is the usual treatment objective, directing a lighter force below the condyles (*green line*) is more tolerable to patients and equally effective. Heavy force with chin cups is no longer recommended.

In essence, chin cup therapy does the same thing as a Class III functional appliance, but offers at least a slim chance of some growth inhibition. For children with a large mandible, chin-cup treatment is essentially transient camouflage. For that reason, it has limited application.

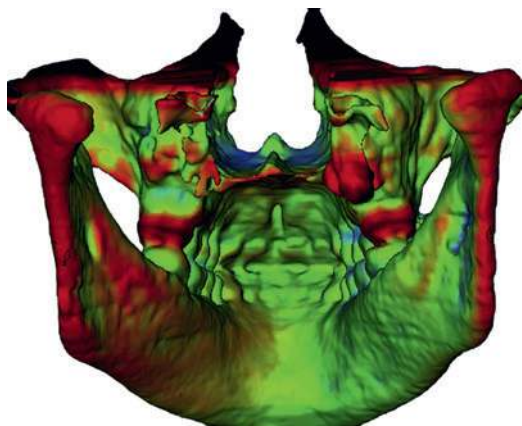
### **Class III Elastics to Skeletal Anchors**

The use of Class III elastics to skeletal anchors as an effective way of producing maxillary protraction was discussed earlier—but this force system also affects the mandible and may eventually provide a way to restrain mandibular growth.<sup>48</sup> Let's begin our evaluation of the mandibular effects by again examining the consecutive cases shown in [Fig. 13.23](#). Four striking effects on the mandible can be observed:

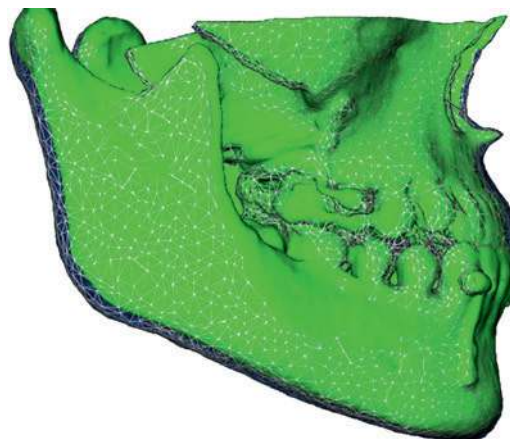
- In three of the patients, the chin moved backward 4 to 5 mm. At first that seems anatomically impossible, but it can (and did) happen by a combination of two things: redirection of vertical growth at the condylar fossa and modeling of both the fossa and condylar head.
- It is important to remember that the point of articulation of the mandible with the temporal bone does grow downward relative to the cranial base. Usually the direction of growth is straight down, and growth in length of the mandible results in projection of the chin. Sometimes the direction of growth has a backward component. This is terribly frustrating when it happens in a skeletal Class II patient (see [Fig. 4.10](#)), but it compensates for growth in length of the mandible in a Class III patient.
- With the 3-D superimpositions, it is possible to remove the other structures and view the jaws from the rear ([Fig. 13.27](#)). You can visualize backward movement of the condyles in two of these patients and see that in one the chin moved



• **Fig. 13.27** With the three-dimensional cranial base superimpositions, it is possible to remove the structures behind the mandibular condyles and observe their direction of change. The red color again indicates movement out of the screen toward you—and what you see is that in one of these six patients, the condyles moved backward more than 4 mm, and in another there was 2 to 4 mm of backward movement.



• **Fig. 13.28** In this patient you see another unexpected finding with the three-dimensional superimpositions, a lack of forward growth of the chin in a patient in whom forward growth of the mandible would be expected. As you see here, the chin remained in its previous position (green = no growth) while the ramus and condylar processes moved back. A lack of forward projection of the chin was seen in more than 80% of these patients.



• **Fig. 13.29** This detailed superimposition of the mandibular change in a typical patient is still another unexpected finding: what amounts to a bending of the mandible at the gonial angle, so the chin is not projected forward as much as it would have been if the inclination of the ramus to the mandibular body had not been changed by the pattern of modeling with the consistent Class III elastic force.

back, and in the other it stayed in the same place. Backward repositioning of the joint contributed to this.

- Modeling of the condyles goes on throughout life, is part of the response to orthognathic surgery, and occurs during growth modification. Modeling on the interior surface of the condylar fossa also occurs in some patients.
- Significant forward movement of the mandible, which would have been expected in this adolescent group, did not occur in 80% of these patients. What did occur in most of them was what you see in more detail in Fig. 13.28: an increase in mandibular length, with the chin staying where it was (green) and mandibular growth expressed as backward movement of the condyles (red). In short, there was a component of inhibition of mandibular growth in far more patients than those who showed backward movement of the chin.
- An unusual pattern of mandibular modeling, with slight backward movement of the condyles and ramus and a decrease in the gonial angle and mandibular plane angle (Fig. 13.29), also occurred in the majority of the patients—a bending of the mandible that would limit forward movement of the chin although growth was occurring.<sup>49</sup>

Does this pattern of change mean that the De Clerck method could be used as much to inhibit mandibular growth as facilitate maxillary growth? Perhaps—but it remains true that the most likely and largest change in treatment was stimulation of forward growth of the maxilla, and that would not be desired in treatment of true mandibular prognathism. As more data for outcomes in relation to patient characteristics become available, it should be possible to better predict whether treatment of an individual will have a greater or lesser effect on mandibular growth.

### Summary

Controlling excessive mandibular growth remains the greatest challenge in orthodontics. Of the three possibilities:

- Mandibular functional appliances offer no possibility of inhibiting the excessive growth. They are capable only of downward–backward rotation of the mandible, which risks creating a long-face problem.

- Backward force against the mandible via chin cups attached to high-pull headgear also offers little beyond downward–backward mandibular rotation. Why is this so ineffective? Probably because successful growth modification requires light force with a long duration, and chin cups deliver heavy force for short durations.
- Class III elastics from miniplates at the base of the zygoma to the anterior surface of the mandible now have been shown to significantly change the pattern of mandibular growth. This includes a lack of forward growth, the possibility of backward movement of the chin, and a reshaping of the mandible with an increase in the gonial angle—that is, an uprighting of the ramus relative to the body of the mandible. Because most skeletal Class III patients have a component of both maxillary deficiency and mandibular excess, the effect on both jaws is an improvement over changing the growth of just one.

For patients whose problem is primarily excessive mandibular growth, there are two potential problems in using this method: effects on the maxilla that may go beyond what is desired, and no data for the extent to which further growth after treatment will lead to a recurrence of the problem. The first problem will be manageable when maxillary versus mandibular effects of treatment become more predictable; data for the second will determine the indications for mandibular growth modification versus orthognathic surgery.

### References

1. Nimkarn Y, Miles PG, O'Reilly MT, et al. The validity of maxillary expansion indices. *Angle Orthod.* 1995;65:321–326.
2. Adkins MD, Nanda RS, Currier GF. Arch perimeter changes on rapid palatal expansion. *Am J Orthod.* 1990;97:10–19.
3. Kilic N, Kiki A, Oktay H. Condylar asymmetry in unilateral posterior crossbite patients. *Am J Orthod Dentofacial Orthop.* 2008;133:382–387.
4. Sandikcioglu M, Hazar S. Skeletal and dental changes after maxillary expansion in the mixed dentition. *Am J Orthod Dentofacial Orthop.* 1997;111:321–327.

5. Agostino P, Ugolini A, Signori A, et al. Orthodontic treatment for posterior crossbites. *Cochrane Database Syst Rev*. 2014;(8):Art. No.: CD000979.
6. Filho R, Ruellas A. Long-term maxillary changes in patients with skeletal Class II malocclusion treated with slow and rapid palatal expansion. *Am J Orthod Dentofacial Orthop*. 2008;134:383–388.
7. Petré S, Bjérklín K, Bondemark L. Stability of unilateral posterior crossbite correction in the mixed dentition: a randomized clinical trial with a 3-year follow-up. *Am J Orthod Dentofacial Orthop*. 2011;139:e73–e81.
8. Chang JY, McNamara JA Jr, Herberger TA. A longitudinal study of skeletal side effects induced by rapid maxillary expansion. *Am J Orthod Dentofacial Orthop*. 1997;112:330–337.
9. Reed N, Ghosh J, Nanda RS. Comparison of treatment outcomes with banded and bonded RPE appliances. *Am J Orthod Dentofacial Orthop*. 1999;116:31–40.
10. Baccetti T, Franchi L, Cameron CG, McNamara JA Jr. Treatment timing for rapid maxillary expansion. *Angle Orthod*. 2001;71:343–350.
11. Angelieri F, Cevidanes LHS, Franchi L, et al. Midpalatal suture maturation: classification method for individual assessment before rapid maxillary expansion. *Am J Orthod Dentofacial Orthop*. 2013;144:759–769.
12. Grünheid T, Larson CE, Larson BE. Midpalatal suture density ratio: a novel predictor of skeletal response to rapid maxillary expansion. *Am J Orthod Dentofacial Orthop*. 2017;151:267–276.
13. Leonardi R, Sicurezza E, Cutrera A, et al. Changes of circumaxillary sutures in young patients treated with rapid maxillary expansion. *Angle Orthod*. 2011;81:36–41.
14. Akkaya S, Lorenzon S, Ucem TT. Comparison of dental arch and arch perimeter changes between bonded rapid and slow maxillary expansion procedures. *Eur J Orthod*. 1998;20:255–261.
15. Geran RG, McNamara JA, Baccetti T, et al. A prospective long-term study on the effects of rapid maxillary expansion in the early mixed dentition. *Am J Orthod Dentofacial Orthop*. 2006;129:631–640.
16. McNamara JA, Baccetti T, Franchi L, et al. Rapid maxillary expansion followed by fixed appliances: a long-term evaluation of changes in arch dimensions. *Angle Orthod*. 2003;73:344–353.
17. Liou EJ, Tsai WC. A new protocol for maxillary protraction in cleft patients: repetitive weekly protocol of alternate rapid maxillary expansions and constrictions. *Cleft Palate Craniofac J*. 2005;42:121–127.
18. Yilmaza BS, Kucukkes N. Skeletal, soft tissue, and airway changes following the alternate maxillary expansions and constrictions protocol. *Angle Orthod*. 2015;85:117–126.
19. Lagravère MO, Carey J, Heo G, et al. Transverse, vertical, and anteroposterior changes from bone-anchored maxillary expansion vs traditional rapid maxillary expansion: a randomized clinical trial. *Am J Orthod Dentofacial Orthop*. 2010;137:304.e1–304.e12.
20. Hourfar J, Kinzinger GS, Ludwig B, et al. Differential treatment effects of two anchorage systems for rapid maxillary expansion: a retrospective cephalometric study. *J Orofac Orthop*. 2016;77:314–324.
21. Lin L, Ahn HW, Kim SJ, et al. Tooth-borne vs bone-borne rapid maxillary expanders in late adolescence. *Angle Orthod*. 2015;85:253–262.
22. Bazargani F, Jönson-Ring I, Nevéus T. Rapid maxillary expansion in therapy-resistant enuretic children: an orthodontic perspective. *Angle Orthod*. 2016;86:481–486.
23. Smith T, Ghoneima A, Stewart K, et al. Three-dimensional computed tomography analysis of airway volume changes after rapid maxillary expansion. *Am J Orthod Dentofacial Orthop*. 2012;141:618–626.
24. Hakan E, Palomo JM. Three-dimensional evaluation of upper airway following rapid maxillary expansion: a CBCT study. *Angle Orthod*. 2014;84:265–273.
25. Compadretti GC, Tasca I, Bonetti GA. Nasal airway measurements in children treated by rapid maxillary expansion. *Am J Rhinol*. 2006;20:385–393.
26. Pirelli P, Saponara M, Guilleminault C. Rapid maxillary expansion in children with obstructive sleep apnea syndrome. *Sleep*. 2004;27:761–766.
27. Villa MP, Malagola C, Pagani J, et al. Rapid maxillary expansion in children with obstructive sleep apnea syndrome: 12 months follow-up. *Sleep Med*. 2007;8:128–134.
28. Villa MP, Rizzoli A, Miano S, Malagola C. Efficacy of rapid maxillary expansion in children with obstructive sleep apnea syndrome: 36 months of follow-up. *Sleep Breath*. 2011;15:179–184.
29. Davidovitch M, Efstathiou S, Sarne O, Vardimon AD. Skeletal and dental response to rapid maxillary expansion with 2- versus 4-band appliances. *Am J Orthod Dentofacial Orthop*. 2005;127:483–492.
30. Levin AS, McNamara JA Jr, Franchi L, et al. Short-term and long-term treatment outcomes with the FR-3 appliance of Fränkel. *Am J Orthod Dentofacial Orthop*. 2008;134:513–524.
31. Ulgen M, Firatli S. The effects of the Fränkel's function regulator on the Class III malocclusion. *Am J Orthod Dentofacial Orthop*. 1994;105:561–567.
32. Wells AW, Sarver DM, Proffit WR. Long-term efficacy of reverse-pull headgear therapy. *Angle Orthod*. 2006;76:915–922.
33. Vaughn GA, Mason B, Moon HB, et al. The effects of maxillary protraction therapy with or without rapid palatal expansion: a prospective, randomized clinical trial. *Am J Orthod Dentofacial Orthop*. 2005;128:299–309.
34. Halicioglu K, Yavuz I, Ceylan I, Erdem A. Effects of face mask treatment with and without rapid maxillary expansion in young adult subjects. *Angle Orthod*. 2014;84:853–861.
35. Liu W, Zhou Y, Wang X, Liu D, Zhou S. Effect of maxillary protraction with alternating rapid palatal expansion and constriction vs expansion alone in maxillary retrusive patients: a single-center, randomized controlled trial. *Am J Orthod Dentofacial Orthop*. 2015;148:641–651.
36. Zhao H, Feng J, Ho TV, Grimes W, et al. The suture provides a niche for mesenchymal stem cells of craniofacial bones. *Nat Cell Biol*. 2015;17:386–396.
37. Cordasco G, Matarese G, Rustico L, et al. Efficacy of orthopedic treatment with protraction facemask on skeletal Class III malocclusion: a systematic review and meta-analysis. *Orthod Craniofac Res*. 2014;17:133–143.
38. De Clerck H, Cevidanes L, Baccetti T. Dentofacial effects of bone-anchored maxillary protraction: a controlled study of consecutively-treated Class III patients. *Am J Orthod Dentofacial Orthop*. 2010;138:577–581.
39. Cornelis MA, Scheffler NR, Mahy P, et al. Modified miniplates for temporary skeletal anchorage in orthodontics: placement and removal surgeries. *J Oral Maxillofac Surg*. 2008;66:1349–1445.
40. De Clerck H, Proffit WR. Growth modification of the face: a current perspective with emphasis on Class III treatment. *Am J Orthod Dentofacial Orthop*. 2015;148:37–46.
41. Cevidanes L, Baccetti T, Franchi L, et al. Comparison of two protocols for maxillary protraction: bone anchors versus face mask with rapid maxillary expansion. *Angle Orthod*. 2010;80:799–806.
42. Sar C, Arman-Özçirpici A, Uçkan S, et al. Comparative evaluation of maxillary protraction with or without skeletal anchorage. *Am J Orthod Dentofacial Orthop*. 2011;139:636–649.
43. Sar C, Sahinoğlu Z, Özçirpici AA, Uçkan S. Dentofacial effects of skeletal anchored treatment modalities for the correction of maxillary retrognathia. *Am J Orthod Dentofacial Orthop*. 2014;145:41–54.
44. Nguyen T, Cevidanes L, Cornelis MA, et al. 3D assessment of maxillary changes associated with bone anchored maxillary protraction. *Am J Orthod Dentofacial Orthop*. 2011;140:790–798.
45. Elnagar MH, Elshourbagy E, Ghobashy S, et al. Comparative evaluation of 2 skeletally anchored maxillary protraction protocols. *Am J Orthod Dentofacial Orthop*. 2016;150:751–762.
46. Nguyen T, De Clerck H, Wilson M, Golden B. Effect of Class III bone anchor treatment on airway. *Angle Orthod*. 2015;85:591–596.



47. Zurfluh MA, Kloukos D, Patcas R, Eliades T. Effect of chin-cup treatment on the temporomandibular joint: a systematic review. *Eur J Orthod*. 2015;37:314–324.
48. De Clerck HJ, Nguyen T, de Paula LK, Cevdanes L. Three-dimensional assessment of mandibular and glenoid fossa changes after bone-anchored Class III intermaxillary traction. *Am J Orthod Dentofacial Orthop*. 2012;142:25–32.
49. Nguyen T, Cevdanes L, Paniagua B, et al. Use of shape correspondence analysis to quantify skeletal changes associated with bone-anchored Class III correction. *Angle Orthod*. 2014;84:329–336.

# 14

## Growth Modification in Class II, Open Bite/Deep Bite, and Multidimensional Problems

### CHAPTER OUTLINE

#### Class II Growth Modification

- Evolution of Class II Growth Modification Treatment Strategies
- Perspectives on Growth Modification
- Functional Appliances
- Headgear
- Functional Appliances Versus Headgear: Some Clarity From Randomized Clinical Trials
- Fixed Class II Correctors: Another Class II Treatment Approach
- Components of Removable and Fixed Class II Functional Appliances
- Clinical Management of Functional Appliances

#### Combined Vertical and Anteroposterior Problems

- Short Face/Deep Bite
- Long Face/Open Bite

#### Facial Asymmetry in Children

- Asymmetric Mandibular Deficiency
- Asymmetric Mandibular Excess

### Class II Growth Modification

Patients with a Class II growth pattern have some combination of deficient forward mandibular growth and excessive maxillary growth that is more likely to be downward than forward. For growing patients, stimulation of forward mandibular growth or restraint of maxillary growth in both directions would be ideal treatment. Alternatively, if the facial appearance is acceptable except for protruding maxillary incisors, mild or moderate Class II skeletal relationships can be accepted and the teeth moved with or without extraction to fit together. This is a solution more often chosen in slow or nongrowing adolescent or postadolescent patients and, although outlined here, is discussed in detail in [Chapter 16](#).

#### Evolution of Class II Growth Modification Treatment Strategies

In the early years of the 20th century, it was all but taken for granted that pressure against the growing face could change the

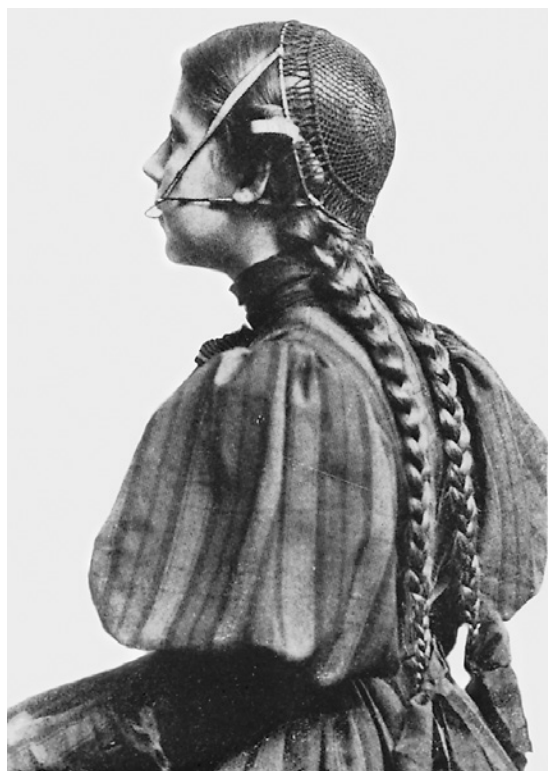way it grew. Extraoral force to the maxilla (headgear) was used by the pioneer American orthodontists ([Fig. 14.1](#)), who found it reasonably effective. This method of treatment was later abandoned, not because it did not work, but because Angle and his contemporaries thought that Class II elastics (from the lower molars to the upper incisors) would cause the mandible to grow forward and that this would produce an easier and better correction. If intraoral elastics could produce a true stimulation of mandibular growth while simultaneously restraining the maxilla, there would be no need to ask a patient to wear an extraoral appliance, nor would there be any reason to begin treatment until the permanent teeth were available.

With the advent of cephalometric analysis, it became clear that interarch elastics corrected Class II malocclusion much more by displacing the mandibular teeth mesially than by stimulating mandibular growth. Even if the lack of desired change in jaw relationships is overlooked, correcting a skeletal Class II problem in this way is undesirable because the protruding lower incisors tend to upright after treatment, and then lower incisor crowding and overjet return. Because of this, these methods, and with them the idea of mandibular growth stimulation, fell into disrepute in the United States.

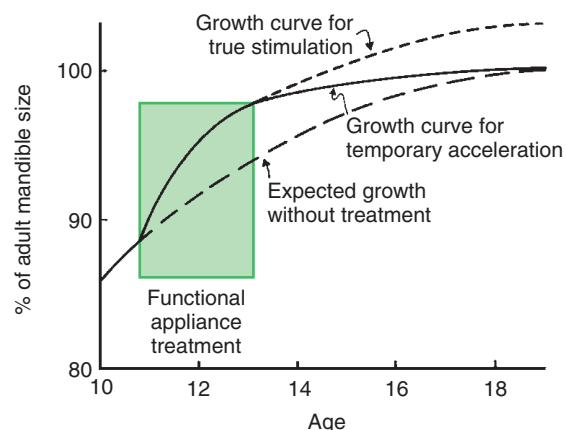
### Perspectives on Growth Modification

Growth stimulation versus restraint can be viewed in two ways: (1) as the attainment of a final size larger than would have occurred without treatment or (2) as the occurrence of more growth during a given period than would have been expected without treatment. [Fig. 14.2](#) is a hypothetical plot of the response to functional appliance treatment, illustrating the difference between absolute stimulation (larger as an adult) and temporal stimulation (acceleration of growth). The more you believe in absolute stimulation, the more enthusiastic you are likely to be about “growing mandibles,” and vice versa.

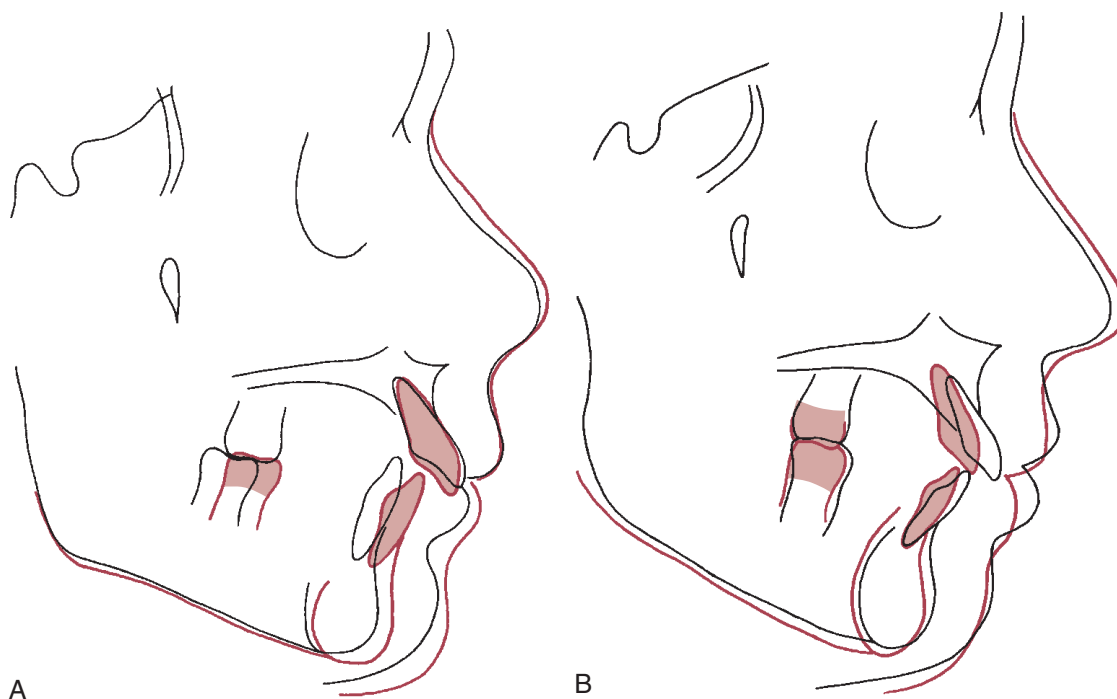
As the figure suggests, an acceleration of growth often occurs when a functional appliance is used to treat mandibular deficiency, but the final size of the mandible is little if at all larger than it would have been without the treatment.<sup>1</sup> Cephalometric superimposition often shows more mandibular growth in the first months of functional appliance treatment than would have been expected ([Fig. 14.3](#)). This is likely to be followed by a decrease in growth later, so although the mandible grew faster than normal for a while, later growth was slower than would have been expected and the



• **Fig. 14.1** Extraoral force to the maxilla was used for Class II correction in the late 1800s and then abandoned, not because it was ineffective, but because the pioneer orthodontists thought that intraoral elastics produced the same effect. (From Angle EH. *Treatment of Malocclusion of the Teeth*. 7th ed. Philadelphia, PA: SS White Manufacturing Co; 1907.)



• **Fig. 14.2** The difference between growth acceleration in response to a functional appliance and true growth stimulation can be represented on a growth chart. If growth occurs at a faster-than-expected rate while a functional appliance is being worn and then continues at the expected rate thereafter so the ultimate size of the jaw is larger, true stimulation has occurred. If faster growth occurs while the appliance is being worn, but slower growth thereafter ultimately brings the patient back to the line of expected growth, there has been an acceleration, not a true stimulation. Although there is a great deal of individual variation, the response to a functional appliance most often is similar to the solid line in this graph, although some claim stimulation when treatment is performed in conjunction with the adolescent growth spurt.



• **Fig. 14.3** (A) Cephalometric superimposition during treatment with a functional appliance (activator), showing excellent downward and forward mandibular growth between ages 11 and 13. (B) Cephalometric superimpositions for same patient between ages 13 and 15, during fixed appliance therapy for final positioning of teeth. For this patient, the growth response to the activator was much more an acceleration than a true stimulation, as revealed by more growth than expected at first, and less growth later; yet the activator phase of treatment was quite successful in improving the jaw relationship.

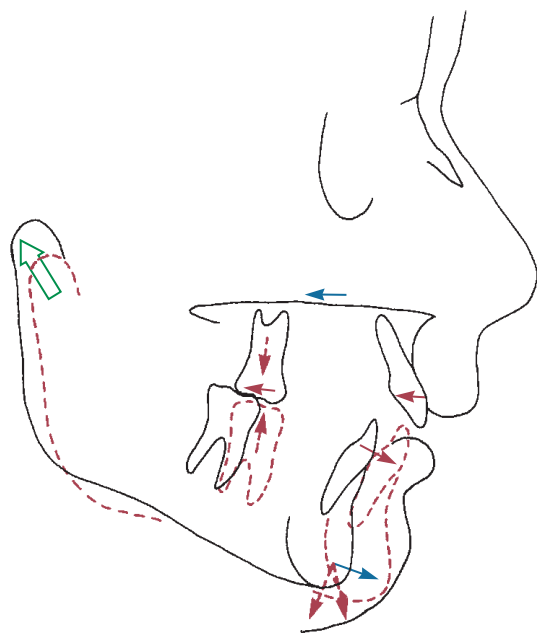


ultimate size of the mandible in treated and untreated patients is similar.

Some published data suggest that timing mandibular growth modification to coincide with the mandibular growth spurt can provide growth change beyond what usually occurs.<sup>2</sup> These data are usually tied to determining the growth spurt timing from the level of maturation of the cervical vertebrae, a method that has supporters and detractors (see [Chapter 7](#)).

## Functional Appliances

By definition, a functional appliance is one that changes the posture of the mandible and causes the patient to hold it open and/or forward for Class II correction or back or open for Class III correction. In fact, these appliances also can affect the maxilla and the teeth in both arches. When the mandible is held forward, the elastic stretch of soft tissues produces a reactive effect on appliances that hold it forward. If the appliance contacts the teeth, this reactive force produces an effect like that of Class II elastics, moving the lower teeth forward and the upper teeth back, and rotating the occlusal plane. In addition, even if contact with the teeth is minimized, soft tissue elasticity can create a restraining force on forward growth of the maxilla, so that a “headgear effect” is observed ([Fig. 14.4](#)). Any combination of these effects can be observed after functional appliance treatment.



• **Fig. 14.4** The potential effects of functional appliance therapy for correction of a Class II skeletal malocclusion are illustrated here. The most desirable and variable effect is for the mandible to increase in length by growth at the condyles (green arrow), which may be accompanied by repositioning the articular fossa by apposition of bone on its posterior wall. The “headgear effect” (blue arrow) restrains the maxilla and the maxillary teeth, and holding the mandible forward often creates forces against the lower teeth that cause anterior movement of the mandibular dentition. The direction in which mandibular growth is expressed, forward (blue arrow) and/or inferiorly, is most related to the eruption of the molars. If the molars erupt more than the ramus grows in height (dashed lines), the forward mandibular change will be negated and the Class II malocclusion will not improve.

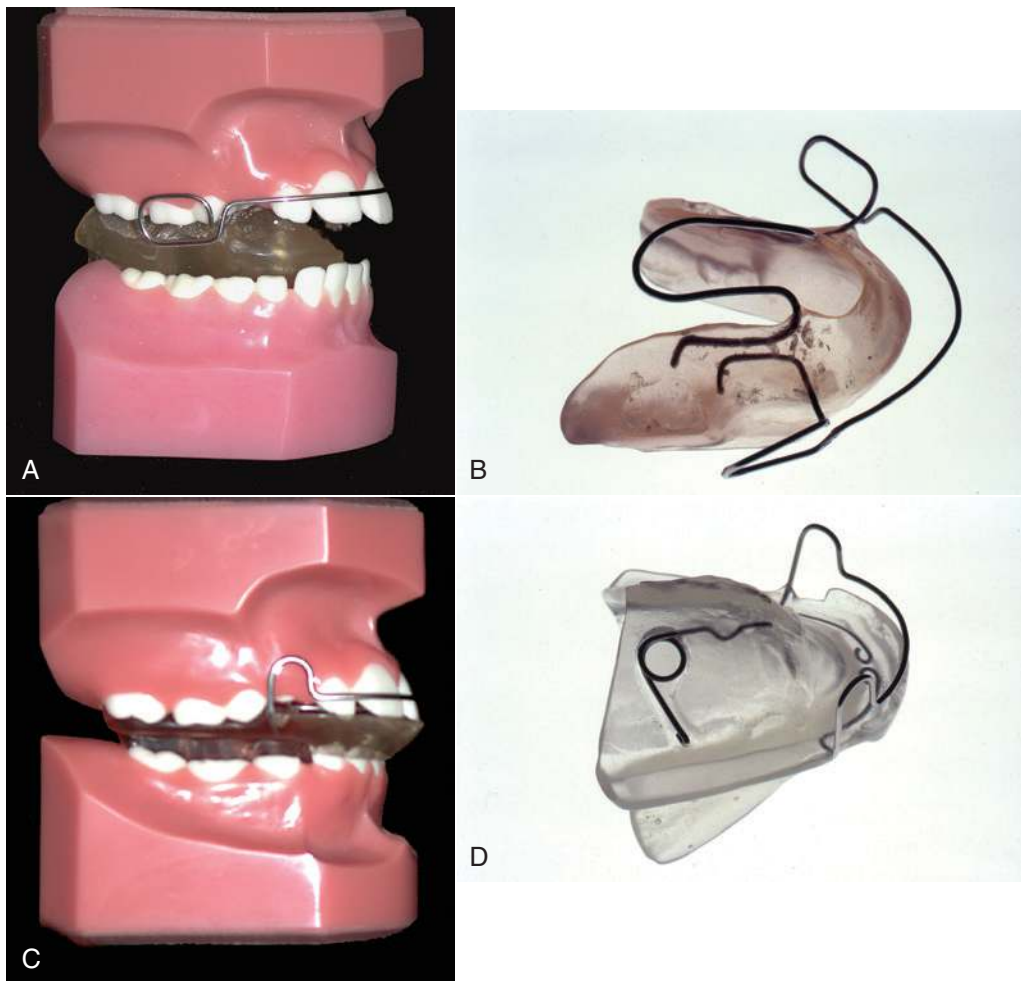
The monobloc developed by Robin in the early 1900s is generally considered the forerunner of all functional appliances, but the activator developed in Norway by Andresen in the 1920s was the first functional appliance to be widely accepted. Both the appliance system and its theoretical underpinnings were improved and extended elsewhere in Europe, particularly by the German school led by Haupl.

Functional appliances were introduced into American orthodontics in the 1960s through the influence of orthodontic faculty members with a background in Europe (of whom Egil Harvold was prominent) and later from personal contact by a number of American orthodontists with their European counterparts. The most popular were the Bionator ([Fig. 14.5](#)) and the Frankel appliance ([Fig. 14.6](#)). A major boost to functional appliance treatment in the United States came from the publication of animal experiment results in the 1970s, which showed that skeletal changes really could be produced by posturing the mandible to a new position and held out the possibility that true stimulation of mandibular growth could be achieved.

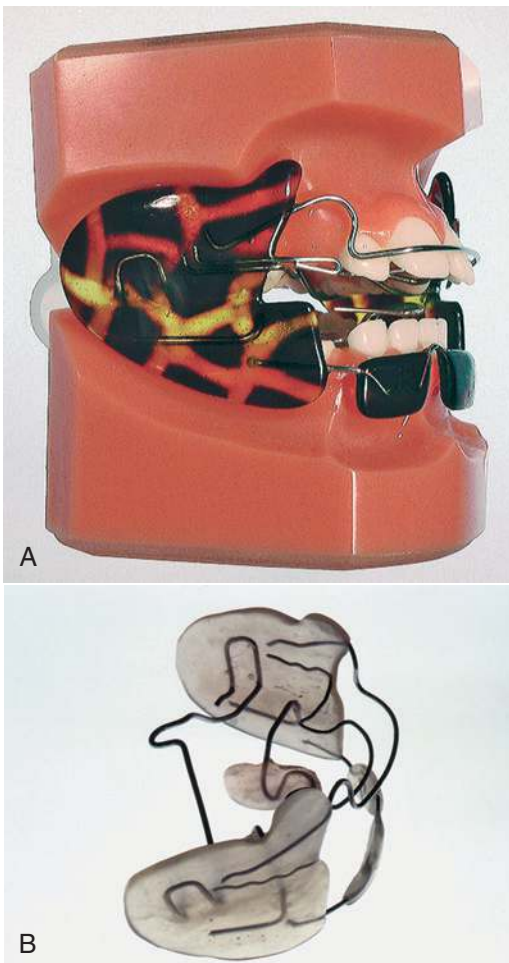
With functional appliances, additional growth is supposed to occur in response to the movement of the mandibular condyle out of the fossa, mediated by reduced pressure on the condylar tissues or by altered muscle tension on the condyle ([Fig. 14.7](#)). Although an acceleration of mandibular growth can occur and has been demonstrated now in several clinical trials,<sup>3</sup> a long-term increase in size is difficult to demonstrate. What does happen for patients with Class II relationships is (1) a modest change in the size of the mandible’s overall length, which, taken over several types of appliances, averaged 0.16 mm per month (range, 0.09 to 0.24 mm per month),<sup>4</sup> and (2) often a reorientation of the maxilla and the mandible, usually facilitated by a clockwise tipping of the occlusal plane ([Fig. 14.8](#)) and a rotation of the maxilla, the mandible, or both. A reduction in forward growth of the maxilla also occurs with Class II functional appliances (the “headgear effect”). This is typically less than 1 mm per year.<sup>5</sup> Although the Twin-Block appliance is reputed to be quite successful in stimulating mandibular growth in preadolescents, published data show that it is equally successful at the peak of the growth spurt as when used early,<sup>6</sup> and the changes it produces are a combination of skeletal (40%) and dental (60%). The dental change is largely a strong effect of Class II elastics—that is, forward movement of the lower arch and distal tipping of the upper incisors (25%).

Functional appliances also can influence eruption of posterior and anterior teeth. It is possible to level an excessive curve of Spee in the lower arch by blocking eruption of the lower incisors while leaving the lower posterior teeth free to erupt. If upper posterior teeth are prohibited from erupting and moving forward while lower posterior teeth are erupting up and forward, the resulting rotation of the occlusal plane and forward movement of the dentition will contribute to correction of the Class II dental relationship. This is another effect of most functional appliance treatment for Class II problems (see [Fig. 14.8](#)). These changes combined with the previously mentioned skeletal effects provide the ability to correct Class II malocclusions—and show that the correction inevitably has a considerable component of tooth movement in addition to growth modification.

It is important to keep in mind that eruption of posterior teeth in a mandibular-deficient patient is beneficial only when good vertical growth is occurring. More eruption of posterior teeth than growth of the ramus causes mandibular growth to be projected more downward than forward. In patients who have a tendency toward vertical rather than anteroposterior growth even without



• **Fig. 14.5** (A) The Bionator is tooth-borne and induces mandibular advancement with contact of lingual flanges with the lingual mucosa. It usually has a buccal wire to maintain the lips off the teeth and can incorporate bite blocks between the posterior teeth and a tongue shield as this one does. (B) The Bionator also incorporates a major palatal connector to stabilize the posterior segments, but the appliance is limited in bulk and relatively easy for the patient to accommodate. (C) The activator is also used to actively advance the mandible and can incorporate anterior and posterior bite blocks and a labial bow. (D) The activator's lingual shields usually extend deeper along the mandibular alveolus than other functional appliances, and sometimes the appliance incorporates a displacing spring so that the patient has to close down and advance the mandible to retain the appliance in place. The theory is that activating the mandibular musculature is important in obtaining a growth effect (thus the activator name), but this theory has not been supported by data and has largely been discarded.



• **Fig. 14.6** (A) The Frankel-II appliance actively advances the mandible via contact of the lingual pad behind the lower incisors with the mucosa in that area and fosters expansion of the arches with the buccal shields. The lower lip pad also moves the lower lip facially. The appliance is largely tissue-borne and potentially causes more soft tissue irritation than other functional appliances, but a patient can talk normally with it in place, which makes full-time wear feasible. (B) Because of the wire framework, it is more susceptible to distortion than functional appliances made largely with plastic. (A courtesy Allesee Orthodontic Appliances [AOA], Sturtevant, WI.)

treatment, further posterior eruption must be prevented to avoid growth being expressed entirely vertically (Fig. 14.9). The special problems created by excessive vertical growth are discussed later in this chapter.

## Headgear

The other possible treatment for mandibular deficiency is to restrain growth of the maxilla with extraoral force (Fig. 14.10) and let the mandible continue to grow more or less normally so that it catches up with the maxilla (Fig. 14.11). After a period in which this method was largely abandoned, an influential 1936 paper by Oppenheim revived the idea that headgear would serve as a valuable adjunct to treatment.<sup>7</sup> However, it was not until the 1940s when Silas Kloehn's impressive results with headgear treatment of Class II malocclusion became widely known<sup>8</sup> that extraoral force to the

maxilla again became an important part of U.S. orthodontics. Cephalometric studies of patients treated with Kloehn-type headgear, which used a neckstrap and relatively light (300 to 400 gm) force, showed that skeletal change in the form of a reorientation of jaw relationships did occur.<sup>9</sup> Experience soon revealed that although greater skeletal effects might be produced by higher levels of force than Kloehn had advocated, this required an upward direction of pull from a headcap to prevent excessive downward movement of the maxilla and a consequent downward and backward rotation of the mandible.<sup>10</sup>

No effect on the mandible would be expected, but restraint of mandibular growth along with restraint of maxillary growth is never observed, and some studies have found improvement in mandibular growth and chin prominence during headgear treatment.<sup>11</sup>

Beyond the skeletal effects, functional appliances and headgear also differ in their effects on the dentition. Removable functional appliances, especially those that rest against the teeth (i.e., tooth-borne ones with a labial bow), often tip the upper incisors lingually and the lower incisors facially. Headgear force against the maxillary molar teeth often tips them distally. This often is accompanied by some distal movement of the maxillary premolars as force is transmitted to them by the supercrestal gingival fibers. There also is a vertical effect on the posterior teeth, extrusive with cervical headgear, possibly intrusive with high-pull headgear (true intrusion rarely occurs, but downward movement of the maxilla and posterior teeth is impeded). Remember that the mere fact that the teeth are moving distally will tend to open the bite anteriorly.<sup>12</sup>

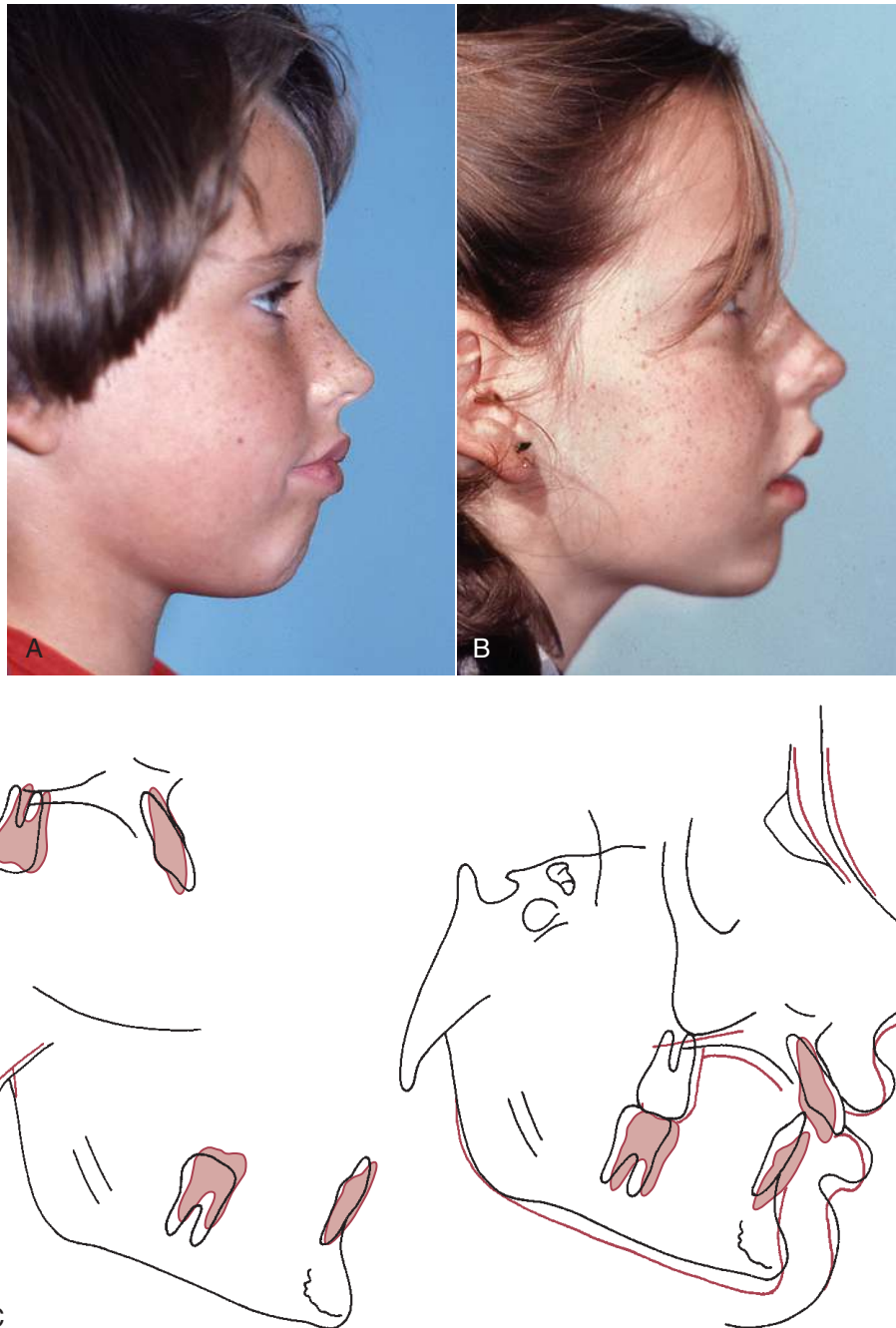## Functional Appliances Versus Headgear: Some Clarity From Randomized Clinical Trials

In the 1990s, two major projects using randomized clinical trial methodology were carried out at the University of North Carolina (UNC) and University of Florida to compare the effects of functional appliances and headgear versus growth in untreated patients.<sup>3,11</sup> Another major trial at the University of Manchester in the United Kingdom was completed more recently,<sup>13</sup> and several additional smaller trials also have been completed. The results provide by far the best data that ever have been available for the response to early Class II treatment. The data from all the trials show that on average, children treated with either headgear or a functional appliance had a small but statistically significant improvement in their jaw relationship during the treatment period (late preadolescence and early adolescence), whereas the untreated children did not. There is no question now that growth modification in children with Class II problems is effective—it works in the majority of the patients.

A more important question relative to the timing of treatment is “Did early treatment with headgear or a functional appliance produce a long-term difference when early treatment outcomes are compared with the outcome of later (adolescent) treatment?” The UNC trial was extended into a second phase of treatment for all the subjects in the study, to compare early two-stage with later one-stage treatment more completely; long-term data from the Florida trial also are available. Both the former controls and the two groups of patients who underwent preadolescent growth modification treatment received comprehensive fixed appliance orthodontics (phase 2) when their permanent teeth erupted, during adolescence.

These data show that changes in skeletal relationships created during early treatment were at least partially reversed by later



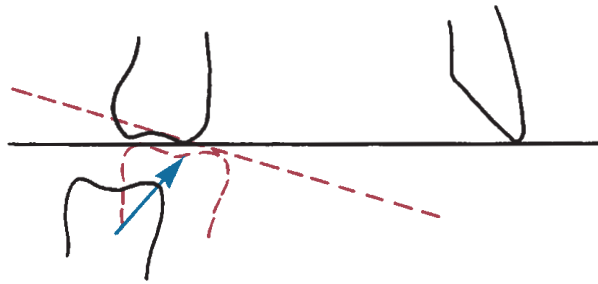


• **Fig. 14.7** This child was treated with a functional appliance in an effort to correct her Class II malocclusion by changing the skeletal relationships. (A) Pretreatment profile. (B) Posttreatment profile. (C) Cephalometric superimposition. Note that the major skeletal change seen in the cranial base superimposition is restriction of forward growth of the maxilla. This “headgear effect” is observed in most functional appliance treatment that anteriorly positions the mandible, presumably because the soft tissues are stretched when the mandible is advanced and this force is transferred to the maxilla. Note also the differential eruption of the lower molars and forward movement of the lower teeth.

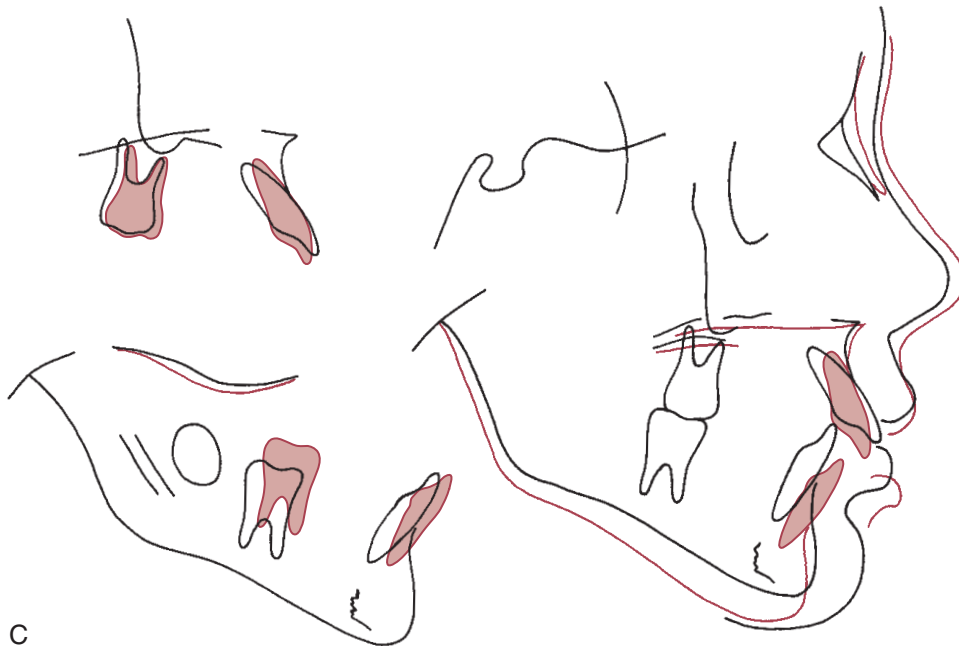
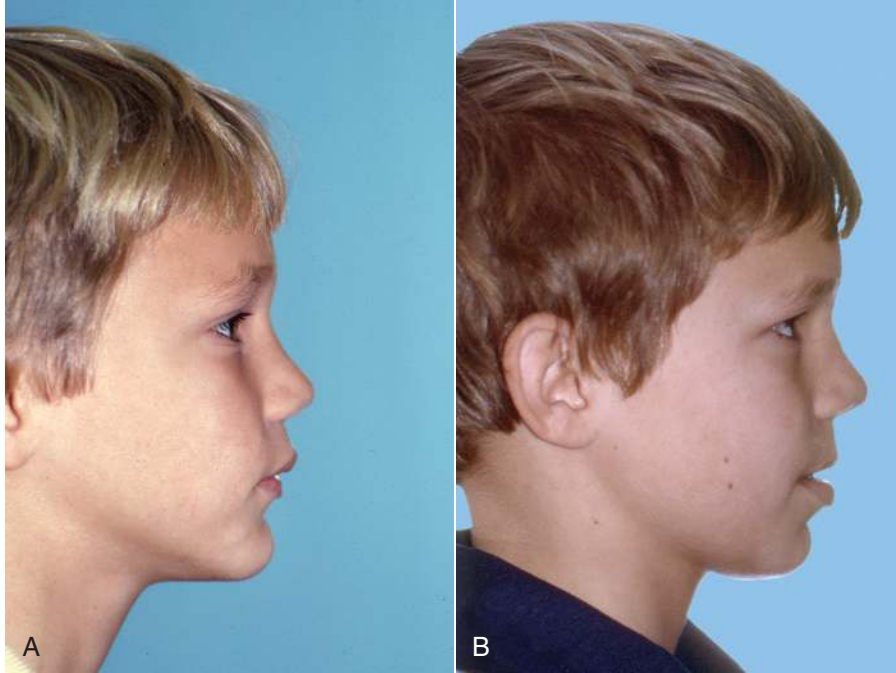compensatory growth in both the headgear and functional appliance groups. By the end of phase 2, the skeletal relationships between the former controls and the early treatment groups were similar. Peer Assessment Rating (PAR) scores, which reflect the alignment and occlusion of the teeth, also were not different at the end of phase 2 between the children who had undergone

early treatment and those who had not. The groups were also similar for extractions and eventual surgical treatment, although functional appliance treatment tended to increase the need for extractions.

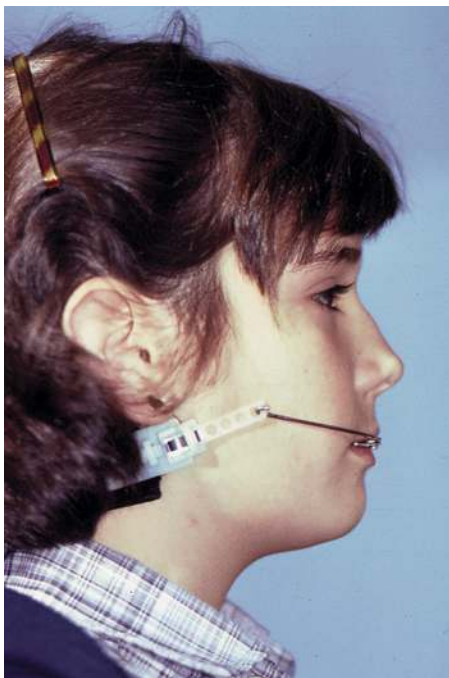From these studies, what can be concluded about the success of attempts to modify growth in children with Class II relationships



• **Fig. 14.8** To facilitate Class II correction, the mesial and vertical eruption of the mandibular molar can be used advantageously. Rotating the occlusal plane upward posteriorly will in itself improve the molar relationship.



• **Fig. 14.9** A poor response to Class II functional appliance treatment. (A) Pretreatment profile. (B) Posttreatment profile. (C) Cephalometric superimpositions. Note that before treatment the child had a tendency toward increased lower face height and a convex profile. The cranial base superimposition indicates that the mandible rotated inferiorly and backward because of excessive eruption of the lower molar, which further increased the lower face height and facial convexity. Note in the mandibular and maxillary superimpositions the anterior movement of the lower incisors and retraction of the upper incisors, neither of which was desirable.



• **Fig. 14.10** A Kloehe-type or cervical headgear appliance. This appliance uses a cervical neckstrap and a facebow to produce distal force on the maxillary teeth and maxilla. Its goal is to control forward growth of the maxilla while allowing the mandible to grow forward.

and the benefits of early treatment for Class II problems? It appears that:

- Skeletal changes are likely to be produced by early treatment with headgear or a functional appliance but tend to be diminished or eliminated by subsequent growth and later treatment.
- Skeletal changes account for only a portion of the treatment effect, even when an effort is made to minimize tooth movement.
- After later comprehensive treatment, alignment and occlusion are very similar in children who did and did not undergo early treatment.
- Early treatment does not reduce the number of children who require extractions during a second phase of treatment or the number who eventually require orthognathic surgery.
- The duration of phase 2 treatment is quite similar in those with and without a first phase of early treatment aimed at growth modification.

Based on these results, it seems clear that for most children with Class II problems, early treatment is no more effective than later treatment, and it is more efficient to modify growth during the adolescent growth spurt than before adolescence.

If early treatment is pursued, when the maxillary skeletal and dental effects that go along with any enhancement of mandibular growth are considered, functional appliances usually are preferred. For many patients who do not have a definitive maxillary excess or mandibular deficiency as part of the Class II problem, either a functional appliance or headgear can be used with some degree of success, and allowing these patient to choose which one they prefer may improve compliance. Headgear probably is a better choice for a patient with frank maxillary excess.

Another finding from the early treatment studies was that among the treated and control groups, both of which had reasonably high self-concepts to begin with, the early treatment group reported less anxiety, higher self-concepts, and better physical appearance, popularity, happiness, and satisfaction than the controls at the end of phase 1. The treated patients also believed the benefits of treatment were general well-being, confidence, health of teeth, and mouth function.<sup>14</sup> This difference, however, disappeared by the end of phase 2 when both groups finished comprehensive treatment, so psychosocial benefits appear to be equally likely with early or later Class II growth modification.

What the clinical trials did not say was that early treatment for increased overjet should never be attempted. For those with esthetic concerns or psychosocial problems related to dental and facial appearance or those with protruded front teeth, spacing problems, and a history of trauma, retraction of the front teeth and later growth modification make sense.<sup>15,16</sup> What this means is that early Class II treatment is indicated for some, but by no means all children.

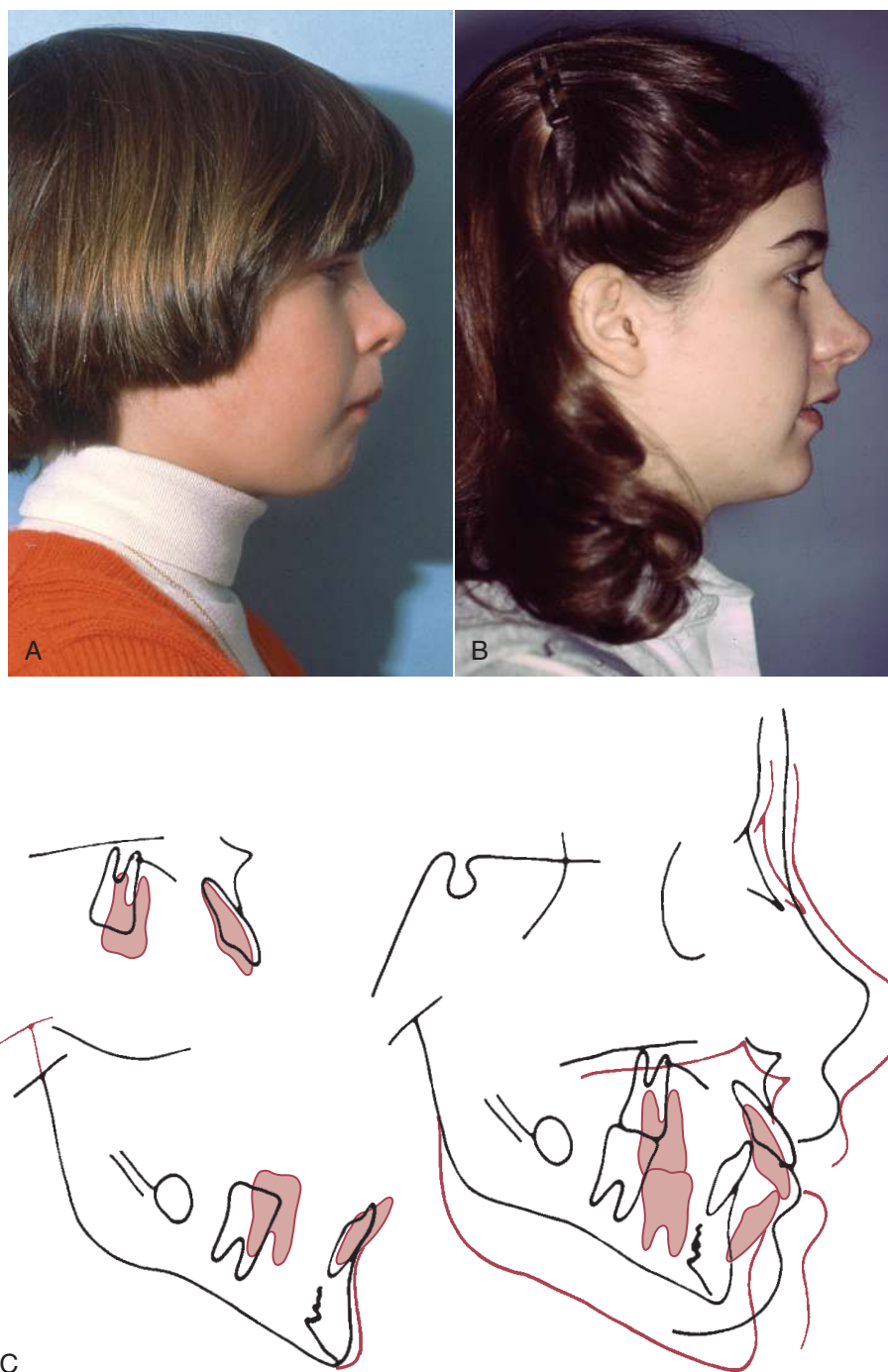
### Fixed Class II Correctors: Another Class II Treatment Approach

Fixed Class II correctors (Herbst), the mandibular anterior repositioning appliance (MARA), and cemented Twin-Block and Forsus devices (Figs. 14.12 to 14.14) are historically newer developments that have recently become quite popular for use in the mixed and early permanent dentitions. The major attraction of these appliances is that they require less patient cooperation (inserting and wearing a removable functional appliance or headgear).

Herbst created his appliance in the early 1900s and reported on it in the 1930s, but then it was largely forgotten until Pancherz rediscovered and popularized it in the 1970s. It forces the patient to maintain an advanced mandibular position and can generate both skeletal and dental changes. In long-term studies of the outcome of treatment with the Herbst appliance, Pancherz noted substantial rebound in the immediate posttreatment period. He now recommends the Herbst appliance for the early permanent dentition when the changes are more localized to the protrusion of the mandible but not for use in the mixed dentition.<sup>17</sup> Because the Herbst appliance can produce maxillary posterior dental intrusion, it provides better results when used in patients with normal or slightly long anterior face height.<sup>18</sup> Although less patient compliance is an advantage, breakage has long been recognized as a significant disadvantage.

In the 1990s, Toll and Eckhart jointly developed the MARA as a more durable and less bulky alternative to the Herbst appliance, but with the same fixed properties and anterior bite guidance. The MARA appears to have a significant if temporary headgear effect and affects the mandible. As measured by change in the SNB angle, it affects the mandible less than the Twin-Block and Herbst appliances.<sup>19</sup> Most fixed functionals tip teeth and have dentoalveolar effects when used in adolescents.<sup>20</sup> The amount of tipping depends on which anterior and posterior teeth are included in the anchorage units through supplementary bonding or banding. In addition, they exert a protrusive effect on the mandibular dentition because the appliance contacts the lower teeth, and some of the reaction force from forward posturing of the mandible is transmitted to them continuously from full-time wear.<sup>21</sup> Although this type of dental change can be reduced with skeletal anchorage, this supplemental anchorage does not affect the skeletal changes.<sup>22</sup>

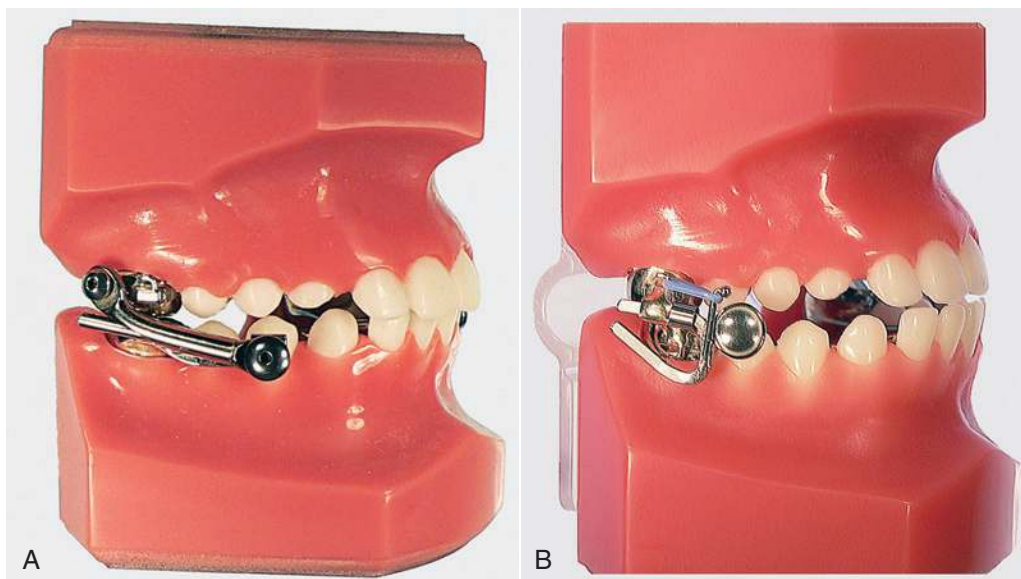




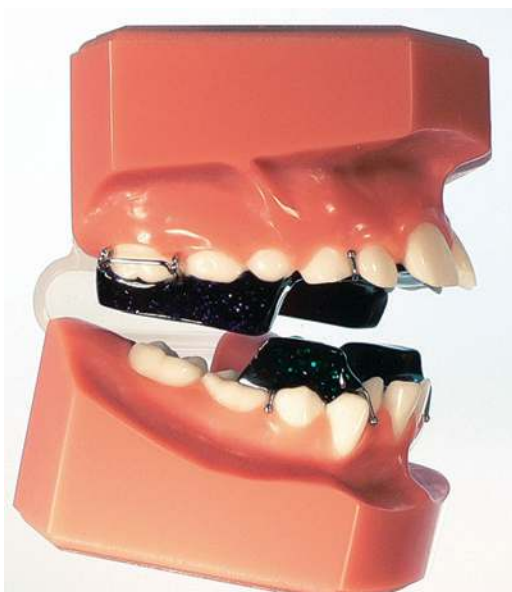• **Fig. 14.11** Headgear can be effective treatment for patients with mandibular deficiencies if the mandible grows while they are wearing it. Facial appearance before (A) and after (B) treatment using headgear and Class II elastics. (C) Pretreatment and posttreatment cephalometric superimpositions. This patient showed restriction of maxillary growth and some impressive mandibular growth, combined with distal movement of the upper teeth and mesial movement of the lower teeth, which were accompanied by posterior eruption.

The combination of maxillary dental retraction and mandibular dental protrusion that all functional appliances (fixed and removable) create is similar to the effect of interarch elastics.<sup>23</sup> This “Class II elastics effect” can be quite helpful in children who have maxillary dental protrusion and mandibular dental retrusion in

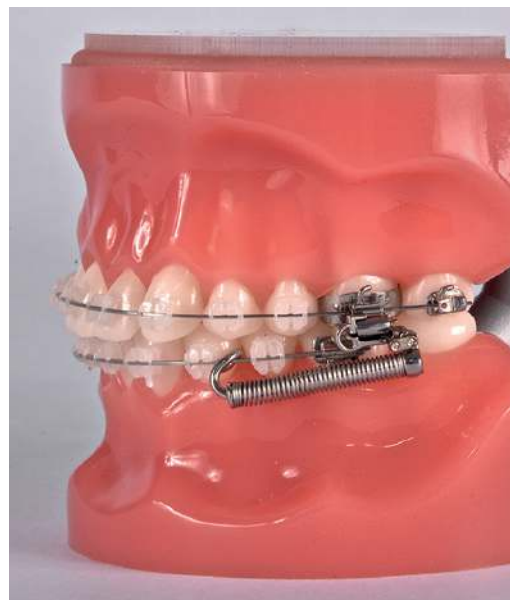conjunction with a Class II skeletal problem, but is deleterious in patients who exhibit maxillary dental retrusion or mandibular dental protrusion. Mandibular dental protrusion usually contraindicates functional appliance treatment. Finally, at present the effects of fixed functional appliances on the temporomandibular



• **Fig. 14.12** (A) The Herbst appliance is probably most successful at the end of the mixed dentition. The most popular design currently uses crowns on the upper first molars and lower molars supported by lingual arch-type connectors for stability. The mandible is forced anteriorly in a passive manner by the plunger and tube that is anchored on the maxillary molars and cantilevered off the lower molar. (More recently, a telescopic design has been used). Spacers can be added to the plunger to advance the mandible farther. This appliance does not require compliance for wear, because it is cemented, but it does require compliance to prevent breakage. (B) The mandibular anterior repositioning appliance (MARA) requires the patient to advance the mandible in order to close. Otherwise, the upper elbow interferes with the lower fixed arm. The appliance, which uses crowns on the molars connected by lingual arches, is durable and stable. Patients find it less bulky than the Herbst appliance and tend to prefer it over the Herbst. To increase the advancement, shims are added to the horizontal portion of the elbow and the elbow is tied back with an elastomeric tie. (Images courtesy Allesee Orthodontic Appliances [AOA], Sturtevant, WI.)



• **Fig. 14.13** The Twin-Block functional appliance is retained on the teeth with conventional clasps (but can be cemented in place). The complementary inclines on the upper and lower portions are relatively steep, forcing the patient to advance the mandible in order to close. The plastic blocks also can be used to control posterior eruption. (Image courtesy Allesee Orthodontic Appliances [AOA], Sturtevant, WI.)



• **Fig. 14.14** The Forsus appliance is another of the fixed Class II correctors. It has moderate bulk but is flexible and adjustable as it causes the mandible to be positioned forward. The appliance can be assembled intraorally by attaching it to the headgear tube and heavy archwires. It is adjusted by adding shims to one or both sides for more mandibular advancement. Clearly, and similar to other fixed correctors, there are upper distal and intrusive and lower mesial dental movements.

joint are poorly documented but do not appear to differ from the low prevalence of temporomandibular dysfunction problems in removable functionals.<sup>24</sup>

It is possible to contrast the fixed versus removable fixed functional appliances, and the results are not as favorable to the fixed appliances as anticipated. It appears that the Forsus device produces more vertical skeletal and dental changes and the Twin-Block device provides more positive mandibular changes.<sup>25</sup> Others making this comparison have found not only the different mandibular effects, but also more maxillary restriction and mandibular incisor proclination with the Forsus appliance.<sup>26</sup> As mentioned earlier, the MARA appliance has more maxillary restriction but less mandibular advancement effect than the Twin-Block device, in the short term.<sup>19</sup>

### Components of Removable and Fixed Class II Functional Appliances

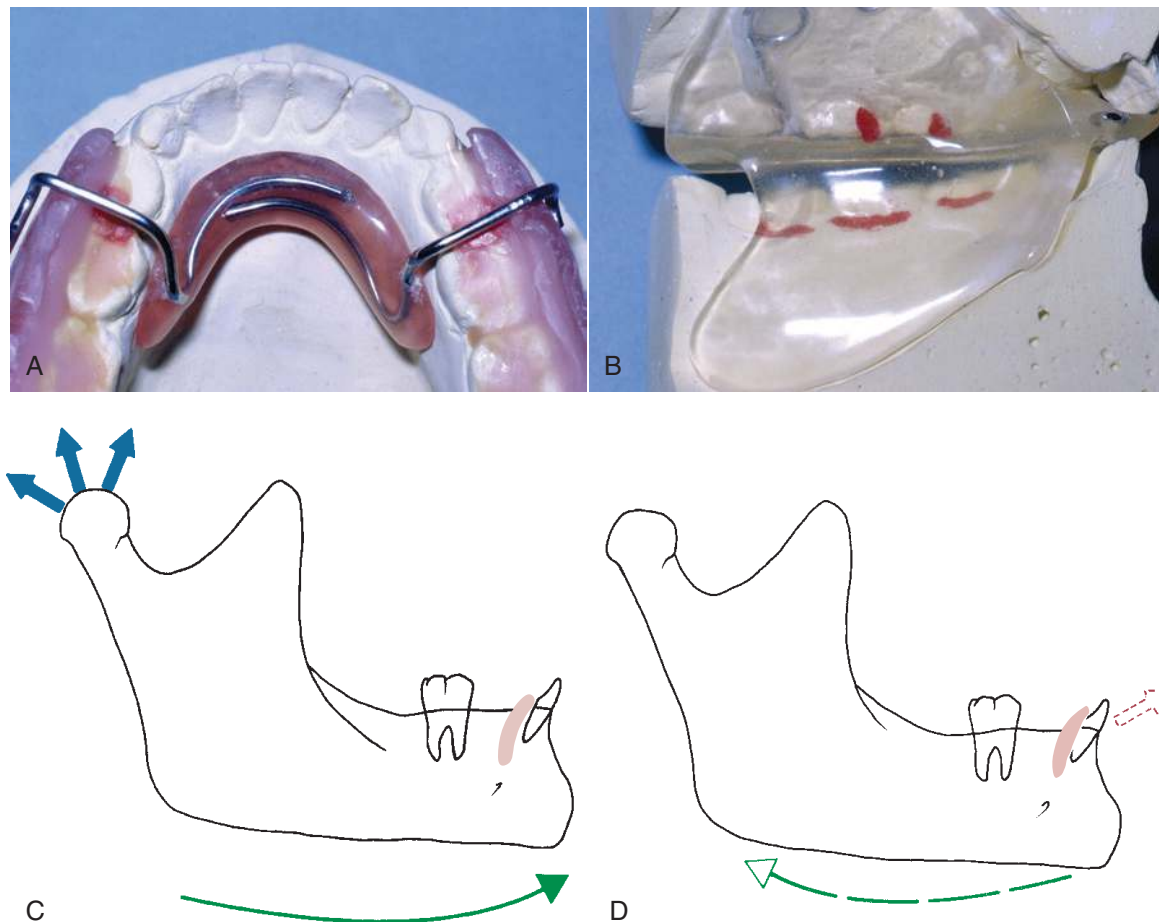
The changes observed with functional appliances, especially the effects on the teeth, are the result of the appliance design. This section will briefly illustrate how the components of the appliances can be used to produce wanted effects and possibly mitigate unwanted effects. An appropriate appliance prescription specifies

the appliance components that would be most effective in solving the patient's specific problems. It is important to have the appliance design in mind before the impressions and bite registration because the impression technique is affected by what appliance components are selected, where they will be placed, and the intra-arch space required for them.

#### Components to Advance the Mandible

Components to advance the mandible are often classified as active or passive. If the patient has to voluntarily move the mandible to avoid an interference, the appliance is active. If it allows only a restricted path of movement or closure, it is passive. By that definition, appliances such as the activator, Bionator, Twin-Block, and MARA are active appliances, and the Herbst and Forsus are passive appliances.

For most mandibular-deficient patients, a Bionator or activator-type appliance (see Fig. 14.5) is the simplest, most durable, and most readily accepted appliance. Flanges, either against the mandibular alveolar mucosa below the mandibular molars or lingual pads contacting the tissue behind the lower incisors, provide the stimulus to posture the mandible to a new more anterior position (Fig. 14.15). The Frankel appliance uses lingual pads against the



• **Fig. 14.15** The lingual pad or flange determines the anteroposterior and vertical mandibular posture for most functional appliances. (A) The small lingual pad from a Frankel appliance. (B) The extensive lingual flange from a modified activator. (C) The lingual components not only position the mandible forward but also exert a protrusive effect (D) on the mandibular incisors when the mandible attempts to return to its original position, especially if some component of the appliance contacts these teeth.



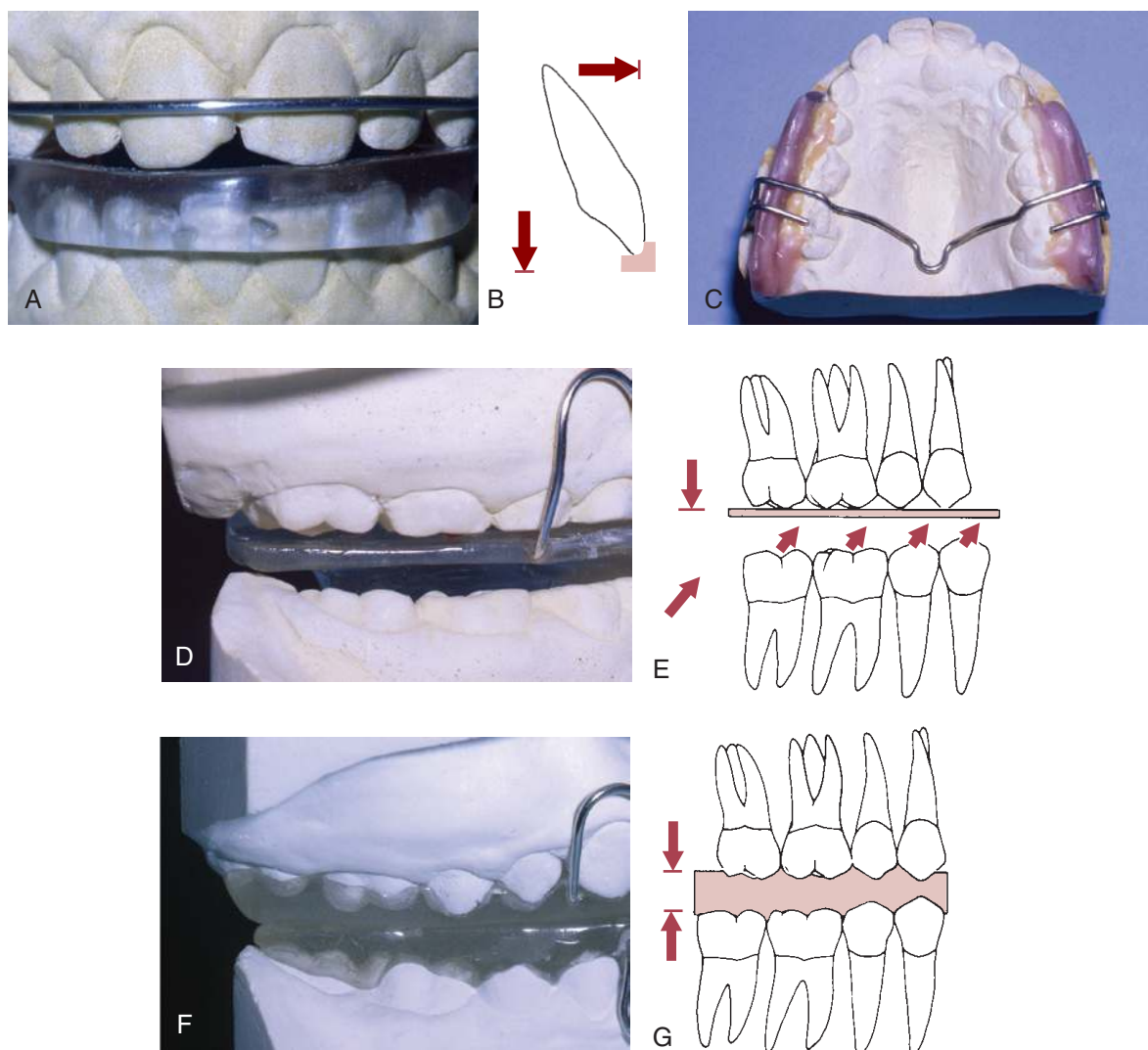
gingiva below the lower incisors to stimulate forward posturing of the mandible. Ramps supported by the teeth, as in the Twin-Block appliance (see Fig. 14.13), are another mechanism for posturing the mandible forward. So is the elbow in the MARA appliance (see Fig. 14.12). With all these appliances, the concept is that growth modification is the result of the patient using his or her own musculature to posture the mandible forward (active), as opposed to the mandible being held forward passively by the appliance, which produces external pressure on the teeth while the patient relaxes.

All the fixed appliances have the advantage of full-time wear and permanent postural change (at least until the dentist removes the appliance). The disadvantage is that pressure against the teeth, which produces compensatory incisor and molar movements, cannot

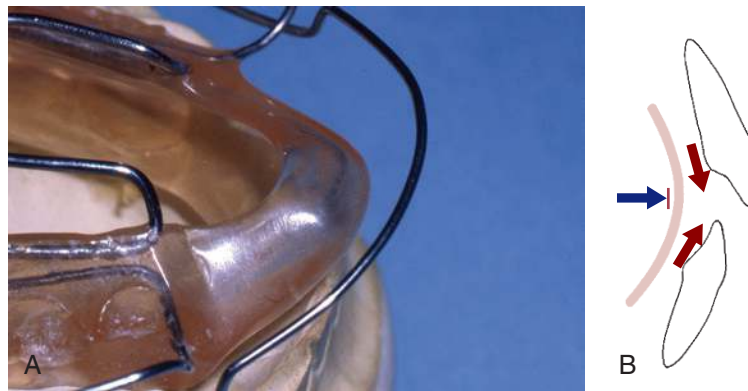be avoided—the patient simply cannot actively hold the mandible forward all the time. The point may be not whether the appliance is active or passive, but where and how the forces are applied to the teeth and how much dental compensation is built into the treatment. The more dental change, the less room there is for skeletal change by whatever means.

### Other Possible Components

**Vertical Control Components.** When acrylic or wire is placed in contact with a tooth and the vertical dimension is opened past the normal postural position, the stretch of the soft tissues will exert an intrusive force on the teeth (Fig. 14.16). Intrusion usually does not occur, probably because the force is not constant, but eruption is likely to be impeded. Thus the presence or absence of



• **Fig. 14.16** Incisal and occlusal stops control eruption of anterior and posterior teeth, respectively. (A) The acrylic caps the lower incisors and serves as a stop for the upper incisors, which prohibits eruption of these incisors. (B) Incisal stops can extend to the facial surface and control the anteroposterior incisor position, as shown for the upper arch in this diagram. (C) Posterior stops can be constructed of wire or acrylic (D) and (E) This positioning of the occlusal stops inhibits maxillary eruption but allows mandibular teeth to erupt. (F) A complete acrylic posterior bite block impedes both maxillary and mandibular eruption (G) and is useful in controlling the amount of increase in anterior face height.



• **Fig. 14.17** (A) A lingual shield restricts the resting tongue (and thumbs, fingers, and other objects) from being positioned between the teeth. (B) The acrylic shield is placed behind the anterior teeth, leaving the anterior teeth free to erupt while (typically) the posterior teeth are blocked.

posterior occlusal or incisal stops, including bite blocks, provides a way to control the vertical position of anterior or posterior teeth, allowing teeth to erupt where this is desired and preventing it where it is not. Vertical control of this type is usually included in the design of any functional appliance.

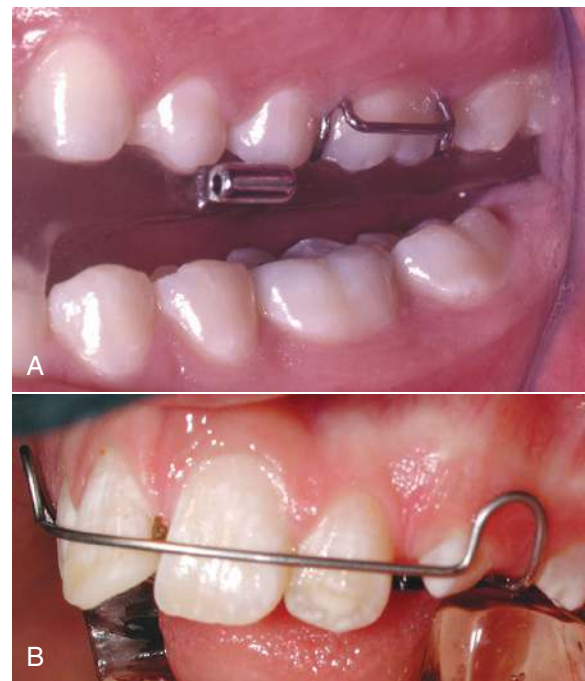The same principle applies to tongue position. Lingual shields prevent the resting tongue from being placed between the teeth (Fig. 14.17). This has the effect of enhancing tooth eruption. A lingual shield is particularly important if eruption of posterior teeth is desired on one side but not the other. One caution here is that this component often limits the patient's acceptance of the appliance because speaking can be difficult.

**Stabilizing Components.** An assortment of clasps can be used to help retain a functional appliance in position in the mouth (Fig. 14.18A) (see also the discussion of clasps for removable appliances in Chapter 10). Clasps often help the first-time wearer adapt to the appliance. They can be used initially and then removed, deactivated, or allowed to gradually loosen with wear if desired, when the patient has learned to use the appliance. The labial bow across the maxillary incisor teeth that is included in many functional appliances (Fig. 14.18B) should be considered and managed as a stabilizing component in almost all instances.

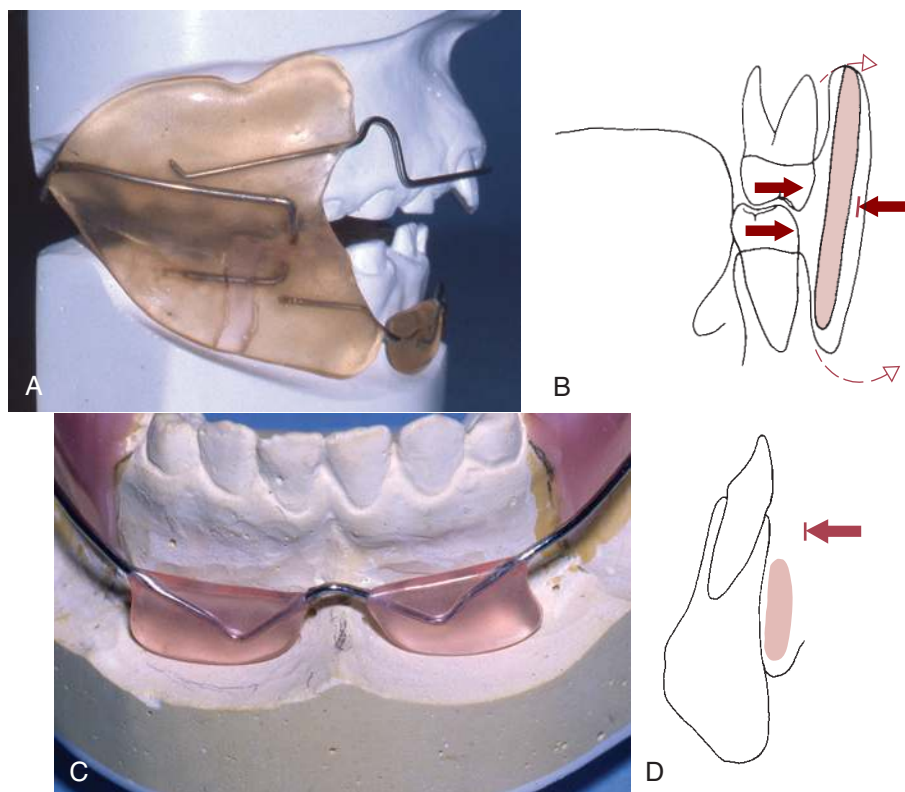
**Passive Components.** Plastic buccal shields and lip pads, both of which are incorporated into the Frankel appliance (Fig. 14.19), hold the soft tissues away from the teeth. The effect is to disrupt the tongue–lip/cheek equilibrium, and this in turn leads to both facial movement of the teeth and arch expansion that results in an increase in arch circumference. This method of obtaining tooth movement reflects the idea that the most stable tooth movement is produced by changing the soft tissue environment, but, of course, when the appliance is removed, the environment is likely to revert to what it was previously.

Buccal shields and lip pads can be added to any appliance to facilitate arch expansion. Their disadvantage is that they add to the potential for soft tissue irritation that can inhibit patient compliance. The addition of a vertical stop over the lower incisors (Fig. 14.20) decreases irritation from the lip pads and makes the appliance more comfortable to wear and more acceptable to patients.

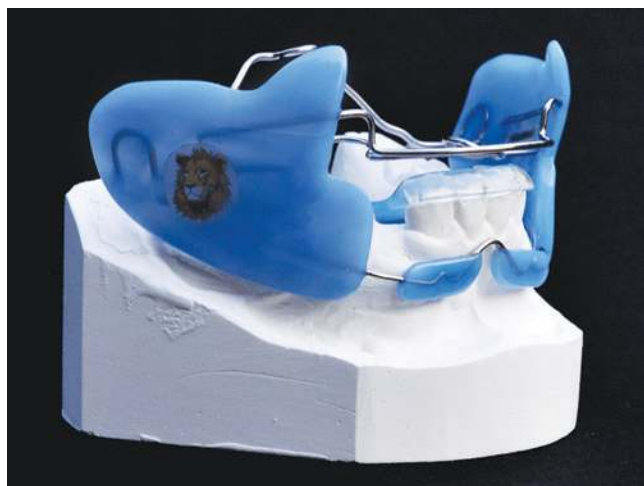**Active Expansion and Alignment Components.** In theory, there is no reason that growth guidance with a functional removable appliance cannot be combined with active tooth movement



• **Fig. 14.18** Clasps add retention, which is needed to help maintain some types of appliances with active components such as springs and expansion screws in position. The clasps also can serve as a training device when patients are learning to accommodate to a functional appliance that repositions their jaws. (A) Note the headgear tube, for high-pull headgear that can stabilize the appliance and provide an extraoral distal force to the maxilla. (B) The purpose of a labial bow on a functional appliance is to help guide the appliance into proper position, not to tip the upper incisors lingually. For this reason, the bow is adjusted so that it does not touch the teeth when the appliance is seated in position. Even then it often contacts them during movement or displacement of the appliance. Undesirable lingual tipping of incisors during functional appliance wear therefore usually reflects a failure of the child to keep the mandible positioned forward while wearing the appliance.



• **Fig. 14.19** (A) A buccal shield holds the cheek away from the dentition and facilitates posterior dental expansion (B) by disrupting the tongue–cheek equilibrium. The shield is placed away from the teeth in areas where arch expansion is desired. If the shield is extended to the depth of the vestibule, there is the potential for periosteal stretching that facilitates deposition of bone (*dashed arrows*). (C) The lip pad holds the lower lip (or upper lip with a Frankel FR-III appliance) away from the teeth and forces the lip to stretch to form a lip seal. (D) The pad must be carefully positioned at the base of the vestibule to avoid soft tissue irritation.



• **Fig. 14.20** Frankel deliberately configured his appliances to minimize contact with the teeth, but this means they can move in a way that creates soft tissue irritation. Adding occlusal coverage of the lower incisors stabilizes the appliance and reduces compliance problems, without detracting from the appliance's ability to guide growth. (Courtesy Dr. A. Willis.)

produced by springs or screws. The original activators did not use any springs or screws, but later, modified activators added the elements of active plates to an activator framework so that teeth could be moved while jaw growth was being manipulated (Fig. 14.21).

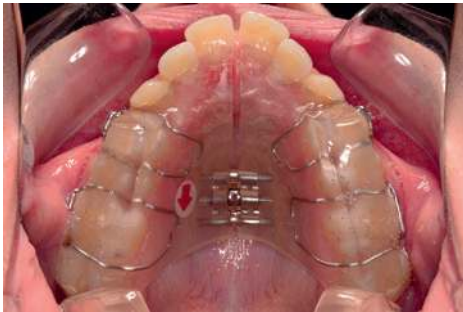
Incorporating active elements into a functional removable appliance is a decidedly mixed blessing. There are three problems. The first is that correcting the occlusal relationships by actively moving teeth is not the goal of functional appliance therapy, and, in fact, the more tooth movement, the less skeletal change can be used or achieved (Fig. 14.22). Next, precise tooth positions cannot be achieved with springs or screws in removable appliances. Finally, the tooth movement will be only from tipping, which is less stable and more susceptible to relapse. This means that in contemporary orthodontics, there are few indications for removable appliances designed to provide all aspects of treatment.

### Treatment Procedures With Functional Appliances

**Pretreatment Alignment.** After treatment goals have been established and the decision has been made to use a functional appliance, the incisor position and relationships should be carefully examined. Because functional appliances for the treatment of mandibular deficiency require the mandible to be held in a protruded position to have a treatment effect, the patient's ability to posture forward at least 4 to 6 mm is critical. Most mandibular-deficient

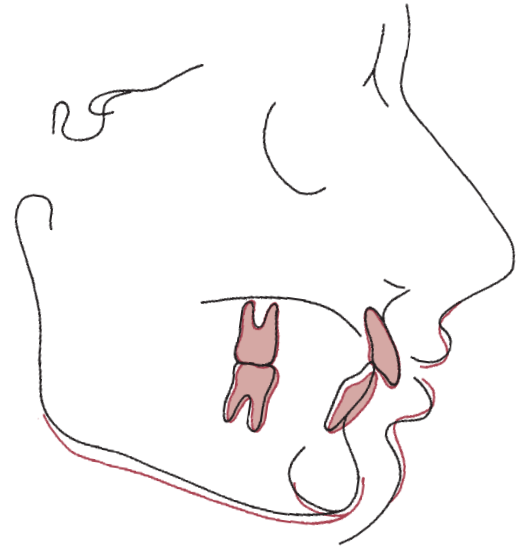


children have a large overjet and can do this readily, but in some patients incisor interferences prevent the mandible from being advanced to the correct position for the bite registration. The problem can be either lingual displacement of the upper incisors (a Class II division 2 incisor pattern) or irregular and crowded incisors in either arch. (It must be kept in mind that facial displacement of the lower incisors, which would be produced by aligning them without creating space to do so, contraindicates functional appliance treatment that would move them even further facially.)

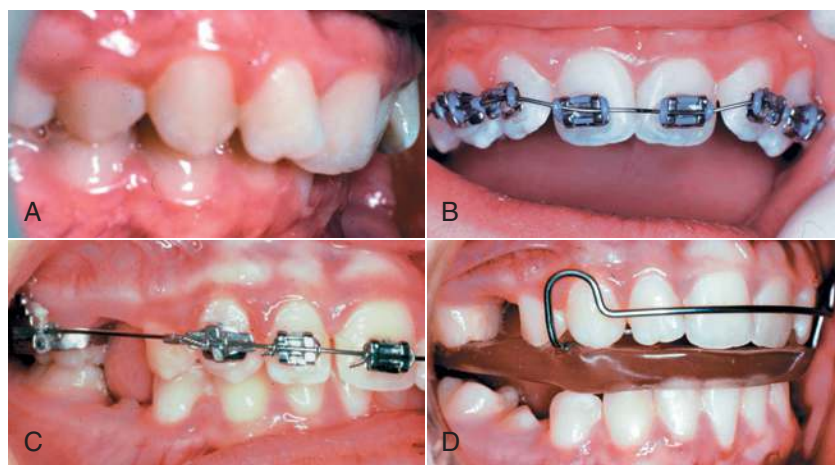


• **Fig. 14.21** Maxillary occlusal view of a twin-block functional appliance, which has an expansion screw to widen the maxillary arch. As the mandible moves forward relative to the maxilla during treatment, some maxillary expansion is likely to be needed to prevent the development of a posterior crossbite. The jackscrew and midline split of the appliance are a tooth-moving adjunct to allow maxillary arch expansion. Activation of a screw like this must be done slowly and in small increments. It is best managed with activation only by the orthodontist at recall visits. It is possible to add other tooth-moving components to functional appliances, such as wire springs to reposition the incisors, and that was popular in Europe when all the treatment was done with removable appliances. Now auxiliary springs and other adjuncts have largely disappeared, and the usual procedure is to follow the functional appliance with a second phase of fixed appliance treatment to obtain the final tooth positions because this is both more effective and more efficient. If a severe posterior crossbite is present and opening the midpalatal suture is needed, it is better to do this before or after the period of functional appliance treatment. (Courtesy Dr. R. Shah.)

For both the Class II division 2 patient with limited overjet and the Class II division 1 patient with crowded and irregular upper incisors, the first step in treatment is to tip the upper incisors forward and/or align them (Fig. 14.23). Either fixed or removable functional appliances can be used for this purpose, depending on



• **Fig. 14.22** Cephalometric superimposition showing an unsatisfactory response to a removable functional appliance for a skeletal Class II malocclusion. Note the lack of skeletal response but dental changes, including forward movement of the lower incisors, slight retraction and elongation of the upper incisors, and downward and backward rotation of the mandible. Adding springs to a functional appliance, if it accentuates this pattern of tooth movement, makes the treatment response worse rather than better.



• **Fig. 14.23** (A) For this girl with a Class II division 2 malocclusion, it was impossible to take the bite registration for a functional appliance until the maxillary incisors were tipped facially. (B) Although a change of this type was made with a removable maxillary appliance with fingersprings until recently, the prefunctional alignment now often can be accomplished more efficiently with a partial fixed appliance. In this case, the molars were banded, the canines and incisors were bonded, and a superelastic nickel–titanium (NiTi) wire was placed. (C) The same patient 2 months later, with alignment accomplished and overjet established. (D) Same patient 4 months later, with a deep bite Bionator in place. (From Proffit WR, White RP, Sarver DM. *Contemporary Treatment of Dentofacial Deformity*. St. Louis: Mosby; 2003.)

the type and magnitude of tooth movement required, but a fixed functional appliance is quite compatible with bonded attachments on incisors and a removable one is not. In general, a short period of treatment with limited banding and bonding of the maxillary teeth accomplishes the necessary alignment and overjet so that an appropriate working bite can be obtained with the mandible positioned anteriorly and inferiorly to correct the horizontal and vertical deficiency. To control the tendency of the repositioned incisors to relapse lingually, they should be held in place for several months after being repositioned.

**Impressions and Working Bite.** The next step is to make impressions of the upper and lower arches and register the desired mandibular position—the “working bite.”

The impression technique for a removable functional appliance depends on the appliance components that will be used. Good reproduction of the teeth and an accurate representation of the area where the lingual pads or flanges will be placed are mandatory. If buccal shields or lip pads are to be used, it is important not to overextend the impressions so that tissue is displaced because this makes it difficult or impossible to accurately locate the appliance components in the vestibule. Improper location of the components leads to long-term soft tissue irritation, discomfort, difficulty in appliance adjustment, and poor patient compliance.

For a cemented, bonded, or partially fixed functional appliance, accurate impressions of the teeth are essential, but extension of the impressions into the vestibules is not important. If bands or steel crowns are used to retain a Herbst appliance, they can be fabricated indirectly by a laboratory on the cast by diskling the teeth to create space, and many clinicians prefer this time-saving method. If the clinician supplies the bands or crowns on casts or in impressions, separation is required before the bands are fitted and at appliance delivery. If laboratory bands or crowns are used, then separation is required only before appliance delivery. Most clinicians have deserted bands for retention of fixed functional appliances because they have proved to be easily distorted and broken. Metal crowns, which are fit without reducing the teeth; cast splints that can be bonded; or bonded acrylic splints are more satisfactory. The crowns should have holes, not for the release of cement but for access to the occlusal surface during appliance removal. This provides a point of leverage on tooth structure.

The working bite, the jaw position to which the appliance is assembled, is the same for fixed and removable functional appliances. It is obtained by advancing the mandible to move the condyles out of the fossa and establishing the desired vertical opening (Fig. 14.24).

Unless an asymmetry is to be corrected, the mandible should be advanced symmetrically so that the pretreatment midline relationships do not change appreciably. We recommend a 4- to 6-mm advancement and a 3- to 4-mm vertical opening, but always one that is comfortable for the patient and does not move the incisors past an edge-to-edge incisor relationship. The practical reason for recommending this modest advancement is better patient comfort, facial esthetics, and patient compliance than with large advancements. Small advancements lead to more appliance adjustments. The claim that small advancements are more effective because muscle adaptation is better has not been supported by evidence. From a scientific perspective, it appears that quite large, modest, or relatively small advancements all can produce growth modification and that there is little difference in the results.<sup>27</sup>

If eruption of upper and lower posterior teeth is to be limited, as in a child with excessive vertical face height (see further discussion later in this chapter), the working bite should be taken with the

patient open 2 to 3 mm past the resting vertical dimension (i.e., 5- to 6-mm total opening in the molar region) so that the soft tissue stretch against the bite blocks will produce a continuous force opposing eruption.

The Forsus appliance does not require a pretreatment working bite but is adjusted clinically to produce the same mandibular advancement as other appliances. Incisor position can be an issue, but anterior teeth can be aligned as with any other functional appliance to allow mandibular advancement, and it is good to have coordinated arches so that the transverse dimensions avoid upper and lower arch interferences. Also, enough alignment should be accomplished so that in a 22-mil appliance, a 19 × 25 steel wire can be inserted and secured with either a wire tied underneath the archwire to connect the teeth to prevent space opening or cinch-back bends to consolidate the arch.

## Clinical Management of Functional Appliances

### Removable Functional Appliances

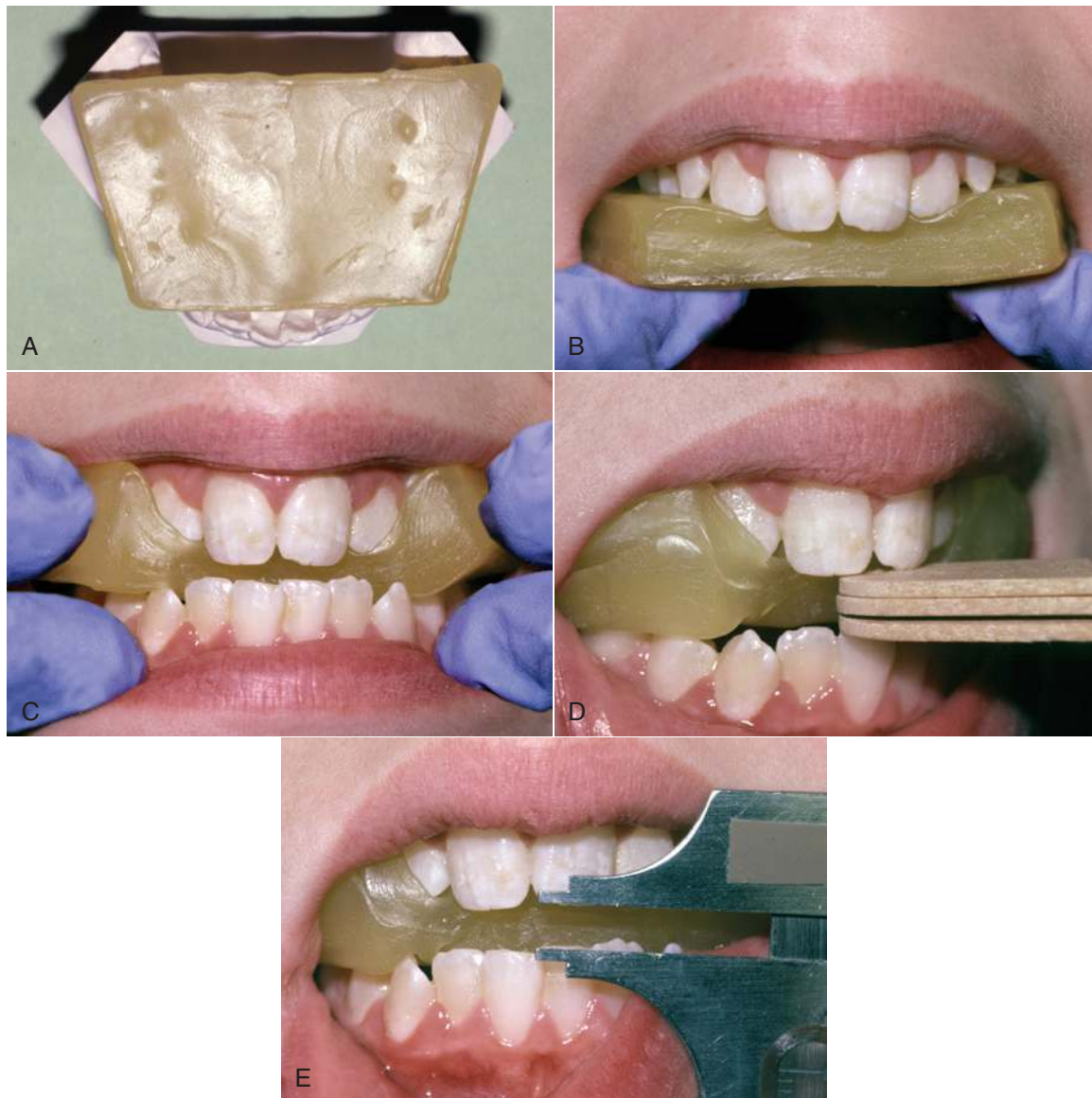When a removable functional appliance is returned from the laboratory, it should be checked for correct construction and fit on the working cast. The best technique for delivery is to adjust the appliance and work with the child to master insertion and removal before any discussion with the parent. This enables the child to be the full focus of attention initially and forestalls the effect of comments by the parents such as “That will be a mouthful!”

With any functional appliance, a break-in period is helpful. Having the child wear the appliance only a short time per day to begin with and increasing this time gradually over the first few weeks is a useful method of introduction. The child should be informed that speaking may be difficult for a while but that comfort and speaking facility will increase. Problems with speech are greatest when there is a bulk of acrylic behind or between the anterior teeth.

To be effective, functional appliances should be worn when growth is occurring and when teeth are erupting. If the appliance is in place during these hours, one can take advantage of skeletal growth and either use or inhibit tooth eruption. It is known now that skeletal growth has a circadian rhythm. Most growth occurs during the evening hours when growth hormone is being secreted; active eruption of teeth occurs during the same time period, typically between 8 PM and midnight or 1 AM. To take practical advantage of this time period, it is suggested that children wear functional appliances from after the evening meal until they awaken in the morning, which should be approximately 12 hours per day. Waiting until bedtime to insert the appliance misses part of the period of active growth. Wearing the appliance during the day may add a small advantage, but this is difficult to achieve because it begins to impinge on school hours and can increase the negative social impact of the appliance, as well as appliance loss and breakage.

A good appointment schedule is to recall the child at 1 and 2 weeks after insertion for inspection of the tissues and the appliance. If the patient does not call about a problem during the first week, the 1-week appointment can be cancelled. Charts for children to record their “wearing time” are helpful, both for the data they provide and because the chart serves as a reinforcement for the desired behavior. Unfortunately, the time reported by patients and actual compliance often do not coincide.

If a sore spot develops, the child should be encouraged to wear the appliance a few hours each day for 2 days before the appointment so that the source of the problem can be determined accurately.



• **Fig. 14.24** Steps for obtaining a “working bite” for functional appliance construction. (A) Multiple layers of hard wax are luted together and cut to the size of the mandibular arch. The patient’s preliminary record casts can be used to trim the wax to a size that will register all posterior teeth, without covering the anterior teeth or contacting the retromolar areas. It is important to avoid interferences from retromolar soft tissues. If such an interference is not detected, the finished appliance will not seat correctly. At best, this will require reduction of the posterior plastic stops if they were integrated into the design. At worst, a new bite registration and appliance will be necessary. (B) In preparation for obtaining the working bite, the wax is softened in hot water and the child is directed to practice the working bite position. Some children can easily reproduce working bites after only a few practice tries, but others need more opportunities and perhaps some help. The softened wax is seated on the maxillary posterior teeth and pressed into place to ensure good indexing of the teeth. (C) With the anterior teeth exposed, the position of the mandible easily can be judged while the bite is being taken. The mandible is guided to the correct antero-posterior and vertical position by watching the midline relationships and the incisal separation. There must be enough space for the laboratory technician to place wire and plastic between the teeth to connect major components of the appliance and construct occlusal and incisor stops. The minimal posterior opening to achieve the vertical space is 3 to 4 mm. Interocclusal stops or facets to guide eruption, as in most activators and Bionators, usually require 4 to 5 mm of posterior separation to be effective. (D) Either stacked tongue blades or (E) a Boley gauge can be used to control the amount of closure and help the patient reproduce the correct bite. If a vertical stop made of tongue blades is used, it must remain in the proper orientation (parallel to the true horizontal). Otherwise, as the tongue blades incline either inferiorly or superiorly, the mandible will either be closed and retruded or opened, respectively, to an incorrect position. When the correct bite has been obtained, the wax should be cooled and removed from the mouth. The bite should be examined for adequate dental registration and soft tissue interferences and rechecked for accuracy. Definite registration of both maxillary and mandibular teeth is required for proper appliance construction.



Usually, smoothing the plastic components can be accomplished quickly. Gross adjustments should be avoided because appliance fit and purpose can be greatly altered. For example, heavy reduction of the lingual flanges will allow the patient to position the mandible in a more posterior position.

Because the initial mandibular advancement is limited to a modest 4 to 6 mm and many children require more anteroposterior correction, a new appliance may be needed after 6 to 12 months of wear and a favorable response. It is a good idea to reevaluate progress at 8 to 10 months after delivery with new records or at least a progress cephalometric radiograph. If little or no change has occurred in that time, then compliance is poor, the design is improper, or the patient is not responding to the appliance. In any case, a new treatment plan is needed.

### Fixed Functional Appliances

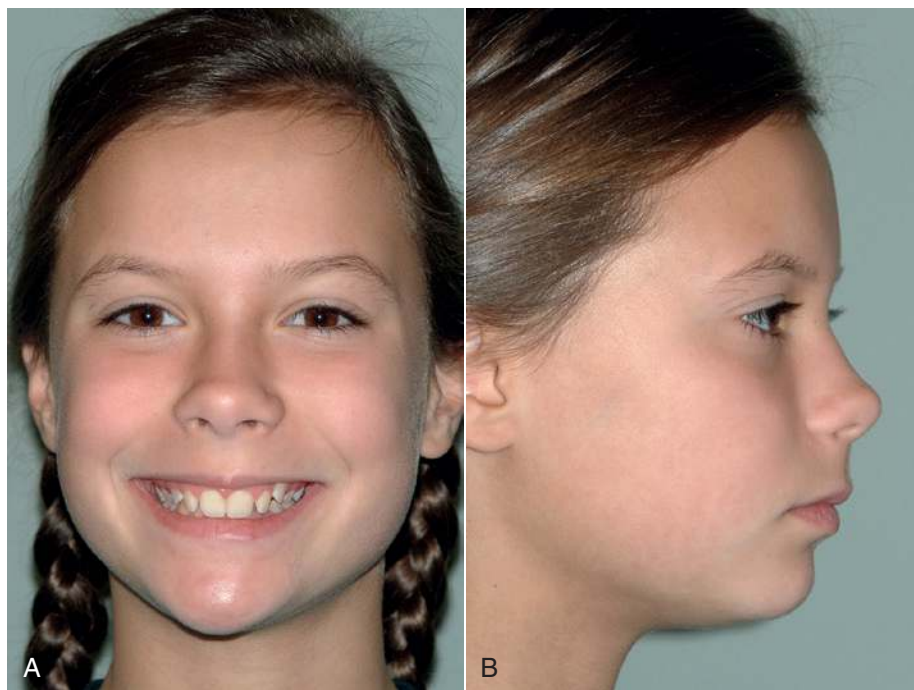
At the insertion of a Herbst appliance, MARA, or cemented Twin-Block, discussion should focus on care of the appliance and acceptable mandibular movements. Because these appliances are fixed, a wear schedule is not required, but some patients initially have problems adapting to the appliance and the forward mandibular position. It is good to warn the patient and parents of this and assure them that accommodation increases rapidly after several days. Soft tissue irritation is not a major problem with the Herbst, Twin-Block, or later versions of the Forsus, but the teeth may be more sensitive than with removable functional appliances. Patients should be instructed that the appliance is meant to remind them to posture the mandible forward and not to force the mandible forward with heavy pressure on the teeth. In this sense, sore teeth for an extended amount of time may indicate poor cooperation. Avoiding hard and sticky foods, large mouthfuls, and exaggerated

mandibular movements can greatly reduce the need for repair of a fixed functional appliance.

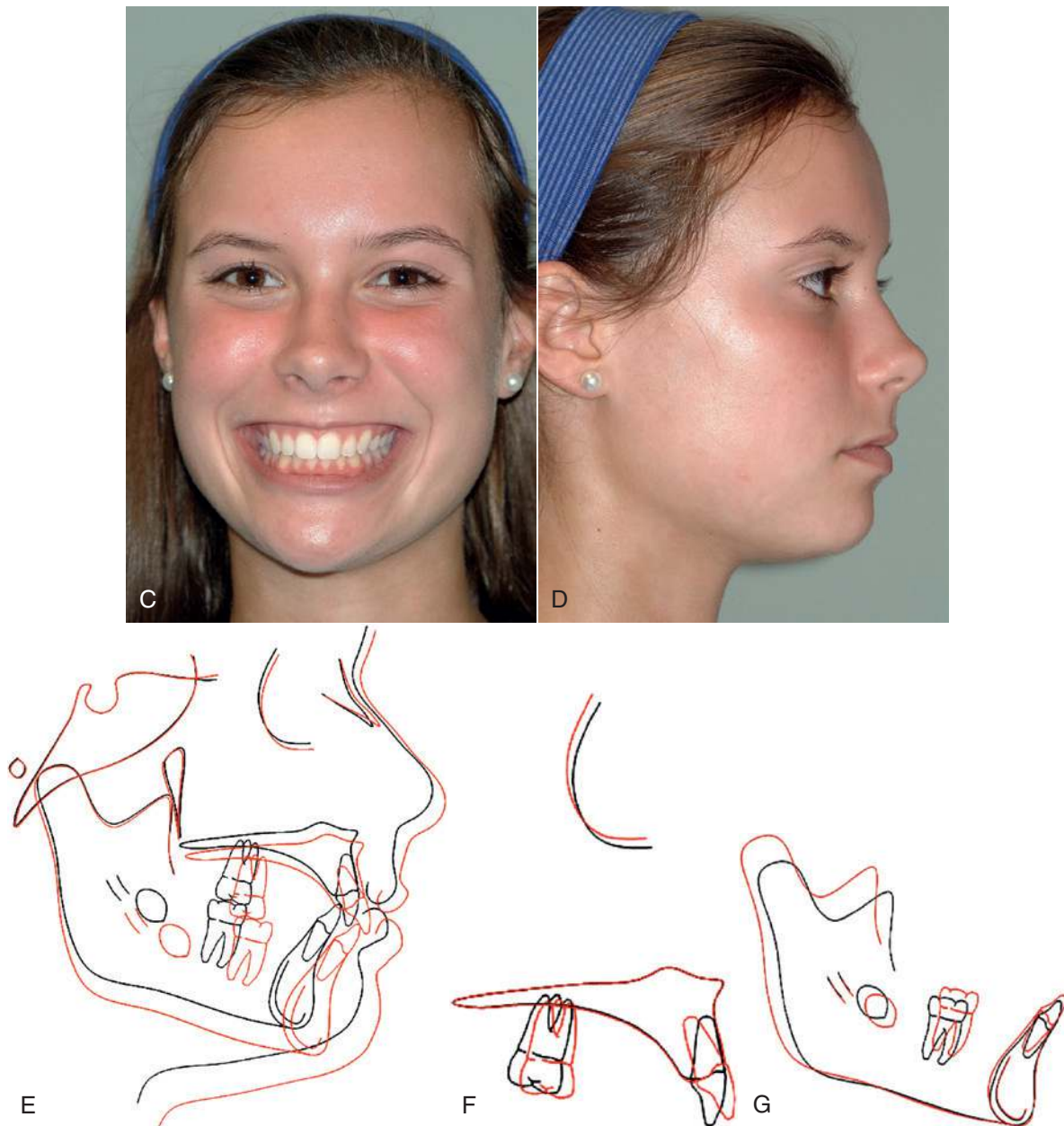
The Herbst appliance and the newer variations can produce good results (Figs. 14.25 and 14.26). The appliance must be carefully inspected for breakage at each visit. With the Herbst, after a positive treatment response is noted, changes in the pin and tube length can be made during treatment to increase the amount of advancement simply by adding sleeves to the pin to restrict its travel into the tube (Fig. 14.27). With the MARA, advancement is achieved with shims on the elbow wire to advance it (Fig. 14.28). A fixed (or removable) Twin-Block appliance can have plastic resin added to the inclines to increase the advancement without totally remaking the appliance. Plastic also can be removed adjacent to the teeth to allow drift, especially on the occlusal surfaces to encourage eruption when that is desirable.

It is possible to make a Twin-Block appliance partially fixed and partially removable (Fig. 14.29). This also is possible with a Herbst appliance. In both cases, this typically involves a fixed upper and removable lower splint. In this case, the fixed and removable parts should be carefully explained so that the child does not remove or loosen the appliance because of a misunderstanding.

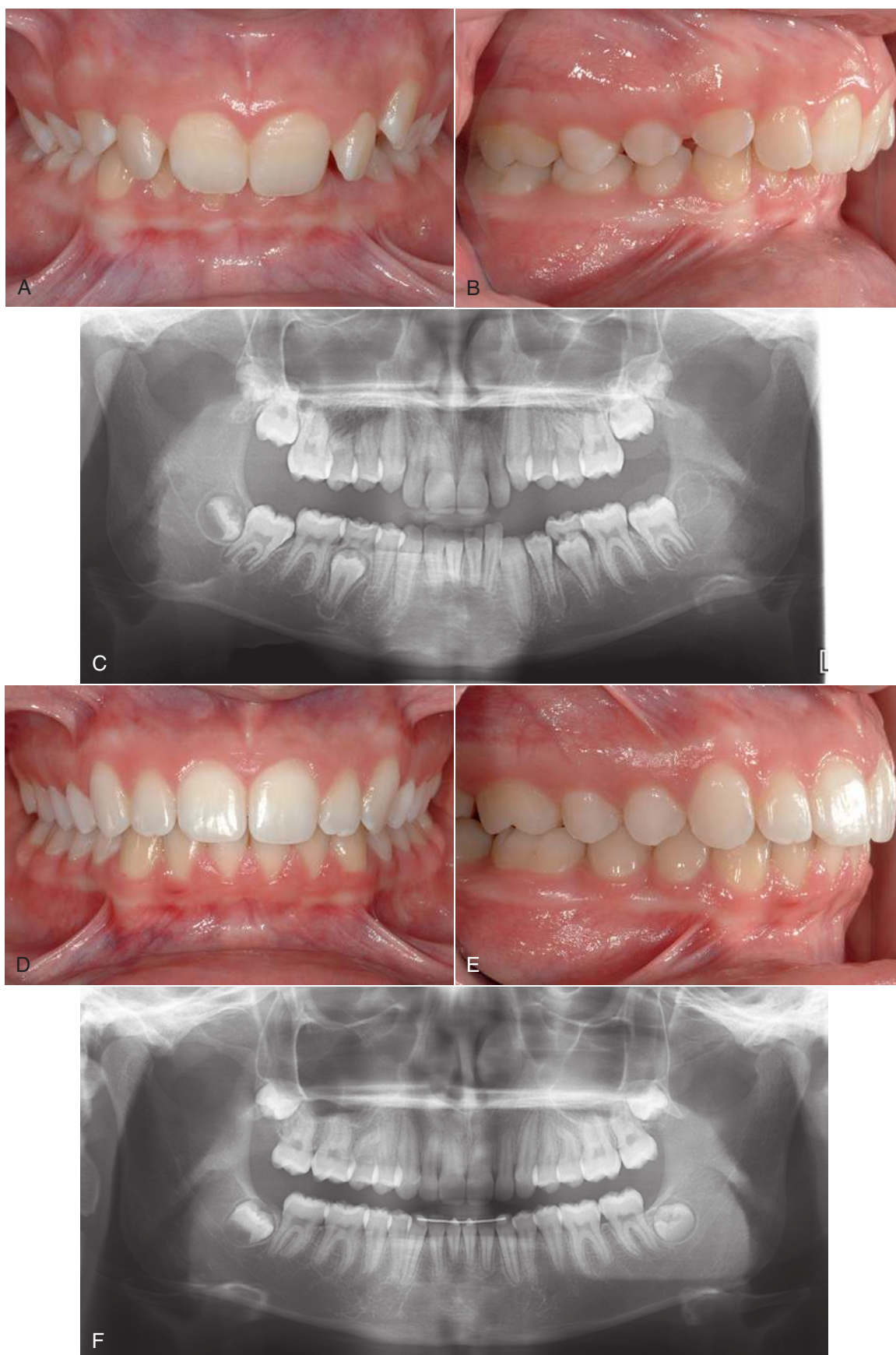
The Forsus appliance requires a different orientation because it is assembled from preformed parts chairside once the archwire sequence has advanced to the required stiffness after alignment of the teeth. It can be helpful to place lingual root torque in the incisors to combat proclination. The spring module is attached to the molar with use of the headgear tube. The Forsus measuring gauge is used to determine the correct size pushrod to insert into the spring module and provide activation. The pushrod can be placed distal to either the lower canine or the first premolar by use of the loop closed around the archwire. This is determined by



• **Fig. 14.25** (A) Pretreatment frontal and (B) lateral images of a patient treated with a Herbst appliance. The patient has mild Class II skeletal and dental relationships and normal vertical facial proportions.

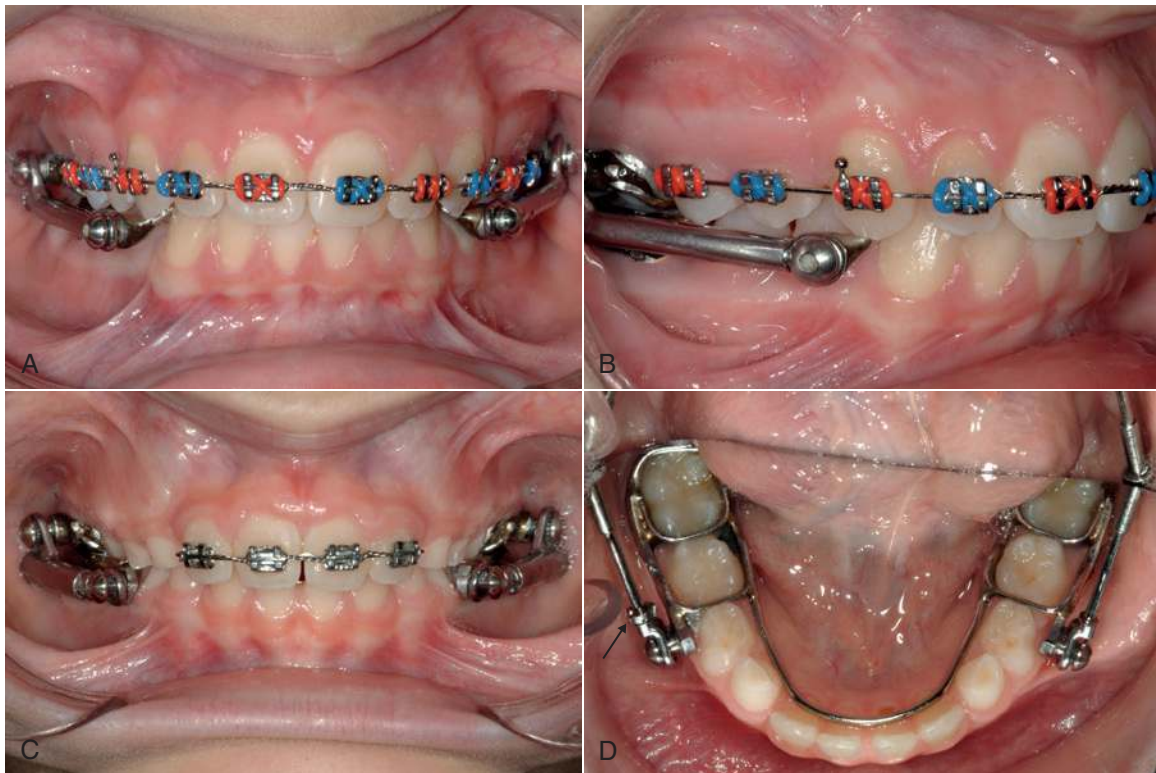


• **Fig. 14.25, cont'd** (C and D) The posttreatment facial images show less facial convexity and, again, normal vertical proportions. (E) The overall cranial base superimposition demonstrates some maxillary restraint (headgear effect) and mandibular downward and forward growth. (F) The maxillary superimposition shows the proclination of the upper incisors so the mandible could be advanced, and (G) the mandibular symposium shows lower molar eruption and mesial movement. These changes allowed and enhanced the Class II correction. (Courtesy Dr. T. Shaughnessy.)

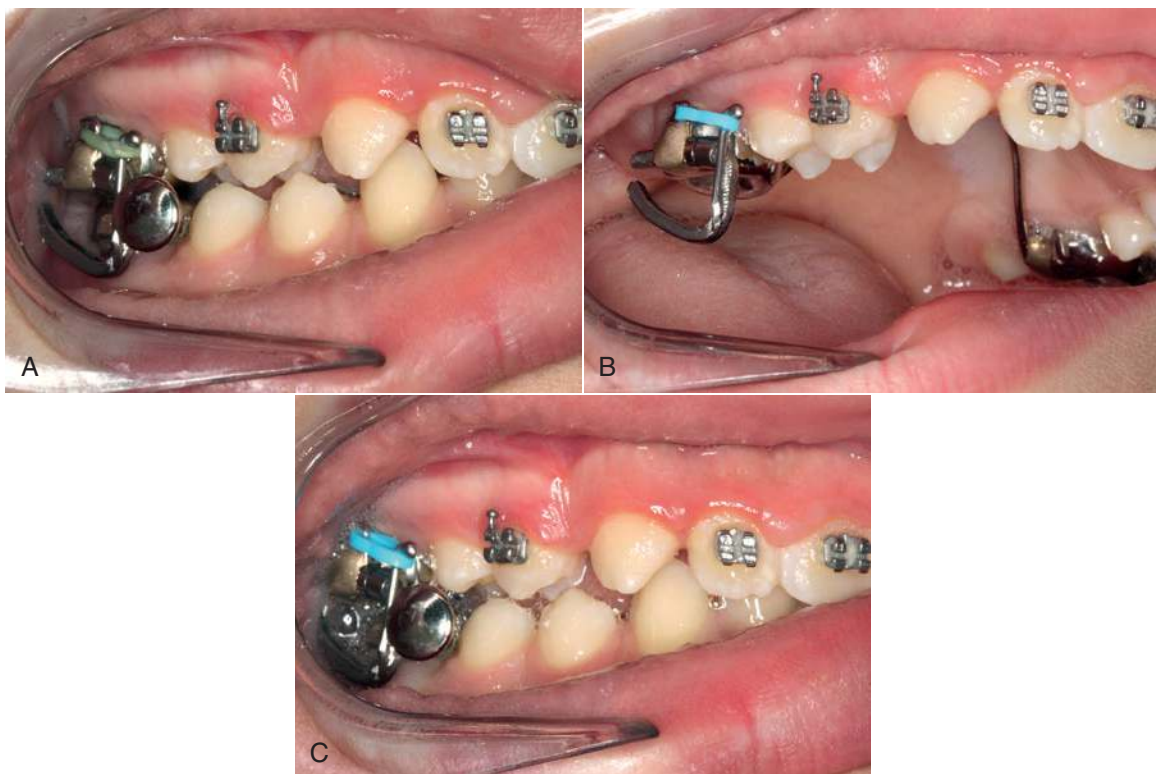


• **Fig. 14.26** (A and B) Prior to treatment, this patient had an anterior deep bite and a Class II molar relationship but limited overjet due to the upright central incisors (really a Class II division 2 incisor relationship). This made pre-Herbst appliance incisor proclination necessary. (C) The panoramic radiograph shows all teeth present or erupting. (D and E) The posttreatment intraoral views show excellent molar, canine, and overjet relationships. (F) At the end of treatment, only third molars remain to erupt. (Courtesy Dr. T. Shaughnessy.)



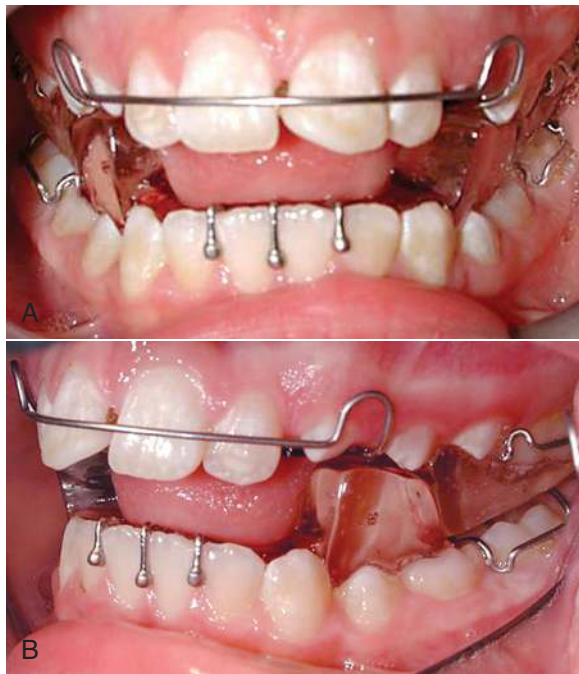

• **Fig. 14.27** (A and B) The Herbst appliance in place after upper incisor alignment. (C and D) Note the shim in place (arrow on mandibular right). This section of a split tube is placed over the plunger and crimped so that the tube is closed to further advance the mandible at an adjustment appointment. This banded appliance is cantilevered off the mandibular molars and supported with a lingual arch.



• **Fig. 14.28** (A) The mandibular anterior repositioning appliance (MARA) in place with the initial shim to advance the upper elbow and force the patient to advance the mandible forward to occlude. (B) A second and smaller shim in place to further advance the mandible. The elbow is secured with a new elastomeric module. (C) The patient in the occluded position after the adjustment.

the direction of force desired and the amount of activation. The appliance can be reactivated for more advancement by either placement of a split spacer on the pushrod, moving from the distal aspect of the canine to the distal aspect of the premolar for pushrod placement, or use of a new, longer pushrod (Fig. 14.30). Usually



• **Fig. 14.29** The Twin-Block appliance can be used as a cemented (fixed) or removable appliance. (A) This patient had a Class II malocclusion treated with a removable Twin-Block appliance that advanced the mandible (B). The ramps on the separate upper and lower units force the mandible to a more protruded and vertically increased position. Adjustments can be made to the occlusal coverage and the inclines to modify eruption and the amount of advancement. Cementing the upper section greatly increases the chance that both parts of the appliance will be worn because the patient then is more comfortable with the lower section in place. (Courtesy Dr. M. Mayhew.)

a reasonable activation has 2 mm of space between the completely compressed spring and the pushrod stop when the patient is in centric relation. Different length pushrods on the right and left sides can be used to correct mild asymmetry.

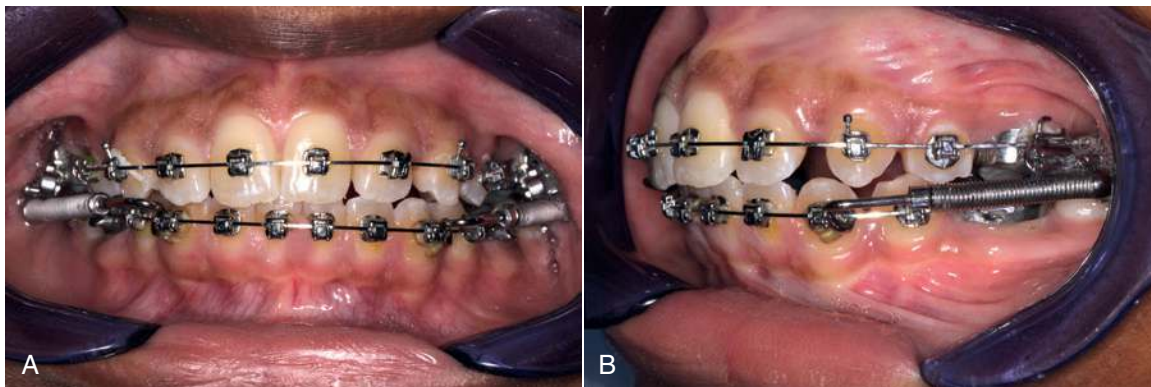
When the desired advancement has been achieved with any of the fixed Class II correctors and the patient is stable (anticipating 1 to 2 mm of relapse), then the appliance can be removed. A Herbst appliance usually is worn for 8 to 12 months, at which point the desired correction should have been obtained, and similar timing is expected with the other fixed functional appliances. In the case of the Herbst appliance or the MARA, a bur to cut the crowns, a crown or band splitter, or band-removing pliers inserted in the crown removal holes are possible removal methods.

For the Forsus, when the desired change has been accomplished after 6 to 8 months, the appliance is deactivated so that the spring is essentially passive for 4 to 6 weeks. Then the spring module is removed from the headgear tube and the pushrod is detached from the archwire by opening the loop with pliers, a cutter, or a scaler. For all the fixed functional appliances, adverse vertical effects (opening of the posterior bite) or adverse horizontal effects (Class III over-correction of Class II relapse) can occur. These can be countered with either a posterior box elastic or Class III or Class II elastics, respectively, if full appliances are in place.

Records should be obtained at the end of phase 1 growth modification treatment to document the progress and plan the details and timing of the second phase of treatment. If the patient is still in the mixed dentition period when the desired correction is achieved, the Herbst appliance or MARA can be removed at that point, but it is important to consider use of a removable functional appliance of the activator or Bionator type as a retainer when this is done (see Chapter 18). This retainer should be worn approximately 12 hours per day until the patient is ready for the second phase of fixed appliance treatment. Avoiding a prolonged retention period is a major reason for delaying fixed functional treatment until the adolescent growth spurt is beginning.

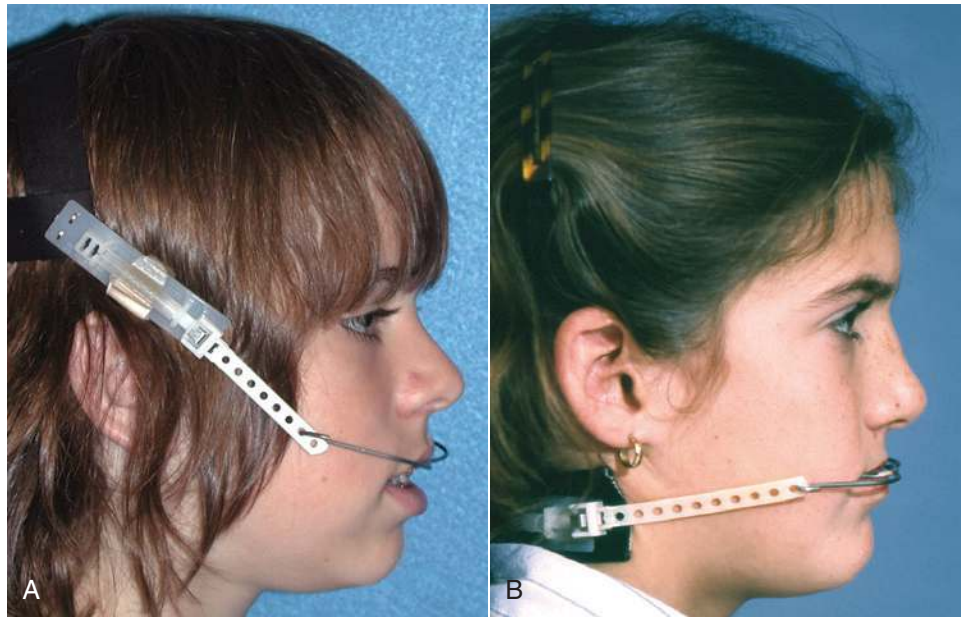### Treatment Procedures With Headgear

**Components of Headgear.** There are two major components of a headgear appliance: the facebow and the neckstrap or headcap. Facebows are fairly standard and simply apply the force to the



• **Fig. 14.30** (A) The Forsus appliance in place with heavy upper and lower archwires and the mandible advanced to near edge-to-edge incisors. (B) Note the crimped spacer adjacent to the spring that activates the mandibular advancement position. Although this shows the appliance from the upper molar to the distal of the canine, it can run from the upper molar to the distal aspect of the second premolar. This is less obtrusive to the patient but will have an increased vertical, intrusive component.





• **Fig. 14.31** Various types of headgear provide different directions of force for different clinical situations. (A) High-pull headgear consists of a headcap connected to a facebow. The appliance places a distal and upward force on the maxillary teeth and maxilla. (B) Cervical headgear is made up of a neckstrap connected to a facebow. This appliance produces a distal and downward force against the maxillary teeth and the maxilla.

teeth, although they come in varying sizes to accommodate the size of the arches. A facebow is usually applied to the permanent first molars but can be applied through splints and functional appliances. The anchorage component (headcap or neckstrap) is responsible for the direction of the force, either above the occlusal plane or below the occlusal plane, respectively (Fig. 14.31).

**Effects of Extraoral Force on the Maxilla.** Numerous studies, including recent clinical trials, have shown that headgear force can decrease the amount of forward and/or downward growth of the maxilla by changing the pattern of apposition of bone at the sutures. Class II correction is obtained as the mandible grows downward and forward normally while similar forward growth of the maxilla is restrained, so mandibular growth is a necessary part of the treatment response to headgear (Fig. 14.32). As noted earlier, there is some evidence of increased mandibular growth during treatment with headgear. Keeling et al suggested that this might be due to the use of a biteplate in conjunction with headgear,<sup>11</sup> but a similar acceleration of mandibular growth has been noted in other studies of headgear outcomes in which a biteplate was not used. Whatever the mechanism, headgear does appear to have both maxillary and mandibular effects.

In a growing patient, headgear must be worn regularly for at least 10 to 12 hours per day to be effective in controlling growth. The growth hormone release that occurs in the early evening strongly suggests that, as with functional appliances, putting the headgear on right after dinner and wearing it until the next morning—not waiting until bedtime to put it on—is an ideal schedule. The current recommendation is a force of 12 to 16 ounces (350 to 450 gm) per side. When teeth are used as the point of force application, some dental as well as skeletal effects must be expected. Extremely heavy forces (greater than 1000 gm total) are unnecessarily

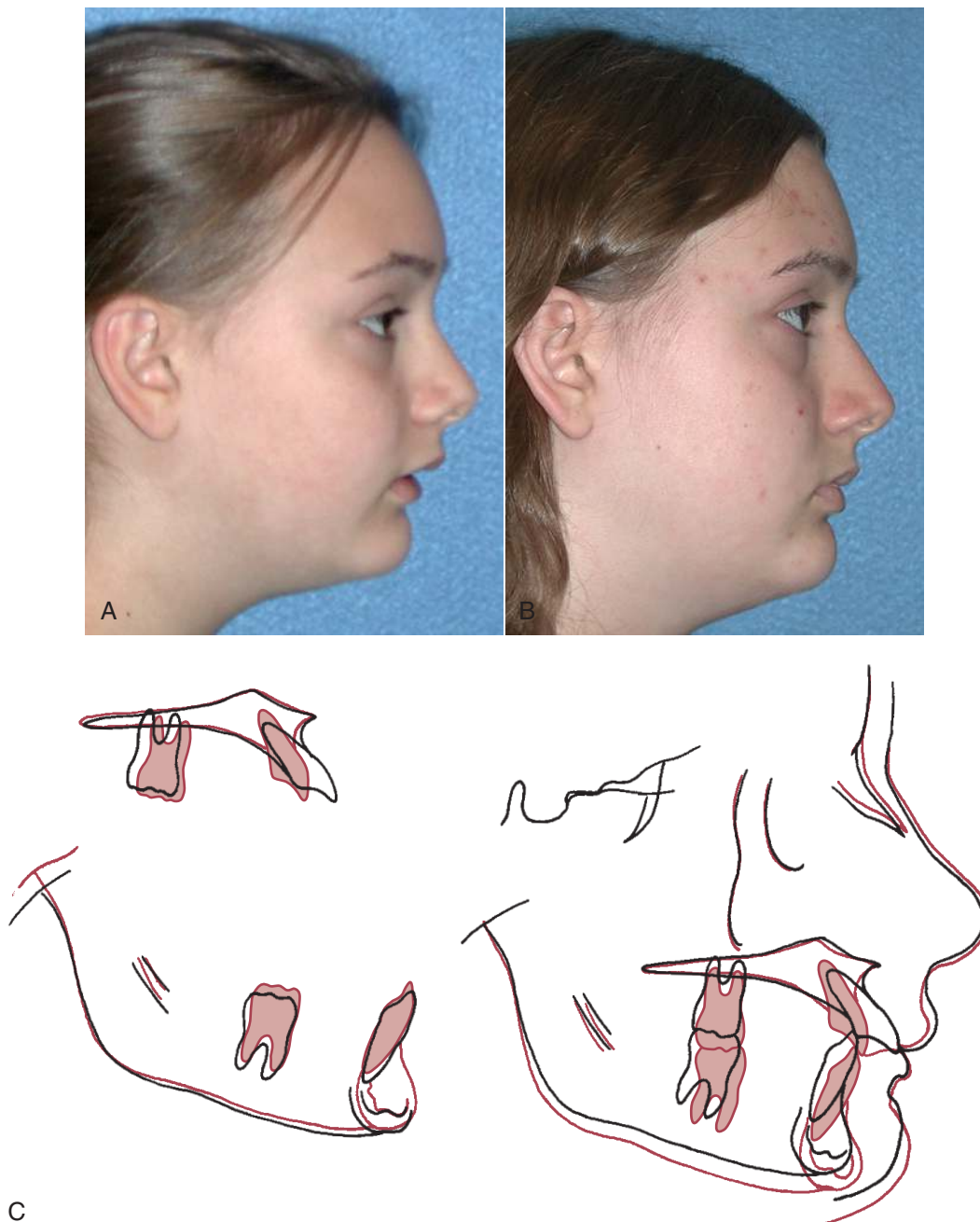traumatic to the teeth and their supporting structures; lighter force may produce dental but not skeletal changes.

To correct a Class II malocclusion, the mandible needs to grow forward relative to the maxilla. For this reason it is important to control the vertical position of the maxilla and the maxillary posterior teeth. Downward movement of either the maxilla or the maxillary posterior teeth tends to project mandibular growth more vertically, which nullifies most of the forward mandibular growth that reduces the Class II relationship (Fig. 14.33). The molars should not be elongated, and distal tipping of these teeth should be minimized when the objective is a change in skeletal relationships (Fig. 14.34). In addition, it is necessary to try to control vertical growth of the maxilla. For these reasons, high-pull headgear usually is preferred.

In theory, the movement of the maxilla can be controlled in the same way as a single tooth is controlled: by managing forces and moments relative to the center of resistance of the jaw. In practice, it is difficult to analyze exactly where the center of resistance and center of rotation of the maxilla might be, but they are above the teeth and most likely above the premolar teeth. Directing the line of force closer to the center of resistance is another major reason for including an upward direction of pull for most children who have headgear force to the maxilla.

**Selection of Headgear Type.** There are three major decisions to be made in the selection of headgear. First, the headgear anchorage location must be chosen to provide a preferred vertical component of force to the skeletal and dental structures. A high-pull headcap will place a superior and distal force on the teeth and maxilla, whereas a cervical neckstrap will place an inferior and distal force on the teeth and skeletal structures (see Fig. 14.31). A straighter distal pull can be produced by a combination of the



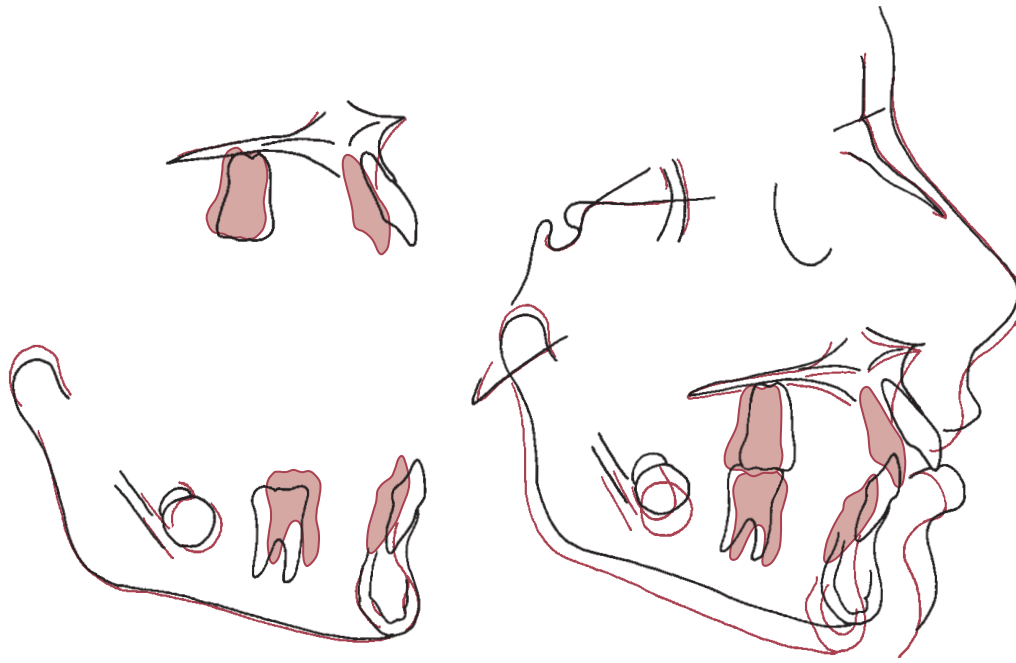


• **Fig. 14.32** A good response to headgear treatment. (A) Pretreatment. (B) Appearance after approximately 2 years of headgear treatment. (C) Cephalometric superimpositions. Note the favorable downward-forward mandibular growth with limited change in the maxillary position. There also were limited incisor changes other than some eruption and maxillary incisor retraction.

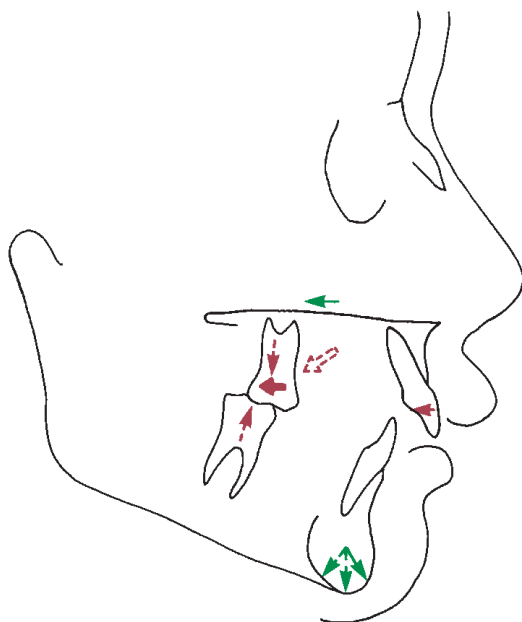
two or a modified and lower headcap, but these methods are not commonly used. The initial choice of headgear configuration is usually based on the original facial pattern: the more signs of a vertically excessive growth pattern are present (see [Chapter 6](#)), the higher the direction of pull and vice versa. Reports of responses to headgear treatment show, however, that there is considerable variation and unpredictability in growth response. Cervical headgear does not always aggravate vertical problems, especially when there is good vertical mandibular growth<sup>28</sup> and minimal distal

movement of maxillary molars, which is the best predictor of vertical opening.

The second decision is how the headgear is to be attached to the dentition. The usual arrangement is a facebow to the large headgear tubes on the permanent first molars. Alternatively, a removable maxillary splint or a functional appliance can be fitted to the maxillary teeth and the facebow attached to it. This may be indicated for children with excessive vertical growth (which is discussed further later in this chapter). Attaching headgear to



• **Fig. 14.33** This child had a poor response to headgear treatment for a Class II malocclusion. The cranial base superimposition indicates that the lips were retracted and the maxilla did not grow anteriorly. The maxillary superimposition shows that the incisors were retracted and the molar movement and eruption were limited. All these effects were beneficial for Class II correction, but the mandible rotated downward and backward because of the inferior movement of the maxilla and eruption of the lower molar. As a result, the profile is more convex than when treatment began, and the Class II malocclusion is uncorrected.



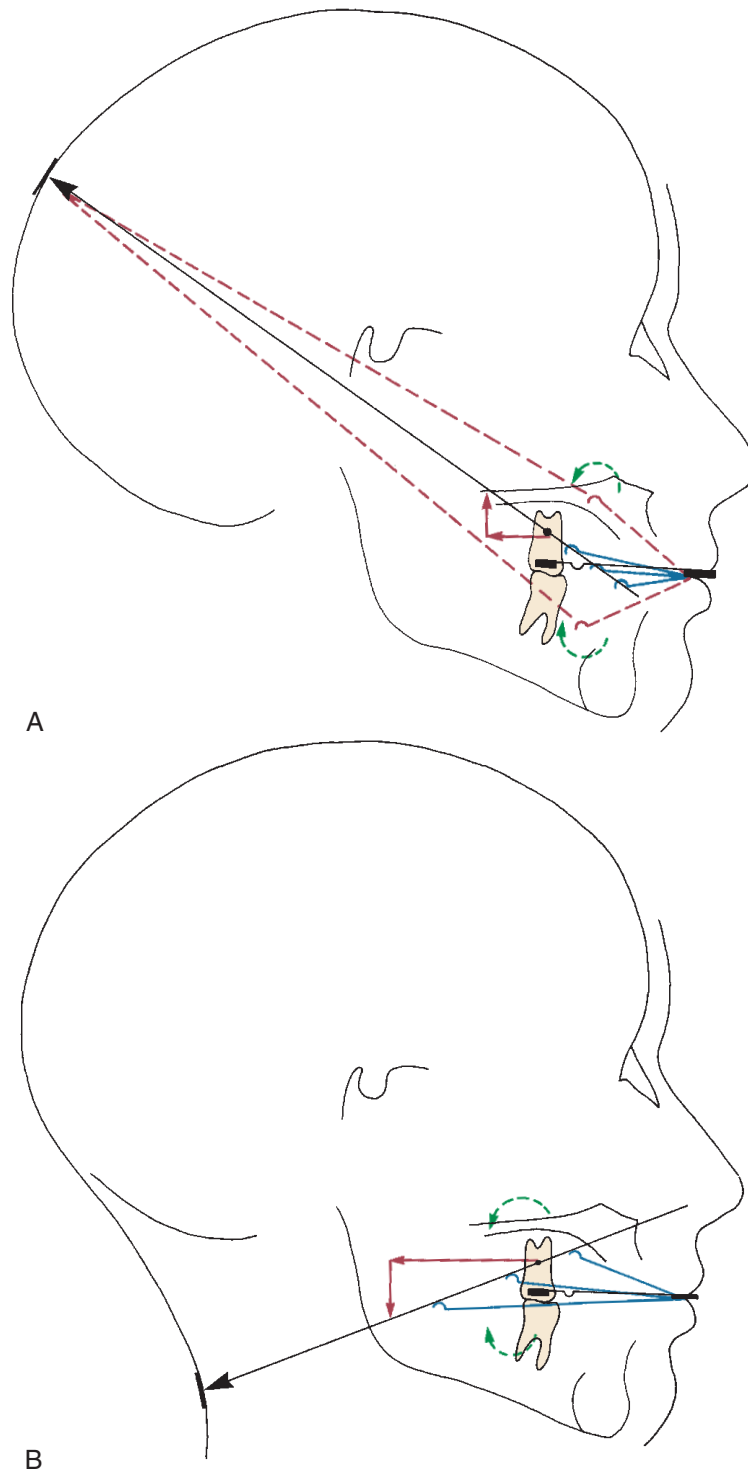
• **Fig. 14.34** Headgear treatment can have several side effects that complicate correction of Class II malocclusion. If the child wears the appliance, maxillary skeletal and dental forward movement will be restricted. Although this helps in correction of the Class II malocclusion, vertical control of the maxilla and maxillary teeth is important because this determines the extent to which the mandible is directed forward and/or inferiorly. Downward maxillary skeletal movement or maxillary and mandibular molar eruption (all shown in *dashed arrows*) can reduce or totally negate forward growth of the mandible.

an archwire anteriorly is possible but rarely practical in children with mixed dentition and produces relatively heavy forces on anterior teeth.

Finally, a decision must be made as to whether bodily movement or tipping of the teeth is desired. Because the center of resistance for a molar is estimated to be in the midroot region, force vectors above this point should result in distal root movement. Forces through the center of resistance of the molar should cause bodily movement, and vectors below this point should cause distal crown tipping. The length and position of the outer headgear bow and the form of anchorage (i.e., headcap or neckstrap) determine the vector of force and its relationship to the center of resistance of the tooth. These factors determine the molar movement.

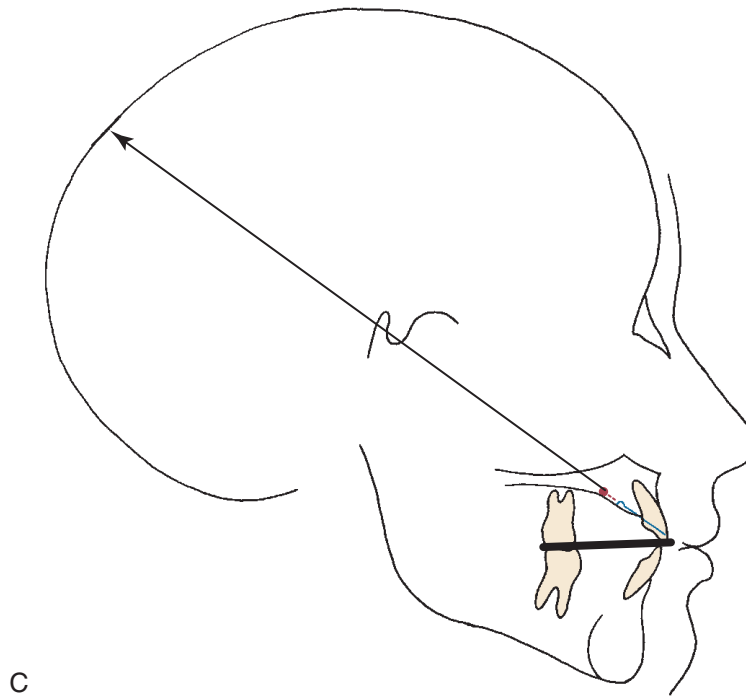
The various combinations of force direction (anchorage), length of outer bow, and position of outer bow are diagrammatically illustrated in Fig. 14.35. As in any growth modification treatment, tooth movement usually is an undesirable side effect, and with headgear, tooth movement is minimized because the teeth must move bodily if they move at all.

Similar considerations apply to the maxilla: unless the line of force is through its center of resistance, rotation of the jaw (the skeletal equivalent of dental tipping) will occur. Control of the line of force relative to the maxilla is easier when a splint covering all the teeth is used to apply the headgear force. The facebow is usually attached to the splint in the premolar region so that the force can be directed through the center of resistance of the maxilla, which is estimated to be located above the premolar roots (see Fig. 14.35C). Distal tipping of the maxillary incisors is likely to occur, however, because the distal component of the force is delivered to these teeth.



• **Fig. 14.35** These diagrams illustrate effects of four commonly used types of facebow and extraoral anchorage attachments. In each diagram, the inner bow is shown in black and the various outer bow possibilities in red or dashed red. (A) High-pull headgear (headcap) to the first molar. To produce bodily movement of the molar (no tipping), the line of force (*black arrow*) must pass through the center of resistance of the molar tooth. This will produce both backward and upward movement of the molar. Note that the line of force is affected by the length and position of the outer bow, so a longer outer bow bent up or a shorter one bent down could produce the same line of force. If bow length or position produces a line of force above or below the center of resistance (*dashed red*), the tooth will tip with the root or the crown, respectively, going distally because of the moment that is produced. (B) Cervical headgear (neckstrap) to the first molar. Again, bodily movement is produced by an outer bow length and position that place the line of force through the center of resistance of the molar; with a lower direction of pull, the tooth is extruded as well as moved backward. Note that the outer bow of a facebow used with cervical traction nearly always is longer than the outer bow used with a high-pull headcap. If the line of force is above or below its center of resistance, the tooth will tip with the root or crown, respectively, going distally as indicated by the dashed arrows.





• **Fig. 14.35, cont'd** (C) High-pull headgear to a short facebow inserted into a maxillary splint. With all the teeth splinted, it is possible to consider the maxilla as a unit and to relate the line of force to the center of resistance of the maxilla. As with headgear force against the first molar, the relationship of the line of force to the center of resistance of the maxilla determines the rotational effect on the maxilla.

**Clinical Management of Headgear.** For headgear treatment, molar bands with headgear tubes (and any other attachments that might be needed later in treatment) are fitted and cemented. Bands, not bonded tubes, are necessary to accommodate the heavy forces, and tight-fitting bands, possibly crimped at the cervical margin, provide the best band retention. Fitting and adjustment of the preformed facebow, which must reflect the biomechanical goals of the treatment plan, are shown in [Figs. 14.36](#) and [14.37](#).

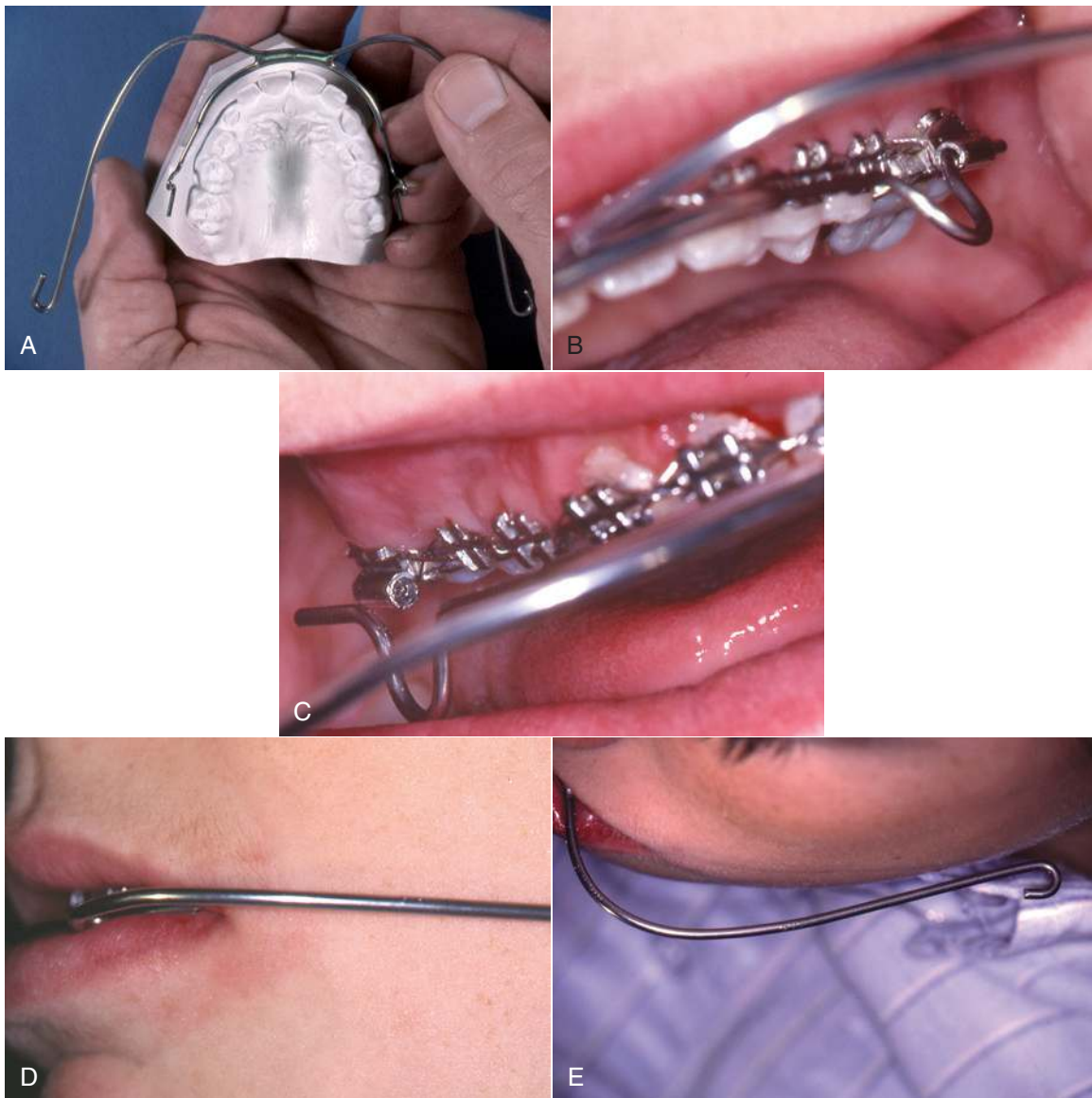
As a Class II molar relationship is corrected, the relative forward movement of the lower arch will produce a crossbite tendency unless the upper arch width is expanded. This must be taken into account from the beginning of treatment. The inner bow should be expanded by 2 mm symmetrically so that when it is placed in one tube, it rests just outside the other tube. The patient will need to squeeze the inner bow as it is inserted to make it fit the tubes, thus providing the appropriate molar expansion.

The appropriate headcap or neckstrap is fitted by selecting the appropriate size. A spring mechanism or tension module—not elastic bands or straps—is strongly recommended to provide the force. The springs deliver consistent forces that can be documented and easily adjusted. The spring attachment is adjusted to provide the correct force with the patient sitting up or standing—not reclining in the dental chair ([Fig. 14.38A–B](#)). It is usually a good idea to start with a low force level to acclimate the patient to the headgear and then gradually increase the force at subsequent appointments. Even if the correct force level is set at the first appointment, the forces will drop when the strap stretches slightly and contours to the patient's neck. Once the forces are correct, the bow position must be rechecked because the pull of the straps and any adjustments to the inner or outer bow to improve fit and

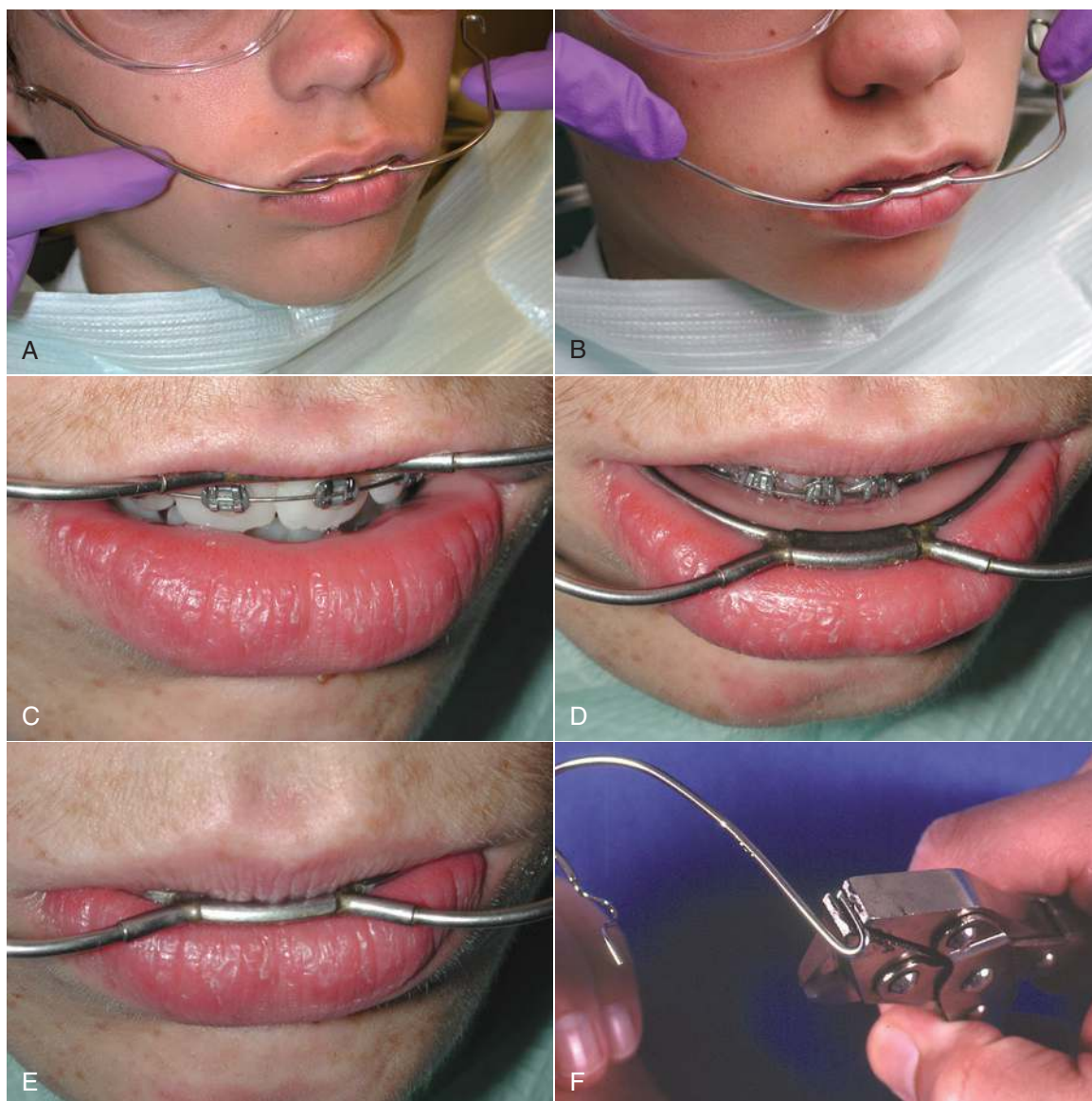
patient comfort can alter the previous bow position so that it needs adjustment.

The patient should place and remove the headgear under supervision several times to be certain that he or she understands how to manipulate it and to ensure proper adjustment. Most headgear is worn after school, during relaxed evening hours, and during sleep. It is definitely not indicated during vigorous activity, bicycle riding, or general roughhousing. Children should be instructed that if anyone grabs the outer bow, they should also grab the bow with their hands. This will prevent breakage and injury. The headgear straps must be equipped with a safety-release mechanism ([Fig. 14.38C–D](#)) to prevent the bow from springing back at the patient and injuring him or her if it is grabbed and pulled by a playmate. Severe injuries, including loss of sight, have occurred from headgear accidents of this type.<sup>29</sup> In a review of commercially available headgear-release mechanisms that included 18 different designs, Stafford et al noted that almost all released at 10 to 20 pounds of force and concluded that the amount of extension before release occurred and the consistency of release were the most important variables from a safety perspective.<sup>30</sup>

Some tooth movement inevitably accompanies efforts at Class II growth modification, but that is not growth modification and, as we have noted, can be considered an undesirable side effect—except that it often is necessary to complete correction of the malocclusion. Of course, treatment with tooth movement alone can be successful if both the facial appearance and dental occlusion are satisfactory, as it can be for patients with less severe mandibular deficiency. This is discussed in [Chapter 16](#), where the focus is on management of camouflage treatment.

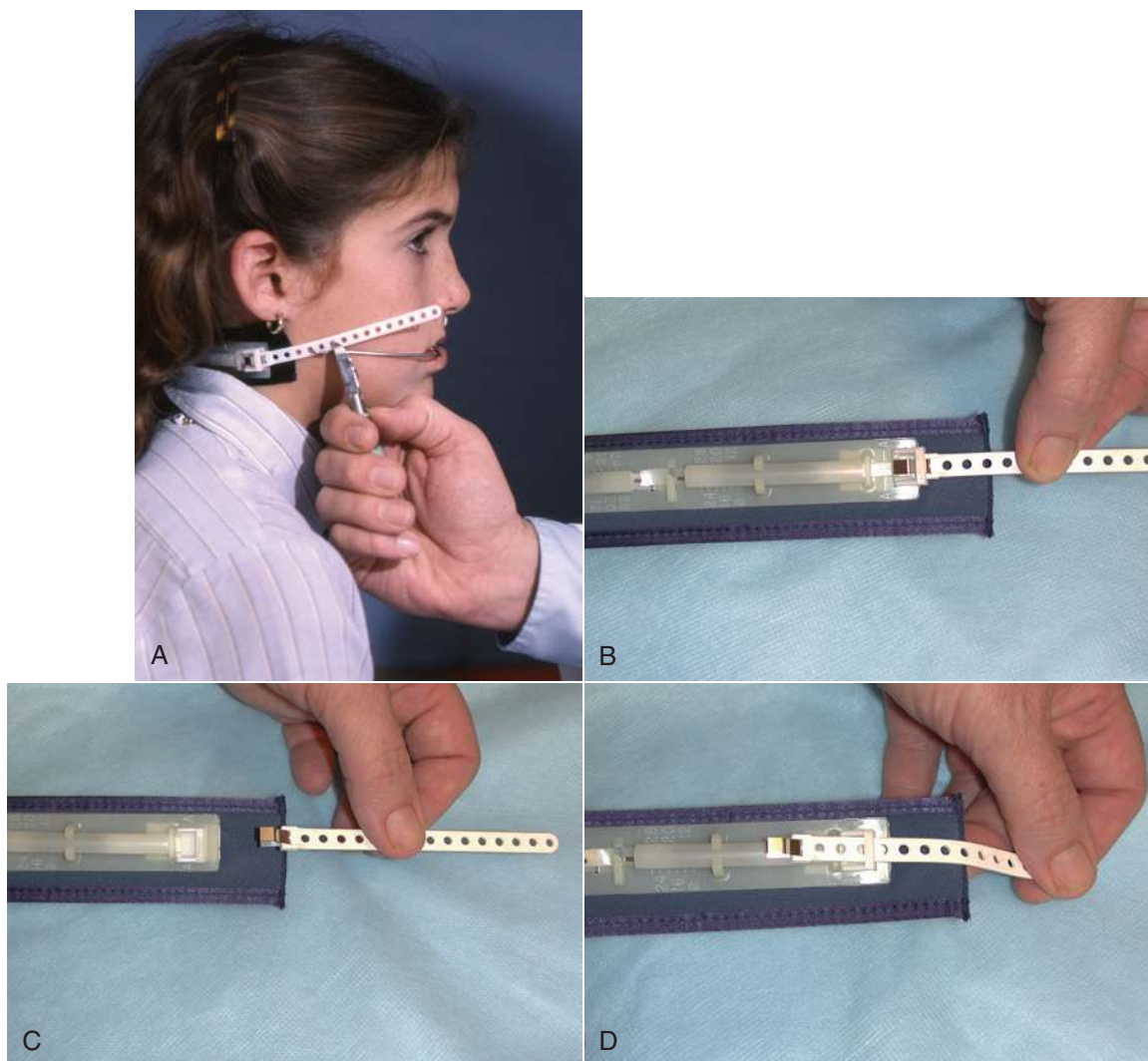


• **Fig. 14.36** The steps for fitting a facebow for a headgear. (A) Preformed facebows are supplied in a variety of inner bow sizes and usually also have an adjustment loop as part of the inner bow. The inner bow should fit closely around the upper arch without contacting the teeth except at the molar tubes (within 3 to 4 mm of the teeth at all points). A simple method for selecting the appropriate size is to fit the bow to the pretreatment maxillary cast. (B) After the bow has been placed in one molar headgear tube, the rest of the facebow is examined to see how it fits relative to the other molar tube and the teeth. (C) By adjusting the loops to expand or contract the inner bow and by bending the short portion of the bow that fits into the molar tubes and facial offsets, it is possible to make the bow passive and allow clearance from the teeth. It should be easy to insert and remove at this point. Then the inner bow must be expanded by 1 to 2 mm to keep the posterior teeth out of crossbite as anteroposterior changes are made. The extension of the inner bow out the end of the headgear tubes should be evaluated. Ideally the end of the inner bow would be flush with the end of the tube, but certainly there is no need for it to extend more than 1 mm past the end of the tube. This limited extension will reduce tissue irritation in the distal portion of the buccal vestibule and friction during application and removal. (D) The facebow should be adjusted so that the junction of the inner and outer bows rests passively and comfortably between the lips. (E) The outer bow should rest several millimeters from the soft tissue of the cheek. This adjustment must be checked both before and after the straps for the headcap or neckstrap are attached.



• **Fig. 14.37** To determine the proper length needed for the outer bow, use the index fingers to apply pressure in the direction of the headgear selected. (A) Pushing up and back in the direction of a high-pull headgear. (B) Pushing down and back in the direction of a cervical headgear. As the fingers are moved from the anterior portion of the outer bow to the posterior portion, the position of the bow between the lips will change. (C) If the bow moves up, the roots on the maxillary first molar will move distally. (D) If the bow moves down on the lower lip, the roots of the maxillary first molar will move mesially and the crown distally. (E) If the bow does not move, the force is through the center of resistance of the maxillary first molar and the molar will move bodily and not rotate. These rules hold true for both high-pull and cervical-pull headgears. (F) After the correct length is chosen and the outer bow cut with pliers, a hook is bent at the end with a heavy pliers.





• **Fig. 14.38** Adjustment of the neckstrap. (A) The neckstrap is attached to the facebow, and the proper force is obtained from the spring mechanism or tension module by moving the hook to adjacent holes on the neckstrap. When the force is correct, the plastic connector is cut so that one extra hole is present in front of the correct hole. This provides a tab for the patient to grasp when placing the headgear. (B) The spring mechanism or tension module delivers a predetermined force when the plastic connector is moved forward and aligned with a calibration mark or when the tension module is extended a given amount (usually best determined with a force gauge). Here the rear of the tab is slightly anterior to the calibration mark. (C) If the connector is stretched further, such as it might be if someone grabbed the facebow and pulled on it, the plastic strap or tension module will release, preventing the bow from springing back into the patient's face and causing injury. (D) The connector can be reassembled by threading it through the back of the safety release or the tension module reattached.

## Combined Vertical and Anteroposterior Problems

Skeletal vertical problems are so intertwined with excessive or deficient dental eruption that it can be difficult to determine the extent to which skeletal disproportions versus tooth eruption deviations are involved. The best way to think about this is to remember that as the mandible grows downward away from the maxilla, a space is created into which the teeth must erupt to remain in contact. From that perspective, it is apparent that a patient with deficient vertical growth also would have deficient eruption of the teeth,

and vice versa. The situation is further confused, however, because the vertical position of the maxillary posterior teeth determines the vertical position of the mandible, and so if for some reason there is excessive eruption of those teeth, the mandible would be rotated downward and backward. That means that short-face problems are easier to manage with growth modification.

### Short Face/Deep Bite

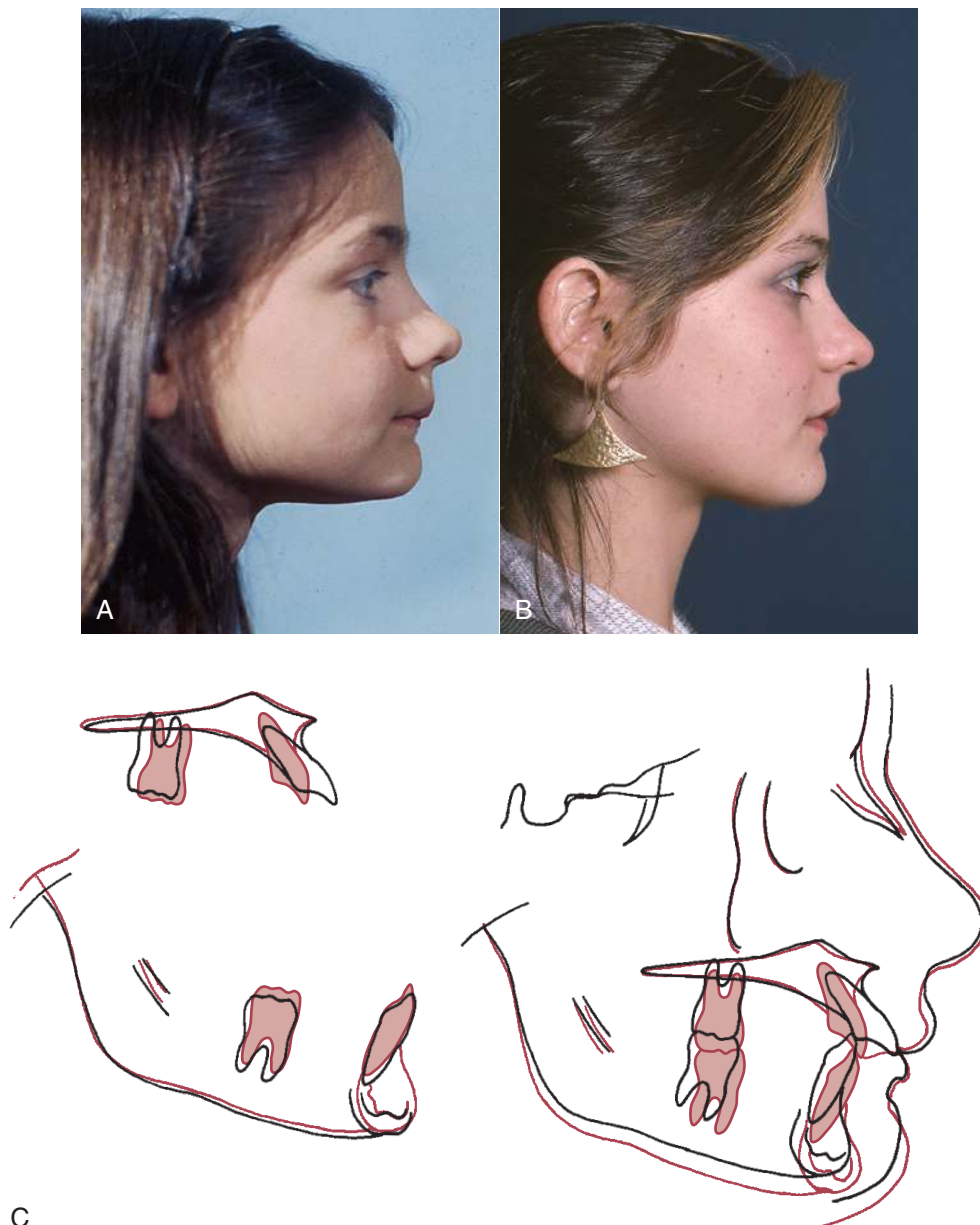
Some children exhibit a skeletal vertical deficiency (short face), almost always in conjunction with an anterior deep bite and some

degree of mandibular deficiency and often with a Class II division 2 malocclusion. The reduced face height is often accompanied by everted and prominent lips that would be normal if the face height were normal.

Children with vertical deficiency can be identified at an early age. They tend to have a low mandibular plane angle (skeletal deep bite) and a long mandibular ramus. Growth is expressed in an anterior direction, with a tendency toward upward and forward rotation of the mandible. The challenge in correcting these problems is to increase eruption of posterior teeth and influence the mandible to rotate downward without decreasing chin prominence too much.

In a patient with Class II malocclusion, one way to correct such problems is with cervical headgear, taking advantage of the extrusive tendency of extraoral force directed below the center of resistance of the teeth and the maxilla (Fig. 14.39). This elongates the upper molars, and eruption of the lower molars can be accentuated by using a biteplate to open the bite along with the headgear. With no posterior occlusion, both upper and lower teeth can erupt.

The other way is to use a functional appliance (usually with mandibular advancement, depending on the anteroposterior jaw relationship) that inhibits eruption of maxillary posterior teeth and allows free eruption of the mandibular posterior teeth

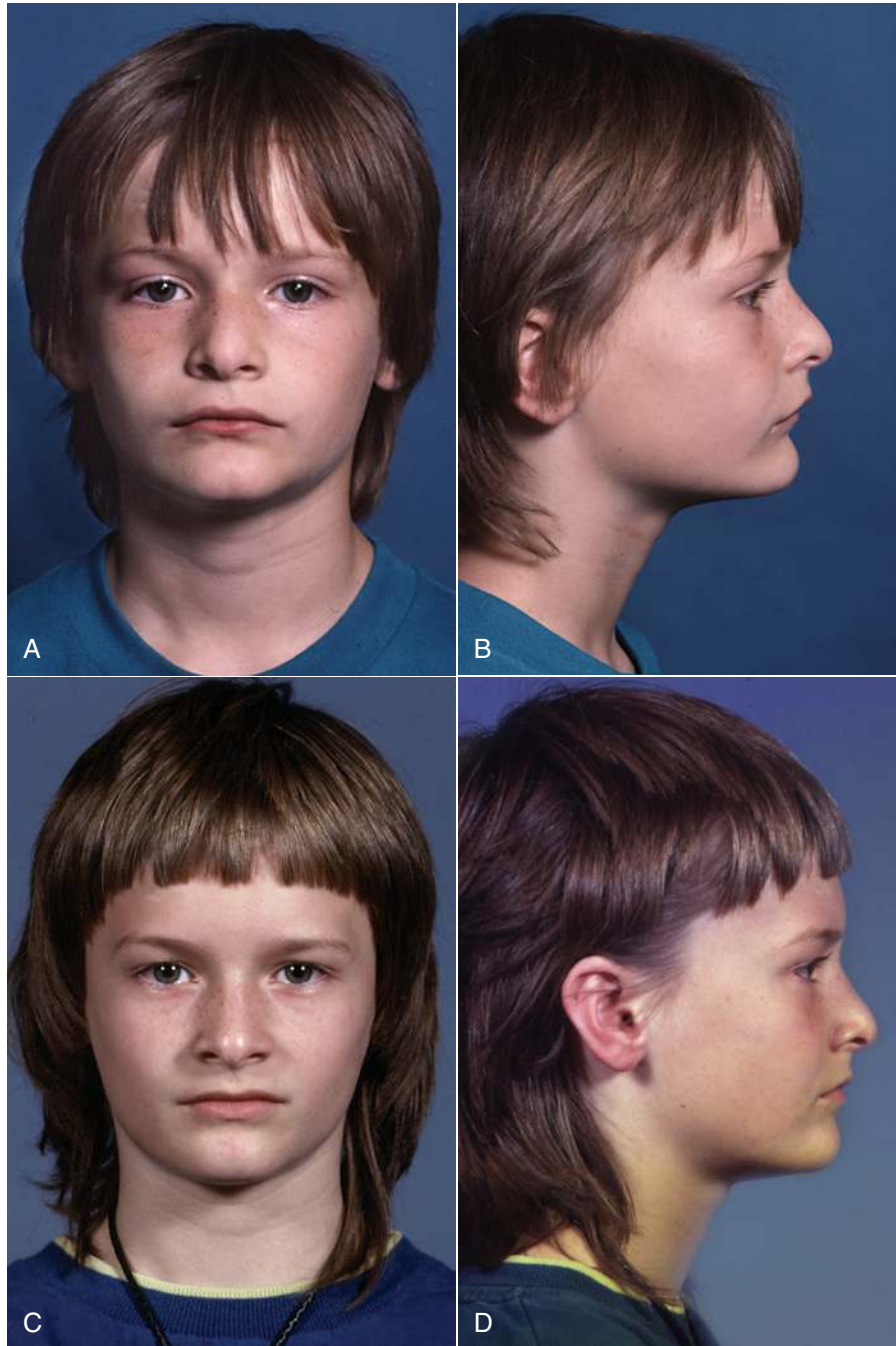

• **Fig. 14.39** Increased vertical development in a child who initially had decreased lower anterior face height. (A) Pretreatment profile. (B) Posttreatment profile. (C) Cephalometric superimpositions. This result was accomplished by increasing the maxillary molar eruption with a cervical-pull headgear, which resulted in downward movement of the mandible and improved facial esthetics. More eruption of the upper than the lower molar, however, can make it more difficult to obtain a good Class I molar relationship.

(Fig. 14.40). Because many short-face children also have a Class II malocclusion, it is important to remember that rotation of the occlusal plane down in front makes it easier to achieve a Class I molar relationship. Cervical headgear produces more eruption of the upper molars and tips the occlusal plane down posteriorly; eruption can be manipulated with a functional appliance so that either the upper or lower molars erupt more. The desired rotation of the occlusal plane occurs when the lower molar erupts more

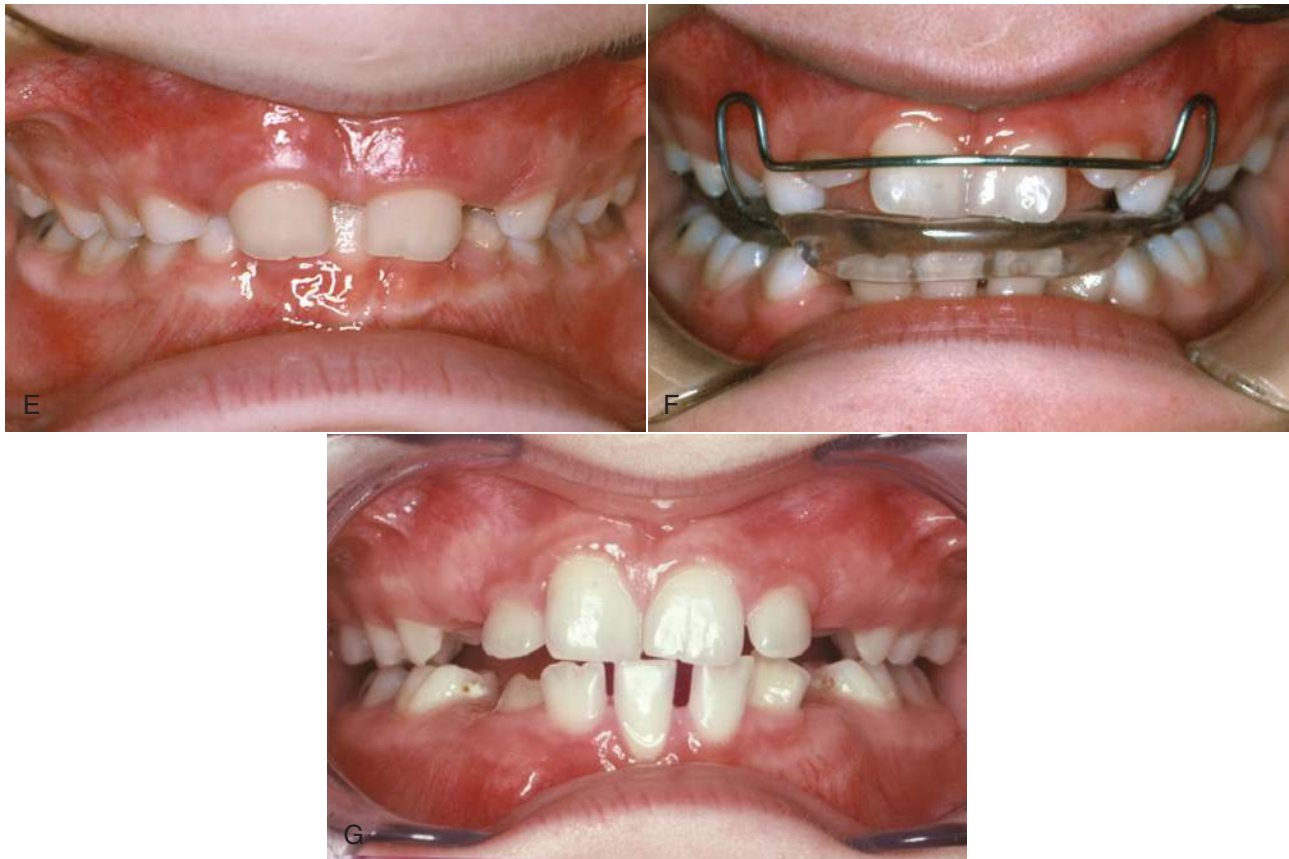than the upper, which means that, all other factors being equal, the functional appliance would be preferred.

The treatment of these short-face Class II patients is a balance between the anteroposterior and the vertical reactions to treatment. One conservative option for a patient with a significant antero-posterior mandibular deficiency and reduced face height is to have growth expressed in an anterior direction first. For this to be accomplished, all vertical eruption is blocked while an appliance



• **Fig. 14.40** Facial changes produced by functional appliance treatment in a boy with a short face and skeletal deep bite malocclusion. (A and B) Age 10 before treatment. (C and D) Age 12 after 26 months of treatment. Note the increase in anterior face height and decrease in the labiomental fold.





• **Fig. 14.40, cont'd** (E) Before treatment. Note the gingival inflammation around the maxillary right central incisor resulting from palatal trauma from the deep bite. (F) Deep bite Bionator, constructed to allow eruption of lower posterior teeth and block eruption of incisors and upper posterior teeth. (G) Dental relationships at the conclusion of phase 1 treatment, age 12. A second stage of treatment will be needed when the remaining succedaneous teeth erupt.

with the mandible advanced is used, which will create a posterior open bite when the appliance is not in place. When the Class II jaw relationship is corrected, the posterior bite block gradually is cut away from the lower molars and premolars while correct overbite is maintained anteriorly, so that slow eruption of lower posterior teeth back into occlusion can occur. This type of treatment places into sharp focus the interaction between the anteroposterior and vertical planes of space that must be addressed during growth modification treatment. The priority is placed on the most severe problem, and then the accompanying problems are addressed.

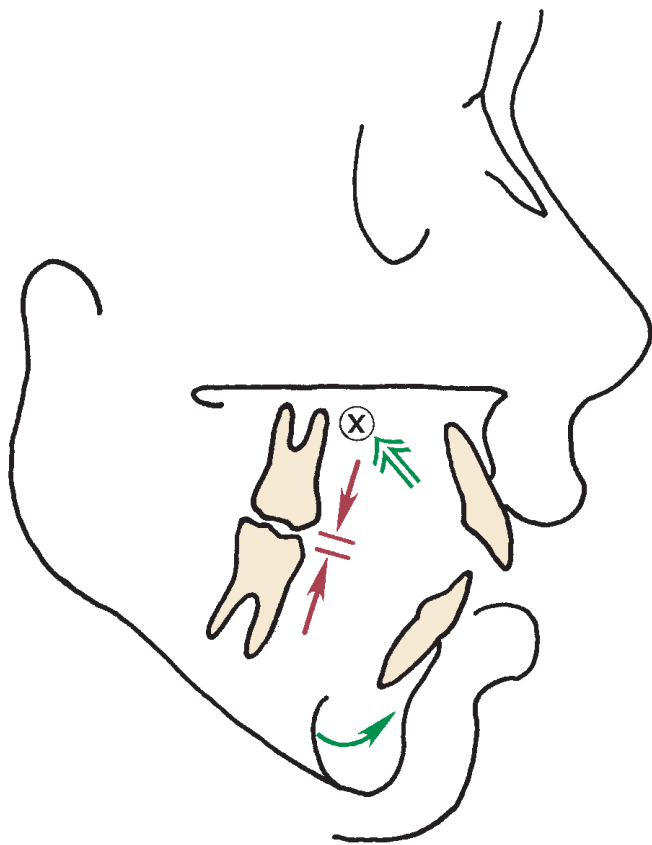
Fixed functional appliances are not good choices in the treatment of short-face problems. Certainly, the Herbst, with its propensity to intrude the upper molars, is not an attractive option for younger patients needing increased vertical dimensions, even though the mandibular plane angle usually does not change very much in Herbst treatment.<sup>31</sup>

It is appropriate to remember that eruption occurs more rapidly in some patients than others, probably because it is affected by resting mandibular posture and freeway space as well as by the amount of appliance wear. Some short-face children show extremely rapid mandibular growth when the bite is opened and incisor overlap is removed, even with so simple an appliance as a biteplate. Unfortunately, this happens only occasionally, and except

for the rare patients in whom there is no mandibular deficiency, posturing the mandible forward to allow the construction of a functional appliance is the better approach. Delivery and adjustment of a functional appliance for a vertically deficient patient are similar to the methods already discussed in the section on mandibular deficiency.

### Long Face/Open Bite

Excessive growth of the maxilla in children with Class II malocclusion has more of a vertical than an anteroposterior component (i.e., there is more excessive growth downward than forward), and if the maxilla moves downward, the mandible rotates downward and backward. The effect is to prevent mandibular growth from being expressed anteriorly. Fortunately, in many preadolescents and young adults, the open bite tendency reduces and may correct completely without treatment.<sup>32</sup> In others, the vertical growth pattern continues through adolescence and into the postadolescent years, and the open bite persists. This means that even successful treatment would need to be retained for a number of years, most likely into the late teens or early 20s. The ideal treatment for these patients would be to stop, or at least decrease, maxillary posterior vertical growth so that the mandible would rotate in an upward



• **Fig. 14.41** Mandibular-deficient children with excessive lower face height need treatment with an appliance that restricts posterior eruption and limits downward growth of the maxilla. This allows mandibular growth to be expressed anteriorly rather than vertically.

and forward direction (Fig. 14.41). This could be accomplished by controlling all tooth eruption if there were adequate mandibular vertical ramus growth.

Vertical facial growth continues through adolescence and into the postadolescent years in the same pattern that created a long-face problem to begin with, which means that even if growth can be modified successfully in the mixed dentition, active retention is likely to be necessary for a number of years. Whatever the appliance and whenever the treatment is started, retention would be critically important until vertical growth is essentially complete in the late teens or early 20s.<sup>32</sup>

The goal of growth modification treatment for long-face problems is to maintain the vertical position of the maxilla and inhibit eruption of the maxillary and mandibular posterior teeth. There are several possible approaches to doing this during preadolescent and adolescent growth. In the order of increasing clinical effectiveness, they are as follows.

### 1. High-Pull Headgear to the Maxillary First Molars

High-pull headgear to the first molars can slow downward growth of the maxilla and stop the eruption of these teeth if it is consistently worn 14 hours a day. The most effective force is about 12 ounces per side (Fig. 14.42). This does not control eruption of the lower molars, which limits its effectiveness in some patients.

### 2. High-Pull Headgear to a Maxillary Splint

A more effective headgear approach for children with excessive vertical development is the use of a plastic occlusal splint to which the facebow is attached.<sup>33</sup> This allows vertical force to be directed against all the maxillary posterior teeth, just the molars, and can be extended forward to contact the incisors if desired. An appliance of this type would be most useful in a child with excessive vertical development of the entire maxillary arch and too much exposure of the maxillary incisors from beneath the lip (i.e., a long-face child who does not have anterior open bite). To achieve both skeletal and dental correction, the patient must be compliant throughout what can be a very long treatment period.

Unfortunately, the maxillary splint still allows mandibular posterior teeth to erupt, and if this occurs, there may be neither redirection of growth nor favorable upward and forward rotation of the mandible.

### 3. Functional Appliance With Bite Blocks

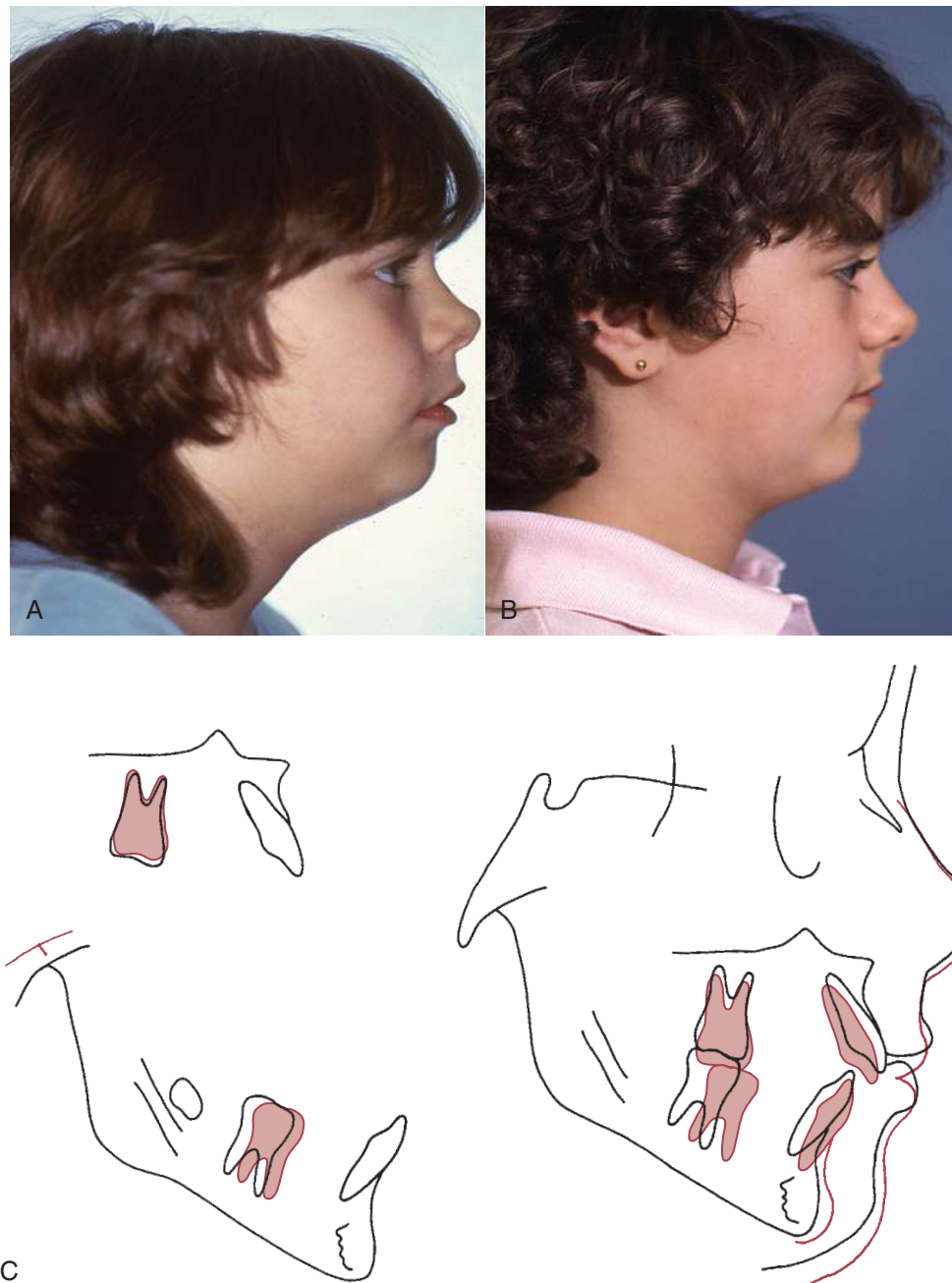
A more effective alternative is the use of a functional appliance that includes posterior bite blocks. The retraction force of the headgear is replaced by the somewhat lesser “headgear effect” of the functional appliance. The primary purpose of the appliance is to inhibit vertical descent of the maxilla and eruption of posterior teeth in both arches. The appliance can be designed with or without positioning the mandible anteriorly, depending on how much mandibular deficiency is present.

Regardless of whether the mandible is brought forward in the working bite, the bite must be opened past the normal resting vertical dimension if molar eruption is to be affected. When the mandible is held in this position by the appliance, the stretch of the soft tissues (including but not limited to the muscles) exerts a vertical intrusive force on the posterior teeth. In children with anterior open bites, the anterior teeth are allowed to erupt, which reduces the open bite, whereas in children with the less common long-face problems without open bite, all teeth are held by the bite blocks. Because there is no compensatory posterior eruption, all mandibular growth should be directed more anteriorly, at least to the extent that the overbite allows.

In the short term, this type of functional appliance treatment can be effective in controlling maxillary vertical skeletal and dental growth,<sup>34</sup> and this helps to close anterior open bites (Fig. 14.43). In the long term, because of the continued vertical growth, if a functional appliance is used for a first phase of treatment during the adolescent growth spurt, posterior bite blocks or other components (such as bone screws for skeletal anchorage) will be needed to control vertical growth and tooth eruption during fixed appliance therapy and probably into retention. This is necessary because fixed appliances do not control eruption well and many biomechanical actions are extrusive.

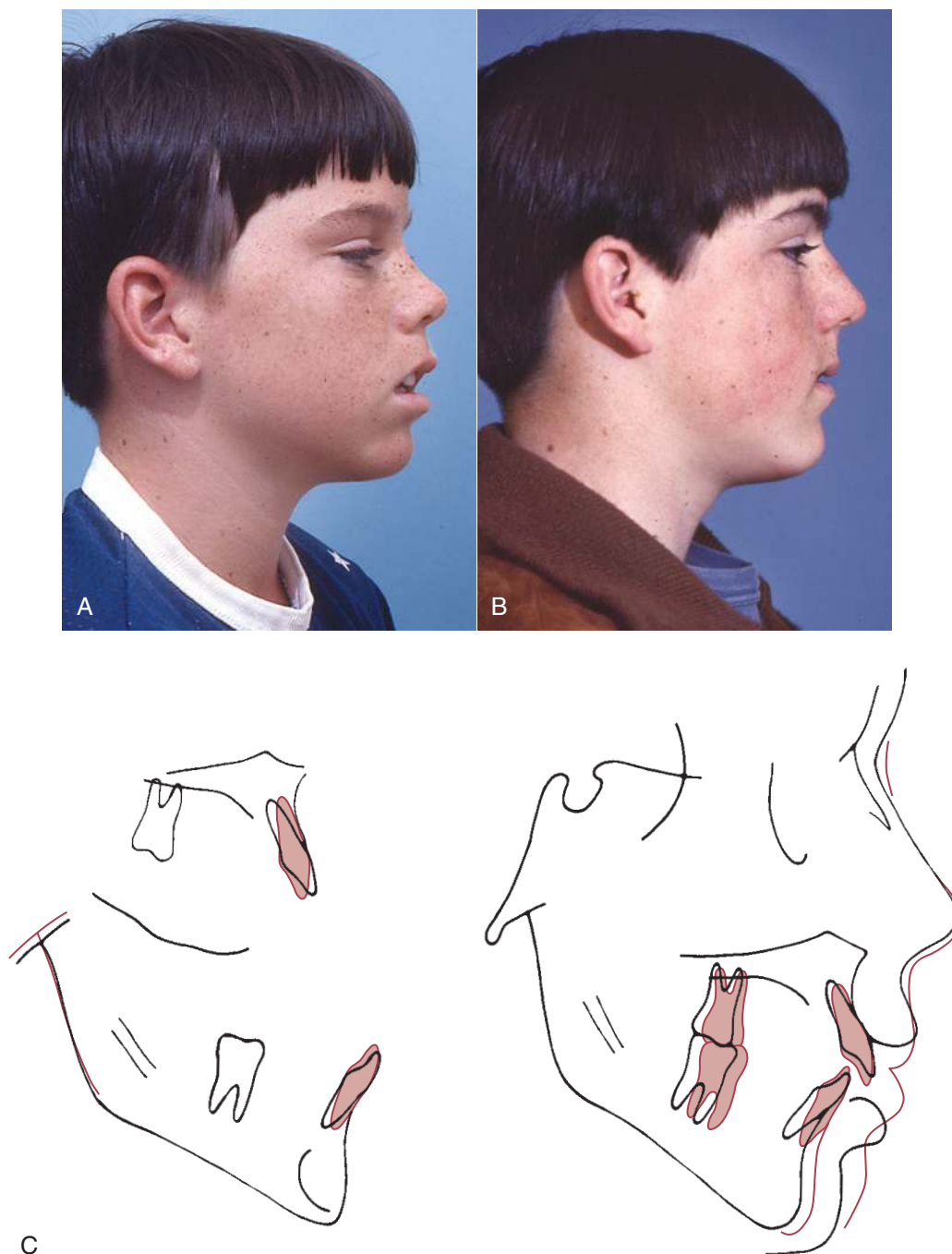
### 4. High-Pull Headgear to a Functional Appliance With Bite Blocks

The most aggressive approach to maxillary vertical excess and a Class II jaw relationship, which has been recommended as a way to treat the most severely affected long-face patients, is a combination of high-pull headgear and a functional appliance with posterior bite blocks to anteriorly reposition the mandible and control eruption (Fig. 14.44). The theory is that the extraoral force increases the control of maxillary growth and allows the force to be delivered to the whole maxilla rather than to simply the permanent first molars. The high-pull headgear improves retention of the functional

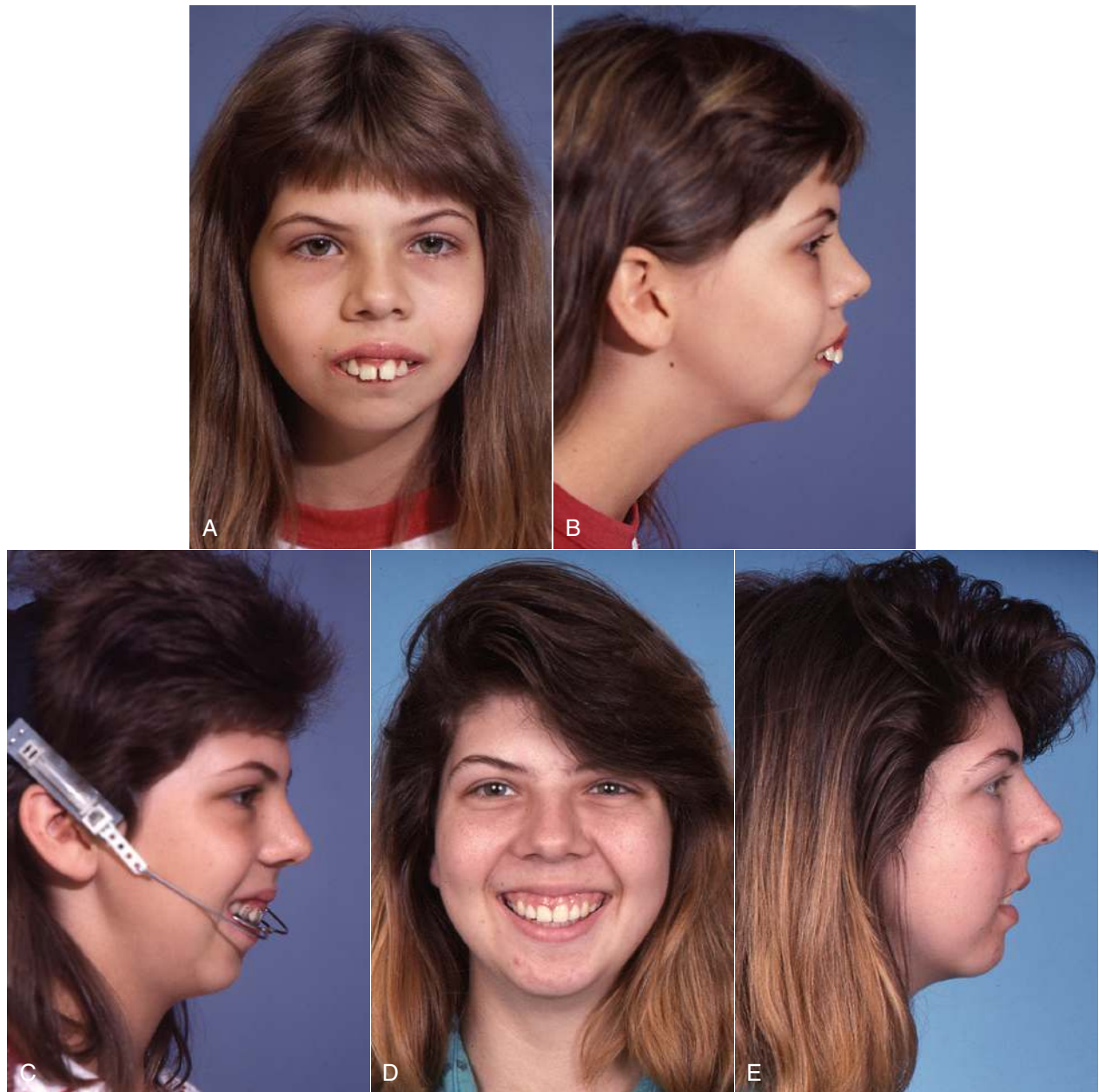

• **Fig. 14.42** These photos show an excellent response to high-pull headgear for a patient with excessive lower face height. (A) Pretreatment profile. (B) Posttreatment profile. (C) Cephalometric superimposition tracing. The cranial base superimposition shows that the maxilla and the maxillary teeth did not move inferiorly; as a result the mandible grew forward and not downward. The mandibular superimposition shows that the lower molar drifted forward into the leeway space. The incisor positions relative to the maxilla and mandible did not change.



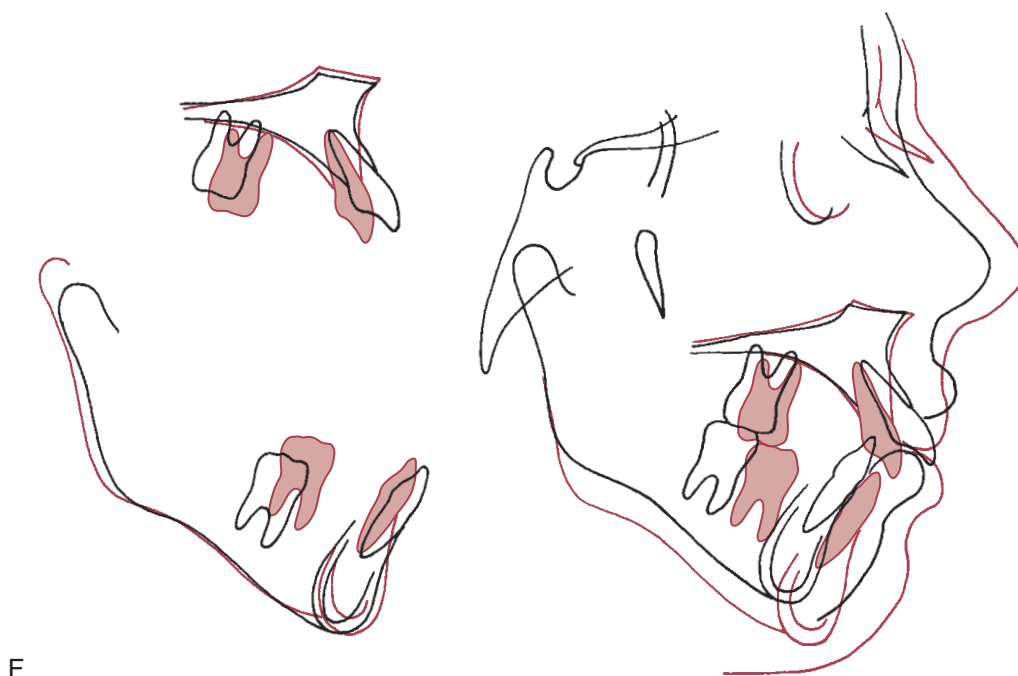


• **Fig. 14.43** This patient demonstrates a good response to functional appliance treatment designed to control vertical development with posterior bite blocks in a child with excessive lower face height. (A) Pretreatment profile. (B) Posttreatment profile. (C) Cephalometric superimposition tracing. Note that no posterior eruption occurred, and all mandibular growth was directed anteriorly. Face height was maintained, and anterior eruption closed the open bite. Maxillary and mandibular molar positions relative to their supporting bone were maintained.



• **Fig. 14.44** The maximum growth-modification approach to a severe long face, mandibular deficiency problem is high-pull headgear attached to a functional appliance with posterior bite blocks. (A and B) Facial appearance before treatment. (C) High-pull headgear with the facebow inserted into tubes in a functional appliance with bite blocks. (D and E) Posttreatment facial appearance is improved but not ideal.

*Continued*



F

• **Fig. 14.44, cont'd** (F) Cephalometric superimposition showing continued downward movement of the chin but no increase in the mandibular plane angle. The major effect of treatment was retraction of the protruding maxillary incisors into a premolar extraction space; little if any modification of the growth pattern occurred.

appliance and produces a force direction near the estimated center of resistance of the maxilla (see Fig. 14.35C). The functional appliance provides the possibility of enhancing mandibular growth while controlling the eruption of the posterior and anterior teeth.

In reality, the addition of headgear appears to provide little if any more vertical skeletal and dental control and has only a modest anteroposterior maxillary skeletal impact. This benefit should be weighed against the effects of the simpler open bite functional appliance without headgear. A study with follow-up through a later stage of fixed appliance therapy concluded that there was so little skeletal impact of the headgear–functional appliance stage of treatment that it could no longer be recommended.<sup>35</sup> For severely affected children with the long-face pattern, the only successful treatment methods are intrusion of posterior teeth by means of skeletal anchorage and segmental maxillary osteotomy, which are discussed in Chapters 19 and 20, respectively.

## Facial Asymmetry in Children

Although almost everyone has some facial asymmetry, asymmetric development of the jaws severe enough to cause a problem affects less than 0.5% of the U.S. population. An asymmetry problem involving only the maxilla is quite rare and almost always is due to trauma to that part of the face. Asymmetry involving only the nose is more frequent and also is most likely to be the result of trauma if only the nose is affected. The mandible is involved in 85% to 90% of facial asymmetry cases because of a growth problem. However, asymmetric mandibular growth has secondary effects on the maxilla, and both jaws are likely to become involved as the asymmetry develops.

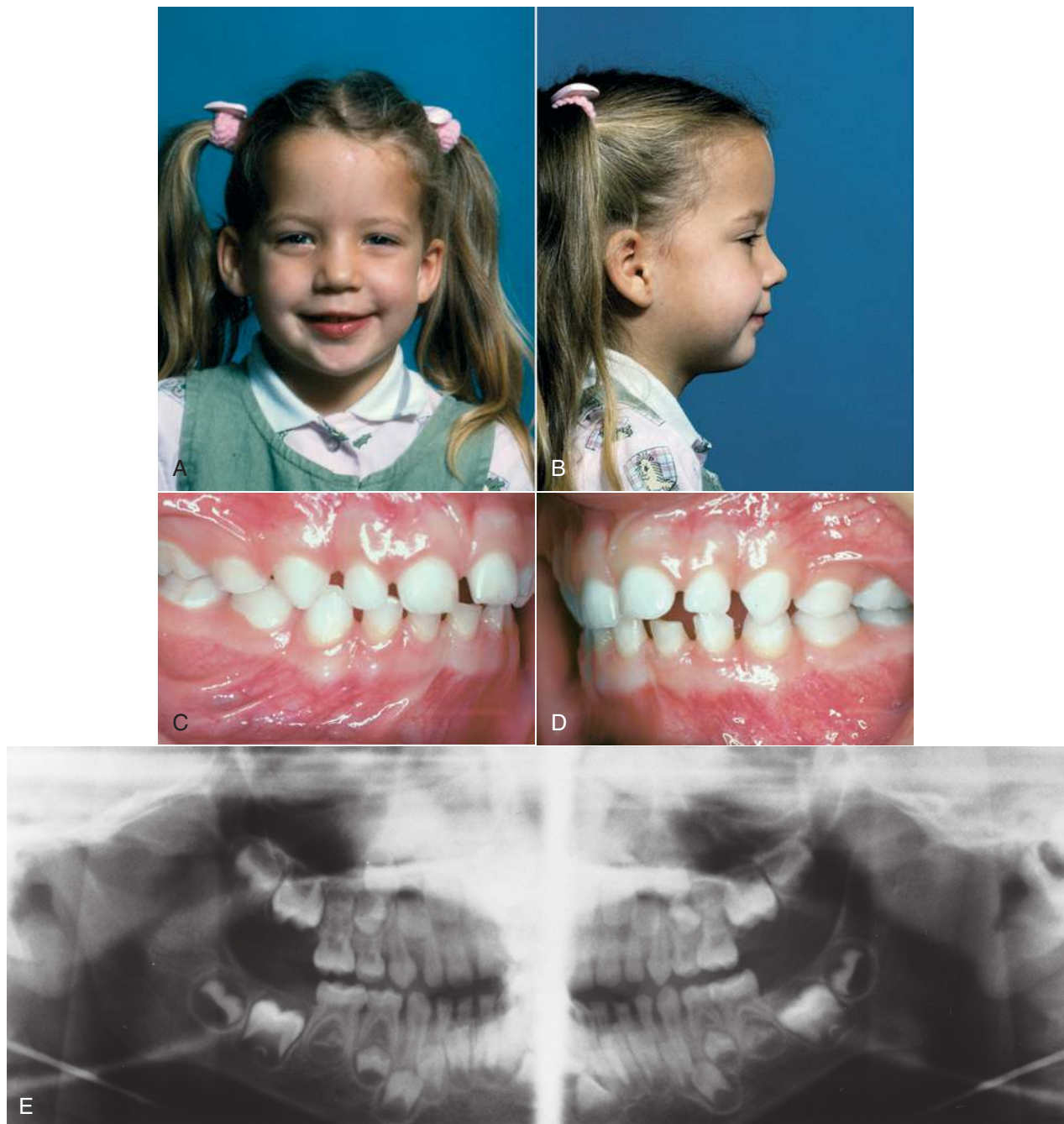## Asymmetric Mandibular Deficiency

Asymmetric mandibular deficiency in a child or adolescent can be due to hemifacial macrosomia or occasionally another problem in prenatal growth but usually arises as a result of a fracture of the condylar process of the mandible (Fig. 14.45).<sup>36</sup> There are three aspects to the differential diagnosis between these two conditions:

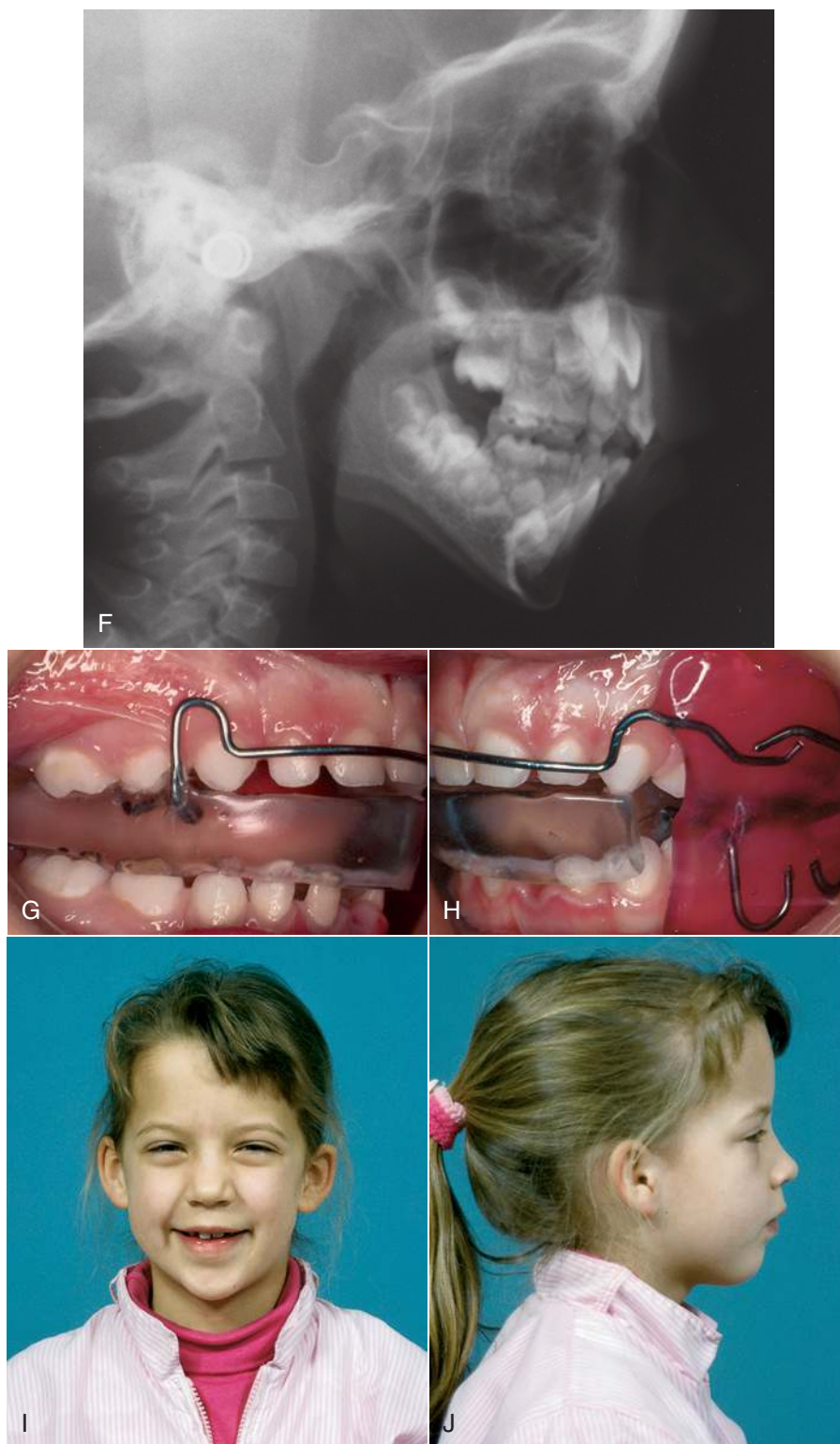
1. A congenital anomaly of any severity is likely to be noticed at birth, and the later the asymmetric deficiency arises, the more likely it is to be due to a condylar fracture.
2. For a young patient with an asymmetry that was not noticed at birth, a mild form of hemifacial macrosomia is part of the differential diagnosis. Because this condition usually affects the ear as well as the mandible, the key question is whether the ear on the affected side is small or malformed (see Fig. 5.6). Because there is a deficiency of soft tissue and muscle, growth modification is possible only in the least affected patients with this problem.
3. In contrast, the asymmetry after a condylar fracture is due to a restriction of growth in the condyle area caused by contraction of scar tissue created by the injury. Growth modification is possible for patients with less intensive restriction of growth.

When a condylar fracture is diagnosed in a child, maintaining function is the key to normal growth. Function does not mean simple opening and closing hinge movements but must also include translation of the mandibular condyles. Translation is necessary for regeneration and stretch of the associated soft tissues in the short term, and for normal growth in the long term. Fortunately, most jaw fractures in preadolescent children can be treated with little or

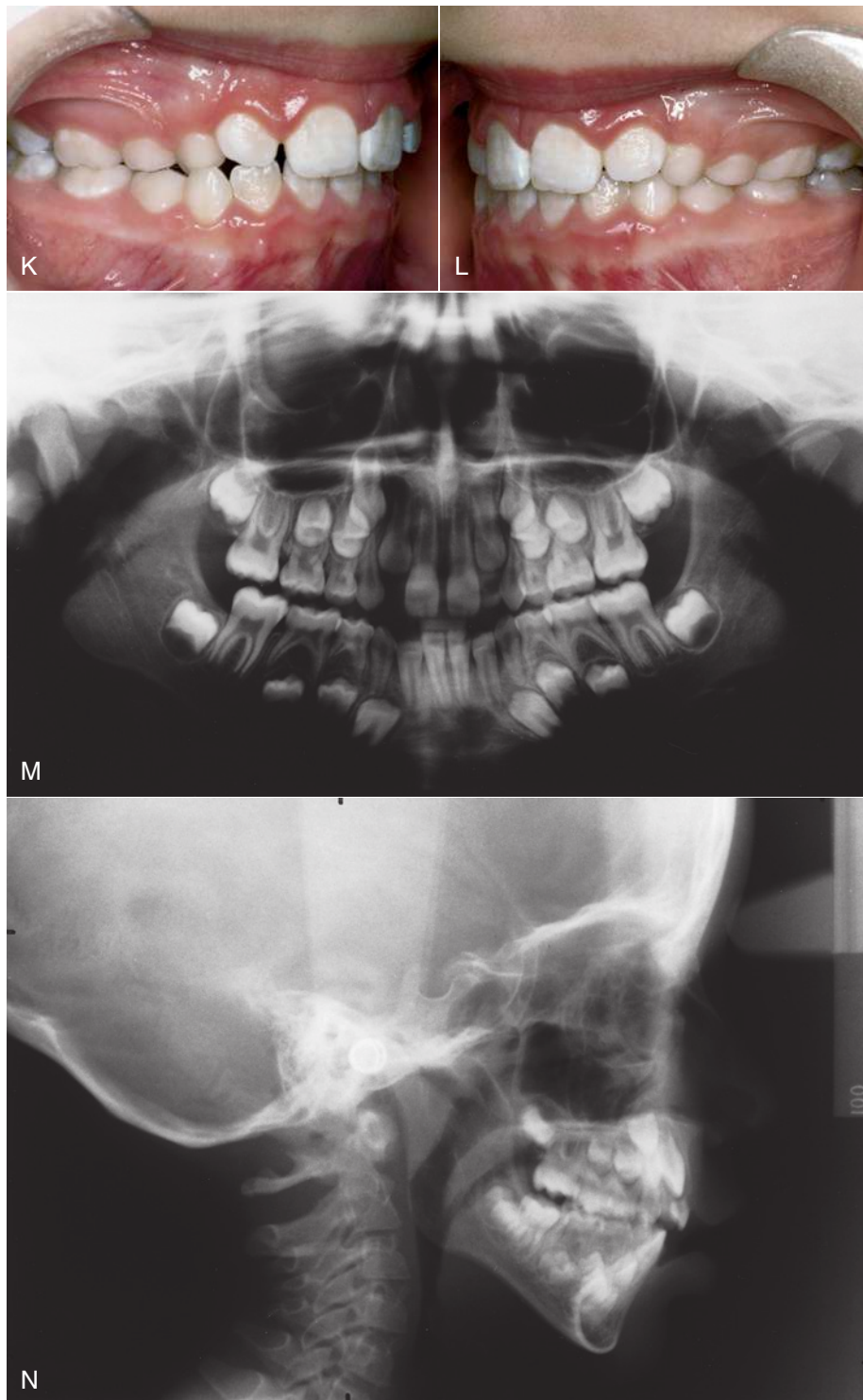




• **Fig. 14.45** (A and B) This 5-year-old girl's family dentist noted her facial asymmetry, with the chin off to the left (she deviated even more on opening) and referred her for further evaluation. (C and D) Her buccal occlusion was normal (Class I) on the right and Class II on the left. (E) The panoramic radiograph showed the classic appearance of a unilateral condylar fracture. Note the normal condyle on the right and only a condylar stub on the left. The injury almost surely occurred at age 2 when she fell but was not diagnosed at the time. *Continued*



• **Fig. 14.45, cont'd** (F) Note the two mandibular borders on the cephalometric radiograph resulting from the shorter ramus on the left. (G and H) She was treated with a series of hybrid functional appliances, with buccal and lingual shields on the left and a bite block anteriorly and on the right. The objective was to encourage mandibular growth and tooth eruption on the deficient left side and restrain eruption on the right. It is important to keep the tongue from between the teeth on the side where eruption is desired; therefore the lingual shield on the left side (cannot be seen in the photos) was a critically important part of the appliance. (I and J) Facial views 2 years later.



• **Fig. 14.45, cont'd** (K and L) Intraoral views 2 years later. Note the improvement in both facial symmetry and occlusion. Treatment with hybrid functional appliances was continued. (M) Panoramic and (N) cephalometric progress views. Note the regeneration of the left condyle (seen clearly in the panoramic view) and reduction in the difference in height of the two mandibular rami, shown in the cephalometric radiograph.



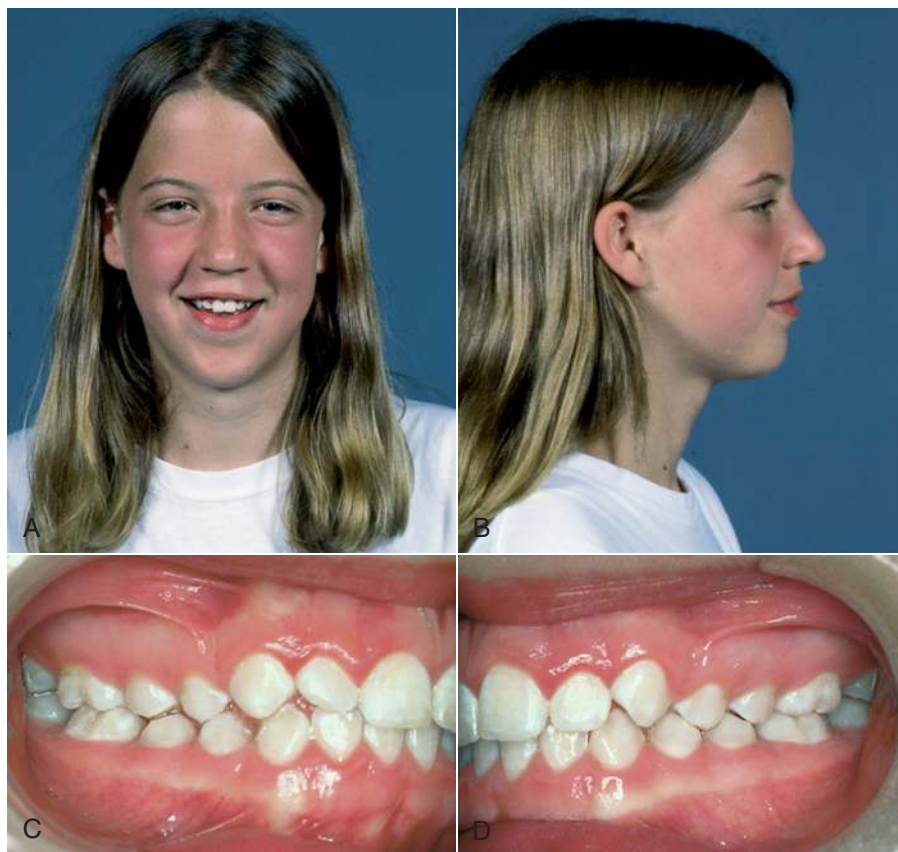no surgical manipulation of the segments and little immobilization of the jaws because the bony segments are self-retentive and the healing process is rapid. Treatment should involve short fixation times (usually maintained with intraoral intermaxillary elastics) and rapid return to function. Open reduction of the fracture should be avoided.<sup>36</sup>

A functional appliance during the postinjury period can be used to minimize any growth restriction. The appliance is a conventional activator or Bionator-type appliance that symmetrically advances the mandible to nearly an edge-to-edge incisor position. Using this appliance, the patient is forced to translate the mandible, and any remodeling can occur with the mandible in the unloaded and forward position.

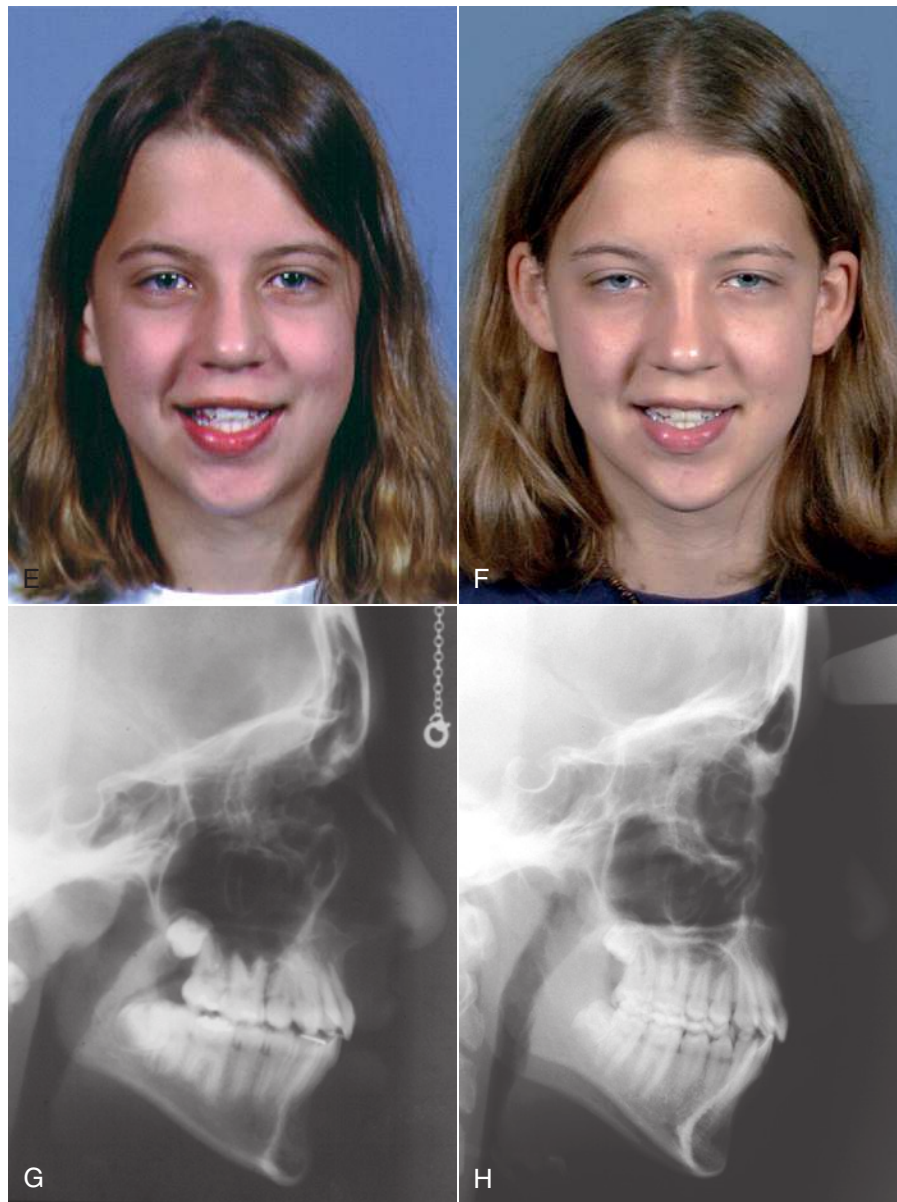
Many condylar fractures are not diagnosed at the time of injury, so when a child with asymmetric mandibular deficiency is seen, trauma is the most likely cause even if a condylar injury was not

noticed. The key to establishing the prognosis for growth modification is the extent to which the affected side can translate. Even if the mandible deviates to the affected side on opening, reasonably normal growth is possible if some degree of translation occurs (see Fig. 14.45). Hybrid functional appliances (Fig. 14.45G–H) offer a way to obtain more growth on one side than the other.<sup>37</sup> Although these appliances may appear confusing, they are simply various components logically combined to achieve specific purposes for individual patients. Progress over a 10-year period in management of this patient with a treatable restriction of growth is shown in Fig. 14.46. The surprising secondary adolescent growth spurt in this patient, and the return of some facial asymmetry when this growth was not controlled, demonstrate the difference with and without growth control.

Surgical intervention for a facial growth problem before adolescence has only one goal: to create an environment in which growth is



• **Fig. 14.46** (A and B) Facial and (C and D) intraoral views at age 13, with nearly complete resolution of the facial asymmetry, although the mandible still deviates to the left on wide opening. Functional appliance treatment was discontinued at age 10, and there was no further orthodontic therapy.



• **Fig. 14.46, cont'd** (E and F) Facial and (G and H) intraoral views at age 15. The patient grew 3 inches taller between ages 13 and 15 in what amounted to a secondary adolescent growth spurt, although she was well beyond menarche at that time, and there was a mild return of the asymmetry when this growth was not controlled. Perhaps this unanticipated long-term effect is the best evidence that the series of appliances did control her symmetric growth during the initial stages of treatment.

possible. Therefore this is indicated only for patients with asymmetric deficiency in whom the abnormal growth is progressively making the problem worse, as in ankylosis that keeps one side from growing. The guideline is that a restriction of jaw opening of less than 15 mm is unlikely to respond to growth modification, whereas an opening of 20 mm or more usually makes nonsurgical growth guidance possible. For the surgery patients, treatment with a hybrid functional appliance will be needed after surgery has made condylar translation possible, to correct the primary growth problem, decompensate the dental arches vertically, and guide function. Problems of this severity usually are better managed through a major medical center.

### Asymmetric Mandibular Excess

Excessive growth of the mandible on one side is labeled now as hemimandibular hyperplasia because the ramus and body of the mandible are affected, although the old name of condylar hypertrophy was not totally wrong (see [Chapter 7](#)). This condition overwhelmingly affects females rather than males. It is a classic progressive deformity, one that steadily gets worse ([Fig. 14.47](#)), and that makes the most severely affected patients candidates for early surgical intervention. Growth modification to stop the excessive growth is not possible. Surgical possibilities for these patients are discussed in [Chapter 20](#).



• **Fig. 14.47** Hemimandibular hypertrophy is the classic example of a progressive deformity: excessive growth of the condyle or lengthening of the condylar process starts with a mild mandibular asymmetry and slowly creates a major deformity if untreated. (A) Age 8, family photo. (B) Age 17, high school graduation photo. (C) Age 19, clinic photograph when she finally sought treatment. The age of onset for this patient was unusually early and the resulting deformity was unusually severe, but the gender and progressive course were typical.

## References

1. Pancherz H, Fackel U. The skeletofacial growth pattern pre- and post-dentofacial orthopedics. *Eur J Orthod.* 1990;12:209–218.
2. Perinetti G, Primožič J, Franchi L, Contardo L. Treatment effects of removable functional appliances in pre-pubertal and pubertal class ii patients: a systematic review and meta-analysis of controlled studies. *PLoS ONE.* 2015;10(10):e0141198.
3. Tulloch JF, Proffit WR, Phillips C. Outcomes in a 2-phase randomized clinical trial of early Class II treatment. *Am J Orthod Dentofac Orthop.* 2004;125:657–667.
4. Cozza P, Baccetti T, Franchi L, et al. Mandibular changes produced by functional appliances in Class II malocclusion: a systematic review. *Am J Orthod Dentofac Orthop.* 2006;129:599.e1–e12.
5. Nucera R, Lo GA, Rustico L, Matarese G, et al. Effectiveness of orthodontic treatment with functional appliances on maxillary growth in the short term: a systematic review and meta-analysis. *Am J Orthod Dentofac Orthop.* 2016;149:600–611, e3.
6. O'Brien K, Wright J, Conboy F, et al. Early treatment for Class II division 1 malocclusion with the Twin-Block appliance: a multi-center, randomized, controlled trial. *Am J Orthod Dentofac Orthop.* 2009;135:573–579.
7. Oppenheim A. Biologic orthodontic therapy and reality. *Angle Orthod.* 1936;6:69–79.
8. Kloehn S. Guiding alveolar growth and eruption of the teeth to reduce treatment time and produce a more balanced denture and face. *Am J Orthod.* 1947;17:10–33.
9. Wieslander L. The effects of orthodontic treatment on the concurrent development of the craniofacial complex. *Am J Orthod.* 1963;49:15–27.



10. Armstrong MM. Controlling the magnitude, direction and duration of extraoral force. *Am J Orthod*. 1971;59:217–243.
11. Keeling SD, Wheeler TT, King GJ, et al. Anteroposterior skeletal and dental changes after early Class II treatment with Bionators and headgear. *Am J Orthod Dentofac Orthop*. 1998;113:40–50.
12. Baumrind S, Molthen R, West EE, et al. Mandibular plane changes during maxillary retraction, part 2. *Am J Orthod*. 1978;74:603–621.
13. O'Brien K, Wright J, Conboy F, et al. Early treatment for Class II division 1 malocclusion with the Twin-Block appliance. *Am J Orthod Dentofac Orthop*. 2009;135:573–579.
14. O'Brien K, Wright J, Conboy F, et al. Effectiveness of early orthodontic treatment with the Twin-Block appliance: a multicenter, randomized, controlled trial. Part 2: psychosocial effects. *Am J Orthod Dentofac Orthop*. 2003;124:488–494.
15. Borzabadi-Farahani A, Borzabadi-Farahani A, Eslamipour F. An investigation into the association between facial profile and maxillary incisor trauma, a clinical non-radiographic study. *Dent Traumatol*. 2010;26:403–408.
16. Glendor U, Koucheiki B, Halling A. Risk evaluation and type of treatment of multiple dental trauma episodes to permanent teeth. *Endod Dent Traumatol*. 2000;16:205–210.
17. Pancherz H. The effects, limitations, and long-term dentofacial adaptations to treatment with the Herbst appliance. *Semin Orthod*. 1997;3:232–243.
18. Franchi L, Baccetti T. Prediction of individual mandibular changes induced by functional jaw orthopedics followed by fixed appliances in Class II patients. *Angle Orthod*. 2006;76:950–954.
19. Siara-Olds NJ, Pangrazio-Kulbersh V, Berger J, et al. Long-term dentoskeletal changes with the Bionator, Herbst, Twin-Block and MARA functional appliances. *Angle Orthod*. 2012;80:18–29.
20. Perinetti G, Primozic J, Furlani G, et al. Treatment effects of fixed functional appliances alone or in combination with multibracket appliances: a systematic review and meta-analysis. *Angle Orthod*. 2014;85:480–492.
21. Pancherz H, Malmgren O, Hagg U, et al. Class II correction in Herbst and Bass therapy. *Eur J Orthod*. 1989;11:17–30.
22. Elkordy SA, Aboelnaga AA, Salah Fayed MM, et al. Can the use of skeletal anchors in conjunction with fixed functional appliances promote skeletal changes? A systematic review and meta-analysis. *Eur J Orthod*. 2015;16:272–278.
23. Jones G, Buschang PH, Kim KB, Oliver DR. Class II non-extraction patients treated with the Forsus Fatigue Resistant Device versus intermaxillary elastics. *Angle Orthod*. 2008;78:332–338.
24. Al-Saleh MA, Alsufyani N, Flores-Mir C, et al. Changes in temporomandibular joint morphology in Class II patients treated with fixed mandibular repositioning and evaluated through 3D imaging: a systematic review. *Orthod Craniofac Res*. 2015;18:185–201.
25. Tarvade SM, Chaudhari CV, Daokar SG, et al. Dentoskeletal comparison of changes seen in Class II cases treated by Twin Block and Forsus. *J Int Oral Health*. 2014;6:27–31.
26. Giuntini V, Vangelisti A, Masucci C, et al. Treatment effects produced by the Twin-Block appliance vs the Forsus Fatigue Resistant Device in growing Class II patients. *Angle Orthod*. 2015;85:784–789.
27. Banks P, Wright J, O'Brien K. Incremental versus maximum bite advancement during Twin-Block therapy: a randomized controlled clinical trial. *Am J Orthod Dentofac Orthop*. 2004;126:583–588.
28. Haralabakis NB, Sifakakis IB. The effect of cervical headgear on patients with high or low mandibular plane angles and the “myth” of posterior mandibular rotation. *Am J Orthod Dentofac Orthop*. 2004;126:310–317.
29. Chaushu G, Chausu S, Weinberger T. Infraorbital abscess from orthodontic headgear. *Am J Orthod Dentofac Orthop*. 1997;112:364–366.
30. Stafford GD, Caputo AA, Turley PK. Characteristics of headgear release mechanisms: safety implications. *Angle Orthod*. 1998;68:319–326.
31. Ruf S, Pancherz H. The effect of Herbst appliance treatment on the mandibular plane angle: a cephalometric roentgenographic study. *Am J Orthod Dentofac Orthop*. 1996;110:225–229.
32. Phelan A, Franchi L, Baccetti T, et al. Longitudinal growth changes in subjects with open-bite tendency: a retrospective study. *Am J Orthod Dentofac Orthop*. 2014;145:28–35.
33. Orton HS, Slattery DA, Orton S. The treatment of severe ‘gummy’ Class II division 1 malocclusion using the maxillary intrusion splint. *Eur J Orthod*. 1992;14:216–223.
34. Weinbach JR, Smith RJ. Cephalometric changes during treatment with the open bite Bionator. *Am J Orthod Dentofac Orthop*. 1992;101:367–374.
35. Freeman CS, McNamara JA Jr, Baccetti T, et al. Treatment effects of the Bionator and high-pull facebow combination followed by fixed appliances in patients with increased vertical dimensions. *Am J Orthod Dentofac Orthop*. 2007;131:184–195.
36. Proffit WR, Turvey TA, Vig KW. Early fracture of the mandibular condyles: frequently an unsuspected cause of growth disturbances. *Am J Orthod*. 1980;78:1–24.
37. Turvey TA, Ruiz R, Blakey GH, et al. Management of facial fractures in the growing patient. In: Fonseca RJ, Walker RV, Betts NJ, et al, eds. *Oral and Maxillofacial Trauma*. Philadelphia: WB Saunders; 2005.

## SECTION VI

# Comprehensive Orthodontic Treatment in the Early Permanent Dentition

Comprehensive orthodontic treatment implies an effort to make the patient's occlusion as ideal as possible, repositioning all or nearly all the teeth in the process. From this perspective, the mixed dentition and growth modification treatment described in [Chapters 11 to 14](#) is not comprehensive, despite its importance for some patients, because the final position of all the permanent teeth is not affected. A second phase of comprehensive treatment after the permanent teeth have erupted, during which the details of occlusal relationships are established, almost always is needed for children with moderate or severe malocclusion even if significant improvement occurred during a first phase of treatment in the mixed dentition.

Comprehensive treatment usually requires a complete fixed appliance. In the chapters that follow, the use of a contemporary edgewise appliance that incorporates offsets, angulation, and torque in the brackets (i.e., a straight-wire appliance) is assumed during much of the discussion. The ideal time for comprehensive treatment is during adolescence, when the succedaneous teeth have just erupted, some vertical and anteroposterior growth of the jaws remains, and social adjustment to orthodontic treatment is no great problem. Not all adolescent patients require comprehensive treatment, of course, and limited treatment to overcome specific problems can certainly be done at any age. Comprehensive treatment is also possible for adults, but it poses some special problems. These are discussed in [Chapter 19](#).

The idea of dividing comprehensive orthodontic treatment into stages, which makes it easier to discuss technique, was introduced by Raymond Begg,<sup>1</sup> and the three major stages he proposed were the focus of his treatment planning. The stages were (1) alignment and leveling, (2) correction of molar relationship and space closure, and (3) finishing. These stages described edgewise treatment well at the time this book first appeared, when improvements in edgewise technique were pushing the Begg appliance into obsolescence. They still fit reasonably well with modern treatment, but three differences have led to modification of the chapters in this section.

First, Begg treatment was built around premolar extraction for most patients, and now extraction is much less frequent. Second, the sequence of treatment procedures in contemporary edgewise varies; you don't always start with alignment or complete leveling before correcting incisor protrusion, although finishing adjustments remain a final step for almost all patients. Third, with the availability of comprehensive treatment with clear aligners, the sequence of steps can be varied, and they may not be the same as what would be done with a fixed appliance.

What is still true of almost all fixed appliance treatment is that even with the most cleverly preadjusted edgewise appliance, change of archwires from round to rectangular will be needed before the finishing stage is reached, and some adjustments to rectangular archwires are quite likely to be necessary in completing the treatment. In this section, what is done primarily with round wires is the focus of [Chapter 15](#). [Chapter 16](#) describes the use of rectangular wires in retraction of protruding incisors and closure of extraction spaces, and [Chapter 17](#) discusses the small but important adjustments that are routinely required in fixed appliance finishing and management of the sequential steps in clear aligner therapy.

Whatever the orthodontic technique, treatment must be discontinued gradually, with some sort of retention appliance used for a time, and this important subject is covered in the last chapter of this section.

## Reference

1. Begg PR, Kesling PC. *Begg Orthodontic Theory and Technique*. Philadelphia: WB Saunders; 1977.

# 15

## Comprehensive Treatment in Adolescents: Alignment and Vertical Problems

### CHAPTER OUTLINE

#### Class I Crowding/Protrusion

Alignment

Other Space Problems

#### Leveling

Leveling by Extrusion (Relative Intrusion)

Leveling by Intrusion

The overlap with growth modification and mixed dentition treatment has already been reviewed in [Chapter 12](#). The equally important overlap with growth modification and adolescent treatment is discussed in [Chapter 16](#), in which camouflage possibilities for skeletal problems, which revolve around repositioning incisors to help fit the dentition into an acceptable relationship with the face, are presented in detail. This chapter focuses on two things: correction of crowding of teeth in patients who have a normal jaw relationship, and problems in all three planes of space that are due more to displacement of teeth than discrepancies in jaw size and position.

At this point, we presume that the patient's problem list has been developed properly and that there is a treatment plan to maximize benefit for him or her. Now our discussion is not of what to do, but how to do it effectively and efficiently.

### Class I Crowding/Protrusion

In almost all patients with malocclusion, at least some teeth are initially malaligned, so alignment is needed for patients with skeletal problems as well as those for whom crowding and/or protrusion is the major problem—but alignment techniques apply in the same way whether or not there also is a jaw discrepancy. For proper alignment, it is necessary not only to bring malposed teeth into the arch but also to specify and control the anteroposterior position of incisors, the width of the arches posteriorly, and the form of the dental arches. Even in the absence of a jaw discrepancy, patients are likely to have excess overbite and an accentuated curve of Spee in the lower arch. It is necessary to determine and control whether

the leveling should occur by elongation of posterior teeth, intrusion of incisors, or some specific combination of the two. In addition, it often is the case that the form of the upper arch is not compatible with that of the lower arch, and one or both must be changed if excellent occlusion is to be obtained.

Although the orthodontist has some latitude in changing arch form, more stable results are achieved when the patient's original lower arch form is preserved during orthodontic treatment (see [Chapter 10](#) for a discussion of arch form and archwire shape). The light resilient archwires used in the first stage of treatment need not be shaped to the patient's arch form as carefully as the heavier archwires used later in treatment, but from the beginning, the archwires should reflect each individual's arch form. If preformed archwires are used for alignment (as is usually the case because superelastic austenitic nickel–titanium [A-NiTi] wires must be formed by the manufacturer), the appropriate large, medium, or small arch form should be selected.

Because the orthodontic mechanotherapy will be different depending on exactly how alignment and leveling are to be accomplished, it is extremely important to clearly visualize the desired position of the teeth before beginning treatment. Computer programs now exist to make this easier ([Fig. 15.1](#)), but it is the thought process that counts. For instance, the best alignment procedures will result in incisors that are far too protrusive if the extractions necessary to prevent protrusion were not part of the plan. Similarly, unless leveling by intrusion is planned when it is needed, the appropriate mechanics are not likely to be selected. Orthodontic treatment without specific goals can be an excellent illustration of the old adage, “If you don't know where you're going, it doesn't matter which road you take.”

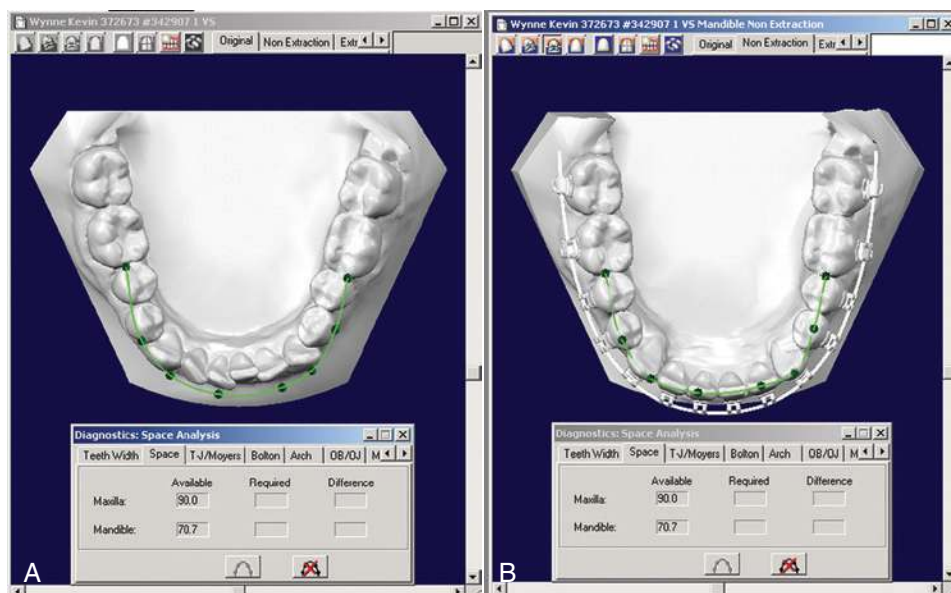
### Alignment

#### Properties of Alignment Archwires

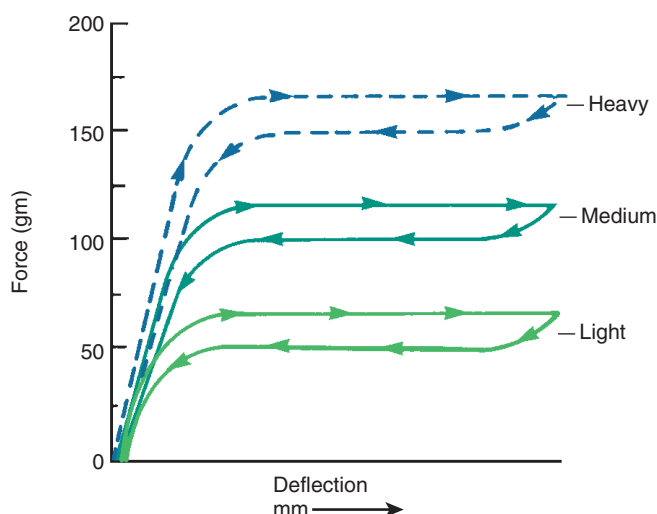
The wires for initial alignment require a combination of excellent strength, excellent springiness, and a long range of action. Ideally, there would be an almost flat load–deflection curve, with the wire delivering about 50 gm (the optimum force for tipping) at almost any degree of deflection ([Fig. 15.2](#)). The variables in selecting appropriate archwires for alignment are the archwire material, its size (diameter or cross-section), and the distance between attachments (interbracket span; see [Chapter 9](#)).

At this point, superelastic A-NiTi wires are so much more effective and efficient for alignment than any alternative that there





• **Fig. 15.1** Digitized dental casts (here in the Ortho-CAD system) can be used quite effectively to calculate the amount of space needed to align the teeth, show the probable outcome of alignment, and calculate the arch length needed. (A) Pretreatment occlusal view of the lower arch, with a line showing the amount of space required for alignment. (B) Virtual appliance in place. This set-up can be used to generate the trays for indirect bonding.



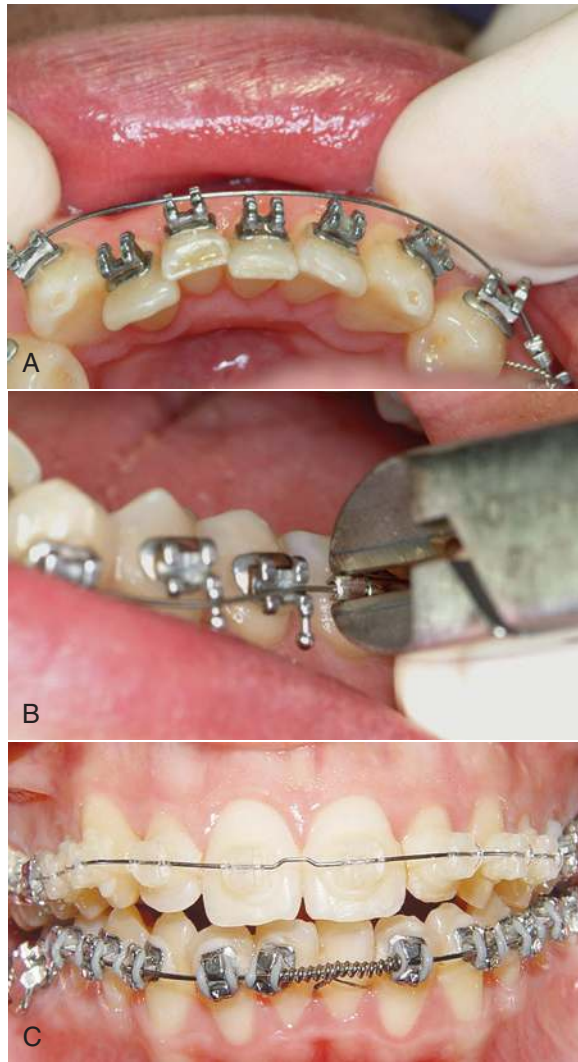
• **Fig. 15.2** Idealized force-deflection curves for 16-mil austenitic nickel-titanium (A-NiTi) wires (Sentinol, Dentsply Sirona, York, PA) prepared by the manufacturer to have different force delivery characteristics. For superelastic wires, the manufacturer's preparation, not the wire size, is the major factor in determining force delivery. Note that the light version of this wire delivers the desired 50 gm for initial alignment. Data of this type should be available for all the archwires used in clinical practice.

is almost no reason to discuss other possibilities. The key to their success is their ability to deliver light force over a long range. When superelastic wires were first introduced, fracture of the wire between appointments was a problem, but improved alloys and manufacturing techniques have largely eliminated this. Because the manufacturer's preparation of the material determines the clinical performance, wire size is a concern primarily with respect to clearance in the bracket slot.

It is possible now to obtain superelastic wires that are almost totally passive when cold but deliver the desired force when at mouth temperature. Placing a passive wire is much easier than placing a springy one, so chilling a segment of the wire to make it temporarily passive can be a significant advantage under some circumstances. On the other hand, once mouth temperature has been reached, there is no reason to expect such a thermally sensitive wire to perform better than one without this feature.

As we have discussed in [Chapter 9](#), it is logical to use narrow (single) brackets with 18-slot edgewise and wider (twin) brackets with 22-slot appliances. Before almost routine use of superelastic wires, bracket slot size and interbracket span were such strong influences on archwire choice that different initial wires often were used with the 18- and 22-slot appliances. This is no longer the case. But with superelastic wires, it is necessary to pay more attention to maintaining arch form during alignment, to the point that alignment when crowding is reasonably symmetric now must be viewed differently than alignment in highly asymmetric situations—an important point that is discussed later.

The flat load-deflection curve of superelastic nickel-titanium (NiTi; see [Fig. 15.2](#)) makes it ideal for initial alignment. The wire provides remarkable range over which a tooth can be moved without generating excessive force (see [Figs. 9.5 to 9.8](#)). Under most circumstances, initial alignment can be accomplished simply by tying 14- or 16-mil A-NiTi that delivers about 50 gm into the brackets of all the teeth. It must be kept in mind, however, that alignment requires opening space for teeth that are crowded out of the arch. There are two ways to do this: use a crimped stop on the wire just in front of the molar tube so that the archwire is “proud” (slightly advanced from the crowded incisors) or use coil springs to open space ([Fig. 15.3](#)). If this is done, the springs must deliver only light force to prevent distortion of arch form. The size of the superelastic wire is not a critical variable if it delivers the desired approximately 50 gm of force, except that 18-mil wires should not be used in the 18-slot appliance.



• **Fig. 15.3** When additional arch length is needed, advanced stops in the flexible initial archwire are useful. (A) Austenitic nickel–titanium (A-NiTi) archwire advanced relative to crowded incisors. Stops on the archwire are needed to hold it in a slightly advanced position. (B) Crimped split tube segments, such as those used to prevent travel, serve well as stops for superelastic initial wires. (C) An alternative for gaining arch length is compressed coil springs to open space for crowded-out incisors. The effect of the two methods is quite similar—incisor proclination occurs about equally.

When superelastic NiTi was first introduced, the major objection to it was its expense. If a large range is not necessary, a triple-strand 17.5-mil multistrand steel wire ( $3 \times 8$  mil) still offers good properties at a fraction of the cost. In theory, this size would be too large for effective use in 18-slot brackets. Clinical research has shown, however, that in both the 18- and 22-slot appliance, if these wires are recontoured monthly and retied with elastomeric ligatures, the time to alignment is equivalent to that with A-NiTi. Force levels certainly are more variable and patient discomfort probably is greater than with superelastic wires, but it is difficult to demonstrate that this makes a difference clinically.

The major reason for this surprisingly good clinical performance by the multistrand steel wire is that flexible archwires allow the teeth to move relative to one another during chewing, as alveolar bone bends under masticatory loads (see [Chapter 8](#)). This releases

binding and allows the bracket to slide along the archwire to the next point at which binding occurs. But the lower cost of the steel archwire is quickly overshadowed by the cost of the additional clinical time necessary to retie it, especially if it must be taken out, reshaped to remove any areas of permanent distortion, and then re-ligated. In a busy practice, you can't afford to use the less expensive wire.

Laboratory data and clinical experience suggest that similar performance to the multistrand steel wire could be obtained with several other possibilities: (1) elastic martensitic nickel–titanium (M-NiTi), (2) a variety of more elaborate multistrand wires (coaxial wires, for instance, that have several smaller wires wound over a larger core wire), or (3) loops in small-diameter steel wires. Both M-NiTi and coaxial multistrand wires are expensive, and the time to bend loops in 14- or 16-mil steel wires also is expensive. These wires, although they were the standard of treatment for initial alignment not long ago, have little or no place in current therapy.

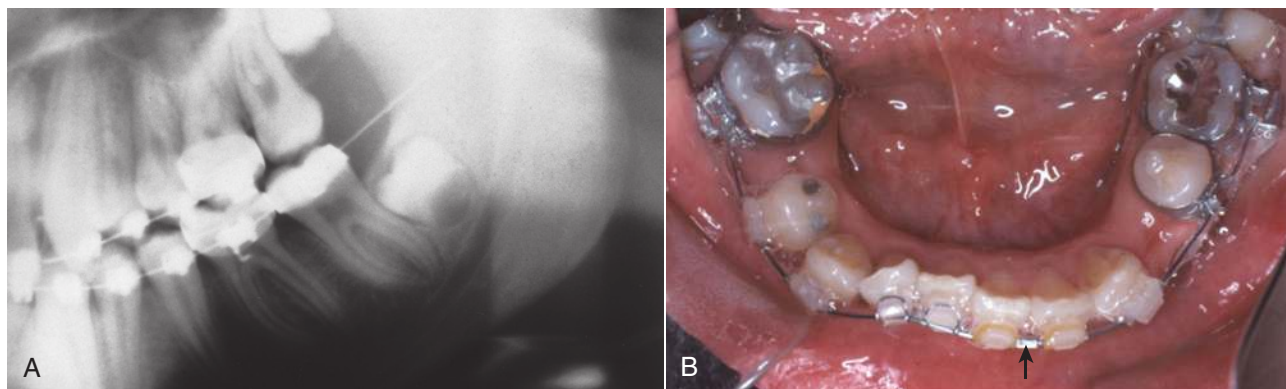
As one might expect, the extreme springiness of superelastic wires is not a totally unmixed blessing. When these wires are tied into a malaligned dental arch, they have a tendency to “travel” around the arch as the patient chews, especially if function is mostly on one side. Then the wire extends out the back of the molar tube on one side and is short out of the tube on the other side. Occasionally, this can be extreme enough to produce the kind of situation Mark Twain called “marvelous and dismaying” ([Fig. 15.4A](#)). Archwire travel can be prevented by crimping a stop tightly onto the archwire between any two brackets that are reasonably close together ([Fig. 15.4B](#)) or by using a wire in which the manufacturer has placed a midline dimple in the wire to prevent travel (see [Fig. 15.3C](#)). A stop to prevent travel should be used routinely on initial superelastic wires.

### Principles in the Choice of Alignment Arches

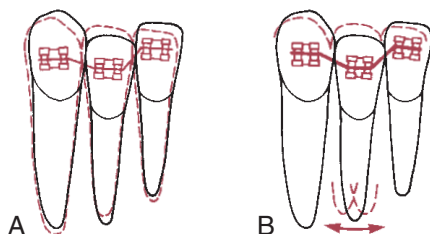
In nearly every patient with malaligned teeth, the root apices are closer to the normal position than the crowns because malalignment almost always develops as the eruption paths of teeth are deflected. Putting it another way, a tooth bud occasionally develops in the wrong place, but the root apices are likely to be reasonably close to their correct positions even though the crowns have been displaced as the teeth erupted. The major exceptions to this guideline are the displacement of all tissues in an area, most often seen as a result of cleft palate surgery, and the severe tipping from lip pressure that displaces maxillary central incisors in Class II division 2 malocclusion.

Bringing teeth into alignment requires a combination of labio-lingual and mesiodistal tipping guided by an archwire, but usually not root movement. Several important consequences for orthodontic mechanotherapy follow from this:

- Initial archwires for alignment should provide light, continuous force of approximately 50 gm to produce the most efficient tipping tooth movement. Heavy force, in contrast, is to be avoided.
- The archwires should be able to move freely within the brackets. For mesiodistal sliding along an archwire, at least 2 mil of clearance between the archwire and the bracket is needed, 4 mil of clearance is desirable, and more than that provides no advantage. This means that the largest initial archwire that should be used with an 18-slot edgewise bracket is 16 mil, and 14 mil would be more satisfactory. With the 22-slot bracket, a 16- or 18-mil archwire would be satisfactory if it delivered the correct force. Whatever the archwire, it should be held loosely in the bracket; however, as we have pointed out in



• **Fig. 15.4** One problem with superelastic wires for initial alignment is their tendency to “travel” so that the wire slips around to one side, protruding distally from the molar tube on one side and slipping out of the tube on the other. (A) This panoramic radiograph shows archwire travel to the point that on one side it penetrated into the ramus, almost to the depth of an inferior alveolar block injection (interestingly, the patient reported only mild discomfort). (B) The most effective way to prevent travel is to tightly crimp a split tube segment onto the wire between two adjacent brackets. The location of the crimped stop, here between the left central and lateral incisors, is not critical. Some preformed austenitic nickel–titanium (A–NiTi) wires now have a dimple in the midline to prevent the archwire from sliding excessively.



• **Fig. 15.5** A tightly fitting resilient rectangular archwire for initial alignment is almost always undesirable because not only is resistance to sliding likely to be problematic, but also the wire produces back-and-forth movement of the root apices as the teeth move into alignment. This occurs because the moments generated by the archwire change as the geometry of the system changes with alterations in tooth position. (A) Diagrammatic representation of the alignment of a malposed lateral incisor with a round wire and clearance in the bracket slot. With minimal moments created within the bracket slot, there is little displacement of the root apex. (B) With a rectangular archwire that has enough torsional stiffness to create root movement, back-and-forth movement of the apex occurs before the tooth ends up in essentially the same place as with a round wire. This has two disadvantages: it increases the possibility of root resorption, and it slows the alignment process.

Chapter 9, friction is not the major component of resistance to sliding, and the claim that more rapid alignment is a major advantage of self-ligating brackets has been shown to be incorrect.

- Rectangular archwires, particularly those with a tight fit within the bracket slot so that the position of the root apex could be affected, normally should be avoided. The principle is that it is better to tip crowns to position during initial alignment rather than displacing the root apices; the corollary is that although a highly resilient rectangular archwire, such as  $17 \times 25$  superelastic NiTi (A–NiTi), could be used in the alignment stage, this is not advantageous because the rectangular archwire can create unnecessary and undesirable root movement during alignment (Fig. 15.5). Superelastic NiTi wires have such low torsional stiffness that for all practical purposes they cannot

torque roots,<sup>1</sup> so this complication is uncommon, but mesiodistal movement of the root apices can and does occur, and this tends to slow the tipping movements needed for alignment.

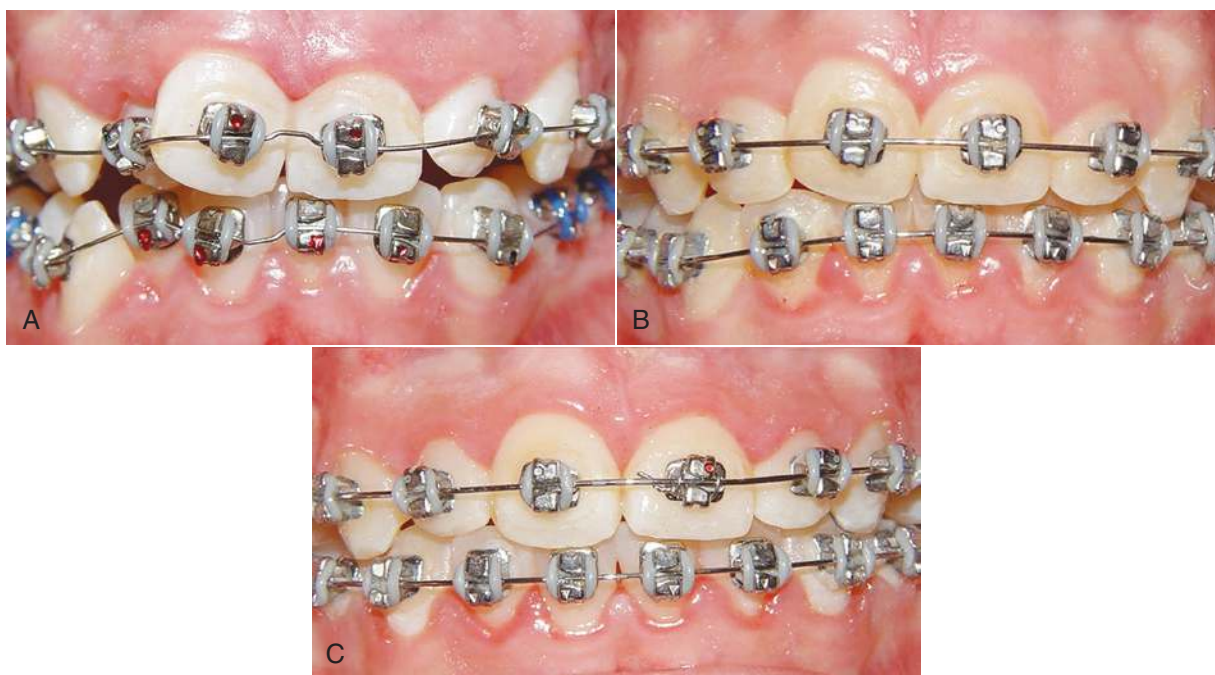
For that reason, round wires for alignment are preferred (Fig. 15.6). There is no reason to pay extra for a high-performance rectangular wire for initial alignment, when alignment with it predictably will be slower and possibly more damaging to the roots than a smaller round wire.

The more flexible the alignment archwire, the more important it is for the crowding to be at least reasonably symmetric. A frequent example of major asymmetry is when one incisor is completely blocked out of the arch but the rest of the arch is reasonably well aligned (Fig. 15.7). In that case, there is a danger that arch form will be distorted if the crowding is resolved with a superelastic wire alone, because if it is tied into the teeth, all of them will experience a displacement force. What is needed is a rigid wire to maintain arch form except where springiness is required, and an auxiliary superelastic wire to reach the malaligned tooth and pull it into position after space for it has been opened.

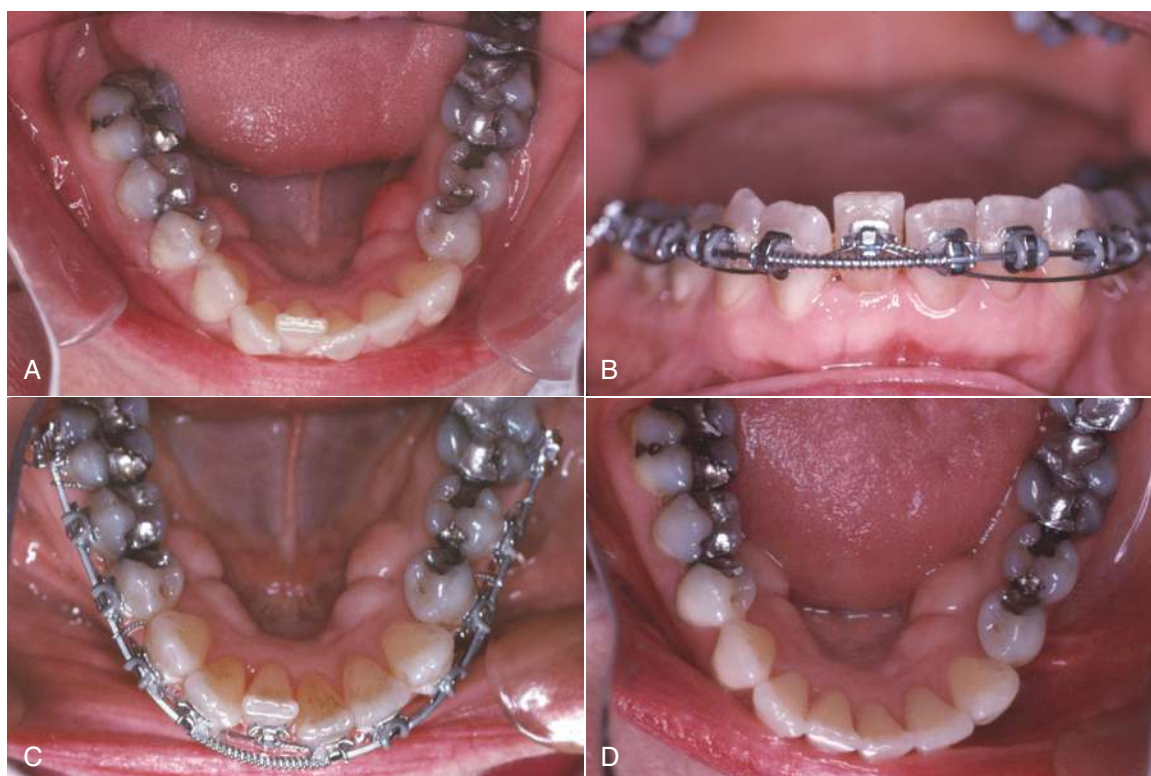
The best way to manage severely asymmetric crowding is to open space for the displaced tooth (or teeth; the same system works with small segments of two teeth) is to use a coil spring on a 16-mil steel wire to open space, and then add a small-diameter superelastic wire as an auxiliary spring overlying the stiffer main wire (see Fig. 15.7). With this arrangement, the correct light force to bring the displaced tooth into alignment is provided by the NiTi wire, and the reciprocal force is distributed over all the rest of the teeth by the stiffer main wire. The result is efficient movement of the displaced tooth, with excellent preservation of arch form. When the displaced tooth is nearly into proper position, the steel base arch can be discarded and the NiTi auxiliary tied into the bracket slots.

Note that there are two advantages of using the superelastic wire as an auxiliary to a rigid steel wire: control of the tendency to distort arch form, and light force against the tooth to be moved. Although auxiliaries of this type are recommended routinely in modern orthodontics, it would be particularly important to use this method for adult patients with loss of alveolar bone and a reduced periodontal ligament area.





• **Fig. 15.6** The sequence of alignment with a fixed appliance, in this case with Tip-Edge brackets (see [Chapter 10](#)). (A) The initial superelastic round wire (16-mil austenitic nickel-titanium [A-NiTij]), which the manufacturer had formed with a midline dimple to prevent archwire travel. (B) Two months later, 16-mil steel for final alignment. (C) Alignment completed 3 months later.



• **Fig. 15.7** Use of an auxiliary superelastic wire for incisor alignment in a patient with asymmetric crowding. (A) Crowding expressed largely as displacement of one lower lateral incisor in an adult with periodontal bone loss in whom light force was particularly important. (B and C) After space was opened for the right lateral incisor, a superelastic wire segment tied loosely beneath the brackets to reduce its slide friction was used to bring the lateral incisor into position, while arch form was maintained by a heavier archwire in the bracket slots. (D) Alignment completed. This approach allows use of optimal force on the tooth to be moved and distributes the reaction force over the rest of the teeth in the arch.

### Arch Expansion for Alignment

Alignment in nonextraction cases requires increasing the arch length, moving the incisors farther from the molars. A key question, of course, is the amount of arch expansion that a given patient can tolerate without the creation of major esthetic and posttreatment stability problems. In the context of this discussion, that decision was made at the treatment planning stage, and the focus here is how to efficiently accomplish an appropriate amount of arch expansion.

For alignment of crowded incisors, just tying a superelastic wire into the bracket slots is ineffective. Two objects cannot occupy the same space at the same time, so alignment cannot occur until space to allow it is created. The most straightforward way to accomplish this is to crimp a stop on a small round superelastic wire at the molar tube, so that it holds the wire just in front of the incisors (see Fig. 15.3). At subsequent appointments, if more arch length is needed, an additional stop or stops can be quickly slipped into position without removing the wire. When a broad arch form is used, transverse expansion across the premolars will occur. Even so, this type of arch expansion has the potential to carry the incisors facially, so it is not indicated in the presence of severe crowding unless incisor protrusion is desired.

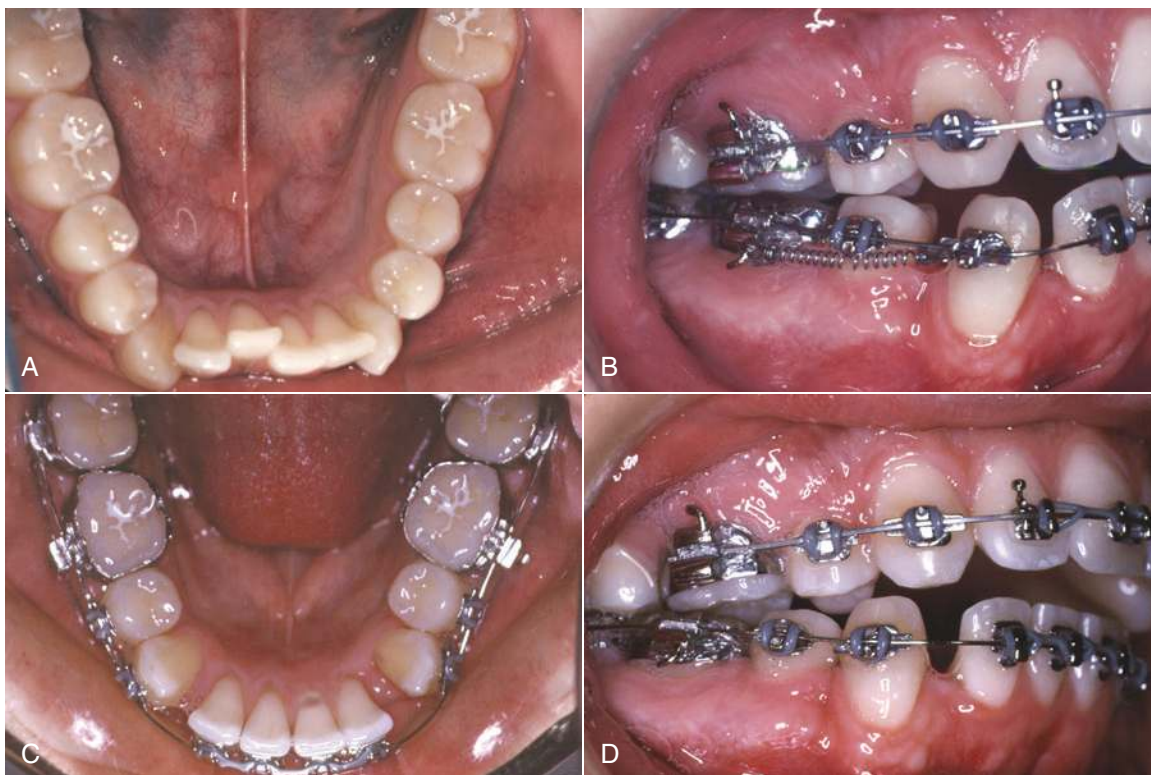
An alternative is to bypass the brackets on teeth that are crowded lingually, and place coil springs over the A-NiTi archwire to generate space (see Fig. 15.3C). When this is done, the archwire must be free to slide forward through the molar tubes and must be slightly long initially so that it will not come completely out of the tubes. The coil spring force must be very light to prevent distortion of

arch form, but it is a misconception that the force is so light the incisors will not be proclined. They will be, just as they are when advanced stops are used.

If incisor crowding is severe and arch expansion would produce unacceptable protrusion, premolar extraction is necessary. With the combination of a small superelastic wire in the bracket slots and NiTi springs to retract the canines (Fig. 15.8), efficient alignment without incisor protrusion can be obtained.

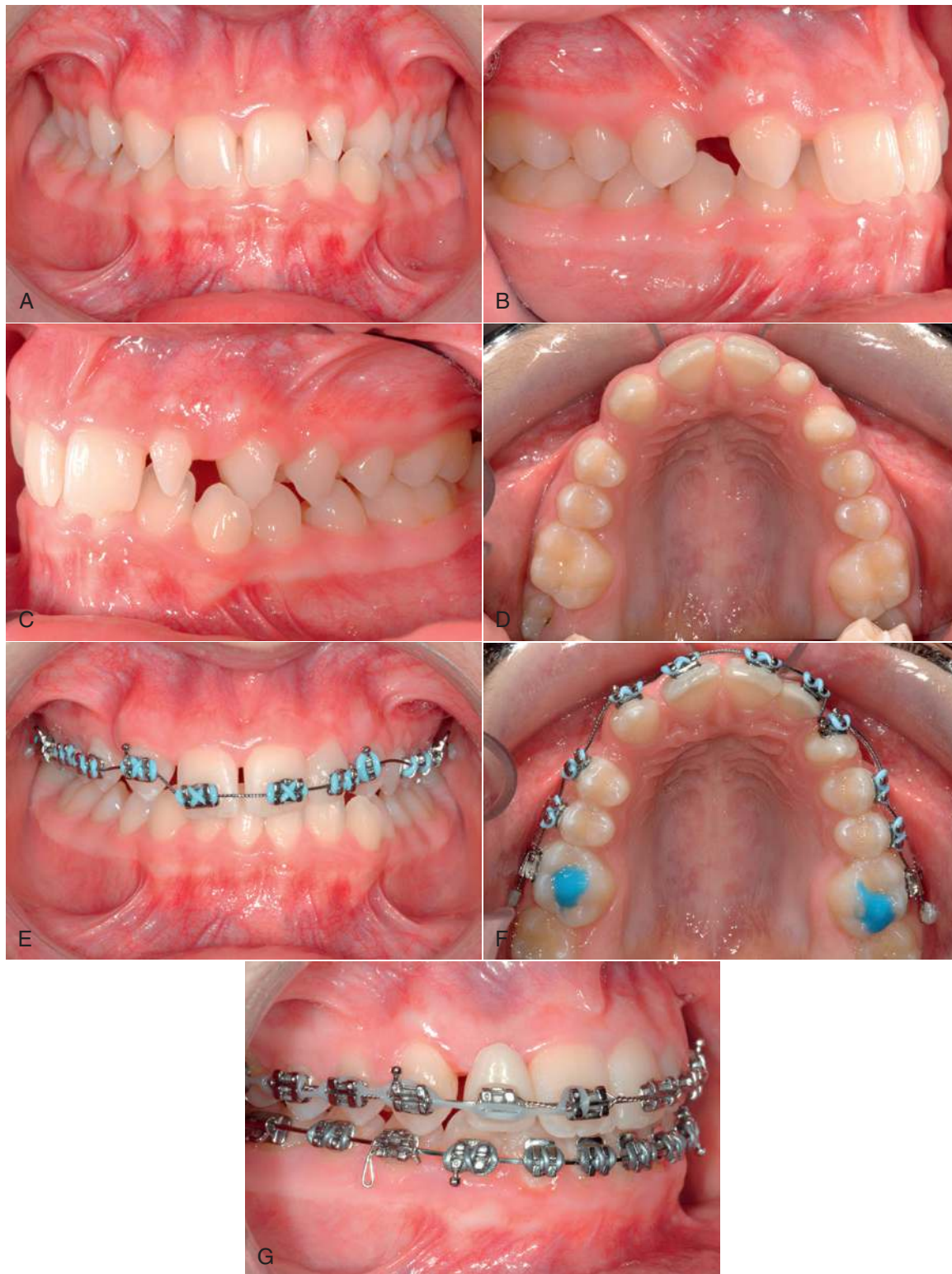The methods just described gain space primarily by advancing the incisors. Another way to gain space for alignment is transverse expansion, which should be focused on expanding across the premolars and molars, not across the canines. Transverse expansion with broad archwires can increase posterior arch width by several millimeters. The limitation in doing this is primarily the risk of fenestration of roots through the labial alveolar bone (see Chapter 8), but also it is difficult to avoid undesirable canine expansion. In the absence of a posterior crossbite (see later), heavy force to open the midpalatal suture just to gain additional space for alignment is not recommended.

Missing or distorted maxillary lateral incisors can pose complex alignment problems, especially if the midline is off because one lateral is missing and the other is present but small (Figs. 15.9 and 15.10). A combination of appropriately stiff archwires and management of the space is required. Note the use of a bonded denture tooth as a semipermanent retainer for the area where an implant eventually will be placed, with the pontic deliberately slightly oversize to ensure that there will be adequate space in the long term for the implant.



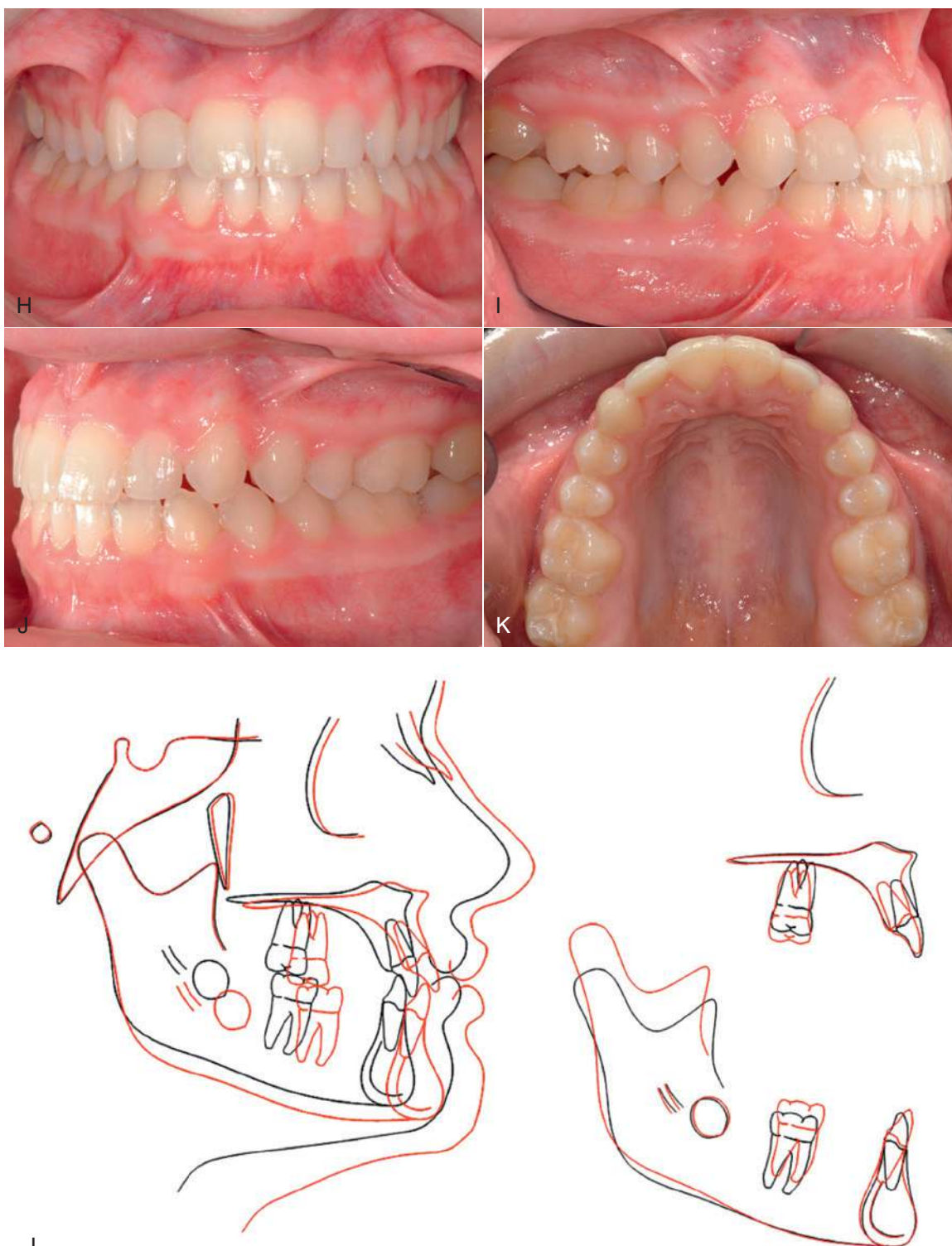
• **Fig. 15.8** Alignment of severely crowded lower incisors with simultaneous distal tipping of the canine into a first premolar extraction space with a nickel-titanium (NiTi) spring (the superelastic equivalent of the original “drag loop”). (A) Occlusal view before treatment. (B) Canine retraction with superelastic coil springs that provide 75 gm of force, and alignment of incisors with a superelastic NiTi wire that incorporates an accentuated reverse curve of Spee and delivers 50 gm. (C and D) Completion of canine retraction and incisor alignment after 5 months of treatment.



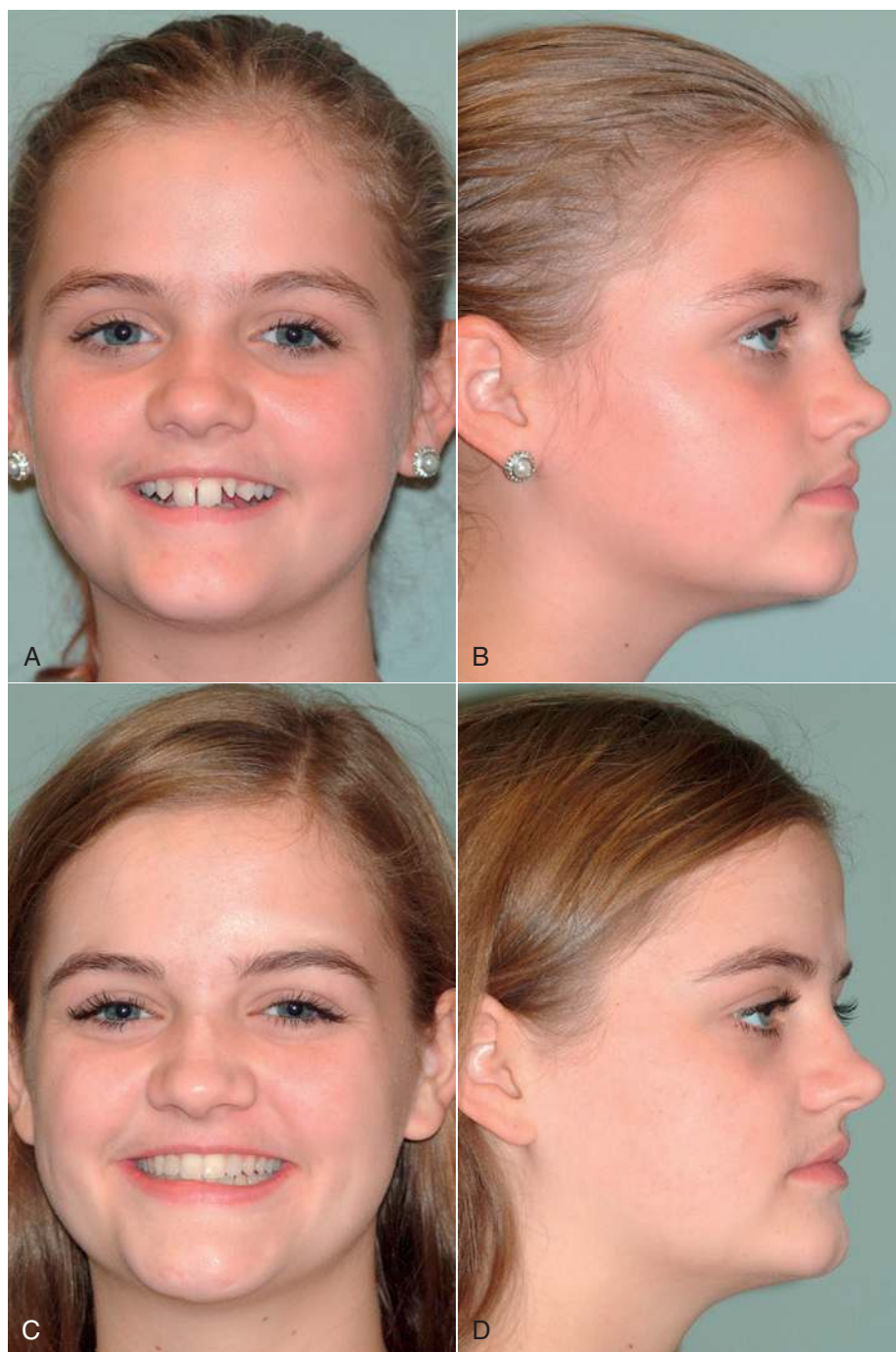


• **Fig. 15.9** A patient with a missing maxillary lateral incisor on one side and an abnormally small one on the other side poses a difficult treatment planning problem. (A to D) For this girl, the maxillary dental midline is well off to the right side, where the lateral incisor is missing; the small and misshapen lateral incisor on the other side is well mesial to the canine, which is rotated 90 degrees and in lingual crossbite with the lower canine but in a reasonably normal anteroposterior position. (E to G) The decision was to open space for an eventual implant to replace the missing lateral, which would facilitate correcting the maxillary incisor position relative to the midfacial line, and to do a prosthetic buildup on the small lateral. Bonded bite blocks were used to allow correction of the canine crossbite. *Continued*





• **Fig. 15.9, cont'd** (H to K) Note the use of a temporary bonded bridge consisting of a slightly oversize denture tooth, to be sure that enough space for the implant would be retained until the patient's late teens, when vertical growth was essentially complete, and the implant would not be left behind by continued eruption of the other teeth. This also stabilizes the rotated canine. A removable retainer is not indicated in this situation. (L) The cephalometric superimpositions show the considerable forward and vertical growth of both jaws during treatment. Note in the maxillary superimposition that the maxillary incisors required lingual root torque to obtain the proper inclination. (Courtesy Dr. T. Shaughnessy.)



• **Fig. 15.10** Same patient as in Fig. 15.9. (A and B) Before treatment. The patient's chief concern was the appearance of the teeth on smile. (C and D) She was quite pleased with the improvement. (Courtesy Dr. T. Shaughnessy.)

### Crossbite Correction

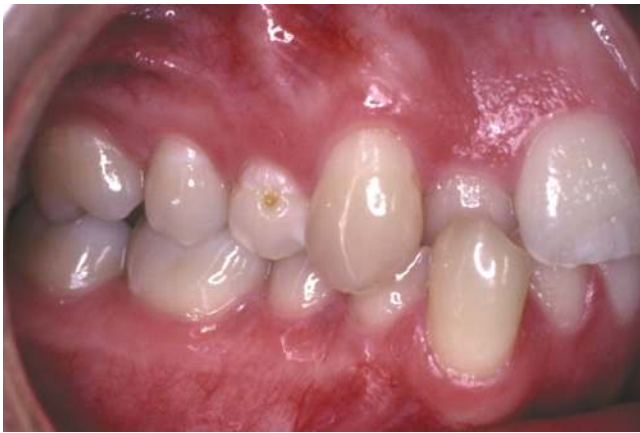Is crossbite correction really a part of alignment? That depends on the extent to which it is a largely a dental problem and on its severity. Skeletal crossbites already have been discussed in [Chapter 13](#). The discussion here is of crossbites that are largely dental. Correcting them usually also provides more space for alignment.

**Individual Teeth Displaced Into Anterior Crossbite.** Anterior crossbite of one or two teeth almost always is an expression of severe crowding ([Fig. 15.11](#)). This is most likely to occur when maxillary lateral incisors that are somewhat lingually positioned to begin with are forced even more lingually by lack of space. Correction of the

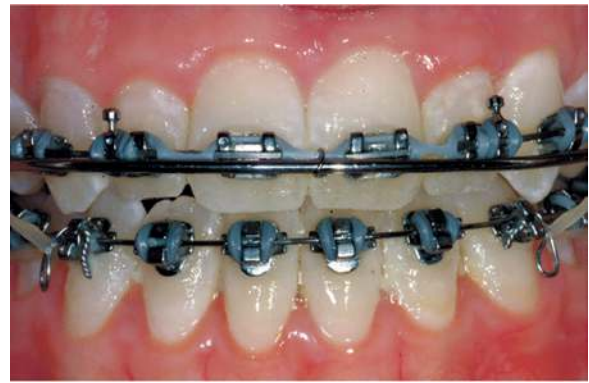crossbite requires first opening enough space, then bringing the displaced tooth or teeth across the occlusion into proper position.

Occlusal interferences can make this difficult. The patient may tend to bite brackets off the displaced teeth, and as the teeth are moved “through the bite,” occlusal force pushes them one way while the orthodontic appliance pulls them the other. It may be necessary to use bite blocks (usually bonding material on lower first molars) temporarily to separate the posterior teeth and create the vertical space needed to allow the teeth to move (see [Fig. 15.9F](#)). During rapid growth in early adolescence, incisors that were locked in anterior crossbite often can be corrected without

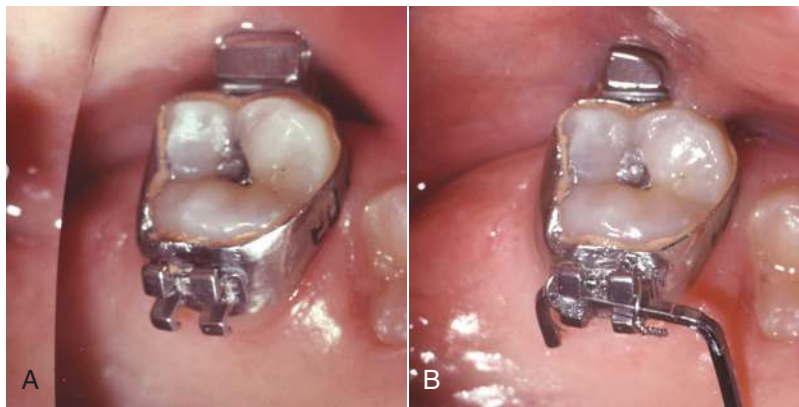



• **Fig. 15.11** Correction of a dental anterior crossbite, as in this patient in late adolescence, requires opening enough space for the lingually displaced maxillary incisor before attempting to move it facially into arch form. At that point, use of bonded bite blocks or a biteplate to obtain vertical clearance often is required.



• **Fig. 15.12** A heavy labial archwire (usually 36- or 40-mil steel) placed in the headgear tubes on first molars can be used for a small amount of expansion and to maintain arch width after palatal suture opening while the teeth are being aligned. This is more compatible with fixed appliance treatment than a removable retainer and does not depend on patient cooperation. (From *Contemporary Treatment of Dentofacial Deformity*. St. Louis, MO: Mosby; 2003.)



• **Fig. 15.13** A flexible transpalatal arch for expansion can be formed from rectangular 32 × 32 wire that fits into a horizontal tube or (A) into a special bracket on the lingual of upper first molars, as shown here. (B) Tying the wire into the bracket makes it easier to remove for adjustment and replace, but over time, gingival overgrowth can make re-ligation difficult.

temporarily opening the bite. After growth is largely completed, bite opening probably will be required.

Anterior crossbites of more than one or two teeth are usually due to a jaw discrepancy, and these patients rarely are candidates for tooth movement to correct malocclusion. That would be successful only if the patient met the criteria for Class III camouflage (discussed in [Chapter 16](#)). These patients may respond to growth modification treatment, especially if the problem is maxillary deficiency (see [Chapter 13](#)), but those with excessive mandibular growth probably will require surgery for correction (discussed in [Chapter 20](#)).

**Correction of Dental Posterior Crossbites.** Three approaches to correction of posterior crossbites due to lingual inclination of upper posterior teeth are feasible: a heavy labial expansion arch, as shown in [Fig. 15.12](#); an expansion lingual arch; or cross-elastics. Removable appliances, although theoretically possible, are not compatible with comprehensive treatment and should be reserved for the mixed dentition or adjunctive treatment.

The inner bow of a facebow is also, of course, a heavy labial arch, and expansion of the inner bow is a convenient way to expand the upper molars in a patient who is wearing headgear (see [Chapter 14](#)). This expansion is nearly always needed for patients with a Class II molar relationship, whose upper arch usually is too narrow to

accommodate the mandibular arch when it comes forward into the correct relationship because the upper molars are tipped lingually. The inner bow is simply adjusted at each appointment to be sure that it is slightly wider than the headgear tubes and must be compressed by the patient when inserting the facebow. If the distal force of a headgear is not desired, a heavy labial auxiliary can provide the expansion effect alone. The effect of the round wire in the headgear tubes, however, is to tip the crowns outward, and so this method should be reserved for patients whose molars are tipped lingually.

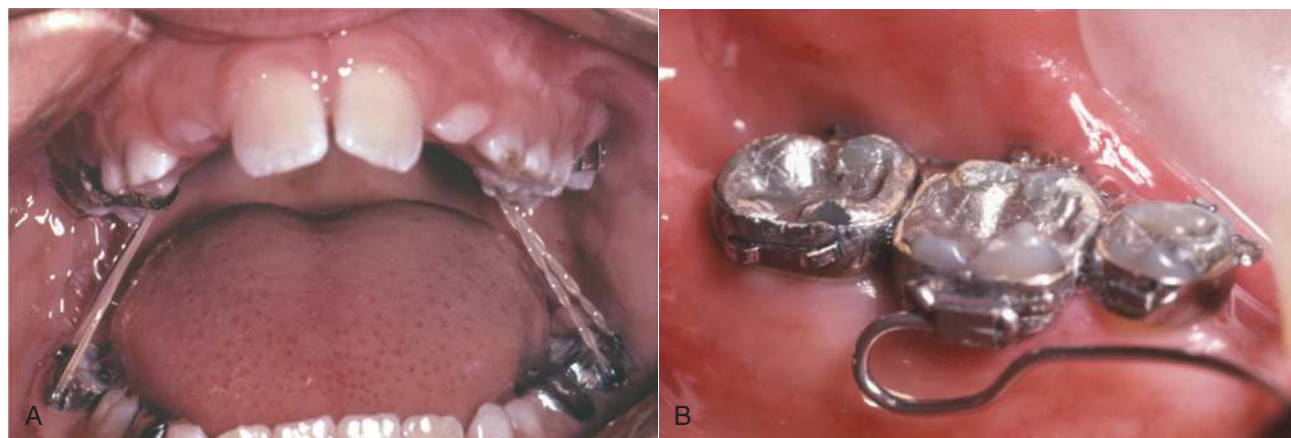
A transpalatal lingual arch for expansion must have some springiness and range of action. As a general principle, the more flexible a lingual arch is, the better it is for tooth movement but the less it adds to anchorage (which becomes important in camouflage treatment, discussed in [Chapter 16](#)). This can be an important consideration in adolescent and adult patients. If anchorage is of no concern, a highly flexible lingual arch such as the quad-helix design (see [Fig. 11.16](#)) is an excellent choice for adolescents as well as children. When the lingual arch is needed for both expansion and anchorage, however, the choices are 30-mil steel wire with an adjustment loop or the newer lingual arch system that allows the use of 32 × 32 TMA wire, which is flexible enough to not need a loop ([Fig. 15.13](#)).



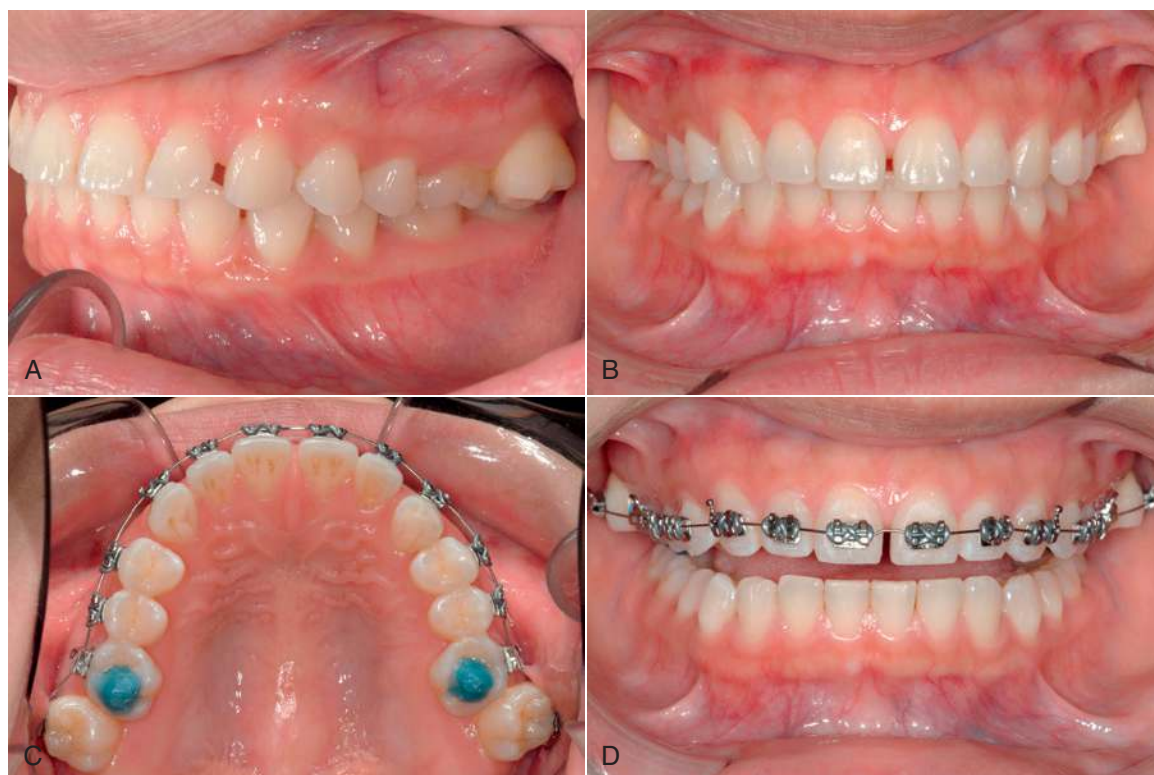The third possibility for moderate maxillary dental expansion is the use of cross-elastics, typically running from the lingual aspect of the upper molar to the buccal aspect of the lower molar and used with a stabilizing lingual arch in the mandible to prevent tipping of the lower molars lingually (Fig. 15.14). These elastics are effective, but their strong extrusive component must be kept in mind. Adolescent patients usually can tolerate a short period of cross-elastic wear to correct a simple crossbite because any

extrusion is compensated for by vertical growth of the ramus, but cross-elastics should be used with great caution, if at all, in adults. As any posterior crossbite is corrected, there is a tendency to rotate the mandible downward and backward, even if cross-elastics are avoided. The elastics accentuate this tendency.

If teeth are tightly locked into a posterior crossbite relationship, bite blocks or a biteplate to separate them vertically can make the correction easier and faster (Fig. 15.15). In children, this is rarely



• **Fig. 15.14** (A) Cross-elastics to correct posterior crossbite, a method that also extrudes the teeth and therefore is not well suited to patients who no longer have vertical growth. (B) Cross-elastics often are used with a mandibular stabilizing lingual arch, like the one shown here, so that the major effect is buccal tipping of the upper molars rather than lingual tipping of the lower molars.



• **Fig. 15.15** For correction of a severe dental crossbite after growth is largely complete, temporary opening of the bite blocks to open the bite is needed. (A and B) This severe buccal crossbite of the second molars would be all but impossible to correct without use of either a removable bite plate or bonded bite blocks. (C) Bonded bite blocks are more effective because they are present full-time and also are more comfortable for the patient. Cross-elastics are extrusive and would not be indicated for a patient like this. (D) An extension of a flexible archwire to bring the second molars into occlusion is the preferred method.

needed. In adolescents and adults, it can be quite helpful. Use of bite blocks during transverse expansion indicates that elongation of the posterior teeth and downward and backward rotation of the mandible is an acceptable outcome.

Maxillary expansion in adolescents by opening of the midpalatal suture is a growth modification procedure and has been discussed in some detail in [Chapter 13](#). As we noted there, opening the suture becomes more difficult after the end of the adolescent growth spurt, and skeletal anchorage for the expansion device becomes important. With the transition from late adolescence to early adult life, surgically assisted palatal expansion (SARPE) or segmental maxillary osteotomy is the only way to generate more than 1 to 2 mm of skeletal expansion, and these methods are discussed in [Chapter 20](#).

## Other Space Problems

### *Impacted or Unerupted Teeth*

Bringing an impacted or unerupted tooth into the arch creates a set of special problems during alignment. The most frequent impaction involves a maxillary canine or canines, but it is occasionally necessary to bring other unerupted teeth into the arch, and the same techniques apply for incisors, canines, and premolars. Impacted lower second molars pose a different problem and are discussed separately.

The problems in dealing with an unerupted tooth fall into three categories: (1) surgical exposure, (2) attachment to the tooth, and (3) orthodontic mechanics to bring the tooth into the arch.

**Surgical Exposure.** Before operation to expose an unerupted tooth, it is obviously important to know with some precision where it is. This is an indication for cone beam computed tomography (CBCT) with use of a unit with a small field of view (FOV) unless there is an indication for a large FOV (primarily, jaw asymmetry).<sup>2</sup> With a CBCT image, often it is apparent that before an impacted canine can be pulled downward toward its position in the dental arch, it will be necessary to move it away from the roots of the central or lateral incisor—information that changes treatment plans and was not available with previous radiographic methods.

It is important for a tooth to erupt through the attached gingiva, not through alveolar mucosa, and this must be considered when exposure of an unerupted tooth is planned. If the canine is labially positioned and probing shows that the crown is not covered with attached tissue, the crown can be exposed with a laser (see [Fig. 7.24](#)). If the unerupted tooth is more apically positioned in the mandibular arch or on the labial side of the maxillary alveolar process, a flap should be reflected from the crest of the alveolus and sutured so that attached gingiva has been transferred to the region where the crown is exposed (see [Fig. 11.45](#)). If this is not done and the tooth is brought through alveolar mucosa, it is quite likely that tissue will strip away from the crown, leaving an unsightly and periodontally compromised gingival margin.<sup>3</sup> For a very high canine that is positioned labially, a tunnel method is an alternative to raising of a flap. If the unerupted tooth is on the palatal side, similar problems with the heavy palatal mucosa are unlikely, and an open exposure can be used.<sup>4</sup>

Occasionally a tooth will obligingly erupt into its correct position after obstacles to eruption have been removed by surgical exposure, and delaying orthodontic traction to palatally impacted canines with incomplete roots is now recommended, but favorable spontaneous movement rarely occurs after root formation is complete. At that stage, even a tooth that is aimed in the right direction usually requires orthodontic force to bring it into position.

**Method of Attachment.** The best contemporary approach is to directly bond an attachment of some type to an exposed area of the crown. In many instances, a button or hook is better than a standard bracket because it is smaller. Then, if the tooth will be covered when the flap is replaced, a piece of fine gold chain is tied to the attachment, and before the flap is repositioned and sutured into place, the chain is positioned so that it extends into the mouth. The chain is much easier to tie to than a wire ligature. Before the availability of direct bonding, a pin was sometimes placed in a hole prepared in the crown of an unerupted tooth, and this remains a possible but much more invasive alternative.

The least desirable way to obtain attachment is for the surgeon to place a wire ligature around the crown of the impacted tooth. This inevitably results in loss of periodontal attachment because bone that is destroyed when the wire is passed around the tooth does not regenerate when it is removed, and this increases the chance of ankylosis. At present, use of wire ligatures around an unerupted tooth approaches malpractice and should be avoided.

It is critical for the surgeon performing the exposure procedure to be aware of the intended direction of orthodontic movement of the impacted tooth and that there is enough space for alveolar bone at the base of the crown when it comes into position ([Fig. 15.16](#)). CBCT views make this much more predictable and accurate and are now the standard of care for evaluating severely impacted teeth ([Fig. 15.16](#)).

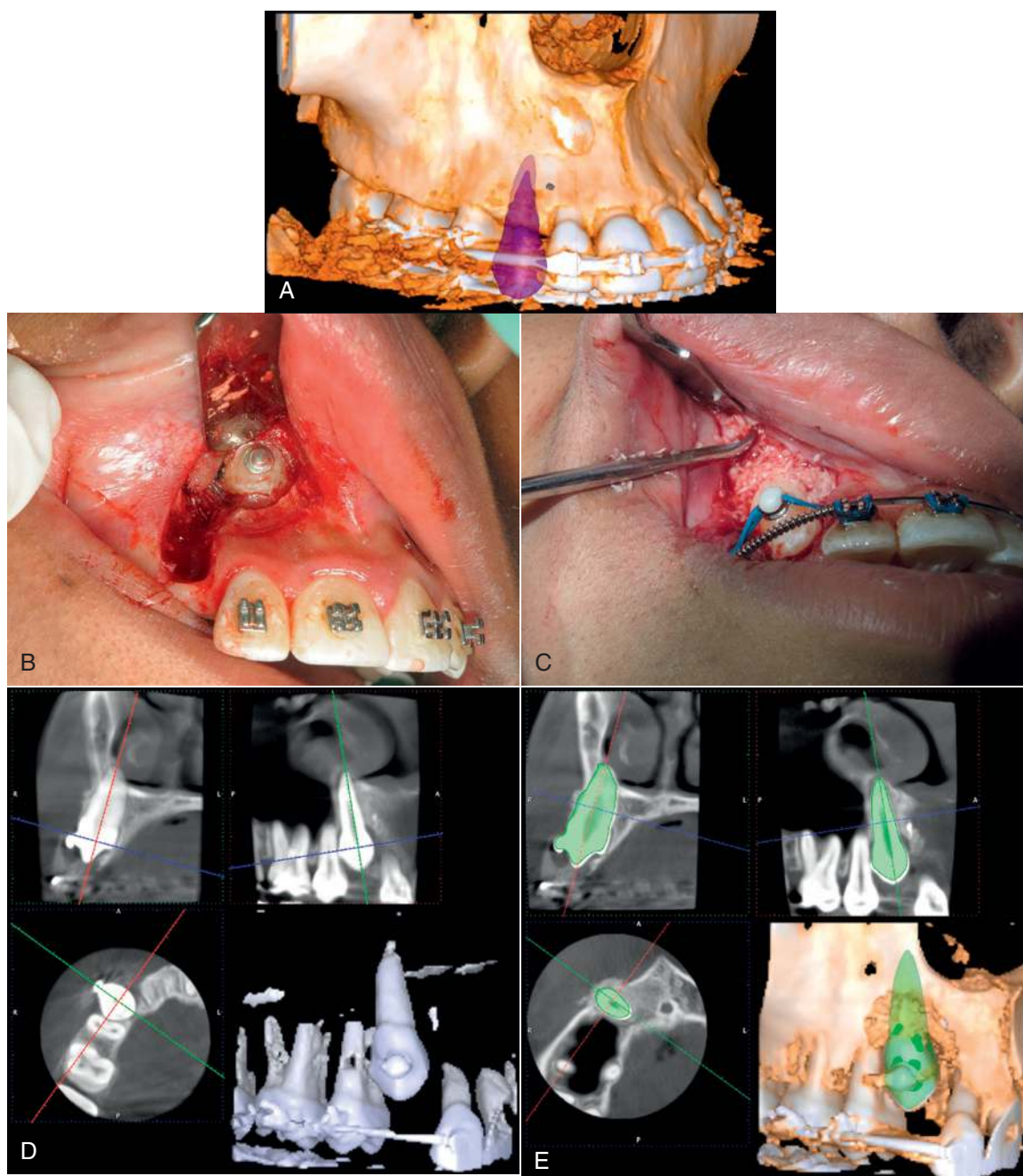
Once the crown of the tooth has been exposed for bonding an attachment, the cells in the follicle that allow bone resorption around enamel are no longer present. This means that any bone left in the direction of the impacted crown movement will be difficult or impossible to resorb. The surgeon needs to remove adequate bone so that no enamel-to-bone contact is created as the tooth is brought into the mouth. Failure to do this can greatly reduce the speed of tooth movement and may make the impacted tooth appear to be ankylosed.

**Mechanical Approaches for Aligning Unerupted Teeth.** Orthodontic traction to move an unerupted tooth away from other permanent tooth roots, if necessary, and then toward its place in the dental arch should begin as soon as possible after the surgical procedure. Ideally, a fixed orthodontic appliance should already be in place before the unerupted tooth is exposed, so that orthodontic force can be applied immediately. If this is not practical, active orthodontic movement should begin no later than 2 or 3 weeks postoperatively.

This means that for a labially impacted canine, orthodontic treatment to open space for the unerupted tooth and allow stabilization of the rest of the dental arch must begin well before the surgical exposure. In this instance, the goals of the presurgical orthodontic treatment are to create enough space if it does not exist, as often is the case, and to align the other teeth so that a heavy stabilizing archwire (at least 18-mil round steel, preferably a rectangular steel wire) can be in position at the time of operation. This allows postsurgical orthodontic treatment to start immediately. For a palatally impacted canine, open exposure often leads to downward drift, so immediate active treatment can be deferred for many of these patients.

As we have noted previously, an unerupted tooth is an extreme example of an asymmetric alignment problem, with one tooth far from the line of occlusion. An auxiliary NiTi wire, overlaid on the stabilizing arch in the same way as recommended for other asymmetric alignment situations (see [Fig. 15.7](#)), is the most efficient way to bring an impacted tooth into position. The numerous alternatives include a special alignment spring, either soldered to





• **Fig. 15.16** In modern correction of impacted canines, three-dimensional (3-D) images are necessary for more severe cases. (A) This 3-D rendering shows the virtual projection of the impacted canine into the dental arch, which allows an evaluation of the amount of bone available in the area around the base of the crown of the tooth. Lack of bone in that area can be a long-term problem. (B) Surgical exposure of the tooth and the creation of an eruption path for it also are greatly facilitated by 3-D images that allow creation of a path around the roots of other teeth. (C) The impacted tooth approaching the occlusal plane, with a bone slurry graft being placed over what otherwise would be a denuded root surface. (D and E) Views from the cone beam computed tomography (CBCT) image used in planning the exposure and eruption path. (Courtesy Dr. J. Fisher.)

a heavy base archwire or bent into a light archwire, or a cantilever spring from the auxiliary tube on the first molar.

Ankylosis of an unerupted tooth is always a potential problem. If an area of fusion to the adjacent bone develops, orthodontic movement of the unerupted tooth becomes impossible, and displacement of the anchor teeth will occur. Occasionally an unerupted

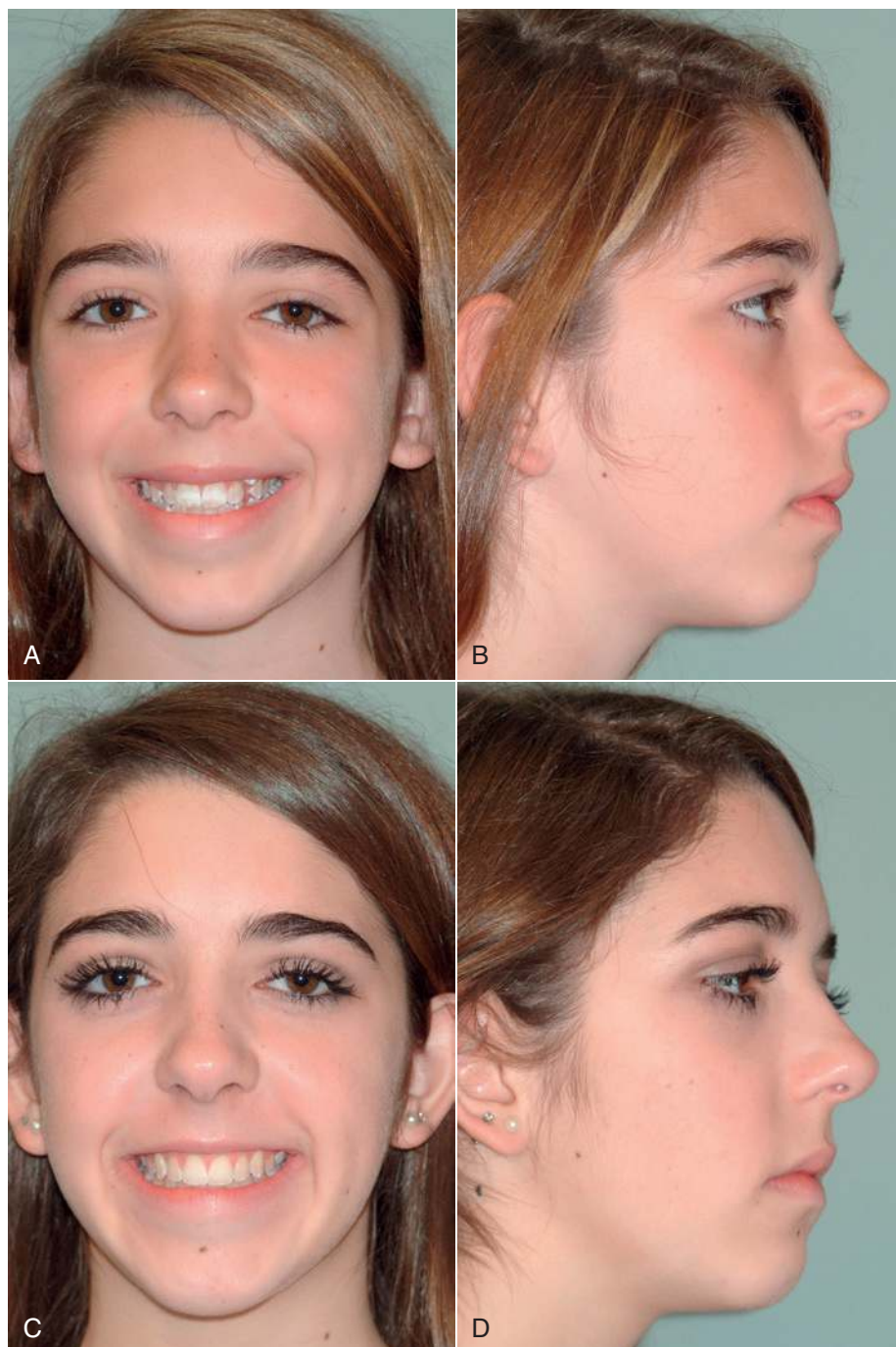
tooth will start to move and then will become ankylosed, apparently held by only a small area of fusion. It can sometimes be freed to continue movement if the area is anesthetized and the tooth lightly luxated, breaking the area of ankylosis. If this procedure is done, it is critically important to apply orthodontic force immediately after the luxation, because it is only a matter of time until the



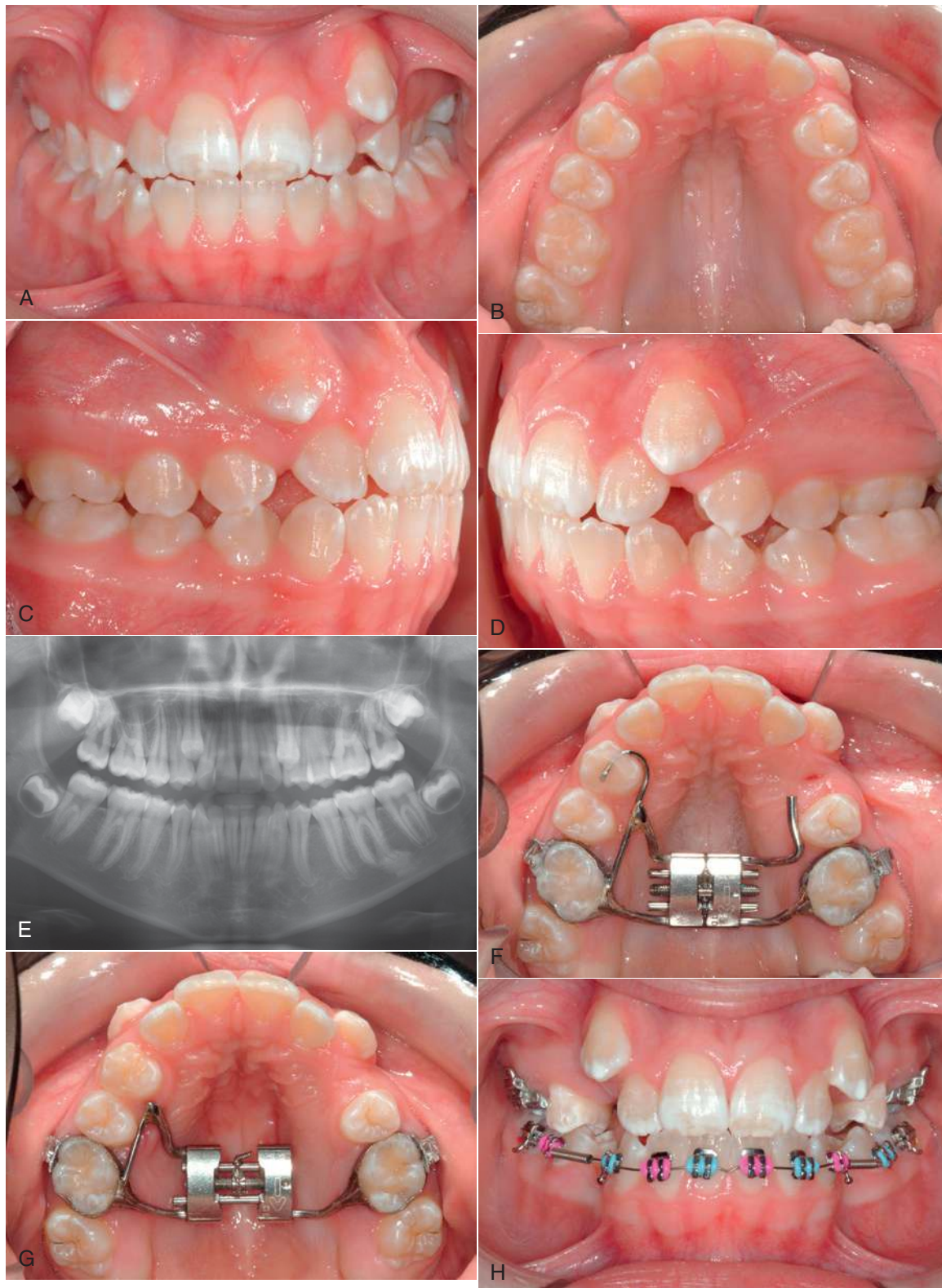tooth re-ankyloses. Nevertheless, this approach can sometimes allow a tooth to be brought into the arch that otherwise would have been impossible to move.

Canine impaction often accompanies a serious space discrepancy, so expanding the arch to make room for unerupted canines or extracting first premolars and using most of the extraction space becomes an important question at the treatment planning stage. Premolar extraction is a better choice than arch expansion that would create excessive incisor protrusion, especially if the canines are in a reasonably vertical position and only modest space closure would be needed (see Figs. 15.17 and 15.18).

**Unerupted or Impacted Lower Second Molars.** Unlike impaction of most other teeth, which is an obvious problem from the beginning of treatment, impaction of lower second molars usually develops during orthodontic treatment. This occurs when the mesial marginal ridge of the second molar catches against the distal surface of the first molar or on the edge of a first molar band so that the second molar progressively tips mesially instead of erupting. Moving the first molar posteriorly during the period of mixed dentition, or even preventing mesial movement to save space when second primary molars are lost, increases the chance that the second molar will become impacted. This possibility must

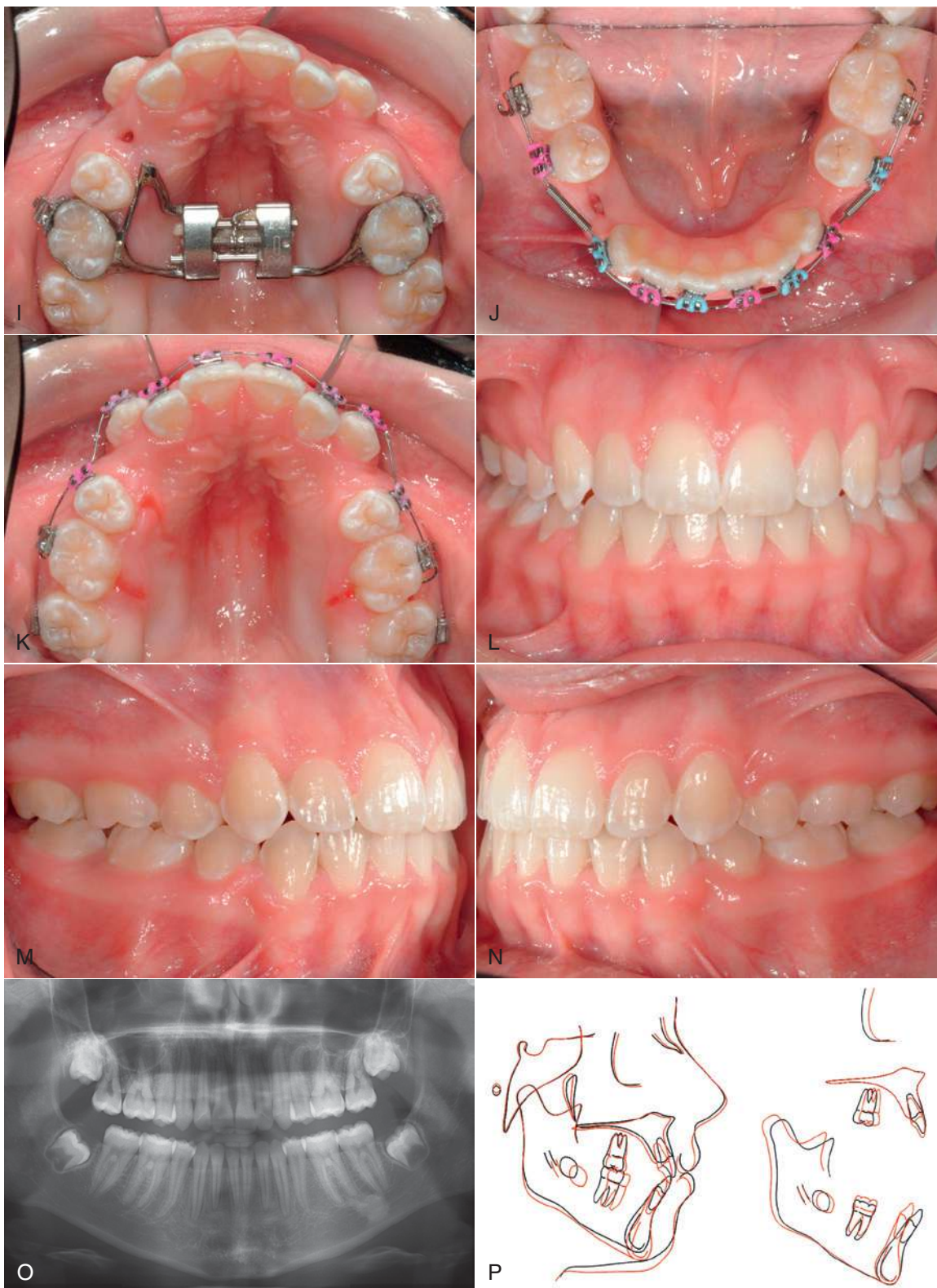


• **Fig. 15.17** (A and B) Pretreatment and (C and D) posttreatment facial appearance. Note the effect on the smile appearance of correcting both the maxillary incisor alignment and the relationship of the maxillary incisors to the lower lip on smile (the smile arc). (Courtesy Dr. T. Shaughnessy.)



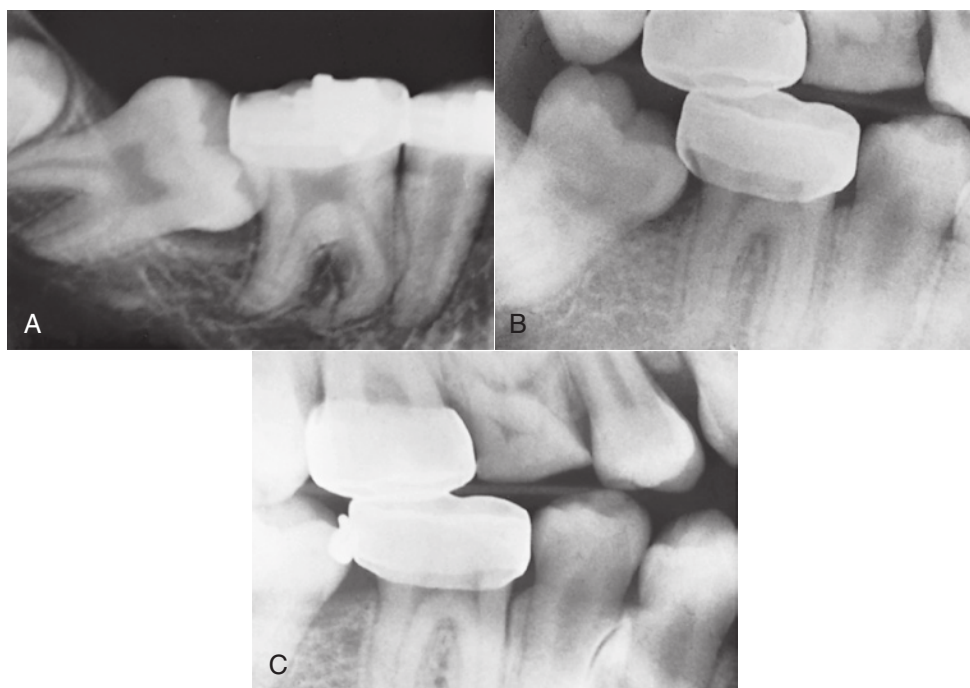
• **Fig. 15.18** Maxillary canines blocked out of the dental arch and erupting facially are a significant problem for a patient (same patient as in Fig. 15.17) who hears that he or she has “fangs.” (A to D) This girl had not only facially projected canines but also a unilateral crossbite, with the maxillary arch constricted on the left side. (E) The panoramic radiograph showed that if space were opened, it should be straightforward to bring the canines into the arch. The key question was whether extractions would be necessary to keep the incisors from becoming too protrusive, and the answer for this patient was that extraction of four first premolars would be the best plan. (F to H) Because unilateral expansion of the maxillary arch was needed, the first premolar on the maxillary right side was retained temporarily as additional anchorage, and this did result in the desired expansion on the constricted side. *Continued*





• **Fig. 15.18, cont'd** (I and J) Then the lower arch was leveled in preparation for space closure with moderate incisor retraction, and the maxillary canines were moved downward and backward into the premolar extraction site. (K to N) Satisfactory alignment, crossbite correction, and occlusion were obtained. (O) Panoramic radiograph at end of treatment. (P) The cephalometric superimposition shows normal position of the incisors posttreatment. For her, nonextraction treatment would have created excessive protrusion. (Courtesy Dr. T. Shaughnessy.)





• **Fig. 15.19** (A) Radiographic view of an impacted mandibular second molar in a 16-year-old patient. Uprighting the tooth from this position requires surgical exposure of a portion of the facial surface of the crown and bonding an attachment (if possible, a tube) so that a spring can be used to tip the tooth distally and bring it into the arch. (B) For a second molar that is caught on the edge of a first molar band, a simpler approach is uprighting achieved with a 20-mil brass wire tightened around the contact. Usually it is necessary to anesthetize the area to place a separator of this type. (C) Uprighting and distal movement obtained with the brass wire separator (same patient as B). A spring clip (one type is sold as the Arkansas de-impaction spring) can be used in the same way, but both brass wire and spring clips are effective only for minimal molar uprighting. Neither would have worked for the situation shown in (A).

be kept in mind when procedures to increase mandibular arch length are employed. Many clinicians now delay or avoid banding lower first molars because of this risk.

Correction of an impacted second molar requires tipping the tooth posteriorly and uprighting it (Fig. 15.19). In most cases, if the mesial marginal ridge can be unlocked, the tooth will erupt on its own. When the second molar is not severely tipped, the simplest solution is to place a separator between the two teeth. For more severe problems, an attachment must be bonded to the second molar. An auxiliary spring (Fig. 15.20) often is useful to bring both upper and lower second molars into alignment when they erupt late in orthodontic treatment. The easiest way to do this is to use a segment of NiTi wire from the auxiliary tube on the first molar to the tube on the second molar. A rectangular wire, usually 16 × 22 M-NiTi, is preferred. This provides a light force to align the second molars while a heavier and more rigid wire remains in place anteriorly, which is much better than going back to a light round wire for the entire arch just to align the second molars.

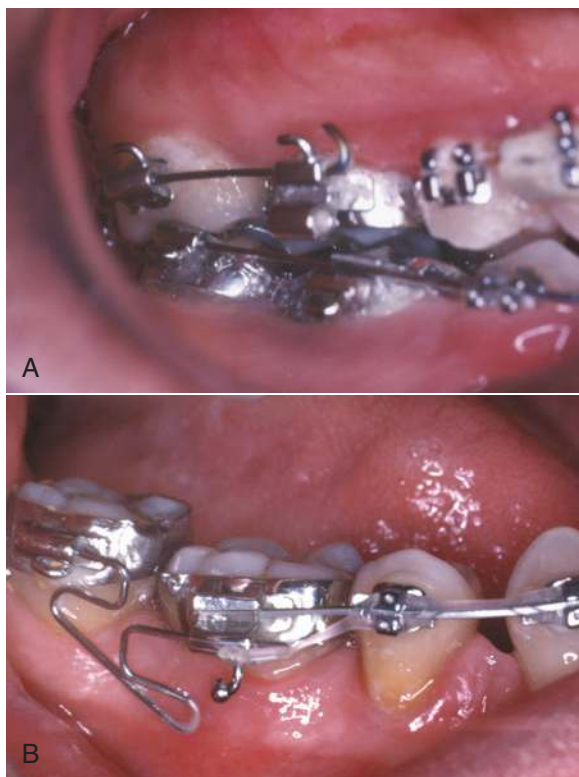
Another possibility in adolescents is surgical uprighting of the impacted second molar, taking advantage of the space that is created when the third molar is extracted. In carefully selected cases, this can work quite nicely. Vitality of the second molar is retained because it essentially is rotated around the root apex, and the defect on the mesial of the uprighted tooth fills in with bone in the same way that it does when orthodontic uprighting is done (Fig. 15.21).<sup>5,6</sup> The outcome is best when some vertical jaw growth remains so that the uprighted tooth does not remain elongated relative to the first molar.

### Diastema Closure

A maxillary midline diastema is often complicated by the insertion of the labial frenum into a notch in the alveolar bone, so that a band of heavy fibrous tissue lies between the central incisors. When this is the case, a stable correction of the diastema almost always requires surgery to remove the interdental fibrous tissue and reposition the frenum. The frenectomy must be carried out in a way that will produce a good esthetic result and must be properly coordinated with orthodontic treatment.

It is an error to surgically remove the frenum at an early age and then delay orthodontic treatment in the hope that the diastema will close spontaneously. If the frenum is removed while there is still a space between the central incisors, scar tissue forms between the teeth as healing progresses, and a long delay may result in a space that is more difficult to close than it was previously.

It is better to align the teeth before frenectomy. Sliding them together along an archwire is usually better than using a closing loop because a loop with any vertical height will touch and irritate the frenum. If the diastema is relatively small, it is usually possible to bring the central incisors completely together before the surgical procedure (Fig. 15.22). If the space is large and the frenal attachment is thick, it may not be possible to completely close the space before surgical intervention. The space should be closed at least partially, and then orthodontic movement to bring the teeth together should be resumed immediately after the frenectomy so that the teeth are brought together quickly after the procedure. When this is done, healing occurs with the teeth together, and the inevitable postsurgical scar tissue stabilizes the teeth instead of creating obstacles to final closure of the space.



• **Fig. 15.20** When a second molar is banded or bonded relatively late in treatment, often it is desirable to align it with a flexible wire while retaining a heavier archwire in the remainder of the arch. (A) Repositioning a maxillary second molar by using a straight segment of rectangular austenitic nickel–titanium (A-NiTi) wire that fits into the auxiliary tube on the first molar and the tube for the main archwire on the second molar. (B) Repositioning a mandibular second molar by using a segment of steel wire with a loop that extends from the auxiliary tube on the first molar. In both arches, after the repositioning a continuous archwire can extend to the second molar.

The key to successful operation is removal of the interdental fibrous tissue. It is unnecessary and in fact undesirable to excise a large portion of the frenum itself. Instead, a simple incision is used to allow access to the interdental area, the fibrous connection to the bone is removed, and the frenum is then sutured at a higher level.<sup>7</sup>

A maxillary midline diastema tends to recur, no matter how carefully the space was managed initially. The elastic gingival fiber network typically did not cross the midline in these patients, and the operation interrupted any fibers that did cross. As a result, in this critical area the normal mechanism to keep teeth in contact is missing. A bonded fixed retainer is recommended (see Fig. 15.22G).

## Leveling

The archwire design for leveling the dental arch when there is an excessive curve of Spee depends on whether there is a need for absolute intrusion of incisors or whether relative intrusion is satisfactory. This important point is discussed in detail in Chapter 7, and the biomechanical considerations in obtaining intrusion are described in Chapters 8 and 9. As a general rule, relative intrusion is quite acceptable for adolescents; absolute intrusion is used for the most part in patients who are too old for relative intrusion to succeed. The following discussion assumes that an appropriate decision about the type of leveling has been made and focuses on the rather different techniques for leveling by relative intrusion

(which is really differential elongation of premolars, for the most part) versus leveling by absolute intrusion of incisors (Fig. 15.23).

## Leveling by Extrusion (Relative Intrusion)

Leveling by extrusion can be accomplished with continuous archwires simply by placing an exaggerated curve of Spee in the maxillary archwire and a reverse curve in the mandibular archwire. For most patients, it is necessary to replace the initial highly resilient alignment arch with a slightly stiffer one to complete the leveling. With both the 18- and 22-slot appliances, when preliminary alignment is completed, the second archwire is almost always 16-mil steel, with an exaggerated curve of Spee in the upper arch and a reverse curve in the lower arch. In most instances, this is sufficient to complete the leveling. A possible alternative is a 16-mil “potato chip” A-NiTi wire, preformed by the manufacturer with an extremely exaggerated curve. The extreme curve needed to generate enough force can lead to problems if patients miss appointments (i.e., the wire does not failsafe), so these wires are not recommended for routine use.

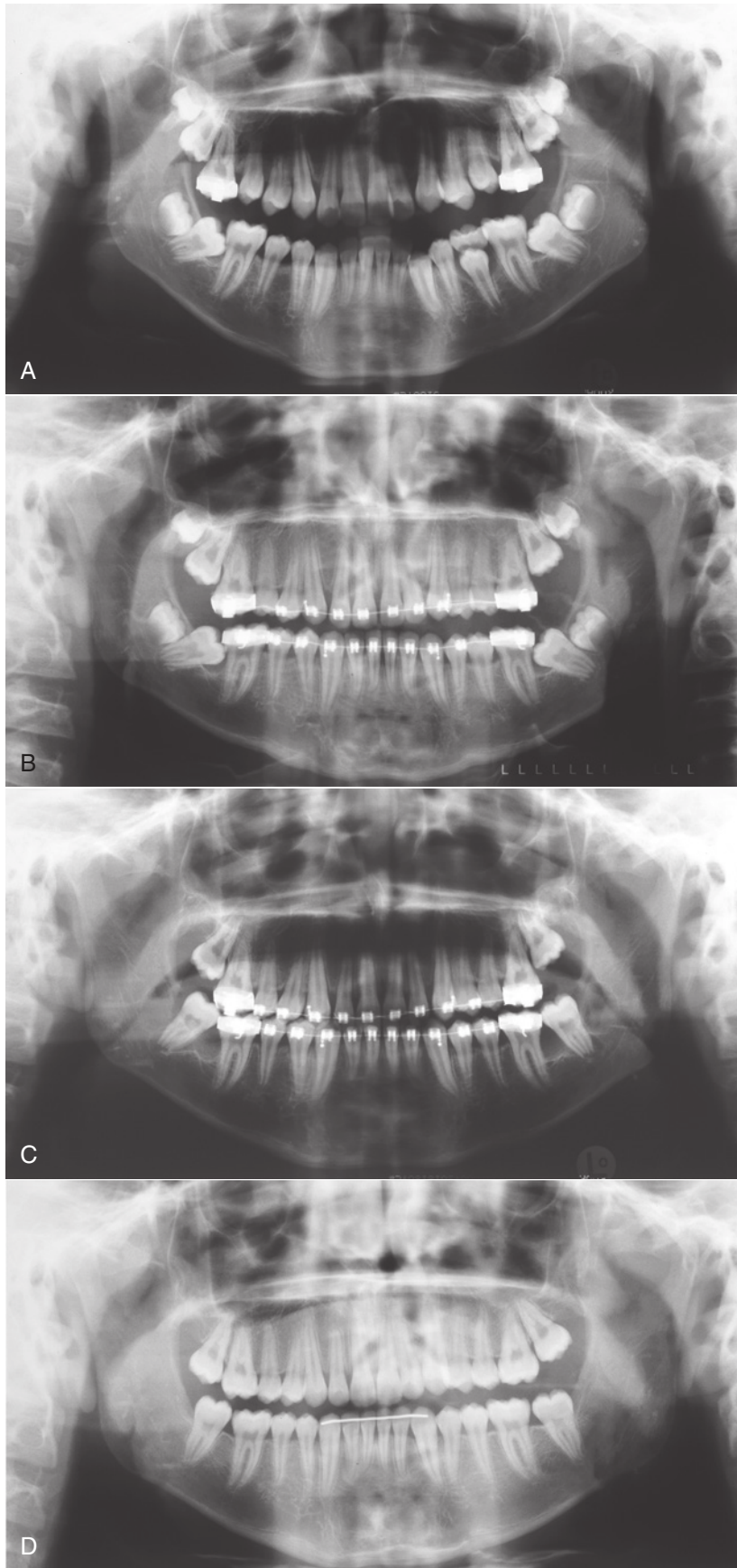
In some patients, particularly in those who have little if any remaining growth, an archwire heavier than 16-mil steel is needed to complete the leveling of the arches. With the 22-slot appliance, an 18-mil archwire is used almost routinely, as a step toward bracket engagement with a larger rectangular wire. With the 18-slot appliance, rather than using an 18-mil round wire, it is usually quicker and easier to leave the 16-mil wire in place and add an auxiliary leveling arch of 17 × 25 mil TMA or steel (Fig. 15.24A–B). This auxiliary wire inserts into the auxiliary tube on the molar and is tied anteriorly beneath the 16-mil base arch. In essence, this augments the curve in the base arch and results in efficient completion of the leveling by the same mechanism as a single continuous wire. Although the auxiliary leveling arch looks like an intrusion arch (Fig. 15.24C–D), it differs in two important ways: the presence of a continuous rather than segmented base arch and the higher amount of force. Leveling will occur almost totally by extrusion as long as a continuous rather than segmented wire is in the bracket slots, and segmenting the arch makes intrusion possible (Fig. 15.24E–F).

For a typical patient using the 22-slot appliance, initial alignment with an A-NiTi wire (delivery of light force, not size, is the critical variable) is usually followed by a 16-mil steel wire with a reverse or accentuated curve and then by an 18-mil round wire to complete the leveling. This archwire sequence is nearly always adequate for completion of leveling, and it is unusual that 20-mil wire or an auxiliary archwire is required.

With either slot size, it is an error to place a rectangular archwire with an exaggerated curve of Spee in the mandibular arch because the curve creates torque to move the incisor roots lingually. Almost always that is undesirable. Inadvertent torque of lower incisor roots is one of the commonest mistakes with the edgewise appliance. The arch should be level before a rectangular wire is placed, or step bends rather than a reverse curve of Spee should be placed in the rectangular wire, and torque in any rectangular wire should be monitored carefully. In the maxillary arch, however, a rectangular wire with an accentuated curve of Spee would be quite acceptable if lingual root torque of the upper incisors is needed, as it often is.

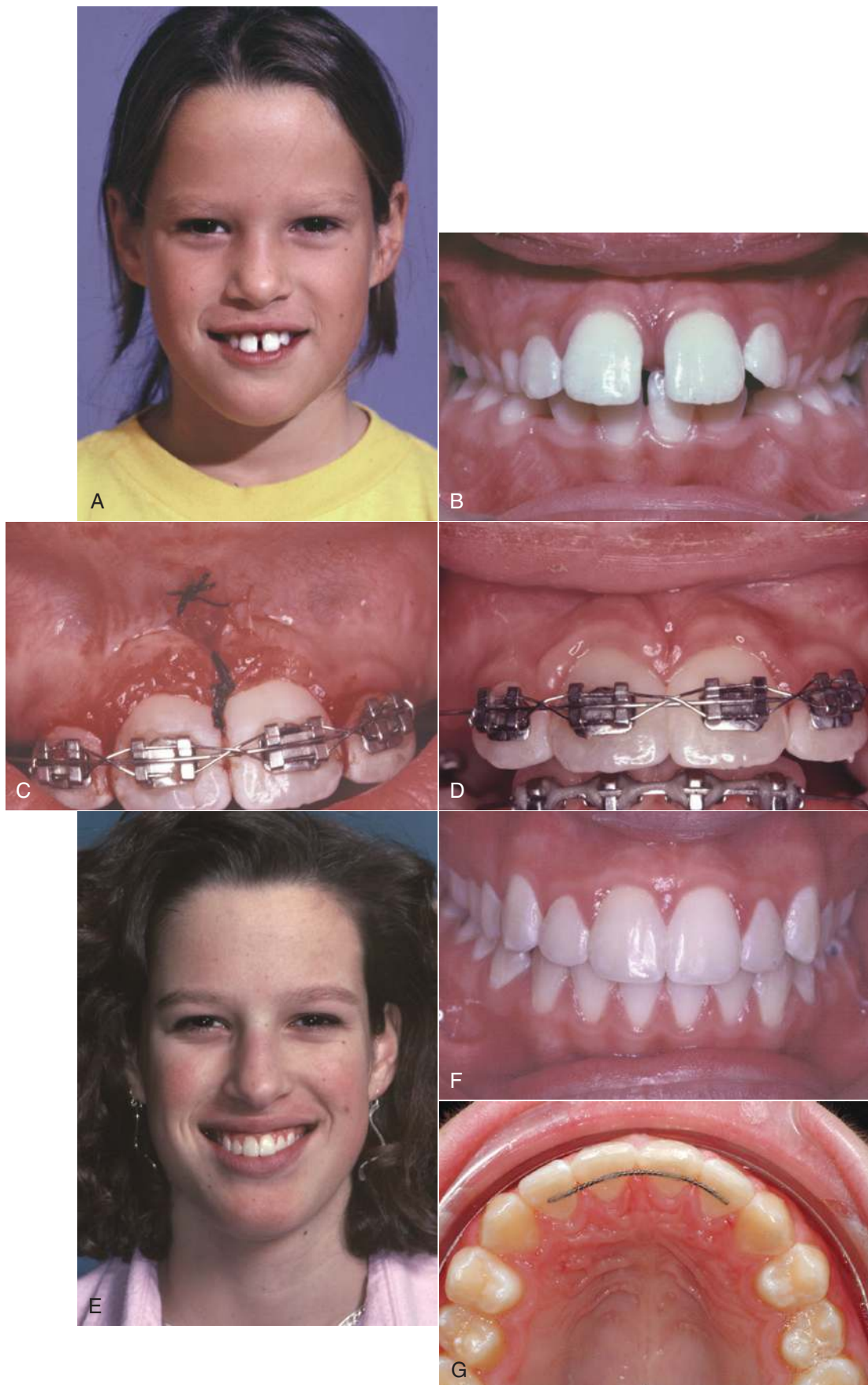
## Clear Aligner Therapy (Invisalign)

As we have noted, the most frequent problem in adolescent orthodontic patients is a combination of malaligned incisors and excessive overbite. For patients with this problem who want clear aligner therapy, the usual choice is arch expansion for alignment,

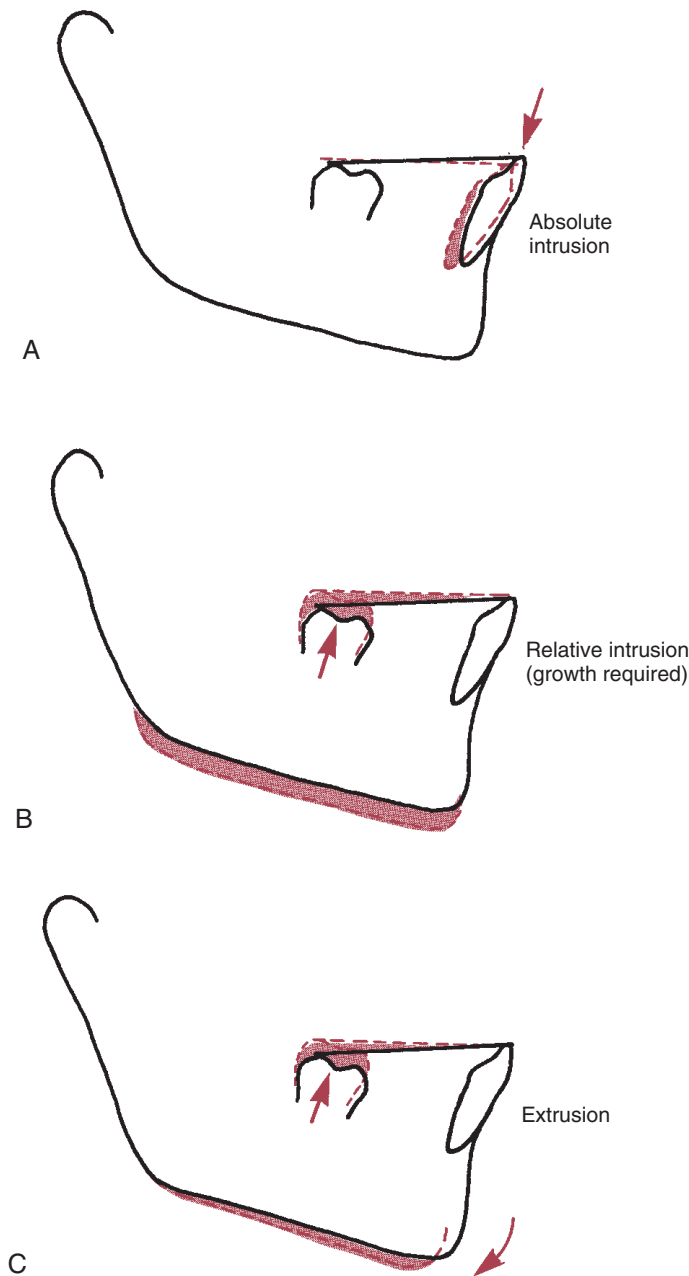


• **Fig. 15.21** Surgical uprighting of impacted mandibular second molars sometimes is the easiest way to deal with severe impactions. (A) Age 12, before loss of the second primary molars, with the permanent second molars tipped mesially against the first molars. Teeth in this position often upright spontaneously when the first molars drift mesially after the primary molars are lost. (B) Age 14, with severe impaction 1 year after the beginning of orthodontic treatment. (C) Age 14, after surgical uprighting of the second molar, which was rotated around its root apex into the space created by third molar extraction. Loss of pulp vitality usually does not occur when this is done. (D) Age 16, after completion of orthodontic treatment. Note the excellent fill-in of bone between the first and second molars.





• **Fig. 15.22** Management of a maxillary midline diastema. (A) Facial appearance showing the protruding maxillary incisors caught on the lower lip. (B) Intraoral view before treatment. (C) Teeth aligned and held tightly together with a figure-of-eight wire ligature before frenectomy. (D) Appearance immediately after frenectomy with the conservative technique advocated by Edwards in which a simple incision is used to allow access to the interdental area, the fibrous connection to the bone is removed, and the frenal attachment is sutured at a higher level. (E) Facial appearance 2 years after completion of treatment. (F) Intraoral view 2 years after treatment. (G) Bonded retainer, made with 1.75-mil steel twist wire. It is important for the retainer wire to be flexible enough to allow some displacement of the incisors in function; a rigid wire is much more likely to break loose.



• **Fig. 15.23** There are three possible ways to level a lower arch with an excessive curve of Spee: (A) absolute intrusion; (B) relative intrusion, achieved by preventing eruption of the incisors while growth provides vertical space into which the posterior teeth erupt; and (C) extrusion of posterior teeth, which causes the mandible to rotate down and back in the absence of growth. Note that the difference between (B) and (C) is whether the mandible rotates downward. This is determined by whether the ramus grows longer while the tooth movement is occurring, not by the orthodontic mechanics.

and tipping the mandibular incisors facially can be enough to correct the overbite in mild cases. When more severe overbite is present, restraining further eruption of lower incisors and encouraging eruption of mandibular canines and premolars—relative intrusion—is needed. This can be managed reasonably well by leaving a space within the lower aligner above the canines and premolars while using attachments on the incisors and molars to stabilize the aligner. The result is a combination of intrusive force

against the incisors while they are being tipped facially, as would be the case with a round wire with a reverse curve of Spee, and removal of any restraint to eruption of the canines and premolars.

The greater the deep bite, the more likely it is that the upper aligner should be modified with virtual bite ramps (see Fig. 19.42). Although no good data exist, case reports suggest that the results with modified aligners are similar to relative intrusion with a fixed appliance.

All other things being equal, relative intrusion is most successful during late childhood or early adolescence because there is more vertical growth then. Aligners, however, are better suited to older adolescents. Fortunately, they usually still have enough vertical growth remaining for a moderate deep bite problem to be corrected.

### Leveling by Intrusion

Leveling by intrusion with a fixed appliance requires a mechanical arrangement other than a continuous archwire attached to each tooth. The key to successful intrusion is light continuous force directed toward the tooth apex. It is necessary to avoid pitting intrusion of one tooth against extrusion of its neighbor because in that circumstance extrusion will dominate. This can be accomplished in three ways: (1) with continuous archwires that bypass the premolar (and frequently the canine) teeth, (2) with segmented archwires (so that there is no connection along the arch between the anterior and posterior segments) and an auxiliary depressing arch, and (3) with aligners that have attachments on the posterior teeth so that when an upward force is placed on the anterior teeth, the aligner does not slide down posteriorly.

### Bypass Archwires

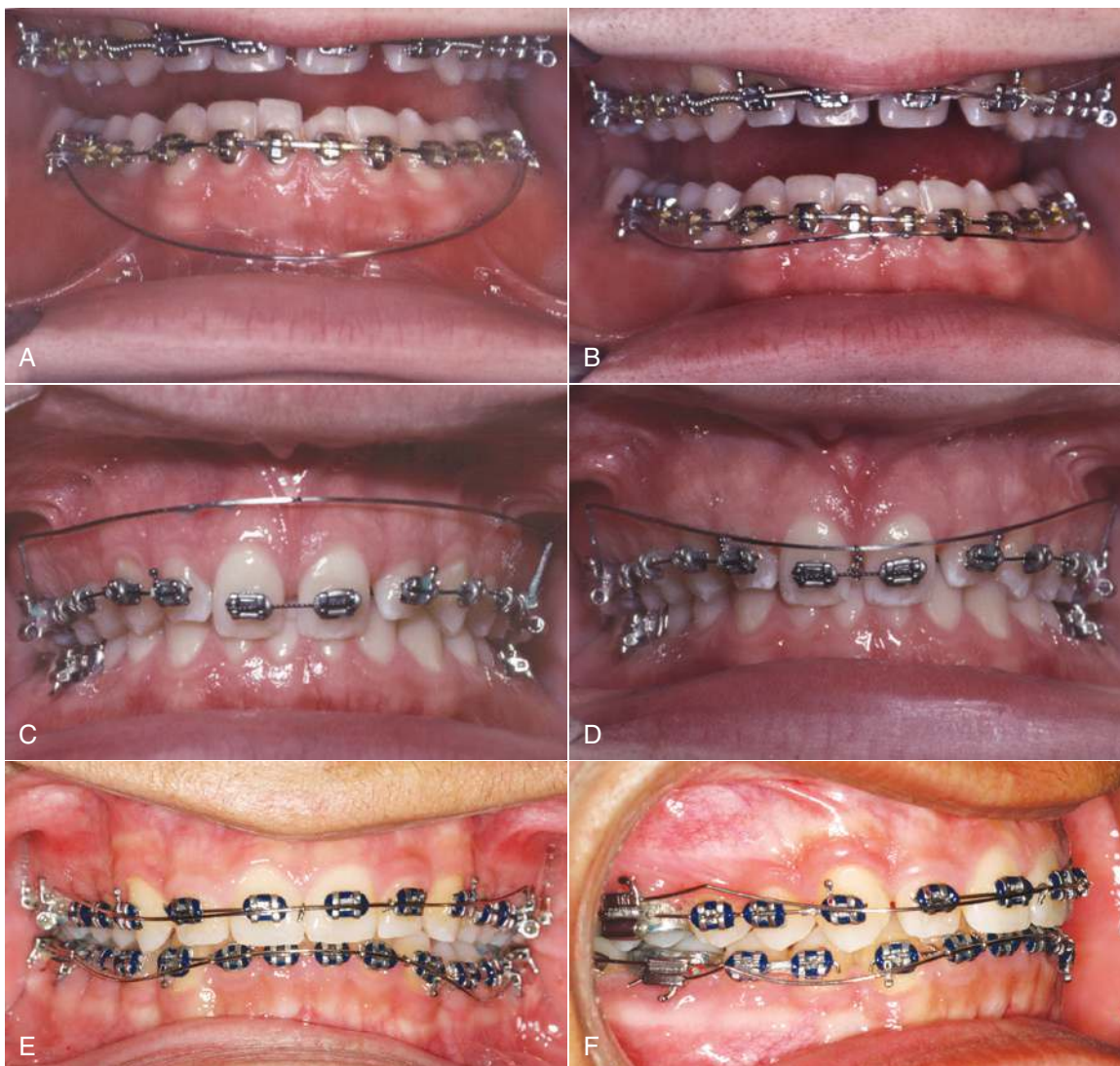
Use of the bypass arches approach to intrusion is most useful for patients who will have a lot of vertical growth (i.e., who are in either the mixed or early permanent dentition period). Three different mechanical arrangements are commonly used, each based on the same mechanical principle: uprighting and distal tipping of the molars, pitted against intrusion of the incisors.

A classic version of this approach to leveling was seen in the first stage of the Begg technique in which the premolar teeth were bypassed and only a loose tie was made to the canine. The same effect can be produced in exactly the same way by using the edgewise appliance, if the premolars and canines are bypassed with a  $2 \times 4$  appliance (only two molars and four incisors included in the appliance setup)<sup>8</sup> (Fig. 15.25) or if brackets on premolars simply do not have the main archwire tied in (see Fig. 15.24E–F).

A more flexible variation of the same basic idea was developed as Ricketts' utility arch.<sup>9</sup> In most cases, a utility arch formed from rectangular wire was placed into the brackets with slight labial root torque to control the inclination of the teeth as the incisors move labially while they intrude. However, this results in a complex two-couple mechanical system that makes it impossible to predict exactly what the effect will be (see discussion in Chapter 9), and utility arches for intrusion have largely been replaced by the segmented arch approach described later because sometimes they work well and sometimes they do not.

Successful use of any type of bypass arch for leveling requires keeping the forces light. This is accomplished in two ways: by selecting a small-diameter archwire, and by using a long span between the first molar and the incisors. Wire heavier than 16-mil steel should not be used, and Ricketts recommended a relatively soft  $16 \times 16$  cobalt–chromium wire for utility arches to prevent heavy forces from being developed. A more modern recommendation





• **Fig. 15.24** With a continuous archwire in place, intrusion is essentially impossible, but an auxiliary leveling archwire can be useful in augmenting the leveling force from a wire tied into the brackets. (A) Auxiliary leveling wire before and after activation (B) by tying it beneath a continuous mandibular archwire. The appropriate force in this instance is approximately 150 gm, and the expected action is leveling by extruding the premolars rather than intruding the incisors. For absolute intrusion, light force (approximately 10 gm per tooth) is necessary. This requires use of archwire segments and an auxiliary intrusion arch. (C) Intrusion arch before and after activation (D) by bending it downward and tying it to the segment to be intruded. The force delivered by the intrusion arch can be measured easily when it is brought down to the level at which it will be tied. (E) Auxiliary leveling arches for extrusion in the maxillary arch and (F) for incisor-canine intrusion in the mandibular arch. Note that the mandibular base arch is segmented, creating a separate incisor segment; a continuous archwire is in place in the maxillary arch and the auxiliary leveling arch is tied into the anterior brackets on top of it. Intrusion requires a segmented base arch and a light intrusive force (here, with six mandibular incisors in the anterior segment, approximately 50 gm would be used). Extrusion can be done with a segmented or continuous archwire by using about 50 gm per tooth in the segment to be extruded.

would be 16 × 22 beta-titanium (beta-Ti) wire. Whatever the wire choice, overactivation of the vertical bends can cause loss of control of the molars in all three planes of space.

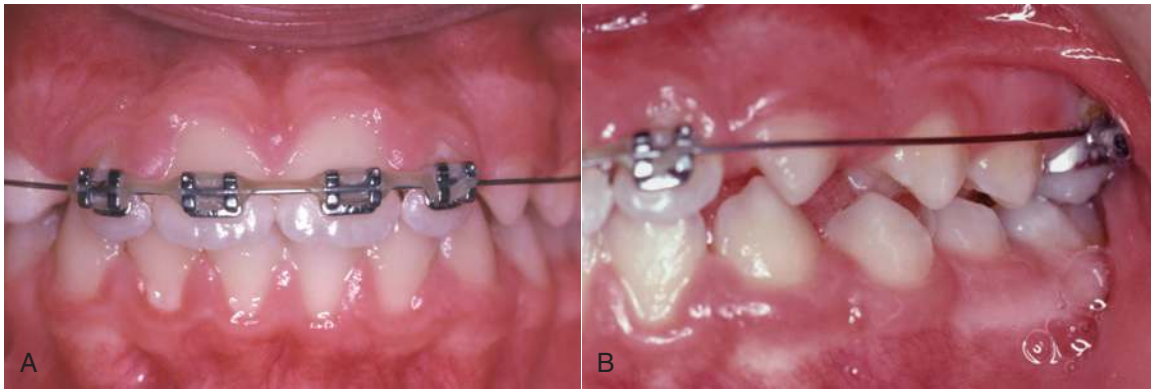
In contrast to leveling with continuous fully engaged archwires, the size of the edgewise bracket slot is largely irrelevant when bypass arches for leveling are used. Whether an 18- or 22-slot appliance is used, the bypass arch should not be stiffer than 16-mil steel wire.

Two weaknesses of the bypass arch systems limit the amount of true intrusion that can be obtained. The first is that, except for

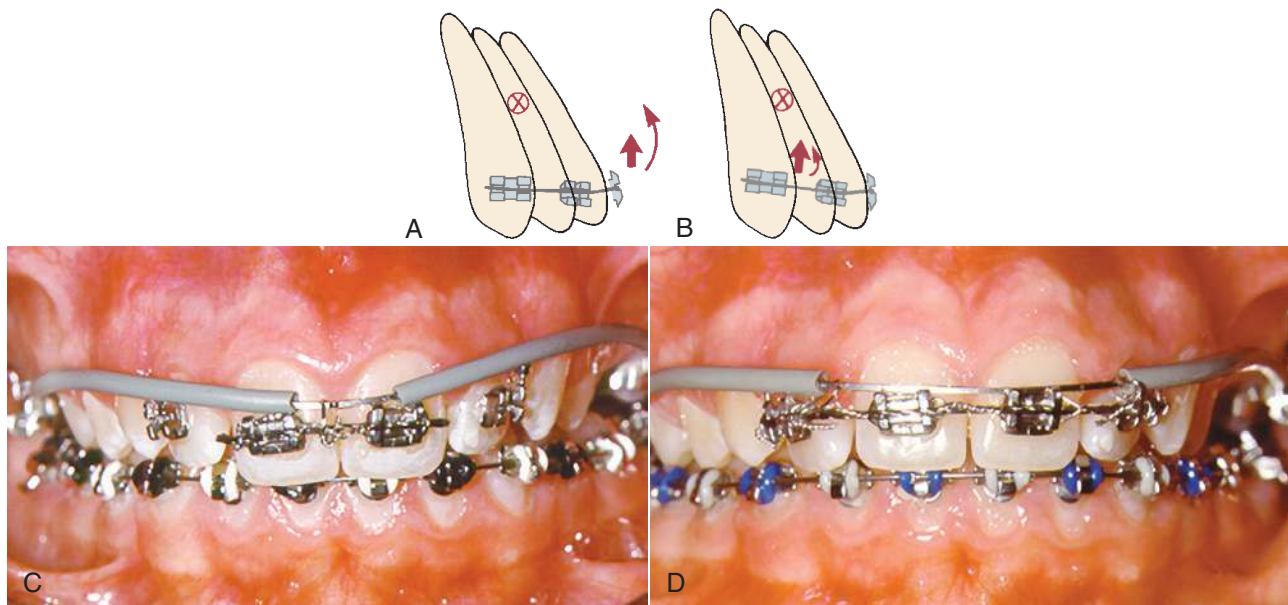
some applications of the utility arch, only the first molar is available as posterior anchorage. This means that significant extrusion of that tooth may occur. In actively growing patients with a good facial pattern, this is not a major problem, but in nongrowing patients or those with a poor facial pattern in whom molar extrusion should be avoided, the lack of posterior anchorage compromises the ability to intrude incisors.

The second weakness is that the intrusive force against the incisors is applied anterior to the center of resistance, and therefore the





• **Fig. 15.25** (A and B) The long span of a  $2 \times 4$  appliance makes it possible to create the light force necessary for incisor intrusion and also makes it possible to create unwanted side effects. This appliance is best described as deceptively simple. When incisor intrusion is desired before other permanent teeth can be incorporated into the appliance, a transpalatal lingual arch for additional anchorage is a good idea.



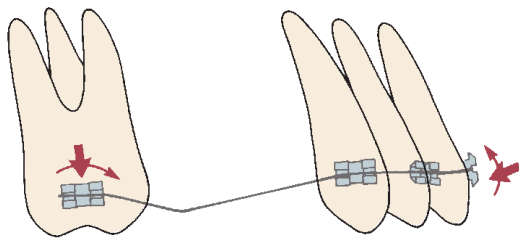
• **Fig. 15.26** (A) When the incisor segment is viewed from a lateral perspective, the center of resistance (X) is lingual to the point at which an archwire attaches to the teeth. For this reason, the incisors tend to tip forward when an intrusive force is placed at the central incisor brackets. (B) Tying an intrusion arch distal to the midline (for instance, between the lateral incisor and canine, as shown here) moves the line of force more posteriorly and therefore closer to the center of resistance. This diminishes or eliminates the moment that causes facial tipping of the teeth as they intrude. (C) Intrusion arch tied in the midline as only the central incisors are intruded, so that the incisors will tip facially as they intrude. (D) In the same patient later, an intrusion arch now is tied between the central and lateral incisors to intrude all four incisors while reducing the amount of facial tipping.

incisors tend to tip forward as they intrude (Fig. 15.26). Without an extraction space, forward movement of the incisors is an inevitable consequence of leveling, but in extraction cases this becomes an undesirable side effect. An anchor bend at the molar in a bypass arch creates a space-closing effect that somewhat restrains forward incisor movement (Fig. 15.27), but this also tends to bring the molar forward, straining the posterior anchorage. A utility arch can be activated (like a closing loop) to keep the incisors from moving forward and has the additional benefit of a rectangular cross-section anteriorly so that tipping can be controlled, but the result is still a strain on posterior anchorage, and, more important, it results in an unknown intrusion force that may be too heavy or too light (see Fig. 9.39).

### Segmented Archwires for Intrusion

The segmented arch approach developed by Burstone, which overcomes these limitations, is recommended for maximum control of the anterior and posterior segments of the dental arch. Data now exist to document equivalent long-term stability with leveling by continuous archwires versus sectional wires in the segmented arch technique.<sup>10</sup>

The segmented arch approach (Fig. 15.26) allows attachments on all the teeth and so provides better control of anchorage. For intrusion of anterior teeth, it depends on establishing stabilized posterior segments and controlling the point of force application against an anterior segment. This technique requires auxiliary rectangular tubes on first molars in addition to the regular bracket



• **Fig. 15.27** Diagrammatic representation of the forces for a leveling arch that bypasses the premolars, with an anchor bend mesial to the molars. A force system is created that elongates the molars and intrudes the incisors. The wire tends to slide posteriorly through the molar tubes, tipping the incisors distally at the expense of bodily mesial movement of the molars. An archwire of this design was used in the first stage of Begg treatment but also can be used in edgewise systems. A long span from the molars to the incisors is essential.

or tube. After preliminary alignment, a full-dimension rectangular archwire is placed in the bracket slots of teeth in the buccal segment, which typically consists of the second premolar, first molar, and second molar. This connects these teeth into a solid unit. In addition, a heavy lingual arch (36-mil round or 32 × 32 rectangular steel wire) is used to connect the right and left posterior segments, further stabilizing them against undesired movement. A resilient anterior segmental wire is used to align the incisors while the posterior segments are being stabilized.

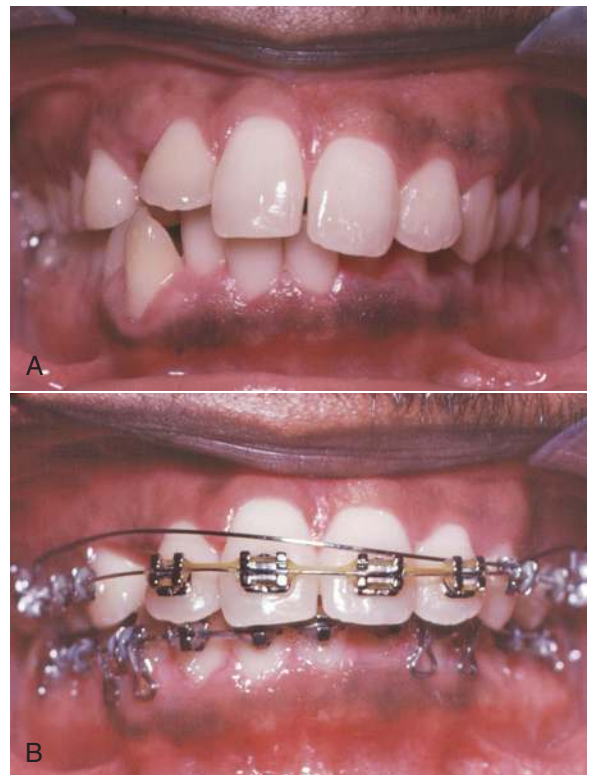For intrusion, an auxiliary arch placed in the auxiliary tube on the first molar is used to apply intrusive force against the anterior segment. It should be made of rectangular wire that will not twist in the auxiliary tube. The auxiliary tube should be 18 × 25 whether the main appliance is an 18- or 22-slot appliance. In it, 17 × 25 steel wire with a 2½-turn helix or 17 × 25 wire works well. If the auxiliary tube is 22 × 28, 19 × 25 TMA wire without a helix or a preformed M-NiTi intrusion arch is acceptable, but the range of light force is lower. This auxiliary arch is adjusted so that it lies gingival to the incisor teeth when passive and applies a light force (approximately 10 gm per tooth, depending on root size) when it is brought up beneath the brackets of the incisors. It is tied underneath or in front of the incisor brackets but not into the bracket slots, which are occupied by the anterior segment wire.

Intrusion of maxillary incisors to level the arch is done more frequently than intrusion of mandibular incisors, but intruding these teeth is necessary for some patients. The technique is the same: an auxiliary intrusion arch is inserted into the auxiliary tubes on the mandibular first molars, and the base arch is segmented (see Fig. 15.30).

An auxiliary intrusion arch can be placed while a light resilient anterior segment is being used to align malposed incisors, but usually it is better to wait to add it until incisor alignment has been achieved and a heavier anterior segment wire has been installed. Full-dimension braided rectangular steel wire or a rectangular TMA wire is usually the best choice for the anterior segment while active intrusion with an auxiliary arch is being carried out.

Two strategies can be used with segmented arches to prevent forward movement of the incisors as they are intruded. The first is the same as with bypass arches: a space-closing force can be created by tying the auxiliary arch back against the posterior segments. Even with stabilized posterior segments, this produces some strain on posterior anchorage.

The second and usually preferable strategy is to vary the point of force application against the incisor segment. If the anterior



• **Fig. 15.28** (A) In this adult patient, the maxillary left central and lateral incisors and particularly the canine had supererupted. Asymmetric intrusion of those teeth was needed. (B) An auxiliary intrusion arch delivering about 30 gm was tied to the elongated canine while preliminary alignment with an austenitic nickel–titanium (A-NiTi) wire was employed. The result was leveling of the maxillary arch with a component of intrusion on the elongated side. Asymmetric intrusion can be accomplished either by asymmetric activation of an intrusion arch that spans from one first molar to the other or by use of a cantilever intrusion arch on one side only.

segment is considered a single unit (which is reasonable when a stiff archwire connects the teeth within the segment), the center of resistance is located as shown in Fig. 15.26. Tying the depressing arch distal to the midline, between the central and lateral incisors or distal to the laterals, also brings the point of force application more posterior so that the force is applied more nearly through the center of resistance. This prevents anterior tipping of the incisor segment without causing anchorage strain, but the auxiliary wire must be tied quite loosely at both points to avoid the risk of inadvertently creating a two-couple system.

Even with the control of posterior anchorage obtained by placing rectangular stabilizing segments and an anchorage lingual arch, the reaction to intrusion of incisors is extrusion and distal tipping of the posterior segments. A stabilizing transpalatal lingual arch is needed to augment anchorage. With careful attention to appropriate forces and moments with the segmented arch approach, it is possible to produce approximately four times as much incisor intrusion as molar extrusion in nongrowing adults. Although successful intrusion can be obtained with round bypass arches, the ratio of anterior intrusion to posterior extrusion is much less favorable.

It is quite feasible to intrude asymmetrically, which requires only adjusting the teeth that are placed in stabilizing and intrusion segments and tying the auxiliary intrusion arch in the area where intrusion is required (Fig. 15.28). If intrusion is desired on only

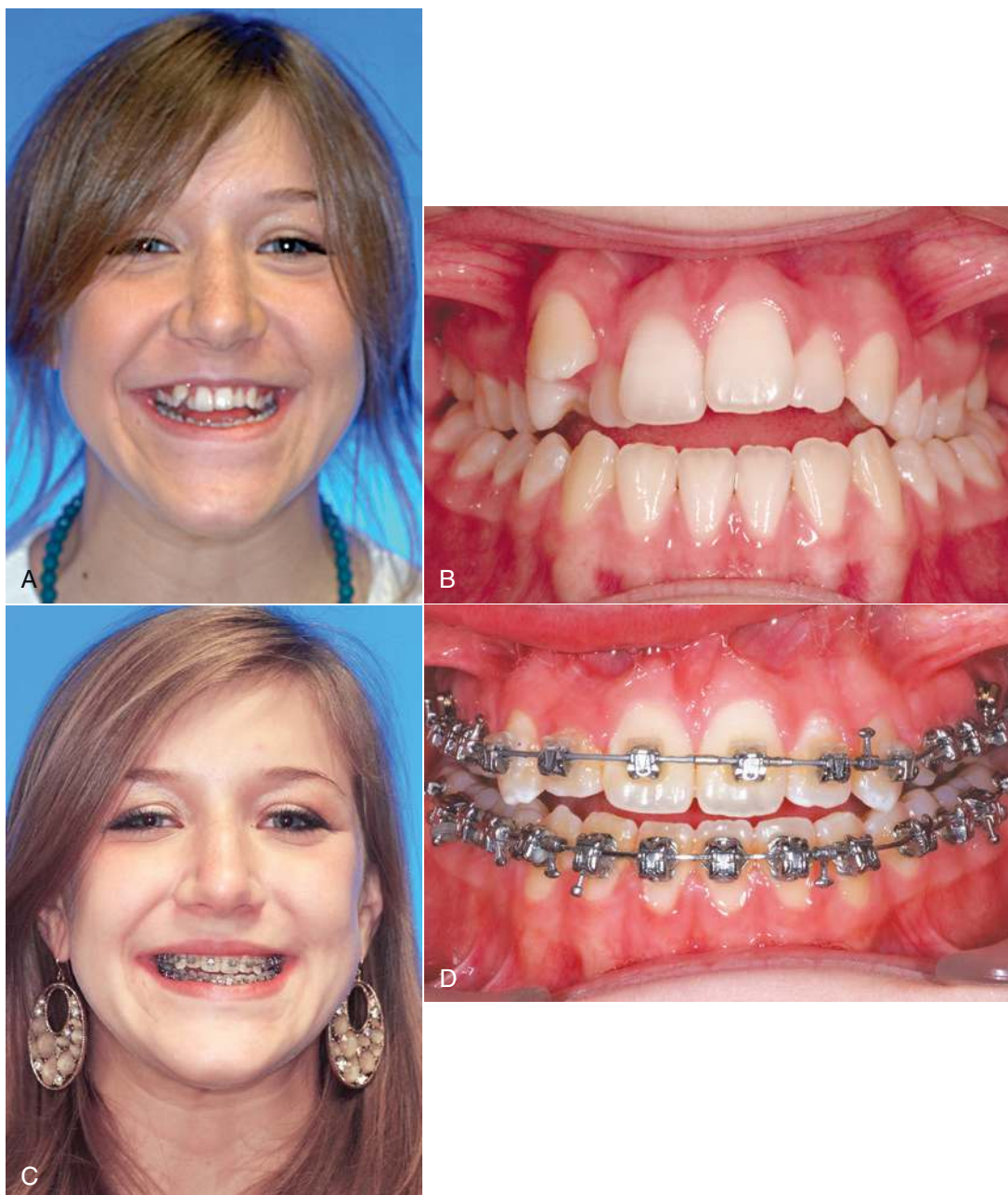

one side, either a cantilevered auxiliary wire extending from one molar or a molar-to-molar auxiliary arch can be used. The key is tying the auxiliary arch at the point where intrusion is desired.

It also is possible to intrude posterior teeth to correct an anterior open bite. Frequently a major component of a skeletal open bite is a tipped palatal plane, and intrusion of maxillary posterior teeth (Fig. 15.29) can provide an acceptable dental compensation if the

problem is not too severe. This requires skeletal anchorage. It should be deferred until after the adolescent growth spurt and for that reason is presented in detail in [Chapter 19](#).

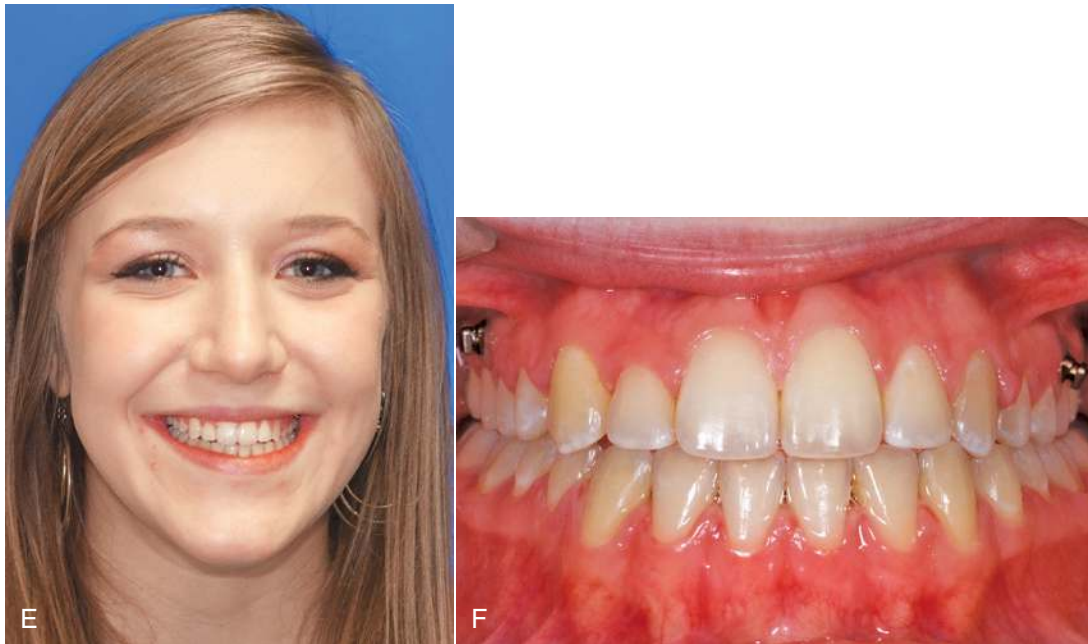
Correction of a severe Class II deep bite malocclusion, with leveling of the maxillary arch by labial tipping of the upper incisors and segmented arch intrusion of the elongated lower incisors, is shown in [Fig. 15.30](#).



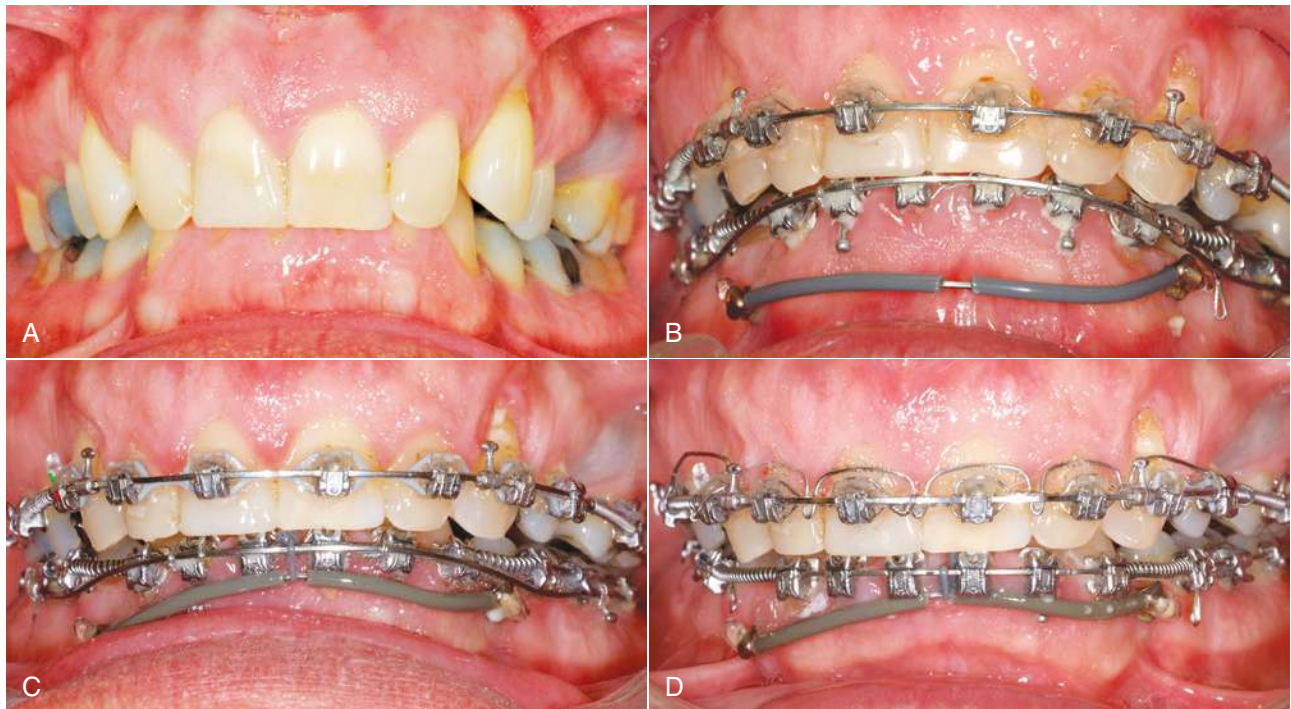
• **Fig. 15.29** (A and B) Prior to treatment, this 15-year-old girl had an unsightly maxillary left canine, anterior open bite, bilateral posterior crossbite, and an anterior crossbite. The treatment plan was to intrude the maxillary posterior teeth with 8-mm long alveolar bone screws bilaterally between the roots of the maxillary first molar and second premolar as anchorage and align the maxillary arch with transverse expansion. (C and D) Progress photos showing corrected alignment and decreased open bite.

*Continued*





• **Fig. 15.29, cont'd** (E and F), Completion of treatment after 7 months of posterior intrusion (24 months total treatment). Note that the bone screws used for intrusion have been left in place so they can be used to control an open bite relapse tendency if needed (this can occur if vertical growth continues). (Courtesy Dr. N. Scheffler.)



• **Fig. 15.30** (A) Extreme anterior deep bite in a 53-year-old man with short anterior face height, super-erupted lower incisors, previously extracted first premolars, and a Class II division 2 pattern of the maxillary incisors. The treatment plan included leveling the mandibular arch by extrusion of the posterior teeth and intrusion of the anteriors, advancement and torquing of the incisors in both arches, and opening spaces for the missing premolars, using a continuous rather than segmented main archwire. (B) The mandibular leveling auxiliary wire, anchored to 6-mm alveolar bone screws bilaterally, augments the leveling force provided by the main archwire. The tubing is to prevent lip and gingival irritation. (C) One-month progress. (D) Bite opening largely achieved after 4 months. Note the auxiliary maxillary torquing arch, which will tip the maxillary incisors anteriorly unless it is tied back posteriorly, allowing control of the amount of torque versus tipping. (Courtesy Dr. N. Scheffler.)

## References

1. Bolender Y, Vernière A, Rapin C, et al. Torsional superelasticity of NiTi archwires. *Angle Orthod.* 2010;80:1100–1109.
2. Alqerban A, Willems G, Bernaerts C, et al. Orthodontic treatment planning for impacted maxillary canines using conventional records versus 3D CBCT. *Eur J Orthod.* 2014;36:698–707.
3. Incerti-Parenti S, Checchi V, Ippolito DR, et al. Periodontal status after surgical-orthodontic treatment of labially impacted canines with different surgical techniques. *Am J Orthod Dentofac Orthop.* 2016;149:463–472.
4. Parkin NA, Milner RS, Deery C, et al. Periodontal health of palatally displaced canines treated with open or closed surgical technique. *Am J Orthod Dentofac Orthop.* 2013;144:176–184.
5. Lau CK, Whang CZ, Bister D. Orthodontic uprighting of severely impacted mandibular second molars. *Am J Orthod Dentofac Orthop.* 2013;143:116–124.
6. Kravitz ND, Yanosky M, Cope JB, et al. Surgical uprighting of lower second molars. *J Clin Orthod.* 2016;50:33–40.
7. Edwards JG. Soft tissue surgery to alleviate orthodontic relapse. *Dent Clin North Am.* 1993;37:205–225.
8. Isaacson RJ, Lindauer SJ, Rubenstein LK. Activating a 2 × 4 appliance. *Angle Orthod.* 1993;63:17–24.
9. Ricketts RW, Bench RW, Gugino CF, et al. *Bioprogressive Therapy*. Denver: Rocky Mountain Orthodontics; 1979.
10. Preston CB, Maggard MB, Lampasso J, et al. Long-term effectiveness of the continuous and the sectional archwire techniques in leveling the curve of Spee. *Am J Orthod Dentofac Orthop.* 2008;133:550–555.

# 16

## Comprehensive Treatment in Adolescence: Space Closure and Class II/Class III Correction

### CHAPTER OUTLINE

#### Space Closure in Incisor Protrusion Problems

- Sliding Versus Loop Mechanics in Space Closure
- Correction of Bimaxillary Protrusion
- Maximum Incisor Retraction (Maximum Anchorage)
- Minimum Incisor Retraction

#### Class II Correction in Adolescents

- Differential Growth in Adolescent Class II Treatment
- Class II Camouflage

#### Class III Camouflage

In Chapter 15 we covered alignment and related problems that would be corrected at or near the beginning of comprehensive treatment and that for the most part would be done with round rather than rectangular archwires. In this chapter, we move forward to treatment that involves bodily repositioning of teeth or root torque that is largely done with rectangular archwires.

### Space Closure in Incisor Protrusion Problems

Excessive protrusion of incisors is a significant orthodontic problem in three conditions:

1. *Bimaxillary dentoalveolar protrusion*, hereafter called just *bimaxillary protrusion* as in most of the orthodontic literature. To the orthodontist, this means that the anterior teeth in both arches are too far forward relative to the basal bone of the maxilla and mandible; to physical anthropologists, the same term describes protrusion of both jaws relative to the cranium.
2. *Class II malocclusion*, which is defined by the molar relationship but characterized by maxillary incisor protrusion creating excessive overjet. Epidemiologic studies have confirmed that the protruding maxillary incisors are the problem for the patient, who is not concerned about the molar relationship (see Chapter 1).
3. *Class III malocclusion*, also defined by the molar relationship but characterized by anterior crossbite and the protruding chin, which are the problems that patients perceive (even if the real problem is maxillary deficiency).

Bimaxillary protrusion is a dental problem in which the teeth are not properly positioned on both the maxilla and mandible. Growth modification for skeletal Class II and Class III problems has already been reviewed, and orthognathic surgery for the most severe of these problems is discussed in Chapter 20. The discussion here is on treatment to correct the malocclusion while creating acceptable dentofacial esthetics—that is, on methods to camouflage jaw discrepancies.

### Sliding Versus Loop Mechanics in Space Closure

In the closure of an extraction space, it is necessary to generate both a force to move the teeth and a root-parallel moment to move them bodily. With a fixed appliance, there are two major ways to do that: by sliding teeth along an archwire (sliding mechanics) or by tying the teeth tightly to archwire segments and moving the segments with a spring between them (closing loop mechanics). The differences are summarized in Table 16.1. Each of the methods has significant advantages and disadvantages. For sliding mechanics, there is significant resistance to sliding in the form of both binding and friction (big disadvantage), but there also is automatic generation of the root-parallel moments at the extraction site (big advantage). For loop mechanics there is no frictional resistance (big advantage), but it is necessary to adjust the loop to generate a root-parallel moment and keep it in proportion with the force to close the space (not necessarily a disadvantage, but extra work and complexity).

Let's explore those differences, starting with a brief review of the mechanical principles outlined in Chapter 9 and some additional clinical recommendations.

#### Sliding Mechanics

For sliding closure of an extraction site, a rectangular archwire is needed to keep the tooth or teeth from rolling facially or lingually while being repositioned (although a small space can be closed on a round wire). The wire on which sliding occurs must have two properties: it must be undersized relative to the bracket and strong enough not to bend significantly when force is applied across the section that spans the extraction site.

The closer the contact between the wire and bracket, the greater the frictional resistance to sliding. Because almost all brackets have a slot size slightly larger than the nominal size and all archwires are slightly smaller than their nominal size, a full-dimension wire in a bracket still has some clearance, and sliding is possible. A 3-mil



**TABLE 16.1** Sliding Versus Loop Mechanics

Method	Sliding teeth on an archwire	Closing loop between segments
Generation of force	Elastic or NiTi spring to single tooth or group of teeth	Activate the loop
Net force desired	100 gm per tooth	150 gm per segment
Resistance to sliding	Approximately 100 gm per tooth	None
Generation of moment	Automatic (bracket width)	Gable bend, approximately 45 degrees

NiTi, Nickel–titanium.

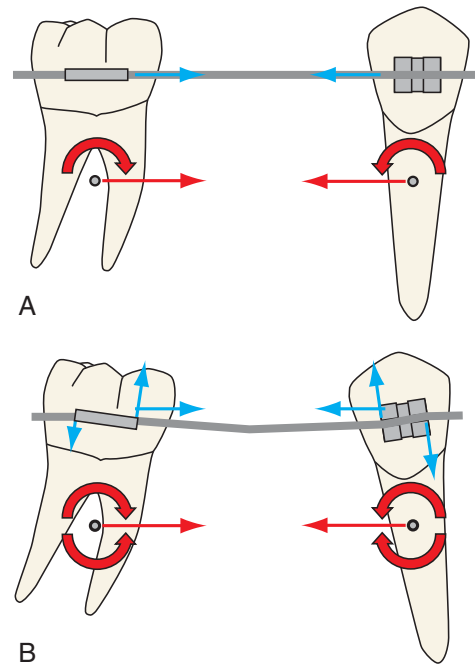
(0.03 inch = 0.5 mm) difference between bracket slot size and wire size is enough to largely eliminate friction, but of course resistance to sliding created by binding on the edges of the slot still is present (see Chapter 9). The usual combination of undersized wires and oversized bracket slots means that a nominal 2-mil clearance usually is adequate for sliding (for instance, 16 × 25 wire in an 18-slot bracket is acceptable, but 19 × 25 wire in a 22-slot is better). A 19 × 25 steel wire has excellent strength and rarely bends during sliding space closure, whereas smaller wires may distort.

To move a tooth bodily along the archwire, both a force to move the tooth and a moment to keep it from tipping are needed. In sliding the moment is generated automatically as the tooth begins to tip and the corners of the bracket contact the archwire. If the wire does not bend in response to the force, the result will be bodily movement; if it bends, tipping will occur (Fig. 16.1). The width of the bracket for sliding is important—wider is better to keep binding forces as low as possible and generate the root-parallel moments—but if brackets are too wide, aligning the teeth is compromised. As noted in Chapter 9, the best compromise is specific brackets for each tooth that are half the width of the tooth.

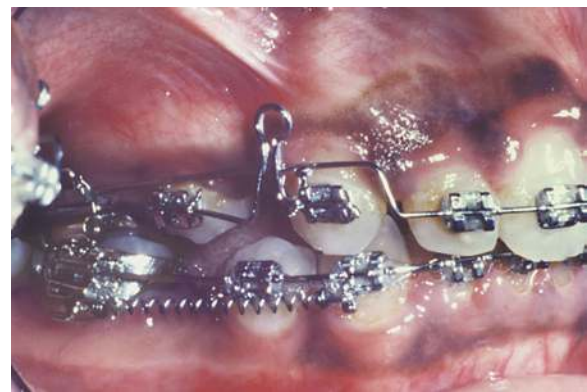
Austenitic nickel–titanium (A-NiTi; superelastic) coil springs are the ideal source of force across the extraction site, because the approximate magnitude of the force is known and changes minimally as the space closes (Fig. 16.2). In contrast, elastomeric chains provide a rapidly decreasing force between appointments, which makes them less ideal for extraction space closure. In the minds of many orthodontists, the easier placement and better oral hygiene than with nickel–titanium (NiTi) springs tend to compensate for this.

An important aspect of any orthodontic tooth movement is that it should fail-safe. This means that the system should either do what it was designed to do or nothing, so that if it fails (or if the patient is lost to follow-up for a time), there are no major side effects. Sliding closure has excellent fail-safe characteristics. If the spring moving the teeth fails or the elastomeric chain breaks, tooth movement simply stops until the patient's next appointment, and in the meantime the heavy wire maintains the teeth where they were.

When maxillary incisors protrude, torque in the incisor brackets often is needed as the teeth are retracted, to keep them from becoming too upright. Sometimes it is forgotten that the reciprocal



• **Fig. 16.1** (A) When a retraction force is placed across an extraction site (blue arrows), the center of resistance of the adjacent teeth feels both a translational force and the moment of a force that initially causes tipping (red arrows). (B) As the teeth tip, the wire engages at opposite edges of the bracket, creating a couple that resists tipping. After a certain level of tipping occurs, the moment of the couple and the moment of the force are in equilibrium and no further tipping occurs. This equilibrium point depends on the retraction force, wire stiffness, interbracket span, and bracket width.

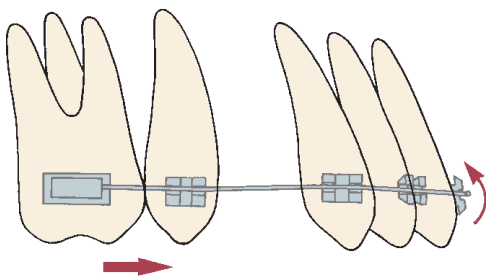


• **Fig. 16.2** In this patient with a 22-slot appliance, sliding space closure in the lower arch is being carried out with a nickel–titanium (NiTi) coil spring while a segmental closing loop is being used in the upper arch for retraction of the canine. Note that the maxillary base archwire bypasses the canine.

for incisor torque is a forward force on the posterior anchorage (Fig. 16.3). In patients with Class II malocclusion it is quite possible to see molars slipping toward a Class II relationship while active torque to the upper incisors is being used. The same effect, of course, could be an advantage for patients with Class III malocclusion who would benefit from forward movement of the upper molars. The moral to the story: not all the moments generated during sliding space closure are so automatic that they require no thought.

### Closing Loop Mechanics

Closing loops also should be made with rectangular wire to prevent the wire from rolling in the bracket slots. The performance of a closing loop, from the perspective of engineering theory, is determined by three major characteristics: its spring properties (i.e., the amount of force it delivers and the way the force changes as the teeth move); the moment it generates, so that root position can be controlled; and its location relative to adjacent brackets (i.e., the extent to which it serves as a symmetric or asymmetric bend in the archwire). Other design principles also can affect clinical treatment. But the frictionless design of closing loops has the potential to reduce anchorage problems and decrease the time



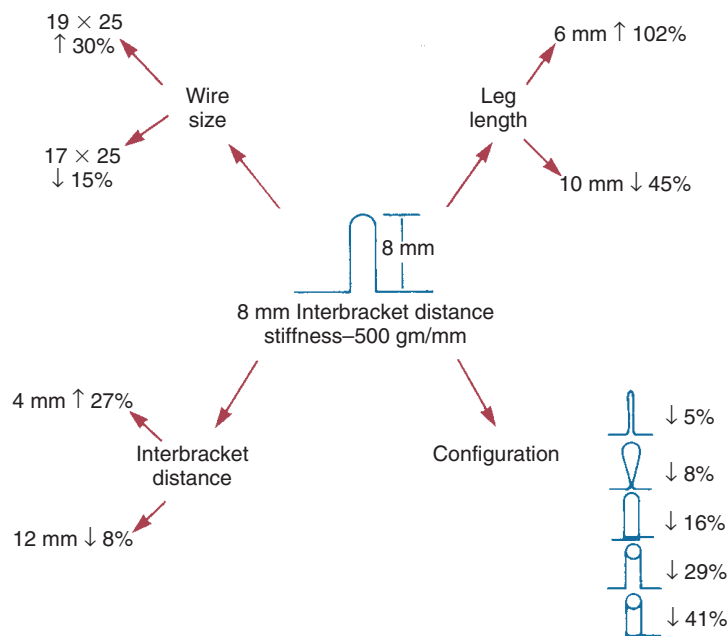
• **Fig. 16.3** Torque forces against the incisors create a crown-forward, as well as a root-backward, tendency. Preventing the incisor crowns from tipping forward tends to pull the posterior teeth forward. Because that would move them toward a Class II relationship, under most circumstances additional force against the molars to prevent this would be indicated—but it would be advantageous if closing space by bringing the posterior teeth forward were desired.

for space closure. Let's examine these performance considerations, starting with spring properties.

**Spring Properties.** The spring properties of a closing loop are determined almost totally by three things: the wire material (at present, either steel or TMA), the size of the wire, and the distance between points of attachment. This distance in turn is largely determined by the amount of wire incorporated into the loop but is affected also by the distance between brackets. Closing loops with equivalent properties can be produced from different types and sizes of wire by increasing the amount of wire incorporated into the loop as the size of the wire increases and vice versa. Wires of greater inherent springiness or smaller cross-sectional area allow the use of simpler loop designs.

Fig. 16.4, from the classic work of Booth,<sup>1</sup> illustrates the effects on the spring characteristics of a steel closing loop from changing wire size, the design of the loop, and the interbracket span. The combination of the last two parameters, of course, determines the amount of wire in the loop. Note that, as expected, changing the size of the wire produces the largest changes in characteristics, but the amount of wire incorporated in the loop is also important. The force characteristics are determined by the center of the apical portion of the loop, regardless of the position of the loop legs.<sup>2</sup> TMA (beta-Ti) wire is a modern alternative to steel for closing loops, which for any size of wire or design of loop would produce about half the force of steel—but the same relative effects of changing these factors would be observed.

**Root-Paralleling Moments.** To close an extraction space while producing bodily tooth movement, a closing loop must generate not only a closing force but also appropriate moments to bring the root apices together at the extraction site. As we have discussed in Chapter 9, for bodily movement the moment of the force used



• **Fig. 16.4** The effect of changing various aspects of a closing loop in an archwire. Note that an 8-mm vertical loop in 19 × 25 wire produces twice as much force as the desired 250-gm per millimeter activation. The major possibilities for producing clinically satisfactory loops are reducing wire size or incorporating additional wire by changing leg length, interbracket distance, and/or loop configuration. (Redrawn from Booth FA. *MS Thesis: Optimum Forces With Orthodontic Loops*. Houston: University of Texas Dental Branch; 1971.)

to move the teeth must be balanced by the moment of a couple. If the center of resistance of the tooth is 10 mm from the bracket, a canine tooth being retracted with a 100-gm force must also receive a 1000 gm-mm moment if it is to move bodily. If the bracket is 1 mm wide, a vertical force of 1000 gm must be produced by the archwire at each side of the bracket.

This requirement to generate a moment limits the amount of wire that can be incorporated to make a closing loop springier because if the loop becomes too flexible, it will be unable to generate the necessary moments even though the retraction force characteristics are satisfactory. Loop design is also affected. Placing some of the wire within the closing loop in a horizontal rather than a vertical direction improves its ability to deliver the moments needed to prevent tipping. Because of this and because a vertically tall loop can impinge on soft tissue, a closing loop that is only 7 to 8 mm tall while incorporating 10 to 12 mm or more of wire (e.g., a delta-, L-, or T-shaped loop) is preferred (Fig. 16.5).

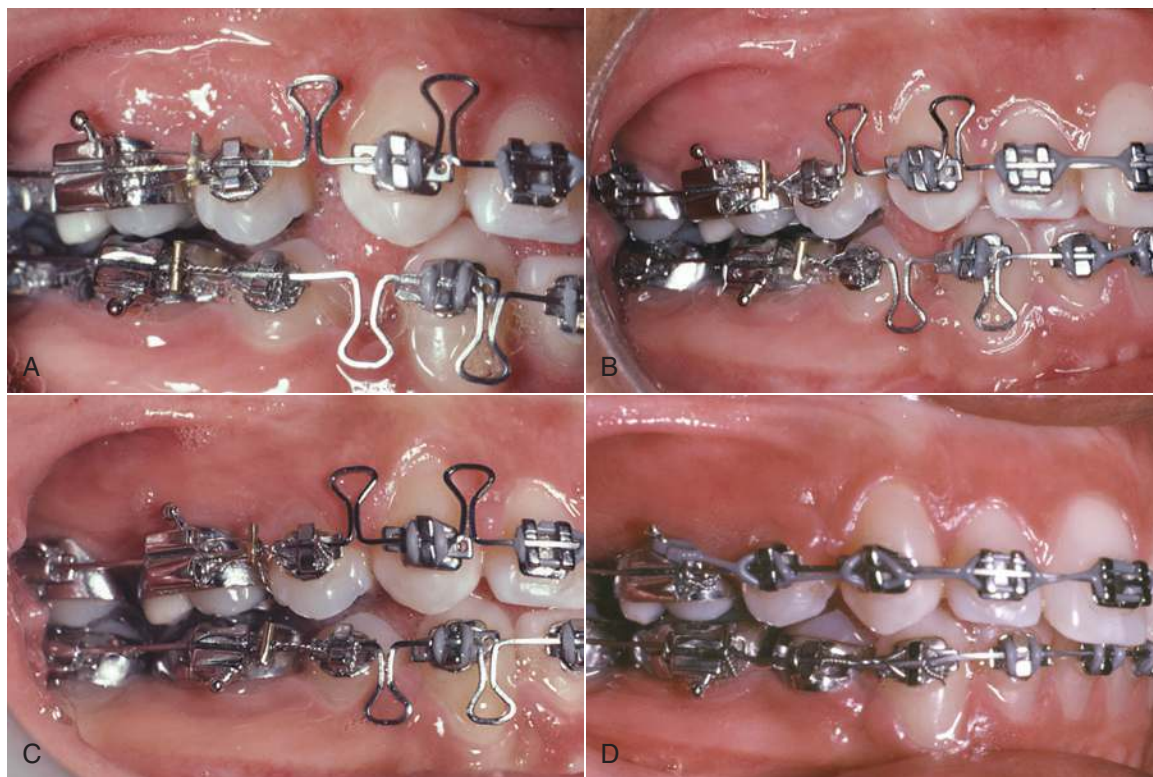
If the legs of a closing loop were parallel before activation, opening the loop would place them at an angle that in itself would generate a moment in the desired direction. Calculations show that unacceptably tall loops would be required to generate appropriate moments in this manner,<sup>3</sup> so additional moments must be generated by gable bends (or their equivalent) before the loop is placed in the mouth (Fig. 16.6).

**Location of the Loop.** A final engineering factor in the performance of a closing loop is its location along the span of wire between adjacent brackets. Because of its gable bends, the closing loop functions as a V-bend in the archwire, and the effect of a V-bend is quite sensitive to its position. Only if it is in the center

of the span does a V-bend produce equal forces and couples on the adjacent teeth (see Figs. 9.40 and 9.41). If it is one-third of the way between adjacent brackets, the tooth closer to the loop will be extruded and will feel a considerable moment to bring the root toward the V-bend, while the tooth farther away will receive an intrusive force but no moment.<sup>3</sup> If the V-bend or loop is closer to one bracket than one-third of the distance, the more distant tooth will not be intruded but will receive a moment to move the root away from the V-bend (which almost never is desirable).

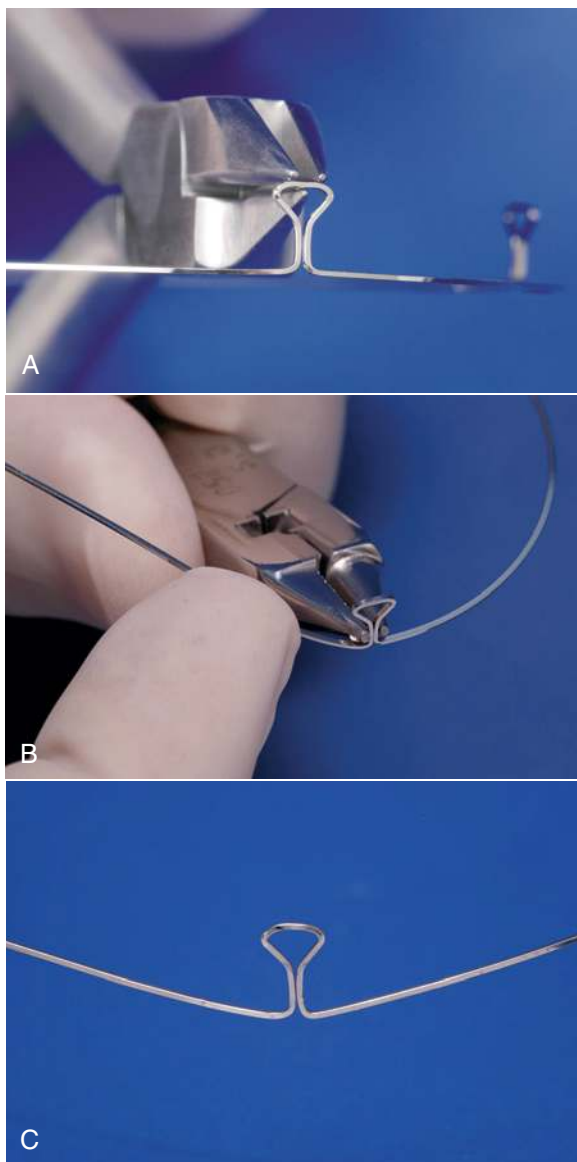
For routine use with fail-safe closing loops (described later), the preferred location for a closing loop is at the spot that will be the center of the embrasure when the space is closed (Fig. 16.7). This means that in a first premolar extraction situation, the closing loop should be placed about 5 mm distal to the center of the canine tooth. The effect is to place the loop initially at the one-third position relative to the canine. The moment on the premolar increases as space closure proceeds. This is not ideal for maximum anchorage but is unavoidable with a loop in a continuous archwire.

**Additional Design Principles.** As it was in sliding and other types of tooth movement, an important principle in closing loop design is that the loop should fail-safe. This means that, although a reasonable range of action is desired from each activation, tooth movement should stop after a prescribed range of movement. Too long a range of action with too much flexibility could produce disastrous effects if a distorted spring were combined with a series of broken appointments. The ideal loop design therefore would deliver a continuous, controlled force designed to produce tooth movement at a rate of approximately 1 mm per month but would not include more than 2 mm of range before it locked up. That



• **Fig. 16.5** Space closure with preformed closing loops in the 18-slot appliance. (A) Use of 16 × 22 closing loops at initial activation, after the completion of stage 1 alignment and leveling. Note the location of the closing loops and the soldered tiebacks for activation. (B) Three months later. (C) Spaces closed at 4 months. (D) Use of 17 × 25 beta-titanium (TMA) wire to begin the finishing phase of treatment.





• **Fig. 16.6** Adjustment of the preformed closing loop before placing it in the mouth. (A) Three-prong pliers should be used to bring the vertical legs of a closing loop together if they are separated. The legs should touch lightly before the loop is activated by opening it. (B) Gable bends to create the root-parallel moment are placed by bending the wire at the base of the loop. (C) Appropriate gable for a 16 × 22 closing loop (40 to 45 degrees total, half that on each side).

would stop the movement if the patient missed a second consecutive monthly appointment. With preformed delta-shaped closing loops, it is important to adjust the loop so that the vertical legs are in contact before the loop is used (see Fig. 16.6A), in order to both be able to know how much it has been activated and be sure that the legs will come back into contact to create a rigid fail-safe wire that stops further movement.

It also is important that the design be as simple as possible because more complex configurations are less comfortable for patients, more difficult to fabricate clinically, and more prone to breakage or distortion. An elegant solution to the design of a closing loop that would provide optimum and nearly constant moment-to-force ratios at variable activations was offered by Siatkowski in

his Opus loop (Fig. 16.8).<sup>4</sup> Engineering analysis, as the Opus loop demonstrates very nicely, shows that a relatively complex design is required to produce the best control of moment–force ratios. The possibilities of clinical problems from increased complexity always must be balanced against the potentially greater efficiency of the more complex design. The Opus loop has not been widely adopted because of concerns about its complexity and sturdiness. Clinical experience suggests that the average adolescent orthodontic patient can—and probably will—destroy almost any orthodontic device that is not remarkably resistant to being distorted.

A third design factor relates to whether a loop is activated by opening or closing. All else being equal, a loop is more effective when it is closed rather than opened during its activation. On the other hand, a loop designed to be opened can be made so that when it closes completely, the vertical legs come into contact, effectively preventing further movement and producing the desired fail-safe effect. A loop activated by closing, in contrast, must have its vertical legs overlap. This creates a transverse step, and the archwire does not develop the same rigidity when it is deactivated. The design with opening of the loop to activate it is preferred because its fail-safe property is more desirable than the better spring quality of closing the loop.

Now, let's apply what we have learned to the correction of the bimaxillary protrusion and Class II and III camouflage.

### Correction of Bimaxillary Protrusion

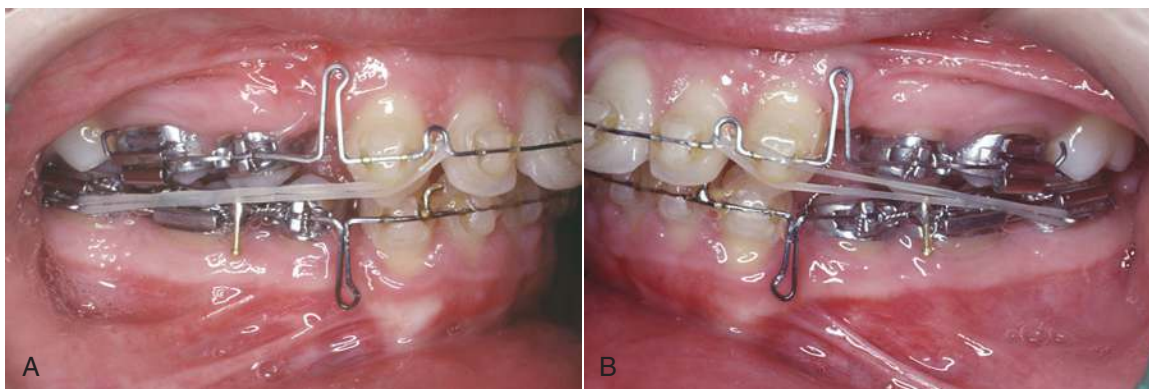
Bimaxillary protrusion requires retraction of the protruding incisors. With only a few exceptions, it is treated by extraction of first premolars in both dental arches and controlled repositioning of the anterior segment of the arches into the extraction site. The objective is optimal improvement in dentofacial appearance and lip function. Clinical management differs depending on how much incisor retraction is needed. Orthodontists traditionally have spoken about this in terms of how much anchorage would be needed to produce the desired amount of retraction, and for the most part we will use the anchorage terminology here, although sometimes it is more direct to focus on just the desired tooth movement.

Let's begin with the usual situation, moderate posterior anchorage to retract the incisors slightly more than the posterior teeth would move forward and allow some tipping to upright the incisors as they are retracted. Then we can discuss how moderate anchorage could be upgraded to maximum anchorage, which would be needed for maximum retraction of the protruding incisors and/or active torque to move the incisor roots further than the crowns. Finally, we will close the discussion with minimum posterior anchorage, for which the goal would be less incisor retraction and more forward movement of the posterior segments.

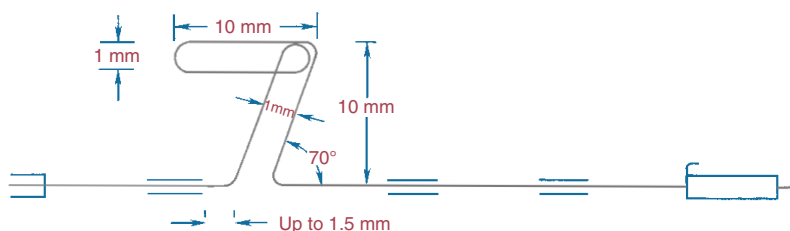
#### Moderate Anchorage Situations

Most patients with bimaxillary protrusion fall into the moderate anchorage category, meaning that after alignment of the incisors to correct crowding has been completed, it is desired to close the remainder of the premolar extraction space with a 50:50 or 60:40 ratio of anterior retraction to posterior protraction.

**Space Closure With 22-Slot Edgewise.** In general, space closure in moderate anchorage situations often is done in two steps to better control posterior anchorage: first retracting the canines, sliding them along an 18 × 25 or 19 × 25 steel archwire with a NiTi spring or elastic that delivers about 200 gm of force, and second, retracting the four incisors (Fig. 16.9). For the canine retraction, a posterior stop on the archwire, usually in front of the



• **Fig. 16.7** (A and B) Closing loops in  $16 \times 22$  wire of fail-safe design and 8-mm height, used with Class II elastics in this patient. Note that the maxillary loop has been activated by pulling the wire through the molar tube and bending it up. In the mandibular arch, the loop is not active at this time, and the approximation of the legs to create a rigid archwire is apparent. The lower archwire has a tieback mesial to the first molar so that this loop can be activated by tying a ligature from the posterior teeth to the wire rather than by bending over the end of the wire distal to the molar tube.



• **Fig. 16.8** The Opus closing loop designed by Siatkowski offers excellent control of forces and moments so that space can be closed under good control. The loop can be fabricated from  $16 \times 22$  or  $18 \times 25$  steel wire or from  $17 \times 25$  TMA wire. It is activated by tightening it distally behind the molar tube and can be adjusted to produce maximal, moderate, or minimal incisor retraction, but like all closing mechanisms with a long range of action, it must be monitored carefully. (Redrawn from Siatkowski RE. *Am J Orthod Dentofac Orthop.* 1997;112:393–402, 484–495.)

first molar tube, is needed. This stop has the effect of incorporating all the teeth except the canine into the anchorage unit. A-NiTi coil springs are preferred because they produce an almost ideal light constant force and there is no danger that the teeth will tip excessively.

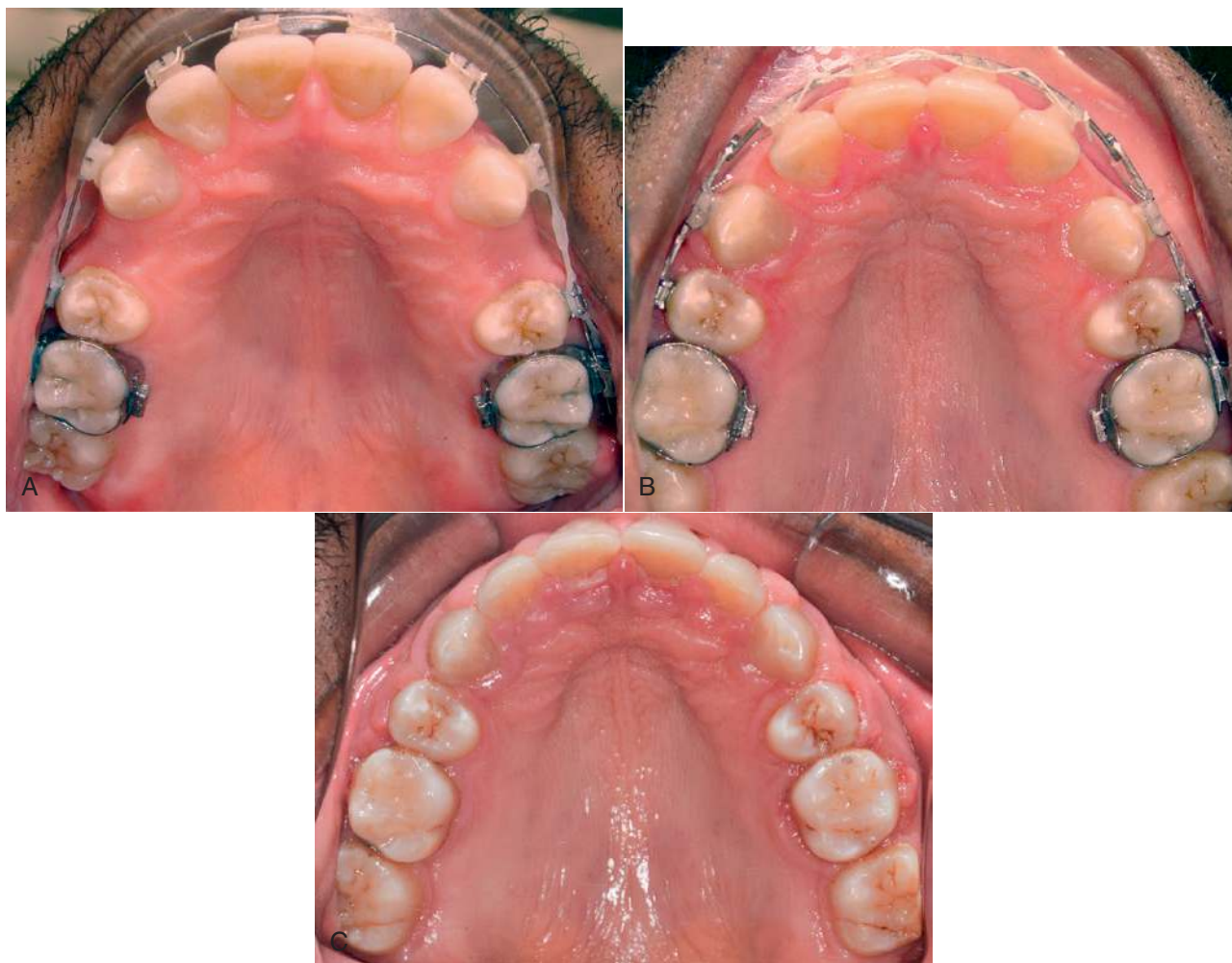In the lower arch the second stage can be continued, sliding along an  $18 \times 25$  wire or a closing loop, often a T-loop in  $18 \times 25$  steel; in the upper arch a closing loop is preferred when greater torque of the incisors is needed, as it often is (see Fig. 16.2). This two-stage closure will produce an approximately 60:40 closure of the extraction spaces, varying somewhat depending on whether second molars are included in posterior anchorage and the incisor torque requirement. En masse sliding leads to 50:50 closure at best, even with bi-dimensional wires that are smaller posteriorly in an effort to avoid friction (because binding still is present).

Although the two-step procedure is predictable and has excellent fail-safe characteristics, which explains why it remains commonly used, it takes longer to close space in two steps than one. One-step closure with the 22-slot appliance has been available with a segmented arch technique based on incorporating the anterior teeth into a single segment, and both the right and left posterior teeth also into a single segment, with the two sides connected by a stabilizing lingual arch. A retraction spring (Fig. 16.10) is used to connect these stable bases, and the activation of the spring is varied to


produce the desired pattern of space closure. These springs are very effective, and with careful initial activation, an impressive range of movement can be produced before reactivation is necessary.<sup>5</sup> The greatest disadvantage of this technique is not its increased complexity but that it does not failsafe. Without a rigid connection between the anterior and posterior segments, there is nothing to maintain arch form and proper vertical relationships if a retraction spring is distorted or activated incorrectly.

Now that preformed closing loops are available in  $19 \times 25$  TMA, one-step closure with a fail-safe design also can be done with 22-slot brackets as it often is with the 18-slot appliance (see later). This is faster than the older two-stage closure. It is not as fast as the segmented arch technique, but it is safer and less complex.

**Space Closure With 18-Slot Edgewise.** In contrast to the 22-slot edgewise appliance, the 18-slot appliance fits well with the design principles for closing loops discussed earlier. An excellent closing loop for 18-slot edgewise is a delta-shaped loop in  $16 \times 22$  steel wire that is activated by opening (see Fig. 16.5). The wire slides through the brackets and tubes only when it is being activated. After that, as the closing loop returns to its original configuration, the teeth move with the archwire, not along it, so there is no resistance to sliding. It allows accurate activation, provides the appropriate root-parallel moment via gable bends, and fails safely when the loop closes completely.



• **Fig. 16.9** Two-step space closure after extraction of maxillary first premolars. (A) Beginning closure with elastic chain being used to slide the canines distally along the archwire. (B) Canines retracted and closing loops in the archwire distal to the lateral incisors being used to retract the anterior segment. (C) Treatment complete with premolar spaces closed and torque of incisors properly controlled.



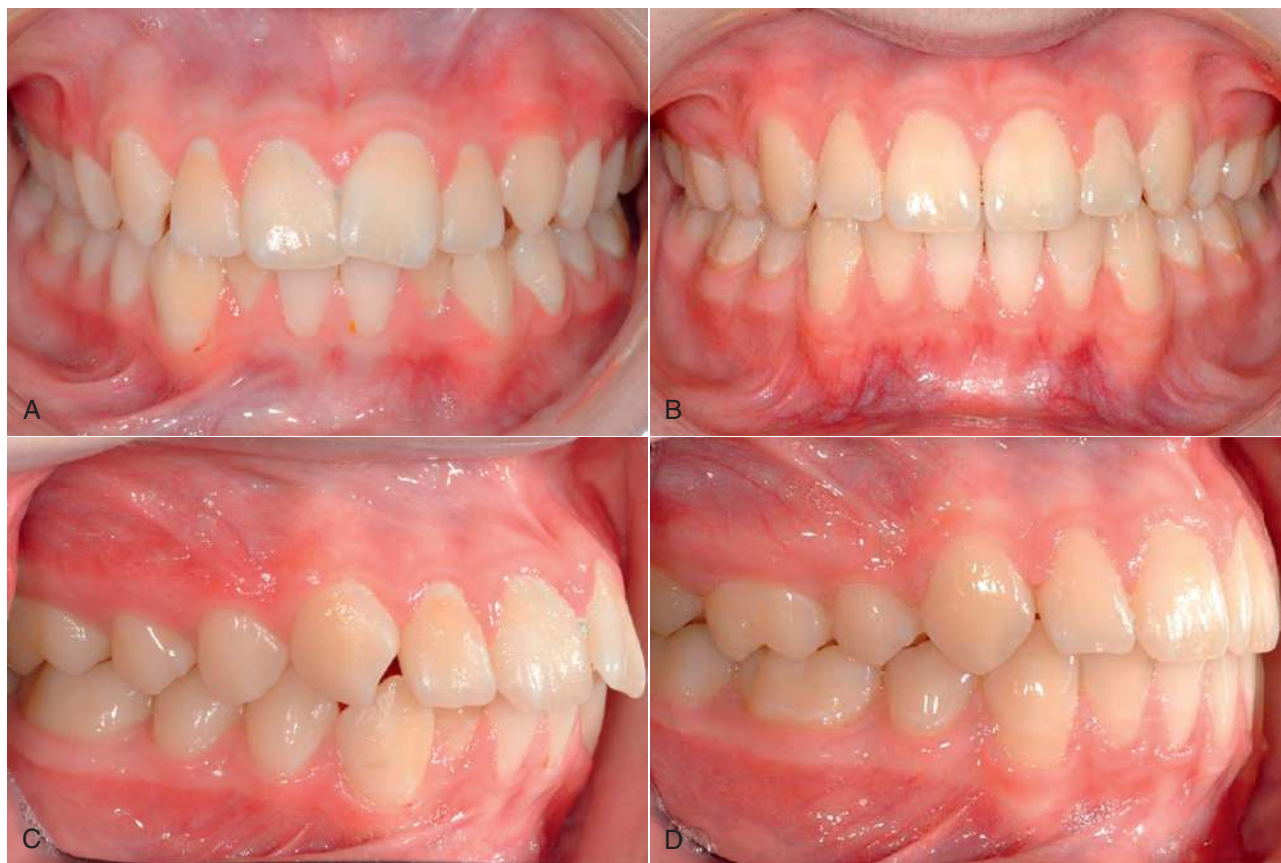• **Fig. 16.10** Composite retraction spring designed by Burstone for use with the segmented arch technique, consisting of 18-mil beta-titanium (beta-Ti) wire (the loop) welded to 17 × 25 beta-Ti. This spring can be used for either en masse retraction of incisors or canine retraction.

There are two ways to hold the archwire in its activated position. The simplest is by bending the end of the archwire gingivally behind the last molar tube. The alternative is to place an attachment—usually a soldered tieback (see Fig. 16.7) on the posterior part of the archwire so that a ligature can be used to tie

the wire in its activated position. With the 16 × 22 loop, usually it is necessary to remove the archwire and reactivate the gable bends after 3 to 4 mm of space closure, but a quick reactivation is all that is needed at most appointments during space closure. If it is anticipated that a closing loop archwire will not have to be removed for adjustment (i.e., the distance to be closed is 4 mm or less), bending the posterior end of the wire is satisfactory. It can be quite difficult to remove an archwire that has been activated by bending over the end, however, and it saves time in the long run to use tiebacks for closing loop archwires that will have to be removed and readjusted.

A reasonably typical correction of moderate bimaxillary protrusion is shown in Figs. 16.11 and 16.12. The improved facial appearance is apparent. As we have noted, Edward Angle was wrong in saying that facial appearance is always best with arch expansion and that extraction is never needed—and that is equally incorrect when it is said now. For a patient with bimaxillary protrusion, it is important at the treatment planning stage to establish the optimum position of the incisors—that is, how much incisor retraction is needed—and then structure the orthodontic mechanics to produce the desired outcome.





• **Fig. 16.11** Treatment of bimaxillary protrusion with four-premolar extraction. (A and C) Before treatment with mild crowding and incisor protrusion. (B and D) After treatment with crowding resolved and proper retraction of incisors to create improved dental esthetics. (Courtesy Dr. T. Shaughnessy.)

### Maximum Incisor Retraction (Maximum Anchorage)

The same basic approach is needed with any appliance when maximum anchorage is needed: increased reinforcement of posterior anchorage and decreased strain on that anchorage. A sequence of steps to do that, along with space closure as outlined earlier, would be as follows.

#### 1. Reinforcement With Stabilizing Lingual Arches

Stabilizing lingual arches must be rigid and should be made from 36-mil or 32 × 32 steel wire. These can be soldered to the molar bands, but it is convenient to be able to remove them, and Burstone's designs (see [Chapter 10](#)) are preferred. The resulting increase in posterior anchorage, although modest, will change the ratio of anterior retraction to posterior protraction to approximately 2:1.

It is important for a lower stabilizing lingual arch to lie behind and below the lower incisors so that it does not interfere with their retraction. If 36-mil round wire is used, the lower lingual arch is more conveniently inserted from the distal than from the mesial of the molar tube. The maxillary stabilizing lingual arch is a straight transpalatal design. Because maximum rigidity is desired for anchorage reinforcement, an expansion loop in the palatal section of this wire is not recommended unless a specific indication exists for including it.

Lingual arches for anchorage control should be removed after space closure is complete. Their presence during the

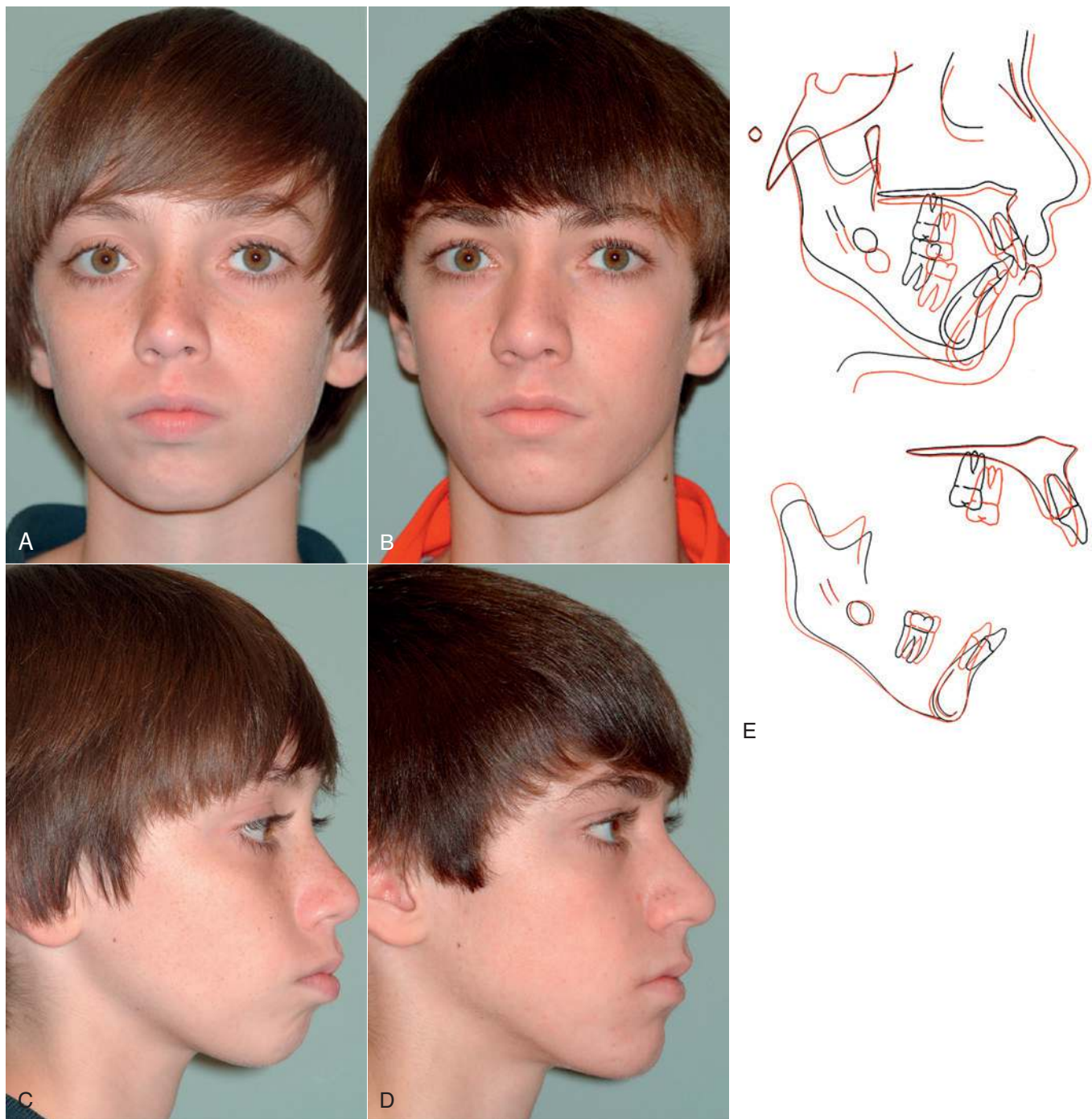
finishing stage of treatment, after extraction spaces have been closed, is not helpful and may interfere with final settling of the occlusion.

#### 2. Reinforcement With Headgear and Interarch Elastics

Extraoral force against the maxillary posterior segments is an obvious and direct method for anchorage reinforcement. It is possible to place extraoral force directly against the mandibular posterior segments, but it is more practical to use Class III elastics to transfer the extraoral force from the upper to the lower arch. Depending on how well the patient cooperates, additional improvement of retraction, perhaps to a 3:1 or 4:1 ratio, can be achieved.

#### 3. Two-Step Frictionless Retraction

Individualized retraction of the canines with auxiliary springs before a second stage of incisor retraction with closing loops is an attractive method for reducing the strain on posterior anchorage and is a readily available with a modern appliance. For use of the retraction spring, an auxiliary tube on the first molars is needed. An auxiliary tube on the canine is unnecessary because the retraction spring can fit directly into the canine bracket. The PG spring designed by Gjessing is an efficient current design ([Fig. 16.13](#))<sup>6</sup> but is somewhat complex to fabricate and activate. After the canine retraction, closing loops, either in a continuous archwire or with a segmented arch approach, are then used for the second stage of retraction of the incisors.

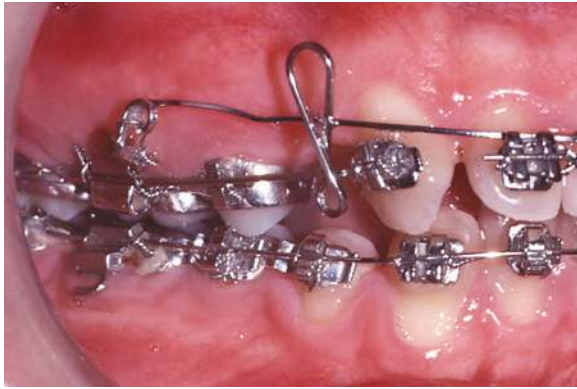

• **Fig. 16.12** Facial images and cephalometric tracings of the bimaxillary protrusion, premolar extraction case shown in Fig. 16.11. (A and C) before treatment. Note lip protrusion and the muscle strain needed for lip closure. (B and D) After treatment the lip posture is relaxed, facial convexity is reduced, and overall facial balance is improved. (E) Cephalometric superimpositions showing mandibular growth to improve chin projection as well as uprighing of upper and lower incisors. Proper anchorage management by the orthodontist during premolar space closure resulted in the desired combination of molar forward movement and incisor retraction to achieve the desired final tooth position. (Courtesy Dr. T. Shaughnessy.)

Frictionless canine retraction with springs of this type presents two problems. The first is that it is difficult to control the position of the canine in all three planes of space as it is retracted. If the canine is pulled distally from an attachment on its buccal surface, the point of attachment is not only some distance occlusal but

also buccal to the center of resistance. This means that without appropriate counterbalancing moments, the tooth will tip distally and rotate mesiobuccally. Both a root-parallel moment and an antirotation moment must be obtained by placing two different gable bends in the same spring. Control of the vertical position





• **Fig. 16.13** For canine retraction, the Gjessing retraction spring offers excellent control of forces and moments and probably is the most effective current design of a spring for this purpose. In this patient, canine retraction is being done simultaneously with intrusion of the incisor segment.

of the canine, particularly after the gable bends in two planes of space have been placed, can be a significant problem.

Second, much more than with en masse retraction using segmented mechanics, segmental retraction of canines is not failsafe. The canine is free to move in three-dimensional space, and there are no stops to prevent excessive movement in the wrong direction if a spring is improperly adjusted or becomes distorted. Loss of vertical control is particularly likely. A missed appointment and a distorted spring can lead to the development of a considerable problem, and patients must be monitored carefully.

#### 4. Retraction With Skeletal Anchorage

Skeletal anchorage for retraction of protruding incisors is the only way to close extraction spaces totally by retracting the incisor–canine arch segment. The options are bone screws in the palate stabilizing a transpalatal arch to provide indirect anchorage to the posterior arch segment (see Fig. 10.50), or bone screws in the dental alveolus between the second premolar and first molar (see Fig. 10.49). Directly attaching a spring to the alveolar screw generates an upward and backward direction of pull; stabilizing the posterior teeth with palatal screws gives a direction of force parallel to the occlusal plane.

Until recently, it was thought that skeletal anchorage was equally effective with individual bone screws in the alveolar process or linked bone screws in the palate, but this is no longer correct. There are two lines of evidence leading to that conclusion. First, two randomized clinical trials of methods for anchorage control in maxillary incisor retraction concluded that, surprisingly, alveolar bone screws were no more effective in maintaining the posterior anchorage than a Nance-type lingual arch with an acrylic pad behind the maxillary incisors (see Fig. 11.55E).<sup>7,8</sup> It was not so much that the Nance appliance was effective as that it and the alveolar bone screws were equally ineffective. In contrast, palatal anchorage has now been shown to be quite effective in preventing mesial movement of the posterior teeth during retraction of incisors into premolar extraction sites,<sup>9</sup> especially when bilateral screws are placed in the anterior palate.<sup>10</sup> For maximum retraction of maxillary incisors, therefore, indirect anchorage from screws in the anterior palate (see Fig. 19.43) now is preferred.

The major advantage of skeletal anchorage in retraction of the anterior segment is that it offers vertical as well as anteroposterior control of the teeth.<sup>11</sup> To create the desired display of the incisors,

they may need to be intruded as well as moved lingually, and although this is possible without bone screws or miniplates (see Fig. 9.48), it is complex and potentially difficult to manage.

There are three options for skeletal anchorage for maximum retraction of mandibular incisors: bone screws in the alveolar process, bone screws in the front of the ramus, or anchors placed vertically into the buccal projection of the mandibular body below the molars (see Fig. 10.52). Although there has not been a study to document that an anchor in the mandibular body is more effective than a mandibular alveolar bone screw, it seems likely that for incisor retraction, screws in mandibular alveolar bone would perform similarly to those in the maxilla and that an attachment in the mandibular body would be equivalent to palatal anchorage for maxillary retraction. Placing such an anchor is easier and less invasive than placing a long screw into the ramus.

The major disadvantage of skeletal anchorage for maximum incisor retraction in either arch is that it makes over-retraction of the incisor segments possible. The treatment objective is to improve the patient's dentofacial appearance and decrease social problems related to it. Retracting the anterior teeth too much makes the patient look worse, not better, as lip support is decreased and the nasolabial fold is accentuated. This is more of a problem in Class II or Class III camouflage than correction of bimaxillary protrusion, and is discussed further later.

Other applications of skeletal anchorage, including distal movement of the entire dental arch to reduce incisor protrusion, are presented in some detail in Chapter 19.

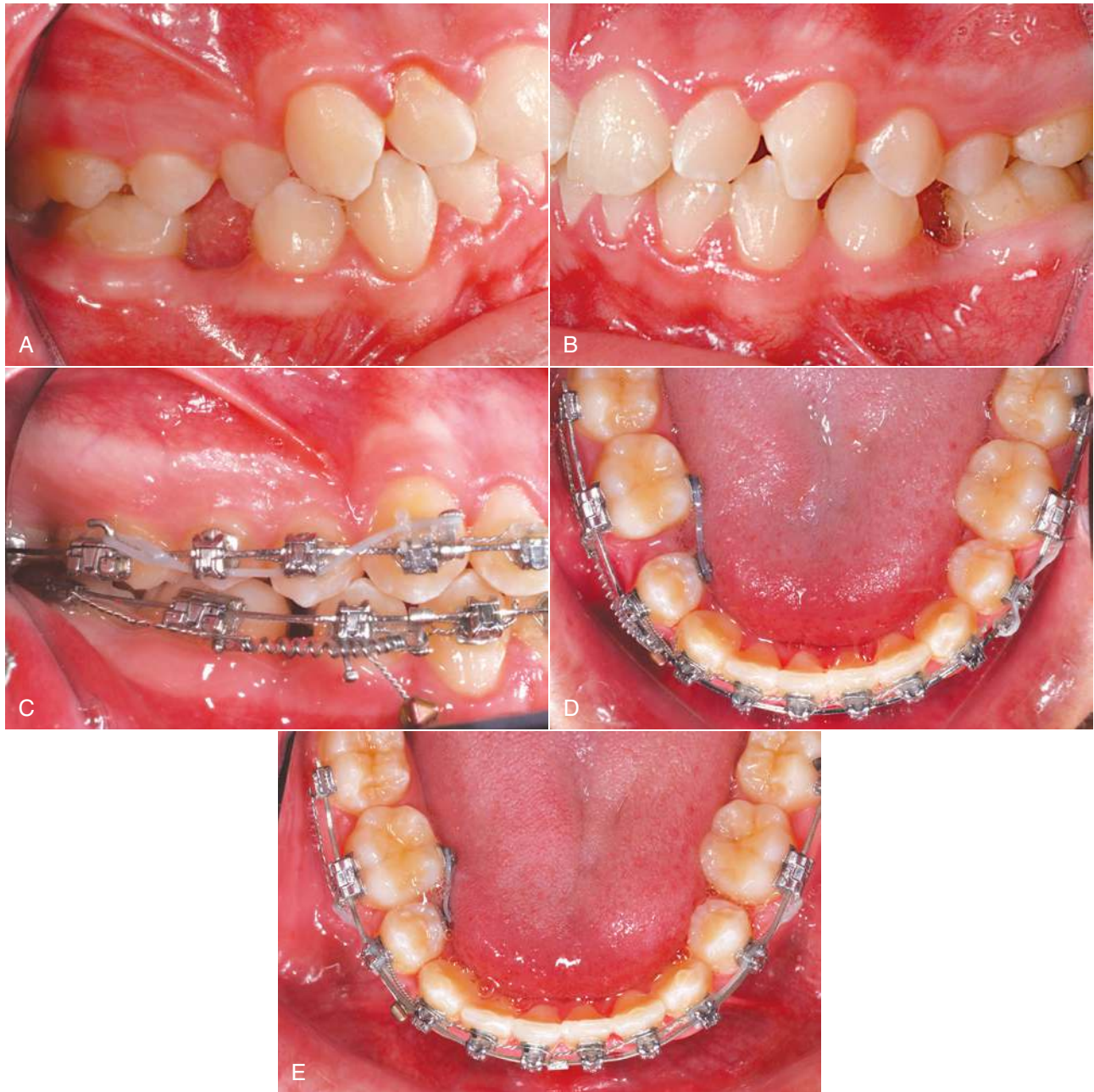#### Minimum Incisor Retraction

Why would there be a need to close extraction spaces if retracting protruding incisors was not a goal of treatment? That could be the case if there were unanticipated residual spaces after alignment of crowded teeth, when space closure was needed after extraction of hopelessly carious teeth, or when some teeth (most likely mandibular second premolars) were congenitally missing (Fig. 16.14). As with any problem requiring anchorage control, the approaches to reducing the amount of incisor retraction when closing extraction spaces involve reinforcement of anchorage (the anterior teeth in this situation) and reduction of strain on that anchorage. An obvious strategy, implemented at the treatment planning stage, is to incorporate as many teeth in the anterior anchor unit as possible. All other factors being equal, the amount of incisor retraction will be less the further posteriorly in the arch an extraction space is located (see Chapter 7, Table 7.1).

A second possibility for reinforcing incisor anchorage is to place active lingual root torque in the incisor section of the archwires, maintaining a more mesial position of the incisor crowns at the expense of somewhat greater retraction of the root apices (see Fig. 16.3). As the figure shows, what is a disadvantage when incisors are being retracted becomes an advantage when, for all practical purposes, the incisors are the anchorage.

A third possibility for maximizing forward movement of posterior teeth is to break down the posterior anchorage, moving the posterior teeth forward one tooth at a time. To close a second premolar extraction site (or the space where a second premolar was congenitally missing), it may be desired to stabilize the eight anterior teeth and to bring the first molars forward independently, creating a space between them and the second molars before bringing the second molars anteriorly. This strategy can readily be combined with increased torque of the anterior teeth to minimize retraction.



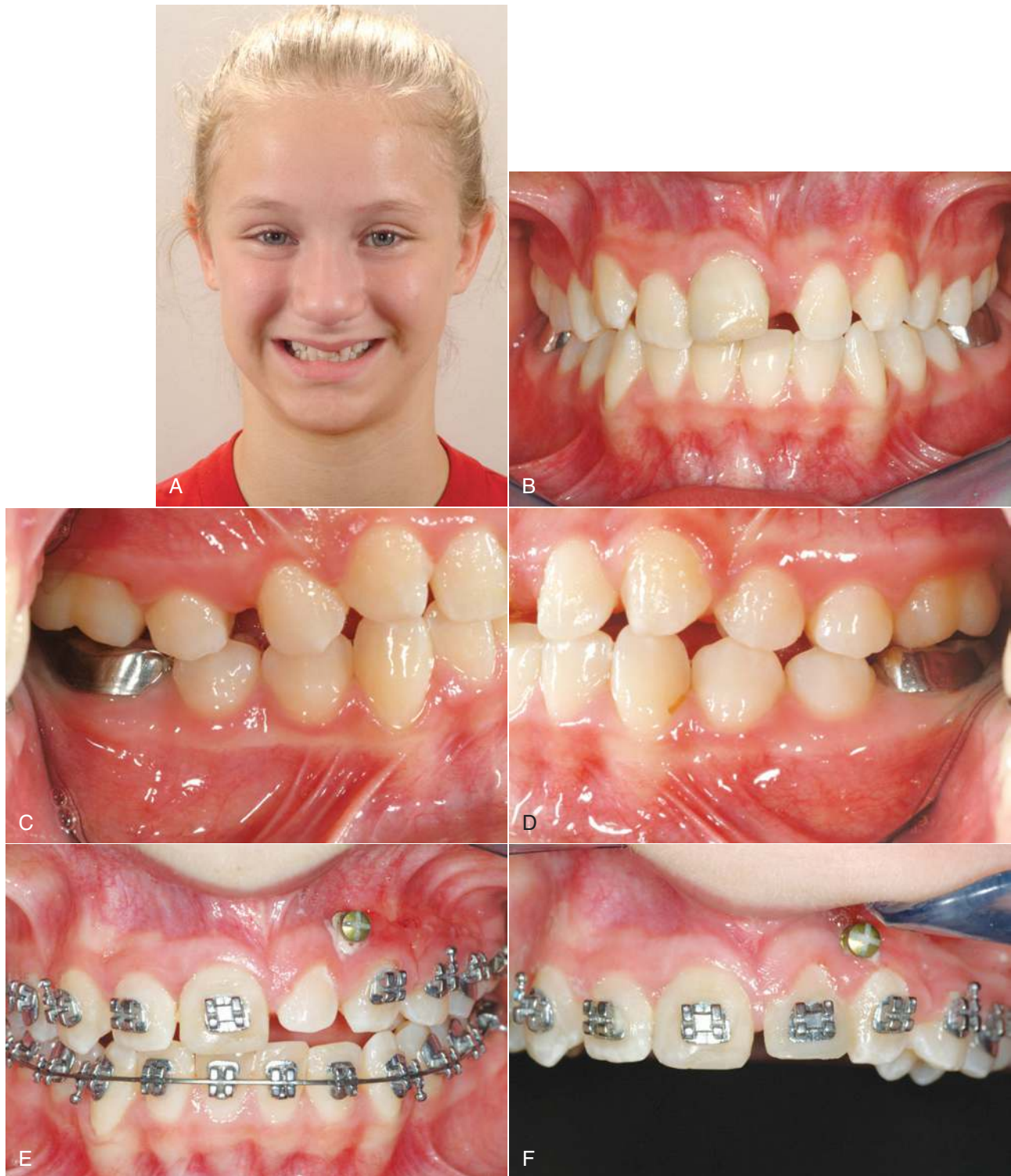


• **Fig. 16.14** (A and B) For this patient, a goal of treatment was closure of the space where mandibular second premolars were missing by bringing the mandibular molars forward, with more movement needed on the right side. (C) A bone screw was placed in the dentoalveolar process between the right central and lateral incisors, and those teeth were stabilized by tying them to the archwire (indirect anchorage), and then the spaces were closed with sliding mechanics (D and E). (Courtesy Dr. N. Scheffler.)

Skeletal anchorage, created by placing bone screws in either arch in the canine region, is the easiest and most effective way to close an extraction space by bringing posterior teeth forward (see Fig. 16.14). This is particularly advantageous when more forward movement is needed on one side than the other (Fig. 16.15). In both minimum and maximum retraction, temporary anchorage devices (TADs) now make it much easier to handle what previously were very difficult situations.

## Class II Correction in Adolescents

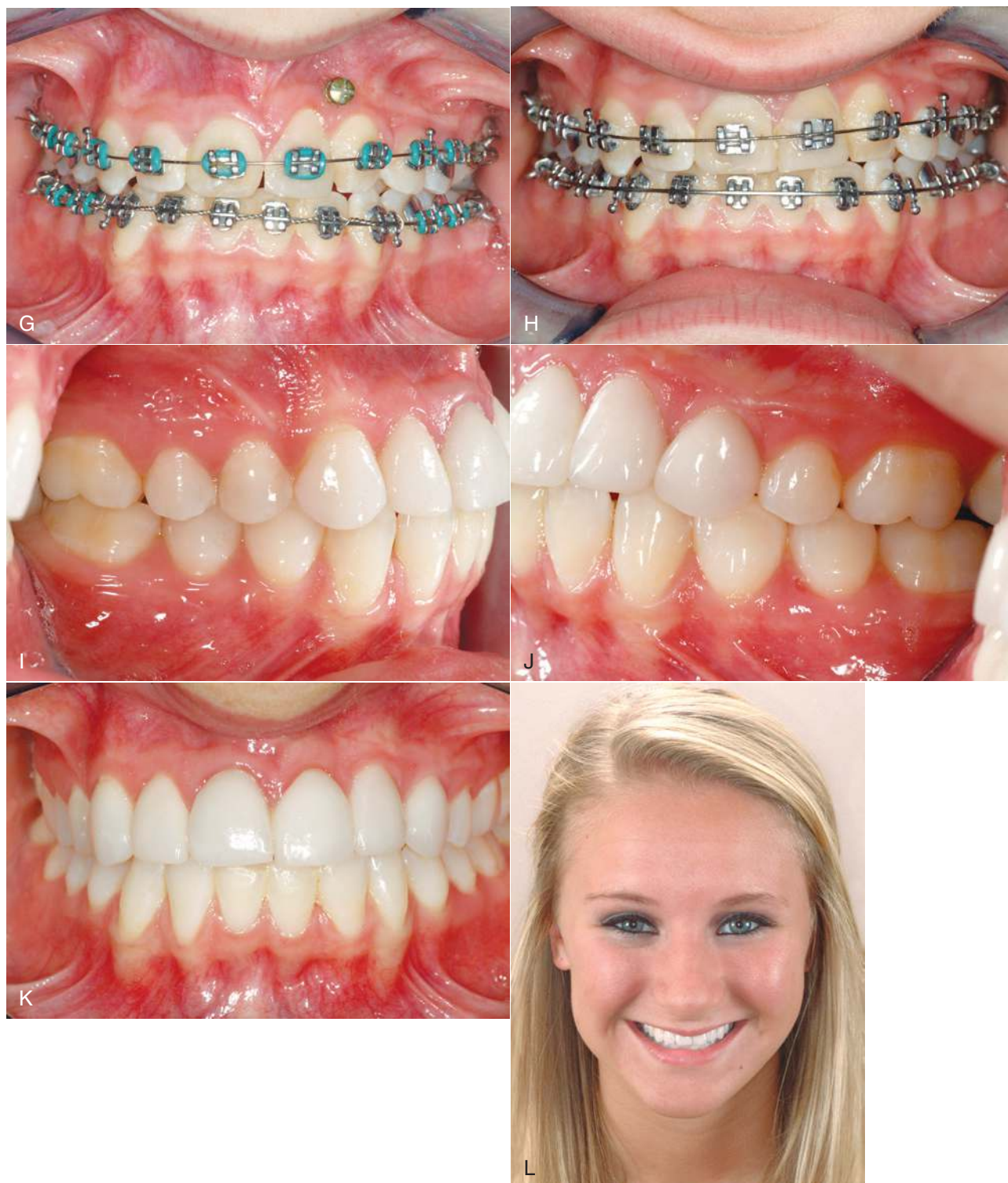
There are two major possibilities for correction of Class II malocclusion in adolescents: (1) differential growth of the jaws, guided by extraoral force or a functional appliance or (2) differential anteroposterior movement of the upper and lower teeth, with or without differential closure of extraction spaces. These approaches are not mutually exclusive, but even when growth modification is successful, it typically provides only a partial correction of a



• **Fig. 16.15** (A) This girl lost her maxillary left central incisor as a result of trauma at age 8, and by the time she was seen by the orthodontist at age 11, the left lateral incisor had moved mesially into the central incisor space. (B to D) Intraoral views at age 11. The treatment plan was to use the lateral incisor as a replacement for the central incisor, intruding it to allow leveling of the gingival margin with the right central, then build it up so that it would be the correct size during the finishing orthodontics, and ultimately use a laminate veneer as part of the final restoration. The canine would be recontoured to make it an acceptable lateral incisor. (E) A bone screw was placed between the lateral incisor and canine, above the root apices, as anchorage to bring the left posterior teeth anteriorly. (F) When the lateral was in the central spot and a Class II molar relationship had been obtained on the left side, a temporary buildup was done to bring the lateral incisor close to the width desired at the end of treatment, the canine was recontoured to serve as a lateral incisor (see Fig. 7.14), and brackets were placed to reposition these teeth.

*Continued*





• **Fig. 16.15, cont'd** (G) Progress in alignment, with the bone screw still in place. At that point, a goal of treatment was to bring the gingival margins to approximately the correct levels for a central and lateral incisor, which required elongating the lateral and then shortening the crown, and then a diode laser was used to refine the gingival contours. (H) Toward the end of treatment, after the gingival recontouring. (I to K), Intraoral views at age 13, after completion of orthodontics and placement of a veneer on the left lateral, and (L) the facial view at that time. She was very pleased with the outcome, but a better smile arc could have been obtained by making the veneer on the lateral slightly longer and slightly elongating the right central (see section on micro-esthetics in [Chapter 7](#)).



full-cusp Class II or Class III malocclusion. Some tooth movement almost always is needed to complete the correction of the molar relationship.

### Differential Growth in Adolescent Class II Treatment

The use of extraoral force or functional appliances to influence jaw growth has been discussed in some detail in [Chapter 14](#). The point was made there that Class II growth modification is most effective during the adolescent growth spurt, and that for most patients a preliminary period of preadolescent treatment with headgear or a removable functional appliance is not more effective and less efficient than just waiting for the growth spurt.

Does that mean that beginning Class II treatment should always wait until the early permanent dentition? Often, but not always. The different timing of skeletal growth in males and females must be kept in mind when this approach is used. During adolescence, the mandible tends to grow forward more than the maxilla, providing an opportunity to improve a skeletal Class II jaw relationship. Girls mature considerably earlier than boys and are often beyond the peak of the adolescent growth spurt before the full permanent dentition is available and comprehensive orthodontic treatment can begin. Boys, who mature more slowly and have a more prolonged period of adolescent growth, are much more likely to have a clinically useful amount of anteroposterior growth during the early permanent dentition period.

When either extraoral force (headgear) or a functional appliance is used to modify growth in patients with Class II problems, a favorable response includes both restraint of maxillary growth and differential forward mandibular growth. For patients who are already in the adolescent growth spurt in the mixed dentition, there is nothing wrong with a first phase of removable functional appliance treatment and then a fixed appliance to obtain detailed occlusal results. A removable functional appliance, however, is unlikely to provide a satisfactory result in the early permanent dentition because it will have to be modified or discontinued when fixed appliance treatment begins. Also, when the permanent canines and premolars have erupted, it is advantageous to go ahead with alignment and transverse and vertical positioning of the dentition while growth modification also is occurring. Headgear is much more compatible with the fixed appliances needed for comprehensive treatment, and most varieties of fixed functional appliances also are reasonably compatible with it.

Many clinicians would like to believe that Class II elastics (or fixed springs that have the same effect) can influence growth as well as move teeth. If so, of course, all you would need would be Class II elastics. Unfortunately, that approach rarely succeeds. In an adolescent in the early permanent dentition period, a rigidly coupled fixed functional appliance such as the Herbst appliance effectively corrects Class II molar relationships (with varying combinations of differential growth and forward displacement of mandibular teeth). For cooperative patients whose lower incisors are already at their forward limit from an esthetic or stability point of view, headgear can be quite effective and does not introduce a Class II elastics effect (lower incisors forward).

#### Headgear for Adolescent Growth Modification

An ideal patient for headgear in the early permanent dentition period is a 12- to 14-year-old boy with a Class II problem whose skeletal maturity is somewhat behind his stage of dental development and who has good growth potential ([Fig. 16.16](#)). Boys at age 13,

it must be remembered, are on the average at the same stage of maturation as girls at 11, and significant anteroposterior skeletal growth is almost always continuing. On the other hand, girls at age 13 are, on the average, at the same developmental stage as boys at 15, and by that time clinically useful changes in jaw relationship from growth guidance are unlikely. For a patient of either gender who is beyond the mixed dentition period but still in the adolescent growth spurt, there is no reason to wait for alignment and leveling to be completed before beginning treatment with a headgear or a fixed functional appliance, especially given that every passing day decreases the probability of a favorable growth response.

Although the main purpose of headgear is growth modification, some tooth movement in all three planes of space inevitably accompanies it because the extraoral force is delivered to the teeth. With headgear for Class II correction, when there is good vertical growth and the maxillary molars are allowed to elongate, the maxillary teeth erupt downward and backward, and spaces may open up in the maxillary arch. Even though the extraoral force is applied against the first molar, it is unusual for space to develop between the first molar and second premolar. Instead, the second premolar and, to a lesser degree, the first premolars follow the molars. The result is often a space distal to the canines, along with a partial reduction of overjet as the jaw relationship improves ([Fig. 16.17](#)).

When this result occurs, the preferred approach is to consolidate space within the maxillary arch at a single location, using elastomeric chains to bring the canines and incisors into an anterior segment and the molar and premolars into a posterior segment. When the molar relationship has been corrected, the residual overjet is then reduced by retracting the incisors in this nonextraction patient in exactly the same way as in a patient who had a first premolar extraction space (see the following discussion). Extraoral force should be continued until an intact maxillary arch has been achieved. Discontinuing it when only the molar relationship has been corrected is unwise, both because the maximum skeletal effect probably has not been obtained at that point and because the retraction of the incisor teeth requires posterior anchorage, which can be reinforced by the headgear.

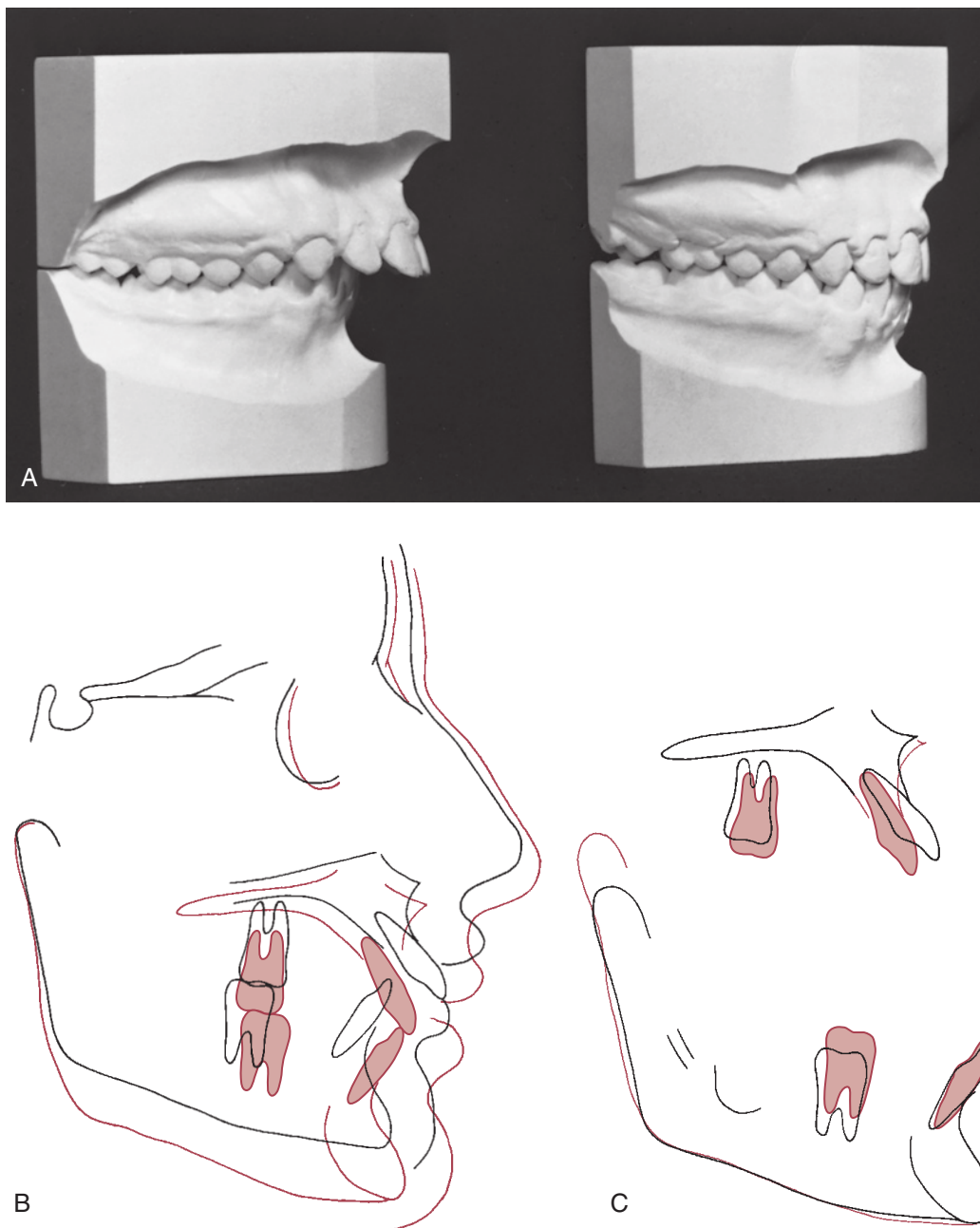
#### Fixed Functional Appliances for Adolescent Growth Modification

As we noted in [Chapter 14](#), the Herbst appliance became the most popular functional appliance in the late 20th century because of its demonstrated effectiveness in correcting Class II malocclusion. With experience, it became clear that it was most effective during adolescent growth in patients who were already in the early permanent dentition period, so that a fixed appliance could be used to control mandibular incisor protrusion and other possible side effects.

In the early permanent dentition, space opening within the maxillary arch rarely occurs when a Herbst appliance or some of its modern variants (see [Fig. 10.7](#)) are used. Bonding the teeth that are available (canines and incisors in both arches, maxillary but usually not mandibular premolars) allows alignment and stabilization of the lower incisors while molar correction is occurring and facilitates the transition to a regular fixed appliance, which usually occurs after about 12 months of Herbst treatment. The Herbst appliance is compatible with both labial and lingual fixed appliances.<sup>12</sup>

#### Class II Camouflage

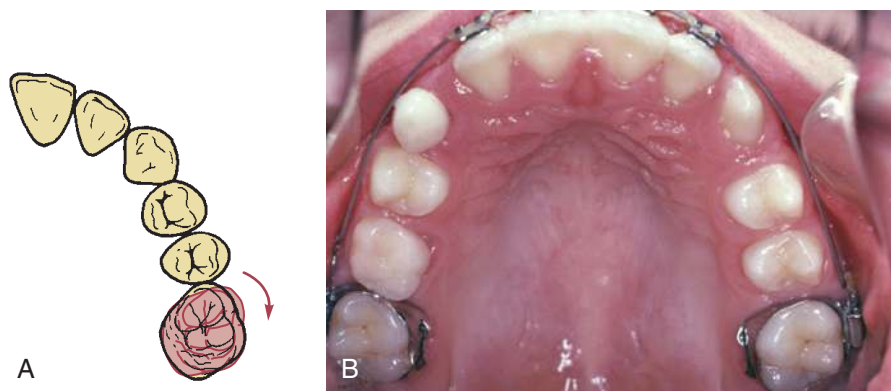
In patients who have reasonable jaw relationships, correcting the excessive overbite that is the hallmark of a Class II problem largely



• **Fig. 16.16** Class II correction in a 13-year-old boy by using extraoral force to the maxilla. (A) Dental casts before and after treatment. (B and C) Cephalometric superimposition showing treatment changes. Note the large amount of vertical growth, which allowed the maxilla and maxillary dentition to be displaced distally as they moved vertically while the mandible grew downward and forward. As the maxillary and mandibular superimpositions show, overbite was corrected by relative intrusion (i.e., the lower incisors were held at the same vertical level while the molars erupted). There was relatively more eruption of the mandibular than the maxillary molar, reflecting the upward and backward direction of headgear force, and only a small amount of distal movement of the upper molars.

by tooth movement is quite possible, with or without correcting the molar relationship. This is acceptable treatment, of course, only if the patient's facial appearance as well as dental alignment and occlusion are satisfactory—thus the earlier statement about reasonable jaw relationships. Moderate skeletal Class II jaw relationships that are still there after orthodontic treatment often are no

longer noticeable enough to be a problem, and therefore the patients with less severe skeletal Class II problems can be treated with tooth movement to camouflage the jaw discrepancy. The patients with more severe problems will need surgical mandibular advancement—and as noted in [Chapter 7](#), it is the patient's decision as to whether surgery would be needed, not the doctor's.



• **Fig. 16.17** (A) In patients with Class II malocclusion, the upper molars usually are rotated mesially, and part of the apparent backward movement of the first molar is a distal rotation of the buccal cusps as the tooth rotates around its lingual root. The inner bow of a headgear facebow should be adjusted to produce this type of rotation. (B) Space tends to open within the maxillary arch when extraoral force to the upper first molars is used and the patient grows well, as in this patient after 12 months of headgear treatment during the adolescent growth spurt. Note that as the molars moved distally, the gingival fiber attachments produced distal movement of the premolars, opening space between these teeth and the canines. When a complete fixed appliance is placed at this stage, one of the first steps is consolidation of the space distal to the canines.

There are three major ways to correct Class II malocclusion with tooth movement: distal movement of upper molars, differential anteroposterior tooth movement using extraction spaces, and nonextraction treatment that consists primarily of forward movement of the lower arch. We will consider them in that order.

### Distal Movement of Upper Molars

The concept of “distal driving” the maxillary posterior teeth has a long orthodontic history. After early cephalometric studies in the 1940s showed that little or no distal movement of upper molars was produced by the Class II elastic treatment of that era, headgear was reintroduced as a means of moving the upper molars back. Skeletal anchorage (miniplates at the base of the zygoma or linked screws in the palate, but not alveolar bone screws) now is the most effective way to accomplish distal movement.

Although the modern methods discussed later have improved the situation, Class II correction by distal movement of upper molars has definite limits that are important to understand and respect. With headgear, it is now clear that significant distal positioning of the upper posterior teeth relative to the maxilla occurs primarily in patients who have vertical growth and elongation of the maxillary teeth (see Fig. 14.11) so that the molars and premolars are tipped distally as they erupt. Without this vertical growth, it is difficult to produce more than 2 to 3 mm of distal movement of the upper molars, unless the upper second molars are extracted (see later). With skeletal anchorage above the roots of the teeth, 4 to 6 mm of distal movement is quite possible, but moving molars back requires space behind them, and second molar extraction may be required for major distalization. If second molars are to be distalized, early removal of third molars is advised; otherwise they may become significantly impacted and difficult to extract.

In patients with mild-to-moderate skeletal Class II malocclusion, the upper molars are likely to have rotated mesially around the lingual root, and merely correcting the rotation changes the occlusal relationship in a Class I direction (see Fig. 10.33). This can be done with a transpalatal lingual arch, an auxiliary labial arch, or

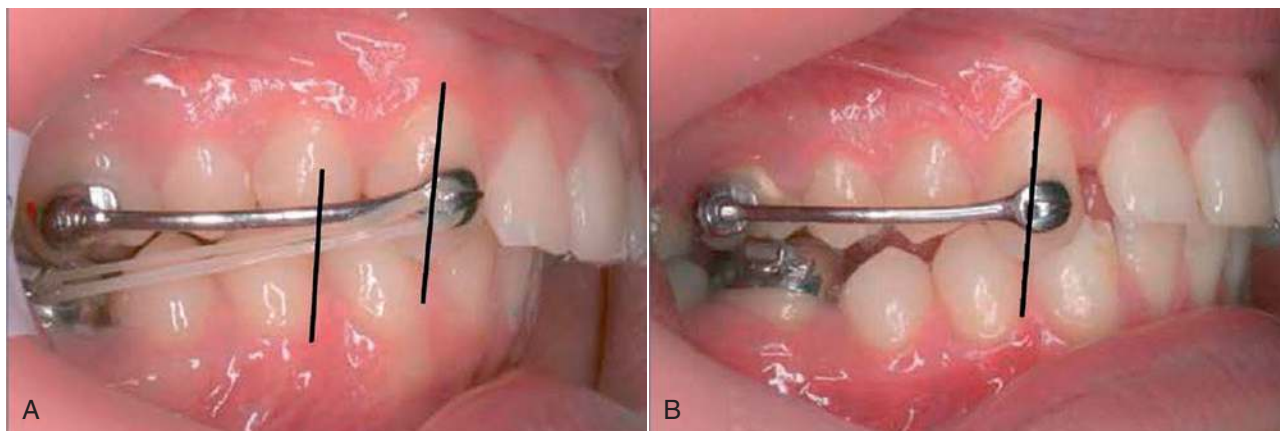
the inner bow of a facebow. Sometimes upper molars are so mesially rotated that it is difficult or impossible to insert a facebow until the rotation has been partially corrected with a more flexible appliance (such as a heavy labial arch, typically 36-mil steel, inserted into the headgear tubes and tied over an initial alignment archwire). Correction of rotated maxillary first molars is the first step in Class II treatment of almost every type.

**Anchorage Systems for Distal Movement.** Mesial movement of teeth is easier than distal movement, simply because there is much more resistance to distal movement. Successful distal movement of molars therefore requires more anchorage than can be supplied by just the other teeth.

**Headgear and Class II Elastics.** The problem with headgear for tooth movement always has been that force of moderate intensity with long duration is needed, but headgear tends to supply relatively high force with only medium duration even in cooperative patients. Unless second molars are extracted (see later), significant distal movement of first molars (>2 mm) with headgear occurs only when the molar is extruded simultaneously, which is acceptable in a patient with substantial growth in height of the ramus, but otherwise leads to unfavorable downward and backward rotation of the mandible. High-pull headgear is not very effective in distalizing molars.

In theory, force from Class II elastics also can be used to push the upper molars distally, by using a sliding jig to concentrate the force on the molars. This was a mainstay of the original Tweed technique, but as with Class II elastics in general, there is the risk of considerably more mesial movement of the lower teeth than distal movement of the upper teeth. The modern variant of the sliding jig is the Carriere Motion appliance shown in Fig. 16.18. As with the other techniques using Class II elastics, the lower molars extrude as the lower teeth move forward and the upper anterior teeth will extrude. In general, the major use of Class II elastics to a sliding jig, or any similar device, would be to accentuate rotation of the upper molar as a component of correcting the molar relationship, with no bodily distal movement expected.





• **Fig. 16.18** Carriere Motion appliance used to apply Class II elastic force to upper molars in a Class II situation. (A) The elastic places a posterior force on the upper canine, then force is transferred to the upper molar. (B) Molar correction to Class I malocclusion is achieved, but the side effects of the Class II elastic wear are apparent. Extrusion of lower molar and loss of lower anchorage are visible, as is extrusion of the upper canine from the vertical force of the Class II elastic. Some of the lower molar extrusion and tipping can be reduced by using an overlay lower clear tray appliance.

### Skeletal Anchorage

**Palatal Anchorage.** The idea that the relative stability of the anterior palate was a good possibility for obtaining additional anchorage goes back to the mid-20th century, far preceding TADs in the palate. Although removable appliances contact the palate, they are not effective in moving molars back, probably because they do not fit well enough. The Nance lingual arch, with a pad against the palatal rugae behind the central incisors, has long been considered an adjunct to preventing forward movement of maxillary molars. A fixed appliance that stabilizes the premolars and includes a plastic pad contacting the rugae—the pendulum appliance (Fig. 16.19) is the best example—was thought to be effective and was briefly popular in the late 20th century. Fortunately, most patients tolerate bulky palatal appliances such as this one with minimal problems, but contacting the palatal tissue has the potential to cause significant tissue irritation, to the point that sometimes the appliance has to be removed.

A greater problem is that however the molars were moved distally, they must be held there while the other teeth are then retracted to correct the overjet. It is one thing to move molars back, and something else to maintain them in that position. Follow-up studies with the pendulum appliance showed that space obtained by pushing the molars back with it was largely lost during later space closure, to the point that overjet reduction often was disappointing.<sup>13</sup>

**Miniplate Anchorage.** An alternative for retraction of the entire maxillary arch is miniplates on each side at the base of the zygomatic arch (Fig. 16.20). This works well as direct anchorage to move the entire arch posteriorly as a single unit if the anterior teeth are well aligned, or as a combined direct and indirect approach. This consists of direct anchorage to move the molars distally to create enough space for anterior alignment and retraction, and then indirect anchorage to stabilize the posterior segment while the incisors are moved back.<sup>14</sup> Both approaches work well, but invasive surgery is required to place and again to remove the miniplates.

It also is possible to use alveolar bone screws for anchorage to distalize molars and then stabilize them while the anterior teeth are retracted. This is no longer recommended because the bone screws must be repositioned during the tooth movement and there is a risk of anchorage failure with single screws.

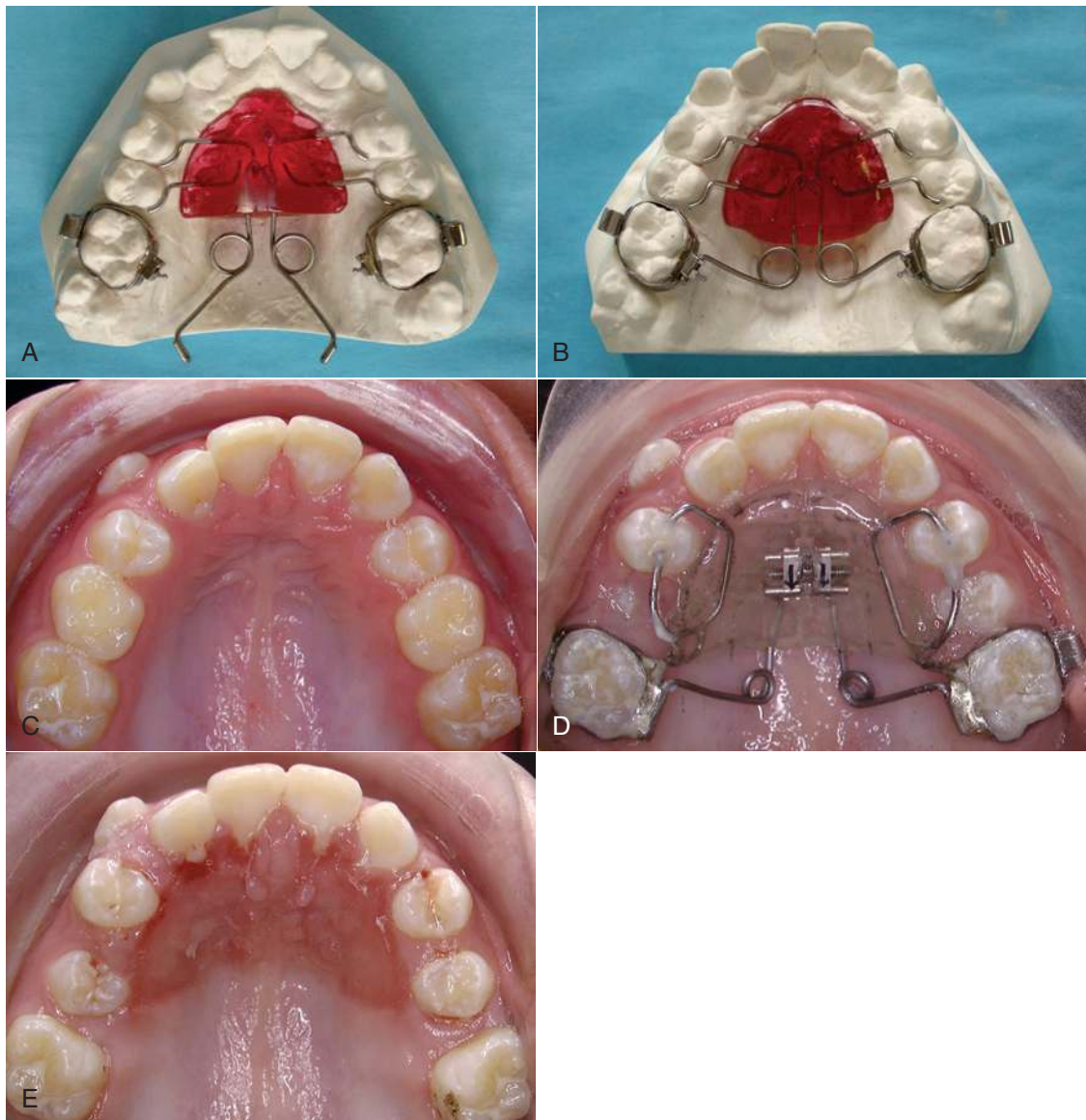
**Palatal Bone Screw Anchorage.** The bone of the anterior palate is the best location in the mouth for bone screws because of the thickness and density of the bone, and indirect skeletal anchorage from this area is the most effective way to move molars distally and hold them there while the other teeth are retracted into this area. This is so much more effective than pressure against palatal soft tissues that the older techniques for palatal anchorage can be considered obsolete.

If all that is needed is distal movement of the maxillary arch, indirect anchorage from two small screws on either side of the midpalatal suture is adequate to first move the molars distally and then hold them there while the premolars and anterior teeth are retracted. Hourfar and colleagues have published a series of cases that demonstrate how a palatal appliance supported by two bone screws can both expand the arch transversely and distalize upper molars.<sup>15</sup>

In a study based on three-dimensional analysis of tooth position and orientation, Duran et al noted that with direct force from a jackscrew in the midline of the palate against the maxillary first molars, effects in all three planes of space were observed.<sup>16</sup> As part of the mean  $5 \pm 2$  mm distal movement of the first molars, on average they were intruded 0.5 mm, moved about 0.7 mm toward the midline, and rotated mesiobuccally  $5 \pm 3$  degrees. Distal tipping, with a mean of 10 degrees, was a component of the distal movement. The method was precise, the wide variability in the responses was typical of outcome studies, and the midline jackscrew for tooth movement was not the best way to do that because of the heavy intermittent force—but this can be considered confirmation of previous findings that transverse expansion is needed when molars are moved distally, and that intrusion would be expected if the anchor is in the depth of the palate.

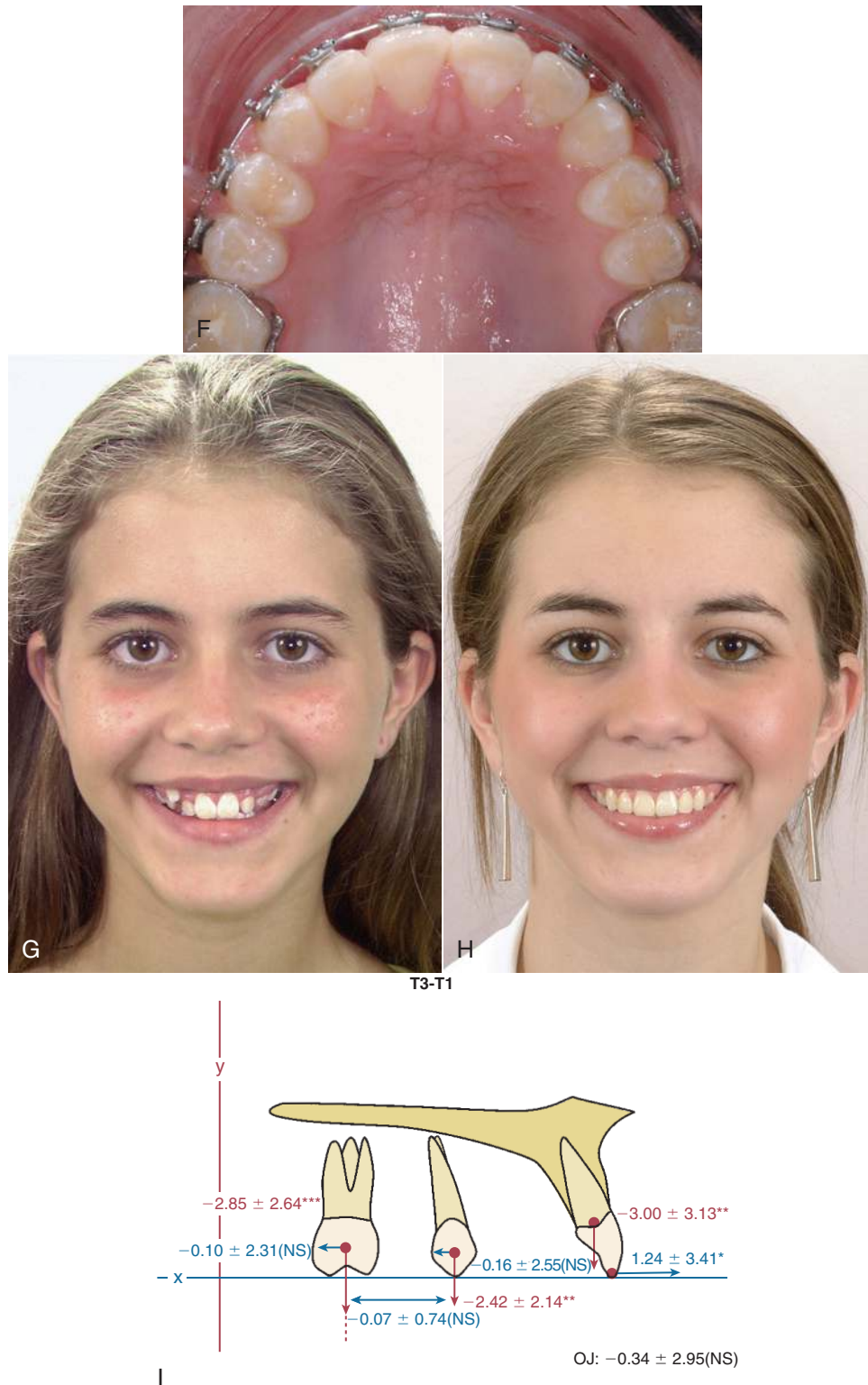
To demonstrate that distal movement of upper molars with bone screw anchors is possible even in adults, Kook et al studied a group of young adults.<sup>17</sup> They found that the upper molars were moved back  $3.3 \pm 2$  mm with a mild degree of distal tipping. The upper incisors were also retracted in this group about 3 mm and the occlusal plane was tipped because of intrusion of the molars and extrusion of the incisors.

Skeletal anchorage or not, two objects cannot occupy the same space at the same time, and there is only so much room at the



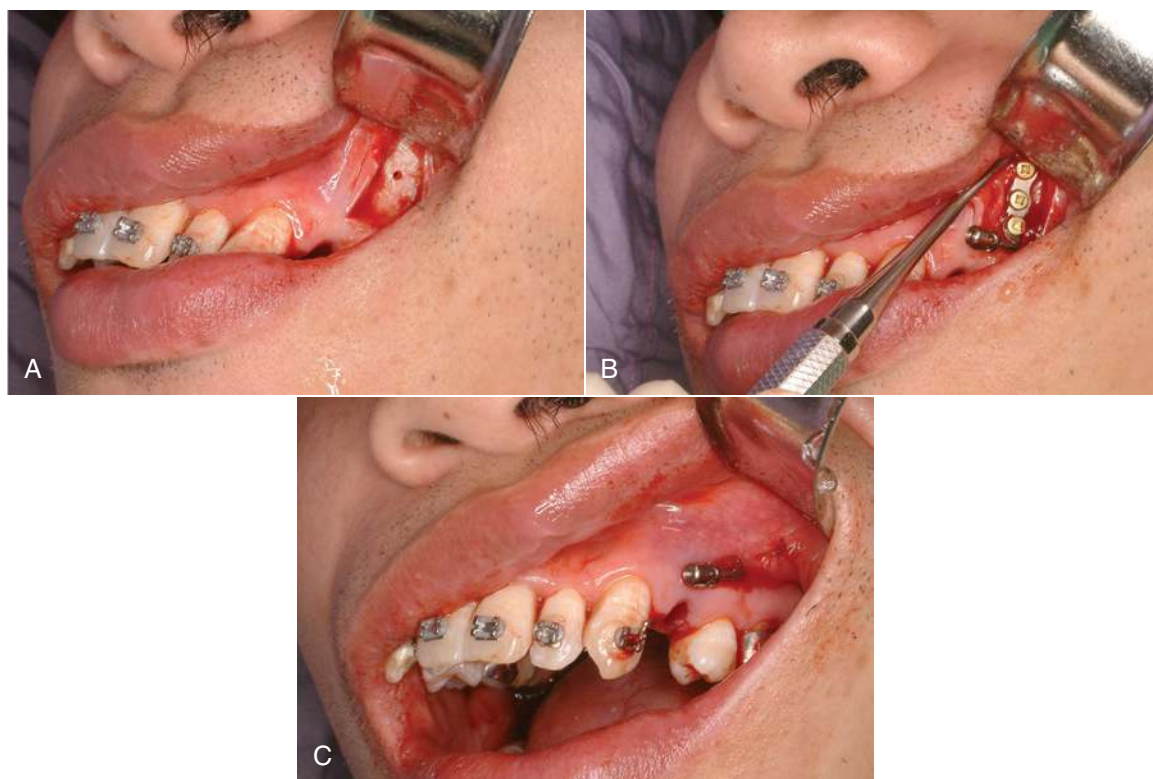
• **Fig. 16.19** Pendulum appliance for molar distalization. (A and B) Appliance on cast before and after activation of the springs. These are formed from beta-titanium (beta-Ti) wire and should deliver 200 to 250 gm of force (steel wire is too stiff; it produces too much force). (C) Occlusal view of a patient with the maxillary canines nearly blocked out of the arch (in an individual who can afford some increase in maxillary incisor prominence). (D) Pendulum appliance with both a jackscrew for transverse expansion and molar distalizing springs (this modification is called the *T-Rex appliance*). (E) Removal of the appliance. Note the increase in space in the arch and the irritation of the palatal tissue beneath the appliance. Both are typical responses.

*Continued*



• **Fig. 16.19, cont'd** (F) Alignment of the upper arch completed. (G and H) Initial and posttreatment smiles. (I) Mean changes in tooth position relative to the maxilla in a sample of 35 Class II patients treated with a first phase of pendulum appliance molar distalization followed by comprehensive fixed appliance treatment, with a mean treatment duration of  $3.1 \pm 0.6$  years. Note the small average net distalization of the molars relative to the maxilla. In the final analysis, successful correction of the Class II malocclusion was due more to jaw growth, transverse expansion of the dental arches, and forward movement of the lower incisors than to distalization of upper molars. (Courtesy Professor A. Darendeliler.)





• **Fig. 16.20** Placement of a bone anchor at the base of the zygoma for maximum retraction of protruding maxillary incisors. (A) Exposure of the zygomatic buttress area; initial hole for screw drilled. (B) Anchor in place, secured by three bone screws. (C) Soft tissue covering the anchor, with only the tube for attachment of a retraction spring exposed in the mouth.

rear of the maxillary arch. This means that in adolescents, extraction of the second molars may be necessary, and if second molars are distalized, early extraction of the third molars is indicated so that they do not end up impacted. In patients who have well-formed maxillary third molars, extraction of the second molars is a better idea than it might sound initially, because maxillary third molars usually erupt into the second molar extraction space nicely, bringing bone with them (Fig. 16.21). The same 75% to 80% chance that maxillary third molars would be satisfactory replacements for the second molars presumably would apply with use of skeletal anchorage, as it did with headgear for distalization.<sup>18</sup>

Occasionally, unilateral molar distalization is indicated, typically when a unilateral Class II malocclusion is present and there is a dental midline discrepancy. Extraction of one second molar facilitates this treatment, and the third molar usually replaces the missing second molar quite satisfactorily. Unilateral cervical headgear can be used for this treatment plan, but skeletal anchorage is preferred now because it is quicker and easier on the patient.

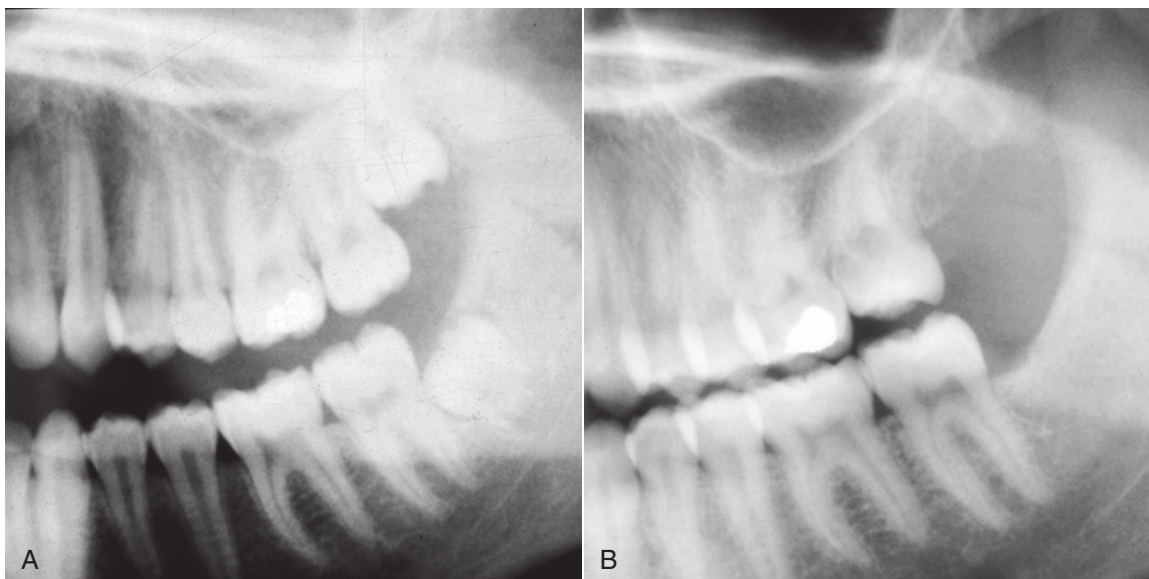
It is difficult to distalize the upper teeth too much with headgear or palatal anchorage. Skeletal anchorage is so effective that over-retraction of the upper incisors is possible, which of course becomes unsuccessful camouflage. This makes it even more important to establish the desired final position of the incisors in planning treatment and then control tooth movement to reach this goal. In one sense, skeletal anchorage makes it possible to do what only surgery could do previously: move the maxillary dentition back too much.

### **Differential Anteroposterior Tooth Movement Using Extraction Spaces**

There are two reasons for extracting teeth in orthodontics, as discussed in detail in Chapter 7: (1) to provide space to align crowded incisors without creating excessive protrusion and (2) to allow camouflage of moderate Class II or Class III jaw relationships when correction by growth modification is not possible. A patient with both Class II (or III) problems and crowding is a difficult problem because the same space cannot be used for both purposes. The more extraction space is required for alignment, the less is available for differential movement in camouflage, and vice versa.

An important part of treatment planning is deciding which teeth to extract and how the extraction spaces are to be closed (i.e., by retraction of incisor teeth, mesial movement of posterior teeth, or some combination). These decisions determine the orthodontic mechanics.

**Class II Camouflage by Extraction of Upper First Premolars.** In the late 20th century, it was claimed by some dentists that extraction of upper first premolars would lead to later temporomandibular dysfunction (TMD) problems. The theory, to the extent that the proponents of this claim had one, was that retracting the upper incisors would inevitably lead to incisor interferences, and this would cause TMD. The claim was never supported by any evidence, and research data have refuted it.<sup>19</sup> It is important to limit first premolar extraction for camouflage of Class II malocclusion to the appropriate patients and not to retract the incisors too much, but if this is done, it can be an excellent treatment method.



• **Fig. 16.21** (A) In this patient the treatment plan was extraction of the maxillary left second molar so that the first molar and premolars on that side could be moved distally to correct a yaw of the maxillary arch. (B) After treatment, with the third molar already erupting into the second molar extraction site. Eventually the remaining three third molars would be scheduled for extraction. A well-formed maxillary third molar can be a satisfactory replacement for an extracted second molar and usually erupts in a way that facilitates the replacement.

With this approach, the objective is to maintain the existing Class II molar relationship, closing the first premolar extraction space largely by retracting the protruding incisor teeth (Fig. 16.22). Anchorage must be reinforced, but one method, Class II elastics from the lower arch, is specifically contraindicated unless the lower incisors need to be moved forward (which rarely is the case). The remaining possibilities are extraoral force to the first molars, a stabilizing lingual arch, retraction of the maxillary anterior segment with extraoral force directly against these teeth, or skeletal anchorage.

Excellent reinforcement of posterior anchorage can be obtained with extraoral force only if it is applied consistently and for long durations. The more constant the headgear wear, the less a stabilizing lingual arch will be needed, but headgear for anchorage in Class II camouflage is rarely used now because poor patient compliance is likely. A stabilizing lingual arch augments the posterior anchorage full-time and is likely to be more effective.

It seems intuitively obvious that a lingual arch with a button against the palatal tissue should be more effective than a straight transpalatal lingual arch, but when first molars are being stabilized in a premolar extraction case, this is not necessarily true. As we noted earlier, anchorage from palatal soft tissue can be troublesome; more important, the effect of the stabilizing lingual arch is primarily to prevent the molars from rotating mesiolingually around their palatal root and secondarily to prevent them from tipping mesially. A straight transpalatal lingual arch is as effective as one with a palatal button in preventing rotation (Fig. 16.23), and for most patients, the marginally better stabilization with a palatal button is not worth the cost in tissue irritation. Note that this is true when a lingual arch is used to stabilize molars, but not true when the lingual arch is used to stabilize premolars, as in the molar distalization technique discussed earlier. When pushed mesially, premolars tip more than they rotate, and a palatal button on a lingual arch is at least a minimal step toward stabilizing them.

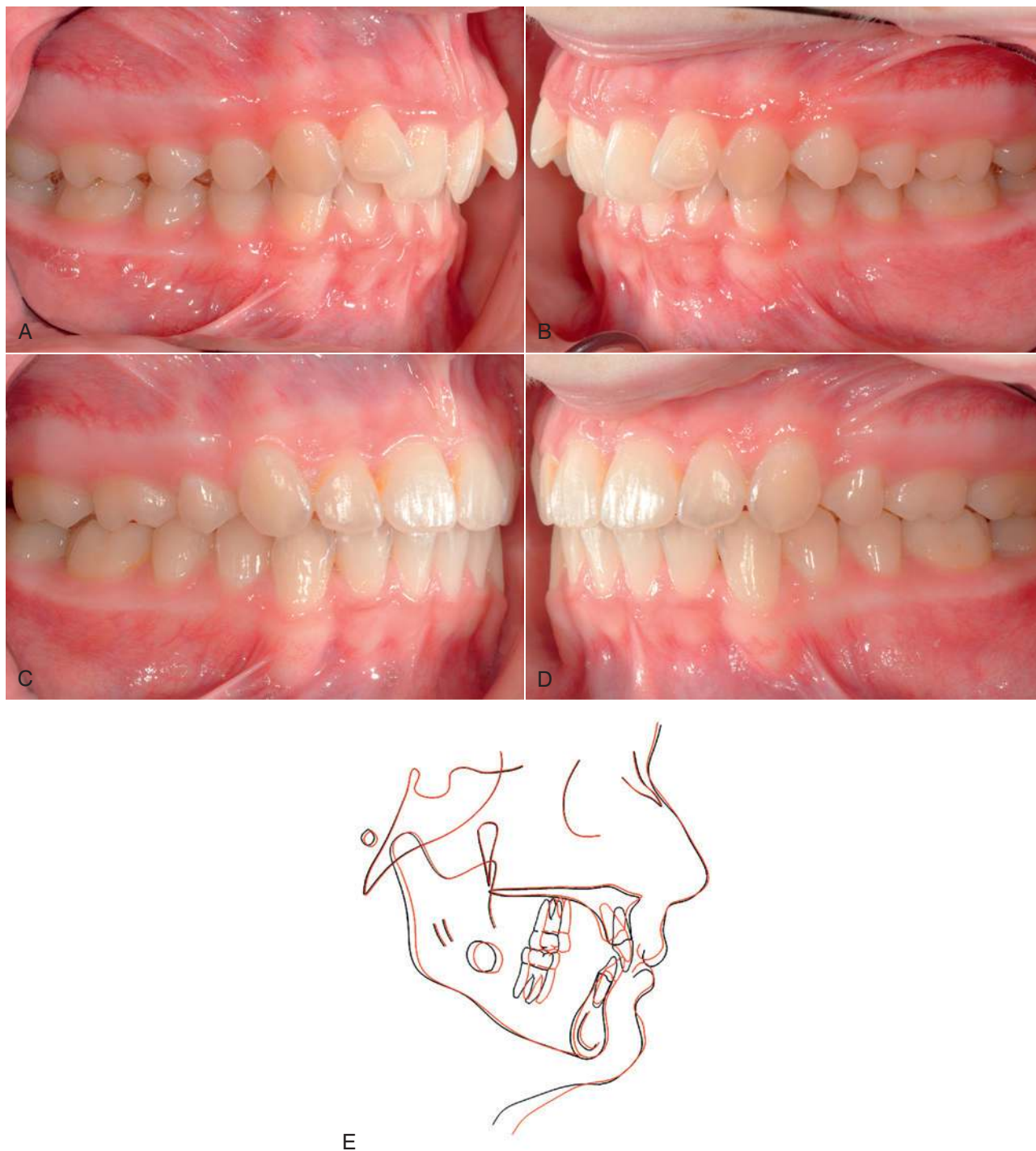In addition to headgear and/or lingual arch stabilization, all the strategies described in Chapter 10 for reducing strain on anchorage (i.e., minimizing binding and friction, retracting canines individually, skeletal anchorage) are appropriate with upper first premolar extraction and can be brought into use.

Retracting protruding maxillary anterior teeth with headgear attached to the archwire (often called *J-hook headgear*) totally avoids strain on the posterior teeth and once was attractive from that point of view. This technique has two major disadvantages: (1) as with any headgear that provides too few hours and too much force, the force system is unfavorable for tooth movement and (2) there is significant binding and friction, not only where teeth slide along the archwire but also within the headgear mechanism itself because the headgear wires that attach to the teeth tend to bind against their protective sleeves.

This makes it difficult to control the amount of force, and more net force on one side than the other may lead to an asymmetric response. In fact, with J-hook headgear it is unusual if space does not close faster on one side than the other. Only if the headgear is worn nearly full-time (including school hours) will efficient tooth movement be obtained. For these reasons, headgear for direct retraction of the incisor segment is no longer recommended.

Skeletal anchorage in these premolar extraction cases is a straightforward way to reinforce anchorage, and retraction of the six anterior teeth usually can be managed satisfactorily with a single bone screw between the second premolar and first molar (see Fig. 10.48). In adolescents, use of TADs is necessary only if maximum retraction of the anterior segment without any elongation of the incisors is desired, a situation more likely to be encountered in adults.

**Extraction of Maxillary and Mandibular Premolars.** Correction of Class II buccal segment relationships with extraction of all four first premolars implies that the mandibular posterior segments will

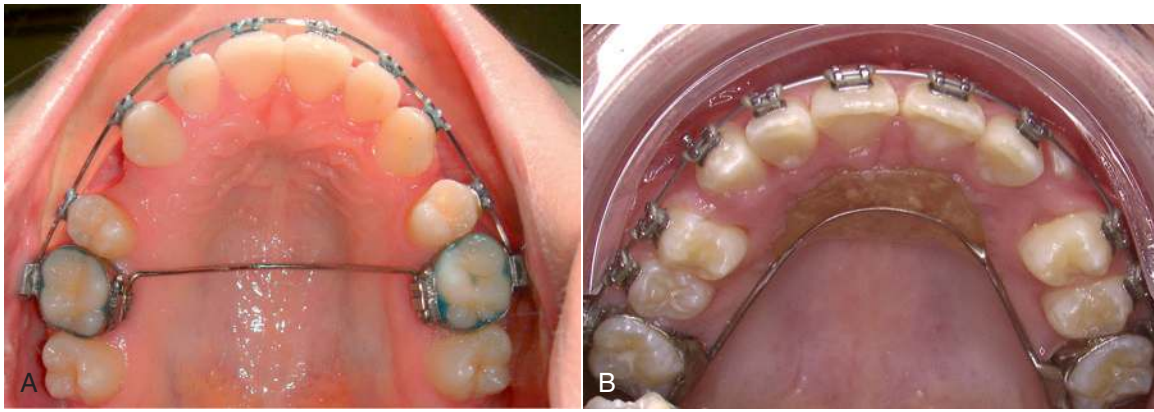


• **Fig. 16.22** An example of the camouflage of a Class II malocclusion by extraction of maxillary premolars. (A and B) Before treatment the molars and canines are Class II and the maxillary central incisors are retroclined in a division 2 pattern. (C and D) After treatment the molars remain Class II but the canines are in an ideal Class I position and the inclination of the incisor has been corrected to allow ideal overbite and overjet. (E) Cephalometric superimposition showing the dental and skeletal changes during treatment.

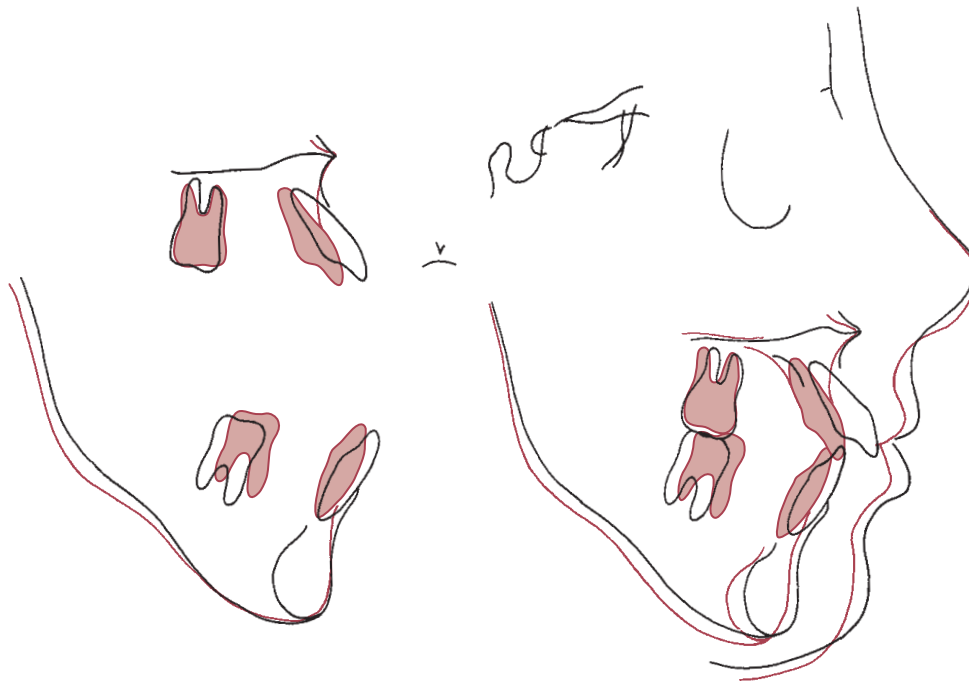
be moved anteriorly nearly the width of the extraction space. At the same time, the protruding maxillary anterior teeth will be retracted with minimal forward movement of the maxillary buccal segments. This, in turn, implies (although it does not absolutely require) that Class II elastics will be used to assist in closing the extraction sites.

With the edgewise appliance, the width of the brackets makes it difficult to close space by tipping the crowns as in the Begg approach, but it is possible to structure anchorage so that space closure by retraction of the maxillary anterior teeth and protraction of the mandibular posterior segments occurs without the use of Class II elastics. The best control is achieved with the segmented





• **Fig. 16.23** (A) A transpalatal lingual arch without an adjustment loop is designed to reinforce anchorage by preventing molar rotation. (B) The Nance lingual arch projects forward into an acrylic pad against the palatal rugae, the most stable part of the palate—but there may be a soft tissue reaction to pressure in that area.



• **Fig. 16.24** Cephalometric superimposition showing the result of treatment with extraction of upper first and lower second premolars. Even with second premolar extraction, some retraction of the mandibular incisors may occur, but most of the space closure will be by mesial movement of the lower molar. This adult patient experienced no growth, and a slight downward and backward rotation of the mandible occurred.

arch technique, using space-closing springs in each arch fabricated specifically for the type of space closure desired (see the discussion of closure of extraction spaces earlier in this chapter).

A more common approach with the edgewise appliance is to extract maxillary first and mandibular second premolars, thus altering the anchorage value of the two segments (Fig. 16.24). With this approach, routine space-closing mechanics will move the lower molars forward more than the upper, particularly if

maxillary posterior anchorage is reinforced with a stabilizing lingual arch or headgear. This upper first–lower second premolar extraction pattern greatly simplifies the mechanics needed for differential space closure with continuous-arch edgewise technique.

Occasionally, however, mesial movement of the lower first molar into a second premolar extraction space is difficult to produce. This is particularly likely when the second premolar was congenitally missing and a retained second primary molar is to be extracted,

because with the wider extraction space to be closed, bone resorption reduces the alveolar ridge dimensions before space closure can be completed. It can be advantageous to remove only the distal root of the second primary molar, leaving the mesial part of the primary tooth in place (with a calcium hydroxide pulpotomy and temporary restoration) until the permanent tooth has been brought forward for that half of the total distance. Then the remaining half of the primary tooth is extracted, and space closure completed.<sup>20</sup>

### Nonextraction Correction With Interarch Elastics

Without extraction spaces, Class II elastics produce molar correction largely by mesial movement of the mandibular arch, with only a small amount of distal positioning of the maxillary arch, and can produce far too much protrusion of lower incisors (Fig. 16.25). When some forward movement of the mandibular dentition is desired, the amount of force varies with the amount of tipping that is allowed. With a well-fitting rectangular wire in the lower arch, approximately 250 gm per side is needed to displace one arch relative to the other. With a lighter round wire in the lower arch, half that amount of force should be used. Incorporating the lower second molars into the appliance and attaching the elastics to a mesial hook on this tooth increase the anchorage and give a more horizontal direction of pull than hooking the elastic to the first molar.

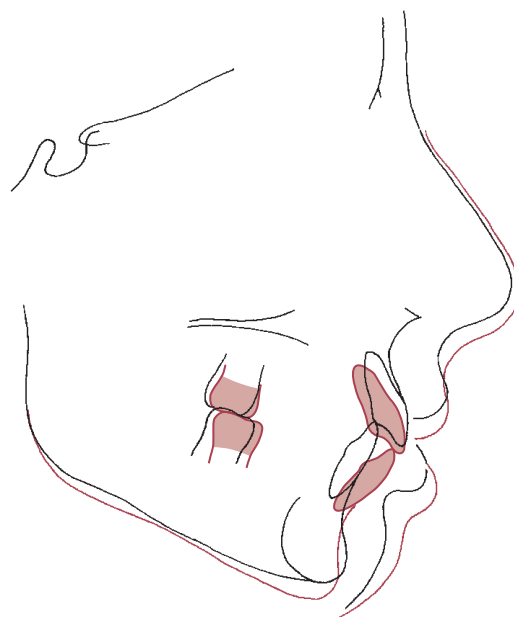
It is important to keep in mind that with or without extraction, Class II elastics produce not only anteroposterior and transverse effects but also a vertical force (Fig. 16.26). This force elongates the mandibular molars and the maxillary incisors, rotating the occlusal plane up posteriorly and down anteriorly. If the molars extrude more than the ramus grows vertically, the mandible itself will be rotated downward (see Fig. 16.25). Class II elastics therefore are contraindicated in nongrowing patients who cannot tolerate some downward and backward rotation of the mandible. The rotation of the occlusal plane, in and of itself, facilitates the desired correction of the posterior occlusion, but even if elongation of the lower molars can be tolerated because of good growth, the corresponding extrusion of the maxillary incisors can be unsightly.

Class II elastics, in short, may produce occlusal relationships that look good on dental casts but are less satisfactory when skeletal relationships and facial esthetics are considered. Because of this, applying heavy Class II force for 9 to 12 months as the major method for correcting a Class II malocclusion rarely produces an acceptable result. Using Class II elastics for 3 or 4

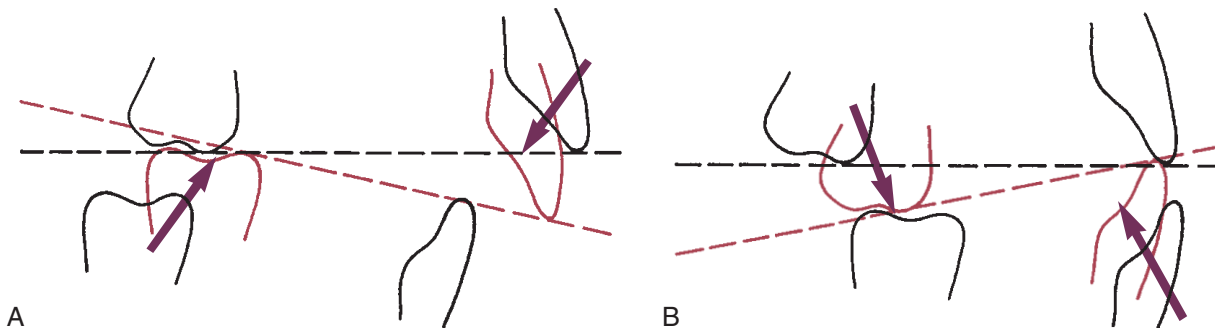
months at the completion of treatment of a patient with Class II malocclusion to obtain good posterior interdigitation, however, is often acceptable.

### Class III Camouflage

Class III camouflage would be based on a combination of retraction of lower incisors and forward movement of maxillary incisors and, of course, would be successful only if the malocclusion was corrected



• **Fig. 16.25** Cephalometric superimposition showing the response to Class II elastics in a girl in whom this was the major method for correcting a Class II malocclusion. Note that with rectangular archwires, some torque of the upper incisors was obtained. Both the downward-backward rotation of the mandible (perhaps less in this patient than often occurs) and the considerably greater forward displacement of the lower teeth than retraction of the upper teeth are typical. This amount of lower incisor protrusion is undesirable because of both the lip protrusion and lack of stability without permanent retention.



• **Fig. 16.26** Rotation of the occlusal plane with Class II (A) and Class III (B) elastics. The rotation of the occlusal plane helps correct the molar relationship, but it can be deleterious in some patients because elongation of the molars may cause undesirable rotation of the mandible or undesirable tooth-lip relationships.

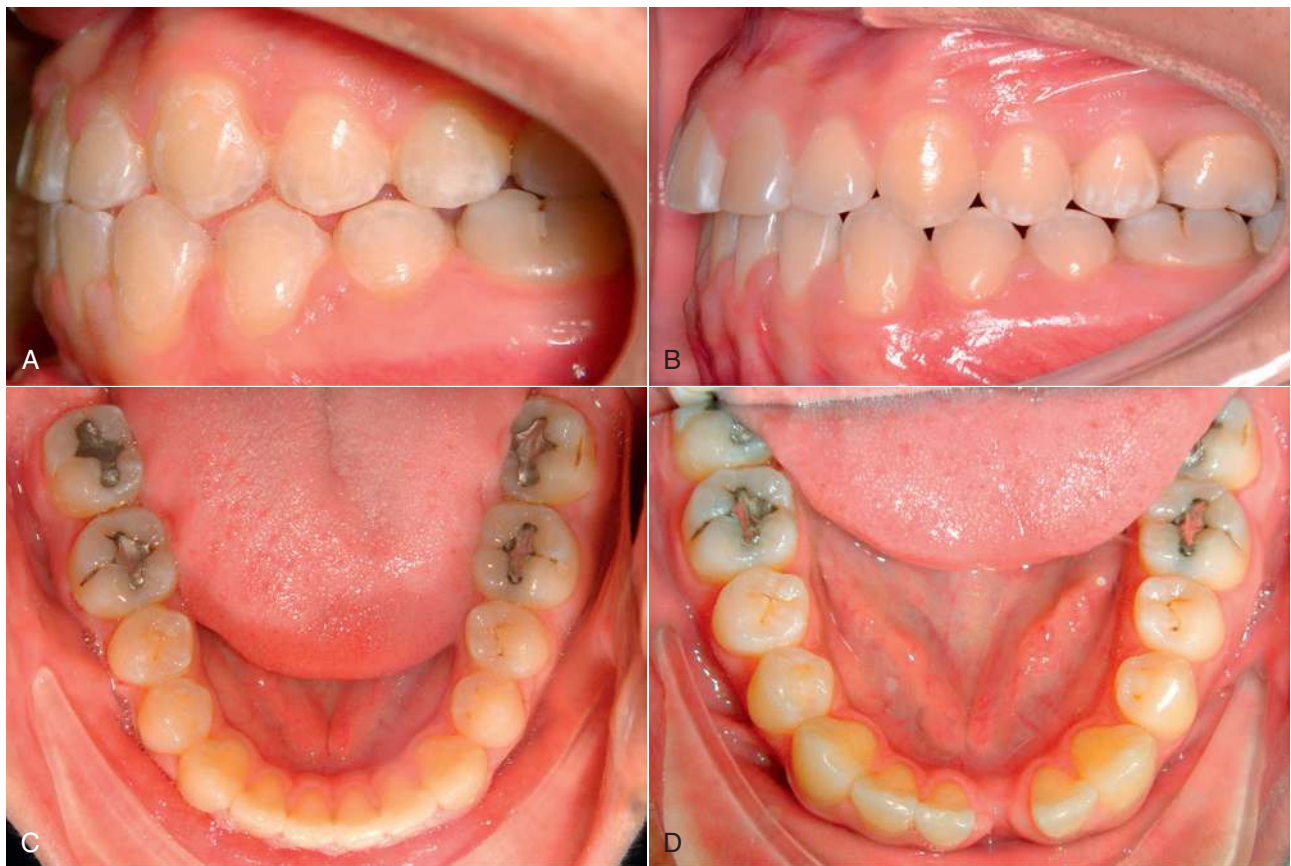
without harming the facial appearance. In theory, Class III elastics could do this, but they also have a significant extrusive component, tending to elongate the upper molars and the lower incisors (see Fig. 16.26). In a short-face patient with a large mandible, rotating the mandible downward and backward, within limits, can help treatment of a Class III problem.

As we have noted previously, retracting the lower incisors is likely to make the chin look more, not less, prominent. For this reason, the reverse of the most popular approach to Class II camouflage, extraction of mandibular first and maxillary second premolars with use of Class III elastics, rarely is a good plan for patients of European descent. They usually do not have mandibular dental protrusion and often cannot tolerate the increased anterior face height that Class III elastics tend to create. It may be a satisfactory plan in Asian patients, who often do have protrusion of lower incisors relative to the mandible and are more likely to tolerate downwards and backward rotation of the mandible.

A better approach to camouflage in patients of European descent with a moderately severe Class III problem is extraction of one lower incisor, which prevents major retraction of the lower teeth,

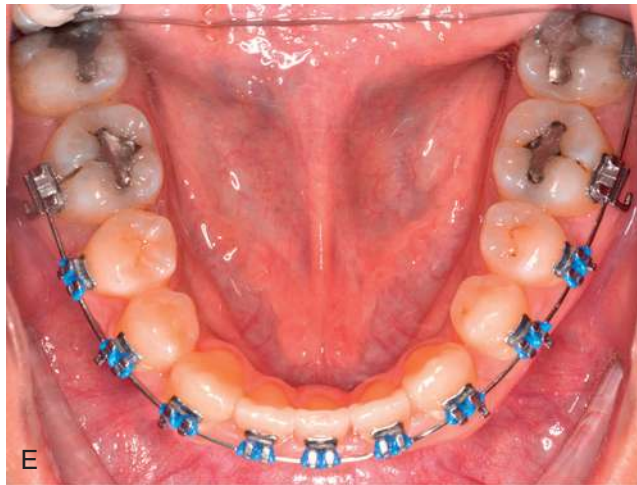while the maxillary incisors are moved facially with some tipping allowed. The combination of upright mandibular incisors and proclined maxillary incisors often leads to good dental occlusion rather than the expected tooth-size problem (Fig. 16.27), but a set-up, digital or plaster, always should be done when one lower incisor extraction is considered to verify the probable occlusal outcome. Another approach to camouflage a moderate Class III problem is removal of mandibular premolars while carefully controlling lower incisor retraction. Figs. 16.28 and 16.29 show an example of this treatment approach using extraction of maxillary and mandibular second premolars to minimize incisor change.

For Asian (or rarely, other) late adolescent Class III patients with major protrusion of the lower incisors, using skeletal anchorage to move the whole lower arch posteriorly can be quite helpful in correcting the problem (see Fig. 19.36).<sup>21</sup> Extraction of third molars usually is needed in order to move the mandibular dental arch back. If second molars are extracted to facilitate distal movement, third molars may erupt as satisfactory replacements, but this is not as likely as in the maxillary arch and therefore is not recommended as a routine procedure.

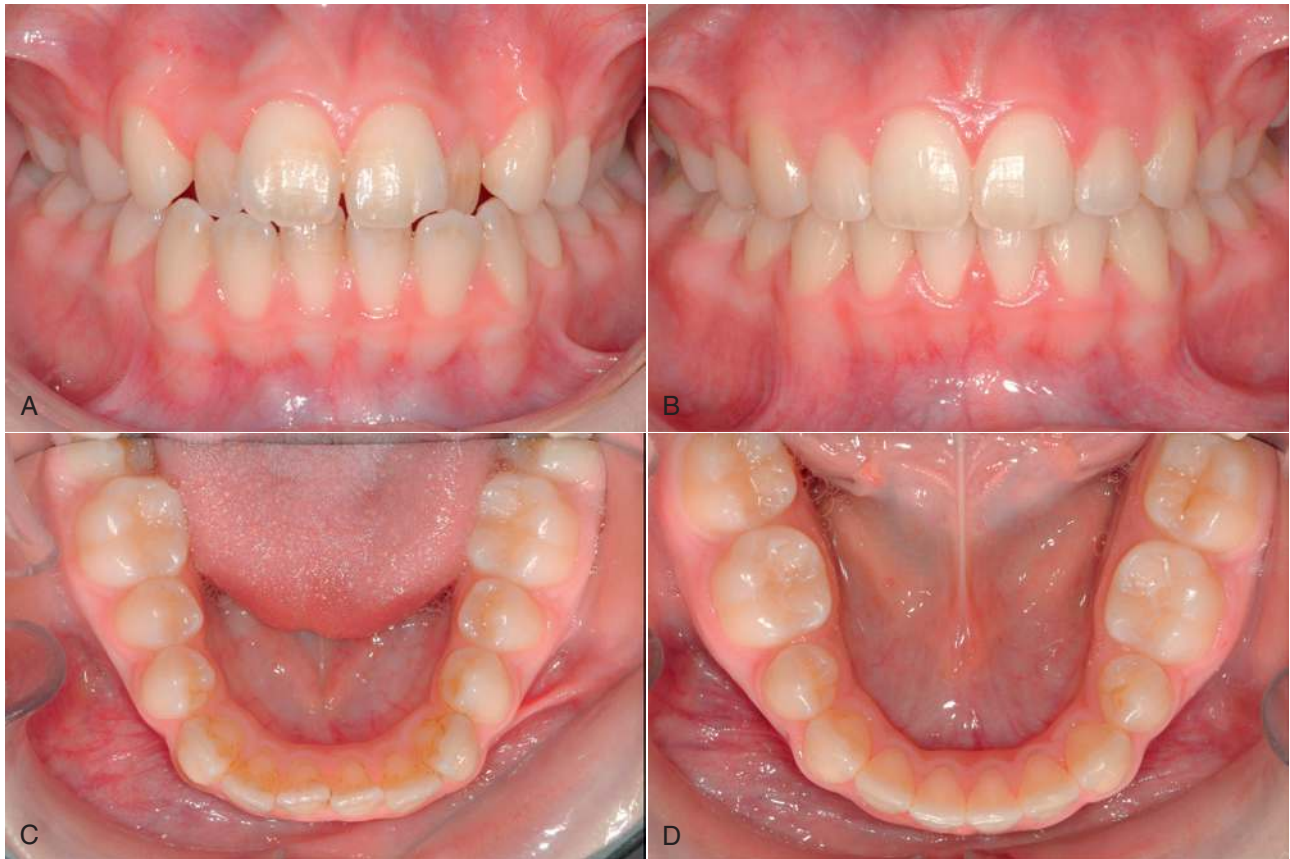

• **Fig. 16.27** Camouflage of a Class III malocclusion using the extraction of a single mandibular incisor. (A) Late mandibular growth after comprehensive treatment resulted in an end-to-end incisor relationship and a Class III tendency. (B) After extraction of the lower left central incisor and space closure to improve the incisor relationship. (C) Lower arch before incisor extraction. (D) Lower arch with incisor removed.

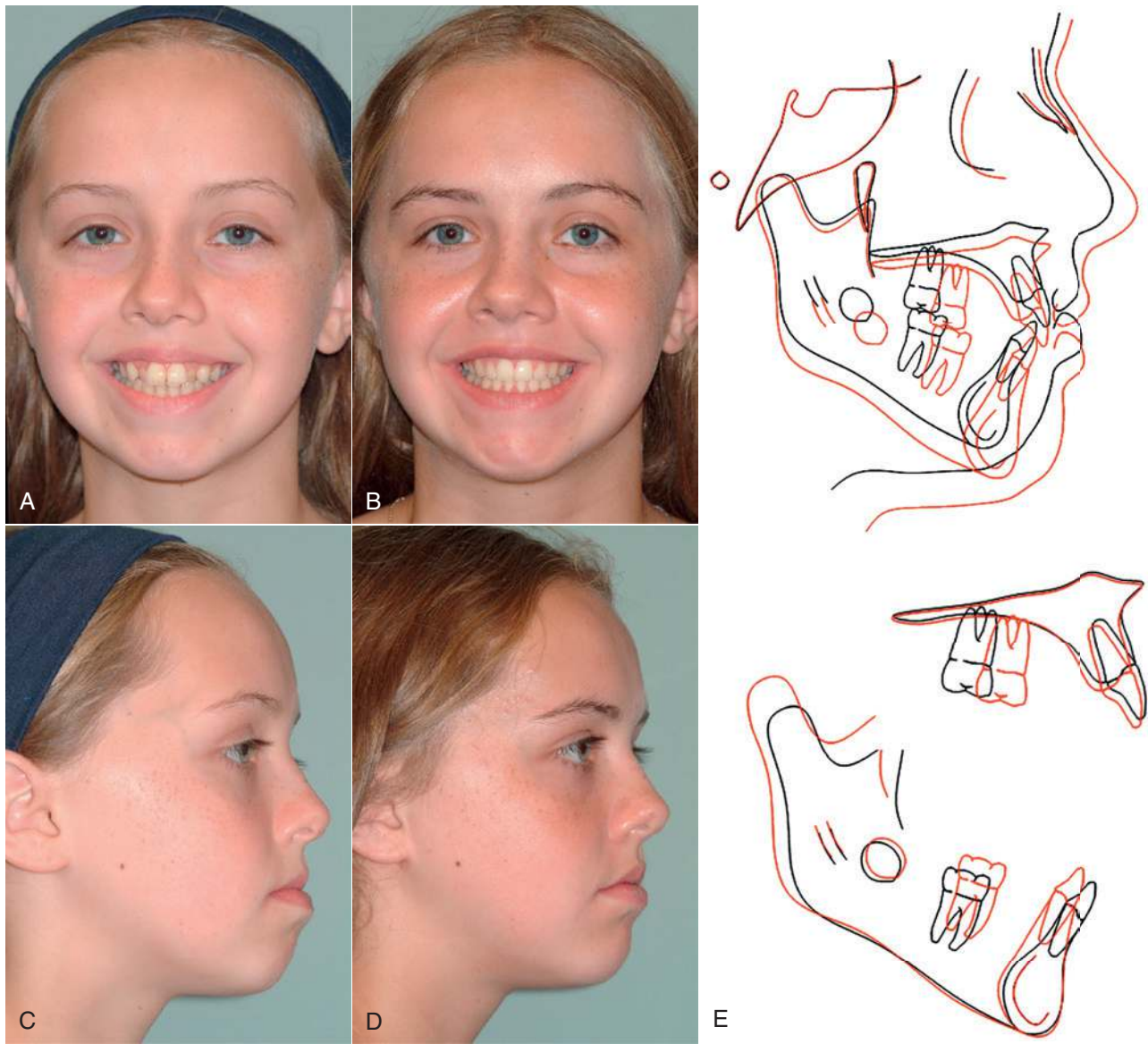




• **Fig. 16.27, cont'd** (E) Fixed appliances used to close incisor extraction space and slightly retract mandibular incisors.



• **Fig. 16.28** Treatment of a mild Class III malocclusion with extraction of four second premolars. (A and C) Before treatment with anterior crossbite and mild crowding. (B and D) After premolar extraction and fixed appliance treatment. (Courtesy Dr. T. Shaughnessy.)



• **Fig. 16.29** Facial images and cephalometric tracings of the mild Class III case shown in Fig. 16.28. (A and C) Before treatment with lower lip eversion resulting in profile imbalance. (B and D) After second premolar extraction and fixed appliance treatment demonstrating improved facial profile and lip balance. (E) Cephalometric tracing showing dental and soft tissue changes as a result of treatment. Note the minimal upper incisor retraction possible with extraction of second premolars and proper management of anchorage. (Courtesy Dr. T. Shaughnessy.)

## References

- Booth FA. *MS Thesis: Optimum Forces With Orthodontic Loops*. Houston: University of Texas Dental Branch; 1971.
- Techalertpaisarn P, Versluis A. Effect of apical portion of T-, sloped L-, and reversed L-closing loops on their force systems. *Angle Orthod*. 2017;87:104–110.
- Ronay F, Kleinert W, Melsen B, et al. Force system developed by V bends in an elastic orthodontic wire. *Am J Orthod Dentofacial Orthop*. 1989;96:295–301.
- Siatkowski RE. Continuous archwire closing loop design, optimization and verification. Parts I and II. *Am J Orthod Dentofacial Orthop*. 1997;112:393–402, 484–495.
- Nanda R, Uribe FA. *Atlas of Complex Mechanics*. St Louis: Elsevier; 2017.
- Eden JD, Waters N. An investigation into the characteristics of the PG canine retraction spring. *Am J Orthod Dentofacial Orthop*. 1994;105:49–60.
- Lagravere MO, Carey J, Heo G, et al. Transverse, vertical, and anteroposterior changes from bone-anchored maxillary expansion vs traditional rapid maxillary expansion: a randomized clinical trial. *Am J Orthod Dentofacial Orthop*. 2010;137:304e1–304e12, discussion 304–305.
- Sandler J, Murray A, Thiruvengkatachari B, et al. Effectiveness of 3 methods of anchorage reinforcement for maximum anchorage in adolescents: a 3-arm multicenter randomized clinical trial. *Am J Orthod Dentofacial Orthop*. 2014;146:10–20.
- Lee J, Miyazawa K, Tabuchi M, et al. Midpalatal miniscrews and high-pull headgear for anteroposterior and vertical anchorage control: cephalometric comparisons of treatment changes. *Am J Orthod Dentofacial Orthop*. 2013;144:238–250.

10. Hourfar J, Ludwig B, Bister D, et al. The most distal palatal ruga for placement of orthodontic mini-implants. *Eur J Orthod.* 2015;37:373–378.
11. Wilmes B, Nienkemper M, Ludwig B, et al. Upper-molar intrusion using anterior palatal anchorage and the Mousetrap appliance. *J Clin Orthod.* 2013;47:314–320.
12. Wiechmann D, Schwestka-Polly R, Pancherz H, et al. Control of mandibular incisors with the combined Herbst and completely customized lingual appliance—a pilot study. *Head Face Med.* posted 11 March 2010;6:3.
13. Byloff FK, Darendeliler MA. Distal molar movement using the pendulum appliance. Part I. Clinical and radiological evaluation. *Angle Orthod.* 1997;67:249–260.
14. Cornelis MA, De Clerck HJ. Maxillary molar distalization with miniplates assessed on digital models: a prospective clinical trial. *Am J Orthod Dentofacial Orthop.* 2007;132:373–377.
15. Hourfar J, Ruff CJ, Wilmes B, Ludwig B, Kanavakis G. Rapid maxillary expansion and upper-molar distalization with a miniscrew-supported hybrid appliance. *J Clin Orthod.* 2016;50(8):476–484.
16. Duran GS, Görgülü S, Dindaroğlu F. Three-dimensional analysis of tooth movements after palatal miniscrew-supported molar distalization. *Am J Orthod Dentofacial Orthop.* 2015;150:188–197.
17. Kook YA, Bayome M, Trang VT, et al. Treatment effects of a modified palatal anchorage plate for distalization evaluated with cone-beam computed tomography. *Am J Orthod Dentofacial Orthop.* 2014;146:47–54.
18. Moffitt AH. Eruption and function of maxillary third molars after extraction of second molars. *Angle Orthod.* 1998;68:147–152.
19. Rinchuse DJ, Rinchuse DJ, Kandasamy S. Evidence-based versus experience-based views on occlusion and TMD. *Am J Orthod Dentofacial Orthop.* 2005;127:249–254.
20. Northway WM. The nuts and bolts of hemisection treatment: managing congenitally missing mandibular second premolars. *Am J Orthod Dentofacial Orthop.* 2005;127:606–610.
21. Kook YA, Park JH, Bayome M, et al. Distalization of the mandibular dentition with a ramal plate for skeletal Class III malocclusion correction. *Am J Orthod Dentofacial Orthop.* 2016;150:364–377.



# Comprehensive Treatment: Finishing

## CHAPTER OUTLINE

### Adjustment of Individual Tooth Positions

- Midline Discrepancies
- Tooth Size Discrepancies
- Root Parallelism
- Torque

### Correction of Vertical Incisor Relationships

- Excessive Overbite
- Anterior Open Bite

### Final “Settling” of Teeth

- Methods for Settling the Teeth Into Ideal Occlusion
- Control of Rebound and Posturing
- Removal of Bands and Bonded Attachments

### Positioners for Finishing

### Special Finishing Procedures to Avoid Relapse

- Control of Unfavorable Growth
- Control of Rebound After Tooth Movement

### Micro-Esthetic Procedures in Finishing

- Recontouring the Gingiva to Improve Tooth Proportions and Display
- Reshaping the Teeth for Enhanced Esthetics

After the teeth are well aligned, extraction spaces are closed with tooth roots reasonably parallel, deep bite or open bite has been corrected, and the teeth in the buccal segments are in a normal Class I relationship, the final stage of treatment is to get the details correct.

In the Begg technique, major root movements of both anterior and posterior teeth still remained to be done at the finishing stage, to obtain root paralleling at extraction sites and proper torque and axial inclination of tipped incisors, and this was accomplished with auxiliary springs. In the modern modified Begg technique, using Tip-Edge brackets, auxiliary springs are augmented with rectangular archwires in stage 3 (Fig. 17.1).

With contemporary edgewise techniques, much less treatment remains to be accomplished at the finishing stage, but minor versions of these same root movements are likely to be required. In addition, in most cases some adjustment of individual tooth positions is required in order to get marginal ridges level, obtain precise in–out positions of teeth within the arches, and generally overcome any discrepancies produced by errors in either bracket placement or appliance prescription. In some cases, it is necessary to alter the vertical relationship of incisors as a finishing procedure, either

correcting moderately excessive overbite or closing a mild anterior open bite. The focus is not just on dental alignment and occlusion—the appearance of the teeth also must be kept in mind.

Although many variations are inevitable to meet the demands of specific cases, it is possible to outline a logical sequence of archwires for continuous arch edgewise technique, and this has been attempted in Box 17.1. The sequence is based on two concepts: (1) that the most efficient archwires should be used, so as to minimize clinical adjustments and chair time, and (2) that it is necessary to fill (or nearly fill) the bracket slot in the finishing stage with appropriately flexible wires to take full advantage of the modern appliance. That means that at this stage the wires should be  $17 \times 25$  in 18-slot brackets and  $21 \times 25$  in 22-slot brackets; the desired degree of bending or torsional stiffness is varied by using different archwire materials. Appropriate use of the recommended finishing archwires and variations to deal with specific situations in finishing are reviewed in some detail later.

## Adjustment of Individual Tooth Positions

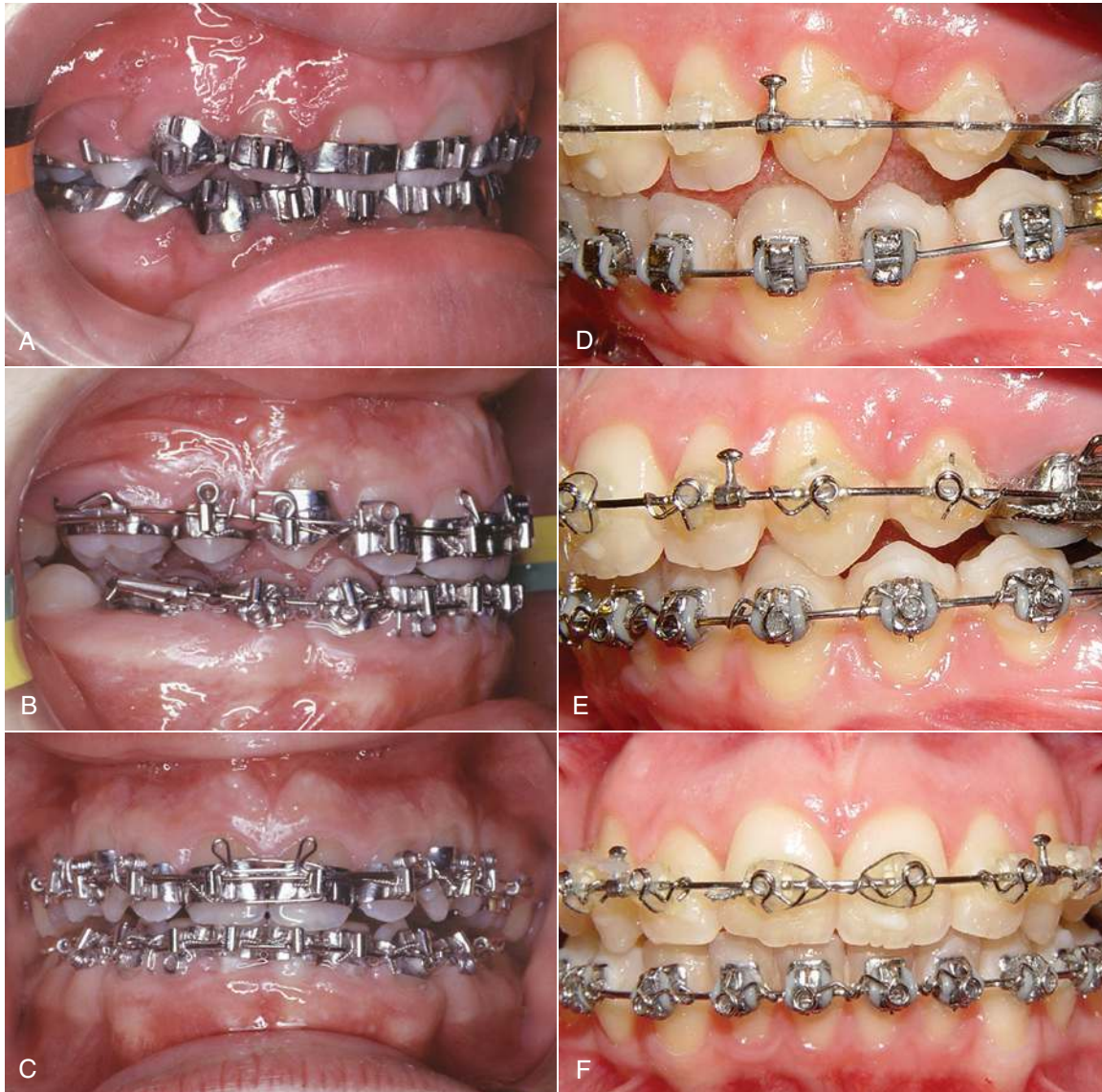At the finishing stage of treatment, it is likely that up–down and in–out relationships of some teeth will need minor change, and the root position of some teeth may require adjustment (whether teeth were extracted or not). If the appliance prescription and bracket positioning were perfect, such adjustments would be unnecessary. Given the variations in both individual tooth anatomy and bracket placement that are encountered frequently, in many cases some adjustment of tooth positions is needed at this point.

When it becomes apparent that a bracket is poorly positioned, usually it is time-efficient to rebond the bracket rather than place compensating bends in archwires. This is particularly true when the inclination of the tooth is incorrect so that angulated step bends in wires would be required. After the bracket is rebonded, however, a flexible wire must be placed to bring the tooth to the correct position. Rectangular steel finishing wires are too stiff in bending for tooth positioning for both the 18- and the 22-slot appliances. In the 18-slot appliance,  $17 \times 25$  beta-titanium (beta-Ti) usually is satisfactory. In the 22-slot appliance,  $21 \times 25$  martensitic nickel–titanium (M-NiTi) often is the best choice;  $21 \times 25$  beta-Ti is too stiff in bending, and smaller TMA wires fit too loosely in the bracket. Minor in–out and up–down adjustments, typically to obtain perfect canine interdigitation and level out marginal ridge heights, can be performed simply and easily by placing mild step bends in the finishing archwires.

If the choice is step bends, they must be placed in a flexible full-dimension wire, the next-to-last wire in the typical sequence shown in Box 17.1. Obviously, any step bends placed in the next-to-last wire ( $17 \times 25$  beta-Ti or  $21 \times 25$  M-NiTi) must be repeated in the final wire that is used for torque ( $17 \times 25$  steel or  $21 \times 25$  beta-Ti). Note that NiTi archwires (both M-NiTi and austenitic

**Stage 3, finishing, in a patient treated in the 1970s with classic Begg technique.**

**Stage 3, finishing, in a patient treated in the 2005-2010 era with Tip-Edge.**



• **Fig. 17.1** Stage 3, Finishing, Comparing a Patient Treated With the Classic Begg Technique in the 1970s with One Treated in the 2005-2010 Era With Tip-Edge, a Successor to Classic Begg. (A) The Begg appliance in a patient who has undergone premolar extraction and space closure and is ready for the finishing stage of treatment. Note the ribbon arch bracket turned upside down from the way Edward Angle positioned it. Archwires are pinned into place. (B) Uprighting springs and a torquing arch in place. The uprighting springs (used here on lateral incisors, canines, and second premolars) fit into the vertical tube portion of the bracket and are hooked underneath the base archwire to create root-positioning moments. An auxiliary torquing arch is threaded over the archwire and places a lingual force against the tooth above the bracket slot. (C) Anterior view of the torquing arch and uprighting springs. **Stage 3, Finishing, in a Patient Treated in the 2005-2010 Era With Tip-Edge.** (D) The finishing stage of treatment with Tip-Edge, a modern extension of the Begg appliance, after tipping the teeth to close space and retract protruding incisors in this patient with Class II problems who had upper premolar extractions. (E) Auxiliary uprighting “SideWinder” springs (seen here on the maxillary lateral incisor, canine, and second premolar) are used for root positioning, with a different type of spring for the incisors where torque is desired, and a rectangular archwire serves as a template and prevents overcorrection. Note the improvement in both inclination of incisors and root paralleling at the extraction sites. (F) Frontal view. Note that the auxiliary spring for torque to incisors now is quite different from the Begg torquing arch or its equivalent for use as an edgewise auxiliary (see Fig. 17.6).

### • BOX 17.1 Sequence of Archwires, Continuous Arch Edgewise Technique

#### 18-Slot Appliance

##### Nonextraction

14 or 16 superelastic NiTi (A-NiTi)  
 16 steel (accentuated/reverse curve)  
 17 × 25 M-NiTi (only if roots displaced)  
 17 × 25 beta-Ti  
 17 × 25 steel

##### Extraction

14 or 16 superelastic NiTi  
 16 steel (accentuated/reverse curve)  
 16 × 22 closing loops  
 17 × 25 beta-Ti (if roots displaced, usually needed)  
 17 × 25 steel

#### 22-Slot Appliances

##### Nonextraction

16 A-NiTi  
 16 steel (accentuated/reverse curve)  
 18 steel (accentuated/reverse curve)  
 21 × 25 M-NiTi  
 21 × 25 beta-Ti

##### Extraction

16 A-NiTi  
 16 steel (accentuated/reverse curve)  
 18 steel (accentuated/reverse curve)  
 19 × 25 steel, A-NiTi coil springs  
 or 18 × 22 steel T-loop or 19 × 25 beta-Ti delta loop  
 21 × 25 M-NiTi (if roots displaced, usually needed)  
 21 × 25 beta-Ti

*For a typical adolescent patient with malocclusion of moderate severity. (Wire sizes in mil.)*

A-NiTi, Austenitic (superelastic) NiTi; beta-Ti, beta-titanium (TMA); M-NiTi, martensitic (elastic, not superelastic) NiTi; NiTi, nickel–titanium.

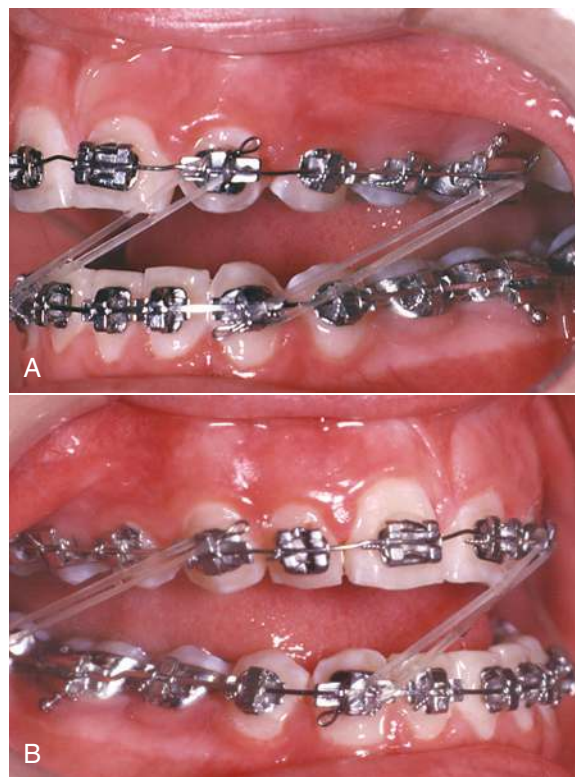
nickel–titanium [A-NiTi]) are *not* recommended for torquing. They simply do not have the torsional properties to be effective (see Chapter 9).

Although the position of a V-bend relative to the adjacent brackets is critical in determining its effect, the position of a step bend is not a critical variable. It makes no difference whether a step bend is in the center of the interbracket span or offset to either side.

### Midline Discrepancies

A relatively common problem at the finishing stage of treatment is a discrepancy in the midlines of the dental arches. This can result from either a preexisting midline discrepancy that was not completely resolved at an earlier stage of treatment or asymmetric closure of spaces within the arch. Minor midline discrepancies at the finishing stage are no great problem, but it is quite difficult to correct large discrepancies after extraction spaces have been closed and occlusal relationships have been nearly established.

As with any discrepancy at the finishing stage, it is important to establish as clearly as possible exactly where the discrepancy arises. Although coincident dental midlines are a component of functional occlusion—all other things being equal, a midline discrepancy will be reflected in how the posterior teeth fit together—it is undesirable esthetically to displace the maxillary midline,



• **Fig. 17.2** (A and B) Midline correction can be approached with any combination of asymmetric posterior and anterior diagonal elastics. In this patient, a combination of Class II, Class III, and anterior diagonal elastics is being used (a “parallel elastics” arrangement), with a rectangular archwire in the lower arch and a round wire in the upper arch, in an attempt to shift the maxillary arch to the right.

bringing it around to meet a displaced mandibular midline. If a dental midline discrepancy results from a skeletal asymmetry, it may be impossible to correct it orthodontically, and treatment decisions will have to be made in the light of camouflage versus surgical correction (see discussion in Chapter 7).

Fortunately, midline discrepancies in the finishing stage usually are not this severe and are caused only by lateral displacements of maxillary or mandibular teeth that are likely to be accompanied by a mild Class II or Class III relationship on one side. In this circumstance, the midline often can be corrected by using asymmetric Class II (or Class III) elastic force. As a general rule, it is more effective to use Class II or Class III elastics bilaterally with heavier force on one side than to place a unilateral elastic. However, if one side is totally corrected while the other is not, patients usually tolerate a unilateral elastic reasonably well. It is also possible to combine a Class II or Class III elastic on one side with a diagonal elastic anteriorly to bring the midlines together (Fig. 17.2). This approach should be reserved for small discrepancies because asymmetric elastic use has asymmetric vertical side effects capable of producing an unesthetic anterior occlusal plane cant. Prolonged use of Class II or Class III elastics during the finishing stage of treatment should be avoided. Coordinated steps in the archwires also can be used to shift the teeth of one arch more than the other.<sup>1</sup>

An important consideration in dealing with midline discrepancies is the possibility of a mandibular shift contributing to the discrepancy. This can arise easily if a slight discrepancy in the transverse position of posterior teeth is present. For instance, a slightly narrow



maxillary right posterior segment can lead to a shift of the mandible to the left on final closure, creating the midline discrepancy. The correction in this instance, obviously, must include some force system to alter the transverse arch relationships (usually careful coordination of the maxillary and mandibular archwires, perhaps reinforced by a posterior cross-elastic). Occasionally, the entire maxillary arch is slightly displaced transversely relative to the mandibular arch so that with the teeth in occlusion, relationships are excellent, but there is a lateral shift to reach that position. Correction again would involve posterior cross-elastics but in a parallel pattern (i.e., from maxillary lingual to mandibular buccal on one side and the reverse on the other side; see Fig. 17.2B).

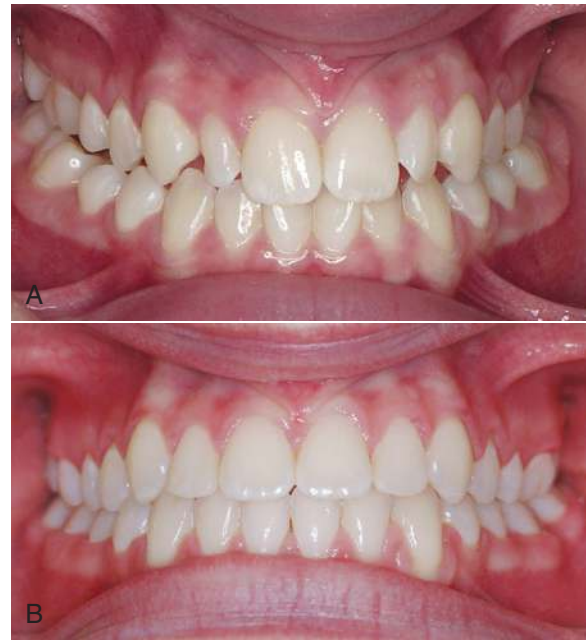## Tooth Size Discrepancies

Correction of tooth size discrepancy or compensation for it must be part of the initial treatment plan, but many of the steps to deal with these problems are taken in the finishing stage of treatment.<sup>2</sup> Interproximal enamel reduction (IPR) is the usual strategy to compensate for discrepancies caused by excess tooth size. When the problem is tooth size deficiency, it is necessary to leave space between some teeth, which may or may not ultimately be closed by restorations. As a general guideline, a 2-mm tooth size discrepancy noted from Bolton analysis is the threshold for clinical significance<sup>3</sup> (i.e., it is predicted that that large a discrepancy will necessitate steps to deal with it during treatment), but at the finishing stage, you get to see how accurate the prediction really was.

One of the advantages of a bonded appliance is that interproximal enamel can be removed at any time. When IPR is part of the original treatment plan, most of the enamel reduction should be done initially, but final reduction can be deferred until the finishing stage. This procedure allows direct observation of the occlusal relationships before the final tooth size adjustments are made. A topical fluoride treatment always is recommended immediately after stripping is done.

Tooth size problems often are caused by small maxillary lateral incisors. Leaving a small space distal to the lateral incisor can be esthetically and functionally acceptable, but a composite resin buildup usually is the best plan for small incisors (Fig. 17.3). Precise finishing is easier if the buildup is done during the finishing stage of the orthodontic treatment. This can be accomplished simply by removing the bracket from the small tooth or teeth for a few hours while the restoration is done, then replacing the bracket and archwires (but bonding to a laminate may damage the surface, so a buildup to establish tooth size is okay, but a laminate should be delayed). It is important to verify that the root position is close to ideal before restoration, because change in root position after buildup can alter esthetics by changing contact points and embrasure relationships. If the restoration is delayed until the orthodontic treatment is completed, it should be done as soon as possible after the patient is in retention. This requires an initial retainer to hold the space, and a new retainer immediately after the restoration is completed. The main reason for waiting until after the orthodontic appliance has been removed would be to allow any gingival inflammation to resolve itself.

More generalized small deficiencies can be masked by altering incisor position in any of several ways. To a limited extent, torque of the upper incisors can be used to compensate: leaving the incisors slightly more upright makes them take up less room relative to the lower arch and can be used to mask large upper incisors, whereas slightly excessive torque can partially compensate for small upper incisors. These adjustments require third-order bends in the finishing



• **Fig. 17.3** Small maxillary lateral incisors create tooth-size discrepancy problems that may become apparent only late in treatment. (A) Small maxillary lateral incisors, one of which is distorted, before treatment. (B) After treatment in which space was created mesial and distal to the laterals so that laminates could be placed to bring the teeth to normal size and appearance.

archwires, done manually or as a new archwire from altering the wire prescription in SureSmile and similar systems for robotic wire-bending. It is also possible to compensate by slightly tipping teeth or by finishing the orthodontic treatment with mildly excessive overbite or overjet, depending on the individual circumstances.<sup>4</sup>

## Root Paralleling

In the original Begg technique (see Fig. 17.1A–C), the moments necessary for root positioning were generated by adding auxiliary springs into the vertical slot of the Begg (ribbon arch) bracket. In the modified Begg technique using the Tip-Edge appliance, root paralleling is accomplished with uprighting springs, very much as it was with traditional Begg treatment (see Fig. 17.1D–F). Rectangular wire is used primarily for torque (faciolingual root movement), not the mesiodistal root movement needed for root paralleling after teeth were allowed to tip during space closure.

During space closure with the edgewise appliance, it is almost always a goal of treatment to produce bodily tooth movement, preventing the crowns from tipping toward each other. If proper moment-to-force ratios have been used, little if any root paralleling will be necessary as a finishing procedure. On the other hand, it is likely that at least a small amount of tipping will occur in some patients and therefore some degree of root paralleling at extraction sites often will be necessary. If brackets were not oriented correctly at the time of placement, root separation or paralleling may be needed in nonextraction cases (this is most likely on maxillary lateral incisors and premolars). It is wise to obtain a panoramic radiograph when major tooth movement has been completed, to check for both root positioning errors and root resorption that might dictate ending treatment early or taking a break from the final active treatment for 3 to 4 months to allow cementum to heal.

The same approach used for root positioning in Begg technique can be employed with the edgewise appliance if it includes a vertical slot behind the edgewise bracket that allows an uprighting spring to be inserted and hooked beneath a base archwire. When only steel archwires were available, this approach often was used, but in contemporary edgewise practice, it has been almost totally abandoned in favor of angulated bracket slots that produce proper root paralleling when a flexible full-dimension rectangular wire is placed.

With the 18-slot appliance, the typical finishing archwire is either  $17 \times 22$  or  $17 \times 25$  steel. These wires are flexible enough to engage narrow brackets even if mild tipping has occurred, and the archwire will generate the necessary root paralleling moments. If a greater degree of tipping has occurred, a more flexible full-dimension rectangular archwire is needed. To correct more severe tipping, a  $17 \times 25$  beta-Ti (TMA) or even a  $17 \times 25$  nickel-titanium (M-NiTi, not superelastic A-NiTi) wire might be needed initially, with a steel archwire used for final expression of torque.

With wider 22-slot brackets on the canines and premolars and with the use of sliding rather than loop mechanics to close extraction sites, there is usually even less need for root paralleling as a finishing procedure. But with 22-slot brackets, if teeth have tipped even slightly into an extraction space or if other root-positioning is needed, steel archwires ( $19 \times 25$  steel, for instance) are much too stiff. A  $21 \times 25$  beta-Ti wire is the best choice for a finishing archwire under most circumstances, and if significant root positioning is needed,  $21 \times 25$  M-NiTi should be used first.

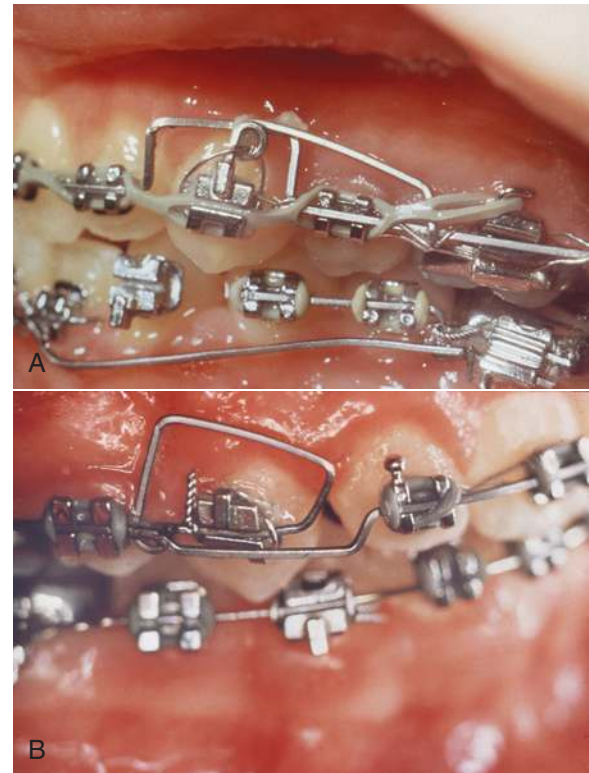
Although superelastic NiTi (A-NiTi) wires perform much better than elastic NiTi (M-NiTi) wires in alignment, this is not true of their performance as rectangular finishing wires. The great advantage of A-NiTi is its very flat load-deflection curve, which gives it a large range. In the finishing stage, however, appropriate stiffness at relatively small deflections, rather than range, is the primary consideration. A-NiTi wires usually deliver less force than their M-NiTi counterparts (this will depend on how the manufacturer manipulated the wire as it was produced [see Chapter 9]), and if rectangular NiTi wires are used in the finishing stage, M-NiTi almost always is the better choice. Why? Because it provides adequate force for root movement and less range, both of which are needed for precise tooth positioning. Occasionally, a severely tipped tooth will be encountered (almost always because of a bracket positioning error), and a greater range of action is needed. This may indicate use of a rectangular A-NiTi wire initially, then M-NiTi. An alternative, usually practical only if the edgewise brackets have a vertical slot or tube, is a Burststone auxiliary root-uprighting spring (Fig. 17.4).

A root-parallelizing moment is a crown-separating moment in edgewise technique just as it is in any other technique. Either the teeth must be tied together or the entire archwire must be tied back against the molars (Fig. 17.5) to prevent spaces from opening. Not only extraction sites but also maxillary incisors must be protected against this complication. When a full-dimension rectangular wire is placed in the maxillary arch, spaces are likely to open between the incisors in nonextraction as well as extraction cases. Tying the maxillary incisors together, which can be done conveniently with a segment of elastomeric chain from the mesial bracket of one upper lateral incisor across to the mesial bracket of the other, is necessary during finishing.

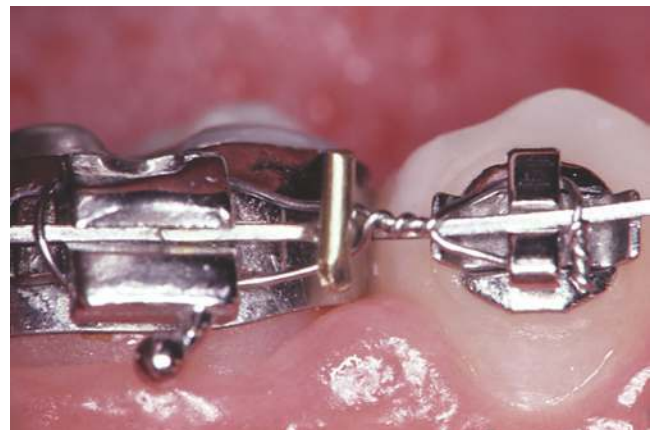## Torque

### Lingual Root Torque of Incisors

If protruding incisors tipped lingually more than desired while they were being retracted, lingual root torque as a finishing procedure



• **Fig. 17.4** (A) An uprighting spring to the maxillary canine, placed in a vertical tube incorporated into the canine bracket, in segmented arch technique. Note that the base archwire bypasses the canine. (B) An auxiliary root-positioning spring welded to the base archwire and tied into the edgewise bracket slot of a maxillary canine, with the base archwire bypassing the canine. Both approaches remain useful for correction of severe root paralleling problems, but with the introduction of contemporary straight-wire appliances, use of auxiliary uprighting springs in edgewise technique has largely been replaced by resilient nickel-titanium (NiTi) or beta-titanium (beta-Ti) continuous archwires in preangulated brackets. (Courtesy Dr. C. Burststone.)



• **Fig. 17.5** A rectangular archwire that incorporates active root paralleling moments or torque must be tied back against the molar teeth to prevent space from opening within the arch. If the ligature used to tie back the archwire is cabled forward and also used to tie the second premolar, the tieback is less likely to come loose.




may be required. In the Begg technique, the incisors were deliberately tipped back during the second stage of treatment, and lingual root torque was a routine part of the third stage of treatment. As with root paralleling, this was accomplished with an auxiliary appliance that fit over the main or base archwire. The torquing auxiliary is a “piggyback arch” that contacts the labial surface of the incisors near the gingival margin, creating the necessary couple with a moment arm of 4 to 5 mm (see Fig. 17.1C).

These piggyback torquing arches can be used in edgewise technique in the same way (see Fig. 15.30D). Although they come in several designs, the basic principle is the same: the auxiliary arch, bent into a tight circle initially, exerts a force against the roots of the teeth as it is partially straightened out to normal arch form (Fig. 17.6).

A torquing force to move the roots lingually is also, of course, a force to move the crowns labially (see Fig. 16.3). In a typical patient with a Class II malocclusion, anchorage is required to maintain overjet correction while upper incisor roots are torqued lingually. For that reason, Class II elastics are likely to be necessary when active lingual root torque is needed during the final stage of Class II treatment.

With a modern edgewise appliance, only moderate additional incisor torque should be necessary during the finishing stage. With the 18-slot appliance, a 17 × 25 steel archwire has excellent properties in torsion, and torque with this archwire is entirely feasible. Built-in torque in the bracket slot means that it is unnecessary to place torquing bends in the archwire, making the accomplishment of torque as a finishing procedure relatively straightforward.

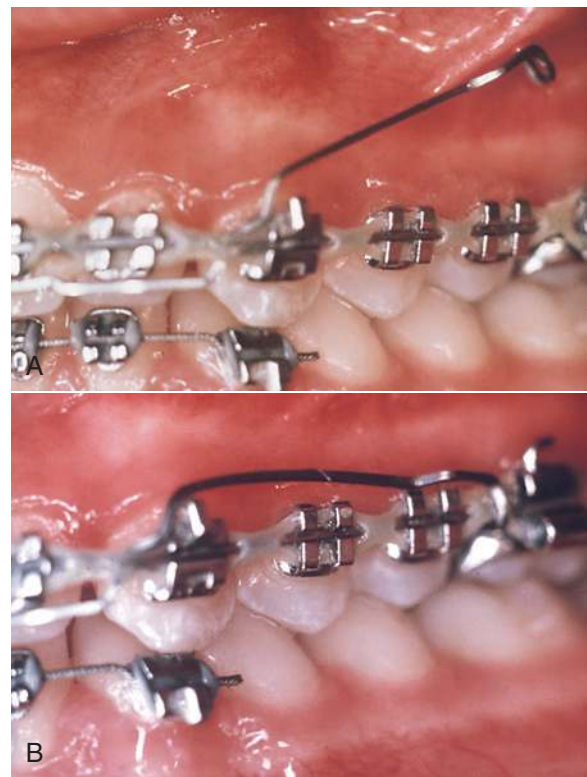
With the 22-slot appliance, full-dimension steel rectangular wires are far too stiff for effective torquing (see Fig. 9.11). If incisors have been allowed to tip lingually too much, correcting this merely by placing a rectangular steel archwire in a torque-prescription bracket is not effective because the wire creates too much torsional force and has a very limited range. Before brackets with built-in torque and titanium archwires were available, torquing auxiliaries were commonly used with the 22-slot appliance. One of the great virtues of torque-slot brackets is that tipping of incisors, for the most part, can be prevented during retraction and space closure.



• **Fig. 17.6** Torquing auxiliary archwires exert their effect when the auxiliary, originally bent in a tight circle as shown, is forced to assume the form of a base archwire over which it will be placed. This tends to distort the base archwire, which therefore should be relatively stiff—at least 18-mil steel.

In addition, full-dimension M-NiTi or beta-Ti archwires can be used to torque incisors with 22-slot brackets (provided the brackets have torque built in), further reducing any need for auxiliary arches. For these reasons, torquing auxiliaries for 22-slot edgewise have almost disappeared from contemporary use, except when upright incisors are to be corrected by tipping the crowns facially. The auxiliaries are probably the best way to do this.

One torquing auxiliary, however, deserves special mention: the Burstone torquing arch (Fig. 17.7). It can be particularly helpful in patients with Class II division 2 malocclusion whose maxillary central incisors are severely tipped lingually and require a long distance of torquing movement, while the lateral incisors need little if any torque. Because of the long lever arm, this is the most effective auxiliary. It is equally effective with the 18- or 22-slot appliance. If all four incisors need considerable torque, use of a wire spanning from the molar auxiliary tube to the incisors, with a V-bend so that the incisor segment receives the greater moment, is a highly efficient approach.<sup>9</sup>



• **Fig. 17.7** The Burstone torquing auxiliary (also see Fig. 9.44) is particularly useful in Class II division 2 cases in which maxillary central incisors need a large amount of torque. The torquing auxiliary is full-dimension steel wire (21 × 25 or 17 × 25, in 22- or 18-slot brackets, respectively) that fits in the brackets only on the incisors. It can be used only on the centrals or on the centrals and laterals, as shown here. The base arch (preferably also full-dimension rectangular wire) extends forward from the molars through the canine or lateral incisor brackets, then steps down and rests against the labial surface of the teeth to be torqued. When the torquing auxiliary is passive (A), its long posterior arms are up in the buccal vestibule. It is activated (B) by pulling the arms down and hooking them beneath the base archwire mesial to the first molar. The segment of the base arch that rests against the labial surface of the central incisors is tied back to the molar buccal tubes (see Fig. 17.5), which prevents the crowns from going forward, and the result is efficient lingual root torque.



Three factors determine the amount of torque that will be expressed by any rectangular archwire in a rectangular slot: the torsional stiffness of the wire, the inclination of the bracket slot relative to the archwire, and the tightness of the fit between the archwire and the bracket. The variations in torque prescriptions in contemporary edgewise brackets are discussed in [Chapter 10](#). These variations largely reflect different determinations of the average contour of the labial and buccal surfaces of the teeth, but some differences are also related to the expected fit of archwires.

With the 18-slot appliance, it is assumed that the rectangular archwires used for finishing will fit tightly in the bracket slot (i.e., that the finishing archwires will have a minimum dimension of 17 mil). With the 22-slot appliance, on the other hand, some prescriptions have extra built-in torque to compensate for rectangular finishing archwires that will have more clearance. Torque will not be expressed to the same extent with a  $19 \times 25$  wire in a 22-slot bracket as with a  $17 \times 25$  wire in an 18-slot bracket. The difference amounts to several degrees of difference in incisor inclination. The “effective torque” of various wire-bracket combinations is shown in [Table 17.1](#). Obviously, when the torque prescription for a bracket is established, it is important to know what finishing wires are intended.

For full expression of the torque built into brackets in the 22-slot appliance, the best finishing wire usually is  $21 \times 25$  beta-Ti. This wire's torsional stiffness is less than that of  $17 \times 25$  steel (see [Fig. 9.11](#)), but the shorter interbracket distances with 22-slot twin brackets bring its performance in torsion close to that of the smaller steel wire. Braided rectangular steel wires are available in a variety of stiffnesses, and the stiffest of these in  $21 \times 25$  dimension also can be useful in 22-slot finishing. A solid  $21 \times 25$  steel wire cannot be recommended because of its stiffness and the resulting extremely high forces and short range of action. If a solid steel wire of this

size is used (the major reason would be surgical stabilization), it should be preceded by  $21 \times 25$  beta-Ti.

Some clinicians are reluctant to use full-dimension archwires in 22-slot brackets, but it should be kept in mind that full torque expression will never be achieved with undersized wires without extreme bracket prescriptions or placement of major twist bends in the wires, and even then it is difficult to obtain adequate torque routinely.

### Buccal Root Torque of Premolars and Molars

It should be kept in mind that buccal root torque of maxillary premolars can be an important esthetic consideration in positioning these teeth. It is surprisingly common that at the end of fixed appliance treatment, maxillary canines and premolars are tipped facially because the prescription in many modern brackets provides negative torque (lingual crown torque) for these teeth (see [Table 10.3](#)). Zachrisson has pointed out that this negatively affects smile esthetics, especially in patients with narrow and tapered arch forms, by making the canines less prominent and causing the first premolars to almost disappear on smile. To obtain a broader and more pleasing smile, the solution is not to further expand across the premolars, but to use buccal crown torque so that the crowns are uprighted ([Figs. 17.8](#) and [17.9](#)).<sup>6</sup> This gives the appearance of a broader smile without the risk of relapse that accompanies arch expansion. Long-term data indicate that the inclinations of these teeth remain the way they were at the end of treatment, so changing the torque is stable.<sup>7</sup>

Research into what patients see as important in dental esthetics did not confirm this subtle effect as important in affecting patient perceptions of the appearance of the teeth. Although some lay people noticed it, the majority simply had no idea what they were looking at. Orthodontists are much more likely to appreciate the esthetic effect of this uprighting, which may also provide better interdigitation of first premolar lingual cusps.

### Correction of Vertical Incisor Relationships

If the first two stages of treatment have been accomplished perfectly, no change in the vertical relationship of incisors will be needed during the finishing stage of treatment. Minor adjustments often are needed, however, and major ones occasionally are required. At this stage, anterior open bite is more likely to be a problem than residual excessive overbite, but either may be encountered.

### Excessive Overbite

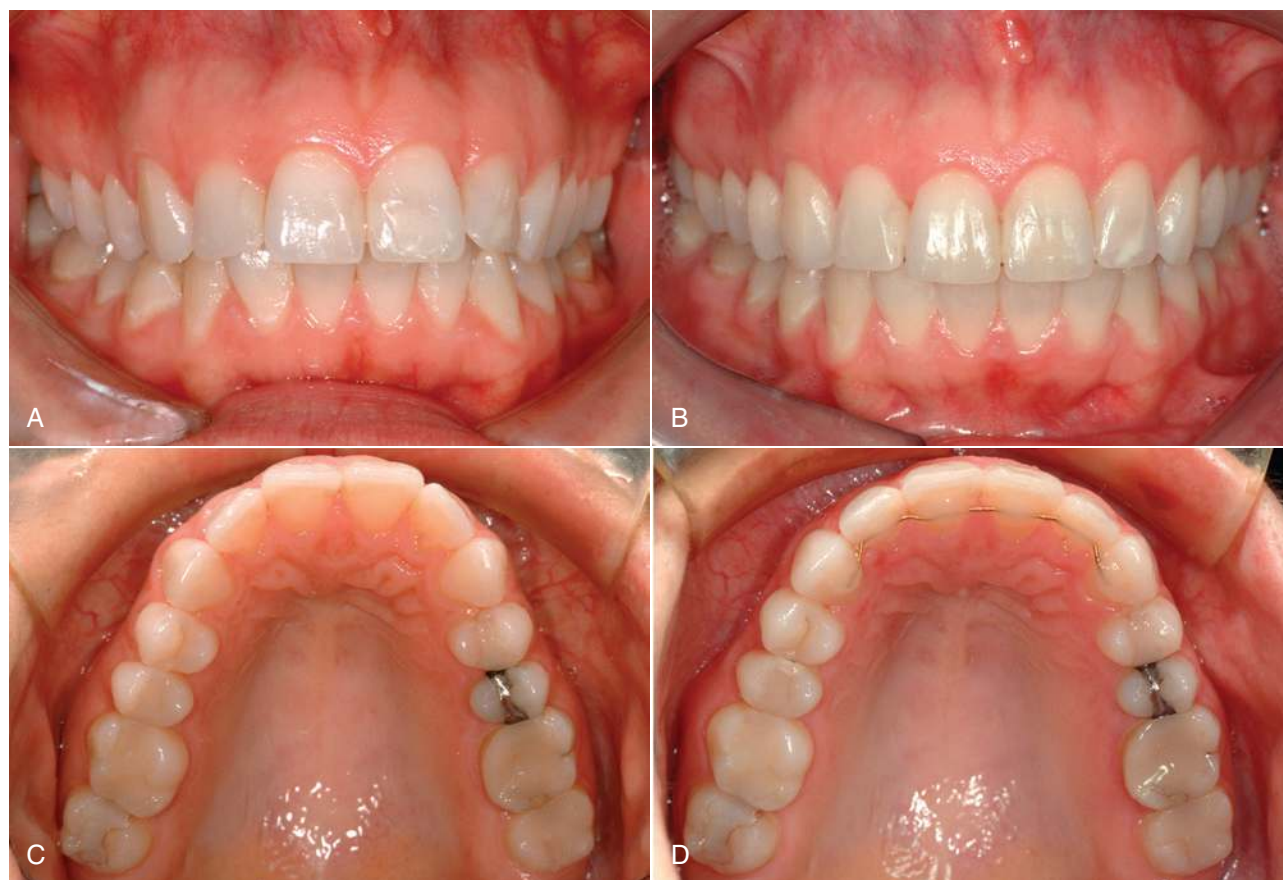Before attempting to correct excess overbite at the finishing stage of treatment, it is important to carefully assess why the problem exists and particularly to evaluate two things: (1) the vertical relationship between the maxillary lip and maxillary incisors and (2) anterior face height. If the display of the maxillary incisors on smile is appropriate, it is important to maintain this and make any overbite correction by repositioning the lower incisors. If display is excessive, intrusion of the upper incisors would be indicated. If face height is short, elongating the posterior teeth slightly (almost always, the lower posterior teeth) would be acceptable; if face height is long, intrusion of incisors would be needed.

If intrusion is indicated and a rectangular finishing archwire is already in place, the simplest approach is to cut this archwire distal to the lateral incisors and install an auxiliary intrusion arch that is tied to this segment in the appropriate place. Remember that when a maxillary auxiliary intrusion arch is used, a stabilizing

**TABLE 17.1** Effective Torque

Wire Size	Play (Degrees)	BRACKET TORQUE ANGLE (DEGREES)		
		10	22	30
		EFFECTIVE TORQUE		
18-Slot Bracket				
16 × 16	10.9	0.0	11.1	19.1
16 × 22	9.3	0.7	12.7	20.7
17 × 25	4.1	5.9	17.9	25.9
18 × 18	1.5	8.5	20.5	28.5
18 × 25	1.0	9.0	21.0	29.0
22-Slot Bracket				
16 × 22	21.9	0	0.1	8.1
17 × 25	15.5	0	6.5	13.5
19 × 25	9.6	0.4	12.4	20.4
21 × 25	4.1	5.9	17.9	25.9
21.5 × 28	1.8	8.2	20.2	28.2

Based on nominal wire and/or slot sizes; actual play is likely to be greater.  
From Semetz. *Kieferorthop Mittell*. 1993;7:13–26.



• **Fig. 17.8** For this patient the maxillary arch looks narrow because the canine and premolars are tipped lingually, but significant expansion across the canines and premolars is not necessary. Instead, torque to the canines and especially to the premolars so that these teeth are uprighted faciolingually without major expansion improves the appearance of the dentition, and the torque changes are stable in a way that expansion is not. (A and B) Before treatment. (C and D) After treatment that included torque to upright the canines and premolars. (Courtesy Dr. B. Zachrisson.)

transpalatal lingual arch may be needed to maintain control of transverse relationships and prevent excessive distal tipping of the maxillary molars (see Fig. 15.23). The greater the desired vertical change in incisor position, the more important it will be to have a stabilizing lingual arch in place and vice versa. Small corrections during finishing usually do not require placement of a lingual arch.

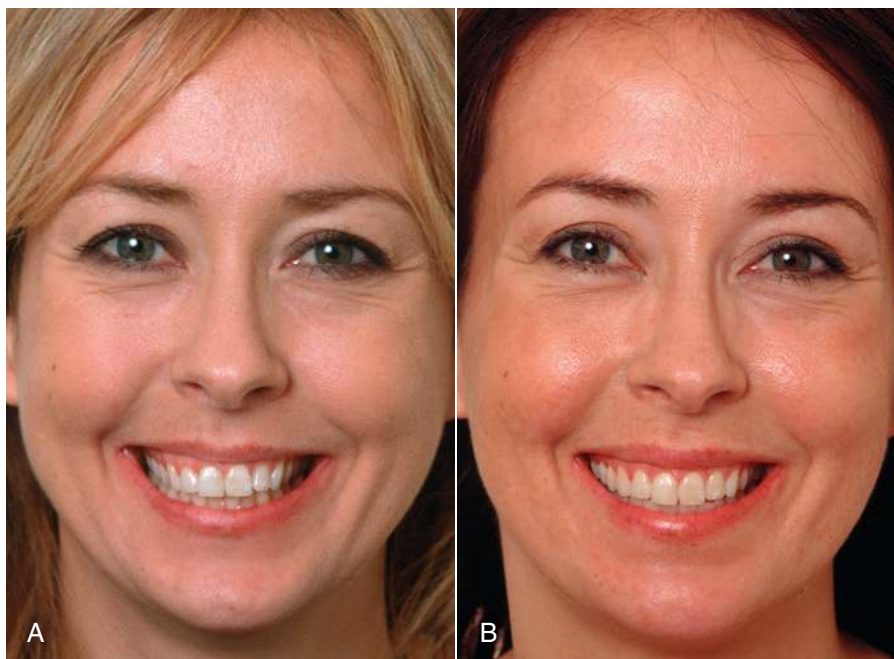Alternatively, if slight elongation of the posterior teeth is indicated, step bends in a flexible archwire would be satisfactory. The intermediate archwire before the final torquing archwire is the one for implementation of these step bends ( $17 \times 25$  TMA with the 18-slot appliance,  $21 \times 25$  M-NiTi with the 22-slot appliance). An auxiliary depressing arch for overbite correction can be effective, but only if the base archwire is a relatively small round wire (see Chapter 15), so this is not the preferred approach for a modest amount of final overbite correction.

### Anterior Open Bite

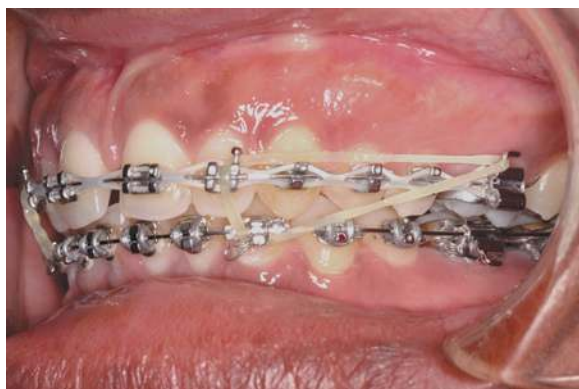As with deep bite, it is important to analyze the source of the difficulty if an anterior open bite persists at the finishing stage of treatment, and as with deep bite, the relationship of the upper incisors to the lip and anterior face height are critical in determining what to do. If the open bite results from excessive eruption of

posterior teeth, whether from a poor growth pattern or excessive use of interarch elastics (Fig. 17.10), correcting it at the finishing stage can be extremely difficult. The most effective approach to intrusion of posterior teeth is skeletal anchorage. Placing miniplates or palatal anchors at the finishing stage to accomplish this implies that the earlier stages of treatment were not completed satisfactorily, but this might be necessary in some patients with a severe long face pattern of growth.

If no severe problems with the pattern of facial growth exist, however, a mild open bite at the finishing stage of treatment often is due to an excessively level lower arch. This condition is managed best by elongating the lower but not the upper incisors, thereby creating a slight curve of Spee in the lower arch. Because of the stiffness of the rectangular archwires used for finishing, even with an 18-slot edgewise appliance, it is futile to use vertical elastics to deepen the bite without altering the form of the archwires. Steps in an appropriately flexible lower archwire, while maintaining a stiffer upper wire, can be effective when supplemented with light vertical elastics (Fig. 17.11). Obviously, if display of the upper incisors is inadequate, elongation of those teeth to close the bite would be indicated, and the same approach with the flexible or stabilizing archwires reversed would be indicated. Elongating the lower incisors to close a moderate anterior open bite is a quite



• **Fig. 17.9** (A and B) Same patient as Fig. 17.8. Note the improvement in smile esthetics and “width of the smile” produced by torque to the canines and premolars. This can be obtained most readily by changing the bracket prescription to decrease or eliminate the negative torque in most current prescription brackets for maxillary canines and premolars (see Table 10.3). (Courtesy Dr. B. Zachrisson.)



• **Fig. 17.10** Class III elastics tend to extrude upper molars, and their use can lead rapidly to the development of anterior open bite. Use of a triangular Class III elastic, as shown here, helps to control the open bite tendency. Class II elastics can do the same thing by extruding lower molars, and the bite opening can be reduced by a similar triangulation. Use of Class III or Class II elastics, of course, presupposes that some elongation of the molars is acceptable.

stable procedure. Elongating the upper incisors is less stable and compromises facial esthetics if it makes them too prominent. This should be kept in mind when vertical repositioning of incisors is planned.

### Final “Settling” of Teeth

At the conclusion of treatment with the edgewise appliance, it is not uncommon for a full-dimension rectangular archwire, no matter

how carefully made, to hold some teeth slightly out of occlusion. The more precisely a stiff finishing archwire fits the brackets and the more bends that have been used to compensate for bracket positioning, the more likely it is that some teeth will be almost but not quite in occlusion. This phenomenon was recognized by the pioneers with the edgewise appliance, who coined the term “arch-bound” to describe it. They found that with precisely fitting wires, it was almost impossible to get every tooth into solid occlusion, although one could come close. From the early days of edgewise treatment to the present, therefore, a final step of bringing the teeth into occlusion, appropriately called “settling” the teeth, has been needed.

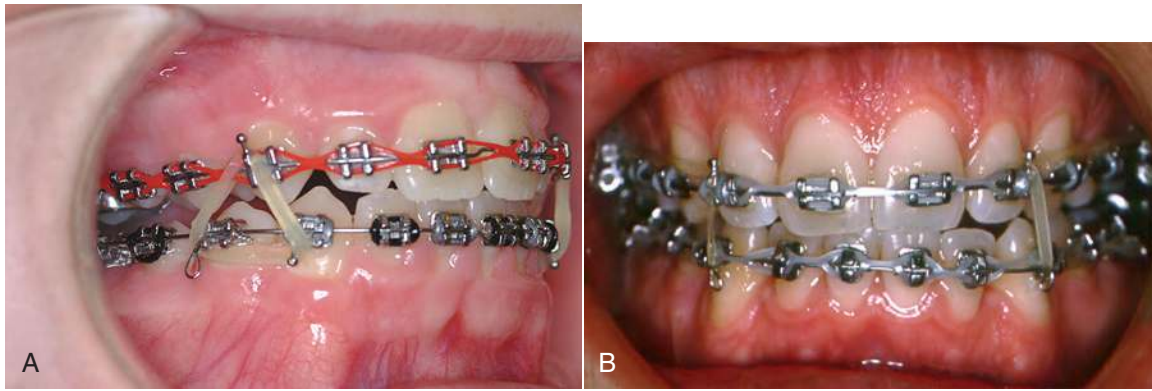
### Methods for Settling the Teeth Into Ideal Occlusion

There are three ways to settle the occlusion:

- Replacing the rectangular archwires at the very end of treatment with light round arches that provide some freedom for movement of the teeth (16 mil in the 18-slot appliance, 16 or 18 mil in the 22-slot appliance) and using light vertical elastics to bring the teeth together
- Using laced posterior vertical elastics after removing the posterior segments of the archwires
- Using a tooth positioner after the bands and brackets have been removed

Replacing full-dimension rectangular wires with light round wires at the very end of treatment was the original method for settling, recommended by Tweed and perhaps by other edgewise pioneers earlier. As we noted earlier, it is simply not correct that when edgewise brackets are used, the final archwires should be full-dimension rectangular ones. That idea went out with Angle—or





• **Fig. 17.11** Vertical elastics, (A) bilaterally in the triangular hook-up shown here in conjunction with an anterior box elastic or (B) as an anterior box elastic alone, can be used to help close a mild anterior open bite at the end of treatment, but this is effective only if the archwires are contoured to allow the tooth movement. Elastics cannot overpower a stiff archwire that is maintaining the open bite.

should have. These light final arches must include any first- or second-order bends used in the rectangular finishing arches. It is usually unnecessary for the patient to wear light posterior vertical elastics during this settling, but they can be used if needed. These light arches will quickly settle the teeth into final occlusion and should remain in place for only a few weeks at most.

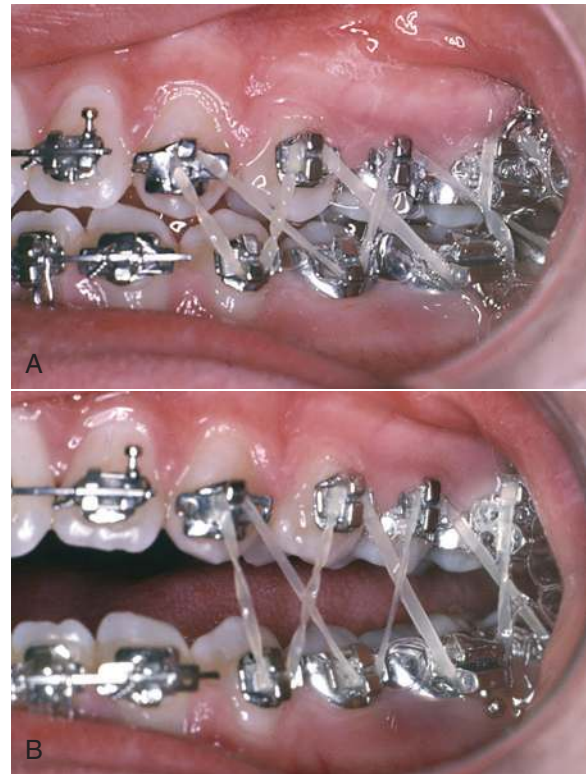
The difficulty with undersized round wires at the end of treatment is that some freedom of movement for settling posterior teeth is achieved, but precise control of anterior teeth is lost. It was not until the 1980s that orthodontists realized the advantage of removing only the posterior part of the rectangular finishing wire, leaving the anterior segment (typically canine-to-canine) in place, and using laced elastics to bring the posterior teeth into tight occlusion (Fig. 17.12).<sup>8</sup> This sacrifices a large degree of control of the posterior teeth and therefore should not be used in patients who had major rotations or posterior crossbite. For the majority of patients who had well-aligned posterior teeth from the beginning, however, this is a remarkably simple and effective way to settle the teeth into their final occlusion. It is the last step in active treatment for most patients at present. Light, not heavy, force is needed.

A typical arrangement is to use light  $\frac{3}{4}$ -inch elastics, with a Class II or Class III direction, depending on whether slightly more correction is desired. An alternative is to use a pair of  $\frac{5}{16}$ - or  $\frac{3}{8}$ -inch interarch elastics on both sides in a vertical triangle. These elastics should not remain in place for more than 2 weeks, and 1 week usually is enough to accomplish the desired settling. At that point the fixed appliances should be removed and the retainers placed.

Because it occurs after the orthodontic appliance has been removed, the use of a tooth positioner for final settling is discussed later after the section on removing bands and bonded brackets.

### Control of Rebound and Posturing

After Class II or Class III correction, the teeth tend to rebound back toward their initial position despite the presence of rectangular archwires. Because of this, it is important to slightly overcorrect the occlusal relationships. In a typical patient with Class II anterior deep bite, the teeth should be taken to an end-to-end incisor relationship, with both overjet and overbite totally eliminated, before discontinuing Class II elastics or another type of Class II



• **Fig. 17.12** (A and B) Laced elastics for settling the posterior teeth into final occlusion at the end of treatment, after the posterior wire segments have been removed. The elastics can be used either with light round archwires or (usually preferred) with rectangular segments in the anterior brackets and no wire at all posteriorly. With this method, the last step in treatment is cutting the rectangular finishing archwires distal to the lateral incisors or canines and removing the posterior segments, followed by 1 to 2 weeks of settling with the light elastics before debonding and debanding.

corrector. This provides some latitude for the teeth to rebound before final settling is accomplished.

Sometimes when Class II elastic force or its equivalent is used, patients begin to posture the mandible forward so that the occlusion looks more corrected than it really is; if the appliances are removed

at that point, the patient is likely to slip back toward a Class II molar relationship and increased overjet. This should not be confused with rebound, which is due only to tooth movement. Rebound is a 1- to 2-mm phenomenon; posturing can lead to 4 to 5 mm of relapse, and obviously it is important to detect it and continue treatment to a true correction.

These considerations lead to the guidelines for finishing treatment when interarch elastics have been used:

- When an appropriate degree of overcorrection has been achieved, the force used with the elastics should be decreased or the wear interval reduced (8 to 12 hours per day) while the elastics are continued for another appointment interval.
- At that point, interarch elastics should be discontinued, 4 to 8 weeks before the orthodontic appliances are to be removed, so that changes due to rebound or posturing can be observed. It is better to tell the patient that he or she is getting a vacation from the elastics and that some further elastic wear may be necessary if changes are observed, rather than saying that elastics are no longer needed. If changes do occur, that makes it easier for patients to accept that the vacation is over and another period of elastics is needed.
- If the occlusion is stable, as a final step in treatment the teeth should be brought into a solid occlusal relationship without heavy archwires present by using one of the methods described earlier.

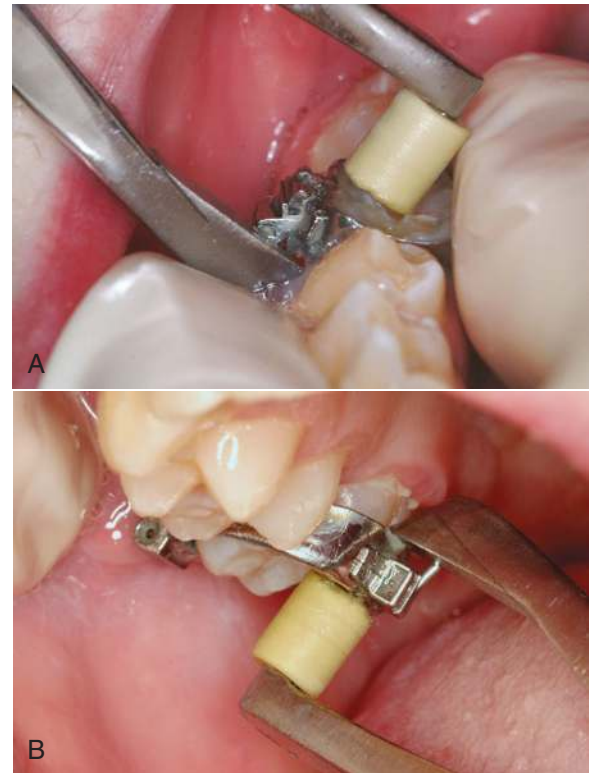### Removal of Bands and Bonded Attachments

Removal of bands is accomplished by breaking the cement attachment and then lifting the band off the tooth, which sounds simpler than it is in some instances. For upper molar and premolar teeth, a band-removing instrument is placed so that first the lingual then the buccal surfaces are elevated (Fig. 17.13). A welded lingual bar is needed on these bands to provide a point of attachment for the pliers if lingual hooks or cleats are not a part of the appliance. For the lower posterior teeth, the sequence of force is just the reverse: the band remover is applied first on the buccal then on the lingual surface.

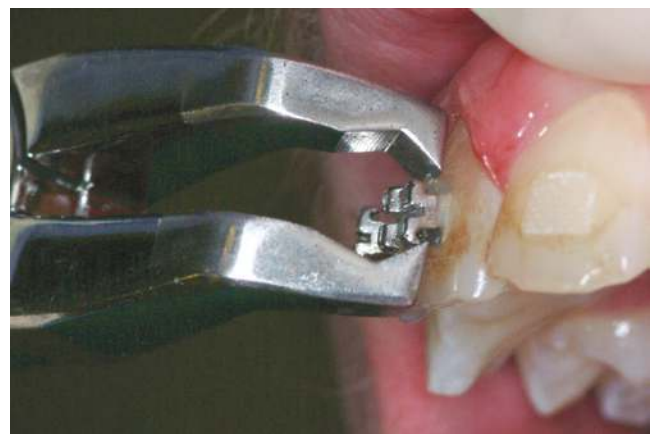Bonded brackets must be removed, insofar as possible, without damaging the enamel surface. This is done by creating a fracture within the resin bonding material or between the bracket and the resin, and then removing the residual resin from the enamel surface. With metal brackets, applying special pliers to the base of the bracket so that the bracket bends (Fig. 17.14) is the safest method. This has the disadvantage of destroying the bracket so that it cannot be reused, but protecting the enamel usually is a more important consideration.

Enamel damage from debonding metal brackets has been considered rare, but soon after ceramic brackets were introduced, there were reports of enamel fractures and removal of chunks of enamel when they were debonded (see Chapter 10 for a more detailed discussion). A recent study evaluated how frequently enamel fragments were found on the bracket base of mechanically debonded maxillary anterior teeth (canine-to-canine).<sup>9</sup> Data from this study are summarized in Table 17.2.

The differences between the groups for enamel damage and bracket fracture are statistically significant and clearly show that damage at debonding is more likely with ceramic than metal brackets. The damage rate with ceramic brackets was significantly less for ceramic brackets bonded with a resin-modified glass ionomer cement (which is discussed in some detail in Chapter 10). The size of the enamel fragments varied with both types of



• **Fig. 17.13** Removal of molar bands with band-removing pliers. (A) Lower posterior bands are removed primarily with pressure from the buccal surface. (B) Upper posterior bands are removed with pressure primarily against the lingual surface, which is easier when a lingual tube (as shown here), cleat, or other attachment was welded to the band initially.



• **Fig. 17.14** Removal of bonded brackets. Special pliers can be used to fracture the bonding resin, which usually results in much of the resin being left on the tooth surface. This works particularly well with twin brackets. The advantage of this method is that the bracket usually is undamaged; the disadvantage is heavy force may cause enamel damage. The alternative is to use a cutter to distort the bracket base. The first approach is more compatible with recycling of brackets, but the second is safer and usually leaves less resin to remove from the tooth surface.

brackets. Only a few patients (4%) had what would be considered major damage.

These data confirm previous reports that it also is easy to fracture a ceramic bracket while attempting to remove it, and if that happens, large pieces of the bracket must be ground away with a diamond



**TABLE 17.2** Enamel Presence on Debonded Brackets

	METAL BRACKETS	CERAMIC BRACKETS		
	Two-Step Etch-and- Bond n = 150	Two-Step Etch-and- Bond n = 144	Self-Etching Primer n = 126	RMGIC <sup>a</sup> n = 66
% Presence of enamel	13.3	30.2	38.2	19.7
% Bracket fracture	0	26.2	6.2	12.1

<sup>a</sup>Modified glass-ionomer cement (see discussion in Chapter 10).  
 RMGIC, Resin-modified glass ionomer cement.  
 Summarized from Cochrane NJ, Lo TW, Adams GG, Schneider PM. *Am J Orthod Dentofac Orthop.* 2017;152:312–319.

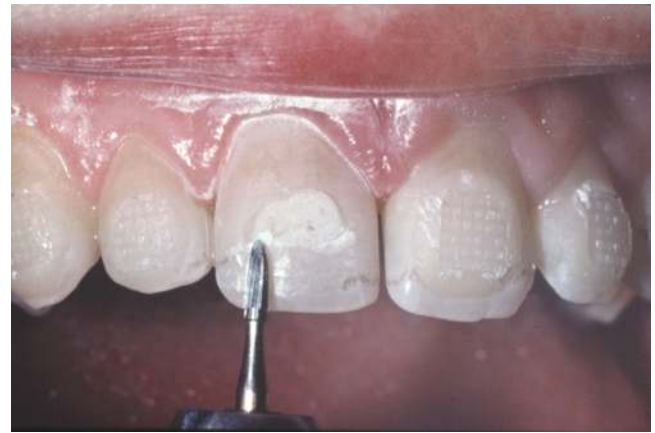stone in a handpiece. This is time-consuming and must be done carefully to avoid enamel damage, so it can be considered an undesirable complication. These problems arise because ceramic brackets have little or no ability to deform—they are either intact or broken. Shearing stresses are applied to the bracket to remove it, and the necessary force can become alarmingly large.

There are three approaches to these problems in debonding ceramic brackets:

- Modify the interface between the bracket and the bonding resin to increase the chance that when force is applied, the failure will occur between the bracket and the bonding material. Chemical bonds between the bonding resin and the bracket can be too good, and most manufacturers now have weakened them or abandoned chemical bonding altogether. As the aforementioned data show, this has not eliminated fracture as a problem—all the ceramic brackets in the study were designed for mechanical, not chemical, bonding.
- Use heat to soften the bonding resin so that the bracket can be removed with lower force. Electrothermal and laser instruments to heat ceramic brackets for removal now are available. There is no doubt that less force is needed when the bracket is heated, and research findings indicate that there is little patient discomfort and minimal risk of pulpal damage.<sup>10</sup> Nevertheless, the ideal solution would be to perfect the third approach, so that ceramic brackets can be debonded without heating as readily as metal ones.
- Modify the bracket so that it breaks predictably when debonding force is applied. One advantage of a metal slot in a ceramic bracket is that then the bracket can be engineered to fracture in the slot area, which makes it much easier to remove.

Because each manufacturer of ceramic brackets has engineered the bracket for a specific removal technique, it is important to follow the manufacturer's recommendations to avoid enamel or bracket fracture. Several ceramic brackets have specific removal pliers designed to make removal easy and predictable for the clinician.

Cement left on the teeth after debanding can be removed easily by scaling, but residual bonding resin is more difficult to remove and removing fragments of a bonded ceramic bracket is even more difficult. For removing bonding resin, the best results are obtained



• **Fig. 17.15** On debonding, the bond failure usually occurs between the base of the bracket and the resin, leaving excess resin on the tooth. Removing excess bonding resin is best accomplished with a smooth 12-fluted carbide bur, followed by pumicing. The carbide bur is used with a gentle wiping motion to remove the resin.

with a 12-fluted carbide finishing bur at moderate speeds in a dental handpiece (Fig. 17.15).<sup>11</sup> This bur cuts resin readily but has little effect on enamel. Topical fluoride should be applied when the cleanup procedure has been completed, however, because some of the fluoride-rich outer enamel layer may be lost with even the most careful approach.

A practical solution to retained residual ceramic bracket material is to carefully remove the bulk of the material with a diamond bur, being certain to not contact the tooth. Then remove the bonding resin with a finishing bur. This is a reasonably rapid method and conserves the finishing burs that are rapidly destroyed by the ceramic bracket material.

## Positioners for Finishing

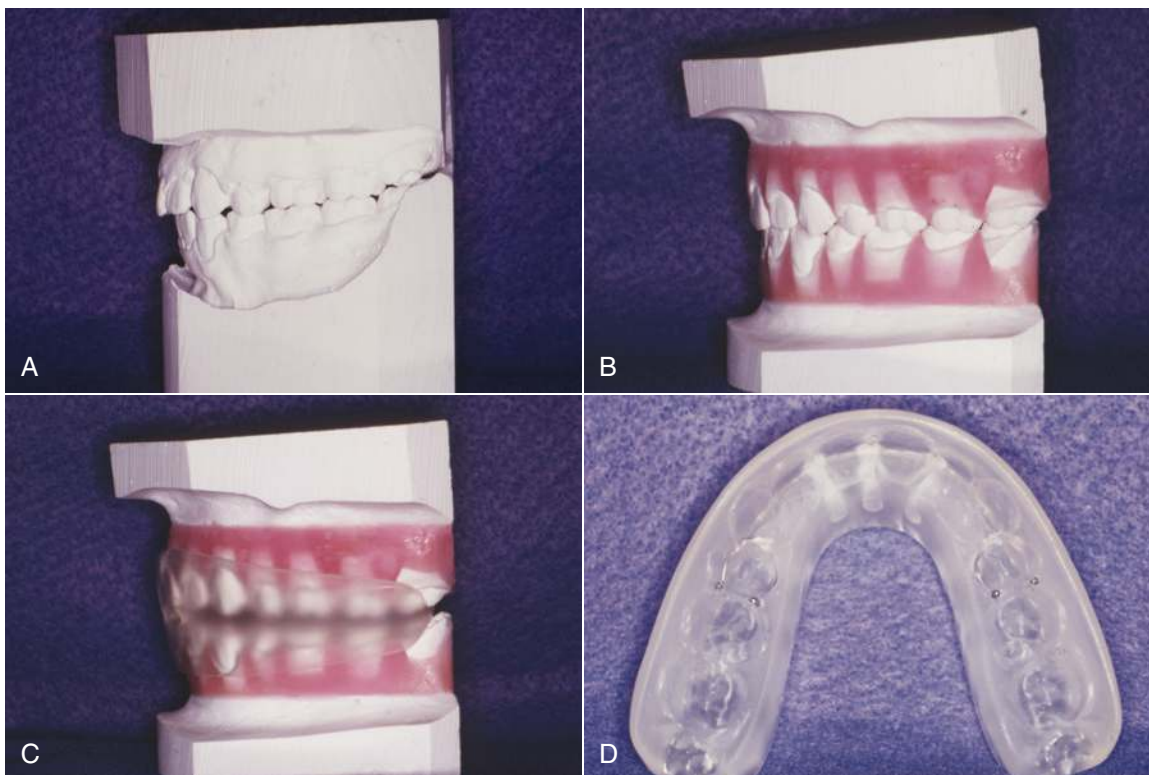
An alternative to segmental elastics or light round archwires for final settling is a full-arch tooth positioner, an elastic device into which a patient bites repetitively to generate small amounts of tooth movement. Positioners were used regularly to assist in finishing after Begg and edgewise treatment in the pre-straight-wire era but now have almost disappeared from routine use, perhaps more completely than they really should have.

A positioner is most effective if it is placed immediately on removal of the fixed orthodontic appliance. Normally, it is fabricated by removing the archwires 4 to 6 weeks before the planned removal of the appliance, taking impressions of the teeth and a registration of occlusal relationships, and then resetting the teeth in the laboratory, incorporating the minor changes in position of each tooth necessary to produce appropriate settling (Fig. 17.16). All erupted teeth should be included in the positioner to prevent supereruption. As part of the laboratory procedure, bands and brackets are trimmed away, and any band space is closed.

The positioner is then fabricated by forming an elastic material (formerly rubber, then usually polyurethane, possibly now a flexible suck-down material) around the repositioned and articulated casts, producing a device with the inherent elasticity to move the teeth slightly to their final position as the patient bites into it.

The use of a tooth positioner rather than final settling archwires has two advantages: (1) it allows the fixed appliance to be removed





• **Fig. 17.16** Use of a positioner for finishing. (A) Dental casts after appliance removal. (B) The positioner set-up. Often the positioner impression is taken 1 month before debanding, with bands and brackets carved off the teeth in the laboratory, so the positioner can be delivered immediately after the appliance is removed. (C) Transparent positioner on set-up. (D) Maxillary occlusal view of the positioner. Note the clasps in the premolar region that help to prevent space from opening. Their use is particularly important when a positioner is used in a maxillary premolar extraction case.

somewhat more quickly than otherwise would have been the case (i.e., some finishing that could have been done with the final archwires can be left to the positioner) and (2) it serves not only to reposition the teeth but also to massage the gingiva, which is almost always at least slightly inflamed and swollen after comprehensive orthodontic treatment. The gingival stimulation provided by a positioner is an excellent way to promote a rapid return to normal gingival contours (Fig. 17.17).

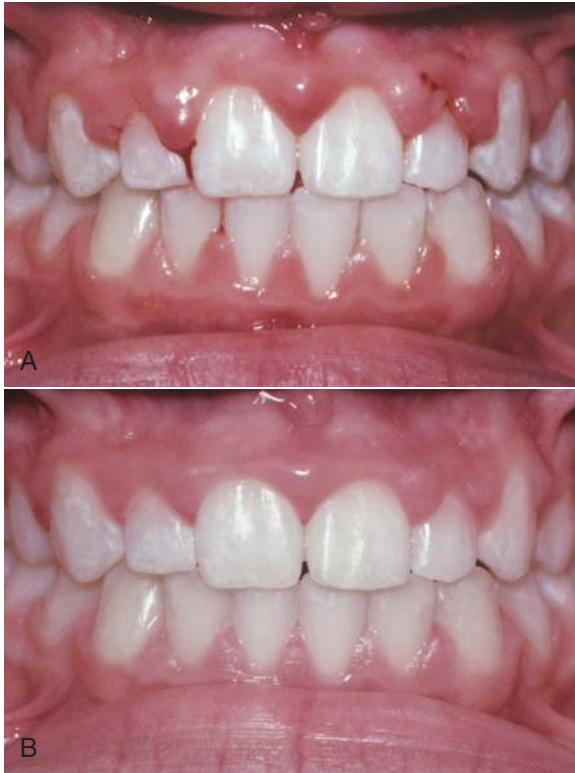The first advantage is no longer compelling—with modern edgewise appliances, it is better to bring the teeth to their final position with archwires than to remove the fixed appliance prematurely. The second one, massage of swollen gingiva, still can be quite useful and should work with an in-office aligner made with the newer and more elastic material.

The use of positioners for finishing also has significant disadvantages. First, they require a considerable amount of laboratory fabrication time and therefore are expensive—but that could be obviated with in-office aligner equipment and manual contouring of the gingival area of casts. Second, settling with a positioner tends to increase overbite more than the equivalent settling with light elastics. This is a disadvantage in the majority of orthodontic patients who had a deep overbite initially but can be advantageous if the initial problem was an anterior open bite. Third, a positioner does not maintain the position of de-rotated teeth well, which

means that minor rotations may recur while a positioner is being worn. Finally, good cooperation is essential. All of these things also would be the case with modified aligners as a replacement for conventional positioners, except that bonded attachments could be used with the aligner to maintain the rotation correction. Severe malalignment and rotated teeth, a deep bite tendency, and an uncooperative patient are contraindications for use of a traditional positioner; deep bite correction during treatment would be less of a contraindication for a final-step aligner because of its lesser thickness.

Because the amount of tooth movement tends to decline rapidly after a few days of use, an excellent schedule is to remove the orthodontic appliances, clean the teeth and apply a fluoride treatment, and place the positioner immediately, asking the patient to wear it as nearly full-time as possible for the first 2 days, then for 4 hours during the day and at night.

As a general rule, a tooth positioner in a cooperative patient will produce any changes it is capable of within 2 to 3 weeks. Final (posttreatment) records and retainer impressions can be taken 2 or 3 weeks after the positioner is placed. Beyond that time, if the positioner is continued, it is serving as a retainer rather than a finishing device—and positioners, even gnathologic positioners made on articulators with a facebow transfer, are not good retainers (see Chapter 18).



• **Fig. 17.17** Gingival improvement with positioner wear. (A) Swollen maxillary papillae immediately after band removal, just before placement of an immediate positioner. (B) Two weeks later. This degree of gingival swelling and puffiness occurs only rarely during fixed appliance treatment, but when it does, a positioner is one of the best means to resolve it.

## Special Finishing Procedures to Avoid Relapse

Relapse after orthodontic treatment has two major causes: (1) continued growth by the patient in an unfavorable pattern and (2) tissue rebound after the release of orthodontic force.

### Control of Unfavorable Growth

Changes resulting from continued growth in a Class II, Class III, deep bite, or open bite pattern contribute to a return of the original malocclusion and in that sense constitute relapse. These changes are due to the pattern of skeletal growth, not just to tooth movement. Controlling this type of relapse requires a continuation of active treatment after the fixed appliances have been removed.

This “active retention” takes one of two forms. One possibility is to continue extraoral force in conjunction with orthodontic retainers (high-pull headgear at night, for instance, in a patient with a Class II open bite growth pattern). The other, which is much more acceptable to the patient, is use of a modified functional appliance rather than a conventional retainer after the completion of fixed appliance therapy. This important subject is discussed in more detail in [Chapter 18](#).

## Control of Rebound After Tooth Movement

A major reason for retention is to hold the teeth until soft tissue remodeling can take place. Even with the best remodeling, however, some rebound from the application of orthodontic forces occurs, and indeed the tendency for rebound after interarch elastics are discontinued has already been discussed. There are two ways to deal with this phenomenon: (1) overtreatment, so that any rebound will only bring the teeth back to their proper position, and (2) adjunctive periodontal surgery to reduce rebound from elastic fibers in the gingiva.

### Overtreatment

Because it can be anticipated that teeth will rebound slightly toward their previous position after orthodontic correction, it is logical to position them at the end of treatment in a slightly overtreated position. Only a small degree of overtreatment is compatible with precise finishing of orthodontic cases as described previously, but it is nevertheless possible to apply this principle during the finishing phase of treatment. Consider four specific situations:

- *Correction of Class II or Class III malocclusion.* Overtreatment of 1 to 2 mm to accommodate for the expected rebound after Class II or Class III correction has already been discussed. As long as the fixed appliance is in place, elastic wear can be reinstituted to obtain a complete correction if there is excessive rebound (or if posturing is detected).
- *Crossbite correction.* Whatever the mechanism used to correct crossbite, it should be overcorrected by at least 1 to 2 mm before the force system is released. If the crossbite is corrected during the first stage of treatment, as should be the case, the overcorrection will gradually be lost during succeeding phases of treatment, but doing this early in treatment should improve stability when transverse relationships are established precisely during the finishing phase.
- *Crowded and irregular teeth.* Just as with crossbites, irregularities can be overcorrected during the first phase of treatment, carrying a tooth that has been lingually positioned slightly too far labial, for instance, and vice versa. It is wise to hold the teeth in a slightly overcorrected position for at least a few months. As a general rule, however, it is not wise to build this overcorrection into rectangular finishing archwires.
- *Rotation correction.* Similarly, a tooth being rotated into position in the arch benefits from being over-rotated. Maintaining an over-rotated position can be done by adjusting the wings of single brackets, or by maintaining a rotation wedge in place with twin brackets. Rotated teeth should be maintained in an overcorrected position as long as possible, but even then, these teeth are often candidates for the periodontal procedures described later.

### Adjunctive Periodontal Surgery: Sectioning Elastic Gingival Fibers

A major cause of rebound after orthodontic treatment is the network of elastic supracrestal gingival fibers. As teeth are moved to a new position, these fibers are stretched, and they remodel very slowly. If the pull of these elastic fibers could be eliminated, a major cause of relapse of previously irregular and rotated teeth should be eliminated. In fact, if the supracrestal fibers are sectioned and allowed to heal while the teeth are held in the proper position, relapse caused by gingival elasticity is greatly reduced.

Surgery to section the supracrestal elastic fibers is a simple procedure that does not require referral to a periodontist unless

possible gingival recession is an esthetic concern. It can be carried out by either of two approaches.

The first method, originally developed by Edwards,<sup>12</sup> is called *circumferential supracrestal fibrotomy* (CSF). After infiltration with a local anesthetic, the procedure consists of inserting the sharp point of a fine blade into the gingival sulcus down to the crest of alveolar bone. Cuts are made interproximally on each side of a rotated tooth and along the labial and lingual gingival margins unless, as is often the case, the labial or lingual gingiva is quite thin, in which case this part of the circumferential cut is omitted. No periodontal pack is necessary, and there is only minor discomfort after the procedure. It now is possible to make these cuts with a laser rather than a knife, and a study in Iran indicated that the laser-assisted CSF was as effective as the original procedure and produced less pain and bleeding. Those researchers reported that irradiation with a gallium-aluminum-arsenide laser at four points around incisors also gave equivalent results.<sup>13</sup>

An alternative method is to make an incision in the center of each gingival papilla, sparing the margin but separating the papilla from just below the margin to 1 to 2 mm below the height of the bone buccally and lingually (Fig. 17.18). This is said to reduce the possibility that the height of the gingival attachment will be reduced after the surgery, and it is particularly indicated for esthetically

sensitive areas (e.g., the maxillary incisor region). Nevertheless, there is little if any risk of gingival recession with the original or laser-assisted CSF procedures unless cuts are made across thin labial or lingual tissues. From the point of view of improved stability after orthodontic treatment, the surgical procedures appear to be equivalent.

Neither CSF nor the papilla-dividing procedure should be done until malalignment of teeth has been corrected and the teeth have been held in their new position for several months. This means that either the surgery should be done a few weeks before removal of the orthodontic appliance or, if it is performed at the same time the appliance is removed, a retainer must be inserted almost immediately. It is easier to do the CSF procedure after the orthodontic appliances have been removed, although it can be carried out with appliances in place. An advantage of the papilla-dividing procedure may be that it is easier to perform with the orthodontic appliance still in place. The problem with placing a retainer immediately after the surgery is that it contacts soft tissue in a sore area, but full-time retention is needed until the soft tissues heal, and this is accomplished best by still having the fixed appliance in place.

Experience has demonstrated that sectioning the gingival fibers is an effective method to control rotational relapse but does not control the tendency for crowded incisors to again become irregular. The primary indication for gingival surgery therefore is a tooth or teeth that were severely rotated. This surgery is not indicated for patients with crowding without rotations.

## Micro-Esthetic Procedures in Finishing

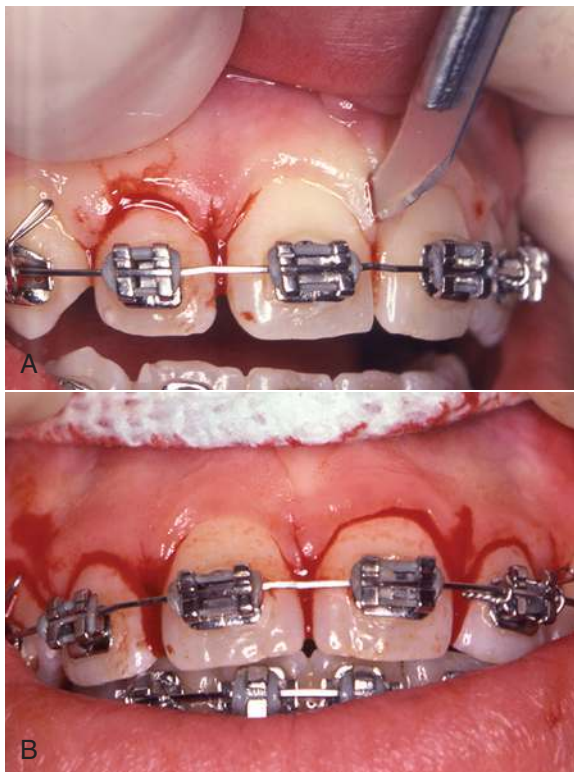
Micro-esthetic considerations in the display and shape of the teeth have been discussed previously in Chapter 6. As a general rule, the soft tissue considerations should be dealt with first, and enameloplasty should be deferred until initial alignment has been achieved and rotations have been corrected.

### Recontouring the Gingiva to Improve Tooth Proportions and Display

Height–width ratios of teeth are greatly affected by the extent to which gingiva covers the upper part of the crown, and this issue should be addressed before recontouring of the teeth is done. Note that for the patient shown in Fig. 17.19, the height–width ratio of the maxillary incisors was well below the normal proportion because the upper portion of the crowns was covered by gingiva. Careful probing established that removal of the gingiva to the level of the cemento–enamel junction was possible, and a diode laser (940 nm, EZlase, Biolase Technology) was used to do this. The effect was an improvement in both tooth proportionality and incisor display.

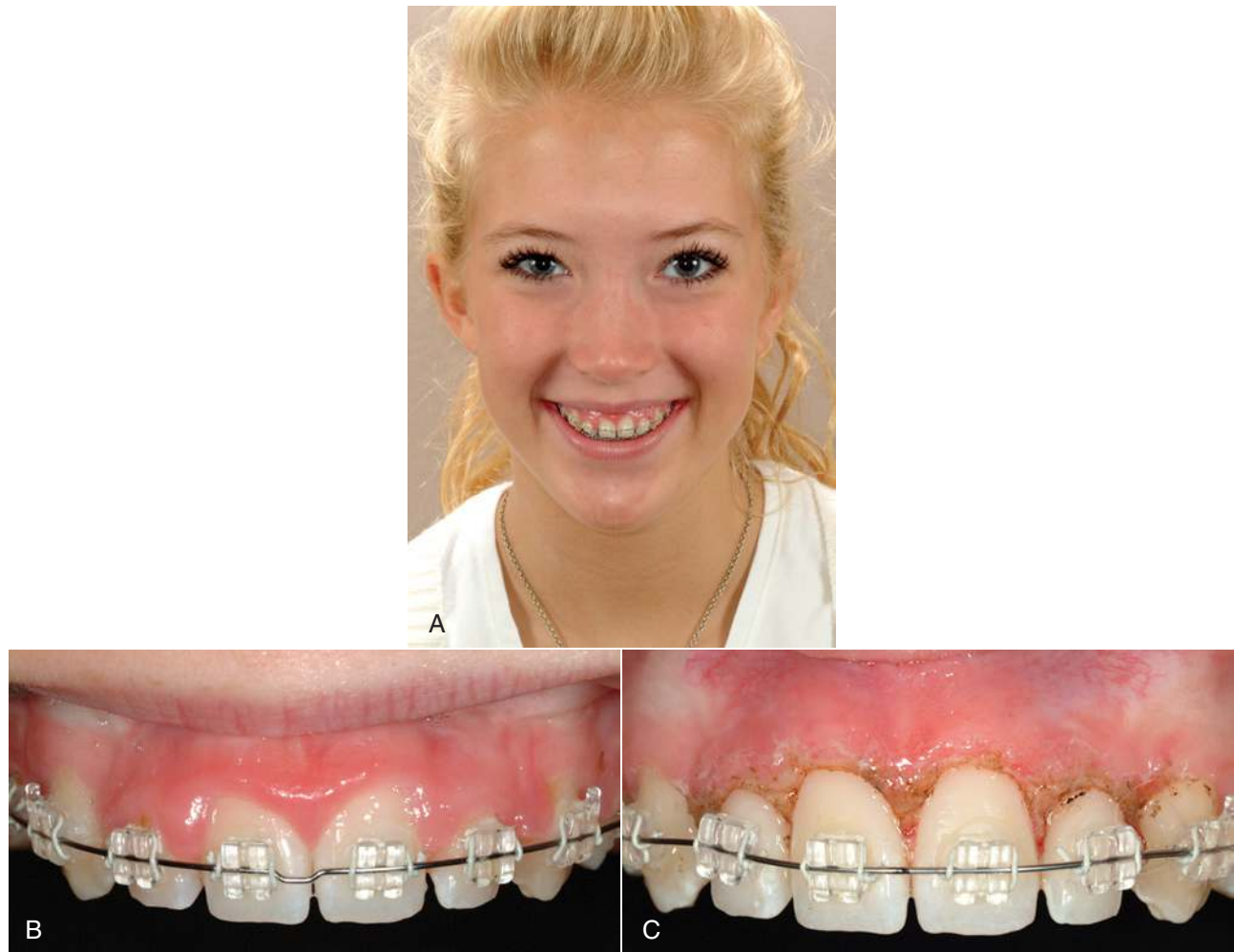### Reshaping the Teeth for Enhanced Esthetics

For many years, dentists have defined tooth shape and morphology in terms of (1) ideal ratios of tooth dimensions, which are affected by the extent to which the gingival tissues cover or expose the crown as discussed earlier, and (2) definitions of tooth shape and contour. Much of modern esthetic dentistry is based on these dimensions and definitions.<sup>14</sup> Identification and treatment of micro-esthetic characteristics can greatly enhance orthodontic outcomes,<sup>15</sup> and therefore this process is an important part of both diagnosis and treatment.

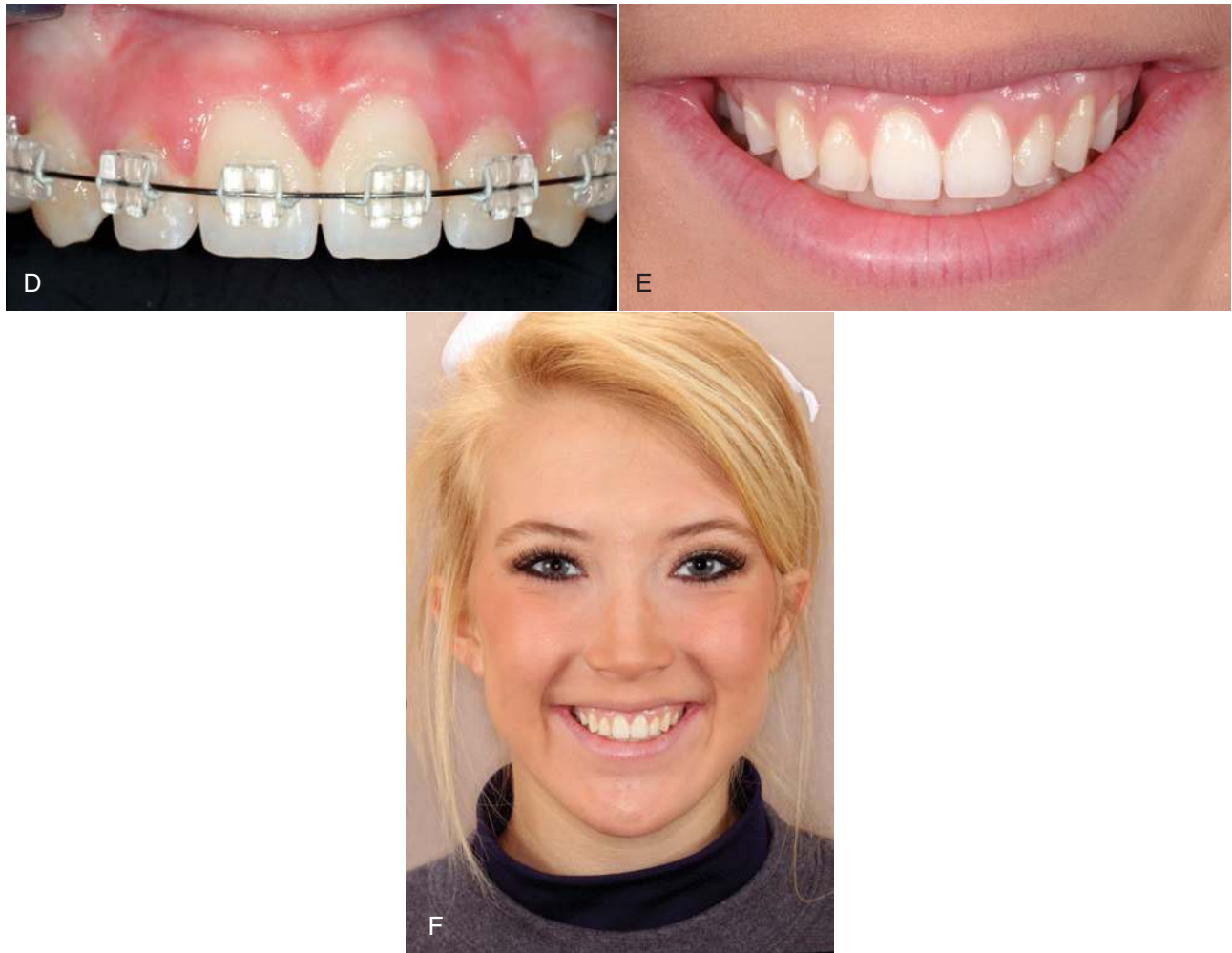


• **Fig. 17.18** The “papilla split” procedure is an alternative to the “around the tooth” circumferential supracrestal fibrotomy (CSF) approach for sectioning gingival circumferential fibers to improve posttreatment stability. It is particularly indicated for esthetically sensitive areas such as the maxillary anterior region. Vertical cuts are made in the gingival papillae without separating the gingival margin at the papilla tip. (A) The blade inserted to make the vertical cut. (B) View at completion of the papilla splits before sutures are placed. Another advantage of this procedure is that it is easier to perform with an orthodontic appliance and archwire in place.





• **Fig. 17.19** (A) For this patient near the end of orthodontic treatment, the inadequate display of the maxillary incisors was primarily due to short clinical crowns because of gingival overgrowth. (B) In this view of the close-up smile, note that the zenith of both central incisor crowns, especially the right central, is too far distal, and that the contour of the gingiva over both lateral incisors is excessive. Probing established that removal of excessive tissue to the level of the cemento-enamel junction was possible. (C) The appearance of the teeth and gingiva immediately after laser recontouring of the gingiva. *Continued*



• **Fig. 17.19, cont'd** (D) Two weeks later. (E) Three months later, close-up, and (F) full-face smile at end of treatment.

Soft tissue recontouring often is done as a first step in treatment. This allows ideal vertical placement of brackets at the beginning of treatment so that gingival margins and placement of incisal edges can be optimized and provides time for healing so that the apparent proportions of the teeth will not be affected by soft tissue changes. Enamel recontouring should not be done until after the initial phase of orthodontic alignment because if a tooth rotation is corrected, the perception of its width is changed while the height is not, giving a misleading height–width ratio. After alignment, reshaping of the teeth can be carried out as desired but should be completed before the end of the finishing stage of treatment.<sup>16</sup>

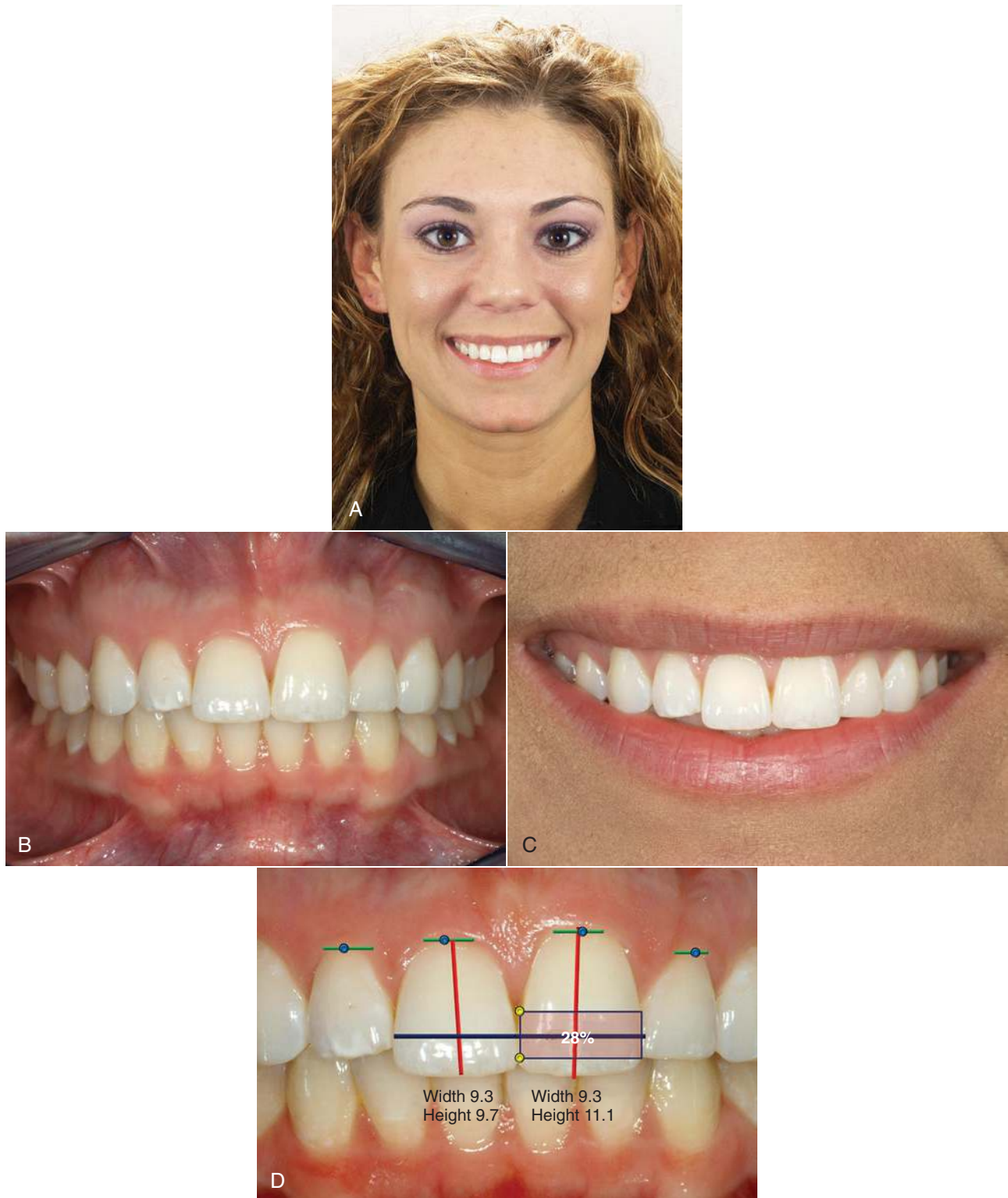
Consider the patient shown in Fig. 17.20, whose chief concern was protruding teeth. She had been treated as an adolescent to reasonably good occlusion and dental alignment but now wanted enhancement of her appearance on smile.

Micro-esthetic considerations on clinical evaluation were:

- Vertical height differences for both the maxillary teeth and gingival margins.
- Different height–width ratios for the central incisors.
- Central incisors disproportionately larger than lateral incisors.
- Short connector length between the central incisors. The ideal connector length for these teeth is 50% of the height of the central incisors, and in this case the connector length was only 28%.
- An excessive gingival embrasure between the central incisors, resulting in a “black triangle.”

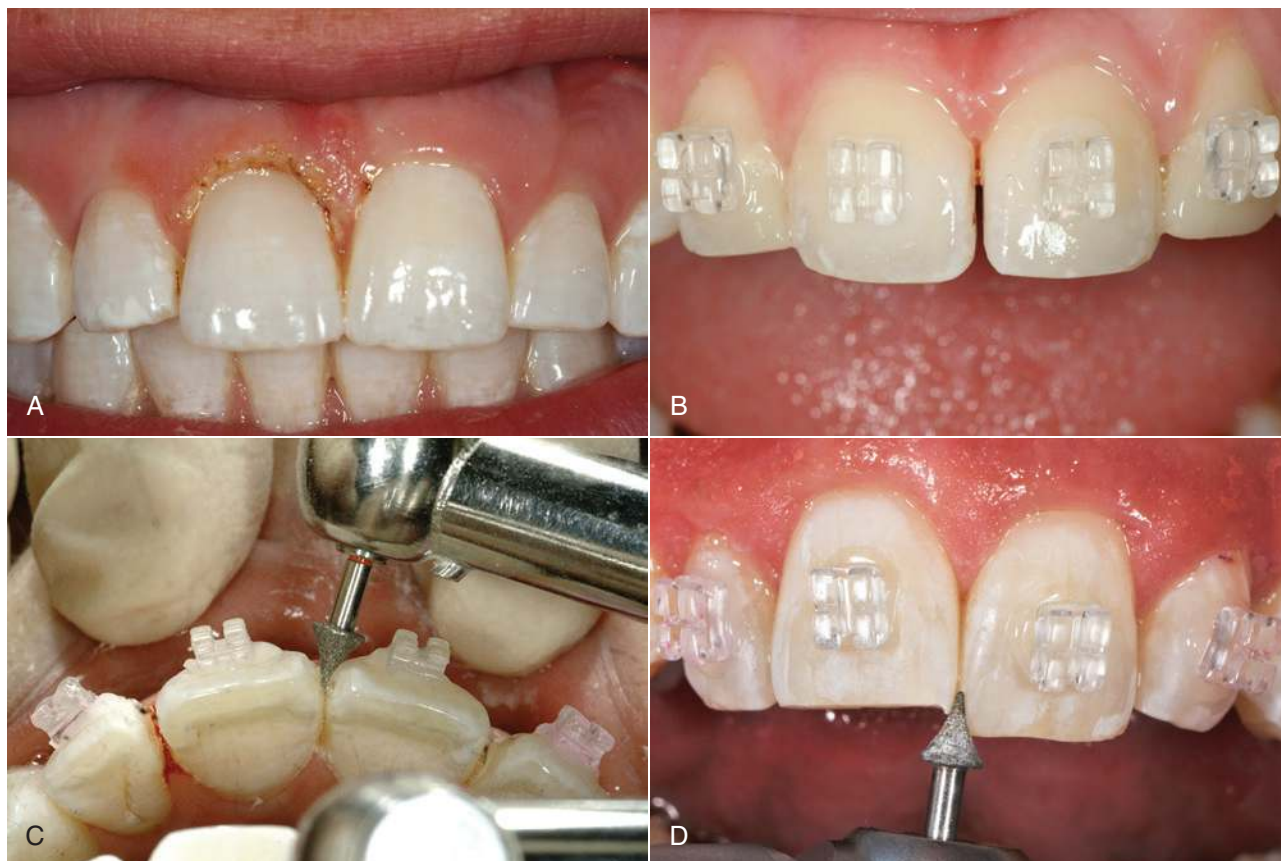The micro-esthetic treatment plan and order of treatment (Fig. 17.21) were as follows:

- Correct the height–width ratios for the central incisors. The ratio for the left central incisor was acceptably close to ideal; the right central incisor needed to be lengthened if possible. The gingival probing depth for the right central was 3 mm;



• **Fig. 17.20** (A) This patient had a chief complaint of protruding teeth. She had been treated as a child to a good occlusion and acceptable smile esthetics. (B and C) She had reasonably well-aligned teeth with good overbite/overjet and smile arc but (1) disparate incisal edges and gingival margins; (2) a 1:1 height-width ratio for the right central incisor, with a more appropriate 8:10 ratio for the left central; and (3) an excessive gingival embrasure between the centrals, which often is referred to as a “black triangle.” (D) Assessment of micro-esthetic characteristics showed that the gingival zeniths (denoted by the blue dots) were well placed, being slightly distal to the long axes of the centrals and coincident to the long axes of the lateral incisors. The excessive gingival embrasure and black triangle were the result of the short connector of only 28% (shown by the box over the left central). The ideal connector length should comprise 50% of the central incisor height.





• **Fig. 17.21** For the patient shown in Fig. 17.20, the height of the right central was shorter than normal, and after periodontal probing demonstrated that adequate tissue could be removed without compromising the gingival attachment, a laser-assisted gingivectomy was carried out. (A) Immediately after the laser procedure. A gingival dressing was not needed because of the coagulation created by the laser. (B) After initial alignment of the teeth, a fine carbide bur was used to lengthen the connector between the centrals and brackets. (C) The interproximal reshaping resulted in line angles that required finishing with a cone-shaped diamond bur. (D) Once the space was closed, the mesial corners of the teeth were shaped to refine the incisal embrasures, and the height of the right central crown and the bracket positions were adjusted so that when the incisal edges were level, the gingival margins also would be level.

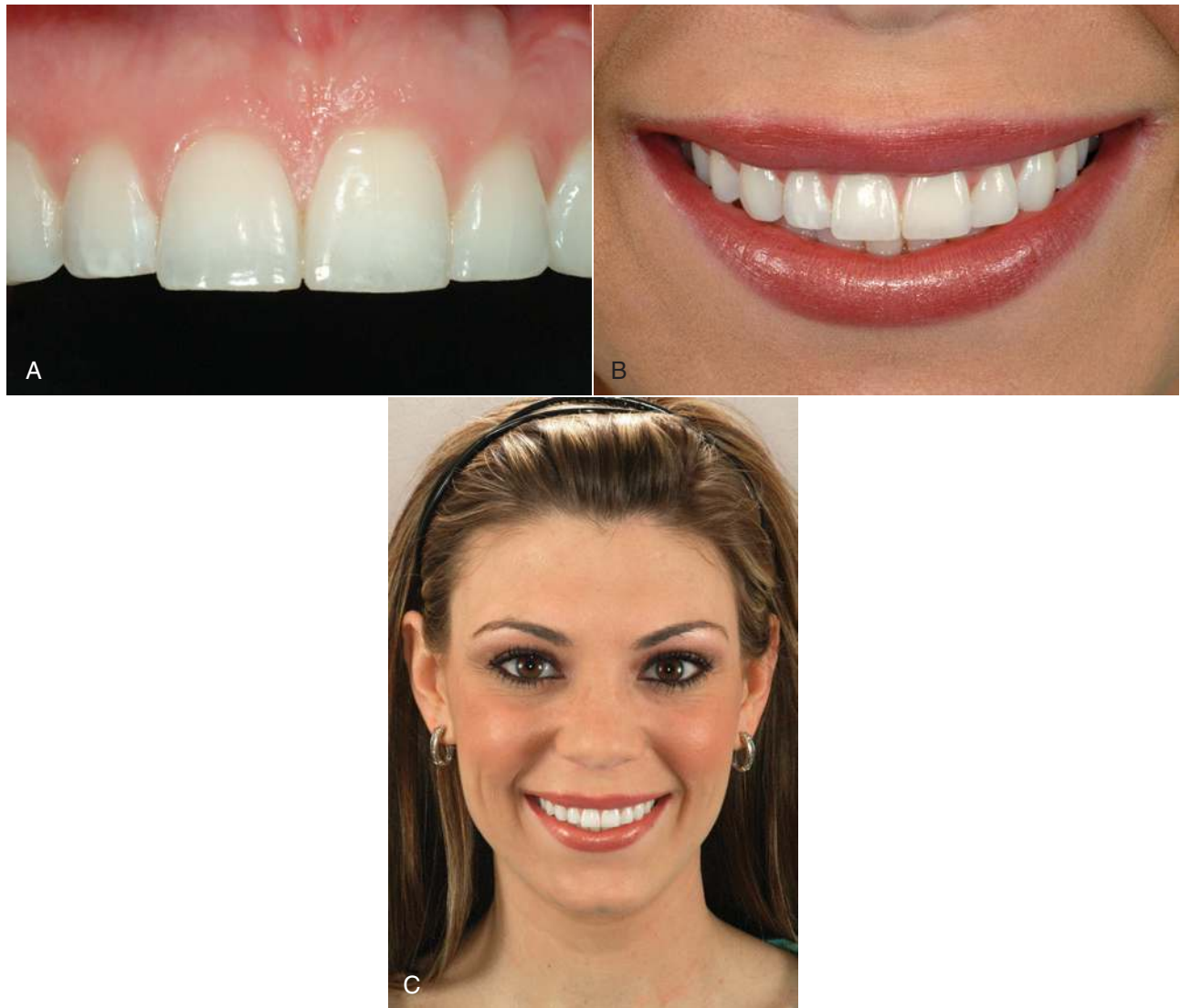
reducing the sulcus depth with a laser-assisted gingivectomy would improve the crown height by 1 to 2 mm.

- Address the width proportions. Because the lateral incisors had normal width while the central incisors were unusually wide, narrowing the central incisors by removing interproximal enamel to improve the height–width ratio was the next step. Doing this only on the mesial surfaces would decrease or eliminate the black triangle between the centrals and increase the connector length. This would result in line angles that would require rounding of the embrasures as the final step in enameloplasty.
- Close the space created by reshaping the centrals, and as the final step in enameloplasty, reshape the incisal embrasures to finish the connector and embrasure form.
- After completion of treatment and removal of the orthodontic appliances, polish the enamel surfaces.

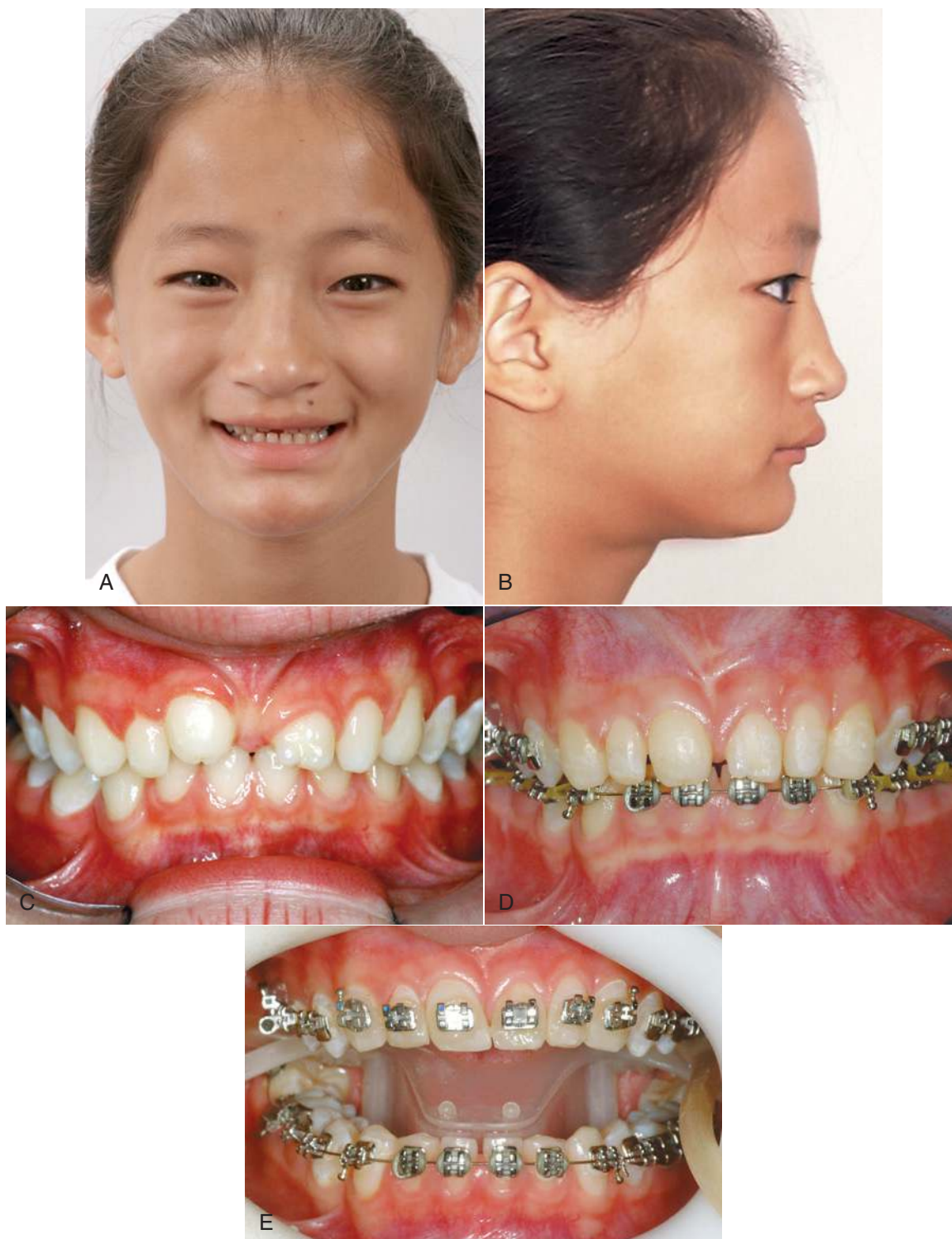The patient's smile after treatment (Fig. 17.22) demonstrates the value of attention to the finishing details so that the characteristics of esthetic teeth are attained.

For a patient with malformed or damaged teeth, the orthodontist needs to interact with a restorative dentist, often both during and at the conclusion of active orthodontic treatment (Fig. 17.23). Temporary restorations so that all teeth are approximately the correct size make orthodontic finishing much easier. Modern restorative procedures, especially the use of laminated veneers, can make a significant difference in the quality of the final result. The orthodontic–restorative interaction is discussed in more detail in Chapter 19.

These micro-esthetic finishing procedures are a simple way to enhance the orthodontic result in a way that patients readily perceive and appreciate.

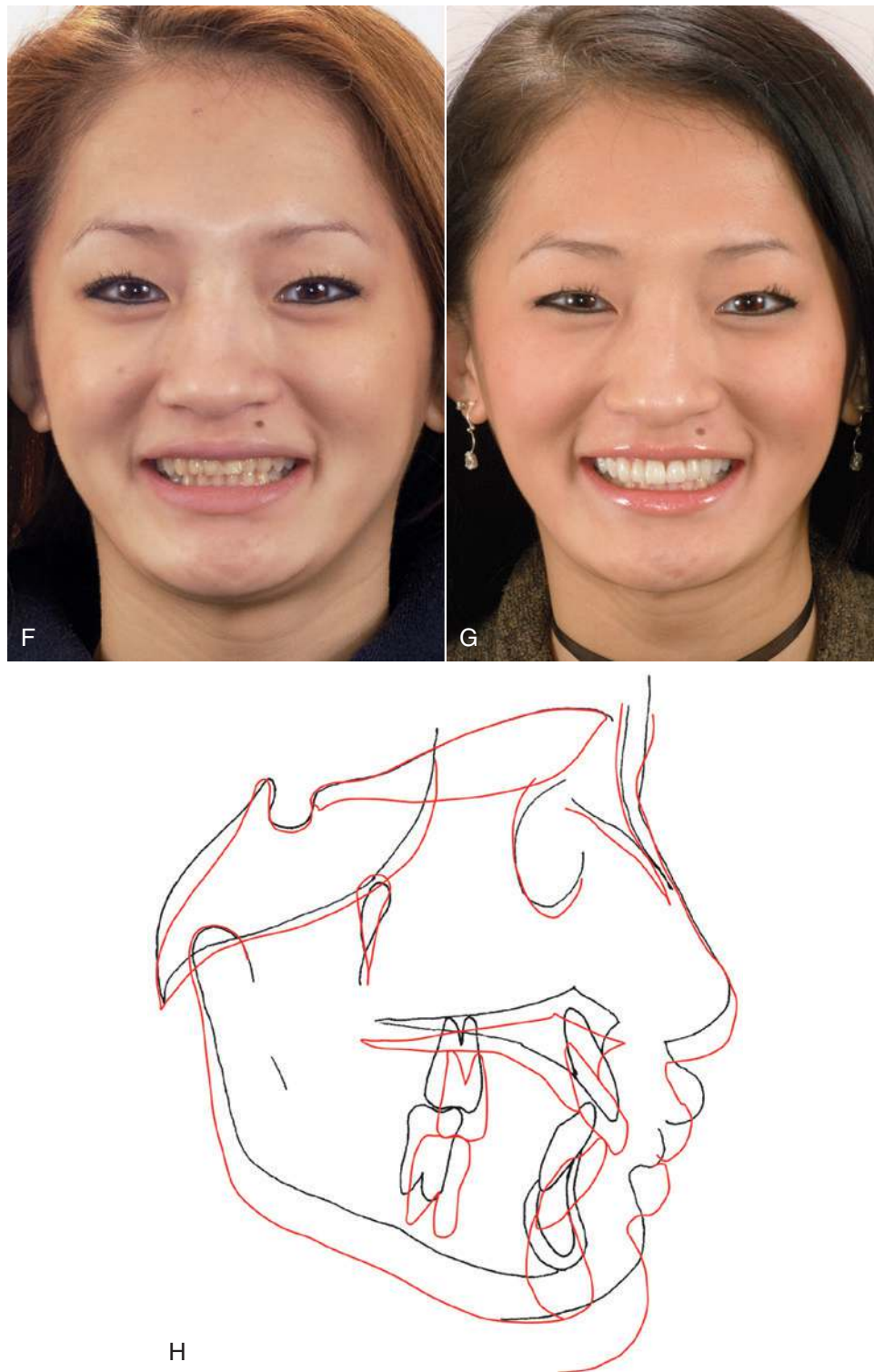


• **Fig. 17.22** Same patient as Figs. 17.20 and 17.21. (A) The desired contact placement, embrasures, and connector length were successfully attained. (B) The final close-up smile and (C) the final full-face smile. The comparison between Figs. 17.20A and 17.22C demonstrates the effect of improving tooth display and contours.



• **Fig. 17.23** (A) Pretreatment smile, (B) profile view, and (C) intraoral view of an 11-year-old girl with malformed maxillary central incisors. Note the short face height, everted upper lip, and short crown heights. Treatment was deferred until age 12½, when she had become quite concerned about the “no teeth” appearance of her smile and was judged to be beginning her adolescent growth spurt. It then was directed toward extrusion of posterior teeth to gain greater face height by using both cervical headgear and vertical elastics. (D) At age 14, after 18 months of treatment, the maxillary brackets were removed so temporary laminates could be placed to improve the proportions of the incisors and increase incisor display. (E) Then brackets were replaced at a more gingival level and treatment was continued.





• **Fig. 17.23, cont'd** (F) After another 9 months of treatment, the braces were removed at age 15. With the temporary laminates still in place, the smile arc was flatter than ideal. (G) At age 18 permanent laminates were placed on the incisor teeth, with a further improvement in the appearance of the smile. (H) Cephalometric superimposition from age 12½ (*black*) to age 15 (*red*), showing the increase in face height and eruption of posterior and anterior teeth that occurred during orthodontic treatment. The increase in face height and balance created by the orthodontic treatment made it possible to provide excellent restorations for the malformed teeth, and the restorations were a critical element in achieving the overall result.

## References

1. Gianelly AA. Asymmetric space closure. *Am J Orthod Dentofacial Orthop.* 1986;90:335–341.
2. Grauer D, Heymann GC, Swift EJ Jr. Clinical management of tooth size discrepancies. *J Esthet Restor Dent.* 2012;24:155–159.
3. Othman S, Harradine N. Tooth size discrepancies in an orthodontic population. *Angle Orthod.* 2007;77:668–674.
4. Fields HW. Orthodontic-restorative treatment for relative mandibular anterior excess tooth size problems. *Am J Orthod.* 1981;79:176–183.
5. Isaacson RJ, Rebellato J. Two-couple orthodontic appliance systems: torquing arches. *Semin Orthod.* 1995;1:31–36.
6. Zachrisson BU. Buccal uprighting of canines and premolars for improved smile esthetics and stability. *World J Orthod.* 2006;7:406–412.
7. Zachrisson BU. Maxillary expansion: long-term stability and smile esthetics. *Am J Orthod Dentofac Orthop.* 2002;121:432–433 (abstracted from *World J Orthod* 2:266–272, 2001).
8. Steffen JM, Haltom FT. The five-cent tooth positioner. *J Clin Orthod.* 1987;21:528–529.
9. Cochrane NJ, Lo TWG, Adams GG, Schneider PM. Quantitative analysis of enamel on debonded orthodontic brackets. *Am J Orthod Dentofac Orthop.* 2017;152:312–319.
10. Feldon PJ, Murray PE, Burch JG, et al. Diode laser debonding of ceramic brackets. *Am J Orthod Dentofac Orthop.* 2010;138:458–462.
11. Eliades T, Gioka C, Eliades G, et al. Enamel surface roughness following debonding using two resin grinding methods. *Eur J Orthod.* 2004;26:333–338.
12. Edwards JG. A long-term prospective evaluation of the circumferential supracrestal fiberotomy in alleviating orthodontic relapse. *Am J Orthod Dentofac Orthop.* 1988;93:380–387.
13. Jahanbin A, Ramazanzadeh B, Ahrari F, et al. Effectiveness of Er:YAG laser-aided fiberotomy and low-level laser therapy in alleviating relapse of rotated incisors. *Am J Orthod Dentofac Orthop.* 2014;146:565–572.
14. Spear FM, Kokich VG, Mathews DP. Interdisciplinary management of anterior dental esthetics. *J Am Dent Assoc.* 2006;137:160–169.
15. Raj V. Esthetic paradigms in the interdisciplinary management of maxillary anterior dentition—a review. *J Esthet Restor Dent.* 2013;25:295–304.
16. Sarver DM. Enameloplasty and esthetic finishing in orthodontics—Identification and treatment of microesthetic features in orthodontics. Part 1. *J Esthet Restor Dent.* 2011;23:296–302; part 2, 23:303–313, 2011.

# 18

## Retention

### CHAPTER OUTLINE

#### Why Is Retention Necessary?

Reorganization of the Periodontal and Gingival Tissues  
Occlusal Changes Related to Growth  
Timing of Retention: Summary

#### Removable Retainers

Hawley Retainers  
Wraparound (Clip) Retainers  
Clear (Vacuum-Formed) Retainers  
Positioners as Retainers

#### Fixed Retainers

Maintenance of Lower Incisor Position During Late Growth  
Maintenance of Diastema Closure  
Inadvertent Tooth Movement With Fixed Lingual Retainers  
Maintenance of Spaces in the Dental Arch

#### Active Retainers

Realignment of Irregular Incisors  
Correction of Occlusal Discrepancies: Modified Functional  
Appliances as Active Retainers

At sporting events, no matter how good things look for one team late in the game, the saying is “It’s not over until it’s over.” In orthodontics, although the patient may feel that treatment is complete when the appliances are removed, an important stage lies ahead. Orthodontic control of tooth position and occlusal relationships must be withdrawn gradually, not abruptly, if excellent long-term results are to be achieved. The type of retention should be included in the original treatment plan.

### Why Is Retention Necessary?

A number of factors can be cited as influencing long-term results, including gender, posttreatment growth, type of malocclusion, magnitude of the pretreatment irregularity, and quality of the orthodontic treatment.<sup>1,2</sup> Most orthodontic treatment results are potentially unstable, and therefore retention is necessary for three major reasons that are summarized in Fig. 18.1:

- The gingival and periodontal tissues are affected by orthodontic tooth movement and require time for reorganization when the appliances are removed.
- The teeth may be in an inherently unstable position after the treatment, so soft tissue pressures constantly produce a relapse tendency.
- Changes produced by growth may alter the orthodontic treatment result.

Even if the teeth are in a position that should be stable and there is no further growth, retention still is vitally important until gingival and periodontal reorganization is completed. If the teeth are unstable, as often is the case following significant arch expansion, gradual withdrawal of orthodontic appliances is of no value. The only possibilities are accepting relapse or using permanent retention. Finally, whatever the situation, retention cannot be abandoned until growth is essentially completed.

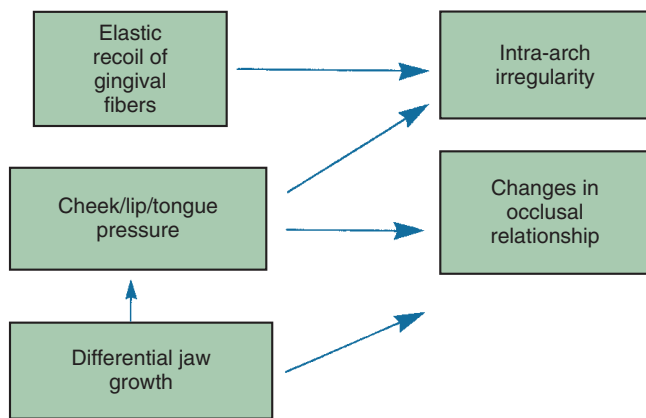
### Reorganization of the Periodontal and Gingival Tissues

Widening of the periodontal ligament (PDL) space and disruption of the collagen fiber bundles that support each tooth are normal responses to orthodontic treatment (see Chapter 8). In fact, these changes are necessary to allow orthodontic tooth movement to occur. Even if tooth movement stops before the orthodontic appliance is removed, restoration of the normal periodontal architecture will not occur as long as a tooth is strongly splinted to its neighbors, as when it is attached to a rigid orthodontic archwire. For that reason, holding the teeth with passive archwires cannot be considered the beginning of retention. Bone bending as each tooth is displaced slightly relative to its neighbor as the patient chews is necessary for recovery from the splinting effect of a fixed orthodontic appliance. Once the teeth can respond individually to the forces of mastication, reorganization of the PDL occurs over a 3- to 4-month period, and the slight mobility present at appliance removal disappears.

This PDL reorganization is important for stability because of the periodontal contribution to the equilibrium that normally controls tooth position. To briefly review our current understanding of the pressure equilibrium (see Chapter 5 for a detailed discussion), the teeth normally withstand occlusal forces because of the shock-absorbing properties of the periodontal system. More important for orthodontics, small but prolonged imbalances in tongue–lip–cheek pressures or pressures from gingival fibers that otherwise would produce tooth movement are resisted by “active stabilization” due to PDL metabolism. It appears that this stabilization is caused by the same force-generating mechanism that produces eruption. The disruption of the PDL produced by orthodontic tooth movement probably has little effect on stabilization against occlusal forces, but it reduces or eliminates the active stabilization. This means that immediately after orthodontic appliances are removed, teeth will be unstable in the face of occlusal and soft tissue pressures that can be resisted later. That is why every patient needs retainers for at least a few months.

The gingival fiber networks are also disturbed by orthodontic tooth movement and must remodel to accommodate the new tooth positions. Both collagenous and elastic fibers are present in the gingiva, and Reitan showed many years ago that the reorganization of





• **Fig. 18.1** The major causes of relapse after orthodontic treatment are elastic recoil of gingival fibers, which can cause intra-arch irregularity; cheek/lip/tongue pressures, which can affect both tooth alignment and occlusal relationships; and differential jaw growth, which can change occlusal relationships. Gingival fibers and soft tissue pressures are especially potent in the first few months after treatment ends, before PDL reorganization has been completed. Unfavorable growth is the major contributor to long-term changes in occlusal relationships.

both occurs more slowly than in the PDL.<sup>3</sup> Within 4 to 6 months, the collagenous fiber networks within the gingiva have normally completed their reorganization, but the elastic supracrestal fibers remodel extremely slowly and can still displace a tooth more than a year after removal of an orthodontic appliance. In patients with severe rotations, sectioning the supracrestal fibers around teeth that initially were severely rotated, at or just before the time of appliance removal, is a recommended procedure because it reduces relapse (see Fig. 17.18 and the discussion of fiberotomy).

This timetable for soft tissue recovery from orthodontic treatment outlines the principles of retention against intra-arch instability. These are:

- The direction of potential relapse can be identified by comparing the position of the teeth at the conclusion of treatment with their original positions. Teeth will tend to move back in the direction from which they came, primarily because of elastic recoil of gingival fibers but also because of unbalanced tongue–lip forces.
- Teeth require daily (essentially full-time) retention after comprehensive orthodontic treatment for the first 3 to 4 months after a fixed orthodontic appliance is removed. Because data from removable Hawley retainers with sensors show that median wear time is about 8 hours per day and rarely exceeds 12 hours but that retainers are reasonably effective if worn at this level,<sup>4</sup> orthodontists have learned to ask for wear every day and for more hours than they really expect.
- To promote reorganization of the PDL, the teeth should be free to flex individually during mastication, as the alveolar bone bends in response to heavy occlusal loads during mastication (see Chapter 8). This requirement can be met by a removable appliance worn regularly except during meals or by a fixed retainer that is not too rigid.
- Because of the slow response of the gingival fibers, retention should be continued for at least 12 months if the teeth were quite irregular initially but can be reduced to part-time after 3 to 4 months. After approximately 12 months, it may be possible to discontinue retention in nongrowing patients, but gradual discontinuation of the appliances can test this process and the stability.

- More precisely, in the absence of growth, the teeth should be stable by 1 to 2 years after treatment if they ever will be. Some patients who are not growing will require permanent retention because of lip, cheek, and tongue pressures that are too great for active stabilization to balance.
- Patients who will continue to grow, however, usually need retention until growth has slowed to the low levels that characterize adult life.

## Occlusal Changes Related to Growth

A continuation of growth is particularly troublesome in patients whose initial malocclusion resulted largely or in part from the pattern of skeletal growth. Skeletal problems in all three planes of space tend to recur if growth continues (Fig. 18.2) because most patients continue in their original growth pattern as long as they are growing. Transverse growth is completed first, which means that long-term transverse changes are less of a problem clinically than changes from late anteroposterior and vertical growth.

Comprehensive orthodontic treatment is usually carried out in the early permanent dentition, and the duration is typically between 18 and 30 months. This means that active orthodontic treatment is likely to conclude at age 14 to 15, whereas anteroposterior and particularly vertical growth often do not subside even to the adult level until several years later. In late adolescence, continued growth in the pattern that caused a Class II, Class III, deep bite, or open bite problem in the first place is a major cause of recurrence after orthodontic treatment and requires careful management during retention.

Long-term studies of adults have shown that very slow growth typically continues throughout adult life, and the same pattern that led to malocclusion in the first place can contribute to a deterioration in occlusal relationships many years after orthodontic treatment is completed.<sup>5</sup>

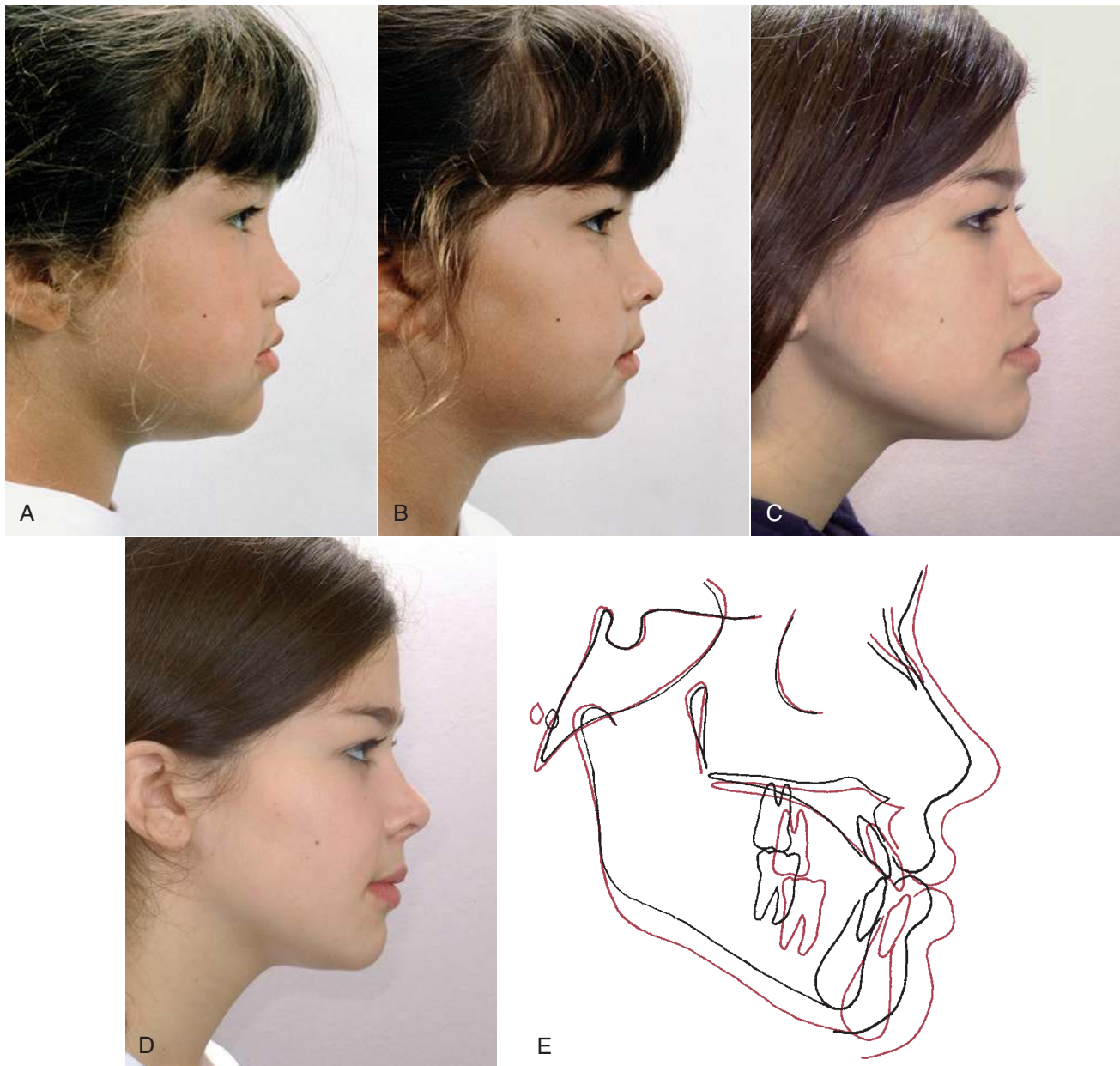
### Retention When a Class II Growth Pattern Exists

Recurrence of a Class II relationship must result from some combination of tooth movement (forward in the upper arch, backward in the lower arch, or both) and differential growth of the maxilla relative to the mandible (Fig. 18.3). As might be expected, tooth movement caused by local periodontal and gingival factors can be an important short-term problem, whereas differential jaw growth is a more important long-term problem because it directly alters jaw position and this contributes to repositioning of teeth.

Overcorrection of the occlusal relationships as a finishing procedure is important in controlling tooth movement that would lead to Class II relapse. Even with good retention, 1 to 2 mm of anteroposterior change caused by adjustments in tooth position is likely to occur after treatment, particularly if Class II elastics were employed. This change occurs relatively quickly after active treatment stops.

In Class II treatment it is important not to move the lower incisors too far forward, but this can happen easily with Class II elastics. In this situation, lip pressure will tend to upright the protruding incisors, leading relatively quickly to crowding and return of both overbite and overjet. Often this occurs in only a few months after full-time retainer wear is discontinued. As a general guideline, if more than 2 mm of forward repositioning of the lower incisors occurred during treatment, permanent retention is very likely to be required.

The slower long-term recurrence that occurs in some patients results primarily from differential jaw growth. In patients with

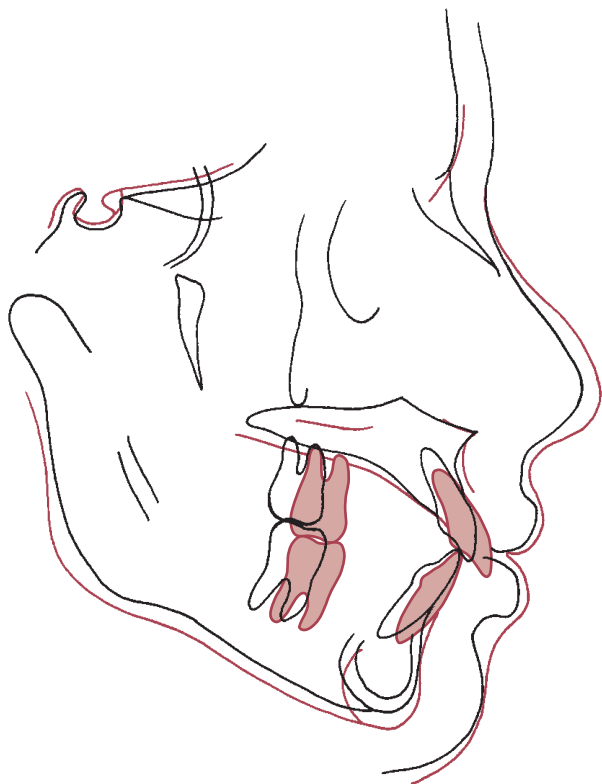


• **Fig. 18.2** Growth after early treatment of a Class III problem is likely to cause the problem to recur, as in this girl. (A) Profile at age 7, before treatment. (B) Age 8, after treatment with reverse-pull headgear (facemask). (C) Five years later, after the adolescent growth spurt. (D) After orthognathic surgery, at age 17—which was not done until she showed no further mandibular growth during the previous year. (E) Cephalometric superimposition showing the pattern of growth from the end of the facemask treatment (*black*) through adolescence to just before surgery (*red*).

Class II problems, this can be controlled in either of two ways. The first, if headgear was used in treatment, is to continue its use on a reduced basis (at night, for instance) in conjunction with a retainer to hold the teeth in alignment. This requires leaving the first molar bands on when everything is removed at the end of active treatment. It is quite satisfactory in well-motivated patients who have been wearing headgear and are willing to continue it during retention, and is compatible with traditional retainers that are worn full-time initially—but compliance with headgear use becomes a problem with all but the most cooperative patients.

The other method is to use a functional appliance of the activator or Bionator type to hold both tooth position and the occlusal relationship (Fig. 18.4). To the patient, this intraoral device is just another variety of retainer, and compliance is less of a problem. If the patient does not have excessive overjet, as should be the case at the end of active treatment, the construction bite for the functional appliance is taken without any mandibular advancement; the idea is to prevent a Class II malocclusion from recurring, not to actively treat one that already exists.

A potential difficulty is that the functional appliance will be worn only part-time, typically just at night, and daytime retainers



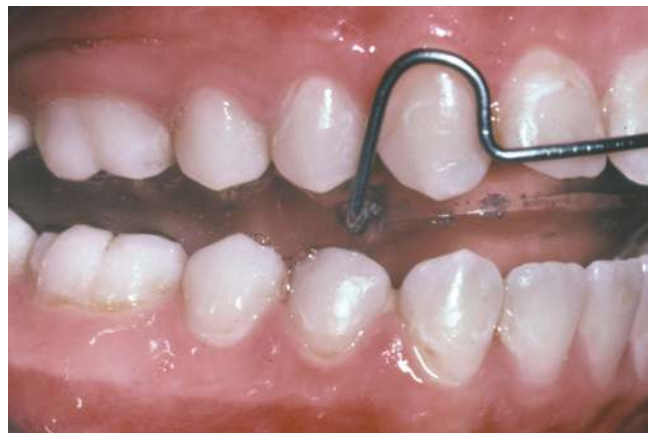• **Fig. 18.3** Cephalometric superimposition demonstrating growth-related relapse in a patient treated to correct Class II malocclusion. *Black*, Immediate posttreatment, age 13; *red*, recall, age 17. After treatment, both jaws grew downward and forward, but mandibular growth did not match maxillary growth, and the maxillary dentition moved forward relative to the maxilla. As in Class III patients, early Class II treatment has little or no effect on the underlying growth pattern.

of conventional design also will be needed to control tooth position during the first few months. Use of a functional appliance as an extra retainer from the beginning makes sense for a patient with a severe growth problem. For patients with less severe problems, in whom continued growth may or may not cause relapse, it may be more rational to use only conventional maxillary and mandibular retainers initially and replace them with a functional appliance to be worn at night if relapse is beginning to occur after a few months.

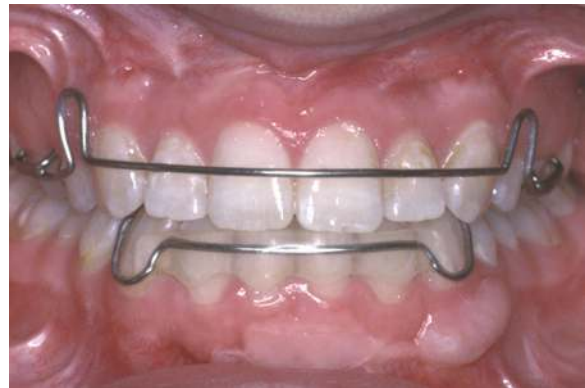This type of retention is often needed for 24 months or more after the daytime retainer has been discontinued in patients who had a skeletal problem initially. The guideline is this: the more severe the initial Class II problem and the younger the patient at the end of active treatment, the more likely that either headgear or a functional appliance will be needed during retention. It is better and much easier to prevent relapse from differential growth than to try to correct it later.

#### Retention When a Class III Growth Pattern Exists

Retention after correction of a Class III malocclusion early in the permanent dentition period can be frustrating, because recurrence from continuing mandibular growth is very likely and extremely difficult to control (see Fig. 18.3). Applying a restraining force to the mandible, as from a chin cup, is not nearly as effective in a patient with Class III malocclusion as a modified functional appliance in a patient with Class II issues. If face height is normal or excessive after orthodontic treatment and recurrence occurs from



• **Fig. 18.4** In patients in whom further growth in the original Class II pattern is expected after active treatment is completed, a functional appliance worn at night can be used to maintain occlusal relationships. In a typical Class II deep bite patient, acrylic over the lower posterior teeth is trimmed away so that these teeth can erupt slightly while other teeth are tightly controlled.



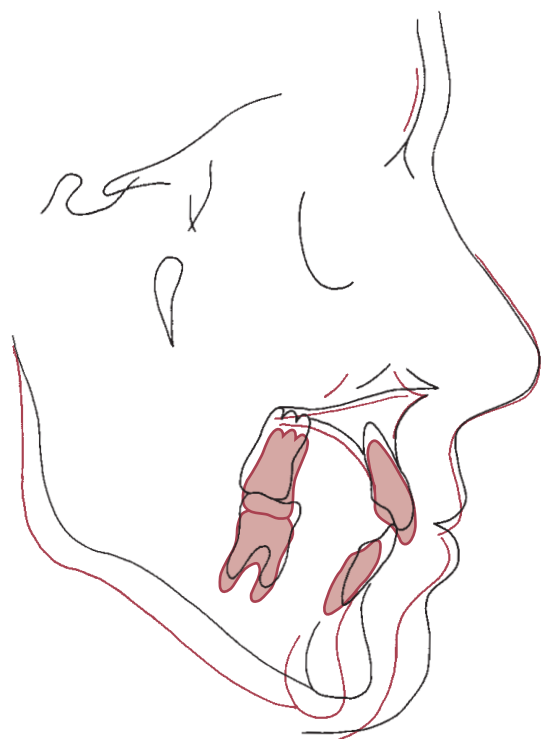
• **Fig. 18.5** Control of the vertical position of teeth in retention is as important as controlling alignment in patients who had a deep bite or open bite initially. For this patient with a deep bite, the lower incisors contact the palatal acrylic of the upper Hawley retainer, while the upper incisors contact the facial surface of the lower Moore retainer. This prevents incisor eruption that would lead to return of excessive overbite.

mandibular growth, surgical correction after the growth has expressed itself may be the only answer. In mild Class III problems, a positioner may be enough to maintain the occlusal relationships during posttreatment growth.

#### Retention After Deep Bite Correction

Correcting excess overbite is an almost routine part of orthodontic treatment, and therefore most patients require control of the vertical overlap of incisors during retention to prevent relapse from uncontrolled incisor eruption. Posttreatment growth in a short face pattern, of course, makes recurrence of excessive overbite more likely. Controlling this is accomplished most readily by using a removable upper retainer made so that the lower incisors will encounter the baseplate of the retainer if they begin to slip vertically behind the upper incisors (Fig. 18.5). The procedure, in other words, is to build a potential biteplate into the retainer, which the lower incisors will contact if the bite begins to deepen. The retainer does not separate the posterior teeth.





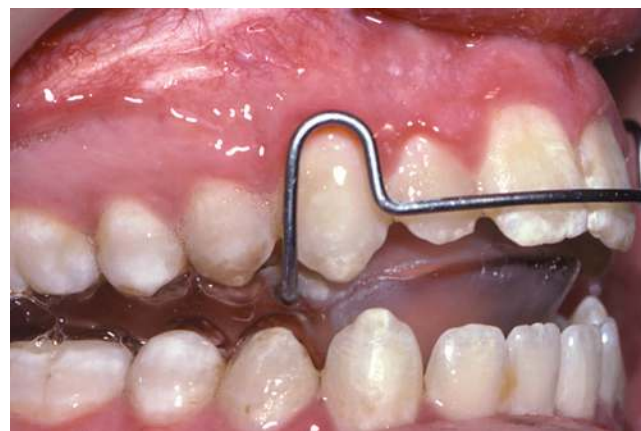• **Fig. 18.6** Four years after removal of the orthodontic appliances and a reasonable correction of the malocclusion, this 18-year-old with a long face growth pattern has an anterior open bite, 5 mm of overjet with an end-on molar relationship, and severe crowding of the mandibular incisors. Relapse of this type is associated with little or no mandibular growth and a downward and backward mandibular rotation as the maxilla grows downward and upper posterior teeth erupt. The incisor crowding is due to uprighing and lingual repositioning of the incisors as the mandibular rotation thrusts them into the lower lip.

Because vertical growth continues into the late teens, a maxillary removable retainer with a bite plane often is needed for several years after fixed appliance orthodontics is completed. Bite depth can be maintained by wearing the retainer only at night, after stability in other regards has been achieved.

### Retention After Anterior Open Bite Correction

Relapse into anterior open bite can occur by any combination of depression of the incisors and elongation of the molars. Active habits (of which thumb-sucking is the best example) can produce intrusive forces on the incisors, while at the same time leading to an altered posture of the jaw that allows posterior teeth to erupt. If thumb-sucking continues after orthodontic treatment, relapse is all but guaranteed. Tongue habits, particularly tongue-thrust swallowing, are often blamed for relapse into open bite, but the evidence to support this contention is not convincing (see discussion in [Chapter 5](#)). In patients who do not place some object between the front teeth, return of open bite is almost always the result of elongation of the posterior teeth, particularly the upper molars, without any evidence of intrusion of incisors ([Fig. 18.6](#)). Controlling eruption of the upper molars therefore is the key to retention in patients with an open bite.

The preferred method to do that is a palate-covering removable appliance (modified Hawley retainer, discussed later) with bite blocks between the posterior teeth to create several millimeters of



• **Fig. 18.7** Controlling the eruption of posterior teeth during late vertical growth is the key to preventing open bite relapse. There are two major approaches to accomplishing this: a maxillary retainer with bite blocks (or a functional appliance) to impede eruption, as shown here in a patient soon after his severe open bite was corrected, or high-pull headgear. In a patient with the long-face growth pattern, one or the other must be continued as a nighttime retainer through the late teens. Although high-pull headgear can be quite effective in a cooperative patient, a removable appliance with bite blocks is a better choice for most patients for two reasons: it controls eruption of both the upper and lower molars, and usually it is better accepted because it is easier to wear.

jaw separation ([Fig. 18.7](#)). This stretches the patient's soft tissues to provide a force opposing eruption. As we have noted previously, bite blocks are ineffective in intruding posterior teeth, but they are capable of impeding eruption. High-pull headgear to the upper molars, in conjunction with a standard removable retainer to maintain tooth position, also can be effective, but the intraoral appliance is better tolerated and controls eruption of lower as well as upper posterior teeth. Excessive vertical growth and eruption of the posterior teeth often continue until late in the teens or early twenties, so retention also must continue well beyond the typical completion of active treatment.

The recent increase in reports of successful treatment of mild open bite malocclusion with clear aligners has led to suggestions that vacuum-formed retainers with thickened plastic over the posterior occlusal surfaces may be useful for retention of these patients. The theory is that this would provide enough of a bite block effect to prevent posttreatment eruption of the posterior teeth and that patient compliance would be better, but no good data exist. As we have noted in [Chapter 10](#), individual cases of open bite correction with aligners often show more incisor extrusion than posterior intrusion, and a recent study from the University of Washington indicated that this is the more likely outcome.<sup>6</sup> It is possible that open bite retention with vacuum-formed retainers also would work mostly by encouraging eruption of anterior teeth. More trials are needed to clarify their usefulness in retaining open bite cases.

### Retention of Lower Incisor Alignment

Not only can continued skeletal growth affect occlusal relationships, it also has the potential to alter the position of teeth. If the mandible grows forward or rotates downward, the effect is to carry the lower incisors into the lip, which creates a force tipping them distally. For this reason, continued mandibular growth in normal or Class III patients is strongly associated with crowding of the lower incisors. Incisor crowding also accompanies the downward

and backward rotation of the mandible seen in skeletal open bite problems (see Fig. 18.3). A retainer in the lower incisor region is needed to prevent crowding from developing until growth has declined to adult levels.

It often has been suggested that orthodontic retention should be continued, at least on a part-time basis, until the third molars have either erupted into normal occlusion or been removed. The implication of this guideline, that pressure from the developing third molars causes late incisor crowding, is almost surely incorrect (see Chapter 5). On the other hand, because eruption of third molars or their extraction usually does not take place until the late teen years, the guideline is not a bad one in its emphasis on prolonged retention in patients who are continuing to grow.

Most adults, including those who underwent orthodontic treatment and once had perfectly aligned teeth, end up with some crowding of lower incisors at 5-year or longer recall. It seems likely that late mandibular growth is the major contributor to this crowding tendency. Steinness et al noted that the amount of lower incisor crowding in untreated individuals was three times greater than in those who had a fixed lingual retainer,<sup>7</sup> documenting the need for maintaining these teeth against the lingual tipping that accompanies late forward growth of the mandible. However, several studies have shown that which individuals will have posttreatment crowding cannot be predicted from the characteristics of the original malocclusion or variables associated with treatment. It makes sense therefore to routinely retain lower incisor alignment until mandibular growth has declined to adult levels (i.e., until the late teens in girls and into the early 20s in boys).

### Timing of Retention: Summary

Retention is needed for all patients who underwent treatment with fixed orthodontic appliances to correct intra-arch irregularities. It should be:

- Daily (essentially full-time) for the first 3 to 4 months, except that removable retainers not only can but should be removed while eating, and fixed retainers should be flexible enough to allow displacement of individual teeth during mastication (unless periodontal bone loss or other special circumstances require permanent splinting)
- Continued on a part-time basis for at least 12 months to allow time for remodeling of gingival tissues.
- If significant growth remains, continued part-time until completion of growth.

For practical purposes, this means that nearly all patients treated in the early permanent dentition will require retention of incisor alignment at least until their late teens, and in those with skeletal disproportions initially, part-time use of a functional appliance or extraoral force probably will be needed.

## Removable Retainers

### Hawley Retainers

Well into the 21st century, the most common removable retainer for the maxillary arch was the Hawley retainer, designed in the 1920s as an active tooth-moving device to close spaces between maxillary incisors and before then serving as a retainer. It incorporates clasps on molar teeth and a characteristic outer bow with adjustment loops, usually spanning from canine to canine (Fig. 18.8). Because it covers the palate, it automatically provides a potential bite plane to control overbite.

The ability of this retainer to provide some tooth movement was an important asset with fully banded fixed appliances because when bands are removed, small spaces between the teeth will be present. With bonded attachments, there is no longer any need to close spaces with a retainer, but it is important that the retainer allow the posterior teeth to settle into occlusion after appliance removal, and slightly trimming the acrylic lingual to the posterior teeth so that an eruption path exists is an important clinical adjustment of the Hawley retainer. The outer bow provides excellent control of the incisors even if it is not adjusted to retract them, especially if the anterior section has acrylic added to fit more tightly, or perhaps even better, if the anterior segment is formed from a clear polymer (see Fig. 18.8D). This modification also improves the esthetics of the retainer.

When first premolars have been extracted, one function of a retainer is to keep the extraction space closed, which the standard design of the Hawley retainer cannot do. Even worse, the standard Hawley labial bow extends across a first premolar extraction space, tending to wedge it open. A common modification of the Hawley retainer for use in extraction cases is a bow soldered to the buccal section of Adams clasps on the first molars so that the action of the bow helps hold the extraction site closed.

Alternative designs for extraction cases are to wrap the labial bow around the entire arch, using circumferential clasps on second molars for retention, or to bring the labial wire from the baseplate between the lateral incisor and canine and bend or solder a wire extension distally to control the canines. The latter alternative does not provide an active force to keep an extraction space closed but avoids having the wire cross through the extraction site and gives positive control of canines that were labially positioned initially. The loop of the traditional Hawley design does not provide this.

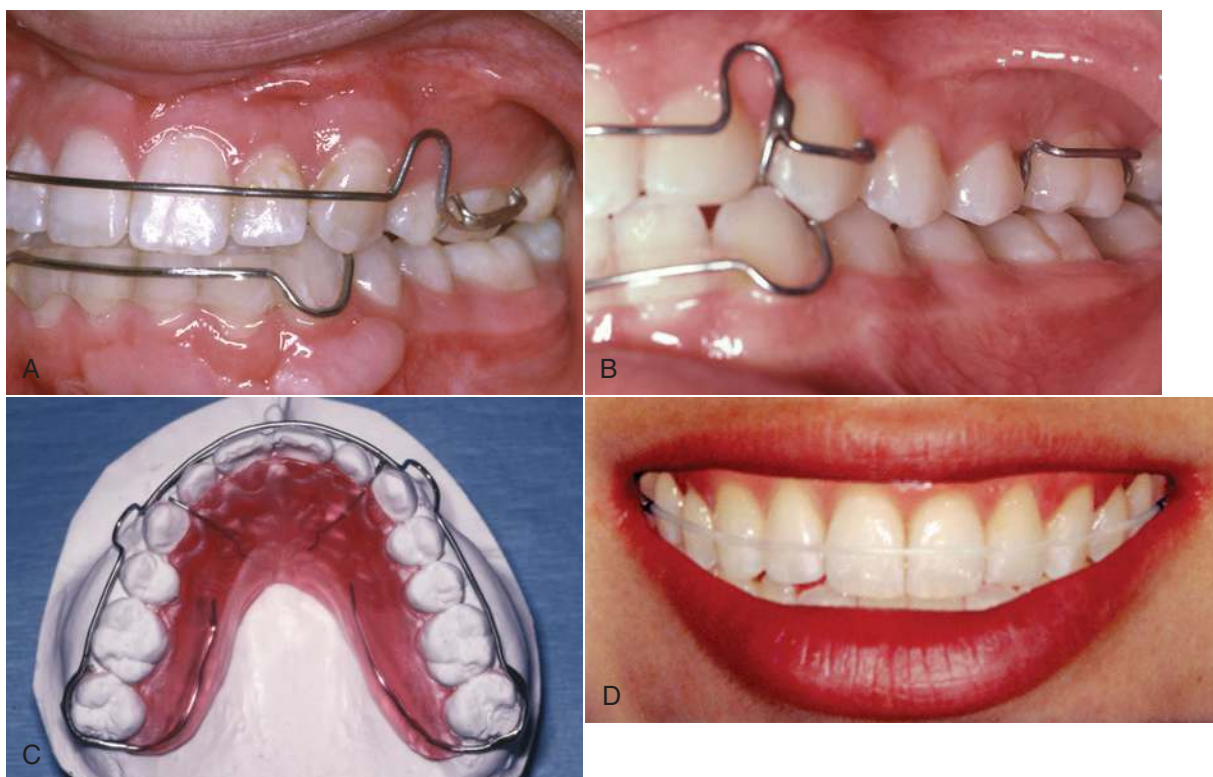
The clasp locations for a Hawley retainer must be selected carefully because clasp wires crossing the occlusal table can disrupt rather than retain the tooth relationships established during treatment. Circumferential clasps on the terminal molar may be preferred over the more effective Adams clasp if the occlusion is tight.

Remember that an important design element for the Hawley retainer is to bring the acrylic behind the upper incisors high enough to control bite depth. For any patient who once had an excessive overbite, light contact of the lower incisors against the baseplate of the retainer is desired.

### Wraparound (Clip) Retainers

A second major type of removable orthodontic retainer is the wraparound or clip-on retainer, which consists of a plastic bar (usually wire-reinforced) along the labial and lingual surfaces of the teeth. Retainers of this type are particularly indicated when the goal is to prevent spaces from reopening. In the mandibular arch, canine-to-canine clip-on retainers are used frequently, occasionally extending to include the first premolars (Fig. 18.9). Maxillary anterior clip-on retainers can be useful in adults with long clinical crowns, but usually would not be tolerated in younger patients because of occlusal interferences.

In a mandibular extraction case, usually it is a good idea to extend a canine-to-canine wraparound distally on the lingual aspect only to the central groove of the first molar (Fig. 18.10). This is called a *Moore retainer*. It provides control of the second premolar and the extraction site but must be made carefully to avoid lingual undercuts in the premolar and molar region. The Hawley design does not work well for the mandibular arch because these undercuts compromise both the insertion-removal path and clasp effectiveness.



• **Fig. 18.8** A canine-to-canine anterior bow and clasps on molars are the characteristic features of the Hawley retainer design. (A) A Hawley retainer for a patient with maxillary premolar extractions, with the anterior bow soldered to Adams clasps on the first molars so that the extraction site is held closed. (B) The adjustment loop of the Hawley anterior bow often keeps the wire from having full contact with the canines. If good control of the canines is needed, as in this patient whose canines were facially positioned before treatment, a wire that extends across the canines can be soldered to an anterior bow that crosses distal to the lateral incisor. (C) In a patient whose second molars have erupted, a wraparound outer bow soldered to C-clasps on the second molars provides a way to avoid interference as the retainer wire crosses the occlusion, but a bow with such a long span will be quite flexible. (D) A removable maxillary retainer with a clear outer bow, which fits more tightly than a metal wire and is better esthetically but cannot be adjusted to modify tooth positions without starting over with a new retainer.

### Clear (Vacuum-Formed) Retainers

A retainer made with a clear heat-softened plastic that is sucked down tightly over the teeth with a vacuum-forming device is another form of the older wraparound retainer made with acrylic and wire. Because the material is transparent and thin, a vacuum-formed retainer is all but invisible, and most patients prefer them. At present this is the most widely used retainer for the maxillary arch, and patients using a clear retainer report greater satisfaction with their treatment than those with other types of retainers.<sup>8</sup> In terms of effectiveness of maintaining incisor alignment, there is no difference between these retainers and a bonded wire retainer.<sup>9</sup> This implies excellent compliance, and it does seem that patients are more likely to wear a clear retainer regularly.

As with anything else, there are limitations to vacuum-formed retainers:

- The thickness of the material over the occlusal surface of the teeth can become a problem, especially if both the upper and lower arches are retained in this way, because separation of the posterior teeth in occlusion may develop. Posterior occlusion is better at 6 months with a Hawley retainer than a vacuum-formed one for just the maxillary arch, but there is no difference

at longer-term recall.<sup>10</sup> The combination of a vacuum-formed upper and a fixed lower retainer is better than maxillary and mandibular vacuum-formed retainers.

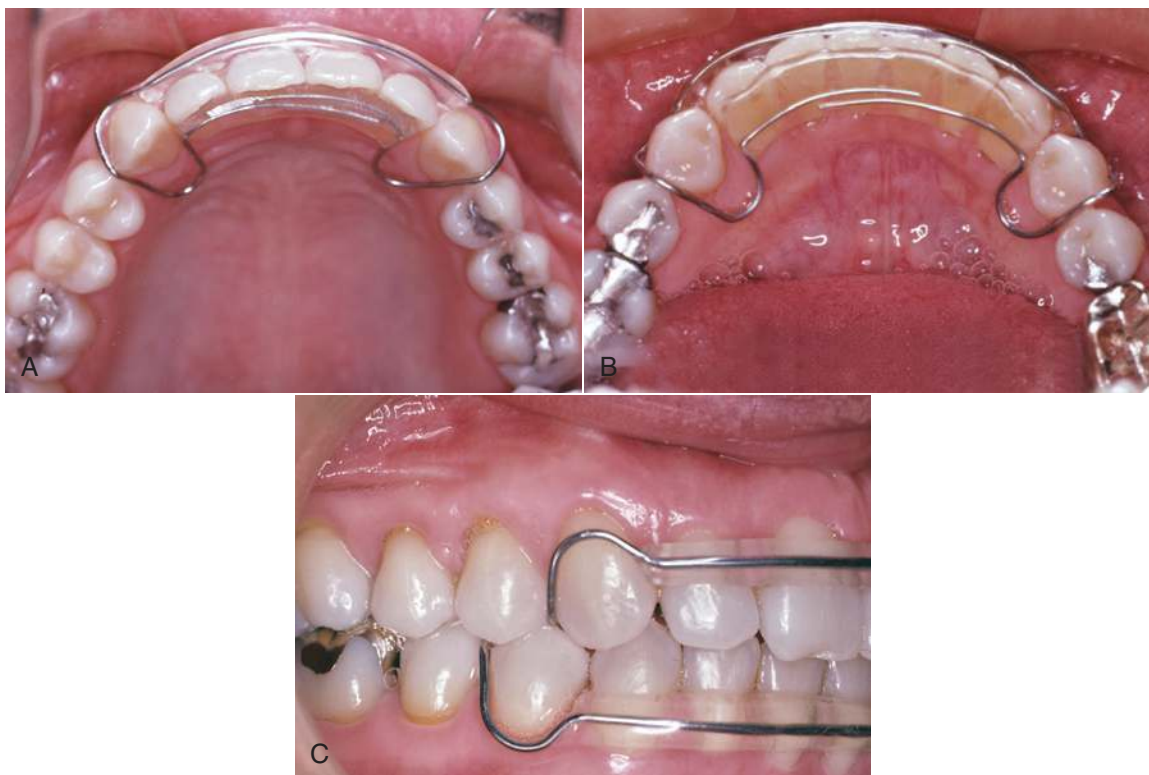- The retainer maintains alignment but does not control deepening of the bite as well as a palate-covering Hawley retainer.
- After 6 to 9 months, a vacuum-formed retainer tends to crack and discolor to the point that it has to be replaced.

It is widely accepted now that use of the final aligner in an Invisalign sequence as a retainer is not as effective as use of other retainer types, because a thinner and less durable material is used in clear-aligner therapy. A heavier material designed specifically for use as a retainer is needed.

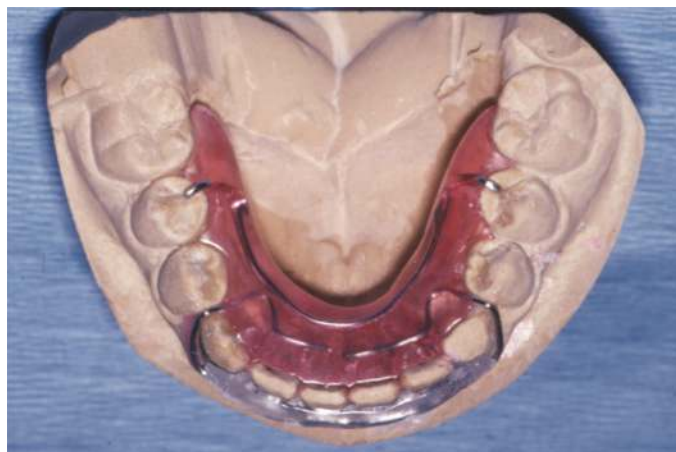
### Positioners as Retainers

A tooth positioner also can be used as a removable retainer, either fabricated for this purpose alone, or more commonly, continued as a retainer after serving initially as a finishing device. As discussed in [Chapter 17](#), positioners now are used primarily as finishing devices for patients with an open bite. A positioner does have one major advantage over a standard removable or wraparound retainer, though; it maintains the occlusal relationships as well





• **Fig. 18.9** (A) A removable maxillary clip-type retainer that controls alignment of the incisors is rarely used because the Hawley retainer does that while controlling maxillary posterior teeth as well while offering vertical control of the lower incisors. Its primary indication is for patients who had major spacing of the upper incisors initially. In contrast, this clip-on design, seen in Fig. 18.10 below, is preferred as a removable lower retainer over the Hawley design because undercuts lingual to the lower molars make it difficult to place a lower retainer that extends posteriorly. (B) If desired, a maxillary (or mandibular) 3-3 clip-on can be extended to one or both first premolars. This is indicated primarily when the canine(s) had been displaced facially before treatment. (C) Anterior clip retainers 3-3 in the maxilla and 4-4 in the mandible in a patient who had maxillary and mandibular anterior spacing before treatment.



• **Fig. 18.10** For a mandibular retainer, the wire Hawley bow is less effective than a wire-reinforced acrylic bar that tightly contacts the lower incisors. This Moore design has almost completely replaced the Hawley design for lower removable retainers that extend to the posterior teeth. Note that the retainer contacts the upper lingual surface of the first molars but does not extend into the lingual undercuts.

as intra-arch tooth positions. With preformed positioners now available (Ortho-Tain, Winnetka, IL), this can be a consideration for patients with an unfavorable growth pattern. A recent review indicated that positioners of this type were as effective as the combination of a maxillary vacuum-formed retainer and a bonded lingual incisor retainer with or without interproximal stripping.<sup>11</sup>

For a patient with a tendency toward Class III relapse, a positioner made with the jaws rotated somewhat downward and backward may be useful. Although a positioner with the teeth set in a slightly exaggerated “supernormal” from the original malocclusion can be used for patients with a skeletal Class II or open bite growth pattern, it is less effective in controlling growth than a functional appliance or nighttime headgear.

## Fixed Retainers

Fixed (bonded) orthodontic retainers are normally used where intra-arch instability is anticipated and prolonged retention is planned.<sup>12</sup> There are three major indications:

- Maintenance of lower incisor position during late growth
- Diastema maintenance
- Maintenance of posterior tooth position in adults

Let's consider them in that order.

## Maintenance of Lower Incisor Position During Late Growth

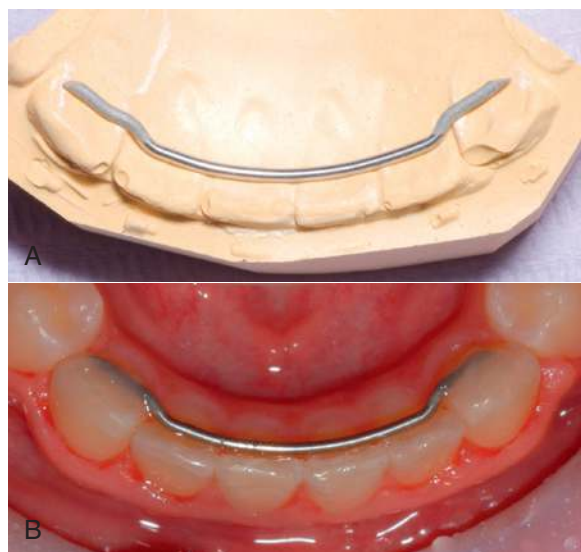
Lower incisor crowding that develops in the late teen years is largely due to late growth of the mandible in the normal growth pattern. Especially if the lower incisors have previously been irregular, even a small amount of differential mandibular growth between ages 16 and 20 can cause a return of incisor crowding. This is relapse because it is caused by tooth movement, but it also is a form of recurrence in that it is related to forward growth of the mandible relative to the other facial structures.

An excellent retainer to hold these teeth in alignment is a fixed lingual bar, attached only to the canines and resting against the flat lingual surface of the lower incisors above the cingulum (Fig. 18.11). This prevents the incisors from moving lingually and is also reasonably effective in maintaining correction of rotations in the incisor segment.

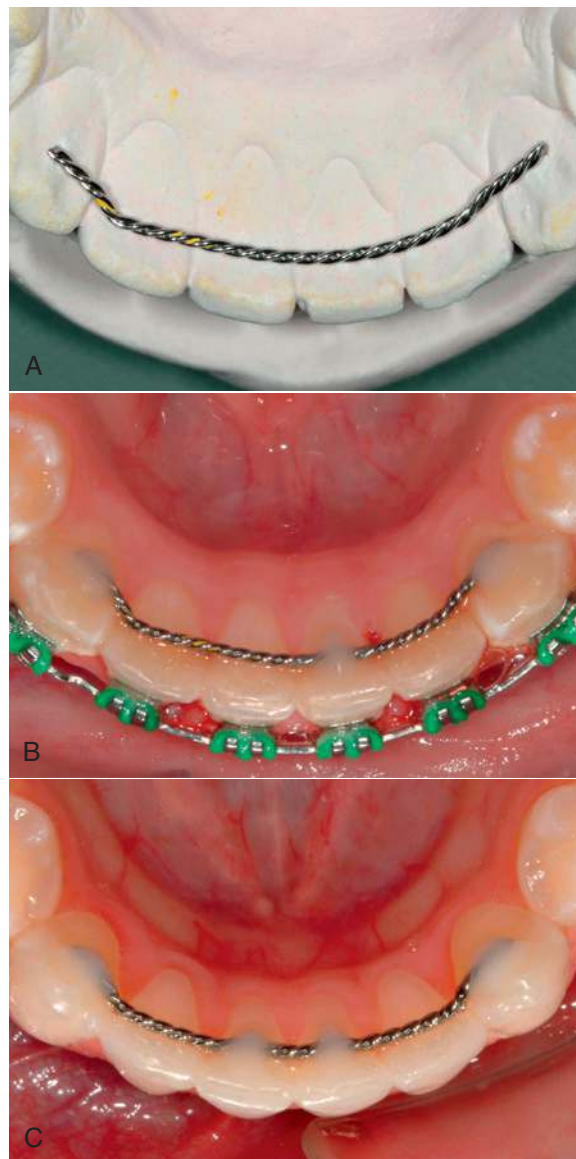
Fixed canine-to-canine retainers must be made from a wire heavy enough to resist distortion over the rather long span between these teeth. Usually 28- or 30-mil steel is used for this purpose. With this design, a bonded retainer can remain in place for many years. Although there has been concern about a long-term effect on periodontal health because of the difficulty of flossing with a retainer in place, long-term recall of patients who had worn a bonded lower retainer for more than 20 years showed no negative effect on periodontal health.<sup>13</sup> In fact, those who were still wearing the retainer many years later tended to be in better health than those who had lost their retainer or had it removed. A similar finding was made in a recent national survey of periodontal health in South Korea: those with previous orthodontic treatment had better periodontal health in the long term.<sup>14</sup>

It is also possible to bond a fixed lingual retainer to all or some of the incisor teeth. The major indication for this variation is a

tooth or teeth that have been severely rotated. Whatever the type of retainer, however, it is desirable not to hold the teeth rigidly during retention. For this reason, if the span of the retainer wire is reduced by bonding an intermediate tooth or teeth, a more flexible wire should be used. A good choice for a fixed retainer with adjacent teeth bonded (Fig. 18.12A–B) is a braided steel archwire of 17.5-mil diameter. A springy wire of this type must be quite passive when bonded in place.

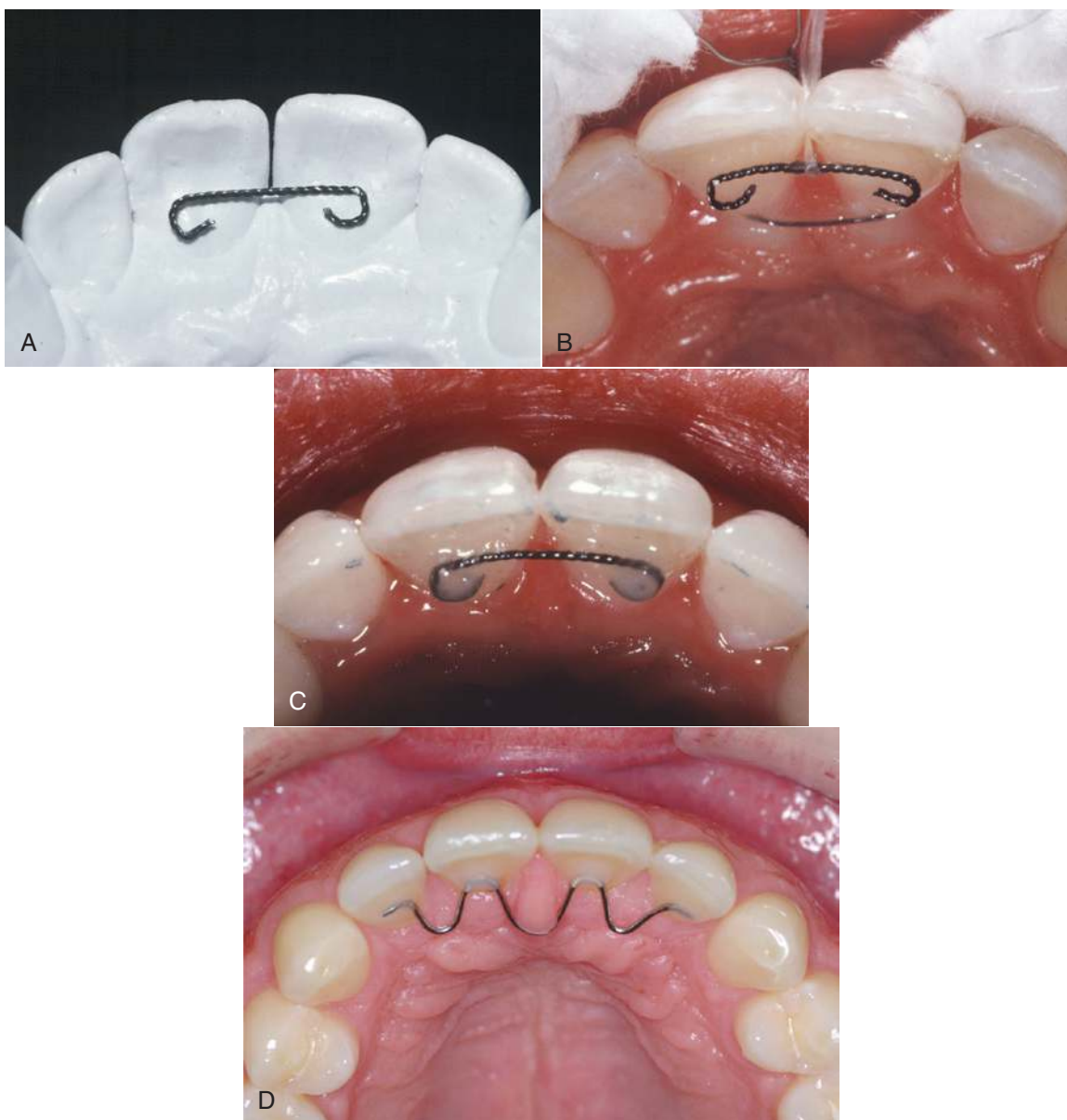


• **Fig. 18.11** (A) A bonded canine-to-canine retainer in the lower arch is fabricated on a lower cast, often with a carrier to hold it in position while it is being bonded. (B) A bonded canine-to-canine retainer, with retention pads, in place. Data now show that wire retention loops are better than retention pads in decreasing the chance that the retainer will break loose.<sup>9</sup>



• **Fig. 18.12** It is desirable to place a bonded lingual retainer in the lower arch immediately after removing the active appliance, and often the best way to do that is to bond the retainer just before removing the archwire and brackets. (A) Fitting a piece of passive 0.032 twist wire on a quick impression of just the lingual surface of the lower teeth, adjusting it to fit above the cingulae of the incisors and canines. (B) The retainer being bonded to the canines and one lower incisor before archwire and bracket removal. (C) The completed retainer. This design, with bonding of the canines and central but not lateral incisors, is an effort to combine some movement of the incisors during function with a larger wire for better stability. No data yet exist to compare it with other fixed lingual retainers. (Courtesy Dr. T. Shaughnessy.)





• **Fig. 18.13** Bonded lingual retainer for maintenance of a maxillary central diastema. (A) Use of 17.5-mil twist wire contoured to fit passively on the dental cast. (B) A wire ligature is passed around the necks of the teeth to hold them tightly together while they are bonded. The wire retainer is held in place with dental floss passed around the contact, and (C) composite resin is flowed onto the cingulum of the teeth, over the wire ends. Note that the retainer wire is up on the cingulum of the teeth to avoid contact with the lower incisors. (D) A Hawley retainer can be worn to stabilize other teeth and maintain vertical control in the presence of a bonded segment of this type.

For long-term stability, enough movement of the mandibular incisors to promote maturation of the supporting bone is important, and the canine-to-canine fixed retainer allows this without restraint. But it does not resist re-rotation as well as a smaller flexible wire bonded to the incisors. On the other hand, with all the teeth bonded, bond failure and long-term problems are a greater risk.

### Maintenance of Diastema Closure

A second indication for a fixed retainer is a situation in which teeth must be permanently or semipermanently bonded together to maintain the closure of a space between them. This is always

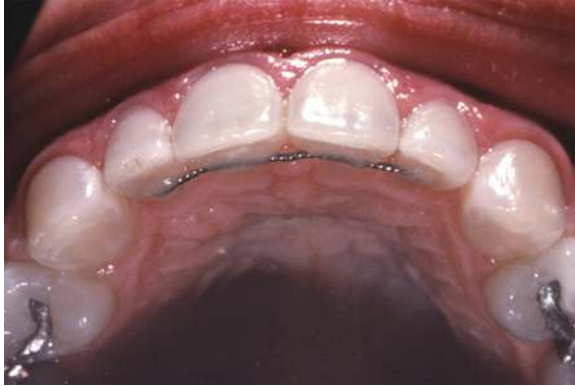the case when a diastema between maxillary central incisors has been closed. Even if a frenectomy has been carried out (see [Fig. 15.22](#)), there is a tendency for a small space to open between the upper central incisors. A removable retainer is not a good choice for prolonged retention of a central diastema. In troublesome cases, the diastema is closed when the retainer is in place but opens up quickly when it is removed. This “jiggling” tooth movement that accompanies this back-and-forth closure is potentially damaging to the periodontium and should be avoided.

The best retainer for this purpose is a bonded segment of flexible wire, as shown in [Fig. 18.13](#). The wire should be contoured so that it lies near the cingulum to keep it out of occlusal contact.



The object of the retainer is to hold the teeth together while allowing them some ability to move independently during function, hence the importance of a flexible wire.

If generalized spacing existed between maxillary or mandibular incisors, a bonded section of flexible wire attached to more teeth can be used to keep the teeth together, extending canine-to-canine



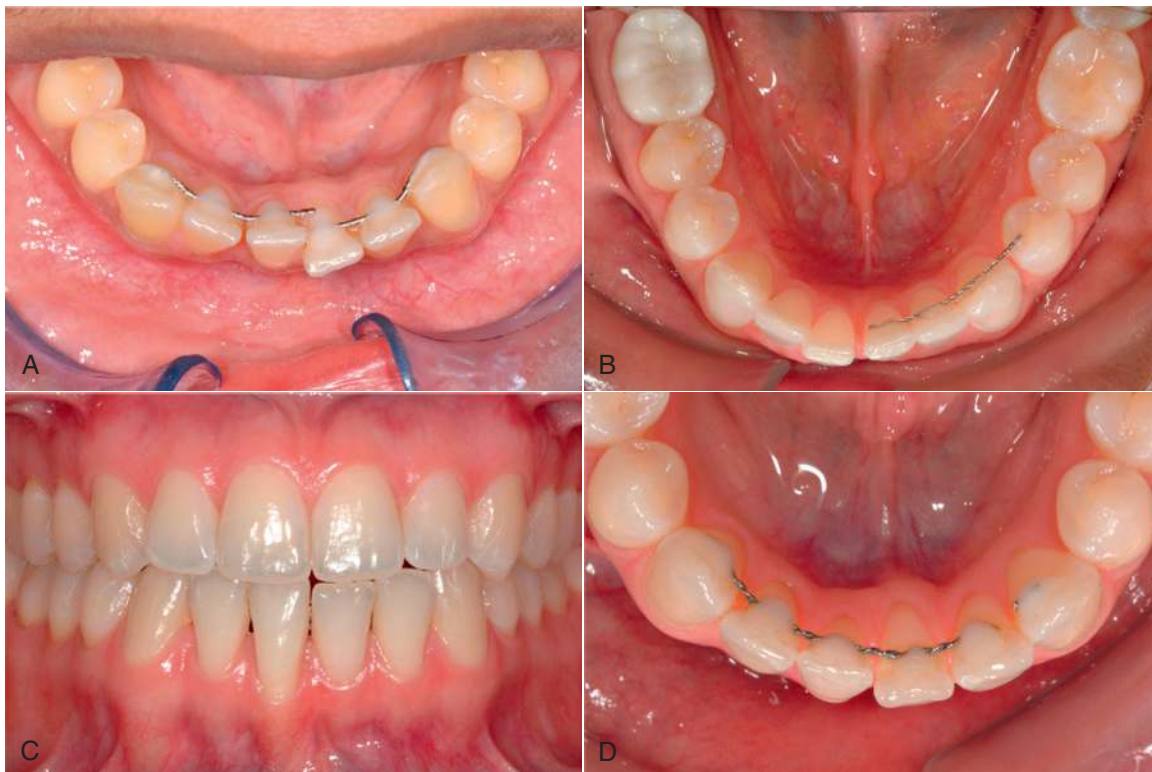• **Fig. 18.14** A section of twist wire, usually bonded just to the four maxillary incisors, also can be used to maintain alignment of maxillary incisors that were severely displaced. A wire segment such as this also can be used to prevent deepening of the bite as lower incisors erupt.

in the same way as a retainer to maintain alignment (Fig. 18.14). Extending the bonded wire to the premolars increases the chance of bonding failure and is indicated only rarely.

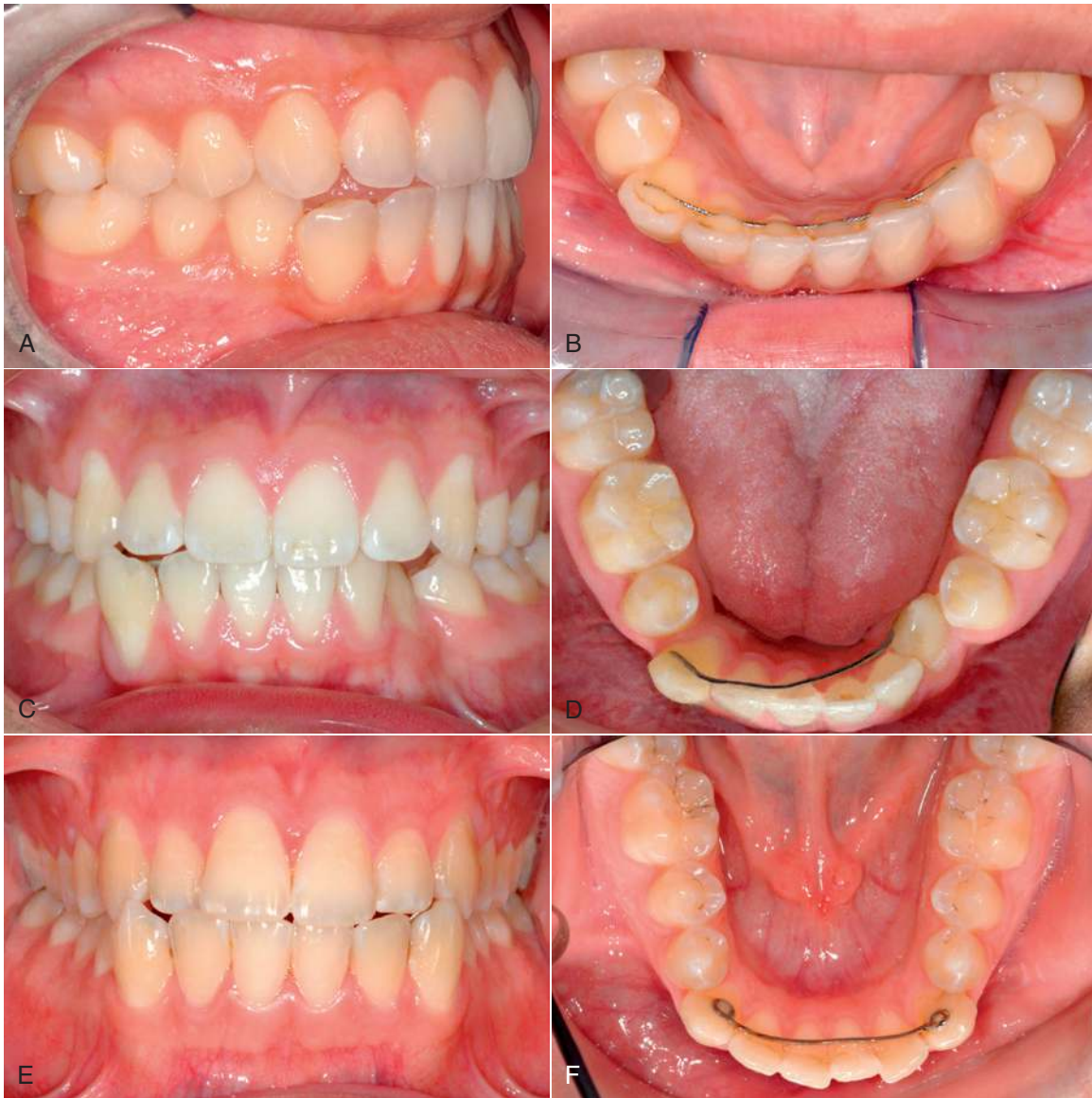### Inadvertent Tooth Movement With Fixed Lingual Retainers

Recent experience has shown an unexpected hazard with fixed lingual retainers: the wires, even those carefully fabricated to be passive, can produce unexpected long-term changes. Fortunately, this happens rarely. Unfortunately, the extent of change when it does occur can be far beyond trivial (Fig. 18.15).<sup>14a</sup> Until recently, most orthodontists were unaware that this occurred; those who had seen it thought it was just bad luck with one or two of their patients. Now it is clear that patients with fixed retainers in place need regular observation, by a family dentist if not the orthodontist, because remarkable changes can develop slowly over time before the patient decides to see someone about it.

Loss of lower incisor alignment from inadvertent tooth movement is more likely when wires break. This is most likely with smaller dimension wires bonded to all the anterior teeth, whether dead soft or small spiral elastic wires were used. When a wire breaks, it is likely to become distorted at the same time, and that can lead to activation of the wire even if it was passive previously. Canine-to-canine wires must be larger and are unlikely to break. Perhaps



• **Fig. 18.15** Breakage of bonded lingual retainers appear to be more frequent (although still rare) when dead soft wire is used, and significant displacement of teeth can occur after breakage, presumably because the fracture also activated the wire. (A) For this patient, after breakage of the wire in the midline, the left incisors were tipped facially and the canine was torqued lingually. The other segment showed less effect, but root movement of the right canine also occurred. (B) This patient lost the wire fragment from the right first premolar to the central incisor, probably well after breakage occurred, which led to root torque in opposite directions on the right central and lateral incisors. The left side remained reasonably stable. (C and D) Breakage of this wire bonded to the canines and all incisors occurred between the left canine and lateral incisor, with torque effects on all the incisors. (Courtesy Dr. T. Shaughnessy.)



• **Fig. 18.16** Displacement of teeth from a bonded lingual retainer wire that is still intact also can occur, with both dead soft and twist wires. (A and B) Dead soft wire completely intact, with long-term facial tipping of the right canine and torque of the right lateral incisor and central incisor in opposite directions. (C and D) This twist wire was still secured at both canines but had debonded from the incisors. Note the skewing of the arch form and the severe torque in opposite directions on the canines. (E and F) This twist wire had debonded from the incisors when it was forced downward, but remained bonded to the canines, both of which were expanded and tipped facially. (Courtesy Dr. T. Shaughnessy.)

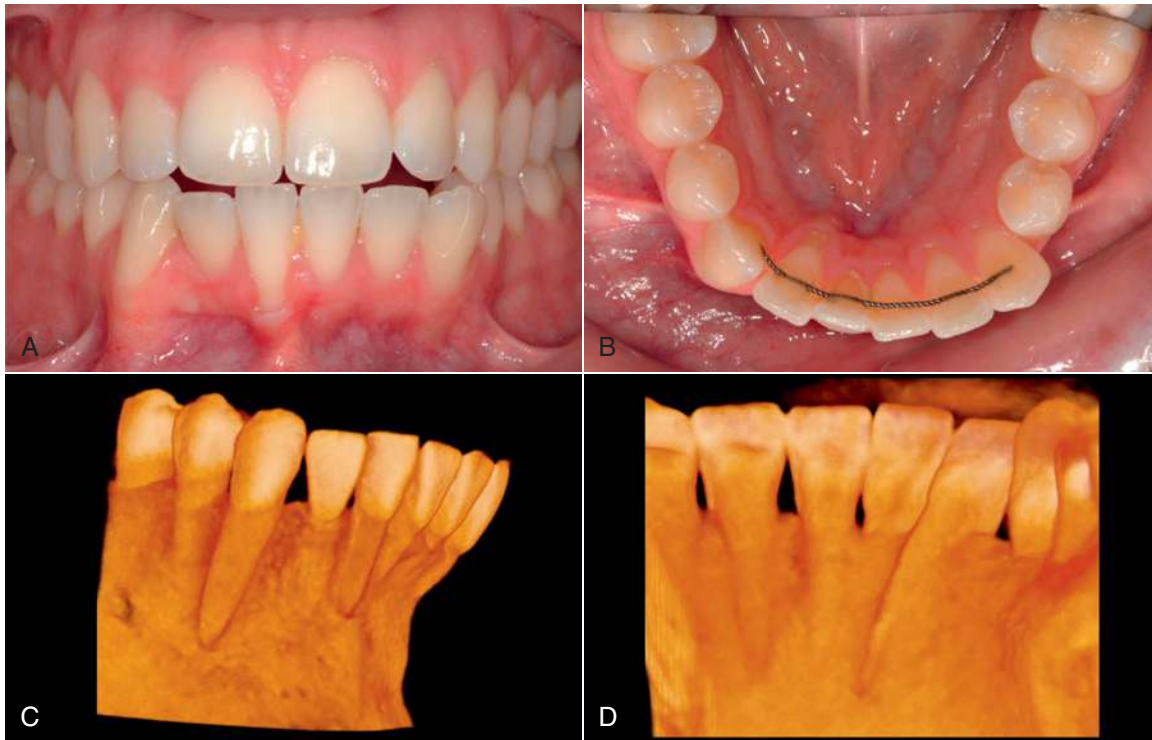
more important, if the bond to one canine is lost, the retainer is likely to break loose from the other one, and if not, the patient will almost surely notice the loose wire.

It is quite possible, however, for problems to arise when the retainer remains bonded (Fig. 18.16). With spiral wires, tooth movement due to a wire that was slightly distorted as it was being bonded could be the problem, and downward deflection of the wire could occur if the bonds to the incisors failed but the canines remained bonded. As the figures show, displacement of the tooth roots by inadvertent torque forces is as likely as displacement of the crowns, and this may cause fenestration of the labial or lingual

alveolar cortical bone (Fig. 18.17). Retreatment is needed in such cases, with light and then rectangular archwires to correct both alignment and root displacement. For patients as severely affected as the one shown in Fig. 18.18, coordinated periodontal surgery and orthodontic treatment is likely to be needed.

Inadvertent tooth movement also can become a problem with a bonded diastema retainer, such as the one shown in Fig. 18.13. Although it has been suggested that a dead soft wire is a safer choice in this situation, there is no evidence that this is correct; long-term problems can occur with dead soft wire as with flexible twist wire (Fig. 18.19).





• **Fig. 18.17** (A and B) Intact twist wire lingual bonded retainer, with severe facial root torque of the right canine, severe lingual root torque of the right lateral incisor, and facial tipping of the right incisors and canine. (C and D) Three-dimensional renderings from small-field-of-view cone beam computed tomography showing that the roots of both canines and the right lateral incisor were through the cortical plate. For problems of this severity, retreatment with coordinated orthodontic and periodontic care is necessary. (Courtesy Dr. T. Shaughnessy.)

This experience makes it plain that long-term professional supervision of fixed lingual retainers is needed. Patients with fixed retainers should be seen in the initial retention period by the orthodontist, perhaps for the first 2 years when bond failure rates are greatest. After 2 years, it would seem most practical for the patient's family dentist to inspect the fixed retainer at regular dental checkups at 6- to 12-month intervals.

### Maintenance of Spaces in the Dental Arch

A fixed retainer is also the best choice to maintain a space where an implant (or bridge poetic) eventually will be placed. There often is a delay in placing the restoration that will serve, among other functions, as a permanent orthodontic retainer. If further periodontal therapy or a bone graft is needed after the teeth have been positioned, several months or even a year can pass, and a fixed retainer is much better than a removable one.

The preferred retainer for maintaining space for posterior restorations is a heavy intracoronal wire bonded to the adjacent teeth (Fig. 18.20). Obviously, the longer the span, the heavier the wire should be. Bringing the wire down out of occlusion decreases the chance that it will be displaced by occlusal forces.

Anterior spaces need a replacement tooth, which can be attached to a removable retainer. This approach guarantees nearly full-time wear and is satisfactory for short periods. After a few months,

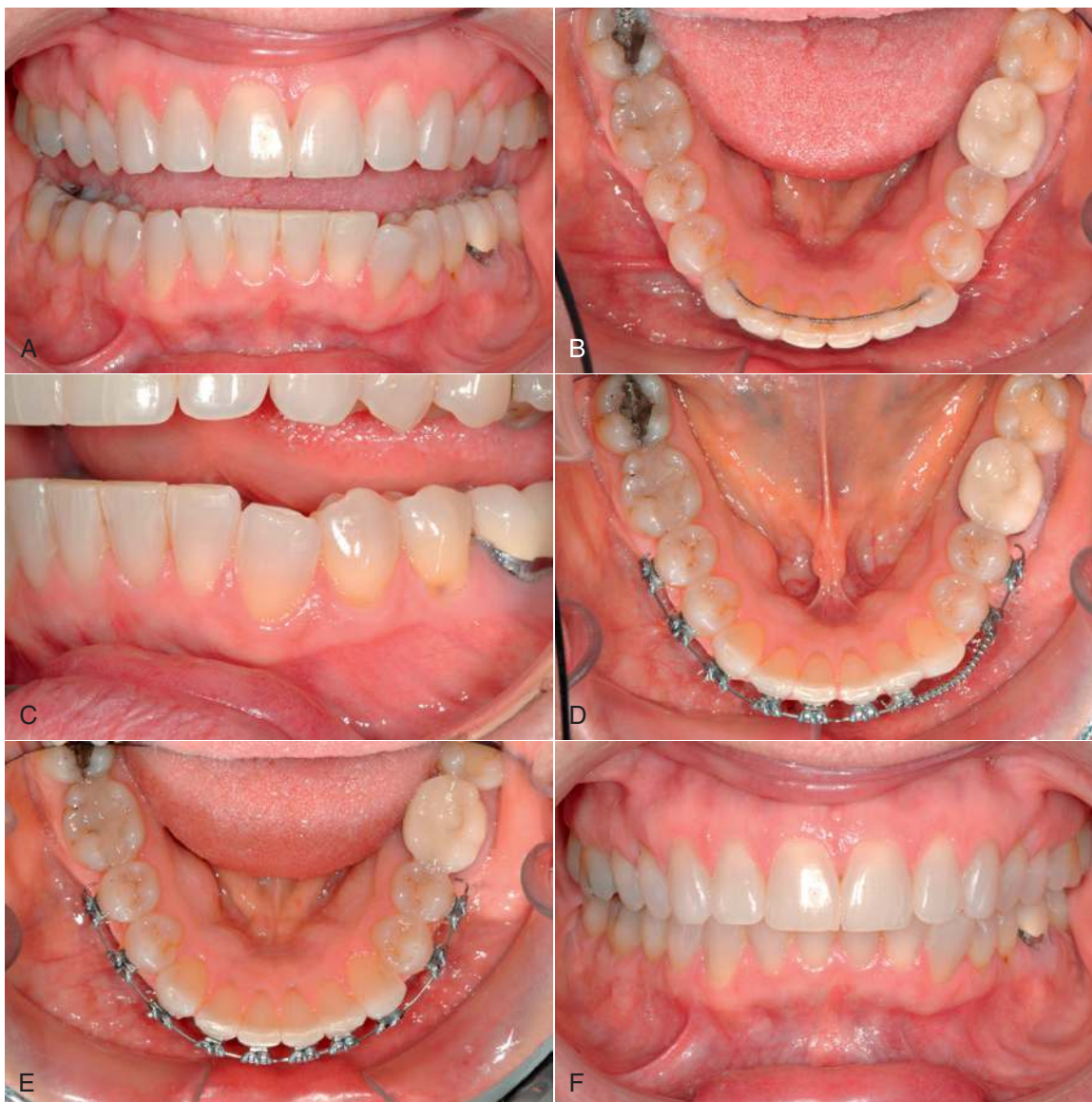especially if an implant or permanent bridge will be delayed for a long time while adolescent vertical growth is completed, it is better to place a fixed retainer in the form of a temporary bonded bridge.

The major objection to any fixed retainer is that it makes interproximal hygiene procedures more difficult, especially in the lower anterior area. In this sense, there is both bad and good news: there is greater plaque buildup when a multistrand wire is bonded to all the lower anterior teeth than when a heavier round wire is bonded only to the canines, but a wire bonded to all the teeth is more effective in maintaining alignment.<sup>15</sup> It is possible to floss between teeth that have a fixed retainer across the interdental contact areas by using a floss-threading device, and the orthodontist should teach and strongly encourage this.

### Active Retainers

"Active retainer" is a contradiction in terms because a device cannot be actively moving teeth and serving as a retainer at the same time. It does happen, however, that relapse or growth changes after orthodontic treatment lead to a need for some tooth movement during retention. This usually is accomplished with a removable appliance that continues as a retainer after it has repositioned the teeth; hence the name. A typical Hawley retainer, if used initially to close a small amount of band space, can be considered an active retainer, but the term usually is reserved for two specific situations:





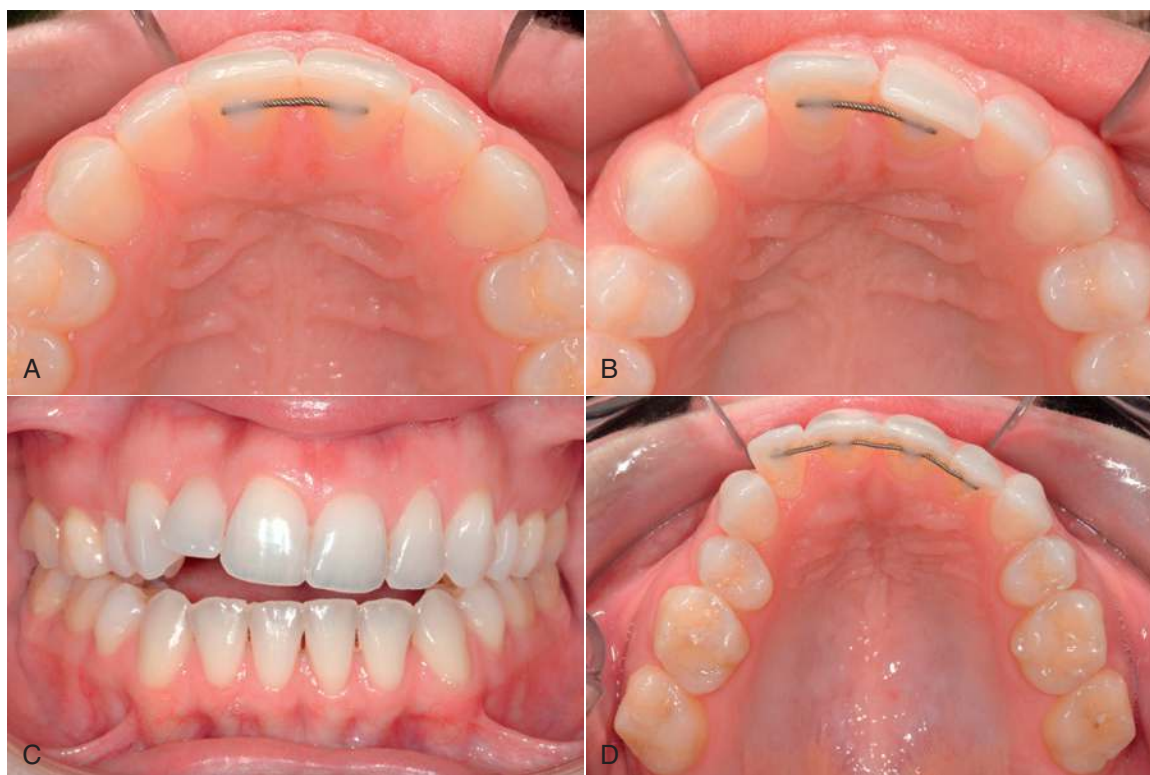• **Fig. 18.18** Retreatment in a patient with significant displacement of a tooth or teeth is done much more efficiently with a bonded labial appliance than with removable appliances of any type. Retreatment for the patient shown in Fig. 18.16 required periodontal bone grafting and bond induction therapy as well as orthodontic repositioning of the displaced roots. (A to C) Four years after treatment the patient returned with concern about the facial tipping of the mandibular right canine, which created an occlusal interference and wear on this tooth that increasingly bothered her. The decision was to bond 5-5, open space to reposition the canine, and then upright it. (D) Coil spring in position on 16-mil steel wire to open space. (E) Steel wire now tied into canine bracket. (F) Realignment completed after 6 months of treatment, with use of a rectangular archwire for final root positioning. (Courtesy Dr. T. Shaughnessy.)

realignment of irregular incisors with spring retainers and management of Class II or Class III relapse tendencies with modified functional appliances.

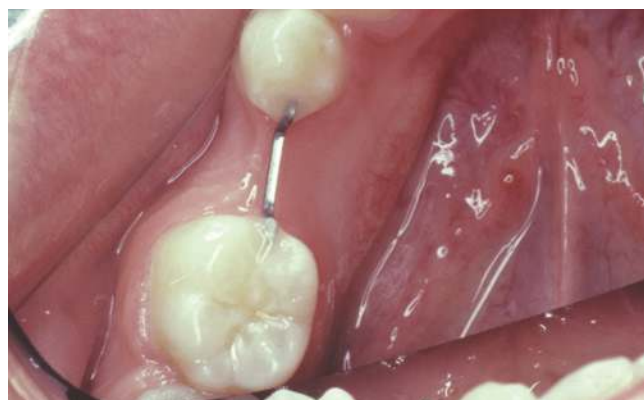### Realignment of Irregular Incisors

Re-crowding of lower incisors is the major indication for an active retainer to correct incisor position. The shape of the incisor crowns

can contribute to re-crowding,<sup>16</sup> but the cause of the problem in these cases usually is late mandibular growth that tipped the incisors lingually. If late crowding has developed, it often is necessary to reduce the interproximal width of lower incisors before realigning them, so that the crowns are not forced labially into an obviously unstable position. Not only does stripping of contacts reduce the mesiodistal width of the incisors, decreasing the amount of space required for their alignment, but it also



• **Fig. 18.19** Bonded retainers to maintain closure of a maxillary central incisor also can produce inadvertent tooth movement. (A) Dead soft retainer wire at end of diastema closure and (B) 8 years later. A photo at 4 years showed a mild irregularity; obviously the active torque in what seemed a passive wire persisted. (C and D) It has been suggested that a retainer wire bonded to both the lateral and the central incisors is a more stable way to maintain a central diastema closure. Obviously, this is not always the case. (Courtesy Dr. T. Shaughnessy.)



• **Fig. 18.20** A fixed retainer (sometimes called an A-splint) to maintain space for eventual replacement of a missing second premolar. A shallow preparation has been made in the enamel of the marginal ridges adjacent to the extraction site, and a section of 21 × 25 wire, stepped down away from the occlusion, is bonded as a retainer.

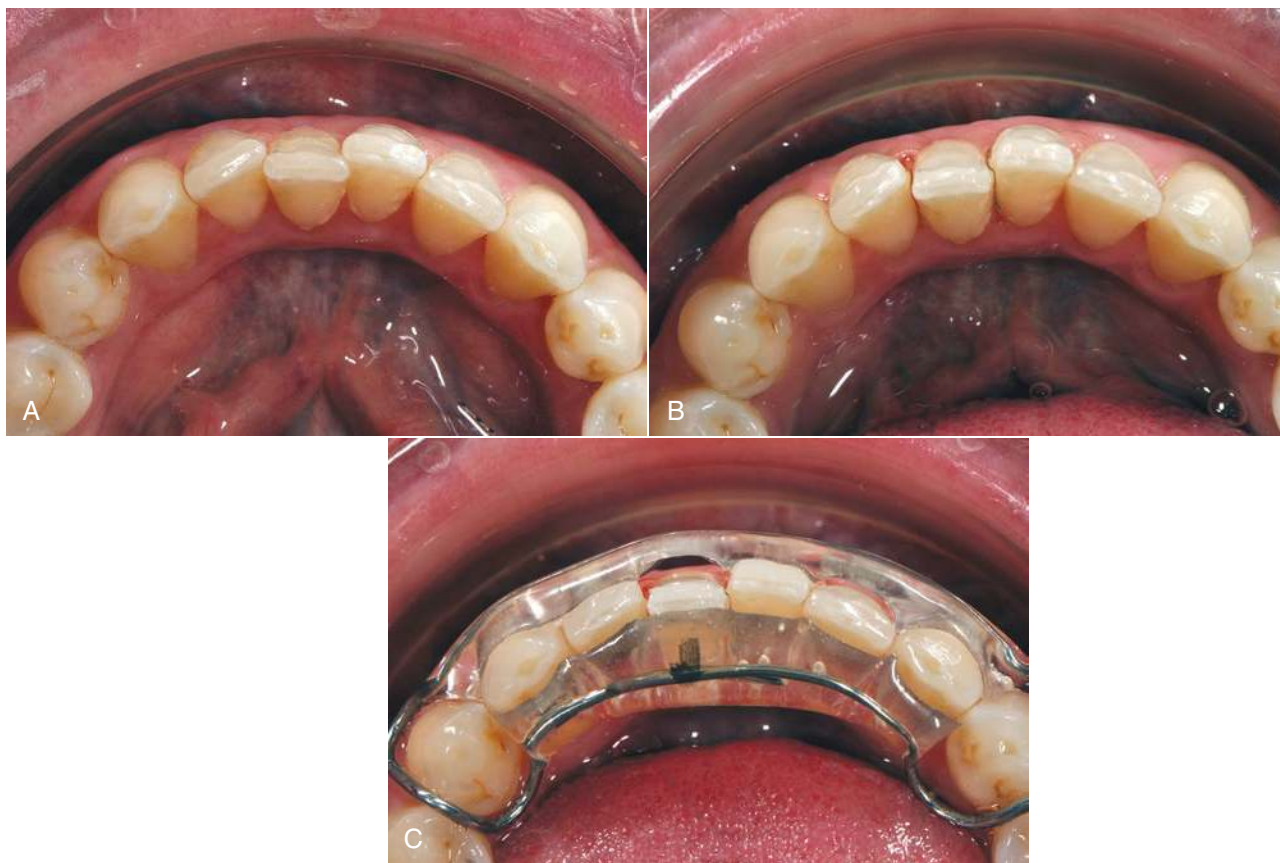flattens the contact areas. This increases the inherent stability of the arch in this region. If stripping is done cautiously and judiciously, data indicate that long-term periodontal health is not affected by the increase in root proximity that would be an inevitable side effect.<sup>17</sup>

Interproximal enamel can be removed with either abrasive strips, thin disks in a handpiece, or thin flame-shaped diamond stones. Obviously, enamel reduction should not be overdone, but if necessary, the width of each lower incisor can be reduced up to 0.5 mm on each side without going through the interproximal enamel. If an additional 2 mm of space can be gained, reducing each incisor 0.25 mm per side (Fig. 18.21), it is usually possible to realign these teeth after moderate relapse.

After interproximal reduction to achieve appropriate space, there now are two ways to complete the realignment: an active canine-to-canine clip-on device, or a short series of aligners produced in-office with a three-dimensional (3-D) printer. The steps in making such an active retainer are (1) reduce the interproximal width of the incisors and apply topical fluoride to the newly exposed enamel surfaces; (2) prepare a laboratory model on which the teeth can be reset into alignment; and (3) fabricate an alignment device to fit the model (Fig. 18.22). The 3-D printer technology to achieve alignment would be the same as with other applications of in-office aligners, and is discussed in Chapter 19.

If there is more than a modest degree of relapse, however, a fixed appliance for retreatment must be considered. With bonded brackets on the lower arch from premolar to premolar, space can be opened and superelastic nickel–titanium (NiTi) wires can be used to bring the incisors back into alignment quite efficiently (Fig. 18.23). It is wise to include some interproximal reduction when this is done, at least enough to flatten the contact areas. Permanent retention obviously will be required after the realignment,





• **Fig. 18.21** Removal of interproximal enamel to facilitate alignment of crowded lower incisors. (A and B) Before and after use of a carbide-coated strip to remove enamel. The surfaces are polished after the stripping is completed. Topical fluoride should be applied immediately after stripping procedures because the fluoride-rich outer layer of enamel has been removed. (C) A canine-to-canine clip-on active retainer for this patient immediately after placement. It was made as described in [Fig. 18.22](#) and must be worn full-time until the teeth are back in alignment.

so a bonded lingual retainer should be placed before the brackets are removed.

### Correction of Occlusal Discrepancies: Modified Functional Appliances as Active Retainers

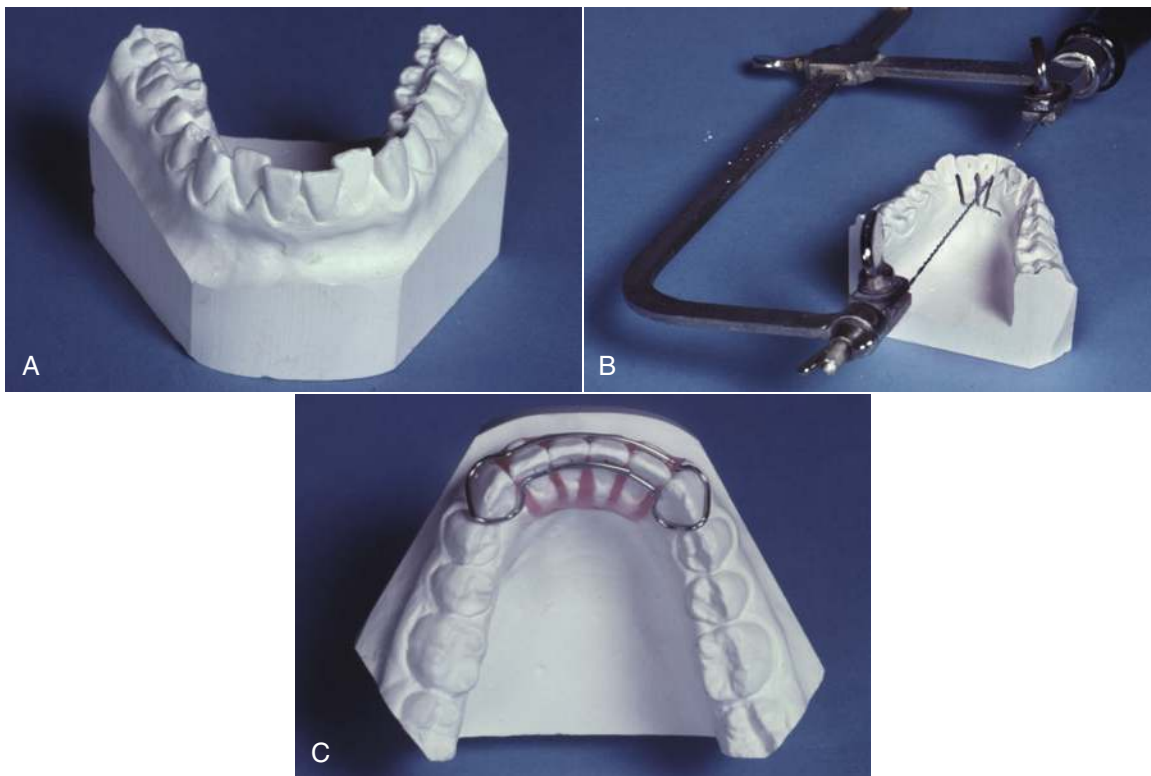
It is possible to describe an activator as consisting of maxillary and mandibular retainers joined by an interocclusal bite block. Although even the simplest activator is more complex than that (see [Chapter 13](#)), the description does illustrate the potential of a modified functional appliance to simultaneously maintain the position of teeth within the arches while altering, at least minimally, the occlusal relationships.

A typical use for an activator or Bionator as an active retainer would be in a male adolescent who had slipped back 2 to 3 mm toward a Class II relationship after early correction. It would look exactly like the functional appliance retainer (see [Fig. 18.5](#)), except that the bite was taken to advance the mandible the 2 to 3 mm needed to correct the occlusion. If the patient still is experiencing some vertical growth (almost all boys younger than age 18 fall

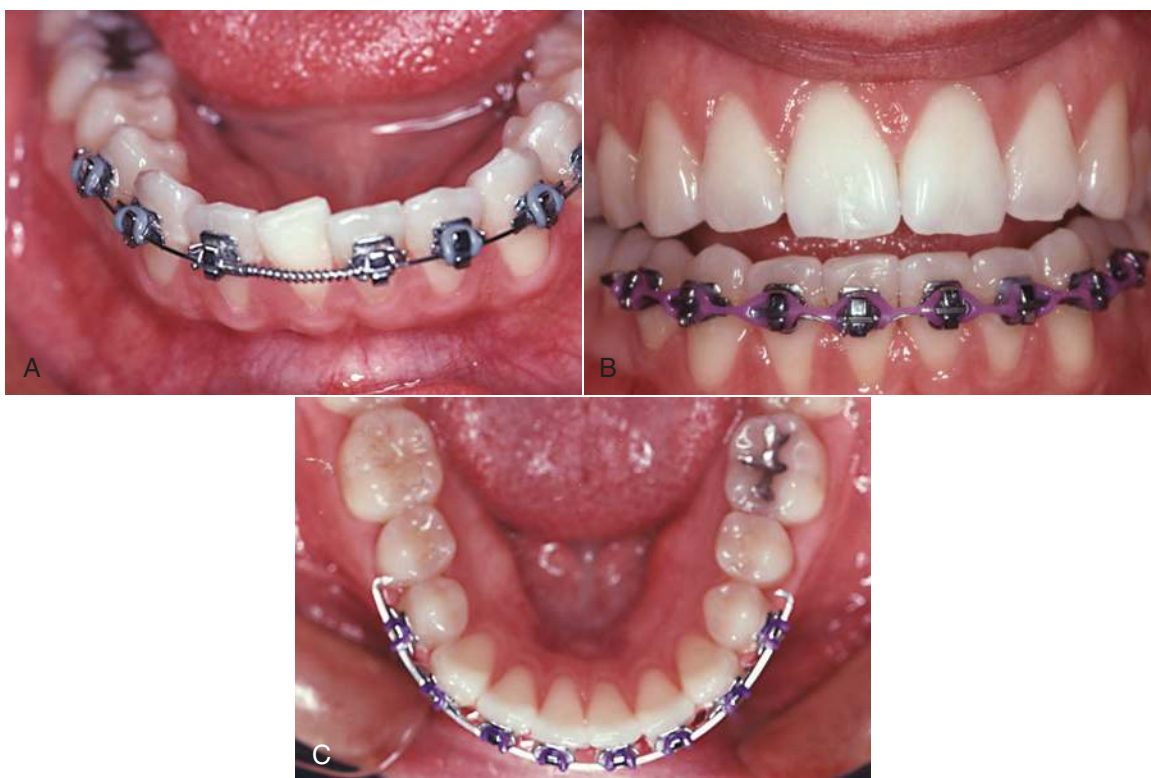into this category), it may be possible to recover the proper occlusal position of the teeth. Differential anteroposterior growth is not necessary to correct a small occlusal discrepancy—tooth movement is adequate—but some vertical growth is required to prevent downward and backward rotation of the mandible. For all practical purposes, this means that a functional appliance as an active retainer can be used in teenagers but is of no value in adults. Stimulating skeletal growth with a device of this type simply does not happen in adults, at least to a clinically useful extent.

The use of a functional appliance as an active retainer differs from its use as a pure retainer. With use as a retainer, the objective is to control growth, and tooth movement is largely an undesirable side effect. In contrast, an active retainer is expected primarily to move teeth—no significant skeletal change is anticipated. An activator or Bionator as an active retainer is indicated only if not more than 3 mm of occlusal correction is sought. Over this distance, correction can be achieved by restraining the eruption of maxillary teeth posteriorly and directing the erupting mandibular teeth anteriorly.





• **Fig. 18.22** Steps in the fabrication of a canine-to-canine clip-on appliance to realign lower incisors. (A) Re-crowded incisors in a patient who decided to “take a vacation” from retainer wear. After the teeth have been stripped appropriately, an impression is made for a laboratory cast. (B) A saw-cut is made beneath the teeth through the alveolar process to the distal of the lateral incisors, and cuts are made up to but not through the contact points. (C) The incisor teeth are broken off the cast and broken apart at the contact points, creating individual dies, and the cast is trimmed to provide space for resetting the teeth; then the teeth are reset in wax in proper alignment and 28-mil steel wire is contoured around the labial and lingual surface of the teeth as shown, with the wire overlapping behind the central incisors. A covering of acrylic is added over the labial part of the wire, completing the aligner, which then looks exactly like a canine-to-canine clip-on retainer. If the appliance is used as an aligner, however, full-time wear is essential until the teeth are back in position.



• **Fig. 18.23** For this patient who was concerned about crowding of lower incisors several years after orthodontic treatment, excessive stripping of interproximal enamel would have been required to gain realignment with a clip-on removable appliance. In that circumstance, a partial fixed appliance with bonded brackets only on the segment to be realigned is the most practical approach. (A) Bonded appliance from first premolar to first premolar, with a coil spring on 16-mil round steel wire to open space for the rotated and crowded right central incisor. (B and C) Alignment of the incisors on rectangular nickel–titanium (NiTi) wire after space was opened, which was completed 4 months after treatment began. At this point a fixed lingual retainer can be bonded before the brackets and archwire are removed.

## References

1. Ormiston JP, Huang GJ, Little RM, et al. Retrospective analysis of long-term stable and unstable orthodontic treatment outcomes. *Am J Orthod Dentofacial Orthop.* 2005;128:568–574.
2. Joondeph DR, Huang G, Little R. Stability, retention, and relapse. In: Graber TM, Vararsdall RL, Vig KWL, Huang G, eds. *Orthodontics: Current Principle and Techniques*. 6th ed. St. Louis: Mosby; 2017.
3. Reitan K. Tissue rearrangement during the retention of orthodontically rotated teeth. *Angle Orthod.* 1959;29:105–113.
4. Schott TC, Schlipf C, Glasl B, et al. Quantification of patient compliance with Hawley retainers and removable functional appliances during the retention phase. *Am J Orthod Dentofacial Orthop.* 2013;144:533–540.
5. Behrents RG. *A treatise on the continuum of growth in the aging craniofacial skeleton*. Ann Arbor: University of Michigan Center for Human Growth and Development; 1984.
6. Khosravi R, Cohanin B, Hujoel P, et al. Management of overbite with the Invisalign appliance. *Am J Orthod Dentofacial Orthop.* 2017;151:691–699.
7. Steinnes J, Johnsen G, Kerosuo H. Stability of orthodontic treatment outcome in relation to retention status. *Am J Orthod Dentofacial Orthop.* 2017;151:1027–1033.
8. Molloy ND, Lindauer SJ, Best AM, et al. Patient attitudes toward retention and perceptions of treatment success. *Angle Orthod.* 2010;80:468–473.
9. Tynelius GE, Bondemark L, Lilja-Karlander E. Evaluation of orthodontic treatment after 1 year of retention—a randomized controlled trial. *Eur J Orthod.* 2010;32:542–547.
10. Mai W, He J, Meng H, Jiang Y, et al. Comparison of vacuum-formed and Hawley retainers: a systematic review. *Am J Orthod Dentofacial Orthop.* 2014;145:720–727.
11. Tynelius EG, Pettrén S, et al. Five-year postretention outcomes of three retention methods—a randomized controlled trial. *Eur J Orthod.* 2015;37:345–353.
12. Zachrisson BU. Long-term experience with bonded retainers: update and clinical advice. *J Clin Orthod.* 2007;41:728–737.
13. Booth FA, Edelman JM, Proffit WR. Twenty-year follow-up of patients with permanently bonded mandibular canine-to-canine retainers. *Am J Orthod Dentofacial Orthop.* 2008;133:70–76.
14. Sim HY, Kim HS, Jung DU, et al. Association between orthodontic treatment and periodontal diseases: results from a national survey. *Angle Orthod.* 2017;87:651–657.
- 14a. Shaughnessy TG, Proffit WR, Samara SA. Inadvertent tooth movement with fixed lingual retainers. *Am J Orthod Dentofac Orthop.* 2016;149:277–286.
15. Al-Nimri K, Al Habashneh R, Obeidat M. Gingival health and relapse tendency: a prospective study of two types of lower fixed retainers. *Aust Orthod J.* 2009;25:142–146.
16. Shah AA, Elcock C, Brook AH. Incisor crown shape and crowding. *Am J Orthod Dentofacial Orthop.* 2003;123:562–567.
17. Zachrisson BU, Nyøygård L, Mobarak K. Dental health assessed more than 10 years after interproximal enamel reduction of mandibular anterior teeth. *Am J Orthod Dentofacial Orthop.* 2007;131:162–169.

## Treatment for Adults

Adult orthodontics has been the fastest growing type of orthodontic treatment in recent years, going from a relative rarity before the 1980s to a commonplace procedure today. In the United States, adults (those older than 18 at the start of treatment) now comprise nearly one-third of all patients receiving comprehensive orthodontic treatment. A similar trend is occurring worldwide in orthodontic practices, trailing behind the U.S. percentage in less-developed countries but increasing steadily everywhere. Adult orthodontics, at this point, is a major component of orthodontic practice.

This does not mean that the treatment procedures can be the same as for adolescents or children. Perhaps the biggest difference is that for adults, other types of dental treatment almost always are required, which makes interdisciplinary interaction and cooperation a necessity from the beginning. The prevalence of periodontal problems increases with age, and even young adults seeking orthodontic treatment are likely to require some level of periodontal care. As adult patients become older, orthodontic treatment must be done in the context of a used dentition with worn teeth and restorative implications, not a new one as with adolescents. The absence of growth in adults (or more accurately, the very small increments of continuing growth) means that growth modification is not a treatment option—everything must be accomplished with tooth movement, restorative dentistry, or orthognathic surgery. In a sense, planning orthodontic treatment for adults can be easier because there are no uncertainties related to the amount and direction of growth, but comprehensive treatment for adults requires a high level of technical skill, knowledge of other disciplines, and an understanding of biomechanics.

Several other considerations are particularly important in the treatment of adults:

1. Treatment planning must involve all the dentists who will play a role in the treatment. It cannot be done by the orthodontist in isolation. With a group of practitioners, an important question is “Who is the conductor of this orchestra?” This, of course, depends on the details of treatment, but when replacement of teeth or extensive restorations are necessary, the planning almost has to start with what the prosthodontist or restorative dentist wants, and the extent to which those desires can be met.
2. Given that many specialties are usually involved in diagnosis, treatment decisions, and treatment delivery, it makes even more sense to start the treatment with the final result in mind. This can be accomplished with a diagnostic set-up or waxup that can be used as a diagnostic and communication tool among the treatment team and between them and the patient, and coordination of this with the facial goals of treatment.
3. Ideal dental occlusion and facial appearance are not necessarily an appropriate treatment goal, even for adults who will have comprehensive treatment involving a complete fixed appliance and specialty care. There is a difference between realistic treatment that is focused on the patient’s problems and ideal treatment aimed at perfection. This must be evaluated for various treatment procedures in the context of cost and risk versus benefit to the patient, so discussion of treatment options and genuinely informed consent are very important.
4. Adults react to being orthodontic patients differently than children and adolescents in two ways: almost always they are intensely interested in their treatment and want to understand what is happening and why, so they require more clinical time in explanations; and either they experience more pain than younger patients or are less tolerant of it, so medication for pain control is more important for them.
5. Disease control is essential before orthodontics can begin. As we have noted earlier in this book, this means bringing both dental and periodontal disease under control, which may add endodontics and oral surgery to the types of treatment. These interactions are reviewed in [Chapter 19](#).



In the chapters that follow, [Chapter 19](#) focuses on orthodontic treatment in interaction with other dental specialists except maxillofacial surgeons, and [Chapter 20](#) adds orthognathic surgery to the considerations in planning and implementing coordinated treatment. Although the focus is on orthodontics in both chapters,

a discussion of treatment procedures by other dental specialists is included in the discussion of interdisciplinary treatment, as it must be. In [Chapter 20](#), the surgical options and the surgeon–orthodontist interaction in the sequencing and management of orthodontic and surgical treatment receive particular attention.

# 19

## Special Considerations in Treatment for Adults

### CHAPTER OUTLINE

#### Adjunctive Versus Comprehensive Treatment

##### Principles of Adjunctive Treatment

- Treatment Goals
- Diagnostic and Treatment Planning Considerations
- Biomechanical Considerations
- Timing and Sequence of Treatment

##### Adjunctive Treatment Procedures

- Uprighting Posterior Teeth
- Crossbite Correction
- Extrusion
- Alignment of Anterior Teeth

##### Comprehensive Treatment in Adults

- Psychologic Considerations
- Temporomandibular Dysfunction as a Reason for Orthodontic Treatment
- Periodontal Considerations
- Prosthodontic–Implant Interactions
- Complex Treatment Procedures

##### Summary

### Adjunctive Versus Comprehensive Treatment

In general, orthodontists consider adults as those whose growth is essentially completed. The mean cutoff age for females is 18 (which means for some slow maturers it would be later), but for males it is 20 or 21, simply because males often are still growing up to that age. Patients who seek orthodontic treatment beyond those ages fall into two quite different groups: (1) younger adults (typically younger than 35, often in their 20s) who desired but did not receive comprehensive orthodontic treatment as youths and now seek it as they become financially independent and (2) an older group, typically in their 40s or 50s, who have other dental problems and need orthodontics as part of a larger treatment plan.

For the first group, the goal is to improve their quality of life. They usually seek the maximum improvement that is possible. They may or may not need extensive treatment by other dental specialists but frequently need interdisciplinary consultation. The second group's goal is quite different. They usually seek to maintain

what they have, not necessarily to achieve as ideal an orthodontic result as possible. For them, orthodontic treatment is needed to meet specific goals that would make control of dental disease and restoration of missing teeth easier and more effective, so the orthodontics is an adjunctive procedure to the larger periodontal and restorative goals.

Adjunctive orthodontic treatment, particularly the simpler procedures, often can be carried out within the context of general dental practice. In adults, growth has been essentially completed and is no longer a variable requiring major consideration in managing treatment, and the types and magnitude of tooth movement required for most adjunctive procedures are straightforward. Adjunctive treatment does not require familiarity with the principles of comprehensive orthodontic treatment, but it does presume an understanding of orthodontic diagnosis and treatment planning.

In contrast, the discussion of comprehensive treatment for adults in the latter part of this chapter builds on the principles discussed in [Chapters 15 to 17](#) and focuses on the aspects of comprehensive treatment for adults that are different from treatment for adolescents. Comprehensive orthodontics for adults tends to be difficult and technically demanding. The absence of growth means that growth modification to treat jaw discrepancies is not possible. The only possibilities are tooth movement for camouflage or orthognathic surgery, but applications of skeletal anchorage now are broadening the scope of orthodontics to include some patients who would have required surgery even a few years ago. Applications of skeletal anchorage are discussed and illustrated in detail in this chapter; a discussion of skeletal anchorage versus surgery follows in [Chapter 20](#).

Adjunctive orthodontic treatment for adults is, by definition, tooth movement carried out to facilitate other dental procedures necessary to control disease, restore function, and/or enhance appearance. Usually it involves only a part of the dentition, and the primary goal usually is to make it easier or more effective to replace missing or damaged teeth. Making it easier for the patient to control periodontal problems is a frequent secondary goal and sometimes the primary goal. The treatment duration tends to be a few months, rarely more than a year, and long-term retention often is supplied by the restorations. Whether one or several practitioners are involved, adjunctive orthodontics must be coordinated carefully with the periodontal and restorative treatment.

In contrast, the goal of comprehensive orthodontics for adults is the same as for adolescents: to produce the best combination of dental and facial appearance, dental occlusion, and stability of the result to maximize benefit to the patient. Comprehensive orthodontics requires either a complete fixed orthodontic appliance or a high level of skill in managing clear aligner therapy. Intrusion

of some teeth is likely to be needed, orthognathic surgery may be considered to improve jaw relationships, and the duration of treatment from braces on to braces off exceeds 1 year. Adults receiving comprehensive treatment are the main candidates for esthetically enhanced appliances; the prime examples are ceramic facial brackets, clear aligners, and lingual appliances. The complexity of the treatment procedures means that an orthodontic specialist is likely to be significantly more efficient in delivering the care.

## Principles of Adjunctive Treatment

### Treatment Goals

Whatever the occlusal status originally, the goals of adjunctive treatment should be to:

- Improve periodontal health by eliminating plaque-harboring areas and improving the alveolar ridge contour adjacent to the teeth
- Establish favorable crown-to-root ratios and position the teeth so that occlusal forces are transmitted along the long axes of the teeth
- Facilitate restorative treatment by positioning the teeth so that:
  - More ideal and conservative techniques (including implants) can be used.
  - Optimal esthetics can be obtained with bonding, laminates, or full-coverage porcelain restorations.

Typically, adjunctive orthodontic treatment will involve any or all of several procedures:

1. Repositioning teeth after extractions or bone loss so that implants can be placed or more ideal fixed or removable partial dentures can be fabricated
2. Aligning anterior teeth to allow more esthetic restorations or successful splinting while maintaining good interproximal bone contour and embrasure form
3. Correcting crossbite if this compromises jaw function (not all crossbites do)
4. Forcing eruption of badly broken-down teeth either to:
  - Expose sound root structure on which to place crowns, or
  - Level bone margins and regenerate alveolar bone

An old rule says that to make clear what something is, it helps to point out what it isn't but might be mistaken for. So, some important corollaries:

- Orthodontic treatment for temporomandibular dysfunction (TMD) should not be considered adjunctive treatment.
- Although intrusion of teeth can be an important part of comprehensive treatment for adults, it probably should be managed by an orthodontist even as an adjunctive procedure because of the technical difficulties involved and the possibility of periodontal complications. As a general guideline in treatment of adults with periodontal involvement and bone loss, lower incisor teeth that are excessively extruded are best treated by reduction of crown height, which has the added advantage of improving the ultimate crown-to-root ratio of the teeth. For other teeth, tooth–lip relationships must be kept in mind when crown height reduction is considered.
- Crowding of more than 3 to 4 mm should not be attempted by stripping enamel from the contact surfaces of the anterior teeth. It may be advantageous to strip posterior teeth to provide space for alignment of the incisors, but this requires a complete orthodontic appliance and cannot be considered adjunctive treatment.

## Diagnostic and Treatment Planning Considerations

Planning for adjunctive treatment requires two steps: (1) collecting an adequate diagnostic database and (2) developing a comprehensive but clearly stated list of the patient's problems, taking care not to focus unduly on any one aspect of a complex situation. The importance of this planning stage in adjunctive orthodontic treatment cannot be overemphasized, because the solution to the patient's specific problems may involve the synthesis of many branches of dentistry. In adjunctive treatment, the restorative dentist usually is the principal architect of the treatment plan, and the use of orthodontics (whether an orthodontist is or is not part of the treatment team) is to facilitate better restorative treatment.

Nevertheless, the steps outlined in [Chapter 6](#) should be followed when the problem list is being developed. The interview and clinical examination are the same whatever the type of orthodontic treatment. Diagnostic records for adjunctive orthodontic patients, however, differ in several important ways from those for adolescents and children.

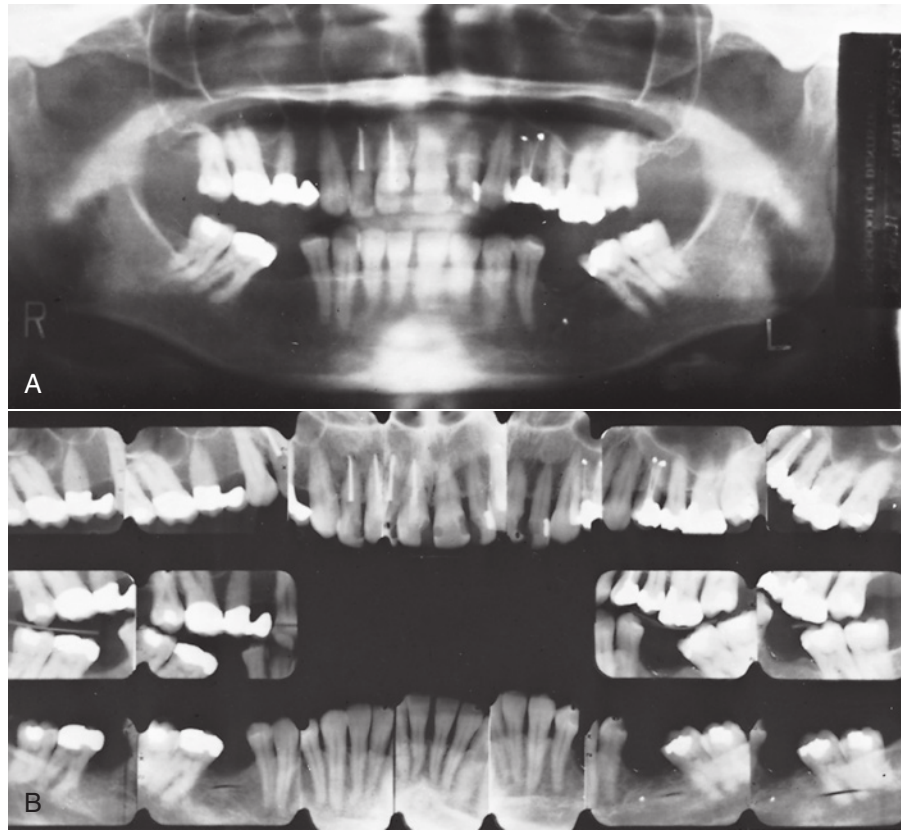
For this adult and dentally compromised population, the records usually should include individual intraoral radiographs to supplement the panoramic radiograph that often suffices for younger and healthier patients ([Fig. 19.1](#)). When active dental disease is present, the panoramic radiograph does not give sufficient detail. The revised guidelines from the U.S. Food and Drug Administration in 2014 (see [Table 6.8](#)) should be followed in determining exactly what radiographs are required in evaluating the patient's oral health status. The American Board of Orthodontics now requires evidence of pretreatment periodontal condition for all adult patients.<sup>1</sup>

For adjunctive orthodontics with a partial fixed appliance, pretreatment cephalometric radiographs usually are not required, but it is important to anticipate the impact of various tooth movements on facial esthetics. In some instances, the computer prediction methods used in comprehensive treatment (see [Chapter 7](#)) can be quite useful in planning adjunctive treatment. Articulator-mounted casts are likely to be needed because they facilitate the planning of associated restorative procedures.

Once all the problems have been identified and categorized, the key treatment planning question is: can the occlusion be restored within the existing tooth positions or must some teeth be moved to achieve a satisfactory, stable, healthy, and esthetic result? The goal of providing a physiologic occlusion and facilitating other dental treatment has little to do with Angle's concept of an ideal occlusion. At this point, it is important to consider the difference between realistic and idealistic treatment planning. In older patients, searching for an "ideal" result could involve more treatment than would really benefit the patient.

Obviously, the time needed for any orthodontic treatment depends on the severity of the problem and the amount of tooth movement desired, but with efficient use of orthodontic appliances, it should be possible to reach the objectives of adjunctive treatment within 6 months. As a practical matter, this means that like comprehensive orthodontics, most adjunctive orthodontics cannot be managed well with traditional removable appliances. It requires either fixed appliances or a sequence of clear aligners to get the job done in a reasonable time frame. In addition, it is becoming increasingly apparent that skeletal anchorage makes adjunctive tooth movement more effective and efficient. For adjunctive treatment, this is almost always in the form of alveolar bone screws.





• **Fig. 19.1** (A and B) For the periodontically compromised adults who are the usual candidates for adjunctive orthodontics, periapical radiographs of the areas that will be treated, as well as a panoramic radiograph, usually are needed. Periodontal disease now is the major indication for periapical radiographs. For this patient who is a candidate for adjunctive orthodontic treatment, adequate detail of root morphology, dental disease, and periodontal breakdown is obtained only from carefully taken periapical radiographs.

## Biomechanical Considerations

### Characteristics of the Orthodontic Appliance

When a partial fixed appliance is to be used for adjunctive treatment, with the possible exception of alignment of anterior teeth, the 22-slot edgewise appliance with twin brackets is preferred. The rectangular bracket slot permits control of buccolingual axial inclinations, the relatively wide bracket helps control undesirable rotations and tipping, and the larger slot size allows the use of stabilizing wires that are somewhat stiffer than ordinarily might be used in comprehensive treatment.

Recently, further developments in clear aligner therapy (see [Chapter 10](#)) have resulted in an effective removable appliance that can be well suited to alignment of anterior teeth. Removable appliances of the traditional plastic-and-wire type are rarely satisfactory for adjunctive (or comprehensive) treatment. They often are uncomfortable and are likely to be worn for too few hours per day to be effective. With clear aligners, both discomfort and interference with speech and mastication are minimized, and patient cooperation improves. The better appearance of a clear aligner also is a factor in choosing it to align anterior teeth.

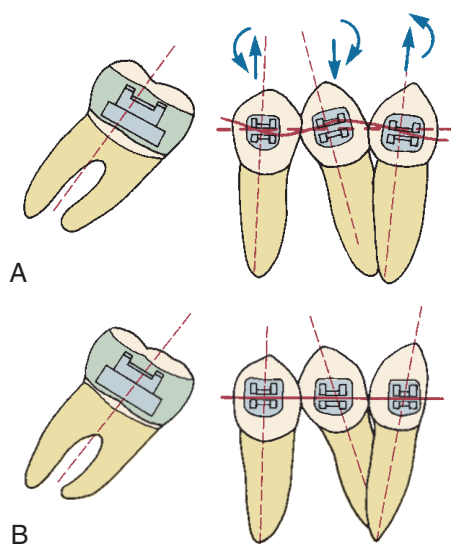
Despite this esthetic advantage, there are biomechanical limitations. Control of root position is difficult with clear aligners, and bonded attachments to teeth and modifications of the aligners are needed to produce several important types of tooth movement

(see [Box 10.1](#)). If these limitations are not important, clear aligners can be considered for adjunctive orthodontics. If they are, most adults who are candidates for adjunctive treatment will accept a visible fixed appliance.

Modern edgewise brackets of the straight-wire type are designed for a specific location on an individual tooth. Placing the bracket in its ideal position on each tooth implies that every tooth will be repositioned if necessary to achieve ideal occlusion ([Fig. 19.2A](#)). Because adjunctive treatment is concerned with only limited tooth movements, usually it is neither necessary nor desirable to alter the position of every tooth in the arch. For this reason, in a partial fixed appliance for adjunctive treatment, the brackets are placed in an ideal position only on teeth to be moved, and the remaining teeth to be incorporated in the anchor system are bracketed so that the archwire slots are closely aligned ([Fig. 19.2B](#)). This allows the anchorage segments of the wire to be engaged passively in the brackets with little bending. Passive engagement of wires produces minimal disturbance of teeth that are in a physiologically satisfactory position. This important point is illustrated in more detail in the sections on specific treatment procedures that follow.

### Effects of Reduced Periodontal Support

Because patients who need adjunctive orthodontic treatment often have lost alveolar bone to periodontal disease before it was brought under control, the amount of bone support of each tooth is an



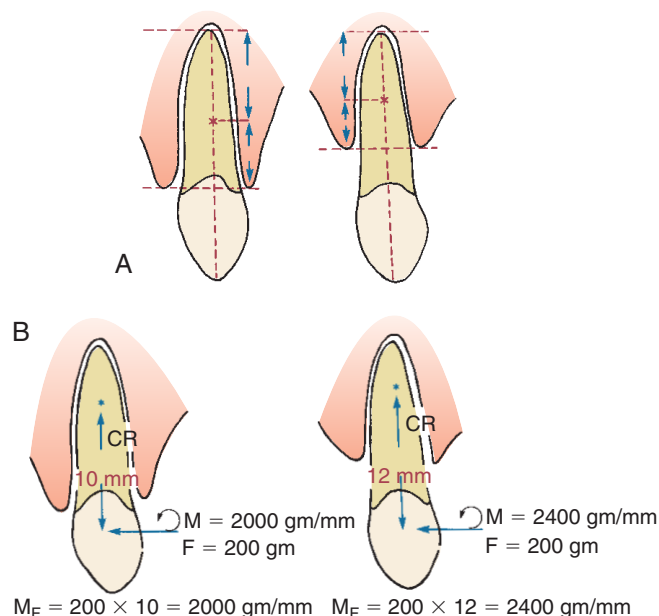
• **Fig. 19.2** (A) Brackets placed in the “ideal” position on moderately irregular anchor teeth for molar uprighting. For adjunctive orthodontic treatment, movement of the anchor teeth usually is undesirable, but a straight length of wire will move them if the brackets are positioned in this way. (B) Brackets placed in the position of maximum convenience, lined up so that a straight length of wire can be placed without moving the anchor teeth. This makes things easier if no movement of the anchor teeth is desired. For adjunctive orthodontic procedures such as molar uprighting, we recommend the use of fully adjusted “straight-wire” 22-slot brackets and working archwires that are somewhat smaller than the bracket slot to reduce unwanted faciolingual movement of anchor teeth even though the brackets are lined up in the other planes of space.

important consideration. When bone is lost, the periodontal ligament (PDL) area decreases, and the same force against the crown produces greater pressure in the PDL of a periodontally compromised tooth than a normally supported one. The absolute magnitude of force used to move teeth must be reduced when periodontal support has been lost. In addition, the greater the loss of attachment, the smaller the area of supported root and the further apical the center of resistance will become (Fig. 19.3). This affects the moments created by forces applied to the crown and the moments needed to control root movement. In general terms, tooth movement is quite possible despite bone loss, but lighter forces and relatively larger moments are needed.

### Timing and Sequence of Treatment

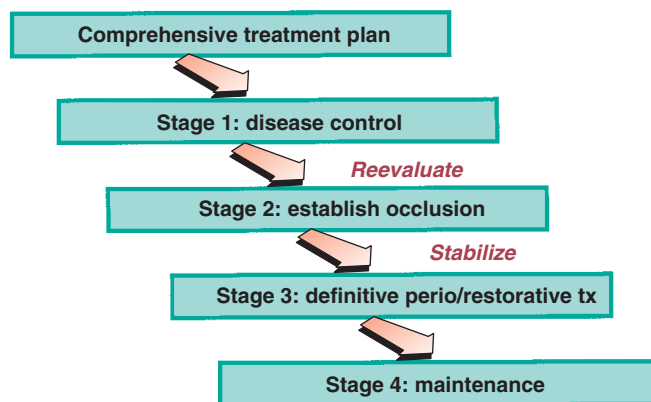
In the development of any orthodontic treatment plan, the first step is control of any active dental disease (Fig. 19.4). Before any tooth movement, active caries and pulpal pathology must be eliminated by using extractions, restorative procedures, and pulpal or apical treatment as necessary. Endodontically treated teeth respond normally to orthodontic force, if all residual chronic inflammation has been eliminated.<sup>2</sup> Before orthodontics, teeth should be restored with well-placed amalgams or composite resins. Restorations requiring detailed occlusal anatomy should not be placed until any adjunctive orthodontic treatment has been completed because the occlusion inevitably will be changed. This could necessitate remaking crowns, bridges, or removable partial dentures.

Periodontal disease also must be controlled before any orthodontics begins because orthodontic tooth movement superimposed



• **Fig. 19.3** (A) The center of resistance of a single-rooted tooth lies approximately  $\frac{1}{10}$  of the distance between the apex of the tooth and the crest of the alveolar bone. Loss of alveolar bone height, as for the tooth on the right, moves the center of resistance closer to the root apex. (B) The magnitude of the tipping moment produced by a force is equal to the force times the distance from the point of force application to the center of resistance. If the center of resistance moves apically, the tipping moment produced by the force ( $M_F$ ) increases, and a larger countervailing moment produced by a couple applied to the tooth ( $M_C$ ) would be necessary to produce bodily movement. This is almost impossible to obtain with traditional removable appliances and very difficult with clear aligners, even when bonded attachments are added. For all practical purposes, a fixed appliance is required if root movement is the goal in patients who have experienced loss of alveolar bone height. CR, Center of resistance;  $F$ , force;  $M$ , moment of force.

### Treatment Sequence: Complex Problems



• **Fig. 19.4** The sequence of steps in the treatment of patients requiring adjunctive orthodontics. Orthodontics is used to establish occlusion but only after disease control has been accomplished, and the occlusion should be stabilized before definitive restorative treatment is carried out.

on poorly controlled periodontal health can lead to rapid and irreversible breakdown of the periodontal support apparatus.<sup>3</sup> Scaling, curettage (by open flap procedures, if necessary), and gingival grafts should be undertaken as appropriate. Surgical pocket elimination and osseous surgical procedures should be delayed until completion of the orthodontic phase of treatment because significant soft tissue and bony recontouring occurs during orthodontic tooth movement. Clinical studies have shown that orthodontic treatment of adults with both normal and compromised periodontal tissues can be completed without loss of attachment, if there is good periodontal therapy both initially and during tooth movement.<sup>4</sup>

During this preparatory phase, the patient's enthusiasm for treatment and ability to maintain good overall oral hygiene should be carefully monitored. Adjunctive orthodontics has the potential to do more harm than good in patients who cannot or will not maintain good oral hygiene. If disease can be controlled, however, adjunctive orthodontics can significantly improve the final restorative and periodontal procedures.

## Adjunctive Treatment Procedures

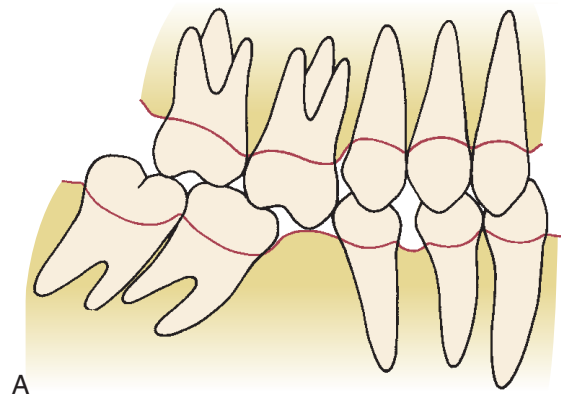
### Uprighting Posterior Teeth

#### Treatment Planning Considerations

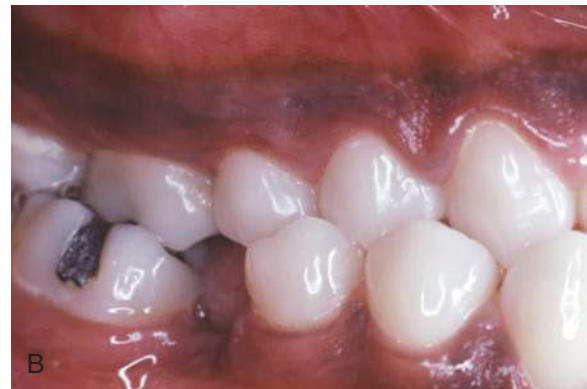When a first permanent molar is lost during childhood or adolescence and not replaced, the second molar drifts mesially and the premolars often tip distally and rotate as space opens between them. As the teeth move, the adjacent gingival tissue becomes folded and distorted, forming a plaque-harboring pseudopocket that may be virtually impossible for the patient to clean (Fig. 19.5). Repositioning the teeth eliminates this potentially pathologic condition and has the added advantage of simplifying the ultimate restorative procedures.

When molar uprighting is planned, several interrelated questions must be answered:

- If the third molar is present, should both the second and third molars be uprighted? For many patients, distal positioning of the third molar would move it into a position in which good hygiene could not be maintained or it would not be in functional occlusion. In these circumstances, it is more appropriate to extract the third molar and simply upright the remaining second molar tooth. If both molars are to be uprighted, the biomechanical requirements change, and the technique must be modified as described later.
- How should the tipped teeth be uprighted? By distal crown movement (tipping), which would increase the space available for an implant or bridge pontic, or by mesial root movement, which would reduce or even close the edentulous space? For most patients, treatment by distal tipping of the second molar and a bridge or implant to replace the first molar is preferred (Fig. 19.6). If extensive ridge resorption has already occurred, particularly in the buccolingual dimension, closing the space by mesial movement of a wide molar root into the narrow alveolar ridge will proceed very slowly. If uprighting with space closure is to be done successfully, skeletal anchorage in the form of a temporary skeletal anchorage often is needed, and the treatment time can be as much as 3 years.
- Is extrusion of a tipped molar permissible? Uprighting a mesially tipped tooth by tipping it distally, which leaves the root apex in its pretreatment position, also extrudes it. This has the merit of reducing the depth of the pseudopocket found on the mesial

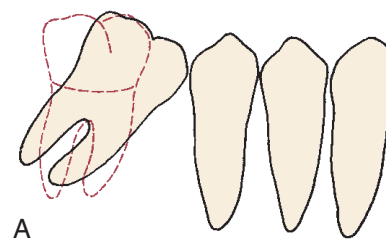


A

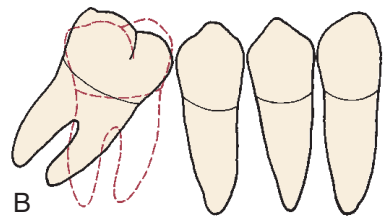


B

• **Fig. 19.5** (A) Loss of a lower molar can lead to tipping and drifting of adjacent teeth, poor interproximal contacts, poor gingival contour, reduced interradicular bone, and supra-eruption of unopposed teeth. Because the bone contour follows the cementoenamel junction, pseudo-pockets form adjacent to the tipped teeth. (B) Note the loss of alveolar bone in the area where a mandibular first molar was extracted many years previously. Mesial drift and tipping of the second molar has closed half the space. The patient's posterior crossbite, however, is unrelated to early loss of the molar.



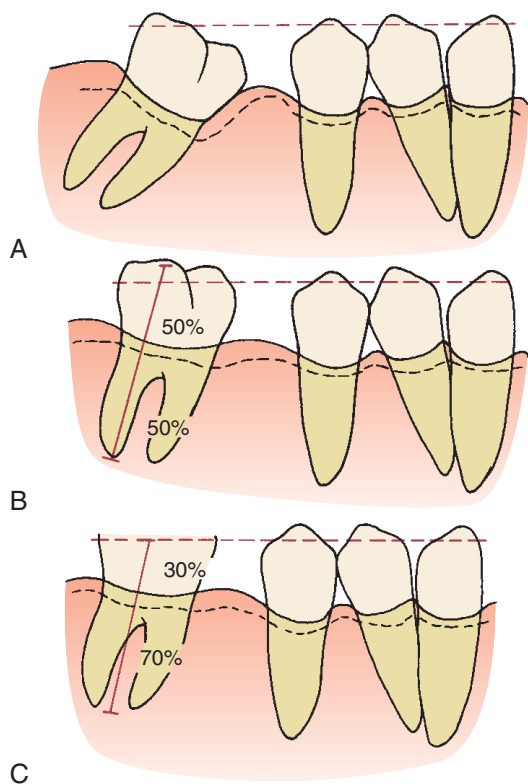
A



B

• **Fig. 19.6** (A) Uprighting a tipped molar by distal crown movement leads to increased space for a bridge pontic or implant, whereas uprighting the molar by mesial root movement (B) reduces space and might eliminate the need for a prosthesis, but this tooth movement can be very difficult and time-consuming to accomplish, especially if the alveolar bone has resorbed in the area where a first molar was extracted many years previously (see Fig. 19.36).





• **Fig. 19.7** (A to C) Uprighting a tipped molar increases the crown height while it reduces the depth of the mesial pocket. Subsequent crown reduction decreases occlusal interference and also improves the ratio of crown height to supported root length of the molar, so reducing the height of the molar crown is a routine part of molar uprighting.

surface, and because the attached gingiva follows the cemen-toenamel junction while the mucogingival junction remains stable, it also increases the width of the keratinized tissue in that area. In addition, if the height of the clinical crown is systematically reduced as uprighting proceeds, the ultimate crown–root length ratio will be improved (Fig. 19.7). Unless slight extrusion or crown–height reduction is acceptable, which usually is the case, the patient should be considered to have problems that require comprehensive treatment and treated accordingly.

- Should the premolars be repositioned as part of the treatment? This will depend on the position of these teeth and the restorative plan, but in many cases the answer is *yes*. It is particularly desirable to close spaces between premolars when uprighting molars because this will improve both the periodontal prognosis and long-term stability. In some instances, uprighting the molar and then moving the premolar back against it will provide a better site mesial to the premolar for an implant.

In molar uprighting, the treatment time will vary with the type and extent of the tooth movement. Uprighting one second molar by distal crown tipping proceeds much more rapidly than mesial root movement. Failure to eliminate occlusal interferences will prolong treatment. The simplest cases should be completed in 8 to 10 weeks, but uprighting two molars in the same quadrant could easily take 6 months, and the complexity of doing this puts it at the outer limit of adjunctive treatment with a partial fixed appliance.

### Appliances for Molar Uprighting

**Distal Crown Tipping.** A partial fixed appliance to upright tipped molars consists of bonded brackets on the premolars and canine in that quadrant and either a bonded rectangular tube on the molar or a molar band. A general guideline is that molar bands are best when the periodontal condition allows, which means for all practical purposes they would be used in younger and healthier patients. The greater the degree of periodontal breakdown around the molar to be uprighted, the more a bonded attachment should be considered.

Where the premolar and canine brackets should be placed depends on the intended tooth movement and occlusion. If these teeth are to be repositioned, the brackets should be placed in the ideal position at the center of the facial surface of each tooth. However, if the teeth are merely serving as anchor units and no repositioning is planned, then the brackets should be placed in the position of maximum convenience where minimum wire bending will be required to engage a passive archwire (see Fig. 19.2).

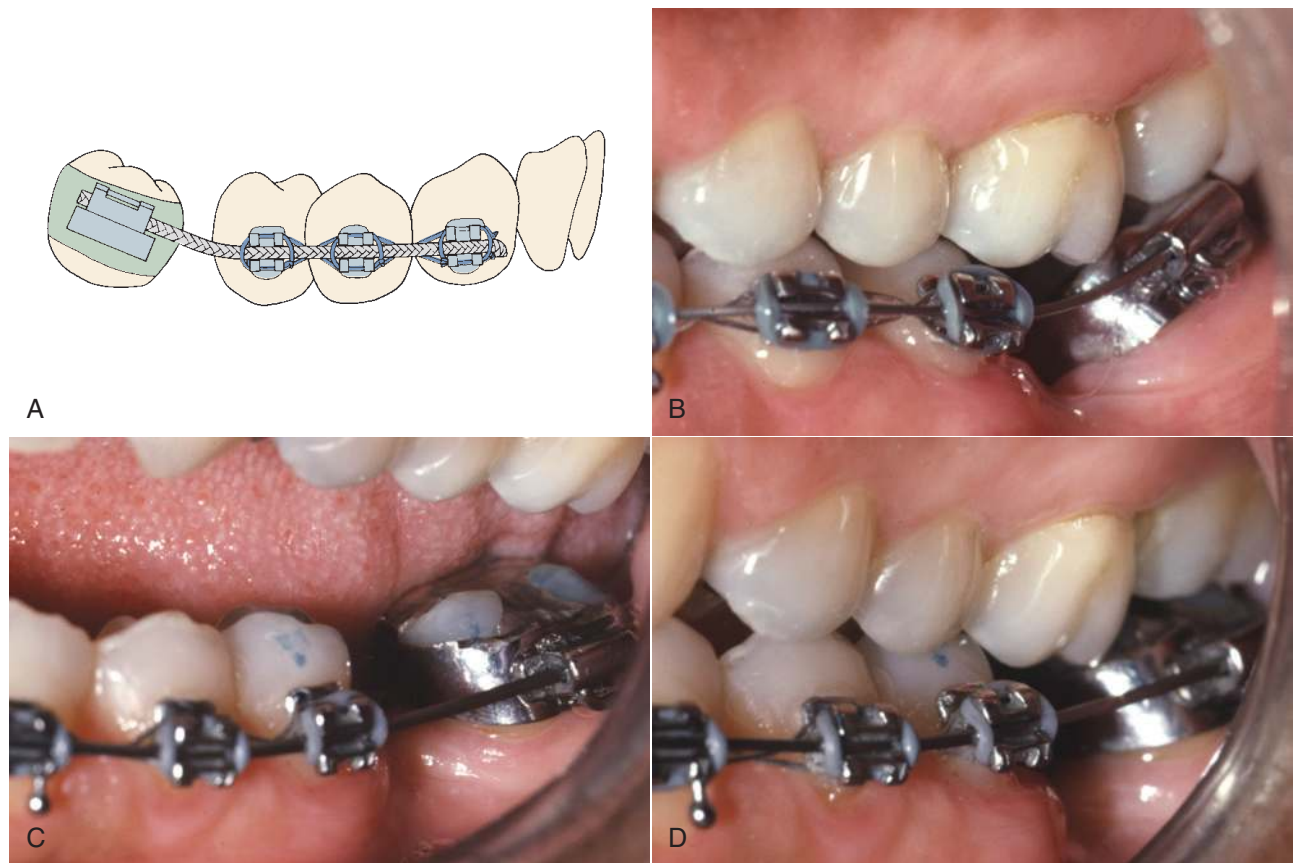If the molar is only moderately tipped, treatment often can be accomplished with a flexible rectangular wire. The best choice is  $17 \times 25$  austenitic nickel–titanium (A-NiTi) that delivers approximately 100 gm of force. With this material, a single wire may complete the necessary uprighting (Fig. 19.8). A braided rectangular steel wire also can be used but is more likely to require removal and reshaping. It is important to relieve the occlusion as the tooth tips upright. Failure to do this may cause excessive tooth mobility and increase treatment time.

If the molar is severely tipped, a continuous wire that uprights the molar will have side effects (which almost always are undesirable) on the position and inclination of the second premolar. For that reason it is better to carry out the bulk of the uprighting by using an auxiliary uprighting spring (Fig. 19.9). After preliminary alignment of the anchor teeth if necessary, stiff rectangular wire ( $19 \times 25$  steel) maintains the relationship of the teeth in the anchor segment, and the auxiliary spring is placed in the molar auxiliary tube. It is formed from either  $17 \times 25$  beta-titanium (beta-Ti) wire without a helical loop or  $17 \times 25$  steel wire with a loop added to provide more springiness. The mesial arm of the helical spring should be adjusted to lie passively in the vestibule and on activation should hook over the archwire in the stabilizing segment. It is important to position the hook so that it is free to slide distally as the molar uprights. In addition, a slight lingual bend placed in the uprighting spring is needed to counteract the forces that tend to tip the anchor teeth buccally and the molar lingually (Fig. 19.9C).

Can distal tipping of a single molar on both sides be done at the same time? Yes, but then a bonded lingual stabilizing wire canine-to-canine should be placed to control the incisor position (Fig. 19.9D).

**Mesial Root Movement.** If mesial root movement is desired, an alternative treatment approach is indicated. Skeletal anchorage is required if the goal is to close the old extraction space (see Fig. 19.36). If a small amount of mesial movement to prevent opening too much space is the goal, a single T-loop sectional archwire of  $17 \times 25$  stainless steel or  $19 \times 25$  beta-Ti wire can be effective (Fig. 19.10).

After initial alignment of the anchor teeth with a light flexible wire, the T-loop wire is adapted to fit passively into the brackets on the anchor teeth and gabled at the T to exert an uprighting force on the molar. Insertion into the molar can be from the mesial or distal side. If the treatment plan calls for maintaining or closing



• **Fig. 19.8** Fixed appliance technique for uprighting one molar with a continuous flexible wire. (A) Initial bracket alignment is achieved by placing a light flexible wire such as 17 × 25 austenitic nickel–titanium (A–NiTi) from molar to canine. (B) Molar uprighting with a continuous martensitic nickel–titanium (M–NiTi) wire. (C) Progress 1 month later. (D) Uprighting essentially completed 2 months later.

rather than increasing the pontic space, the distal end of the archwire should be pulled distally through the molar tube, opening the T-loop by 1 to 2 mm, and then bent sharply gingivally to maintain this opening. This activation provides a mesial force on the molar that counteracts distal crown tipping while the tooth uprights (Fig. 19.10D). If opening the space is desired, the end of the wire is not bent over so the tooth can slide distally along it.

The T-loop appliance also is indicated if the molar to be uprighted is severely tipped but has no occlusal antagonist. In that circumstance, a T-loop minimizes the extrusion that accompanies uprighting, which can be excessive with the other methods when there is no antagonist.

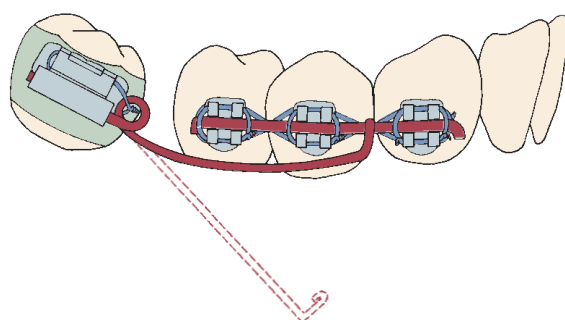
**Final Positioning of Molar and Premolars.** Once molar uprighting is almost complete, often it is desirable to increase the available pontic space and close open contacts in the anterior segment. This is done best by using a relatively stiff base wire, with a compressed coil spring threaded over the wire to produce the required force system. With 22-slot brackets, the base wire should be 18-mil round or 17 × 25 steel. It should engage the anchor teeth and the uprighted molar more or less passively and extend through the molar tube, projecting about 1 mm beyond the distal end. An open coil steel spring (0.009 inch wire, 0.030 inch lumen) is cut so that it is 1 to 2 mm longer than the space, slipped over the base wire (Fig. 19.11), and compressed between the molar and distal premolar. This provides a force of approximately 150 gm to move the premolars mesially while

continuing to tip the molar distally. The coil spring can be reactivated without removing it by compressing the spring and adding a split stop to maintain the compression (Fig. 19.11B).

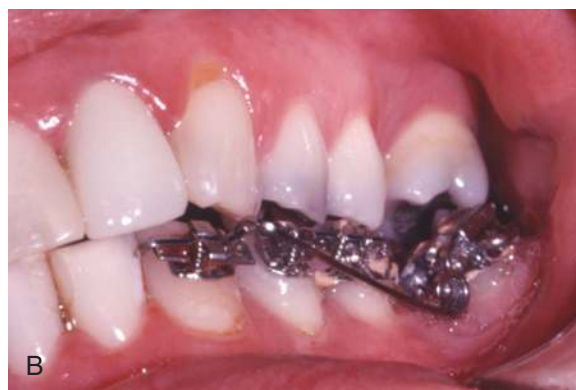### Uprighting Two Molars in the Same Quadrant

Because the resistance offered when uprighting two molars is considerable, only small amounts of tooth movement should be attempted unless comprehensive orthodontic treatment with a complete fixed appliance is planned. The goal should be a modest amount of distal crown tipping of both teeth, which typically would leave space for a premolar-sized implant or pontic. In the lower arch, a bonded canine-to-canine lingual stabilizing wire (which is similar to a bonded retainer) is needed to control the position of the anterior teeth (see Fig. 19.9D). Trying to upright both the second and third molars bilaterally at the same time is not a good idea; significant movement of the anchor teeth is inevitable unless skeletal anchorage is used.

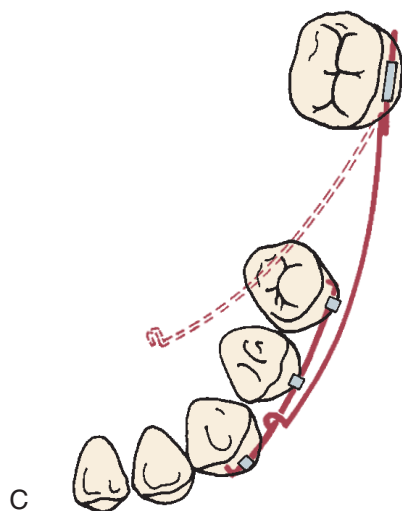
When both the second and the third molars are to be uprighted, the third molar should carry a single rectangular tube and the second molar a bracket. Because the second molar is usually more severely tipped than the third molar, increased flexibility of the wire mesial and distal to the second molar is required. The best approach is to use a highly flexible wire initially—17 × 25 A–NiTi usually is a good choice—and then proceed to a TMA wire of the same size. Excessive mobility of the teeth can result from failure to reduce occlusal interferences.



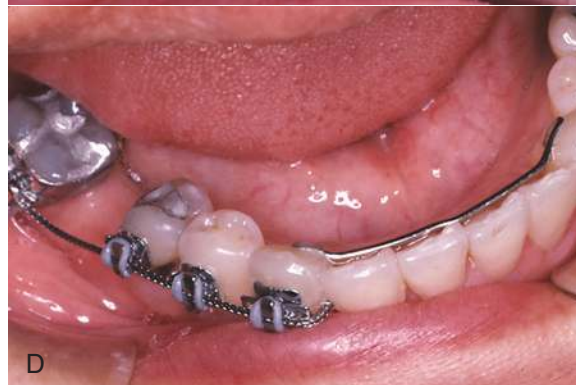A



B



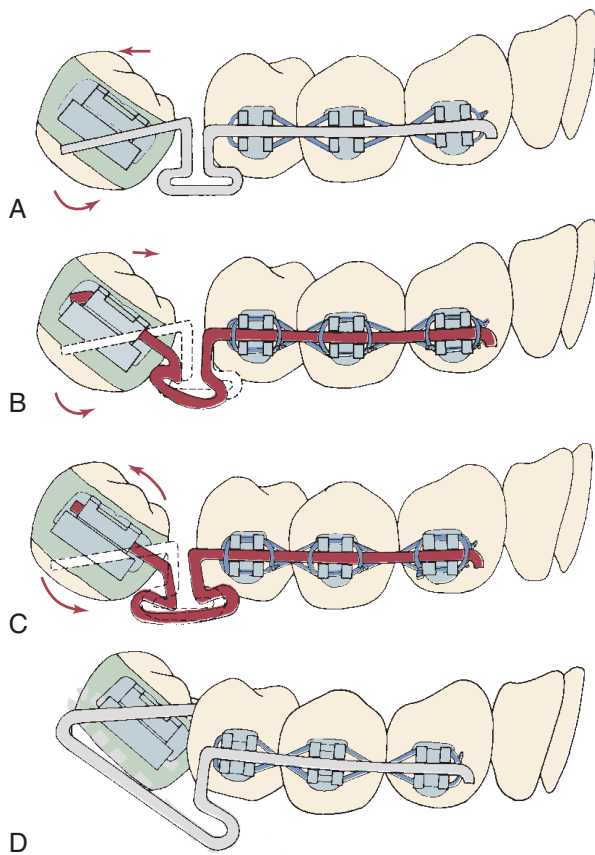
C



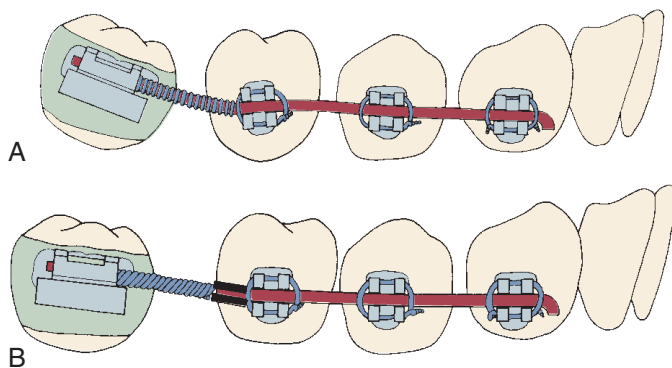
D

• **Fig. 19.9** Uprighting with an auxiliary spring. (A) If the relative alignment of the molar precludes extending the stabilizing segment into the molar bracket, then a rigid stabilizing wire, 19 × 25 stainless steel, is placed in the premolars and canine only (often with the brackets positioned so this wire is passive—see Fig. 19.2). The mesial arm of the uprighting spring lies in the vestibule before engagement, and the spring is activated by lifting the mesial arm and hooking it over a stabilizing wire in the canine and premolar brackets. (B) Auxiliary uprighting spring to molar just after initial placement. Note the helix bent into the steel wire that forms the spring to provide better spring qualities. (C) Because the force is applied to the facial surface of the teeth, an auxiliary uprighting spring tends not only to extrude the molar but also to roll it lingually, while intruding the premolars and flaring them buccally. To counteract this side effect, the uprighting spring should be curved buccolingually so that when it is placed into the molar tube, the hook would lie lingually to the archwire before activation (*dashed line*). (D) Better control of anchorage, with either a continuous wire or an auxiliary spring, is obtained when a canine-to-canine stabilizing wire is bonded on the lingual surface of these teeth.

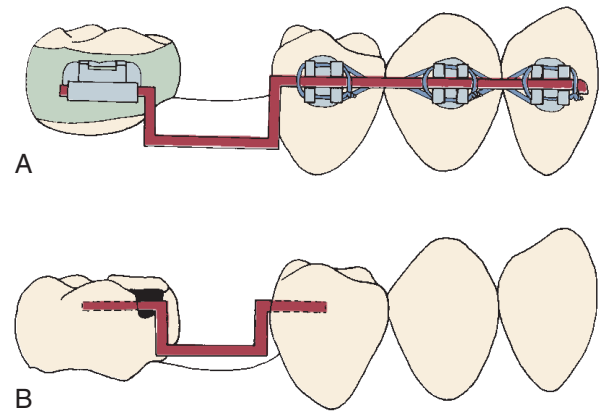




• **Fig. 19.10** (A) T-loop spring in  $17 \times 25$  steel wire, showing the degree of angulation of the wire before it is inserted into the molar tube that is necessary to upright a single-tipped molar. (B) If a T-loop is activated by pulling the distal end of the wire through the molar tube and bending it, the tooth cannot move distally. This generates a moment that results in molar uprighting by mesial root movement with space closure. (C) A T-loop for uprighting by distal tipping. Note that the tooth can move back by sliding along the wire. (D) Modification of a T-loop that can be used to upright a severely tipped or rotated molar by distal tipping. The wire is inserted into the distal end of the tube on the molar. The additional wire in the loop provides a longer range of action, but the uprighting still is by distal crown tipping.



• **Fig. 19.11** (A) A compressed coil spring on a round wire (usually 18-mil steel) may be used to complete molar uprighting while closing remaining spaces in the premolar region. (B) The coil spring can be reactivated by compressing it against a split spacer crimped over the archwire just behind the premolar bracket.



• **Fig. 19.12** A molar that has been uprighted is unstable and must be maintained in its new position until a fixed bridge or implant is placed to stabilize it. There are two ways to provide temporary stabilization: (A) a heavy rectangular ( $19 \times 25$ ) steel wire engaging the brackets passively and (B) an intracoronal splint (often called an *A-splint*) made with  $19 \times 25$  or  $21 \times 25$  steel wire that is bonded in shallow preparations in the proximal enamel with composite resin. This causes minimal tissue disturbance. The intracoronal splint is preferred, particularly if retention is to be continued for more than a few weeks.

### Retention

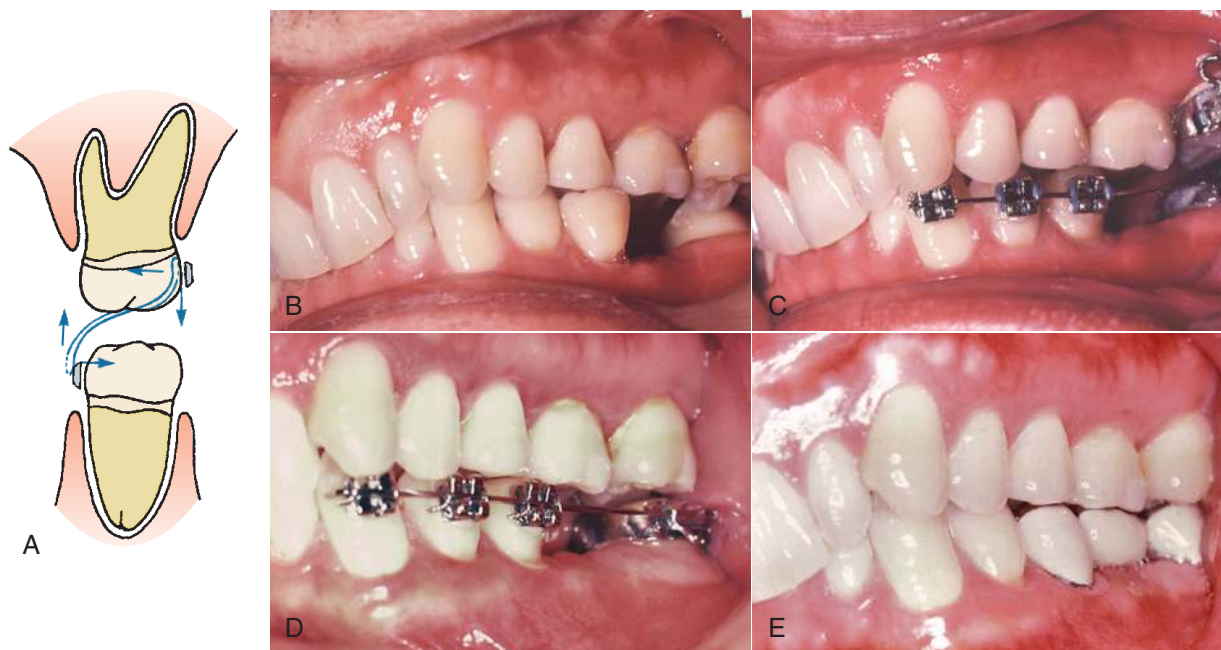
After molar uprighting, the teeth are in an unstable position until the implant or prosthesis that will provide long-term retention is placed, and a retainer is needed. If an auxiliary uprighting spring was used, a wire shaped as shown in [Fig. 19.12A](#) works well. Especially if an implant is planned, there may be a considerable delay while a bone graft heals and the implant becomes integrated. If retention is needed for more than a few weeks, the preferred approach is to remove the orthodontic appliance and place an intracoronal wire splint ( $19 \times 25$  or heavier steel wire) bonded into shallow preparations in the abutment teeth ([Fig. 19.12B](#)). This type of splint causes little gingival irritation and can be left in place for a considerable period, but it would have to be removed and rebonded to allow bone grafting and implant surgery.

### Crossbite Correction

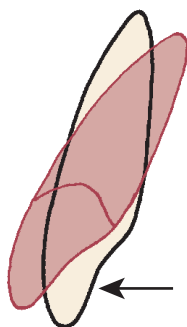
Posterior crossbites frequently are corrected using “through the bite” elastics from a conveniently placed tooth in the opposing arch, which moves both the upper and lower tooth ([Fig. 19.13A](#)). This tips the teeth into the correct occlusion but also tends to extrude them, which can change occlusal relationships throughout the mouth. These elastics should be used only for a short time.

Often it is desirable to move the maxillary teeth more than the mandibular. One way to do that is to have several teeth in the lower arch stabilized by a heavy archwire segment ([Fig. 19.13B–D](#)). Of course, the same approach could be used in reverse to produce more movement of a mandibular tooth. Sometime that is the case when a mesially tipped lower molar also is in buccal crossbite. An auxiliary uprighting spring can move it lingually as it uprights by two modifications in design: omitting the inward bending of the spring before it is activated (see [Fig. 19.9C](#)) and making the spring from round wire.

If an anterior crossbite is due only to a displaced tooth and correcting it requires only tipping (as in the case of a maxillary incisor that was tipped lingually into crossbite), then a removable



• **Fig. 19.13** (A) “Through the bite” or cross-elastics produce both horizontal and vertical forces and will extrude the teeth while moving them buccolingually. If these elastics are used to correct posterior crossbite in adults, care must be taken not to open the bite anteriorly too much. Cross-elastics are rarely indicated for an anterior crossbite. (B) Buccal crossbite of the second molars in a patient at age 50 who had lost the mandibular first molar years previously. The lower second molar had tipped mesially and lingually. (C) The standard orthodontic appliance for uprighting a lower molar was used, consisting of a band on the mandibular second molar, a bonded canine-to-canine mandibular lingual wire to augment anchorage, and bonded brackets on the facial aspect of the premolars and canine. In addition, a lingual cleat was placed on the lower band, and a band with a facial hook was placed on the maxillary second molar so that cross-elastics could be worn. (D) The molar uprighting was completed after the crossbite was corrected. (E) The completed bridge in place. This is classic adjunctive orthodontics. The anterior deep bite and incisor alignment were not problems for this patient and were not corrected.



• **Fig. 19.14** A labially directed force against a maxillary incisor (from a removable or fixed appliance) will tip the tooth and cause an apparent intrusion of the crown, which reduces the overbite (or makes anterior open bite worse).

appliance or clear aligner may be used to tip the tooth into a normal position. However, that also produces an apparent intrusion and a reduction in overbite (Fig. 19.14). This can present a problem during retention because a positive overbite serves to retain the crossbite correction.

If a deep overbite accompanies an anterior crossbite, correcting it will be much easier if a temporary bite plane that frees the occlusion is added. This bite plane should be carefully constructed to contact the occlusal surfaces of all teeth to prevent any

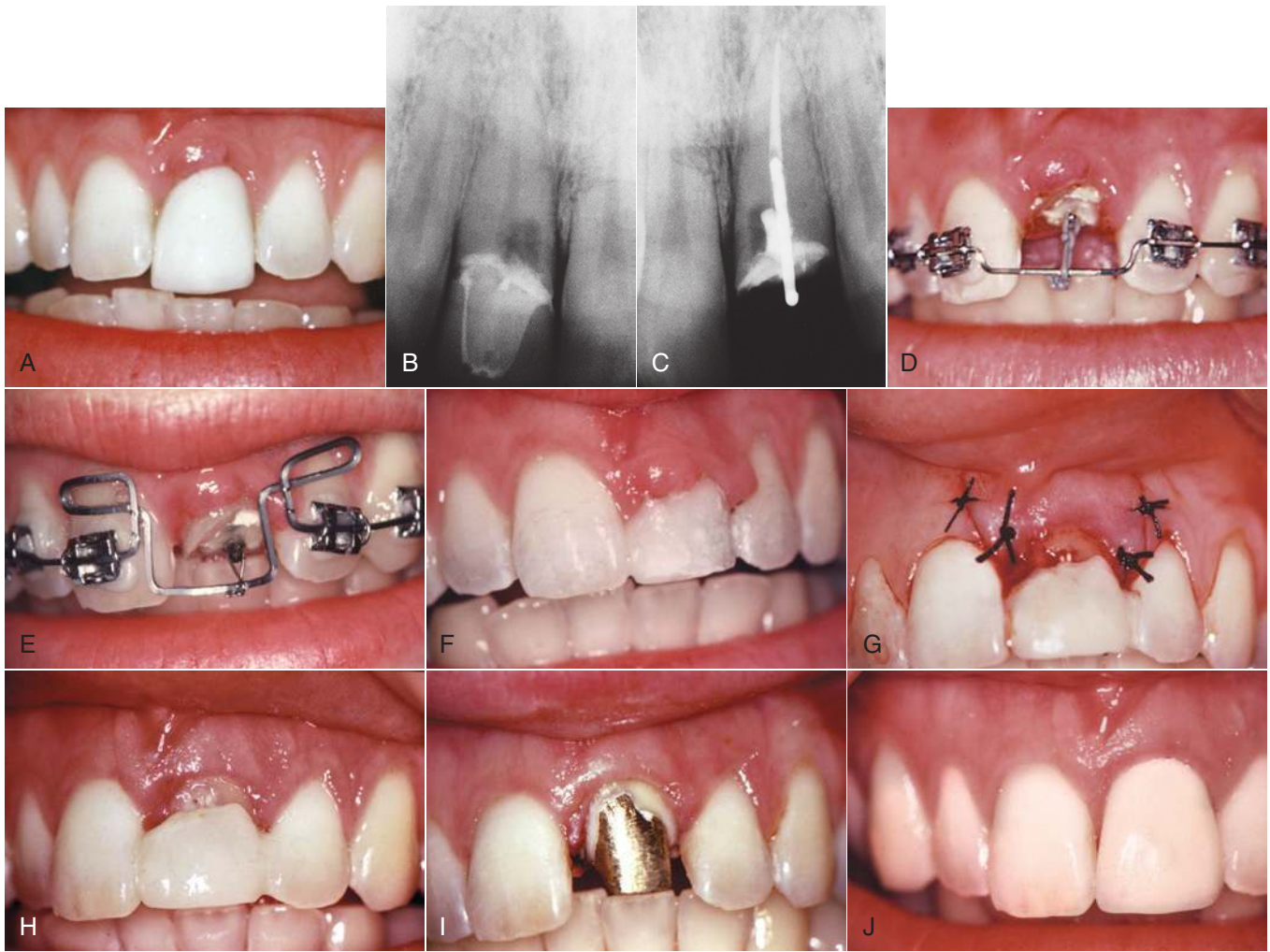supereruption during treatment. As soon as the patient can bite behind the tooth that was in crossbite, the bite plate should be removed. Establishing a good overbite relationship is the key to maintaining the crossbite correction.

## Extrusion

### Treatment Planning

For teeth with defects in or adjacent to the cervical third of the root, controlled extrusion (sometimes called *forced eruption*) can be an excellent alternative to extensive crown-lengthening surgery.<sup>5</sup> This procedure is designed to gain more clinical crown but can be less predictable than ideal in this regard. Its advantages over crown-lengthening surgery are that extrusion of the tooth can allow isolation under a rubber dam for endodontic therapy when it would not be possible otherwise, and it allows crown margins to be placed on sound tooth structure while maintaining a uniform gingival contour that provides improved esthetics (Fig. 19.15). In addition, the alveolar bone height is not compromised, the apparent crown length is maintained, and the bony support of adjacent teeth is not compromised. It usually is necessary to perform some limited recontouring of the gingiva, and often of the bone, to produce a contour even with the adjacent teeth and a proper biologic width.

In general, control of apical infection should be completed before extrusion of the root begins. For some patients, however,



• **Fig. 19.15** Forced eruption can move a tooth that is unrestorable because of subgingival pathology into a position that allows treatment. (A) This central incisor had a crown placed after having been chipped previously, but now showed gingival inflammation and elongation. (B) A periapical radiograph revealed internal root resorption below the crown margin. (C) The treatment plan was endodontic treatment to arrest the internal resorption, then elongation of the root so that a new crown margin could be placed on sound root structure. (D) Initially, an elastomeric tie was used from an archwire segment to an attachment on the post that was cemented in the root canal. (E) Then loops in a flexible rectangular wire (17 × 25 beta-titanium [beta-Ti]) were used for quicker and more efficient tooth movement. (F) Four millimeters of elongation occurred in as many weeks, and a temporary restoration was placed. (G and H) An apically repositioned flap was used to create the correct gingival contour. (I and J) Then a coping and final ceramic crown were prepared. Extraction of the tooth was avoided, and a highly esthetic restoration was possible.

the orthodontic movement must be completed before definitive endodontic procedures because one purpose of extrusion may be to provide better access for endodontic and restorative procedures. If so, preliminary endodontic treatment to relieve symptoms is done initially, and the tooth is maintained with a temporary root filling or other palliative treatment until it has been moved to a better position.

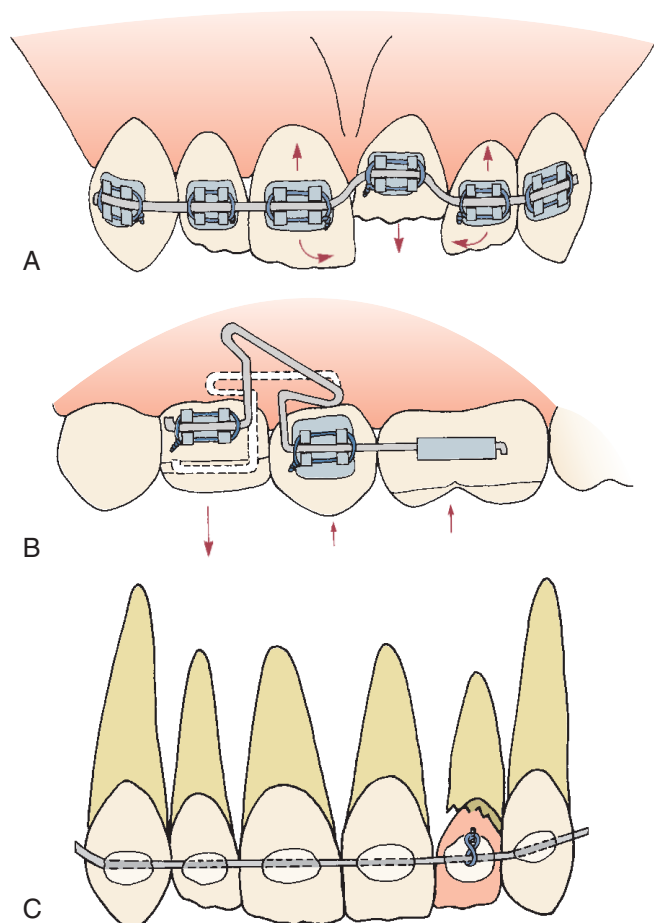
The distance the tooth should be extruded is determined by three things:

1. The location of the defect (e.g., fracture line, root perforation, or resorption site)
2. Space to place the margin of the restoration so that it is not at the base of the gingival sulcus (typically, 1 mm is needed)
3. An allowance for the biologic width of the gingival attachment (about 2 mm)

Thus, if a fracture is at the height of the alveolar crest, the tooth should be extruded about 3 mm; if it is 2 mm below the crest, 5 mm of extrusion ideally would be needed. The size of the pulp chamber or canal at the level of the margin of the future restoration also is a consideration—the wall of the tooth at that location must not be too thin. The crown-to-root ratio at the end of treatment should be 1:1 or better. A tooth with a poorer ratio can be maintained only by splinting it to adjacent teeth.

Isolated one- or two-wall vertical pockets pose a particular esthetic problem if they occur in the anterior region of the mouth. Surgical correction may be contraindicated simply on esthetic grounds. Forced eruption of such teeth, with concomitant crown reduction, can improve the periodontal condition while maintaining excellent esthetics.



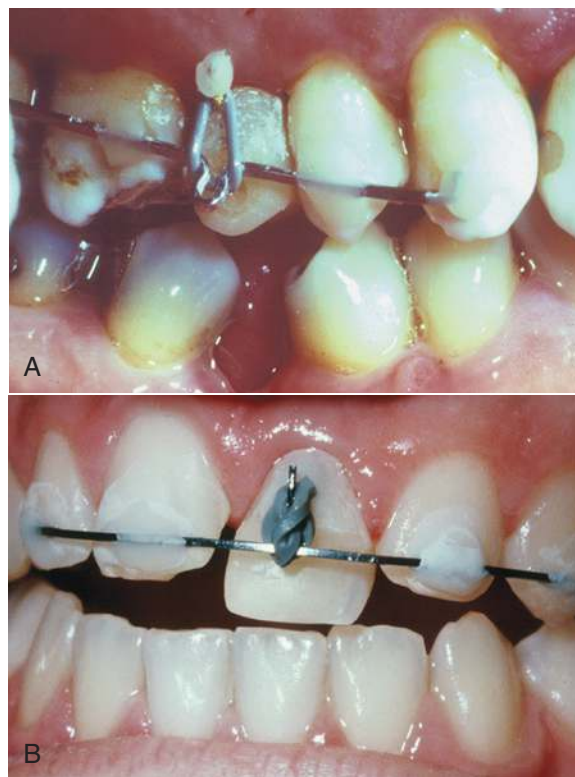


• **Fig. 19.16** (A) Although a continuous orthodontic wire activated as shown will produce the desired extrusive force, it will also cause the teeth on either side to tip toward each other, reducing the space available for the extruding tooth. (B) A segmental T-loop in a rectangular wire ( $17 \times 25$  steel in 18-slot brackets,  $19 \times 25$  beta-titanium [beta-Ti] in 22-slot appliance) will extrude a tooth while controlling mesiodistal tipping of the anchor teeth. (C) Extrusion also can be done without conventional orthodontic attachments by bonding a  $19 \times 25$  steel-stabilizing wire directly to the facial surface of adjacent teeth. An elastomeric module is stretched between the stabilizing wire and a pin placed directly into the crown of the tooth to be extruded. If a temporary crown is used for better esthetics while the extrusion is being done, it must be progressively cut away to make the tooth movement possible. (C courtesy Dr. L. Osterle.)

In general, extrusion can be as rapid as 1 mm per week without damage to the PDL, so 3 to 6 weeks is sufficient for almost any patient. Too much force, and too rapid a rate of movement, runs the risk of tissue damage and ankylosis.

### Orthodontic Technique for Extrusion

Because extrusion is the tooth movement that occurs most readily and intrusion is the movement that occurs least readily, ample anchorage is usually available from adjacent teeth. The appliance needs to be quite rigid over the anchor teeth, and flexible where it attaches to the tooth that is being extruded. A continuous flexible archwire (see Fig. 19.15) produces the desired extrusion but must be managed carefully because it also tends to tip the adjacent teeth toward the tooth being extruded, reducing the space for subsequent restorations and disturbing the interproximal contacts within the arch (Fig. 19.16A). A flexible cantilever spring to extrude a tooth



• **Fig. 19.17** (A) For extrusion of this fractured premolar so that a satisfactory permanent restoration could be made, an elastomeric module was stretched between the stabilizing wire and a pin placed directly into the crown of the premolar. (B) The same technique can be used to extrude an incisor. The temporary restoration placed on the tooth while it is being extruded needs to be reduced at frequent intervals. (Courtesy Dr. L. Osterle.)

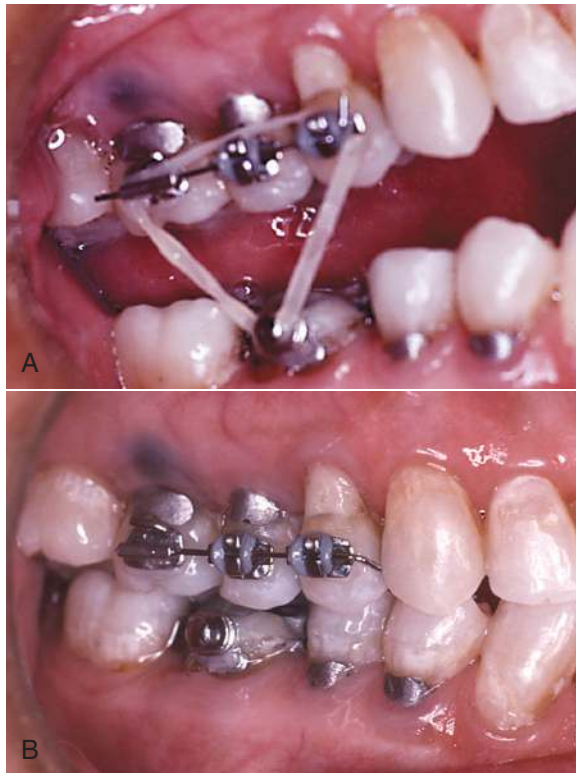
(Fig. 19.16B), or a rigid stabilizing wire and an auxiliary elastomeric module or spring for extrusion (Fig. 19.16C) provide better control.

Two methods are suggested for extrusion in uncomplicated cases. The first employs a stabilizing wire,  $19 \times 25$  or  $21 \times 25$  stainless steel, bonded directly to the facial surface of the adjacent teeth (Fig. 19.17). A post and core with temporary crown and pin is placed on the tooth to be extruded, and an elastomeric module is used to extrude the tooth. This appliance is simple and provides excellent control of anchor teeth, but better control can be obtained when orthodontic brackets are used.

The alternative is to bond brackets to the anchor teeth, bond an attachment (often a button rather than a bracket) to the tooth to be extruded, and use interarch elastics (Fig. 19.18) or a flexible archwire (Fig. 19.19). If the buccal surface of the tooth to be extruded is intact, a bracket should be bonded as far gingivally as possible.

If the crown of a posterior tooth is hopelessly destroyed, an orthodontic band with a bracket usually can be placed over the remaining root surface. An orthodontic band has the benefit of helping isolation procedures during emergency endodontic treatment. Once endodontic treatment is completed, a pin in the tooth can be used for the attachment, and a temporary crown can be placed if needed for esthetics. Adjacent teeth are bonded to serve as the anchor unit.

With any technique for controlled extrusion, the patient must be seen every 1 to 2 weeks to remove any occlusal contacts that would impede eruption (for instance, shorten the height of a



• **Fig. 19.18** For this patient in her 60s, the facial surface of a lower first molar fractured to below the gingival margin. (A) The maxillary premolars and first molar were bonded and stabilized, and an elastic to a button bonded on the lower molar was used to elongate it to the point that (B) the fracture line was exposed and a satisfactory crown preparation was possible.

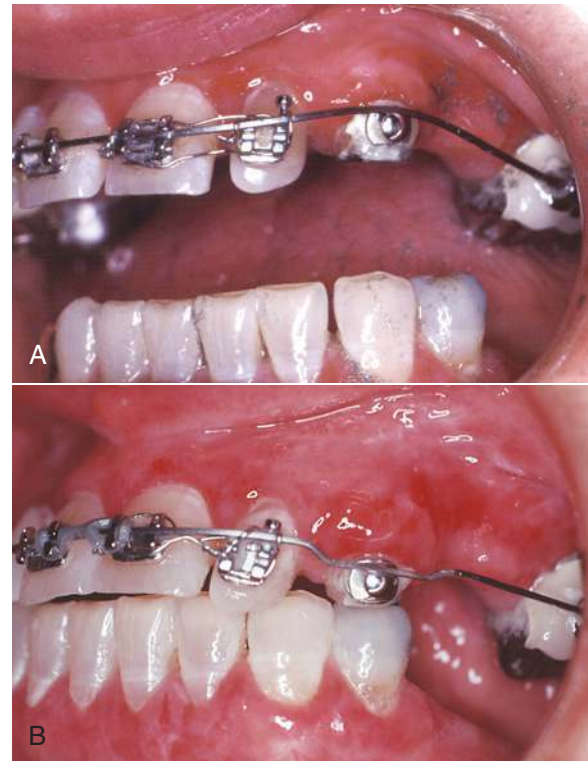
temporary crown) (see Fig. 19.17), control inflammation, and monitor progress. After active tooth movement has been completed, a period of at least 3 weeks but not more than 6 weeks of stabilization is needed to allow reorganization of the PDL. If a periodontal surgical procedure is needed to recontour the alveolar bone and/or reposition the gingiva, it can be done a month after completion of extrusion. As with molar uprighting, it is better to complete the definitive prosthetic treatment without extensive delay.

## Alignment of Anterior Teeth

### Diastema Closure and Space Redistribution

The major indication for adjunctive orthodontic treatment to correct malaligned anterior teeth is preparation for buildups, veneers, or implants to improve the appearance of the maxillary incisor teeth. The most frequent problem is a maxillary central diastema, which is often further complicated by irregular spacing related to small or missing lateral incisors (Fig. 19.20).

A “diagnostic set-up” is very helpful in planning the correction of such problems. For this procedure, the study casts are duplicated and the malaligned teeth are carefully cut from the model, repositioned, and then waxed back onto the cast in a new position. If digital casts are available, a modern alternative is to do this on a computer screen, and this is part of routine treatment planning when a sequence of clear aligners will be used in comprehensive treatment (see later). This allows evaluation of the feasibility of the crown and root movements required, the anchorage available,



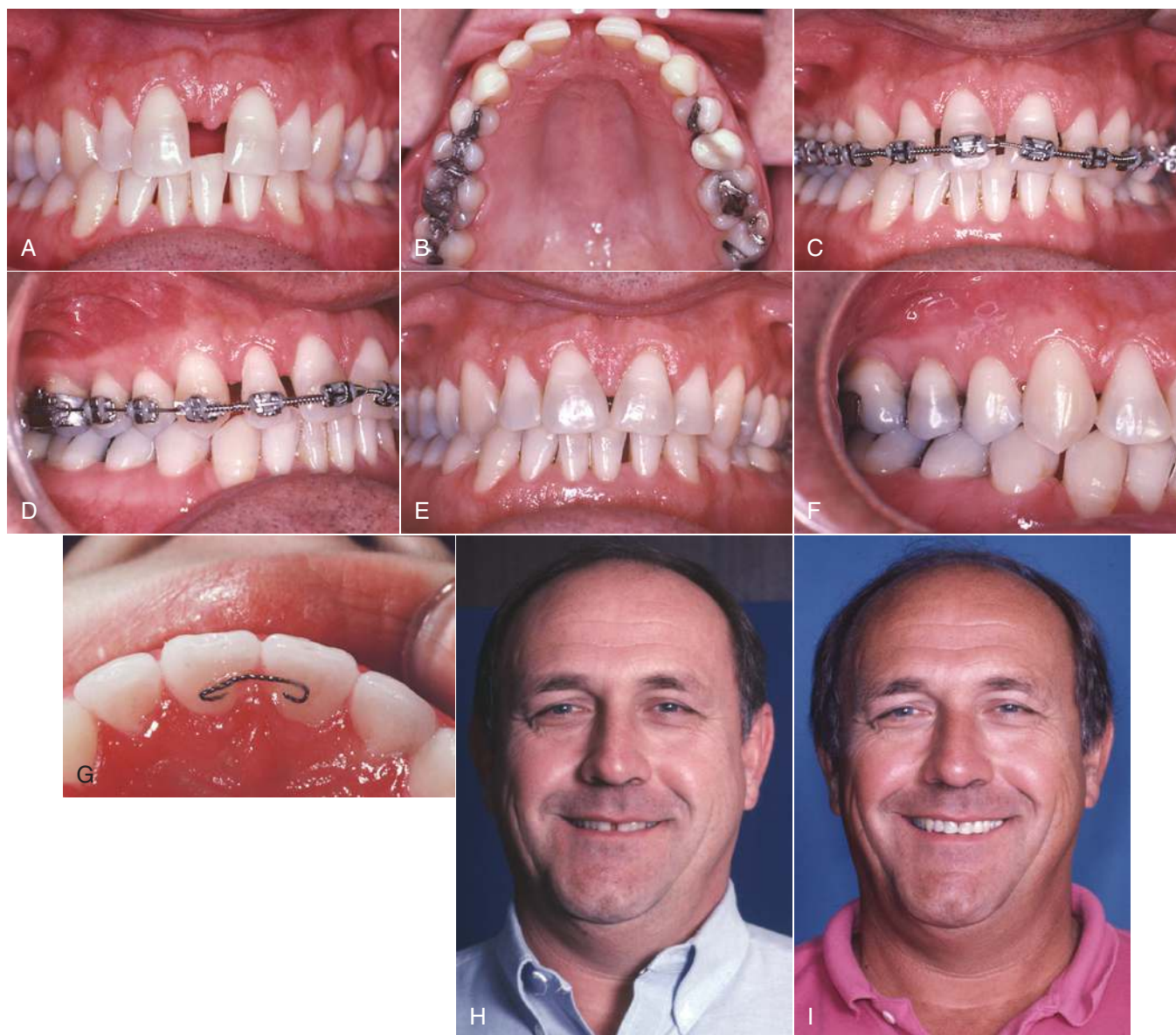• **Fig. 19.19** A bridge attached to the maxillary left canine failed because of caries beneath the crown on the canine. After endodontic treatment, a button was bonded to an amalgam temporary buildup on the root, and (A) a continuous archwire (17 × 25 beta-titanium [beta-Ti]) was used to extrude the tooth; amalgam was removed from temporary buildup weekly. (B) At the point at which a permanent restoration could be placed, all the amalgam buildup had been removed and the tooth had been elongated 5 mm.

the periodontal support for each tooth, and the possible occlusal interferences.

There are two possible orthodontic techniques: a partial fixed appliance as shown in Fig. 19.20, typically with bonded brackets on most if not all the maxillary teeth and a bonded tube on the first molars for additional anchorage control, or a sequence of clear aligners. With a fixed appliance, initial alignment is carried out by using a light wire such as 16-mil A-NiTi or 17.5-mil braided steel. This wire is replaced after the teeth are aligned with a 16- or 18-mil round steel wire, along which the teeth are repositioned with elastomeric modules or coil springs. There is always a tendency for the space to reopen after any degree of diastema closure. Bonding a flexible wire on the lingual surface of the incisors as a permanent retainer is recommended.

An alternative is the use of a sequence of clear aligners. These can be produced in two ways: (1) for modest amounts of tooth movement, aligners can be made in the office with relatively inexpensive computer software and three-dimensional (3-D) printing (see Fig. 10.12) and (2) for more extensive tooth movement, a set of 15 to 50 aligners can be fabricated on stereolithographic models created from computer models of the projected tooth movement (Invisalign, ClearCorrect, others). In adjunctive treatment, the first method is potentially quite useful. The second method, discussed in more detail in the latter part of this chapter, is almost prohibitively expensive unless comprehensive treatment is planned and requires excellent patient compliance when space closure with root movement is required.





• **Fig. 19.20** If spacing of maxillary incisors is related to small teeth and a tooth-size discrepancy, composite buildups are an excellent solution, but satisfactory esthetics may require redistribution of the space before the restorations are placed, as in this patient who was concerned about his large central diastema. (A and B) Before treatment, age 48. (C and D) Redistribution of the space by using a fixed appliance with coil springs on a 16-mil steel archwire immediately before removal of the orthodontic appliance and placement of the restorations (to be done the same day). A 17.5-mil multistrand steel wire was used for initial alignment before the coil springs were placed. (E and F) Completed restorations (composite buildups). (G) Note the fixed retainer of bonded 21.5-mil multistrand wire on the lingual surface of the central incisors to prevent partial reopening of the midline space. Surgical revision of the frenum was not performed, partially in deference to the patient's age. (H) Appearance on smile before and (I) after treatment.

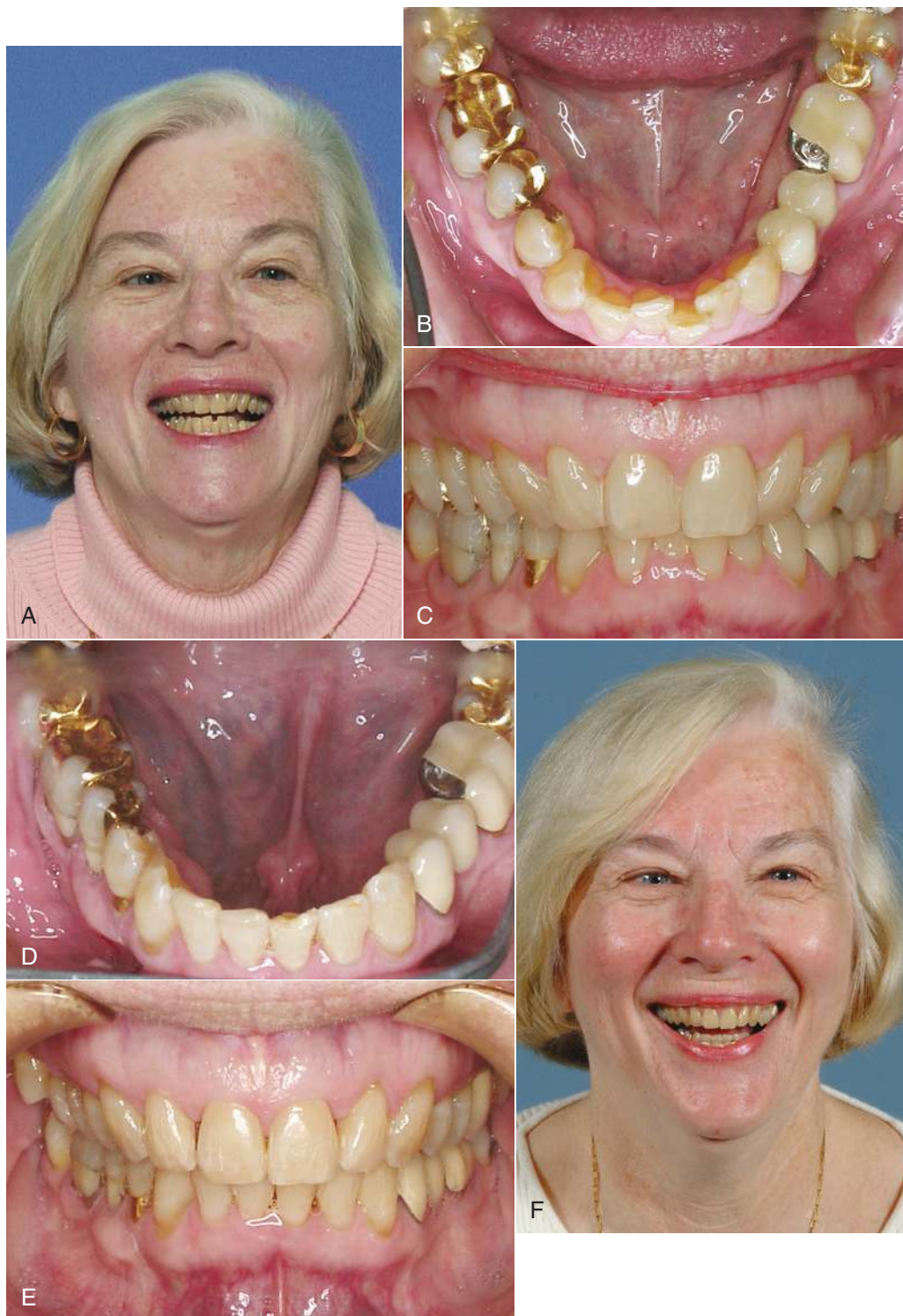### Crowded, Rotated, and Displaced Incisors

As a rule, spacing is the problem when maxillary incisors need realignment to facilitate other treatment. Crowding usually is the problem when alignment of lower incisors is considered to provide access for restorations, achieve better occlusion, or enable the patient to maintain the teeth. In some cases, alignment of incisors in both arches must be considered. The key question is whether the crowding should be resolved by expanding the arch, removing some interproximal enamel from each tooth to provide space,<sup>6</sup> or removing one lower incisor.

Expansion of a crowded incisor segment can be done with clear aligners, but if only the lower arch is to be treated, the esthetics of the appliance is not a consideration, and a partial fixed appliance is more efficient and cost-effective (Fig. 19.21). A segment of A-NiTi wire, with stops to make it slightly advanced, usually is the best way to bring the teeth into alignment (see Fig. 15.3).

Stripping the contact points of the teeth to remove enamel can provide space for alignment of mildly irregular lower incisors, and either a fixed appliance or a clear aligner sequence can provide the tooth movement. This should be undertaken with





• **Fig. 19.21** In an adult with a damaged lower incisor (in this case, the left central incisor with a crown fracture) and incisor crowding, there were two treatment possibilities: extract the damaged tooth and use the space to align the remaining teeth, or align the teeth with arch expansion and restore the damaged one. The decision had an esthetic component because the lower incisors are visible on smile in older individuals. In this patient, aligning the lower incisors without extraction would also require aligning the upper incisors, but this expansion would increase lip support and improve the overall facial appearance as well as the dental appearance. (A) Smile before treatment, after loss of one corner of the lower right central incisor. (B) Mandibular occlusal view. (C) Frontal view. Note the moderately deep bite and lack of overjet. The restorative dentist sought orthodontic consultation, thinking that extraction of the damaged tooth might be the best plan. The patient wanted the best esthetic result and accepted a period of treatment with a fixed appliance on both arches, after which the incisor would be restored. The orthodontic alignment required 5 months. (D) Mandibular occlusal view after alignment. (E) Frontal view. (F) Smile after restoration was completed.

caution, however, because it may have an undesirable effect on overjet, overbite, posterior intercuspation, and esthetics.<sup>7</sup> In severe crowding, removing one lower incisor and using the space to align the other three incisors can produce a satisfactory result and can be managed with clear aligner therapy if bonded attachments are part of the treatment plan (Fig. 19.22). The treatment time and difficulty, whatever the type of appliance, put this at or across the border of comprehensive treatment. Neither stripping nor incisor extraction should be undertaken without a diagnostic set-up to verify feasibility.

Remember that stretched gingival fibers are a potent force for relapse after rotations have been corrected, and that good long-term stability may require a fibrotomy (see Chapter 17). Whether clear aligners or a fixed appliance was used, retention is necessary until restorative or other treatment is completed. This can be the final aligner in a sequence (although this may be too flexible to be a good retainer), a molded thermoplastic retainer after a fixed appliance is removed, a canine-to-canine clip retainer, or a bonded fixed retainer (see Chapter 18).

## Comprehensive Treatment in Adults

### Psychologic Considerations

A major motivation for orthodontic treatment of younger patients is the parents' desire to do the best they can for their children. The typical child or adolescent accepts orthodontics in about the same rather passive way that he or she accepts going to school, summer camp, and the inevitable junior high school dance: as just another in the series of events that one must endure while growing up. Occasionally, of course, an adolescent actively resists orthodontic treatment, and the result can be unfortunate for all concerned if the treatment becomes the focus of an adolescent rebellion. In most instances, however, children tend not to become emotionally involved in their treatment.

Adults in both the younger and older groups, in contrast, seek comprehensive orthodontic treatment because they themselves really want it. For the younger patients who are trying to improve their lot in life, exactly what they want is not always clearly expressed, and some young adults have a remarkably elaborate hidden set of motivations. It is important to explore why an individual wants treatment, and why now as opposed to some other time. This is the only way to avoid setting up a situation in which the patient's expectations for treatment cannot possibly be met. Sometimes, orthodontic treatment is sought as a final effort to improve personal appearance to deal with a series of complicated social problems. Orthodontic treatment obviously cannot be relied on to repair personal relationships, save jobs, or overcome a series of financial disasters. If the prospective patient has unrealistic expectations of that sort, it is much better to deal with them sooner than later.

Most adults in both the younger and older groups, fortunately, understand why they want orthodontics and are realistic about what they can obtain from it. One might expect those who seek treatment to be less secure and less well adjusted than the average adult, but for the most part, they have a more positive self-image than average.<sup>8</sup> It apparently takes a good deal of ego strength to seek orthodontic treatment as an adult, and ego strength rather than weakness characterizes most potential adult patients. A patient who seeks treatment primarily because he or she wants it (internal motivation) is more likely to respond well psychologically than a patient whose motivation is the urging of others or the expected impact of treatment on others (external motivation). Patients with

an inadequate or pathologic personality (Fig. 19.23) are more likely to have a complex set of unrecognized expectations for treatment, the proverbial hidden agenda.

One way to identify the minority of individuals who may present problems because of their unrealistic expectations is to compare the patient's perception of his or her orthodontic condition with the doctor's evaluation. If the patient thinks that the appearance or function of the teeth is creating a severe problem but an objective assessment simply does not corroborate that, orthodontic treatment should be approached with caution.

Even highly motivated adults are likely to have some concern about the appearance of orthodontic appliances. The demand for an invisible orthodontic appliance comes almost entirely from young adults or late adolescents who are concerned about the reaction of others to obvious orthodontic treatment. In an earlier era, this was a major reason for using removable appliances in adults, particularly the Crozat appliance in the United States (see Fig. 10.1).

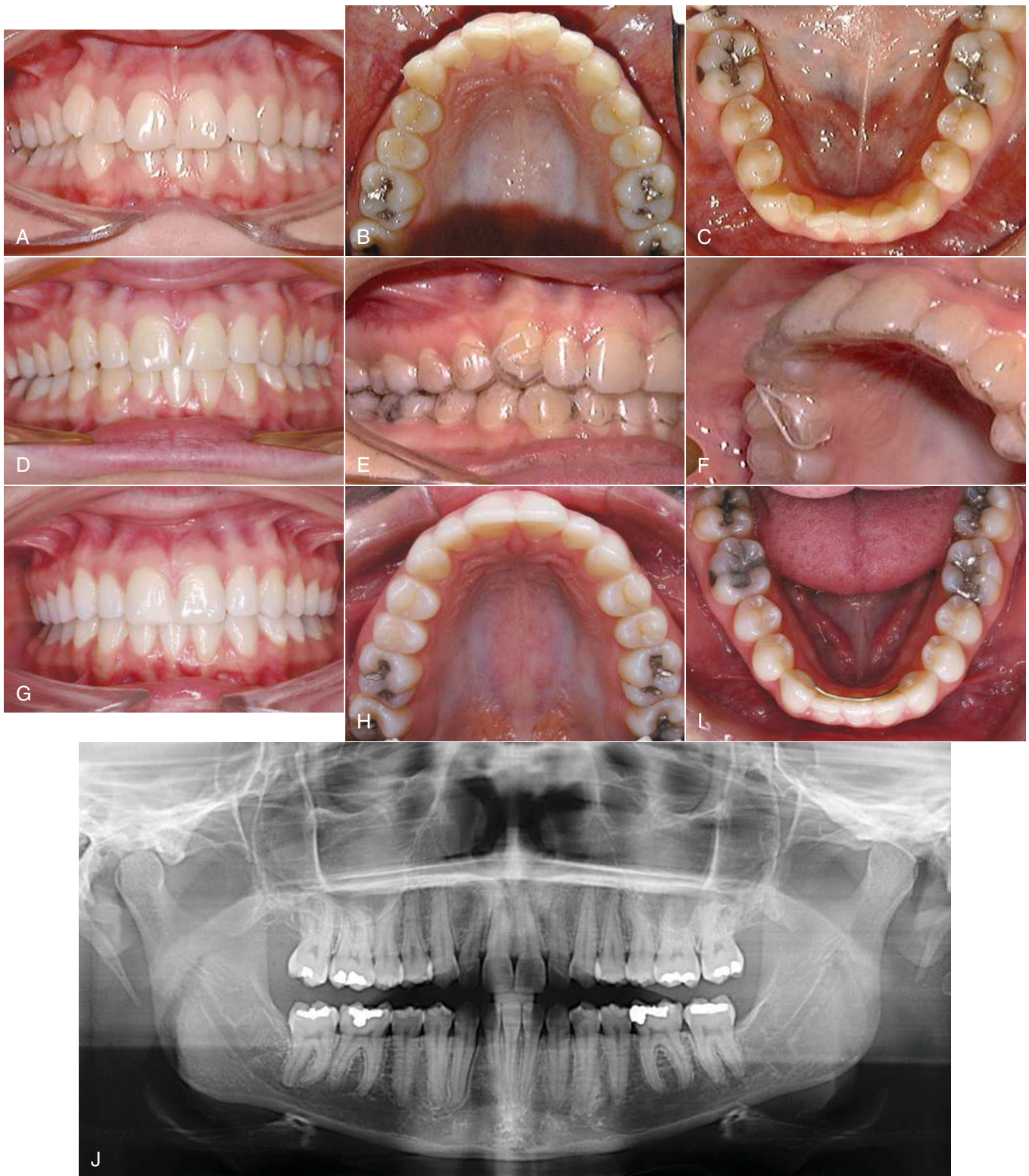All the possibilities for a better appearing appliance, however, can lead to potential compromises in the orthodontic treatment. Plastic brackets create problems in controlling root position and closing spaces. Ceramic brackets, although much better, inevitably make treatment more difficult because of the problems outlined in Chapter 10. Lingual appliances have been greatly improved since the turn of the 21st century and now make all types of tooth movement quite possible but still are technically difficult for the doctor to use efficiently and can be difficult for patients to tolerate. Clear aligners manage some types of tooth movement quite well but have difficulty with others (see Box 10.1). Small bonded attachments on teeth that require complex movements give the aligner a better purchase, partially overcoming this difficulty, but this makes the treatment much more complex).

Although there is nothing wrong with using the most esthetic appliance possible for an adult patient, the compromises associated with this approach should be thoroughly discussed in advance. It is unrealistic for a patient to expect that orthodontic treatment can be carried out without other people knowing about it. The whole issue of the visibility of the orthodontic appliances is much less important, at least in the United States, than many patients fear. Orthodontic treatment for adults is certainly socially acceptable, and one does not become a victim of discrimination because of visible orthodontic appliances. In a sense, the patient's expectations become a self-fulfilling prophecy. If the patient faces others confidently, a visible orthodontic appliance causes no problems. Only if the patient acts ashamed or defensive is there likely to be any negative reaction from others.

The question of whether an orthodontic office should have a separate treatment area for adults, separated from the adolescents who still constitute the bulk of most orthodontic practices, is related to the same set of negative attitudes. Most comprehensive orthodontic treatment for adolescents is carried out in open treatment areas, not only because this is efficient but also because the learning effect from having patients observe what is happening to others is a positive influence in patient adaptation to treatment. Should adults be segregated into private rooms, rather than joining the group in the open treatment area? This is logical only if the adult is greatly concerned about privacy (which is truer of Europeans than Americans) or is vaguely ashamed of being an orthodontic patient.

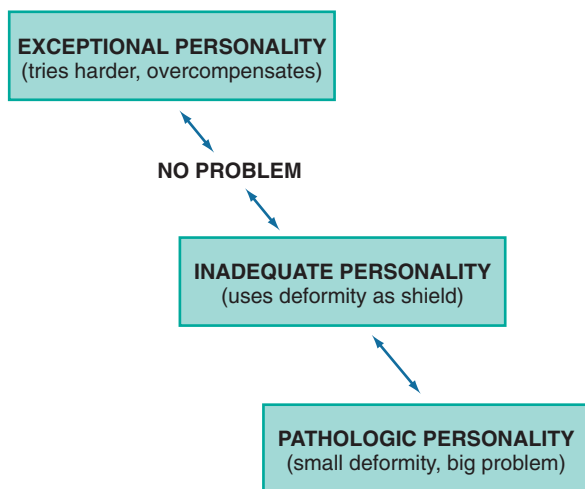
Sometimes, for some adults, treatment in a private room may be preferable, but for most adults, learning from interacting with other patients helps them understand and tolerate the treatment procedures. There are positive advantages in having patients at





• **Fig. 19.22** This 24-year-old patient had a congenitally missing mandibular right lateral incisor and a retained but failing primary incisor, and was selected for Invisalign treatment. (A) Frontal view. (B) Maxillary occlusal. Note the rotation of the maxillary right canine. (C) Mandibular occlusal. The plan was extraction of the primary incisor and closure of the extraction site with a series of Invisalign aligners and bonded attachments to produce the necessary rotation and root movement. Before treatment began, air-rotor stripping of the maxillary posterior quadrants was done to reduce the tooth-size discrepancy. (D) Note the hard-to-see bonded attachments on the maxillary right canine and incisors and on the mandibular right canine and central incisor. The original plan called for 13 upper and 15 lower aligners, plus three overcorrection aligners. (E and F) After eight aligners it was noted that the maxillary right canine was not tracking, and an elastic to additional bonded attachments was used along with the aligner to further rotate it. New records were taken, and four upper and five lower revision aligners, with three revision overcorrection aligners, were fabricated. (G to I) Completion of treatment. A bonded canine-to-canine mandibular retainer was used, and the final maxillary aligner was continued at night as the maxillary retainer. (J) Panoramic radiograph at the completion of treatment. Total treatment time was 19 months (which included 2 months waiting for revision aligners). (Courtesy Dr. W. Gierie.)





• **Fig. 19.23** Dentofacial deformity can affect an individual's life adjustment. Fortunately, most potential adult orthodontic patients fall into the "no problem" category psychologically. A few highly successful individuals (who nevertheless may seek treatment) can be thought of as almost overcompensating for their deformity with their exceptional personality, but they tend to be personable and very pleasant to work with. For some individuals, however, the orthodontic condition can become the focus for a wide-ranging set of social adjustment problems that orthodontics alone will not solve. These patients fall into the "inadequate personality" and "pathologic personality" categories; these patients are difficult and almost impossible, respectively, to help. An important aspect of orthodontic diagnosis for adults is understanding where a patient fits along this spectrum.

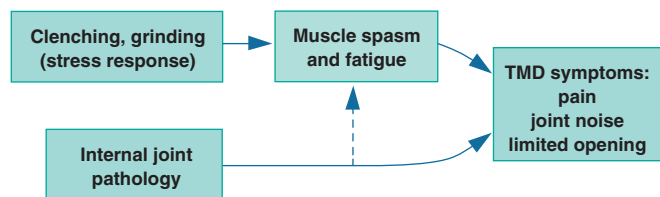
various stages of treatment compare their experiences, and this is at least as beneficial to adults as to children, perhaps more so.

Although adults can be treated in the same area as adolescents, they cannot be handled in the same way. The typical adolescent's passive acceptance of what is being done is rarely found in adult patients, who want and expect a considerable degree of explanation of what is happening and why. An adult can be counted on to be interested in the treatment, but that does not automatically translate into compliance with instructions. Unless adults understand why they have been asked to do various things, they may choose not to do them, not in the passive way an adolescent might just shrug it off but from an active decision not to do it. In addition, adults, as a rule, are less tolerant of discomfort and more likely to complain about pain after adjustments and about difficulties in speech, eating, and tissue adaptation. Additional chair time to meet these demands should be anticipated.

These characteristics might make adults sound like less desirable orthodontic patients than adolescents, but this is not necessarily so. Working with individuals who are intensely interested in their own treatment and motivated to take care of their teeth can be a pleasant and stimulating alternative to the less-involved adolescents. If the expectations of both the doctor and the patient are realistic, comprehensive treatment for adults can be a rewarding experience for both.

### Temporomandibular Dysfunction as a Reason for Orthodontic Treatment

TMD and temporomandibular (TM) pain rarely are encountered in children seeking orthodontic treatment, but TMD is a significant motivating factor for some adults who consider orthodontic treatment.<sup>9</sup> The relationship between dental occlusion and TMD is



• **Fig. 19.24** Temporomandibular dysfunction (TMD) symptoms arise from two major causes: muscle spasm and fatigue, which almost always are related to excessive clenching and grinding in response to stress, and internal joint pathology. As a general guideline, patients with symptoms of muscle spasm and fatigue may be helped by orthodontic treatment, but simpler methods should be attempted first. Orthodontics alone is rarely useful for patients with internal joint pathology.

highly controversial, and it is important to view this objectively. Orthodontic treatment can sometimes help patients with TMD, but it cannot be relied on to correct these problems.<sup>10</sup> Patients need to understand what may happen to their symptoms during and after orthodontics.

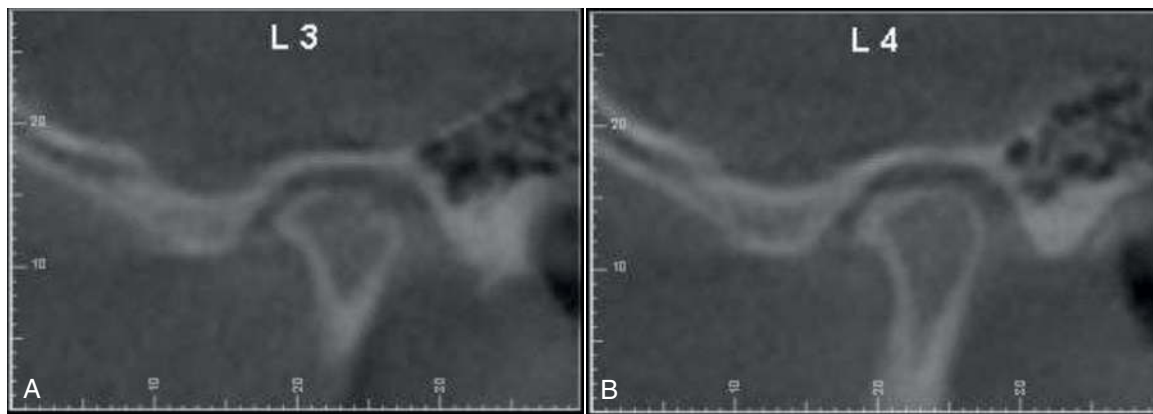
### Types of Problems

In diagnosis of TMD problems, patients are classified as being in one of four large groups: those with masticatory muscle disorders, TM joint disorders, chronic mandibular hypomobility, or growth disorders.<sup>11</sup> From the perspective of potential orthodontic treatment in adults, differentiating between the first two groups is particularly important (Fig. 19.24). Because muscle spasm and joint pathology can coexist, the distinction in many patients is difficult. Nevertheless, it is unlikely that orthodontics will relieve TMD symptoms in a patient who has internal joint problems or other nonmuscular sources of pain. Those who have myofascial pain or dysfunction, on the other hand, may benefit from improved dental occlusion. It is interesting that in men with severe malocclusion, occlusal characteristics are directly associated with health-related quality of life. Even though women with severe malocclusion are more likely to have TMD, this was not true for them, although pain and TMD do show a significant association. This suggests that correcting the malocclusion might be more helpful in male than female TMD patients.<sup>12</sup>

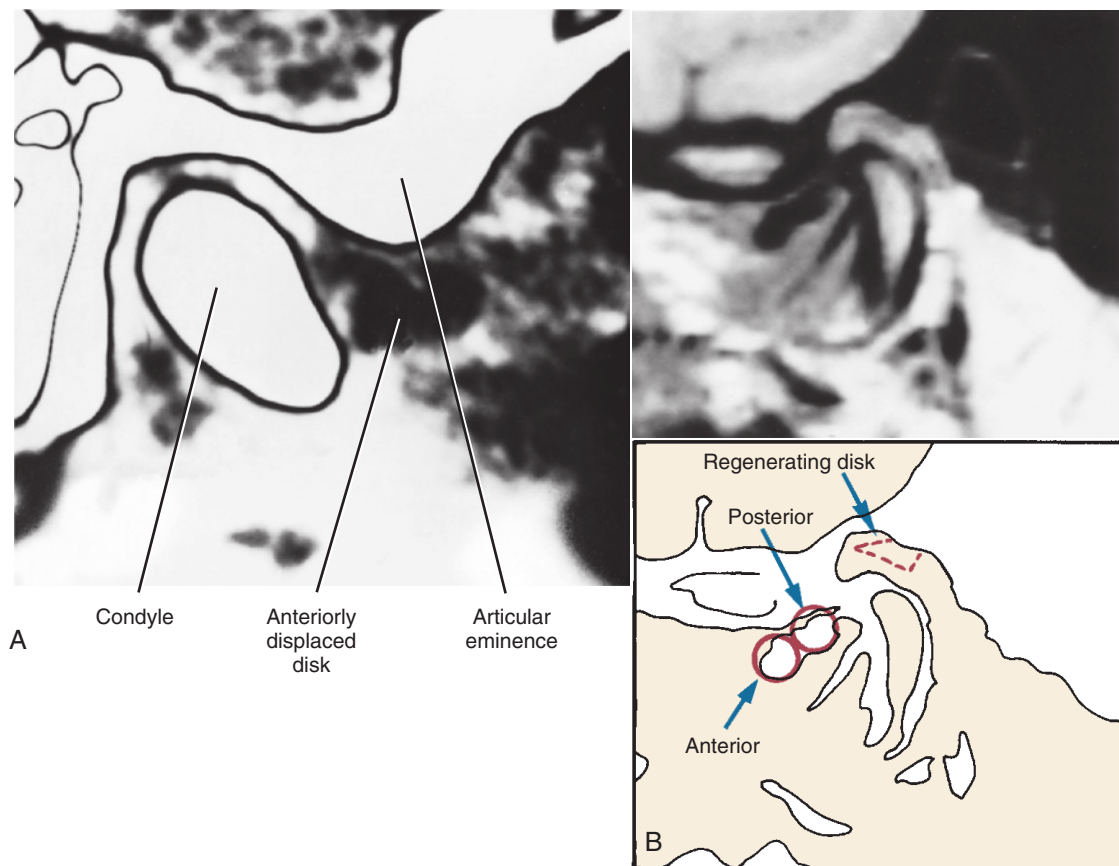
Almost all of us develop some symptoms of degenerative joint disease as we grow older, and it is not surprising that the jaw joints sometimes are involved (Fig. 19.25). Arthritic involvement of the TM joints is most likely to be the cause of TMD symptoms in patients who have arthritic changes in other joints of the body. A component of muscle spasm and muscle pain should be suspected in individuals whose only symptoms are in the TM joint area, even if radiographs show moderate arthritic degeneration of the joint.

Displacement of the disc (Fig. 19.26) is increasingly frequent as age increases and can arise from a number of causes. One possibility is trauma to the joint such that the ligaments that oppose the action of the lateral pterygoid muscle are stretched or torn. In this circumstance, muscle contraction moves the disk forward as the mandibular condyles translate forward on wide opening, but the ligaments do not restore the disk to its proper position when the jaw is closed. The result is a click on opening and closing, as the disk pops into place over the condylar head as the jaw opens but is displaced anteriorly on closure.

The click and symptoms associated with it can be corrected if an occlusal splint is used to prevent the patient from closing



• **Fig. 19.25** Pathologic changes in the condylar head, as seen in cone beam computed tomography (CBCT) images from a large field-of-view scan. (A) Note the erosion of the distal surface of the condylar head and (B) the lipping of the anterior surface in the adjacent slice.



• **Fig. 19.26** Hard and soft tissue imaging of disk displacement in the temporomandibular joint. (A) Computed tomography (CT) view of a displaced mandibular disk, which can be visualized (as a darker area) in front of the condyle. (B) Magnetic resonance imaging (MRI) view of a displaced disk, with the anterior and posterior bands indicated on the adjacent sketch. There is evidence on this scan of a regenerating disk, as shown in the dashed area. MRI scans have largely replaced radiographic views for the diagnosis of disk displacement because the soft tissues can be seen more clearly and no ionizing radiation is required; cone beam computed tomography (CBCT) is preferred for visualization of bony changes.

the jaw beyond the point at which displacement occurs. The resulting relief of pain influences patients and dentists to seek either restorative or orthodontic treatment to increase facial vertical dimension. However, orthodontic elongation of all posterior teeth to control disk displacement is not a treatment procedure that

should be undertaken lightly. Often the patient whose symptoms have been controlled by a splint can tolerate its reduction or removal, without requiring major occlusal changes. Usually there are better ways of handling disc displacement than orthodontic treatment.

Myofascial pain develops when muscles are overly fatigued and tend to go into spasm. It is all but impossible to overwork the jaw muscles to this extent during normal eating and chewing. To produce myofascial pain, the patient must be clenching or grinding the teeth for many hours per day, presumably as a response to stress. Great variations are seen in the way different individuals respond to stress, both in the organ system that feels the strain (many problems besides TMD are related to stress) and in the amount of stress that can be tolerated before symptoms appear (tense individuals develop stress-related symptoms before their relaxed colleagues do). For this reason, it is impossible to say that occlusal discrepancies of any given degree will lead to TMD symptoms, although recent multicenter research has at least clarified the possibilities.<sup>13</sup>

It is possible to demonstrate that some types of occlusal discrepancies predispose patients who clench or grind their teeth to the development of TMD symptoms. It must be kept in mind, however, that it takes two factors to produce myofascial pain: an occlusal discrepancy *and* a patient who clenches or grinds the teeth. Perhaps the most compelling argument against malocclusion as a primary cause of TMD is the observation that TMD is no more prevalent in patients with severe malocclusion than in the general population.<sup>14</sup> The dictum “let your teeth alone” would solve myofascial pain problems if it could be followed by the patient.

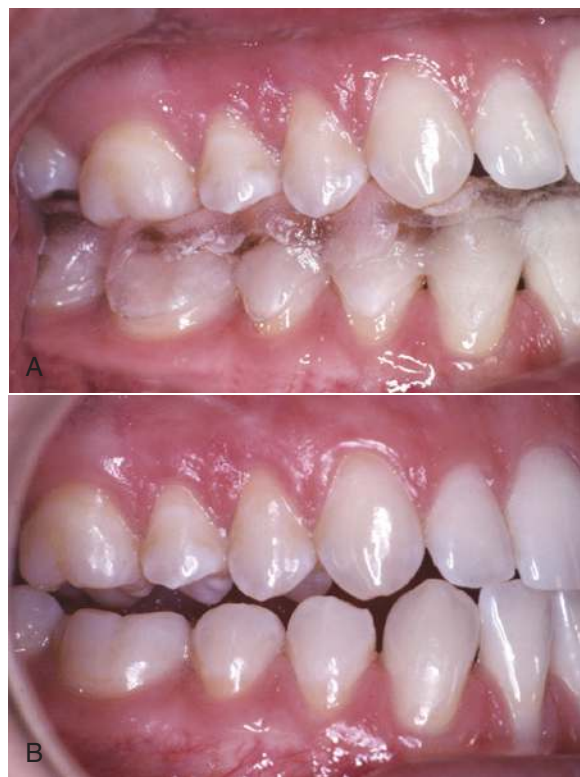### Treatment Indications

From this perspective, three broad approaches to myofascial pain symptoms can be considered: reducing the amount of stress; reducing the patients' reactions to stress; or improving the occlusion, thereby making it harder for patients to hurt themselves. Drastic alteration of the occlusion, by either restorative dental procedures or orthodontics, is logical only if the less invasive stress-control and stress-adaptation approaches have failed. In that circumstance, orthodontic treatment to alter the occlusion so that the patient can better tolerate parafunctional activity may be worth attempting. In some instances, this may involve orthognathic surgery to reposition the jaws.

The extent to which TMD symptoms in many adults disappear when comprehensive orthodontic treatment begins can be surprising and overly gratifying to those who do not understand the etiology of myofascial pain. Orthodontic intervention can appear almost magical in the way that TMD symptoms disappear long before the occlusal relationships have been corrected. The explanation is simple—orthodontic treatment makes the teeth sore, so grinding or clenching sensitive teeth as a means of handling stress does not produce the same subconscious gratification as previously. Then the parafunctional activity stops, and the symptoms vanish.

The changing occlusal relationships also contribute to breaking up the habit patterns that contributed to the muscle fatigue and pain. No matter what the type of orthodontic treatment, as long as treatment that produces strongly deflective contacts is avoided, symptoms are unlikely to be present while movement of a significant number of teeth is occurring. Prolonged use of Class II or Class III elastics may not be well tolerated in adults who have had TMD problems and should be avoided (for that matter, prolonged use of elastics should be avoided in most other adult patients as well).

The moment of truth for TMD patients who have had orthodontic treatment comes sometime after the orthodontic treatment is completed, when the clenching and grinding that originally caused the problem tend to recur. At that point, even if the occlusal relationships have been significantly improved, it may be impossible to keep the patient from moving into extreme jaw positions and



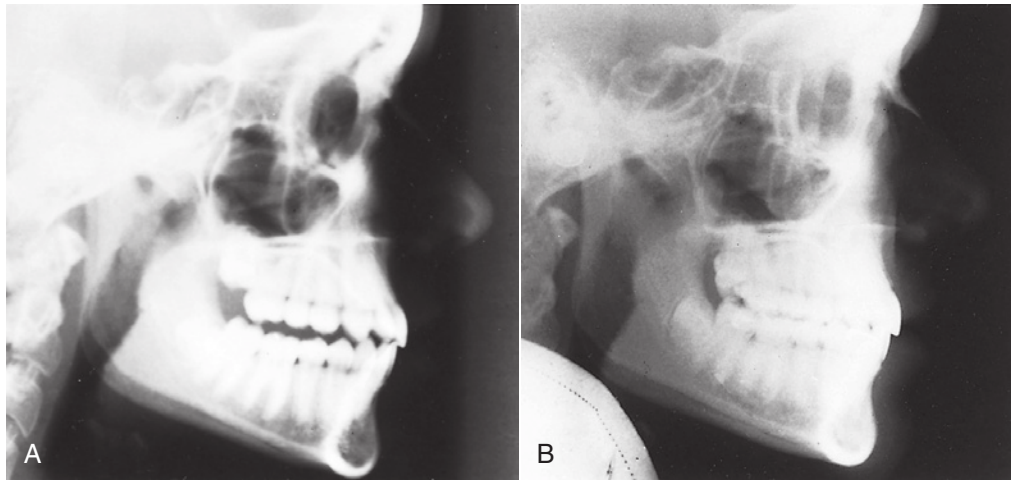
• **Fig. 19.27** (A) Occlusal relationships in a 24-year-old woman who had worn a splint covering only her posterior teeth for the previous 18 months. (B) Note the posterior open bite when the splint was taken out. This was created by a combination of intrusion of the posterior teeth and further eruption of the anterior teeth. Orthodontic treatment to bring the posterior teeth back into occlusion required tranquilizers during treatment because she was uncomfortable without the splint until occlusion was reestablished.

engaging in parafunctional activity that produces pain. The use of interocclusal splints in this situation may be the only way to keep symptoms from recurring. In short, the miraculous cure that orthodontic treatment often provides for myofascial pain tends to disappear with the appliance. Those who have had symptoms in the past are always at risk of having them recur.

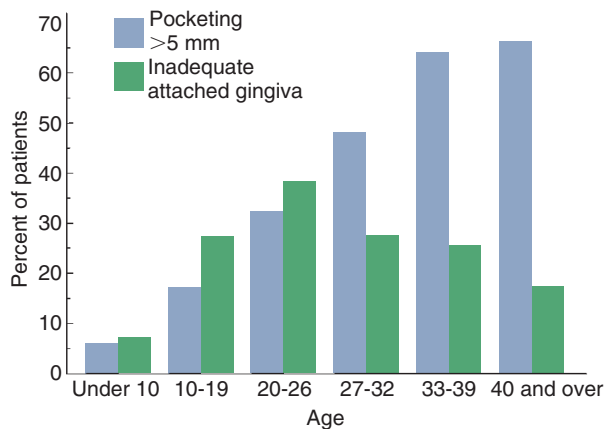
Occasionally, orthodontic treatment is made more complicated by previous splint therapy. If an occlusal splint for TMD symptoms covers the posterior but not the anterior teeth, the anterior teeth that have been taken out of occlusion begin to erupt again and may come back into occlusion even though the posterior teeth are still separated (Fig. 19.27). Clinically, it may appear that the posterior teeth are being intruded, but incisor eruption usually is a greater contributor to the development of posterior open bite. In only a few months, the patient may end up in a situation in which discarding the splint has become impossible. Then the only treatment possibilities are elongation of the posterior teeth, either with crowns or orthodontic extrusion, or intrusion of the anterior teeth.

Orthodontic intervention at this stage is difficult because TMD symptoms are likely to develop immediately if the splint is removed, and it is not possible to elongate the posterior teeth orthodontically without discarding or cutting down the splint. Placing orthodontic attachments on the posterior teeth and using light vertical elastics to the posterior segments is a method that can be used to bring





• **Fig. 19.28** Cephalometric radiographs for the patient shown in Fig. 19.27. Before (A) and after (B) orthodontic treatment to extrude the posterior teeth back into occlusion.



• **Fig. 19.29** The prevalence of periodontal pockets of 5 mm or more and prevalence of inadequate attached gingiva as a function of age in 1000 consecutive patients with severe orthodontic problems who were referred for possible surgical-orthodontic treatment. (Redrawn from Moriarty JD, Simpson DM. *J Dent Res*. 1984;63[Special Issue A, 1249].)

the posterior teeth back into occlusion (Fig. 19.28), if the patient can tolerate this treatment. Some re-intrusion of the elongated anterior teeth is likely to occur, but a significant increase in face height is often maintained. This should be considered an unfortunate side effect, not something that might be beneficial.

## Periodontal Considerations

Periodontal problems are rarely a major concern during orthodontic treatment of children and adolescents because periodontal disease usually does not arise at an early age and tissue resistance is higher in younger patients. For the same reasons, periodontal considerations are increasingly important as patients become older, regardless of whether periodontal problems were a motivating factor for orthodontic treatment.

The prevalence of periodontal disease as a function of age in a large group of potential orthodontic patients with severe malocclusion is shown in Fig. 19.29. Note that up to the late 30s, there is nearly a straight-line relationship between age and periodontal

pocketing (defined here as the presence of pockets of 5 mm or more). In contrast, the prevalence of mucogingival problems peaks in the 20s. The odds are that any patient over the age of 35 has some periodontal problems that could affect orthodontic treatment, and mucogingival considerations are important in treatment of the younger adult group.

Periodontal disease is not a continuous and steadily progressive degenerative process. Instead, it is characterized by episodes of acute attack on some but usually not all areas of the mouth, followed by quiescent periods. It is obviously important to identify high-risk patients and high-risk sites. The best indicator that disease may be present is a history of disease. At present, persistent bleeding on gentle probing is the best indicator of active and presumably progressive disease, which is why it is important for the orthodontist to probe carefully during an orthodontic clinical examination. New diagnostic procedures to evaluate subgingival plaque and crevicular fluids for the presence of indicator bacteria, enzymes, or other chemical mediators now are clinically useful. These are likely to be used on potential orthodontic patients referred for further periodontal evaluation. There appear to be at least three risk groups in the population for progression of periodontal bone loss: those with rapid progression (about 10%), those with moderate progression (the great majority, about 80%), and those with no progression (about 10%).<sup>15</sup>

There is no contraindication to treating adults who have had periodontal disease and bone loss, as long as the disease has been brought under control (Fig. 19.30). Progression of untreated periodontal breakdown must be anticipated, however, and the patient's periodontal situation must receive major attention in planning and executing orthodontic treatment for adults.

## Treatment of Patients With Minimal Periodontal Involvement

Any patient undergoing orthodontic treatment must take extra care to clean the teeth, but this is even more important in adult orthodontics. Bacterial plaque is the main etiologic factor in periodontal breakdown, and its effect is largely determined by the host response. Orthodontic appliances simultaneously make maintenance of oral hygiene more difficult and more important. In children and adolescents, even if gingivitis develops in response to the presence of orthodontic appliances, it almost never extends

into periodontitis. This cannot be taken for granted in adults, no matter how good their initial periodontal condition.

The periodontal evaluation of a potential adult orthodontic patient must include not only the response to periodontal probing but also the level and condition of the attached gingiva. Labial movement of incisors in some patients can be followed by gingival recession and loss of attachment. The risk is greatest when irregular teeth are aligned by expanding the dental arch, which stresses and thins the gingiva, adding to the stress that might be created by gingival inflammation or toothbrush trauma. Once recession begins, it can progress rapidly, especially if there is little or no keratinized attached gingiva and the attachment is only alveolar mucosa.

It was once thought that the width of the gingival attachment was the major factor in whether recession occurred. The concept now is that two characteristics are important: the width of the attached gingiva (not all keratinized gingiva is attached) and the thickness of the gingival tissue. The width of the attached gingiva can be observed most readily by inserting a periodontal probe and observing the distance between the point at which the gingival attachment is encountered and the point at which the alveolar mucosa begins. Lingually tipped lower incisors in patients with a prominent chin have a high risk of recession, and thin gingival tissue probably is the reason.

For adult orthodontic patients, it is much better to prevent gingival recession than to try to correct it later. For this reason, a gingival graft (Fig. 19.31) must be considered in adults with minimal attached gingiva or thin tissue, particularly those for whom arch expansion will be used to align incisors and those who will have surgical mandibular advancement or genioplasty (see Chapter 20).

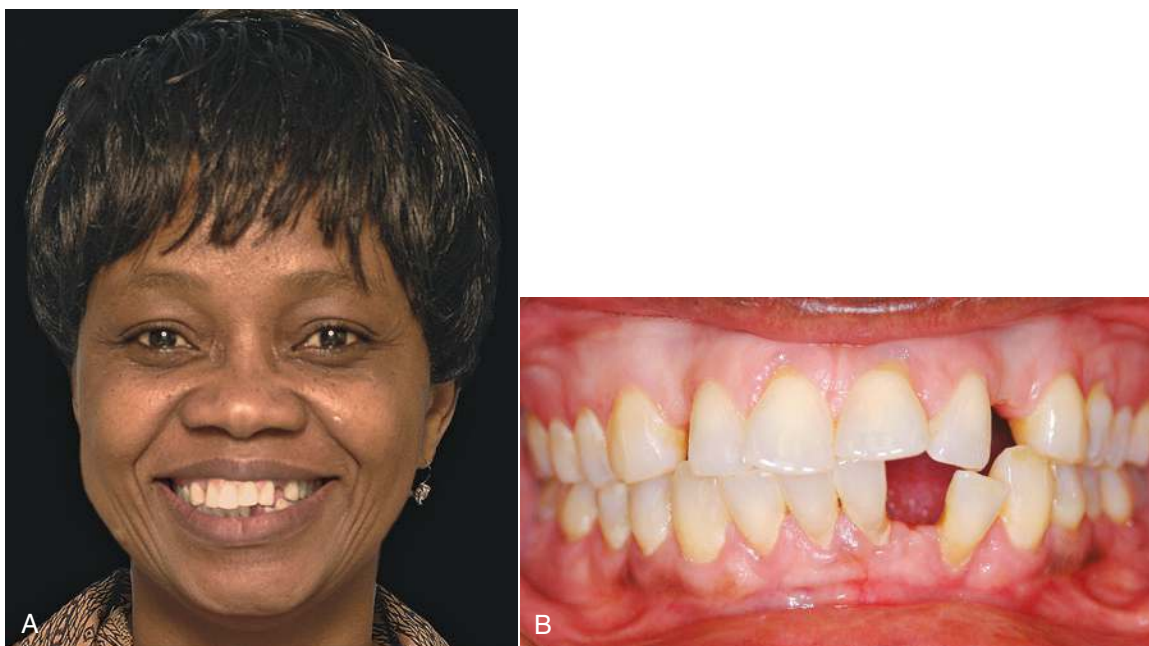### Moderate Periodontal Involvement

Before orthodontic treatment is attempted for patients who have preexisting periodontal problems, dental and periodontal disease must be brought under control. Preliminary therapy can include all aspects of periodontal treatment. It is important to remove all calculus and other irritants from periodontal pockets before any tooth movement is attempted, and it is often wise to use surgical flaps to expose these areas to ensure the best possible scaling. Is a bone graft slurry indicated to prevent bone dehiscence and gingival recession when significant arch expansion is planned for an adult? Data to indicate the point at which that might make a significant difference are lacking.

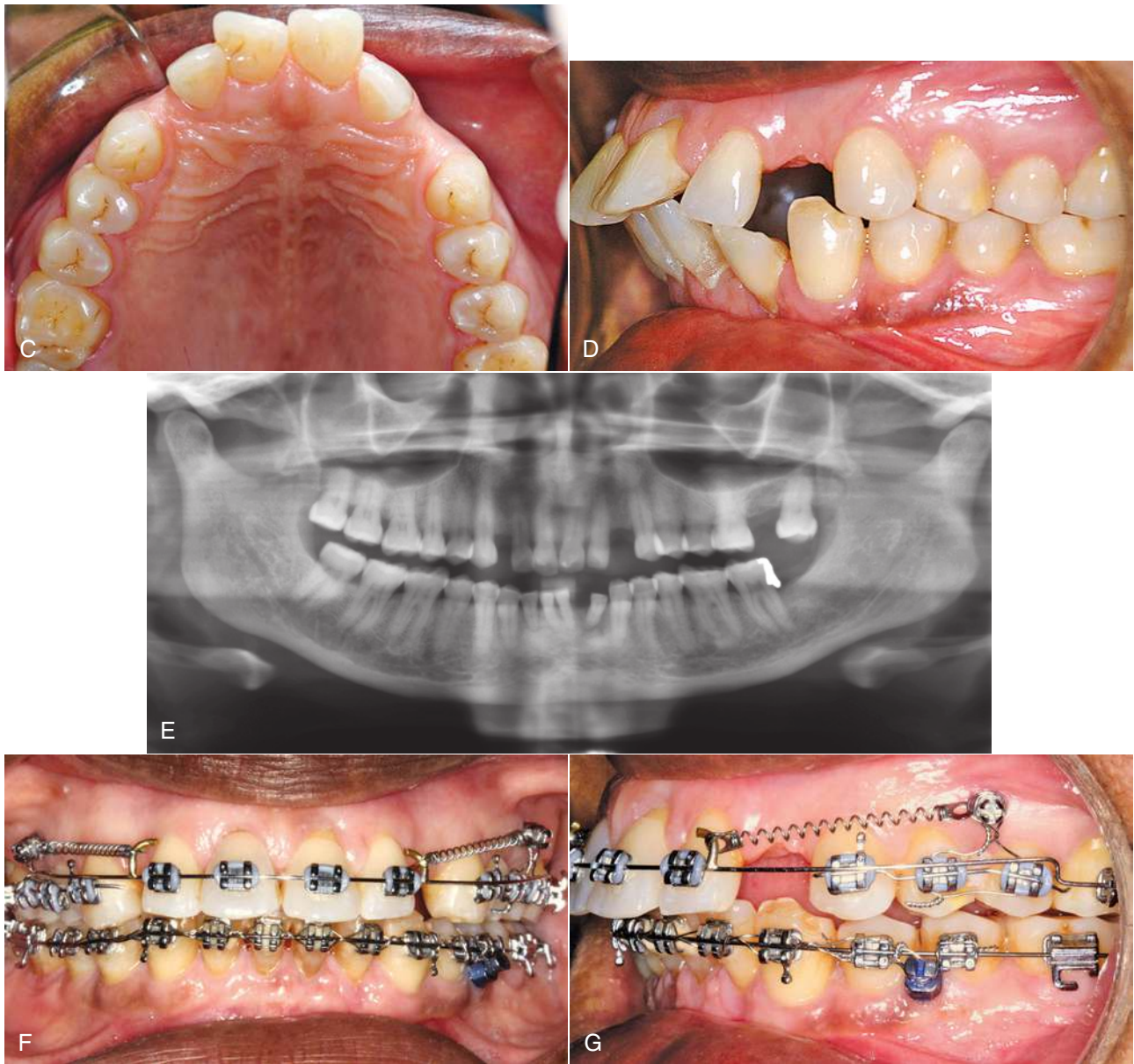
Treatment procedures to facilitate the patient's long-term maintenance, such as osseous recontouring or repositioned flaps to compensate for areas of gingival recession, are best deferred until the final occlusal relationships have been established. A period of observation following preliminary periodontal treatment to make sure that the patient's disease is adequately controlled and to allow healing after the periodontal therapy should precede comprehensive orthodontics.

Disease control also requires endodontic treatment of any pulpally involved teeth. There is no contraindication to the orthodontic movement of an endodontically treated tooth, so root canal therapy before orthodontics will cause no problems. Attempting to move a pulpally involved tooth, however, is likely to cause a flare-up of pulpitis and pain.

The general guideline for preliminary restorative treatment is that temporary restorations should be placed to control caries, with the definitive restorative dentistry delayed until after the

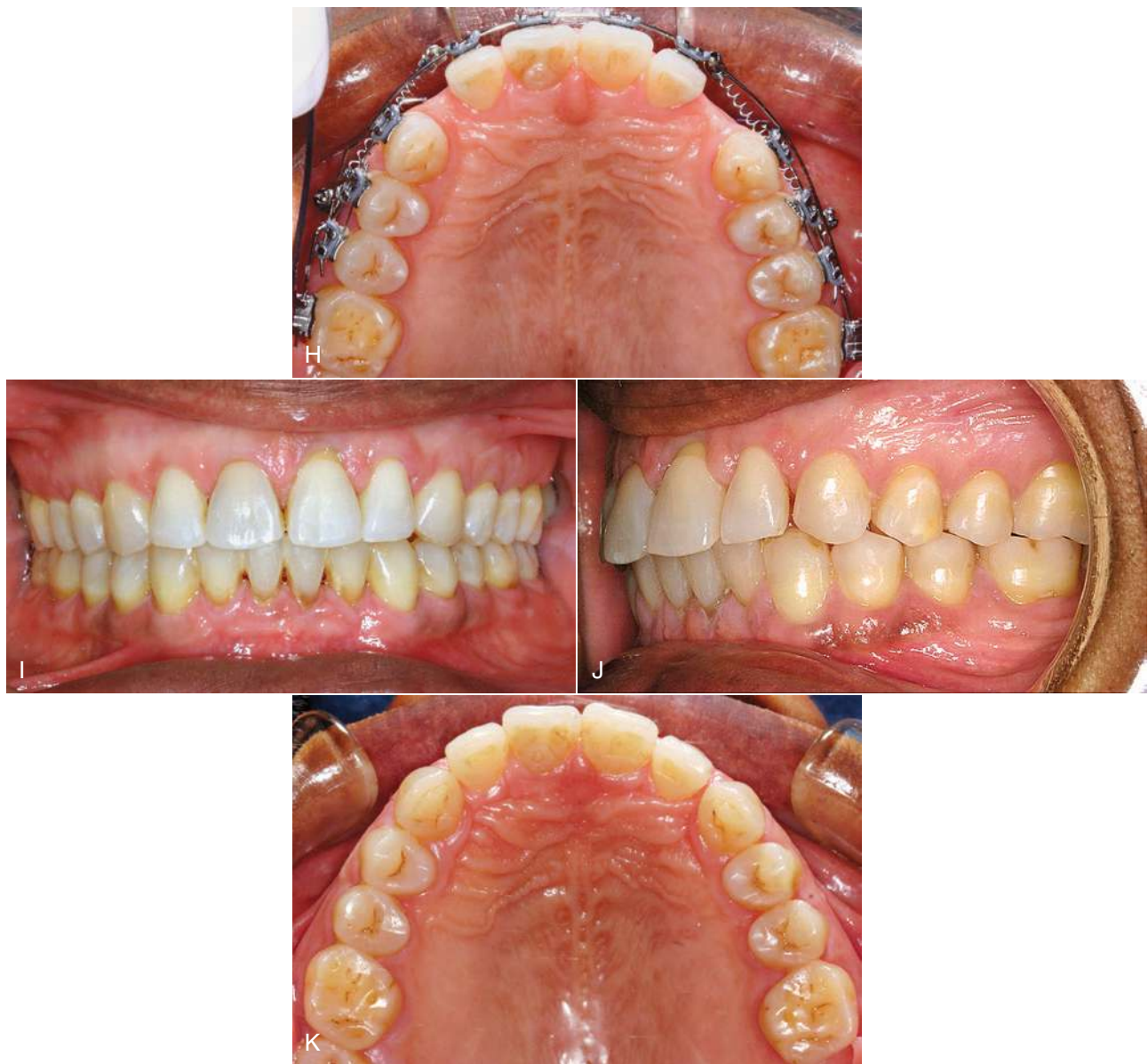

• **Fig. 19.30** Comprehensive orthodontic treatment for a patient with severe periodontal disease requires that active disease has been brought under control and that control is maintained, but given that, major tooth movement without worsening the periodontal condition is quite possible. (A) Initial smile and (B) initial close-up frontal view, showing the spacing in both arches created by the drifting of teeth that accompanied her severe periodontal problems.

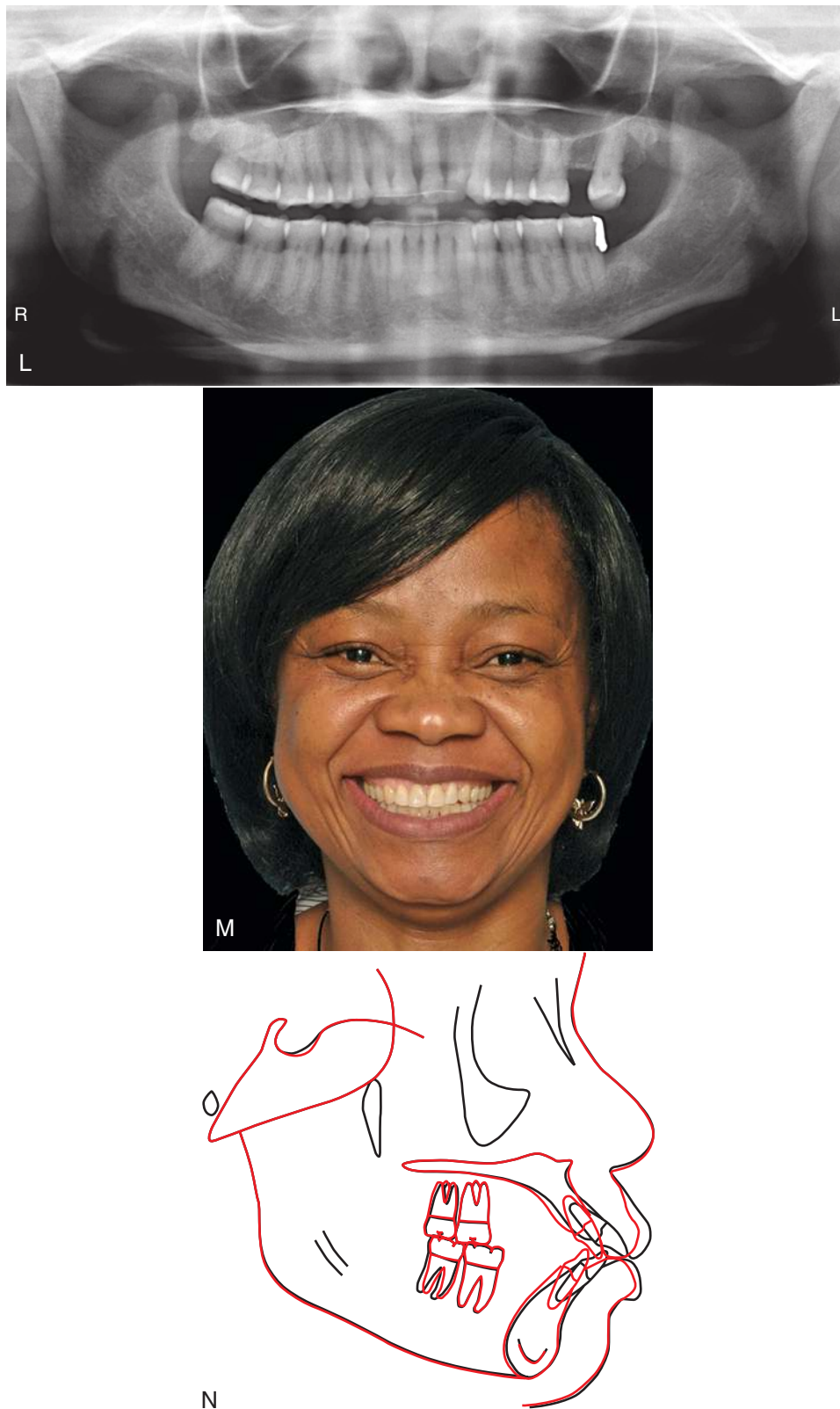


• **Fig. 19.30, cont'd** (C and D) Occlusal and lateral intraoral views before treatment. (E) Initial panoramic radiograph. She had moderately severe generalized periodontal disease with localized severe bone loss. After the periodontal disease was brought under control, she sought treatment to retract her protruding incisors and close the anterior spaces in both arches. The plan was to use skeletal anchorage (alveolar bone screws) in both arches to retract the incisors while maintaining normal overbite. Closure of the old maxillary left second molar extraction space was judged to be more than could be managed even with skeletal anchorage without compromising the symmetry of the anterior segment. (F and G) Austenitic nickel-titanium (A-NiTi) coil springs and sliding mechanics were used for space closure in both arches, with screws placed between the first and second premolars in both arches. Note the combination of direct and indirect anchorage in the maxillary arch. *Continued*



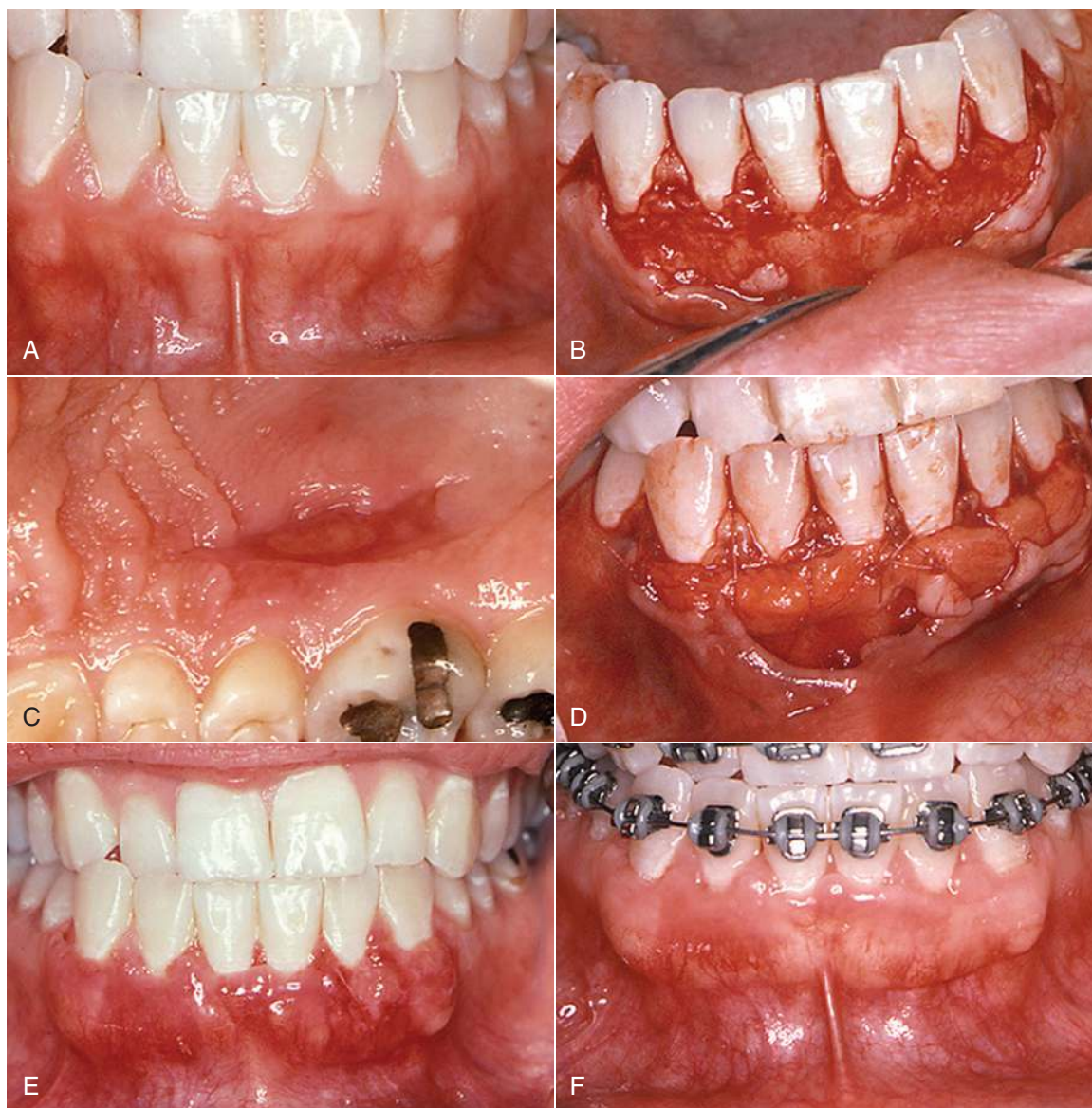

• **Fig. 19.30, cont'd** (H) Occlusal view of temporary anchorage device (TAD)-supported space closure in the maxillary arch. (I to K) Age 58, after completion of orthodontic treatment that required 35 months. Note the improvement in dental alignment and occlusion, and the maintenance of her periodontal health.



• **Fig. 19.30, cont'd** (L) Posttreatment panoramic radiograph. The overhang on the distal of the lower left first molar was removed during later restorative dentistry. (M) Posttreatment smile. (N) Cephalometric superimposition showing the major retraction of the incisors with no forward movement of the posterior teeth. (Courtesy Dr. D. Grauer.)





• **Fig. 19.31** In adults who will undergo comprehensive orthodontic treatment, gingival grafting to create adequate quantity and thickness of attached gingiva is important before orthodontic tooth movement is begun. (A) Lack of attached gingiva and thin gingival tissue in the mandibular anterior region in a patient whose lower incisors must be advanced to align them. Note the alveolar mucosa extending almost to the gingival margin on all anterior teeth. (B) Surgical preparation of a bed for grafting. (C) The palatal donor site for tissue for the gingival graft. (D) The graft sutured in place. (E) Healing 1 week later, showing incorporation of the grafts. (F) Initial alignment archwire in place 3 months later, with the gingival grafts creating both a thicker contour of the gingival tissue and a generous band of attachment. (Courtesy Dr. J. Moriarty.)

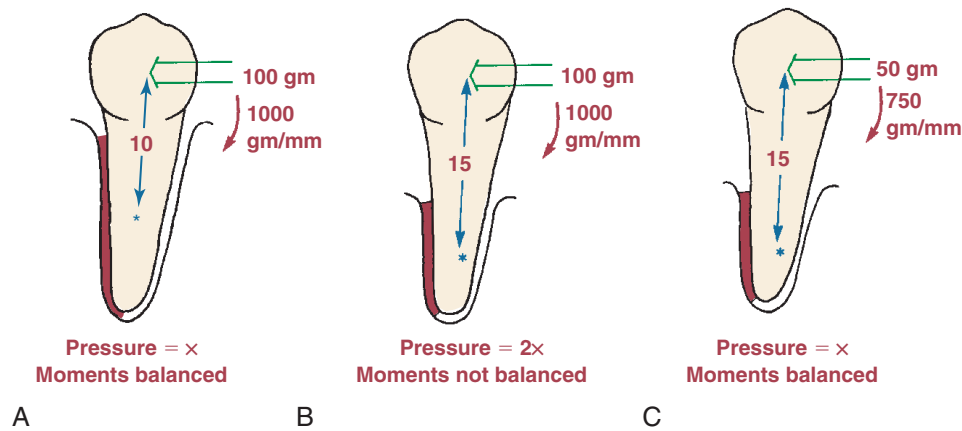
orthodontic phase of treatment. Temporary restoration, however, should not be taken to mean the use of a short-lived material that will last only a few months. Composite resin is now the preferred temporary restorative material while orthodontics is being carried out. Cast restorations should be delayed until after the final occlusal relationships have been established.

Because the margins of bands can make periodontal maintenance more difficult, it is better to use a fully bonded orthodontic appliance for periodontally involved adults. Self-ligating brackets or steel ligatures are preferred for patients with periodontal involvement,

rather than elastomeric rings to retain orthodontic archwires, because patients with elastomeric rings have higher levels of microorganisms in gingival plaque.<sup>16</sup>

During comprehensive orthodontics, a patient with moderate periodontal problems must be on a maintenance schedule, with the frequency of cleaning and scaling depending on the severity of the periodontal disease. Periodontal maintenance therapy at 2- to 4-month intervals is the usual plan. Adjunctive chemical agents between appointments (including chlorhexidine if needed) also should be considered.





• **Fig. 19.32** Bone loss around a tooth that is to be moved affects both the force and the moment needed. (A) For optimum bodily movement of a premolar whose center of resistance is 10 mm apical to the bracket (i.e., normal height of alveolar bone support), a 100-gm force and a 1000 gm-mm moment is needed. (B) The same force system would be inappropriate for an identical premolar whose bone support had been reduced by periodontal disease such that the periodontal ligament (PDL) area is half as large as it was originally and the center of resistance is now 15 mm apical to the bracket. For such a tooth, the 100-gm force would produce twice the optimum pressure in the PDL, and the moment would not be large enough to prevent tipping. (C) The correct force system for the periodontally involved tooth would be a 50-gm force and a  $15 \times 50 = 750$  gm-mm moment. Orthodontic movement of periodontally involved teeth can be done only with careful attention to forces (smaller than normal) and moments (relatively larger than normal).

### Severe Periodontal Involvement

The general approach to treatment for patients with severe periodontal involvement is the same as that outlined earlier, but the treatment itself must be modified in two ways: (1) periodontal maintenance should be scheduled at more frequent intervals, perhaps with the patient being seen as frequently for periodontal maintenance as for orthodontic appliance adjustments (i.e., every 4 to 6 weeks), and (2) orthodontic treatment goals and mechanics must be modified to keep orthodontic forces to an absolute minimum because the reduced area of the PDL after significant bone loss means higher pressure in the PDL from any force (Fig. 19.32). Sometimes it is helpful to temporarily retain a tooth that is hopelessly involved periodontally, using it to help support an orthodontic appliance that will contribute to saving other teeth.

The crown–root ratio is a significant factor in the long-term prognosis for a tooth that has sustained periodontal bone loss. Shortening the crown has the virtue of improving the crown–root ratio. In adults with bone loss and an anterior deep bite, the orthodontist should not hesitate to remove part of the crown of elongated lower incisors as an alternative to intrusion, when this would both simplify orthodontic leveling of the arch and improve the periodontal prognosis. Reducing crown height of upper incisors must be approached cautiously because of the possible adverse effect on anterior tooth display, and often intrusion of abraded incisors so that the crown can be restored to normal height is a better approach.<sup>17</sup> It is interesting that even after severe periodontal problems have developed, orthodontic treatment can be carried out without further loss of alveolar bone *if* good control of the periodontal condition is maintained. Space closure in areas of major bone loss sometimes leads to an improvement in bone height if at least one wall of the periodontal pocket remains (Fig. 19.33). As part of informed consent, patients like this can be told that they can have comprehensive orthodontic treatment without undue risk of making their periodontal situation worse, but they should not be promised an improvement.

### Prosthetic–Implant Interactions

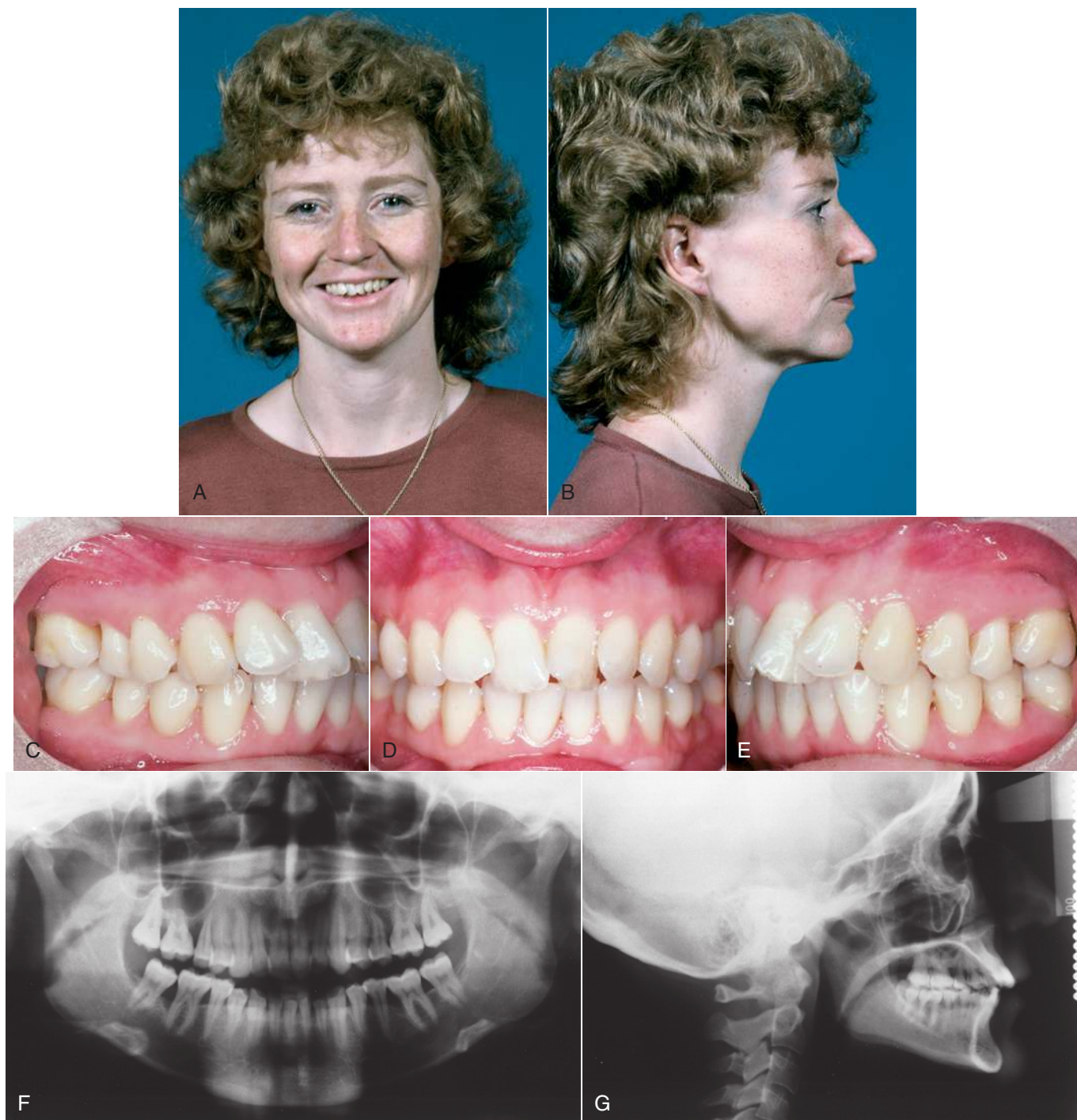Adults seeking comprehensive orthodontic treatment often also have dental problems that require restorations. Such problems include loss of tooth structure from wear and abrasion or trauma, gingival esthetic problems, and missing teeth that require replacement with either conventional prosthetics or implants.

#### Problems Related to Loss of Tooth Structure

The positioning of damaged, worn, or abraded teeth during comprehensive orthodontics must be done with the eventual restorative plan in mind. Early consultation with the restorative dentist obviously becomes important. There are four important considerations in deciding where the orthodontist should position teeth that are to be restored: the total amount of space that should be created, the mesiodistal positioning of the tooth within the space, the buccolingual positioning, and the vertical positioning. It is important to determine in advance whether the orthodontic goal is to level the incisal edges and marginal ridges, the gingival margins and contours, and/or the bone levels.

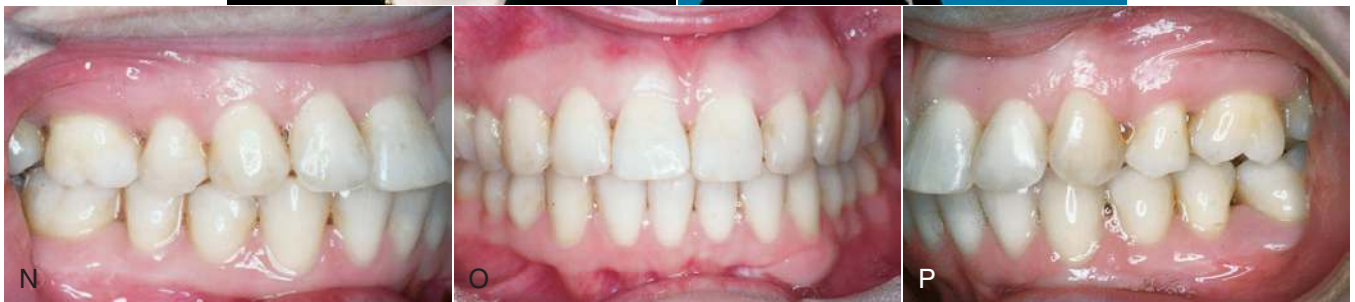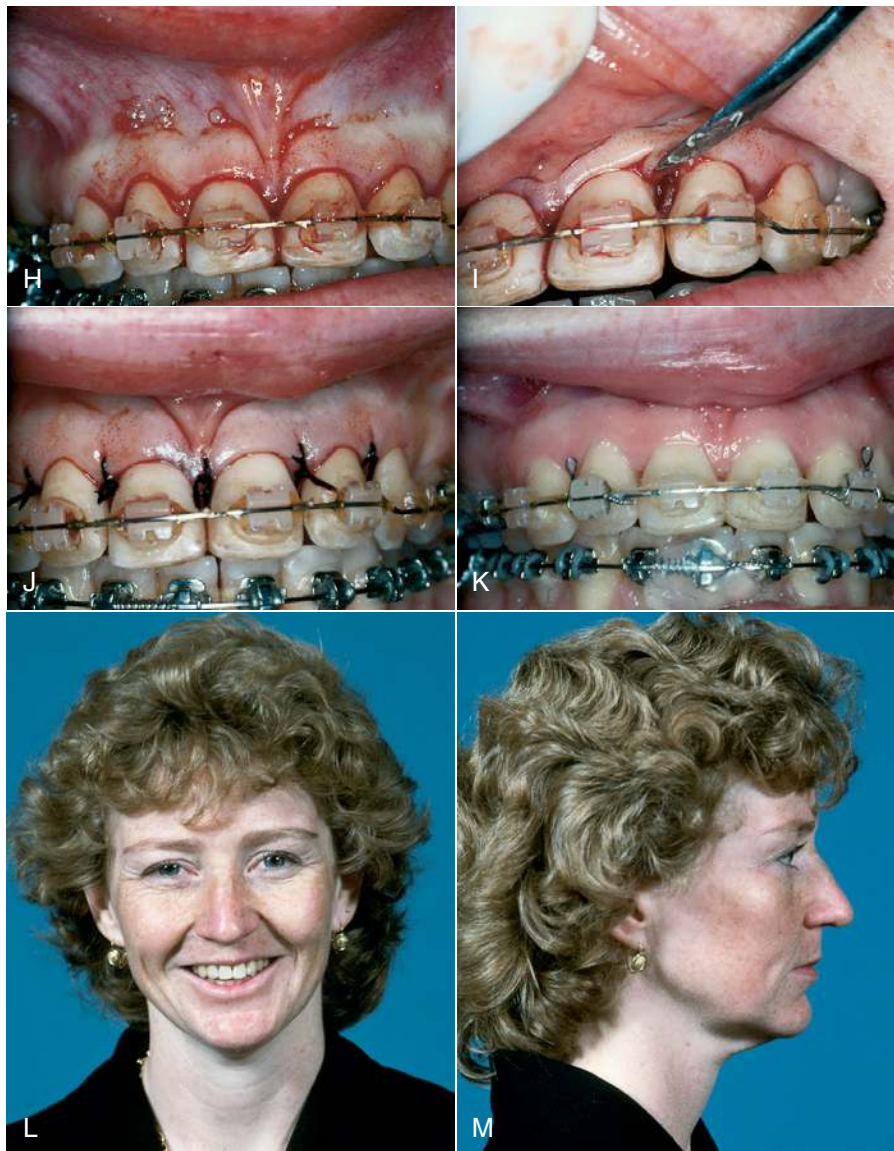When tooth structure has been lost all the way to beyond the normal contact point, the tooth becomes abnormally narrow, and restoration of the lost crown width, as well as height, is important. The orthodontic positioning must provide adequate space for the appropriate addition of the restorative material. The ideal position may or may not be in the center of the space mesiodistally; this would depend on whether the most esthetic restoration would be produced by symmetric addition on each side of the tooth or whether a larger buildup on one side would be better.

Similarly, the ideal buccolingual position of a worn or damaged maxillary tooth would be influenced by how the restoration was planned. If crowns are planned, the tooth should be in the center of the dental arch without tight contact with the opposing arch. But if a facial veneer is to be used for an incisor or canine



• **Fig. 19.33** (A to E) At age 27, this woman sought orthodontic treatment because her periodontist thought that her periodontal disease could be controlled better if the alignment of her teeth were improved, and because she had never liked the appearance of her extremely crowded and irregular maxillary incisors. There was a full-cusp Class II molar relationship and minimal overbite. (F) The panoramic radiograph showed severe bone loss in multiple areas, but active disease was now under control. (G) The cephalometric radiograph showed a mild skeletal Class II jaw relationship, with moderate maxillary incisor protrusion. The treatment plan called for extraction of the maxillary left first premolar and the right second premolar (chosen because of the large periodontal defect distal to it, although this would make the orthodontic treatment more difficult). The extraction space, plus reduction of interproximal enamel to compensate for the tooth-size discrepancy created by the very large maxillary lateral incisors, would allow for alignment of the upper teeth without creating incisor protrusion.

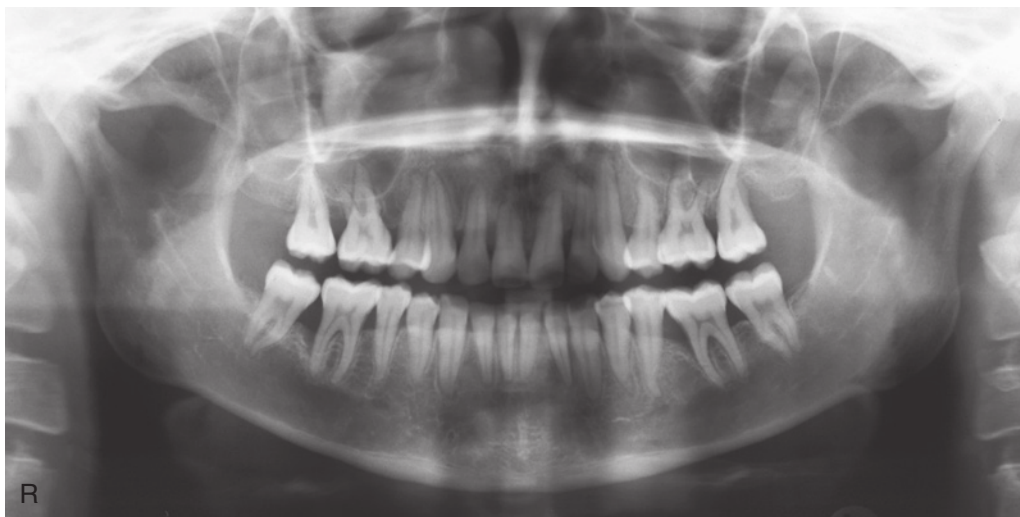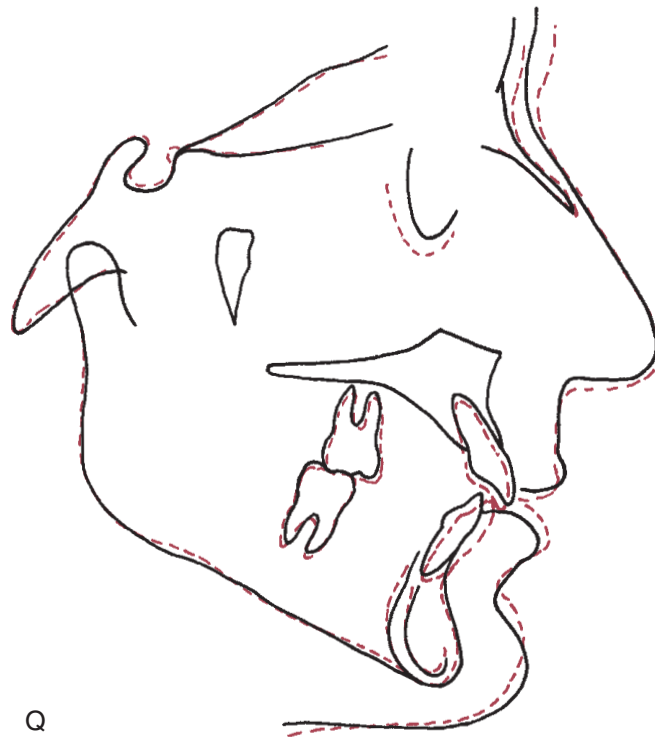




• **Fig. 19.33, cont'd** (H to J) Because of the severe rotations of the irregular maxillary incisors, after alignment was completed but with the orthodontic appliance still in place, repositioning of the maxillary frenum and sectioning of the elastic gingival fibers were carried out. (K) Three weeks later. (L to P) After 18 months of treatment, both the occlusion and the appearance of the teeth were greatly improved.

*Continued*



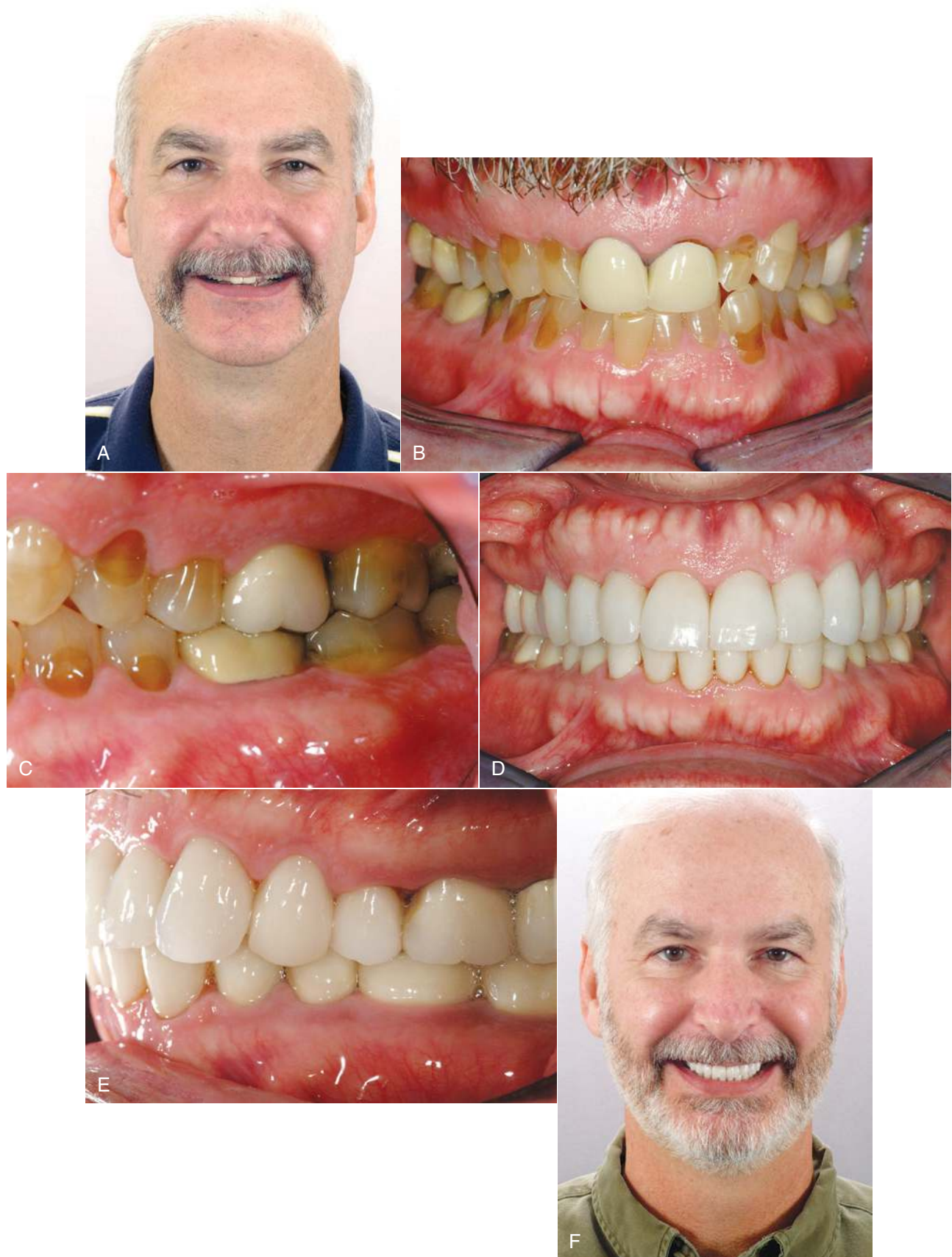

• **Fig. 19.33, cont'd** (Q) Cephalometric superimposition shows slight retraction of the maxillary incisors and mild proclination of the mandibular incisors, as was desired in this case. (R) Panoramic radiograph 1 year after the orthodontic treatment was completed. The periodontal condition remained under good control during and after the orthodontic treatment. Note the fill-in of alveolar bone in the area where the severely affected maxillary right second premolar was extracted. The periodontal defects remain in the lower arch but did not get worse during the extensive orthodontic treatment. (Periodontal surgery by Dr. R. Williams.)

(Fig. 19.34), the orthodontist should place the tooth more lingually than otherwise would be the case, in contact with its antagonist in the lower arch, to accommodate the thickness of the veneer on the facial surface. Finally, better restorations can be done if the orthodontist provides slightly more space than is required, so there is room for the restorative dentist to finish and polish proximal surfaces. The slight excess space can then be closed with a retainer.

If only a small amount of tooth structure has been lost—for instance, if the incisal edge of one incisor has been fractured—it may be possible to smooth the fractured area and elongate the

damaged tooth so that the incisal edges line up. The result, however, will be uneven gingival margins, which means that elongation of a fractured tooth must be done with caution and with consideration of the extent to which the gingival margins are exposed when the patient smiles. Before acceptably esthetic composite resin buildups of anterior teeth were available, orthodontic elongation of fractured teeth was a more acceptable treatment approach than it is at present. Now, more than 1 to 2 mm of elongation rarely is a good plan unless the patient never exposes the gingiva.



• **Fig. 19.34** (A) This 49-year-old man sought treatment to improve the appearance of his teeth, which were badly worn and stained. He was careful to minimize the display of his incisors on smile. (B) Crowns had been placed on the maxillary central incisors, but they were too short for their width. (C) The other teeth in both arches were badly worn and stained. The treatment plan was to align the teeth, opening some space to facilitate buildups and laminates. (D to F) Age 51, after treatment, with crowns and laminates for correction of the wear and staining that were placed after the end of active orthodontic treatment. The posttreatment smile, with as much display of lower as upper teeth, is appropriate for his age, although slightly longer veneers for the upper incisors would have been better. The patient chose to have the crowns and laminates made whiter than was consistent with his age, and obviously valued the contrast with his previous condition.

### Gingival Esthetic Problems

Gingival esthetic problems fall into two categories: those created by excessive and/or uneven display of gingiva and those created by gingival recession after periodontal bone loss.

The importance of maintaining a reasonably even gingival margin in the maxillary incisor area, especially when patients show the gingiva when they smile, is a factor in deciding on the best treatment when one lateral incisor is missing. Substituting a canine on one side will result in uneven gingival margins unless great care is taken to extrude the canine and reduce its crown height, even if the crown of the substituted canine is recontoured. If several teeth have been worn or fractured, extruding them can create an unesthetic “gummy smile” even if the gingival margins are kept at the same level across all the teeth. In that circumstance, it would be better to intrude the incisors to obtain a proper gingival exposure and then restore the lost crown height.

Dental esthetics is not just the teeth. A particularly distressing problem is created by gingival recession after periodontal bone loss in the maxillary incisor region, which creates “black triangles” between these teeth (see Fig. 6.32). The best approach to this problem is to remove some interproximal enamel so that the incisors can be brought closer together. This moves the contact points more gingivally, minimizing the open space between the teeth. The more bulbous the crowns were initially, the more successful this approach can be.

### Missing Teeth: Space Closure Versus Prosthetic Replacement

**Old Extraction Sites.** In adults, closing an old extraction site is likely to be difficult. The problem arises because of resorption and remodeling of alveolar bone. After several years, resorption results in a decrease in the vertical height of the bone, but more important, remodeling produces a buccolingual narrowing of the alveolar process as well. When this has happened, closing the extraction space requires a reshaping of the cortical bone that comprises the buccal and lingual plates of the alveolar process. Cortical bone will respond to orthodontic force in most instances, but the response is significantly slower.

Closing an old mandibular first molar extraction site is very difficult, because mesial drift of the second and third molars and distal drift of premolars have partially closed it, and the molars have tipped mesially. In adjunctive treatment, as shown earlier (see Figs. 19.6 and 19.7), a mesially tipped second molar usually is uprighted by tipping it distally, and then an implant or bridge is placed. If comprehensive treatment is planned, should the space be closed by bringing the first molar mesially? This depends very much on the specific problems of an individual patient. Often, it is better judgment to open a partially closed old extraction site and replace the missing tooth. This decision should be considered carefully in consultation between the orthodontist and prosthodontist.

Panoramic radiographs of two patients with similar spacing in the lower arch after early loss of mandibular first molars—one who had distal tipping for bilateral uprighting of second and third molars, and the other who had bilateral space closure with mesial root movement—are shown in Figs. 19.35 and 19.36. Both had comprehensive treatment with use of alveolar bone screws as anchorage. For the patient with space opening, the factor that determined treatment time was other aspects of the malocclusion; for the one with space closure, the long treatment time was primarily determined by the slow remodeling of cortical bone in the old extraction site.

**Tooth Loss Due to Periodontal Disease.** A space closure problem is also posed by the loss of a tooth to periodontal disease. Sometimes, closure of the space where a hopelessly involved tooth was extracted results in an improvement of the periodontal situation (see Fig. 19.33). Unless at least one bony wall remains, however, it is better to move teeth away from such an area in preparation for a prosthetic replacement, because normal bone formation cannot be expected as the tooth moves into the defect.

However, there is an exception. First molars and incisors are lost in some adolescents and young adults to aggressive juvenile periodontitis, which differentially attacks these teeth and is characterized by high levels of a specific microbe, *Aggregatibacter actinomycetemcomitans*. This problem is rare, but it is estimated to occur up to three times more frequently in African-American children, and in a sequence of cases detected in one county in Florida, all 60 children were black.<sup>18</sup> In the etiology of the disease, both immune and inflammatory responses to the bacteria in the gingival sulcus are important, and it appears that some bacteria may play a protective role. Once the disease process has been brought under control, which now typically involves antibiotic therapy, the causative agent largely disappears and the disease rarely recurs. Although bone around the first molars often is completely destroyed, neither the second molar nor the second premolar is significantly affected in most patients.

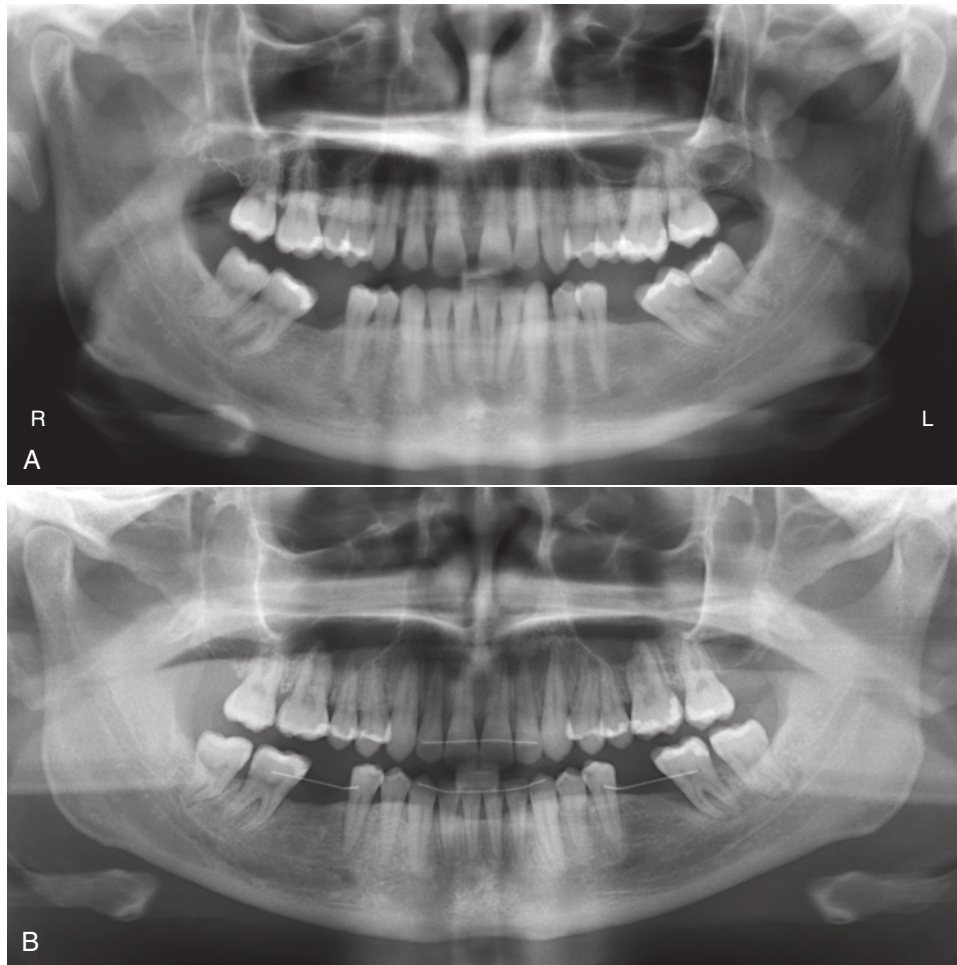
Orthodontic closure of the incisor spaces is rarely feasible because of loss of bone created by the disease, but in adolescent or young adult patients who lost first molars to aggressive local periodontitis, it often is possible to orthodontically close the extraction sites, bringing the second permanent molar forward into the area where the first molar was lost. Usually this does not require bone screws or implants for additional anchorage. The second molar brings its own investing bone with it, and the large bony defect disappears.

This favorable response is attributed to some combination of three factors: the relatively young patients, the fact that the original attack was almost entirely on the first molars, and the change in the bacterial flora. In an older patient who lost a first molar to periodontal disease, it is unlikely that the other teeth have been totally spared or that the bacterial flora have changed, and it would not be good judgment to attempt to close the space.

**Comprehensive Orthodontics in Patients in Whom Implants Are Planned.** In older patients with long-standing tooth loss, bone grafts often are necessary to widen the alveolar process where a future implant will be required. Usually it is advantageous to go ahead with placement of grafts in areas that will receive implants while orthodontic treatment is being carried out in other areas of the mouth. The goal should be to have the patient ready for definitive prosthodontic treatment as soon as possible after the orthodontic appliances are removed, rather than having a considerable delay while both grafts and implants are done.

After the grafts have matured to the point that implants can be inserted, it also may be possible to do the implant operation before all orthodontic treatment is finished. The implant surgical procedure itself rarely causes significant delay, and an osseointegration period during the orthodontic treatment is advantageous. A long delay caused by graft healing and maturation before implants can become a problem in orthodontic retention. Almost always, a fixed orthodontic retainer is the best choice to maintain a space for an implant. In the anterior area, patients often prefer a temporary resin-bonded bridge (Fig. 19.37), which must be removed for the implant operation and reinserted afterward unless immediate loading of the implant is feasible.



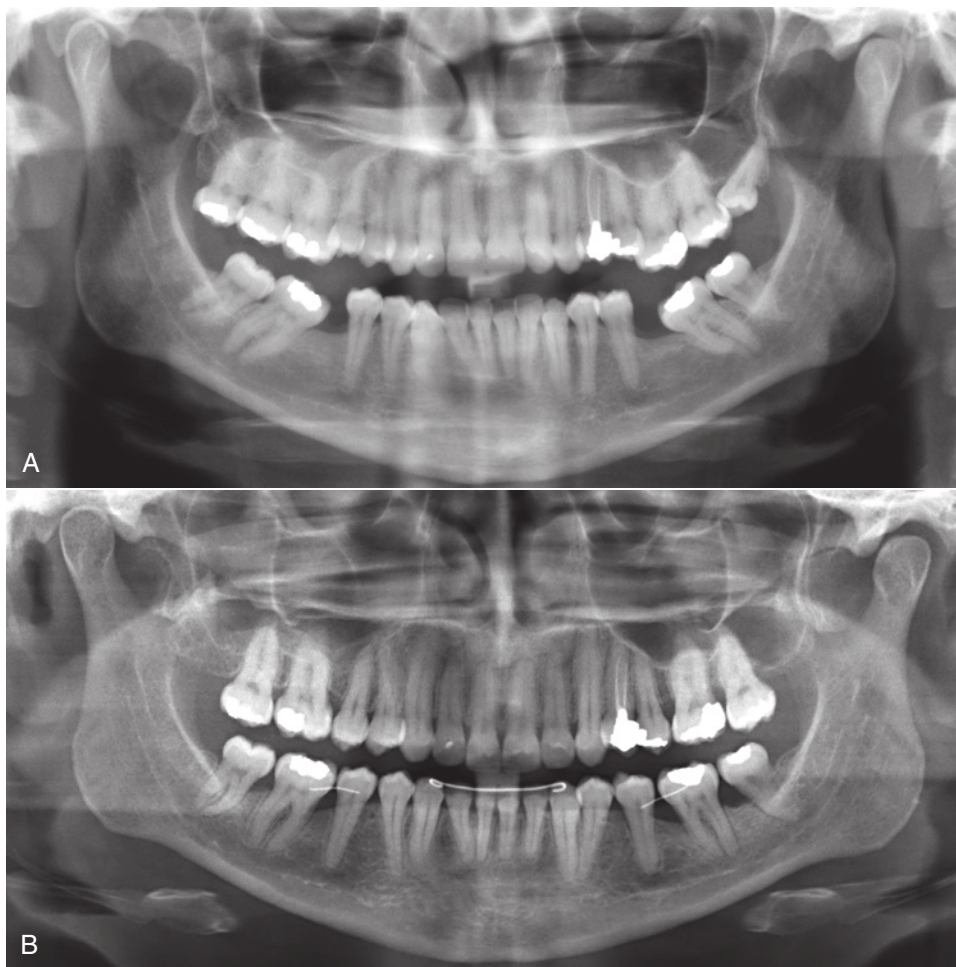


• **Fig. 19.35** (A) Panoramic radiograph of a 32-year-old patient who lost mandibular first molars years ago and now desired treatment to correct her malocclusion. She chose comprehensive fixed appliance treatment, including uprighting of both the second and third molars, opening space for replacement of the missing first molars with either implants or fixed bridges. Treatment time was 30 months. It would have taken about 6 months to upright only the first molars, but uprighting two molars on each side requires much more time, and it is difficult to maintain the occlusal relationships without a maxillary appliance. (B) Posttreatment radiograph. Uprighting the second molar does not create new bone but does tend to improve the periodontal condition; in this patient the persisting one-wall pocket on the mesial of the left second molar is much more treatable than it would have been without the uprighting. Note that fixed retainers are being used to maintain both incisor alignment and the position of the molars until restorations can be placed.

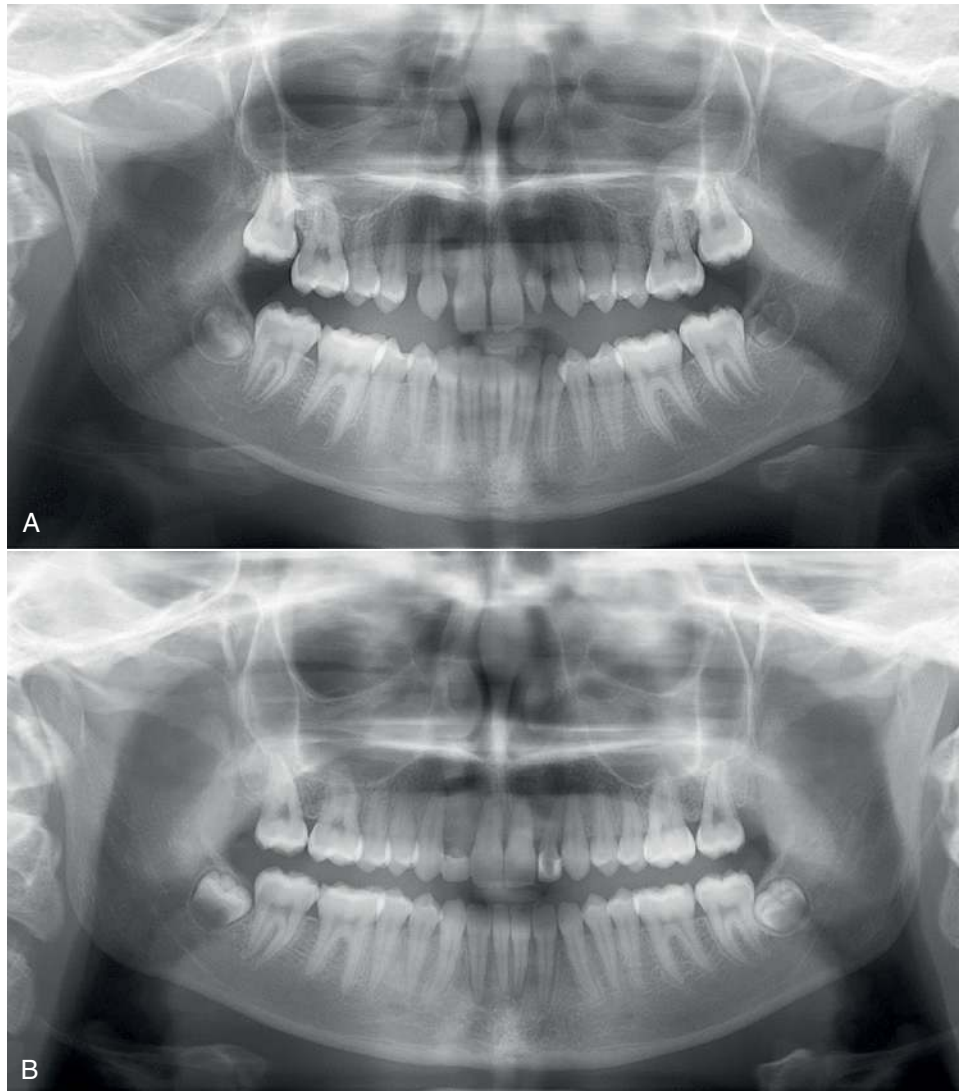
A damaged and ankylosed maxillary incisor or canine in a teenager poses a special problem when eventual replacement with an implant is planned. The ankylosed tooth interferes with orthodontic treatment to align the other teeth and can become quite unsightly, but alveolar atrophy will occur if the tooth is extracted before vertical growth is completed and the implant can be placed. In this situation, the alveolar bone can be “banked” by removing the crown of the offending tooth but retaining the endodontically treated root (Fig. 19.38), or simply decoronating the tooth without endodontic treatment. Either way, there is a better chance of successful implant placement later without a bone graft. Meanwhile, the orthodontic treatment can be completed

with a pontic tied to an archwire, and then a more substantial resin-bonded bridge is worn until vertical growth is completed and it is safe to place the implant.

However successful the treatment is up to that point, placing an implant too soon creates a major problem. The implant becomes the equivalent of an ankylosed tooth and will appear to intrude as vertical development continues and the other teeth erupt (Fig. 19.39). This creates a discrepancy of the gingival margins as well as the incisal edges, which is very difficult to manage even if the implant is removed and replaced with a new crown. With adult patients, this problem can occur later in life because slow vertical growth often continues into middle age.

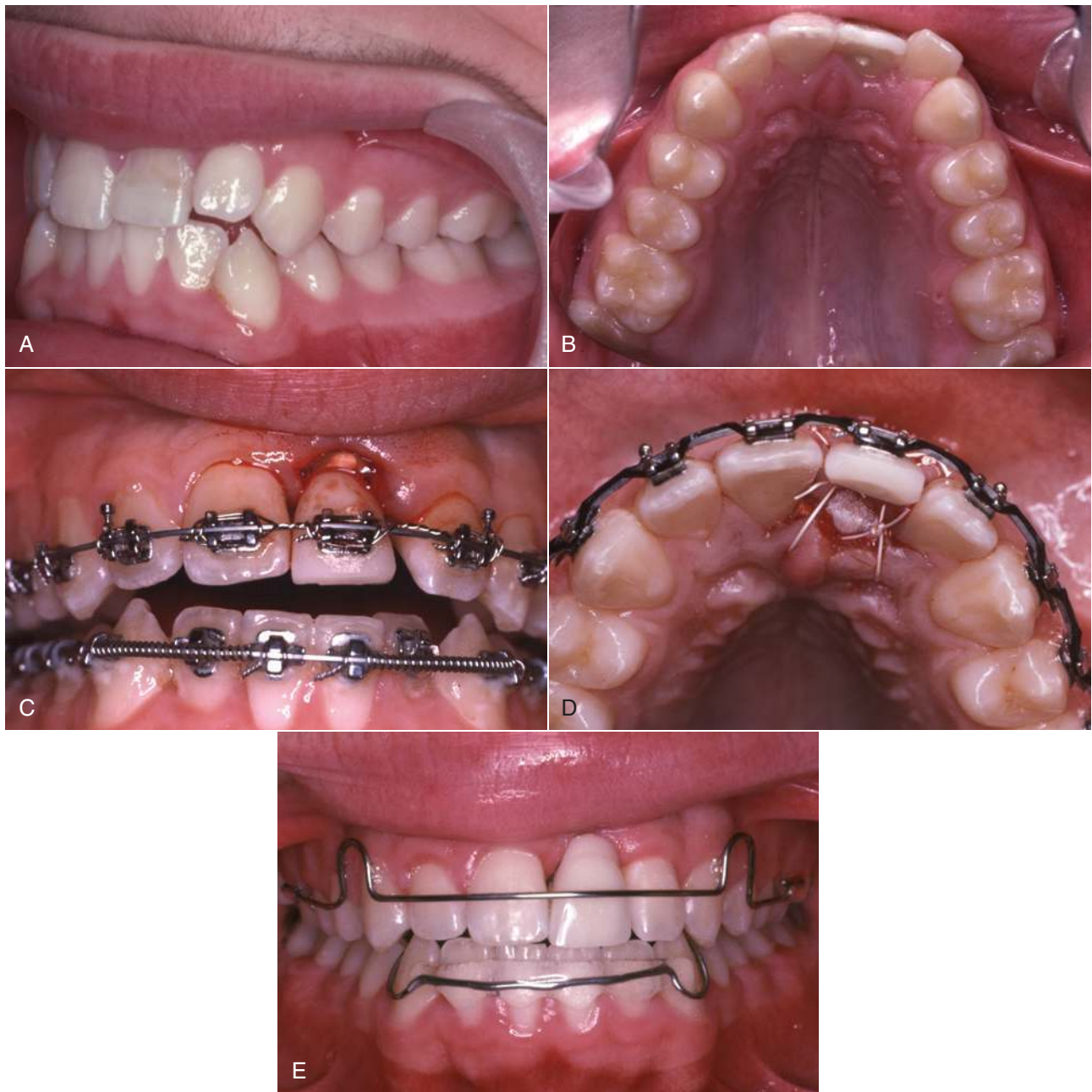


• **Fig. 19.36** (A) Panoramic radiograph of a 39-year-old patient who also lost mandibular first molars years ago. Comprehensive orthodontics was planned to align the anterior teeth in both arches, correct the supereruption of the maxillary first molars, and close the old extraction spaces. (B) After completion of treatment, which required 36 months primarily because tooth movement into old extraction spaces like this requires remodeling of cortical bone. Note that the periodontal situation on the mesial of the second molars remains less than ideal and that fixed retainers are being used to maintain closure of the extraction spaces, as well as incisor alignment.



• **Fig. 19.37** For this girl, whose treatment is shown in [Figs. 15.9](#) and [15.10](#), a bonded bridge to maintain space for an implant to replace the missing right lateral incisor was an important part of the treatment plan. (A) The panoramic radiograph just after the canine erupted shows it on the mesial side of the space, but moving it distally would help to correct the dental midline. (B) The post-treatment pan shows the buildups on the left lateral incisor and the bridge between the right canine and central incisor. Note that to obtain optimum esthetics, the crown of the lateral incisor has been oriented properly even though the dilacerated root then is tipped distally, which is appropriate in this situation. You also can see that there is adequate space for the implant. Perhaps the most important advantage of a bonded bridge is that it controls the position of the tooth roots during further eruption in late adolescence, in a way that a removable retainer with a pontic cannot. (Courtesy Dr. T. Shaughnessy.)





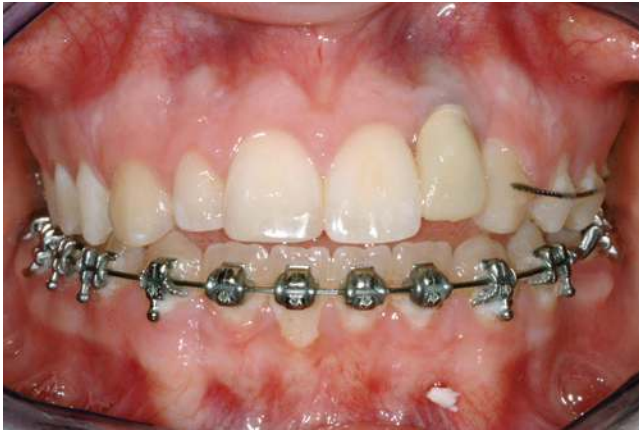• **Fig. 19.38** This 14-year-old boy had a lingually displaced and ankylosed maxillary central incisor after a basketball injury. (A and B) Before treatment. It was not possible to correct the alignment of other teeth without removing the ankylosed tooth, which eventually would be replaced with an implant, but loss of alveolar bone in the area would result from early extraction. (C) The decision was to remove only the crown of the ankylosed tooth, retaining the root as a way of maintaining the alveolar bone. With an orthodontic appliance in place, a pontic was tied to the archwire when the crown was removed. The root was filled with calcium hydroxide, and gingival and palatal tissue (D) was sutured over it. (E) It then was possible to expand both arches and correct the malocclusion. At the end of active treatment, a pontic was placed on the orthodontic retainer as a temporary replacement. An implant was placed successfully at age 18.

## Complex Treatment Procedures

### Lingual Orthodontics

Progress in lingual orthodontics in the last few years has culminated in the development of techniques that overcome most of the previous difficulty in using this technology. The most advanced current

lingual technique uses a custom-formed pad for each tooth to provide more secure bonding of the appliance, a low-profile bracket printed in a new proprietary alloy with bracket slots that are much more precise than those with edgewise brackets and made so that wires can be inserted from above, and computer-controlled wire-bending robots to generate the archwires. These changes in the

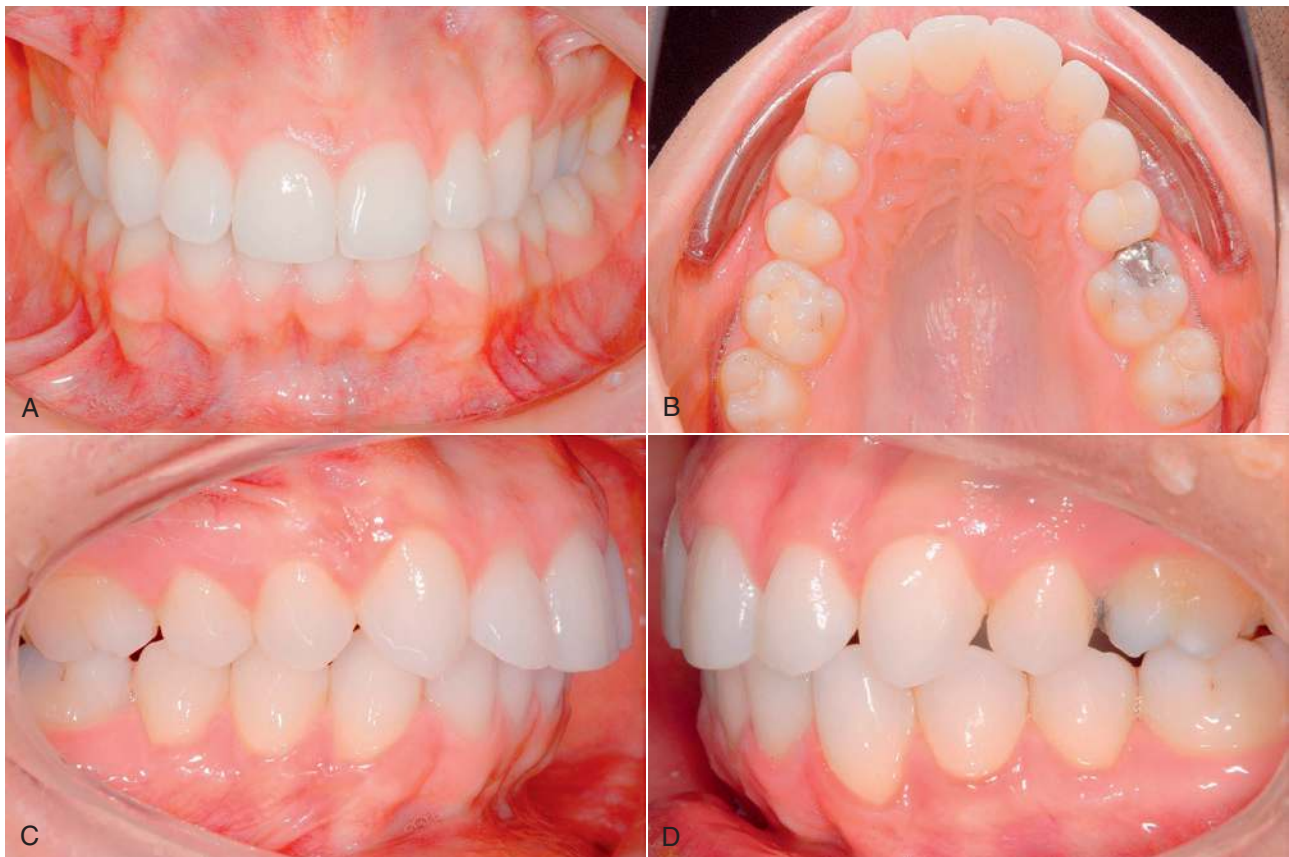

• **Fig. 19.39** For this patient, an implant to replace a missing maxillary lateral incisor was placed at age 15. At age 17, further vertical growth had led to unesthetic relative intrusion of the implant, with displacement of both the incisal edge and gingival margin. At this point, a longer crown on the implant is not a satisfactory solution. There is no good alternative to removing the implant, grafting the area, and placing a new implant.

appliance are described in [Chapter 10](#) (see [Fig. 10.42](#)) and are further illustrated here.

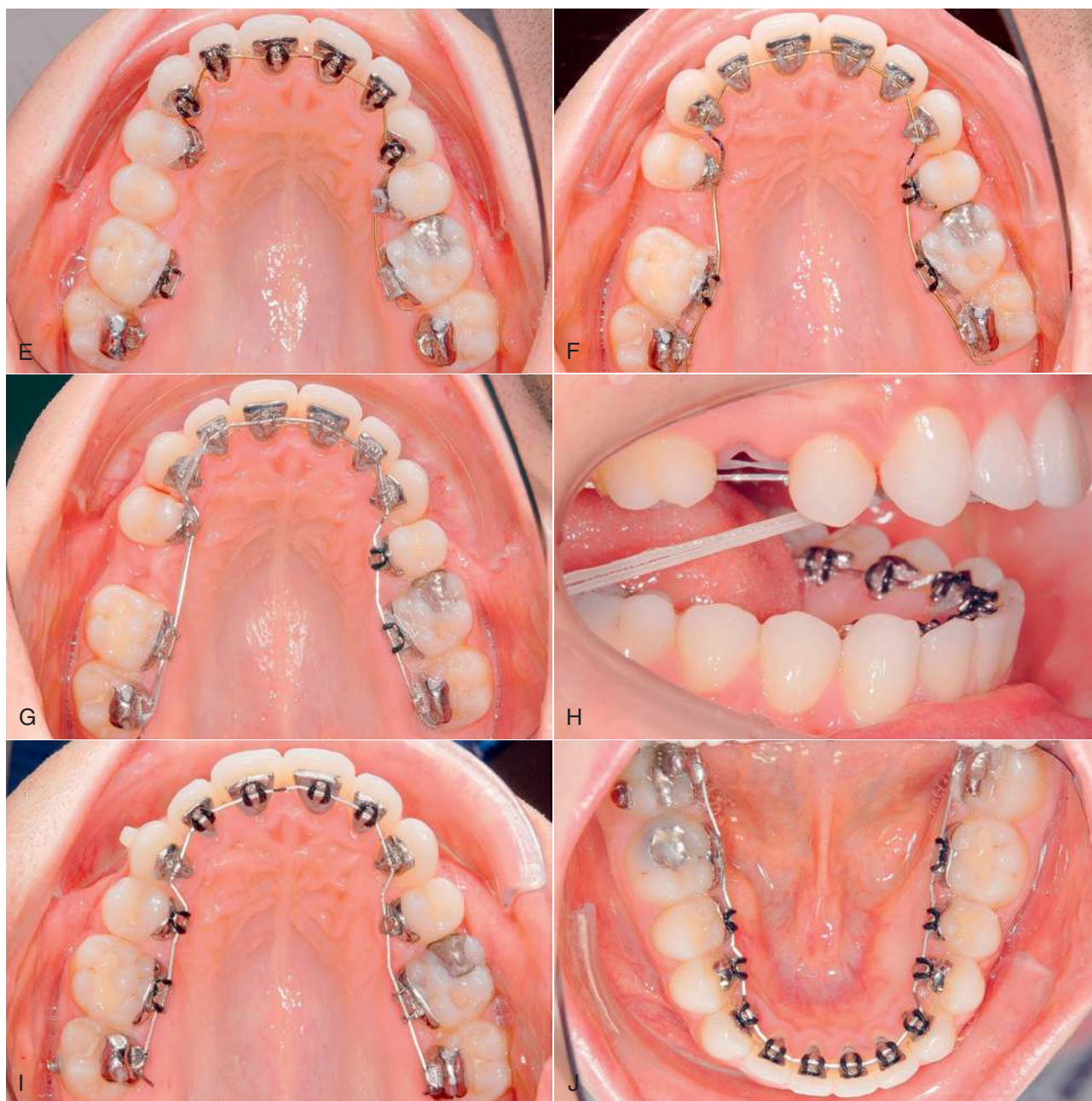
In lingual orthodontics, the wire-bending robots are an important part of the system. They provide compensation for an unavoidable problem, the short distances between the teeth on the lingual aspect. For any wire, the shorter the span, the stiffer the material. The distances between the teeth along the archwire are so short that even with narrow brackets, it can be hard to align severely crowded lower incisors without reshaping the archwires, including the A-NiTi wire for initial alignment. Remotely forming the wires with a wire-bending robot makes this a much more precise and less time-consuming procedure. One way to look at it is that although modern lingual orthodontic treatment is quite different from clear aligner therapy, it is based on computer technology to a similar extent.

With lingually bonded brackets and archwires, any type of tooth movement now can be produced quite efficiently, including root positioning at extraction sites and root torque. Steps in the lingual appliance treatment of a patient with a complex malocclusion are shown in [Figs. 19.40](#) and [19.41](#).



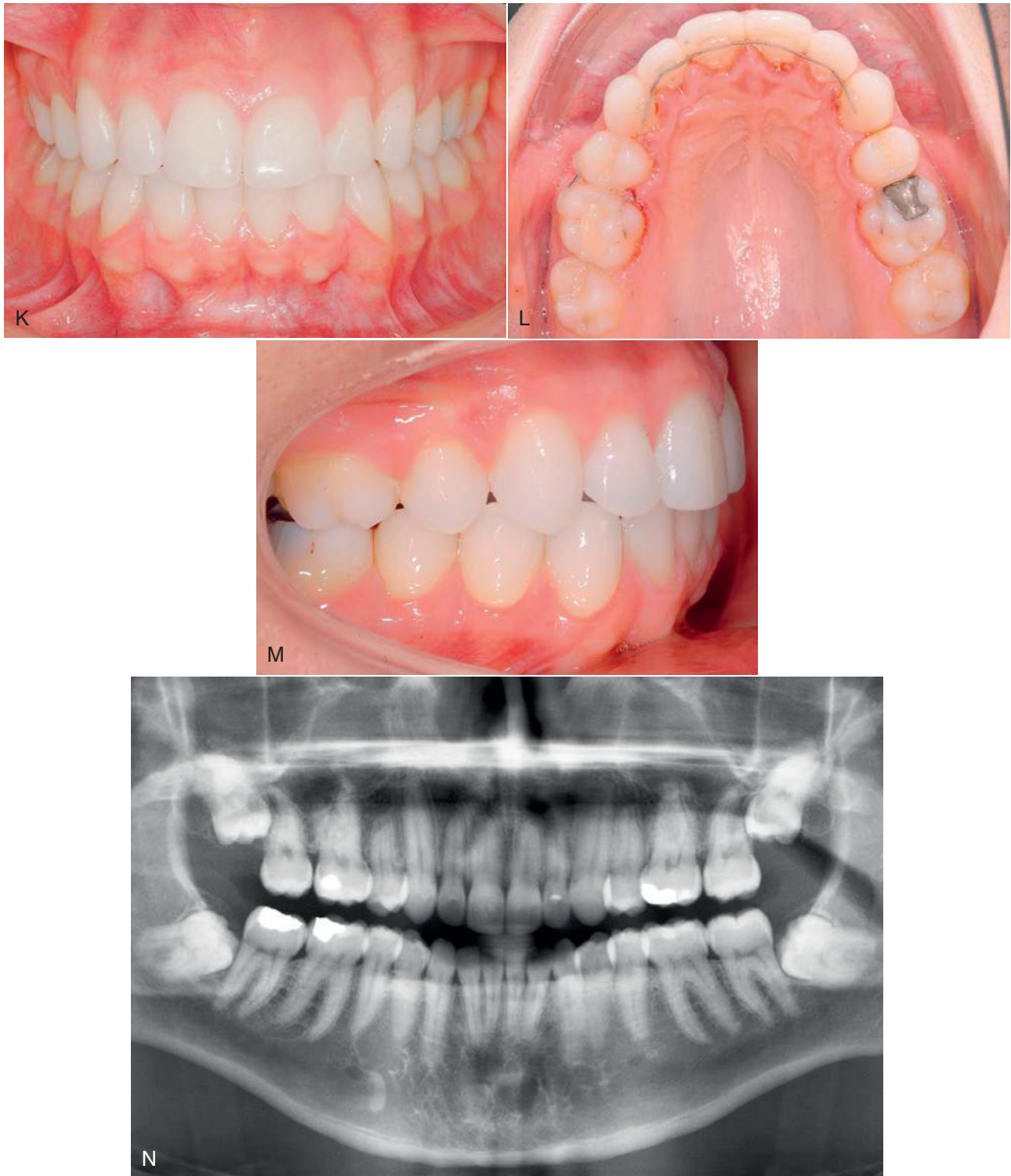• **Fig. 19.40** The modern lingual appliance offers more precise archwire sizes and slots than current labial appliances, along with computer-formed archwires that allow better accomplishment of the planned occlusion—but the plan must be adjusted by the orthodontist to achieve placement of the dentition in the face. (A to D) Initial records for a patient with a midline discrepancy because of a missing maxillary left second premolar. The plan was to extract the other maxillary second premolar and close the space by bringing the maxillary arch around toward the midline. *Continued*



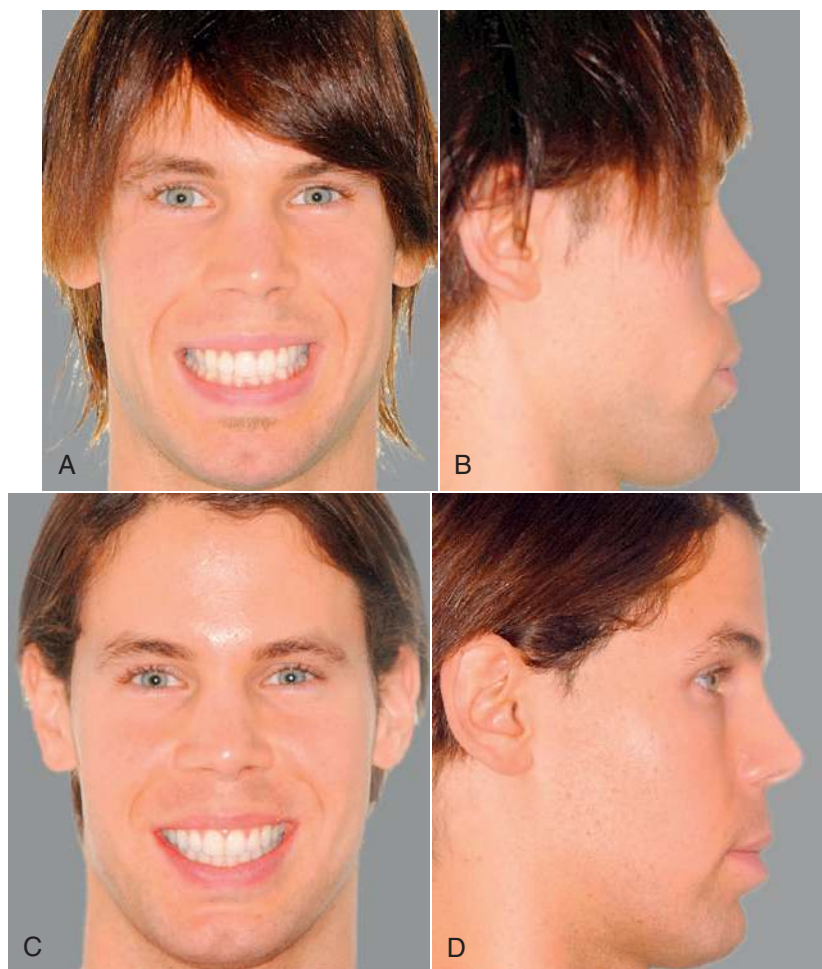


• **Fig. 19.40, cont'd** (E and F) The lingual brackets were indirectly bonded before the premolar extraction, and a light nickel–titanium (NiTi) archwire was used for initial alignment. (G and H) Then the extraction space was closed by sliding on an undersized rectangular archwire, using a unilateral Class II elastic to swing the maxillary anterior teeth toward the midline. (I and J) Coordinated archwires toward the end of space closure. Note that a facial attachment for the Class II elastic was used after initial attachment of the elastic on the lingual aspect.





• **Fig. 19.40, cont'd** (K to M) The completed correction of the malocclusion, and (N) the panoramic radiograph at the completion of treatment, before extraction of the impacted third molars. (Courtesy Dr. D. Wiechmann.)



• **Fig. 19.41** For the patient in Fig. 19.40, facial images before (A and B) and after (C and D) treatment. Note the amount of correction of the maxillary dental midline to the skeletal midline. (Courtesy Dr. D. Wiechmann.)

An important question is the extent to which the treatment plan, represented by the set-up of teeth from which the shape of archwires is derived, is achieved in the posttreatment alignment and occlusion of the teeth. For the Incognito lingual technique, this information was achieved by digital superimposition of the treatment outcome on the set-up.<sup>19</sup> The data show (see Fig. 10.41) that there was a precise reproduction of the treatment goal in the tooth positions that were achieved, except that second molars were not positioned quite as accurately. Information of this type is not yet available for any of the other types of computer-oriented treatment methods. It has the potential to improve accuracy for all computer-aided design/computer-aided manufacturing (CAD/CAM) methods that now are being introduced into orthodontics and was used to improve the performance of the WIN system that followed Incognito.

### Clear Aligner Therapy in Complex Cases

Treating complex cases with Invisalign or its clear aligner competitors is deceptively similar to treatment of less severe problems. Treatment still involves the use of a sequence of aligners that lead to a predicted endpoint, but there are three big differences: (1) the sequence of steps typically used by the computer system technicians typically needs to be modified, (2) the direction and amount of movement

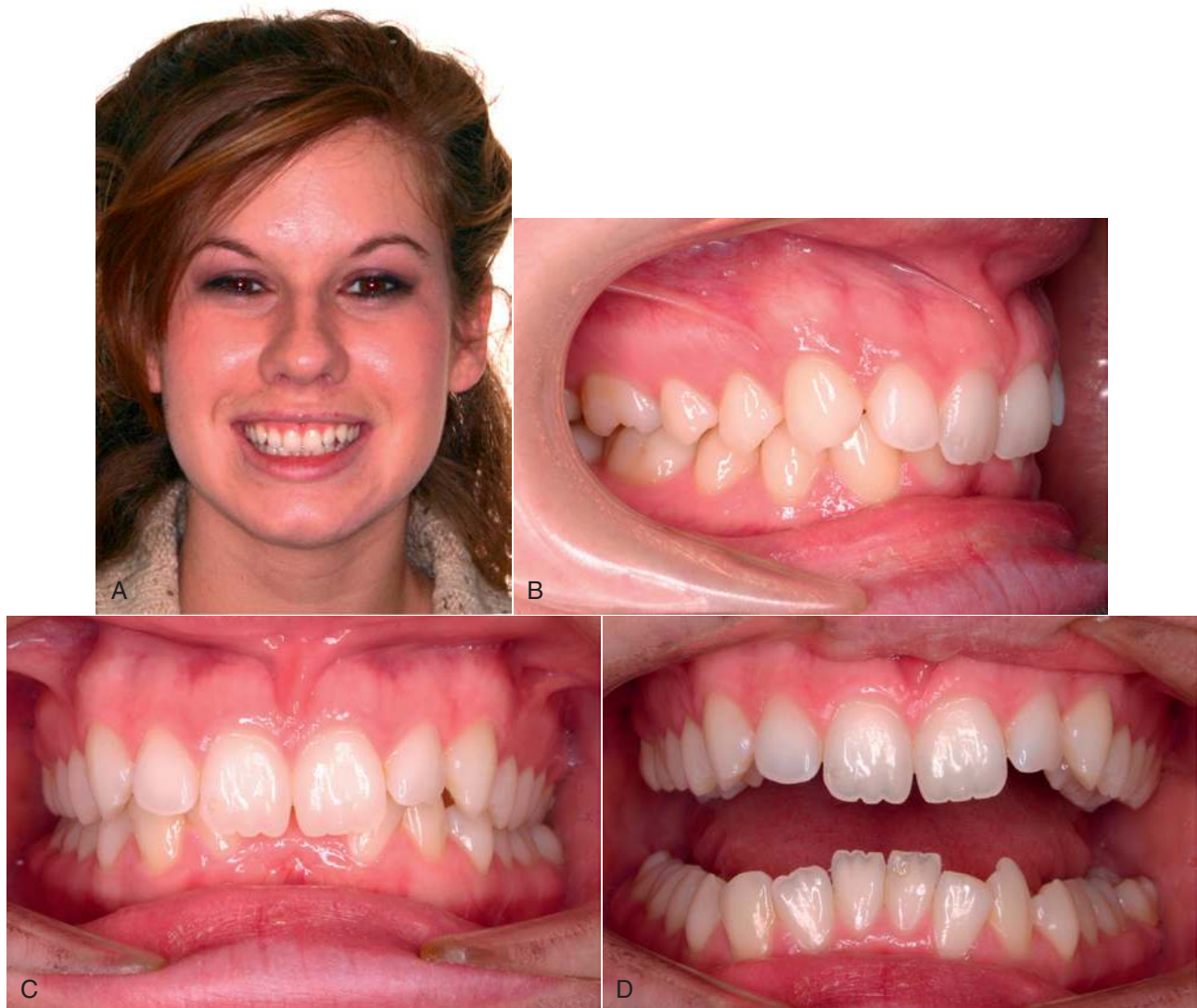
of teeth produced by the standard algorithms often are reduced, and (3) new records and a new set of revision aligners often are needed during the treatment process.

What that means is a much greater involvement of the doctor during the planning and clinical management of these cases. Skilled orthodontists managing difficult cases with Invisalign often prepare the steps from the initial to the final aligner themselves, without starting with a ClinCheck prepared by the company's technicians. If a ClinCheck from the technicians was received, it would be significantly modified, often with smaller changes from one aligner to the next and/or a different sequence of steps in repositioning teeth. It takes both time and skill to do that.

Why would a new set of records and revision aligners often be needed? Experience has shown that as the amount of movement and treatment steps increase, it is better to set an initial goal that is an intermediate to the final goal and then establish the sequence of aligners starting from there to complete the treatment. The golf analogy: a chip and a shorter putt is likely to produce a better result than a really long putt.

Given that degree of planning and management on the part of the doctor, complex cases can be managed with clear aligners, and this is illustrated in the cases shown in Figs. 19.42 and 19.43.

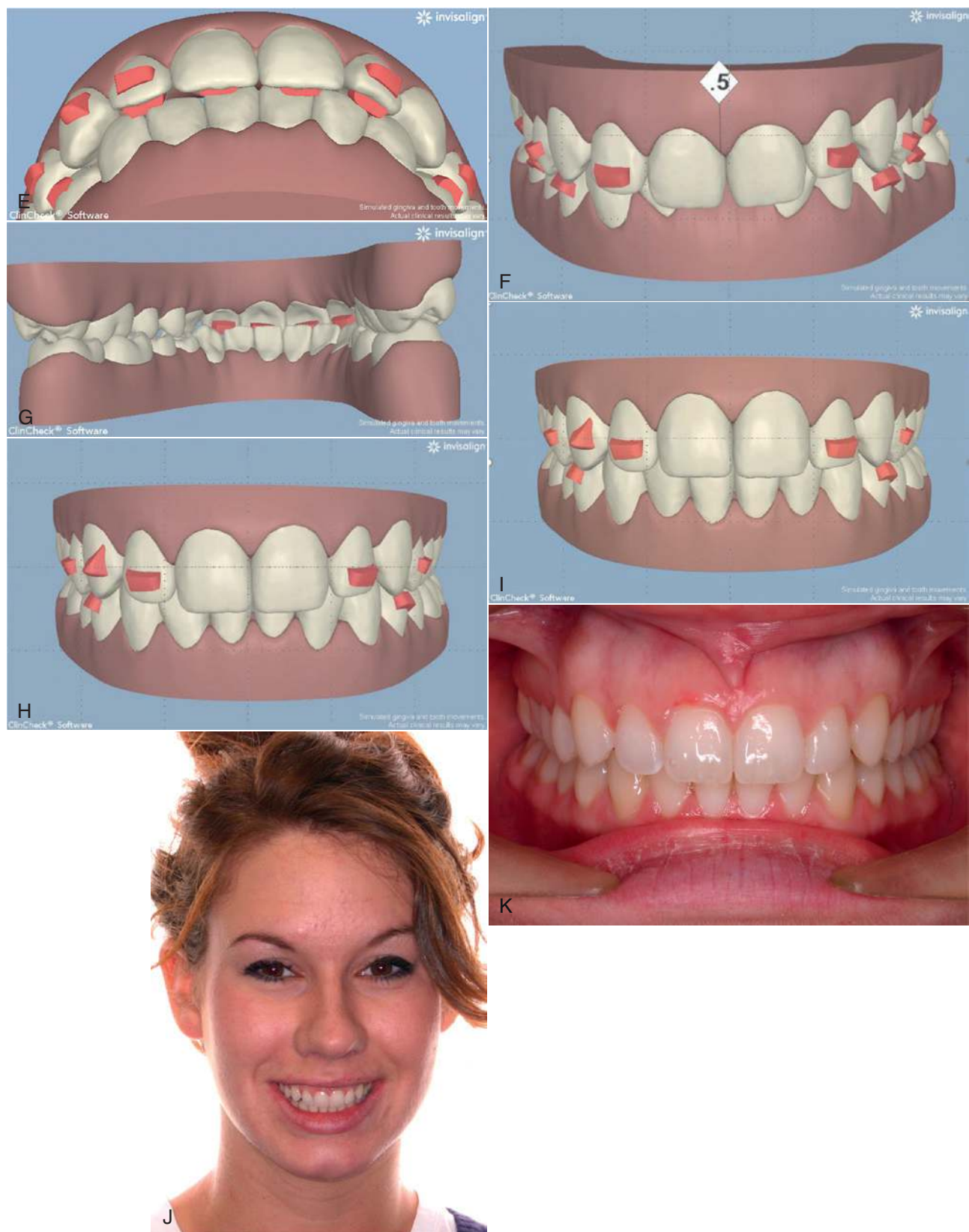
*Text continued on p. 644*



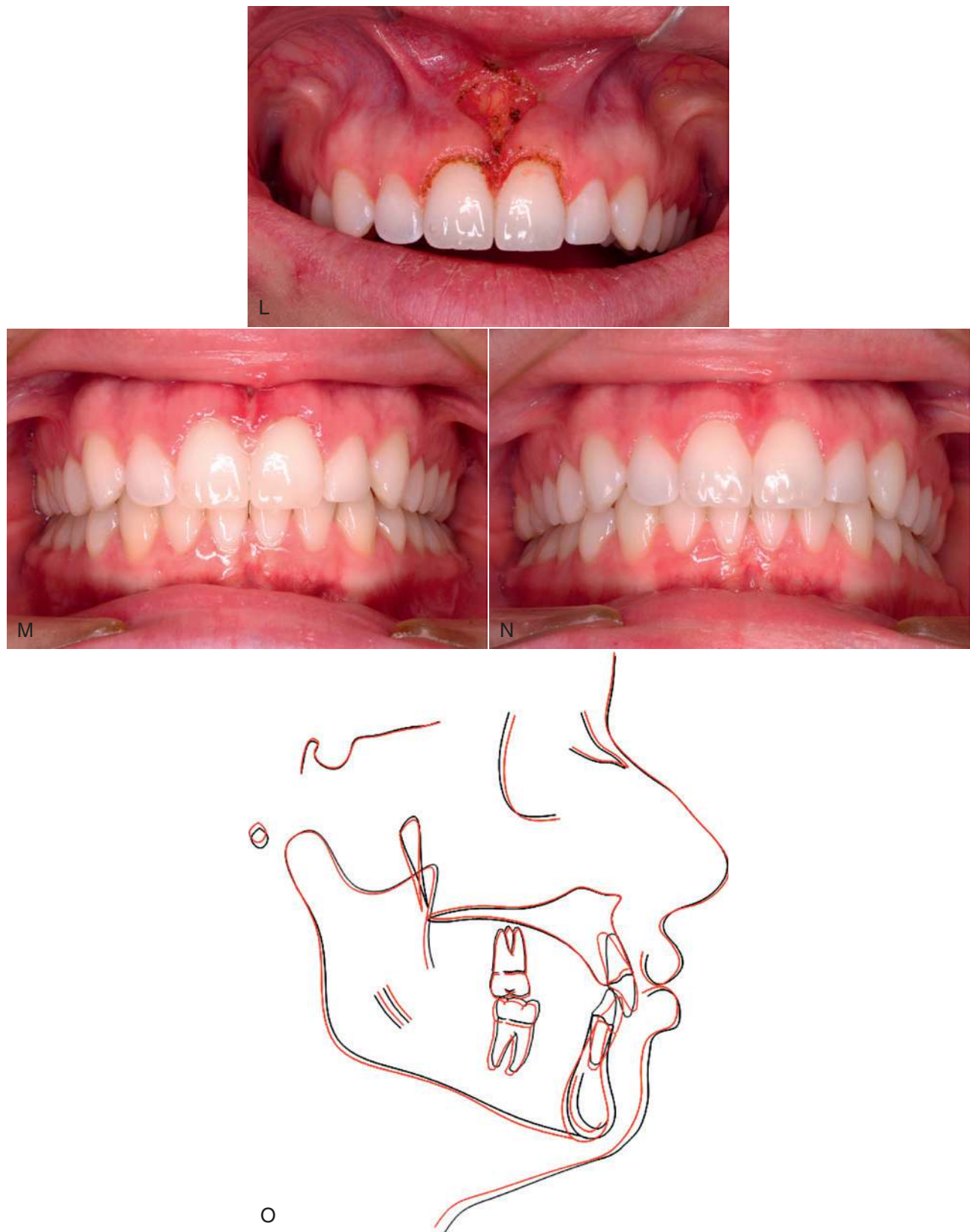
• **Fig. 19.42** Because Invisalign aligners provide light force, intrusion of teeth with aligners is quite possible. In a patient with a deep bite as shown here, an important question is the amount of intrusion of incisors versus extrusion of posterior teeth and increase in anterior face height. Bite ramps on the lingual aspect of maxillary incisors open the bite posteriorly and facilitate molar eruption; thickening of the aligner material over the posterior teeth would inhibit eruption. (A to D) Initial records for a young adult for whom intrusion of maxillary and mandibular central incisors was desired, along with a moderate increase in anterior face height. The plan was an initial stage of treatment with 23 aligners to an intermediate goal with forward movement and intrusion of the maxillary central incisors, followed by forward movement, alignment, and intrusion of the mandibular incisors, then new records and revision aligners to complete treatment.

*Continued*

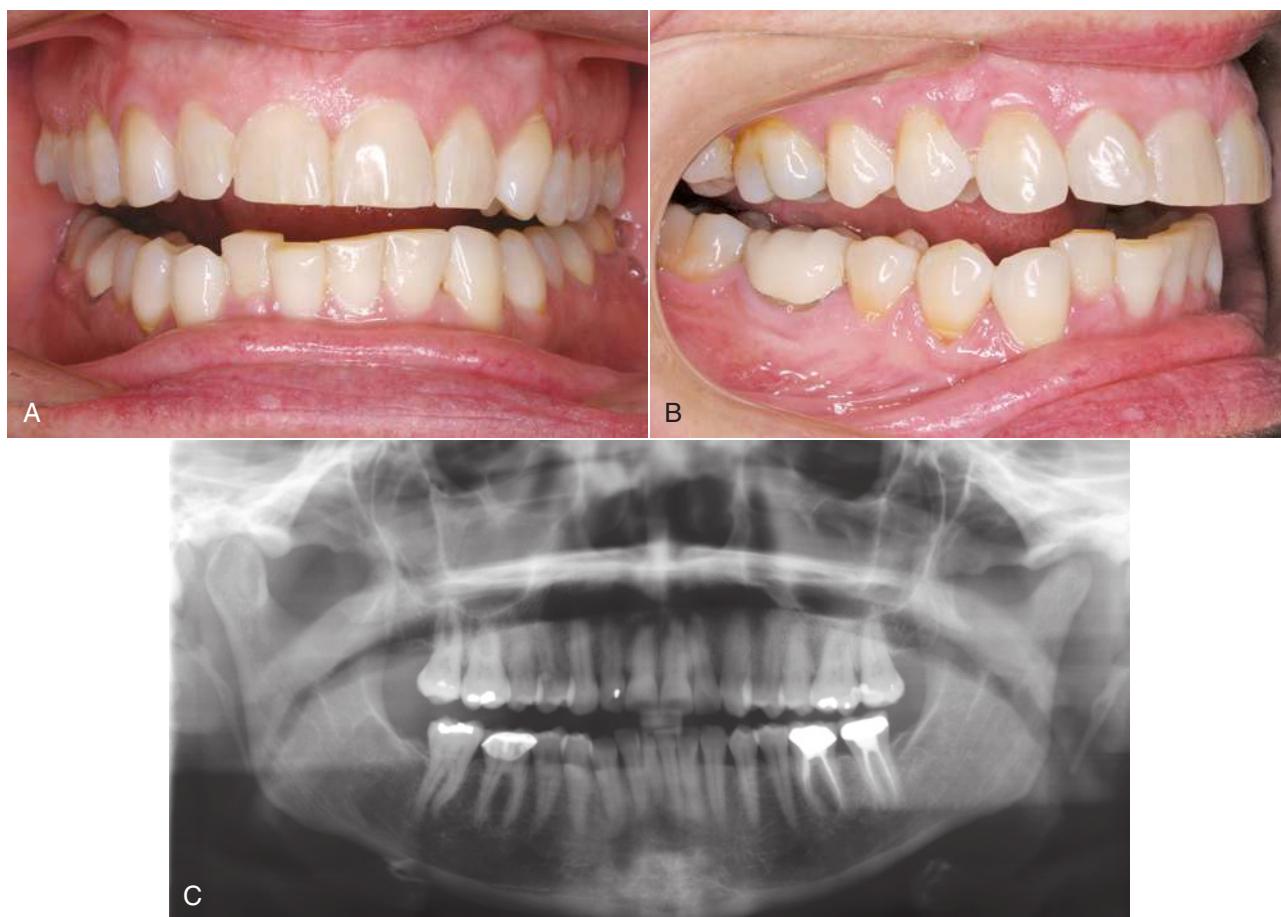



• **Fig. 19.42, cont'd** (E and F) ClinCheck stage 0, showing the bite ramps behind the upper incisors and attachments on the maxillary lateral incisors and canines to resist extrusion while the central incisors were intruded. Note the planned initial reshaping of the maxillary central incisors, repositioning their contact point downward. (G and H) ClinCheck stage 23, showing the expected overbite and alignment at that intermediate point, and (I) ClinCheck revision stage 10, at completion of treatment. (J and K) Smile and close-up of occlusion at end of treatment.

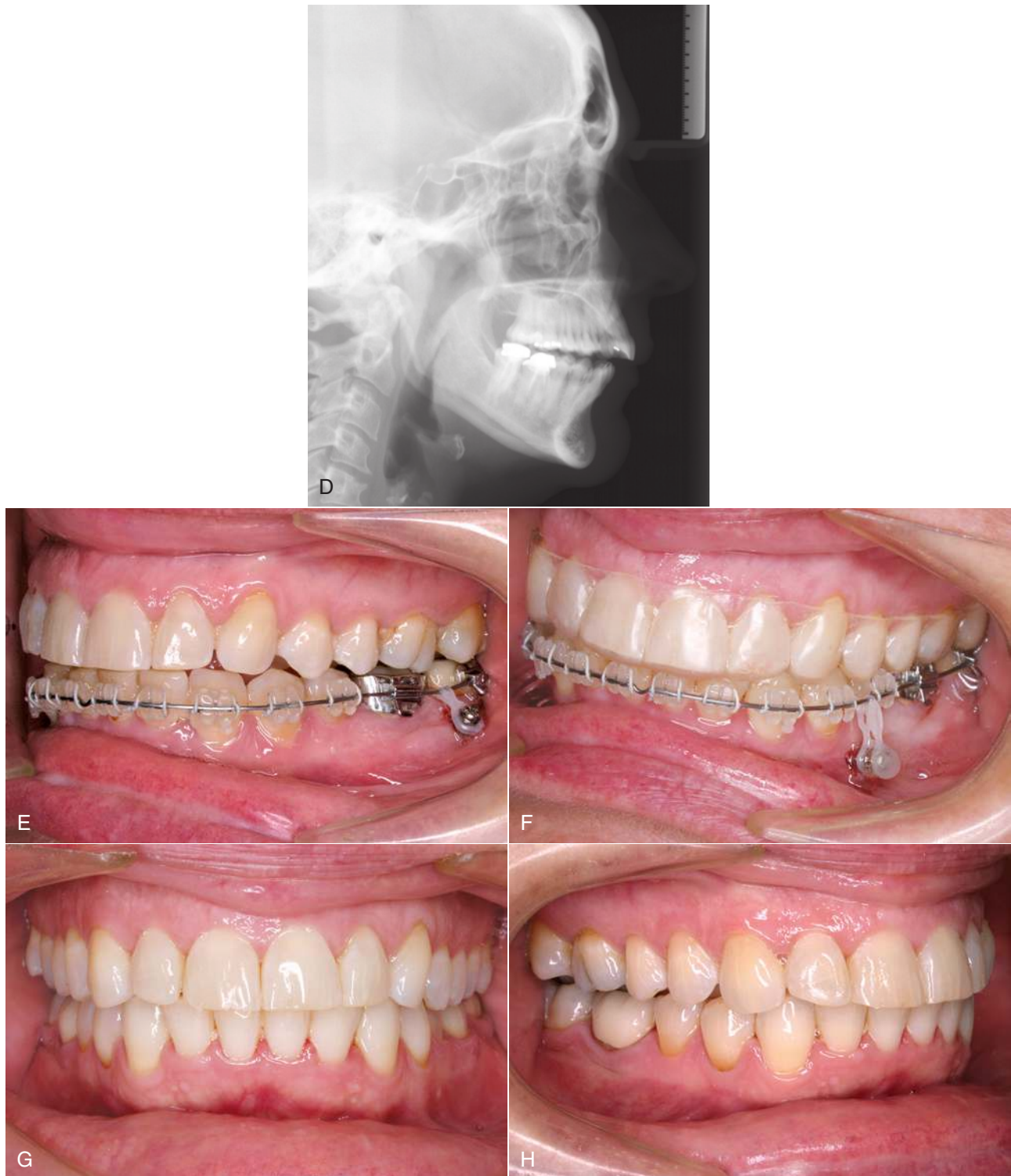


• **Fig. 19.42, cont'd** (L) The finishing stage of treatment was laser release of the tight maxillary central frenum and gingival recontouring of the central incisors to obtain the correct height-width proportion. (M) Healing at 1 week and (N) 2 weeks after the surgical procedure. (O) The superimposition tracing from beginning to end of treatment (23 months) shows that the desired amount of intrusion and mandibular rotation was achieved. A mandibular bonded 3-3 retainer and a maxillary clear retainer were placed. (Courtesy Dr. W. Gierie.)



• **Fig. 19.43** Invisalign can be combined with fixed appliance treatment to achieve tooth movement that would be very difficult with Invisalign alone. (A and B) For this 47-year-old woman, an unusual unilateral open bite had developed slowly over the previous 5 years, with little or no change during the last year. (C) The panoramic radiograph showed condylar asymmetry, with resorption of the left condyle that was tentatively attributed to osteoarthritis.





• **Fig. 19.43, cont'd** (D) The cephalometric radiograph showed a different vertical level of the mandibular posterior teeth on the two sides, and virtual intrusion of the mandibular posterior teeth on the left side indicated that this would allow the mandible to rotate upward and forward, closing the unilateral open bite and bringing her to nearly normal occlusion. The treatment plan was to use a fixed appliance in the lower arch with skeletal anchorage to close the posterior teeth on the left side and close the open bite, while aligning the upper arch with Invisalign and completing treatment with Invisalign in both arches. (E) Bone screw as anchorage for intrusion of the mandibular molars. (F) A second bone screw later for anchorage to intrude the premolars. While the intrusion was occurring, a series of aligners was used in the maxillary arch; note the final aligner being used as a retainer at this point in treatment. Once the bite was closed (which took 8 months), the expected relapse tendency was not observed during the next 6 months, and at that point a revision series of aligners was used over a period of another 4 months to complete the treatment. (G and H) Frontal and lateral posttreatment views. At 3 years' posttreatment (*not pictured*), the mild posterior open bite on the right side had closed, and the anterior open bite correction was stable. (Courtesy Dr. W. Gierie.)

### Applications of Skeletal Anchorage

There are now four major applications for skeletal anchorage in treatment of adults:

1. Positioning individual teeth when no other satisfactory anchorage is available (usually because other teeth have been lost to dental or periodontal disease)
2. Retraction of protruding incisors
3. Distal or mesial movement of molars (and the entire dental arch if needed)
4. Intrusion of posterior teeth to close an anterior open bite or anterior teeth to open a deep bite

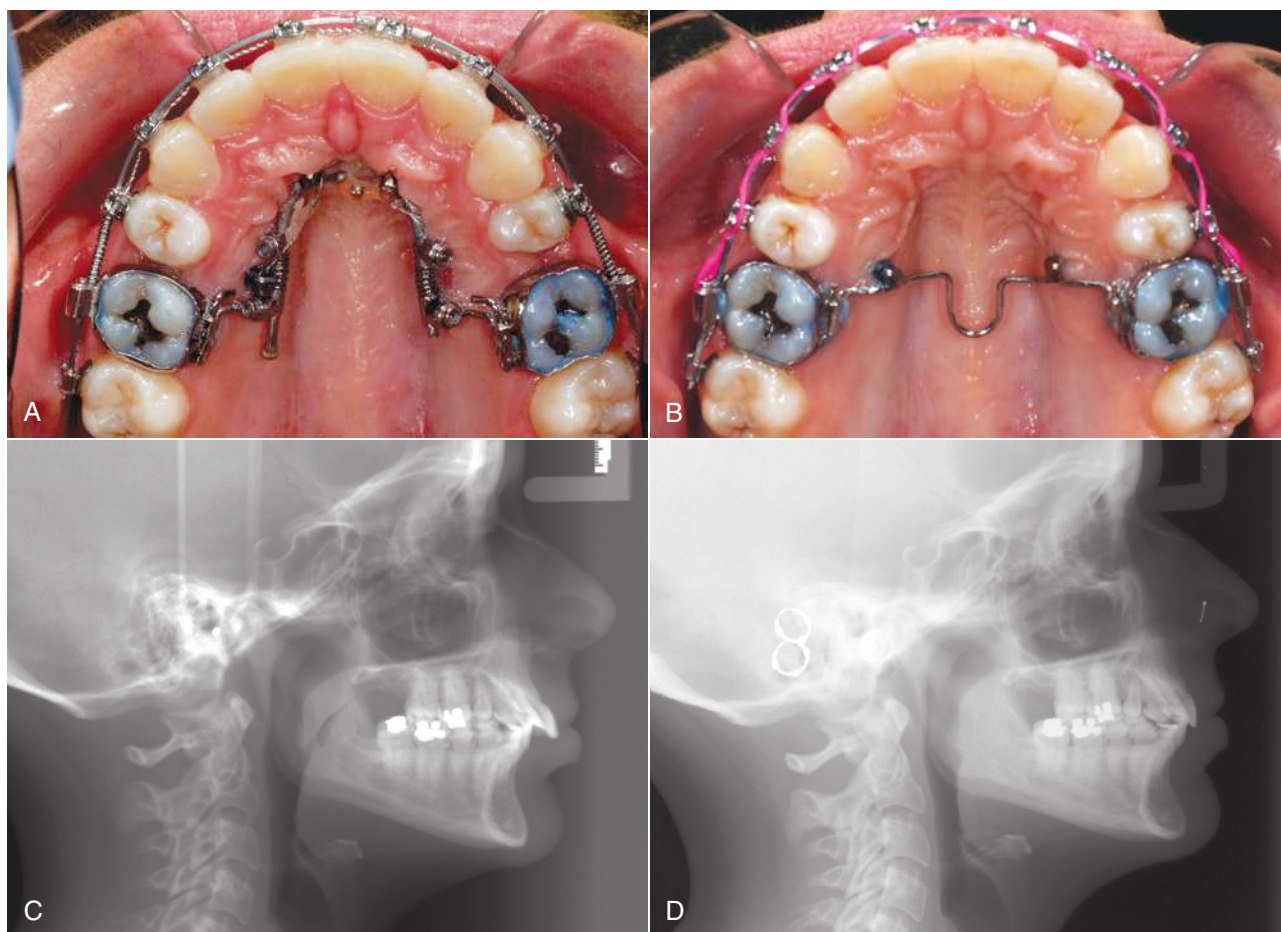
Positioning of individual teeth and closing extraction spaces have been covered in [Chapters 15](#) and [16](#); the more demanding applications in adults are discussed and illustrated here.

**Retraction of Protruding Incisors.** Retraction of maxillary anterior teeth into a premolar extraction site with bone screws in the palate as anchorage was one of the first applications of skeletal anchorage. An implant in the center of the palate can be used to

stabilize a lingual arch that prevents movement of the molars to which it is attached (see [Fig. 9.35](#)), but stabilization away from the midline is better and both direct and indirect anchorage are available as desired ([Fig. 19.44](#)). Retraction of mandibular anterior teeth into an extraction site (which could be a molar as well as a premolar site) can be managed best with alveolar bone screws in the buccal shelf below the molars (see [Fig. 10.52](#)).

Distal movement of the entire dental arch is the most ambitious treatment plan for retraction of protrusion of incisors. This was impossible until skeletal anchorage became available but now can be done for both arches—if there is space behind the molars. Second molar extraction may be needed to provide that. For the maxillary arch, this is done most readily with miniplates below the zygomatic arch, but it also is possible with palatal anchorage. Distal movement of the mandibular arch can be accomplished with bone screws in the buccal shelf ([Fig. 19.45](#)) or in the mandibular ramus.

In Asian adults who had significant retraction of incisors to correct bimaxillary protrusion, bony spicules sometimes appear between the roots of the teeth ([Fig. 19.46A](#)). These have previously



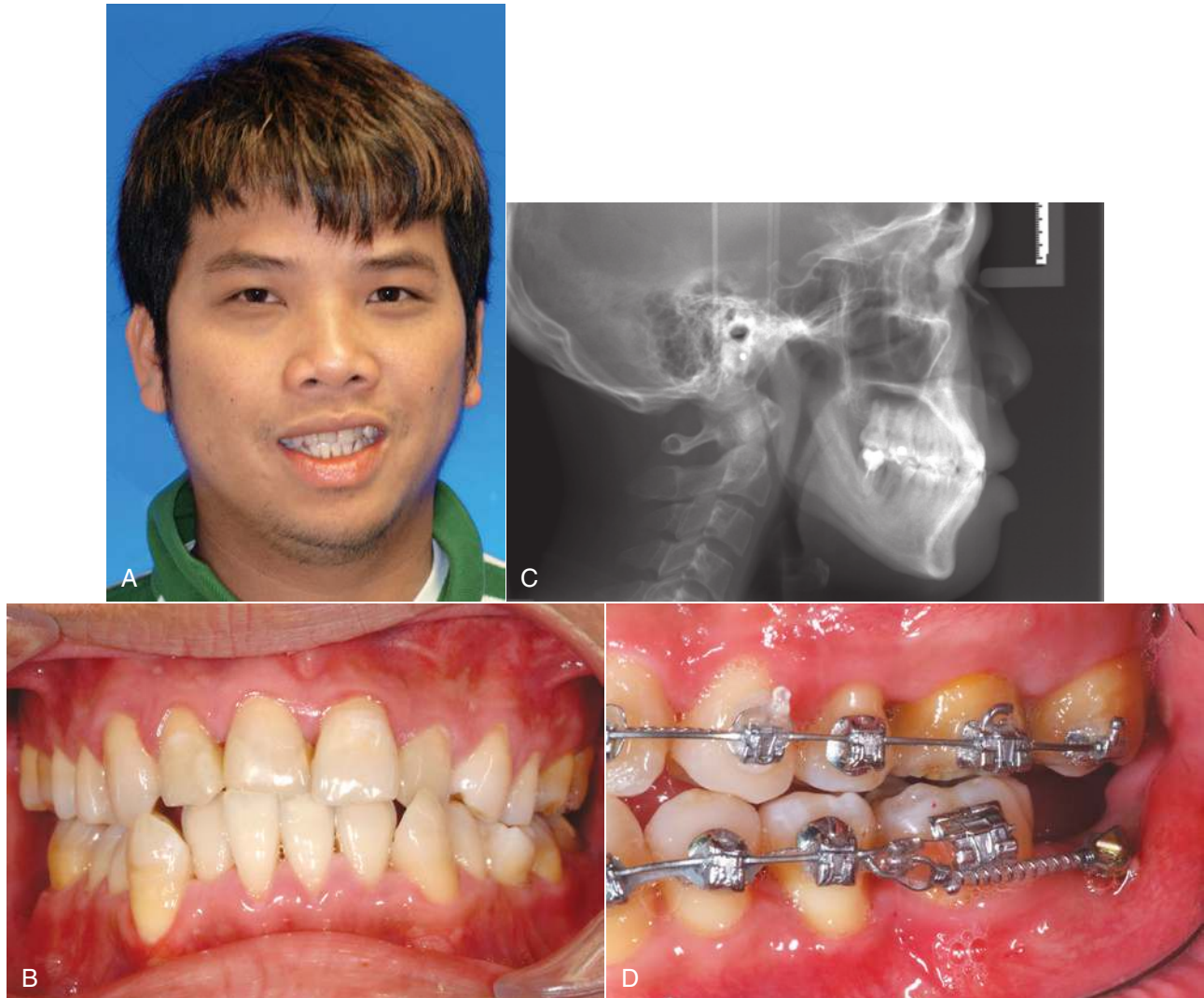
• **Fig. 19.44** (A) For this 28-year-old patient with protrusion of the maxillary arch and a partially corrected Class II malocclusion despite previous maxillary first premolar extraction, the treatment plan was palatal anchorage with bilateral bone screws for distalization of the entire maxillary arch. Initially, the molars were distalized to move them back to a Class II relationship rather than a super-Class II. (B) Then the palatal screws were used to stabilize the molars while the other teeth were retracted. (C) The pretreatment and (D) posttreatment cephalometric radiographs show the overjet reduction and attainment of the desired molar relationship. (Courtesy Dr. N. Scheffler.)



been labeled as bony exostoses, but new research at Yonsei University/University of North Carolina with 3-D imaging has shown that this is not correct. Instead, as you can see in the 3-D superimposition of CBCT images before and after treatment for the same patient (Fig. 19.46B), they are created by differential remodeling of alveolar bone as the teeth are moved posteriorly. The bone immediately adjacent to the tooth remodels the same distance as the tooth moved; in affected patients, bone between and over the teeth remodels less, and this creates the irregular bony protrusions.

Why this occurs only in adults of Asian descent (or has not been noticed if it occurs in other populations) and why it occurs only in a minority of those who have incisor retraction, is not known at this point.

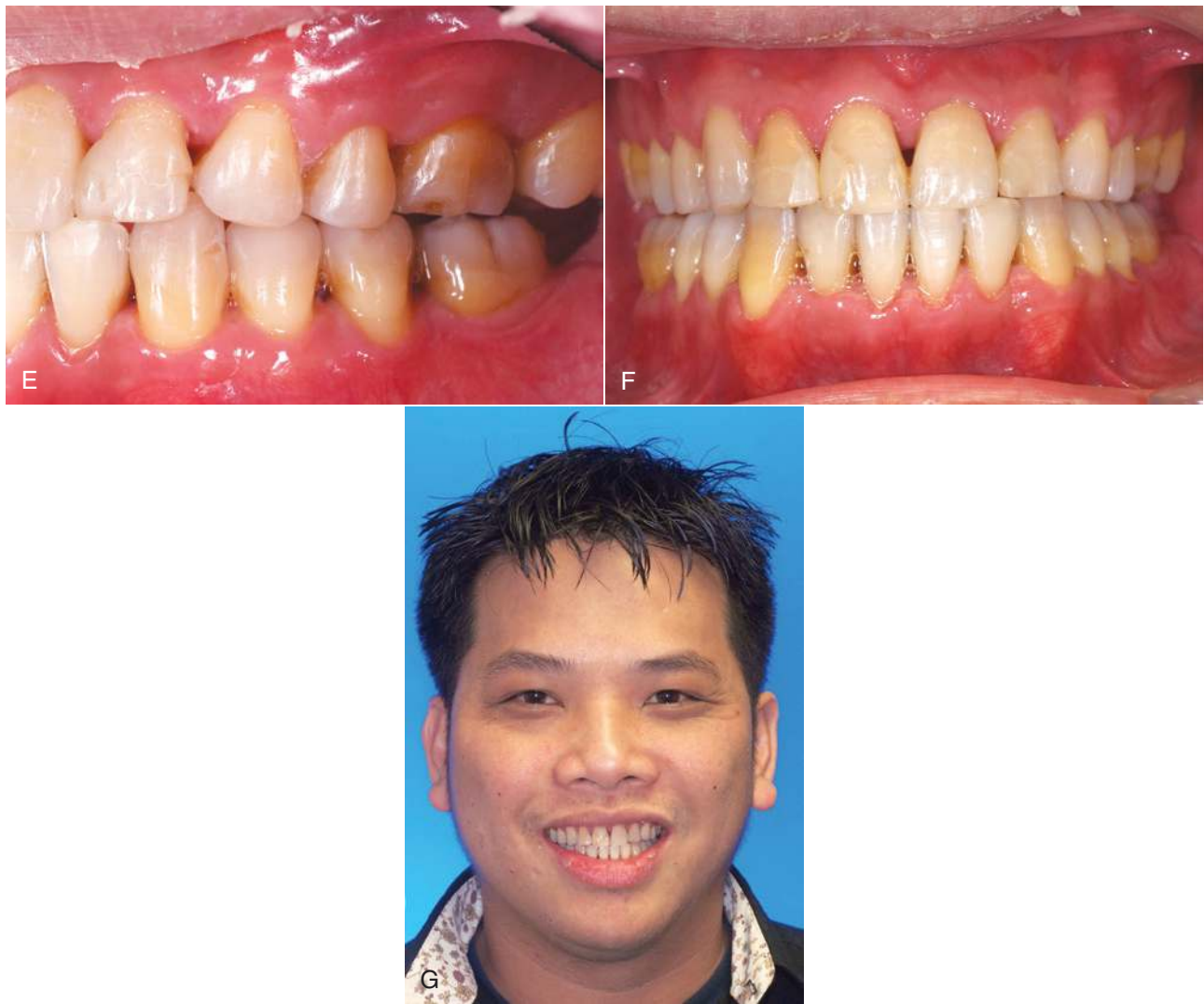**Retraction and Intrusion of Protruding Incisors.** Protruding maxillary incisors usually are tipped facially, and tipping them lingually is an obvious way to correct their axial inclination. This movement also brings the incisal edges downward, which is good if increasing incisor display and closing an anterior open bite are part of the treatment plan, but bad if maintaining or decreasing



• **Fig. 19.45** For patients of European descent, it is rarely appropriate to correct a Class III tendency and anterior crossbite by retracting the lower incisors. Asians, however, often have a component of mandibular dental protrusion; if so, retracting the incisors or moving the entire mandibular arch distally can correct the crossbite without harm to the facial appearance. (A and B) Pretreatment smile and dental appearance, with crowding and moderate protrusion of the lower anterior teeth. (C) The pretreatment cephalometric radiograph showing the protrusion of the lower incisors. One mandibular second molar had been lost previously to caries, the other had been treated endodontically, and the third molars had been removed. The plan was extraction of the remaining mandibular second molar, with distalization of the entire arch to gain a better functional molar relationship, as well as correct the crossbite. (D) Bone screws were placed bilaterally in the buccal shelf of the alveolar process (which is preferred over a screw in the ramus when this area is available), and nickel–titanium (NiTi) springs were used to move the dental arch posteriorly.

*Continued*





• **Fig. 19.45, cont'd** (E and F) The posttreatment dental appearance and (G) smile, with correction of the mandibular anterior crowding and crossbite. The smile was greatly improved, with little effect on apparent chin prominence. (Courtesy Dr. N. Scheffler.)

incisor display and correcting an anterior deep bite are needed. With segmented arch mechanics, maxillary incisors can be both retracted and intruded (see Fig. 9.48) if excellent anchorage is maintained with stabilizing lingual arches and headgear if necessary. This is technically much more difficult than just retraction of the incisors, which often can be managed with a stabilizing lingual arch, and requires excellent patient cooperation. If retraction and intrusion are needed, skeletal anchorage now is recommended. With alveolar bone screws between the molar roots or miniplates at the base of the zygomatic arch, the direction of force, both upward and backward, is ideal for this purpose, and A-NiTi retraction springs provide a constant known force level.

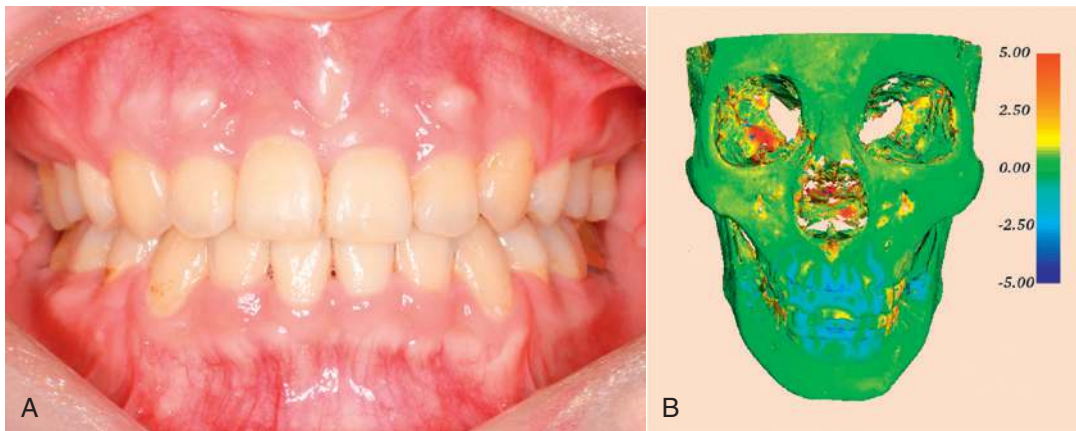
#### Distal Movement of Molars or the Entire Dental Arch

**Maxillary Distalization.** Distal movement of the maxillary molars is one way to provide space in a crowded maxillary arch; distal movement of the entire maxillary dental arch would provide a way to correct a Class II malocclusion due to a forward position of the upper teeth on their skeletal base. For both types of

movement, miniplates below the zygomatic arch or palatal bone screws provide a predictable outcome. Bone screws in the alveolar process interfere with root movement and are not recommended. Single bone screws in the infrazygomatic process away from the roots are a possibility but may not withstand the amount of force needed to move multiple teeth. The entire arch usually can be moved back 2 to 4 mm. More than that usually requires extraction of the second molars.

**Mandibular Distalization.** Moving the entire mandibular arch distally was simply impossible until skeletal anchorage became available. It can be done now by using a long bone screw into the mandibular buccal shelf or the ramus (usually less desirable)—but most American orthodontists still do not think of it in the two circumstances in which it can be helpful:

1. Class III malocclusion with a component of mandibular dental protrusion, which is almost never seen in Class III patients of European origin but does occur reasonably frequently in Asians, for whom this form of Class III camouflage can be quite acceptable (see Fig. 19.45).



• **Fig. 19.46** (A) After orthodontic treatment to retract protruding incisors into first premolar extraction spaces, this adult developed bony protrusions between and over some of the teeth. These are not due to the formation of new bone on the surface of the alveolar process (exostosis), as previously thought. (B) Instead, as this color map superimposition of 3-D images before and after treatment shows, the alveolar bone over the roots of the teeth remodels to follow the tooth movement, while less change occurs for some of the bone between or over the teeth. The green color indicates no change, the blue color shows backward movement, and the intensity of the color shows the amount of change. Note the dark blue around the roots of the anterior teeth, with light blue and green over the roots. The light orange color over the crowns of the posterior teeth indicates a small amount of transverse expansion of these teeth. (Courtesy Dr. J. C. Chung.)

2. Incisor protrusion created during treatment of severe crowding. This was avoided by extraction to prevent it until popularization of the idea that light forces and just the right self-ligating bracket somehow allowed nonextraction treatment without protrusion,<sup>20</sup> which of course it really didn't. In fact, lower incisor protrusion with Damon and similar self-ligating brackets is a common accompaniment to arch expansion. Use of skeletal anchorage during alignment to keep from advancing the incisors can produce a better relationship of the dental arch to basal bone.<sup>21</sup>

**Molar Protraction.** Space closure by bringing molars forward is accomplished most readily with indirect anchorage to stabilize the anterior dental segments, from bone screws in the palate for maxillary molar protraction and in the mandibular buccal shelf or ramus for the mandible (Figs. 19.47 and 19.48).

**Intrusion.** Intrusion of teeth in adults is a consideration in two situations: (1) overerupted incisors leading to excessive display and/or anterior deep bite and (2) overerupted molars in anterior open bite with excessive face height. Occasionally intrusion of other teeth is indicated.

**Intrusion of Incisors.** In adolescents and young adults with excessive overbite, the choice between intrusion of incisors or extrusion of posterior teeth often can be resolved in favor of extrusion because vertical growth will compensate for it. In adults, the choice often must be intrusion, which is much more effective when skeletal anchorage in the form of miniplates or screws is available and when segmented rather than continuous archwires are used. The practical effect is to make both segmented arch treatment and skeletal anchorage more important in adults than in younger patients.

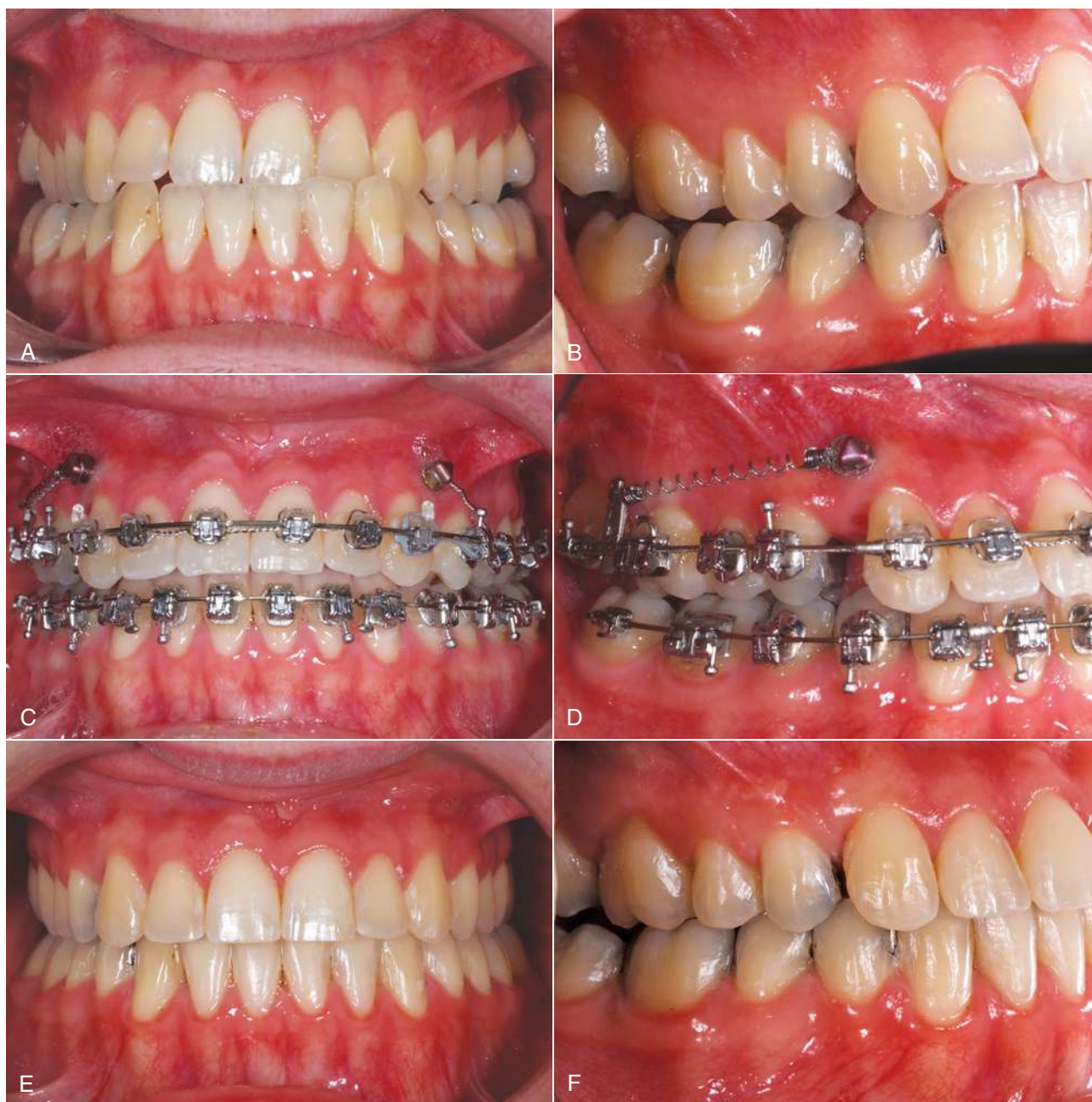One potential problem with intrusion in adults with periodontal involvement is the prospect that a deepening of periodontal pockets might be produced by this treatment. Ideally, of course, intruding a tooth would lead to a reattachment of the periodontal fibers, but there is no basis for expecting this. What seems to happen

instead is the formation of a tight epithelial cuff, so that the position of the gingiva relative to the crown improves clinically while periodontal probing depths do not increase. If good hygiene is maintained, clinical experience has shown that it is possible to maintain teeth that have been treated in this way and that root length and alveolar bone height are not greatly affected.<sup>22</sup>

The mechanotherapy needed to produce incisor intrusion in an adult is not different from the methods for younger patients described in some detail in Chapters 9 and 14. In adults, however, careful stabilization of dental arch segments during incisor intrusion is even more important, especially if the patient also has had periodontal bone loss. For those patients, skeletal anchorage via alveolar bone screws is particularly advantageous. Differential intrusion of maxillary incisors, with more intrusion on one side or intrusion on one side and extrusion on the other, also can be used to help correct a canted maxillary occlusal plane if the cant is not too severe (see the discussion of roll deformity in Chapter 6 and Fig. 15.29 to view an asymmetric intrusion arch).

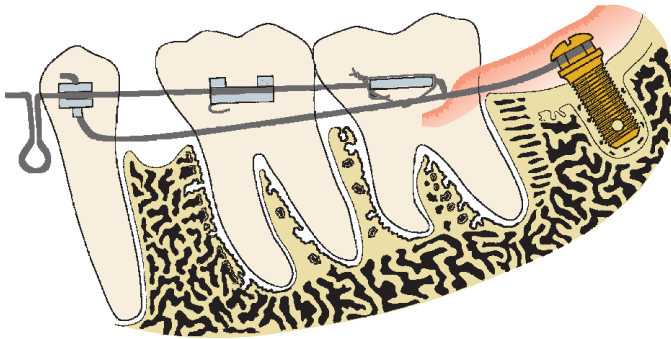
**Intrusion of Posterior Teeth to Close Anterior Open Bite.** Most patients with anterior open bite have elongation of the maxillary and/or mandibular posterior teeth, so the mandible is rotated downward and backward. The maxillary incisor segment often is reasonably well positioned relative to the upper lip. Extrusion of the upper incisors to close the bite in a patient with this issue is neither esthetically acceptable nor stable. Intrusion of the maxillary posterior segments so that the mandible can rotate upward and forward is the ideal approach to treatment (Fig. 19.49). This was essentially impossible until segmental maxillary surgery was developed in the early 1970s so that the maxillary posterior segments could be moved upward. Skeletal anchorage to intrude the posterior teeth has the potential to create the same mandibular response (Fig. 19.50). This now makes orthodontic intrusion a possible alternative to surgery, at least for patients with the less severe long-face problems.





• **Fig. 19.47** (A and B) This 28-year-old man had a unilateral anterior crossbite and a one-half cusp Class III molar relationship, with mild skeletal maxillary deficiency. The treatment plan was movement of the entire maxillary arch forward, using skeletal anchorage to maintain the anteroposterior position of the mandibular dental arch. (C) Bone screws distal to the canines were used to stabilize the maxillary posterior segments while the maxillary incisors were advanced to correct the crossbite. (D) Then the space distal to the canines was closed by bringing the posterior segments forward. Note the power arm to place the point of force application closer to the center of resistance of the posterior teeth to decrease their tendency to tip as they are advanced. (E and F) Dental appearance and posterior occlusion after completion of treatment. (Courtesy Dr. N. Scheffler.)





• **Fig. 19.48** Use of indirect anchorage from a bone screw in the mandibular ramus to move mandibular second and third molars forward to close an old mandibular first molar extraction site. The skeletal anchorage makes this movement possible when it otherwise would not be, but it is still quite slow because remodeling cortical bone in the collapsed alveolar area at the extraction site occurs very slowly. Treatment time typically is 2 to 3 years.

As the range of treatment with Invisalign has broadened, correction of anterior open bite and deep bite has become possible, with the presumed mechanism for open bite being intrusion of posterior teeth. A recent review of experience at the University of Washington showed that a median gain of 1.5 mm in overbite was obtained in patients with open bite but that the effect was largely extrusion of incisors, not intrusion of molars.<sup>23</sup>

For intrusion of maxillary posterior teeth, miniplates at the base of the zygomatic arch (see Fig. 13.21) provide excellent anchorage. These plates are held with multiple screws and are covered by the oral soft tissues. The fixture for attachment to the orthodontic appliance extends through the soft tissue, preferably at the junction between gingiva and mucosa. A major problem with miniplates is that they require more surgery than most orthodontists want to do, but at present many oral and maxillofacial surgeons have not been trained to do this procedure, and surgical help may not be available.

A long bone screw extending into the base of the zygomatic arch, which orthodontists with experience with alveolar bone screws can place, is a possible alternative. A screw of this type should be placed through attached gingiva if possible because bone screws placed in unattached tissue are at greater risk of infection and tissue overgrowth. Some preliminary separation of roots in the region in which the screw will be placed makes it easier to avoid root contact and is recommended (Fig. 19.51). The screw can be placed above and between the first and second molars (if some retraction of the maxillary arch might also be needed to assist with Class II correction) or above and between the first molar and second premolar (if the patient also has a mild Class III tendency and some mesial movement of the dental arch would help).

An ideal force system for intrusion is created by A-NiTi springs, which provide a relatively constant known force over a considerable range of activation. An upward force on the facial aspect of the posterior teeth is also a force to tip them facially, and control to prevent this is essential. Transpalatal lingual arches are one possibility, but controlling all the teeth in the segment being intruded is necessary. A bonded plate covering the occlusal surface of the teeth, fabricated so that it is off the palate enough

to allow the intrusion, is the preferred method at present (see Fig. 19.49E).

As the mandible rotates upward and forward as the posterior teeth intrude, it may be advantageous to have a Class II or Class III component to the force so that the maxillary arch is moved a little forward or back as the intrusion occurs, to help in obtaining correct overjet at the end of treatment. This can be facilitated by adjusting the point of attachment of the spring to the plate (Fig. 19.52), as well as by locating the screw as described earlier.

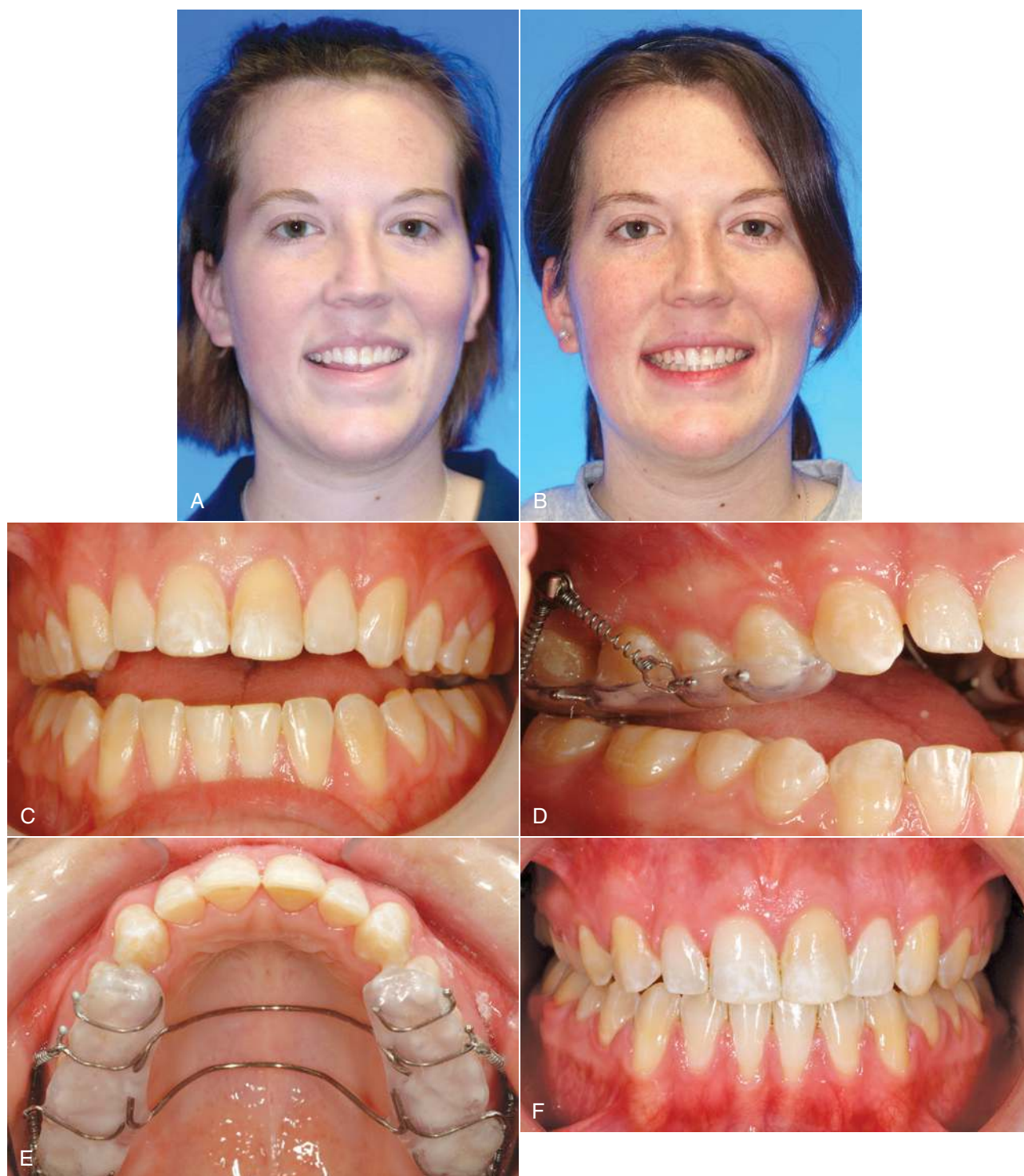Even with appropriate light force (not more than 200 gm to a three-tooth posterior segment), intrusion does not occur as quickly as other types of tooth movement. Space closure and most other types of movement occur at the rate of about 1 mm per month. At best, posterior intrusion occurs at half that rate. Because 1 mm intrusion of maxillary posterior teeth should translate into about 2 mm of closure of anterior open bite, a 4-mm open bite often closes in as many months. At that point, the rest of a complete fixed appliance can be placed (see Fig. 19.50) and the other necessary treatment can be completed while the intruded segment remains tied to the anchor screw or miniplate. After intrusion of the posterior segments, the same anchors used for that purpose easily can serve as anchorage for retraction or protraction of the maxillary arch.

Two publications in 2014 described this technique in more detail<sup>24</sup> and present the best data to date for outcomes with this technique.<sup>25</sup> The sample for the study is described in Box 19.1, and the outcomes are briefly summarized in Box 19.2. Based on jaw geometry, it was expected that there would be a 2-mm decrease in open bite (or increase in overbite) for every millimeter of posterior intrusion. All the patients were treated to at least 1 mm of overjet.

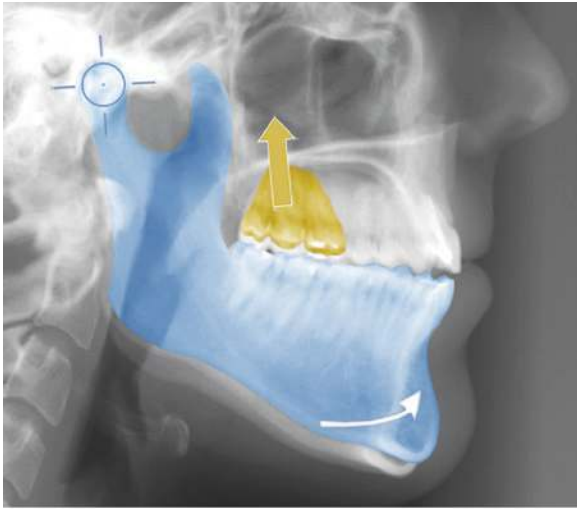
The outcomes are an excellent example of a clinical data set that is much easier to understand when the percentages of patients with clinically significant changes are shown, not just the means and standard variations for the whole sample. That usually is the case when there was large variability in the response to treatment and not a normal distribution around the mean, which occurs frequently in clinical outcome studies. For this study, changes in cephalometric measurements of more than 2 mm or 2 degrees were considered outside the range of measurement error and clinically significant, and changes greater than 4 mm or 4 degrees were considered highly clinically significant.

First, note the changes created by treatment as reported in the standard fashion of means and standard deviations (see Box 19.2). The mean amount of intrusion of the maxillary first molar, mean decrease in anterior face height, and mean increase in overbite all were significantly different from zero. But there were large standard deviations for all three changes, which indicates a large amount of variability in the results, and none of the patients had the expected amount of decrease in face height (2 mm for every 1 mm of posterior intrusion).

Now, look at Fig. 19.53, which shows the percentage of patients with clinically significant changes in anterior face height. Changes in anterior face height, of course, would reflect changes in the vertical position of the mandible as posterior teeth were intruded and the mandible rotated upward and forward to correct the anterior open bite. Changes at the later times during completion of treatment after intrusion was complete, and then at 1 and 2 years after treatment, would show how many patients experienced relapse or progressive change. This makes it apparent that the reported mean decrease in anterior face height of 1.7 mm is misleading. What really happened was that during active intrusion, 40% of the patients had 2.4 mm of decrease in face height and another 10% had more than



• **Fig. 19.49** Intrusion of maxillary posterior teeth can be effective treatment for an adult or late adolescent patient with a moderate long-face, open bite problem. (A) Age 26, before treatment for correction of anterior open bite and reduction of anterior face height. The chin was 2 to 3 mm off to the right, but this was not a problem. A chin deviation of less than 4 mm rarely is noticed—the patient was unaware of it. (B) Age 27, after treatment. Note the improved facial proportions as well as correction of the open bite. (C) Frontal intraoral view, showing the 6-mm anterior open bite and contact only on the distal aspect of the first molars and second molars. (D) Right lateral view with intrusion beginning. A long bone screw into the base of the zygoma is used for anchorage, with a modified Erverdi plate (AOB plate) used to control the teeth. (E) Palatal view of the AOB plate, showing the twin transpalatal arches connecting the splints, which must be off the palate initially so that they do not contact the soft tissues until intrusion is complete. (F) Open bite closed. The mild dental midline discrepancy, with mandibular dentition 2 mm off to the right, was not corrected because doing so would have pulled the maxillary midline off the midline of the face. (Courtesy Dr. N. Scheffler.)



• **Fig. 19.50** Schematic drawing of mandibular rotation up and forward to correct anterior open bite by intrusion of maxillary posterior teeth. One of the assumptions with this technique is that the mandible will rotate to the correct anteroposterior position, and a major indication for orthognathic surgery for open bite patients is that the mandible would not rotate to the correct position without ramus osteotomy to shorten or lengthen it, or Le Fort I osteotomy to reposition the maxilla forward or back.

#### • BOX 19.1 Scheffler et al: The Sample Consecutive Patients Treated Identically

- Maxillary intrusion splint
- Temporary anchorage device (TAD) at base of zygomatic buttress
- Nickel–titanium (NiTi) springs from TAD to splint, net intrusion force (about 100 grams on each side)

#### Data Points (Cephalometric Radiographs)

- Pretreatment
- Completion of intrusion
- Completion of treatment
- One-year recall (n = 27)
- Two-year recall (n = 25)

#### • BOX 19.2 During Active Intrusion

Two millimeters of posterior maxillary intrusion should produce an approximately 4-mm decrease in anterior face height and an approximately 4-mm decrease in open bite, but often the results are less.

- Mean intrusion of maxillary first molar =  $2.0 \pm 1.6$  mm
- Mean decrease in anterior face height =  $1.7 \pm 1.6$  mm
- Mean increase in overbite =  $1.8 \pm 1.6$  mm

#### Why Does This Happen?

- Because lower molars often erupt  $0.6 \pm 1.6$  mm as the upper molars are intruded

4 mm of decrease. One patient's face height increased rather than decreased.

Fig. 19.53 also shows the changes after overbite correction was completed and intrusion stopped. You can see that 20% of the patients had a clinically significant amount of relapse in face height

during the completion of treatment, and that some patients had changes in both directions after the end of treatment.

A clearer view of molar intrusion and relapse is shown in Fig. 19.54, which shows changes in the vertical position of the maxillary first molar to the palatal plane—that is, the actual amount of intrusion that was produced and then the amount of relapse. Note that two-thirds of the patients had more than 2 mm (clinically significant) of molar intrusion; then 10% had more than 2 mm of re-eruption during the last part of treatment, and by 2 years after treatment, 16% had experienced this amount of re-eruption. From the geometry of the mandible, you would expect about twice as much change in face height and overbite as the change in vertical molar position. Comparison with Fig. 19.53 makes it clear that the change anteriorly was not as much as the 1:2 ratio suggests.

You have already seen in Box 19.2 that eruption of lower molars was a major factor in achieving less mandibular rotation than was expected during active intrusion. Fig. 19.55 shows the number of patients with clinically significant lower molar eruption. Lower molar eruption during maxillary molar intrusion was the major reason for failure to obtain the expected change in anterior dimensions, and further eruption during the orthodontic treatment continued to be a factor in relapse—but almost no change beyond that was shown.

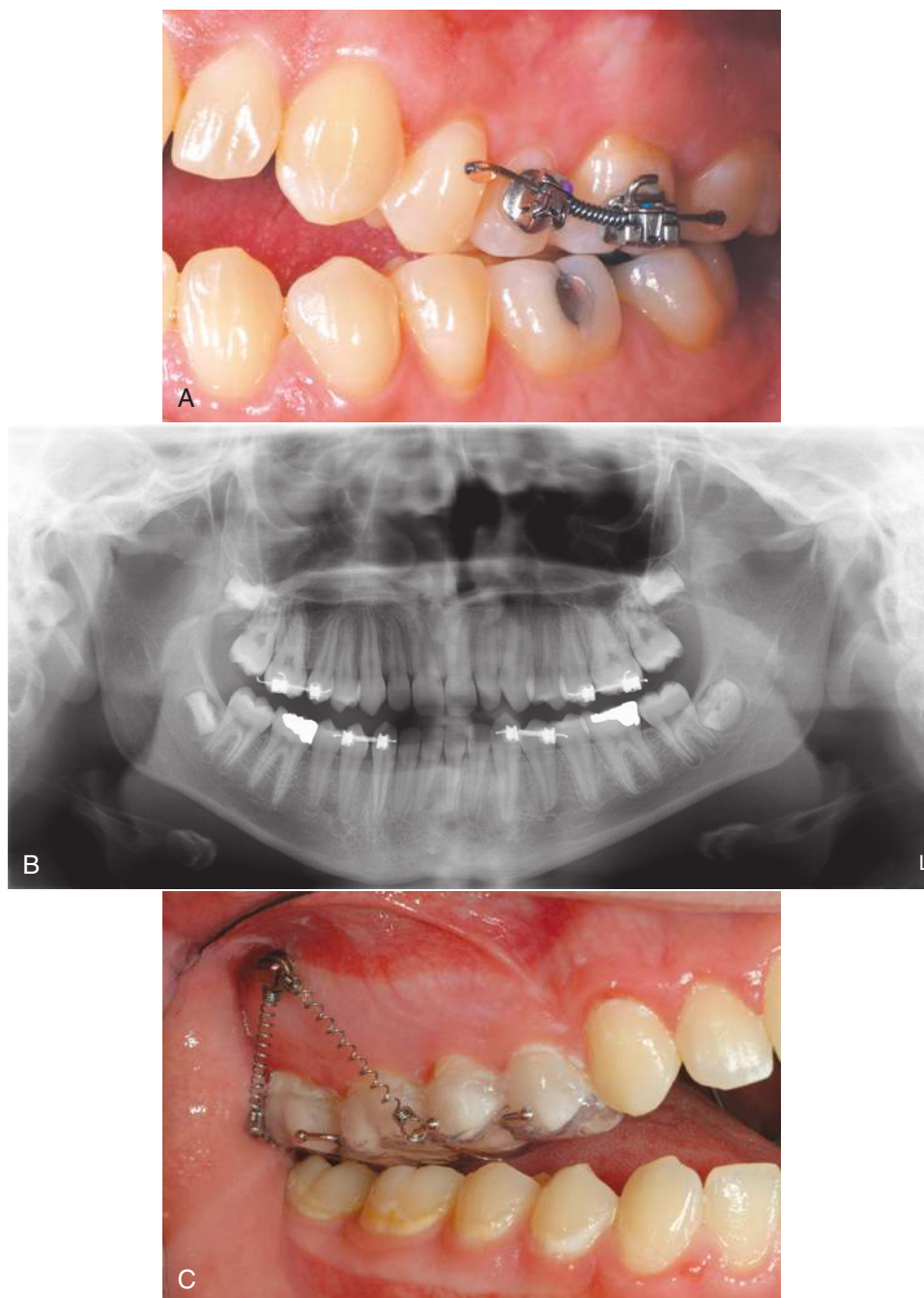
Fig. 19.56 shows the change for four critical dimensions from pretreatment to 1-year after treatment. This gives you the net changes over that time, essentially a look at the long-term outcomes. The percentages for increase in overjet are higher than for decrease in anterior face height. In fact, none of the patients had a return of open bite, although 20% went from positive overbite to zero overbite—that is, to an end-to-end incisor relationship. How did that happen? Because eruption of the incisors, which continued after the orthodontic treatment was completed, largely compensated for the further relapse in molar intrusion in a few patients, or for some downward movement of the maxilla (unexpected late growth) after treatment in the small number of patients in whom that occurred. It is interesting that late vertical growth also has been observed after surgical superior repositioning of the maxilla (see the comparison in Chapter 20 of this surgical procedure versus orthodontic intrusion).

Would the same outcomes occur if palatal rather than zygomatic buttress anchorage were used for posterior intrusion? No studies to answer that question have been presented, but there is no reason to think that how the teeth were intruded would change their response. After all, teeth have no way to know or care exactly how force against them was developed.

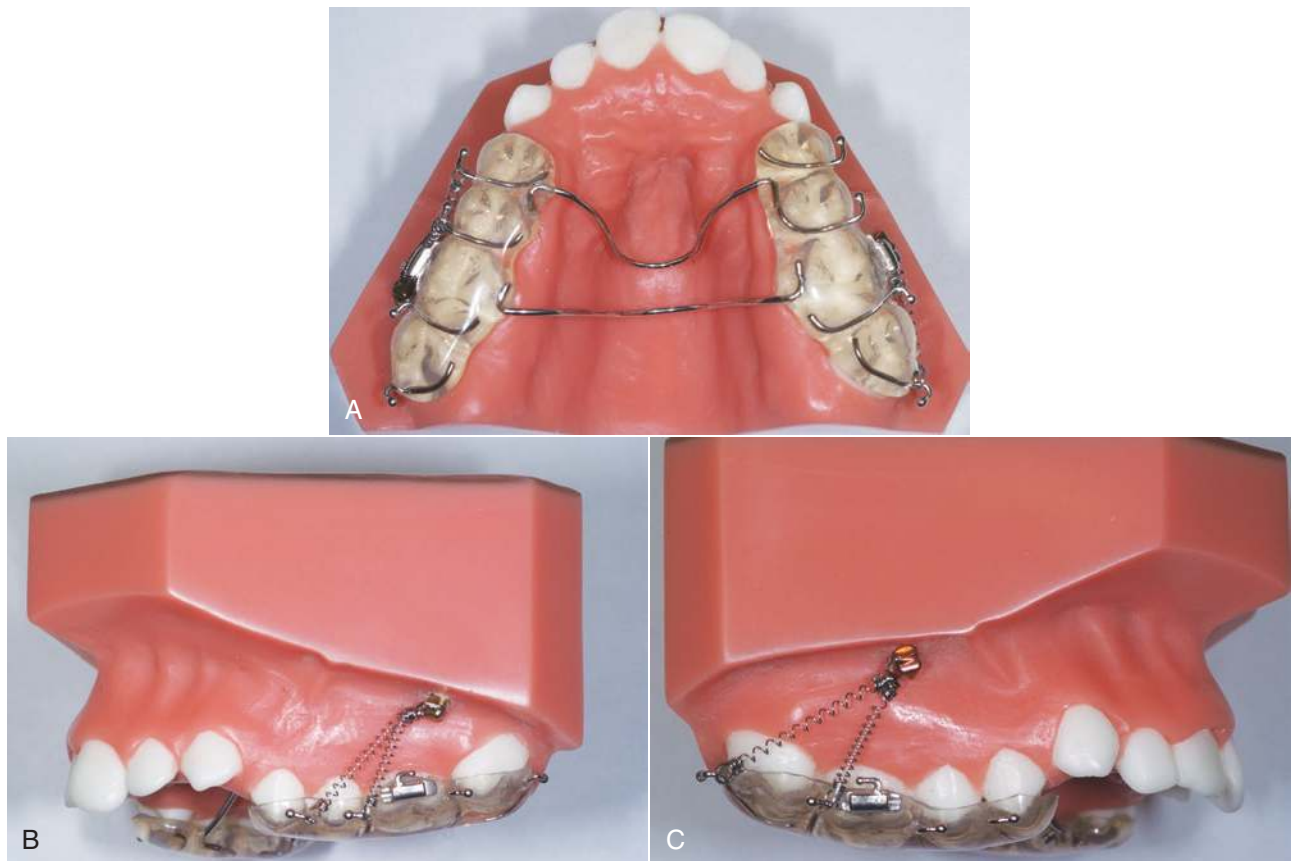In summary:

- Maxillary molar intrusion can give satisfactory correction of moderately severe open bite (up to 6 mm in the long term from intrusion, more with extrusion of incisors).
- Control of lower molar eruption now is recognized as important in gaining the desired skeletal change and should be included routinely when maxillary molar intrusion is done (see Fig. 19.57).
- Clinical experience (unfortunately, not well documented beyond case reports) suggests that intrusion of both maxillary and mandibular posterior teeth can allow closure of more severe open bites (Fig. 19.58)
- Eruption of maxillary and/or mandibular incisors partially compensates for re-rotation of the mandible, so bite opening after open bite correction rarely occurs.
- It appears that Le Fort I surgery to superiorly reposition the maxilla is more likely to produce a significant shortening of anterior face height.

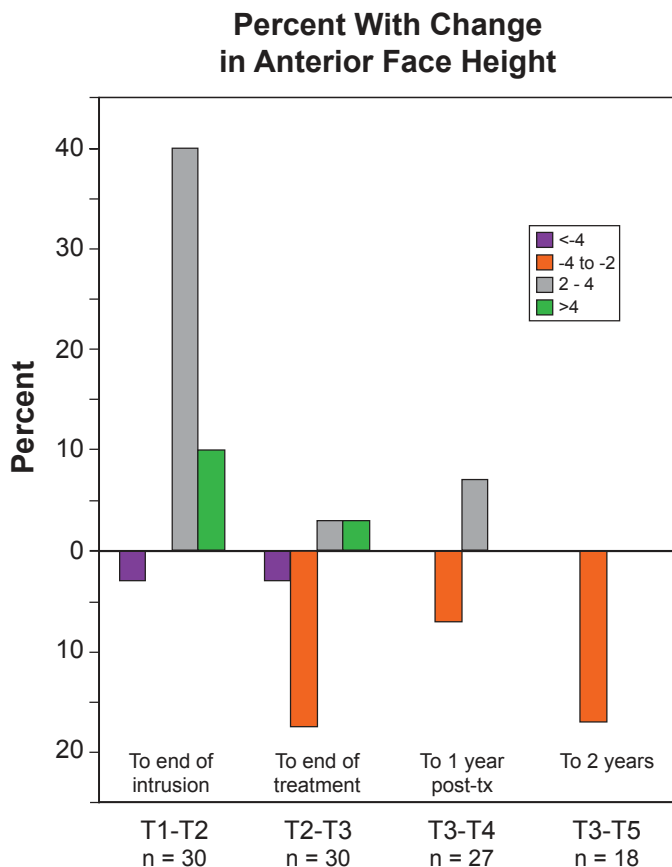




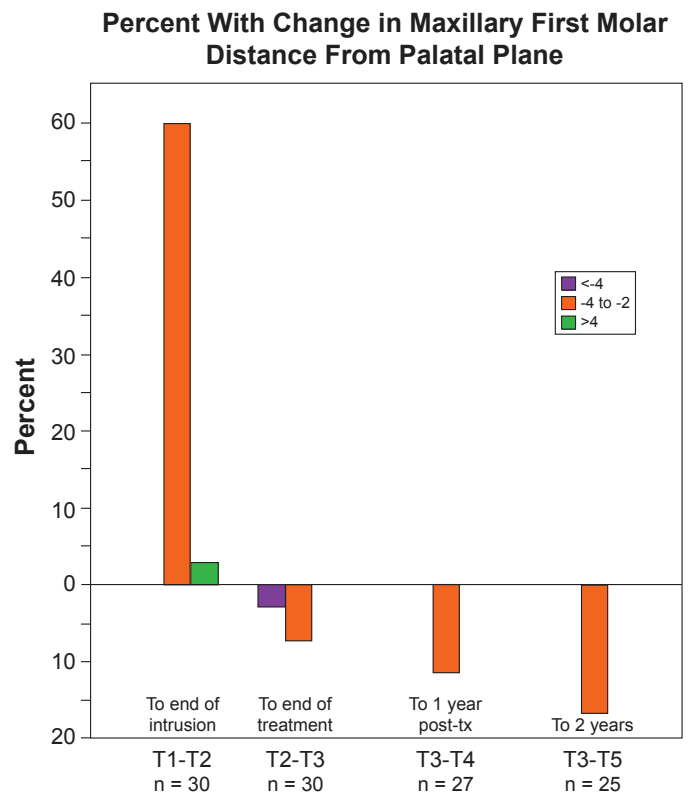
• **Fig. 19.51** (A) Before intrusion of the maxillary posterior segments to correct an anterior open bite, the roots of the second premolar and first molar are diverged to facilitate placing an alveolar bone screw between their roots. (B) A panoramic radiograph of a different patient being prepared for placement of bone screws for maxillary intrusion, showing the root divergence needed for placement of a long screw into the base of the zygomatic arch. (C) The bone screw being used as anchorage for intrusion, with use of a modified Erverdi appliance to prevent buccal tipping of the teeth in the intrusion segment. (Courtesy Dr. N. Scheffler.)



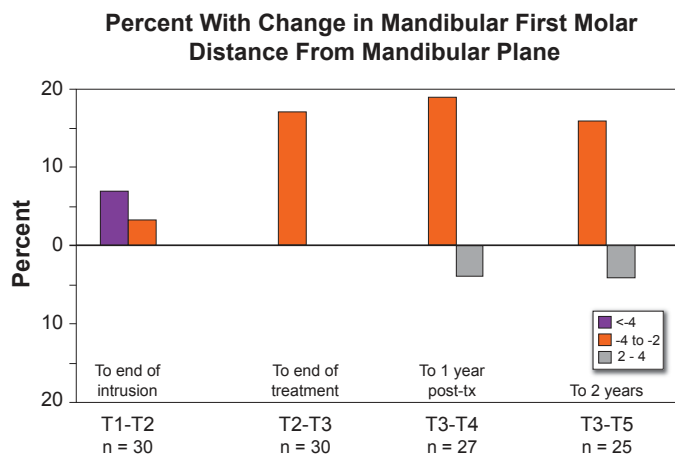
• **Fig. 19.52** (A) Occlusal splint for intrusion of maxillary posterior teeth. The lingual arches are off the palate, giving room for intrusion to occur without forcing them into the soft tissues. (B) Intrusion springs to the bone anchor with a Class II as well as vertical direction of force. (C) Intrusion springs with a Class III direction of pull. (Courtesy Dr. N. Scheffler.)



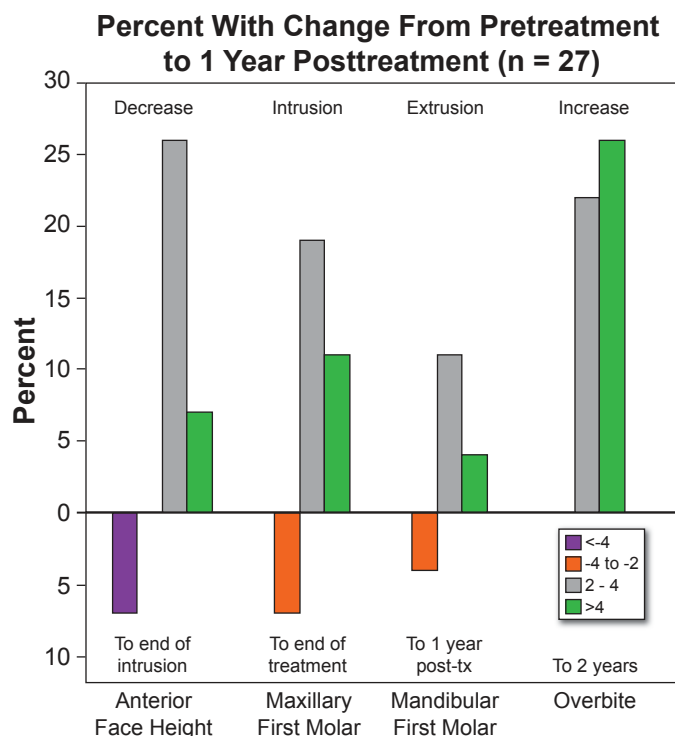
• **Fig. 19.53** Percentage of patients with clinically significant change in anterior face height with intrusion of posterior teeth. (Figs. 19.53–19.56 redrawn from Scheffler et al. *Am J Orthod Dentofac Orthop.* 2014;146:594–602.)



• **Fig. 19.54** Percentage of patients with change in the vertical position of the maxillary first molar relative to the palatal plane (true intrusion). Note that the number of patients with clinically significant decrease in face height (see Fig. 19.53) is less than would be expected from the geometric prediction of twice as much decrease in overjet and face height as intrusion of molars.



• **Fig. 19.55** Percentage of patients with clinically significant change in lower molar position from before intrusion to 2 years after treatment.



• **Fig. 19.56** Percentage of patients with changes in anterior face height, maxillary first molar vertical position, and mandibular first molar position from before intrusion to 1 year after treatment.

Are adults willing to accept as invasive a procedure as miniplates for maxillary posterior intrusion to correct severe anterior open bite? Especially when the only alternative is orthognathic surgery, most of them are. What was the treatment experience like, and were they satisfied with the outcomes? The best data are for miniplates at the base of zygomatic arch, which show that problems with these multiscrew anchors are surprisingly small.<sup>26</sup> On a 1 to 4 scale, the mean score for pain associated with the operation was 1, minimal pain. Postsurgical swelling had a mean rating of 2, but a few patients gave it a score of 4, so it is important that patients not be surprised by the extent of swelling. There was essentially no pain or discomfort during the period of active intrusion (Fig. 19.59). After 1 year, 83% of the patients said that their experience with skeletal anchorage was better than they expected, and 73% said they did not mind having the miniplate anchor. The majority commented that they did not experience as much pain and discomfort as they thought they might.

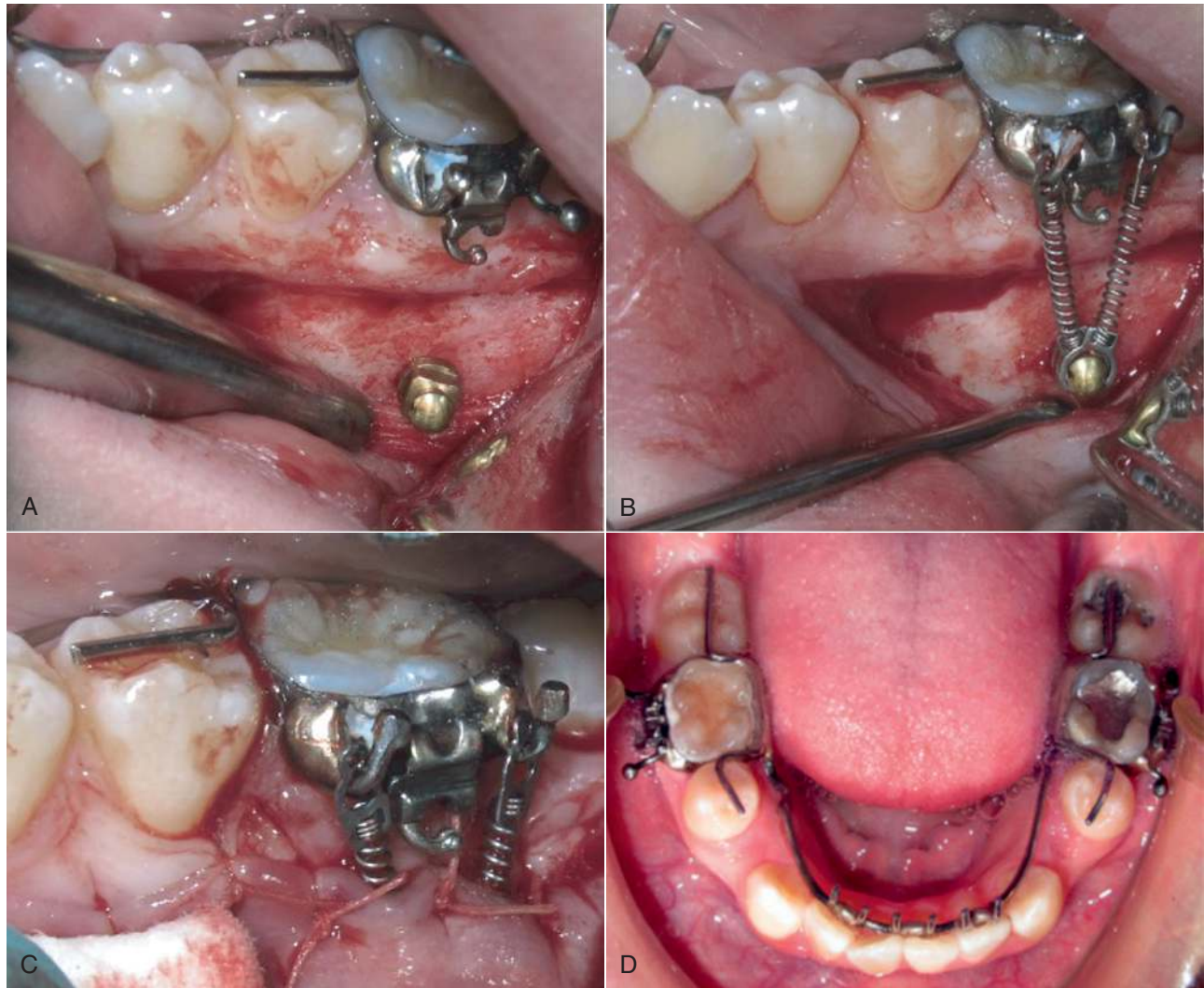
The reaction of the doctors to miniplates was also favorable. On a scale of 1 to 4 from very easy to very difficult, the surgeons who placed the skeletal anchorage rated the procedure as 1.7. The average time for a surgeon to place a single miniplate with two or three screws was 15 minutes. The orthodontists involved in these cases initially anticipated treatment of these patients to be somewhat or very difficult. However, with use of miniplates, the same cases were then considered to be very to moderately easy, and the orthodontists judged the complexity of use of skeletal anchorage to be very to moderately easy over all time points. At the 1-year time point, all the orthodontists said they would use miniplate anchorage again, and their average degree of satisfaction was 3.8 on a 4-point scale (3, moderately satisfied; 4, very satisfied).

## Summary

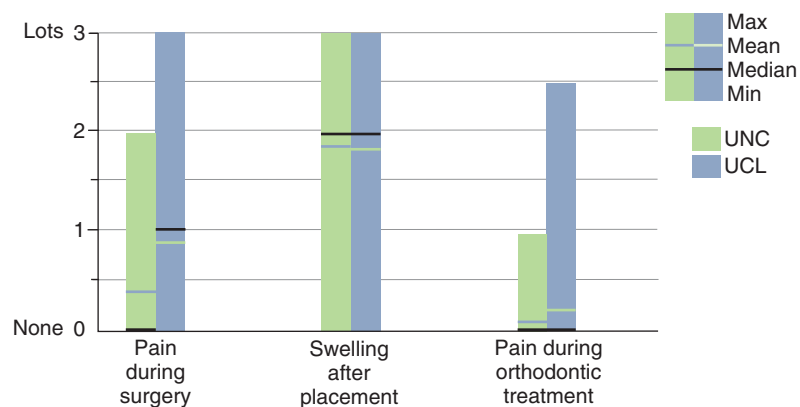
Comprehensive orthodontic treatment for adults has gone from almost zero 50 years ago to nearly 30% of the orthodontic patient population at present. With skeletal anchorage, the range of treatment possibilities has greatly increased in recent years.

The effect on orthodontists of more treatment of adults has been greater involvement in the larger scope of dental treatment, simply because adults are much more likely to have problems that extend beyond their need for orthodontics. Most orthodontists now work more closely with dental colleagues in treatment of adults, rather than focusing almost totally on children and adolescents—and being more involved in other aspects of dentistry is stimulating and interesting, as well as important in achieving the best outcomes and greatest benefit for adult patients.

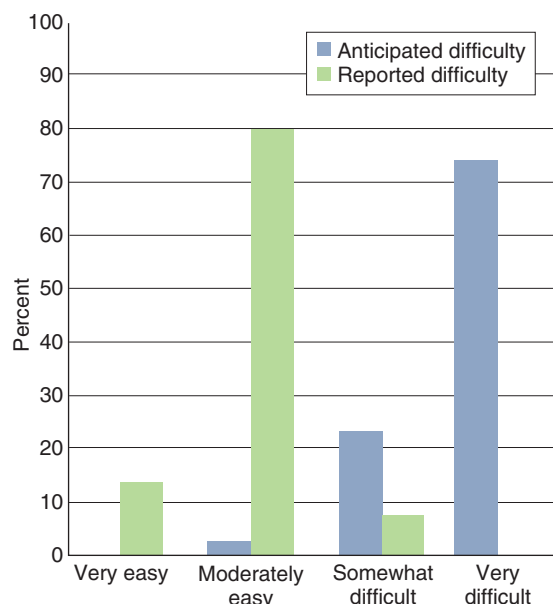




• **Fig. 19.57** Skeletal anchorage can be used to restrain eruption of lower molars or to intrude them, and if more than 6 mm closure of open bite is needed, intrusion of both upper and lower molars is needed. For mandibular posterior intrusion: (A) Alveolar bone screw placed between the molar and premolar roots; (B) nickel-titanium (NiTi) coil springs for intrusion; (C) gingival flap repositioned over the bone screw head; (D) occlusal view showing the wires to transfer force to the second molar and second premolar soldered to the molar bands. Note the adjustable lingual arch and spurs attached to the lingual arch to create tongue repositioning away from the open bite. (Courtesy Dr. J. Fisher.)



• **Fig. 19.58** Pain and swelling as reported by patients treated with miniplates as temporary skeletal anchors at University of North Carolina (UNC) and Université catholique de Louvain (UCL). (Redrawn from Cornelis MA, et al. *Am J Orthod Dentofac Orthop.* 2008;133:18–24.)



• **Fig. 19.59** Orthodontists' expectations at University of North Carolina (UNC) of difficulty of treating patients for whom miniplates as anchors were planned, and the actual difficulty these orthodontists reported. Although they had expected that almost all (98%) of the cases would be somewhat difficult or very difficult, they rated almost all the actual treatment as very easy (15%) or moderately easy (80%), and none as very difficult. (Redrawn from Cornelis MA, et al. *Am J Orthod Dentofac Orthop.* 2008;133:18–24.)

## References

- Grubb JE, Greco PM, English JD, et al. Radiographic and periodontal requirements of the American Board of Orthodontics: a modification in the case display requirements for adult and periodontally involved adolescent and preadolescent patients. *Am J Orthod Dentofacial Orthop.* 2008;134:3–4.
- Esteves T, Ramos AL, Pereira CM, et al. Orthodontic root resorption of endodontically treated teeth. *J Endod.* 2007;33:119–122.
- Thilander B. Infrabony pockets and reduced alveolar bone height in relation to orthodontic therapy. *Semin Orthod.* 1996;2:55–61.
- Ogihara S, Wang HL. Periodontal regeneration with or without limited orthodontics for the treatment of 2- or 3-wall infrabony defects. *J Periodontol.* 2010;81:1734–1742.
- Ziskind D, Schmidt A, Hirschfeld Z. Forced eruption technique: rationale and technique. *J Prosthet Dent.* 1998;79:246–248.
- Chudasama D, Sheridan JJ. Guidelines for contemporary air-rotor stripping. *J Clin Orthod.* 2007;41:315–320.
- Grauer D, Heymann GC. Clinical management of tooth-size discrepancies. *J Esthet Restor Dent.* 2012;24:155–159.
- Phillips C, Broder HL, Bennett ME. Dentofacial disharmony: motivations for seeking treatment. *Int J Adult Orthodon Orthognath Surg.* 1997;12:7–15.
- Dahlström L, Carlsson GE. Temporomandibular disorders and oral health-related quality of life. A systematic review. *Acta Odontol Scand.* 2010;68:80–85.
- Mohlin B, Axelsson S, Paulin G, et al. TMD in relation to malocclusion and orthodontic treatment. *Angle Orthod.* 2007;77:542–548.
- Macfarlane TV, Kenealy P, Kingdon HA, et al. Twenty-year cohort study of health gain from orthodontic treatment: temporomandibular disorders. *Am J Orthod Dentofacial Orthop.* 2009;135:692.e1–692.e8, discussion 692–693.
- Rusanen J, Silvola AS, Tolvanen M, et al. Pathways between temporomandibular disorders, occlusal characteristics, facial pain, and oral health-related quality of life among patients with severe malocclusion. *Eur J Orthod.* 2012;34:512–517.
- Slade GD, Ohrbach R, Greenspan JD, et al. Painful temporomandibular disorder: decade of discovery from OPPERA studies. *J Dent Res.* 2016;95:1084–1092.
- Okeson JP. *Management of Temporomandibular Disorders and Occlusion.* 7th ed. St. Louis: Mosby-Elsevier; 2013.
- Brown LJ, Brunelle JA, Kingman A. Periodontal status in the United States, 1988–91: prevalence, extent, and demographic variation. *J Dent Res.* 1996;75:672–683.
- Türkkahraman H, Sayin MO, Bozkurt FY, et al. Archwire ligation techniques, microbial colonization, and periodontal status in orthodontically treated patients. *Angle Orthod.* 2005;75:231–236.
- Bellamy LJ, Kokich VG, Weissman JA. Using orthodontic intrusion of abraded incisors to facilitate restoration: the technique's effects on alveolar bone level and root length. *J Am Dent Assoc.* 2008;139:725–733.
- Shaddox LM, Huang H, Lin T, et al. Microbiological characterization in children with aggressive periodontitis. *J Dent Res.* 2012;91:927–933.
- Grauer D, Proffit WR. Accuracy in tooth positioning with fully customized lingual orthodontic appliances. *Am J Orthod Dentofacial Orthop.* 2011;140:433–443.
- Damon D. Treatment of the face with biocompatible orthodontics. In: Graber TM, Vanarsdall RL, Vig KWL, eds. *Orthodontic Principles and Techniques.* 4th ed. St Louis: Elsevier/Mosby; 2005.
- Lin J. Creative orthodontics blending the Damon system and TADs to manage difficult malocclusions. Taipei: Yong Chieh Co.; 2007.
- Melsen B. Intrusion of incisors in adult patients with marginal bone loss. *Am J Orthod Dentofacial Orthop.* 1989;96:232–241.
- Kosravi R, Cohan B, Hujoel P, et al. Management of overbite with the Invisalign appliance. *Am J Orthod Dentofacial Orthop.* 2017;151:691–699.
- Scheffler NR, Proffit WR. Skeletal anchorage technique for intrusion of maxillary posterior teeth in treatment of anterior open bite. *J Clin Orthod.* 2014;48:158–165.
- Scheffler NR, Proffit WR, Phillips C. Outcomes and stability in long face / open bite patients treated with TADs and a maxillary intrusion splint. *Am J Orthod Dentofacial Orthop.* 2014;146:594–602.
- Cornelis MA, Scheffler NR, Nyssen-Behets C, et al. Patients' and orthodontists' perceptions of miniplates used for temporary skeletal anchorage: a prospective study. *Am J Orthod Dentofacial Orthop.* 2008;133:18–24.

# 20

## Combined Surgical and Orthodontic Treatment

### CHAPTER OUTLINE

#### Development of Orthognathic Surgery

##### The Borderline Patient: Camouflage Versus Surgery

- Malocclusion Severity as an Indication for Surgery
- Orthognathic Surgery Versus Temporary Skeletal Anchorage
- Esthetic and Psychosocial Considerations
- Computer Simulation of Alternative Treatment Outcomes
- Extraction of Teeth and the Camouflage Versus Surgery Decision

#### Contemporary Surgical Techniques

- Mandibular Surgery
- Maxillary Surgery
- Dentoalveolar Surgery
- Distraction Osteogenesis
- Adjunctive Facial Procedures
- Postsurgical Stability and Clinical Success

#### Special Considerations in Planning Surgical Treatment

- Timing of Surgery
- Correction of Combined Vertical and Anteroposterior Problems
- Special Points in Planning Orthognathic Surgery

#### Putting Surgical and Orthodontic Treatment Together: Who Does What and When?

- Orthodontic Appliance Considerations
- Presurgical Orthodontics
- Patient Management at Operation
- Postoperative Care
- Postsurgical Orthodontics

For patients whose orthodontic problems are so severe that neither growth modification nor camouflage offers a solution, surgery to realign the jaws or reposition dentoalveolar segments is the only possible treatment. Surgical treatment is not a substitute for orthodontics in these patients. Instead, it must be properly coordinated with orthodontics and other dental treatment to achieve good overall results. Dramatic progress in recent years has made it possible for combined treatment to correct many severe problems that simply were untreatable only a few years ago (Fig. 20.1).

#### Development of Orthognathic Surgery

Surgery for mandibular prognathism began early in the 20th century with occasional treatment that consisted of a body ostectomy,

removing a molar or premolar tooth and an accompanying block of bone. Edward Angle, commenting on a patient who underwent treatment of this type over 100 years ago, described how the result could have been improved if orthodontic appliances and occlusal splints had been used. Although there was gradual progress in techniques for setting back a prominent mandible throughout the first half of the 20th century, the introduction of the sagittal split ramus osteotomy in 1957 marked the beginning of the modern era in orthognathic surgery.<sup>1</sup> This technique used an intraoral approach, which avoided the necessity of a potentially disfiguring skin incision. The sagittal split design also offered a biologically sound method for lengthening or shortening the lower jaw with the same bone cuts, thus allowing treatment of mandibular deficiency or excess (Fig. 20.2).

During the 1960s, American surgeons began to use and modify techniques for maxillary surgery that had been developed in Europe, and a decade of rapid progress in maxillary surgery culminated in the development of the Le Fort I downfracture technique, which allowed repositioning of the maxilla in all three planes of space (Fig. 20.3).<sup>2,3</sup> By the 1980s, it was possible to reposition either or both jaws, move the chin in all three planes of space, and reposition dentoalveolar segments surgically as desired. In the 1990s, rigid internal fixation greatly improved patient comfort by making immobilization of the jaws unnecessary, and a better understanding of typical patterns of postsurgical changes made surgical outcomes more stable and predictable. With the introduction of facial distraction osteogenesis around the turn of the century and its rapid development since then, larger jaw movements and treatment at an earlier age became possible for patients with the most severe problems (usually related to syndromes).

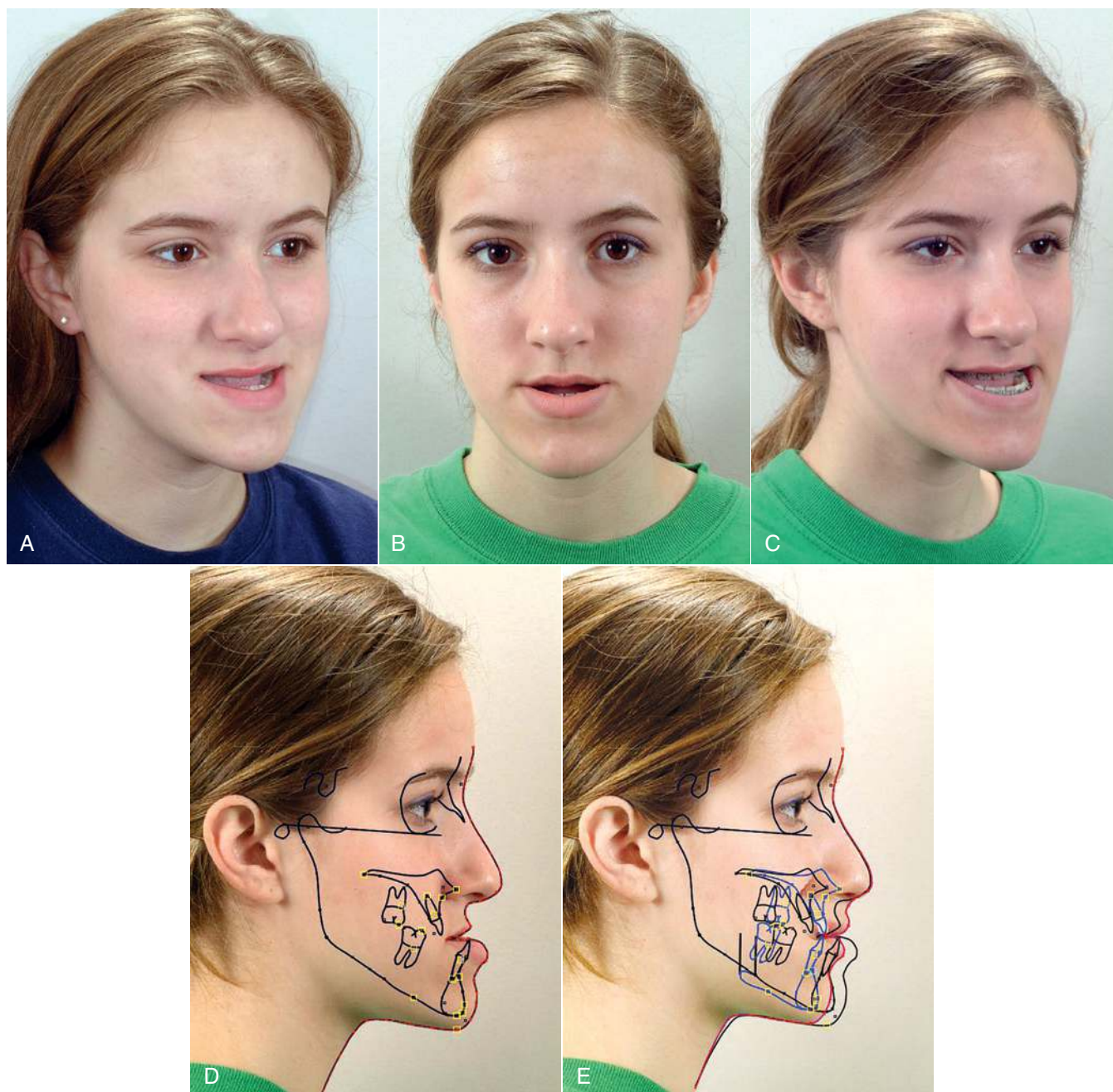
Combined surgical and orthodontic treatment can now be carried out successfully for patients with a severe dentofacial problem of any type. This chapter provides an overview of current orthognathic surgery, which is covered in detail in two well-illustrated texts.<sup>4,5</sup>

### The Borderline Patient: Camouflage Versus Surgery

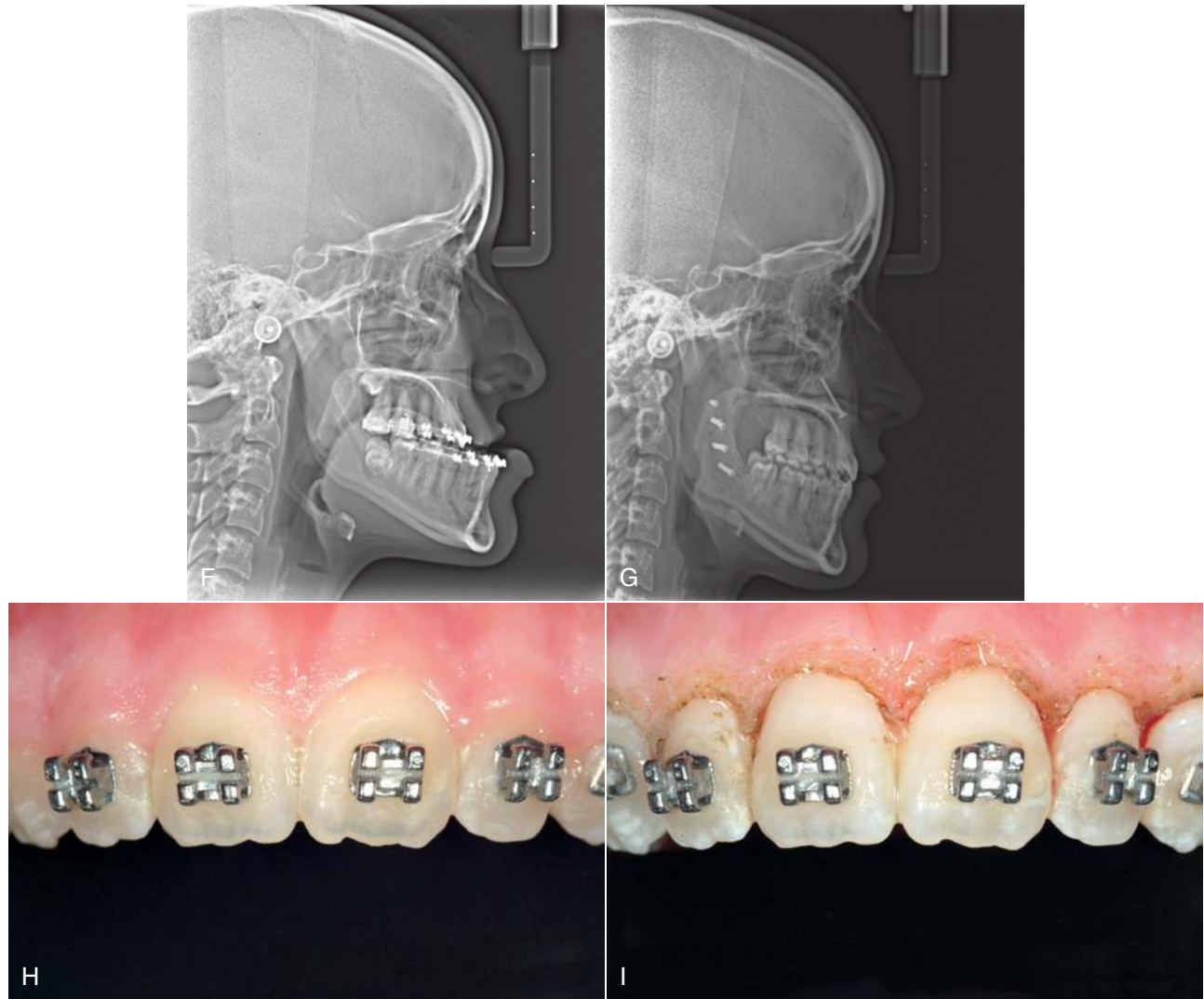
#### Malocclusion Severity as an Indication for Surgery

One indication for surgery obviously is a malocclusion too severe for orthodontics alone. It is possible now to be at least semiquantitative about the limits of orthodontic treatment in the context of producing normal occlusion. As the diagrams of the “envelope



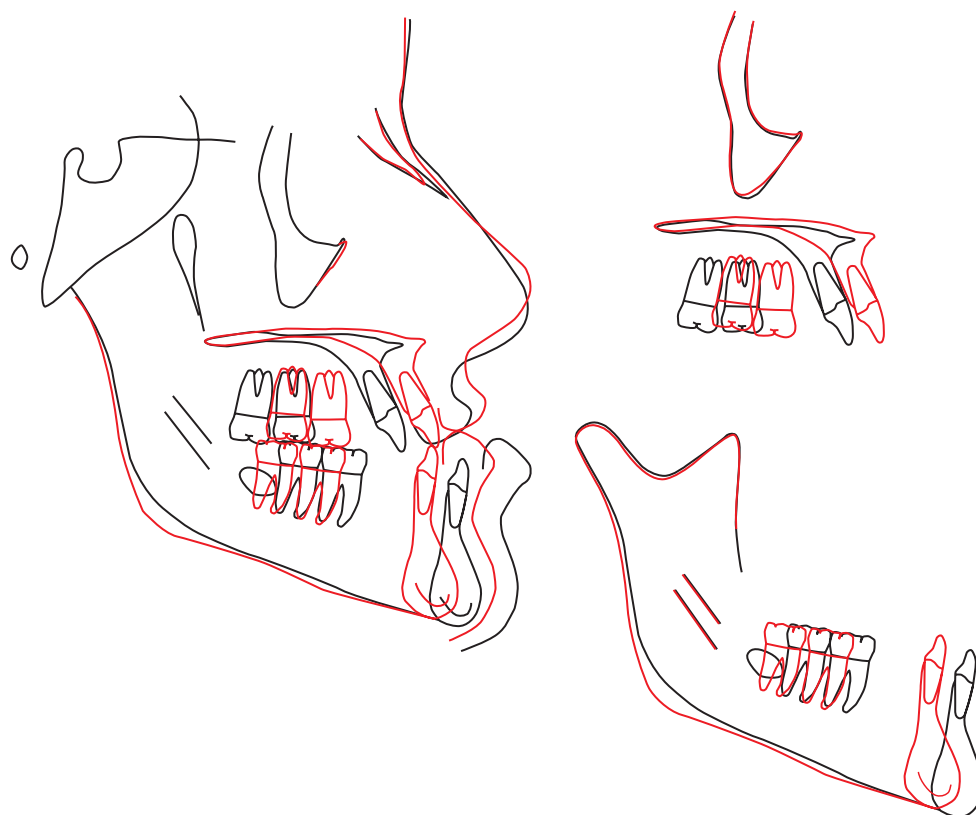
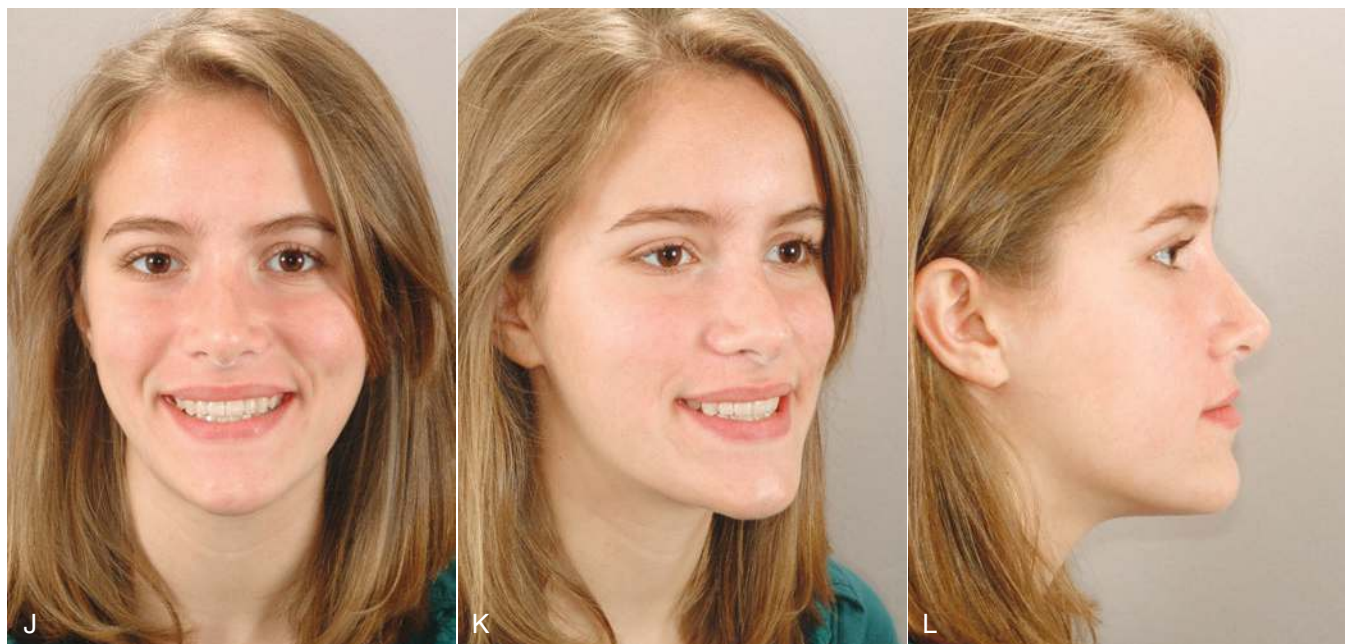

• **Fig. 20.1** (A) At age 14, when she was first seen for orthodontic consultation, this girl had significant anteroposterior and vertical maxillary deficiency (note the lack of maxillary incisor display on smile) and a large mandible. Although she had reached sexual maturity 3 years previously, the decision was to obtain a cephalometric radiograph and see her on 1-year recall to be sure that active mandibular growth had effectively ended before beginning orthodontic preparation for orthognathic surgery. Treatment was started at age 15, with the goal of removing dental compensation for the skeletal discrepancy. This required extraction of maxillary first premolars so that the proclined maxillary incisors could be retracted, with nonextraction treatment of the lower arch and some proclination of the lower incisors. Although she was in buccal crossbite, placing the dental casts in Class I occlusion showed that when the anteroposterior jaw discrepancy was corrected, transverse dental relationships would be approximately normal, so expansion of the maxillary arch was not necessary. (B and C) Age 17, after presurgical orthodontics, which temporarily made her facial appearance worse. It is important that patients understand in advance that this will occur. (D) The cephalometric tracing at that point was linked to the facial photograph so that predictions of various combinations of maxillary advancement and mandibular setback could be evaluated. (E) This prediction shows that anticipated effect of approximately equal advancement of the maxilla and setback of the mandible.



• **Fig. 20.1, cont'd** (F) The presurgical cephalometric radiograph. The surgical plan was 5 mm of maxillary advancement with some downward movement, 5 mm of mandibular setback, and rhinoplasty to correct the drooping nasal tip and decrease the width of the alar base. (G) Postsurgical cephalometric radiograph. (H) At the end of the postsurgical orthodontic treatment, the crowns of the central incisors were disproportionately wide for their height because of gingival overgrowth. (I) The gingival margins were recontoured with a diode laser.

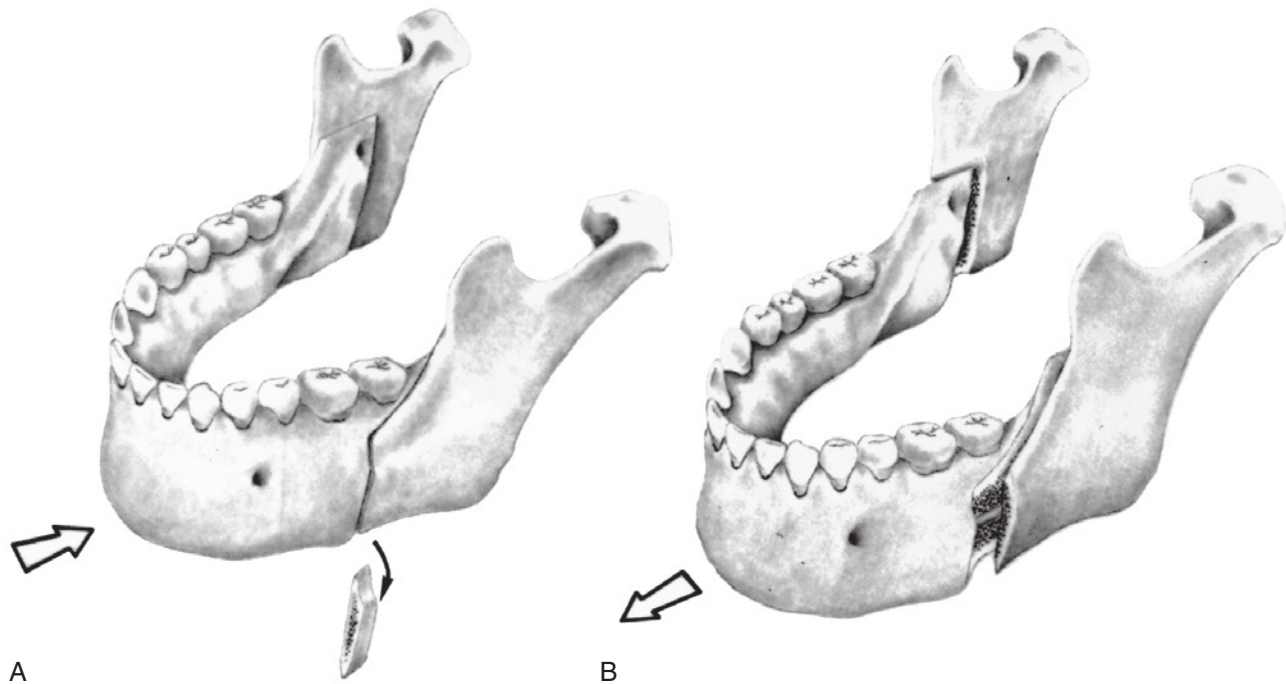
*Continued*



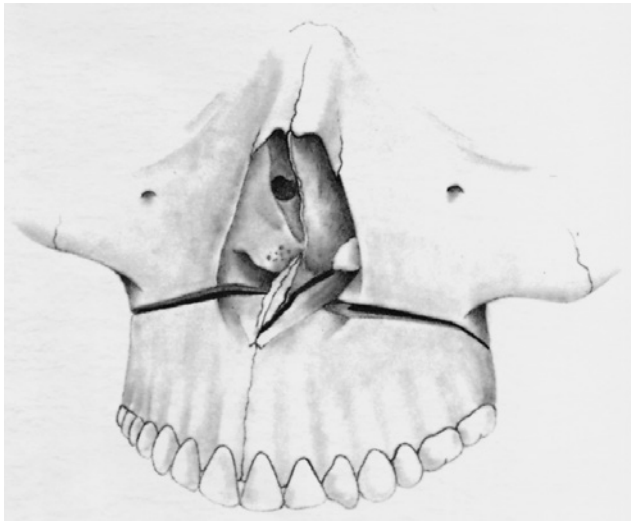
M

• **Fig. 20.1, cont'd** (J to L) Frontal and oblique smiles and resting profile views at the completion of treatment. (M) Superimposition of pretreatment and posttreatment tracings shows the hard tissue and soft tissue profile changes during treatment. Note in the superimposition tracing and the posttreatment facial views that the nose was tipped forward but the rhinoplasty prevented further upward tipping of the nasal tip and improved tip projection.





• **Fig. 20.2** The sagittal split osteotomy procedure can be used to set back or advance the mandible, as shown in (A) and (B), respectively.



• **Fig. 20.3** The location of the osteotomy cuts for the Le Fort I down-fracture technique, which allows the maxilla to be moved up and forward readily. Moving it down is feasible but requires careful retention during healing. Moving it back is very difficult because of the structures behind the maxilla, but moving protruding incisors back can be accomplished easily with a segmental osteotomy to move the canine-to-canine segment back into a premolar extraction space.

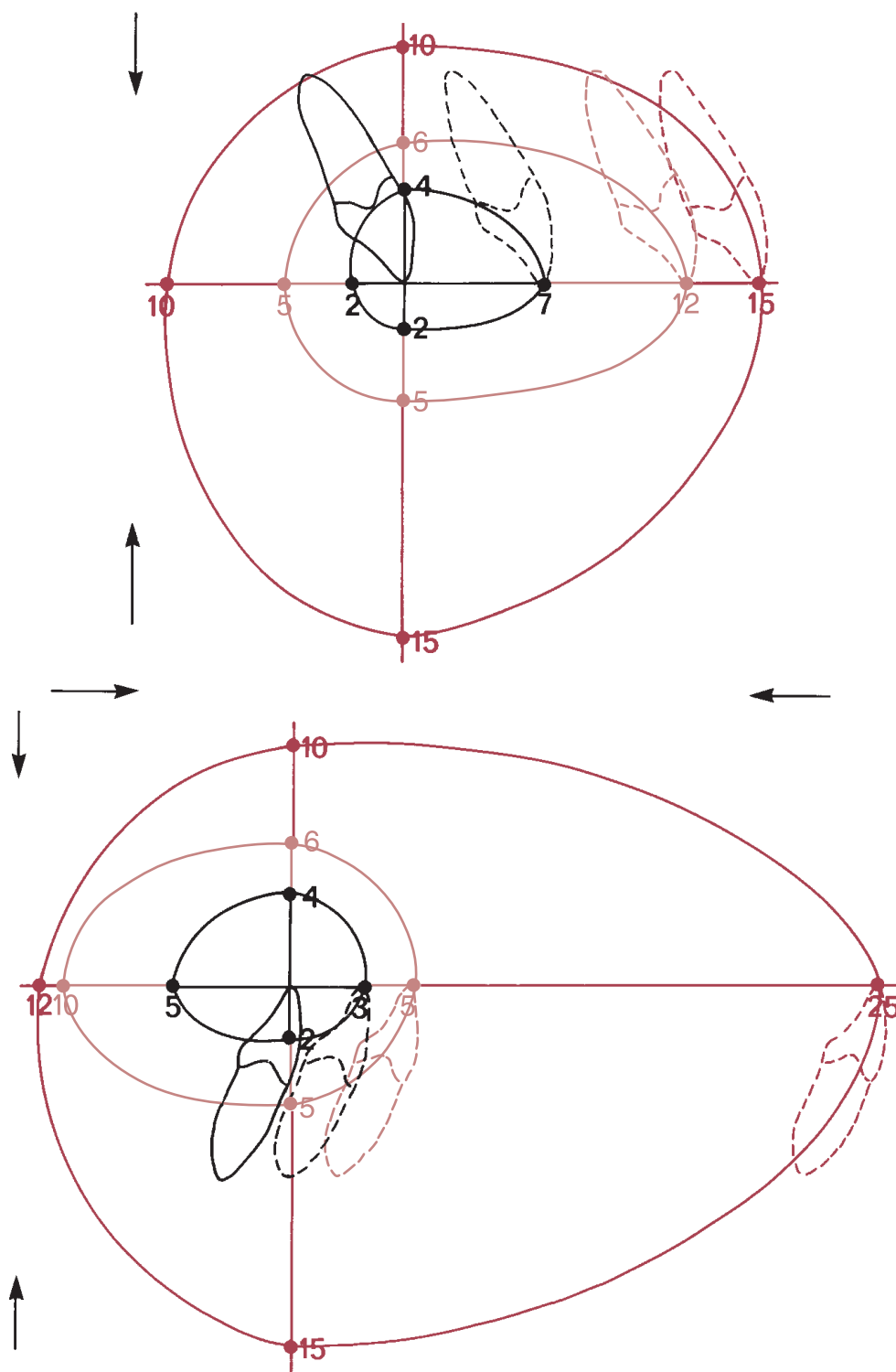
of discrepancy” (Fig. 20.4) indicate, the limits vary according to the tooth movement that would be needed. As the figure shows, teeth can be moved farther in some directions than others at any age (the limits for tooth movement change little if any with age), but growth modification is possible only while active growth is occurring. Because growth modification in children enables greater

changes than are possible by tooth movement alone in adults, some conditions that could have been treated with orthodontics alone in children (e.g., a centimeter of overjet) become surgical problems in adults. On the other hand, some conditions that initially might look less severe (e.g., 5 mm of reverse overjet) can be seen even at an early age to require surgery if they are ever to be corrected.

Keep in mind that the envelope of discrepancy outlines the limits of hard tissue change toward ideal occlusion, *if* other limits due to the major goals of treatment do not apply. In fact, soft tissue limitations not reflected in the envelope of discrepancy often are a major factor in the decision for orthodontic or surgical–orthodontic treatment. Measuring millimeter distances to the ideal condylar position for normal function is problematic, and measuring distances to define ideal esthetics is impossible. The diagnostic and treatment planning approach discussed in [Chapters 6 and 7](#) reflects the heavy emphasis on soft tissue considerations in modern treatment and is essential when camouflage versus surgery is considered.

### Orthognathic Surgery Versus Temporary Skeletal Anchorage

The advent of temporary skeletal anchorage in the form of miniplates or bone screws has led many orthodontists to wonder if this could decrease the number of patients who would need surgery. Applications of skeletal anchorage in treatment of adults have been discussed in detail in [Chapter 19](#). Tooth movement for patients with a jaw discrepancy, of course, is camouflage—successful only if the jaw discrepancy is no longer apparent enough to be a problem. It is true that protruding maxillary incisors in a patient with mandibular deficiency can be retracted further with skeletal anchorage. This is as likely to produce a camouflage failure as it is to correct the problem. The limits of orthodontic treatment are much more a matter of facial appearance than anchorage.



• **Fig. 20.4** With the ideal position of the upper and lower incisors shown by the origin of the x- and y-axes, the envelope of discrepancy shows the amount of change that could be produced by orthodontic tooth movement alone (the inner envelope of each diagram); orthodontic tooth movement combined with growth modification (the middle envelope); and orthognathic surgery (the outer envelope). Note that the possibilities for each direction of movement are not symmetric. There is more potential to move teeth forward than back and more potential for extrusion than intrusion. Because growth of the maxilla cannot be modified independently of the mandible, the growth modification envelope for the two jaws is the same. Surgery to move the lower jaw back has more potential than surgery to advance it.

There are two circumstances, however, in which skeletal anchorage may be an alternative to orthognathic surgery. Moving the maxilla up with a Le Fort I osteotomy is highly stable and predictable. This has made it possible to correct anterior open bite/long-face problems that previously could not be corrected. Maxillary posterior teeth can be intruded with miniplates at the base of the zygomatic arch, long bone screws reaching into the same area, or palatal anchorage (see [Chapter 17](#)). It is clear now that 3 to 4 mm of intrusion can be achieved, with an expected short-term relapse of about 1 mm, and that for the average patient, 2 mm of closure of the open bite occurs for every 1 mm of posterior intrusion. This means that closure of a 6-mm anterior open bite is about the limit unless lower as well as upper molars are intruded, and that a surgical procedure still will be required unless the mandible rotates to the correct position as face height decreases. For example, it can rotate into an anterior crossbite that cannot be managed with either mandibular dental retraction or maxillary proclination.

The other interesting possibility for skeletal anchorage is protraction of the maxilla in preadolescent children (see [Chapter 13](#)). It is apparent now that Class III elastics to skeletal anchors in the posterior maxilla and anterior mandible are much more effective than reverse-pull headgear to the teeth in moving the maxilla forward. As with facemask treatment, however, the moment of truth comes during adolescence, when mandibular growth can lead to a return of the Class III problem. Can the maxilla be moved far enough forward at ages 10 to 12 to prevent the need for later surgical advancement? That depends on the severity of the maxillary and midface deficiency, on the amount of dental compensation, and even more on the pattern of adolescent growth.

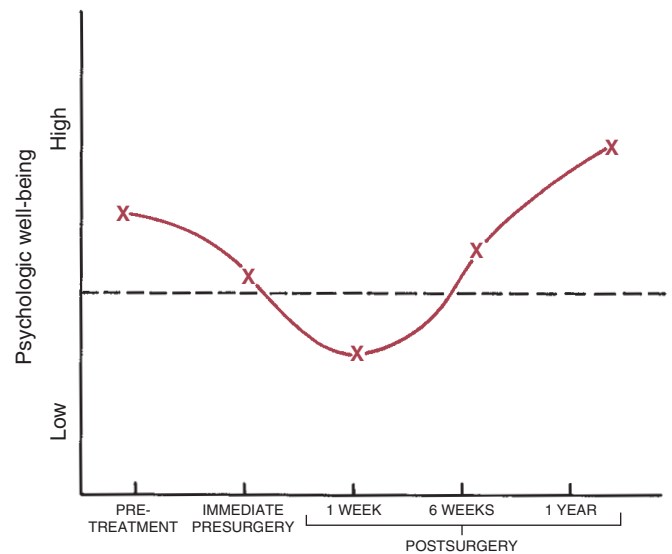
At present, both intrusion of posterior teeth and maxillary protraction during adolescence are appropriate treatment for the less severe skeletal open bite and maxillary deficiency patients—as long as the patient and parents understand that surgical treatment still may be needed because of posttreatment growth.

## Esthetic and Psychosocial Considerations

The negative effect on psychic and social well-being from dentofacial disfigurement is well documented<sup>6</sup> and is why most patients seek orthodontic treatment. Those who look different are treated differently, and this becomes a social handicap. This motivation, not surprisingly, is even stronger in patients with the more severe deviations from the norm that might require orthognathic surgery. If an improvement in appearance is a major goal of treatment, it makes sense that in addition to changes in the jaws and teeth, changes in the nose and perhaps other changes in facial soft tissue contours that could be produced by facial plastic surgery should also be considered in the treatment planning. The integration of orthognathic and facial plastic surgery is a current and entirely rational trend.<sup>7</sup>

The great majority of patients who undergo orthognathic procedures report long-term satisfaction with the outcome (80% to 90%, depending on the type of surgical procedure). A similar number say that, knowing the outcome and what the experience was like, they would recommend such treatment to others and would undergo it again.<sup>8</sup> On long-term recall, patients often comment that the changes produced by their surgical treatment gave them the confidence they needed to succeed in their business or profession.

This does not mean, of course, that there are no negative psychologic effects from surgical treatment. First, a few patients have great difficulty in adapting to significant changes in their



• **Fig. 20.5** A generalized representation of the typical psychologic response to orthognathic surgery, based on the work of Kiyak et al.<sup>20</sup> Before treatment, patients who seek orthognathic surgery tend to have scores above the mean for most psychosocial parameters. Immediately before operation, patients are not quite so positive, as anxiety and other concerns increase. In the days immediately after operation, a period of negativism typically occurs (e.g., depression, dissatisfaction). This is related in part to steroid use at operation and withdrawal afterward but is not totally explained by this. By 6 weeks after operation the patients usually are on the positive side of normal again, and at 1 year typically rate quite high for satisfaction with treatment and general well-being.

facial appearance. This is more likely to be a problem in older individuals. If you are 19, your facial appearance has been changing steadily for all your life, and another change is not a great surprise. If you are 49 and now suddenly see a different face in the mirror, the effect may be unsettling. Psychologic support and counseling therefore are particularly important for older patients, and major esthetic changes in older adults may not be desirable. As we have discussed in [Chapter 19](#), adults seeking treatment fall into two groups: a younger group who seek to improve their lot in life, and an older group whose goal is primarily to maintain what they have. The older group may need orthognathic surgery to achieve their goal, but for them, often treatment should be planned to limit facial change, not maximize it.

Second, whatever the age of the patient, a period of psychologic adjustment following a facial surgical procedure must be expected ([Fig. 20.5](#)). In part, this is related to the use of steroids at operation to minimize postoperative swelling and edema. Steroid withdrawal, even after short-term use, causes mood swings and a drop in most indicators of psychologic well-being. The adjustment period lasts longer than can be explained by the steroid effects, however. The surgeon learns to tolerate complaining patients for the first week or two after surgery. By the time orthodontic treatment resumes at 3 to 6 weeks after operation, the patients are usually—but not always—on the positive side of the psychologic scales. Sometimes the orthodontist also has to wait for a patient to make peace with his or her surgical experience.

In the short term, an important influence on the patient's reaction to surgical treatment is how well the actual experience matched what he or she was expecting. Interestingly, orthognathic



surgery does not rate high on discomfort and morbidity scales. Operations involving the mandibular ramus require about the same amount of pain medication as extraction of impacted wisdom teeth; maxillary procedures are tolerated better than that. From a psychologic perspective, it is not so much the amount of pain or discomfort you experienced that determines your reaction; it is how this compares with what you thought would happen. This highlights the importance of carefully preparing patients for their surgical experience.

### Computer Simulation of Alternative Treatment Outcomes

It always has been a moral and ethical imperative to allow the patient to make important decisions about what treatment he or she will accept, and now it is a legal obligation as well. Involving the patient as decisions about the choice of alternative treatments are made is an essential element of informed consent (see Chapter 7).

Computer image predictions are particularly valuable in helping patients decide between camouflage and surgery and in planning surgical treatment. The patient can view the impact on the soft tissue profile of orthodontic camouflage versus surgery when these are realistic treatment alternatives (Fig. 20.6). He or she also can view the effect of varying amounts of surgical change, not just the change in jaw position—more or less mandibular advancement, for example—but also the effect of genioplasty or rhinoplasty in addition to change in jaw position. Predictions of changes in the frontal view still are more art than science, but current computer prediction programs do a good job of predicting profile changes, and steady improvements continue to occur. It is one thing to describe in words what the different outcomes of camouflage and surgery would be and something else to help the patient visualize them by seeing image predictions.

At one point, there was great concern that showing predictions to patients might lead to unrealistic expectations and disappointment with the actual result, but patient responses show that this risk is minimal or nonexistent. In a randomized trial, those who saw the prediction images before operation were more, not less, likely to be satisfied with their result.<sup>9</sup> Only the patient can decide whether the difference between surgical correction of jaw relationships and orthodontic camouflage would be worth the additional risk and cost of surgery. Computer simulations help them do that.

### Extraction of Teeth and the Camouflage Versus Surgery Decision

The decision for camouflage or surgery must be made before treatment begins because the orthodontic treatment to prepare for surgery often is just the opposite of orthodontic treatment for camouflage. It is a serious error to attempt camouflage on the theory that if it fails, the patient can then be referred for surgical correction. At that point, another phase of “reverse orthodontics” to eliminate the effects of the original treatment will be required before surgery can provide both normal jaw relationships and normal occlusion (Fig. 20.7).

The critical importance of deciding on camouflage or surgery at the beginning of treatment is illustrated by the difference in extractions needed with the two approaches. In camouflage, extraction spaces are used to produce dental compensations for the jaw discrepancy, and the extractions are planned accordingly. For

example, with orthodontic treatment alone, a patient with mandibular deficiency and a Class II malocclusion might have upper first premolars removed to allow the retraction of the maxillary anterior teeth. Extraction in the lower arch would be avoided, and the lower incisors probably would be tipped facially to help reduce the overjet (see Fig. 16.22).

The extraction pattern for a patient with a similar malocclusion but a more severe mandibular deficiency would be quite different if mandibular advancement were planned (see Fig. 20.6). Instead of creating dental compensation for the jaw deformity, the orthodontic treatment now would be planned to remove it. In the upper arch, the position of the incisors relative to the maxilla often is normal or retrusive; if so, upper premolar extraction would be undesirable. Often in mandibular deficiency the lower incisors are protrusive relative to the chin. Then there are two possibilities: extraction in the lower arch to retract them and temporarily increase the overjet so the chin will be brought further forward when the mandible is advanced, or a lower border osteotomy to move the chin forward.

A similar but reversed situation would be seen in a patient with a skeletal Class III problem. If camouflage were planned, typical extractions might be lower first premolars alone, lower first and upper second premolars, or one lower incisor. Surgical preparation of a patient with a Class III problem often requires moving the lower incisors forward and retracting the upper incisors (which may require extraction of upper first premolars) to correct their axial inclinations and increase the reverse overjet (see Fig. 20.7). As a general rule, Class III problems are less amenable to camouflage than Class II issues because retracting the lower incisors may make the chin appear even more prominent—just the opposite of effective camouflage. If space were needed in the lower arch, second rather than first premolar extraction would be a logical choice so that the lower incisors were not retracted.

It obviously is important for the patient who could be treated with either orthodontics or surgery to understand all these considerations in deciding which to choose. Although the patient can and must make the decision, it remains true that some conditions can be treated better with orthodontics alone than others, simply because the impact on facial esthetics is likely to be better. Some characteristics that can make the difference between satisfactory camouflage treatment and camouflage failure are summarized in Box 20.1.

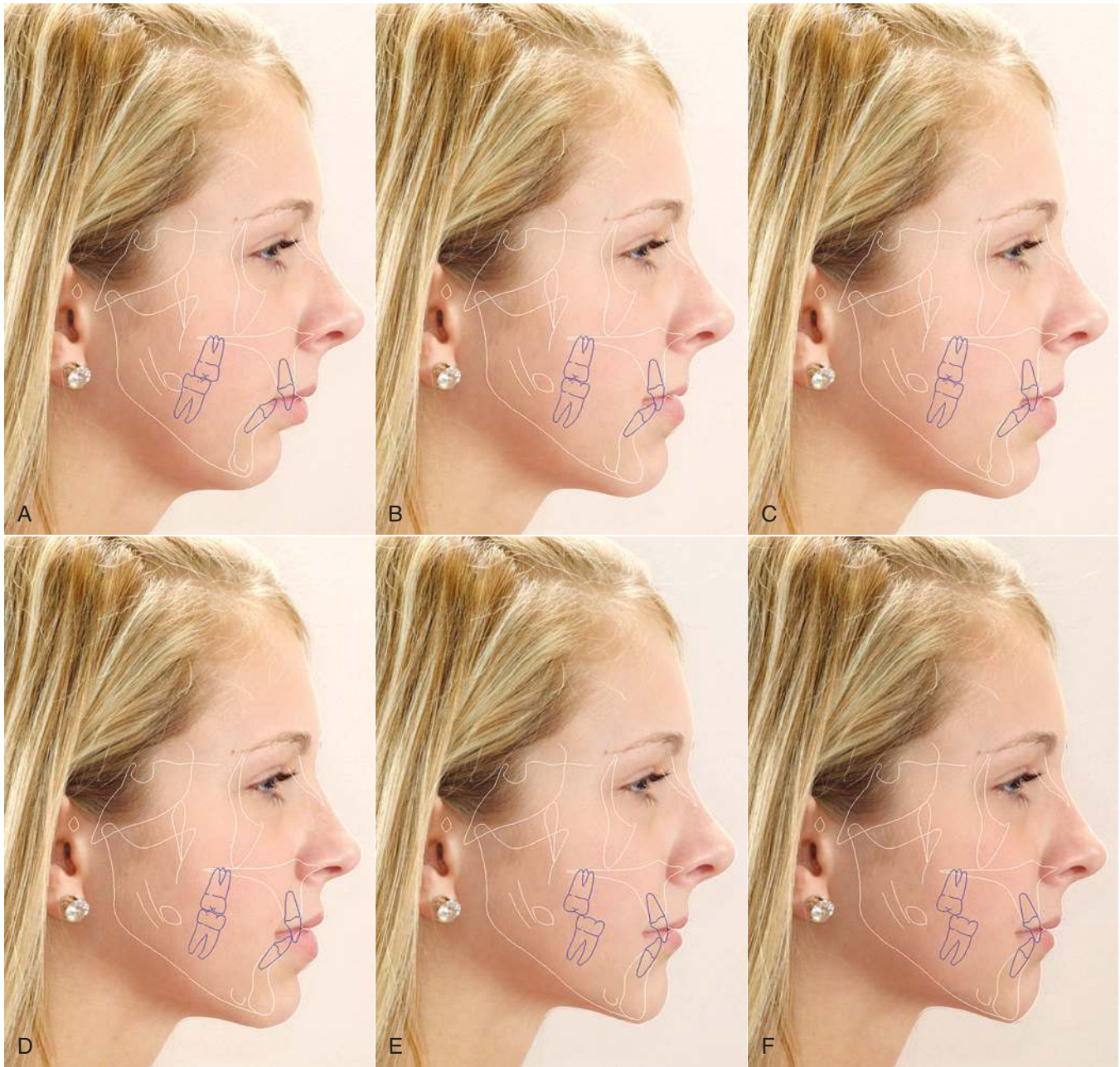#### • BOX 20.1 Orthodontic Camouflage of Skeletal Malocclusion

##### Acceptable Results Likely

- Average or short facial pattern
- Mild anteroposterior jaw discrepancy
- Crowding less than 4 to 6 mm
- Normal soft tissue features (nose, lips, chin)
- No transverse skeletal problem

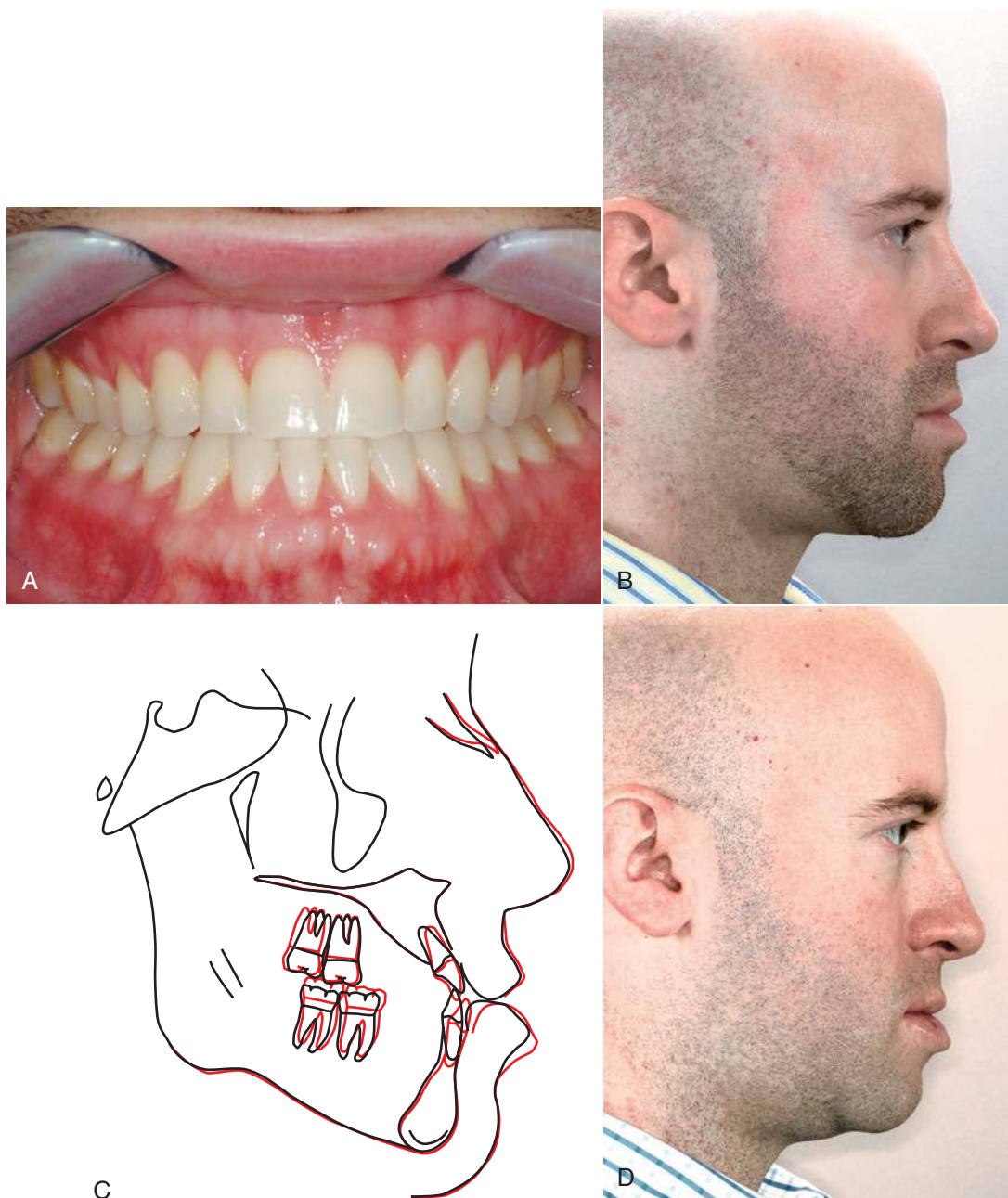##### Poor Results Likely

- Long vertical facial pattern
- Moderate or severe anteroposterior jaw discrepancy
- Crowding greater than 4 to 6 mm
- Exaggerated features
- Transverse skeletal component of problem



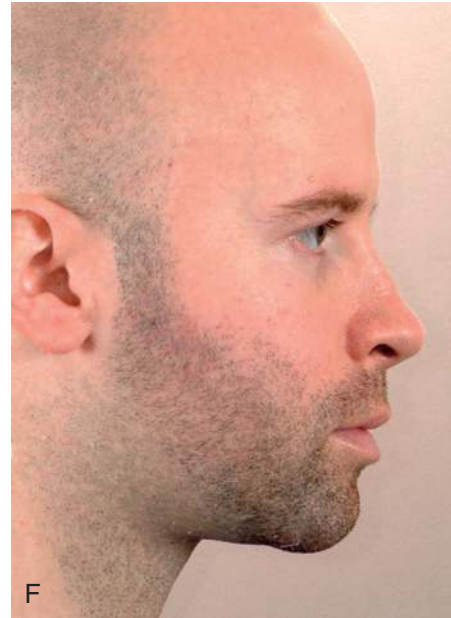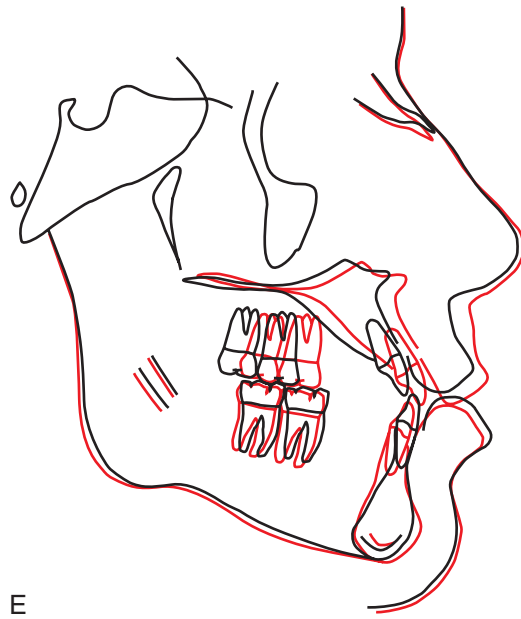
• **Fig. 20.6** Surgical predictions for a patient with mild maxillary retrusion, severe mandibular deficiency, and inadequate projection of the chin. (A) The initial tracing linked to the profile photograph. (B) Simulation of 5 mm of mandibular advancement, an amount of advancement corresponding to the initial overjet. (C) Five millimeters of mandibular advancement plus genioplasty to improve chin projection relative to the lower incisor. (D) Six millimeters of maxillary advancement, 11 mm of mandibular advancement, and rhinoplasty. The maxilla was advanced to increase support of the upper lip and allow for greater mandibular advancement. (E) Preoperative retraction of the lower incisors after lower premolar extraction, creating more overjet and allowing a 9-mm mandibular advancement. (F) Retraction of lower incisors, 9 mm of advancement, and rhinoplasty. The rhinoplasty changes were subtle, and rhinoplasty was not recommended. After the patient and her parents viewed the simulations and discussed them with the orthodontist, (E) was selected as the plan.



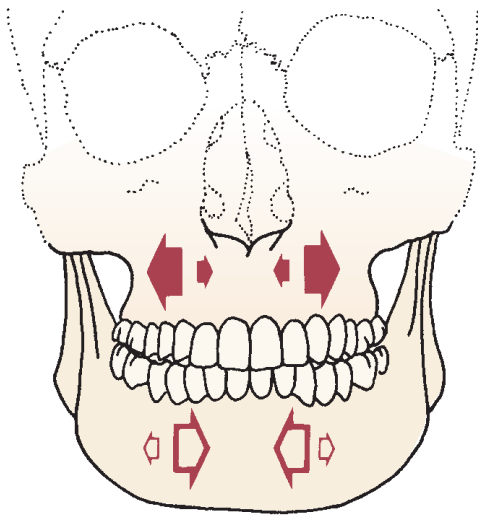


• **Fig. 20.7** (A) This man, who had undergone previous orthodontic treatment to correct his Class III malocclusion, now has minimal reverse overjet but (B) an obvious maxillary deficiency and prominent chin on profile view. This is a Class III camouflage failure as determined by the patient himself, who sought further treatment to improve his facial appearance. The treatment plan was presurgical orthodontics to remove the dental compensation created in the previous treatment, retracting the maxillary incisors and proclining the lower incisors to create reverse overjet similar to what he had before the original orthodontic treatment. (C) The superimposition tracing shows the presurgical changes. (D) The facial appearance before operation. The “reverse orthodontics” has temporarily made his appearance worse.





• **Fig. 20.7, cont'd** (E) Cephalometric superimposition showing the changes created by maxillary advancement surgery. (F) The profile at the end of treatment, with the jaw relationship now corrected.



• **Fig. 20.8** The surgical movements that are possible in the transverse dimension are shown on this illustration of the lower face skeleton. The solid arrows indicate that the maxilla can be expanded laterally or constricted with reasonable stability. The smaller size of the arrows pointing to the midline represents the fact that the amount of constriction that is possible is less than the possible amount of expansion. The only transverse movement easily achieved in the mandible is constriction, although limited expansion now is possible with distraction osteogenesis.

## Contemporary Surgical Techniques

The possible jaw movements with orthognathic surgery are shown diagrammatically in [Figs. 20.8](#) and [20.9](#). As the figures illustrate, both jaws can be repositioned three dimensionally, but not all directions of movement are feasible. The mandible can be moved forward or backward, rotated, and moved down anteriorly to increase

the mandibular plane and anterior face height—but rotating it up with a ramus osteotomy to decrease the mandibular plane angle and decrease anterior face height will create instability unless the maxilla is moved up posteriorly at the same time so that this rotation does not lengthen the ramus and stretch the elevator muscles. The mandible can be narrowed anteriorly but widened only with distraction osteogenesis (discussed later).

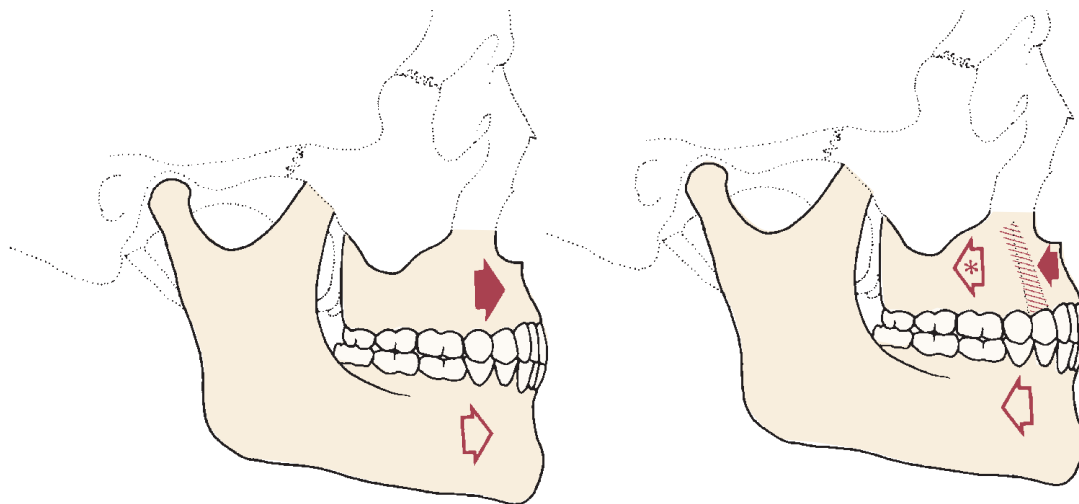
The maxilla can be moved up and forward with excellent stability, moved down with difficulty because of instability, and moved back only with great difficulty because of all the structures behind it that are in the way. Fortunately, protruding anterior teeth can be moved back via segmental osteotomy, so there is no reason to move the posterior maxilla back. Segmental osteotomy also allows the maxilla to be widened or narrowed, but widening it tends to be unstable because of the pull of stretched palatal tissues.

## Mandibular Surgery

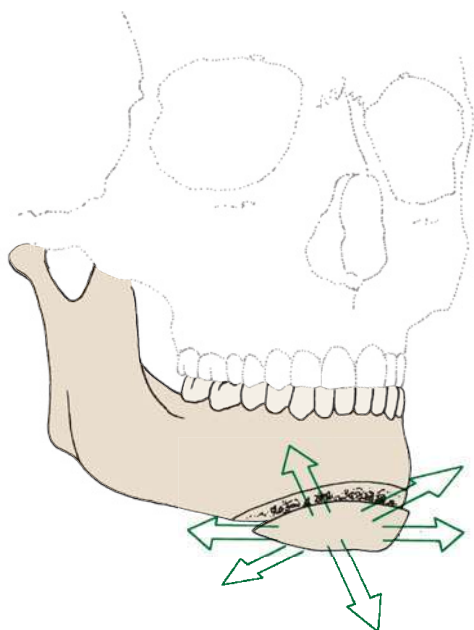
The sagittal split osteotomy (see [Fig. 20.2](#)) now is used for almost all mandibular surgery because of several advantages over alternative techniques for ramus surgery:

- The mandible can be moved forward or back as desired, and the tooth-bearing segment can be rotated down anteriorly (increasing the mandibular plane angle) when additional anterior face height is desired.
- This procedure is quite compatible with the use of rigid intraoral fixation (RIF), so immobilization of the jaws during healing is not required.
- Excellent bone-to-bone contact after the osteotomy means that problems with healing are minimized, and postsurgical stability is good.

In contemporary treatment, a lower border osteotomy of the mandible to reposition the chin relative to the mandibular body ([Fig. 20.10](#)) is a major adjunct to ramus procedures, especially when the mandible is advanced. It is used in about 30% of the



• **Fig. 20.9** The maxilla and mandible can be moved anteriorly and posteriorly as indicated by the red arrows in these line drawings. Anterior movements of the mandible greater than approximately 10 mm create considerable tension in the investing soft tissues and tend to result in increasing instability with greater advancement. Anterior movement of the maxilla is similarly limited to 6 to 8 mm in most circumstances; the possibility of relapse or speech alteration from nasopharyngeal incompetence increases with larger movements. Posterior movement of the entire maxilla, although possible, is difficult and usually unnecessary. Instead, posterior movement of protruding incisors up to the width of a premolar is accomplished by removal of a premolar tooth on each side, followed by segmentation of the maxilla. The major limitation of posterior movement of the mandible is its effect on the appearance of the throat. When the mandible is moved back, the tongue moves down as the airway is maintained, and a “turkey gobbler” prominence appears below the chin.



• **Fig. 20.10** The chin can be sectioned anterior to the mental foramen and repositioned in all three planes of space. The lingual surface remains attached to muscles in the floor of the mouth, which provide the blood supply. Moving the chin anteriorly, upward, or laterally usually produces highly favorable esthetic results. Moving it back or down may produce a “boxy” appearance.

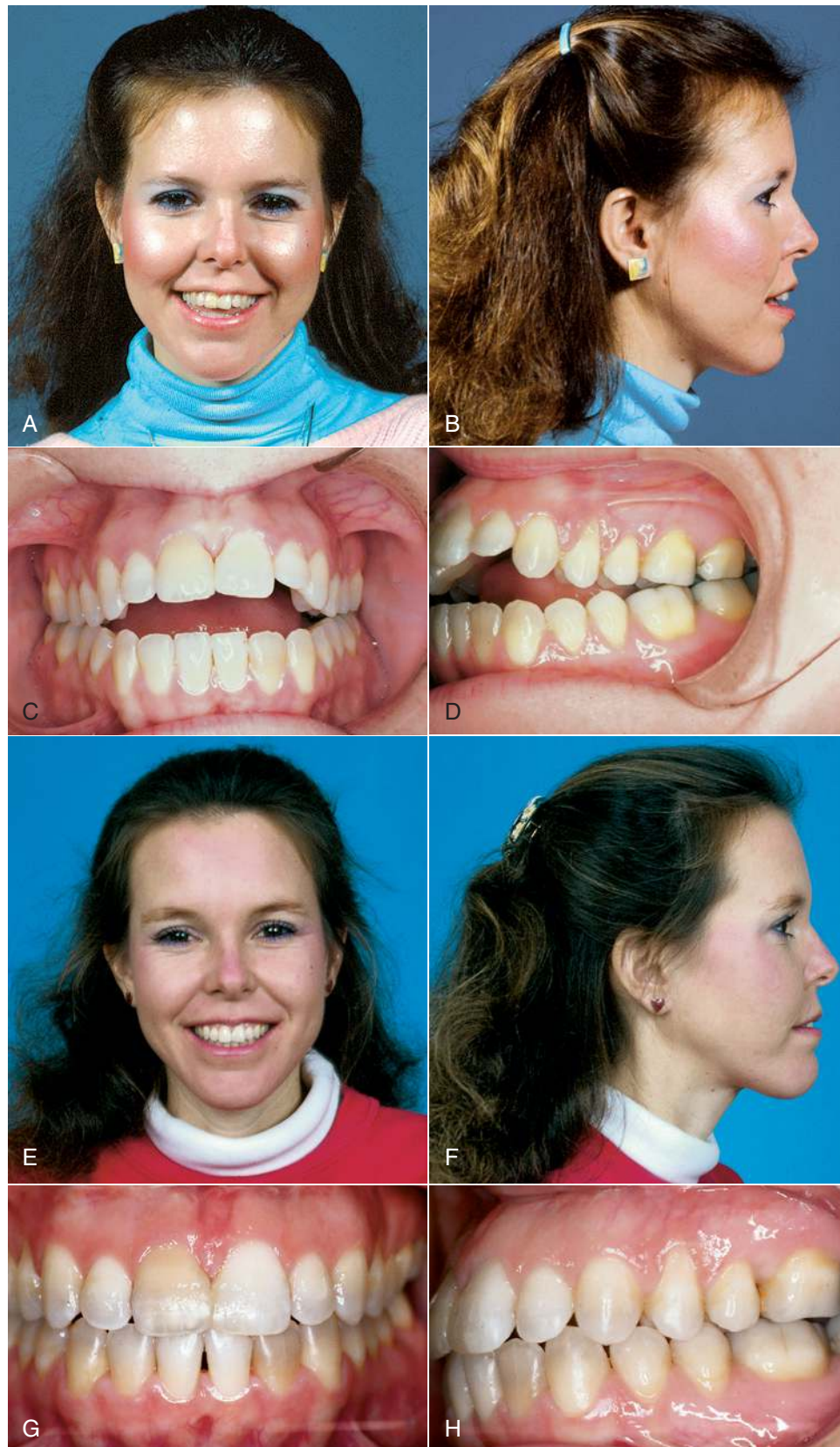patients who receive a ramus osteotomy and in about the same number of patients with maxillary surgery. The lower border procedure allows the chin to be moved transversely, forward or back, and up or down.

Other mandibular procedures are used primarily for major advancements or surgery involving the condyles. An extraoral approach often is required, and a bone graft is likely to be needed. Rarely, a midline osteotomy of the mandible with removal of an incisor is used to narrow it anteriorly.<sup>10</sup>

## Maxillary Surgery

The Le Fort I osteotomy with downfracture of the maxilla (see Fig. 20.3) dominates contemporary maxillary surgery just as the sagittal split dominates mandibular surgery. It allows the maxilla to be moved up and/or forward with excellent stability. Moving the entire maxilla back is quite difficult because of the structures behind it, but this is not necessary when the upper teeth are protrusive. A segmental osteotomy, closing the space where a premolar was extracted, allows the anterior teeth to be retracted and posterior teeth to be moved superiorly so that anterior open bite is closed as the mandible rotates upward and forward (Fig. 20.11). Segmental osteotomies also allow the posterior maxilla to be widened or (less frequently) narrowed.

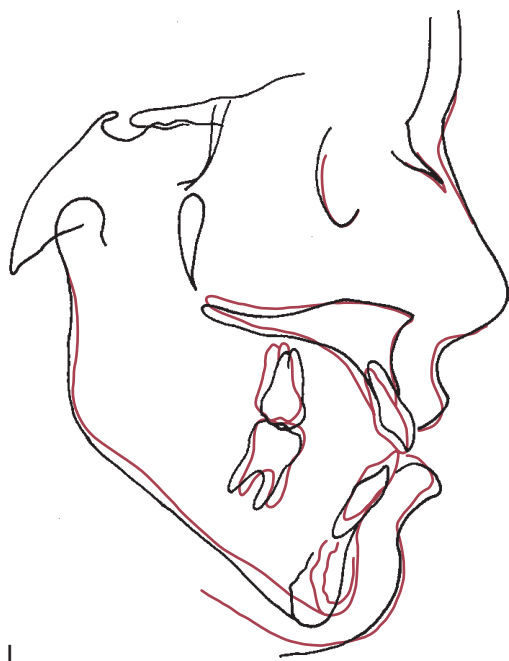Expansion is done with parasagittal osteotomies in the lateral floor of the nose or medial floor of the sinus that are connected by a transverse cut anteriorly. In a two-piece osteotomy, a midline extension runs forward between the roots of the central incisors; this may or may not be included in a three-piece osteotomy (Fig. 20.12). If constriction is desired, bone is removed at the



• **Fig. 20.11** Superior repositioning of the maxilla is indicated to correct severe anterior open bite if the lower facial third is long, as in this patient. (A and B) Facial proportions and (C and D) occlusal relationships before treatment. (E and F) Facial proportions and (G and H) occlusal relationships after segmental Le Fort I osteotomy to move the maxillary posterior segments up and the anterior segment down, steepening the occlusal plane. This allowed the mandible to rotate up and forward to close the open bite while providing better incisor display.

*Continued*



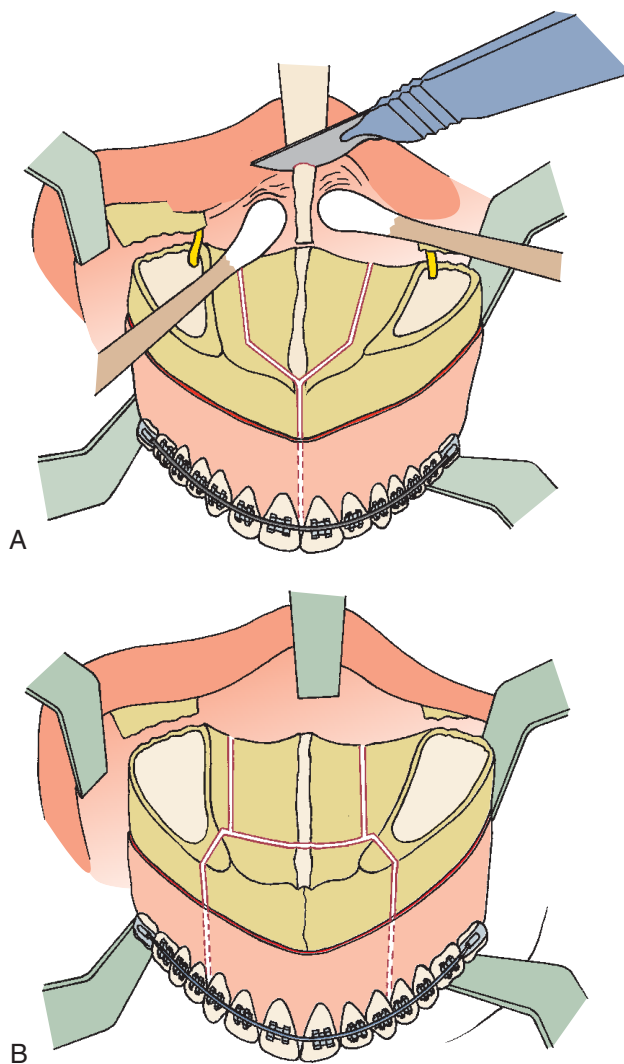


• **Fig. 20.11, cont'd** (I) Cephalometric superimposition showing the repositioning of the maxillary segments and the decrease in anterior face height. When the posterior maxilla is repositioned vertically, both the postural (rest) and occlusal positions of the mandible change.

parasagittal osteotomy sites. In expansion, either bone harvested in the downfracture or bank bone is used to fill the void created by lateral movement of the posterior segments.

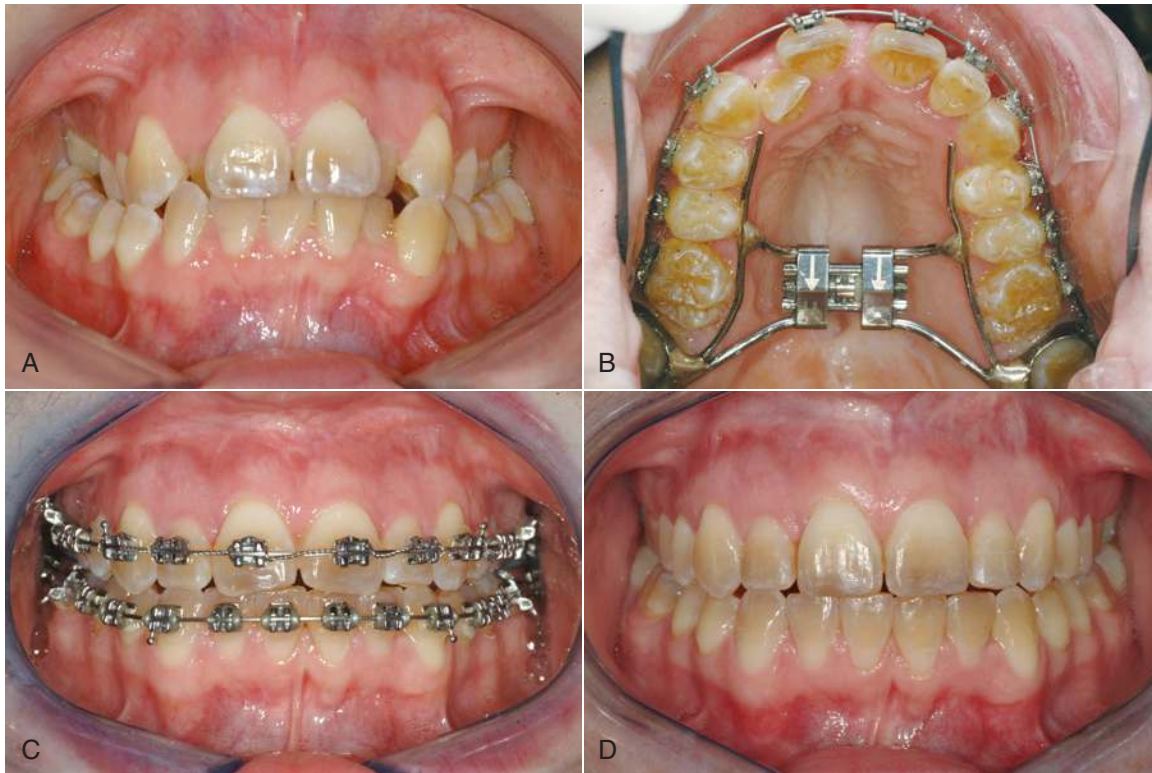Orthopedic palatal expansion of the type used in adolescents is not feasible in adults because of the increasing resistance from interdigitated midpalatal and lateral maxillary sutures, although recent studies have shown that a small increase in maxillary width still can be achieved when palatal anchorage is used (see [Chapter 19](#)). Surgically assisted rapid palatal expansion (SARPE), using bone cuts to reduce the resistance followed by expansion of the jackscrew to separate the halves of the maxilla, is another possible treatment approach for adult patients with a narrow maxilla ([Fig. 20.13](#)). The original idea of surgically assisted expansion was that cuts in the lateral buttress of the maxilla would decrease resistance to the point that the midpalatal suture could be forced open (i.e., microfractured) in older patients. Although this usually works in patients in their late teens or early 20s, the chance of inadvertent fractures in other areas is a concern, especially for patients in their 30s or older. For SARPE now, surgeons usually make all the cuts needed for a Le Fort I osteotomy, omitting only the final step of downfracture.<sup>11</sup> This allows widening of the maxilla against only soft tissue resistance, manipulating the osteotomy sites with what amounts to distraction osteogenesis. If only expansion is desired, this provides a somewhat less invasive approach than segmental osteotomy. Unfortunately, however, there is no guarantee of symmetric expansion—one of the main disadvantages of this procedure.

The implication of SARPE is that the problem affects only the transverse plane of space, and this is when it is most useful. One of its purported advantages over segmental osteotomy was better stability, and some surgeons advocated a preliminary phase of SARPE before Le Fort I osteotomy to move the maxilla

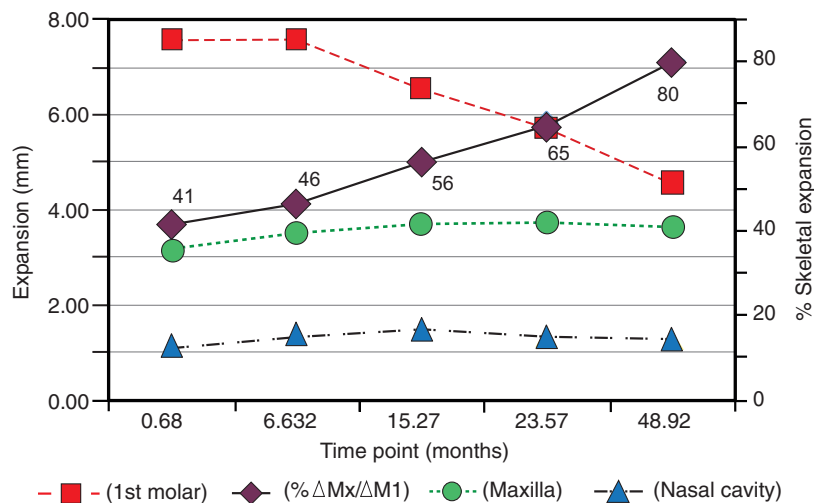


• **Fig. 20.12** (A) The location of lateral para-midline and anterior midline interdental osteotomies to widen the maxilla in two pieces and resection of cartilage of the nasal septum so that the maxilla can be moved up are shown in this view of the maxilla in a downfractured position during Le Fort I osteotomy. A major advantage of Le Fort I osteotomy over surgically assisted transverse expansion is that the maxilla can be repositioned in all three planes of space rather than just transversely. (B) The location of lateral para-midline and anterior interdental osteotomies for a three-piece maxilla. This allows widening posteriorly and differential vertical movement of the anterior and posterior segments. (From Proffit WR, White RP, Sarver DM. *Contemporary Treatment of Dentofacial Deformity*. St. Louis: Mosby; 2003.)

anteroposteriorly or vertically. Current data, however, show that relapse of the dental expansion accompanies SARPE ([Fig. 20.14](#)) and that its long-term stability is similar to that with segmental osteotomy.<sup>12</sup> It is difficult, therefore, to justify the additional cost and morbidity of surgically assisted expansion as a first stage of surgical treatment in a patient who would require another operation later to reposition the maxilla in the anteroposterior or vertical planes of space. The primary indication for preliminary SARPE is such severe maxillary constriction that segmental expansion of the maxilla in the Le Fort I procedure might compromise the blood supply to the segments.



• **Fig. 20.13** In this adult patient with maxillary posterior crossbite and severe crowding, surgically assisted rapid palatal expansion (SARPE) was used to allow transverse expansion that otherwise would not have been possible. The modern surgical technique includes all the bone cuts for a Le Fort I osteotomy except the downfracture. (A) Narrow maxillary arch, posterior crossbite, and maxillary incisor crowding before treatment. (B) Expansion appliance in place after operation and activation of the screw over a period of 4 days after a brief latency period, showing the amount of expansion that was obtained. (C) Fixed appliance for completion of alignment. A compressed coil spring that was used to open space for the maxillary left lateral incisor after the palatal expansion was removed 3 months after operation. (D) Widening the maxilla corrected the posterior crossbite and provided space to align the incisors, which made it possible to plan later cosmetic restoration of these stained teeth.



• **Fig. 20.14** Changes in the dental and skeletal dimensions over time after surgically assisted rapid palatal expansion (SARPE) and in the percentages of skeletal versus dental expansion. Squares indicate expansion at the first molar, diamonds indicate percentages of skeletal expansion at each time point, circles indicate maxillary skeletal expansion, and triangles indicate expansion across the nasal cavity. Note that almost all relapse was dental rather than skeletal; the change in the percentage of skeletal change is shown on the right vertical axis. Repeated-measures analysis of variance confirmed a significant relationship between the amount of dental relapse and the time after operation, whereas skeletal changes were stable and unaffected by time after operation. (Redrawn from Chamberland S, et al: *Am J Orthod Dentofac Orthop.* 2011;139:815–822.)



## Dentoalveolar Surgery

### Recovery From Inadvertent Tooth Movement

Although it is not orthognathic surgery, it is part of orthodontic management of patients to include coordinated periodontal surgery to help with correction of malposed tooth roots, which can happen when teeth undergo unplanned tooth movement after archwires or fixed retainers break or are distorted (see Fig. 18.15). Induction of new bone formation now is possible with local bone-stimulating hormone therapy and bone grafts so that when displaced roots are repositioned into the alveolar process with torque force, root fenestration can be corrected as well (Fig. 20.15). This requires close coordination between the periodontist and orthodontist.

### Repositioning Alveolar Segments

Segments of the dentoalveolar process can be repositioned surgically in all three planes of space (Fig. 20.16), but there are important limitations with this procedure. The principal one is the distance of movement that is possible: in most instances, only a few millimeters. A significant but less important limitation is the size of the segment: a three-tooth or larger segment is preferred, a two-tooth segment is acceptable but less predictable, and a one-tooth segment is a problem waiting to occur.

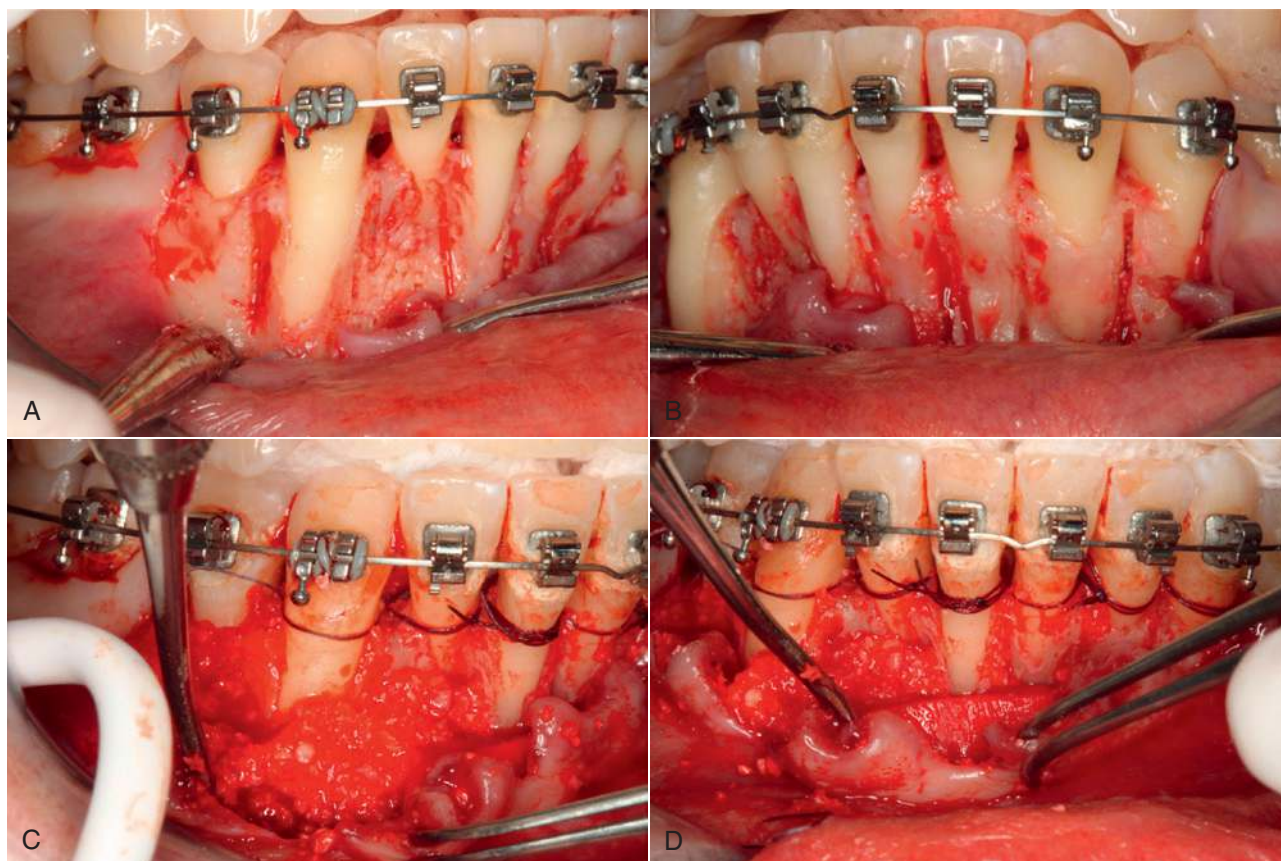
The reason for both limitations is the same. After an osteotomy beneath the bone segment and teeth, the blood supply is the

surprisingly good collateral circulation via the facial and lingual mucosa. This must be preserved to maintain the vitality of the teeth and the integrity of the bone. The further a segment is moved and the smaller it is, the greater the chance of interrupting not only the usual blood supply but also the collateral supply.

An osteotomy below the root apices cuts the nerves to the pulp of the teeth in that segment, and of course there is no collateral innervation. The short-term result is something that dentists rarely observe: a vital but denervated pulp that does not respond to electrical stimulation. At that point, pulp vitality can be demonstrated by the maintenance of either normal pulp temperature (temperature probe) or blood flow (Doppler flow meter), and re-innervation of the pulp often occurs after a few months. Even though the major vessels to the tooth pulp are cut, less than 2% of the involved teeth require endodontic treatment. Even if the apex of a tooth is inadvertently cut off, pulp vitality is likely to be maintained by blood flow through auxiliary foramina.

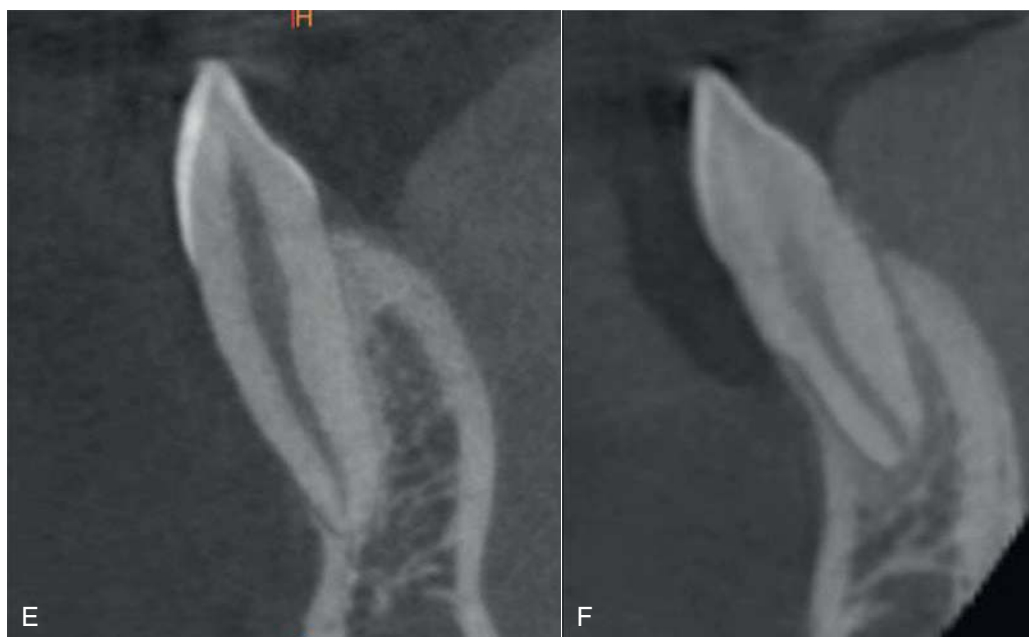### Distraction Osteogenesis

Distraction osteogenesis is based on manipulation of a healing bone, stretching an osteotomized area before calcification has occurred to generate the formation of additional bone and investing soft tissue (see Chapter 13). For correction of facial deformities, this has two significant advantages and one equally significant disadvantage.

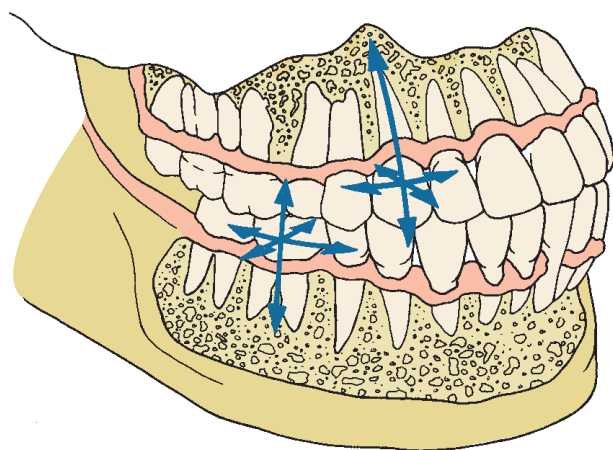


• **Fig. 20.15** (A) Severe root torque and bone fenestration after inadvertent tooth movement from a distorted bonded lingual retainer. (B) Periodontal treatment involved a gingival flap to expose the fenestrated roots and corticotomy cuts to accelerate bone remodeling, then (C) a bone graft slurry to cover the roots and (D) covering of the area as the gingiva was sutured into position.





• **Fig. 20.15, cont'd** (E) A small-field-of-view three-dimensional image showing the original position of the right canine outside the bone of the root (shown also in A). (F) Active root torque with orthodontic treatment that started immediately after the periodontal surgical procedure succeeded in getting the root back into the alveolar process, and the image shows bone over the lower half of the facial surface of the tooth. (Courtesy Dr. T. Shaughnessy.)



• **Fig. 20.16** The key to surgery to reposition dentoalveolar segments is maintaining an adequate blood supply to the bone and teeth through intact labial or lingual mucosa. In the mandibular posterior area, temporarily lifting the inferior alveolar neurovascular bundle out into the cheek allows cuts to be made safely beneath the teeth. Although the nerve supply to the teeth is interrupted, sensation usually returns and endodontic treatment almost never is required. (From Proffit WR, White RP, Sarver DM. *Contemporary Treatment of Dentofacial Deformity*. St. Louis: Mosby; 2003.)

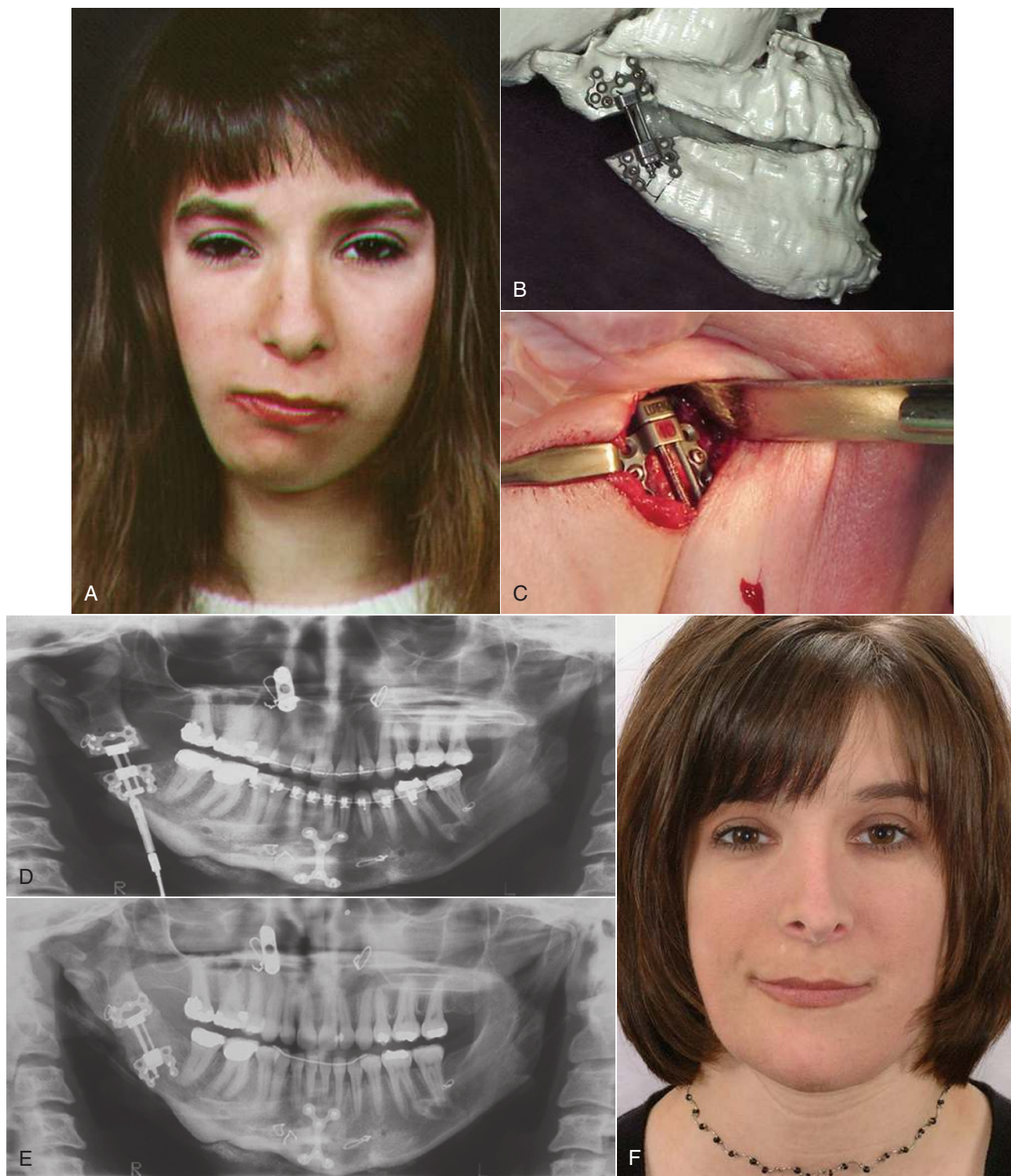The advantages of distraction are that (1) larger distances of movement are possible than with conventional orthognathic surgery and (2) deficient jaws can be increased in size at an earlier age. The great disadvantage is that precise movements are not possible. With distraction, the mandible or maxilla can be moved forward, but there is no way to position the jaw or teeth in exactly a

preplanned place, as can be done routinely with orthognathic procedures. This means that patients with craniofacial syndromes are the prime candidates for distraction of the jaws. They are likely to need intervention at early ages and large distances of movement, and precision in establishing the posttreatment jaw relationship is not so critical for them.

Moderately severe hemifacial microsomia, in which a rudimentary ramus is present on the affected side, is a major indication for distraction because it is the only way to generate new bone to replace the missing part (Fig. 20.17). Distraction is not needed in the milder forms of this syndrome in which mandibular asymmetry exists but the mandible is reasonably complete (for these patients, growth modification is possible), and it cannot be used as the initial stage of treatment in patients so severely affected that the entire distal portion of the mandible is absent. For them, a bone graft is necessary, and distraction later can be one way to lengthen the graft.

The timing of treatment for patients with moderately severe hemifacial problems remains controversial, but social acceptability becomes a factor in the decision. To improve the child's facial appearance, intervention to advance the mandible on the affected side often is considered at ages 6 to 8, and at that time both of its advantages make distraction a frequent choice. Early distraction, however, is unlikely to be followed by normal growth of the distracted area, and later orthognathic surgery or a second round of distraction probably will be required.

Patients with facial syndromes that include severe maxillary deficiency (e.g., Crouzon, Apert; see Fig. 5.11) also are candidates for early distraction. In these patients, appropriate bone cuts in the posterior and superior areas of the maxilla can allow advancement of the entire midface, similarly to what can be achieved with Le Fort III surgery but without the need for extensive bone grafts. For patients with problems of this type, the precision with which



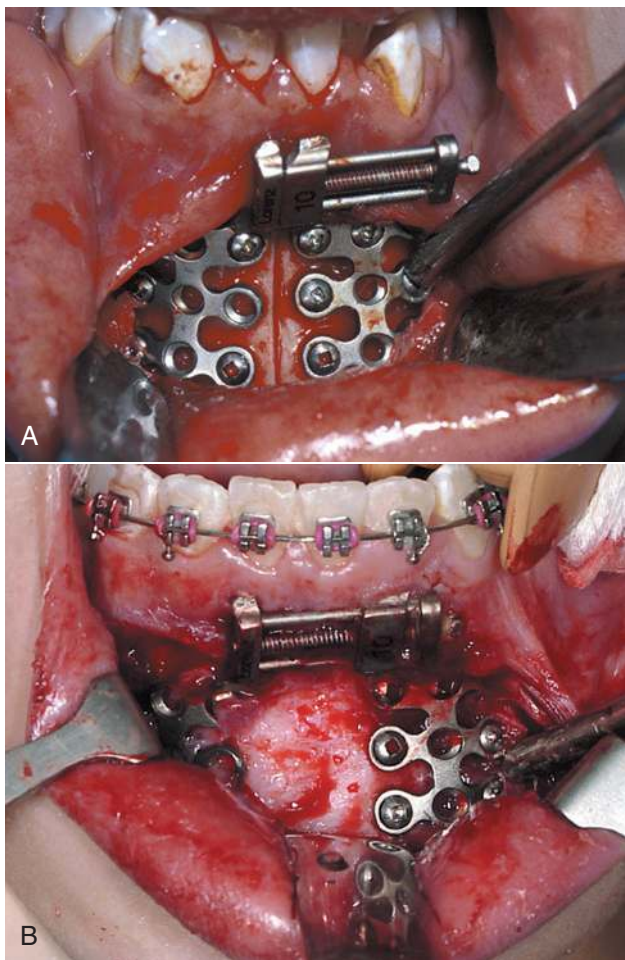
• **Fig. 20.17** Distraction osteogenesis to lengthen the deficient mandibular ramus in a girl with hemifacial microsomia. (A) Facial appearance before treatment. (B) Distractor fitted on stereolithographic models made from a computed tomography scan. (C) Distractor placed at operation. After the device is in place, cuts are made through the cortical bone of the mandible, and activation of the distractor begins after a latency period to allow initial healing. (D) Panoramic view during distraction showing the opening created by stretching of the healing bone callus. (E) Panoramic view 3 months later, at the end of the postdistraction stabilization period during which the newly formed bone is remodeled and becomes normally calcified. (F) Facial appearance at the completion of treatment. Creating new mandibular bone with distraction, as a general rule, is more effective than placing bone grafts, but distraction cannot be used to replace grafts in all circumstances. (Courtesy Dr. C. Crago.)



the teeth can be placed in proper occlusion simply becomes a secondary consideration. The fact that later orthodontic and surgical treatment will be required reinforces this attitude toward the initial treatment.

For less severe maxillary or mandibular deficiency, however, distraction offers no advantage over a sagittal split or Le Fort I osteotomy, and after a period of initial enthusiasm about treatment of these patients, it is almost never used now. The orthognathic procedures allow the teeth and jaws to be precisely positioned, and an excellent clinical result can be anticipated. For these patients, distraction is a more difficult way to accomplish a surgical result that requires more extensive postsurgical orthodontics.

One of the things that cannot be done with orthognathic surgery is widening the mandibular symphysis, because there is not enough soft tissue to cover a bone graft in that area. Distraction makes this possible (Fig. 20.18) and provides additional space in the incisor area. Does that make it an acceptable method for nonextraction treatment of lower incisor crowding? Usually, no.



• **Fig. 20.18** Mandibular symphysis distraction to provide greater width to the anterior mandible. (A) Placement of the distraction device. After the device has been contoured to fit and screwed in place, cuts are made through the facial and lingual cortical plates of the mandible, usually extending all the way through the symphysis. Distraction begins after a 5- to 7-day latency period, with the screw activated 2 turns (0.5 mm) twice a day. (B) Intraoperative view when the distractor was removed 16 weeks after the initial surgical procedure. Note the normal appearance of the regenerate bone across the distraction site. (Courtesy Dr. C. Crago.)

When crowded incisors are aligned with orthodontic expansion, this is accomplished at the expense of incisor protrusion and doubtful stability, especially if mandibular canines are expanded without also retracting them. The important clinical questions therefore are whether symphysis distraction provides a more stable and less protrusive result than nonextraction orthodontics, and whether either approach to expanding the mandibular dental arch gives a better result than premolar extraction to provide space for alignment.

With distraction at the symphysis, not only osteogenesis (formation of new bone) but also histogenesis (formation of new soft tissue) occurs. The formation of new periosteum over the distracted area is what makes widening of the symphysis possible. To relieve lip and cheek pressure against expanded mandibular canines, however, soft tissue changes would have to extend to the muscles of facial expression at the corners of the mouth. To date, there is no evidence that expansion with distraction is more stable than conventional expansion, and given the distance from the osteotomy site to the soft tissues at the corner of the mouth, it seems unlikely that this would be the case. As with distraction for mandibular advancement, symphysis distraction has been abandoned except for patients with what amounts to a midline cleft, with both missing incisors and the bone to support them (see Fig. 13.12).

### Adjunctive Facial Procedures

A variety of adjunctive facial procedures can be used as adjuncts to orthognathic surgery to improve the soft tissue contours beyond what is available from repositioning the jaws.<sup>13</sup> Conceptually, this can be viewed as a form of camouflage, done surgically rather than orthodontically. These procedures can be put into five groups: chin augmentation or reduction, rhinoplasty, facial soft tissue contouring with implants, lip procedures, and submental procedures. We will consider them briefly, in turn.

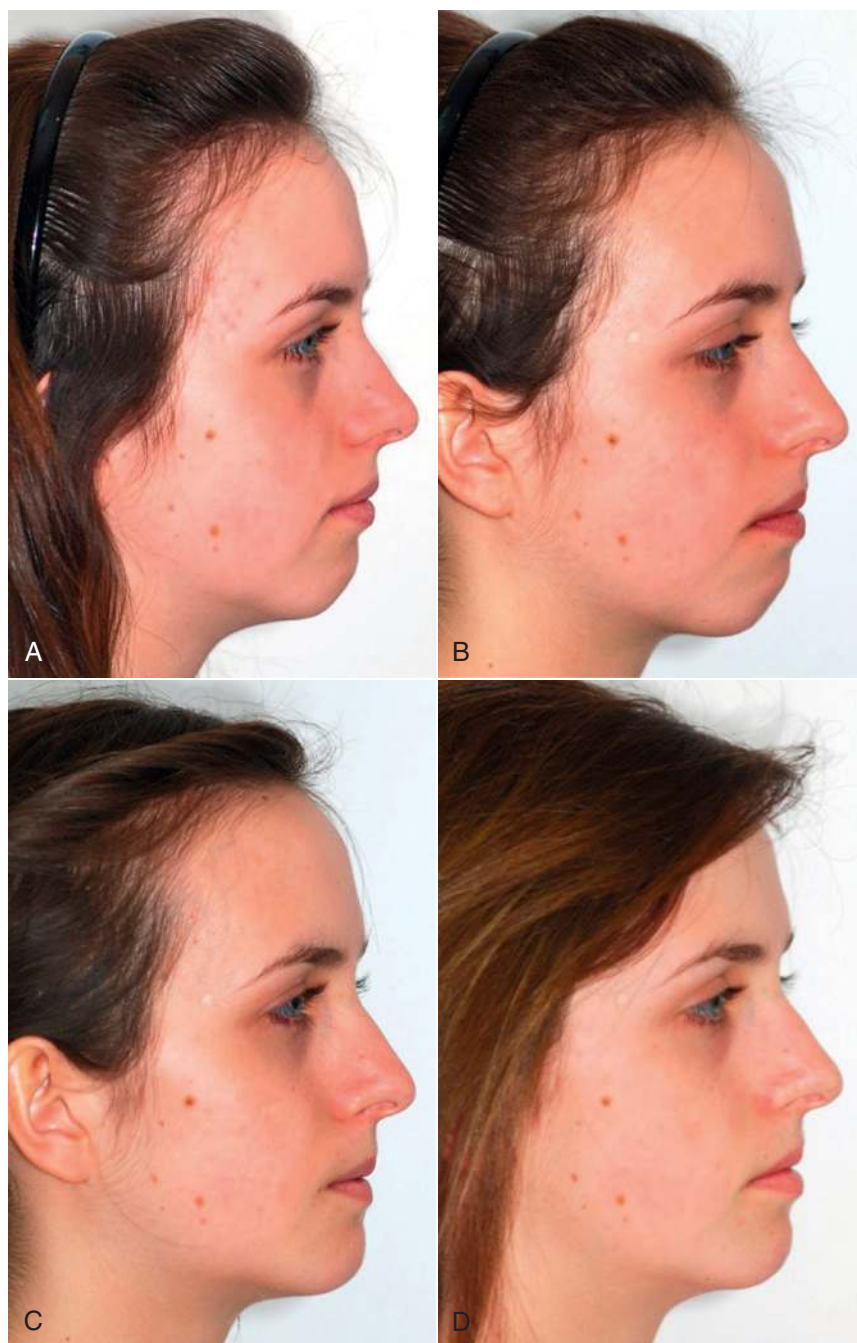#### Chin Augmentation or Reduction

There are two approaches to repositioning the chin relative to the rest of the mandible: a lower border osteotomy to slide it to its new location or (augmentation only) placement of an alloplastic implant.

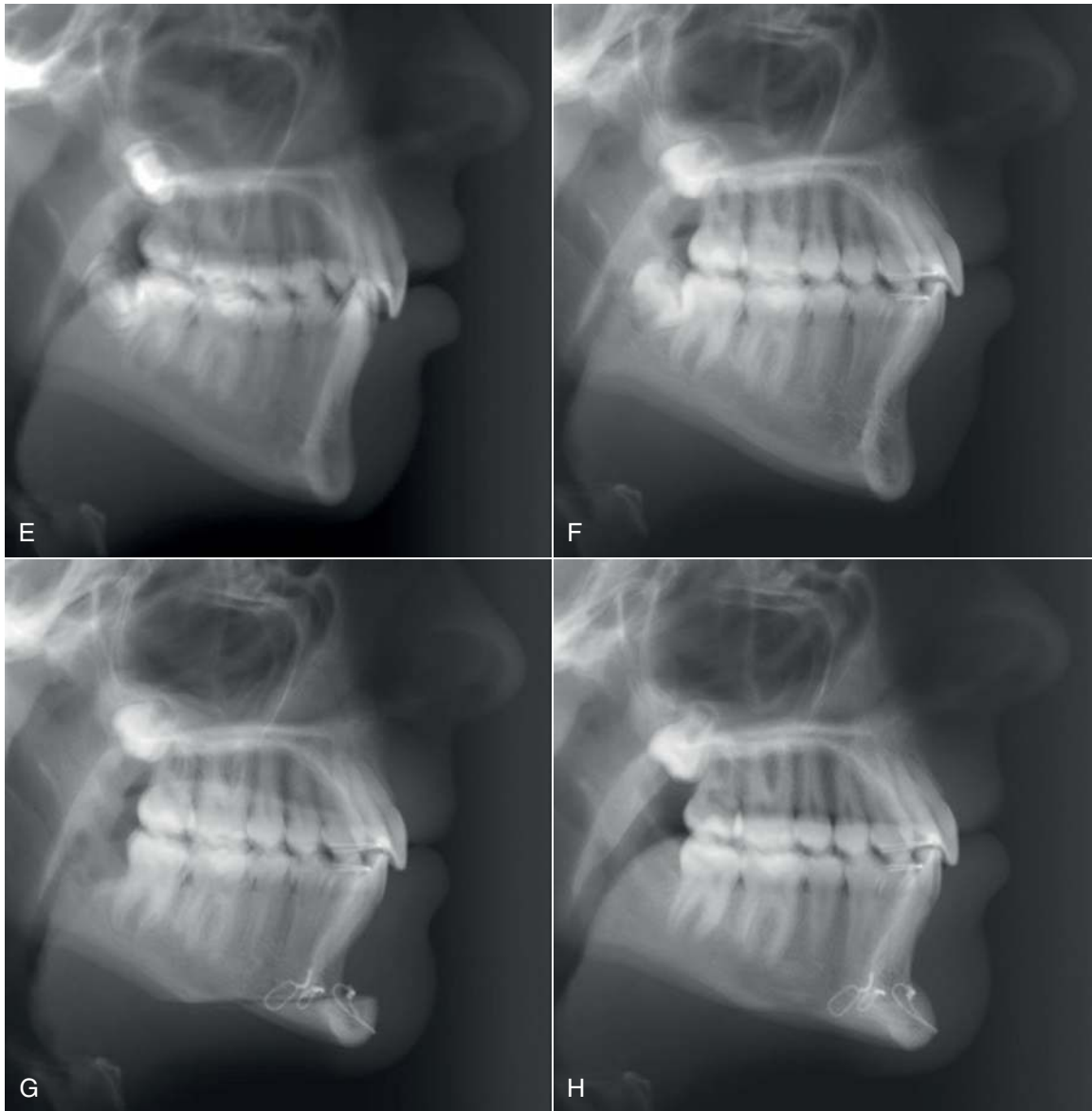
The lower border osteotomy to advance the chin has the advantages of well-documented predictability and stability, and (because it advances the genial tubercles) it tightens the suprahyoid musculature and produces desirable changes in chin–neck contour. It is particularly advantageous in patients with a combination of vertical excess and anteroposterior deficiency, which results in strain to bring the lips together. Sliding the chin upward and forward in patients with this facial pattern is a “functional genioplasty,” in that it allows normal lip function as well as correction of the facial disproportion (Fig. 20.19).<sup>14</sup> Bone remodeling thickens the alveolar process below the teeth, and the notch above the repositioned chin fills in with new bone that extends up to the alveolar crest, creating new bone in an area where it is needed for future gingival stability (Fig. 20.20). In later periodontal therapy to control gingival stripping, that area often is bone grafted.

Functional genioplasty, and augmentation with sliding of the chin forward more generally, are more successful when done before age 15 (Fig. 20.21), so this is just the opposite of an orthognathic procedure that should wait until growth is essentially completed. The more the lower incisors erupt after the genioplasty, the better the formation of new bone above the displaced chin. How early can it be done? The practical limit is eruption of the mandibular





• **Fig. 20.19** (A to D) Profile and (E to H) cephalometric images of a patient who benefited from functional genioplasty after orthodontic treatment to correct her Class II malocclusion. This provides not only improved facial proportions but also normalization of lip function, decreasing lip separation at rest and allowing the lips to be brought into contact without muscle strain. (Courtesy Dr. S. Chamberland.)



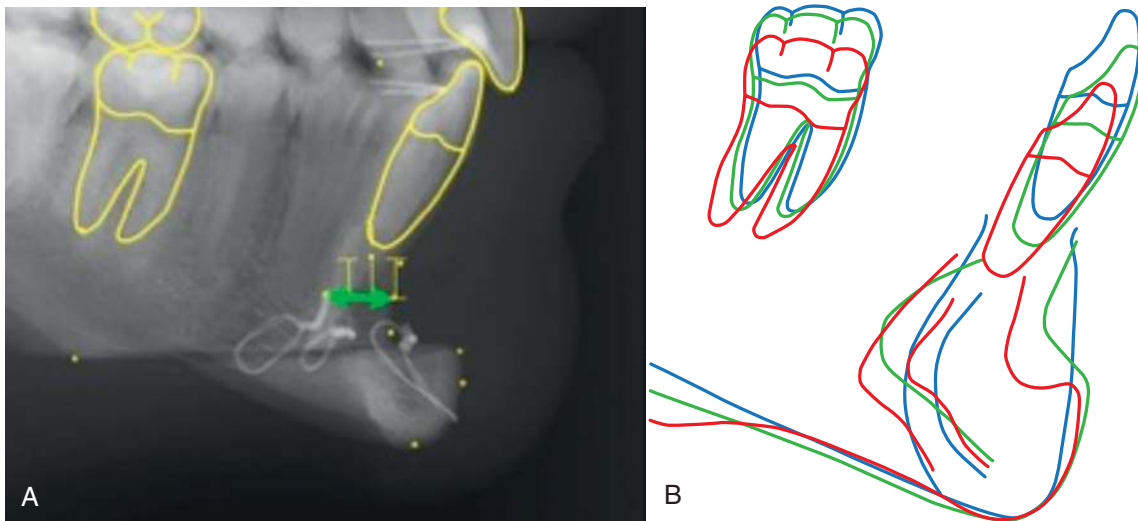
• Fig. 20.19, cont'd

canines, which would be in the way of the osteotomy until they have moved into the oral cavity. Bone remodeling occurs above and behind the repositioned chin, but the bony chin does not remodel and is remarkably stable over time. Augmentation genioplasty with alloplastic materials is favored by plastic surgeons, who prefer to avoid osteotomy and often are working with late adolescents or adults—although lower border osteotomy still remodels well in older patients. With greater chin advancement in older patients, prominence of the lateral border of the chin that creates a notch along the lower border can become a problem. To compensate for this, there are two possibilities: either splitting the chin so the posterior margins can be moved medially to eliminate the notch, or bone grafts or alloplastic augmentation materials over the lower border to fill in the posterior notch.

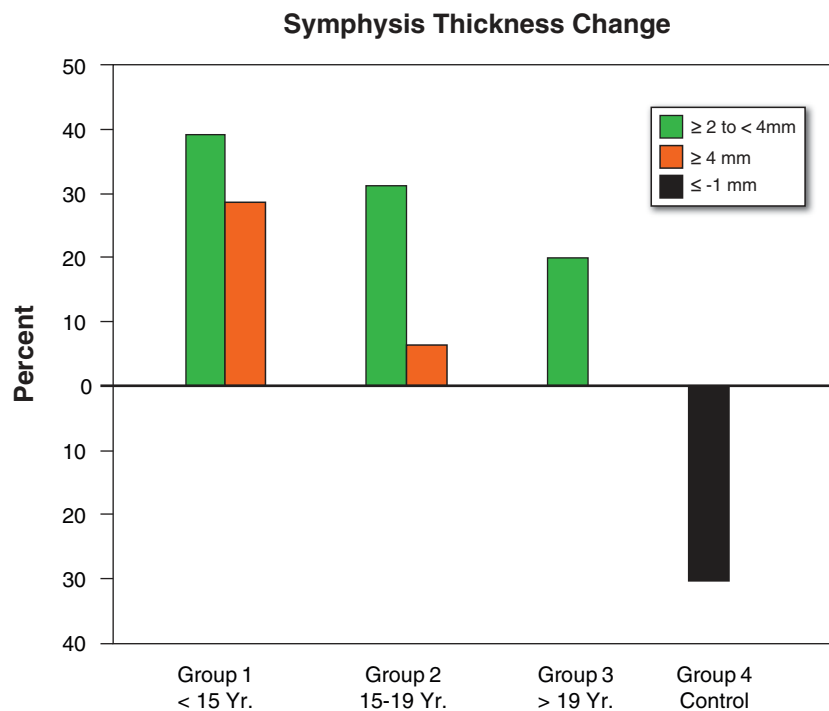
A chin implant has two advantages: the possibility of removal if the patient is unhappy with the result, and less risk of decreased sensation in the lower lip (from trauma to the nerve that emerges from the mental foramen to innervate the lip, which must be avoided in any genioplasty). It also has a major disadvantage,

particularly with silicone implants: erosion of the implant into the surface of the bone or migration into the neck. Newer implant materials placed into a soft tissue pocket rather than directly against the bone provide much better stability and have almost totally replaced silicone. Removal of one of these implants, however, is difficult, and undesirable soft tissue changes may result if this is necessary.<sup>12</sup>

There are two aspects of deformity of the chin in patients with excessive mandibular growth: prominence of the chin relative to the dentition, and excessive height of the chin. In patients with a prominent chin, if a lower border osteotomy is used to simply slide the bony chin backward, and especially if the chin surface is cut away, the soft tissue chin tends to look like an underinflated ball because of the loss of skeletal volume. In patients with excess chin height, however, vertical reduction of the chin by removing a wedge of bone above the chin prominence and then repositioning the chin upward (and often slightly forward) can greatly improve the facial appearance and result in a measurable improvement in the patients' quality of life.<sup>15</sup>



• **Fig. 20.20** When a lower border osteotomy is used to move the chin forward, remodeling along the lower border smooths the bony contour there. New bone formation above the prominence of the chin fills in the notch that is present immediately after the operation, and this extends all the way to the alveolar crest in patients who are still growing vertically. (A) The result is a clinically significant thickening of the symphysis. (B) Cephalometric superimposition tracing shows the change from before (*green*) to after (*red*) and 2 years after (*blue*) the surgical procedure. Note the amount of new bone in the symphysis area and its upward extension toward the alveolar crest accompanying eruption of the incisors in this young patient.



• **Fig. 20.21** This surgical procedure is more effective if it is done before age 15, although it still is applicable to late adolescents and adults. Vertical growth and eruption of the lower incisors increase the amount of new bone formation at the symphysis. A lower border osteotomy should not be done until eruption of mandibular canines has cleared the way for the osteotomy. As in the patient seen in Fig. 20.19, genioplasty at the end of active orthodontics often is the optimum time. (Redrawn from Chamberland et al. *Angle Orthod.* 2015;85:360–373.)



### Rhinoplasty

The smile is framed by the chin below and the nose above. It may be necessary to change both to achieve optimal changes in facial appearance. Mandibular surgery repositions the chin relative to the rest of the face, and as we have seen, repositioning the chin relative to the jaw also may be needed. Maxillary surgery via Le Fort I osteotomy rarely has a positive effect on the appearance of the nose and may compromise it. Moving the maxilla up and/or forward can have two major deleterious effects on the nose: rotation of the nasal tip upward, resulting in deepening of the supratip depression, and widening of the alar base. Rhinoplasty, simultaneous with orthognathic surgery or staged to follow it (see Figs. 20.6 and 20.34), can prevent these problems, so it is indicated for this purpose as well as for correction of a preexisting nasal deformity. Although Le Fort II and III procedures do move the nose along with the upper parts of the maxilla, these more extensive and riskier operations are indicated only in the most severe deformities.

Rhinoplasty usually is focused on the contour of the nasal dorsum, the shape of the nasal tip, and the width of the alar base. All these aspects can be significantly improved with modern surgical techniques. Because the soft tissue contours around the nose will be affected by repositioning of the jaws, rhinoplasty follows the orthognathic procedure. It can be done immediately afterward, as part of the same surgical experience, with a switch from nasal to oral intubation after the jaw operation is completed. This is technically more difficult and requires excellent interaction between the orthognathic and rhinoplasty surgeons but greatly increases the chance that the rhinoplasty actually will be accomplished.

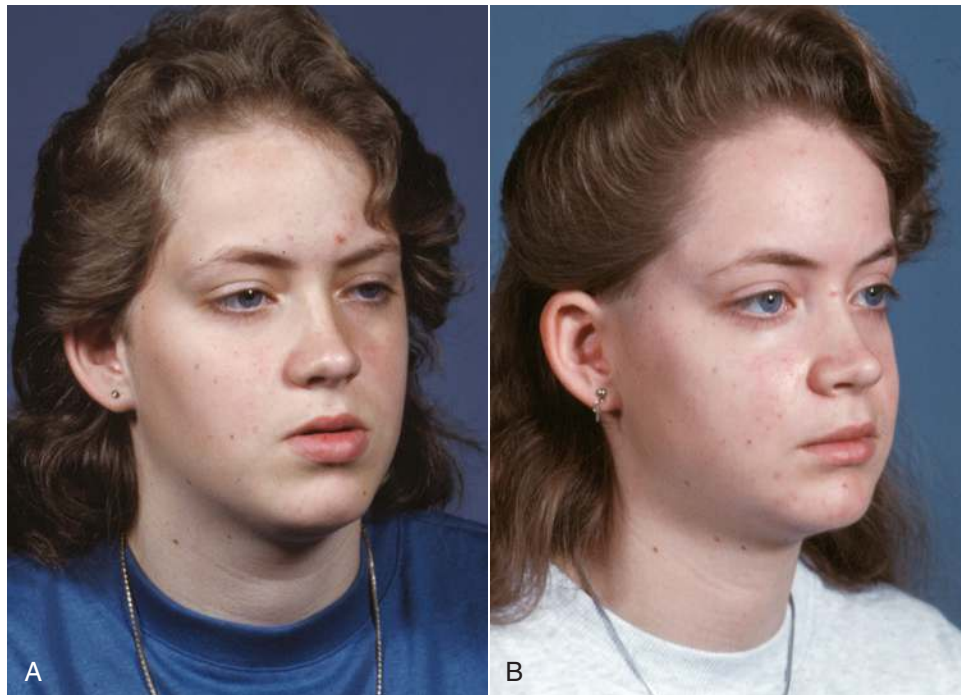### Facial Soft Tissue Contouring With Implants

Implants on the surface of the face can greatly improve soft tissue contours and are particularly advantageous for correction of two problems: the paranasal deficiency that often accompanies maxillary deficiency (Fig. 20.22), and the soft tissue deficiencies that accompany facial syndromes such as hemifacial microsomia. Onlay grafts in the paranasal area can be done successfully with use of the patient's own bone, freeze-dried cadaver bone, or alloplastic materials. The more extensive implants needed in patients with congenital anomalies usually are made from alloplastic materials that can be shaped in advance.

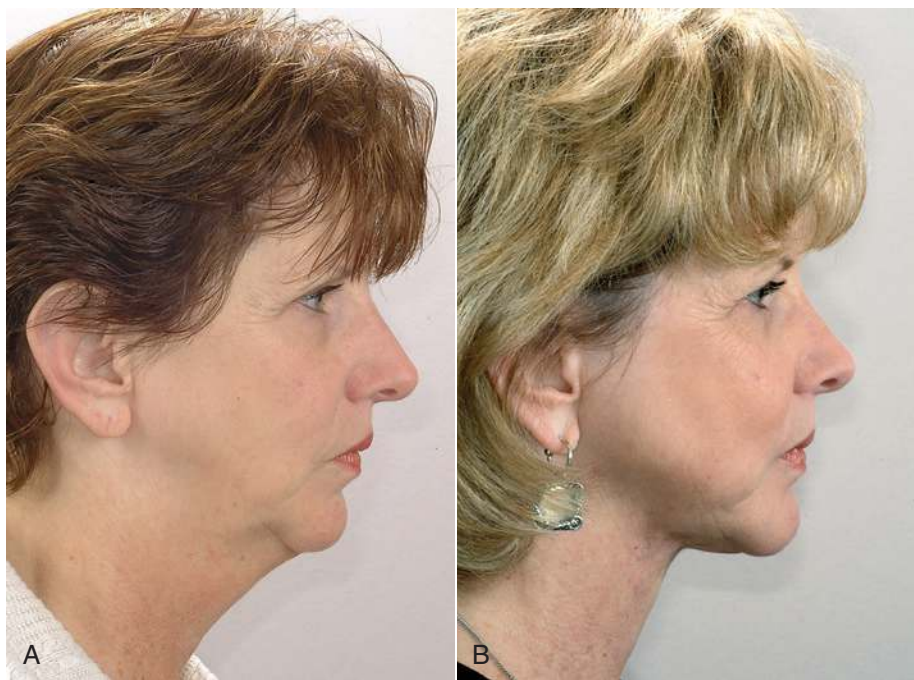### Lip Procedures

Instead of changing soft tissue contours indirectly with skeletal surgery, lip procedures directly augment or reduce the lips. Lip augmentation rarely accompanies orthognathic procedures; this usually is done to counteract the loss of lip fullness that accompanies aging. Although injections of collagen or other materials into the lips can be successful, the results tend to be temporary. A more permanent increase in lip projection can be obtained with AlloDerm (human dermis in sheet form), a synthetic material such as Gore-Tex, or the patient's own soft tissue harvested during a simultaneous face lift procedure. These are placed by creating a tunnel beneath the mucosa and threading the material into this space. This approach is preferred when lip augmentation is needed for orthognathic patients.

Lip reduction rarely is performed now but can greatly improve outcomes for the rare patients with extremely thick and prominent lips. It is accomplished via intraoral incisions parallel to the vermilion



• **Fig. 20.22** In patients with maxillary deficiency who will have the maxilla advanced, surface grafts to augment the paranasal area often are needed, as in this girl. (A) Before operation. (B) After maxillary advancement and paranasal grafts. Note the increased fullness alongside the nose, which would not have been created just by moving the maxilla.



• **Fig. 20.23** (A) This woman in her 50s sought treatment because of concern about her protruding maxillary incisors. This issue was due to the mandibular deficiency that is obvious on profile examination. Surgery to advance her mandible was recommended and accepted. At the time of that operation, she also had a submental lipectomy and platysma lift to improve her throat form. (B) Appearance 18 months later, after treatment. Note the contribution of better throat form to the improvement in facial appearance.

border and excision of soft tissue, avoiding the removal of muscle but including submucosal glands.

### Submental Procedures

Correction of an unesthetic throat form often is needed as an adjunct to orthognathic procedures in older patients. Advancing the mandible improves throat form, and a lower border osteotomy to advance the chin tightens sagging throat tissues even more, but the orthognathic procedures alone are not sufficient to correct a “double chin” or “turkey gobbler” deformity. This often requires a combination of removal of excessive submental fat and tightening the platysma muscle sling (Fig. 20.23). Both can be done readily at the time of the orthognathic surgery. Localized fat deposits superficial to the platysma can be removed with liposuction. Fat below the platysma requires an approach through the muscle that allows direct removal of the fat, then closure of the platysma muscle layer. Loose musculature in the area can be tightened as this is done.

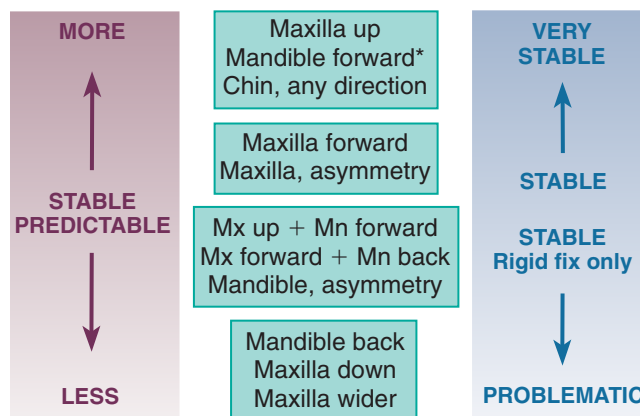
## Postsurgical Stability and Clinical Success

### The Hierarchy of Stability and Predictability

Stability after surgical repositioning of the jaws depends on the direction of movement, the type of fixation, and the surgical technique, largely in that order of importance. Enough data exist now to rank different jaw movements in order of stability and predictability (Fig. 20.24).

The most stable orthognathic procedure is superior repositioning of the maxilla, closely followed by mandibular advancement in patients whose anterior facial height is maintained or increased. These procedures, the key ones in correcting severe Class II problems, can be considered to produce a highly stable result even without

### Surgical-Orthodontic Treatment: A Hierarchy of Stability



\* Short or normal face height only

• **Fig. 20.24** The hierarchy of stability during the first postsurgical year, based on data from the University of North Carolina (UNC) Dentofacial Clinic. In this context, “very stable” means a 90% chance of no significant postsurgical change; “stable” means a greater than 80% chance of no change and almost no chance of more than 2 mm of relapse; “problematic” means some degree of relapse is likely and major relapse is possible. It is interesting to note that the key procedures in surgical treatment of Class II problems (superior repositioning of the maxilla, mandibular advancement, and their combination) are quite stable. In Class III treatment, maxillary advancement is the most stable procedure, whereas downward movement of the maxilla and mandibular setback remain problematic.

rigid fixation, and this remains true when they are combined in the treatment of patients with mandibular deficiency and a long face—but only if rigid fixation is used.

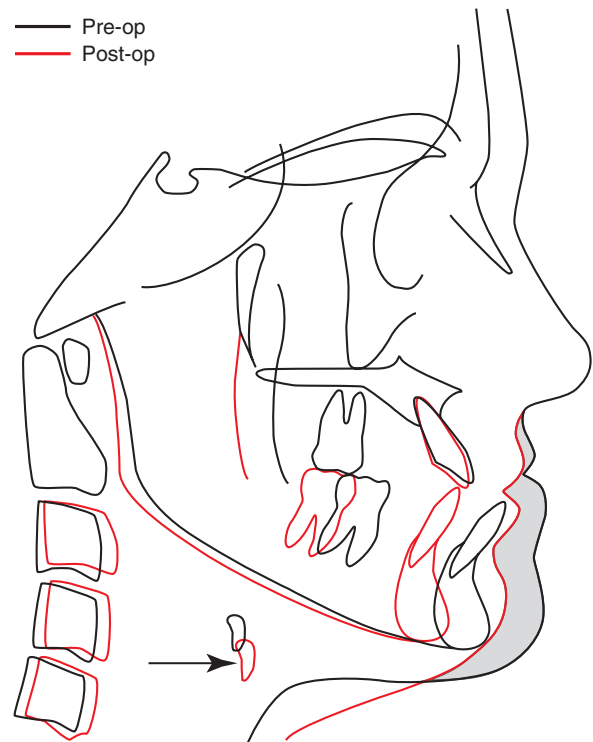
In the treatment of patients with Class III problems, the maxilla remains forward just where it was put in about 80% of the patients, and there is almost no tendency for major relapse (4 mm or more). With rigid fixation, the combination of maxillary advancement and mandibular setback is acceptably stable. In contrast, isolated mandibular setback often is unstable. So is downward movement of the maxilla that creates downward–backward rotation of the mandible. For this reason, almost all Class III patients now have maxillary advancement, either alone or (more frequently) combined with mandibular setback.

Surgical widening of the maxilla has the least stable result among the orthognathic surgical procedures. Widening the maxilla stretches the palatal mucosa, and its elastic rebound is the major cause of the relapse tendency. Strategies to control relapse include overcorrection initially and careful retention afterward, with either a heavy orthodontic archwire or a palatal bar during the completion of orthodontic treatment, and then a palate-covering retainer for at least the first postsurgical year. SARPE is preferred over a three-segment maxillary osteotomy if only expansion is required, but SARPE is not advantageous when vertical and/or anteroposterior change is needed, because then it would be the first stage of an unnecessary two-stage procedure.

### Influences on Stability

Three principles that influence postsurgical stability help to put this in perspective:

- Neuromuscular adaptation is essential for stability. Fortunately, there is good neuromuscular adaptation to most orthognathic procedures. When the maxilla is moved up, the postural position of the mandible alters in concert with the new maxillary position, and occlusal forces tend to increase rather than decrease. This controls any tendency for the maxilla to immediately relapse downward and contributes to the excellent stability of this surgical movement. Repositioning of the tongue to maintain airway dimensions (i.e., a change in tongue posture) occurs as an adaptation to changes produced by mandibular osteotomy, so surgical reduction of the tongue is not needed when the mandible is set back (Fig. 20.25). When the mandible is moved forward, a similar adaptation in tongue posture can be advantageous in patients with sleep-disordered breathing, and a lower border osteotomy to bring the chin forward also produces forward movement of the tongue because the tongue is attached to the genial tubercles (Fig. 20.26).
- In contrast, neuromuscular adaptation does not occur when the pterygomandibular sling is stretched during mandibular osteotomy, as when the mandible is rotated to close an open bite as it is advanced or set back, so movement of the mandible that stretches the elevator muscles should be avoided.
- Stability is greatest when soft tissues are relaxed during the surgical procedure and least when they are stretched. Moving the maxilla up relaxes tissues. Moving the mandible forward stretches tissues, but rotating it up at the gonial angle and down at the chin decreases the amount of stretch. It is not surprising that the most stable mandibular advancements rotate the mandible in this way, whereas the least stable advancements are those that rotate it in the opposite direction, lengthening the ramus and rotating the chin up. The least stable orthognathic surgical procedure, widening the maxilla, stretches the heavy, relatively inelastic palatal mucosa.



• **Fig. 20.25** This cephalometric superimposition shows how the airway is maintained when the mandible is set back. Although the dentition was moved posteriorly with a ramus osteotomy, the tongue moved down and a little forward rather than back, so the airway was maintained; note the change in position of the hyoid bone, which indicates the position of the base of the tongue. At one time it was routine to remove part of the tongue when the mandible was set back, but this is not necessary because of the physiologic adaptation. The adaptation shows, however, in the form of soft tissue prominence beneath the mandible, the proverbial “double chin.”

- Neuromuscular adaptation affects the length of the masticatory muscles but not their orientation, and adaptation to a new orientation cannot be expected. This concept is best illustrated by the effect of changing the inclination of the mandibular ramus when the mandible is set back or advanced. Successful mandibular advancement requires keeping the ramus in an upright position rather than letting it incline forward as the mandibular body is brought forward. The same is true, in reverse, when the mandible is set back: a major cause of instability appears to be the tendency at operation to push the ramus posteriorly when the chin is moved back, thus changing its orientation. The orientation is restored when jaw function resumes after operation, and that moves the jaw forward again. The stability of two-jaw Class III correction is better than mandibular setback alone, apparently because it is easier to avoid pushing the mandible back when a two-jaw operation is done (see Fig. 20.1M).<sup>16</sup>

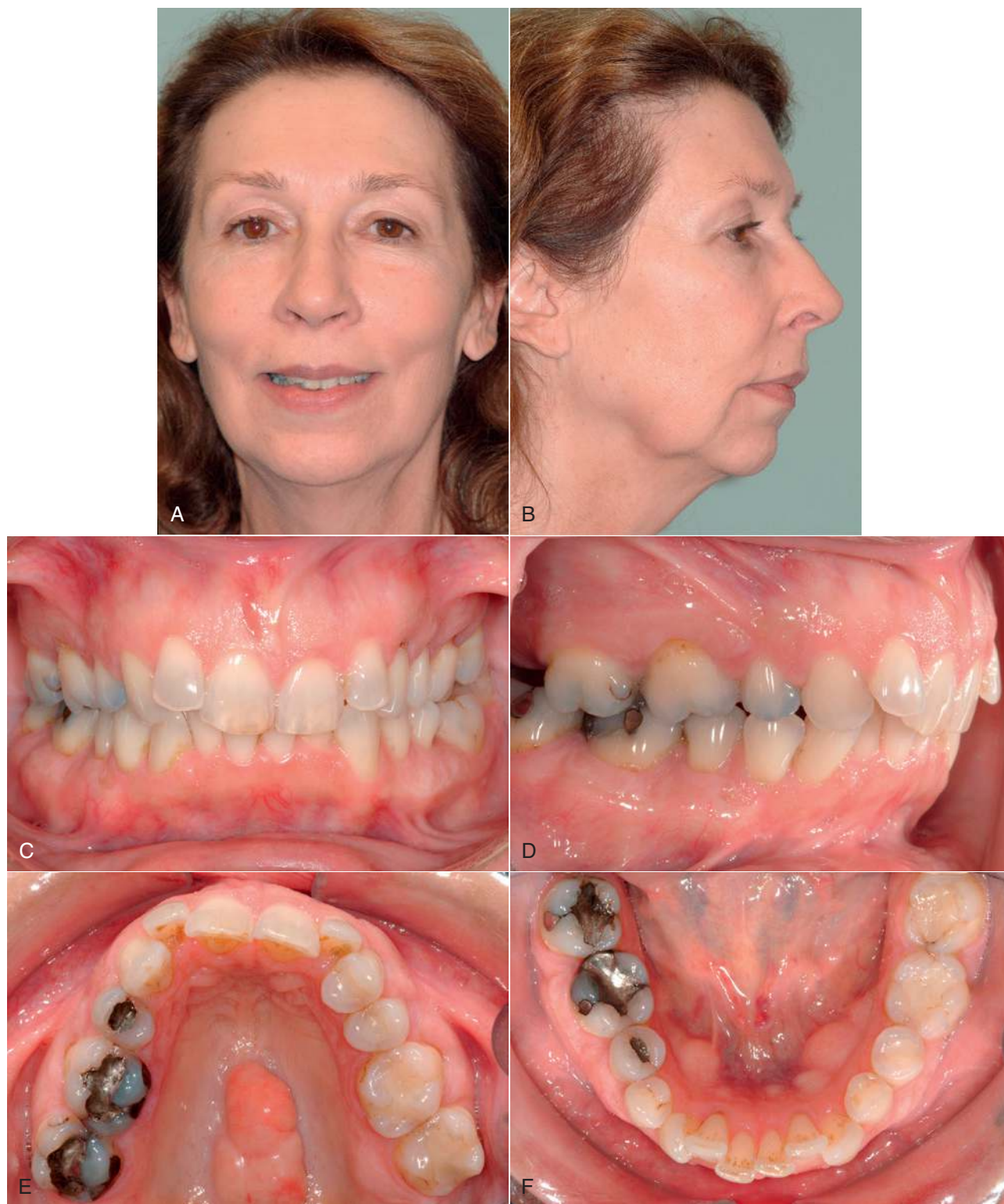## Special Considerations in Planning Surgical Treatment

### Timing of Surgery

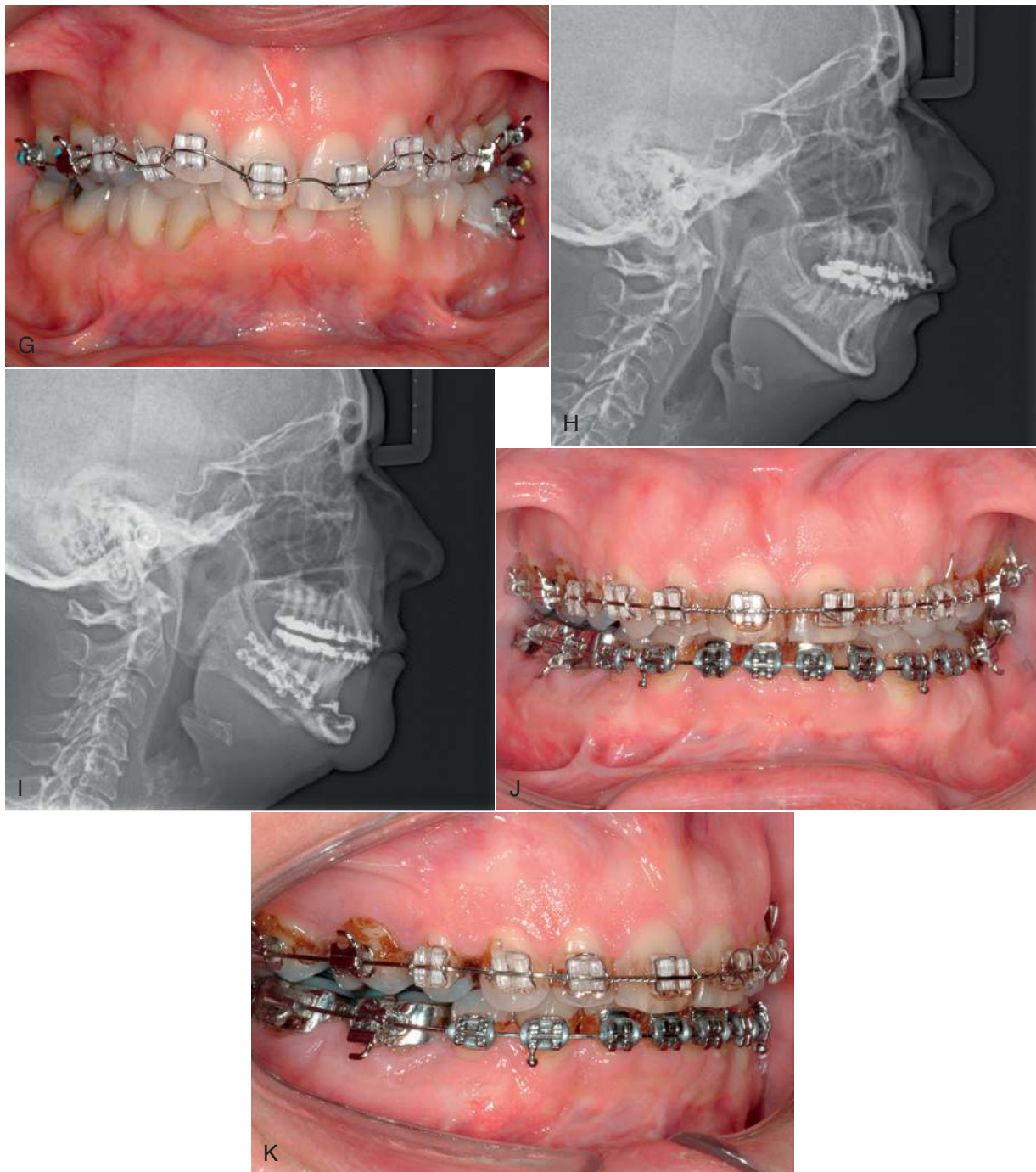
#### Progressive Deformity

In the discussion of growth modification in Chapters 13 and 14, the focus was on what is seen in almost all orthodontic patients





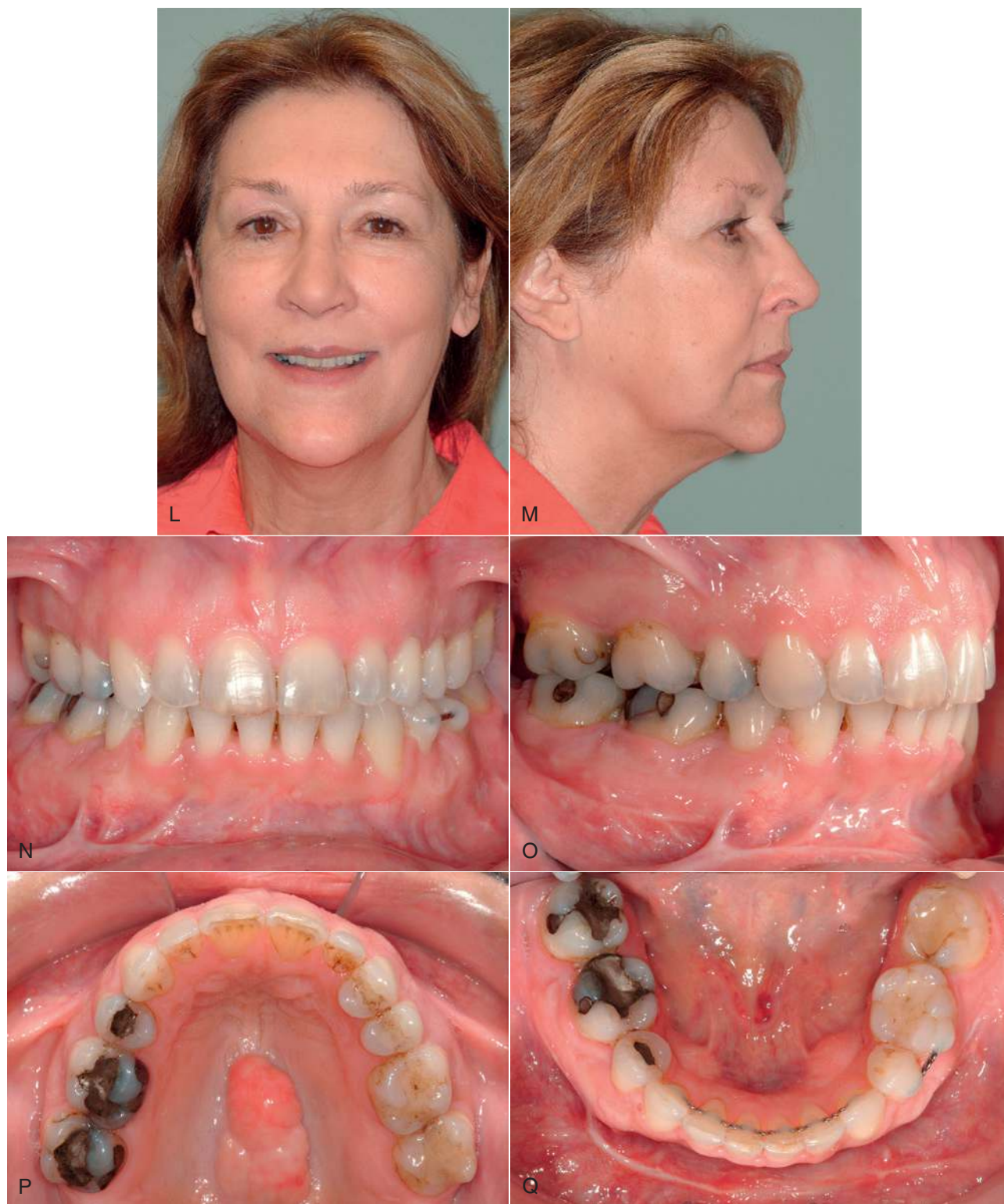• **Fig. 20.26** This woman in her late 50s sought orthodontic consultation about her “crooked teeth” and their effect on her smile. As an adolescent she had undergone extraction of her maxillary right first premolar and left canine and orthodontic treatment to align the teeth; the alignment was lost in the long term without permanent retention. When she was told that her Class II occlusion reflected her jaw relationship, she said she was well aware of her mandibular deficiency and had never liked it. She was referred to an oral and maxillofacial surgeon to discuss the possibility of mandibular advancement, and when he learned that she snored loudly and was chronically tired, he suggested that improving sleep-disordered breathing might be another reason to choose surgery. No sleep study was done, but she agreed that she wanted the esthetic benefit of surgery and the possible airway improvement. (A and B) Frontal smile and lips-together profile; (C to F) intraoral views. Her treatment plan was extraction of the mandibular right first premolar and left second premolar, with an approximately 7-mm mandibular advancement and 6-mm advancement genioplasty.



• **Fig. 20.26, cont'd** (G) Initial alignment of the maxillary arch; the mandibular extractions and presurgical preparation of the lower arch followed. (H and I) Cephalometric radiographs before and after operation. (J and K) Intraoral views near the end of treatment. Postsurgical orthodontics took only 3 months.

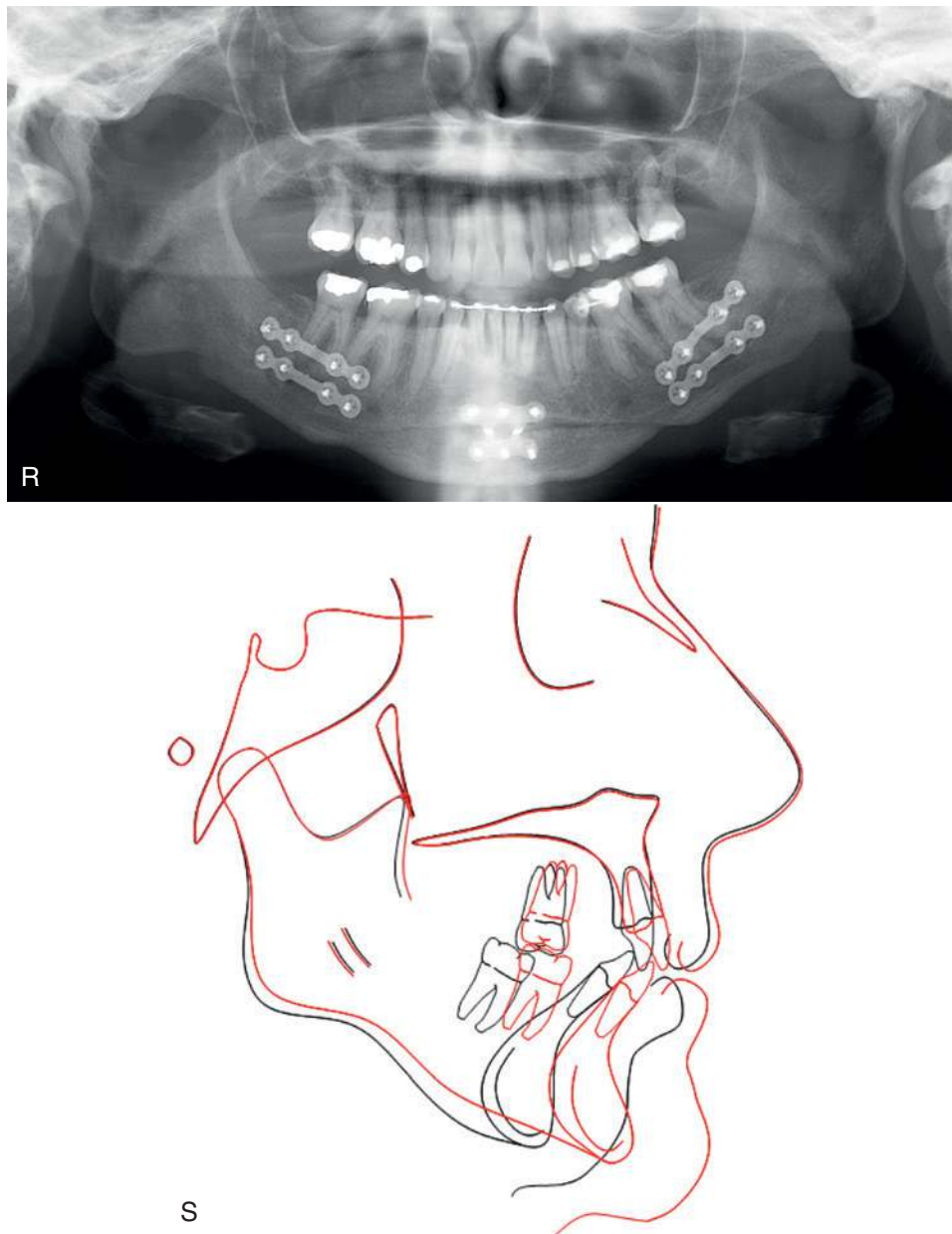
*Continued*





• **Fig. 20.26, cont'd** (L and M) Facial appearance and (N to Q) intraoral views at debanding. Note the use of a facial bonded retainer wire to keep the second premolar extraction space closed; extending a bonded lingual retainer to the premolar is not recommended.





• **Fig. 20.26, cont'd** (R) Panoramic radiograph after placement of a bonded mandibular retainer; a removable maxillary retainer was to be worn full-time except for eating. She was quite pleased and reported that she no longer snores and feels that she has more energy, so perhaps there was an airway benefit. (S) Cephalometric superimposition pretreatment to posttreatment. The amount of face height increase was controlled by vertical positioning of the lower incisors. (Courtesy Dr. T. Shaughnessy.)

with excessive or deficient growth of the jaws: a relatively stable jaw relationship over time, that is, a problem that persists but doesn't rapidly get worse. If growth modification is done early, the problem tends to recur because of later growth in the same pattern, so the usual guidance is to wait until the adolescent growth spurt to start treatment. But rarely, that is not the situation. Instead, the patient has a progressive deformity, one that does get worse over time. Almost always, the problem is asymmetric growth of the mandible, and that is an indication for early surgery. In contrast to orthognathic surgery more generally, the goal of the surgical

procedure is not to correct the deformity, but to create an environment in which normal growth is possible.

Asymmetric mandibular deficiency has two major causes: (1) a congenital anomaly, most likely a form of hemifacial macrosomia (see Fig. 20.17), or (2) an old condylar fracture with a limitation on growth from scar tissue that limits translation of the condyle (see Figs. 14.45 and 14.46). Correction of this problem may or may not require surgery, depending on the severity of the limitation. For the more severe forms of hemifacial macrosomia and for failure of translation of the condyles, surgical intervention is indicated

when the problem is recognized. Cases of this type are best managed through problem-oriented clinics at a university medical center.

Asymmetric mandibular excess is described by its more scientific name, *hemimandibular hyperplasia*, but the cause is unknown. Important characteristics of this problem include:

- The excessive growth is not a tumor; the histologic diagnosis is normal hard and soft tissue, just too much growth. That means it has the potential to stop growing on its own, which will not correct the asymmetry but would stop it from getting worse.
- Most of the patients are female, about 85% of the total.
- In many adolescent girls, a mild asymmetry develops as one side stops growing and the other continues for a while but then also stops growing. A mild asymmetry created by this last phase of growth is not a problem—but of course if the asymmetric growth continues, there will be problems of both function and facial disproportion.
- The excessive growth occurs in two patterns at the condyles—enlargement of the condyle or lengthening of the condylar neck (Fig. 20.27)—and two patterns in terms of lengthening of the ramus versus the body of the mandible. The more the body of the mandible lengthens, the greater the lateral displacement of the center of the chin; the more the ramus lengthens, the greater the vertical asymmetry, which often includes a lower position of one side of the chin in addition to an asymmetry at the gonial angles. The vertically asymmetric mandibular growth induces a cant in the occlusal plane, and surgical correction is likely to require two-jaw surgery plus genioplasty (Fig. 20.28).

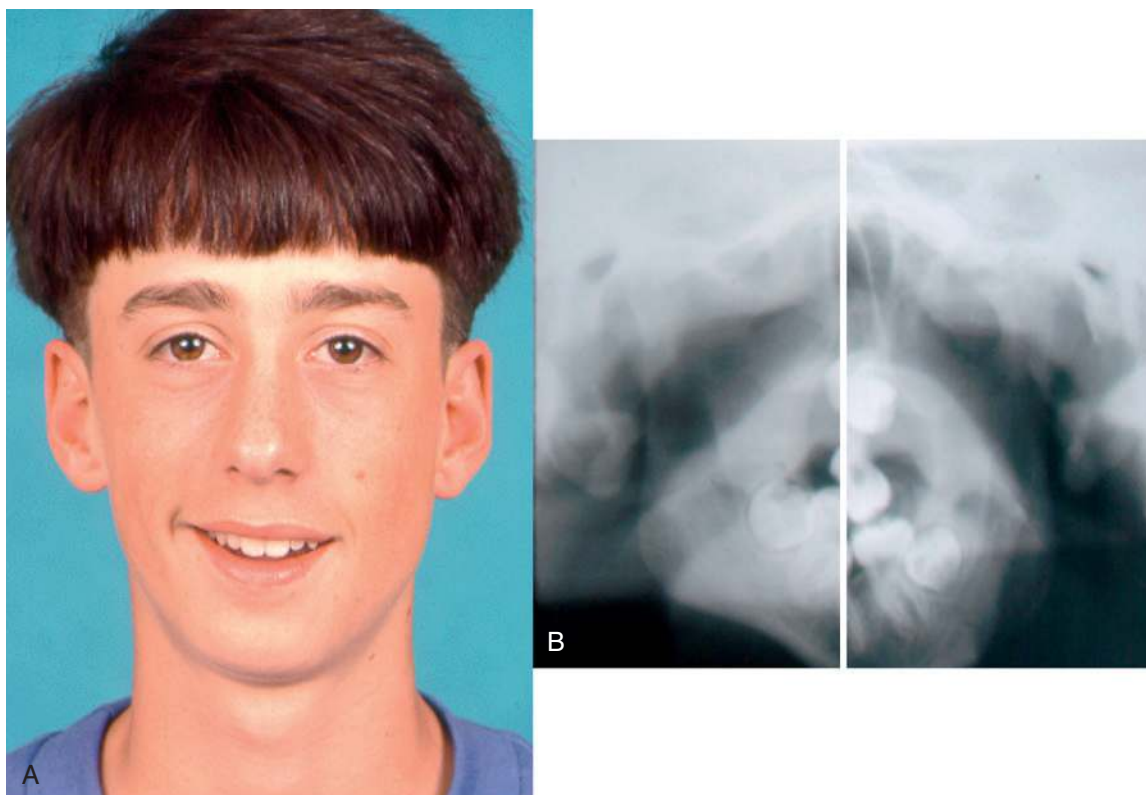- The clinical impression is that patients whose excessive growth is a lengthening of the condylar process appear to be more likely to stop growing than those who have an enlargement of the condyle, but this has not been documented in a large study.
- Removing the condyle on the affected side stops the excessive growth, even though the deviant growth pattern affects the rest of the mandible, not just the condyle. If the condyle is distorted to the point that it no longer fits into the condylar fossa, condylectomy is indicated. If the excessive growth is an elongation of the condylar neck, a “condylar shave” that removes the superior surface where cellular proliferation occurs can be successful.

For younger patients with either asymmetric deficiency or asymmetric excessive growth, hybrid functional appliances can aid in managing asymmetry before or after orthognathic surgery. These appliances are discussed in [Chapter 14](#).

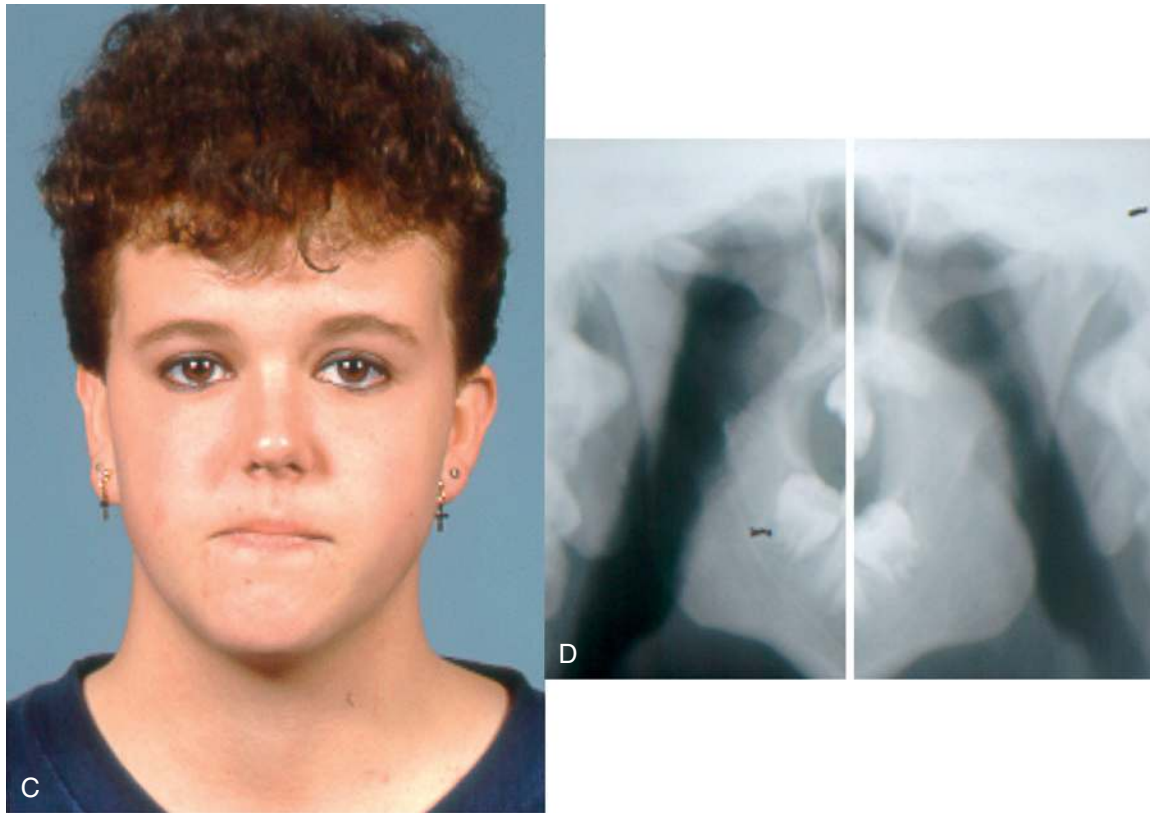### Symmetric Excess Growth

With the exception of condylectomy in patients with hemimandibular hypertrophy, early jaw surgery has little inhibitory effect on further growth. For this reason, orthognathic surgery should be delayed until growth is essentially completed in patients who have symmetric excessive growth, especially mandibular prognathism. For patients with growth deficiencies, earlier surgery can be considered, but rarely before the adolescent growth spurt.

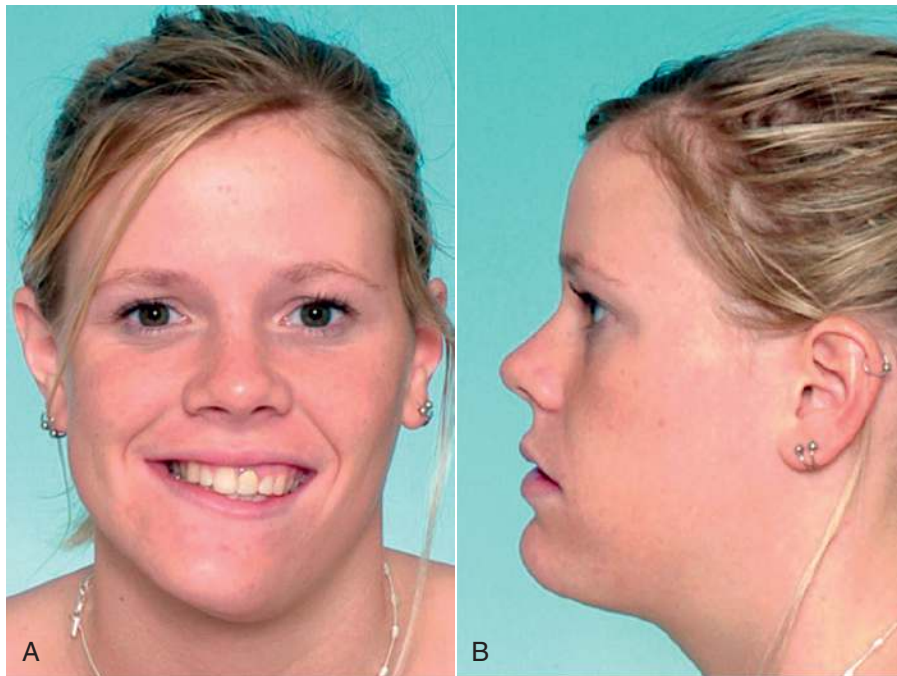Actively growing patients with mandibular prognathism can be expected to outgrow early orthodontic or surgical correction and require retreatment (see [Fig. 18.1](#)), so the timing of this operation often is a critical consideration. Indirect methods of assessing



• **Fig. 20.27** Two patterns of growth are seen at the mandibular condyles in patients with hemimandibular hyperplasia: (A) excessive growth on the patient's left side and (B) enlargement of the left condyle.



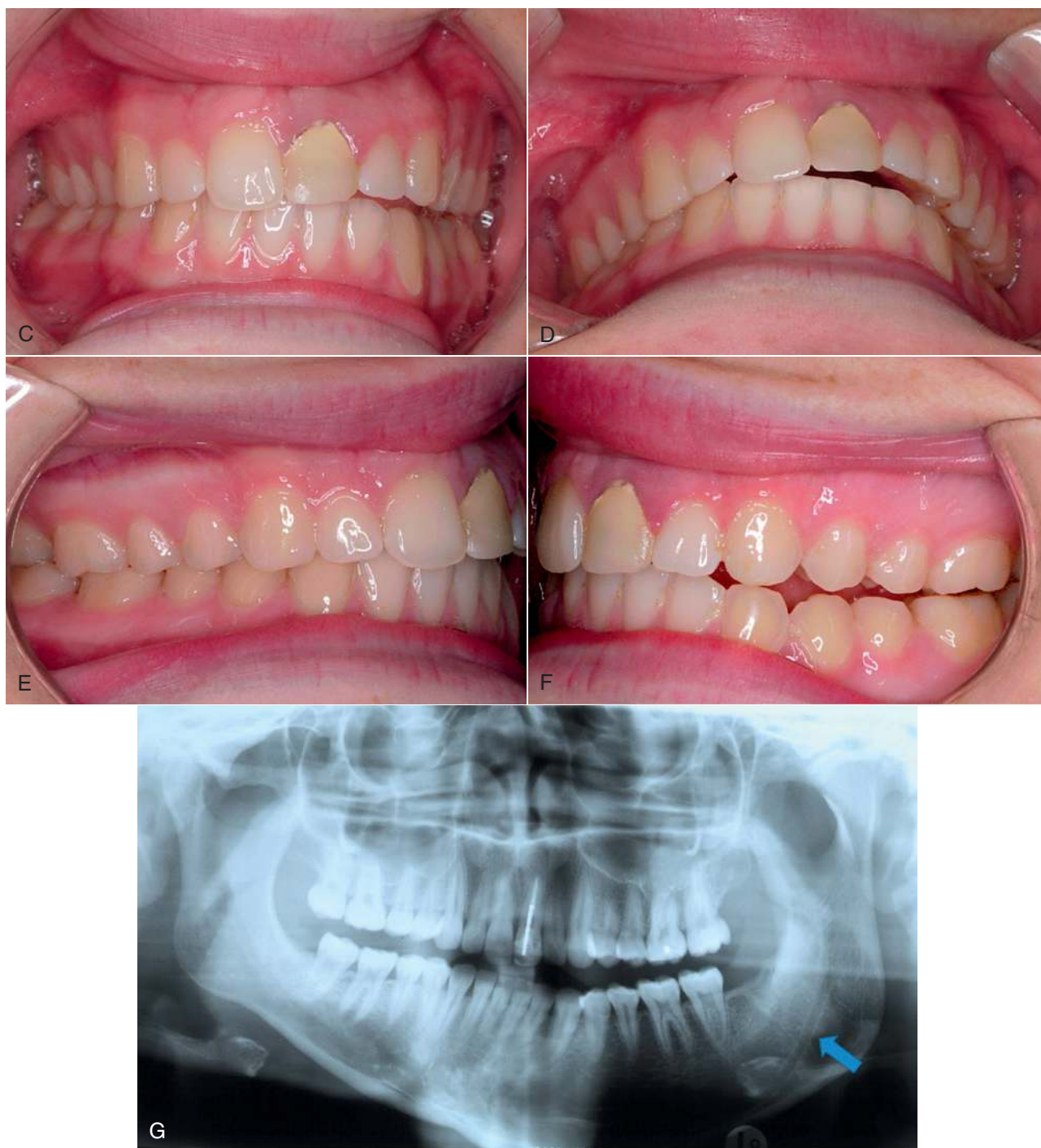- **Fig. 20.27, cont'd** (C) Excessive growth on the patient's left side and (D) lengthening of the left condylar neck but no increase in the size of the condyle. A clinical impression is that patients with elongation of the condylar neck are more likely to stop growing spontaneously than those with enlargement of the condyle, but there are no good data to document this.



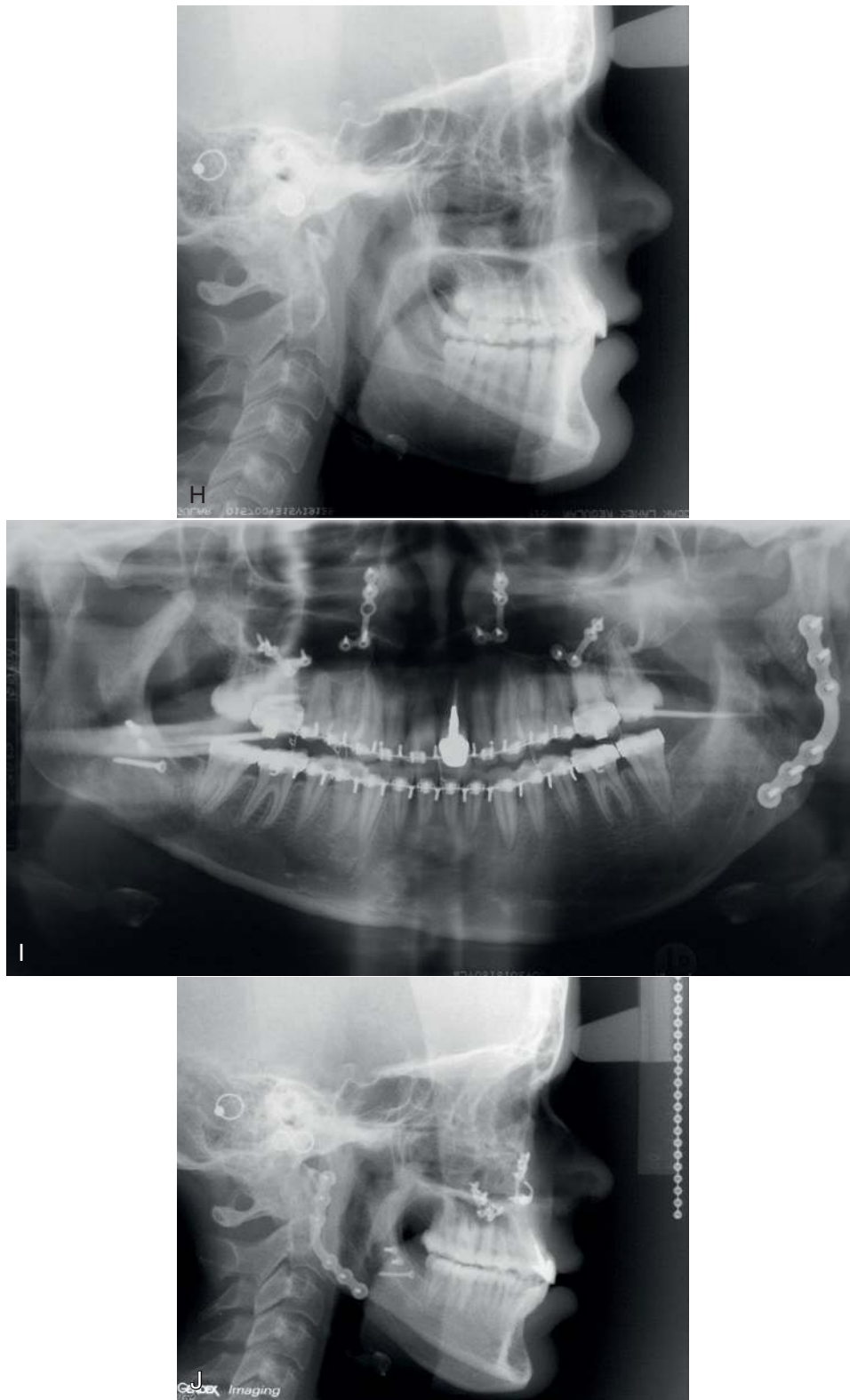
- **Fig. 20.28** (A and B) Untreated hemimandibular hyperplasia can slowly lead to a major facial asymmetry, as in this 18-year-old college freshman. Her jaw asymmetry was noted at age 11 when she had orthodontic treatment to align crowded teeth. The decision was to wait to see what happened with further growth before any surgical intervention, and the asymmetric growth continued.

*Continued*

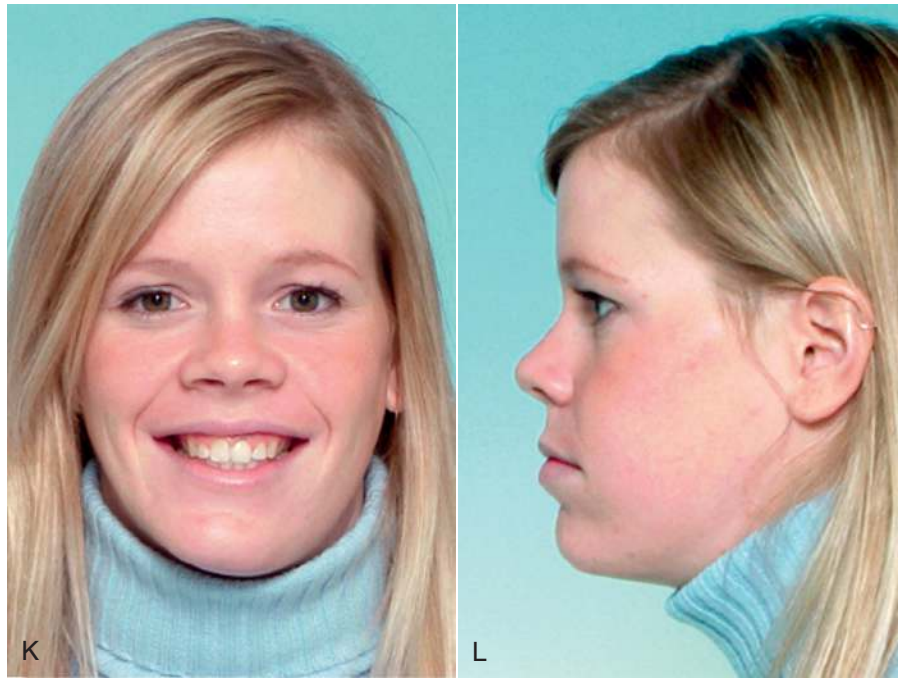



• **Fig. 20.28, cont'd** (C to F) Intraoral views of the teeth. The maxillary left central incisor had been fractured in an accident, but the teeth were still well aligned after the previous orthodontic treatment. Note the normal molar relationship on the right and the half-cusp Class II relationship on the left. (G) The panoramic radiograph shows the tremendous enlargement of the left condyle, which can no longer fit into the condylar fossa, the downward path of the mandibular neurovascular bundle on the affected side (*arrow*), and the excessive bone formation below the mandibular teeth on the left side. Note that this goes all the way to the midline.



• **Fig. 20.28, cont'd** (H) The cephalometric radiograph shows the vertical lengthening of the ramus on the left. The almost purely vertical excess growth for this patient is unusual; these patients show all possible combinations of excessive vertical versus horizontal growth. At this stage surgical treatment consisted of condylectomy on the right side plus bilateral sagittal split osteotomy (BSSO) on the left side (necessary for correct positioning of that condyle), Le Fort I osteotomy to level the maxillary cant, and lower border osteotomy to remove as much of the excess bone as possible below the teeth on the left side. (I) Panoramic radiograph immediately after operation. At operation, first the maxilla was rotated up on the left side to level the occlusal plane to achieve optimum display of the maxillary teeth; then the right condyle was removed, and a cut across the ramus below the condylar stump created a condylar segment that was moved up into the condylar fossa. It is not necessary to bone graft an area the size of the defect seen here on the left side; bone fills in defects of this magnitude during healing. (J) The cephalometric radiograph at the end of orthodontic treatment, which took only 8 months because minimal use of pre-surgical and postsurgical orthodontics was needed, shows the leveling of the maxilla and removal of bone along the left lower border up to the level of the neurovascular bundle. *Continued*



• **Fig. 20.28, cont'd** (K and L) Frontal and lateral photographs at the end of treatment. The mildly excessive lower border of the mandible on the left side is hardly detectable and would not be noticed unless you were really looking for it.

growth status, such as hand–wrist radiographs or vertebral stages to determine bone age, are not accurate enough for planning the time of operation. The best method is serial cephalometric radiographs, with the surgical procedure delayed until good superimposition documents that the adult deceleration of growth has occurred. Often the correction of excessive mandibular growth must be delayed until the late teens, unless a second, later surgical correction can be justified because of psychosocial considerations.

The situation is not so clear-cut for patients with the long-face (skeletal open bite) pattern that can be characterized as vertical maxillary excess. There appears to be a reasonable chance for stable surgical correction of this problem before growth is totally completed, but the difference in clinical stability between treatment at, for example, ages 14 and 18 remains incompletely understood. Should patients with a long face have early surgical treatment? Probably not, unless they are willing to have a second later operation if additional growth occurs. Precision planning for cases of this type can produce almost exactly the desired outcome—in the absence of growth. That means delaying the surgical procedure until growth has essentially stopped makes the treatment outcome predictable in a way it cannot be if done early.

### Growth Deficiency

Surgery in infancy and early childhood is required for some congenital problems that involve deficient growth. Craniosynostosis and severe hemifacial microsomia are two examples. The major indication for orthognathic surgery before puberty, however, is a progressive deformity caused by restriction of growth. A common cause is ankylosis of the mandible (unilaterally or occasionally bilaterally) after a condylar injury or severe infection (see [Chapter 5](#)). Operation to release the ankylosis, followed by functional appliance therapy to guide subsequent growth, is needed in these unusual problems.

A child with a severe and progressive deficiency should be distinguished from one with a severe but stable deficiency, such as a child with a small mandible whose facial proportions are not changing appreciably with growth. A progressive deficiency is an indication for early surgery, whereas a severe but stable deficiency usually is not. The principal exception is an extremely severe problem in which preliminary orthodontic or surgical treatment would improve the patient's quality of life even though operation would be needed later to deal with the jaw deformity. In keeping with the general principle that orthognathic surgery has surprisingly little impact on growth, early surgery does not improve the growth prognosis unless it relieves a specific restriction on growth, nor does it produce a subsequently normal growth pattern.

**Early Mandibular Advancement.** In the 1980s, some surgeons advocated early mandibular advancement, assuming that normal growth would occur thereafter and the problem would not recur. As with early setback and with early distraction osteogenesis for advancement, that is an unwarranted assumption. Many younger patients have further mandibular growth after surgical advancement. Most of this growth is expressed vertically, however, and results in minimal forward movement at the pogonion.<sup>17</sup> To say it differently, the mandible grows no further forward after early advancement, although there is likely to be enough vertical growth to prevent downward and backward rotation. In our view, mandibular advancement before the adolescent growth spurt, with surgery or distraction, is not indicated for patients who do not have a progressive deformity or psychosocial problems severe enough to warrant a second operation later.

On the other hand, if facial growth declines to adult levels at the end of the adolescent growth spurt, there would seem to be no reason to delay mandibular advancement. Minimal facial growth can be expected in patients with severe deficiency during late



adolescence, and relapse from that cause is unlikely. However, recent research has shown two interesting findings for patients who underwent mandibular advancement before age 18 compared with those who underwent the surgical procedure at a later age:

1. Some of the adolescent patients had downward and backward rotation of the mandible, which led to a decrease in chin prominence, and a few had shortening of mandibular length that had the same effect. It appears that delaying advancement probably does increase the chance of long-term stability.
2. Both the younger and older patients had high satisfaction levels at 5 years after surgery, but those who had early surgery were even more satisfied with their treatment than those who had surgical treatment at an older age. This was true even though they often recognized that their chin was no longer as prominent as it was shortly after surgery.<sup>18</sup>

How does that translate to informed consent? The data indicate that if a patient really is anxious to have early surgical correction despite knowing that the risk of mild recurrence exists, he or she probably should have it because of the psychosocial benefit. And those who understand the risk and decide they can wait should do so.

**Early Maxillary Advancement.** Early (adolescent) advancement of a sagittally deficient maxilla or midface remains relatively stable if there is careful attention to detail and grafts are used to combat relapse, but further forward growth of the maxilla is quite unlikely. Subsequent growth of the mandible is likely to result in reestablishment of Class III malocclusion and a concave profile. The patient and parents should be cautioned about the possible need for a second stage of surgical treatment later. In general, maxillary advancement should be delayed until after the adolescent growth spurt unless earlier treatment is needed for psychosocial reasons.

Although surgery to reposition the entire maxilla may affect future growth, this is not necessarily the case for the surgical procedures used to correct cleft lip and palate. In patients with cleft lip and palate, bone grafts to alveolar clefts before eruption of the permanent canines can eliminate the bony defect, which greatly improves the long-term prognosis for the dentition. A review of patients with cleft palate treated with the Oslo protocol (i.e., closure of the lip and hard palate at 3 months, posterior palatal closure at 18 months, and cancellous alveolar bone grafting at 8 to 11 years)<sup>19</sup> showed no interference with the total amount of facial growth.<sup>19</sup> As surgical methods for initial closure of a cleft palate continue to improve, the number of cleft patients who need maxillary advancement as a final stage of treatment should continue to decrease.

## Correction of Combined Vertical and Anteroposterior Problems

### Short-Face Class II: Increasing Anterior Face Height

Both mandibular and maxillary deficiencies often are accompanied by short anterior face height, and a goal of treatment should be to increase it. It is important to keep in mind that moving the mandible forward allows a stable increase in face height along with the anteroposterior movement, whereas moving the maxilla down and forcing the mandible to rotate down and back can be problematic.

The most stable type of mandibular advancement rotates the mandibular body segment as it is advanced, so that the chin comes forward and downward and the mandibular plane angle increases. The excellent bony contact after a sagittal split osteotomy easily

allows the rotation. The effect is to shorten the mandibular ramus. Although the soft tissues of the anterior lower face are stretched as the chin is advanced and moved down, this is mitigated by relaxation of the posterior soft tissues (which include the mandibular elevator muscles), and the result is little soft tissue pressure in a relapse direction.

In contrast, moving the maxilla down stretches both the anterior and posterior facial soft tissues. Although muscle adaptation appears to occur, there is a strong tendency for the maxilla to relapse upward. Therefore, mandibular ramus surgery is preferred to increase face height, and downward movement of the posterior maxilla, so that the mandible is forced to rotate down and back, is avoided if possible.

### Long-Face Class II or Class III Patients: Decreasing Face Height

Moving the maxilla up so that the mandible can rotate up and forward is the most stable orthognathic procedure (see discussion of stability later). A Le Fort I osteotomy therefore is the preferred procedure for a patient with an anterior open bite and/or a Class II malocclusion due to downward-backward rotation of the mandible (see Fig. 20.11).

In contrast, although a mandibular ramus osteotomy can be used to decrease anterior face height and decrease the mandibular plane angle, the result is highly unstable because the mandibular elevator muscles are stretched and do not adapt. Moving the maxilla up produces a change in the postural position of the mandible. A ramus osteotomy does not produce the same neuromuscular adaptation, which is why it is unstable. Therefore, a Le Fort I osteotomy to elevate the posterior maxilla is preferred to reduce face height. If the mandible is still deficient after it rotates up and forward, a mandibular advancement in combination with the maxillary procedure does not stretch the muscles and is acceptably stable.

For patients with Class III problems, the same guidelines for vertical change are applicable. The recommendations:

- To increase face height, use a mandibular ramus osteotomy in combination with a maxillary osteotomy if downward movement of the maxilla is desired.
- To decrease face height, use a maxillary osteotomy in combination with a mandibular ramus osteotomy if further mandibular advancement or mandibular setback is required.

## Special Points in Planning Orthognathic Surgery

Three further special points should be considered when orthognathic surgery is involved:

1. Incision lines contract somewhat as they heal, and when incisions are placed in the vestibule, this can stress the gingival attachment, leading to stripping or recession of the gingiva. This is most likely to be a problem with the lower incisors after the incision for a genioplasty. If the attached gingiva is inadequate, gingival grafting (see Fig. 19.31) should be completed before genioplasty.
2. Many young adults being prepared for orthognathic surgery have unerupted or impacted third molars. If rigid fixation (bone screws) with mandibular ramus surgery is planned, it is desirable to remove the lower third molars at least 6 months before the orthognathic procedure. This allows good bone healing in the area where the screws will be placed.
3. If the patient's primary motivation for treatment is temporomandibular dysfunction (TMD), the unpredictable impact of orthognathic surgery on TMD must be carefully discussed. TMD symptoms usually improve during presurgical orthodontic

treatment, just as with any other active orthodontics, and it is important for the patient to understand that this improvement may be transient. If TM joint surgery along with maxillary and/or mandibular surgery will be required, usually it is better to defer this until after the orthognathic surgery because the outcome of joint surgery is more predictable after the new joint positions and occlusal relationships have been established.

As with all adult orthodontic patients, whether orthognathic or TM joint surgery is or is not involved, definitive restorative and prosthetic treatment is the last step in the treatment sequence. Initial restorative treatment should stabilize or temporize the existing dentition with restorations that will be serviceable and provide patient comfort during the orthodontic and surgical phases. When the final skeletal and dental relationships have been achieved, it is possible to obtain accurate articulator mountings and complete the final occlusal rehabilitation.

## Putting Surgical and Orthodontic Treatment Together: Who Does What and When?

### Orthodontic Appliance Considerations

In contemporary surgical–orthodontic treatment, a fixed orthodontic appliance has three uses: to (1) accomplish the tooth movement needed in preparation for surgery; (2) stabilize the teeth and basal bone at the time of operation and during healing (which is less important now when rigid internal fixation is used almost routinely) and provide attachments for intermaxillary fixation; and (3) produce the necessary postsurgical tooth movement while retaining the surgical change. A fixed appliance should permit the use of full-dimension rectangular archwires for strength and stability during the stabilization phase of treatment.

Any of the variations of the edgewise appliance (including self-ligating brackets), with either 18 or 22 slots, are acceptable for stabilization, but the self-ligating bracket should allow a full-dimension steel wire to be ligated in place for the surgical stabilization. Integral hooks on brackets, however, are not recommended for intermaxillary fixation because tying directly to a bracket increases the chance of dislodging it at a particularly awkward time.

For surgical–orthodontic treatment, ceramic brackets pose a dilemma. Their appearance makes them appealing to esthetically conscious adults who choose surgery, but the brittleness of the ceramic material makes them susceptible to fracture, especially when the jaws are being tied together in the operating room so rigid fixation can be placed. Patients who are told that ceramic brackets might compromise their surgical result usually accept metal brackets instead. If ceramic brackets are used, they should be restricted to the maxillary anterior teeth. The surgeon must treat them gently and be prepared to deal with problems in the operating room.

A modern lingual appliance can be used in surgery patients, as can clear aligners, but with both some attachments on the facial surface of the teeth must be placed for temporary intermaxillary fixation, and patients using Invisalign routinely would have bonded attachments on many teeth for better control. For clear aligner surgical cases, there is a premium on precise internal fixation and accurate construction of splints, especially when segmental osteotomies will be used, because the aligner provides no support at the time of operation—but excellent results can be obtained with three-dimensional (3-D) imaging as the basis for

detailed planning of the surgical procedure and splint fabrication (Fig. 20.29).

## Presurgical Orthodontics

### Goals of Presurgical Treatment

The objective of presurgical treatment is to prepare the patient for the surgical procedure, placing the teeth relative to their own supporting bone without concern for the dental occlusion at that stage. Because some postsurgical orthodontics will be required in any case, it is inefficient to do tooth movement before operation that could be accomplished more easily and quickly during or after operation. For example, when a maxillary osteotomy is needed for correction of a vertical or anteroposterior problem, there is no reason to expand the arch transversely during the presurgical orthodontics—this can be done as part of the same maxillary procedure. Most patients with deep overbite before treatment need leveling of the lower arch by extrusion of posterior teeth, and this can be done more quickly and easily during the postsurgical orthodontic treatment (see later).

This means that the amount of presurgical orthodontics can be quite variable, ranging from only appliance placement in a few patients to 12 months or so of treatment in others with severe crowding or protrusion. The presurgical phase should almost never require more than a year, unless it is delayed by waiting for growth to be completed.

The length of the postsurgical phase of treatment depends on the amount of detailing needed. However, when postsurgical treatment extends beyond about 6 months postsurgically, patients tend to become discouraged and satisfaction with treatment decreases.<sup>20</sup> Another way to express the goal of presurgical orthodontics is that it should prepare the patient so that postsurgical treatment can be completed within 6 months.

### Steps in Orthodontic Preparation for Surgery

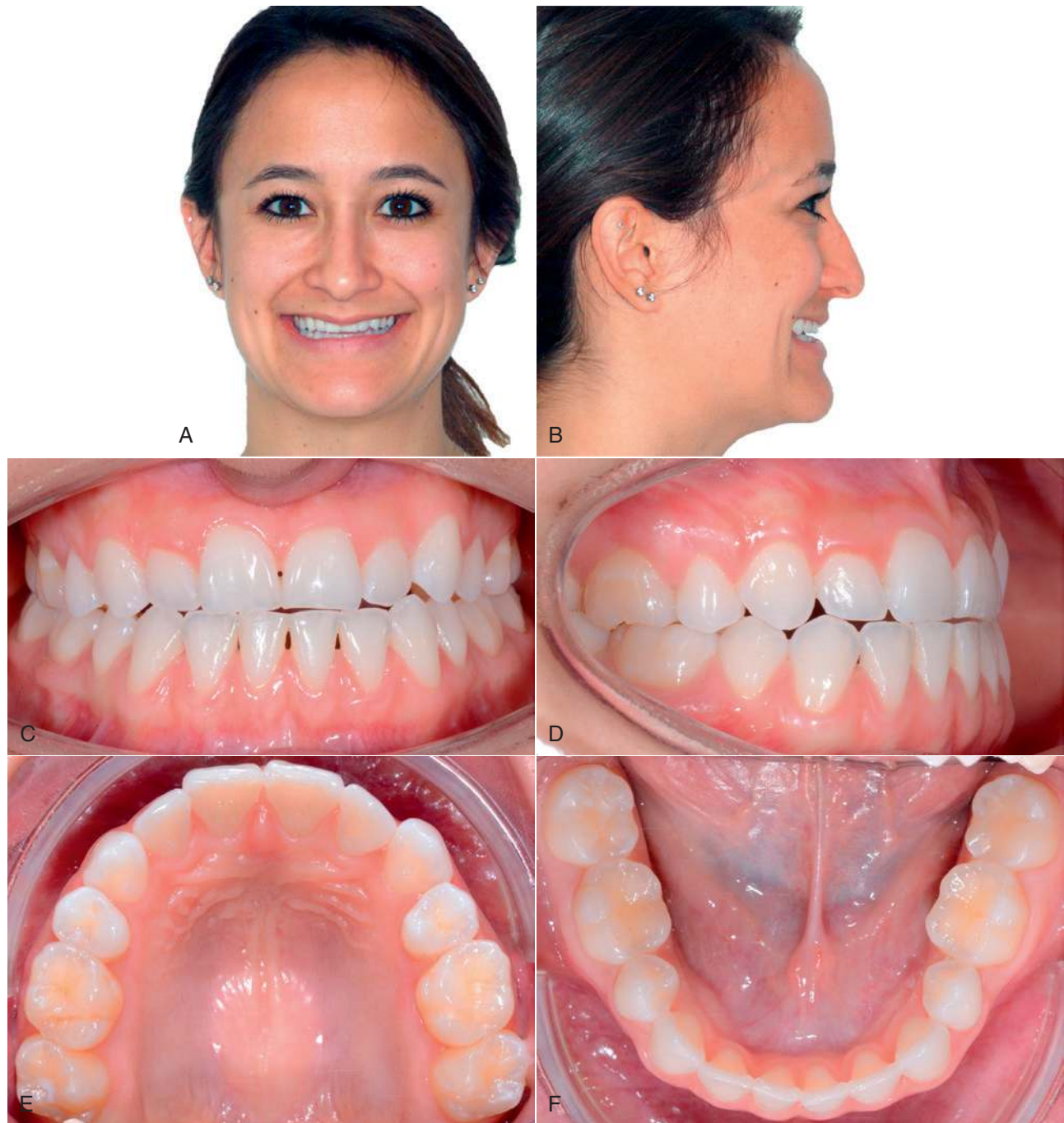
The essential steps in presurgical orthodontics are to arrange the teeth so they will not interfere with placing the jaws in the desired position. This requires aligning the arches or arch segments to make them compatible, and establishing the anteroposterior and vertical position of the incisors. Planning exactly how the dental arches will be leveled is particularly important. The guideline is that extrusion generally is done more easily postsurgically, whereas intrusion must be accomplished presurgically or handled surgically. Two common problems require special consideration: how to level an accentuated curve of Spee in the lower arch of a patient with deep overbite and how to level the upper arch in a patient with open bite who has a large vertical discrepancy between anterior and posterior teeth.

**Leveling the Mandibular Arch.** When an accentuated curve of Spee is present in the lower arch, the decision to level by intrusion of incisors or extrusion of premolars must be based on the desired final face height. In short-face, deep bite patients who need additional face height, almost always it is advantageous to level the lower arch after surgery. Before surgery, the teeth are aligned and the anteroposterior and vertical position of the incisors is established, but the lower arch is not leveled beyond that point, and steps are needed in all rectangular archwires, including the surgical stabilizing wire. This means the surgical splint will be thicker in the premolar region than anteriorly or posteriorly. At operation, normal overjet and overbite are created, and the space between the premolar teeth is corrected postoperatively by extruding these teeth with working archwires with a reverse curve of Spee.

The leveling occurs rapidly, typically within the first 8 weeks after orthodontic treatment resumes, because there are no occlusal contacts to oppose the tooth movement. Some clinicians attribute this to a regional acceleration of bone remodeling due to the ramus osteotomy. That seems unlikely because of the distance from the

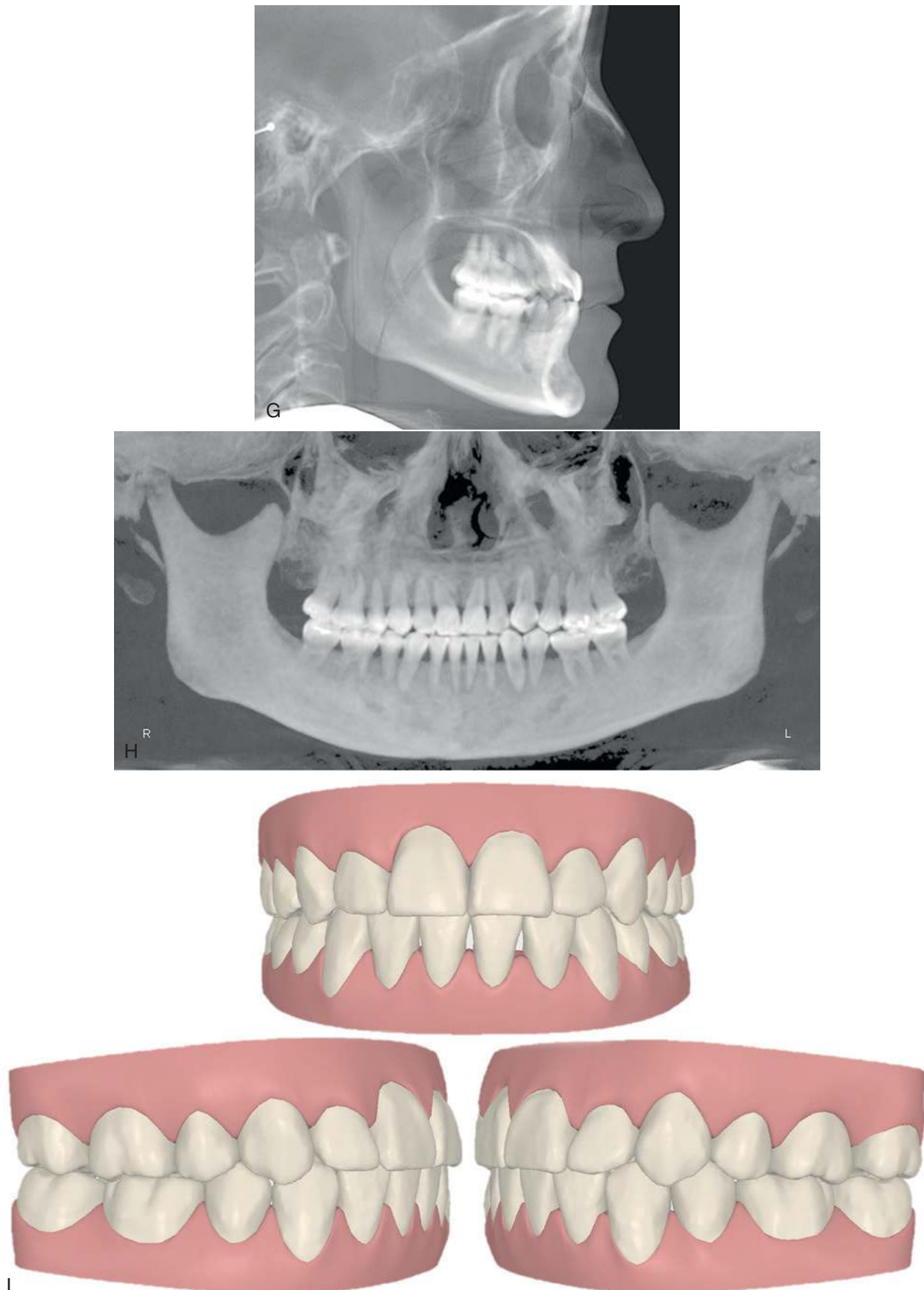
surgical site. Regional acceleration of tooth movement occurs quite locally, not at distance beyond a few millimeters.

If intrusion is required to keep from increasing face height too much, a segmented arch approach (see [Chapter 10](#)) is indicated in the presurgical orthodontics. For the lower arch, surgical leveling

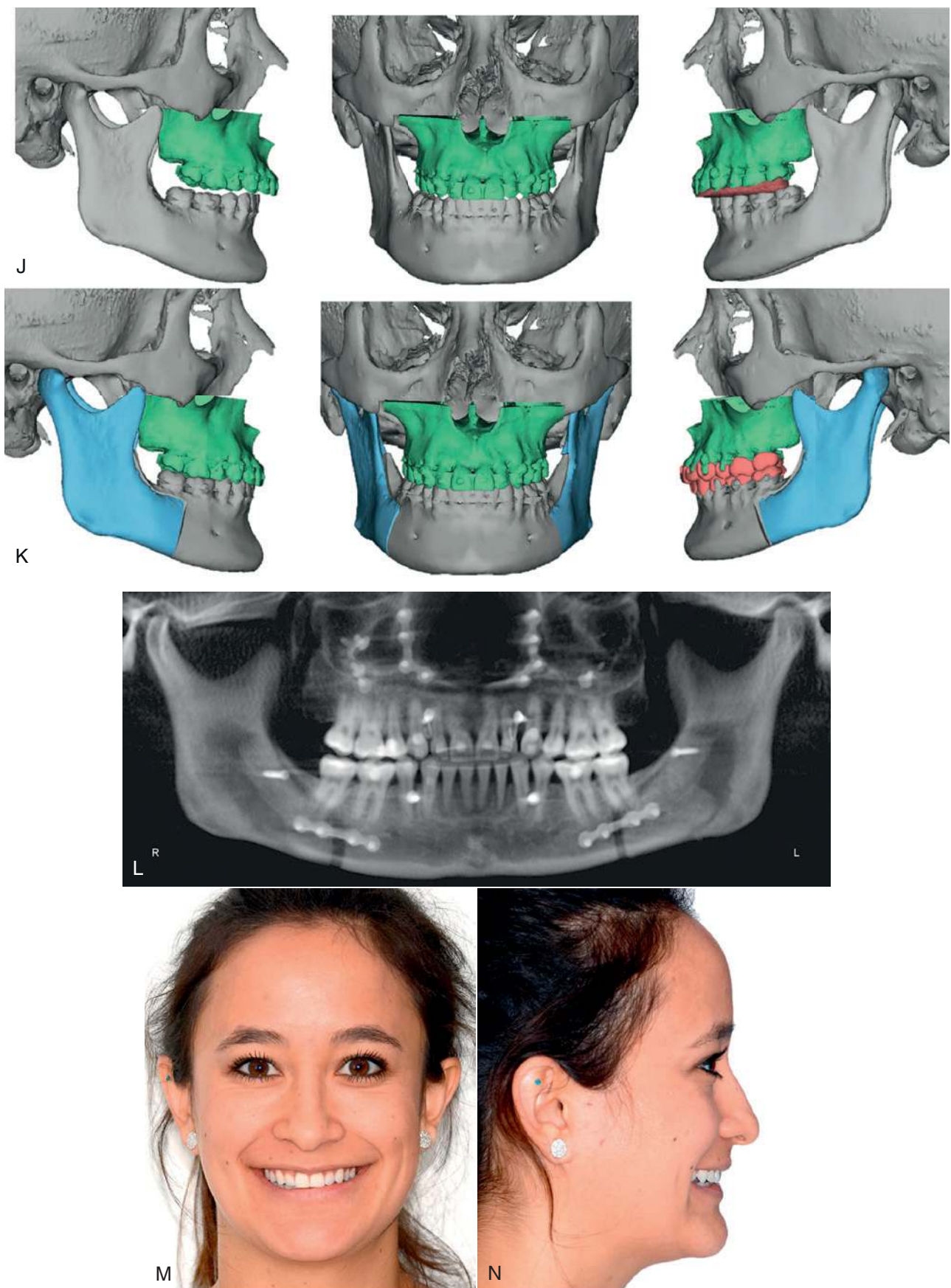


• **Fig. 20.29** Orthognathic surgery cases now can be managed with Invisalign rather than a fixed appliance, but temporary attachments for intermaxillary fixation while rigid internal fixation is placed are necessary. A set of aligners for presurgical tooth movement and a second set for postsurgical orthodontics are required. (A and B) This woman sought treatment because she was worried about the way her upper teeth were behind her lower teeth, the presence of intermittent temporomandibular (TM) joint pain, and the concave appearance of her midface. She had inadequate display of her maxillary incisors on smile. (C to F) Intraoral views before treatment. Note that both maxillary lateral incisors are in a crossbite relationship whereas the other anterior teeth are end-to-end with the lower arch. *Continued*



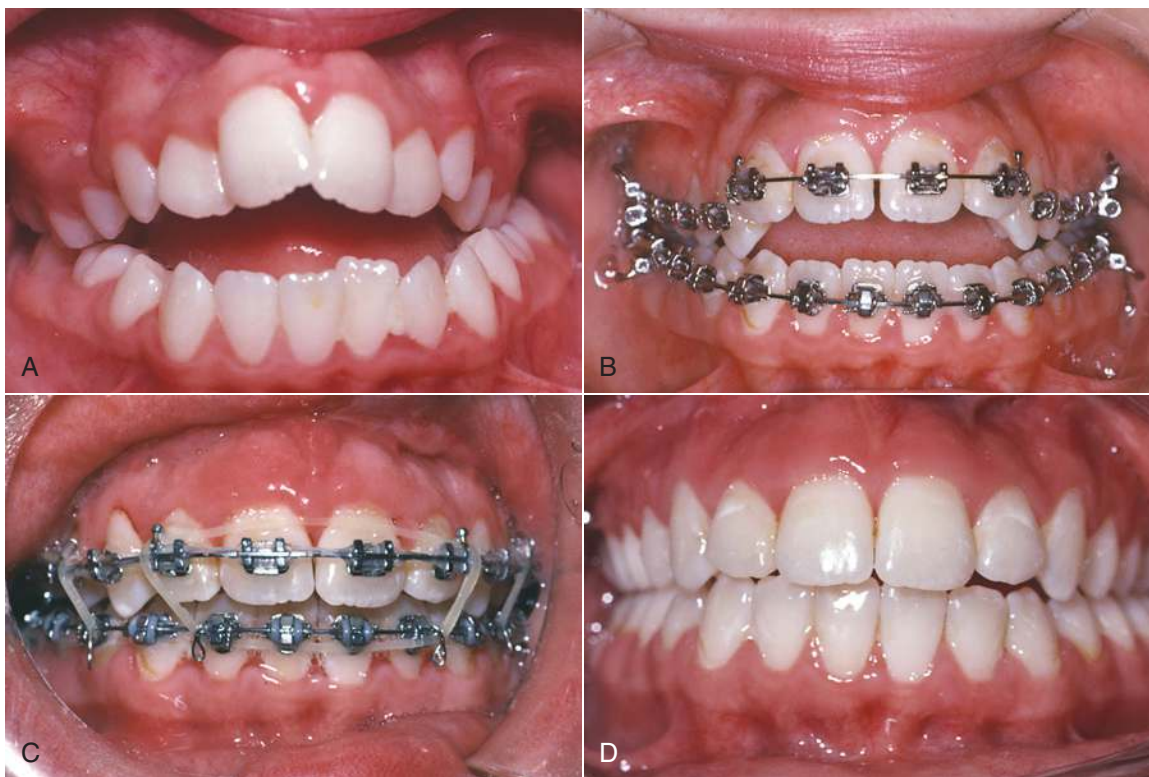

• **Fig. 20.29, cont'd** (G) In her diagnostic workup, a large-field-of-view cone beam computed tomography (CBCT) scan was done, and the pretreatment “synthetic ceph” constructed from the three-dimensional (3-D) data shows the severe maxillary deficiency and protrusion of the maxillary anterior teeth, with the mandibular anterior teeth relatively retruded to the mandible. There was no evidence of TM joint pathology. (H) A “synthetic pan” revealed that all her teeth had short and conical roots, so they were at high risk of root resorption during orthodontics unless force levels could be kept low. Invisalign treatment was offered because it would be quite compatible with work that put her on public display frequently. (I) The first of three ClinCheck plans for her treatment, showing the alignment possible with forward movement of the maxilla and uprighting of the maxillary and mandibular teeth.



• **Fig. 20.29, cont'd** (J) Based on the CBCT images, the plan included Le Fort I osteotomy of the maxilla with 6 mm of maxillary advancement and rotation of the maxilla to move the anterior teeth down and the posterior teeth up. (K) A mandibular bilateral sagittal split osteotomy (BSSO) would then be used to slightly advance the mandible and fit it with the repositioned maxilla. To do this, an intermediate University of Southern California full-coverage splint with partial coverage of the teeth for better positional control of the bony segments was used to relate the repositioned maxilla to the intact mandible. Then a second final splint was used to relate the mandible to the maxilla after maxillary fixation was completed. Temporary labial attachments shaped to retain wires and/or elastics were placed before operation for fixation to allow placement of the bone plates for stabilization; these were removed when the postsurgical aligner therapy began. (L) A synthetic panoramic radiograph after operation shows the maxillary and mandibular bone plates. (M and N) Facial appearance after treatment. The greater prominence of the maxilla and increased display of the maxillary teeth with the teeth at correct inclinations and a compatible smile arc were a major part of the esthetic improvement. (Courtesy Drs. D. Grauer and R. Relle.)





• **Fig. 20.30** In preparation for maxillary segmental surgery, often it is better for the orthodontist to level and align the teeth only within the planned segments, leaving complete leveling of the arch to the surgeon. (A) Pretreatment occlusal relationships in a patient with anterior open bite, a narrow maxilla, and posterior crossbites, in whom treatment with superior repositioning of the maxilla in three segments was planned. (B) Leveling and alignment have been accomplished within the planned anterior and posterior maxillary segments, with archwire segments rather than a continuous archwire. Note that for this patient, the canines are in the posterior segments. (C) Occlusal relationships during postsurgical orthodontic treatment, with light vertical elastics to maintain the vertical position of the teeth. (D) Completion of treatment with reduction in open bite, posterior crossbite, and overjet.

rarely is indicated, although a subapical osteotomy to depress the incisor segment is possible.

**Leveling the Maxillary Arch.** In a patient with open bite who will have vertical repositioning of the maxilla, severe vertical discrepancies within the maxillary arch are an indication for multiple segment surgery. When this is planned, the upper arch should *not* be leveled conventionally. Presurgical leveling should be done only within each segment (Fig. 20.30), and then the segments are leveled at operation. Extrusion of anterior teeth before surgery must be avoided because even mild orthodontic relapse could cause a problem with postsurgical bite opening.

#### **Establishment of Incisor Position and Space Closure**

The anteroposterior position of the incisors determines where the mandible will be placed relative to the maxilla at operation and therefore is a critical element in planning treatment. This is often the major consideration in planning the closure of extraction sites.

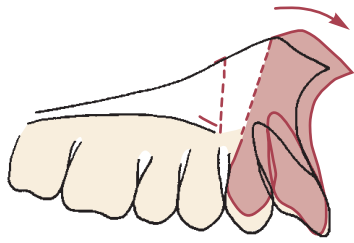
In mandibular advancement, before rigid internal fixation was available, slight over-retraction of protruding lower incisors before surgery was the usual plan. This was done because, while the jaws were wired together as initial healing took place, the incisors would be displaced forward relative to the jaw by the pull of stretched soft tissues. In this situation, the occlusal relationship would be maintained, but orthodontic tooth movement would allow the mandible to slip backward. With rigid fixation of the mandibular

segments, the jaws are immobilized for only a day or two postsurgically if at all, there is little or no pressure against the teeth, and overcorrection of the incisor positions is unnecessary.

When several surgical segments are planned for the maxilla, a different consideration arises: the axial inclination of the upper incisors and canines should be established presurgically so that major rotation of the anterior segment at operation can be avoided (Fig. 20.31). Otherwise, establishing correct torque of the incisors surgically will elevate the canines above the occlusal plane, and proper postoperative repositioning of the canines becomes difficult if not impossible. An extraction site that will be the location of an osteotomy cut should not be completely closed before surgery to leave room for the interdental cuts, but most of the extraction space can be closed without creating difficulty for the surgeon.

Recently, an old idea from the early days of orthognathic surgery was reintroduced: surgery first, without any presurgical orthodontics. This method was evaluated and discarded in the 1970s. The presumed advantages now would be faster treatment because segmental osteotomies could be used to accomplish much of the presurgical tooth movement, teeth close to osteotomy sites might move more rapidly, and patients would be more satisfied because their major problem would be addressed first and total treatment time would be shorter.<sup>21</sup> Not surprisingly, both the surgical procedure (with multiple segments and often corticotomy cuts to accelerate healing) and the postsurgical orthodontics would be





• **Fig. 20.31** In segmental maxillary surgery, it is important to establish the correct inclination of the incisors preoperatively. Otherwise, it will be necessary to rotate the anterior segment at operation in order to maintain the vertical position of the maxillary incisor while its inclination is changed. This tends to elevate the canine off the occlusal plane and diverge the roots at the osteotomy site.

**TABLE 20.1** Sequence of Surgical–Orthodontic Treatment

Consensus Sequence	Surgery First
Orthodontic plan, preliminary surgical plan	3-D imaging (?), surgical plan, postsurgical orthodontic plan, splints
Presurgical orthodontics	Orthodontic appliance only, no surgical stabilizing archwire
Final surgical plan	
Orthodontic surgical procedure with final, intermediate (?) splints	Orthognathic surgery, dentoalveolar surgery, corticotomy (?), intermediate and final splints, temporary anchorage devices (TADs) for postsurgical orthodontics
Minimal postsurgical orthodontics, 3–6 months	Extensive (bone screws or miniplates) for postsurgical orthodontics

more difficult. There would be some limitations in anteroposterior changes because of the lack of presurgical decompensation of incisor positions that often requires TAD-supported postsurgical decompensation. In addition, as we have noted, a longer duration of postsurgical orthodontics (9 to 12 months in most surgery-first patients) has been shown to decrease patient satisfaction with surgical treatment.<sup>20</sup> The treatment sequence with the consensus approach described earlier and surgery first is summarized in Table 20.1.

As of late 2017, most of the limited use of surgery first has been in Asia and Europe, and there still are no good data to document the claimed advantages, but it is generally acknowledged now that patients with severely crowded teeth and deep bites are not good candidates for surgery first.<sup>22</sup> A survey showing that surgery first was less successful in reducing treatment time than many case reports had claimed, and the suggestion that limited presurgical orthodontics would facilitate early surgery, has brought this thinking back closer to the consensus method described earlier.<sup>23</sup>

### Stabilizing Archwires

As the patient is approaching the end of orthodontic preparation for surgery, it is helpful to take impressions and examine the

hand-articulated models for occlusal compatibility. Minor interferences that can be corrected easily with adjustment of flexible archwires can significantly limit surgical movement.

When final orthodontic adjustments have been made, stabilizing archwires should be placed at least 4 weeks before operation so that they are passive when the impressions are taken for the surgical splint (usually 1 to 2 weeks before operation). This ensures that there will be no tooth movement that would result in a poorly fitting splint and potential compromise of the surgical result.

The stabilizing wires are full-dimension edgewise wires (i.e., 17 × 25 steel in the 18-slot appliance, 21 × 25 TMA or steel in the 22-slot appliance). Hooks as attachments to the archwires are needed to tie the jaws together while rigid fixation is placed. These can be added at the time of the splint impressions. They can be brass wires soldered to a steel stabilizing wire or prefabricated ball-hooks that are soldered or mechanically locked in place on the archwire. Sliding the ball-hooks over the wire without securing them is undesirable because they can slip or rotate when they are used to tie the jaws together during operation. For patient comfort, tucking the hooks in toward the gingiva is essential. Tight intermaxillary fixation is necessary at least long enough to place rigid fixation.

With surgery first, often there are no archwires at operation, but an orthodontic appliance has been placed so that archwires or archwire segments can be placed at operation or soon afterward. Typically, active orthodontic treatment begins during the first postsurgical week, which is not a happy time for patients undergoing steroid withdrawal.

## Patient Management at Operation

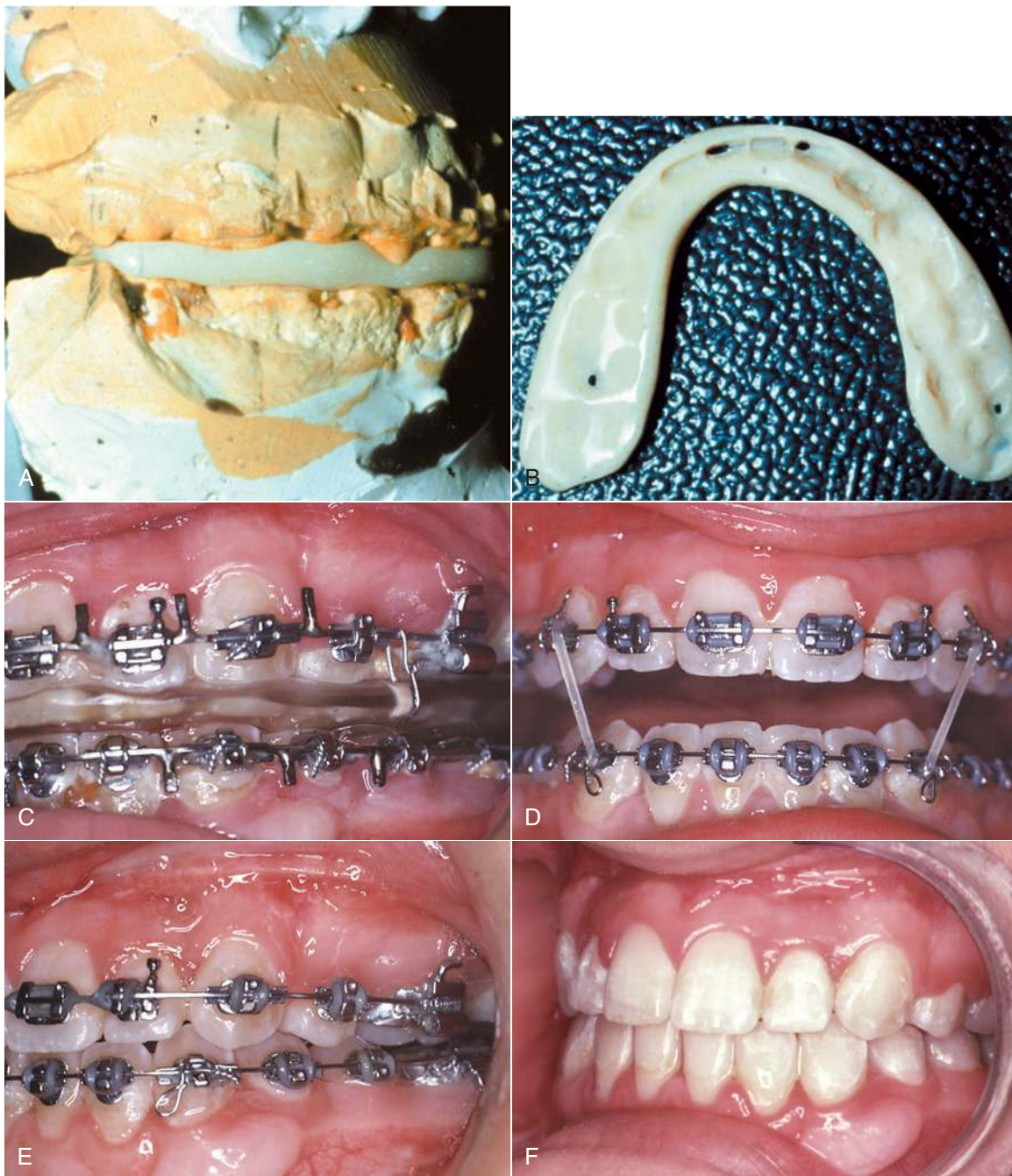
### Final Surgical Planning

When the orthodontist considers surgical preparation completed, presurgical records should be obtained. If jaw asymmetry is to be corrected or use of computer-formed archwires is planned, cone beam computed tomography (CBCT) is indicated. Otherwise, the presurgical records consist of panoramic and lateral cephalometric radiographs, periapical radiographs of interdental osteotomy sites, dental casts, and photographs. Casts should be mounted on a semiadjustable articulator (or detailed scans oriented to its virtual equivalent) if maxillary surgery is planned. To avoid distortion, it is better to take the impressions with the stabilizing archwires removed. The archwires should be passive by the time these final presurgical impressions for model surgery and splints are taken.

The final planning requires a repetition of the predictions that were done initially. The difference is that the actual rather than predicted orthodontic movements are now available. It frequently is observed that teeth have not been fully decompensated, and this must be considered in the final plan. A current cephalometric radiograph (or the CBCT) is used to simulate surgical movements and evaluate the resulting soft tissue profile. When satisfactory functional and esthetic balance has been achieved, the surgical movements are duplicated in the virtual or actual model surgery, and the surgical splint is fabricated according to the dental relationships it established (Fig. 20.32).

### Splints and Stabilization

We recommend the routine use of an interocclusal wafer splint made from the casts as repositioned by the virtual or actual model surgery. Because this splint will define the postsurgical result,



• **Fig. 20.32** Surgical splints play an important role in obtaining the planned surgical outcome. (A) For this patient with mandibular deficiency and a deep bite anteriorly, the plan was to level the mandibular arch after mandibular advancement surgery. An interocclusal splint was fabricated using the model surgery casts, articulated as they would be after operation. (B) For a patient such as this one, the splint can be quite thin in the anterior and molar areas (note that two incisors and a molar on each side teeth touch through the splint) and thicker in the canine and premolar areas. (C) After the operation the patient functions into the splint, which is tied to either the maxillary (as here) or mandibular archwire, until the surgeon is satisfied with initial healing. (D) At that point the interocclusal splint and the stabilizing archwires are removed (the splint should *not* be removed until the stabilizing archwires also are replaced), and light working archwires are placed. For this patient, the maxillary archwire was 17 × 25 beta-titanium (beta-Ti) and the mandibular archwire was 16-mil steel. Light posterior box elastics are worn full-time, including when eating, for the first month. During the second month, the elastics can be removed during eating, but otherwise are worn full-time. (E) After 2 months, the teeth usually have settled into occlusion, and the vertical elastics can be reduced to night only. (F) Braces removed, 4 months after postsurgical orthodontics began. Note the gingival graft that was placed presurgically to prevent stripping of tissue facial to the mandibular left canine.



the orthodontist and surgeon should review the model surgery together. In patients requiring prosthodontic rehabilitation, the dentist responsible for this phase of treatment should be consulted about the acceptability of abutment and ridge relationships. The final planning for the surgical cuts and movements at operation can be done interactively with Medical Modeling (Denver, CO) or a similar service, and both intermediate and final splints can be fabricated there or printed with other software (see Figs. 20.29 and 20.33).

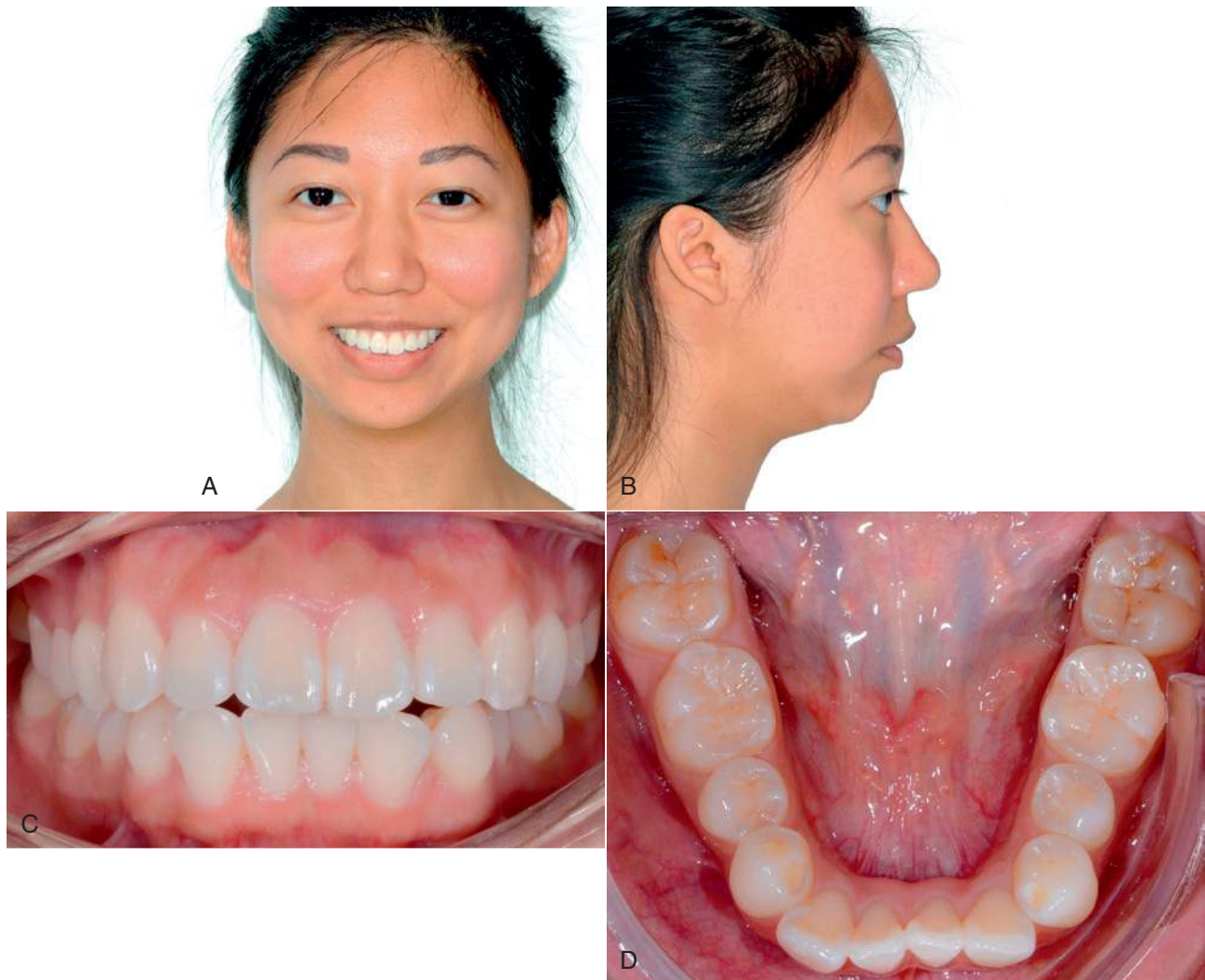
The splint should be as thin as is consistent with adequate strength. This means that it almost never should be more than 2 mm thick at the thinnest point where teeth are separated minimally. When the lower arch has not been leveled presurgically, some teeth can contact through the splint (see Fig. 20.30B).

Because the splint stays in place during initial healing (typically 2 weeks now), it should be trimmed to allow good access to the teeth for hygiene and permit lateral movements during jaw function. It is a mistake to remove the splint immediately after its use in the operating room. It should remain in place until the stabilizing wires also are replaced with lighter and more flexible archwires.

### Postoperative Care

With the current emphasis on controlling health care costs, hospital stays for modern orthognathic surgery have been reduced considerably. Sagittal split osteotomies of the mandibular ramus often are

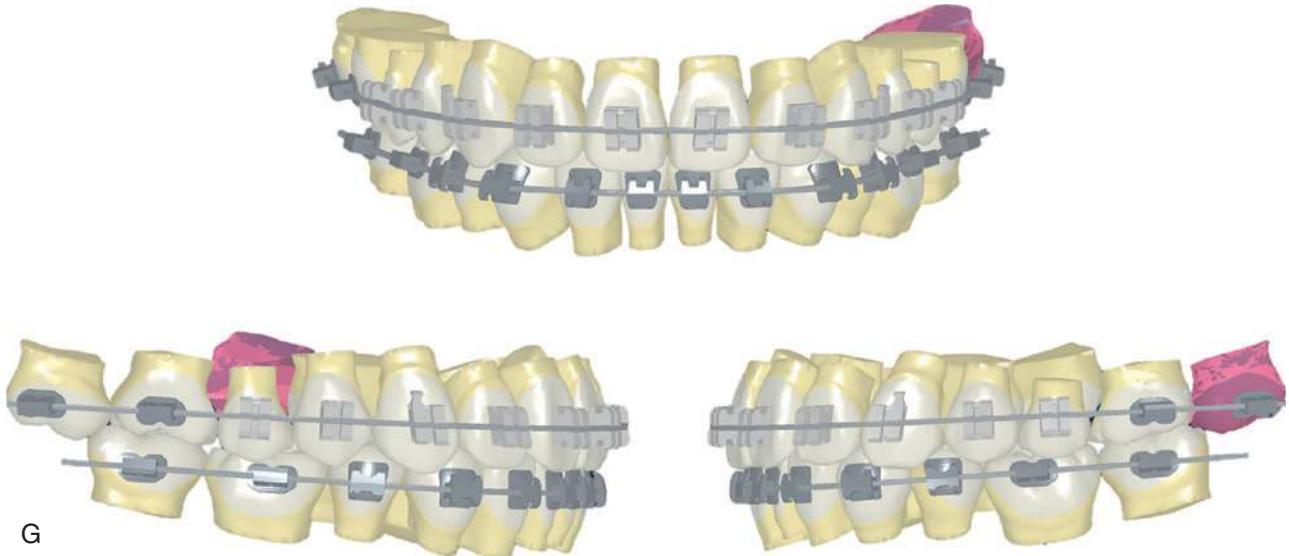
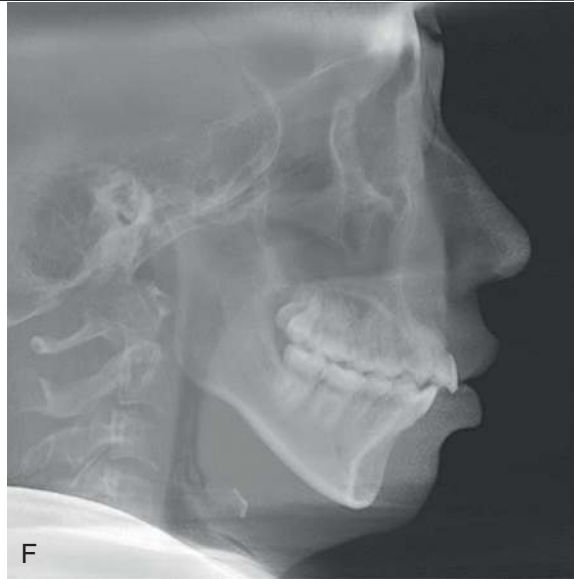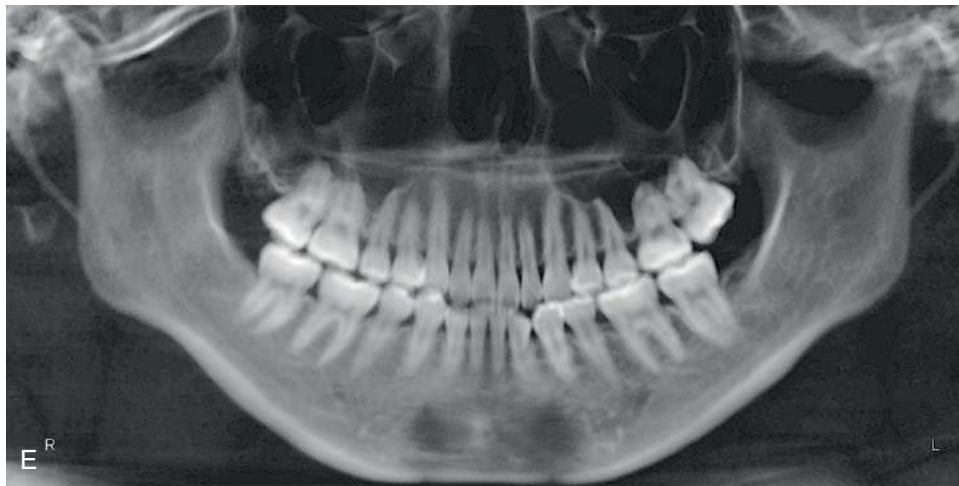
*Text continued on p. 704*



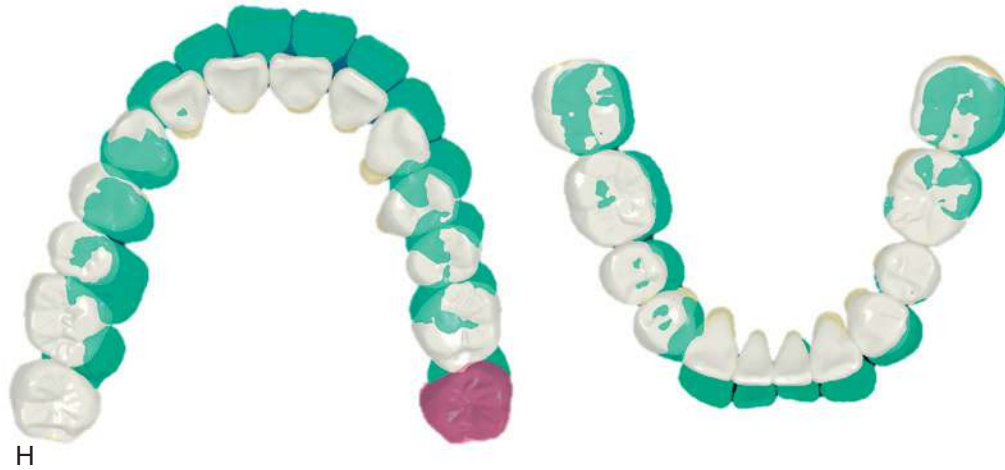• **Fig. 20.33** Customized orthodontic appliances combined with virtual surgical planning and splints now make it possible now to deliver exceptionally precise treatment outcomes. (A and B) Facial views before treatment for a patient who was concerned about her chin deficiency and its effect on her appearance, the gingival display during smile, and the lack of contact between her anterior teeth. (C and D) Frontal view of occlusion and lower occlusal view. The maxillary incisors were well aligned after previous orthodontic treatment; the lower anterior teeth were protrusive and slightly crowded even though she had congenitally missing lower canines.

*Continued*

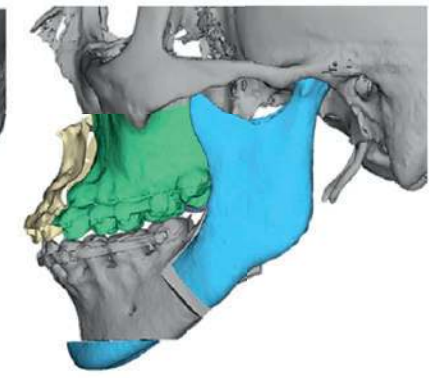
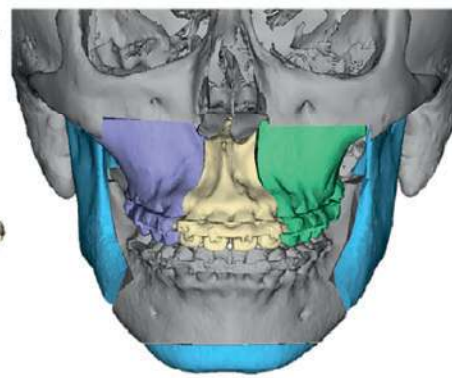
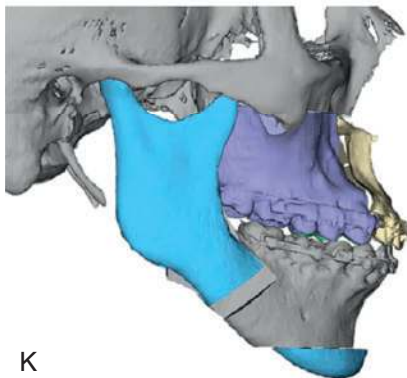
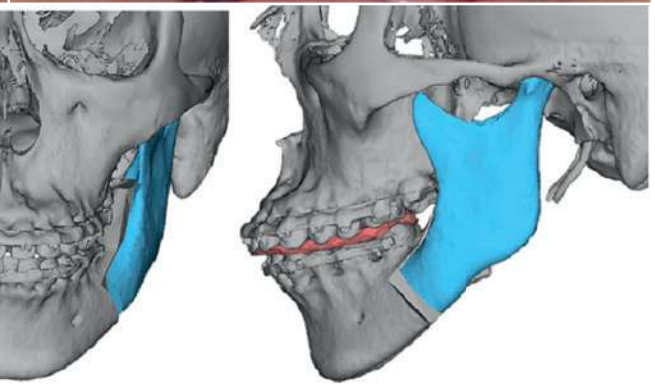
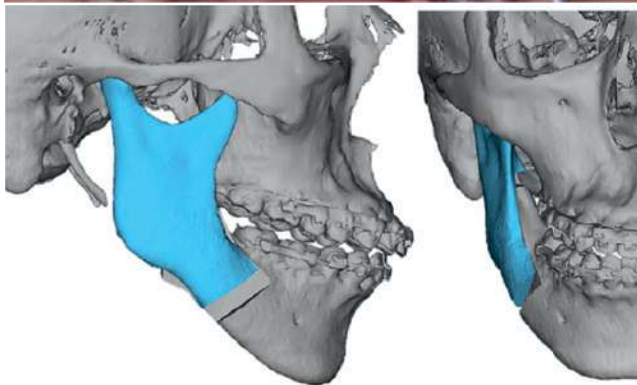
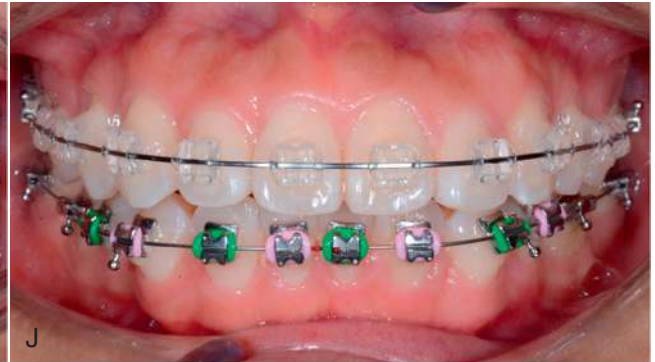
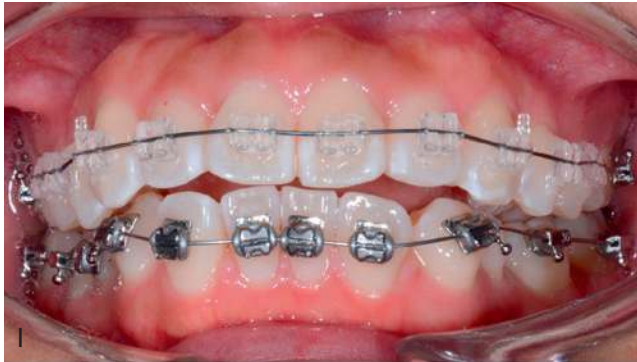


• **Fig. 20.33, cont'd** (E and F) Pretreatment panoramic and cephalometric views reconstructed from the cone beam computed tomography scan. Note the extreme protrusion of the lower anterior teeth relative to the chin but the reasonably normal inclination of maxillary incisors, which was the result of extensive Class II elastic wear during previous treatment but good torque control of the maxillary teeth. This probably also contributed to the mild anterior open bite. The result now would be correctly labeled as an orthodontic camouflage failure. (G) Computer-guided braces are fabricated on a virtual set-up. This allows for assessment of the compatibility of the dental arches, the intra-arch alignment, and the occlusion planned after surgical treatment. The virtual set-up is a diagnostic, treatment planning, treatment delivery, and communication tool. The red second molar in this image was not present in the digital scan and was mirrored from the contralateral one to fabricate its tube.



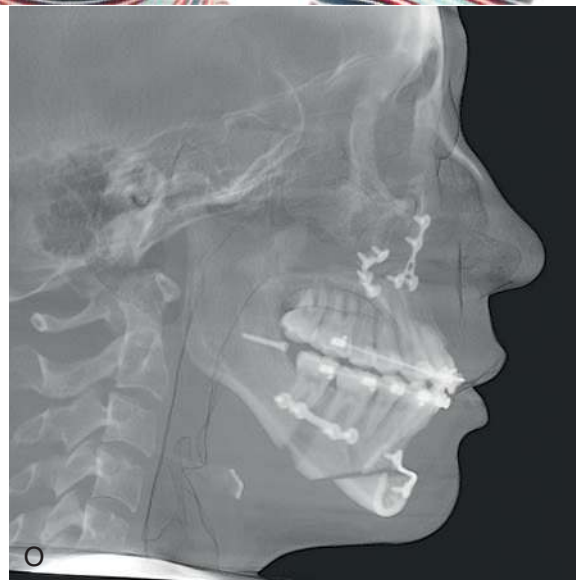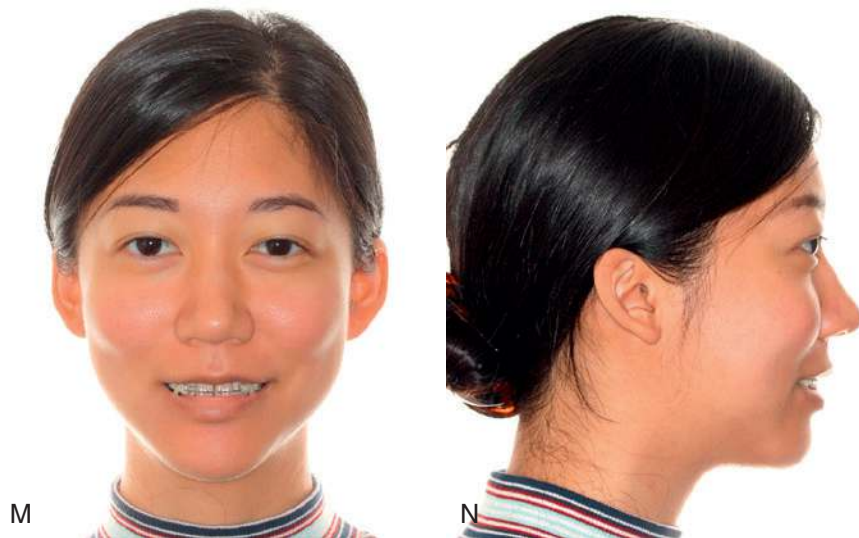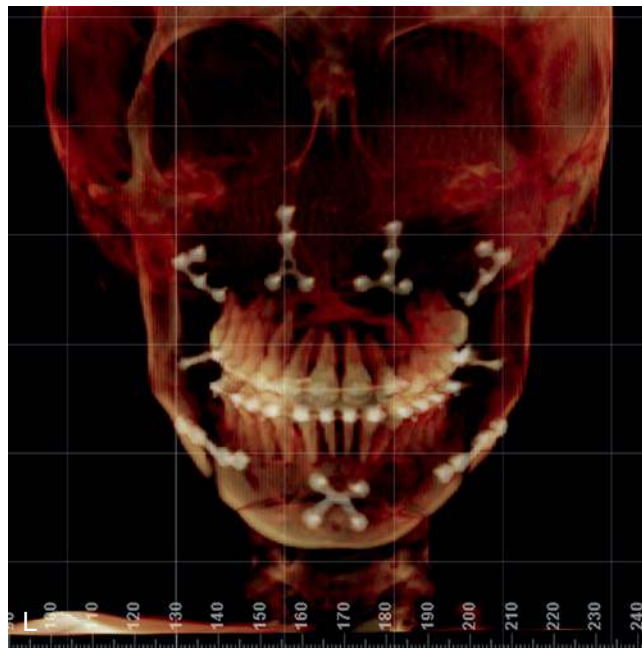
H



K

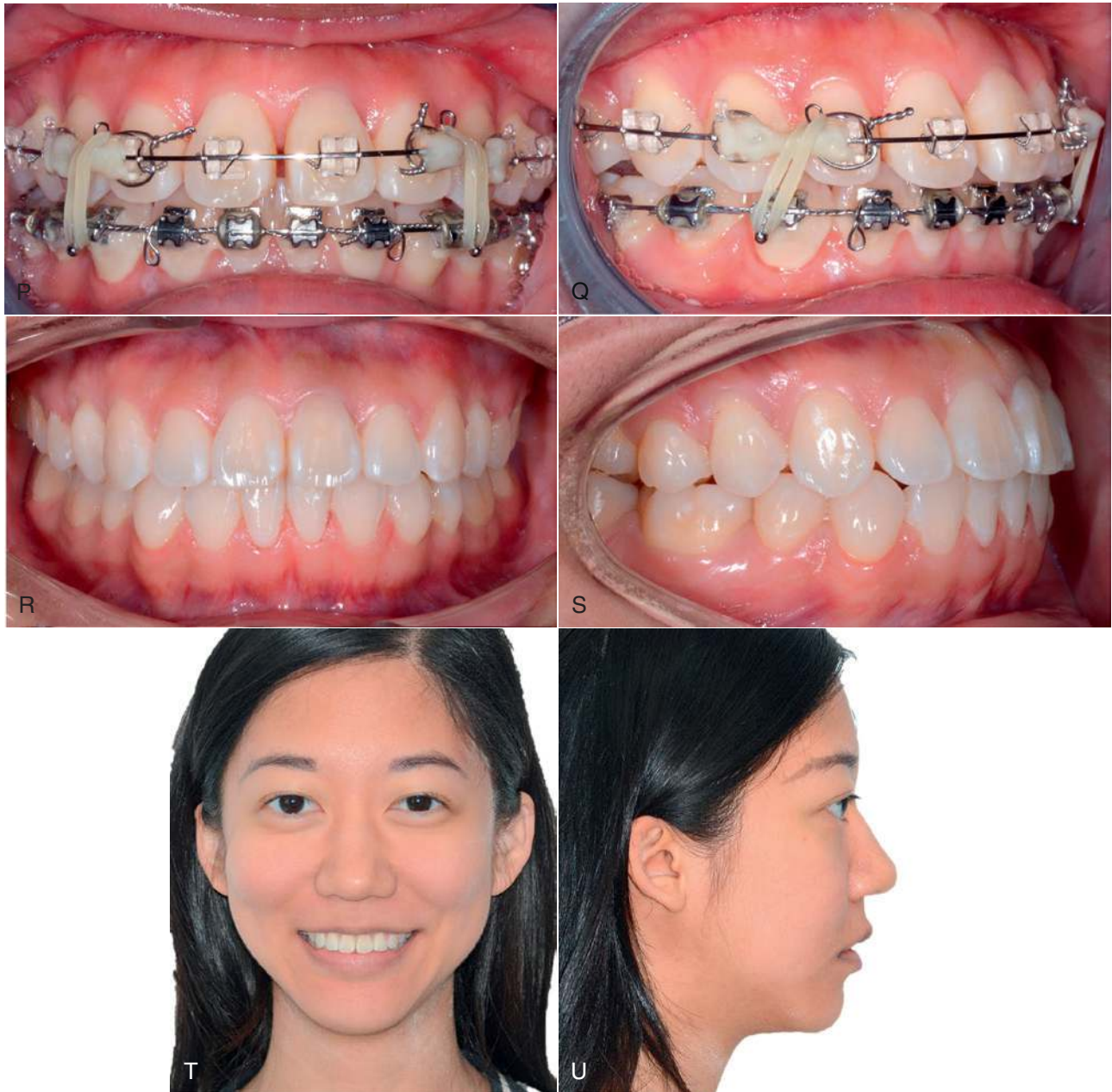
• **Fig. 20.33, cont'd** (H) This image (*green*, final position; *white*, original position) shows a comparison between the initial malocclusion and virtual goals. For the mandible it shows the change in tooth position that will be achieved with the customized fixed appliance. For the maxilla it depicts the tooth movement change and the change in occlusion that will occur at operation. The patient's treatment plan was (I and J) alignment of the teeth in both arches with preservation of the maxillary incisor vertical position, then (K) operation to advance the mandible, slightly advance and rotate the maxilla to correct the open bite, and reduce the vertical height of the chin and advance it. These images were produced as part of the virtual planning of the surgical procedure that allowed precise positioning of the jaws and fabrication of intermediate and final splints for use at operation.

*Continued*



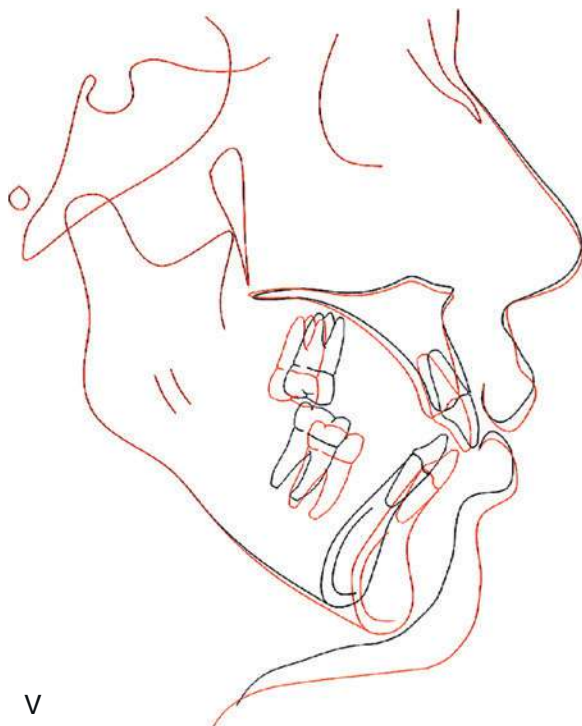
• **Fig. 20.33, cont'd** (L) Three-dimensional (3-D) rendering of the surgical result from cone beam computed tomography images. (M and N) Facial views at 6 weeks after operation, showing the improved facial balance despite some swelling at that point. (O) The postoperative cephalometric image shows the rigid fixation that will remain in place indefinitely. The intermediate and final splints allowed precise placement of the jaws as planned, and the chin also was repositioned as planned. The chin osteotomy angle was established with use of the 3-D plan so that the advancement also produced vertical shortening.





• **Fig. 20.33, cont'd** (P and Q) Vertical elastics were used to stabilize the patient's occlusion in the target position. The final surgical splint was used during operation to ensure that the reposition of the jaws matched the 3-D virtual plan, then was removed and the patient's occlusion performed the function of a final splint—which is possible only if the occlusion is almost ideal at that point. (R and S) Intraoral views at finish. The Class III molar relationship is because of the congenitally missing lower canines but allows perfectly normal function. (T and U) Posttreatment facial images, frontal smile, and profile with lips at rest.

*Continued*



• **Fig. 20.33, cont'd** (V) Superimposition tracing of virtual cephalometric images showing the changes from before to after treatment.

performed now at outpatient surgery centers without overnight hospitalization, and lower border osteotomy of the mandible almost never requires an overnight stay. Maxillary osteotomies also can be managed now at outpatient surgery facilities; two-jaw surgery still usually requires an overnight stay, although that can be at a separate surgical center rather than a general hospital. A well-qualified and experienced nursing team is important in providing the postoperative care. With early discharge after jaw surgery, telephone access to the nursing team is important. Patients require surprisingly little pain medication, particularly after maxillary surgery. Rigid fixation and an early return to jaw movements eliminate the discomfort associated with having the jaws wired together for several weeks.

Patients are advised to maintain a soft diet (e.g., milkshakes, potatoes, scrambled eggs, yogurt) for the first week after operation. Over the next 2 weeks they can progress to foods that require some chewing (soft pasta, meat cut into pieces), using the degree of discomfort as a guide to their rate of progression. By 6 to 8 weeks after operation, they should be back on a normal diet. Note that this coincides with the time when the orthodontist can allow the patient to eat without the use of elastics (see later).

This progression can be assisted considerably by physical therapy beginning as soon as the postoperative intracapsular joint edema is resolved—typically about 1 week after the operation. For the first week, patients are advised to open and close the jaw gently within comfortable limits. Over the next 2 weeks, three 10- to 15-minute sessions of opening and closing exercises as well as lateral movements are indicated, with the patient closing into the splint. From the third to the eighth weeks, the range of

motion is increased. The goal is to achieve optimum function by 8 weeks.

### Postsurgical Orthodontics

Once a satisfactory range of motion has been achieved and the surgeon is satisfied with the initial healing, the finishing stage of orthodontics can be started. It is critically important that when the splint is removed, the stabilizing archwires are also removed and replaced by working wires to bring the teeth to their final position. This means that usually the orthodontist, not the surgeon, should remove the splint.

Light vertical elastics are needed initially with these working archwires (see Fig. 20.33P–Q), not so much for tooth movement—the archwires should do that—but to override proprioceptive impulses from the teeth that otherwise would cause the patient to seek a new position of maximum intercuspation. Until the stabilizing archwires are removed, the teeth are held tightly in the presurgical position. Removing the splint without allowing the teeth to settle into better interdigitation can result in the patient adopting an undesirable convenience bite, which in turn complicates orthodontic finishing and could stress recent surgical sites.

The choice of archwires during postsurgical orthodontic treatment is determined by the type and amount of movement needed. The typical settling of teeth into full occlusion can be achieved rapidly with light round wires (typically 16-mil steel) and posterior box elastics with an anterior vector that supports the sagittal correction. A flexible rectangular wire is used in the upper arch to maintain torque control of the maxillary incisors. In 18-slot brackets, this would be  $17 \times 25$  beta-titanium (beta-Ti [TMA]). In 22-slot brackets,  $21 \times 25$  martensitic nickel–titanium (M-NiTi [Nitinol or equivalent]) often is a good choice. A round wire in the lower arch typically is used because for most patients, more movement of mandibular than maxillary teeth is desired during this settling into occlusion. If that were not the case, it would be better to use a flexible rectangular wire in the lower arch and perhaps a round wire in the upper arch.

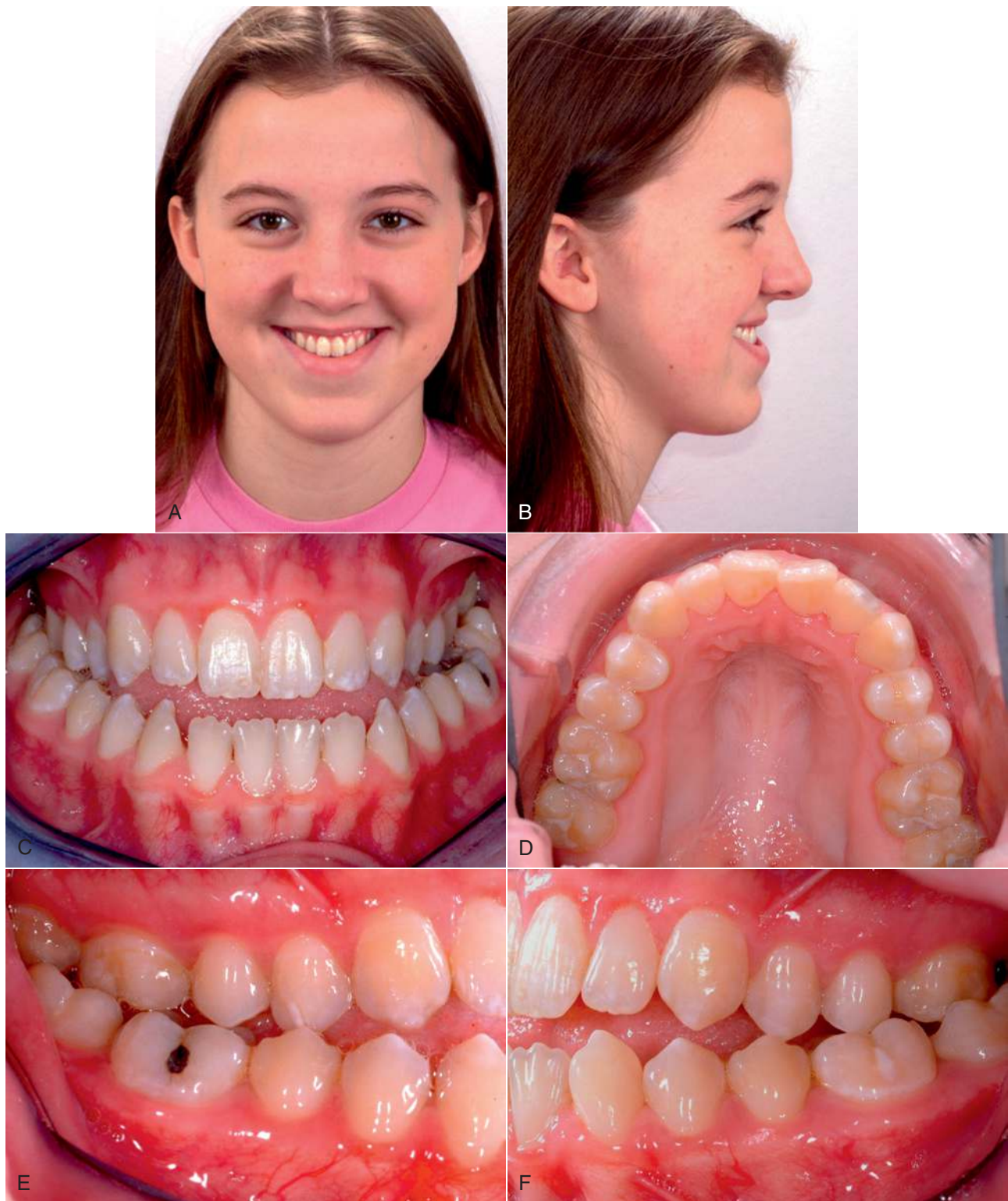Elastics should not be discontinued until a solid occlusion has been established. Typically, patients wear the light elastics full-time, including while they are eating, for the first 4 weeks; full-time except for eating for another 4 weeks; then just at night for a third 4-week period. Elastics can be discontinued during any further detailing of the occlusion. As we have noted, patients are increasingly intolerant of continued treatment after about 6 months, so it is important to finish the postsurgical orthodontic treatment within that time if possible.

Management of two complex cases, one with a customized orthodontic appliance and virtual surgical planning (see Fig. 20.33) and the other with a segmental maxillary osteotomy and adjunctive rhinoplasty and genioplasty (Fig. 20.34), illustrate the application of the principles in surgical–orthodontic treatment that we have emphasized. Details in both cases are provided in the figure captions.

Finally, retention after surgical orthodontic treatment is no different than for other adult patients (see Chapter 18), with one important exception: if the maxilla was expanded transversely, it is critically important not only to maintain the expansion during the finishing orthodontics, but also to have full-time retainer wear in the maxilla for at least 6 months. If a transpalatal lingual arch was placed after surgery, it should not be removed during the first postsurgical year.

*Text continued on p. 709*

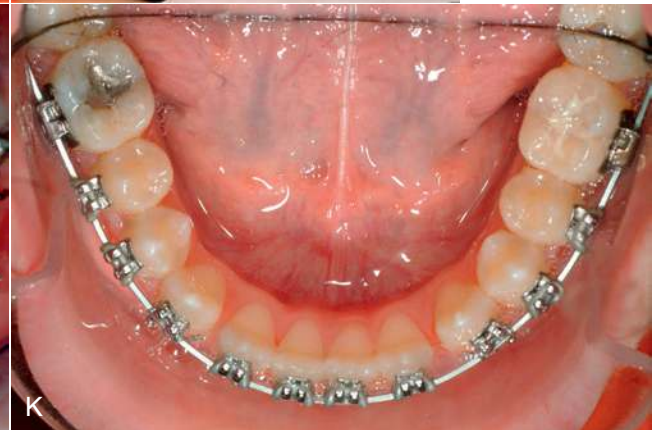
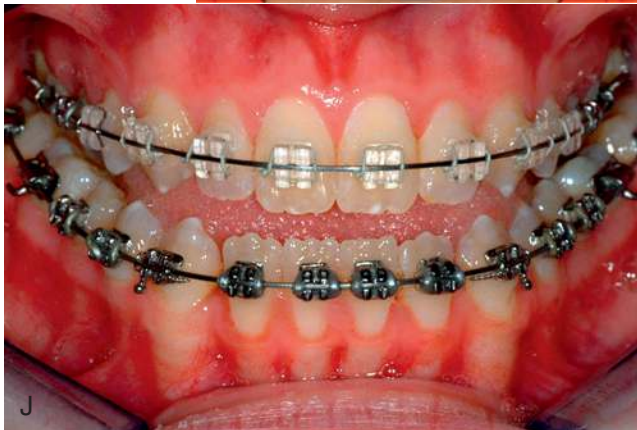
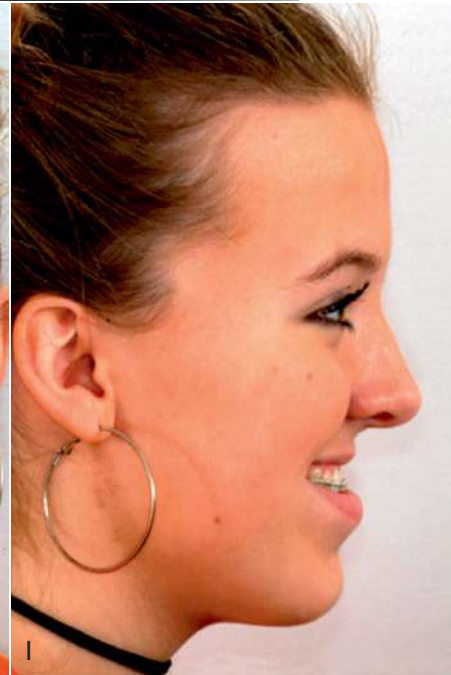
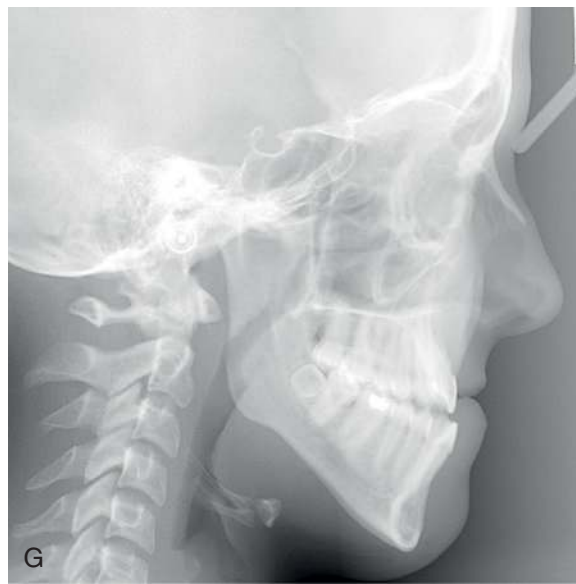
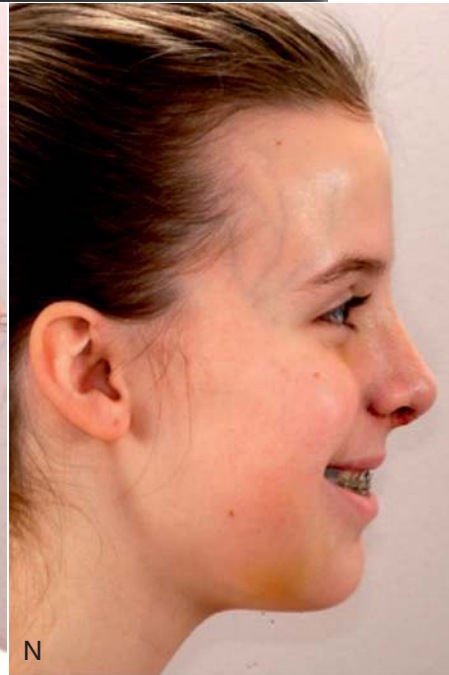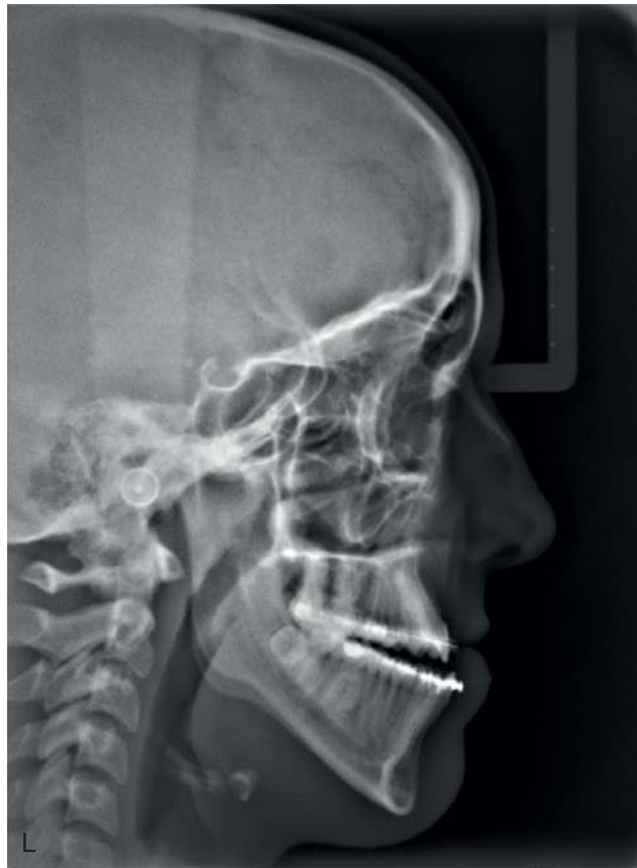• **Fig. 20.34** For a patient who will need significant maxillary advancement, simultaneous rhinoplasty as well as genioplasty should be considered because advancing the maxilla tends to tip the nasal tip up and widen the nostrils. (A and B) Facial appearance at age 15, for a girl who was followed for several years after it was determined that her problems could not be managed with protraction of the maxilla alone, waiting for cessation of growth before correction. Serial cephalometric radiographs are the best way to do this because other indicators of maturation correlate poorly with the end of growth. (C to F) Pretreatment intraoral views showing a full-cusp molar Class III relationship, anterior and posterior crossbites, anterior open bite, and dental midline discrepancy. If you look carefully at the frontal smile (A), you can see that the maxillary midline is slightly to the left of the midface, and the chin is slightly further left.

*Continued*





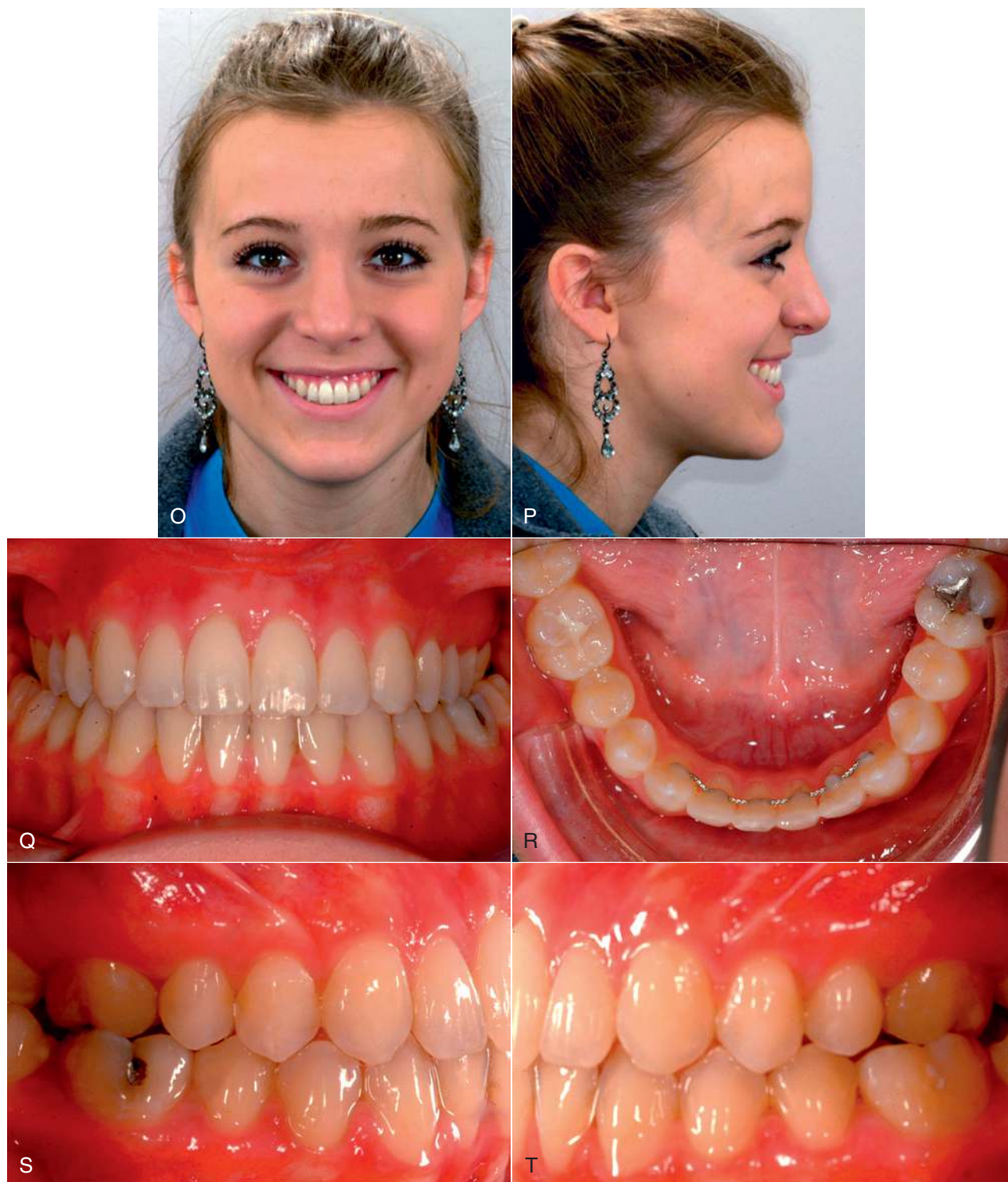
• **Fig. 20.34, cont'd** (G) The cephalometric radiograph shows the skeletal maxillary deficiency, the excess height of the chin (excessive distance from the lower incisors to the bottom of the chin), and the forward position of the lower incisors to the chin. In development of the treatment plan, it was obvious that the maxilla would need to be advanced. The only way to know whether forward movement of the maxilla would also correct the posterior crossbites was to hand-articulate the dental casts. This showed that the posterior expansion would be necessary, so a three-piece maxillary osteotomy was planned along with a lower border osteotomy to remove a wedge of bone above the chin and allow the chin to be moved both up and forward. Because the maxillary advancement would result in some widening of the nasal base, a simultaneous rhinoplasty to maintain nasal width and reposition the nasal tip for optimal esthetics was suggested, and the suggestion was accepted. (H and I) Facial appearance and (J and K) intraoral views.



- **Fig. 20.34, cont'd** (L) Cephalometric radiograph just before operation. (M and N) Facial appearance at resumption of orthodontics 3 weeks after operation. The incisions at the base of the nose to control widening and between the nostrils to improve the nasal tip position and contour also can be seen.

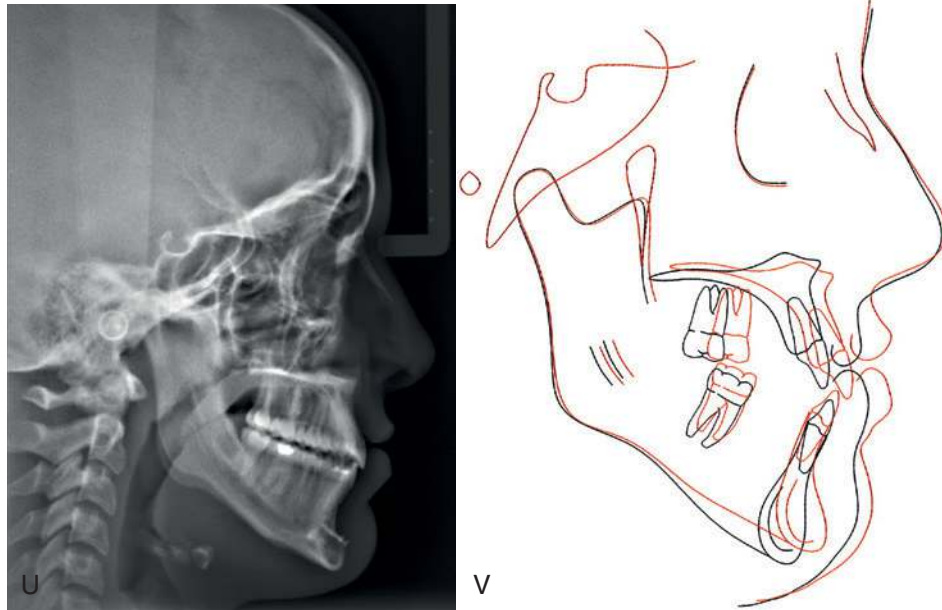
*Continued*





• **Fig. 20.34, cont'd** (O and P) Facial appearance and (Q to T) intraoral views at end of treatment at age 17. Note the correction of the Class III malocclusion and midlines, and the one-half cusp crossbite for the molars. This was accepted because the lower arch was so wide posteriorly that expanding the posterior maxilla that much would have compromised future dental health.





• **Fig. 20.34, cont'd** (U) Posttreatment cephalometric image showing the contribution to the upward-forward movement of the chin to the overall facial balance, and (V) cephalometric superimposition showing the changes from pretreatment to posttreatment. The reduction of face height and anterior positioning of the chin with the genioplasty, and control of nasal tip position and contour with the rhinoplasty, were important components of the treatment outcome.

## References

1. Trauner R, Obwegeser H. The surgical correction of mandibular prognathism and retrognathia with consideration of genioplasty. *Oral Surg Oral Med Oral Pathol.* 1957;10:671–692.
2. Bell WH. Le Fort I osteotomy for correction of maxillary deformities. *J Oral Surg.* 1975;33:412–426.
3. Epker BN, Wolford LM. Middle third facial osteotomies: their use in the correction of acquired and developmental dentofacial and craniofacial deformities. *J Oral Surg.* 1975;33:491–514.
4. Proffit WR, White RP Jr. *Contemporary Treatment of Dentofacial Deformity.* St. Louis: Mosby; 2003.
5. Posnick J. *Orthognathic Surgery: Principles and Practice.* St. Louis: Elsevier; 2013.
6. Oland J, Jensen J, Elklit A, et al. Motives for surgical–orthodontic treatment and effect of treatment on psychosocial well-being and satisfaction: a prospective study of 118 patients. *J Oral Maxillofac Surg.* 2011;69:104–113.
7. Sarver D. *Esthetic Orthodontics and Orthognathic Surgery.* St. Louis: CV Mosby; 1997.
8. Phillips C, Proffit WR. Psychosocial aspects of dentofacial deformity and its treatment. In: Proffit WR, White RP, Sarver DM, eds. *Contemporary Treatment of Dentofacial Deformity.* St. Louis: Mosby; 2003:[Chapter 3].
9. Phillips C, Bailey LJ, Kiyak HA, et al. Effects of a computerized treatment simulation on patient expectations for orthognathic surgery. *Int J Adult Orthodon Orthognath Surg.* 2001;16:87–98.
10. Joondeph DR, Bloomquist D. Mandibular midline osteotomy for constriction. *Am J Orthod Dentofacial Orthop.* 2004;126:268–270.
11. Hamed Sangsari A, Sadr-Eshkevari P, Al-Dam A, et al. Surgically assisted rapid palatomaxillary expansion with or without pterygomaxillary disjunction: a systematic review and meta-analysis. *J Oral Maxillofac Surg.* 2016;74:338–348.
12. Chamberland S, Proffit WR. Short- and long-term stability of SARPE revisited. *Am J Orthod Dentofacial Orthop.* 2011;139:815–822.
13. Sarver DM, Rouso DR. Plastic surgery combined with orthodontic and orthognathic procedures. *Am J Orthod Dentofacial Orthop.* 2004;126:305–307.
14. Chamberland S, Proffit WR, Chamberland P-E. Genioplasty in growing patients. *Angle Orthod.* 2015;85:360–373.
15. Rustemeyer J, Lehman A. Reduction genioplasty enhances quality of life in female patients with prognathism and maxillary hypoplasia undergoing bimaxillary osteotomy. *Int J Oral Maxillofac Surg.* 2013;42:1083–1092.
16. Proffit WR, Phillips C, Turvey TA. Stability after mandibular setback: mandible-only versus 2-jaw surgery. *J Oral Maxillofac Surg.* 2012;70:e408–e414.
17. Snow MD, Turvey TA, Walker D, et al. Surgical mandibular advancement in adolescents: postsurgical growth related to stability. *Int J Adult Orthodon Orthognath Surg.* 1991;6:143–151.
18. Proffit WR, Phillips C, Turvey TA. Long-term stability of adolescent versus adult surgery for treatment of mandibular deficiency. *Int J Oral Maxillofac Surg.* 2010;39:327–332.
19. Roberts HG, Semb G, Hathorn I, et al. Facial growth in patients with unilateral clefts of the lip and palate: a two-center study. *Cleft Palate Craniofac J.* 1996;31:372–375.
20. Kiyak HA, West RA, Hohl T, et al. The psychological impact of orthognathic surgery: a 9-month follow-up. *Am J Orthod.* 1982;81:404–412.
21. Nagasaka H, Sugawara J, Kawamura H, Nanda R. Surgery first skeletal Class III correction using the skeletal anchorage system. *J Clin Orthod.* 2009;43:97–105.
22. Hernandez-Alfaro F, Guijarro-Martinez R, Piero-Guijarro MA. Surgery first in orthognathic surgery: what have we learned? A comprehensive workflow based on 45 consecutive cases. *J Oral Maxillofac Surg.* 2014;72:376–390.
23. Jeong WS, Choi JW, Kim DY, et al. Can a surgery-first orthognathic approach reduce the total treatment time? *Int J Oral Maxillofac Surg.* 2017;46:473–482.

# Index

- A**
- Aborigines, mandibles, example of, 102*f*
- Absolute intrusion, 227*f*
- AcceleDent vibratory system, 263, 263*f*
- Accelerated osteogenic orthodontics (AOO), 260
- bone grafting in, 261*f*
  - corticotomy in, 261*f*
- Accelerated tooth movement, 260–264
- Accommodation, 55
- Achondroplasia
- rarity of, 122
  - severity, midface deficiency in, 123*f*
- Ackerman-Proffit scheme, elements (combination), 196
- Acquisition, of behavior, 51
- Acromegaly, profile view/cephalometric radiograph in, 119*f*
- Acrylic caps, 466*f*
- Acrylic retainer, 435*f*
- Actinobacillus actinomycetemcomitans*, 630
- Activator, 312
- bulk of, removal of, 313*f*
  - tooth-borne passive appliance, 312*f*
- Activator (Andresen), 312
- Active aligners, development of, 310–312, 311*f*
- Active plates, for arch expansion, 312
- Active retainers, 591–594
- modified functional appliances as, 594
- “Active retention”, 569
- “Active stabilization”, 579
- Active tooth-borne functional appliances, 313
- Adams, Philip, 311
- Adams clasp, clinical adjustments of, 311*f*
- Adenoid facies
- appearance of, 131
  - characterization of, 132*f*
- Adenoidectomy, requirement of, 134
- Adenoids, size of, 132
- Adjacent teeth, space (diastema), 5*f*
- Adjunctive facial procedures, 675–680
- Adjunctive orthodontics
- with partial fixed appliance, 600
  - treatment sequence, 602*f*
- Adjunctive orthodontic treatment
- biomechanical considerations for, 601–602
  - comprehensive *versus*, 599–600
  - diagnostic considerations for, 600, 601*f*
  - goals of, 600
  - indication for, 611
  - principles of, 600–603
  - procedures for, 603–614
  - timing and sequence of, 602–603, 602*f*
  - treatment planning considerations for, 600, 601*f*
- Adjunctive periodontal surgery, 569–570
- Adolescence, 84–87
- aging changes in, 96–104
  - alignment, changes in, 98–103
  - complexity of, 54*f*
  - comprehensive treatment in, 528–555
  - dentofacial complex, growth patterns in, 88–96
  - disturbances arising in, 116
  - early permanent dentition years, 84–87
  - facial soft tissues, changes in, 98
  - girls, stages, 86
  - growth at
    - affected by racial, ethnic, and national variables, 87*f*
    - cessation of, 86
    - velocity curves for, 86*f*
  - growth modification
    - fixed functional appliances for, 541
    - headgear for, 541, 542*f*–543*f*
  - imaginary audience, influence, 57
  - incisor display at, age function, 99*f*
  - initiation of, 84–85
  - jaw growth, rotation of, 90–96
  - maturational changes in, 96–104
  - nasomaxillary complex, growth of, 88
  - occlusion, changes in, 98–103
  - permanent teeth, crown height (increase), 105*f*
  - physical development of, 54
  - physical growth, seasonal/cultural factors of, 86
- Adolescents
- aggressive periodontitis in, 147*f*
  - Class II correction in, 538–551
    - differential growth in, 541
  - comprehensive treatment in, 501–527
  - growth, secondary sexual characteristics *versus*, 150*t*
  - jaws, growth of, spurt in, 87*f*
  - maxilla in, transverse force across, 212*f*
  - palatal expansion in, 433–434
- Adult-onset rheumatoid arthritis, impact of, 237
- Adults
- biomechanical considerations for, 601–602
  - chewing movements, contrasts of, 65*f*
  - chewing pattern of, 65
  - complex treatment procedures in, 634–654
  - comprehensive orthodontic treatment in, 614–654
    - gingival grafting, 624*f*
    - psychologic considerations for, 614–616, 616*f*
  - cooperation, problem in, 146
  - facial anthropometric measurements in, 151*t*
  - facial growth in, 96–98
  - growth changes in, 97*f*–98*f*
  - guidance of, 55
  - occlusal equilibrium, 74
  - orthodontic treatment, comparison, 16*f*
  - periodontal evaluation for, 619
  - periodontically compromised, 601*f*
  - swallow pattern, appearance of, 130
  - treatment for, 597
- Aggressive periodontitis, 147*f*
- Airway, establishment of, 64
- Alignment
- arch expansion for, 506, 506*f*–509*f*
  - arches, choice of, principles of, 503–504, 505*f*
  - archwires, properties of, 501–503, 502*f*–504*f*
  - changes in, adolescence, 98–103
  - in Class I crowding/protrusion, 501–512
  - crowding
    - space analysis, 172
    - symmetric, 502
  - evaluation of, 200
  - of impacted teeth, 512–517
  - in nonextraction, 506
  - premolar extraction in, 506
  - pretreatment, with functional appliances, 468–470, 469*f*
  - rectangular archwire for, 504*f*
  - sequence of, 505*f*
  - space, digitized dental casts in, 502*f*
  - of unerupted teeth, 512–517
- Alizarin (dye), 28
- injections of, 28*f*
  - specimen, example of, 33*f*
- AlloDerm, use of, 679
- Alveolar bone
- bending of, 98–101
  - loss of, 267*f*
  - supporting structure, construction of, 124–125
- Alveolar bone height
- tendency for, 273
  - tooth position and, relationship of, 272–273
  - treatment on, effects of, 272–273
- Alveolar process, ultrasound and, 263
- Alveolar segments, repositioning of, 672, 673*f*
- American standard cephalometric arrangement, diagrammatic representation of, 174*f*
- Anatomic drawings, facial structural components (superimposition), 174*f*
- Anatomic porion, 178–179
- Anatomically complete template, 184
- ANB angle, 179
- ANB limitations, 182
- Anchor teeth
- displacement, minimization of, 266*f*
  - PDL pressure in, 266*f*
  - response of, 266*f*
- Anchorage
- availability of, 610
  - with bone screws, 644*f*, 649*f*
  - cortical, 267
  - dental, 442–444
  - for distal movement, 543–547
  - maximum, 535–537
  - moderate, 532–534
  - reinforcement of, 265–266
    - extraoral appliance in, usage of, 296
    - production of, 296*f*
    - requirements of, 296
  - resistance, 265
  - situations, 265–267

- Anchorage (*Continued*)  
 skeletal, 267, 544–547  
 retraction with, 537  
 stationary, 266–267  
 strain, reduction of, 537  
 types of, 295–297  
 value, 265  
 root surface area to, equivalence of, 266f
- Anchorage control, 265–267, 353  
 improvement in, 296  
 mechanical aspects of, 292–298  
 methods for, 295–298
- Angle  
 classification, descriptions of, 195f  
 line, teeth (relationship), 197f  
 system, 194
- Angle, Edward H., 2, 3f
- E-arch, 322, 322f  
 edgewise, 322, 323f  
 paradigms, soft tissue paradigms (contrast), 4t  
 pin and tube, 322  
 rectangular archwire and, 291  
 ribbon arch, 322, 322f  
 sleeping habit, 130
- Animism, 56
- Ankylosed maxillary central incisor, 634f
- Ankylosed maxillary incisor, 631  
 repositioning of, 259–260
- Ankylosed maxillary second primary molar,  
 eruption (delay), 74f
- Ankylosed primary teeth, 383–385, 384f–385f
- Ankylosed teeth, movement of, 259f
- Anodontia, 116–118
- Anterior bite malocclusion, skeletal open bite  
 (characterization), 202
- Anterior box elastic, vertical elastics and, 565f
- Anterior crossbite, 368–372, 607–608  
 correction of, 510f  
 displaced teeth into, 509–510, 510f–511f  
 etiology of, 368–370, 370f  
 example of, 5f  
 flowchart in, 373f  
 nonskeletal, treatment of, 370–372  
 fixed appliance therapy, 371f–372f, 372  
 removable appliance therapy, 370, 371f
- Anterior deep bite, mandibular deficiency with, 698f
- Anterior face height, increase in, 691
- Anterior maxillary implants, mean growth tracks  
 of, 92f
- Anterior midline interdental osteotomies, 670f
- Anterior occlusion, 101–103
- Anterior open bite, 372–375, 563–564  
 correction  
 retention after, 583  
 severity, 669f–670f  
 malocclusion, 131  
 oral habits and open bites, 372–375  
 appliance therapy in, 375, 375f  
 flowchart in, 376f  
 nondental intervention in, 374–375, 375f  
 sucking habits, effects of, 372–374, 374f  
 posterior teeth in, intrusion of, 647–654,  
 650f–656f, 651b  
 prevalence of, 131f  
 sucking habits, impact of, 130  
 thumbsucking, association with, 129
- Anterior overbite, correction of, 226
- Anterior segment, tipping, 266
- Anterior teeth  
 alignment of, 611–614  
 size discrepancy, analysis of, 174
- Anterior vertical dimensions, cephalometric analysis  
 of, 203f
- Anteroposterior facial growth, 429
- Anteroposterior maxillary deficiency, 440–449  
 significance of, 658f–660f
- Anteroposterior plane of space, jaw position  
 (proportion), 153–155
- Anteroposterior problems  
 in preadolescent children, 357–358, 359f  
 prevalence of, 6–7  
 vertical problems combined with, 484–492  
 correction of, 691
- Anteroposterior tooth movement, differential, using  
 extraction spaces, 547–551
- Anthropometric analysis, facial measurements for,  
 152f
- Anthropometric data, cross-section expression of,  
 27
- Anthropometry, 24
- Apical infection, control of, 608–609
- A-pogonion line, usage of, 182–183
- Appliances  
 fixed, 321–349  
 philosophy, 297  
 prescription, 325  
 removable, 310–319  
 therapy, 375, 375f
- Arch expansion, impact of, 210
- Arch form, 342–345
- Arches  
 alignment, choice of, principles of, 503–504,  
 504f–505f  
 circumference, increase, 423f  
 dimensions, 81f  
 length  
 additional, 503f  
 discrepancy, 213  
 relief, 425f  
 mechanics  
 continuous, 308  
 segmented, 306–308  
 vertical clearance, 413  
 width measurements, 186t
- Archwires, 421f  
 alignment, properties of, 501–503, 502f–504f  
 bracket  
 movement, 294f  
 tipping, allowance of, 294f  
 bypass, in intrusion, 521–523, 523f–524f  
 choice of, for postsurgical orthodontic selection,  
 704  
 closing loop in, 530f  
 comparison of, 281–282  
 fabrication, 342–345  
 faciolingual bends, 324  
 move freely, 503–504  
 preformed, 342–343, 342f  
 segmented, for intrusion, 523–525, 524f,  
 526f  
 sequence of, 558b  
 shape of, 285–287  
 size of, 285–287, 285t  
 surface of  
 distortion of, 295f  
 qualities of, 292  
 undersize of, 291  
 “Around the tooth” circumferential supracrestal  
 fibrotomy (CSF) approach, 570f
- Arthritic degeneration, impact of, 237
- Articulator mounting, 168–170
- A-splint, 593f
- Assimilation, 55
- Asymmetric bends, 301
- Asymmetric crowding  
 alignment in, 504  
 incisor alignment in, auxiliary superelastic wire  
 for, 505f
- Asymmetric dental development, in preadolescent  
 children, 360
- Asymmetric facial skeleton, dimensioned  
 stereolithographic model of, 188
- Asymmetric mandibular deficiency  
 causes of, 238  
 condylar fracture causing, 116
- Asymmetric mandibular setback, preoperative and  
 postoperative findings (color map  
 representation), 194f
- Asymmetric V-bend, 301  
 intrusive force and, 304f  
 moment and, creation of, 303f
- Attachment, method of, 512, 513f–514f
- Austenitic NiTi, 279  
 coil springs, 529, 529f  
 wires, activation/deactivation curves for, 280f
- Australian aboriginal man, 9f
- Australian aboriginal mandibles, 102f
- Automatic rotational control, 324, 324f
- Autonomy  
 development of, 52–53  
 example of, 53f  
 failure, 53  
 paternalism *versus*, 229–230
- Autotransplantation, 417–419
- Auxiliary intrusion, 299–300
- Auxiliary leveling archwire, 522f
- Auxiliary NiTi wire, 512–513
- Auxiliary root positioning springs, usage of, 289f
- Auxiliary spring, superelastic wire as, 504
- Auxiliary superelastic wire, 505f
- Auxiliary torquing springs, usage of, 289f
- Average root length change, 271t
- Average-maturing girls, growth velocity for, 23f
- Axial CT, application of, 24
- B**
- Band-and-loop space maintainers, 388–389,  
 389f
- Banded palatal expander, attachment, 433f
- Band-removing pliers, 566f
- Bands  
 for attachments, 325–327  
 cementation, 327, 327f  
 fitting bands, 325–327  
 indications for, 325  
 separation, 325, 326f  
 steps in, 325–327  
 fixed jackscrew appliances attached to, 431  
 removal of, 566
- Basic trust, development of, 52
- Basioccipital bones, location of, 31
- Basion-nasion line, usage of, 182–183
- Beam  
 diameter of, change in, 285f  
 length of, change in, 285f  
 materials, properties of, 276
- Begg, Raymond, 4
- Begg appliance, 321–323, 323f–324f  
 usage of, 289f
- Begg approach, 549–550
- Begg technique, 557f, 559
- Behavior  
 acquisition of, 51  
 modification, operant conditioning (usage),  
 49–50  
 performance of, 51
- Behavioral development, 46–59  
 dentist office, 48  
 learning, relationship of, 47–52  
 stages, construction of, 46–47
- Behavioral evaluation, 145–146
- Bending  
 description of, 281  
 moment, deflection *versus*, 279f  
 nomograms, 283f
- Beta-titanium, 281  
 bending nomograms of, 283f  
 torsion nomograms of, 284f



- Bilateral cleft lip/palate, 113*f*  
 movement in, necessity of, 241
- Bilateral expansion, creation of, 307*f*
- Bilateral toe-in bends, couple creation in, 306*f*
- Bilaterally missing permanent mandibular second premolars, 415*f*
- Bimaxillary dentoalveolar protrusion, 155–156, 528  
 correction of, 532–534  
 in facial appearance, 156*f*
- Bimaxillary protrusion, 155–156
- Binding  
 friction *versus*, 292–295  
 sliding resistance and, 294*f*
- Biologic electricity, 250–251
- Biolux device, 264
- Bionator, 457, 458*f*, 465–466  
 design, 313, 313*f*
- Birth, 60  
 injuries, 114–115  
 physical adaptations of, 60  
 trauma, to mandible, 115
- Bisphosphonates, 258–260  
 impact of, 404–406, 406*f*  
 problem, reasons, 258–259  
 receiving, increase, 406
- Biting force, eruption and, 126
- Björk, Arne, 29  
 implant studies, lateral cephalometric radiograph from, 29*f*
- Black triangles, 573*f*  
 correction of, 221  
 creation of, 630
- Black youths, orthodontic need, 15*f*
- Blood flow, changes in, 252*f*
- Blood vascular elements, ingrowth of, 31
- Blood vessels  
 compression, increase in, diagrammatic representation of, 253*f*  
 dilation of, 252*f*
- Bodily distal movement, 422
- Body  
 growth, jaw growth (correlation), 87  
 movement of, 256*f*  
 proportions  
 changes, schematic representation of, 19*f*  
 secular changes in, 64  
 tissue systems, growth (Scammon's curves), 19*f*
- Bolton analysis, 172
- Bolton point, 177*f*
- Bolton template  
 cranial base superimposition of, 185*f*  
 superimposition of, 185*f*  
 usage of, 184
- Bond failure, 567*f*
- Bonded and banded appliance, 421*f*
- Bonded appliance, advantages of, 559
- Bonded attachments, 327–330, 328*f*–331*f*  
 removal of, 566–567
- Bonded brackets, removal of, 566  
 special pliers for, 566*f*
- Bonded canine-to-canine retainer, 587*f*
- Bonded lingual retainer, 588*f*
- Bonded (fixed) orthodontic retainers, 586
- Bonded palatal expander, usage, 438
- Bonded retainer, alternative, 593*f*
- Bonded splints, fixed jackscrew appliances attached to, 431
- Bonding  
 basis of, 327, 328*f*  
 direct, 327–328, 329*f*–330*f*  
 indirect, 328–330, 331*f*
- Bone  
 anchors, retention of, screws in, 298*f*  
 bending, extent of, 249  
 calcification, occurrence of, 28  
 direct apposition of, 30
- Bone (*Continued*)  
 force to, application of, 249*f*  
 formation, 31  
 graft, 262*f*  
 panoramic radiograph of, 242*f*–243*f*  
 placement of, 241  
 loss of, 237*f*, 625*f*  
 resorption of, 67  
 rate of, 67  
 response, 248–250  
 scan, with <sup>99m</sup>Tc, 239*f*  
 surface  
 apposition of, 30  
 remodeling of, 35*f*
- Bone screws, 345–347, 345*f*  
 design factors for, 347*b*  
 ease of use of, 346*f*–347*f*, 347  
 linked screws in palatal anchorage, 347, 348*f*  
*versus* miniplates, 350*t*  
 stability of, 345–347, 345*f*
- Bone-anchored expanders, configuration of, 436*f*
- Bone-seeking isotope (99mTc), usage of, 239
- Bone-supported miniplates, 444
- Bone-to-bone contact, 667
- Bony changes, vital staining, 28
- Borderline patient, 657–664  
 esthetic and psychosocial considerations for, 663–664
- Bovine or allograft bone, mixture of, 260
- Bow calipers, usage of, 152*f*
- Boys (males)  
 arches, space of, 80*f*  
 height and weight curves for, 87*f*  
 height growth curve for, 63*f*  
 infancy, length/weight growth (graphs), 62*f*  
 mandible  
 fracture, radiographs, 71*f*  
 mean dimensional changes in, 98*f*  
 maturation, slowness of, 87  
 medical problem, growth chart of, 21*f*–22*f*  
 secondary sexual characteristics, attainment of, 150  
 sexual development, stages of, 86
- Bracket fracture, 566
- Brackets  
 ceramic brackets, popularity of, 293  
 composite plastic brackets, usage of, 293  
 debonded, enamel presence on, 567*t*  
 movement of, force for, 294*f*  
 narrow, 502  
 placement of, 602*f*  
 removal of, 566*f*  
 sliding, 295*f*  
 slot dimensions, alteration in, 324  
 surface qualities of, 292–293  
 tipping, allowance of, 294*f*  
 V-bend, position and, 558  
 width of, 291  
 impact of, 291*f*  
 wire orientation, 293*f*
- Bracket/tube prescription, 336*t*
- Brader arch form, 342, 342*f*
- Brain case (calvarium), length increase/width decrease and, 60
- Break-in period, for removable functional appliances, 470
- Buccal corridors  
 negative space of, 160  
 width of, 162*f*  
 maxilla and, transverse expansion of, 218*f*
- Buccal crossbite (X-occlusion), 7
- Buccal drift, 67
- Buccal root torque, 562
- Buccal shields, 467, 468*f*
- Burstone torquing auxiliary, 560, 561*f*
- Bypass archwires, in intrusion, 521–523, 523*f*–524*f*
- C**
- Calcification, sequence of, 60
- Calvarium (brain case), length increase/width decrease and, 60
- Camouflage  
 decision for, 664  
 orthodontic, of skeletal malocclusion, 664*b*  
 surgery, 214–216  
 contrast, 657–664
- Canine  
 brackets, placement of, 604  
 ectopic eruption of, 382*f*  
 replacement, space relationships in, 80–83  
 retraction of, 297*f*, 535–537  
 Gjessing retraction spring for, 537*f*  
 sliding movement and, 296*f*  
 with superelastic coil spring, 506*f*  
 substitution, performance of, 220–221
- Canine-to-canine anterior bow, 585*f*
- Canine-to-canine clip-on, fabrication, steps in, 595*f*
- Cantilever beams, 282  
 illustration of, 277*f*
- Cantilever spring  
 applications of, 299  
 creation of, 300*f*
- Caries (control), fluoridated water and fluoride-containing toothpaste, 273
- Carious lesions, enamel, 273
- Cartilage  
 craniofacial growth determinant, 38–42  
 growth center, tests, 40  
 proliferation of, 32*f*  
 removal, effect (tests), 41  
 theory, usage, 38–39
- Cartilaginous nasal septum  
 loss, cases of, 41–42  
 removal of, 41*f*
- Cartilaginous skeletal development, occurrence, 30
- Case presentation, outline (example), 229*b*
- Catenary curve, 3*f*
- Cell membrane potentials and permeability, electromagnetic fields and, 251
- Cementation, 327, 327*f*
- Cemented habit crib, 375*f*
- Cemented Twin-Block, 462
- Cementum, clast cells and, attack of, 271*f*
- Center of resistance  
 attachments in, extension of, 289*f*  
 bodily movement, 625*f*  
 definition of, 288  
 midpoint of, 288*f*
- Center of rotation, definition of, 288–289
- Central incisors  
 crown in, placement of, 609*f*  
 different height-width ratios for, 572  
 elongation of, 222*f*  
 eruption of, 75  
 protrusion of, 289  
 spaces develop in, 435*f*
- Cephalocaudal growth gradient, 19
- Cephalometric analysis, 174–186  
 development of, 175–178  
 early, 174–175  
 goal of, 177–178  
 lateral digitization model for, 178*f*
- Cephalometric data, cross-section expression of, 27
- Cephalometric landmarks, definitions of, 177*f*  
 lateral cephalometric tracing, usage of, 177*f*
- Cephalometric methodology, in digital age, 185–186
- Cephalometric radiograph, 170–171  
 digitizing, 153*f*  
 disadvantage of, 24  
 head positioning device, usage, 24*f*  
 obtaining, 67

- Cephalometric radiograph (*Continued*)  
 synthetic ceph, comparison of, 189f  
 vertebral pathologic characteristics in, 176f
- Cephalometric radiography  
 advent of, 151  
 popularity of, 4
- Cephalometric radiology, 24, 24f
- Cephalometric superimpositions  
 changes in, display of, 234f–235f  
 growth modification and, 455–457, 456f  
 response to removable functional appliance, 469f  
 tracings, 176f
- Cephalometric tracings, superimposition of, 26f
- Cephalometric values, 180t
- Ceramic brackets, 332, 332f, 333t  
 debonded, 566  
 popularity of, 293
- Cervical headgear  
 appliance, 462f  
 components of, 477f
- Cervical neckstrap, 462f
- Cervical vertebra maturation staging (CVMS), 433–434
- Cervical vertebrae, lateral cephalometric radiograph of, 68f
- Cheek  
 holding, buccal shield, 468f  
 loss, of tropical infection (impact), 125f  
 pressures, 129  
 resting pressures from, 250f  
 teeth, vertical relationship of, 198f
- Chewing  
 activity, pressure (generation), 125–126  
 simulation, occlusal force (comparison), 127f
- Chief concern, 140–142, 141f
- Childhood  
 diastema, spontaneous correction of, 5f  
 jaw fractures, 115–116  
 malignancies, long-term survival after, 237  
 midline diastema, presence in, 5–6  
 progressive deformities, 115–116
- Children  
 acquired behavior, performance (factors), 51  
 adenoidectomy, requirement of, 134  
 composite (mean) cephalometric tracings for, 134f  
 adults, chewing movements (contrast), 65f  
 aggressive periodontitis in, 147f  
 asymmetric mandibular deficiency, condylar fracture causing, 116  
 comprehensive orthodontic treatment for, 237  
 cooperation, problem in, 146  
 dentist treatment area, exit (reward), 50f  
 developmental parameters, changes of, 69f  
 ectodermal dysplasia in, 120f  
 environmental influences in, 124–134  
 equilibrium considerations in, 124–125  
 facial asymmetry in, 492–497  
 genetic influences in, 121–124  
 infantile swallow in, 130  
 instructions, example of, 57f  
 mandibular asymmetry in, 116f  
 maxillary incisors, lateral flare, 81f  
 medical/dental history, obtaining, 142f–144f  
 normal-face children, occlusal forces (comparison), 128f  
 parents, bond, 52  
 posterior bite blocks, vertical development and, 490f  
 rapid palatal expansion in, 432f  
 sucking, habits and, 126–130  
 tonsillectomy, requirement of, 134  
 treatment, cooperation with, 53
- Chin  
 augmentation of, 675–677, 678f  
 deviation of, 199f, 493f–495f
- Chin (*Continued*)  
 implant for, advantages of, 677  
 inactivity of, 36  
 prominence, accentuation of, 88  
 protrusion, complaints on, 224  
 reduction of, 675–677  
 sectioned, 668f
- Chin-cup  
 appliances, 450–451, 450f–451f  
 hard plastic cup, 450
- Chondrocranium  
 development of, 31f  
 early stage, diagrammatic representation, 41f  
 maturation of, 31f
- Chronic illness, 61  
 impact of, 61
- Chronic respiratory obstruction, production of, 132
- Chronologic ages, developmental stages (association), 52
- Cingulum thickness, reduction of, 220f
- Circadian rhythm, 72  
 of skeletal growth, 470
- Circumferential supracrestal fibrotomy (CSF), 570
- Clasps, for retention, 467, 467f
- Class I crowding/protrusion, 501–518, 502f
- Class I malocclusion, 6–7
- Class II buccal segment, 201
- Class II camouflage, 541–551  
 by extraction, of upper first premolars, 547–548, 549f–550f
- Class II correction, 528–555  
 in adolescents, 538–551
- Class II elastics  
 for distal movement, 543  
 effect, 463–465
- Class II growth  
 modification, 455–481  
 completion of, 225  
 fixed Class II correctors for, 462  
 functional appliances for, 457–459, 457f–461f  
 headgear for, 459, 462f–463f  
 treatment strategies for, evolution of, 455  
 pattern of, 194  
 continuation, 582f  
 retention and, 580–582
- Class II jaw relationship, 194
- Class II malocclusion, 411–413, 528  
 correction of, 569  
 maxillary incisors, retraction of, 157f  
 orthodontic correction, growth (cephalometric tracings) during, 91f
- Class II molar occlusion, 202
- Class II problems, growth, impact after, 581f
- Class II treatment, functional appliances for, 431–432
- Class III buccal segment, 201
- Class III camouflage, 551–552, 551f–554f
- Class III correction, 528–555  
 facilitate, 442f  
 retention after, 583
- Class III elastics  
 to skeletal anchors, 451–452  
 upper molars and, 564f
- Class III functional appliance, working bite for, 450
- Class III growth modification, 440–452
- Class III malocclusion, 528  
 Chinese, migration of, 123  
 correction of, 569  
 orthodontic treatment for, 666f–667f  
 genetic component of, 30  
 production of, 10
- Class III problems, treatment of, with maxillary deficiency, 447f
- Class III traction, 449f
- Classical conditioning, 47–48  
 impact of, 47  
 operant conditioning, contrast, 49f  
 perspective of, 48–49
- Classical genetics (Mendelian genetics), development of, 134
- Classification  
 scheme, focus, 196  
 view of, 194f
- Clear aligner  
 in complex cases, 638, 639f–643f  
 developments in, 601  
 sequence of, 611
- Clear aligner therapy, 315–319, 518–521  
 applicability, 318b  
 current considerations in, 317–319, 320f–321f  
 development of, 315–316  
 Invisalign production process in, 316–317  
 clinician's role in ClinCheck, 316–317  
 preparation of, 316, 317f–319f
- Clear polymer archwires, 343–344
- Clear retainers (vacuum-formed retainers), 585
- Cleft lip, 241–245  
 orthognathic surgery for, 243–245
- Cleft palate, 241–245  
 orthognathic surgery for, 243–245  
 treatment sequence for, 241t
- Cleft site, alveolar segments at, displacement of, 242f–243f
- Cleidocranial dysplasia, panoramic radiograph of, 70f
- Clenching, occlusion (imperfections), 10
- Clinical effectiveness, evidence of, 11f
- Clinical evaluation, 146–166  
 micro-esthetic considerations on, 572  
 oral health, 146–147
- Clinical examination  
 Angle classification on, 195f  
 data, example of, 204b  
 facial dimensions, evaluation checklist during, 155t  
 focus, increase on, 4
- Clinical orthodontics, nickel-titanium wires in, 279–281
- Clinical procedures, evaluation (gold standard), 12
- Clip retainers (removable wraparound retainers), 584, 586f
- Close-up smile, 574f–575f
- Closing loop archwire, use of, 413f
- Closing loops, 530–532  
 additional design principles of, 531–532  
 loop, location of, 531  
 Opus closing loop, 531–532, 533f  
 performance of, 530  
 preformed closing loops, 531f  
 root-parallelizing moments of, 530–531  
 16 x 22 wire, 533f  
 spring properties of, 530  
 usage of, 296f  
 vertical legs, three-prong pliers, 532f
- Coated archwires, 344–345
- Cobalt-chromium alloys, 278
- Cognitive development, 55–59  
 periods, division of, 55f  
 stages of, 52–59
- Cognitive structures, 55
- Coil spring, usage, 434f
- Cold-cure acrylic, use of, 433f
- Collagen  
 force to, application of, 249f  
 maturation of, 71  
 cross-linking of, 71
- Collagenous matrix materials, production of, 248
- Complete appliance, partial appliance and, biomechanical difference between, 353, 353f

- Complex orthognathic surgery, 188
- Composite buildups, solution for, 612f
- Composite photographs, usage of, 152f
- Composite plastic brackets, 334  
usage of, 293
- Composite plastics, 281
- Composite retraction spring, 534f
- Comprehensive orthodontic treatment, 580, 614–654, 616f  
adjunctive *versus*, 599–600  
goals of, 600  
psychologic considerations for, 614–616
- Comprehensive orthodontics, in implants, 630–631, 633f–635f
- Comprehensive treatment, in adolescents, 501–527  
alignment in, 501–512
- Compressed coil spring, 607f
- Compressed periodontal ligament (PDL), histologic specimen of, 255f
- Computed axial tomography (CAT), 24
- Computed tomography (CT) scans  
superimposition of, 26f  
usage, 25f
- Computer analysis, usage of, 185
- Computer image predictions, 214  
value of, 664
- Concrete operations, period of, 57
- Conditioned behavior, extinction of, 48
- Conditioned stimulus  
generalization, opposite of, 48  
unconditioned stimulus, association of, 48  
strengthening, 48f
- Condylar cartilage, development, 31  
condensation area, 33f
- Condylar fracture  
condyle, regeneration of, 43f  
diagnosis of, 492–496  
growth reduction, 42
- Condylar hyperplasia, 116
- Condylar process  
destruction, panoramic radiograph of, 238f  
fracture of, 42f  
loss, rheumatoid arthritis and, 238f  
regeneration of, 43f
- Condyle, resorption/regeneration of, 43f
- Condylectomy, usage of, 238–239
- Cone beam computed tomography (CBCT), 24, 140  
advent of, 186–187  
availability of, 188  
basic concepts of, 187–188  
images  
in cleft lip and palate, 192f  
diagnostic scope of, 191–193  
in ectopic, impacted, or supernumerary teeth, 190f  
in migrating and erupting impacted tooth, 191f  
in unerupted teeth, 190f  
indication for, 512  
large-field, 191f  
orthodontic applications of, 188–191  
radiation dose, reduction of, 186–187  
three-dimensional images, analysis, 186–191  
usage of, 167  
increases, 193
- Congenital deformities, 188–191
- Congenitally missing mandibular right lateral incisor, 615f
- Congenitally missing teeth, 116–118
- Connector length, successfully attained, 575f
- Connectors, 165
- Contact placement, 575f
- Contact points, stripping, 612–614
- Contemporary edgewise appliance, 323–325  
automatic rotational control, 324, 324f
- Contemporary edgewise appliance (*Continued*)  
bracket slot dimensions, alteration in, 324  
straight-wire bracket prescriptions, 324
- Contemporary fixed appliances  
angle's progression, to edgewise appliance, 321–322, 322f–323f  
Begg appliance, 322–323, 323f–324f  
characteristics of, 330–345  
appliance choices, 341–342  
appliance materials, 330–334  
arch form and archwire fabrication, 342–345  
contemporary straight-wire brackets and tubes, 336–338  
lingual appliances, 340–341, 340f–341f  
straight-wire concepts in bracket and tube design, 334–336, 334f  
contemporary edgewise, 323–325, 324f  
development of, 321–325  
labiolingual, 322  
twin wire, 322
- Contemporary orthodontic appliances, 310–351  
fixed appliances, 321–349  
bands for attachments, 325–327, 326f–327f  
bonded attachments, 327–330, 328f–331f  
contemporary, 321–325, 322f–324f  
temporary anchorage devices, 345–349  
removable appliances, 310–319  
active aligners, development of, 310–312, 311f  
clear aligner therapy, 315–319, 317f–321f, 318b  
functional appliances, for growth modification, 312–315, 312f–315f, 316f
- Continuous arch  
advantages and disadvantages of, 308  
edgewise technique, 558b  
mechanics, 308
- Continuous archwire, placement of, 522f
- Continuous forces  
avoidance of, 257–258  
production of, 257
- Continuous orthodontic wire, activation of, 610f
- Cortical anchorage, 267
- Cortical bone, area of, creation of, 267f
- Corticosteroids, interference, 258
- Corticotomy  
complications of, 262f  
impact of, 260  
modified, 260–261
- Corticotomy-assisted orthodontics, outcomes of, 260
- Counterpart analysis, 183–184
- Couple  
creation, interbracket bend and, 301–303  
definition of, 288  
forces, equivalence of, 288f  
usage of, 289–291
- Cranial base, 33–34  
growth of, 45–46  
mandible, growth of, 36f  
registration of, 184  
sutures, premature fusion, 44f  
synchondroses  
diagrammatic representation of, 34f  
growth center action, 42
- Cranial base superimpositions, 184  
of Bolton template, 185f  
color map, 448f  
illustration of, 95f  
in long-face pattern, 95f  
three-dimensional, 94f, 451f
- Cranial (horizontal) reference line, choice of, 178–179
- Cranial sutures, 33
- Cranial vault, 33  
flat bones, 33
- Craniofacial complex  
sites and types of growth in, 32–37  
tissues, interaction within, 30
- Craniofacial growth  
determinants  
cartilage, usage, 38–42  
theories in, 37  
periosteal tissues, determinants, 37–38  
sutures, determinant, 37–38  
understanding of, 18
- Craniofacial microsomia, 108
- Craniofacial skeleton, growth determinant, 42
- Craniofacial units, growth of, 45t
- Cranimetry, 23
- Cranium  
growth of, 42  
hydrocephaly, impact, 42  
3-D reconstruction of, 24  
width, narrowness, 44f
- Crestal bone height, loss of, excess, 272–273
- Crossbite  
anterior, 5f  
buccal (X-occlusion), 7  
correction of, 509–512, 569, 607–608, 608f  
posterior crossbite, existence, 5f
- Cross-elastics  
for posterior crossbite, 511f  
use of, 511
- Crouzon's syndrome  
facial appearance in, 114f  
occurrence of, 113–114
- Crowded incisors, 612–614, 613f
- Crowding  
alignment, space analysis, 172  
dental  
esthetic considerations for, 210  
expansion and extraction in, 209–214  
extraction guidelines in, 213  
orthodontic treatment for, 119f  
stability considerations for, 210  
minimum, 8f  
moderate and severe, 419–422  
symmetric, alignment, 502
- Crown  
application of, simultaneity of, 255  
corners of, rounding of, 220f  
force to, application of, 255f  
formation of, 67  
height, increase, 105f  
tipped molar, uprighting, 604f  
in method of attachment, 512
- Crown-forward, torque forces in, 530f
- Crown-to-root ratios, establishment of, 600
- Crozat appliance, 310, 311f, 614
- Crystal lattice, electrons within, migration of, 251
- Crystalline structure  
distortion of, 251  
force to, application of, 249f
- Cultural conditions, need/demand (perception), 15
- Curve of Spee, 692–693  
excessive, 227f  
lower arch with, 521f
- Customized brackets, 337–338, 339f
- Cyclic adenosine monophosphate (cAMP), increase in, 251
- Cyclic nucleotide levels, increase in, 256
- Cystic fibrosis, 237
- D**
- Dachshund, achondroplasia and, 122
- Debonding, bond failure in, 567f
- Debonding ceramic brackets, 334
- Deep bite, 375, 455–499, 563  
correction, retention after, 582–583  
severe, 6–7  
short face and, 484–487



- Deep overbite, 608
- Deflection
  - bending moment *versus*, 279f
  - measurement of, 277f
- Deformity, definition of, 107
- Degenerative joint disease, symptoms of, 616
- Delaire-type facemask, stability, 442f
- Delayed incisor eruption, 383, 384f
- Demineralized freeze-dried bone, 260
- Dental age
  - characterization of, 75
  - eruptions of, 78
  - eruption, sequence/timing of, 74–78, 78f
  - indicator of, 76
- Dental appearance, 149–166
  - micro-esthetics, 161–166
  - pretreatment, 645f–646f
  - systematic examination of, 150–166
- Dental arches
  - alignment/symmetry, evaluation of, 200
  - distal movement of, 646–647
  - expansion of, 210f
  - pressure, third molar (impact), 102f
  - size, function and, 126
  - width, increase, 79–80
- Dental casts
  - analysis, 172–174
    - symmetry/space/tooth size, 172–174
  - for orthodontic purposes, 168
- Dental components, facial components (relationship), 175f
- Dental conditions, disfiguring (psychic distress), 15
- Dental crowding
  - esthetic considerations for, 210
  - expansion and extraction in, 209–214
  - extraction guidelines in, 213
  - orthodontic treatment for, 119f
  - stability considerations for, 210
- Dental decay, malocclusion (impact), 11
- Dental development, disturbances of, 116–120
- Dental disease
  - malocclusion, relationship of, 10–11
  - problems, 236–237
  - relationship to, 10–11
- Dental esthetics, 149–150
- Dental expansion, 218
  - cross-elastics in, 511
- Dental history, 142
  - obtaining, 142f–144f
- Dental midline deviations, 196
- Dental occlusion
  - emphasis, 3–4
  - example of, 236f
- Dental protrusion, excessive, in preadolescent children, 358, 359f
- Dental records, 168
- Dental retrusion, excessive, in preadolescent children, 358, 359f
- Dental treatment, anxiety (example), 53f
- Dentist office, behavior management of, 48
- Dentition
  - downward roll of, 199f
  - esthetic line of, 196
    - pitch/roll/yaw in, 196
  - rotation of, 196
  - supporting structure, consideration of, 124–125
  - up-down transverse rotation of, 159
- Dentoalveolar segments (repositioning), surgery, 673f
- Dentoalveolar surgery, 672
- Dentofacial complex
  - changes of, 88–90
  - growth patterns in, 88–96
- Dentofacial conditions, orthodontic treatment, 16
- Dentofacial deformity, 616f
  - etiologic processes of, 37
- Dentofacial development, teratogens affecting, 108t
- Dentofacial proportions, records for, 170–171
- Dentofacial relationships, cephalometric analysis of, 172
- Dentofacial traits, characteristics (classification), 200b
- Desired movement, subdivision of, 296
- Determinate force system, 299
  - indeterminate force system *versus*, 298–308
- Development
  - early stages of, 60–83
  - growth and, concepts of, 18–59
  - later stages of, 84–106
  - studies of, 18
  - term, usage of, 18
  - timing, variability of, 18–23
  - variability of, 18–23
- Developmental ages
  - assessment of, 66–67, 150
  - correlation between, 67
- Developmental problems, pathologic problems *versus*, 223–224
- Developmental stages, chronologic ages (association), 52
- Dewey, Martin, 194
- Diagnosis
  - problem-oriented approach, 140–207
  - problem-oriented method, 229
- Diagnostic database
  - being assembled, 158f
  - development of, 137
- Diagnostic records, 166–193
  - analysis of, 172–193
    - example of, 205b
  - summary, 172
- Diagnostic set-up, 611
- Diagnostic workup, 231f
- Diaphysis, 31
- Diastema (teeth spacing), 5f, 80
  - childhood diastema, spontaneous correction, 5f
  - midline diastema, presence in, 5–6
- Diastema closure, 517–518, 520f
  - in anterior teeth, alignment of, 611
  - maintenance of, 588–589, 589f
    - fixed retainer, 413f
  - requirement, 412f
- Diet, attrition (absence), 101
- Differential anteroposterior tooth movement, using extraction spaces, 547–551
- Digital casts
  - accurate measurements from, 173f
  - generation of, 168
- Digital records, advent of, 171
- Digitized dental casts, 502f
- Dilaceration, 67–69, 120
- Direct bonding, 327–328, 329f–330f
- Discrepancy outlines, 661
- Discrimination, 48
- Displaced incisors, 612–614, 613f
- Displacement, of teeth, 406–409
- Dissected skull, examination of, 78
  - example of, 79f
- Distal crown
  - movement, 603f
  - tipping, 603–604, 605f–606f
- Distal shoe space maintainers, 390, 390f
- Distal step, 80–81
- Distraction osteogenesis, 44–45, 672–675, 674f
  - in ankylosed teeth, movement of, 259f
  - diagrammatic representation of, 46f
- Dogs, breeding experiments/malocclusions with, 123f
- Dolphin Imaging, 178f
- Double chin, correction of, 680
- Drag loop, 506f
- Duchenne smile, 159
- E**
  - E-arch appliance, 322, 322f
  - Early adult life, disturbances arising in, 116
  - Early childhood, primary dentition years, 60–66
  - Early embryos, weight increase (data), 27f
  - Early (serial) extraction, 422–426
  - Early mandibular advancement, 690–691
  - Early maxillary advancement, 691
  - Early mixed dentition
    - crowding in, expansion for, 420
    - palatal expansion in, 430–431
    - treatment, 241–243
  - Early permanent dentition
    - treatment, 243
    - years (adolescence), 84–87
  - Early-maturing girls, growth velocity for, 23f
  - Ectodermal dysplasia, 118
    - appearance of, 120f
  - Ectopic eruption, in preadolescent children, 377–385
    - ankylosed primary teeth, 383–385, 384f–385f
    - delayed incisor eruption, 383, 384f
    - lateral incisors, 377–378, 377f–378f
    - maxillary canines, 379–381, 382f–383f
    - maxillary first molars, 378–379, 378f–381f
    - supernumerary teeth, 381–383
  - Ectopically erupting teeth, 188
    - requiring surgical exposure, 188
  - Edgewise appliance, 322, 323f, 549–550, 568
  - Edgewise brackets, of straight-wire type, 601
  - Edgewise techniques, 556
  - Effective torque, 562t
  - Egocentrism, 56
  - 18-slot appliance, 518
    - finishing archwire and, 560
  - 18-slot bracket, effective torque, 562t
  - 18-slot edgewise, space closure with, 533–534
  - Elastic binding, impact of, 293–295
  - Elastic force, sources of, 287–288
  - Elastic gingival fibers, sectioning, 569–570
  - Elastic materials
    - asperities, 292
    - force-deflection curve for, 277f
    - geometry of
      - length and attachment, 282–285
      - size and shape, 282
    - properties of, 276–278
    - shape memory of, 278
    - stiffness and strength, combination of, 286
    - stiffness of, 277f
    - surfaces of, contact with, 292f
    - usage of, 276–288
    - variation of, 285–287
    - wire size of, 285t
  - Elastic properties, of beams, effects on, 282–287
  - Elastics, downward and forward, 442f
  - Elastomeric plastics, for orthodontic purposes, 287–288
  - Elastomeric separators, 325, 326f
  - Electromagnetic fields, impact of, 251
  - Electron micrographs, in human embryonic development, 109f
  - Electrons, migration of, 251
  - Elgiloy, advantage of, 278
  - Embrasures, 165
    - black triangles, 165
    - successfully attained, 575f
  - Embryologic development, disturbances in, 107–114
  - Embryos
    - diagrammatic lateral section, 110f
    - human, palate closure, stages of, 113f
  - Emotional development, 52–55
    - stages, sequence, 52f
  - Enamel
    - after deproteinization of, 330f

- Enamel (*Continued*)  
 in bonding, 327, 328f  
 demineralization of, 273–274  
 Enamel damage, 566  
 Endochondral ossification, 31  
 occurrence, 31  
 Endocrine signals, diagrammatic representation of, 85f  
 Endodontic treatment, 407–408  
 Enhanced esthetics, reshaping the teeth for, 570–574  
 Enhancements, 16  
 technology, orthodontics, 16  
 Enlow's counterpart analysis, emphasis of, 184f  
 Enucleation, 425  
 Environmental influences, 124–134  
 Epiphyseal cartilage, growth center action, 42  
 Epiphyseal plate, 31  
 cartilage cells, active division, 31  
 endochondral ossification, 32f  
 Epiphysis, 31  
 removal of, 41f  
 Equilibration, in posterior bite, 364–365, 365f  
 Equilibrium considerations, 124–125  
 Equilibrium influences, 126t  
 Erikson, Erik, 52  
 autonomy, development of, 52–53  
 basic trust, development of, 52  
 emotional development stages of, 52–55, 52f  
 initiative, development of, 53–54  
 intimacy, development of, 55  
 personal identity, development of, 54–55  
 skills, mastery of, 54  
 Eruption  
 amount, requirement of, 75  
 delayed incisor, 402, 403f  
 ectopic, of mandibular lateral incisor, 403f  
 panoramic radiograph of, 69f  
 path, cleared, 405f  
 primary failure of, 69–71, 403–404, 405f, 406t  
 characterization, 405f  
 rate, jaw growth rate (parallelism), 72  
 sequence, 74–78, 78f  
 change in, 78  
 variations in, 78  
 of teeth  
 alveolar bone and, relationship of, 272–273  
 amount of, 73f  
 jaw rotation, interaction between, 95–96  
 periodontal ligament in, role of, 250  
 removal of, obstacles to, 512  
 timing, 74–78, 78f  
 Eruption problems, 402–406  
 in preadolescent children, 361–362  
 management of, 375–385  
 overretained primary teeth, 375–377, 377f  
 Esthetics  
 acceptability, maximum/minimum for, 163t  
 biomechanical limitations of, 601  
 considerations, 210  
 enhanced, reshaping the teeth for, 570–574  
 evaluation of, 198–200  
 pitch/roll/yaw in, 196  
 variables, 163t  
 Estrogen production, by Leydig cells, 86  
 Ethmoid bones, location of, 33  
 European removable appliance orthodontics, 311  
 Expander, coil spring in, 434f  
 Expansion  
 versus extraction, 419–420  
 flexible transpalatal arch for, 510f  
 parasagittal osteotomies with, 668–670  
 rapid, 432–433, 433f  
 in children, 432f  
 slow, 431–433  
 transpalatal lingual arch for, 510  
 External ear, deficiency/absence of, 111f  
 External motivation, treatment as, 145  
 External rotation, 90  
 occurrence of, 94  
 Extinction of conditioned behavior, 48  
 Extracellular material, secretion of, 30  
 Extracellular matrix, secretion of, 31  
 Extraction  
 versus expansion, 419–420  
 guidelines, 213  
 pattern for, 664  
 site, closure of, 291  
 space from, 213t  
 of teeth, 664  
 Extraoral appliance, 422f  
 usage of, 296  
 Extraoral force, to the maxilla, 455, 456f  
 effect of, 477, 478f–481f  
 Extreme tipping, 270f  
 Extremities, long bones (ossification), 31  
 Extrusion, 255–256, 608–611  
 arches, 299–300  
 leveling by, 518–521, 522f  
 methods for, 610  
 orthodontic technique for, 610–611, 610f–611f  
 treatment planning for, 608–610, 609f  
**F**  
 Face  
 cephalocaudal growth gradient, impact of, 19  
 dentition, relationship of, 150  
 frontal view, examination of, 153  
 growth, pattern of, 34  
 proportions, changes of, 19f–20f  
 structural components, anatomic drawing (superimposition), 174f  
 3-D reconstruction of, 24  
 views, CBCT (usage), 186–187  
 Face height  
 anterior, increase in, 691  
 decrease in, 691  
 Facebows, 476–477  
 fitting of, for a headgear, 482f–483f  
 inner bow of, 510  
 neckstrap for, 481  
 Facemask (reverse headgear), 442–444, 442f  
 cephalometric superimpositions, 441f  
 Facemask traction, to skeletal anchorage, 444  
 Facial anthropometric measurements, 151t  
 Facial appearance, 149–166  
 bimaxillary dentoalveolar protrusion in, 156f  
 discrimination of, 9–10  
 posttreatment facial appearance, 234f–235f  
 systematic examination of, 150–166  
 Facial asymmetry, 188  
 cause of, 238  
 in children, 492–497  
 chin deviation, 493f–495f  
 composite photographs, usage of, 152f  
 dental crowding, orthodontic treatment for, 119f  
 masseter muscle, absence (impact), 117f  
 resolution of, 496f–497f  
 rheumatoid arthritis, impact of, 117f  
 severity of, 188  
 in torticollis, 118f  
 Facial attractiveness, 159  
 esthetic acceptability, maximum/minimum for, 163t  
 Facial background, 149–150  
 Facial changes, functional appliance treatment and, 486f–487f  
 Facial components, dental components (relationship), 175f  
 Facial conditions, disfiguring (psychic distress), 10  
 Facial considerations, 13  
 Facial convexity, increased, 202  
 Facial deformity, long-face pattern of, 124  
 Facial dimensions, evaluation checklist of, 155t  
 Facial disproportions, correction for, 214  
 Facial esthetics  
 facial proportions *versus*, 150–158  
 improvement in, incisor retraction in, 211f  
 Facial examples, 236f  
 Facial form analysis, 157  
 Facial growth  
 adults in, 96–98  
 anteroposterior facial growth, 429  
 continuation of, 97  
 determination, serial cephalometric radiographs (usage), 145  
 vertical facial growth, 429  
 Facial height/width, proportional relationship (facial index), 151  
 Facial index (indices), 151  
 list of, 151t  
 Facial measurements, for anthropometric analysis, 152f  
 Facial muscles, impact of, 116  
 Facial photographs, 171, 171f  
 Facial processes, fusion (schematic representations), 112f  
 Facial profile, goals of, 153  
 Facial proportions, 150  
 evaluation of, 198–200  
 facial esthetics *versus*, 150–158  
 in frontal plane, 151f  
 macro-esthetics, 150–158  
 occlusion, impact, 3–4  
 Facial scans, axial CT (application), 24  
 Facial skeleton, anatomic studies of, 35  
 Facial soft tissues, 36–37  
 changes in, 37  
 adolescence, 97  
 contouring of, with implants, 679  
 downward movement of, 101f  
 growth of lips, 36–37  
 Facial surfaces, flattening of, 220f  
 Facial symmetry, improvement in, 493f–495f  
 Facial syndromes, 673–675  
 Facial tipping, control in, 300–301  
 Facial tissue, micro-incisions through, usage of, 262f  
 Facial trauma, 188–191  
 syndromes/sequelae of, 188  
 Faciolingual bends, 324  
 Fat spurt, 86  
 Fetal alcohol syndrome (FAS)  
 facial appearance of, 109f  
 facies, characteristic of, 108  
 Fetal molding, 114–115  
 Fetal period, growth disturbances in, 114–115  
 Fetal rat bones, autoradiograph of, 29f  
 Fibroblasts, osteoblasts and, comparison of, 248  
 Field of view (FOV)  
 CBCT scan in, 189f  
 different, 188f  
 size, decrease in, 187–188  
 Final treatment plan, example of, 230b  
 Finishing  
 micro-esthetic procedures in, 570–574  
 positioners for, 567–568, 568f  
 procedures, relapse (avoidance), 569–570  
 Finishing stage, of treatment, for midline discrepancies, 558–559  
 First molars, bilateral toe-in bends at, 306f  
 First permanent molars, transverse movement of, production of, 305f  
 First premolars  
 eruption of, transposition of, 244f–245f  
 extraction, site, spring, placement of, 265  
 lateral incisor position in, 244f–245f  
 First-order bends, compensations for, 334, 335f

- Five-characteristics classification system  
 additions to, 196–198  
 systematic description, pitch/roll/yaw in, 196
- Fixed appliance treatment, 232*f*  
 friction in, 292–293
- Fixed appliances, 321–349  
 bands for attachments, 325–327, 326*f*–327*f*  
 bonded attachments, 327–330, 328*f*–331*f*  
 contemporary, 321–325, 322*f*–324*f*  
 sequence of alignment with, 505*f*  
 systems, brackets in, 291  
 technique, 605*f*  
 temporary anchorage devices, 345–349
- Fixed canine-to-canine retainers, 587
- Fixed Class II correctors, 462
- Fixed functional appliances  
 for adolescent growth modification, 541  
 as not good choices for short-face problems, 487
- Fixed jackscrew appliances, attached, 431
- Fixed prosthodontics, abutments for, 243
- Fixed retainers, 586–591  
 objection to, 591  
 space maintenance in, 591
- Flanges, 465–466
- Flap (reflection), modified corticotomy and, 262*f*
- Flared maxillary incisors, space analysis in, 397–399
- Flat bones, separation of, 33
- Flattened (nonconsonant) smile arc, 160
- Flexible transpalatal arch, for expansion, 510*f*
- Floating point norms, usage of, 184
- Flush terminal plane, 80–81  
 moral relationship, 82  
 end-to-end relationship, 82
- Focal adhesion kinase (FAK), mechanoreceptor, 251–254
- Fontanelles, 34*f*
- Foramen magnum, anterior margin of, 177*f*
- Force  
 bends, step bends and V-bends and, 304*t*  
 continuous forces, production of, 257  
 control of, 285–287  
 creation, interbracket bend and, 301–303  
 decay  
 diagrammatic representation of, 257*f*  
 effects of, 256–258  
 definition of, 288  
 distribution, effects of, 254–256  
 efficiency and duration of, contrast in, theoretical plot of, 256*f*  
 intermittent forces, production of, 257  
 interrupted forces, production of, 257  
 magnitude  
 effects of, 256–257  
 interaction between, 257  
 measurement of, 277*f*  
 reduction in, 302  
 systems, defining, 298–308  
 tangential force, application of, 292  
 tooth movement and, relationship of, 265  
 usage of, 289–291
- Force duration  
 classification of, 256–257  
 effects of, 256–258  
 threshold, clinical experience in, 256
- Forced eruption, 608, 609*f*
- Force-deflection curves, 277*f*  
 for 16-mil austenitic nickel-titanium (A-NiTi) wires, 502*f*
- Formability, defining, 277*f*
- Formal operations, period of, 57–59
- Form-function relationships, 124
- Forsus appliance, 464*f*; 470, 472  
 deactivation of, 476  
 results of, 472–476
- Forward traction, 445*f*  
 applied, 445*f*
- Fox plane demonstration, 199*f*
- Frankel appliance, 457, 459*f*; 465–466, 465*f*  
 buccal shields and lip pads in, 467, 468*f*
- Frankfort plane, 178  
 difficulties of, 178–179  
 for dried skull orientation, 178*f*  
 usage of, 182–183
- Freud, Sigmund, 52
- Friction  
 binding *versus*, 292–295  
 factors affecting, 292
- Frictional resistance, absence of, 293*f*
- FR-III functional appliance, 440–442  
 response to, 441*f*  
 upper lip, 440*f*
- Frontal examination, 150–153
- Frontal plane, facial proportions in, 151*f*
- Frontal resorption, undermining resorption *versus*, 255*f*
- Frontal smiles, 658*f*–660*f*
- Frontal view, vertical facial proportion in, 154*f*
- Front-to-back maturation, principle of, 65
- Full-cusp Class II molar relationship, 626*f*–628*f*
- Full-dimension rectangular, replacing, 564–565
- Full-time retention, requirement of, 580
- Functional appliances  
 active tooth-borne, 313  
 for Class II growth modification, 457–459, 457*f*–458*f*  
 poor response to, 461*f*  
 clinical management of, 470–481  
 components, 314–315, 316*t*  
 design of, 490*f*  
 growth acceleration in response to, 456*f*  
 for growth modification, 312–315, 312*f*  
*versus* headgear, 459–462  
 hybrid, 314, 315*f*  
 passive tooth-borne, 313, 313*f*–314*f*  
 removable and fixed, components of, 465–470  
 active expansion and alignment, 467–468, 469*f*  
 to advance the mandible, 465–466  
 passive, 467  
 stabilizing, 467  
 for vertical control, 466–468, 466*f*–467*f*  
 tissue-borne, 313–314, 315*f*  
 treatment procedures with, 468–470  
 impressions and working bite in, 470, 471*f*  
 pretreatment alignment in, 468–470, 469*f*  
 usage of  
 facial changes produced by, 486*f*–487*f*  
 for short face/deep bite, 485–486  
 “Functional jaw orthopedics” method, 4
- Functional mandibular movements, occlusal interferences with, 149
- Functional matrix growth theory, 42–46
- Functional occlusal plane, drawing of, 182
- Functional occlusion, 4
- G**
- Gable bends, 532*f*
- Gamma-emitting isotope technetium 99m (<sup>99m</sup>Tc), usage of, 28–29
- Generalized moderate crowding, 397, 397*f*; 419–422
- Genetic control, expression of, 37
- Genetic influences, 121–124
- Geometry  
 length and attachment, 282–285  
 size and shape, 282
- Gingiva  
 display, amount of, 159  
 height/contour of, 165  
 improvement, with positioner wear, 569*f*  
 recession, 212*f*
- Gingiva (*Continued*)  
 recontouring, 570  
 shape of, 165  
 curvature, 165
- Gingival attachment, 624*f*  
 compromising, 574*f*
- Gingival contours, 233*f*–234*f*  
 appearance of, 166*f*  
 reshaping, soft tissue laser and, 223
- Gingival embrasure, excessive, 572
- Gingival esthetic problems, 630
- Gingival fibers, response, slowness, 580
- Gingival grafting, 624*f*
- Gingival margin, 630
- Gingival surgery, results after, 232*f*
- Gingival tissues, reorganization of, 579–580
- Girls (females)  
 adolescence, division of, 86  
 arches, space of, 80*f*  
 first molar, eruption (cessation), 74*f*  
 medical problem, growth chart of, 21*f*–22*f*  
 secondary sexual characteristics, attainment of, 150  
 velocity curves for, 23*f*
- Gjessing retraction spring, 537*f*
- Gold, replacement, steel archwires and, 291
- Golden proportion, 163–164
- Grid, mathematical transformation (D’Arcy Thompson), 27*f*
- Grinding, occlusion (imperfections), 10
- Growth  
 centers, sites (contrast), 37–38  
 computer predictions of, inaccuracy of, 226*f*  
 deficiency of, 690–691  
 development and, concepts of, 18–59  
 diagrammatic representation of, 34*f*  
 effects, timing variation (impact), 20  
 evaluation of, 193  
 excess, 686–690  
 functional matrix theory of, 42–46  
 genetic influences on, 29–30  
 height/weight plotting of, 23*f*  
 hormone deficiency, 63*f*  
 late, maintenance of lower incisor position during, 587–588, 587*f*  
 in length and weight graphs, 62*f*  
 “normal variability” of, 20  
 occlusal changes related to, 580–584  
 occurrence, 32*f*  
 pattern of, 18–23  
 predictability, 19–20  
 problem, 63*f*  
 Scammon’s curves of, 19*f*  
 secular change in, 62–64  
 studies of, 18  
 temporary cessation of, 61  
 term, usage of, 18  
 timing of, 18–23  
 variability of, 18–23  
 velocity  
 curves for, 23*f*  
 data, plotting of, 27*f*
- Growth control  
 level of, 37–38  
 theories of, 37–46
- Growth modification, 216–217, 268  
 approach to, 491*f*–492*f*  
 Class II, 455–481  
 fixed Class II correctors for, 462  
 functional appliances for, 457–459, 457*f*–461*f*  
 headgear for, 459, 462*f*–463*f*  
 treatment strategies for, evolution of, 455  
 perspectives on, 455–457, 456*f*
- Growth-related relapse, cephalometric superimposition, 582*f*
- Gummy smile, 234*f*–235*f*, 630



- H**
- Haas-type RPE device, usage, 436
- Hand, radiograph (usage), 66f
- “Handicapping malocclusion,” concept of, 10
- Hapsburg jaw, 121
- mandibular prognathism in, 122f
- Harvold analysis, 181–182
- measurements, usage of, 182f
- Wits analysis, contrast to, 182
- Harvold standard values (millimeters), 182t
- Hawley retainers, 584
- clasp locations for, 584
- example of, 585f
- Head**
- cephalocaudal growth gradient, impact of, 19
- distortion of, 61f
- positioning device, usage (cephalometric radiograph), 24f
- posture, change in, 132f
- proportions, changes of, 19f–20f
- stereolithographic model of, 192f
- views, CBCT (usage), 186–187
- Headgear**
- for adolescent growth modification, 541, 542f–543f
- for Class II growth modification, 459, 462f–463f
- clinical management of, 481
- components of, 476–477, 477f
- for distal movement, 543
- effect, functional appliances and, 457, 457f
- facebow fitting, 482f–483f
- functional appliances *versus*, 459–462
- instructions, example of, 57f
- reinforcement with, 535
- selection of, 477–479
- treatment procedures with, 476–481
- tubes, heavy labial archwire in, 510f
- Health literacy, importance of, 229**
- Height-width relationships, 164–165**
- Hemifacial microsomia, 108, 674f**
- CT scans and, 25f
- external ear/mandibular ramus, deficiency/absence of, 111f
- Hemimandibular hyperplasia, 686f–690f**
- Hemimandibular hypertrophy, 116, 238–239, 497, 498f**
- Herbst appliance, 313, 314f, 462, 464f, 472**
- results of, for Class II growth modifications, 472, 472f–475f
- Heredity, influence (estimation), 124**
- Higher animals, mandible (development), 31**
- High-pull headgear, 422f**
- continuation of, 232f
- demonstration of, 422f
- to maxillary first molars, 488
- to maxillary splint, 488
- response to, 489f
- Hispanic population, alignment, 6–7**
- Holdaway ratio, 179–180**
- “Hollywood smile”, 79f
- Horizontal forces, “through the bite” or cross-elastics, 608f**
- Horizontal planes, inspection of, 181f**
- Horizontal (cranial) reference line, choice of, 178–179**
- Hormone, replacement of, 61**
- Human growth hormone (HGH), administration of, 63f**
- Human racial groups, differences of, 126**
- Hunter, John, 28
- Hybrid functional appliances, 314, 315f**
- treatment with, 493f–495f
- usage of, 238
- Hydrocephaly, 42**
- Hyperplasia, 30**
- Hypertrophy, 30**
- Hypodontia, 116–118**
- I**
- Identity, establishment of, 54**
- “Imaginary audience,” reaction of, 57
- Impacted canine, 237f**
- on medium-field-of-view CBCT image, 191f
- modern correction of, 514f
- Impacted lower second molars, 514–517, 517f–519f**
- Impacted mandibular second molars**
- radiographic view of, 517f
- surgical uprighting of, 519f
- Impacted maxillary canine, in panoramic radiograph, 169f**
- Impacted teeth, 188**
- alignment of, 512–517
- requiring surgical exposure, 188
- Implants**
- comprehensive orthodontics in, 630–631, 633f–635f
- radiography, 29
- space, maintenance of, 591
- superimposition on, 93f–94f
- Impressions, for functional appliances, 470, 471f**
- In vivo submental-vertex CBCT view, 197f**
- Incisor display**
- at age function, 99f
- amount of, 159
- increase in, 217f
- minimize, 629f
- Incisor irregularity**
- expression of, 5f
- U.S. children, 5
- Incisor retraction, 210**
- cephalometric superimposition in, 620f–623f
- maximum, 535–537
- minimum, 537–538, 538f–540f
- ratio, 297f
- Incisors**
- alignment, auxiliary superelastic wire for, 505f
- crowded, 612–614, 613f
- developmental spaces of, 66
- displaced, 612–614, 613f
- eruption of
- continuation, average velocity of, 95f
- preventing, 521f
- exposure, on orthodontic treatment completion, 100f
- flare, forward direction of, 156f
- inclination (change), two-couple archwires to, 303–304
- interferences, 149f
- intrusion, 2 x 4 appliance in, 523f
- lingual root torque of, 560–562
- prominence, evaluation of, 155–156
- by profile view, 157
- protrusion of
- excess, 211f
- tipped lingually, 560–561
- replacement of, space relationship in, 78–80
- rotated, 612–614, 613f
- Incognito lingual appliance, 340, 340f–341f**
- Indeterminate force system, 299**
- determinate force system *versus*, 298–308
- Index of Treatment Need (IOTN)**
- development of, 13
- esthetic index, stimulus examples of, 14f
- grades, NHANES III data set, 13
- scores, comparison of, 14
- treatment grades of, 13b
- India ink, perfusion of, 252f**
- Indirect bonding, 328–330, 331f**
- Indirect genetic control (epigenetic control), 37**
- Inelastic binding, impact of, 293–295**
- Infancy**
- length and weight, growth (graphs), 62f
- primary dentition years, 60–66
- Infantile swallow**
- in children, 130
- sequence of, 64
- Infants**
- airway, establishment of, 64
- at-risk groups, growth curves, 63f
- bilateral cleft lip/palate in, 113f, 241f
- lower lip, tongue placement of, 65f
- orthopedics, 241
- presurgical orthopedics, impact of, 241
- respiratory movements in, 64
- segments in, repositioning of, 241
- unilateral cleft lip in, 113f
- Informed consent, obtaining, 229–230**
- Inheritance, tests of, 122**
- Initial crowding, accommodation of, 424f**
- Initiative, development of, 53–54**
- Injury, malocclusion (relationship), 10–11**
- Insignia system, 337, 339f**
- Insult, definition of, 108**
- Integrity, attainment of, 55**
- Intellectual capabilities, development of, 55**
- Intelligence, development of, 55**
- Interarch elastics**
- finishing treatment and, 566
- nonextraction correction with, 551, 551f
- reinforcement with, 535
- Interarch mechanics, 353–354, 354f**
- Interbracket bend, usage of, 301–303**
- Interdental fibrous tissue, removal of, 517**
- Interdigitation, wax bite/polysiloxane record of, 168**
- Intermittent forces, production of, 257**
- Internal motivation, treatment as, 145**
- Internal rotation, 90**
- occurrence of, 94
- Interproximal enamel reduction (IPR), 318, 321f**
- Interproximal enamel removal, impact, 594f**
- Interrupted forces, production of, 257**
- Intersphenoid synchondrosis, 33**
- growth, diagrammatic representation of, 34f
- maxilla development by, 34
- Interstitial growth, 30**
- impossibility of, 32
- Interview, 140–146**
- data, example of, 204b
- questions, 141f
- Interzone, mineralization zone, 46f**
- Intimacy, development of, 55**
- factors affecting, 55
- Intramembranous bone formation, 32**
- Intramembranous ossification, 31**
- Intraoral photographs, purpose of, 167**
- Intrauterine development, 30**
- Intrauterine molding, 114–115**
- Intrusion, 255–256**
- bypass archwires in, 521–523, 523f–524f
- continuous archwire in, 522f
- indicated, 562–563
- leveling by, 521–525
- relative, 518–521, 522f
- segmented archwires for, 523–525, 524f–526f
- of teeth, 647–654
- utility arches for, 300–301
- Intrusion arch**
- action, of factors in, 301f
- creation of, 299f
- utility arch *versus*, 302f
- Intrusive force, step bend and, 304f**
- Invisalign**
- ClinCheck form, 321f
- new features of, 320f

- Invisalign (*Continued*)  
 production process in, 316–317  
 clinician's role in ClinCheck, 316–317  
 preparation of, 316, 317f–319f
- Irregular incisors  
 adequate space in, 394–395, 395f  
 realignment of, 592–594, 595f
- Irregular maxillary incisors, 626f–628f
- Irregularity, mixed dentition treatment of, 423f
- Ischemic areas, development of, 268  
 pain source in, 268
- J**
- Jackscrew appliance, activation, 432f
- Jaw  
 adolescent spurt in growth of, 87f  
 asymmetry, no sign of, 119f  
 childhood fractures, 115–116  
 development, habits (impact), 130  
 discrepancy, increase, 184f  
 disproportion of, 155f  
 external rotation, visualization of, 90–92  
 function of, 147–149  
   changes, determination, 9  
   screening exam for, 149b  
   TMJ function, relationship of, 148  
 injuries, 237–238  
 internal rotation, visualization of, 90–92  
 nasion perpendicular, relationship of, 183  
 positioning precision, possibility of, 45  
 proportionate position, in anteroposterior plane  
   of space, 153–155  
 relationships, 414–415  
 respiration, impact of, 132  
 rotation of, 196  
 size, progressive reduction in, 8–9  
 space (increase), vertical growth (impact), 73f  
 width, growth in, 89
- Jaw growth  
 acceleration in, 87  
 alteration, orthodontic treatment (usage), 4  
 body growth, correlation of, 87  
 rate of, 72–74  
 rotation, 90–96
- Jaw rotation  
 changes, terminology in, 92t  
 implant studies of, 90–95  
 in long-face pattern, 95f  
 tooth eruption, interaction between, 95–96
- J-hook headgear, 548
- Juvenile occlusal equilibrium, 72
- Juvenile rheumatoid arthritis (JRA), impact of, 237
- K**
- Kingsley, Norman, 2
- Kloehn, Silas, 459
- Kloehn-type or cervical headgear appliance, 462f
- Kusy, Robert, 281–282
- L**
- Labial archwire, in headgear tubes, 510f
- Labially directed force, 608f
- Labiolingual appliance, 322
- Labiolingual displacements, 424
- Laced elastics, 565f
- Laced posterior vertical elastics, 564
- Lactating mammals, milk ducts of, 64
- Laminate veneers, appearance of, 221f
- Landmarks, for superimposition (alternative), 193
- Late adult, integrity (attainment), 55
- Late childhood  
 developmental ages, assessment of, 66–67  
 mixed dentition years of, 66–83  
 physical development in, 66  
 skeletal ages, assessment of, 66–67
- Late fetal development, 60
- Late incisors, crowding of, 103
- Late mandibular growth, 101–103
- Late mixed dentition  
 expansion for crowding, 422  
 palatal expansion in, 431–433  
 sutural expansion, 438–440  
 TAD-supported molar distalization, 424f
- Late primary dentition treatment, 241–243
- Late-maturing girls, growth velocity for, 23f
- Lateral cephalometric radiograph, 29f
- Lateral digitization model, usage of, 178f
- Lateral incisors  
 dilaceration of, 121f  
 ectopic eruption of, in preadolescent children,  
   377–378, 377f–378f  
 smallness of, 222f
- Lateral nasal prominence, 110
- Lateral para-midline, location of, 670f
- Lateral pterygoid muscle, impact, 42f
- Lateral view, vertical facial proportion in, 154f
- Latex elastic, for posterior crossbite, 366–368
- Le Fort I downfracture technique, location of the  
 osteotomy cuts for, 661f
- Le Fort I osteotomy, with downfracture of the  
 maxilla, 668
- Learning  
 by association, 47  
 behavior development of, 47–52
- Leeway space, 80
- Left lateral incisor, moved mesially, 539f–540f
- Left mandibular condylar process fracture, impact  
 of, 145f
- Leveling, 518–525, 521f  
 by extrusion, 518–521, 522f  
 by intrusion, 521–525
- Leydig cells, estrogen production by, 86
- Lingual appliances, 340–341, 340f–341f
- Lingual arches  
 activation of, 306  
 space maintainers, 390–392, 391f  
 stabilizing, reinforcement with, 535  
 two-couple systems, 306
- Lingual orthodontics, 634–638, 635f–638f
- Lingual root torque, 560–562
- Lingual shields, 467f
- Lingually bonded brackets and archwires, 635
- Lip pads, 467, 468f
- Lips  
 bilateral cleft, 113f  
 clefting, occurrence of, 112  
 connection of, strain in, 210  
 downward sag, 98  
 fullness, decrease in, 100f  
 growth of, 37, 38f  
 height increases, 101f  
 incompetence, 156  
 posture, evaluation of, 155–156  
 procedures for, 679–680  
 prominence  
   evaluation of, 157f  
   impact of, 157  
 protrusion, evaluation of, 157  
 reduction of, 679–680  
 resting pressures from, 250f  
 teeth, vertical relationship of, 198f  
 thickness, increase, 39f  
 upper lip, backward incline, 211f  
 vertical tooth-lip relationships, 217–218
- Load-deflection curve, ratios in, application of,  
 281–282
- Loading-unloading curves, 287f
- Local injury, effects of, 260–264
- Localized growth problems, diagnosis of, 28–29
- Localized moderate-to-severe crowding, 419
- Logical processes, usage of, 57
- Logical reasoning, capabilities of, 56
- Long-face, 94  
 of biting forces, 126  
 characterization of, 94–95  
 Class II, 691  
 growth-modification approach for, 491f–492f  
 nasal respiration, percentage (comparison), 133f  
 open bite and, 487–492  
 pattern  
   of facial deformity, 124  
   identification of, 126  
   jaw rotation in, 95f
- Longitudinal data, production of, 24
- Long-term relapse, occurrence, 580–581
- Long-term total nasal obstruction, 132
- Loop mechanics, closing, in space closure,  
 530–532  
 additional design principles of, 531–532,  
   532f–533f  
 aspects, changing, 530f  
 loop, location of, 531, 533f  
 root-parallel moments of, 530–531,  
   531f–532f  
 spring properties of, 530, 530f
- Low birth weight (premature birth), 61
- Lower anterior face height, decreased, 485f
- Lower anterior teeth, linguallly tipped, 420f
- Lower arches  
 bonded canine-to-canine retainer in, 587f  
 constraint in, 212f  
 in Crozat appliances, 311f  
 expansion of  
   fixed appliance for, 420f  
   limits of, 210  
 leveling, 521f  
 possibilities of, 227f
- Lower border osteotomy, chin advancement and,  
 675, 676f–678f
- Lower crowding, mixed dentition treatment of,  
 423f
- Lower face  
 height, excess in, 489f  
 lengthening of, 118f
- Lower first molar, fractured, facial surface of, 611f
- Lower incisor crowding, 261f  
 alignment  
   drag loop in, 506f  
   facilitation, interproximal enamel removal,  
     594f  
   gingival recession in, 212f  
   patient concern, 594f
- Lower incisors  
 damaged, 613f  
 lingual tipping, increase of, 103f  
 minimal attached gingiva in, 147f  
 position of, 662f  
   maintenance, 587–588, 587f  
 re-crowding of, 592–593  
 Ricketts analysis, relationship of, 182–183  
 tipping of, 424
- Lower jaw, lack of growth of, 60
- Lower lip curvature, smile arc (relationship), 163f
- Lower molars  
 eruption of, excess, 203f  
 loss of, 603f
- Lower premolar extraction, 665f
- Lower second molars, unerupted or impacted,  
 514–517, 517f–519f
- Lymphoid tissue, proliferation of, 66
- M**
- Macro-esthetics  
 considerations of, 200, 214–217  
 facial proportions, 150–158
- Magnetic resonance imaging (MRI), 26  
 usage of, 167
- Magnets, usage of, 288

- Malformation, definition of, 107
- Malformed teeth, 118–120
- Malocclusion
- causes of, 107–120
  - characteristics of
    - classification by, 198–202
    - NHANES III evaluation, 5, 7f
    - via Venn diagram, 195f
  - classification (Angle), 2
  - classes, 2
  - differences, 7
  - clinical effectiveness, evidence of, 11f
  - dental disease, relationship to, 10–11
  - dental/skeletal contributions, cephalometric analysis in, 175f
  - as developmental condition, 107
  - disease of civilization, 126
  - epidemiology of, 5–7
  - etiologic processes, understanding, 37
  - as genetic problem, 122
  - handicapping, concept of, 10
  - increase, evidence of, 9
  - injury relationship, 10–11
  - mouth breathing, relationship of, 133
  - musical instrument playing, impact of, 130
  - normal classes, 3f
  - occurrence, experiments (Stockard), 122
  - prevalence, increase, 9
  - psychosocial problems of, 10
  - racial/ethnic composition, differences of, 7
  - randomized clinical trials of, 11–12
  - retrospective studies, control group (requirement), 12
  - severity
    - impact, 13
    - as indication for surgery, 657–661
    - mastication difficulty, 147
  - speech difficulties related to, 148t
  - speech problems, relationship of, 147
  - treatment of
    - demand for, 15
    - type, evidence-based selection, 11–12
  - types, prevalence (changes), 6f
- Mandible, 35–36
- alizarin injections of, 28f
  - angles, bone formation (excess), 127f
  - anterior movement of, 668f
  - anteroposterior position of, maxilla vertical position and, interaction with, 227f
  - birth trauma to, 115
  - blow, impact, 42f
  - Bolton template, superimposition of, 185f
  - bone
    - formation, diagrammatic representation, 33f
    - limb bones, structural similarity, 45
  - condylar fracture of, 142
  - condylar neck, vulnerability of, 115
  - core of, rotation, 93
  - dentition, position of, 101–103
  - development of, 35–36
  - differential growth of, 81–82
  - downward and backward rotation of, 175f
  - forward rotation of, 95f
  - fracture, radiographs, 71f
  - height, growth (timing), 89–90
  - internal rotation of, 93f
  - lengthening, external fixation for, 46f
  - long bone, analogy of, 41f
  - mean dimensional changes in, 98f
  - movement of, 667
  - position of, effect of orthodontic leveling, 696f
  - posterior movement of, 668f
  - set-back of, 681f
  - superimposition, 185
  - vertical position of, maxilla vertical position and, interaction with, 227f
- Mandible (*Continued*)
- visualization of, 93f
    - method, 39
    - width, growth (timing), 89–90
- Mandible growth (mandibular growth), 36, 60, 88–89
- curves for, 85f
  - excess
    - functional appliances in treatment of, 450
    - prolongation of, 103f
  - feature of, 88
  - perspective of, 36f
- Mandible length
- changes of, 91t
  - growth, 37f
  - timing, 89–90
  - increase, longitudinal data for, 87f
- Mandibular advancement, surgery, advantages of, 215
- Mandibular anterior repositioning appliance (MARA), 462, 464f
- Mandibular arch
- leveling of, 692–696
  - space, 66
- Mandibular asymmetry, 116f
- cause of, 238
- Mandibular buccal segment expansion, facial movement of, 420
- Mandibular canines
- changes in, average, 91f
  - eruption of, 77f
  - repositioning of, 80
  - space, 65–66
- Mandibular condylar head, pathologic changes in, 616, 617f
- Mandibular condyle
- endochondral ossification, occurrence, 31
  - fracture, impact, 43f
  - neck, fragility of, 42
- Mandibular deficiency
- anterior deep bite combined with, 698f
  - asymmetric, 492–497
  - problem in, growth modification approach for, 491f–492f
  - severity of, 675
  - sleep apnea, relationship of, 147–148
- Mandibular dental arches, 8f
- Mandibular dentition, superimposition on, 197f
- Mandibular disk, displacement of, 616, 617f
- Mandibular distalization, 646–647
- Mandibular excess, 450–452
- asymmetric, 497
- Mandibular first molars
- compromised, 418f
  - extraction site of, 630
  - loss of, panoramic radiograph of, 631f–632f
- Mandibular first premolars, eruption of, 77f
- Mandibular implants, superimposition on, 93f, 96f
- Mandibular incisors
- crowding, tendency for, 101–103
  - irregularity of, 80f
  - proclination of, 626f–628f
- Mandibular lateral incisor, ectopic eruption of radiograph of, 402
- Mandibular miniplates, class III elastics to, 444–449
- Mandibular permanent central incisors, proximal contact of, 80
- Mandibular plane angles
- clinical visualization of, 158f
  - comparison of, 134f
  - evaluation of, 157
- Mandibular posterior teeth, vertical level of, cephalometric radiograph of, 642f–643f
- Mandibular premolars, extraction of, 548–551, 550f
- Mandibular primary canines, loss, 419
- Mandibular prognathism
- in Hapsburg family, 122f
  - inherited tendencies, impact of, 124
- Mandibular ramus, 674f
- deficiency/absence of, 111f
  - location of, 36
  - osteotomy, usage of, 238–239
  - vertical growth of, 73f
- Mandibular right lateral incisor, missing, 615f
- Mandibular right second primary molar, ankylosis, 74f
- Mandibular second molars
- early eruption of, 78
  - impacted, surgical uprighting of, 519f
- Mandibular second premolars
- eruption of, 77f
  - space closure in, 538f
- Mandibular shift, equilibration for, 364–365, 365f
- Mandibular space regaining, 394, 394f–395f
- Mandibular stabilizing lingual arch, 511f
- Mandibular surgery, 667–668
- Mandibular symphysis
- distraction of, 675f
  - widening of, 675
- Mandibular teeth, eruption path of, 95
- Mandibular-deficient children, with excessive lower face height, 488f
- Mandibulofacial dysostosis (Treacher Collins syndrome), 110f
- Martensitic NiTi, 279
- bending nomograms of, 283f
  - relative strength, stiffness, and range for, 281f
  - torsion nomograms of, 284f
- Masseter muscle
- absence, impact of, 117f
  - hypertrophy of, 127f
- Mastication, difficulty in, malocclusion (impact), 147
- Masticatory function, 125–126
- teeth and periodontal structures in, forces in, 249
- Masticatory muscles, neuromuscular adaptation, 681
- Masticatory system, disturbances into, 122
- Mastoid air cells, infection of, 45f
- “Maternal deprivation” syndrome, 52
- Mathematical transformations
- grid (D’Arcy Thompson), 27f
  - usage of, 27
- Maturing collagen, cross-links in development, 71
- Maxilla
- anterior movement of, 668f
  - Bolton template, superimposition of, 185f
  - curves for, 85f
  - dentition, position of, 101–103
  - downfracture of, 668
  - downward movement of, 681
  - downward/forward translation of, 88f
  - extraoral force to, 455, 456f
  - effect of, 477, 478f–481f
  - formation of, 31–32
  - height, growth (timing), 89–90
  - implants, superimposition on, 94f
  - internal rotation, occurrence of, 94
  - length, growth (timing), 89–90
  - nasomaxillary complex, 34–35, 35f
  - orthodontic force against, effects of, 268
  - posterior movement of, 668f
  - superimposition, 185
  - illustration of, 96f
  - superior repositioning of, 669f–670f
  - transverse expansion of, 218f
  - transverse force across, 212f
  - vertical position, mandible positions and, interaction with, 227f
  - width, growth (timing), 89–90



- Maxillary advancement  
early, 691  
preoperative and postoperative findings, color map representation in, 194f  
simultaneous rhinoplasty with, 705f-709f
- Maxillary anterior alveolar bone, retain, root burial to, 409f
- Maxillary anterior teeth  
laminate veneers, appearance of, 221f  
space closure, appearance of, 221f
- Maxillary arch  
constricted, expansion of, 365-366, 365f-367f  
expander for, 437f  
leveling of, 696  
narrowness of, 162f, 438f-439f, 563f  
splint attached to, 443f
- Maxillary canines  
ectopic eruption of, in preadolescent children, 379-381, 382f-383f  
eruption of, 76f, 78  
impaction, panoramic radiograph in, 169f  
reshaping of, 220f  
uprighting spring, 560f
- Maxillary central diastema (maintenance), bonded lingual retainer (usage), 588f
- Maxillary central incisors  
fracture, 10f  
height-width proportions for, 164f  
height-width relationships for, 164-165  
lingually displaced and ankylosed, 634f  
malformed, 576f-577f  
tipped mesiodistally, 164f  
torque of, 305f
- Maxillary constriction, tendency towards, 134
- Maxillary deficiency  
anteroposterior and vertical, 440-449  
maxillary advancement and, 679f  
severity of, 673-675
- Maxillary dental arch, width (proportion), 162f
- Maxillary dental protrusion and spacing, 411-413
- Maxillary dentition, yaw of, 200f
- Maxillary distalization, 646
- Maxillary expanders, configuration of, 437f
- Maxillary expansion, 431f  
antineuritic effect of, 240f
- Maxillary first molars  
ectopic eruption in, in preadolescent children, 378-379, 378f-381f  
high-pull headgear to, 488
- Maxillary gingiva, display of, 154f  
excessive, 217-218  
cause of, 154f
- Maxillary growth  
front surfaces, remodeling of, 35  
manipulation of, 45  
mechanism, diagrammatic representation of, 88f
- Maxillary incisors  
ankylosed, 631  
crowding, 166f-167f  
damaged, 631  
display of, 161f  
exposure, 99f  
extreme tipping of, 270f  
labially directed force against, 608f  
protrusion of, 10-11  
measurement of, 183f  
treatment of, 680f  
retraction of, 157f  
cephalometric superimposition of, 626f-628f  
closing loops and, usage of, 296f  
risk factors for, 272t  
rotated, 166f  
spacing of, 612f  
uprighting of, 96f
- Maxillary injuries, 237-238
- Maxillary lateral incisors  
absence, substitution, 220f  
eruption of, characterization by, 76f  
missing, 415-417, 416f-417f  
implant for, 635f  
placement of, 76f  
size, disproportion of, 120f  
small, tooth size problems by, 559
- Maxillary left canine, bridge in, failure of, 611f
- Maxillary left central incisor  
avulsed, 409f  
loss, trauma (impact), 539f-540f
- Maxillary midline, supernumerary teeth location for, 121f
- Maxillary midline diastema, 5f, 398f-400f, 399  
complication of, 517  
management of, 520f  
recurrence of, 518
- Maxillary miniplates, class III elastics to, 444-449
- Maxillary molars, headgear to move, 422
- Maxillary occlusal, 615f
- Maxillary papillae, swollen, 569f
- Maxillary posterior crossbite, 671f
- Maxillary posterior teeth, eruption of  
excess, 227f  
inhibition of, 485-486
- Maxillary premolars, extraction of, 548-551, 550f  
Hawley retainer, usage of, 585f
- Maxillary protraction  
defer, 442-443  
Delaire-type facemask, 442f
- Maxillary protrusion, 183f
- Maxillary removable splint, usage, 443f
- Maxillary retrusion, surgical predictions for, 665f
- Maxillary right central incisor  
apex, periapical radiolucency at, 407f  
gingival inflammation in, 486f-487f  
resorption of root of, 409f
- Maxillary right lateral incisor, root, apex, curvature, 71f
- Maxillary segments, repositioning of (cephalometric superimposition), 669f-670f
- Maxillary skeletal base, width (appearance), 201
- Maxillary space regaining, 392-394, 393f
- Maxillary splint, high-pull headgear to, 488
- Maxillary structures, active growth of, 88
- Maxillary surgery, 668-670  
segmental, 697f
- Maxillary teeth  
contact points, move progressively gingivally, 165f  
exposure of, inadequacy, 217f  
forward displacement, 444  
protrusion of, 175f
- Maxillary unit length, measurement of, 181-182
- Maxillary-deficient child, 444
- Maximum anchorage, 535-537
- Maximum incisor retraction, 535-537
- McNamara analysis, 182-183  
measurements, usage of, 183f
- Measurement  
analysis, 178-185  
approaches, cephalometric analysis (elements), 201f  
data  
acquisition, 23-26  
analysis of, 27-28, 27f  
graphic presentation of, 27
- Meckel's cartilage  
bone formation of, 33f  
disintegration of, 31
- Medial nasal prominence, 110
- Medical history, 142  
obtaining, 142f-144f
- Menarche  
age at, 64f  
times, velocity curves for, 23f
- Mendelian genetics (classical genetics),  
development of, 134
- Mesial crown and root movement, 409-410
- Mesial root, movement of, 604-605, 607f
- Mesial step, 80-81
- Mesiodens, 118-120  
location of, 121f
- Metal brackets, debonding, 566
- Mexican-American youths, orthodontic need, 15f
- Microcephaly, 42
- Micro-esthetics, 150  
considerations, 219-221  
dental appearance, 161-166  
procedures, 570-574  
treatment plan, 572-574
- Micro-incisions, usage of, 262f
- Midface, width, proportional to, 162f
- Midface deficiency  
achondroplasia, impact of, 123f  
development of, 41-42  
improvement of, 114f
- Midline correction, 558f
- Midline diastema  
localized excess space problem of, 409-410  
presence of, 5-6
- Midline discrepancies, 558-559
- Midline shift, bodily tooth movement, 419f
- Midpalatal suture, opening of, 212f, 218, 431f  
early expansion by, 421f  
maxillary expansion in, 512
- Midsagittal suture, absence of, 44f
- Mineralization  
occurrence, 30  
zone of, 46f
- Mini-esthetics, 150  
considerations of, 200, 217-219  
tooth-lip relationships to, 158-161
- Minimal attached gingiva, 147f
- Minimal periodontal involvement, treatment of patients with, 619-620
- Minimal space discrepancy, 394-395
- Minimum incisor retraction, 537-538, 538f-540f
- Miniplate anchorage, 544, 547f
- Miniplates, 348-349, 348f-350f  
bone screws *versus*, 350t  
failure rate, 349t
- Mixed dentition  
early, palatal expansion in, 430-431  
late  
palatal expansion in, 431-433  
sutural expansion, 438-440  
occlusal relationships in, 80-81  
treatment, expansion *versus* extraction in, 419-420, 423f  
years, in late childhood, 66-83
- Modeling, 32  
observational learning, 51-52, 51f
- Moderate anchorage  
situations, 532-534  
space closure  
with 18-slot edgewise, 533-534  
with 22-slot edgewise, 532-533, 534f
- Moderate arch-length, increase, 421f
- Moderate generalized resorption, 271
- Moderate nonskeletal problems, in preadolescent children, 356-401
- Moderate periodontal involvement, 620-624
- Moderately severe hemifacial microsomia, 673
- Modified corticotomy, 260-261, 263f  
impact of, 262f
- Modified functional appliances, as active retainers, 594
- Molar tube/bracket prescriptions, 337t
- Molars  
bilateral expansion of, creation of, 307f

Molars (*Continued*)

- buccal root torque of, 562
  - distal movement of, 420, 646–647
  - distalization of, 422
    - arch circumference, increase, 423*f*
    - for expansion for crowding, 422
  - extraction of, 213
  - final positioning of, 605, 607*f*
  - protraction, 647, 648*f*–649*f*
  - region, soft tissue pressures (diagrammatic representation), 129*f*
  - relationship of, 195*f*
    - transition, possibilities of, 82
  - separation, maximum effort of, 127*f*
  - uprighting
    - appliances for, 604–605
    - auxiliary spring, 606*f*
    - brackets in, 602*f*
    - planning, 603–604
    - tipped, 604*f*
    - two, in same quadrant, 605
    - unstable, 607*f*
  - widths, changes (average), 91*f*
- Moment
- creation of, asymmetric V-bend and, 303*f*
  - definition of, 288
  - force, ratio, 290*f*
  - magnitude of, decrease in, 288
  - reduction in, 302
  - usage of, 289–291
- Moment of couple (MC), 290
- moment of force, ratio, 290
- Moment-to-force ratio, 290
- Monobloc, 457
- Monozygotic twins, dizygotic twins (comparison), 123
- Moore retainer, 584
- Moorrees mesh, 184
- Mothering, unstable, 52
- Mounting casts, reasons for, 168
- Mouse embryos, scanning electron micrographs in frontal plane, 111*f*
- Mouth
- negative pressure, during sucking, 129
  - scarring of, 125*f*
  - splaying of, 125*f*
- Mouth breathing
- clinical tests for, 133
  - extent, quantification of, 133
  - malocclusion, relationship of, 133
- Multidimensional problems, 455–499
- Multiple permanent teeth, roots of (panoramic radiograph), 406*f*
- Multiple supernumerary teeth, 412*f*
- Multistrand wire, 413*f*
- Muscle contraction, excessive, 116
- Muscle dysfunction, 116
- Muscle weakness syndrome, lower face (lengthening), 118*f*
- Myofascial pain, development of, 618

## N

- Narrow brackets, wide brackets *versus*, 291
- Nasal bone, growth of, 37, 40*f*
- Nasal breathers, 131
- Nasal respiration, percentage (comparison), 133*f*
- Nasal structures, passive displacement of, 88
- Nasomaxillary complex
  - growth, 34–35, 35*f*
  - in adolescence, 88
  - maxillary structures/nose, active growth of, 88
  - passive displacement in, 88
- Natal tooth, presence of, 65
- National Health and Nutrition Examination Survey III (NHANES III)
  - IOTN grades, 13
- National Health and Nutrition Examination Survey III (NHANES III) (*Continued*)
  - malocclusion evaluation, 5, 7*f*
  - posterior crossbite, 364
- Native population of northern America,
  - craniofacial morphology (characteristics), 126
- Natural dentition, normal occlusion (definition), 2
- Natural head position (NHP), cephalometric radiographs in, 179
- true vertical line, 179*f*
- Near-perfect alignment, 8*f*
- Neckstrap
  - adjustment of, 484*f*
  - for facebow, 481
- Negative reinforcement, 49
  - operant conditioning of, 50
  - punishment, contrast, 49
- Negative space, 160
- Neonatal period, survival, 61
- Neural crest
  - cells, migrations of, 108
  - formation of, 110*f*
  - migration, importance of, 108
- Neural folds, formation of, 110*f*
- Neural groove, formation of, 110*f*
- Neural tube formation, 107–108
- Neuromuscular adaptation, 681
  - stability and, 681, 681*f*–685*f*
- Neutral stimulus, classical conditioning (impact), 47*f*
- New adjuncts, to aligners, 318
- Newborn infant
  - head distortion of, 61*f*
  - survival of, 64
- Newborn skull, fontanelles of, 34*f*
- Nickel-titanium alloys, 278–281
  - austenitic form of, 279
  - bending moment in, deflection *versus*, 279*f*
  - crystal structure of, 278
  - martensitic form of, 279
  - properties of, 278–279
  - shape memory of, 278
  - superelasticity of, 278–279
  - wires, 279–281
- Nickel-titanium (NiTi) wire, in bonding, 327–328
- 19 x 25 TMA, 533
- <sup>99m</sup>Tc (gamma-emitting isotope technetium 99m),
  - usage of, 28–29
- Nitinol
  - bending nomograms of, 283*f*
  - torsion nomograms of, 284*f*
  - usage of, 279
- Nomograms
  - bending nomograms, 283*f*
  - torsion nomograms, 284*f*
- Nonconsonant (flattened) smile arc, 160
- Nonextraction correction, with interarch elastics, 551, 551*f*
- Nonextraction treatment plan, 424*f*
- Nonmetallic appliance materials, 331–334
- Nonsteroidal antiinflammatory drugs (NSAIDs),
  - impact of, 258
- Normal eruption, panoramic radiograph of, 69*f*
- Normal-face children, occlusal forces (comparison), 127*f*
- Normal function
  - periodontal and bone response to, 248–250
  - response to, 249
- Normal girls (females), growth chart of, 21*f*–22*f*
- Normal occlusion, concept, establishment of, 3–4
- “Normal variability,” of growth, 20
- Nose
  - active growth of, 88
  - floor, movement of, 36*f*
  - growth of, 37
  - jaws before adolescence and, 89*f*–90*f*

Nostrils, blockage of, 132*f*

Nutrition, adequacy, 61–62

Nutritional status, 61–62

## O

- Oblique smiles, 658*f*–660*f*
- Observational learning, 51–52, 51*f*
  - behavior acquisition, 51
  - modeling, 51–52
- Occlusal discrepancies, correction of, 594
- Occlusal function, 147–149
- Occlusal interferences, 509–510
- Occlusal plane
  - cant to, 159*f*
  - orientation, Fox plane demonstration of, 199*f*
  - rotates, 450
- Occlusal relationship
  - considerations of, 6
  - overcorrection, finishing procedure of, 580
  - problems in, management of, 364–375
    - anterior crossbite, 368–372
    - anterior open bite, 372–375
    - deep bite, 375
    - posterior bite, 364–368, 364*f*–369*f*
  - in splint, 618*f*
- Occlusion
  - Angle's line, teeth (relationship), 197*f*
  - changes in, adolescence, 98–103
  - concept, development of, 2
  - emphasis, 3–4
  - example of, 236*f*
  - functional, 4
  - imperfections, impact of, 10
  - improvement in, 493*f*–495*f*
  - line, catenary curve, 3*f*
  - methods for settling the teeth into, 564–565
  - normal occlusion, concept (establishment), 3–4
  - stability of, 244*f*–245*f*
  - stable, 566
- Old extraction sites, 630
- Older children, positive reinforcement of, 50
- Oligodontia, 116–118
- Omission (time-out), 49
- One dental arch, early treatment on, 354
- One-couple systems, 299–300
- One-wall vertical pockets, esthetic problem in, 609
- Open bites, 372–375
  - appliance therapy in, 375, 375*f*
  - deep bite relationship of, 7*f*
  - flowchart in, 376*f*
  - long faces and, 487–492
  - nondental intervention in, 374–375, 375*f*
  - sucking habits, effects of, 372–374, 374*f*
- Operant conditioning, 48–51
  - classical conditioning, contrast of, 49*f*
  - principle of, 49
  - punishment of, 49
  - theory of, 49
  - types of, 49, 49*f*
  - usage, 50
- Opus closing loop, 531–532, 533*f*
- Oral cavity, physiologic functions of, 64
- Oral Deformities (Kingsley), 2
- Oral disease, orthodontic treatment (etiological agent), 11
- Oral function, 10
  - malocclusion, impact, 10
  - maturation of, 64–65
  - characterization of, 64–65
- Oral habits, 372–375
  - appliance therapy in, 375, 375*f*
  - flowchart in, 376*f*
  - nondental intervention in, 374–375, 375*f*
  - sucking habits, effects of, 372–374, 374*f*
- Oral health, clinical evaluation of, 146–147

- Oral hygiene, 146f  
importance of, 56
- Oral structures, health, 167–168
- Organ culture, fetal rat bones (autoradiograph), 29f
- Orthodontic anchorage, 295
- Orthodontic appliances  
characteristics of, 601, 602f  
considerations for, 692, 693f–695f  
design factors in, 288–292  
reactivation, avoidance of, 258  
removal of, 233f–234f  
problems, 583f
- Orthodontic archwires  
beta-titanium, 281  
cobalt-chromium alloys, 278  
comparative properties of, 280t  
comparison of, 281–282  
composite plastics, 281  
consideration for, 276  
elastic material, force-deflection curve for, 277f  
materials, 278–282  
nickel-titanium alloys, 278–281  
shape of, 285–287  
size of, 285–287, 285t  
stainless steel alloys, 278  
surface qualities of, 292
- Orthodontic casts (trimming), symmetric bases (usage), 170f
- Orthodontic classification, 193–202  
five-characteristics classification system, additions to, 196–198  
scheme, focus, 196  
systems, development of, 193–196  
view of, 194f
- Orthodontic comprehensive treatment, planning, steps in, 223
- Orthodontic consultation, 658f–660f
- Orthodontic development, 2–4
- Orthodontic diagnosis, 208  
process of, 137
- Orthodontic elastics, wearing, 58f
- Orthodontic force  
control of, 285–287  
duration, classification of, 256–257  
effects of, 268–274  
mechanical principles in, 276–309  
production of, 276–288  
response to, drug effects on, 258–260  
skeletal effects of, 268  
threshold for, implication of, 250
- Orthodontic intervention, requirement of, 241–243
- Orthodontic movement  
optimum forces for, 256t  
tipping in, 254
- Orthodontic patients, diagnostic evaluation of, 223f
- Orthodontic pretreatment, panoramic/cephalometric radiographs before, 205f
- Orthodontic problems, 5–7  
etiology of, 107–136  
in contemporary perspective, 134–135  
list, priorities for, 224  
understanding of, 30
- Orthodontic research, 12
- Orthodontic teeth  
alveolar process and, ultrasound and, 263  
movement of, 249  
bone loss during, 237f
- Orthodontic therapy, biologic basis of, 248–275
- Orthodontic traction, 512
- Orthodontic treatment, 571f–572f  
alignment in, 263  
basis of, 248  
benefit *versus* cost and risk, analysis of, 228  
burden of, 260  
changes, evaluation of, 193
- Orthodontic treatment (*Continued*)  
completion of, 620f–623f  
complexity of, 209  
control before, 203f  
deferral, 231f  
dentist and dental specialist plan in, 208  
detailed plan of, 230–231  
effectiveness of, 124  
as external motivation, 145  
as internal motivation, 145  
mobility, relationship with, 268–269  
motivation, classification of, 145  
Norwegian system, 312  
pain in, relationship with, 268–269  
periodontal considerations for, 619–625, 619f  
plans  
conference, 228f  
final treatment plan, example of, 230b  
possibilities, 209–223  
evaluation, factors in, 224–229  
interaction of, example of, 228b  
posttreatment profile of, computer-generated simulation of, 214f  
root resorption and, combination of, 272f  
surgical treatment together with, 692–704, 697t  
temporomandibular dysfunction in, 616–619  
time, reduction of, 260  
usage of, 54
- Orthodontic treatment goals, 223, 228  
change, 2–5  
demand for, 13–16  
financial constraints, impact of, 15–16  
etiologic agents for, 11  
need, epidemiologic estimates of, 13–15  
primary, 4  
psychosocial problems, 10  
rarity, 16  
secondary, 4  
soft tissue paradigm, 4–5  
type, evidence-based selection of, 11–12  
U.S. population percentage of, 15f
- Orthodontic treatment planning, 208–246  
complexity of, 138  
comprehensiveness, 223–231  
decisions and, patient interaction, 230  
errors in, 231  
patient input in, 208–209  
patient interaction in, 138, 139f  
predictability and success with, 138  
process of, 137  
sequence, 209f  
in special circumstances, 236–245  
timing of, 138
- Orthodontic triage, 356–364  
dental development, 358–362, 360f  
facial profile analysis, 357–358, 358f  
occlusal discrepancies, 362–364, 363f–364f  
space problems, 361f–362f, 362  
syndromes and developmental abnormalities, 357, 357f–358f
- Orthodontic wires, comparative properties of, 280t
- Orthodontic-pediatric dentistry practice, child entry, 48f
- Orthodontic-restorative interaction, management of, 221–223
- Orthodontics  
CBCT, usage of, 193  
clinical effectiveness, evidence of, 11f  
enhancement technology, 16  
opinion-driven specialty, cessation of, 12  
quality, hierarchy of, 11f  
randomized clinical trials of, 11  
retrospective studies, control group (requirement), 12
- Orthodontist, restorative dentist and, interaction between, 221–223
- Orthognathic procedures  
esthetic and psychosocial considerations, 663–664  
stability of, 680f
- Orthognathic surgery  
development of, 657  
esthetic and psychosocial considerations for, 663–664  
indication of, 657–661  
jaw movements with, 667f–668f  
planning for, 691–692  
psychological response to, generalized representation of, 663f  
rhinoplasty with, combination of, 216f  
*versus* temporary skeletal anchorage, 661–663  
widening, 675
- Orthopedic palatal expansion, 670
- Ossification centers, appearance of, 31f
- Osteoblastic activity, stimulation of, 254
- Osteoblasts  
fibroblasts and, comparison of, 248  
requirement of, 254
- Osteoclastic activity, stimulation of, 254
- Osteoporosis, as postmenopausal problem, 258
- Osteoprotegerin (OPG), increase in, 251–254
- Osteotomy cuts, location for, 661f
- Overbite  
definition of, 6f  
excessive, 562–563  
incisor horizontal overlap, 6f  
increase, 424  
relationship, establishing, 608  
reverse overjet, 7f  
vertical deviations from, 6–7
- Overcorrection aligners, 615f
- Overjet  
anteroposterior deviation indication of, 6  
Class II (U.S. population), 7f  
presence of, 130–131
- Overretained primary teeth, 375–377, 377f
- Overtreatment, 569
- P**
- Palatal anchor, surgical placement of, 298f
- Palatal anchorage, 544, 545f–546f
- Palatal bone screw anchorage, 544–547, 548f
- Palatal expansion, 430–431  
acrylic retainer for, 435f  
devices, clinical management of, 437–438
- Palatal plate, pinning of, 242f–243f
- Palatal root torque, improvement in, 234f–235f
- Palatal vault, remodeling of, 36f
- Palate  
bilateral cleft lip/palate, 113f  
remodeling of, 94
- Palate-covering removable appliance, 583
- Panoramic radiograph  
supplementation of, 167–168  
value of, 167
- “Papilla split” procedure, 570f
- Papilla-dividing procedure, 570
- Paradigm, definition of, 4
- “Parallel elastics” arrangement, 558f
- Parasagittal osteotomies, 668–670
- Parathyroid hormone receptor gene (PTH1R), 69–71
- Parent, child (bond), 52
- Partial appliance, complete appliance and, biomechanical difference between, 353, 353f
- Partial denture space maintainers, 389–390, 389f
- Partial fixed appliance, adjunctive orthodontics with, 600
- Passive tooth-borne functional appliances, 313, 313f–314f



- Paternalism, autonomy *versus*, 229–230
- Pathologic problems  
developmental problems *versus*, 223–224  
example of, 224*b*
- Pathology  
cephalometric radiographs, screen for, 174–175  
dental radiographic examination (U.S. Public Health Service guidelines) for, 168*t*  
issues, in CBCT imaging, 191–193
- Patient compliance, timing, 429
- Patient-parent consultation, 229
- Pavlov, Ivan, 47
- Pediatric dentistry-orthodontic office, orthodontic treatment (example), 51*f*
- Peer Assessment Rating (PAR) scores, 459–460
- Perinatal period, growth disturbances in, 114–115
- Periodontal disease  
control of, 602–603, 626*f*–628*f*  
prevalence of, 619  
susceptibility to, 9–10
- Periodontal evaluation, 146
- Periodontal health, improvement of, 600
- Periodontal involvement  
moderate, 620–624  
severe, 625, 625*f*–628*f*
- Periodontal ligament (PDL)  
adaptation in, 249  
area, decrease, 601–602  
blood flow in, changes in, 252*f*  
cells, FAK mechanoreceptor in, 251–254  
cellular elements in, 248  
collagen cross-linking in, 72  
compression of, 251, 254  
decrease in, 251  
Histologic specimen of, 255*f*  
zone of, 270*f*  
cyclic nucleotide levels, increase in, 256  
fibers of, angulation of, 249*f*  
force generation ability of, 250  
ischemic areas of, development of, 268  
necrosis within, 250  
osteoblasts and fibroblasts in, comparison of, 248  
pressure in  
maximum, 254  
relationship of, theoretical representation of, 265*f*  
reorganization of, 579–580  
importance of, 579  
response of, 269  
space, 248  
enlargement of, 252*f*  
fluid within, presence of, 249  
pressure-tension in, 251  
structure and function of, 248–275  
supporting structure, construction of, 124–125  
sustained force, response of, 250–264
- Periodontal pockets, prevalence of, 619*f*
- Periodontal problems, 619
- Periodontal response, 248–250
- Periodontal structures, diagrammatic representation of, 249*f*
- Periodontal support, reduced, effects of, 601–602
- Periodontal tissues, reorganization of, 579
- Periodontal treatment procedures, usage of, 237
- Permanent canines, replacement by, 416*f*
- Permanent dentition, tooth development, chronology of, 75*t*
- Permanent first molars, defer maxillary protraction, 442–443
- Permanent incisors  
crowns of, 66*f*  
labial positioning of, 80  
tip lingual of, 419
- Permanent lateral incisors, congenitally missing, 416*f*
- Permanent maxillary left central incisor, unerupted, 418*f*
- Permanent molars  
end-to-end relationship of, 82  
occlusal relationships of, 82*f*
- Permanent premolars, primary molars, size difference, 81*f*
- Permanent right incisor, extrusive displacement injuries to, 408*f*
- Permanent teeth  
crown height of, increase, 105*f*  
enamel defects on, 148*f*  
eruption of, 67–74  
objective of, 243  
panoramic radiograph of, 69*f*  
pulp chamber size, 103–104  
missing, 413–419  
pulp chamber, size (decrease), 104*f*  
spacing of, 409–411  
traction following intrusion of, 408*f*
- Permeability, electromagnetic fields and, 251
- Personal fable, functions (usefulness), 58
- Personal identity, development of, 54–55
- Pharyngeal airway, in lateral cephalometric radiographs, 240*f*
- Pharyngeal arches, formation of, 108
- Pharyngeal tonsils, size of, 132
- Physical casts, virtual casts *versus*, 168–170
- Physical defect, impact of, 10
- Physical growth  
deficit, production of, 52  
evaluation, 142–145  
experimental approached of, 28–29  
mathematical transformations, usage, 27  
measurement approaches of, 23–28  
measurement data  
acquisition, 23–26  
analysis of, 27–28, 27*f*  
graphic presentation, 27  
methods of studying, 23–30  
seasonal/cultural factors of, 86  
status, 142–144  
studying, methods for, 23–30  
vital staining of, 28–29
- Physiologic adaptations, dramatic set (requirement), 60
- Piaget, Jean, 55
- Pierre Robin sequence, 115  
appearance of, 115*f*
- Piezoelectric knife, usage of, 262*f*
- Piezoelectric signals, characteristics of, 251
- Pin and tube appliance, 322
- Pituitary gonadotropins, 84  
stimulation of, 84–85
- Pituitary portal system, 84
- Plastic brackets, problems, 614
- Plastic deformation, as cold work, 277*f*
- Plastic materials, 287
- Polycrystalline alumina brackets, 333–334, 333*f*
- Polysiloxane record, 168
- Polyvinyl siloxane (PVS) impressions, 319
- Pont's index, usage of, 213
- Poor man's cephalometric analysis, 153
- Positioners  
advantages of, 585–586  
for finishing, 567–568, 568*f*  
and retainers, 585–586
- Positive reinforcement, 49  
example of, 50*f*
- Postemergent eruption, 72–74, 72*f*
- Postemergent spurt, 72
- Posterior bite, 364–368  
approaches to, 364–366, 365*f*–368*f*  
expansion lingual arch in, 364, 364*f*  
flowchart in, 369*f*
- Posterior crossbite  
correction of, 304–306, 510–512, 510*f*–511*f*  
dental/skeletal characteristic of, 201*f*  
description of, 201
- Posterior eruption, cephalometric tracing showing, 129*f*
- Posterior maxillary implants, mean growth tracks of, 92*f*
- Posterior permanent teeth, eruption, primary failure of, 405*f*
- Posterior teeth  
alignment, control, removable clip-type retainer (usage), 586*f*  
eruption, control of, 583*f*  
extrusion of, cephalometric radiograph for, 619*f*  
transverse movement of, 304–306  
uprighting, 603–607
- Postoperative care, 699–704
- Postsurgical orthodontics, 704, 705*f*–709*f*  
choice of archwires for, 704
- Postsurgical stability  
clinical success of, 680–681  
hierarchy of, 680–681, 680*f*  
predictability, 680–681
- Posttreatment cephalometric radiographs, usage of, 234*f*–235*f*
- Posttreatment dental occlusion, example of, 699*f*–704*f*
- Posttreatment facial appearance, example of, 234*f*–235*f*
- Posttreatment profile, computer-generated simulation of, 214*f*
- Posttreatment smile/profile, example, 699*f*–704*f*
- Posturing, control of, 565–566
- Preadolescents  
anteroposterior problems in, 357–358, 359*f*  
appliance/braces, usage of, 145  
asymmetric dental development in, 360  
ectopic eruption in, 377–385  
ankylosed primary teeth, 383–385, 384*f*–385*f*  
delayed incisor eruption, 383, 384*f*  
lateral incisors, 377–378, 377*f*–378*f*  
maxillary canines, 379–381, 382*f*–383*f*  
maxillary first molars, 378–379, 378*f*–381*f*  
supernumerary teeth, 381–383  
eruption problems in, 361–362  
management of, 375–385  
overretained primary teeth, 375–377, 377*f*  
excessive dental protrusion or retrusion, 358, 359*f*  
moderate from complex treatment problems, distinguishing, 356–364  
moderate nonskeletal problems in, 356–401  
occlusal relationship problems in, management of, 364–375  
anterior crossbite, 368–372  
anterior open bite, 372–375  
deep bite, 375  
posterior bite, 364–368, 364*f*–369*f*  
orthodontic triage, 356–364  
dental development, 358–362, 360*f*  
facial profile analysis, 357–358, 358*f*  
occlusal discrepancies, 362–364, 363*f*–364*f*  
space problems, 361*f*–362*f*, 362  
syndromes and developmental abnormalities, 357, 357*f*–358*f*  
palatal expansion in, 431–433  
permanent teeth in, missing, 360–361  
space analysis in, 385–388  
principles of, 385–386, 385*f*–386*f*  
unerupted permanent teeth, 386–388, 386*b*, 387*f*–388*f*  
space problems  
adequate space, 394–395  
generalized moderate crowding, 397, 397*f*

- Preadolescents (*Continued*)  
 in other tooth displacements, 397–399, 398f–400f  
 quantification of, 385–388  
 space maintenance, 388–392  
 space management, 395–397, 396f–397f  
 space regaining, 392–394  
 treatment of, 388–399  
 supernumerary teeth in, 361  
 treatment in  
 anchorage control, 353  
 biomechanical difference between complete and partial appliance, 353, 353f  
 early, 352  
 focus in, 352  
 goals in, 352, 353f  
 interarch mechanics, 353–354, 354f  
 mixed dentition treatment with partial fixed appliance in, 352–353  
 one dental arch, early treatment on, 354  
 retention, 354, 354f  
 space closure, 353  
 unerupted teeth, 353, 354f  
 very early, 352  
 vertical problems in, 357–358, 359f  
 Precious metal alloys, 278  
 Prediction program, lateral digitization model (usage), 178f  
 Preemergent eruption, 67–71  
 processes, requirement of, 67  
 Preemergent propulsive mechanism, 71  
 Preformed arch wires, 342–343, 342f  
 Preformed closing loops, 531f–532f  
 Premature birth (low birth weight), 61  
 Premature infant, survival, 61  
 Premaxillary segment, 110  
 Premolars  
 buccal root torque of, 562  
 congenital absence of, 74f  
 distal drift of, 630  
 extraction of, 584  
 in incisor crowding, 506  
 site, closure, 297f  
 final positioning of, 605, 607f  
 fractured, extrusion of, 610f  
 root of, coronal section of, 270f  
 uprighting, 562  
 Preoperational period, 56  
 Preoperative and postoperative findings, color map representation in, 194f  
 Prepubescent children, long-face pattern (identification), 126  
 Preschool years  
 chronic illness and, 61  
 nutritional status in, 61–62  
 physical development in, 60  
 premature birth (low birth weight), 61  
 Presurgery smile, example, 699f–704f  
 Presurgical orthodontics, 692–697  
 amount of, variation in, 692  
 Presurgical treatment  
 goals of, 692  
 objective of, 692  
 Pretreatment smile, 576f–577f  
 Primary canines, extraction of, 424  
 Primary dentition  
 relationship in, 82f  
 spacing of, 66  
 tooth development, chronology of, 61t  
 Primary failure of eruption (PFE), 69–71  
 identification of, 30  
 Primary incisors, magnitude, spacing of, 79f  
 Primary laterals, long-term retention of, 415  
 Primary mandibular second molars, retained, 414f  
 Primary mixed dentition, palatal expansion in, 430–431  
 Primary molars  
 eruption of, 64  
 occlusal relationship of, 82f  
 permanent premolars, size difference of, 81f  
 replacement, space relationships in, 80–83  
 Primary second molars  
 ankylosed, without successors, 408–409, 410f–411f  
 extraction of, 414f  
 loss of, 81  
 maintaining, 413  
 Primary teeth  
 developmental scale of, 62f  
 eruption of, 65–66  
 timing and sequence of, 65–66  
 resorption of, 67  
 stage, characterization of, 75f  
 Primate evolution, teeth number (reduction), 9f  
 Primate spaces, 66  
 Primitive human populations, in malocclusion, 122  
 Prioritized problem list  
 example of, 224b  
 solutions to, evaluation for, 224f  
 Problem list  
 development of, 202–204  
 example of, 205b  
 diagnosis, example of, 223b  
 prioritized problem list, example of, 224b  
 solutions, 224–226  
 example of, 224b  
 interaction among, 226–227  
 Problem-oriented approach, orthodontic diagnosis, 140–207  
 Problem-oriented method  
 requirements of, 229–230  
 usefulness of, 229  
 Profile analysis, 153–158  
 Profile convexity/concavity, 155f  
 Profile relationships, 414–415  
 Prognathic mandible, 121  
 Progressive posterior remodeling, space creation, 36  
 Proliferating cartilage cells, location of, 34f  
 Proliferating fibroblasts, presence of, 46f  
 Prostaglandin E  
 mediation of, 254  
 role of, importance of, 258  
 Prostaglandins  
 drugs on, effects of, 258  
 inhibitors, 258  
 Prosthetic replacement  
 space closure *versus*, 630–631  
 teeth, creation of, 2  
 Prosthodontic-implant interactions, 625–631  
 Prosthodontics, 2  
 Protruding incisors, retraction and intrusion of, 645–646  
 Protrusion  
 dental, excessive, in preadolescent children, 358, 359f  
 presence of, 213  
 Protrusive maxillary incisors, closing loop archwire, used to retract, 413f  
 Psychic distress, 10  
 Psychosocial considerations, 14–15  
 Psychosocial development, 52  
 Psychosocial stress, mechanisms by, 63f  
 Pubertal growth spurt, cessation of, 74  
 Puberty  
 occurrence, 84  
 questions, 144  
 timing of, 85–87  
 genetic/environmental influences of, 86  
 Pulp, effects on, 269  
 Pulp chambers, size (decrease), 104f  
 Punishment  
 negative reinforcement, contrast, 49  
 operant conditioning type, 49–50
- Q**  
 Quad helix  
 designs, lingual arches, 431  
 for posterior crossbite, 365–366, 367f  
 Quality, hierarchy, 11f  
 Quality of life (QOL), improvement of, 141  
 Questionnaire/interview, 140–146
- R**  
 Radiation exposure, problem in, 12  
 Radiation therapy, impact of, 404–406  
 Radiographic equipment, doses and risk associated with, 187t  
 Randomized trials, avoidance of, 12  
 Range  
 definition of, 277  
 improvement in, 286f  
 Rapid expansion, 432–433  
 in children, 432f  
 Rapid tooth movement, corticotomy in, 260  
 Rat (growth), mandible, 28f  
 Rebound, control of, 565–566  
 after tooth movement, 569–570  
 Receptor activator of nuclear factor-kappa ligand (RANKL), increase in, 251–254  
 Reciprocal tooth movement, 265  
 production of, 265f  
 Rectangular archwire, 562  
 fitting of, 290f  
 for initial alignment, 504f  
 replacing, 564  
 usage of, 291  
 Rectangular finishing archwire, 562–563  
 Rectangular slot, fitting of, 290f  
 Redistribution, space, 611, 612f  
 Reinforced anchorage, 265–266  
 Reinforcement, 295–296  
 concepts of, 50–51  
 extinction, contrast, 50–51  
 negative, 50  
 positive, 49  
 production of, 296f  
 Relapse  
 avoidance, 569–570  
 causes of, 580f  
 direction, identification, 580  
 growth-related relapse, cephalometric superimposition, 582f  
 long-term relapse, occurrence, 580–581  
 tendency toward Class III, 586  
 Relative intrusion, 227f, 518–521, 522f  
 Releasing factors, 84  
 Remodeling, 32  
 resorption, example of, 36  
 Removable acrylic appliances, with springs, 312  
 Removable appliances, 310–319  
 active aligners, development of, 310–312, 311f  
 cantilever springs, incorporation of, 286f  
 clear aligner therapy, 315–319, 317f–321f, 318b  
 functional appliances, for growth modification, 312–315, 312f–315f, 316t  
 retainer function of, 583  
 of Schwarz plate type, 311f  
 vulcanite bases and precious metal or nickel-silver wires, combinations of, 310  
 wearing, 54, 57f  
 Removable clip-type retainer, control of, 586f  
 Removable orthodontic appliances  
 advantages of, 310  
 disadvantages of, 310  
 Removable wraparound (clip) retainers, 584, 586f  
 Resilience, defining, 277f  
 Resistance  
 center of, 602f  
 friction *versus* binding in, 292–295  
 Resistance to sliding, 292–295

- Resorption  
 moderate generalized, 271  
 severe generalized, 271  
 severe localized, 271–272  
 surfaces, illustration of, 43*f*
- Respiratory pattern, 131–134  
 during resting conditions, 131–132
- Restorative dentist, orthodontist and, interaction  
 between, 221–223
- Restorative treatment, facilitate, 600
- Retainers  
 active, 591–594  
 bonded canine-to-canine, 587*f*  
 bonded (fixed) orthodontic, 586  
 clear (vacuum-formed retainers), 585  
 clip (removable wraparound retainers), 584, 586*f*  
 fixed, 586–591  
 fixed lingual, inadvertent tooth movement with,  
 589–591, 589*f*–592*f*  
 Hawley, 584  
 positioners, 585–586  
 removable, 584–586  
 wraparound (clip), 584, 586*f*
- Retention, 354, 354*f*, 579–596, 607, 607*f*  
 after anterior open bite correction, 583  
 after deep bite correction, 582–583  
 Class II growth pattern, 580–582  
 Class III growth pattern, 582  
 full-time, requirement of, 580  
 of lower incisor alignment, 583–584  
 necessity, reason, 579–584  
 timing of, 584
- Retraction  
 force, placement of, 529*f*  
 of protruding incisors, 644–646, 644*f*–646*f*  
 skeletal anchorage with, 537  
 springs, attachment of, 295  
 two-step frictionless, 535–537, 537*f*
- Reverse overjet, 7*f*  
 anteroposterior deviation indication of, 6  
 Class III (U.S. population), 7*f*
- Reverse-pull headgear (facemask), 442–444, 442*f*
- Rheumatoid arthritis, impact of, 117*f*  
 condylar process loss in, 238*f*
- Rhinoplasty, 679  
 focus of, 679  
 orthognathic surgery with, combination  
 of, 216*f*  
 simultaneous with maxillary advancement,  
 705*f*–709*f*
- Ribbon arch appliance, 322, 322*f*
- Ricketts analysis, 182–183
- Ricketts's utility arch, 521
- Rigid intraoral fixation (RIF), 667
- Roll deformity, 159*f*
- Root  
 burial, 409*f*  
 form, distortion (dilaceration), 120  
 appearance of, 121*f*  
 lingually, torquing force and, 561  
 paralleling, 559–560  
 surface area of, anchorage value and, relationship  
 of, 266*f*
- Root position  
 control of, 290  
 two-point contact for, 288–291  
 distortion, severity of, 120  
 MC/MF ratios and, 290  
 terms, definition of, 288–289
- Root resorption, 269–272  
 degree of, percentage of, 272*t*  
 orthodontic treatment and, combination of, 272*f*
- Root-backward, tendency, 530*f*
- Root-filled teeth, root resorption and, 236–237
- Root-parallel moments, 530–531, 560*f*
- Rotated incisors, 612–614, 613*f*
- Rotation, 90–96  
 center of, definition of, 288–289  
 production of, 255
- Rotational changes, terminology for describing, 90
- Round wire, compressed coil spring on, 607*f*
- Rubber materials, 287–288
- S**
- Sagittal split osteotomy, 661*f*, 667
- Sassouni analysis, 181
- Sassouni lines, indication of, 202*f*
- Scammon's curves  
 background of, 85*f*  
 of growth, 19*f*
- Schwarz, Martin, 311
- Schwarz plate, 311*f*
- Second molars  
 banded, 518*f*  
 mesial drift of, 630
- Second premolars  
 eruption plots  
 fiber optic cable, usage, 72*f*  
 Moire magnification, 73*f*  
 extraction of, 213  
 missing, 413–415  
 space of, extraction, to reduce the treatment  
 time, 415  
 treated by extraction, 414*f*
- Second primary molars, loss of, 80
- Secondary palate  
 closure of, 112  
 formation of, 108–110
- Secondary sexual characteristics  
 adolescent growth *versus*, 150*t*  
 attainment of, 150
- Second-order bends, 324–325  
 compensations for, 334, 335*f*–336*f*
- Segmented arch  
 approach, 308*f*  
 mechanics, 306–308  
 technique, with composite retraction spring,  
 534*f*
- Segmented archwires, for intrusion, 523–525,  
 524*f*–526*f*
- Self-control, sense of, 53
- Self-ligating brackets, 336–337, 338*f*, 647
- Sella turcica (S), line from, 179
- Sensorimotor period, 56
- Separating springs, 325, 326*f*
- "Separation anxiety", 52
- Sequential 3-D images, 193
- Serial extraction, 422–426, 425*f*–426*f*
- Sertoli cells, 86
- Severe generalized resorption, 271
- Severe localized resorption, 271–272
- Severe periodontal involvement, 625, 625*f*–628*f*
- Severe root resorption, risk factors for, 272*t*
- Sex hormones  
 control of, hypothalamus (impact), 85  
 release of, pituitary gonadotropins (impact), 85  
 secretion of, 84
- Sexual development  
 boys, stages of, 86  
 endocrine signals, diagrammatic representation  
 of, 85*f*
- Sexual maturation, signs of, 62
- Shape memory, 278
- Short-face, 94  
 of biting forces, 126  
 characterization of, 94  
 Class II, anterior face height increase in, 691  
 deep bite and, 484–487  
 functional appliance treatment for, 486*f*–487*f*  
 pattern, cranial base superimposition for, 96*f*
- Simulated chewing, occlusal force (comparison),  
 127*f*
- Single-rooted tooth, center of resistance of, 602*f*
- 16 x 22 wire, 533, 533*f*
- Skeletal ages, assessment of, 66–67  
 cervical vertebrae, basis on, 67
- Skeletal anchorage, 267, 297–298  
 absolute anchorage, provision of, 268*f*  
 applications of, 644–654  
 Class III elastics for, 451–452  
 derivation of, 297  
 for expansion, 434  
 facemask traction to, 444, 446*f*  
 for retraction, 537
- Skeletal cartilage, transplantation effects of, 40–41
- Skeletal Class II, problem correction, possibilities  
 for, 225*f*
- Skeletal deep bite, 181
- Skeletal deformities (details), CT scans (usage), 25*f*
- Skeletal development, 31*f*
- Skeletal discrepancies  
 distinguish, 182  
 increase, 184*f*
- Skeletal expansion, 420
- Skeletal growth  
 nature of, 30–32  
 process, occurrence of, 61
- Skeletal malocclusion, orthodontic camouflage and,  
 664*b*
- Skeletal mandibular deficiency, juvenile rheumatoid  
 arthritis and, 237
- Skeletal open bite, 181  
 characterization of, 202
- Skeletal problems, 214–217  
 existence of, treatment discussion on, 230
- Skeleton, extracellular material (mineralization), 30
- Skills, mastery of, 54
- Skin, tightening, 215*f*
- Skinner, B.F., 48–49
- Skull  
 bones, cleared alizarin-stained specimen, 33*f*  
 dissection, examination of, example of, 79*f*  
 flat bones, separation of, 33  
 hydrocephaly, 44*f*  
 scaphocephaly, 44*f*
- Sleep apnea, 239–240  
 mandibular deficiency (relationship), 147–148
- Sleeping habit (Angle), 130
- Sliding, resistance to, 292–295  
 binding and, impact of, 294*f*  
 elastic and inelastic binding in, 293–295  
 magnitude of, 295
- Sliding mechanics, in space closure, 528–529,  
 529*f*–530*f*, 529*t*
- Slow expansion, 431–433
- Slow palatal expansion, 435–437
- Small-for-gestational age (SGA) twins, growth  
 curves, 63*f*
- Smile  
 analysis, 158–161  
 appearance, impairment, 217*f*  
 brackets, placement of, 218  
 close-up views of, 204*f*, 233*f*–234*f*  
 esthetics, improvement in, 218*f*, 564*f*  
 facial appearance of, 666*f*–667*f*  
 framework, improvement in, 217–219  
 gummy smile, 234*f*–235*f*  
 improvement of, 645*f*–646*f*  
 incisor exposure on, 100*f*  
 maxillary gingiva on, display of, excess, 217–218  
 maxillary incisor exposure on, 99*f*  
 symmetry, 219  
 teeth, exposure of, 101*f*  
 transverse dimensions of, 160, 218  
 variables, 160*t*
- Smile arc, 160, 218  
 example of, 236*f*  
 flatter, 576*f*–577*f*



- Smile arc (*Continued*)  
 importance of, 219f  
 lower lip curvature and, 163f  
 SmileSonica Aevo device, 264, 264f  
 SN distance, approximation of, 184  
 SN line, horizontal planes (drawing), 181f  
 SNA/SNB  
 angles, usage of, 180f  
 contrast, 179  
 Social conditions, need/demand (perception), 15  
 Social development, 46–59  
 Social environment, change (effect), 63f  
 Social evaluation, 145–146  
 Social smile, 159  
 Soft tissues  
 facial, 36–37  
 growth, 30  
 laser, applications of, 223  
 limitation, 210  
 matrix, 37  
 paradigm, 4  
 angle paradigm, contrast of, 4t  
 pressures, diagrammatic representation of, 129f  
 stability and, 681  
 Space  
 anteroposterior planes of, 197f  
 evaluation of, 201–202  
 available, 385, 385f–386f  
 cast analysis, 172  
 different planes of, 429  
 excess, 409–411  
 graphic representation of, 80f  
 maintenance, 388–392, 392f  
 fixed retainers, usage, 591  
 management, 395–397, 396f–397f  
 relationships, 414–415  
 required, 385, 385f–386f  
 transverse planes of, 197f  
 evaluation of, 200–201  
 vertical clearance, 413  
 vertical planes of, 197f  
 evaluation of, 202  
 Space analysis, 172, 385–388  
 form, 387f  
 principles of, 385–386, 385f–386f  
 unerupted permanent teeth, 386–388, 386b, 388f  
 Space closure, 243, 353, 528–555  
 anchorage control in, 297–298  
 appearance of, 221f  
 for bimaxillary protrusion  
 with 18-slot edgewise, 533–534, 535f–536f  
 with 22-slot edgewise, 532–533, 534f  
 bracket advantage in, 291  
 edgewise appliance for, 559  
 extraction for, 414f  
 goal, 416–417  
 in incisor protrusion problems, 528–538  
 prosthetic replacement *versus*, 630–631  
 sliding *versus* loop mechanics in, 528–532, 529t  
 Space deficiency, severe, 425f  
 Space problems  
 adequate space, 394–395  
 generalized moderate crowding, 397, 397f  
 in other tooth displacements, 397–399, 398f–400f  
 quantification of, 385–388  
 space maintenance, 388–392, 392f  
 space management, 395–397, 396f–397f  
 space regaining, 392–394  
 treatment of, 388–399  
 Spaced maxillary incisors, space analysis in, 397–399  
 Space-related problems, 409–426  
 Speech, problems, 9–10  
 malocclusion, relationship of, 147  
 Spheno-ethmoidal synchondrosis, 33  
 Spheno-occipital synchondrosis, 33  
 Splints  
 maxillary removable, 443f  
 patient functions of, 698f  
 use of, 697–699  
 Split plate appliances, 311, 311f  
 Spring properties, of closing loop mechanics, 530–532  
 Spring retainers, 591–592  
 Springiness, improvement in, 286f  
 Springs  
 consideration for, 276  
 removable acrylic appliances with, 312  
 Stability  
 considerations for, 210  
 influences of, 681  
 Stabilization, use of, 697–699  
 Stabilizing archwires, 697  
 Stabilizing lingual arches, attachment of, 298f  
 Stainless steel alloys, 278  
 archwires, springiness and range, improvement in, 286f  
 bending nomograms of, 283f  
 gold replacement of, 291  
 relative strength, stiffness, and range for, 281f  
 torsion nomograms of, 284f  
 Stainless steel brackets, 330–331  
 Stationary anchorage, 266–267  
 Steel closing loop, characteristics of, 530  
 Steiner analysis, 179–181  
 problems with, 180–181  
 SNA/SNB angles, usage of, 180f  
 upper incisor, NA line (relationship), 180f  
 Stem cell transplantation, prevalence (increased), 404–406  
 Step bend, 301  
 impact of, 304t  
 intrusive force and, 304f  
 Straight calipers, usage of, 152f  
 Straight-wire bracket prescriptions, 324  
 Straight-wire concept, 334–336, 334f  
 Streaming potential, 251  
 Strength  
 stiffness and, combination of, 286  
 stress unit measurement of, 276  
 Stress relaxation, properties, improvement in, 287f  
 Stress-generated signals, importance of, 251  
 Stress-strain curve  
 resilience/formability in, defining, 277f  
 superelasticity in, demonstration of, 279f  
 Stress-strain diagram, 276  
 Submental procedures, 680  
 Submental tissues, contour of, 158f  
 Succedaneous permanent teeth, eruption, 77  
 Succedaneous teeth, eruption of, 70f  
 characterization of, 77  
 Sucking, habits and, 126–130  
 Sunday bite, 149  
 Superelastic A-NiTi wires  
 advanced, 503f  
 for alignment, 501–502  
 force-deflection curves for, 502f  
 objection in, 503  
 Superelastic materials, usage of, 279  
 Superelastic NiTi wires, 560  
 activation and deactivation for, 280f  
 Superelastic wires  
 as auxiliary spring, 504  
 problem with, 504f  
 springiness of, 503  
 Superelasticity, 278–279  
 example of, 279f  
 Superimpositions, 452f  
 three-dimensional cranial base, 451f  
 Supernumerary teeth, 118–120  
 ectopic eruption of, in preadolescent children, 381–383  
 location of, 121f  
 result from, 118–120  
 Supported beams, 282  
 illustration of, 277f  
 Supporting structures, aging changes in, 103–104  
 Supracrestal elastic fibers, surgery, 569–570  
 SureSmile technique, 343, 344f  
 Surface irregularities, interlocking of, 292  
 Surface remodeling, effects of, 88  
 Surgery  
 camouflage, 214–216  
 contrast, 657–664  
 decision for, 664  
 final surgical planning of, 697  
 indication for, malocclusion severity as, 657–661  
 orthodontic preparation of, 692–696  
 orthodontic treatment and, combination of, 692–704, 697t  
 patient management at, 697  
 special consideration in planning, 681–692  
 timing of, 681–691  
 Surgical mandibular advancement, 215f  
 Surgical techniques, contemporary, 667–681  
 Surgically assisted rapid palatal expansion (SARPE), 670  
 advantage of, 681  
 changes in the dental and skeletal dimensions and, 671f  
 implication of, 670  
 use of, 671f  
 Sustained force, periodontal ligament and bone response to, 250–264  
 Swallowing  
 occlusal force, comparison of, 127f  
 problems, 9–10  
 Symmetric bases, usage of, 170f  
 Symmetric bends, 301  
 Symmetric crowding, alignment in, 502  
 Symmetric V-bend, 301  
 placement of, 303f  
 Symmetry  
 cast analysis, 172  
 evaluation of, 200  
 Symphysis, distraction at, 675  
 Synchondroses, diagrammatic representation of, 34f  
 Synostosis syndromes, 113–114  
 Synthetic cephalometric radiograph, standard cephalometric radiograph (comparison), 189f  
 Systemic disease problems, 237  
 T  
 Tanaka and Johnston prediction values, in unerupted permanent teeth, 386–387, 386b  
 Tangential force, application of, 292  
 Teenagers, imaginary audience and, 59  
 Teeth  
 aging changes in, 103–104  
 alignment  
 with figure-of-eight wire ligature, 520f  
 patient concern about, 141  
 anchorage value of, 265  
 Angle's line, relationship of, 197f  
 appearance of  
 enhancement of, 219–221  
 improve, 629f  
 bone loss, 237f, 625f  
 cheek, vertical relationship of, 198f  
 color, 165–166  
 correction of, 221f  
 congenital absence, 116–118  
 contact points of, stripping, 612–614  
 contour, correction of, 221f  
 crowding and malalignment of, 7

Teeth (*Continued*)

- crown of, force to, application of, 255f
- decay, susceptibility, 9–10
- development, chronology of, 61t
- permanent dentition, 75t
- displacement of, into anterior crossbite, 509–510, 510f–511f
- display
  - improvement, gingiva (recontouring), 570
  - inadequacy, 217
- early alignment of, 295
- emergence of, 77
- eruption of
  - alveolar bone and, relationship of, 272–273
  - amount of, 73f
  - jaw rotation, interaction between, 95–96
  - periodontal ligament in, role of, 250
  - removal of, obstacles to, 512
- extraction of, 664
- extrusion of, 639f–641f
- follicle, 67
- forced eruption in, 609f
- forces and
  - application of, 248, 442
  - concentration of, 256f
  - magnitude/duration of, 126t
- full-time retention, requirement, 580
- greater exposure of, 104
- health of, 167–168
- heavy pressure against, physiologic response to, 250t
- height-width relationships of, 164–165
- impacted or unerupted, 512–517
- intrusion of, 256f, 647–654
- lips
  - relationships, 158–161
  - vertical relationship of, 198f
- malformation, 118–120
- missing, 630–631
- number, reduction of, 9f
- occlusion, patient concern about, 141
- oral structures, health and, 167–168
- overtreatment, 569
- position of
  - adjustment of, 556–562
  - alveolar bone height and, relationship of, 272–273
- positioner, use of, 565
- positioning of, anchorage (usage), 644
- pressure to, application of, 268
- proportions, 161–165
  - change in, 220–221
  - improvement, gingiva (recontouring), 570
- protruding, complaint of, 573f
- reshaping, 570–574
- respiration, impact, 132
- retraction of, 260
- roots, shortening of, 271
- “setting”, 564–567
  - laced elastics for, 565f
- shade, 165–166
- stabilization, periodontal ligament in, role of, 250
- structure of, problems related to loss of, 625–628, 629f
- supernumerary, 118–120
- sustained force in, 251–254
- sustained pressure against, physiologic response to, 253t
- tetracycline staining in, 29f
- tipped, uprighted, 603
- translation of, 256f
- traumatic displacement, 120, 406–409
- vertical displacement of, 407–408
- vertical position of
  - control of, 582f
  - description, roll (usage), 199f

Teeth (*Continued*)

- vertical tooth-lip relationships, 217–218
- visibility of, 60
- vitality, loss of, 269
- wear of, 74
- width relationships of, 163–164
  - frontal views of, 164f
  - without open apices, 408f
- Teeth movement
  - acceleration, 260–264
  - biologic control of, 250–251
  - clast cells in, attack of, 271f
  - control of rebound after, 569–570
  - corticotomy-assisted orthodontics in, outcomes of, 260
  - couples in, 289–291
  - direction of, 252f
  - efficiency of, 254
    - duration, contrast in, theoretical plot in, 256f
  - forces and, 289–291
    - relationship of, 265
  - inadvertent, recovery from, 672, 672f–673f
  - moments in, 289–291
  - subdivision of, impact of, 296
  - time course of, diagrammatic representation of, 255f
  - types of, 254
- Teeth size, 81f
  - analysis, 172–174
    - Bolton analysis, 173f
  - cast analysis, 172–174
  - decline in, 8f
  - discrepancies, 559, 559f
  - problems, 559
  - relationships, 172t
- Template analysis, 184–185
  - dentofacial structures, relationship of, 185
  - measurements, series of, 185
- Templates, 178
  - computer analysis, usage of, 185
  - superimposition of, 185
- Temporary anchorage devices, 345–349, 415
  - bone screws, 345–347, 345f
    - design factors for, 347b
    - ease of use of, 346f–347f, 347
    - linked screws in palatal anchorage, 347, 348f
    - versus miniplates, 350t
    - stability of, 345–347, 345f
  - miniplates, 348–349, 348f–350f
    - bone screws versus, 350t
    - failure rate, 349t
  - molar distalization and, 424f
  - TAD-supported molar-distalizing appliances, 422
- Temporary skeletal anchorage, orthognathic surgery for, 661–663
- Temporomandibular dysfunction (TMD), 9–10
  - orthodontic treatment for, 600, 616–619
  - symptoms of, 616f
    - cause of, 616
    - development of, 618–619
    - extent to, 618
  - treatment indications for, 618–619, 618f–619f
  - types of problems in, 616–618, 617f
- Temporomandibular joint (TMJ)
  - ankylosis, impact, 44
  - damage of, 115
  - formation of, 35
  - jaw function
    - relationship of, 148
    - screening exam for, 149b
  - problems, hard tissue aspects of, 191
- Teratogens, 107
  - affecting dentofacial development, 108t
- Testosterone production (increase), Sertoli cells (impact), 86

## Tetracycline staining, 29f

- Third molars
  - horizontal impaction, pressure, 102f
  - mesial drift of, 630
  - pressure from, 101–103
- Third National Health and Nutrition Estimates Survey III (NHANES III), 5
- IOTN grades on, 13
- Third-order bends, 325
  - compensations for, 334–336, 336f
- Thompson, D'Arcy
  - mathematical transformations grid, 27f
  - proportions/growth changes, similarities of, 27–28
- Thought processes, 56
- Threaded connector, stop on, 434f
- 3dMD camera, 26f
- Three-dimensional cranial base superimpositions, 451f
- Three-dimensional imaging, 24–26
- Three-dimensional superimpositions, 452f
- Throat form, evaluation of, 157
- “Through the bite” elastics, 607, 608f
  - horizontal and vertical forces, production, 608f
- Thumb-sucking
  - anterior open bite associated with, 129
  - in children, 129f
  - comparison of, 128f
  - negative pressure during, 129
  - prevalence of, 131f
- Time-out (omission), 49
- Timing, different, 429
- Tip bends, 324–325
- Tip-Edge appliance, 321
- Tipped molar
  - crown height, uprighting, 604f
  - extrusion of, 603–604
  - uprighting, 603f–604f
- Tipped teeth, uprighted, 603
- Tipping, 254, 296–297
  - extreme, 270f
  - lower molar, loss of, 603f
- Tissue-borne functional appliances, 313–314, 315f
- Tissues
  - interaction, 30
  - system, growth (Scammon's curves), 19f
- Titanium, as alternative to stainless steel, 331, 332f
- T-loop appliance, indication for, 605
- T-loop spring, in 17 x 25 steel wire, 607f
- TMA wires
  - bending nomograms of, 283f
  - relative strength, stiffness, and range for, 281f
  - torsion nomograms of, 284f
  - usage of, 281
- Tongue
  - forward resting posture of, 131
  - lip-cheek pressures, imbalances, 579
  - placement of, 65f
  - resting pressures from, 250f
  - thrusting, 130–131
    - swallow, appearance of, 130f
    - term, misnomer, 130
    - in transitional stage, 130
- Tonsillectomy, requirement of, 134
- Tooth agenesis, 116–118
- Tooth-colored or clear brackets, 331–332, 332f
- Torque, 560–562
  - effective, 562t
  - expression of, 562
  - factors, 562
  - forces, 530f
- Torque bends, 325
- Torquing arch, 557f
- Torquing auxiliary, Burststone torquing arch, 561, 561f
- Torquing auxiliary archwires, effects of, 561f

- Torquing force, 561  
 Torquing movements, limitation of, 267  
 Torsion nomograms, 284f  
 Torticollis, facial asymmetry in, 118f  
 Total arcial analysis, by Sassouni description, 181  
 Total body irradiation, prevalence (increased), 404–406  
 Total nasal obstruction  
   effect of, cephalometric superimposition, 133f  
   rarity of, 132  
 Traction, impact of, 408f  
 Transpalatal lingual arch, for expansion, 510  
 Transposition, 402–403, 403f–404f  
 Transverse growth, restriction of excessive, 438–440  
 Transverse mandibular constriction, treatment of, 438  
 Transverse maxillary deficiency, treatment of, 430–440  
 Trauma, susceptibility, 9–10  
 Traumatically extruded teeth, restoration of, 408  
 Traumatized teeth, multiple vertically positioned radiographs of, 407f  
 Treacher Collins syndrome (mandibulofacial dysostosis), example of, 110f  
 Treatment  
   changes, evaluation of, 193  
   complexity of, 209  
   motivation for, 54–55  
   outcomes, computer simulation, 663–664  
   possibilities, 209–223  
 Treatment planning  
   issues in, 208–209  
   patient input in, 208–209  
 True horizontal line, usage of, 179  
 True vertical line  
   of upper lip, backward incline to, 211f  
   usage of, 183  
 Turkey gobbler, correction of, 680  
 Tweed, Charles, 4  
 22-slot appliance, 522  
   in sliding space closure, 529f  
 22-slot bracket, effective torque, 562t  
 22-slot edgewise, space closure with, 532–533, 534f  
 Twin wire appliance, 322  
 Twin-Block appliance, 313, 313f, 462, 464f  
   results of, 472, 476f  
 2 x 4 appliance, in incisor intrusion, 523f  
 2 x 6 appliance, usage of, 305f  
 Two-couple archwires, impact of, 303–304  
 Two-couple configuration, utility arch in, 302f  
 Two-couple systems, 300–306  
   lingual arches, 306  
 Two-point contact, 288–291  
 Two-stage space closure, 297f  
 Two-step frictionless retraction, 535–537  
 Two-step space closure, 534f  
 Two-wall vertical pockets, esthetic problem in, 609
- U**  
 “Ugly duckling” stage, 81f  
 Ultrasound, therapeutic, 264, 264f  
 Unconditioned stimulus, conditioned stimulus, association of, 48  
 Uncontrolled diabetes, bone loss in, 237f  
 Undermining resorption, 254  
   frontal resorption *versus*, 255f  
 Undifferentiated mesenchymal cells, presence of, 46f  
 Unerrupted lower second molars, 514–517, 517f–519f  
 Unerrupted permanent maxillary left central incisor, dilacerated root and, 418f
- Unerrupted teeth, 353, 354f  
   alignment of, 512–517  
     mechanical approaches for, 512–514, 515f–516f  
     method of attachment in, 512, 513f–514f  
     surgical exposure in, 512  
 Unfavorable growth, control of, 569  
 Unilateral cleft lip, 113f  
   long-term treatment observation of, 242f–243f  
 Unilateral condylar fracture, appearance of, 493f–495f  
 Unilateral open bite, development of, 642f–643f  
 Unilateral repositioning, of teeth, 366, 368f  
 Unilateral space, closure, facilitate, 415  
 Unilateral toe-in bends, rotation of, 306f  
 Unstable mothering, 52  
 Upper arches  
   in Crozat appliances, 311f  
   maxillary removable splint, 443f  
   smile, transverse dimensions of, 160  
 Upper first premolars, class II camouflage in, 547–548, 549f–550f  
 Upper incisors  
   angulation of, improvement in, 234f–235f  
   appearance of, patient complaint of, 222f  
   lingual surface, lower incisal edges (contact), 6f  
   position of, 261f, 662f  
   protrusion, sucking habits, impact of, 130  
   retraction of, 211f  
 Upper lip  
   backward incline of, 211f  
   base of, soft tissue in, 440f  
 Upper molars  
   buccal tipping of, cross-elastics in, 511f  
   distal movement of, 543–547  
   extrusion, Class III elastics, 564f  
 Uprighting, 296–297  
   with auxiliary spring, 606f  
   springs, 557f  
 U.S. children, incisors (alignment), 5  
 U.S. population  
   incisor irregularity, 5, 6f  
   occlusion, normalcy (percentage), 107f  
   open bite and deep bite relationships in, 7f  
   orthodontic treatment, percentage of, 15f  
   overjet (Class II), 7f  
   percentage of, 15f  
   reverse overjet (Class III), 7f  
 U.S. Public Health Service (USPHS)  
   guidelines, for dental radiographic examination, 168t  
   surveys, 5  
 Utility arch  
   activation of, 302f  
   intrusion arch *versus*, 302f  
   usage of, 300–301
- V**  
 Vacuum-formed retainers (clear retainers), 585  
   limitations to, 585  
 V-bends  
   impact of, 304t  
   position of, 558  
 Velocity curve, 23f  
   menarche, times of, 23f  
 Vertebral ages, calculation of, 68f  
 Vertebral development, stage (usage), 145  
 Vertebral pathology, observation of, 176f  
 Vertical development  
   control of, response to functional appliance for, 490f  
   increased, 485f  
 Vertical deviations, overbite, 6–7
- Vertical discrepancy, with ankylosed primary second molars, 411f  
 Vertical elastics, 565f  
 Vertical facial growth, continuation of, 488  
 Vertical facial height, increases in, 432  
 Vertical facial proportions  
   in frontal/lateral views, 154f  
   reevaluation of, 157  
 Vertical forces  
   production of, 302  
   “through the bite” or cross-elastics, 608f  
 Vertical growth  
   continuation of, 583  
   expectation of, 226  
 Vertical incisor relationships, correction of, 562–564  
 Vertical maxillary deficiency, 440–449, 658f–660f  
 Vertical position  
   control of, 582f  
   description of, 199f  
 Vertical problems  
   anteroposterior problems combined with, 484–492  
   correction of, 691  
   cause of, 153  
   severity, cephalometric analysis for, 202f  
 Vertical tooth-lip relationships, 217–218  
 Vibration method, 263–264  
 Virtual articulators, 170, 170f  
 Virtual casts, physical casts *versus*, 168–170  
 Vital staining, 28–29  
   studies of, 28  
 Vital stains, studies using, 28  
 Voice control, punishment, 50
- W**  
 W-arch  
   lingual arches of, 431  
   for posterior crossbite, 365–366, 366f–367f  
 Wax bite, usage of, 168  
 Weight, increase (data), 27f  
 White spot lesions, 148f, 273  
 White youths, orthodontic need, 15f  
 Wide brackets, narrow brackets *versus*, 291  
 WildSmiles, shaped brackets, 341–342  
 Wire-bending robots, 343, 343f  
 Wires, surface qualities of, 292  
 Wits analysis, 181–182  
   conceived primarily, 182  
   Harvold analysis, contrast to, 182  
 Working bite  
   for functional appliances, 470, 471f  
   mandible brought forward in, 488  
   production of, 450  
 Wraparound (clip) retainers, 584, 586f  
 Wrinkles, decrease in, 215f  
 Wrist, radiograph (assessment), 66f
- X**  
 X-occlusion (buccal crossbite), 7
- Y**  
 Young adults  
   facial anthropometric measurements of, 151t  
   facial indices of, 151t  
   orthodontic care of, 55  
   teeth in, 167f
- Z**  
 Zygomatic arch  
   base of, 444  
   miniplate, 446f  
   shadow of, 177f



















