

PDF Compressor Free Version

Handbook of

LOCAL ANESTHESIA

SEVENTH EDITION

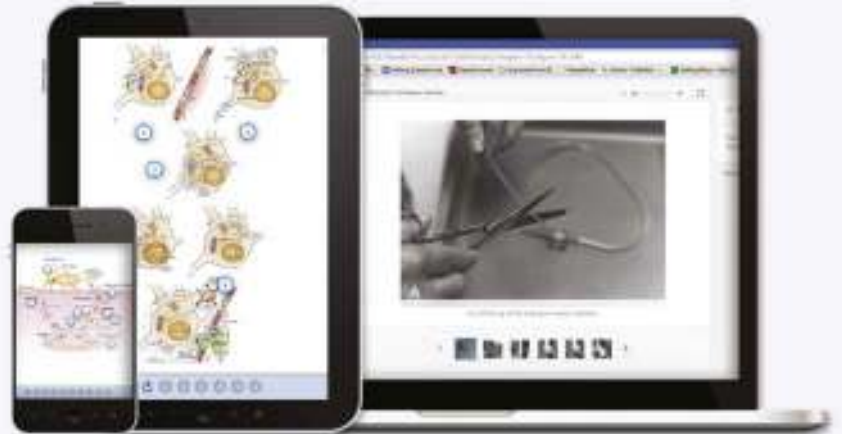STANLEY F. MALAMED

ELSEVIER

PDF Compressor Free Version

Any screen.
Any time.
Anywhere.

Activate the eBook version
of this title at no additional charge.



Expert Consult eBooks give you the power to browse and find content, view enhanced images, share notes and highlights—both online and offline.

Unlock your eBook today.

- 1 Visit expertconsult.inkling.com/redeem
- 2 Scratch off your code
- 3 Type code into “Enter Code” box
- 4 Click “Redeem”
- 5 Log in or Sign up
- 6 Go to “My Library”

It's that easy!

Scan this QR code to redeem your eBook through your mobile device:



Place Peel Off
Sticker Here

For technical assistance:
email expertconsult.help@elsevier.com
call 1-800-401-9962 (inside the US)
call +1-314-447-8200 (outside the US)

ELSEVIER

Use of the current edition of the electronic version of this book (eBook) is subject to the terms of the nontransferable, limited license granted on expertconsult.inkling.com. Access to the eBook is limited to the first individual who redeems the PIN, located on the inside cover of this book, at expertconsult.inkling.com and may not be transferred to another party by resale, lending, or other means.

PDF Compressor Free Version

Handbook of Local Anesthesia

This page intentionally left blank

PDF Compressor Free Version

PDF Compressor Free Version

Handbook of Local Anesthesia

SEVENTH EDITION

Stanley F. Malamed, DDS

Dentist Anesthesiologist
Emeritus Professor of Dentistry
Herman Ostrow School of Dentistry of USC
Los Angeles, California

For additional online content visit ExpertConsult.com



ELSEVIER

Edinburgh London New York Oxford Philadelphia St Louis Sydney 2020

No part of this publication may be reproduced, transmitted, stored, or by any means, electronic or mechanical, including photocopying, recording, or any information storage and retrieval system, without permission in writing from the publisher. Details on how to seek permission, further information about the Publisher's permissions policies and our arrangements with organizations such as the Copyright Clearance Center and the Copyright Licensing Agency, can be found at our website: www.elsevier.com/permissions.

This book and the individual contributions contained in it are protected under copyright by the Publisher (other than as may be noted herein).

Notice

Practitioners and researchers must always rely on their own experience and knowledge in evaluating and using any information, methods, compounds, or experiments described herein. Because of rapid advances in the medical sciences—in particular, independent verification of diagnoses and drug dosages—should be made. To the fullest extent of the law, no responsibility is assumed by Elsevier, authors, editors, or contributors for any injury and/or damage to persons or property as a matter of products liability, negligence or otherwise, or from any use or operation of any methods, products, instructions, or ideas contained in the material herein.

Library of Congress Control Number: 2019936243

Content Strategist: Alexandra Mortimer
Content Development Manager: Louise Cook
Content Development Specialist: Humayra Rahman Khan
Senior Content Development Manager: Ellen Wurm-Cutter
Publishing Services Manager: Deepthi Unni
Project Manager: Radjan Lourde Selvanadin
Designer: Ryan Cook

Printed in China

Last digit is the print number: 9 8 7 6 5 4 3 2 1



3251 Riverport Lane
St. Louis, Missouri 63043



Working together
to grow libraries in
developing countries

www.elsevier.com • www.bookaid.org

Contents

PDF Compressor Free Version

Preface, vii

Acknowledgments, ix

Dedication, xi

Contributors, xiii

New to This Edition, xv

Part I: Drugs

- 1 Neurophysiology, 2**
- 2 Pharmacology of Local Anesthetics, 27**
- 3 Pharmacology of Vasoconstrictors, 41**
- 4 Clinical Action of Specific Agents, 57**

Part II: The Armamentarium

- 5 The Syringe, 86**
- 6 The Needle, 99**
- 7 The Cartridge, 111**
- 8 Additional Armamentarium, 121**
- 9 Preparation of the Armamentarium, 125**

Part III: Techniques of Regional Anesthesia in Dentistry

- 10 Physical and Psychological Evaluation, 134**
- 11 Basic Injection Technique, 173**

12 Anatomic Considerations, 186

13 Techniques of Maxillary Anesthesia, 204

14 Techniques of Mandibular Anesthesia, 239

15 Supplemental Injection Techniques, 268

**16 Anesthetic Considerations in Dental
Specialties, 289**

Part IV: Complications, Legal Considerations, Questions, and the Future

- 17 Local Complications, 308**
- 18 Systemic Complications, 330**
- 19 Problems in Achieving Pain Control, 361**
- 20 Recent Advances in Local Anesthesia, 367**
- 21 Future Trends in Pain Control, 395**
- 22 Frequently Asked Questions, 403**
- 23 Legal Considerations, 412**

Index, 427

This page intentionally left blank

PDF Compressor Free Version

Preface

PDF Compressor Free Version

The seventh edition of *Handbook of Local Anesthesia!*

As happened with previous editions, it is truly difficult to comprehend how many years have passed since the first edition was published in 1978. It has been 5 years since the sixth edition, and in this time a significant number of changes, many of them advances, in the art and science of pain control in dentistry have occurred.

Although the drugs remain the same—articaine hydrochloride, bupivacaine hydrochloride, lidocaine hydrochloride, mepivacaine hydrochloride, and prilocaine hydrochloride—the years since the sixth edition have seen the introduction and refinement of drugs and devices that work to help the dental profession come ever closer to the twin goals of truly pain-free dentistry and truly pain-free local anesthetic injections.

As I have stated repeatedly in previous editions, “Local anesthetics are the safest and the most effective drugs available in all of medicine for the prevention and the management of pain.” To this statement I must add the proviso “when used properly.” “Indeed, there are no other drugs that truly prevent pain; no other drugs that actually prevent a propagated nociceptive nerve impulse from reaching the patient’s brain, where it would be interpreted as pain. Deposit a local anesthetic drug in close proximity to a sensory nerve and clinically adequate pain control will result in essentially all clinical situations.”

Find the nerve with a local anesthetic drug and pain control is virtually assured. Yet in certain clinical situations “finding the nerve” remains a recurring problem. This is especially so in the mandible, primarily permanent mandibular molars. Over my 45 years as a teacher of anesthesia in dentistry, I and my dentist anesthesiologist colleagues have worked at “fixing” this problem.

Have we succeeded? Not yet.

Are we getting close? Yes.

This seventh edition of *Handbook of Local Anesthesia* includes significant updates to many chapters and the addition of two new chapters: **Chapter 19** (Problems in

Achieving Pain Control) and **Chapter 20** (Recent Advances in Local Anesthesia).

Chapter 19 was added as a consequence of my many continuing dental education programs on local anesthesia. One of the most frequently asked questions has to do with the inability to consistently achieve effective pulpal anesthesia when one is treating teeth that are acutely pulpally involved. **Chapter 19** expands on the discussion begun in **Chapter 16** (Anesthetic Considerations in Dental Specialties).

In **Chapter 20** I have taken the prerogative of including a discussion of five relatively new additions to the pain control armamentarium in dentistry. As an educator, author, and lecturer in the area of local anesthesia since 1973, I have been approached by “inventors,” researchers, and drug and equipment manufacturers, all of whom have developed—in their words—“revolutionary technologies that will forever change the management of pain control in dentistry.” Previous editions of this textbook included discussions of many such “innovations.” Many, if not most, failed to meet their developer’s expectations and have disappeared or remain, at best, fringe techniques or devices. I have selected five innovations that I absolutely believe can be, have been, or should be included in the pain control armamentarium of most practicing dentists.

Feedback from readers of this textbook is always appreciated. Should errors be noted, or suggestions for improvement be made, contact me at malamed@usc.edu.

One final, but extremely important and exciting word: On the 11th of March 2019 the American Dental Association officially recognized anesthesiology as a specialty of dentistry in the United States. This culminated the almost 40 year struggle by Dentist Anesthesiologists to gain recognition from our parent organization - the ADA. Congratulations to all dentist anesthesiologists.

Stanley F. Malamed

March 2019

Los Angeles, California, United States

This page intentionally left blank

PDF Compressor Free Version

Acknowledgments

PDF Compressor Free Version

Thanks to the manufacturers of local anesthetic drugs and devices in North America, including Beutlich Pharmaceuticals, Dentsply, Kodak (Cook-Waite Laboratories), Midwest, Milestone Scientific, Novocol, Septodont Inc., and Sultan Safety LLC, for their assistance in supplying photographs and graphics for use in this edition.

I also wish to thank those wonderful people at Mosby (Elsevier), specifically Jennifer Flynn-Briggs, senior content strategist; Laurie Gower, director, content development; Humayra Rahman Khan, content development specialist; and Alexandra Mortimer, content strategist, who had the task of dealing with this author. Their perseverance—once again—has paid off with this seventh edition.

Finally, I wish to thank the many members of our profession, the dentists and dental hygienists, who have provided me with written and verbal input regarding prior editions of this textbook. Many of their suggestions for additions, deletions, and corrections have been incorporated into this new text. Thanks to you all!

Stanley F. Malamed

March 2019

Los Angeles, California, United States

This page intentionally left blank

PDF Compressor Free Version

PDF Compressor Free Version

*To Beverly, Heather, Jennifer, and Jeremy, and the next generation:
Matthew, Rachel, Gabriella, Ashley, Rebecca, Elijah, and Ethan*

This page intentionally left blank

PDF Compressor Free Version

Contributors

PDF Compressor Free Version

Mark N. Hochman, DDS

Private Practice Limited to Periodontics, Orthodontics, and
Implant Dentistry
Specialized Dentistry of New York
New York City, New York, United States
Clinical Associate Professor
Stony Brook School of Dental Medicine
Stony Brook, New York, United States
Clinical Consultant
Milestone Scientific Inc.

Timothy M. Orr, DMD, JD

Diplomate American Dental Board of Anesthesiology
Co-Principal, Sedadent Anesthesiology Group
Austin, Texas, United States

Daniel L. Orr II, BS, DDS, MS (Anesthesiology), PhD, JD, MD

Professor and Director
Anesthesiology and Oral & Maxillofacial Surgery
University of Nevada Las Vegas School of Dental Medicine
Las Vegas, Nevada, United States
Clinical Professor
Anesthesiology and Oral & Maxillofacial Surgery
University of Nevada School of Medicine
Las Vegas, Nevada, United States

PDF Compressor Free Version

New to This Edition

PDF Compressor Free Version

Two new chapters: [Chapter 19](#) (Problems in Achieving Pain Control) and [Chapter 20](#) (Recent Advances in Local Anesthesia)

Significant updating of [Chapter 16](#) (Anesthetic Considerations in Dental Specialties) and [Chapter 17](#) (Local Complications)

This page intentionally left blank

PDF Compressor Free Version

DRUGS

Neurophysiology

Desirable Properties of Local Anesthetics

Local anesthesia has been defined as loss of sensation in a circumscribed area of the body caused by depression of excitation in nerve endings or inhibition of the conduction process in peripheral nerves.¹ An important feature of local anesthesia is that it produces this loss of sensation without inducing loss of consciousness. In this one major area, local anesthesia differs dramatically from general anesthesia.

Many methods are used to induce local anesthesia:

1. mechanical trauma (compression of tissues)
2. low temperature
3. anoxia
4. chemical irritants
5. neurolytic agents such as alcohol and phenol
6. chemical agents such as local anesthetics

However, only those methods or substances that induce a transient and completely reversible state of anesthesia have application in clinical practice. The following are those properties deemed most desirable for a local anesthetic:

1. It should not be irritating to the tissue to which it is applied.
2. It should not cause any permanent alteration of nerve structure.
3. Its systemic toxicity should be low.
4. It must be effective regardless of whether it is injected into the tissue or is applied topically to mucous membranes.
5. The time of onset of anesthesia should be as short as possible.
6. The duration of action must be long enough to permit completion of the procedure yet not so long as to require an extended recovery.

Most local anesthetics discussed in this section meet the first two criteria: they are (relatively) nonirritating to tissues and their effects are completely reversible. Of paramount importance is systemic toxicity, because all injectable and most topical local anesthetics are eventually absorbed from their site of administration into the cardiovascular system. The potential toxicity of a drug is an important factor in its consideration for use as a local anesthetic. Toxicity differs greatly among the local anesthetics currently in use. Toxicity is discussed more thoroughly in [Chapter 2](#). Although it is a desirable characteristic, not all local anesthetics in clinical

use today meet the criterion of being effective, regardless of whether the drug is injected or applied topically. Several of the more potent injectable local anesthetics (e.g., procaine, mepivacaine) prove to be relatively ineffective when applied topically to mucous membranes. To be effective as topical anesthetics, these drugs must be applied in concentrations that prove to be locally irritating to tissues, while increasing the risk of systemic toxicity. Dyclonine, a potent topical anesthetic, is not administered by injection because of its tissue-irritating properties. Lidocaine and tetracaine, on the other hand, are effective anesthetics when administered by injection or topical application in clinically acceptable concentrations. The last factors—rapid onset of action and adequate duration of clinical action—are met satisfactorily by most of the clinically effective local anesthetics in use today. Clinical duration of action differs considerably among drugs and also among different preparations of the same drug, as well as by the type of injection administered (e.g., nerve block vs. supraperiosteal). The duration of anesthesia necessary to complete a procedure is a major consideration in the selection of a local anesthetic.

In addition to these qualities, Bennett² lists other desirable properties of an ideal local anesthetic:

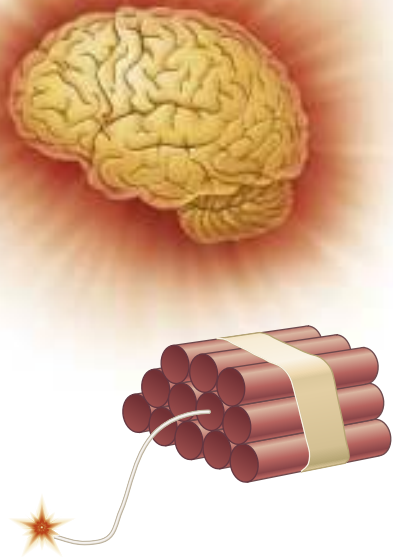
1. It should have potency sufficient to give complete anesthesia without the use of harmful concentrated solutions.
2. It should be relatively free from producing allergic reactions.
3. It should be stable in solution and should readily undergo biotransformation in the body.
4. It should be sterile or capable of being sterilized by heat without deterioration.

No local anesthetic in use today satisfies all these criteria; however, all anesthetics do meet most of them. Research continues in an effort to produce newer drugs that possess a maximum of desirable factors and a minimum of negative ones.

Fundamentals of Impulse Generation and Transmission

The discovery in the late 1800s of a group of chemicals with the ability to prevent pain without inducing loss of consciousness was a major step in the advancement of the

PDF Compressor Free Version



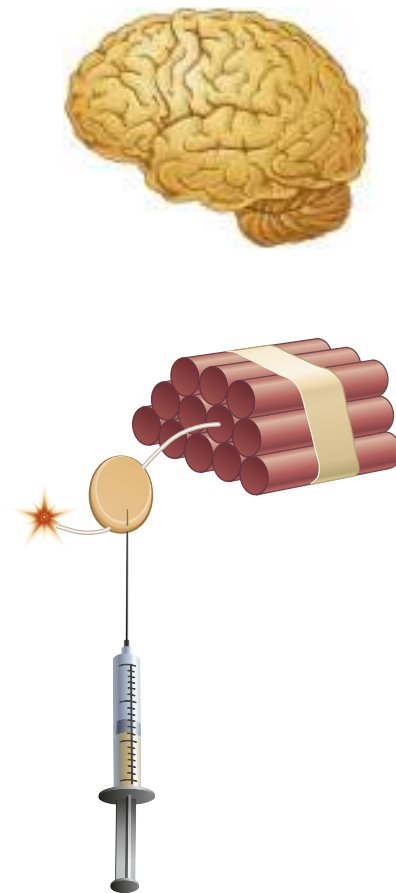
• **Fig. 1.1** The fuse is lit and the flame reaches the dynamite; an explosion occurs, and the patient experiences pain.

medical and dental professions. For the first time, medical and dental procedures could be performed easily and in the absence of pain in conscious patients, a fact that is taken for granted by contemporary medical and dental professionals and their patients.

The concept behind the actions of local anesthetics is simple: they prevent both the generation and the conduction of a nerve impulse. In effect, local anesthetics set up a chemical roadblock between the source of the impulse (e.g., the scalpel incision in soft tissues) and the brain. The aborted impulse, prevented from reaching the brain, cannot be interpreted by the patient as pain.

This is similar to the effect of lighting the fuse on a stick of dynamite. The fuse represents the “nerve,” whereas the stick of dynamite is the “brain.” If the fuse is lit and the flame reaches the dynamite, an explosion occurs (Fig. 1.1). When a nerve is stimulated, an impulse is propagated that will be interpreted as pain when it reaches the brain. If the fuse is lit, but “water” (e.g., local anesthetic) is placed somewhere between the end of the fuse and the dynamite stick, the fuse will burn up to the point of water application and then the burning will die out. The dynamite does not explode. When a local anesthetic is placed at some point between the pain stimulus (e.g., the drill) and the brain, a nerve impulse is still propagated, traveling up to the point of local anesthetic application and then “dies,” never reaching the brain, and pain does not occur (Fig. 1.2).

How, in fact, do local anesthetics, the most used drugs in dentistry, function to abolish or prevent pain? A discussion of current theories seeking to explain the mode of action of



• **Fig. 1.2** Local anesthetic is placed at some point between the pain stimulus and the brain (dynamite). The nerve impulse travels up to the point of local anesthetic application and then “dies,” never reaching the brain, and pain does not occur.

local anesthetic drugs follows. To understand their action better, however, the reader must be acquainted with the fundamentals of nerve conduction. A review of the relevant characteristics and properties of nerve anatomy and physiology follows.

The Neuron

The neuron, or nerve cell, is the structural unit of the nervous system. It is able to transmit messages between the central nervous system (CNS) and all parts of the body. There are two basic types of neuron: sensory (afferent) and motor (efferent). The basic structure of these two neuronal types differs significantly (Fig. 1.3A–B).

Sensory neurons capable of transmitting the sensation of pain consist of three major portions.³ The *peripheral process* (also known as the *dendritic zone*), composed of an arborization of free nerve endings, is the most distal segment of the sensory neuron. These free nerve endings respond to stimulation produced in the tissues in which they lie, provoking an impulse that is transmitted centrally along the axon. The *axon* is a thin cable-like structure that may be quite long (the giant squid axon has been measured at 100 to 200 cm). At its mesial (or

central) end is an arborization similar to that seen in the peripheral process. However, in this case the arborization forms synapses with CNS neurons. The *cell body* distribute incoming (sensory) impulses to their appropriate sites within the CNS for interpretation. The *cell body* is the third part of the neuron. In the sensory neuron described here, the cell body is located at a distance from the axon, the main pathway of impulse transmission in this nerve. The cell body of the sensory nerve therefore is not involved in the process of impulse transmission, its primary function being to provide vital metabolic support for the entire neuron (Fig. 1.3B).

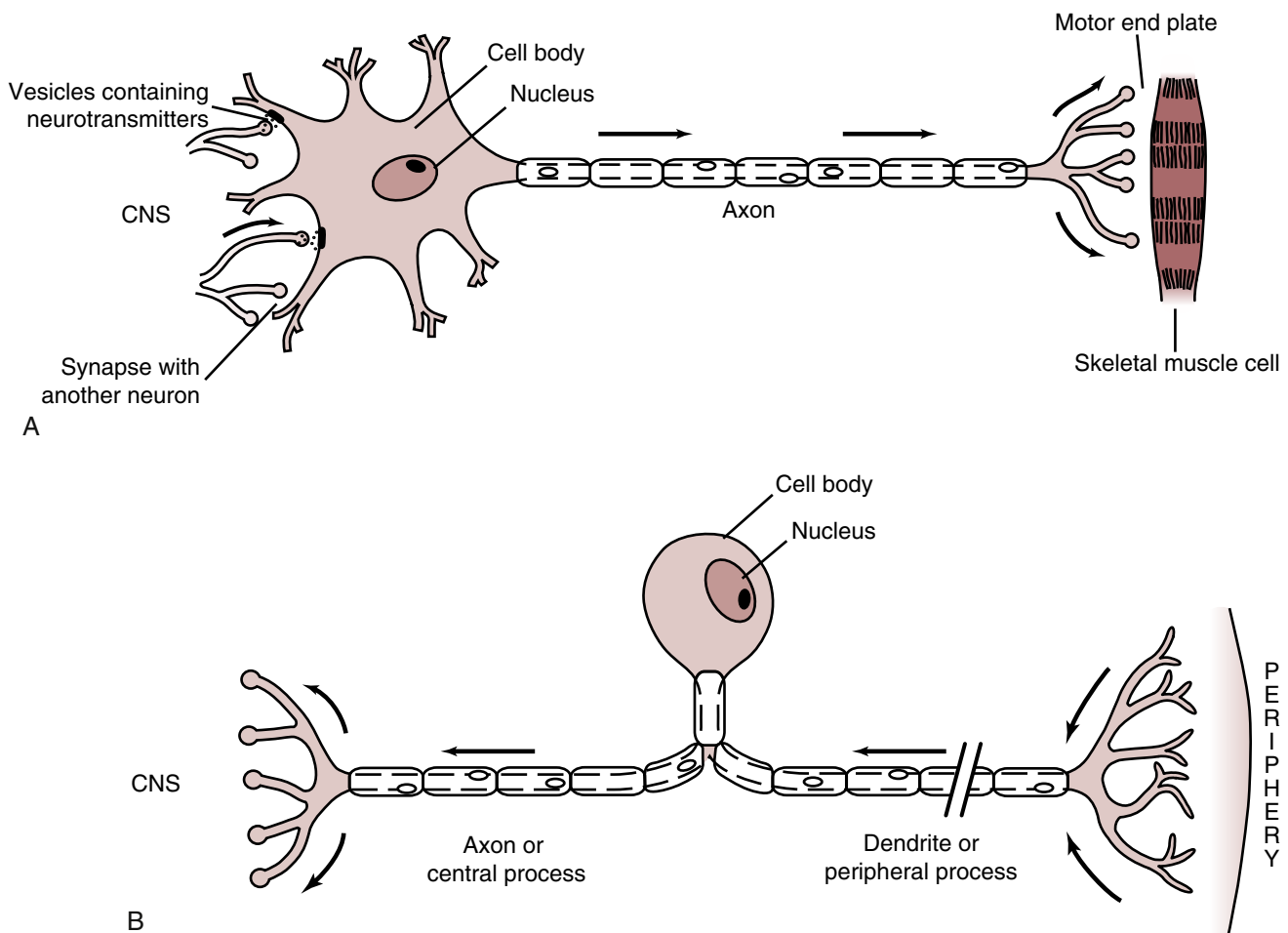
Nerve cells that conduct impulses from the CNS toward the periphery are termed *motor neurons* and are structurally different from the sensory neurons just described in that their cell body is interposed between the axon and dendrites. In motor neurons the cell body not only is an integral component of the impulse transmission system but also provides metabolic support for the cell. Near its termination, the axon branches, with each branch ending as a bulbous axon terminal (or bouton). Axon terminals synapse with muscle cells (Fig. 1.3A).

The Axon

The single nerve fiber, the axon, is a long cylinder of neural cytoplasm (axoplasm) encased in a thin sheath, the nerve membrane, or axolemma. Neurons have a cell body and a nucleus, as do all other cells; however, neurons differ from other cells in that they have an axonal process from which the cell body may be at a considerable distance. The axoplasm, a gelatinous substance, is separated from extracellular fluids by a continuous nerve membrane. In some nerves, this membrane is itself covered by an insulating lipid-rich layer of myelin.

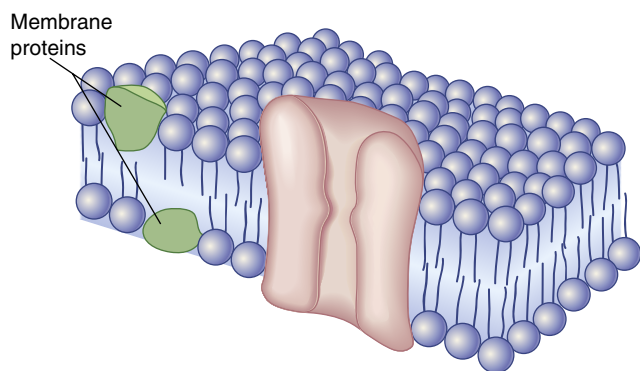
Both sensory nerve excitability and conduction are attributable to changes that develop within the nerve membrane. The cell body and the axoplasm are not essential for nerve conduction. They are important however, for the metabolic support of the nerve membrane is probably derived from the axoplasm.

The nerve (cell) membrane itself is approximately 70 to 80 Å thick. (An angstrom is 1/10,000 of a micrometer.) Fig. 1.4 presents a currently acceptable configuration. All biological membranes are organized to block



• **Fig. 1.3** A, Multipolar motor neuron. B, Unipolar sensory neuron. (From Liebgott B: *Anatomical basis of dentistry*, ed 2, St Louis, 2001, Mosby.)

the diffusion of water-soluble molecules, to be selectively permeable to certain molecules via specialized pores or channels, and to transmit information via active protein receptors responsive to chemical or physical stimulation by neurotransmitters or hormones (chemical) or light, vibration, or pressure (physical).⁴ The membrane is described as a flexible nonstretchable structure consisting of two layers of lipid molecules (bilipid layer of phospholipids) and associated proteins, lipids, and carbohydrates. The lipids are oriented with their hydrophilic (polar) ends facing the outer surface and their hydrophobic (nonpolar) ends projecting to the middle of the membrane. Proteins are visualized as the primary



• **Fig. 1.4** Configuration of a nerve membrane. Basic membrane lipoprotein framework that separates axoplasm from extraneural fluid. Hydrophilic polar ends face outward; hydrophobic lipid tails face inward, forming an almost impenetrable barrier. This bimolecular lattice provides a rigid platform for integral protein macromolecules whose voltage-driven configurational state changes cause transmembrane ion channels (bulbous central structure) to open and close. (Redrawn from de Jong RH: *Local anesthetics*, St Louis, 1994, Mosby.)

organizational elements of membranes, and are classified as transport proteins (channels, carriers, or pumps) and receptor sites. Channel proteins are thought to be continuous pores through the membrane, allowing some ions (Na^+ , K^+ , Ca^{2+}) to flow passively, whereas other channels are gated, permitting ion flow only when the gate is open.⁴ The nerve membrane lies at the interface between extracellular fluid and axoplasm. It separates highly diverse ionic concentrations within the axon from those outside. The resting nerve membrane has an electrical resistance about 50 times greater than that of the intracellular and extracellular fluids, thus preventing the passage of sodium, potassium, and chloride ions down their concentration gradients.⁵ However, when a nerve impulse passes, electrical conductivity of the nerve membrane increases approximately 100-fold. This increase in conductivity permits the passage of sodium and potassium ions along their concentration gradients through the nerve membrane. It is the movement of these ions that provides an immediate source of energy for impulse conduction along the nerve.

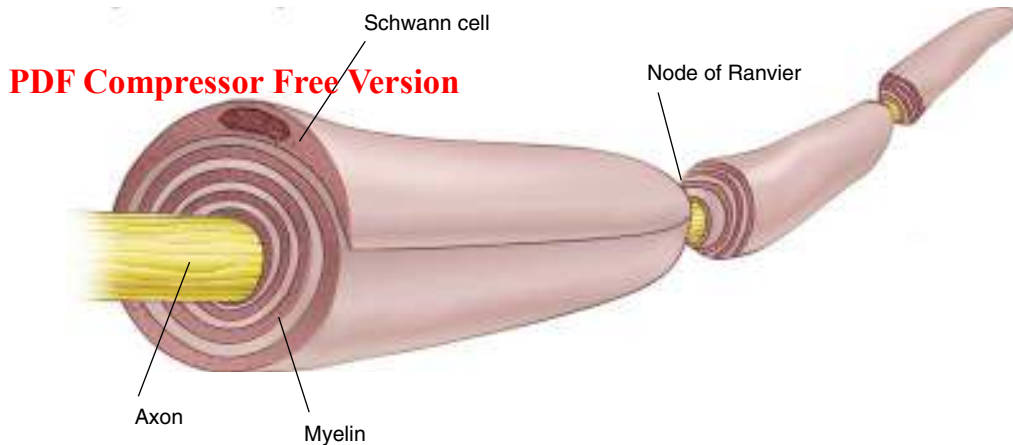
Some nerve fibers are covered by an insulating lipid layer of myelin. In vertebrates, myelinated nerve fibers include all but the smallest of axons (Table 1.1).⁶ Myelinated nerve fibers (Fig. 1.5) are enclosed in spirally wrapped layers of lipoprotein myelin sheaths, which are actually a specialized form of Schwann cell. Although primarily lipid (75%), the myelin sheath also contains some protein (20%) and carbohydrate (5%).⁷ Each myelinated nerve fiber is enclosed in its own myelin sheath. The outermost layer of myelin consists of the Schwann cell cytoplasm and its nucleus. Constrictions are located at regular intervals (approximately every 0.5 to 3 mm) along the myelinated nerve fiber. These nodes

TABLE 1.1

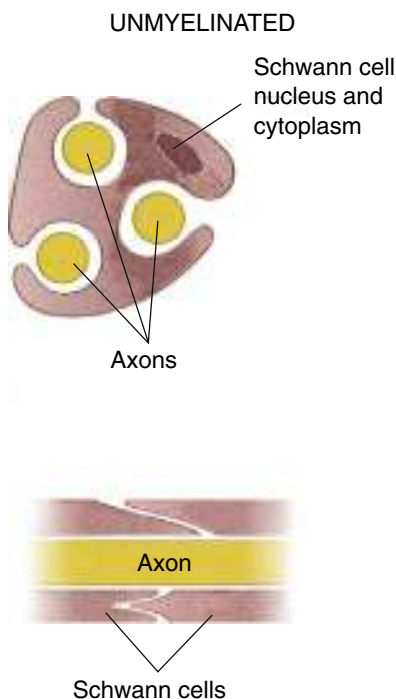
Classification of Peripheral Nerves According to Fiber Size and Physiologic Properties

Fiber Class	Subclass	Myelin	Diameter (μm)	Conduction Velocity (m/s)	Location	Function
A	Alpha	+	6–22	30–120	Afferent to and efferent from muscles and joints	Motor, proprioception
	Beta	+	6–22	30–120	Afferent to and efferent from muscles and joints	Motor, proprioception
	Gamma	+	3–6	15–35	Efferent to muscle spindles	Muscle tone
	Delta	+	1–4	5–25	Afferent sensory nerves	Pain, temperature, touch
B		+	<3	3–15	Preganglionic sympathetic	Various autonomic functions
C	sympatheticC	–	0.3–1.3	0.7–1.3	Postganglionic sympathetic	Various autonomic functions
	dorsal root gammaC	–	0.4–1.2	0.1–2.0	Afferent sensory nerves	Various autonomic functions; pain, temperature, touch

From Berde CB, Strichartz GR: *Local anesthetics*. In Miller RD, editor: *Anesthesia*, ed 5, Philadelphia, 2000, Churchill Livingstone, pp 491–521.



• **Fig. 1.5** Structure of a myelinated nerve fiber. (Redrawn from de Jong RH: *Local anesthetics*, St Louis, 1994, Mosby.)



• **Fig. 1.6** Types of Schwann cell sheaths. (Redrawn from Wildsmith JAW: *Peripheral nerve and anaesthetic drugs*, *Br J Anaesth* 58:692–700, 1986.)

of Ranvier form a gap between two adjoining Schwann cells and their myelin spirals.⁸ At these nodes the nerve membrane is exposed directly to the extracellular medium.

Unmyelinated nerve fibers (Fig. 1.6) are also surrounded by a Schwann cell sheath. Groups of unmyelinated nerve fibers share the same sheath.

The insulating properties of the myelin sheath enable a myelinated nerve to conduct impulses at a much faster rate than an unmyelinated nerve of equal size.

Physiology of the Peripheral Nerves

The function of a nerve is to carry messages from one part of the body to another. These messages, in the form of electrical

action potentials, are called *impulses*. Action potentials are transient depolarizations of the membrane that result from a brief increase in the permeability of the membrane to sodium, and usually also from a delayed increase in its permeability to potassium.⁹ Impulses are initiated by chemical, thermal, mechanical, or electrical stimuli.

Once an impulse has been initiated by a stimulus in any particular nerve fiber, the amplitude and shape of that impulse remain constant, regardless of changes in the quality of the stimulus or in its strength. The impulse remains constant without losing strength as it passes along the nerve because the energy used for its propagation is derived from energy that is released by the nerve fiber along its length and not solely from the initial stimulus. De Jong¹⁰ has described impulse conduction as being like the active progress of a spark along a fuse of gunpowder. Once lit, the fuse burns steadily along its length, with one burning segment providing the energy necessary to ignite its neighbor. Such is the situation with impulse propagation along a nerve.

Electrophysiology of Nerve Conduction

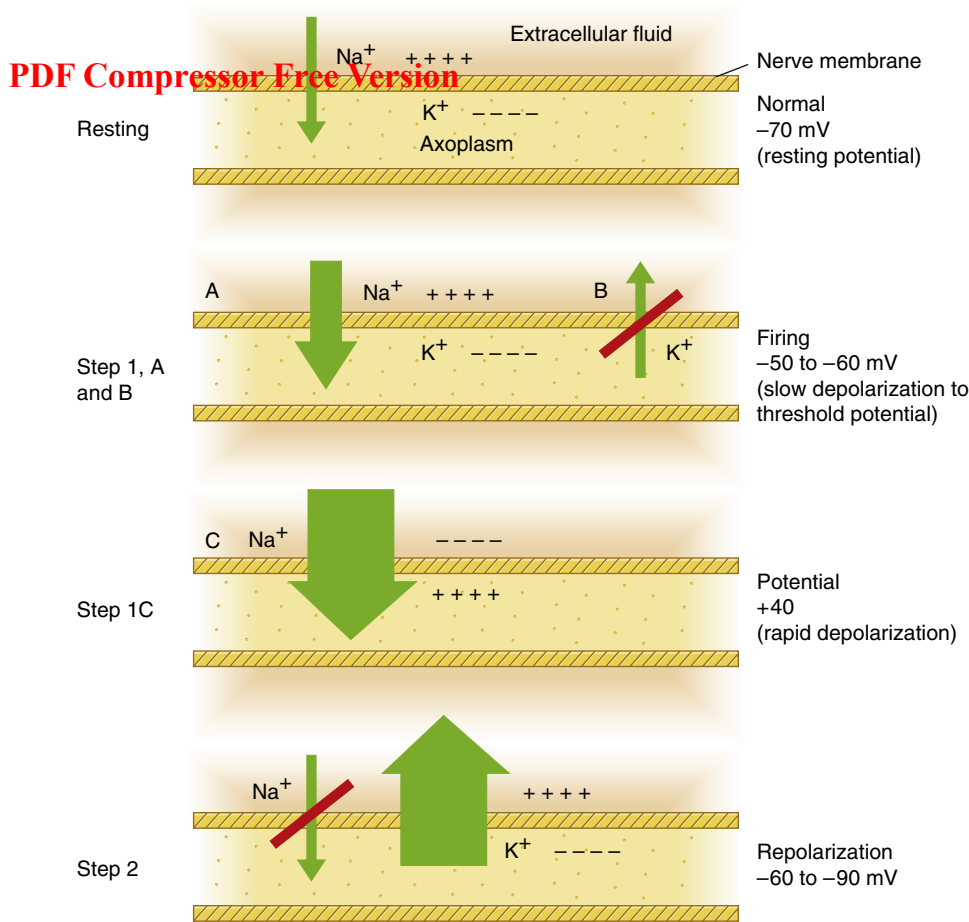
A description of electrical events that occur within a nerve during the conduction of an impulse follows. Subsequent sections describe the precise mechanisms for each of these steps.

A nerve possesses a resting potential (Fig. 1.7, step 1). This is a negative electrical potential of -70 mV that exists across the nerve membrane, produced by differing concentrations of ions on either side of the membrane (Table 1.2). The interior of the nerve is negative relative to the exterior.

Step 1

A stimulus excites the nerve, leading to the following sequence of events:

1. An initial phase of slow depolarization. The electrical potential within the nerve becomes slightly less negative (see Fig. 1.7, step 1A).
2. When the falling electrical potential reaches a critical level, an extremely rapid phase of depolarization results. This is termed *threshold potential*, or *firing threshold* (see Fig. 1.7, step 1B).



• **Fig. 1.7** Resting potential, slow depolarization to threshold (step 1, A and B), rapid depolarization (step 1C), repolarization (step 2).

3. This phase of rapid depolarization results in a reversal of the electrical potential across the nerve membrane (see Fig. 1.7, step 1C). The interior of the nerve is now electrically positive in relation to the exterior. An electrical potential of $+40$ mV exists inside the nerve cell.¹¹

Step 2

After these steps of depolarization, repolarization occurs (Fig. 1.7, step 2). The electrical potential gradually becomes more negative inside the nerve cell relative to outside until the original resting potential of -70 mV is again achieved.

The entire process (steps 1 and 2) requires 1 millisecond: depolarization (step 1) takes 0.3 milliseconds; repolarization (step 2) takes 0.7 milliseconds.

Electrochemistry of Nerve Conduction

The preceding sequence of events depends on two important factors: the concentrations of electrolytes in the axoplasm (interior of the nerve cell) and extracellular fluids, and the permeability of the nerve membrane to sodium and potassium ions.

TABLE 1.2 Intracellular and Extracellular Ionic Concentrations

Ion	Intracellular (mEq/L)	Extracellular (mEq/L)	Ratio (Approximate)
Potassium (K^+)	110–170	3–5	27:1
Sodium (Na^+)	5–10	140	1:14
Chloride (Cl^-)	5–10	110	1:11

Table 1.2 shows the differing concentrations of ions found within neurons and in the extracellular fluids. Significant differences exist for ions between their intracellular and extracellular concentrations. These ionic gradients differ because the nerve membrane exhibits selective permeability.

Resting State

In its resting state, the nerve membrane is

- slightly permeable to sodium ions (Na^+)
- freely permeable to potassium ions (K^+)
- freely permeable to chloride ions (Cl^-)

Potassium remains within the axoplasm, despite its ability to diffuse freely through the nerve membrane and its concentration gradient (passive diffusion usually occurs from a region of greater concentration to one of lesser concentration), because the negative charge of the nerve membrane restrains the positively charged ions by electrostatic attraction.

Chloride remains outside the nerve membrane instead of moving along its concentration gradient into the nerve cell, because the opposing, nearly equal, electrostatic influence (electrostatic gradient from inside to outside) forces outward migration. The net result is no diffusion of chloride through the membrane.

Sodium migrates inwardly because both the concentration (greater outside) and the electrostatic gradient (positive ion attracted by negative intracellular potential) favor such migration. Only the fact that the resting nerve membrane is relatively impermeable to sodium prevents a massive influx of this ion.

Membrane Excitation

Depolarization

Excitation of a nerve segment leads to an increase in permeability of the cell membrane to sodium ions. This is accomplished by a transient widening of transmembrane ion channels sufficient to permit the unhindered passage of hydrated sodium ions. The rapid influx of sodium ions to the interior of the nerve cell causes depolarization of the nerve membrane from its resting level to its firing threshold of approximately -50 to -60 mV (see Fig. 1.7, steps 1A and 1B).¹² In reality, the firing threshold is the magnitude of the decrease in negative transmembrane potential that is necessary to initiate an action potential (impulse).

A decrease in negative transmembrane potential of 15 mV (e.g., from -70 to -55 mV) is necessary to reach the firing threshold; a voltage difference of less than 15 mV will not initiate an impulse. In a normal nerve the firing threshold remains constant. Exposure of the nerve to a local anesthetic raises its firing threshold. Elevating the firing threshold means that more sodium must pass through the membrane to decrease the negative transmembrane potential to a level where depolarization occurs.

When the firing threshold is reached, membrane permeability to sodium increases dramatically and sodium ions rapidly enter the axoplasm. At the end of depolarization (the peak of the action potential), the electrical potential of the nerve is actually reversed; an electrical potential of $+40$ mV exists (see Fig. 1.7, step 1C). The entire depolarization process requires approximately 0.3 milliseconds.

Repolarization

The action potential is terminated when the membrane repolarizes. This is caused by the extinction (*inactivation*) of increased permeability to sodium. In many cells, permeability to potassium also increases, resulting in the efflux of K^+ , and leading to more rapid membrane repolarization and return to its resting potential (see Fig. 1.7, step 2).

Movement of sodium ions into the cell during depolarization and subsequent movement of potassium ions out of the cell during repolarization are passive (not requiring the expenditure of energy), because each ion moves along its concentration gradient (higher to lower). After the return of the membrane potential to its original level (-70 mV), a slight excess of sodium exists within the nerve cell, along with a slight excess of potassium extracellularly. A period of metabolic activity then begins in which active transfer of sodium ions out of the cell occurs via the sodium pump. An expenditure of energy is necessary to move sodium ions out of the nerve cell against their concentration gradient; this energy comes from the oxidative metabolism of adenosine triphosphate. The same pumping mechanism is thought to be responsible for the active transport of potassium ions into the cell against their concentration gradient. The process of repolarization requires 0.7 milliseconds.

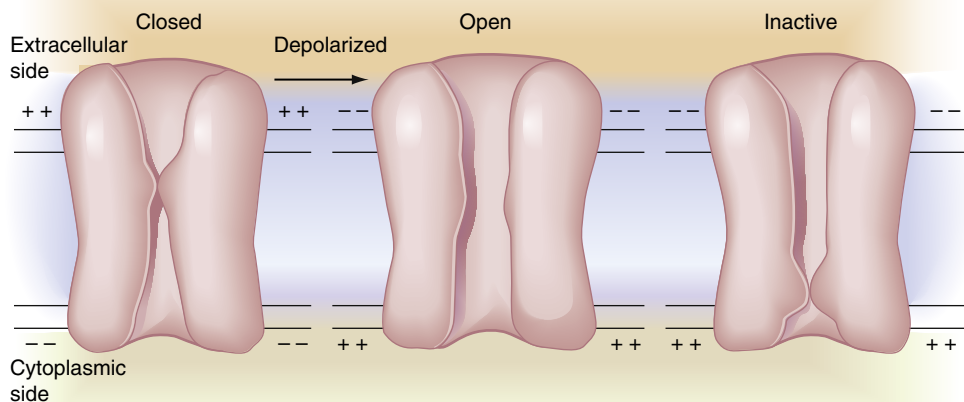
Immediately after a stimulus has initiated an action potential, a nerve is unable, for a time, to respond to another stimulus regardless of its strength. This is termed the *absolute refractory period*, and it lasts for about the duration of the main part of the action potential. The absolute refractory period is followed by a *relative refractory period*, during which a new impulse can be initiated but only by a stronger-than-normal stimulus. The relative refractory period continues to decrease until the normal level of excitability returns, at which point the nerve is said to be *repolarized*.

During depolarization a major proportion of ionic sodium channels are found in their open (O) state (thus permitting the rapid influx of Na^+). This is followed by a slower decline into a state of inactivation (I) of the channels to a nonconducting state. Inactivation temporarily converts the channels to a state from which they cannot open in response to depolarization (absolute refractory period). This inactivated state is slowly converted back, so most channels are found in their closed (C) resting form when the membrane has repolarized (-70 mV). On depolarization, the channels change configuration, first to an open ion-conducting (O) state and then to an inactive nonconducting (I) state. Although both C and I states correspond to nonconducting channels, they differ in that depolarization can recruit channels to the conducting O state from the C state but not from the I state. Fig. 1.8 describes the sodium channel transition stages.¹³

Membrane Channels

Discrete aqueous pores through the excitable nerve membrane, called *sodium* (or *ion*) *channels*, are molecular structures that mediate its permeability to sodium. A channel appears to be a lipoglycoprotein firmly situated

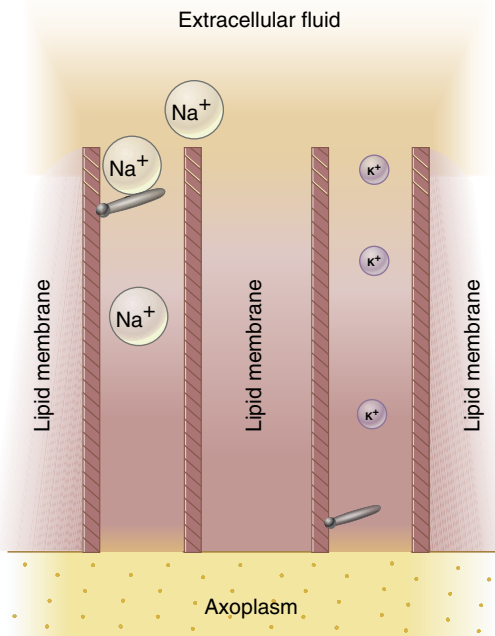
PDF Compressor Free Version



• **Fig. 1.8** Sodium channel transition stages. Depolarization reverses resting membrane potential from interior negative (left) to interior positive (center). The channel proteins undergo corresponding conformational changes from the resting state (closed) to the ion-conducting stage (open). State changes continue from open (center) to inactive (right), where the channel configuration assumes a different, but still impermeable, state. With repolarization, the inactivated refractory channel reverts to the initial resting configuration (left), ready for the next sequence. (Redrawn from Siegelbaum SA, Koester F: Ion channels. In Kandel ER, editor: *Principles of neural science*, ed 3, Norwalk, 1991, Appleton-Lange.)

in the membrane (see Fig. 1.4). It consists of an aqueous pore spanning the membrane that is narrow enough at least at one point to discriminate between sodium ions and other ions; Na^+ passes through 12 times more easily than K^+ . The channel also includes a portion that changes its configuration in response to changes in membrane potential, thereby “gating” the passage of ions through the pore (C, O, and I states are described). The presence of these channels helps explain membrane permeability or impermeability to certain ions. Sodium channels have an internal diameter of approximately 0.3 to 0.5 nm.¹⁴

The diameter of a sodium ion is less than that of a potassium or chloride ion and therefore a sodium ion should diffuse freely down its concentration gradient through membrane channels into the nerve cell. However, this does not occur, because all these ions attract water molecules and thus become hydrated. Hydrated sodium ions have a radius of 3.4 Å, which is approximately 50% greater than the 2.2-Å radius of potassium and chloride ions. Sodium ions therefore are too large to pass through narrow channels when a nerve is at rest (Fig. 1.9). Potassium and chloride ions can pass through these channels. During depolarization, sodium ions readily pass through the nerve membrane because configurational changes that develop within the membrane produce transient widening of these transmembrane channels to a size adequate to allow the unhindered passage of sodium ions down their concentration gradient into the axoplasm (transformation from the C to the O configuration). This concept can be visualized as the opening of a gate during depolarization

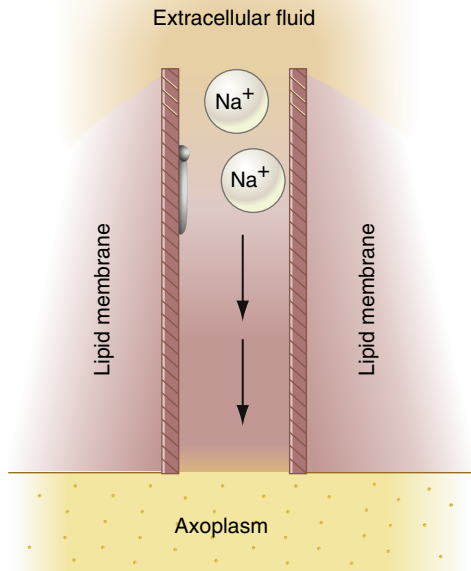


• **Fig. 1.9** Membrane channels are partially occluded; the nerve is at rest. Hydrated sodium ions (Na^+) are too large to pass through channels, although potassium ions (K^+) can pass through unimpeded.

that is partially occluding the channel in the resting membrane (C) (Fig. 1.10).

Evidence indicates that channel specificity exists in that sodium channels differ from potassium channels.¹⁵ The gates on the sodium channel are located near the external surface of the nerve membrane, whereas those on the

PDF Compressor Free Version



• **Fig. 1.10** Membrane channels are open; depolarization occurs. Hydrated sodium ions (Na^+) now pass unimpeded through the sodium channel.

potassium channel are located near the internal surface of the nerve membrane.

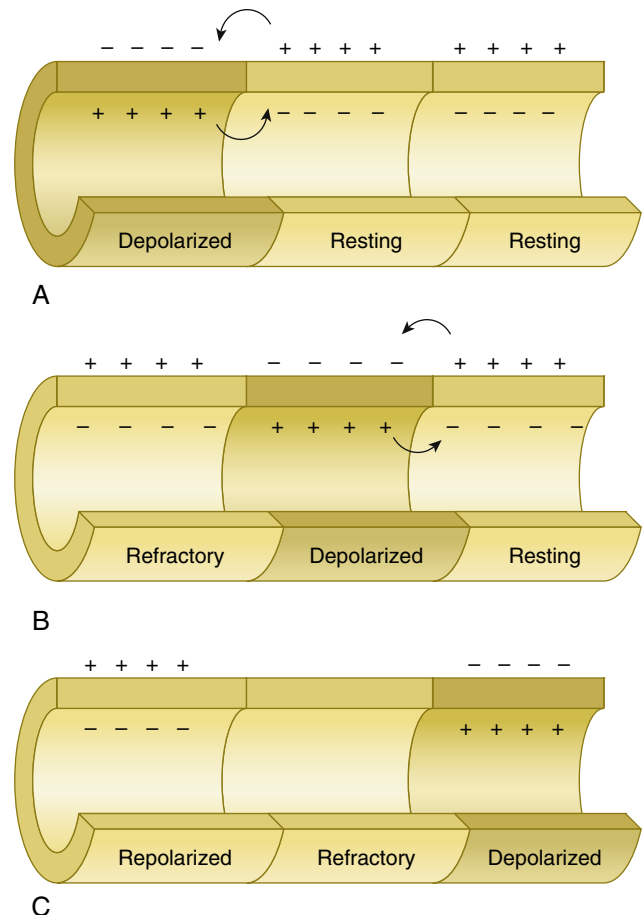
Impulse Propagation

After initiation of an action potential by a stimulus, the impulse must move along the surface of the axon. Energy for impulse propagation is derived from the nerve membrane in the following manner.

The stimulus disrupts the resting equilibrium of the nerve membrane; the transmembrane potential is reversed momentarily, with the interior of the cell changing from negative to positive, and the exterior changing from positive to negative. This new electrical equilibrium in this segment of nerve produces local currents that begin to flow between the depolarized segment and the adjacent resting area. These local currents flow from positive to negative, extending for several millimeters along the nerve membrane.

As a result of this current flow, the interior of the adjacent area becomes less negative and its exterior becomes less positive. The transmembrane potential decreases, approaching the firing threshold for depolarization. When the transmembrane potential is decreased by 15 mV from the resting potential, a firing threshold is reached and rapid depolarization occurs. The newly depolarized segment sets up local currents in adjacent resting membrane, and the entire process starts anew.

Conditions in the segment that has just depolarized return to normal after the absolute and relative refractory periods. Because of this, the wave of depolarization can spread in only one direction. Backward (retrograde)



• **Fig. 1.11** Propagation. (A) Current flows between active (depolarized) and resting (polarized) membrane patches because depolarization reverses the membrane potential. (B) The previously resting membrane segment is now depolarized, setting up new current flows between it and the next membrane patch. The previously depolarized nerve segment (A) is on the road back to repolarization, leaving it refractory. The impulse can move forward only, as retrograde propagation is prevented by inexcitable (refractory) membrane. (C) The wave of depolarization has advanced by another segment, always trailed by a refractory membrane patch. The leftmost membrane segment, refractory in (A), has repolarized meanwhile and is once again ready to conduct a fresh impulse. (Redrawn from deJong RH: *Local anesthetics*, St Louis, 1994, Mosby.)

movement is prevented by the unexcitable, refractory segment (Fig. 1.11A–C).

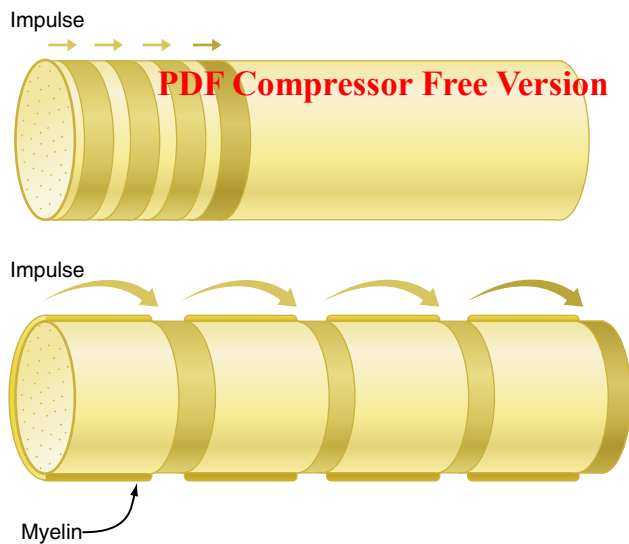
Impulse Spread

The propagated impulse travels along the nerve membrane toward the CNS. The spread of this impulse differs depending on whether a nerve is myelinated or not.

Unmyelinated Nerves

An unmyelinated nerve fiber is basically a long cylinder with a high-electrical-resistance cell membrane surrounding a low-resistance conducting core of axoplasm, all of which is bathed in low-resistance extracellular fluid.

The high-resistance cell membrane and low-resistance intracellular and extracellular media produce a rapid decrease in the density of current within a short distance of



• **Fig. 1.12** Saltatory propagation. Comparison of impulse propagation in nonmyelinated (upper) and myelinated (lower) axons. In nonmyelinated axons, the impulse moves forward by sequential depolarization of short adjoining membrane segments. Depolarization in myelinated axons, on the other hand, is discontinuous; the impulse leaps forward from node to node. Note how much farther ahead the impulse is in the myelinated axon after four depolarization sequences. (Redrawn from de Jong RH: *Local anesthetics*, St Louis, 1994, Mosby.)

the depolarized segment. In areas immediately adjacent to this depolarized segment, local current flow may be adequate to initiate depolarization in the resting membrane. Farther away it will be inadequate to achieve a firing threshold.

The spread of an impulse in an unmyelinated nerve fiber therefore is characterized as a relatively slow forward-creeping process (Fig. 1.12). The conduction rate in unmyelinated C fibers is 1.2 m/s compared with 14.8 to 120 m/s in myelinated A α and A δ fibers.¹⁶

Myelinated Nerves

Impulse spread within myelinated nerves differs from that in unmyelinated nerves because of the layer of insulating material separating the intracellular and extracellular charges. The farther apart are the charges, the smaller is the current necessary to charge the membrane. Local currents thus can travel much farther in a myelinated nerve than in an unmyelinated nerve before becoming incapable of depolarizing the nerve membrane ahead of it.

Impulse conduction in myelinated nerves occurs by means of current leaps from node (node of Ranvier) to node, a process termed *saltatory conduction* (see Fig. 1.12) (*saltare* is the Latin verb “to leap”). This form of impulse conduction is much faster and more energy efficient than that used in unmyelinated nerves. The thickness of the myelin sheath increases with increasing diameter of the axon. In addition, the distance between adjacent nodes of Ranvier increases with greater axonal diameter. Because of these two factors, saltatory conduction is more rapid in a thicker axon.

Saltatory conduction usually progresses from one node to the next in a stepwise manner. However, it can be demonstrated that the current flow at the next node still exceeds

that necessary to reach the firing threshold of the nodal membrane. If conduction of an impulse is blocked at one node, the local current skips over that node and is adequate to raise the membrane potential at the next node to its firing potential, producing depolarization. A minimum of perhaps 8 to 10 mm of nerve must be covered by anesthetic solution to ensure thorough blockade.¹⁷

Mode and Site of Action of Local Anesthetics

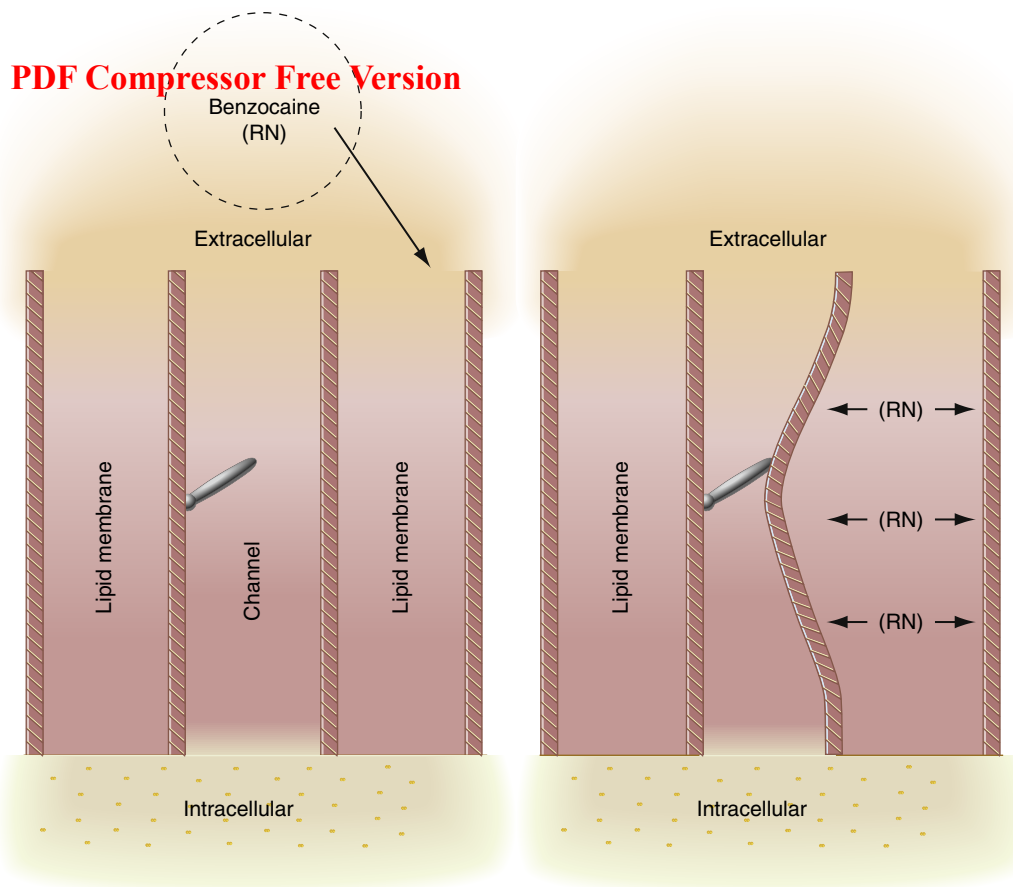
How and where local anesthetics alter the processes of impulse generation and transmission needs to be discussed. It is possible for local anesthetics to interfere with the excitation process in a nerve membrane in one or more of the following ways:

1. altering the basic resting potential of the nerve membrane
2. altering the threshold potential (firing level)
3. decreasing the rate of depolarization
4. prolonging the rate of repolarization

It has been established that the primary effects of local anesthetics occur during the depolarization phase of the action potential.¹⁸ These effects include a decrease in the rate of depolarization, particularly in the phase of slow depolarization. Because of this, cellular depolarization is not sufficient to reduce the membrane potential of a nerve fiber to its firing level, and a propagated action potential does not develop. There is no accompanying change in the rate of repolarization.

Where Do Local Anesthetics Work?

The nerve membrane is the site at which local anesthetics exert their pharmacologic actions. Many theories have been proposed over the years to explain the mechanism of action of local anesthetics, including the acetylcholine, calcium displacement, and surface charge theories. The *acetylcholine theory* states that acetylcholine is involved in nerve conduction, in addition to its role as a neurotransmitter at nerve synapses.¹⁹ No evidence exists indicating that acetylcholine is involved in neural transmission along the body of the neuron. The *calcium displacement theory*, once popular, maintains that local anesthetic nerve block is produced by the displacement of calcium from some membrane site that controls permeability to sodium.²⁰ Evidence that varying the concentration of calcium ions bathing a nerve does not affect local anesthetic potency has diminished the credibility of this theory. The *surface charge (repulsion) theory* proposes that local anesthetics act by binding to the nerve membrane and changing the electrical potential at the membrane surface.²¹ Cationic (RNH⁺) (p. 15) drug molecules are aligned at the membrane-water interface, and because some of the local anesthetic molecules carry a net positive charge, they make the electrical potential at the membrane surface more positive, thus decreasing the excitability of the nerve by



• Fig. 1.13 Membrane expansion theory.

increasing the threshold potential. Current evidence indicates that the resting potential of the nerve membrane is unaltered by local anesthetics (they do not become hyperpolarized), and that conventional local anesthetics act *within* membrane channels rather than at the membrane surface. Also, the surface charge theory cannot explain the activity of uncharged anesthetic molecules in blocking nerve impulses (e.g., benzocaine).

Two other theories, membrane expansion and specific receptor theories, are given credence today. Of the two, the specific receptor theory is more widely held.

The *membrane expansion theory* states that local anesthetic molecules diffuse to hydrophobic regions of excitable membranes, producing a general disturbance of the bulk membrane structure, expanding some critical region(s) in the membrane, and preventing an increase in permeability to sodium ions.^{22,23} Local anesthetics that are highly lipid soluble can easily penetrate the lipid portion of the cell membrane, producing a change in configuration of the lipoprotein matrix of the nerve membrane. This results in a decreased diameter of sodium channels, which leads to inhibition of both sodium conductance and neural excitation (Fig. 1.13). The membrane expansion theory serves as a possible explanation for the local anesthetic activity of a drug such as benzocaine, which does not exist in cationic form yet still exhibits potent topical anesthetic activity. It

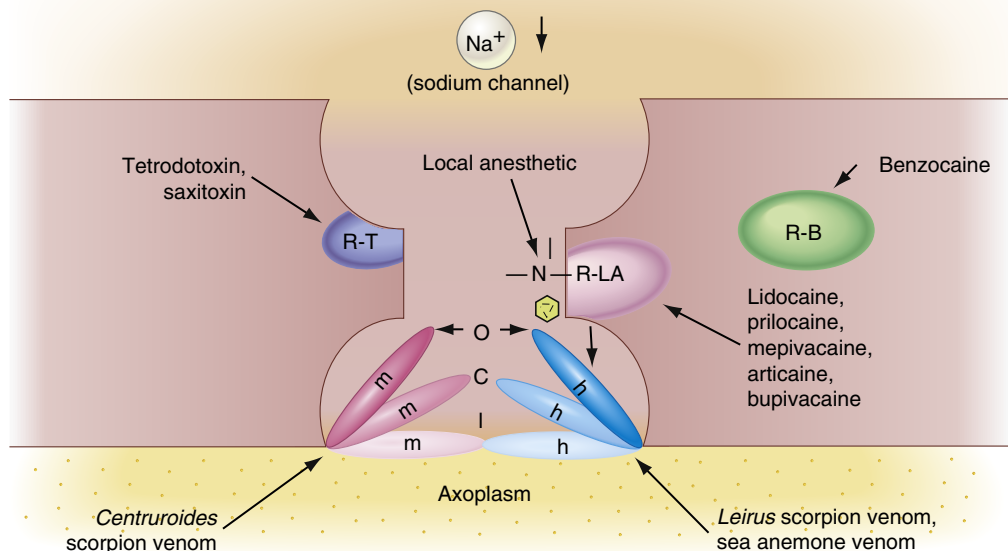
has been demonstrated that nerve membranes do expand and become more fluid when exposed to local anesthetics. However, no direct evidence suggests that nerve conduction is entirely blocked by membrane expansion per se.

The *specific receptor theory*, the most favored today, proposes that local anesthetics act by binding to specific receptors on the sodium channel (Fig. 1.14).^{24, 25} The action of the drug is direct, not mediated by some change in the general properties of the cell membrane. Both biochemical and electrophysiologic studies have indicated that a specific receptor site for local anesthetics exists in the sodium channel either on its external surface or on the internal axoplasmic surface.^{26, 27} Once the local anesthetic has gained access to the receptors, permeability to sodium ions is decreased or eliminated, and nerve conduction is interrupted.

Local anesthetics are classified by their ability to react with specific receptor sites in the sodium channel. It appears that drugs can alter nerve conduction in at least four sites within the sodium channel (see Fig. 1.14):

1. within the sodium channel (tertiary amine local anesthetics, e.g., lidocaine, articaine, mepivacaine, prilocaine, bupivacaine)
2. at the outer surface of the sodium channel (tetrodotoxin, saxitoxin)
3. at the activation gate (scorpion venom)
4. at the inactivation gate (scorpion venom)

PDF Compressor Free Version



• **Fig. 1.14** Tertiary amine local anesthetics inhibit the influx of sodium during nerve conduction by binding to a receptor within the sodium channel (R-LA). This blocks the normal activation mechanism (O gate configuration, depolarization) and also promotes movement of the activation and inactivation gates (m and h) to a position resembling that in the inactivated state (I). Biotoxins (R-T) block the influx of sodium at an outer surface receptor; various venoms do it by altering the activity of the activation and inactivation gates; and benzocaine (R-B) does it by expanding the membrane. C, Channel in the closed configuration. (Redrawn from Pallasch TJ: *Dent Drug Serv Newsl* 4:25, 1983.)

Table 1.3 provides a biological classification of local anesthetics based on their site of action and the active form of the compound. Drugs in class C exist only in the uncharged form (RN), whereas class D drugs exist in both the charged form and the uncharged form. Approximately 90% of the blocking effects of class D drugs are caused by the cationic form of the drug; only 10% of blocking action is produced by the base (Fig. 1.15).

Myelinated Nerve Fibers

One additional factor should be considered with regard to the site of action of local anesthetics in myelinated nerves. The myelin sheath insulates the axon both electrically and pharmacologically. The only site at which molecules of a local anesthetic have access to the nerve membrane is at the nodes of Ranvier, where sodium channels are found in abundance. Ionic changes that develop during impulse conduction arise only at the nodes.

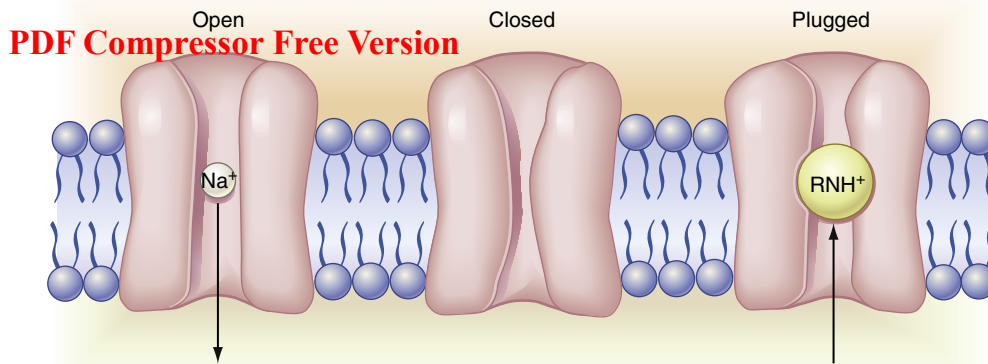
Because an impulse may skip over or bypass one or two blocked nodes and continue on its way, it is necessary for at least two or three nodes immediately adjacent to the anesthetic solution to be blocked to ensure effective anesthesia—a length of approximately 8 to 10 mm.

Sodium channel densities differ in myelinated and unmyelinated nerves. In small unmyelinated nerves, the density of sodium channels is about 35/ μm , whereas at the

TABLE 1.3 Classification of Local Anesthetic Substances According to Biological Site and Mode of Action

Class	Definition	Chemical Substance
A	Agents acting at receptor site on external surface of nerve membrane	Biotoxins (e.g., tetrodotoxin, saxitoxin)
B	Agents acting at receptor site on internal surface of nerve membrane	Quaternary ammonium analogues of lidocaine Scorpion venom
C	Agents acting by a receptor-independent physicochemical mechanism	Benzocaine
D	Agents acting by combination of receptor and receptor-independent mechanisms	Most clinically useful local anesthetic agents (e.g., articaine, bupivacaine, lidocaine, mepivacaine, prilocaine)

Modified from Covino BG, Vassallo HG: *Local anesthetics: mechanisms of action and clinical use*, New York, 1976, Grune & Stratton.



• **Fig. 1.15** Channel entry. On the left is an open channel, inward permeant to sodium ion. The center channel is in the resting closed configuration; although impermeant to sodium ion here, the channel remains voltage responsive. The channel on the right, although in open configuration, is impermeant because it has local anesthetic cation bound to the gating receptor site. Note that local anesthetic enters the channel from the axoplasmic (lower) side; the channel filter precludes direct entry via the external mouth. Local anesthetic renders the membrane impermeant to sodium ion, and hence inexcitable by local action currents. (Redrawn from de Jong RH: *Local anesthetics*, St Louis, 1994, Mosby.)

nodes of Ranvier in myelinated fibers, it may be as high as 20,000/ μm . On an average nerve length basis, relatively few sodium channels are present in unmyelinated nerve membranes. For example, in the garfish olfactory nerve, the ratio of sodium channels to phospholipid molecules is 1:60,000, corresponding to a mean distance between channels of 0.2 μm , whereas at densely packed nodes of Ranvier, the channels are separated by only 70 Å.^{28,29}

How Local Anesthetics Work to Block Nerve Conduction

The primary action of local anesthetics in producing a conduction block is to decrease the permeability of ion channels to sodium ions (Na^+). Local anesthetics selectively inhibit the peak permeability to sodium, whose value is normally about five to six times greater than the minimum necessary for impulse conduction (e.g., there is a safety factor for conduction of five to six times).³⁰ Local anesthetics reduce this safety factor, decreasing both the rate of rise of the action potential and its conduction velocity. When the safety factor falls below unity,¹⁰ conduction fails and nerve block occurs.

Local anesthetics produce a very slight, virtually insignificant, decrease in potassium (K^+) conductance through the nerve membrane.

Calcium ions (Ca^{2+}), which exist in bound form within the cell membrane, are thought to exert a regulatory effect on the movement of sodium ions across the nerve membrane. Release of bound calcium ions from the ion channel receptor site may be the primary factor responsible for increased permeability of the nerve membrane to sodium. This represents the first step in nerve membrane depolarization. Local anesthetic molecules may act through competitive antagonism with calcium for some site on the nerve membrane.

The following sequence is a proposed mechanism of action of local anesthetics¹:

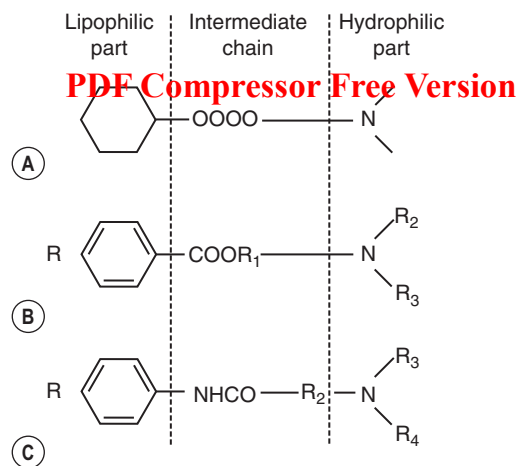
1. displacement of calcium ions from the sodium channel receptor site, which permits ...
2. binding of the local anesthetic molecule to this receptor site, which produces ...
3. blockade of the sodium channel and a ...
4. decrease in sodium conductance, which leads to ...
5. depression of the rate of electrical depolarization and ...
6. failure to achieve the threshold potential level, along with ...
7. lack of development of propagated action potentials, which is called ...
8. *conduction blockade*

The mechanism whereby sodium ions gain entry to the axoplasm of the nerve, thereby initiating an action potential, is altered by local anesthetics. The nerve membrane remains in a polarized state because the ionic movements responsible for the action potential fail to develop. Because the membrane's electrical potential remains unchanged, local currents do not develop, and the self-perpetuating mechanism of impulse propagation is stalled. An impulse that arrives at a blocked nerve segment is stopped because it is unable to release the energy necessary for its continued propagation. Nerve block produced by local anesthetics is called a *nondepolarizing nerve block*.

Active Forms of Local Anesthetics

Local Anesthetic Molecules

Most injectable local anesthetics are tertiary amines. Only a few (e.g., prilocaine, hexylcaine) are secondary amines. The typical local anesthetic structure is shown in Figs. 1.16 and 1.17. The lipophilic part is the largest portion



• Fig. 1.16 (A) Typical local anesthetic. (B) Amino ester. (C) Amino amide.

of the molecule. Aromatic in structure, it is derived from benzoic acid, aniline, or thiophene (articaine). All local anesthetics are amphipathic; that is, they possess both lipophilic and hydrophilic characteristics, generally at opposite ends of the molecule. The hydrophilic part is an amino derivative of ethyl alcohol or acetic acid. Local anesthetics without a hydrophilic part are not suited for injection but are good topical anesthetics (e.g., benzocaine). The anesthetic structure is completed by an intermediate hydrocarbon chain containing an ester or an amide linkage. Other chemicals, especially histamine blockers and anticholinergics, share this basic structure with local anesthetics and commonly exhibit weak local anesthetic properties.

Local anesthetics may be classified as amino esters or amino amides according to their chemical linkages. The nature of the linkage is important in defining several properties of the local anesthetic, including the basic mode of biotransformation. Ester-linked local anesthetics (e.g., procaine) are readily hydrolyzed in aqueous solution. Amide-linked local anesthetics (e.g., lidocaine) are relatively resistant to hydrolysis. A greater percentage of an amide-linked drug than of an ester-linked drug is excreted unchanged in the urine. Procainamide, which is procaine with an amide linkage replacing the ester linkage, is as potent a local anesthetic as procaine, yet because of its amide linkage, it is hydrolyzed much more slowly. Procaine is hydrolyzed in plasma in only a few minutes, but just approximately 10% of procainamide is hydrolyzed in 1 day.³¹

As prepared in the laboratory, local anesthetics are basic compounds that are poorly soluble in water and unstable on exposure to air.³² Their pK_a values range from 7.5 to 10. In this form, they have little or no clinical value. However, because they are weakly basic, they combine readily with acids to form local anesthetic salts, in which form they are quite soluble in water and comparatively stable. Local anesthetics used for injection are dispensed as acid salts, most commonly the hydrochloride salt (e.g., lidocaine hydrochloride, articaine hydrochloride), dissolved in sterile water or saline.

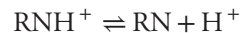
It is well known that the pH of a local anesthetic solution (as well as the pH of the tissue into which it is injected) greatly influences its nerve-blocking action. Acidification of tissue decreases local anesthetic effectiveness. Inadequate anesthesia frequently occurs when local anesthetics are injected into inflamed or infected areas. The inflammatory process produces acidic products: the pH of normal tissue is 7.4; the pH of an inflamed area is 5 to 6. Local anesthetics containing epinephrine or other vasopressors are acidified by the manufacturer to inhibit oxidation of the vasopressor (p. 18). The pH of local anesthetic solutions without epinephrine is about 6.5; epinephrine-containing solutions have a pH in the range of about 3.5 to 4.4. Clinically, this lower, more acidic, pH is more likely to produce a “burning” sensation on injection, a slightly slower onset of anesthesia, and more postinjection soreness at the site of drug administration.

Elevating the pH (alkalinization) of a local anesthetic solution speeds its onset of action, increases its clinical effectiveness, and makes its injection more comfortable.^{33,34} However, the local anesthetic base, because it is unstable, precipitates out of alkalinized solutions, making these preparations ill-suited for clinical use. Buffered (e.g., alkalinized) local anesthetics have received much attention in recent years in both medicine and dentistry.^{35,36} Sodium bicarbonate or, less commonly, carbon dioxide (CO_2) added to the anesthetic solution immediately before injection provides greater comfort and more rapid onset of anesthesia (see Chapter 20).^{37,38} The use of buffered local anesthetics in dentistry is detailed in Chapter 21.

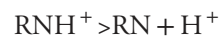
Despite the potentially wide variation in the pH of extracellular fluids, the pH in the interior of a nerve remains stable. Normal functioning of a nerve therefore is affected very little by changes in the extracellular environment. However, the ability of a local anesthetic to block nerve impulses is profoundly altered by changes in extracellular pH.

Dissociation of Local Anesthetics

As discussed, local anesthetics are available as acid salts (usually hydrochloride) for clinical use. The acid salt of the local anesthetic, both water soluble and stable, is dissolved in sterile water or saline. In this solution, it exists simultaneously as uncharged molecules (RN), also called the *base*, and as positively charged molecules (RNH^+), called the *cation*. As the pH of the solution is acidic, hydrogen ions (H^+) are also present.



The relative proportion of each ionic form in the solution varies with the pH of the solution or surrounding tissues. In the presence of a high concentration of hydrogen ions (low pH), the equilibrium shifts to the left, and most of the local anesthetic solution exists in cationic form:

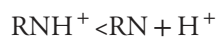

Aromatic residue	Intermediate chain	Amino terminus	Aromatic residue	Intermediate chain	Amino terminus
ESTERS			AMIDES		
	COOCH ₂ CH ₂			NHCOCH ₂	
Procaine			Lidocaine		
	COOCH ₂ CH ₂			NHCOCH	
Propoxycaine			Etidocaine		
	COOCH ₂ CH ₂			NHCOCH	
Tetracaine			Mepivacaine		
	COOCHCH ₂ CH			NHCOCH	
Cocaine			Bupivacaine		
	COOCH ₂ CH ₃			NHCOCH	
Benzocaine			Prilocaine		
	COCH ₂ CH ₂			NHCOCH	
Dyclonine*			Articaine		

*Dyclonine is a ketone.

• **Fig. 1.17** Chemical configuration of local anesthetics. (From Yagiela JA, Neidle EA, Dowd FJ: *Pharmacology and therapeutics for dentistry*, ed 6, St Louis, 2010, Mosby.)

As hydrogen ion concentration decreases (higher pH), the equilibrium shifts toward the free base form:



The relative proportion of ionic forms also depends on the pK_a , or dissociation constant, of the specific local anesthetic. The pK_a is a measure of the affinity of a molecule for hydrogen ions (H^+). When the pH of the solution has the same value as the pK_a of the local anesthetic, exactly 50%

$$\text{pH} = \text{p}K_a + \log \frac{[\text{conjugate base}]}{[\text{acid}]}$$

• **Fig. 1.18** Henderson-Hasselbalch equation.

of the drug exists in the RNH^+ form and 50% in the RN form. The percentage of the drug existing in either form can be determined from the Henderson-Hasselbalch equation (Fig. 1.18).

TABLE
1.4**Dissociation Constants (pK_a) of Local Anesthetics**

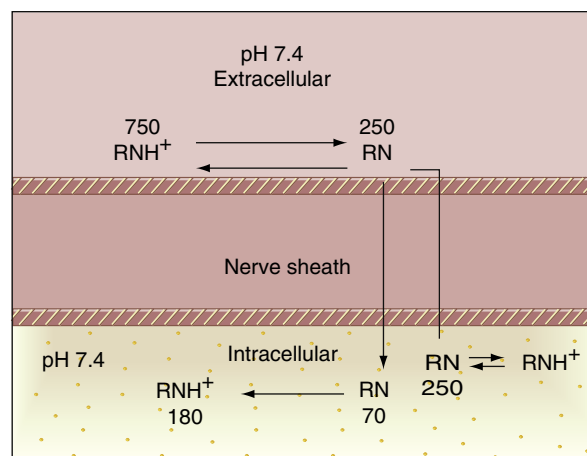
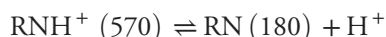
Agent	pK_a	Percentage of Base (RN) at pH 7.4	Approximate Onset of Action (min)
Benzocaine	3.5	100	—
Mepivacaine	7.7	33	2-4
Lidocaine	7.7	29	2-4
Prilocaine	7.7	25	2-4
Articaine	7.8	29	2-4
Etidocaine	7.9	25	2-4
Ropivacaine	8.1	17	2-4
Bupivacaine	8.1	17	5-8
Tetracaine	8.6	7	10-15
Cocaine	8.6	7	—
Chlorprocaine	8.7	6	6-12
Propoxycaine	8.9	4	9-14
Procaine	9.1	2	14-18
Procainamide	9.3	1	—

Table 1.4 lists the pK_a values for commonly used local anesthetics. Note that pK_a values for local anesthetics may differ slightly in different studies.

Actions on Nerve Membranes

The two factors involved in the action of a local anesthetic are (1) diffusion of the drug through the nerve sheath and (2) binding at the receptor site in the ion channel. The uncharged, lipid-soluble, free base form (RN) of the anesthetic is responsible for diffusion through the nerve sheath. This process is explained in the following example:

1. One thousand molecules of a local anesthetic with a pK_a of 7.9 are injected into the tissues outside a nerve. The tissue pH is normal (7.4) (Fig. 1.19).
2. From Table 1.4 and the Henderson-Hasselbalch equation, it can be determined that at normal tissue pH, 75% of local anesthetic molecules are present in the cationic form (RNH^+) and 25% in the free base form (RN).
3. In theory then, all 250 lipophilic RN molecules will diffuse through the nerve sheath to reach the interior (axoplasm) of the neuron.
4. When this happens, the $RNH^+ \rightleftharpoons RN$ extracellular equilibrium has been disrupted by passage of the free base forms into the neuron. The remaining 750 extracellular RNH^+ molecules will now reequilibrate according to the tissue pH and the pK_a of the drugs:

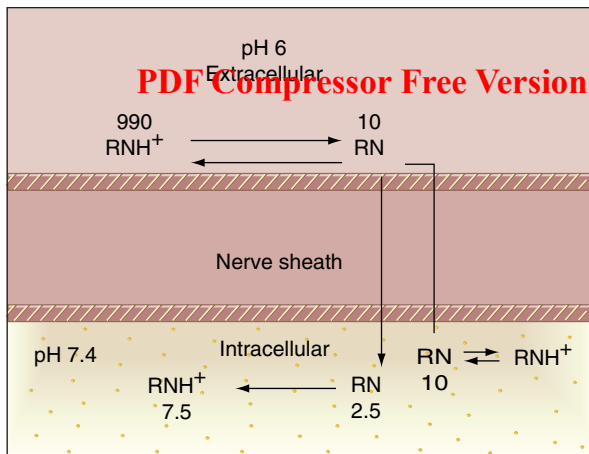


• Fig. 1.19 Mechanism of action of the local anesthetic molecule. Anesthetic pK_a of 7.9; tissue pH of 7.4.

5. The 180 newly created lipophilic RN molecules diffuse into the cell, starting the entire process (step 4) again. Theoretically, this will continue until all local anesthetic molecules diffuse into the axoplasm.
6. The reality, however, is somewhat different. Not all the local anesthetic molecules will eventually reach the interior of the nerve, because of the process of diffusion (drugs will diffuse in a three-dimensional pattern, not just toward the nerve), and because some will be absorbed into blood vessels (e.g., capillaries) and extracellular soft tissues at the injection site.
7. The inside of the nerve should be viewed next. After penetration of the nerve sheath and entry into the axoplasm by the lipophilic RN form of the anesthetic, reequilibration occurs inside the nerve, because a local anesthetic cannot exist in only the RN form at an intracellular pH of 7.4. Seventy-five percent of those RN molecules present within the axoplasm revert to the RNH^+ form; the remaining 25% of molecules remain in the uncharged RN form.
8. From the axoplasmic side, the RNH^+ ions enter sodium channels, bind to the channel receptor site, and ultimately are responsible for the conduction blockade that results (see Figs. 1.14 and 1.15).

Of the two factors—diffusibility and binding—responsible for local anesthetic effectiveness, the former is extremely important in practice. The ability of a local anesthetic to diffuse through the tissues surrounding a nerve is of critical significance, because in clinical situations the local anesthetic cannot be applied directly to the nerve membrane as it can in a laboratory setting. Local anesthetic solutions better able to diffuse through soft tissue provide an advantage in clinical practice.

A local anesthetic with a high pK_a has very few molecules available in the RN form at a tissue pH of 7.4. The onset of anesthesia of this drug is slow because too few base molecules are available to diffuse through the nerve membrane (e.g., procaine, with a pK_a of 9.1). The rate of onset of anesthesia is related to the pK_a of the local anesthetic (see Table 1.4).



• **Fig. 1.20** Effect of decreased tissue pH on the actions of a local anesthetic.

A local anesthetic with a lower pK_a (e.g., lidocaine, pK_a 7.7) has a greater number of lipophilic free base molecules available to diffuse through the nerve sheath; however, the anesthetic action of this drug is inadequate because at an intracellular pH of 7.4 only a very small number of base molecules dissociate back to the cationic form necessary for binding at the receptor site.

In actual clinical situations with the currently available local anesthetics, it is the pH of the extracellular fluid that determines the ease with which a local anesthetic moves from the site of its administration into the axoplasm of the nerve cell. Intracellular pH remains stable and independent of the extracellular pH, because hydrogen ions (H^+) do not readily diffuse through tissues. The pH of extracellular fluid therefore may differ considerably from that of the nerve membrane. The ratio of anesthetic cations to uncharged base molecules (RNH^+/RN) also may vary greatly at these sites. Differences in extracellular and intracellular pH are highly significant in pain control when inflammation or infection is present.³⁹ The effect of a decrease in tissue pH on the actions of a local anesthetic is described in Fig. 1.20. This can be compared with the example in Fig. 1.19, involving normal tissue pH:

1. Approximately 1000 molecules of a local anesthetic with a pK_a of 7.9 are deposited outside a nerve. The tissue is inflamed and infected and has a pH of 6.
2. At this tissue pH, approximately 99% of local anesthetic molecules are present in the charged cationic form (RNH^+), with approximately 1% in the lipophilic free base form (RN).
3. Approximately 10 RN molecules diffuse across the nerve sheath to reach the interior of the cell (in contrast with 250 RN molecules in the healthy example). The pH of the interior of the nerve cell remains normal (e.g., 7.4).
4. Extracellularly, the $RNH^+ \rightleftharpoons RN$ equilibrium, which has been disrupted, is reestablished. The relatively few newly created RN molecules diffuse into the cell, starting the entire process again. However, a sum total of fewer RN molecules succeed in eventually crossing the nerve sheath than would be successful at a normal pH because

of greatly increased absorption of anesthetic molecules into the blood vessels in the region (increased vascularity is noted in the area of inflammation and infection).

5. After penetration of the nerve sheath by the base form, reequilibrium occurs inside the nerve. Approximately 75% of the molecules present intracellularly revert to the cationic form (RNH^+), 25% remaining in the uncharged free base form (RN).
6. The cationic molecules bind to receptor sites within the sodium channel, resulting in conduction blockade.

Adequate blockade of the nerve is more difficult to achieve in inflamed or infected tissues because of the relatively small number of RN molecules able to cross the nerve sheath and the increased absorption of remaining anesthetic molecules into dilated blood vessels in this region. Although it presents a potential problem in all aspects of dental practice, this situation is seen most often in endodontics. Possible remedies are described in Chapter 16.

Clinical Implications of pH and Local Anesthetic Activity

Most commercially prepared solutions of local anesthetics without a vasoconstrictor have a pH between 5.5 and 7. When they are injected into tissue, the vast buffering capacity of tissue fluids returns the pH at the injection site to a normal 7.4. Local anesthetic solutions containing a vasoconstrictor (e.g., epinephrine) are acidified by the manufacturer through the addition of sodium (meta)bisulfite to retard oxidation of the vasoconstrictor, thereby prolonging the period of effectiveness of the drug (e.g., increased shelf life). The pH of a dental cartridge of local anesthetic containing epinephrine may range from 2.8 to 5.5. (See Chapter 3 for a discussion of the appropriate use of vasoconstrictors in local anesthetics.)

Epinephrine may be added to a local anesthetic solution immediately before its administration without the addition of antioxidants; however, if the solution is not used in a short time, the epinephrine will oxidize, slowly turning yellow then brown (much like the oxidation of a sliced apple).

Rapid oxidation of the vasoconstrictor may be delayed, thereby increasing the shelf life of the local anesthetic solution, through addition of antioxidants. Sodium bisulfite in a concentration between 0.05% and 0.1% is commonly used. Frank and Lalonde⁴⁰ assayed 2% lidocaine without epinephrine (plain) and with epinephrine 1:100,000. The pH values were 6.00 ± 0.27 and 3.93 ± 0.43 , respectively. A dental cartridge of 3% solution of mepivacaine hydrochloride (no epinephrine), with a pH between 4.5 and 6.8, is acidified, as a 2% solution with vasoconstrictor, to 3.3 to 5.5 by the addition of a bisulfite.⁴¹

Even in this situation, the enormous buffering capacity of the tissues tends to maintain a normal tissue pH; however, it does require a longer time to do so after injection of a pH 3.3 solution than with a pH 6.8 solution. During this time the local anesthetic is not able to function at its full effectiveness, resulting in a slower onset of clinical action for

local anesthetics with vasoconstrictors compared with their plain counterparts.

Local anesthetics are equally effective on free nerve endings and free nerve endings. Free nerve endings lying below intact skin may be reached only by injection of anesthetic beneath the skin. Intact skin forms an impenetrable barrier to the diffusion of local anesthetics. EMLA (eutectic mixture of local anesthetics lidocaine and prilocaine) enables local anesthetics to penetrate intact skin, albeit slowly.^{42,43}

Mucous membranes and injured skin (e.g., burns, abrasions) lack the protection afforded by intact skin, permitting topically applied local anesthetics to diffuse through them to reach free nerve endings. Topical anesthetics can be used effectively wherever skin is no longer intact because of injury, as well as on mucous membranes (e.g., cornea, gingiva, pharynx, trachea, larynx, esophagus, rectum, vagina, bladder).⁴⁴

The buffering capacity of mucous membrane is poor; thus topical application of a local anesthetic with a pH between 5.5 and 6.5 lowers the regional pH to below normal, and less local anesthetic base is formed. Diffusion of the drug across the mucous membrane to free nerve endings is limited, and nerve block is ineffective. Increasing the pH of the drug provides more of the RN form, thereby increasing the potency of the topical anesthetic; however, the drug in this form is more rapidly oxidized.

To enhance their clinical efficacy, topically applied local anesthetics are usually manufactured in a more concentrated form (5% or 10% lidocaine) than for injection (2% lidocaine). Although only a small percentage of the drug is available in the base form, raising the concentration provides additional RN molecules for diffusion and dissociation to the active cation form at free nerve endings.

Some topical anesthetics (e.g., benzocaine) are not ionized in solution, and therefore their anesthetic effectiveness is unaffected by pH. Because of the poor water solubility of benzocaine, its absorption from the site of application is minimal, and systemic reactions (e.g., overdose) are rarely encountered.

Kinetics of Local Anesthetic Onset and Duration of Action

Barriers to Diffusion of the Solution

A peripheral nerve is composed of hundreds to thousands of tightly packed axons. These axons are protected, supported, and nourished by several layers of fibrous and elastic tissues. Nutrient blood vessels and lymphatics course throughout the layers (Fig. 1.21A).

Individual nerve fibers (axons) are covered with, and are separated from each other by, the endoneurium. The perineurium then binds these nerve fibers together into bundles called *fasciculi*. The radial nerve, located in the wrist, contains between 5 and 10 fasciculi. Each fasciculus contains between 500 and 1000 individual nerve fibers. Five thousand nerve fibers occupy approximately 1 mm² of space.

In a microscopic study of 10 human inferior alveolar nerves at the level of the lingula, the average nerve contained 18.3 fascicles.⁴⁵ Pogrel et al.⁴⁶ microscopically examined 12 human cadavers, finding a mean of 7.2 fascicles for the inferior alveolar nerve (range 3 to 14), while the lingual nerve at the same location was found to have a mean of 3 fascicles (range 1 to 8). Four of the 12 lingual nerves (33%) were unifascicular at this location (Table 1.5).

The thickness of the perineurium varies with the diameter of the fasciculus it surrounds. The thicker the perineurium, the slower the rate of local anesthetic diffusion across it.⁴⁷ The innermost layer of perineurium is the *perilemma*. It is covered with a smooth mesothelial membrane. The perilemma represents the main barrier to diffusion into a nerve.

Fasciculi are contained within a loose network of areolar connective tissue called the *epineurium*. The epineurium constitutes between 30% and 75% of the total cross section of a nerve. Local anesthetics are readily able to diffuse through the epineurium because of its loose consistency. Nutrient blood vessels and lymphatics traverse the epineurium. These vessels absorb local anesthetic molecules, removing them from the site of injection.

The outer layer of the epineurium surrounding the nerve is denser and is thickened, forming what is termed the *epineural sheath* or *nerve sheath*. The epineural sheath does not constitute a barrier to diffusion of local anesthetic into a nerve.

Table 1.6 summarizes the layers of a typical peripheral nerve.

Induction of Local Anesthesia

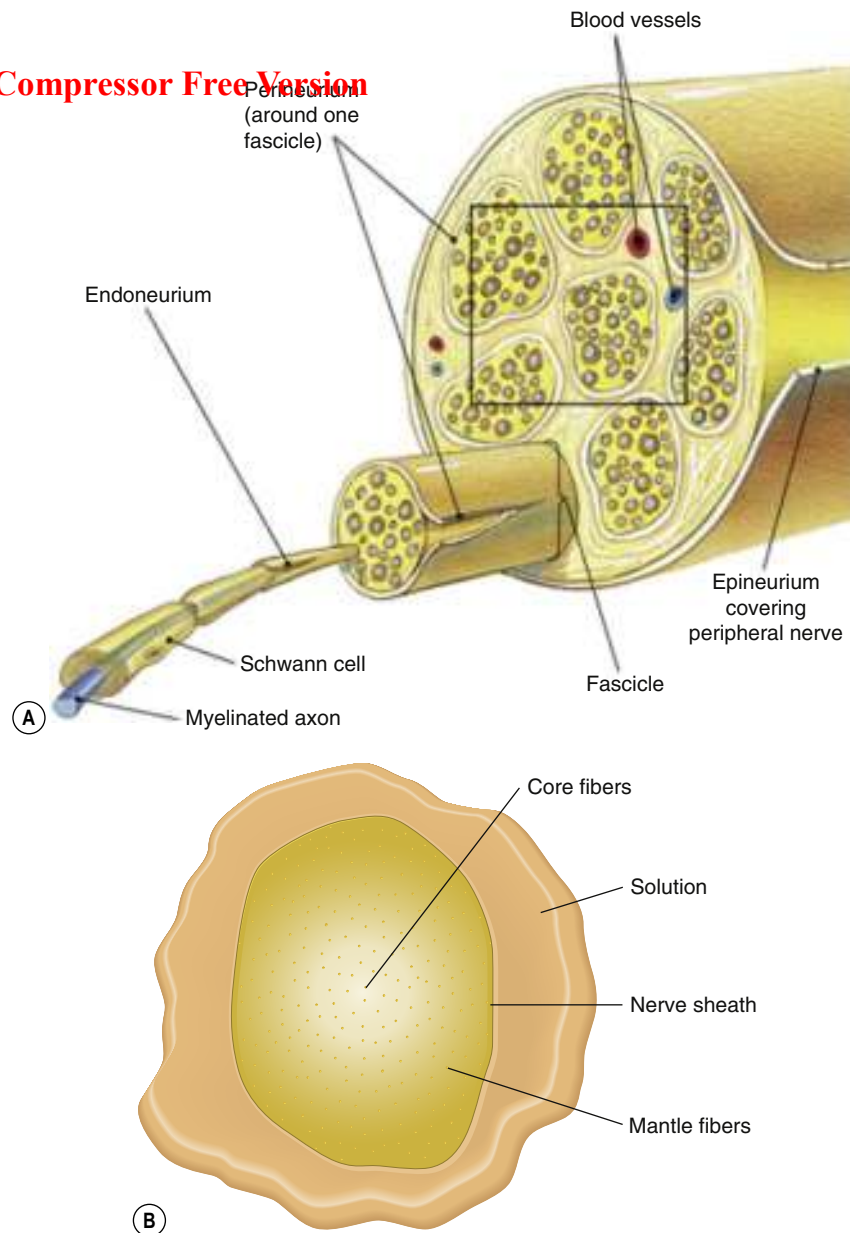
Following administration of a local anesthetic into the soft tissues near a nerve, molecules of the local anesthetic traverse the distance from one site to another according to their concentration gradient. During the induction phase of anesthesia, the local anesthetic moves from its extraneural site of deposition toward the nerve (as well as in all other possible directions). This process is termed *diffusion*. It is the unhindered migration of molecules or ions through a fluid medium under the influence of the concentration gradient. Penetration of an anatomic barrier to diffusion occurs when a drug passes through a tissue that tends to restrict free molecular movement. The perineurium is the greatest barrier to penetration of local anesthetics.

Diffusion

The rate of diffusion is governed by several factors, the most significant of which is the concentration gradient. The greater the initial concentration of the local anesthetic, the faster the diffusion of its molecules and the more rapid its onset of action.

Fasciculi that are located near the surface of the nerve are termed *mantle bundles* (Fig. 1.21A). Mantle bundles are the first ones reached by the local anesthetic and are exposed to a higher concentration of it. Mantle bundles are usually blocked completely shortly after injection of a local anesthetic (Fig. 1.21B).

PDF Compressor Free Version



• **Fig. 1.21** (A) Composition of nerve fibers and bundles within a peripheral nerve. (B) In a large peripheral nerve (containing hundreds or thousands of axons), local anesthetic solution must diffuse inward toward the nerve core from the extraneural site of injection. Local anesthetic molecules are removed by tissue uptake, while tissue fluid mixes with the carrier solvent. This results in gradual dilution of the local anesthetic solution as it penetrates the nerve toward the core. A concentration gradient occurs during induction and so the outer mantle fibers are solidly blocked, whereas the inner core fibers are not yet blocked. Not only are core fibers exposed to a lower local anesthetic concentration, but the drug arrives later. Delay depends on the tissue mass to be penetrated and the diffusivity of the local anesthetic. ([A] Redrawn from <http://heritance.me/>, [B] redrawn from de Jong RH: *Local anesthetics*, St Louis, 1994, Mosby.)

Fasciculi found closer to the center of the nerve are called *core bundles*. Core bundles are contacted by a local anesthetic only after much delay and by a lower anesthetic concentration because of the greater distance that the solution must traverse and the greater number of barriers to be crossed.

As the local anesthetic diffuses into the nerve, it becomes increasingly diluted by tissue fluids, with some being absorbed by capillaries and lymphatics. Ester anesthetics undergo almost immediate enzymatic hydrolysis. Therefore

core fibers are exposed to a decreased concentration of local anesthetic, which may explain the clinical situation of inadequate pulpal anesthesia developing in the presence of subjective symptoms of adequate soft tissue anesthesia. Complete conduction blockade of all nerve fibers in a peripheral nerve requires that an adequate volume, as well as an adequate concentration, of the local anesthetic be deposited. In no clinical situation are 100% of the fibers within a peripheral nerve blocked, even in cases of clinically excellent

TABLE 1.5 Fascicular pattern of All Lingual Nerves and Inferior Alveolar Nerves at Lingula

Nerve	Number of Fascicles	
	Lingual Nerve at Lingula	Inferior Alveolar Nerve at Lingula
1	1	3
2	3	3
3	1	6
4	8	14
5	4	7
6	3	14
7	3	5
8	1	10
9	3	8
10	5	4
11	1	6
12	3	6
Mean	3.0	7.3
Standard deviation	±2.0	±3.8

With permission from Pogrel MA, Schmidt BL, Sambajon, Jordan RCK. Lingual nerve damage due to inferior alveolar nerve blocks. *J Amer Dent Assoc* 134(2):195–199, 2003.

TABLE 1.6 Organization of a Peripheral Nerve

Structure	Description
Nerve fiber	Single nerve cell
Endoneurium	Covers each nerve fiber
Fasciculi	Bundles of 500–1000 nerve fibers
Perineurium ^a	Covers fasciculi
Perilemma ^a	Innermost layer of perineurium
Epineurium	Alveolar connective tissue supporting fasciculi and carrying nutrient vessels
Epineural sheath	Outer layer of epineurium

^aThe perineurium and perilemma constitute the greatest anatomic barriers to diffusion in a peripheral nerve.

pain control.⁴⁸ Fibers near the surface of the nerve (mantle fibers) tend to innervate more proximal regions (e.g., the molar area with an inferior alveolar nerve block), whereas fibers in the core bundles innervate the more distal points

of nerve distribution (e.g., the incisors and canines with an inferior alveolar block).

Blocking Process

After deposition of local anesthetic as close to the nerve as possible, the solution diffuses three-dimensionally according to prevailing concentration gradients. A portion of the injected local anesthetic diffuses toward the nerve and into the nerve. However, a significant portion of the injected drug also diffuses away from the nerve. The following reactions then occur:

1. Some of the drug is absorbed by nonneural tissues (e.g., muscle, fat).
2. Some is diluted by interstitial fluid.
3. Some is removed by capillaries and lymphatics from the injection site.
4. Ester-type anesthetics are hydrolyzed by plasma cholinesterase.

The sum total effect of these factors is to decrease the local anesthetic concentration outside the nerve; however, the concentration of local anesthetic within the nerve continues to rise as diffusion progresses. These processes continue until an equilibrium results between intraneural and extraneural concentrations of anesthetic solution.

Induction Time

Induction time is defined as the period from deposition of the anesthetic solution to complete conduction blockade. Several factors control the induction time of a given drug. Those under the operator's control are the concentration of the drug and the pH of the local anesthetic solution. Factors not under the clinician's control include the diffusion constant of the drug and anatomic barriers to diffusion.

Physical Properties and Clinical Actions

Other physicochemical factors of a local anesthetic may influence its clinical characteristics.

The effect of the *dissociation constant* (pK_a) on the rate of onset of anesthesia has been described. Although both molecular forms of the anesthetic are important in neural blockade, drugs with a lower pK_a possess a more rapid onset of action than those with a higher pK_a .⁴⁹

Lipid solubility of a local anesthetic appears to be related to its intrinsic potency. The approximate lipid solubilities of various local anesthetics are presented in Table 1.7. Greater lipid solubility permits the anesthetic to penetrate the nerve membrane (which itself is 90% lipid) more easily. This is reflected biologically in increased potency of the anesthetic. Local anesthetics with greater lipid solubility produce more effective conduction blockade at lower concentrations (lower-percentage solutions or smaller volumes deposited) than is produced by less lipid-soluble local anesthetics.

The degree of *protein binding* of the local anesthetic molecule is responsible for the duration of anesthetic activity. After penetration of the nerve sheath, a reequilibrium occurs between the base and cationic forms of the local anesthetic according to the Henderson-Hasselbalch equation. Now, in

TABLE
1.7

Chemical Structure, Physicochemical Properties, and Pharmacologic Properties of Local Anesthetic Agents

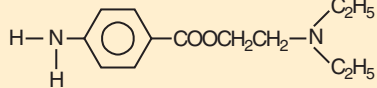
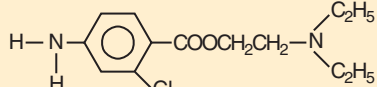
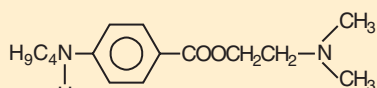
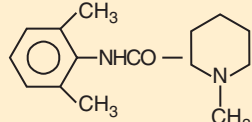
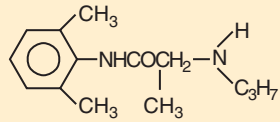
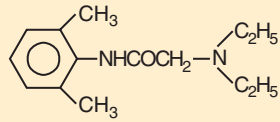
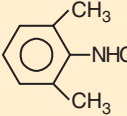
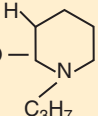
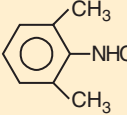
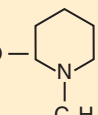
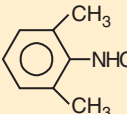
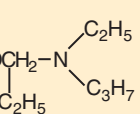
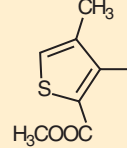
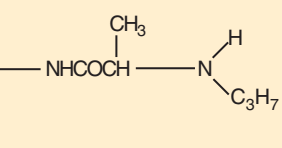
Agent	Chemical Configuration			Physicochemical Properties			Pharmacologic Properties			
	Aromatic (Lipophilic)	Intermediate Chain	Amine (Hydrophilic)	Molecular Weight (Base)	pK _a (36°C)	Onset	Approximate Lipid Solubility	Usual Effective Concentration (%)	Protein Binding	Duration
Esters										
Procaine				236	9.1	Slow	1.0	2-4	5	Short
Chloroprocaine				271	8.7	Fast	NA	2	NA	Short
Tetracaine				264	8.4	Slow	80	0.15	85	Long
Amides										
Mepivacaine				246	7.9	Fast	1.0	2-3	75	Moderate
Prilocaine				220	7.7	Fast	1.5	4	55	Moderate
Lidocaine				234	7.7	Fast	4.0	2	65	Moderate

TABLE 1.7

Chemical Structure, Physicochemical Properties, and Pharmacologic Properties of Local Anesthetic Agents—cont'd

Agent	Chemical Configuration			Physicochemical Properties			Pharmacologic Properties			
	Aromatic (Lipophilic)	Intermediate Chain	Amine (Hydrophilic)	Molecular Weight (Base)	pK _a (36°C)	Onset	Approximate Lipid Solubility	Usual Effective Concentration (%)	Protein Binding	Duration
Ropivacaine				274	8.1	Moderate	2.8	0.2–0.5	94	Long
Bupivacaine				288	8.1	Moderate	NA	0.5–0.75	95	Long
Etidocaine				276	7.9	Fast	140	0.5–1.5	94	Long
Articaine				320	7.8	Fast	17	4	95	Moderate

NA, Not available.
 Modified from Rogers MC, Covino BG, Tinker JH, et al, editors: *Principles and practice of anesthesiology*, St Louis, 1993, Mosby.

the sodium channel itself, RNH^+ ions bind at the receptor site. Proteins constitute approximately 10% of the nerve membrane, and local anesthetics (e.g., etidocaine, bupivacaine) possessing a greater degree of protein binding (see Table 1.7) than others (e.g., procaine) appear to attach more securely to the protein receptor sites and to possess a longer duration of clinical activity.⁵⁰

Vasoactivity affects both the anesthetic potency and the duration of anesthesia provided by a drug. Injection of local anesthetics, such as procaine, with greater vasodilating properties increases vascular perfusion at the injection site. The injected local anesthetic is absorbed into the cardiovascular compartment more rapidly and taken away from the injection site and from the nerve, thus providing a shortened duration of anesthesia, as well as decreased potency of the drug. Table 1.8 summarizes the influence of various factors on local anesthetic action.

Recovery From Local Anesthetic Block

Emergence from a local anesthetic nerve block follows the same diffusion patterns as induction; however, it does so in the reverse order.

The extraneural concentration of local anesthetic is continually depleted by diffusion, dispersion, and vascular uptake of the drug, whereas the intraneural concentration of local anesthetic remains relatively stable. Once the concentration gradient has been reversed with the intraneural concentration exceeding the extraneural concentration, anesthetic molecules begin to diffuse out of the nerve.

Fasciculi in the mantle begin to lose the local anesthetic much sooner than do the core bundles. Local

anesthetic within the core then diffuses into the mantle, so the first nerve fibers to lose anesthesia entirely are those centermost in the nerve. Mantle fibers remain anesthetized the longest, and core fibers the shortest. Recovery from anesthesia is a slower process than induction because the local anesthetic is bound to the drug receptor site in the sodium channel and therefore is released more slowly than it is absorbed.

Readministration of Local Anesthetic

Occasionally a dental procedure lasts longer than the duration of clinically effective pain control, and a repeated injection of local anesthetic is required. Usually this repeated injection results in the immediate return of profound anesthesia. On some occasions, however, the clinician may encounter greater difficulty in reestablishing adequate pain control with subsequent injections.

Recurrence of Immediate Profound Anesthesia

At the time of reinjection the concentration of local anesthetic in the core fibers is less than that in the mantle fibers. Partially recovered core fibers still contain some local anesthetic, although not enough to provide complete anesthesia. After deposition of a new high concentration of anesthetic near the nerve, the mantle fibers are once again exposed to a concentration gradient directed inward toward the nerve; this eventually leads to an increased concentration in the core fibers. This combination of residual local anesthetic (in the nerve) and the newly deposited local anesthetic results in rapid onset of profound anesthesia and administration of a smaller volume of local anesthetic drug.

TABLE 1.8 Factors Affecting Local Anesthetic Action

Factor	Action Affected	Description
pK_a	Onset	Lower pK_a results in more rapid onset of action as more RN molecules are present to diffuse through the nerve sheath; thus the onset time is decreased
Lipid solubility	Anesthetic potency	Increased lipid solubility results in increased potency (e.g., procaine = 1; etidocaine = 140) Etidocaine produces conduction blockade at very low concentrations, whereas procaine poorly suppresses nerve conduction, even at higher concentrations
Protein binding	Duration	Increased protein binding allows anesthetic cations (RNH^+) to be more firmly attached to proteins located at receptor sites; thus the duration of action is increased
Nonnervous tissue diffusibility	Onset	Increased diffusibility results in decreased time of onset
Vasodilator activity	Anesthetic potency and duration	Greater vasodilator activity results in increased blood flow to the region, resulting in rapid removal of anesthetic molecules from the injection site; thus anesthetic potency and duration are decreased

From Cohen S, Burns RC: *Pathways of the pulp*, ed 6, St Louis, 1994, Mosby.

Difficulty Reaching Profound Anesthesia

In this second situation, as in the first, the dental procedure has lasted longer than the clinical effectiveness of the local anesthetic drug, and the patient is experiencing pain. The doctor readministers a volume of local anesthetic, but unlike in the first scenario, effective control of pain does not develop.

Tachyphylaxis

In this second situation, a process known as *tachyphylaxis* occurs. Tachyphylaxis is defined as increasing tolerance to a drug that is administered repeatedly. It is much more likely to develop if nerve function returns before reinjection (e.g., if the patient complains of pain). The duration, intensity, and spread of anesthesia with reinjection are greatly reduced.^{51,52}

Although difficult to explain, tachyphylaxis is probably brought about by some, or all, of the following factors: edema, localized hemorrhage, clot formation, transudation, hypernatremia, and decreased pH of tissues. The first four factors isolate the nerve from contact with the local anesthetic solution. The fifth, hypernatremia, raises the sodium ion gradient, thus counteracting the decrease in sodium ion conduction brought about by the local anesthetic. The last factor, a decrease in pH of the tissues, is brought about by the first injection of the acidic local anesthetic. The ambient pH at the injection site may be somewhat lower, so fewer local anesthetic molecules are transformed into the free base (RN) on reinjection.

Duration of Anesthesia

As local anesthetic is removed from the nerve, the function of the nerve returns rapidly at first, but then gradually more slowly. Compared with onset of the nerve block, which is rapid, recovery from the nerve block is much slower because the local anesthetic is bound to the nerve membrane. Longer-acting local anesthetics (e.g., bupivacaine, etidocaine, ropivacaine, tetracaine) are more firmly bound in the nerve membrane (greater protein binding) than are shorter-acting drugs (e.g., procaine, lidocaine) and therefore are released more slowly from receptor sites in the sodium channels. The rate at which an anesthetic is removed from a nerve has an effect on the duration of neural blockade; in addition to increased protein binding, other factors that influence the rate of removal of a drug from the injection site are the vascularity of the injection site and the presence or absence of a vasoactive substance. Anesthetic duration is increased in areas of decreased vascularity (e.g., Gow-Gates mandibular nerve block vs. inferior alveolar nerve block), and the addition of a vasopressor decreases tissue perfusion to a local area, thus increasing the duration of the block.

References

- Covino BG, Vassallo HG. *Local Anesthetics: Mechanisms of Action and Clinical Use*. New York: Grune & Stratton; 1976.
- Bennett CR. *Monheim's Local Anesthesia and Pain Control in Dental Practice*. 5th ed. St Louis: Mosby; 1974.
- Fitzgerald MJT. *Neuroanatomy: Basic and Clinical*. London: Baillière Tindall; 1992.
- Noback CR, Strominger NL, Demarest RJ. *The Human Nervous System: Introduction and Review*. 4th ed. Philadelphia: Lea & Febiger; 1991.
- Singer SJ, Nicholson GL. The fluid mosaic model of the structure of cell membranes. *Science*. 1972;175:720–731.
- Guyton AC. *Basic Neuroscience: Anatomy and Physiology*. 2nd ed. Philadelphia: WB Saunders; 1991.
- Guidotti G. The composition of biological membranes. *Arch Intern Med*. 1972;129:194–201.
- Denson DD, Maziot JX. Physiology, pharmacology, and toxicity of local anesthetics: adult and pediatric considerations. In: Raj PP, ed. *Clinical Practice of Regional Anesthesia*. New York: Churchill Livingstone; 1991.
- Heavner JE. Molecular action of local anesthetics. In: Raj PP, ed. *Clinical Practice of Regional Anesthesia*. New York: Churchill Livingstone; 1991.
- de Jong RH. *Local Anesthetics*. 2nd ed. Springfield: Charles C Thomas; 1977.
- Hodgkin AL, Huxley AF. A quantitative description of membrane current and its application to conduction and excitation in nerve. *J Physiol (Lond)*. 1954;117:500–544.
- Noback CR, Demarest RJ. *The Human Nervous System: Basic Principles of Neurobiology*. 3rd ed. New York: McGraw-Hill; 1981:44–45.
- Keynes RD. Ion channels in the nerve-cell membrane. *Sci Am*. 1979;240:326–335.
- Cattarall WA. Structure and function of voltage-sensitive ion channels. *Science*. 1988;242:50–61.
- Hille B. Ionic selectivity, saturation, and block in sodium channels: a four-barrier model. *J Gen Physiol*. 1975;66:535–560.
- Ritchie JM. Physiological basis for conduction in myelinated nerve fibers. In: Morell P, ed. *Myelin*. 2nd ed. New York: Plenum Press; 1984:117–145.
- Franz DN, Perry RS. Mechanisms for differential block among single myelinated and non-myelinated axons by procaine. *J Physiol*. 1974;235:193–210.
- de Jong RH, Wagman IH. Physiological mechanisms of peripheral nerve block by local anesthetics. *Anesthesiology*. 1963;24:684–727.
- Dettbarn WD. The acetylcholine system in peripheral nerve. *Ann NY Acad Sci*. 1967;144:483–503.
- Goldman DE, Blaustein MP. Ions, drugs and the axon membrane. *Ann NY Acad Sci*. 1966;137:967–981.
- Wei LY. Role of surface dipoles on axon membrane. *Science*. 1969;163:280–282.
- Lee AG. Model for action of local anesthetics. *Nature*. 1976;262:545–548.
- Seeman P. The membrane actions of anesthetics and tranquilizers. *Pharmacol Rev*. 1972;24:583–655.
- Strichartz GR, Ritchie JM. The action of local anesthetics on ion channels of excitable tissues. In: Strichartz GR, ed. *Local Anesthetics*. New York: Springer-Verlag; 1987.
- Scholz A. Mechanisms of (local) anaesthetics on voltage-gated sodium and other ion channels. *Br J Anaesth*. 2002;89(1):52–61.
- Butterworth JFIV, Strichartz GR. Molecular mechanisms of local anesthesia: a review. *Anesthesiology*. 1990;72:711–734.
- Ritchie JM. Mechanisms of action of local anesthetic agents and biotoxins. *Br J Anaesth*. 1975;47:191–198.

28. Rasminsky M. Conduction in normal and pathological nerve fibers. In: Swash M, Kennard C, eds. *Scientific Basis of Clinical Neurology*. Edinburgh: Churchill Livingstone; 1985.
29. Ritchie JM. The distribution of sodium and potassium channels in mammalian myelinated nerve. In: Ritchie JM, Keyes RD, Bolis L, eds. *Ion Channels in Neural Membranes*. New York: Alan R Liss; 1986.
30. Hille B, Courtney K, Dum R. Rate and site of action of local anesthetics in myelinated nerve fibers. In: Fink BR, ed. *Molecular Mechanisms of Anesthesia*. New York: Raven Press; 1975:13–20.
31. Hollman A. Procaine and procainamide. *Br Heart J*. 1992;67(2):143.
32. Setnikar I. Ionization of bases with limited solubility: investigation of substances with local anesthetic activity. *J Pharm Sci*. 1990;55:1190–1195.
33. Malamed SF. Buffering local anesthetics in dentistry. *ADSA Pulse*. 2011;44(3):8–9.
34. Stewart JH, Chinn SE, Cole GW, Klein JA. Neutralized lidocaine with epinephrine for local anesthesia-II. *J Dermatol Surg Oncol*. 1990;16:942–945.
35. Yag-Howard C. Commentary: a prospective comparison between neutralizing the pH of 1% lidocaine with epinephrine (buffering) and pre-operative skin cooling in reducing the pain of infiltration of local anesthetic. *Dermatol Surg*. 2012;38(10):1660–1661.
36. Comerci AW, Maller SC, Townsend RD, Teepe JD, Vandewalle KS. Effect of a new local anesthetic buffering device on pain reduction during nerve block injections. *Gen Dent*. 2015;63(6):74–78.
37. Bokesch PM, Raymond SA, Strichartz GR. Dependence of lidocaine potency on pH and pCO₂. *Anesth Analg*. 1987;66:9–17.
38. Bieter RN. Applied pharmacology of local anesthetics. *Am J Surg*. 1936;34:500–510.
39. Ueno T, Tsuchiya H, Mizogami M, Takakura K. Local anesthetic failure associated with inflammation: verification of the acidosis mechanism and the hypothetic participation of inflammatory peroxynitrite. *J Inflamm Res*. 2008;1:41–48.
40. Frank SG, Lalonde DH. How acidic is the lidocaine we are injecting, and how much bicarbonate should we add? *Can J Plast Surg*. 2012;20(2):71–73.
41. *Carbocaine Drug Package Insert*. Cook-Waite. Cambridge, Ontario: Carestream Health Inc. Novocol Pharmaceutical of Canada, Inc.; 2013. Canada N1R 6X3.
42. Buckley MM, Benfield P. Eutectic lidocaine/prilocaine cream: a review of the topical anesthetic/analgesic efficacy of a eutectic mixture of local anesthetics (EMLA). *Drugs*. 1993;46:126–151.
43. Lee HS. Recent advances in topical anesthesia. *J Dent Anesth Pain Med*. 2016;16(4):237–244.
44. Campbell AH, Stasse JA, Lord GH, Willson JE. In vivo evaluation of local anesthetics applied topically. *J Pharm Sci*. 1968;57:2045–2048.
45. Svane TJ, Wolford LM, Milam SB, Bass RK. Fascicular characteristics of the human inferior alveolar nerve. *J Oral Maxillofac Surg*. 1986;44(6):431–434.
46. Pogrel MA, Schmidt BL, Sambajon V, Jordan RC. Lingual nerve damage due to inferior alveolar nerve blocks: a possible explanation. *J Am Dent Assoc*. 2003;134(2):195–199.
47. Noback CR, Demarest RJ. *The Human Nervous System: Basic Principles of Neurobiology*. 3rd ed. New York: McGraw-Hill; 1981.
48. de Jong RH. *Local Anesthetics*. 2nd ed. Springfield: Charles C Thomas; 1977:66–68.
49. Becker DE, Reed KR. Essentials of local anesthetic pharmacology. *Anesth Prog*. 2006;53(3):98–109.
50. Tucker GT. Plasma binding and disposition of local anesthetics. *Int Anesthesiol Clin*. 1975;13:33.
51. Cohen EN, Levine DA, Colliss JE, Gunther RE. The role of pH in the development of tachyphylaxis to local anesthetic agents. *Anesthesiology*. 1968;29:994–1001.
52. Scott DB. Tachyphylaxis and local anesthetics. In: Wust HJ, Stanton-Hicks M, eds. *New Aspects in Regional Anesthesia 4. Anaesthesiology and Intensive Care Medicine*. Vol. 176. Berlin: Springer; 1986.

Pharmacology of Local Anesthetics

Local anesthetics, when used for the management of pain, differ from most other drugs commonly used in medicine and dentistry in one important manner. Virtually all other drugs, regardless of the route through which they are administered, must ultimately enter the circulatory system in sufficiently high concentrations (e.g., attain therapeutic blood levels in their target organ[s]) before they can exert a clinical action. Local anesthetics, however, when used for pain control, *cease* to provide a clinical effect when they are absorbed from the site of administration into the circulation. One prime factor involved in the termination of action of local anesthetics used for pain control is their redistribution from the nerve fiber into the cardiovascular system (CVS).

The presence of a local anesthetic in the circulatory system means that the drug will be transported to every part of the body. Local anesthetics have the ability to alter the functioning of some of these cells. In this chapter, the actions of local anesthetics, other than their ability to block conduction in nerve axons of the peripheral nervous system, are reviewed. A classification of local anesthetics is shown in [Box 2.1](#).

Pharmacokinetics of Local Anesthetics

Uptake

When injected into soft tissues, local anesthetics exert pharmacologic action on blood vessels in the area. All local anesthetics possess a degree of vasoactivity, most producing dilation of the vascular bed into which they are deposited, although the degree of vasodilation may differ, and some (e.g., cocaine) may produce vasoconstriction. To some degree, these effects may be concentration dependent.¹ Relative vasodilating values of amide local anesthetics are shown in [Table 2.1](#).

Ester local anesthetics are also potent vasodilating drugs. Procaine, the most potent vasodilator among local anesthetics is, on rare occasion, injected clinically to induce vasodilation when peripheral blood flow has been compromised because of (accidental) intra-arterial injection of a drug (e.g., thiopental)² or injection of epinephrine or norepinephrine into a fingertip or toe.³ Intra-arterial administration of an irritating drug such as thiopental may produce arteriospasm, with an attendant decrease in tissue perfusion that if prolonged could lead to tissue death, gangrene, and loss of the

affected limb. In this situation, procaine is administered intra-arterially in an attempt to break the arteriospasm and reestablish blood flow to the affected limb. Tetracaine, chloroprocaine, and propoxycaine also possess vasodilating properties to differing degrees but not to the degree of procaine.

Cocaine is the only local anesthetic that consistently produces vasoconstriction.⁴ The initial action of cocaine is vasodilation, followed by an intense and prolonged vasoconstriction. It is produced by inhibition of the uptake of catecholamines (especially norepinephrine) into tissue binding sites. This results in an excess of free norepinephrine, leading to a prolonged and intense state of vasoconstriction. This inhibition of the reuptake of norepinephrine has not been demonstrated with other local anesthetics, such as lidocaine and bupivacaine.

A significant clinical effect of vasodilation is an increase in the rate of absorption of the local anesthetic into the blood, thus decreasing the duration and quality (e.g., depth) of pain control, while increasing the anesthetic blood (or plasma) concentration and its potential for overdose (toxic reaction). The rates at which local anesthetics are absorbed into the bloodstream and reach their peak blood level vary according to the route of administration ([Table 2.2](#)).

Oral Route

With the exception of cocaine, local anesthetics are absorbed poorly, if at all, from the gastrointestinal tract after oral administration. In addition, most local anesthetics (especially lidocaine) undergo a significant hepatic first-pass effect after oral administration. After absorption of lidocaine from the gastrointestinal tract into the enterohepatic circulation, a fraction of the drug dose is carried to the liver, where approximately 72% of the dose is biotransformed into inactive metabolites.⁵ This has seriously hampered the use of lidocaine as an oral antidysrhythmic drug. In 1984 Astra Pharmaceuticals and Merck Sharp & Dohme introduced an analogue of lidocaine, tocainide hydrochloride, that is effective orally.⁶ The chemical structures of tocainide and lidocaine are presented in [Fig. 2.1](#).

Topical Route

Local anesthetics are absorbed at differing rates after application to mucous membrane: in the tracheal mucosa, absorption

• **BOX 2.1** Classification of Local Anesthetics

Esters PDF Compressor Free Version

Esters of benzoic acid

Butacaine
Cocaine
Ethyl aminobenzoate (benzocaine)
Hexylcaine
Piperocaine
Tetracaine

Esters of *p*-aminobenzoic acid

Chloroprocaine
Procaine
Propoxycaine

Amides

Articaine
Bupivacaine
Dibucaine
Etidocaine
Lidocaine
Mepivacaine
Prilocaine
Ropivacaine

Quinoline

Centbucridine

TABLE 2.1 Relative Vasodilating Values of Amide-Type Local Anesthetics

	Vasodilating Activity	Mean Percentage Increase in Femoral Artery Blood Flow in Dogs After Intra-Arterial Injection ^a	
		1 min	5 min
Articaine	1 (approximately)	NA	NA
Bupivacaine	2.5	45.4	30
Etidocaine	2.5	44.3	26.6
Lidocaine	1	25.8	7.5
Mepivacaine	0.8	35.7	9.5
Prilocaine	0.5	42.1	6.3
Tetracaine	NA	37.6	14

^aEach agent injected rapidly at a dose of 1 mg/0.1 mL saline.

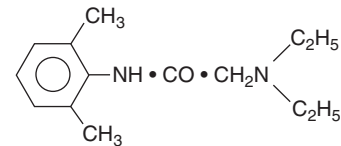
NA, Not available.

Modified from Blair MR. Cardiovascular pharmacology of local anesthetics. *Br J Anaesth.* 1975;47(suppl):247–252.

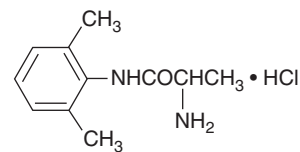
is almost as rapid as with intravenous (IV) administration (indeed, intratracheal drug administration [epinephrine, lidocaine, atropine, naloxone, and flumazenil] is used in certain emergency situations); in the pharyngeal mucosa, absorption is slower; and in the esophageal or bladder mucosa, uptake is even slower than occurs through the pharynx. Wherever no layer of intact skin is present, topically applied local anesthetics

TABLE 2.2 Time to Achieve Peak Blood Level

Route	Time (min)
Intravenous	1
Topical	5 (approximately)
Intramuscular	5–10
Subcutaneous	30–90



A



B

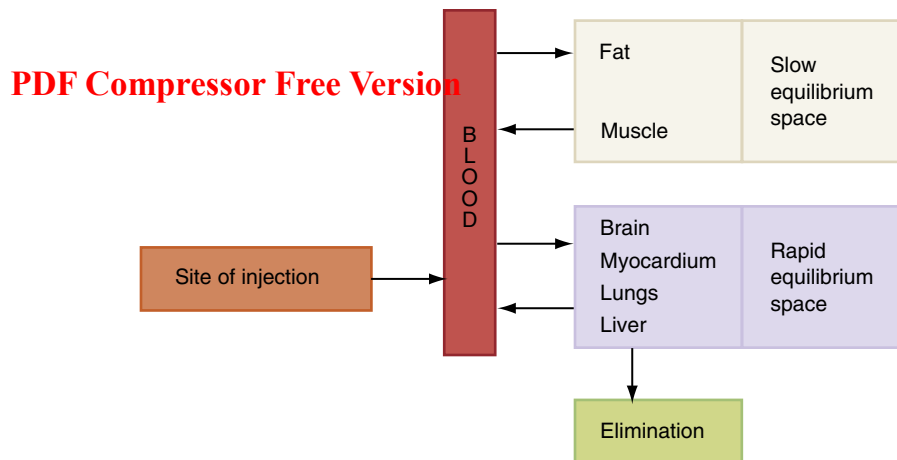
• **Fig. 2.1** (A) Tocainide, a modification of lidocaine (B) that is able to pass through the liver after oral administration with minimal hepatic first-pass effect.

can produce an anesthetic effect. Sunburn remedies (e.g., Solarcaine, Schering-Plough HealthCare Products Inc., Memphis, Tennessee, United States) usually contain lidocaine, benzocaine, or other anesthetics in an ointment formulation. Applied to intact skin, they do not provide an anesthetic action, but with skin damaged by the sun, they bring rapid relief of pain. A eutectic mixture of local anesthetics lidocaine and prilocaine (EMLA) has been developed that is capable of providing surface anesthesia of intact skin.⁷ EMLA is frequently used as an aid before venipuncture in needle-phobic patients.⁸

Injection

The rate of uptake (absorption) of local anesthetics after parenteral administration (subcutaneous, intramuscular, or IV) is related to both the vascularity of the injection site and the vasoactivity of the drug.

IV administration of local anesthetics provides the most rapid elevation of blood levels and is used clinically in the primary management of ventricular dysrhythmias.⁹ Rapid IV administration can lead to significantly high local anesthetic blood levels, which can induce serious adverse reactions. The benefits to be accrued from IV drug administration must always be carefully weighed against any risks associated with IV administration. Only when the benefits clearly outweigh the risks should the drug be administered, as is the case with prefatal ventricular dysrhythmias such as premature ventricular contractions.¹⁰



• **Fig. 2.2** Pattern of distribution of local anesthetics after absorption. (Redrawn from Wildsmith JAW, Armitage EN, McClure JH. *Principles and Practice of Regional Anesthesia*. 3rd ed. Edinburgh: Churchill Livingstone; 2003.)

TABLE 2.3 Percentages of Cardiac Output Distributed to Different Organ Systems

Region	Percentage of Cardiac Output Received
Kidney	22
Gastrointestinal system, spleen	21
Skeletal muscle	15
Brain	14
Skin	6
Liver	6
Bone	5
Heart muscle	3
Other	8

Modified from Mohrman DE, Heller LJ. *Cardiovascular Physiology*. 7th ed. New York: Lange Medical Books/McGraw-Hill; 2010.)

Distribution

Once absorbed into the blood, local anesthetics are distributed throughout the body to all tissues (Fig. 2.2). Highly perfused organs (and areas), such as the brain, head, liver, kidneys, lungs, and spleen, initially will have higher anesthetic blood levels than less highly perfused organs. Skeletal muscle, although not as highly perfused as these areas, contains the greatest percentage of local anesthetic of any tissue or organ in the body because it constitutes the largest mass of tissue in the body (Table 2.3).

The plasma concentration of a local anesthetic in certain target organs has a significant bearing on the potential toxicity of the drug. The blood level of the local anesthetic is influenced by:

1. the rate at which the drug is absorbed into the CVS
2. the rate of distribution of the drug from the vascular compartment to the tissues (more rapid in healthy

patients than in those who are medically compromised [e.g., congestive heart failure], thus leading to lower blood levels in healthier patients)

3. elimination of the drug through metabolic or excretory pathways

The latter two factors serve to decrease the blood level of the local anesthetic.

The rate at which a local anesthetic is removed from the blood is described as its *elimination half-life*. Simply stated, the elimination half-life is the time necessary for a 50% reduction in the blood level (one half-life is equivalent to 50% reduction; two half-lives are equivalent to 75% reduction; three half-lives are equivalent to 87.5% reduction; four half-lives are equivalent to 94% reduction; five half-lives are equivalent to 97% reduction; six half-lives are equivalent to 98.5% reduction) (Table 2.4).

All local anesthetics readily cross the blood-brain barrier. They also readily cross the placenta and enter the circulatory system of the developing fetus.

Metabolism (Biotransformation, Detoxification)

A significant difference between the two major groups of local anesthetics, the esters and the amides, is the means by which the body biologically transforms the active drug into one that is pharmacologically inactive. Metabolism (also known as *biotransformation* or *detoxification*) of local anesthetics is important because the overall toxicity of a drug depends on a balance between its rate of absorption into the bloodstream at the site of injection and its rate of removal from the blood through the processes of tissue uptake and metabolism.

Ester Local Anesthetics

Ester local anesthetics are hydrolyzed in the plasma by the enzyme pseudocholinesterase.¹¹ The rate at which hydrolysis of different esters occurs varies considerably (Table 2.5).

TABLE 2.4 Half-Life of Local Anesthetics

Drug	Half-Life (h)
Chlorprocaine ^a	0.1
Procaine ^a	0.1
Tetracaine ^a	0.3
Articaine ^b	0.5
Cocaine ^a	0.7
Prilocaine ^b	1.6
Lidocaine ^b	1.6
Mepivacaine ^b	1.9
Ropivacaine ^b	1.9
Etidocaine ^b	2.6
Bupivacaine ^b	3.5
Propoxycaine ^a	NA

^aEster.
^bAmide.
 NA, Not available.

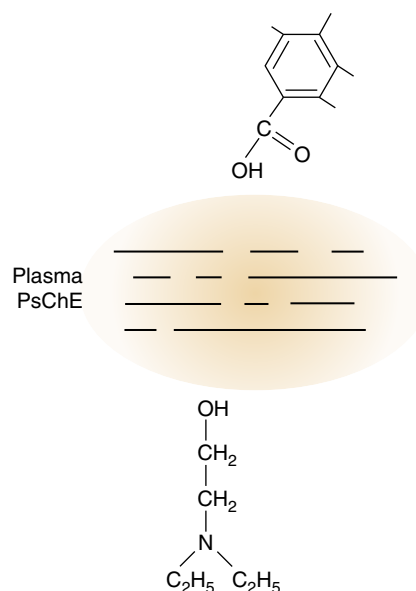
TABLE 2.5 Hydrolysis Rate of Esters

Drug	Rate of Hydrolysis ($\mu\text{mol/mL/h}$)
Chlorprocaine	4.7
Procaine	1.1
Tetracaine	0.3

The rate of hydrolysis has an impact on the potential toxicity of a local anesthetic.¹ Chlorprocaine, the most rapidly hydrolyzed, is the least toxic, whereas tetracaine, hydrolyzed 16 times more slowly than chlorprocaine, has the greatest potential toxicity. Procaine undergoes hydrolysis to *p*-aminobenzoic acid (PABA), which is excreted unchanged in the urine, and to diethylamine alcohol, which undergoes further biotransformation before excretion (Fig. 2.3). Allergic reactions that occur (rarely) in response to ester local anesthetic administration are usually related not to the parent compound (e.g., procaine) but rather to PABA, which is a major metabolic product of many ester local anesthetics.

Succinylcholine is a short-acting muscle relaxant commonly used during the induction phase of general anesthesia. It produces respiratory arrest (apnea) for a period of approximately 2 to 3 minutes. Then as plasma pseudocholinesterase hydrolyzes succinylcholine, blood levels fall,

¹Approximately 1 in every 2800 persons has an atypical form of pseudocholinesterase, which causes an inability to hydrolyze ester local anesthetics and other chemically related drugs (e.g., succinylcholine).¹² The presence of atypical plasma pseudocholinesterase leads to prolongation of higher local anesthetic blood levels and increased potential for toxicity.



• **Fig. 2.3** Metabolic hydrolysis of procaine. *PsChE*, Pseudocholinesterase. (From Tucker GT. Biotransformation and toxicity of local anesthetics. *Acta Anaesthesiol Belg.* 1975;26(suppl):123.)

and spontaneous respiration resumes. Persons with atypical pseudocholinesterase are unable to hydrolyze succinylcholine at a normal rate, resulting in the duration of apnea being prolonged. Atypical pseudocholinesterase is a hereditary trait. Any familial history of adverse events during general anesthesia should be carefully evaluated by the doctor before dental care commences. A confirmed or strongly suspected history, in the patient or biological family, of atypical pseudocholinesterase represents a relative contraindication to administration of ester-type local anesthetics.

There are absolute and relative contraindications to the administration of drugs. An *absolute contraindication* implies that under no circumstance should the drug in question be administered to the patient as the possibility of potentially toxic or lethal reactions is increased, whereas a *relative contraindication* means that the drug in question may be administered to the patient after careful weighing of the risk associated with use of the drug versus the potential benefit to be gained, and if an acceptable alternative drug is not available. However, the smallest clinically effective dose should always be used because the likelihood of adverse reaction to this drug is increased in the patient.

Amide Local Anesthetics

The biotransformation of amide local anesthetics is more complex than that of ester local anesthetics. The primary site of biotransformation of amide local anesthetics is the liver. Virtually the entire metabolic process occurs in the liver for lidocaine, mepivacaine, etidocaine, and bupivacaine. Prilocaine undergoes primary metabolism in the liver, with some also possibly occurring in the lung.^{13,14} Articaine, a hybrid molecule containing both ester and amide components, undergoes metabolism in both the blood (primarily) and the liver.^{15,16}

The rates of biotransformation of lidocaine, mepivacaine, etidocaine, and bupivacaine are similar. Therefore

liver function and hepatic perfusion significantly influence the rate of biotransformation of an amide local anesthetic. Approximately 70% of the administered lidocaine undergoes biotransformation in patients with normal liver function.⁵ Patients with lower-than-usual hepatic blood flow (hypotension, congestive heart failure) or poor liver function (cirrhosis) are unable to biotransform amide local anesthetics at a normal rate.^{17,18} This slower-than-normal biotransformation results in higher anesthetic blood levels and increased risk of toxicity. Significant liver dysfunction (American Society of Anesthesiologists [ASA] physical status classification system class 4 or 5) or heart failure (ASA class 4 or 5) represents a relative contraindication to the administration of amide local anesthetic drugs (Table 2.6). Articaine has a shorter half-life than other amides (27 minutes vs. 90 minutes) because a significant portion of its biotransformation occurs in the blood by the enzyme plasma cholinesterase.¹⁹

The biotransformation products of certain local anesthetics can possess significant clinical activity if they are permitted to accumulate in the blood. This may be seen in renal or cardiac failure and during periods of prolonged drug administration. A clinical example is the production of methemoglobinemia in patients receiving large doses of prilocaine.^{20,21} Prilocaine, the parent compound, does not produce methemoglobinemia, but orthotoluidine, a primary metabolite of prilocaine, does induce the formation

TABLE 2.6 Lidocaine Disposition in Various Groups of Patients

Group	Lidocaine Half-Life (h)	Mean Total Body Clearance (mL/kg/min)
Normal	1.8	10
Heart failure	1.9	6.3
Hepatic disease	4.9	6
Renal disease	1.3	13.7

Data from Thomson PD, Melmon KL; Richardson JA, et al. Lidocaine pharmacokinetics in advanced heart failure, liver disease, and renal failure in humans. *Ann Intern Med.* 1973;78:499–513.

of methemoglobin, which is responsible for methemoglobinemia. When methemoglobin blood levels become elevated, clinical signs and symptoms are observed. Methemoglobinemia is discussed more fully in Chapter 10. Another example of pharmacologically active metabolites is the sedative effect occasionally observed after lidocaine administration. Lidocaine does not produce sedation; however, two metabolites—monoethylglycinexylidide and glycinexylidide—are thought to be responsible for this clinical action.²²

The metabolic pathways of lidocaine and prilocaine are shown in Figs. 2.4 and 2.5.

DEVELOPMENT OF LOCAL ANESTHETIC AGENTS: TIMELINE

Esters

Cocaine Procaine Tetracaine Chloroprocaine



1884 1905 1932 1933 1948 1955 1956 1960 1963 1971 1975 1997 1999

Amides

Dibucaine Lidocaine Mepivacaine Prilocaine Bupivacaine Etidocaine Articaine Ropivacaine Levobupivacaine

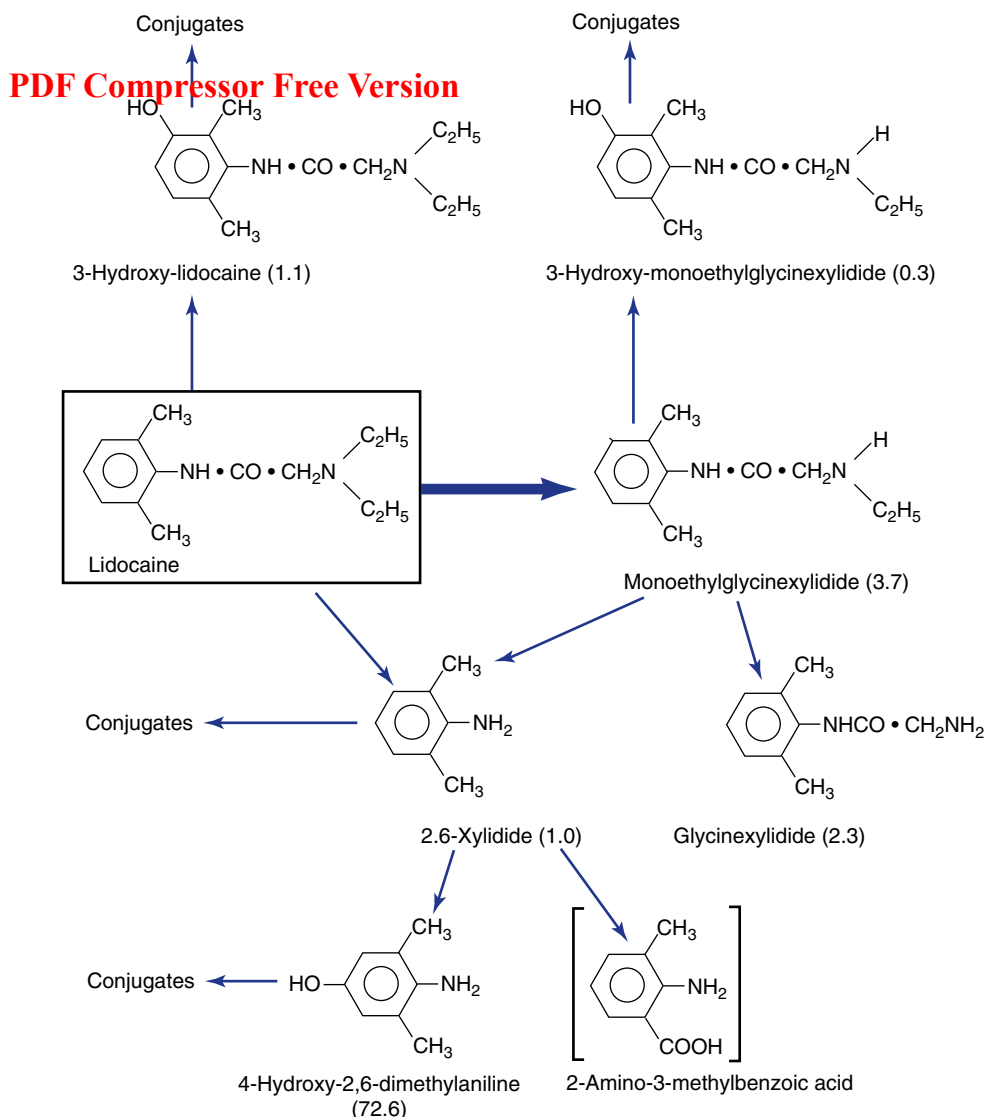
Excretion

The kidneys are the primary excretory organ for both the local anesthetic and its metabolites. A proportion of a given dose of local anesthetic is excreted unchanged in the urine. This proportion varies according to the drug. Esters appear only in very small concentrations as the parent compound in the urine because they are hydrolyzed almost completely in the plasma. Procaine appears in the urine as PABA (90%) with 2% unchanged. Ten percent of a cocaine dose is found in the urine unchanged. Amides are usually present in the urine as the parent compound in a greater percentage than the esters, primarily because of their more complex process of biotransformation. Although the percentages of parent drug found in urine differ from study to study, less than 3% lidocaine, 1% mepivacaine, and 1% etidocaine is found unchanged in the urine.

Patients with significant renal impairment may be unable to eliminate the parent local anesthetic compound or its major metabolites from the blood, resulting in slightly elevated blood levels and therefore increased potential for toxicity. This may occur with the esters or amides, and is especially likely with cocaine. Thus significant renal disease (ASA class 4 or 5) represents a relative contraindication to the administration of local anesthetics. This includes patients undergoing renal dialysis and those with chronic glomerulonephritis or pyelonephritis.

Systemic Actions of Local Anesthetics

Local anesthetics are chemicals that reversibly block action potentials in all excitable membranes (see Chapter 1). The central nervous system (CNS) and the CVS therefore are



• **Fig. 2.4** Metabolic pathways of lidocaine. Percentages of the dose found in urine are indicated in parentheses. (From Kennaghan JB, Boyes RN. The tissue distribution, metabolism, and excretion of lidocaine in rats, guinea pigs, dogs and man. *J Pharmacol Exp Ther.* 1972;180[2]:454-463.)

especially susceptible to their actions. Most of the systemic actions of local anesthetics are related to their blood or plasma level in a target organ (CNS, CVS). The higher the blood level, the greater will be the clinical action.

Centbuclidine (a quinoline derivative) has proved to be five to eight times as potent a local anesthetic as lidocaine, with an equally rapid onset of action and an equivalent duration.^{23,24} Of potentially great importance is the finding that it does not adversely affect the CNS or CVS, except in very high doses. It has been used both by injection and by topical application in ophthalmic surgery but not, as yet, in dentistry.^{25,26}

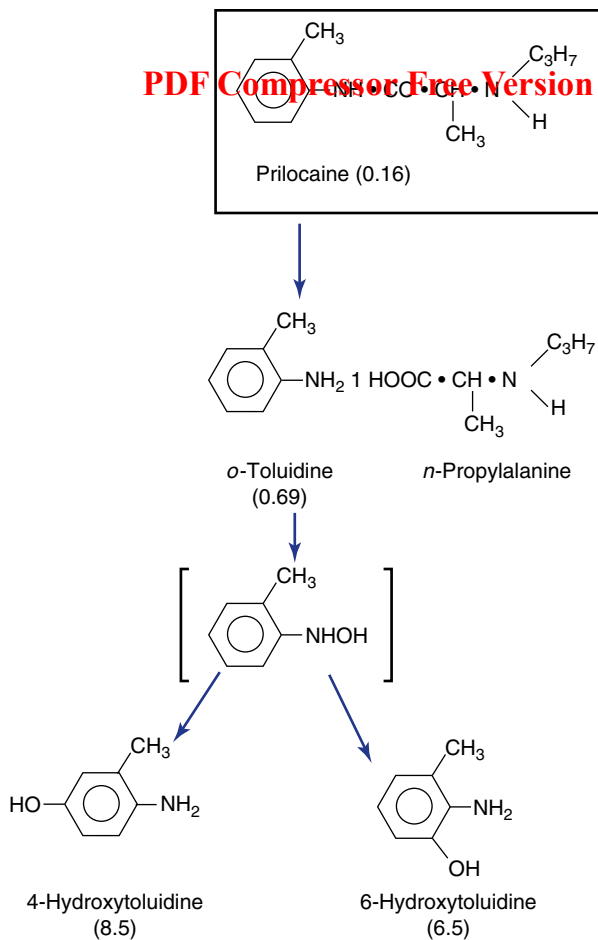
Local anesthetics are absorbed from their site of administration into the circulatory system, which effectively dilutes them and carries them to all cells of the body. The resulting blood level of the local anesthetic depends on its rate of uptake from the site of administration into the circulatory system (increasing the blood level), and on the rates of

distribution in tissue and biotransformation (in the liver), processes that remove the drug from the blood (decreasing the blood level) (see Fig. 2.2).

Central Nervous System

Local anesthetics readily cross the blood-brain barrier. Their pharmacologic action on the CNS is one of depression. At low (therapeutic, nontoxic) blood levels, no CNS effects of any clinical significance have been noted. At higher (toxic, overdose) levels the primary clinical manifestation is a generalized tonic-clonic convulsion. Between these two extremes exists a spectrum of other clinical signs and symptoms (see Box 2.2).

It is important to note that individual patients may respond either more positively or more negatively to doses or blood levels of a drug that are considered to be "normal" (e.g., within an acceptable range). These reactions are



• **Fig. 2.5** Metabolic pathways of prilocaine. Percentages of the dose found in urine are indicated in parentheses.

• BOX 2.2 Preconvulsive Signs and Symptoms of Central Nervous System Toxicity

Signs (Objectively Observable)

Slurred speech
Shivering
Muscular twitching
Tremor of muscles of face and distal extremities
Generalized lightheadedness
Dizziness
Visual disturbances (inability to focus)
Auditory disturbance (tinnitus)
Drowsiness
Disorientation

Symptoms (Subjectively Felt)

Numbness of tongue and circumoral region
Warm, flushed feeling of skin
Pleasant dreamlike state

based on where that individual lies on a normal distribution curve—commonly called a *bell-shaped curve* (Fig. 4.1). (The normal distribution curve is described more fully in [Chapter 4](#).) However, approximately 15% of persons are “hyperresponders” to an “average” dose of a given drug. Within this

TABLE 2.7 Lidocaine Blood Levels and Seizure Activity

Clinical Situation	Lidocaine Blood Level ($\mu\text{g/mL}$)
Anticonvulsive level	0.5–4
Preseizure signs and symptoms	4.5–7
Tonic-clonic seizure	>7.5

15% there is a normal distribution curve, so yet another 15% of these persons would be considered as “extreme hyperresponders.” In such an individual an “average” or “normal” dose of a drug could result in the manifestation of significant signs and symptoms of toxicity (overdose).

Anticonvulsant Properties

The “classic” overdose reaction to a local anesthetic is a generalized tonic-clonic convulsion. Some local anesthetics (e.g., procaine, lidocaine, mepivacaine, prilocaine, and even cocaine) have demonstrated anticonvulsant properties.^{27,28} These occur at a blood level considerably below that at which the same drugs produce seizure activity. Values for anticonvulsive blood levels of lidocaine are shown in [Table 2.7](#).²⁹

Procaine, mepivacaine, and lidocaine have been used intravenously to terminate or decrease the duration of both grand mal and petit mal seizures.^{27,30} Of the local anesthetics tested, lidocaine appeared to be the most promising anticonvulsant as it exhibits the widest therapeutic range: a three-fold margin between seizure-protecting and seizure-inducing doses.^{27,31} The anticonvulsant blood level of lidocaine (about 0.5 to 4 $\mu\text{g/mL}$) is very close to its cardiotherapeutic range (see later). It has been demonstrated to be effective in temporarily arresting seizure activity in most human epileptic patients.³² It was especially effective in interrupting status epilepticus at therapeutic doses of 2 to 3 mg/kg when given intravenously at a rate of 40 to 50 mg/min. In 1965 Bernhard and Bohm²⁷ reviewed the anticonvulsant use of local anesthetics in depth. This use of local anesthetics has been essentially dormant since then as more effective anticonvulsants have been introduced into clinical practice.

Mechanism of Anticonvulsant Properties of Local Anesthetics

Epileptic patients possess hyperexcitable cortical neurons at a site within the brain where the convulsive episode originates (called the *epileptic focus*). Local anesthetics, by virtue of their depressant actions on the CNS, raise the seizure threshold by decreasing the excitability of these neurons, thereby preventing or terminating seizures.

Preconvulsive Signs and Symptoms

With a further increase in the blood level of the local anesthetic to above its therapeutic level, adverse reactions may be observed. Because the CNS is much more susceptible than other systems to the actions of local anesthetics, it is

not surprising that the initial clinical signs and symptoms of overdose (toxicity) are of CNS origin. With lidocaine, this second phase is observed at a blood level of 4.5 to 7 $\mu\text{g}/\text{mL}$ in the average normal healthy patient.² Initial clinical signs and symptoms of CNS toxicity are usually excitatory in nature (see Box 2.2).

Lidocaine and procaine differ somewhat from other local anesthetics in that the usual progression of signs and symptoms just noted may not be seen. Lidocaine and procaine frequently produce an initial mild sedation or drowsiness (more common with lidocaine).³⁴ Because of this potential, “air crew/SOD (special operational duty) members cannot fly for at least 8 hours after receiving a local or regional anesthetic agent.”³⁵

Sedation may develop in place of the excitatory signs. If excitation or sedation is observed during the first 5 to 10 minutes after intraoral administration of a local anesthetic, it should serve as a warning to the clinician of a rising local anesthetic blood level and the possibility (if the blood level continues to rise) of a more serious reaction, including a generalized convulsive episode.

In patients receiving lidocaine in a dose of 1.0 mg/kg, less than 10% experience fleeting lightheadedness (the mean venous lidocaine blood level was 4.5 $\mu\text{g}/\text{mL}$).³⁶ Increasing the dose to 1.5 mg/kg produced a mean venous blood level of 5.4 $\mu\text{g}/\text{mL}$. Eighty percent of individuals experienced uncomfortable lightheadedness, often accompanied by slurring of speech. Lie et al.³⁷ evaluated 212 patients receiving intravenously administered lidocaine for prevention of ventricular fibrillation. Patients received a bolus of 100 mg of intravenously administered lidocaine as a loading dose, plus a 3 mg/min lidocaine infusion for the next 48 hours. Minor toxicity (drowsiness was most common) developed in 15% of patients. A blood level of 4.0 $\mu\text{g}/\text{mL}$ appeared to be the “dividing line” in these patients as symptom-free patients had a mean lidocaine blood level of 3.5 $\mu\text{g}/\text{mL}$ while in the symptomatic patients the mean blood level was 4.2 $\mu\text{g}/\text{mL}$.³⁷

Convulsive Phase

Further increase in local anesthetic blood level leads to signs and symptoms consistent with a generalized tonic-clonic convulsive episode. The duration of seizure activity is related to the local anesthetic blood level and is inversely related to

²All of these signs and symptoms, except for the sensation of circumoral and lingual numbness, are related to the direct depressant action of the local anesthetic on the CNS. Numbness of the tongue and circumoral regions is not caused by CNS effects of the local anesthetic.³³ Rather it is the result of a direct anesthetic action of the local anesthetic, present in high concentrations, on free nerve endings in these highly vascular tissues. The anesthetic has been transported to these tissues by the CVS. A dentist treating a patient might have difficulty conceptualizing why anesthesia of the tongue is considered to be a sign of a toxic reaction when lingual anesthesia is commonly produced after mandibular nerve blocks. Consider for a moment a physician administering a local anesthetic into the patient’s foot. Overly high blood levels would produce bilateral numbing of the tongue, as contrasted with the usual unilateral anesthesia seen after dental nerve blocks.

TABLE 2.8 Effects of PaCO₂ on the Convulsive Threshold (CD₁₀₀) of Various Local Anesthetics in Cats

Agent	CD ₁₀₀ (mg/kg)		Percent Change in CD ₁₀₀
	PaCO ₂ (25–40 Torr)	PaCO ₂ (6581 Torr)	
Procaine	35	17	51
Mepivacaine	18	10	44
Prilocaine	22	12	45
Lidocaine	15	7	53
Bupivacaine	5	2.5	50

Data from Englesson S, Grevsten S, Olin A. Some numerical methods of estimating acid-base variables in normal human blood with a haemoglobin concentration of 5 g/100 cm³. *Scand J Lab Clin Invest.* 1973;32:289–295.

the arterial partial pressure of carbon dioxide (CO₂).³⁸ At a normal arterial partial pressure of CO₂, a lidocaine blood level between 7.5 and 10 $\mu\text{g}/\text{mL}$ usually results in a convulsive episode. When CO₂ levels are increased, the blood level of the local anesthetic necessary for seizures decreases, while the duration of the seizure increases.³⁸ Seizure activity is generally self-limiting, because cardiovascular activity is usually not significantly impaired, and redistribution and biotransformation of the local anesthetic continue throughout the episode. This results in a decrease in anesthetic blood level and termination of seizure activity, usually within 1 minute (with airway maintenance).

However, several other mechanisms also at work act to prolong the convulsive episode. Both cerebral blood flow and cerebral metabolism are increased during local anesthetic-induced convulsions. Increased blood flow to the brain leads to an increase in the volume of local anesthetic being delivered to the brain, tending to prolong the seizure. Increased cerebral metabolism leads to a progressive metabolic acidosis as the seizure continues, tending to prolong seizure activity (by lowering the blood level of anesthetic necessary to provoke a seizure), even in the presence of a declining local anesthetic level in the blood. As noted in Tables 2.8 and 2.9, the dose of local anesthetic necessary to induce seizures is markedly diminished in the presence of hypercarbia (see Table 2.8) or acidosis (see Table 2.9).^{38,39}

Further increases in local anesthetic blood level result in cessation of seizure activity as electroencephalographic tracings become flattened, indicative of a generalized CNS depression. Respiratory depression also occurs at this time, culminating in respiratory arrest if anesthetic blood levels continue to rise. Respiratory effects are a result of the depressant action of the local anesthetic drug on the CNS.

Mechanism of Preconvulsant and Convulsant Actions

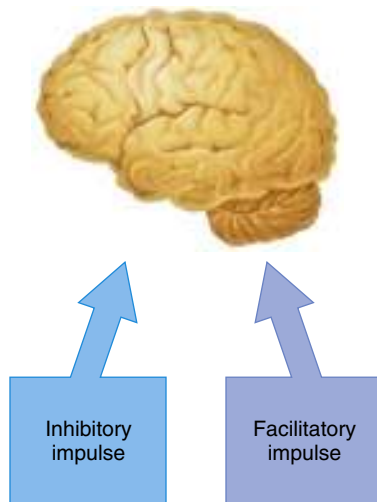
Local anesthetics exert a depressant action on excitable membranes, yet the primary clinical manifestation associated

TABLE 2.9 Convulsant Dose (CD₁₀₀) and Acid-Base Status^a

PaCO ₂ (mmHg)	pH 7.10	pH 7.20	pH 7.30	pH 7.40
30	—	—	27.5	26.6
40	—	20.6	21.4	22.0
60	13.1	15.4	17.5	—
80	11.3	14.3	—	—

^aIntravenous administration of lidocaine, 5 mg/kg per minute, cats; doses in milligrams per kilogram.

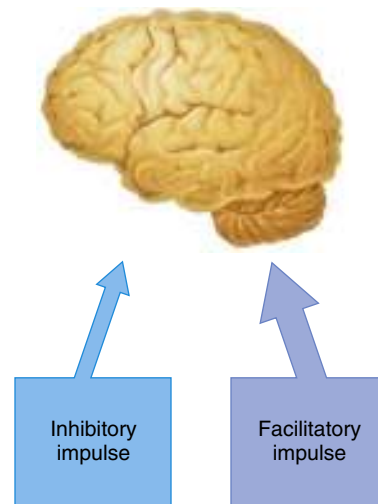
From Englesson S. The influence of acid-base changes on central nervous toxicity of local anaesthetic agents. *Acta Anaesthesiol Scand.* 1974;18:88–103.



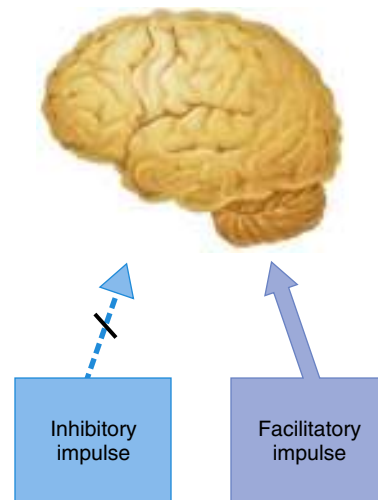
• **Fig. 2.6** Balance between inhibitory and facilitatory impulses in a normal cerebral cortex.

with high local anesthetic blood levels is related to varying degrees of CNS stimulation. How can a drug that depresses the CNS be responsible for the production of varying degrees of CNS stimulation, including tonic-clonic seizure activity? It is thought that local anesthetics produce clinical signs and symptoms of CNS excitation (including convulsions) through selective blockade of inhibitory pathways in the cerebral cortex.³⁹⁻⁴² De Jong⁴³ states that “inhibition of inhibition thus is a presynaptic event that follows local anesthetic blockade of impulses traveling along inhibitory pathways.”⁴³

The cerebral cortex has pathways of neurons that are essentially inhibitory and others that are facilitatory (excitatory). A state of balance is normally maintained between the degrees of effect exerted by these neuronal paths (Fig. 2.6). At preconvulsant local anesthetic blood levels, the observed clinical signs and symptoms are produced by the local anesthetic selectively depressing inhibitory neurons (Fig. 2.7). Balance is then tipped slightly in favor of excessive facilitatory (excitatory) input, leading to symptoms including tremor and slight agitation.



• **Fig. 2.7** In the preconvulsive stage of local anesthetic action, the inhibitory impulse is more profoundly depressed than the facilitatory impulse.



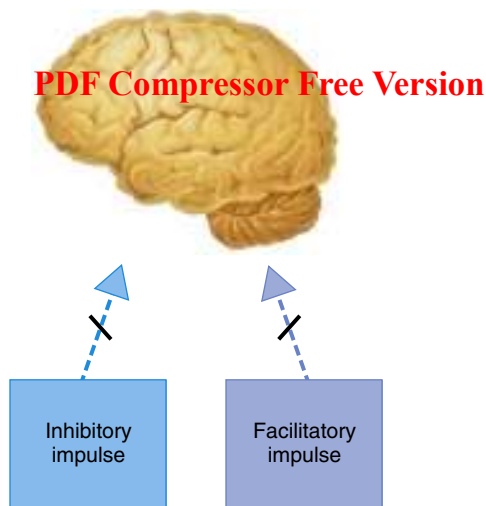
• **Fig. 2.8** In the convulsive stage of local anesthetic action, the inhibitory impulse is totally depressed, permitting unopposed facilitatory impulse activity.

At higher (convulsive) blood levels, inhibitory neuron function is completely depressed, allowing unopposed function of facilitatory neurons (Fig. 2.8). Pure facilitatory input without inhibition produces the tonic-clonic activity observed at these levels.

Further increases in anesthetic blood level lead to depression of both the facilitatory pathway and the inhibitory pathway, producing a generalized CNS depression (Fig. 2.9). The precise site of action of the local anesthetic within the CNS is not known but is thought to be at the inhibitory cortical synapses or directly on the inhibitory cortical neurons.

Analgesia

Local anesthetics possess a second action in relation to the CNS. Administered intravenously, they increase the pain reaction threshold and also produce a degree of analgesia.



• **Fig. 2.9** In the final stage of local anesthetic action, both inhibitory and facilitatory impulses are totally depressed, producing generalized central nervous system depression.

In the 1940s and 1950s procaine was administered intravenously for the management of chronic pain and arthritis.⁴⁴ The “procaine unit” was commonly used for this purpose; it consisted of 4 mg per kilogram of body weight administered over 20 minutes. The technique was ineffective for acute pain. Because of the relatively narrow safety margin between the analgesic actions of procaine and the occurrence of signs and symptoms of overdose, this technique is no longer in use today.

Mood Elevation

The use of local anesthetic drugs for mood elevation and rejuvenation has persisted for centuries, despite documentation of both catastrophic events (mood elevation) and lack of effect (rejuvenation).

Cocaine has long been used for its euphoria-inducing and fatigue-lessening actions, dating back to the chewing of coca leaves by Incas and other South American natives.^{45,46} Unfortunately, as is well documented today, prolonged use of cocaine leads to habituation. William Stewart Halsted (1852–1922), the father of American surgery, cocaine researcher, and the first person to administer a local anesthetic by injection, suffered greatly because of an addiction to cocaine.⁴⁷ In more recent times the sudden, unexpected deaths of several prominent professional athletes caused by cocaine and the addiction of many others clearly demonstrate the dangers involved in the casual use of potent drugs.^{48,49}

More benign, but totally unsubstantiated, is the use of procaine (Novocain) as a rejuvenating drug. Clinics professing to “restore youthful vigor” claim that procaine is a literal “fountain of youth.” These clinics operate primarily in central Europe and Mexico, where procaine is used under the proprietary name Gerovital. A recent Cochrane meta-analysis concludes: “This review suggests that the evidence for detrimental effects of procaine and its preparations is stronger than the evidence for benefit in preventing and/or

TABLE 2.10 Intravenous Dose of Local Anesthetic Agents Required for Convulsive Activity (CD_{100}) and Irreversible Cardiovascular Collapse (LD_{100}) in Dogs

Agent	CD_{100} (mg/kg)	LD_{100} (mg/kg)	LD_{100}/CD_{100} Agent Ratio
Lidocaine	22	76	3.5
Etidocaine	8	40	5.0
Bupivacaine	4	20	5.0
Tetracaine	5	27	5.4

Data from Liu P, et al. Acute cardiovascular toxicity of intravenous amide local anesthetics in anesthetized ventilated dogs. *Anesth Analg.* 1982;61:317–322.

treating dementia or cognitive impairment. However, the clear evidence of side effects suggest that the risks might outweigh the benefits.”⁵⁰

Cardiovascular System

Local anesthetics have a direct action on the myocardium and peripheral vasculature. In general, however, the CVS is more resistant than the CNS to the effects of local anesthetic drugs (Table 2.10).⁵¹

Direct Action on the Myocardium

Local anesthetics modify electrophysiologic events in the myocardium in a manner similar to their actions on peripheral nerves. As the local anesthetic blood level increases, the rate of rise of various phases of myocardial depolarization is reduced. No significant change in resting membrane potential occurs, and no significant prolongation of the phases of repolarization is seen.⁵²

Local anesthetics produce a myocardial depression related to the local anesthetic blood level. Local anesthetics decrease the electrical excitability of the myocardium, decrease conduction rate, and decrease the force of contraction.^{53–55}

Therapeutic advantage is taken of this depressant action in managing the hyperexcitable myocardium, which manifests itself as various dysrhythmias. Although many local anesthetics have demonstrated antidysrhythmic actions in animals, only procaine and lidocaine have gained significant clinical reliability in humans. Lidocaine is the most widely used and intensively studied local anesthetic in this regard.^{10,34,56,57}

Procainamide is the procaine molecule with an amide linkage replacing the ester linkage. Because of this, it is hydrolyzed much more slowly than procaine.⁵⁸

Tocainide, a chemical analogue of lidocaine, was introduced in 1981 as an oral antidysrhythmic drug because lidocaine is ineffective after oral administration because of a significant hepatic first-pass effect.^{59–61} Following its oral administration, lidocaine undergoes extensive hepatic first-pass metabolism. Its bioavailability is only 0.21 to 0.46 (79% and 54% metabolized, respectively).^{60,61}

• BOX 2.3 Signs & Symptoms of Local Anesthetic Overdose

Minimal to Moderate Overdose Levels

Signs
Talkativeness
Apprehension
Excitability
Slurred speech
Generalized stutter, leading to muscular twitching and tremor in the face and distal extremities
Euphoria
Dysarthria
Nystagmus
Sweating
Vomiting
Failure to follow commands or be reasoned with
Elevated blood pressure
Elevated heart rate
Elevated respiratory rate

Moderate to High Overdose Levels

Tonic-clonic seizure activity followed by
Generalized central nervous system depression
Depressed blood pressure, heart rate, and respiratory rate

From Malamed SF. *Medical Emergencies in the Dental Office*. 7th ed. St Louis: Mosby; 2015.

Symptoms (Progressive With Increasing Blood Levels)

Lightheadedness and dizziness
Restlessness
Nervousness
Sensation of twitching before actual twitching is observed (see “Generalized stutter” under “Signs”)
Metallic taste
Visual disturbances (inability to focus)
Auditory disturbances (tinnitus)
Drowsiness and disorientation
Loss of consciousness

Tocainide is effective in managing ventricular dysrhythmias but is associated with a 40% incidence of adverse effects, including nausea, vomiting, tremor, paresthesias, agranulocytosis, and pulmonary fibrosis.^{62,63} Tocainide worsens symptoms of congestive heart failure in about 5% of patients and may provoke dysrhythmias (i.e., is pro-dysrhythmic) in 1% to 8% of patients.⁶⁴ By 1984 its use was associated with cases of agranulocytosis, aplastic anemia, and thrombocytopenia, some of which were fatal. This led some regulatory authorities to restrict the indications for its use. The major manufacturer has subsequently restricted its use on a worldwide basis to the treatment of symptomatic ventricular dysrhythmias not responding to other therapy, or when other therapy is contraindicated.⁶⁵

Blood levels of lidocaine usually noted after intraoral injection of one or two dental cartridges, 0.5 to 2 $\mu\text{g}/\text{mL}$, are not associated with cardiodepressant activity. Increasing lidocaine blood levels slightly is nontoxic and is associated with anti-dysrhythmic actions. Therapeutic blood levels of lidocaine for antidysrhythmic activity range from 1.8 to 6 $\mu\text{g}/\text{mL}$.^{55,66}

Lidocaine is administered intravenously as a bolus of 50 to 100 mg at a rate of 25 to 50 mg/min in management of ventricular tachycardia and ventricular fibrillation.⁶⁷ This dose is based on 1.0 to 1.5 mg per kilogram of body weight every 3 to 5 minutes, and is frequently followed by a continuous IV infusion of 1 to 4 mg/min. Signs and symptoms of local anesthetic overdose will be noted if the blood level rises beyond 6 $\mu\text{g}/\text{mL}$.⁶⁶ According to the 2015 American Heart Association guidelines for cardiopulmonary resuscitation and emergency cardiac care, lidocaine may be considered as

an alternative to amiodarone for management of ventricular fibrillation or pulseless ventricular tachycardia that is unresponsive to CPR, defibrillation, and vasopressor therapy.⁶⁷

Direct actions of local anesthetics on the myocardium at blood levels greater than the therapeutic (antidysrhythmic) level include a decrease in myocardial contractility and decreased cardiac output, both of which lead to circulatory collapse (see Table 2.10).

Box 2.3 summarizes the CNS and cardiovascular effects of increasing local anesthetic blood levels.

Direct Action on the Peripheral Vasculature

Cocaine is the only local anesthetic drug that consistently produces vasoconstriction at commonly used dosages.⁴ Ropivacaine produces cutaneous vasoconstriction, whereas its congener bupivacaine produces vasodilation.⁶⁸ All other injectable local anesthetics produce a peripheral vasodilation through relaxation of smooth muscle in the walls of blood vessels. This leads to increased blood flow to and from the site of local anesthetic deposition (see Table 2.1). Increased local blood flow increases the rate of drug absorption, in turn leading to decreased depth and duration of local anesthetic action, increased bleeding in the treatment area, and increased local anesthetic blood levels.

Table 2.11 provides examples of peak blood levels achieved after local anesthetic injection with and without the presence of a vasopressor.⁶⁸⁻⁷⁰

The primary effect of local anesthetics on blood pressure is hypotension. Procaine produces hypotension more frequently and significantly than does lidocaine: 50% of

TABLE
2.11

Peak Plasma Levels Following Local Anesthetic Administration With and Without a Vasopressor

PDF Compressor Free Version

Injection Type	Anesthetic	Dose	Epinephrine Dilution	Peak Level (µg/mL)
Infiltration	Lidocaine	400 mg	None	2.0
Infiltration	Lidocaine	400 mg	1:200,000	1.0
Intercostal	Lidocaine	400 mg	None	6.5
Intercostal	Lidocaine	400 mg	1:200,000	5.3
Intercostal	Lidocaine	400 mg	1:80,000	4.9
Infiltration	Mepivacaine	5 mg/kg	None	1.2
Infiltration	Mepivacaine	5 mg/kg	1:200,000	0.7

Data from Kopacz DJ, Carpenter RL, Mackay DL. Effect of ropivacaine on cutaneous capillary flow in pigs. *Anesthesiology*. 1989;71:69; Scott DB, Jebson PJR, Braid DP, et al. Factors affecting plasma levels of lignocaine and prilocaine. *Br J Anaesth*. 1972;44:1040–1049; Duhner KG, Harthorn JGL, Hebring BG, Lie T. Blood levels of mepivacaine after regional anaesthesia. *Br J Anaesth*. 1965;37:746–752.

patients in one study receiving procaine became hypotensive, compared with 6% of those receiving lidocaine.⁷¹ This action is produced by direct depression of the myocardium and smooth muscle relaxation in the vessel walls by the local anesthetic.

In summary, negative effects on the CVS are not noted until significantly elevated local anesthetic blood levels are reached. The usual sequence of local anesthetic-induced actions on the CVS is as follows:

1. At nonoverdose levels, a slight increase or no change in blood pressure occurs because of increased cardiac output and heart rate as a result of enhanced sympathetic activity; direct vasoconstriction of certain peripheral vascular beds is also noted.
2. At levels approaching, yet still below, overdose, a mild degree of hypotension is noted; this is produced by a direct relaxant action on the vascular smooth muscle.
3. At overdose levels, profound hypotension is caused by decreased myocardial contractility, cardiac output, and peripheral resistance.
4. At lethal levels, cardiovascular collapse is noted. This is caused by massive peripheral vasodilation and decreased myocardial contractility and heart rate (sinus bradycardia).
5. Certain local anesthetics such as bupivacaine (and to a lesser degree ropivacaine and etidocaine) may precipitate potentially fatal ventricular fibrillation.^{72,73}

Local Tissue Toxicity

Skeletal muscle appears to be more sensitive than other tissues to the local irritant properties of local anesthetics. Intramuscular and intraoral injection of articaine, lidocaine, mepivacaine, prilocaine, bupivacaine, and etidocaine can produce skeletal muscle alterations.^{74–77} It appears that longer-acting local anesthetics cause more localized skeletal muscle damage than shorter-acting anesthetics. The changes that occur in skeletal muscle are reversible, with muscle regeneration being complete within 2 weeks after local anesthetic

administration. These muscle changes have not been associated with any overt clinical signs of local irritation.

Respiratory System

Local anesthetics exert a dual effect on respiration. At non-overdose levels, they have a direct relaxant action on bronchial smooth muscle, whereas at overdose levels, they may produce respiratory arrest as a result of generalized CNS depression. In general, respiratory function is unaffected by local anesthetics until near-overdose levels are achieved.

Miscellaneous Actions

Drug Interactions

In general, CNS depressants (e.g., opioids, antianxiety drugs, phenothiazines, barbiturates) when administered in conjunction with local anesthetics lead to potentiation of the CNS-depressant actions of the local anesthetic. The conjoint use of local anesthetics and drugs that share a common metabolic pathway can produce adverse reactions. Both ester local anesthetics and the depolarizing muscle relaxant succinylcholine require plasma pseudocholinesterase for hydrolysis. Prolonged apnea may result from concomitant use of these drugs.⁷⁸

Drugs that induce the production of hepatic microsomal enzymes (e.g., barbiturates) may alter the rate at which amide local anesthetics are metabolized. Increased hepatic microsomal enzyme induction increases the rate of metabolism of the local anesthetic.

Specific drug-drug interactions related to the administration of local anesthetics are reviewed in [Chapter 10](#).

Malignant Hyperthermia

Malignant hyperthermia (MH; hyperpyrexia) is a pharmacogenic disorder in which a genetic variant in an individual alters that person's response to certain drugs. Acute clinical manifestations of MH include tachycardia, tachypnea, unstable blood pressure, cyanosis, respiratory and metabolic acidosis, fever (temperature as high as 42°C [108°F]), muscle

rigidity, and death. Mortality rates of 80% in the 1980s have been decreased to less than 5% (2006).⁷⁹ Many commonly used anesthetic agents are contraindicated in patients with

PDF Compressor Free Version

Until the late 1990s, the amide local anesthetics were thought to be capable of provoking MH and were considered to be absolutely contraindicated in MH-susceptible patients.⁸⁰ The Malignant Hyperthermia Association of the United States, after evaluating recent clinical research, concluded that no documented cases in the medical or dental literature (over the past 40 years) support the concept of amide anesthetics triggering MH.⁸⁰⁻⁸⁵

The Malignant Hyperthermia Association of the United States maintains a website with information for both health care providers and patients: <https://www.mhaus.org>.

References

1. Aps C, Reynolds F. The effect of concentration in vasoactivity of bupivacaine and lignocaine. *Br J Anaesth*. 1976;48:1171-1174.
2. Covino BG. Pharmacology of local anaesthetic agents. *Br J Anaesth*. 1986;58:701-716.
3. Procaine Drug Monograph. November 17, 2018. www.clinicalkey.com; 1998. Accessed 27 November 2018.
4. Benowitz NL. Clinical pharmacology and toxicology of cocaine. *Pharmacol Toxicol*. 1993;72:1-12.
5. Arthur GR. Pharmacokinetics of local anesthetics. In: Strichartz GR, ed. *Local Anesthetics: Handbook of Experimental Pharmacology*. Vol. 81. Berlin: Springer-Verlag; 1987.
6. Hohnloser SH, Lange HW, Raeder E, et al. Short- and long-term therapy with tocainide for malignant ventricular tachyarrhythmias. *Circulation*. 1986;73:143-149.
7. Soliman IE, Broadman LM, Hannallah RS, McGill WA. Comparison of the analgesic effects of EMLA (eutectic mixture of local anesthetics) to intradermal lidocaine infiltration prior to venous cannulation in unpremedicated children. *Anesthesiology*. 1988;68:804-806.
8. Schreiber S, Ronfani L, Chiaffoni GP, et al. Does EMLA cream application interfere with the success of venipuncture or venous cannulation? A prospective multicenter observational study. *Eur J Pediatr*. 2013;172(2):265-268.
9. Otto CW. Cardiopulmonary resuscitation. In: Ortega R, ed. *Clinical Anesthesia*. Philadelphia: Lippincott Williams & Wilkins; 2013:1684.
10. Haugh KH. Antidysrhythmic agents at the turn of the twenty-first century: a current review. *Crit Care Nurs Clin North Am*. 2002;14:13-69.
11. Kalow W. Hydrolysis of local anesthetics by human serum cholinesterase. *J Pharmacol Exp Ther*. 1952;104:122-134.
12. Watson CB. Respiratory complications associated with anesthesia. *Anesth Clin North Am*. 2002;20:375-399.
13. Gutenberg LL, Chen JW, Trapp L. Methemoglobin levels in generally anesthetized pediatric dental patients receiving prilocaine versus lidocaine. *Anesth Prog*. 2013;60(3):99-108.
14. Arthur GR. *Distribution and Elimination of Local Anesthetic Agents: The Role of the Lung, Liver, and Kidneys*, PhD Thesis. Edinburgh: University of Edinburgh; 1981.
15. Oertel R, Berndt A, Kirch W. Saturable in vitro metabolism of articaine by serum esterases: does it contribute to the resistance of the local anesthetic effect? *Reg Anesth*. 1996;21:576-581.
16. Oertel R, Rahn R, Kirch W. Clinical pharmacokinetics of articaine. *Clin Pharmacokinet*. 1997;33(6):417-425.
17. Nation RL, Triggs EJ. Lidocaine kinetics in cardiac patients and aged subjects. *Br J Clin Pharmacol*. 1977;4:439-448.
18. Klotz U. Antiarrhythmics: elimination and dosage considerations in hepatic impairment. *Clin Pharmacokinet*. 2007;46(12):985-986.
19. Oertel R, Rahn R, Kirch W. Clinical pharmacokinetics of articaine. *Clin Pharmacokinet*. 1997;33:617-625.
20. Prilocaine-induced methemoglobinemia—Wisconsin, 1993. *MMWR Morb Mortal Wkly Rep*. 1994;43:3555-3557.
21. Wilburn-Goo D, Lloyd LM. When patients become cyanotic: acquired methemoglobinemia. *J Am Dent Assoc*. 1999;130:626-631.
22. Strong JM, Parker M, Atkinson AJ Jr. Identification of glycinoxylidide in patients treated with intravenous lidocaine. *Clin Pharmacol Ther*. 1973;14:67-72.
23. Gupta PP, Tangri AN, Saxena RC, Dhawan BN. Clinical pharmacology studies on 4-N-butylamino-1,2,3,4-tetrahydroacridine hydrochloride (Centbucridine), a new local anaesthetic agent. *Indian J Exp Biol*. 1982;20:344-346.
24. Vacharajani GN, Parikh N, Paul T, Satoskar RS. A comparative study of centbucridine and lidocaine in dental extraction. *Int J Clin Pharmacol Res*. 1983;3:251-255.
25. Beri S, Biswas NR, Shende DR, Das GK, Pandey RM, Ghose S. Injectable centbucridine and lidocaine hydrochloride for intraocular surgery. *Ophthalmic Surg Lasers*. 1997;28(12):1027-1029.
26. Ghose S, Biswas NR, Das GK, et al. A prospective randomized double masked controlled clinical trial to determine the efficacy of multiple drop centbucridine as an ocular surface anesthetic. *Indian J Physiol Pharmacol*. 2004;48(4):466-470.
27. Bernhard CG, Bohm E. *Local Anesthetics as Anticonvulsants: A Study on Experimental and Clinical Epilepsy*. Stockholm: Almqvist & Wiksell; 1965.
28. Bernhard CG, Bohm E, Wiesel T. On the evaluation of the anti-convulsive effect of different local anesthetics. *Arch Int Pharmacodyn Ther*. 1956;108:392-407.
29. Julien RM. Lidocaine in experimental epilepsy: correlation of anticonvulsant effect with blood concentrations. *Electroencephalogr Clin Neurophysiol*. 1973;34:639-645.
30. Berry CA, Sanner JH, Keasling HH. A comparison of the anticonvulsant activity of mepivacaine and lidocaine. *J Pharmacol Exp Ther*. 1961;133:357-363.
31. De Jong RH. Therapeutic properties of local anesthetics. In: *Local Anesthetics*. St Louis: Mosby; 1994:257.
32. Walker IA, Slovis CM. Lidocaine in the treatment of status epilepticus. *Acad Emerg Med*. 1997;4:918-922.
33. Chen AH. Toxicity and allergy to local anesthesia. *J Calif Dent Assoc*. 1998;26:983-992.
34. Katz J, Feldman MA, Bass EB, et al. Injectable versus topical anesthesia for cataract surgery: patient perceptions of pain and side effects. *Ophthalmology*. 2000;107:2054-2060.
35. Official Air Force Aerospace Medicine Approved Medications. Effective: 5 June 2014 Approved by AF/SG3P on 5 June 2014.
36. Klein SW, Sutherland RIL, Morch JE. Hemodynamic effects of intravenous lidocaine in man. *Can Med Assoc J*. 1968;99:472-475.
37. Lie KI, Wellens HJ, van Capelle FJ, et al. Lidocaine in the prevention of primary ventricular fibrillation: a double-blind, randomized study of 212 consecutive patients. *N Engl J Med*. 1974;291:1324-1326.
38. Barcelos KC, Furtado DP, Ramacciato JC, Cabral AM, Haas DA. Effect of PaCO₂ and PaO₂ on lidocaine and articaine toxicity. *Anesth Prog*. 2010;57(3):104-108.
39. Englesson S, Grevsten S, Olin A. Some numerical methods of estimating acid-base variables in normal human blood with a haemoglobin concentration of 5 g-100 cm³. *Scand J Lab Clin Invest*. 1973;32:289-295.

40. de Jong RH, Robles R, Corbin RW. Central actions of lidocaine-synaptic transmission. *Anesthesiology*. 1969;30(19).
41. Huffman RD, Yin GW. Effects of diphenhydramine, ethanol and lidocaine on central inhibition. *Int J Neuropharmacol*. 1969;8:217.
42. Tanaka K, Yamasaki M. Blocking of cortical inhibitory synapses by intravenous lidocaine. *Nature*. 1966;209:207.
43. de Jong RH. Central nervous system effects. In: *Local Anesthetics*. St Louis: Mosby; 1994:286.
44. Graubard DJ, Peterson MC. *Clinical Uses of Intravenous Procaine*. Springfield: Charles C Thomas; 1950.
45. Garcilasso de la Vega. Commentarios reales de los Incas (1609–1617). In: Freud S, ed. *Uber Coca*. Vienna: Moritz Perles; 1884.
46. Disertacion sobre el aspecto, cultivo, comercio y virtudes de la famosa planta del Peru nombrado coca: Lima, 1794. In: Freud S, ed. *Uber Coca*. Vienna: Moritz Perles; 1884.
47. Olch PD, William S. Halsted and local anesthesia: contributions and complications. *Anesthesiology*. 1975;42:479–486.
48. Loper KA. Clinical toxicology of cocaine. *Med Toxicol Adverse Drug Exp*. 1989;4(3):174–185.
49. Harriston k, Jenkins S. Maryland basketball star Len Bias is dead at 22. *Washington Post*. 1986.
50. Szatmari S, Berezcki D. Procaine treatment for cognition and dementia. *Cochrane Database Syst Rev*. 2008;4:CD005993.
51. Scott DB. Toxicity caused by local anaesthetic drugs. *Br J Anaesth*. 1981;53:553–554.
52. Pinter A, Dorian P. Intravenous antiarrhythmic agents. *Curr Opin Cardiol*. 2001;16:17–22.
53. Sugi K. Pharmacological restoration and maintenance of sinus rhythm by antiarrhythmic agents. *J Cardiol*. 1999;33(suppl 1):59–64.
54. Alexander JH, Granger CB, Sadowski Z, et al. Prophylactic lidocaine use in acute myocardial infarction: incidence and outcomes from two international trials. *Am Heart J*. 1999;137:799–805.
55. Cannom DS, Prystowsky EN. Management of ventricular arrhythmias: detection, drugs, and devices. *JAMA*. 1999;281:272–279.
56. Tan HL, Lie KI. Prophylactic lidocaine use in acute myocardial infarction revisited in the thrombolytic era. *Am Heart J*. 1999;137:570–573.
57. Kowey PR. An overview of antiarrhythmic drug management of electrical storm. *Can J Cardiol*. 1996;12(suppl B):3B–8B; discussion 27B–28B.
58. Slavik RS, Tisdale JE, Borzak S. Pharmacologic conversion of atrial fibrillation: a systematic review of available evidence. *Prog Cardiovasc Dis*. 2001;44:221–252.
59. Lalka D, Meyer MB, Duce BR, Elvin AT. Kinetics of the oral antiarrhythmic lidocaine congener, tocainide. *Clin Pharmacol Ther*. 1976;19:757–766.
60. Pond SM, Tozer TN. First-pass elimination. Basic concepts and clinical consequences. *Clin Pharmacokinet*. 1984;9:1–25.
61. Bennett PN, Aarons LJ, Bending MR, Steiner JA, Rowland M. Pharmacokinetics of lidocaine and its deethylated metabolite: dose and time dependency studies in man. *J Pharmacol*. 1973;50:581–591.
62. Perlow GM, Jain BP, Pauker SC, Zarren HS, Wistran DC, Epstein RL. Tocainide-associated interstitial pneumonitis. *Ann Intern Med*. 1981;94(4 Pt 1):489–490.
63. Volosin K, Greenberg RM, Greenspon AJ. Tocainide associated agranulocytosis. *Am Heart J*. 1985;109:1392.
64. Bronheim D, Thys DM. Cardiovascular drugs. In: Longnecker DE, Tinker JH, Morgan GE Jr, eds. *Principles and Practice of Anesthesiology*. 2nd ed. St Louis: Mosby; 1998.
65. Department of Economic and Social Affairs of the United Nations Secretariat. Tocainide. In: *Consolidated List of Products Whose Consumption and/or Sale Have Been Banned, Withdrawn, Severely Restricted or Not Approved by Governments. 12th Issue, Pharmaceuticals*. New York: United Nations Publications Board; 2005:268.
66. Kudenchuk PJ. Advanced cardiac life support antiarrhythmic drugs. *Cardiol Clin*. 2002;20:19–87.
67. Link MS, Berkow LC, Kudenchuk PJ, et al. Part 7: adult advanced cardiovascular life support: 2015 American Heart Association guidelines update for cardiopulmonary resuscitation and emergency cardiovascular care. *Circulation*. 2015;132(suppl 2):S444–S464.
68. Kopacz DJ, Carpenter RL, MacKay DL. Effect of ropivacaine on cutaneous capillary flow in pigs. *Anesthesiology*. 1989;71(69).
69. Scott DB, Jebson PJR, Braid DP, Ortengren B, Frisch P. Factors affecting plasma levels of lignocaine and prilocaine. *Br J Anaesth*. 1972;44(10):1040–1049.
70. Duhner KG, Harthorn JGL, Hebring BG, Lie T. Blood levels of mepivacaine after regional anaesthesia. *Br J Anaesth*. 1965;37:746–752.
71. Kimmey JR, Steinhaus JE. Cardiovascular effects of procaine and lidocaine (Xylocaine) during general anesthesia. *Acta Anaesthesiol Scand*. 1959;3:9–15.
72. de Jong RH, Ronfeld R, DeRosa R. Cardiovascular effects of convulsant and supraconvulsant doses of amide local anesthetics. *Anesth Analg*. 1982;61(3).
73. Feldman HS, Arthur GR, Covino BG. Comparative systemic toxicity of convulsant and supraconvulsant doses of intravenous ropivacaine, bupivacaine and lidocaine in the conscious dog. *Anesth Analg*. 1989;69:794.
74. Zink W, Graf BM, Sinner B, Martin E, Fink RH, Kunst G. Differential effects of bupivacaine on intracellular Ca^{2+} regulation: potential mechanisms of its myotoxicity. *Anesthesiology*. 2002;97(3):710–716.
75. Irwin W, Fontaine E, Agnolucci L, et al. Bupivacaine myotoxicity is mediated by mitochondria. *J Biol Chem*. 2002;277:12221–12227.
76. Benoit PW, Yagiela JA, Fort NF. Pharmacologic correlation between local anesthetic-induced myotoxicity and disturbances of intracellular calcium distribution. *Toxicol Appl Pharmacol*. 1980;52:187–198.
77. Hinton RJ, Dechow PC, Carlson DS. Recovery of jaw muscle function following injection of a myotoxic agent (lidocaine-epinephrine). *Oral Surg Oral Med Oral Pathol*. 1986;59:247–251.
78. Bevan DR, Donati F. Succinylcholine apnoea: attempted reversal with anticholinesterases. *Can Anaesth Soc J*. 1983;30(5):536–539.
79. Rosenberg H, Pollock N, Schiemann A, Bulger T, Stowell K. Malignant hyperthermia: a review. *Orpanet J Rare Dis*. 2015;10:93.
80. Denborough MA, Forster JF, Lovell RR, et al. Anaesthetic deaths in a family. *Br J Anaesth*. 1962;34:395–396.
81. Reifensstahl EF, Rowshan HH. Malignant hyperthermia and its implications in general dentistry. *Gen Dent*. 2009;57(3):242–246.
82. Laureano F, Rodrigues J, de Oliveira N, et al. Successful management of malignant hyperthermia during orthognathic surgery: a case report. *J Oral Maxillofac Surg*. 2008;66(7):1485–1488.
83. Paasuke PT, Brownell AKW. Amine local anaesthetics and malignant hyperthermia (editorial). *Can Anaesth Soc J*. 1986;33:126–129.
84. Collins CP, Beirne OR. Concepts in the prevention and management of malignant hyperthermia. *J Oral Maxillofac Surg*. 2003;61(11):1340–1345.
85. Malignant Hyperthermia Association of the United States. <https://www.mhaus.org>. Accessed November 27, 2017.

Pharmacology of Vasoconstrictors

All clinically effective injectable local anesthetics are vasodilators. The degree of vasodilation ranges from significant (procaine) to minimal (prilocaine, mepivacaine) as well as with both the injection site and individual patient response. After deposition of a local anesthetic into tissues, blood vessels (arterioles and capillaries primarily) in the area dilate, resulting in increased perfusion at the site, leading to the following reactions:

1. an increased rate of absorption of the local anesthetic into the cardiovascular system, which in turn removes it from the injection site (redistribution of the drug);
2. higher plasma levels of the local anesthetic, with an attendant increase in the risk of local anesthetic toxicity (overdose);
3. decrease in both the depth and the duration of anesthesia because the local anesthetic is removed from the site of injection more rapidly;
4. increased bleeding at the site of treatment as a result of increased perfusion.

Vasoconstrictors are drugs that constrict blood vessels and thereby control tissue perfusion. They are added to local anesthetic solutions to oppose the inherent vasodilatory actions of the local anesthetics. Vasoconstrictors are important additions to a local anesthetic solution for the following reasons:

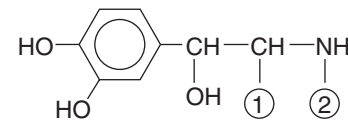
1. By constricting blood vessels, vasoconstrictors decrease blood flow (perfusion) to the site of drug administration.
2. Absorption of the local anesthetic into the cardiovascular system is slowed, resulting in lower anesthetic blood levels.^{1,2} Table 3.1 compares blood levels of local anesthetic both with and without a vasoconstrictor.¹
3. Local anesthetic blood levels are lowered, thereby decreasing the risk of local anesthetic toxicity from overadministration of the drug. (Overdose from rapid intravascular injection can still occur.)
4. More local anesthetic diffuses into the nerve, where it remains longer, thereby increasing (in some cases significantly,³ in others minimally⁴) the duration of action of most local anesthetics.
5. Vasoconstrictors decrease bleeding at the site of administration. Their inclusion in the local anesthetic solution is useful when increased bleeding is anticipated (e.g., during a surgical procedure).^{5,6}

The vasoconstrictors commonly used in conjunction with injected local anesthetics are chemically identical or similar to the sympathetic nervous system mediators epinephrine and norepinephrine. The actions of the vasoconstrictors so resemble the response of adrenergic nerves to stimulation that they are classified as sympathomimetic, or adrenergic, drugs. These drugs have many clinical actions besides vasoconstriction.

Sympathomimetic drugs may also be classified according to their chemical structure and mode of action.

Chemical Structure

Classification of sympathomimetic drugs by chemical structure is related to the presence or absence of a catechol nucleus. Catechol is also known as *o*-dihydroxybenzene. Sympathomimetic drugs that have hydroxyl (OH) substitutions at the third and fourth positions of the aromatic ring are termed *catechols*.



	①	②
Epinephrine	H	CH ₃
Levonordefrin	CH ₃	H
Norepinephrine	H	H

If they also contain an amine group (NH₂) attached to the aliphatic side chain, they are called *catecholamines*. Epinephrine, norepinephrine, and dopamine are the naturally occurring catecholamines of the sympathetic nervous system. Isoproterenol and levonordefrin are synthetic catecholamines.

Vasoconstrictors that do not possess OH groups at the third and fourth positions of the aromatic molecule are not catechols but are amines because they have an NH₂ group attached to the aliphatic side chain.

TABLE 3.1 Effects of a Vasoconstrictor (Epinephrine 1:200,000) on Peak Local Anesthetic Levels in Blood

PDF Compressor Free Version

Local Anesthetic	Dose (mg)	Peak Level ($\mu\text{g/mL}$)	
		Without Vasoconstrictor	With Vasoconstrictor
Mepivacaine	500	4.7	3
Lidocaine	400	4.3	3
Prilocaine	400	2.8	2.6
Etidocaine	300	1.4	1.3

Data from Cannall H, Walters H, Beckett AH, Saunders A. Circulating blood levels of lignocaine after peri-oral injections. *Br Dent J.* 1975;138:87–93.

• BOX 3.1 Categories of Sympathomimetic Amines

Direct Acting	Indirect Acting	Mixed Acting
Epinephrine	Tyramine	Metaraminol
Norepinephrine	Amphetamine	Ephedrine
Levonordefrin	Methamphetamine	
Isoproterenol	Hydroxyamphetamine	
Dopamine		
Methoxamine		
Phenylephrine		

Catecholamines

Epinephrine
Norepinephrine
Levonordefrin
Isoproterenol
Dopamine

Noncatecholamines

Amphetamine
Methamphetamine
Ephedrine
Mephentermine
Hydroxyamphetamine
Metaraminol
Methoxamine
Phenylephrine

Felypressin, a synthetic analogue of the polypeptide vaso-pressin (antidiuretic hormone), is available in many countries as a vasoconstrictor. As of the time of writing (January 2018), felypressin is not available in the United States.

Modes of Action

Three categories of sympathomimetic amines are known: direct-acting drugs, which exert their action directly on adrenergic receptors; indirect-acting drugs, which act by releasing norepinephrine from adrenergic nerve terminals; and mixed-acting drugs, with both direct and indirect actions (Box 3.1).¹⁻³

Adrenergic Receptors

Adrenergic receptors are found in most tissues of the body. The concept of adrenergic receptors was proposed by Ahlquist⁷ in 1948, and is well accepted today. Ahlquist recognized two types of adrenergic receptors, termed *alpha* (α)

TABLE 3.2 Adrenergic Receptor Activity of Vasoconstrictors

Drug	α_1	α_2	β_1	β_2
Epinephrine	+++	+++	+++	+++
Norepinephrine	++	++	++	+
Levonordefrin	+	++	++	+

Relative potency of drugs is indicated as follows: +++, high; ++, intermediate; and +, low.

From Jastak JT, Yagiela JA, Donaldson D. *Local Anesthesia of the Oral Cavity*. Philadelphia: WB Saunders; 1995.

and *beta* (β), on the basis of inhibitory or excitatory actions of catecholamines on smooth muscle.

Stimulation of α receptors by a sympathomimetic drug usually produces a response that includes contraction of smooth muscle in blood vessels (vasoconstriction). On the basis of differences in their function and location, α receptors have been subcategorized. Whereas α_1 receptors are excitatory postsynaptic, α_2 receptors are inhibitory postsynaptic.⁸

Stimulation of β receptors produces smooth muscle relaxation (vasodilation and bronchodilation) and cardiac stimulation (increased heart rate and strength of contraction).

Beta receptors are further divided into β_1 and β_2 receptors: β_1 receptors are found in the heart and small intestine and are responsible for cardiac stimulation and lipolysis; β_2 receptors, found in the bronchi of the lungs, vascular beds, and uterus, produce bronchodilation and vasodilation.⁹

Table 3.2 illustrates the differences in degrees of α and β receptor activity of three commonly used vasoconstrictors.

Table 3.3 lists the systemic effects, based on α and β receptor activity, of epinephrine and norepinephrine.

Release of Catecholamines

Other sympathomimetic drugs, such as tyramine and amphetamine, act indirectly by causing the release of the catecholamine norepinephrine from storage sites in adrenergic nerve terminals. In addition, these drugs may exert direct action on α and β receptors.

TABLE 3.3 Systemic Effects of Sympathomimetic Amines

Effector Organ or Function

Cardiovascular System

	Epinephrine	Norepinephrine
Heart rate	+	–
Stroke volume	++	++
Cardiac output	+++	0, –
Dysrhythmias	++++	++++
Coronary blood flow	++	++

Blood Pressure

Systolic arterial	+++	+++
Mean arterial	+	++
Diastolic arterial	+, 0, –	++

Peripheral Circulation

Total peripheral resistance	–	++
Cerebral blood flow	+	0, –
Cutaneous blood flow	–	–
Splanchnic blood flow	+++	0, +

Respiratory System

Bronchodilation	+++	0
-----------------	-----	---

Genitourinary System

Renal blood flow	–	–
------------------	---	---

Skeletal Muscle

Muscle blood flow	+++	0, –
-------------------	-----	------

Metabolic Effects

Oxygen consumption	++	0, +
Blood glucose	+++	0, +
Blood lactic acid	+++	0, +

+, Increase; –, decrease; 0, no effect.

Data from Goldenberg M, Aranow H Jr, Smith AA, Faber M. Pheochromocytoma and essential hypertensive vascular disease. *Arch Intern Med.* 1950;86:823–836.

The clinical actions of this group of drugs therefore are quite similar to the actions of norepinephrine. Successively repeated doses of these drugs will be less effective than those given previously because of depletion of norepinephrine from storage sites. This phenomenon is termed *tachyphylaxis* and is not seen with drugs that act directly on adrenergic receptors.

Dilutions of Vasoconstrictors

The dilution of vasoconstrictors is commonly referred to as a *ratio* (e.g., 1:1000). Because the maximum doses of

vasoconstrictors are presented in milligrams, or more commonly today in micrograms, the following interpretations should enable the reader to convert these terms readily:

- A concentration of 1:1000 means that 1 g (1000 mg) of drug is contained in 1000 mL of solution.
- Therefore, a 1:1000 dilution contains 1000 mg in 1000 mL or 1.0 mg per milliliter of solution (1000 µg/mL).

Vasoconstrictors, as used in dental local anesthetic solutions, are much more dilute than the 1:1000 concentration described in the preceding paragraph. To produce these more dilute, clinically safer, yet effective concentrations, the 1:1000 dilution must be diluted further. This process is as follows:

- To produce a 1:10,000 concentration, 1 mL of a 1:1000 solution is added to 9 mL of solvent (e.g., sterile water); therefore 1:10,000 = 0.1 mg/mL (100 µg/mL).
- To produce a 1:100,000 concentration, 1 mL of a 1:10,000 concentration is added to 9 mL of solvent; therefore 1:100,000 = 0.01 mg/mL (10 µg/mL).

The milligram per milliliter and microgram per milliliter values of the various vasoconstrictor dilutions used in medicine and dentistry are shown in [Table 3.4](#).

The genesis of vasoconstrictor dilutions in local anesthetics began with the discovery of epinephrine in 1897 by Abel. In 1903 Braun¹⁰ suggested using epinephrine as a chemical tourniquet to prolong the duration of local anesthetics. Braun recommended the use of a 1:10,000 dilution of epinephrine, ranging to as dilute as 1:100,000, with cocaine in nasal surgery (a highly vascular area). It appears at present that an epinephrine concentration of 1:200,000 provides comparable results, with fewer systemic side effects. The 1:200,000 dilution, which contains 5 µg/mL (or 0.005 mg/mL), has become widely used in both medicine and dentistry, and is currently found for articaine, prilocaine, lidocaine (although not in North America), etidocaine, and bupivacaine. In several European and Asian countries, lidocaine with epinephrine concentrations of 1:300,000 and 1:400,000 is available in dental cartridges.

Although it is the most used vasoconstrictor in local anesthetics in both medicine and dentistry, epinephrine is *not* an ideal drug. The benefits to be gained from adding epinephrine (or any vasoconstrictor for that matter) to a local anesthetic solution must be weighed against any risks that might be present. Epinephrine is absorbed from the site of injection, just as is the local anesthetic. Measurable epinephrine blood levels are obtained, influencing the heart and blood vessels. Resting plasma epinephrine levels (39 pg/mL) are doubled after administration of one cartridge of lidocaine with epinephrine 1:100,000.¹¹ Elevation of epinephrine plasma levels is linearly dose dependent and persists from several minutes to 30 minutes after administration.¹² Contrary to a previously held position that intraoral administration of usual volumes of epinephrine produces no cardiovascular response, and that patients are more at risk from endogenously released epinephrine than they are from exogenously administered epinephrine,^{13,14} evidence now demonstrates that epinephrine plasma levels equivalent

TABLE 3.4 Concentrations of Clinically Used Vasoconstrictors

PDF Compressor Free Version

Dilution	Milligrams per Milliliter	Micrograms per Milliliter	Amount per 1.8-mL Cartridge (μg)	Therapeutic Use
1:1000	1.0	1000		Epinephrine—emergency medicine (IM/SC in anaphylaxis)
1:2500	0.4	400		Phenylephrine
1:10,000	0.1	100		Epinephrine—emergency medicine (IV/ET in cardiac arrest)
1:20,000	0.05	50	90	Levonordefrin—local anesthetic
1:30,000	0.033	33.3	73 (2.2-mL cartridge)	Norepinephrine—local anesthetic
1:50,000	0.02	20	36	Epinephrine—local anesthetic
1:80,000	0.0125	12.5	27.5 (2.2-mL cartridge)	Epinephrine—local anesthetic (United Kingdom)
1:100,000	0.01	10	18	Epinephrine—local anesthetic
1:200,000	0.005	5	9	Epinephrine—local anesthetic
1:400,000	0.0025	2.5	4.5	Epinephrine—local anesthetic

ET, Endotracheal; IM, intramuscular; IV, intravenous; SC, subcutaneous.

to those achieved during moderate to heavy exercise may occur after intraoral injection.^{15,16} These are associated with moderate increases in cardiac output and stroke volume (see the following section). Blood pressure and heart rate, however, are minimally affected at usual doses.¹⁷

In patients with preexisting cardiovascular or thyroid disease, the side effects of absorbed epinephrine must be weighed against those of elevated local anesthetic blood levels. It is currently thought that the cardiovascular effects of conventional epinephrine doses are of little practical concern, even in patients with heart disease.¹² However, even after usual precautions (e.g., aspiration, slow injection) have been taken, sufficient epinephrine can be absorbed to cause sympathomimetic reactions such as apprehension, tachycardia, sweating, and pounding in the chest (palpitation): the so-called epinephrine reaction.¹⁸

Intravascular administration of vasoconstrictors and their administration to sensitive individuals (hyperresponders), or the occurrence of unanticipated drug-drug interactions, can, however, produce significant clinical manifestations. Intravenous administration of 0.015 mg of epinephrine with lidocaine results in an increase in the heart rate ranging from 25 to 70 beats per minute, with elevations in systolic blood pressure from 20 to 70 mmHg.^{12,19,20} Occasional rhythm disturbances may be observed, and premature ventricular contractions are most often noted.

Other vasoconstrictors used in medicine and dentistry include norepinephrine, phenylephrine, levonordefrin, and felypressin. Norepinephrine, lacking significant β_2 actions, produces intense peripheral vasoconstriction with possible dramatic elevation of blood pressure, and is associated with a side effect ratio nine times higher than that of epinephrine.²¹ Although it is currently available in some countries

in local anesthetic solutions, the use of norepinephrine as a vasopressor in dentistry is diminishing and cannot be recommended. The use of a mixture of epinephrine and norepinephrine is to be absolutely avoided.²² Phenylephrine, a pure α -adrenergic agonist, theoretically possesses advantages over other vasoconstrictors. However, in clinical trials, peak blood levels of lidocaine were actually higher with phenylephrine 1:20,000 (lidocaine blood level 2.4 $\mu\text{g}/\text{mL}$) than with epinephrine 1:200,000 (1.4 $\mu\text{g}/\text{mL}$).²³ The cardiovascular effects of levonordefrin most closely resemble those of norepinephrine.²⁴ Felypressin was shown to be about as effective as epinephrine in reducing cutaneous blood flow.⁵

Epinephrine remains the most effective and the most used vasoconstrictor in medicine and dentistry.

Pharmacology of Specific Agents

The pharmacologic properties of the sympathomimetic amines commonly used as vasoconstrictors in local anesthetics are reviewed. Epinephrine is the most useful and represents the best example of a drug mimicking the activity of sympathetic discharge. Its clinical actions are reviewed in depth. The actions of other drugs are compared with those of epinephrine.

Epinephrine

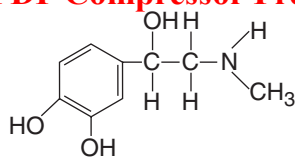
Proprietary Name

Adrenalin.

Chemical Structure

Epinephrine as the acid salt is highly soluble in water. Slightly acid solutions are relatively stable if they are protected from air. Deterioration (through oxidation) is hastened by heat

and the presence of heavy metal ions. Sodium bisulfite is commonly added to epinephrine solutions to delay this deterioration. **PDF Compressor Free Version**



Source

Epinephrine is available as a synthetic and is also obtained from the adrenal medulla of animals (epinephrine constitutes approximately 80% of adrenal medullary secretions). It exists in both levorotatory and dextrorotatory forms; the levorotatory form is approximately 15 times as potent as the dextrorotatory form.

Mode of Action

Epinephrine is a nonselective adrenergic agonist, stimulating α_1 -, α_2 -, β_1 -, and β_2 -adrenergic receptors. The degree of stimulation varies with the concentration of epinephrine at the specific receptor.

Systemic Actions

Myocardium

Epinephrine stimulates β_1 receptors of the myocardium. There is a positive inotropic (force of contraction) and a positive chronotropic (rate of contraction) effect. Both cardiac output and heart rate are increased.

Pacemaker Cells

Epinephrine stimulates β_1 receptors and increases the irritability of pacemaker cells, leading to an increased incidence of dysrhythmias. Ventricular tachycardia and premature ventricular contractions are common.

Coronary Arteries

Epinephrine produces dilation of the coronary arteries, increasing coronary artery blood flow.

Blood Pressure

Systolic blood pressure is increased. Diastolic pressure is decreased with small doses of epinephrine because of the greater sensitivity to epinephrine of β_2 receptors compared with α receptors in blood vessels supplying skeletal muscle. Diastolic blood pressure is increased with larger doses of epinephrine because of constriction of blood vessels supplying the skeletal muscles caused by α -receptor stimulation.

Cardiovascular Dynamics

The overall action of epinephrine on the heart and cardiovascular system is one of direct stimulation:

- increased systolic and diastolic pressures
- increased cardiac output
- increased stroke volume
- increased heart rate
- increased strength of contraction
- increased myocardial oxygen consumption

These actions lead to an overall *decrease* in cardiac efficiency.

Chaudhry et al.²⁵ assessed the cardiovascular responses to the administration of two 1.8-mL cartridges of 2% lidocaine with epinephrine 1:100,000 in hypertensive patients. Blood pressure and heart rate were recorded before injection and at 2 and 5 minutes after injection. A decrease in systolic blood pressure in patients with stage 2 hypertension (blood pressure between 160 and 179 mmHg and/or between 100 and 109 mmHg) was noted after 2 and 5 minutes, whereas the diastolic blood pressure decreased after the injections. Mean heart rate increased from 3 to 4 beats per minute except in stage 2 hypertensives where it slightly decreased.²⁵

In 2014 Scarparo et al.²⁶ assessed the effect on cardiovascular activity of 2% mepivacaine with epinephrine 1:100,000 in patients undergoing third molar extraction receiving 5.4 mL (two-third molar extractions) or 10.8 mL (four-third molar extractions) of anesthetic—equivalent to 54 and 108 μg of epinephrine. Heart rate and blood pressure were monitored for 2 hours following injection of the local anesthetic. They concluded that there were no statistically significant differences in heart rate and blood pressure monitored before and after injection. Meral et al.²⁷ reported no significant changes in blood pressure, heart rate, or ECG in normotensive patients undergoing third molar extraction when 50 μg epinephrine was administered. In a study using articaine, either 1:100,000 or 1:200,000, via intraosseous injection in patients with irreversible pulpitis, Pereira et al.²⁸ demonstrated that there were no significant changes in heart rate, systolic blood pressure, diastolic blood pressure, oxygen saturation (SpO_2), and ECG in the patients studied.

Vasculature

The primary action of epinephrine is on smaller arterioles and precapillary sphincters. Blood vessels supplying the skin, mucous membranes, and kidneys primarily contain α receptors. Epinephrine produces constriction in these vessels. Vessels supplying the skeletal muscles contain both α and β_2 receptors, with β_2 receptors predominating. Small doses of epinephrine produce dilation of these vessels as a result of β_2 actions. β_2 receptors are more sensitive to epinephrine than are α receptors. Larger doses produce vasoconstriction because α receptors are stimulated.

Hemostasis

Clinically, epinephrine is used frequently as a vasoconstrictor for hemostasis during surgical procedures. Injection of epinephrine directly into surgical sites rapidly produces high tissue concentrations, predominant α -receptor stimulation, and hemostasis. As the tissue levels of epinephrine decrease over time, its primary action on blood vessels reverts to vasodilation because β_2 actions predominate; therefore it is common for some bleeding to be noted at about 6 hours after a surgical procedure. In a clinical trial involving extraction of third molars, postsurgical bleeding occurred in 13 of 16 patients receiving epinephrine with their local anesthetic for hemostasis, whereas none of 16 patients receiving local

anesthetic without a vasoconstrictor (mepivacaine plain) had bleeding 6 hours after surgery.²⁹ Additional findings of increased postoperative pain and increased bleeding were noted in the epinephrine-receiving group.²⁹

Respiratory System

Epinephrine primarily exerts a relaxant effect on bronchial smooth muscle via stimulation of β_2 receptors. β_2 stimulation also prevents mast cell secretion of histamine and other corticoids, thus antagonizing its effect on end organs and reversing bronchospasm and edema.³⁰ As such, epinephrine is an important drug for management of refractory episodes of bronchospasm (e.g., status asthmaticus).³¹

Central Nervous System

In usual therapeutic dosages, epinephrine is not a potent central nervous system (CNS) stimulant. Its CNS-stimulating actions become prominent when an excessive dose is administered.

Metabolism

Epinephrine increases oxygen consumption in all tissues. Through β action, it stimulates glycogenolysis in the liver and skeletal muscle, elevating blood glucose levels at plasma epinephrine concentrations of 150 to 200 pg/mL.³² The equivalent of four dental local anesthetic cartridges of epinephrine 1:100,000 must be administered to elicit this response.³³

Termination of Action and Elimination

The action of epinephrine is terminated primarily by its reuptake by adrenergic nerves. Epinephrine that escapes reuptake is rapidly inactivated in the blood by the enzymes catechol *O*-methyltransferase (COMT) and monoamine oxidase (MAO), both of which are present in the liver.³⁴ Only small amounts (approximately 1%) of epinephrine are excreted unchanged in the urine.

Side Effects and Overdose

The clinical manifestations of epinephrine overdose relate to CNS stimulation, and include increasing fear and anxiety, tension, restlessness, throbbing headache, tremor, weakness, dizziness, pallor, respiratory difficulty, and palpitation.

With increasing levels of epinephrine in the blood, cardiac dysrhythmias (especially ventricular) become more common; ventricular fibrillation is a rare but possible consequence. Dramatic increases in both systolic blood pressure (>300 mmHg) and diastolic blood pressure (>200 mmHg) may be noted, and have led to cerebral hemorrhage.³⁵ Anginal episodes may be precipitated in patients with coronary artery insufficiency. Because of the rapid inactivation of epinephrine, the stimulatory phase of the overdose (toxic) reaction is usually brief. Vasoconstrictor overdose is discussed in greater depth in [Chapter 18](#).

Clinical Applications

- Management of acute allergic reactions
- Management of refractory bronchospasm (status asthmaticus)

- Management of cardiac arrest
- As a vasoconstrictor, for hemostasis
- As a vasoconstrictor in local anesthetics to decrease absorption into the cardiovascular system
- As a vasoconstrictor in local anesthetics to increase the depth of anesthesia
- As a vasoconstrictor in local anesthetics to increase the duration of anesthesia
- To produce mydriasis

Availability in Dentistry

Epinephrine is the most potent and widely used vasoconstrictor in dentistry. It is available in the following dilutions and drugs:

Epinephrine Dilution	Local Anesthetic (Generic)
1:50,000	Lidocaine
1:80,000	Lidocaine (lignocaine) (United Kingdom)
1:100,000	Articaine Lidocaine
1:200,000	Articaine Bupivacaine Etidocaine ^a Lidocaine Mepivacaine ^b
1:300,000	Prilocaine Lidocaine ^b
1:400,000	Articaine ^b

^aNo longer marketed in dental cartridges in the United States (2002).

^bNot available in the United States (January 2018).

Maximum Doses

The least concentrated solution that produces effective pain control should be used. Lidocaine is available with two dilutions of epinephrine—1:50,000 and 1:100,000—in the United States and Canada, and with 1:80,000, 1:200,000, and 1:300,000 dilutions in other countries. The duration of effective pulpal and soft tissue anesthesia is equivalent with all forms. Therefore it is recommended (in North America) that the 1:100,000 epinephrine concentration be used with lidocaine when extended pain control is necessary. Where epinephrine 1:200,000 or epinephrine 1:300,000 is available with lidocaine, these concentrations are preferred for pain control.³⁶

That a vasoconstrictor is important for the production of more profound and longer-duration anesthesia is seen in a study by Pitt Ford et al.,³⁷ where either 1 to 2 mL of 2% plain lidocaine or with epinephrine 1:80,000 epinephrine were infiltrated at the apex of a maxillary incisor. The duration of pulpal anesthesia (determined with electric pulp testing) was 25.1 minutes (standard deviation [SD] 6.23 minutes) with the plain formulation compared with 100 minutes (SD 15.09 minutes) for the epinephrine-containing formulation. Himuro et al.³⁸ administered inferior alveolar nerve block with 2% lidocaine with epinephrine 1:80,000 and epinephrine 1:200,000. They found no significant difference in the onset and duration of anesthesia. However, with maxillary

TABLE 3.5 Recommended Maximum Doses of Epinephrine**PDF Compressor Free Version**

Epinephrine Concentration	Cartridges	
	Normal, Healthy Patient (ASA Class 1) ^a	Patient With Clinically Significant Cardiovascular Disease (ASA Class 3 or 4) ^b
1:50,000 (36 µg/cartridge)	5.5	1
1:100,000 (18 µg/cartridge)	11 ^c	2
1:200,000 (9 µg/cartridge)	22 ^c	4

^aMaximum epinephrine dose of 0.2 mg or 200 µg per appointment.
^bMaximum recommended dose of 0.04 or 40 µg per appointment.
^cActual maximum volume of administration is limited by the dose of the local anesthetic drug.
 ASA, American Society of Anesthesiologists.

TABLE 3.6 Means of Maximum Changes from the Baseline for Blood Pressure and Heart Rate^a

	Maximum Change in SBP (mmHg)	Maximum Change in DBP (mmHg)	Maximum Change in HR (Beats per Minute)
Hypertensive Patients			
Anesthesia with epinephrine	15.3	2.3	9.3
Anesthesia without epinephrine	11.7	3.3	4.7
Normotensive Patients			
Anesthesia with epinephrine	5.0	-0.7	6.3
Anesthesia without epinephrine ^a	5.0	4.0	0.7

^aUnweighted mean of participant means reported in three studies.

DBP, Diastolic blood pressure; HR, heart rate; SBP, systolic blood pressure.

Data from Agency for Healthcare Research and Quality. *Cardiovascular effects of epinephrine in hypertensive dental patients. Summary. Evidence report/Technology Assessment: Number 48.* AHRQ Publication Number 02-E005. Agency for Healthcare Research and Quality, Rockville;2002. <http://www.ahrq.gov/clinic/epcix.htm> (accessed 8 November 2018).

infiltration the 1:80,000 epinephrine solution provided pulpal anesthesia for 103.4 minutes (SD 18.5 minutes). The 1:200,000 epinephrine solution provided pulpal anesthesia for 52.0 minutes (SD 13.0 minutes), whereas plain lidocaine provided pulpal anesthesia for 23.0 minutes (SD 5.1 minutes).

The doses in Table 3.5 represent recommended maximums as suggested by this author. They are conservative figures but still provide the dental practitioner with adequate volumes to produce clinically acceptable anesthesia. The American Heart Association as far back as 1964 stated that “the typical concentrations of vasoconstrictors contained in local anesthetics are not contraindicated in patients with cardiovascular disease so long as preliminary aspiration is practiced, the agent is injected slowly, and the smallest effective dose is administered.”³⁹ In 1954 the New York Heart Association (predecessor to the American Heart Association) recommended that maximal epinephrine doses be limited to 0.2 mg per appointment.⁴⁰ In the following years, the American Heart Association recommended the restriction of epinephrine in local anesthetics when administered to patients with ischemic heart disease.⁴¹

In 2002 the Agency for Healthcare Research and Quality reviewed the published literature on the subject of the effects of epinephrine in dental patients with high blood pressure.⁴² The report reviewed six studies that evaluated the effects of dental treatment (extraction of teeth) in hypertensive patients when they received local anesthetics with and without epinephrine. The results suggest that hypertensive patients undergoing a tooth extraction will experience small increases in systolic blood pressure and heart rate associated with the use of a local anesthetic containing epinephrine. These increases associated with the use of epinephrine occur in addition to increases in systolic and diastolic blood pressures and heart rate associated with undergoing the procedure without epinephrine that are larger for hypertensive patients than for normotensive patients. No adverse outcomes were reported among any of the patients in the studies included in the review, and only one report of an adverse event associated with the use of epinephrine in local anesthetic in a hypertensive patient was identified in the literature (Table 3.6).⁴²

In cardiovascularly compromised patients, it seems prudent to limit or avoid exposure to vasoconstrictors,

if possible. These include poorly controlled American Society of Anesthesiologists (ASA) physical status classification system class 3 and greater cardiovascular risk patients and all ASA class 4 and greater cardiovascular risk patients (the ASA physical status classification system is discussed in depth in [Chapter 10](#)). However, as stated, the risk of epinephrine administration must be weighed against the benefits to be gained from its inclusion in the local anesthetic solution. *Can clinically adequate pain control be provided for this patient without a vasoconstrictor in the solution? What is the potential negative effect of poor anesthesia on endogenous release of catecholamines in response to sudden, unexpected pain?*

The use of vasoconstrictors in cardiovascularly compromised patients is reviewed in greater depth in [Chapter 22](#).

Hemostasis

Epinephrine-containing local anesthetic solutions are used, via infiltration into the surgical site, to prevent or to minimize hemorrhage during surgical and other procedures. The 1:50,000 dilution of epinephrine is more effective in this regard than less concentrated 1:100,000 or 1:200,000 solutions.⁴³ Epinephrine dilutions of 1:50,000 and 1:100,000 are considerably more effective in restricting surgical blood loss than are local anesthetics without vasoconstrictor additives.²⁹

Clinical experience has shown that effective hemostasis can be obtained with an epinephrine concentration of 1:100,000. Although the small volume of epinephrine 1:50,000 required for hemostasis does not increase a patient's risk, consideration should always be given to use of the 1:100,000 dilution, especially in patients known to be more sensitive to catecholamines. These include hyperresponders on the bell-shaped curve, as well as ASA class 3 or 4 risk cardiovascularly compromised individuals and geriatric patients.

Moore et al.⁴⁴ compared the hemostatic efficacy of 4% articaine with epinephrine dilutions of 1:100,000 and 1:200,000 for periodontal surgery. They concluded that for patients undergoing periodontal surgery, 4% articaine anesthetic formulations containing epinephrine (1:100,000 or 1:200,000) provided excellent surgical pain control. For patients who can tolerate higher amounts of epinephrine, the 4% articaine and epinephrine 1:100,000 formulation had the additional therapeutic advantage of providing better visualization of the surgical field and less bleeding.

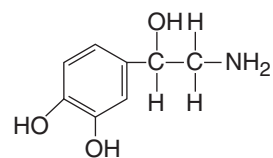
Norepinephrine (Levarterenol)

Proprietary Name

Levophed.

Chemical Structure

Norepinephrine (as the bitartrate) in dental cartridges is relatively stable in acid solutions, deteriorating on exposure to light and air. Acetone–sodium bisulfite is added to the cartridge to retard deterioration.



Source

Norepinephrine is available in both synthetic and natural forms. The natural form constitutes approximately 20% of the catecholamine production of the adrenal medulla. In patients with pheochromocytoma, a tumor of the adrenal medulla, norepinephrine may account for up to 80% of adrenal medullary secretions. It exists in both levorotatory and dextrorotatory forms; the levorotatory form is 40 times as potent as the dextrorotatory form. Norepinephrine is synthesized and stored in postganglionic adrenergic nerve terminals.

Mode of Action

Norepinephrine acts predominantly on α -adrenergic receptors to produce constriction of resistance and capacitance vessels, thereby increasing systemic blood pressure and coronary artery blood flow. Norepinephrine also acts on β_1 receptors, although quantitatively less than either epinephrine or isoproterenol. In relatively lower doses, the cardiac-stimulant effect of norepinephrine is predominant; with larger doses, the vasoconstrictor effect predominates.⁴⁵

The primary pharmacodynamic effects of norepinephrine are cardiac stimulation, particularly at lower doses, and vasoconstriction, which tends to predominate with moderate to higher doses of the drug. Metabolic effects observed with epinephrine, such as glycogenolysis, inhibition of insulin release, and lipolysis, also occur with norepinephrine but are much less pronounced.

The actions of norepinephrine are almost exclusively on α receptors (90%). Norepinephrine also stimulates β actions in the heart (10%). It is one-fourth as potent as epinephrine.

Systemic Actions

Myocardium

Norepinephrine has a positive inotropic action on the myocardium through β_1 stimulation.

Pacemaker Cells

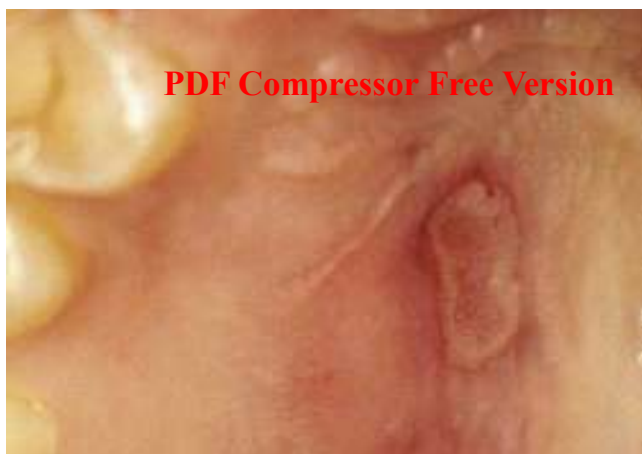Norepinephrine stimulates pacemaker cells and increases their irritability, leading to a greater incidence of cardiac dysrhythmias (β_1 action).

Coronary Arteries

Norepinephrine produces an increase in coronary artery blood flow through a vasodilatory effect.

Heart Rate

Norepinephrine produces a decrease in heart rate caused by reflex actions of the carotid and aortic baroreceptors and the vagus nerve after a marked increase in both systolic and diastolic blood pressures.



• **Fig. 3.1** Sterile abscess on the palate produced by excessive use of a vasoconstrictor (norepinephrine).

Blood Pressure

Both systolic blood pressure and diastolic blood pressure are increased, systolic to a greater extent. This effect is produced through the α -stimulating actions of norepinephrine, which lead to peripheral vasoconstriction and a concomitant increase in peripheral vascular resistance.

Cardiovascular Dynamics

The overall action of norepinephrine on the heart and cardiovascular system is as follows:

- increased systolic pressure
- increased diastolic pressure
- decreased heart rate
- unchanged or slightly decreased cardiac output
- increased stroke volume
- increased total peripheral resistance

Vasculature

Norepinephrine, through α stimulation, produces constriction of cutaneous blood vessels. This leads to increased total peripheral resistance and increased systolic and diastolic blood pressures.

The degree and duration of ischemia noted after norepinephrine infiltration into the hard palate have led to soft tissue necrosis (Fig. 3.1).

Respiratory System

Norepinephrine does not relax bronchial smooth muscle, as does epinephrine. It does, however, produce α -induced constriction of lung arterioles, which reduces airway resistance to a small degree. Norepinephrine is not clinically effective in the management of bronchospasm.

Central Nervous System

Similarly to epinephrine, norepinephrine does not exhibit CNS-stimulating actions at usual therapeutic doses; its CNS-stimulating properties are most prominent after overdose. The clinical manifestations are similar to those of epinephrine overdose (p. 46) but are less frequent and usually are not as severe.

Metabolism

Norepinephrine increases basal metabolic rate. Tissue oxygen consumption is also increased in the area of injection. Norepinephrine produces an elevation in blood glucose levels in the same manner as epinephrine but to a lesser degree.

Termination of Action and Elimination

The action of norepinephrine is terminated through its reuptake at adrenergic nerve terminals and its oxidation by MAO. Exogenous norepinephrine is inactivated by COMT.

Side Effects and Overdose

The clinical manifestations of norepinephrine overdose are similar to but less frequent and less severe than those of epinephrine. They normally involve CNS stimulation. Excessive levels of norepinephrine in the blood produce markedly elevated systolic and diastolic pressures, with increased risk of hemorrhagic stroke, headache, anginal episodes in susceptible patients, and cardiac dysrhythmias.

Extravascular injection of norepinephrine into tissues may produce necrosis and sloughing because of intense α stimulation. In the oral cavity, the most likely site to encounter this phenomenon is the hard palate (see Fig. 3.1). Use of norepinephrine should be avoided for vasoconstriction purposes (e.g., hemostasis), especially on the palate. An increasing number of authorities have stated that norepinephrine should not be used at all with local anesthetics.^{36,46}

Clinical Applications

Norepinephrine is used as a vasoconstrictor in local anesthetics and for the management of hypotension.

Availability in Dentistry

In North America, norepinephrine is not available in local anesthetic solutions used in dentistry. In the past, it was included with the local anesthetics propoxycaïne and procaine in a 1:30,000 concentration. In other countries, norepinephrine is included with lidocaine (Germany) and mepivacaine (Germany) or as the combination of norepinephrine and epinephrine with lidocaine (Germany) or tolycaïne (Japan).²¹

Maximum Doses

When given, norepinephrine should be used for pain control only, there being no justification for its use in obtaining hemostasis. It is approximately 25% as potent a vasopressor as epinephrine, and therefore is used clinically as a 1:30,000 dilution.

Recommendations of the International Federation of Dental Anesthesiology Societies suggest that norepinephrine be eliminated as a vasoconstrictor in dental local anesthetics, a statement with which this author wholeheartedly agrees.³⁶

Normal healthy patient: 0.34 mg per appointment; 10 mL of a 1:30,000 solution.

Patient with clinically significant cardiovascular disease (ASA class 3 or 4): 0.14 mg per appointment; approximately 4 mL of a 1:30,000 solution.

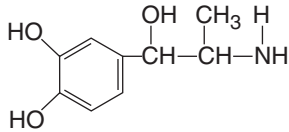
Levonordefrin

Proprietary Name PDF Compressor Free Version

Neo-Cobefrin.

Chemical Structure

Levonordefrin is freely soluble in dilute acidic solutions. Sodium bisulfite is added to the solution to delay its deterioration.



Source

Levonordefrin, a synthetic vasoconstrictor, is prepared by the resolution of nordefrin into its optically active isomers. The dextrorotatory form of nordefrin is virtually inert.

Mode of Action

It appears to act through direct α -receptor stimulation (75%), with some β activity (25%), but to a lesser degree than epinephrine. Levonordefrin is 15% as potent a vasopressor as epinephrine.⁴⁷

Systemic Actions

Levonordefrin produces less cardiac and CNS stimulation than is produced by epinephrine.

Myocardium

The same action as epinephrine is seen but to a lesser degree.

Pacemaker Cells

The same action as epinephrine is seen but to a lesser degree.

Coronary Arteries

The same action as epinephrine is seen but to a lesser degree.

Heart Rate

The same action as epinephrine is seen but to a lesser degree.

Vasculature

The same action as epinephrine is seen but to a lesser degree.

Respiratory System

Some bronchodilation occurs but to a much lesser degree than with epinephrine.

Central Nervous System

The same action as epinephrine is seen but to a lesser degree.

Metabolism

The same action as epinephrine is seen but to a lesser degree.

Termination of Action and Elimination

Levonordefrin is eliminated through the actions of COMT and MAO.

Side Effects and Overdose

These are the same as with epinephrine but to a lesser extent. With higher doses, additional side effects include hypertension, ventricular tachycardia, and anginal episodes in patients with coronary artery insufficiency.

Clinical Applications

Levonordefrin is used as a vasoconstrictor in local anesthetics.

Availability in Dentistry

Levonordefrin is combined with mepivacaine in a 1:20,000 dilution.

Maximum Doses

Levonordefrin is considered one-sixth (15%) as effective a vasopressor as epinephrine; therefore it is used in a higher concentration (1:20,000).

For all patients, the maximum dose should be 1 mg per appointment; 20 mL of a 1:20,000 dilution (11 cartridges); the maximum volume for administration may be limited by the dose of the local anesthetic.

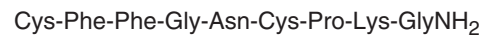
In the concentration at which it is available, levonordefrin has the same effect on the clinical activity of local anesthetics as does epinephrine in 1:50,000 or 1:100,000 concentration.^{48,49}

Felypressin

Proprietary Name

Octapressin.

Chemical Structure



Source

Felypressin is a synthetic analogue of the antidiuretic hormone vasopressin. It is a nonsympathomimetic amine, categorized as a vasoconstrictor.

Mode of Action

Felypressin acts as a direct stimulant of vascular smooth muscle. Its actions appear to be more pronounced on the venous microcirculation than on the arteriolar microcirculation.⁵⁰

Systemic Actions

Myocardium

Several studies have demonstrated that felypressin may induce an imbalance between oxygen supply and demand in the myocardium of patients with preexisting cardiovascular disease although with minimal changes in heart rate and blood pressure.⁵¹⁻⁵³

Pacemaker Cells

Felypressin is nondysrhythmogenic, in contrast to the sympathomimetic amines (e.g., epinephrine, norepinephrine).

Coronary Arteries

When administered in high doses (greater than therapeutic), felypressin may induce a constriction of the coronary arteries.⁵¹

Vasculature

With high doses of felypressin (greater than therapeutic), felypressin-induced constriction of cutaneous blood vessels may produce facial pallor.

Central Nervous System

Felypressin has no effect on adrenergic nerve transmission; thus it may be safely administered to hyperthyroid patients and to anyone receiving MAO inhibitors or tricyclic antidepressants.

Uterus

Felypressin has both antidiuretic and oxytocic actions, the latter contraindicating its use in pregnant patients.

Side Effects and Overdose

Laboratory and clinical studies with felypressin in animals and humans have demonstrated a wide margin of safety.⁵⁴ The drug is well tolerated by the tissues into which it is deposited, with little irritation developing. The incidence of systemic reactions to felypressin is minimal.

Clinical Applications

Felypressin is used as a vasoconstrictor in local anesthetics, primarily prilocaine, to decrease absorption and increase duration of action.

Availability in Dentistry

Felypressin is used in a dilution of 0.03 international units (IU) per milliliter with 3% prilocaine in Japan, Germany, and other countries. It is not available as a vasoconstrictor in dental local anesthetics in North America.

Maximum Doses

Felypressin-containing solutions are not recommended for use where hemostasis is necessary because of its predominant effect on the venous circulation rather than the arterial circulation.⁵⁵ This would likely *increase* bleeding at the surgical site rather than minimize it.

For patients with clinically significant cardiovascular impairment (ASA class 3 or 4), the maximum recommended dose is 0.27 IU; 9 mL of 0.03 IU/mL solution.

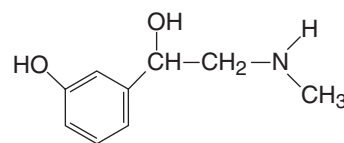
Phenylephrine Hydrochloride

Proprietary Name

Neo-Synephrine.

Chemical Structure

Phenylephrine is quite soluble in water. It is the stablest and the weakest vasoconstrictor used in dentistry.



Source

Phenylephrine is a synthetic sympathomimetic amine.

Mode of Action

Direct α -receptor stimulation occurs (95%). Although the effect is less than with epinephrine, the duration is longer. Phenylephrine exerts little or no β action on the heart. Only a small portion of its activity results from its ability to release norepinephrine.⁵⁶ Phenylephrine is only 5% as potent as epinephrine.

Systemic

Myocardium

It has little chronotropic or inotropic effect on the heart.

Pacemaker Cells

Little effect is noted.

Coronary Arteries

Increased blood flow occurs as the result of dilation.

Blood Pressure

Increases in both systolic pressure and diastolic pressure are produced as a result of α action.

Heart Rate

Bradycardia is produced by reflex actions of the carotid-aortic baroreceptors and the vagus nerve. Cardiac dysrhythmias are rarely noted, even after large doses of phenylephrine.

Cardiovascular Dynamics

Overall, the cardiovascular actions of phenylephrine are:

- increased systolic and diastolic pressures
- reflex bradycardia
- slightly decreased cardiac output (resulting from increased blood pressure and bradycardia)
- powerful vasoconstriction (most vascular beds constricted, peripheral resistance increased significantly) but without marked venous congestion
- rarely associated with inducing cardiac dysrhythmias

Respiratory System

Bronchi are dilated but to a lesser degree than with epinephrine. Phenylephrine is not effective in treating bronchospasm.

Central Nervous System

A minimum effect on CNS activity is noted.

Metabolism

Some increase in the metabolic rate is noted. Other actions (e.g., glycogenolysis) are similar to those produced by epinephrine.

Termination of Action and Elimination

Phenylephrine undergoes hydroxylation to epinephrine, then oxidation. **PDF Compressor Free Version** It is eliminated in the same manner as epinephrine.

Side Effects and Overdose

CNS effects are minimal with phenylephrine. Headache and ventricular dysrhythmias have been noted after overdose. Tachyphylaxis is observed with long-term use.

Clinical Applications

Phenylephrine is used as a vasoconstrictor in local anesthetics, for the management of hypotension, as a nasal decongestant, and in ophthalmic solutions to produce mydriasis.

Availability in Dentistry

Phenylephrine was used with 4% procaine in a 1:2,500 dilution (phenylephrine is no longer available in dental cartridges).

Maximum Doses

Phenylephrine is considered only 1/20 as potent as epinephrine, hence its use in a 1:2,500 dilution (equivalent to a 1:50,000 epinephrine concentration). It is an excellent vasoconstrictor, with few significant side effects.

Normal healthy patient: 4 mg per appointment; 10 mL of a 1:2500 solution.

Patient with clinically significant cardiovascular impairment (ASA class 3 or 4): 1.6 mg per appointment, equivalent to 4 mL of a 1:2,500 solution.

Selection of a Vasoconstrictor

Two vasoconstrictors are available in local anesthetic solutions in North America: epinephrine and levonordefrin.

In the selection of an appropriate vasoconstrictor, if any, for use with a local anesthetic, several factors must be considered: the length of the dental procedure, the need for hemostasis during and after the procedure, the requirement for postoperative pain control, and the medical status of the patient (Box 3.2).

Length of the Dental Procedure

The addition of any vasoactive drug to a local anesthetic prolongs the duration and depth of both pulpal and soft tissue anesthesia of most local anesthetics. For example, pulpal and

hard tissue anesthesia with 2% lidocaine lasts approximately 10 minutes; the addition of 1:50,000, 1:80,000, 1:100,000, or 1:200,000 epinephrine solution increases this to approximately 60 minutes. The addition of a vasoconstrictor to prilocaine, on the other hand, does not significantly increase the duration of clinically effective pain control. Prilocaine (4%), after nerve block injection, provides pulpal anesthesia of about 40 to 60 minutes' duration. (Infiltration injection with 4% prilocaine provides approximately 10 to 15 minutes of pulpal anesthesia.) The addition of a 1:200,000 epinephrine concentration to prilocaine increases this slightly (approximately 60 to 90 minutes).⁵⁷

Average durations of pulpal and hard tissue anesthesia expected from commonly used local anesthetics with and without vasoconstrictors are shown in Table 3.7.

In the United States, the typical dental patient is scheduled for a 1-hour appointment. The duration of actual treatment (and the desirable duration of profound pulpal anesthesia) is 47.9 minutes (SD 14.7 minutes) in a general dentistry office, whereas in the offices of dental specialists the treatment time is 39.1 minutes (SD 19.4 minutes).⁵⁸

For routine restorative procedures, it might be estimated that pulpal anesthesia will be required for approximately 40 to 50 minutes. As can be seen in Table 3.7, it is difficult to achieve consistently reliable pulpal anesthesia without inclusion of a vasoconstrictor.

TABLE 3.7 Average Durations of Pulpal and Hard Tissue Anesthesia

Local Anesthetic	Infiltration (min)	Nerve Block (min)
Lidocaine Hydrochloride		
2%—no vasoconstrictor	5–10 ^a	~10–20 ^a
2% + epinephrine 1:50,000	~60	≥60
2% + epinephrine 1:100,000	~60	≥60
2% + epinephrine 1:200,000	~60	≥60
Mepivacaine Hydrochloride		
3%—no vasoconstrictor	5–10 ^a	20–40 ^a
2% + levonordefrin 1:20,000	≤60	≥60
2% + epinephrine 1:100,000	≤60	≥60
Prilocaine Hydrochloride		
4%—no vasoconstrictor	10–15 ^a	40–60 ^a
4% + epinephrine 1:200,000	≤60	60–90
Articaine Hydrochloride		
4% + epinephrine 1:100,000	≤60	≥60
4% + epinephrine 1:200,000	≤60	≥60

^aThe duration of pulpal anesthesia is usually inadequate to provide pain control for a typical 48-minute procedure.

• BOX 3.2 Considerations when selecting a vasoconstrictor

- Length of the dental procedure
- Need for hemostasis during and following the procedure
- Requirement for postoperative pain control
- Medical status of the patient

Requirement for Hemostasis

Epinephrine is effective in preventing blood loss during surgical procedures. However, epinephrine also produces a rebound vasodilatory effect as its tissue level decreases, leading to possible postoperative bleeding that could potentially interfere with wound healing.²⁹

Epinephrine, which possesses both α and β actions, produces vasoconstriction through its α effects. Used in a 1:50,000 concentration, and even at 1:100,000 (but also to a lesser extent), epinephrine produces a definite rebound β effect once α -induced vasoconstriction has ceased. This leads to increased postoperative blood loss, which, if significant (not usually the case in dentistry), might compromise a patient's cardiovascular status.

Phenylephrine, a longer-acting, almost pure α -stimulating vasoconstrictor, does not produce a rebound β effect because its β actions are minimal. Therefore because it is not as potent a vasoconstrictor as epinephrine, hemostasis during the procedure is not as effective; however, because of the long duration of action of phenylephrine compared with epinephrine, the postoperative period passes with less bleeding. Total blood loss is usually lower when phenylephrine is used. Phenylephrine is not available in any dental local anesthetic formulation at this time.

Norepinephrine is a potent α stimulator and vasoconstrictor that has produced documented cases of tissue necrosis and sloughing. Norepinephrine cannot be recommended as a vasoconstrictor in dentistry because its disadvantages outweigh its advantages. Other more or equally effective vasoconstrictors are available that do not possess the disadvantages of norepinephrine.^{59,60}

Felypressin constricts the venous circulation more than the arteriolar circulation and therefore is of minimal value for hemostasis.⁵⁵

Vasoconstrictors must be deposited locally into the surgical site (area of bleeding) to provide hemostasis. They act directly on α receptors in the vascular smooth muscle. Only small volumes of local anesthetic solutions with vasoconstrictor are required to achieve hemostasis (i.e., just enough to produce ischemia at the site).

Medical Status of the Patient

Few contraindications are known to administration of vasoconstrictors in the concentrations in which they are found in dental local anesthetics. For all patients, and for some in particular, the benefits and risks of including the vasopressor in the local anesthetic solution must be weighed against the benefits and risks of using a plain anesthetic solution.⁶¹⁻⁶³ In general, these groups consist of:

- patients with more significant cardiovascular disease (ASA class 3 and 4)
- patients with certain noncardiovascular diseases (e.g., thyroid dysfunction, diabetes, sulfite sensitivity)
- patients receiving MAO inhibitors, tricyclic antidepressants, and phenothiazines

In each of these situations, it is necessary to determine the degree of severity of the underlying disorder to determine whether a vasoconstrictor may be safely included or should be excluded from the local anesthetic solution. It is not uncommon for medical consultation to be sought to aid in determining this information.

Management of these patients is discussed in depth in [Chapters 10 and 21](#). Briefly, however, it may be stated that local anesthetics with vasoconstrictors are not absolutely contraindicated for the patient whose medical condition has been diagnosed and is under control through medical or surgical means (ASA class 2 or 3 risk), and if the vasoconstrictor is administered slowly, in minimal doses, after negative aspiration has been ensured.

Patients with a resting (minimum 5-minute rest) systolic blood pressure greater than 200 mmHg or diastolic blood pressure greater than 115 mmHg ought not receive elective dental care until their more significant medical problem (high blood pressure) has been corrected. These blood pressures are considered as ASA class 4. Patients with severe cardiovascular disease (ASA class 3 or 4 risk) may be at too great a risk for elective dental therapy; for example, a patient who has had a recent (within the past 6 months) acute myocardial infarction with significant myocardial damage; a patient who has been experiencing anginal episodes at rest on a daily basis, or whose signs and symptoms are increasing in severity (preinfarction or unstable angina); or a patient whose cardiac dysrhythmias are refractory to antidysrhythmic drug therapy.⁶¹ Epinephrine and other vasoconstrictors can be administered, within limits, to patients with mild to moderate cardiovascular disease (ASA class 2 or 3). Because felypressin has minimum cardiovascular stimulatory action and is nondysrhythmogenic, it is the recommended drug, where available, for the ASA class 3 or 4 cardiovascular risk patient. Epinephrine is also relatively contraindicated in patients exhibiting clinical evidence of the hyperthyroid state.⁶² Signs and symptoms include exophthalmos, hyperhidrosis, tremor, irritability and nervousness, increased body temperature, inability to tolerate heat, increased heart rate, and increased blood pressure. Minimum dosages of epinephrine as a vasoconstrictor are recommended during general anesthesia when a patient (in any ASA category) is receiving a halogenated anesthetic (halothane, isoflurane, sevoflurane, or enflurane). These inhalation (general) anesthetics sensitize the myocardium such that epinephrine administration is frequently associated with the occurrence of ventricular dysrhythmias (premature ventricular contractions or ventricular fibrillation).⁶⁴ Felypressin is recommended in these situations; however, because of its potential oxytocic actions, felypressin is not recommended for pregnant patients. Once the impaired medical status of the patient has improved (e.g., ASA class 4 becomes ASA class 3), routine dental care involving the judicious administration of local anesthetics with vasoconstrictors is indicated.

Patients being treated with MAO inhibitors may receive vasoconstrictors within the usual dental dosage parameters without increased risk.^{63, 65, 66} Patients receiving tricyclic

antidepressants are at greater risk of the development of dysrhythmias with epinephrine administration. It is recommended that if a vasoconstrictor is administered to these patients, its dose and concentration be minimal. Administration of levonordefrin or norepinephrine is absolutely contraindicated in patients receiving tricyclic antidepressants.¹² Large doses of vasoconstrictor may induce severe (exaggerated) responses.

Local anesthetic formulations with vasoconstrictors also contain an antioxidant (to retard oxidation of the vasoconstrictor). Sodium bisulfite is the most frequently used antioxidant in dental cartridges. It increases the shelf life of the anesthetic solution with a vasoconstrictor. However, sodium bisulfite renders the local anesthetic considerably more acidic than the same solution without a vasoconstrictor. Acidic solutions of local anesthetics contain a greater proportion of charged cation molecules (RNH⁺) than of uncharged base molecules (RN). Because of this, diffusion of the local anesthetic solution into the axoplasm is slower, resulting in (slightly) slower onset of anesthesia when local anesthetics containing sodium bisulfite (and vasoconstrictors) are injected.

Additionally, sulfites are allergens. Sulfites were commonly used in restaurants to prevent the oxidation of certain foods (e.g., dried fruits, bottled lemon and lime juice, wine, grape juices). In 1986 the US Food and Drug Administration banned the use of bisulfites in fresh foods.⁶⁷ Any food containing more than 10 parts per million concentration of bisulfites must have this declared on the label.

Campbell et al.⁶⁸ reported a case of sulfite allergy following administration of lidocaine with epinephrine to a dental patient.

Vasoconstrictors are important additions to local anesthetic solutions. Numerous studies have demonstrated conclusively that epinephrine, when added to short- or medium-duration local anesthetic solutions, slows the rate of absorption, lowers the systemic blood level, delays cresting of the peak blood level, prolongs the duration of anesthesia, intensifies the depth of anesthesia, and reduces the incidence of systemic reactions.¹⁸ In the contemporary practice of dentistry, adequate pain control of sufficient clinical duration and depth is difficult to achieve without inclusion of vasoconstrictors in the local anesthetic solution. Unless specifically contraindicated by a patient's medical status (ASA class 4 or greater) or by the required duration of treatment (short), inclusion of a vasoconstrictor should be considered routinely. When these drugs are used, however, care must always be taken to avoid unintended intravascular administration of the vasoconstrictor (as well as the local anesthetic) through multiple aspirations and slow administration of minimum concentrations of both the vasoconstrictor and the local anesthetic.

References

1. Moore PA, Hersh EV. Local anesthetics: pharmacology and toxicity. *Dent Clin North Am.* 2010;54:587–599.
2. FINDER RL, MOORE PA. Adverse drug reactions to local anesthesia. *Dent Clin North Am.* 2002;46:447–457.
3. Brown G. The influence of adrenaline, noradrenaline vasoconstrictors on the efficacy of lidocaine. *J Oral Ther Pharmacol.* 1968;4:398–405.
4. Cowan A. Further clinical evaluation of prilocaine (Citanest), with and without epinephrine. *Oral Surg Oral Med Oral Pathol.* 1968;26:304–311.
5. Carpenter RL, Kopacz DJ, Mackey DC. Accuracy of Doppler capillary flow measurements for predicting blood loss from skin incisions in pigs. *Anesth Analg.* 1989;68:308–311.
6. Myers RR, Heckman HM. Effects of local anesthesia on nerve blood flow: studies using lidocaine with and without epinephrine. *Anesthesiology.* 1989;71:757–762.
7. Ahlquist RP. A study of adrenotropic receptors. *Am J Physiol.* 1948;153:586–600.
8. Hieble JP. Adrenoceptor subclassification: an approach to improved cardiovascular therapeutics. *Pharm Acta Helvet.* 2000;74:63–71.
9. Smiley RM, Kwatra MM, Schwinn DA. New developments in cardiovascular adrenergic receptor pharmacology: molecular mechanisms and clinical relevance. *J Cardiothorac Vasc Anesth.* 1998;12:10–95.
10. Braun H. Über den Einfluss der Vitalität der Gewebe auf die örtlichen und allgemeinen Giftwirkungen localanästhesierender Mittel, und über die Bedeutung des Adrenalin für die Lokalanästhesie. *Arch Klin Chir.* 1903;69:541–591.
11. Tolas AG, Pflug AE, Halter JB. Arterial plasma epinephrine concentrations and hemodynamic responses after dental injection of local anesthetic with epinephrine. *J Am Dent Assoc.* 1982;104:41–43.
12. Jastak JT, Yagiela JA, Donaldson D, eds. *Local Anesthesia of the Oral Cavity.* Philadelphia: WB Saunders; 1995.
13. Holroyd SV, Requa-Clark B. Local anesthetics. In: Holroyd SV, Wynn RL, eds. *Clinical Pharmacology in Dental Practice.* 3rd ed. St Louis: Mosby; 1983.
14. Malamed SF. *Handbook of Local Anesthesia.* 5th ed. St Louis: Mosby; 2004.
15. Cryer PE. Physiology and pathophysiology of the human sympathoadrenal neuroendocrine system. *N Engl J Med.* 1980;303:436–444.
16. Yagiela JA. Epinephrine and the compromised heart. *Orofac Pain Manage.* 1991;1:5–8.
17. Kaneko Y, Ichinohe T, Sakurai M, et al. Relationship between changes in circulation due to epinephrine oral injection and its plasma concentration. *Anesth Prog.* 1989;36:188–190.
18. de Jong RH. Uptake, distribution, and elimination. In: *Local Anesthetics.* St Louis: Mosby; 1994.
19. Huang KC. Effect of intravenous epinephrine on heart rate as monitored with a computerized tachometer. *Anesthesiology.* 1990;73:A762.
20. Narchi P, Mazoit JX, Cohen S, Samii K. Heart rate response to an IV test dose of adrenaline and lignocaine with and without atropine pretreatment. *Br J Anaesth.* 1991;66:583–586.
21. Malamed SF, Sykes P, Kubota Y, et al. Local anesthesia: a review. *Anesth Pain Control Dent.* 1992;1:11–24.
22. Lipp M, Dick W, Daublander M. Examination of the central venous epinephrine level during local dental infiltration and block anesthesia using tritium marked epinephrine as vasoconstrictor. *Anesthesiology.* 1988;69:371.
23. Stanton-Hicks M, Berges PU, Bonica JJ. Circulatory effects of peridural block. IV. Comparison of the effects of epinephrine and phenylephrine. *Anesthesiology.* 1973;39:308–314.

24. Robertson VJ, Taylor SE, Gage TW. Quantitative and qualitative analysis of the pressor effects of levonordefrin. *J Cardiovasc Pharmacol.* 1984;6(9):929–935.
25. Chaudhry S, Iqbal HA, Izhar F, et al. Effect on blood pressure and pulse rate after administration of an epinephrine containing dental local anaesthetic in hypertensive patients. *J Pak Med Assoc.* 2011;61(11):1088–1091.
26. Scarparo HC, Maia RN, de Gois SR, Costa FW, Ribeiro TR, Soares EC. Effects of mepivacaine 2% with epinephrine on the cardiovascular activity of patients undergoing third molar surgery: a prospective clinical study. *J Craniofac Surg.* 2014;25(1): e9–e12.
27. Meral G, Tasar F, Sayin F, et al. Effects of lidocaine with and without epinephrine on plasma epinephrine and lidocaine concentrations and hemodynamic values during third molar surgery. *Oral Surg Oral Med Oral Pathol Oral Radiol Endod.* 2005;100:25–30.
28. Pereira LA, Groppo FC, Bergamaschi CD, et al. Articaine (4%) with epinephrine (1:100,000 or 1:200,000) in intraosseous injections in symptomatic irreversible pulpitis of mandibular molars: anesthetic efficacy and cardiovascular effects. *Oral Surg Oral Med Oral Pathol Oral Radiol.* 2012;116:85–91.
29. Sveen K. Effect of the addition of a vasoconstrictor to local anesthetic solution on operative and postoperative bleeding, analgesia, and wound healing. *Int J Oral Surg.* 1979;8:301–306.
30. *Epinephrine drug monograph.* ClinicalKey. Available at: <http://www.clinicalkey.com>. Accessed December 18, 2017.
31. Shah R, Saltoun CA. Chapter 14: acute severe asthma (status asthmaticus). *Allergy Asthma Proc.* 2012;33(suppl 1):S47–S50.
32. Clutter WE, Bier DM, Shah SD, Cryer PE. Epinephrine plasma metabolic clearance rates and physiologic thresholds for metabolic and hemodynamic actions in man. *J Clin Invest.* 1980;66:94–101.
33. Meechan JG. The effects of dental local anaesthetics on blood glucose concentration in healthy volunteers and in patients having third molar surgery. *Br Dent J.* 1991;170:373–376.
34. Lefkowitz RJ, Hoffman BB, Taylor P. Neurohumoral transmission: the autonomic and somatic motor nervous system. In: Brunton LL, Lazo JS, Parker KL, eds. *Goodman and Gilman's the Pharmacological Basis of Therapeutics.* 11th ed. New York: McGraw-Hill; 2006.
35. Campbell RL. Cardiovascular effects of epinephrine overdose: case report. *Anesth Prog.* 1977;24:190–193.
36. Jakob W. Local anaesthesia and vasoconstrictive additional components. *Newsl Int Fed Dent Anesthesiol Soc.* 1989;2(1).
37. Pitt Ford TR, Seare MA, McDonald F. Action of adrenaline on the effect of dental local anaesthetic solutions. *Endod Dent Traumatol.* 1993;9(1):31–35.
38. Himuro H, Murata T, Tamesue A, et al. Determination of the desirable epinephrine concentration containing in dental local anesthetics. Comparison between two lidocaine solutions containing 1/80,000 and 1/200,000 epinephrine. *Fukuoka Shika Daigaku Gakkai Zasshi.* 1989;16(2):323–327.
39. Management of dental problems in patients with cardiovascular disease: report of a working conference jointly sponsored by the American Dental Association and American Heart Association. *J Am Dent Assoc.* 1964;68:333–342.
40. Use of epinephrine in connection with procaine in dental procedures: report of the Special Committee of the New York Heart Association, Inc., on the use of epinephrine in connection with procaine in dental procedures. *J Am Dent Assoc.* 1955;50:108.
41. Kaplan EL, ed. *Cardiovascular Disease in Dental Practice.* Dallas: American Heart Association; 1986.
42. Agency for Healthcare Research and Quality. *Cardiovascular Effects of Epinephrine in Hypertensive Dental Patients: Summary, Evidence Report/Technology Assessment Number 48.* AHRQ Publication Number 02-E005. Rockville: Agency for Healthcare Research and Quality; 2002. Available at: <http://www.ahrq.gov/clinic/epcix.htm>.
43. Buckley JA, Ciancio SG, McMullen JA. Efficacy of epinephrine concentration in local anesthesia during periodontal surgery. *J Periodontol.* 1984;55:653–657.
44. Moore PA, Doll B, Delie RA, et al. Hemostatic and anesthetic efficacy of 4% articaine HCl with 1:200,000 epinephrine and 4% articaine with 1:100,000 epinephrine when administered intraorally for periodontal surgery. *J Periodontol.* 2007;78(2): 247–253.
45. *Norepinephrine Drug Monograph.* ClinicalKey. Available at: <http://www.clinicalkey.com>. Accessed December 18, 2017.
46. Kaufman E, Garfunkel A, Findler M, et al. Emergencies evolving from local anesthesia. *Refuat Hapeh Vehashinayim.* 2002;19(98):13–18.
47. *Scandanest (Mepivacaine Hydrochloride and Levonordefrin Injection) Package Insert.* New Castle: Septodont Inc; 2007.
48. Lawaty I, Drum M, Reader A, Nusstein J. A prospective, randomized, double-blind comparison of 2% mepivacaine with 1:20,000 levonordefrin versus 2% lidocaine with 1:100,000 epinephrine for maxillary infiltrations. *Anesth Prog.* 2010;57(4): 139–144.
49. Su N, Liu Y, Yang X, Shi Z, Huang Y. Efficacy and safety of mepivacaine compared with lidocaine in local anaesthesia in dentistry: a meta-analysis of randomized controlled trials. *Int Dent J.* 2014;64(2):96–107.
50. Altura BM, Hershey SG, Zweifach BW. Effects of a synthetic analogue of vasopressin on vascular smooth muscle. *Proc Soc Exp Biol Med.* 1965;119:258–261.
51. Agata H, Ichinohe T, Kaneko Y. Felypressin-induced reduction in coronary blood flow and myocardial tissue oxygen tension during anesthesia in dogs. *Can J Anaesth.* 1999;46(11):1070–1075.
52. Miyachi K, Ichinohe T, Kaneko Y. Effects of local injection of prilocaine-felypressin on the myocardial oxygen balance in dogs. *Eur J Oral Sci.* 2003;111(4):339–345.
53. Inagawa M, Ichinohe T, Kaneko Y. Felypressin, but not epinephrine, reduces myocardial oxygen tension after an injection of dental local anesthetic solution at routine doses. *J Oral Maxillofac Surg.* 2010;68(5):1013–1017.
54. Sunada K, Nakamura K, Yamashiro M, et al. Clinically safe dosage of felypressin for patients with essential hypertension. *Anesth Prog.* 1996;43:408–415.
55. Newcomb GM, Waite IM. The effectiveness of local analgesic preparations in reducing haemorrhage during periodontal surgery. *J Dent.* 1972;1:37–42.
56. *Phenylephrine Drug Monograph.* ClinicalKey. Available at: <http://www.clinicalkey.com>. Accessed December 20, 2017.
57. Epstein S. Clinical study of prilocaine with varying concentrations of epinephrine. *J Am Dent Assoc.* 1969;78:85–90.
58. *American Dental Association: 2009 Survey of Dental Practice.* Chicago: American Dental Association; 2010.
59. van der Bijl P, Victor AM. Adverse reactions associated with norepinephrine in dental local anesthesia. *Anesth Prog.* 1992;39: 37–89.
60. Hirota Y, Hori T, Kay K, Matsuura H. Effects of epinephrine and norepinephrine contained in 2% lidocaine on hemodynamics of the carotid and cerebral circulation in older and younger adults. *Anesth Pain Control Dent.* 1992;1:343–351.
61. Goulet JP, Perusse R, Turcotte JY. Contraindications to vasoconstrictors in dentistry. Part I. Cardiovascular diseases. *Oral Surg Oral Med Oral Pathol.* 1992;74:579–686.

62. Goulet JP, Perusse R, Turcotte JY. Contraindications to vasoconstrictors in dentistry. Part II. Hyperthyroidism, diabetes, sulfite sensitivity, cold-dependent asthma, and photodermatoma. *Oral Surg Oral Med Oral Pathol.* 1992;74:587–691.
63. Goulet JP, Perusse R, Turcotte JY. Contraindications to vasoconstrictors in dentistry. Part III. Pharmacologic interactions. *Oral Surg Oral Med Oral Pathol.* 1992;74:592–697.
64. Brenner GM, Stevens CW. Local and general anesthetics. In: *Brenner and Stevens' Pharmacology.* 5th ed. St Louis: Elsevier; 2018:231–241.
65. Wahl MJ. Local anesthetics and vasoconstrictors: myths and facts. *Pract Periodont Aesthet Dent.* 1997;9:649–652.
66. Hersh EV. Local anesthesia in dentistry: clinical considerations, drug interactions, and novel formulations. *Compend Cont Educ Dent.* 1993;14:1020–1028.
67. Molotsky I. *U.S. Issues Ban on Sulfites' Use in Certain Foods.* New York Times; July 9, 1986.
68. Campbell JR, Maestrello CL, Campbell RL. Allergic response to metabisulfite in lidocaine anesthetic solution. *Anesth Prog.* 2001;48:21–26.

Clinical Action of Specific Agents

Selection of a Local Anesthetic

Although many drugs are classified as local anesthetics and find use within the health professions, only a handful are currently used in dentistry. In 1980, when the first edition of this book was published, five local anesthetics were available in dental cartridge form in the United States: lidocaine, mepivacaine, prilocaine, and the combination of procaine and propoxycaine.¹ In the 38 years since that first edition, increased demand for longer-acting local anesthetics led to the introduction, in dental cartridges, of bupivacaine (1982 Canada, 1983 United States) and etidocaine (1985). The hybrid (ester/amide) molecule articaine became available in 1975 Germany, and later throughout Europe. Articaine came to Canada in 1983 and to the United States in 2000. Articaine is classified as an intermediate-duration local anesthetic.

The combination of procaine and propoxycaine was withdrawn from the US dental market in January 1996. Although used extensively in medicine, etidocaine was withdrawn from the US dental market in 2002.

As this seventh edition of *Handbook of Local Anesthesia* goes to press, the local anesthetic armamentarium (available in glass cartridges) in North American dentistry includes articaine, bupivacaine, lidocaine, mepivacaine, and prilocaine.

With the availability of these local anesthetics, in various combinations with and without vasoconstrictors, it is possible for a doctor to select a local anesthetic solution that possesses the specific pain-controlling properties necessary to provide pain-free treatment for virtually all dental patients. [Table 4.1](#) lists local anesthetics and the various combinations in which they are currently available in the United States and Canada. [Box 4.1](#) lists these combinations by their expected duration of clinical action (durations of pulpal and soft tissue anesthesia).

In this chapter, each of the available local anesthetics in its various combinations is described. In addition, the rationale for selection of an appropriate local anesthetic for a given patient at a given appointment is presented. It is strongly suggested that the reader—the potential administrator of these drugs—become familiar with this material, including contraindications to the administration of certain local anesthetic combinations ([Table 4.2](#)).

In the following discussion of the clinical properties of specific local anesthetic combinations, several concepts are presented that require explanation. These include the expected duration of action of the drug and determination of the maximum recommended dose (MRD).

Duration

The duration of pulpal (hard tissue) and soft tissue (total anesthesia cited for each drug is an approximation. Many factors affect both the depth and the duration of a drug's anesthetic action, prolonging or decreasing it. These factors include but are not limited to:

1. individual response to the drug (the normal distribution curve or “bell-shaped” curve)
2. accuracy in deposition of the local anesthetic
3. status of tissues at the site of drug deposition (vascularity, pH)
4. anatomic variation
5. type of injection administered (supraperiosteal [“infiltration”] or nerve block)

In the subsequent discussion of individual local anesthetics, the durations of anesthesia (pulpal and soft tissue) are presented for the middle of the normal distribution curve (the normoresponder)

1. *Normal distribution curve (bell-shaped curve)*: Variation in individual response to a drug is common and expected and is depicted in the so-called bell or normal distribution curve ([Fig. 4.1](#)). Most patients will respond in a predictable manner to a drug's actions (e.g., 60 minutes). However, some patients (with none of the other factors that influence drug action obviously present) will have a shorter or longer duration of anesthesia. This is to be expected and is entirely normal.

For example, if an appropriate dose of 2% lidocaine hydrochloride with epinephrine 1:100,000 is administered to 100 persons via supraperiosteal injection over a maxillary lateral incisor and a pulp tester is used to assess the duration of anesthesia, approximately 70% (68.26%) will have pulpal anesthesia for approximately 60 minutes. These represent the normoresponders. Approximately 15% will have pulpal anesthesia that lasts beyond the expected 60 minutes—perhaps 70 or

TABLE 4.1 Local Anesthetics Available in North America (February 2019)

PDF Compressor Free Version

Local Anesthetic (+ Vasoconstrictor)	Duration of Action ^a
Articaine hydrochloride	
4% + epinephrine 1:100,000	Intermediate
4% + epinephrine 1:200,000	Intermediate
Bupivacaine hydrochloride	
0.5% + epinephrine 1:200,000	Long
Lidocaine hydrochloride	
2% + epinephrine 1:50,000	Intermediate
2% + epinephrine 1:100,000	Intermediate
Mepivacaine hydrochloride	
3%	Short
2% + levonordefrin 1:20,000	Intermediate
2% + epinephrine 1:100,000	Intermediate
Prilocaine hydrochloride	
4%	Short (infiltration); intermediate (nerve block)
4% + epinephrine 1:200,000	Intermediate

^aThe classification of duration of action is approximate, for extreme variations may be noted among patients. Short-duration drugs provide pulpal or deep anesthesia for <30 min, intermediate-duration drugs provide it for about 60 min, and long-duration drugs provide it for longer than 90 min.

80 minutes, and even longer for some. These persons are termed *hyperresponders*. No dentist complains about these patients because their dental treatment proceeds and is completed with no pain or need for repeated injection of local anesthetic. However, it is the final 15%, the *hyporesponders*, who are well remembered by the dentist. These patients, given lidocaine with epinephrine, are anesthetized for 45 minutes, 30 minutes, 15 minutes, or even less. These are the patients about whom the doctor states (incorrectly): “They metabolize the drug rapidly.” As mentioned in [Chapter 2](#), metabolism (biotransformation, detoxification) has nothing whatsoever to do with the clinical effects of a local anesthetic dissipating. The duration of anesthesia is based simply on the way some persons respond to this drug (or group of drugs).

2. *Accuracy in administration of the local anesthetic* is another factor that influences drug action. Although not as significant in certain techniques (e.g., suprapariosteal) or with certain drugs (e.g., articaine), accuracy in deposition is a major factor in many nerve blocks in which a considerable thickness of soft tissue must be penetrated to access the nerve being blocked. The classic inferior alveolar nerve block is the prime example of a technique

• BOX 4.1 Approximate Duration of Action of Local Anesthetics

- Short Duration** (Pulpal anesthesia for approximately 30 min)
 Mepivacaine hydrochloride, 3%
 Prilocaine hydrochloride, 4% (by infiltration)
- Intermediate Duration** (Pulpal anesthesia for approximately 60 min)
 Articaine hydrochloride, 4%, with epinephrine 1:100,000
 Articaine hydrochloride, 4%, with epinephrine 1:200,000
 Lidocaine hydrochloride, 2%, with epinephrine 1:50,000
 Lidocaine hydrochloride, 2%, with epinephrine 1:100,000
 Mepivacaine hydrochloride, 2%, with levonordefrin 1:20,000
 Mepivacaine hydrochloride, 2%, with epinephrine 1:100,000
 Prilocaine hydrochloride, 4% (via nerve block only)
 Prilocaine hydrochloride, 4%, with epinephrine 1:200,000
- Long Duration** (Pulpal anesthesia for 90 min or longer)
 Bupivacaine hydrochloride, 0.5%, with epinephrine 1:200,000

in which the depth and duration of anesthesia are greatly influenced by the accuracy of injection. Deposition of local anesthetic close to the nerve provides greater depth and duration of anesthesia compared with the same anesthetic deposited at a greater distance from the nerve to be blocked.

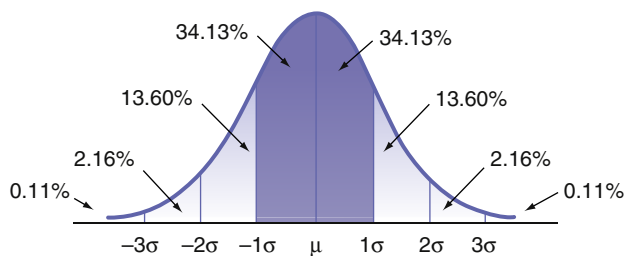
3. *The status of the tissues into which a local anesthetic is deposited* influences the observed duration of anesthetic action. The presence of normal healthy tissue at the site of drug deposition is assumed. Inflammation, infection, or pain (acute or chronic) usually decreases the depth and anticipated duration of anesthesia. Increased vascularity at the site of drug deposition results in more rapid absorption of the local anesthetic and a decreased duration of anesthesia. Not only is this most notable in areas of inflammation and infection, but also it is consideration in “normal” anatomy. The neck of the mandibular condyle, the target for local anesthetic deposition in the Gow-Gates mandibular nerve block, is considerably less vascular than the target area for the inferior alveolar nerve block. The expected duration of anesthesia for any local anesthetic will be greater in a less vascular region. The “problem” of achieving effective pain control with infected teeth (symptomatic irreversible pulpitis) is discussed in depth in [Chapter 16](#) and [19](#).
4. *Anatomic variation also influences clinical anesthesia.* The normal anatomy of the maxilla and the mandible is described in [Chapter 12](#). The most notable aspect of “normal” anatomy is the presence of extreme variation (e.g., in the size and shape of the head or in the thickness of bone) from person to person. (There is a bell-shaped curve when one is describing “normal” anatomy.) The techniques presented in subsequent chapters are based on the middle of the bell curve, the so-called normoresponders. Anatomic variations away from this “norm” may influence the duration of clinical drug action. Although most obvious in the mandible (height of

TABLE 4.2 Contraindications for Local Anesthetics

PDF Compressor Free Version

Medical Problem	Drugs to Avoid	Type of Contraindication	Alternative Drug
Local anesthetic allergy, documented	All local anesthetics in same chemical class (e.g., esters)	Absolute	Local anesthetics in different chemical class (e.g., amides)
Bisulfite allergy	Vasoconstrictor-containing local anesthetics	Absolute	Any local anesthetic without a vasoconstrictor
Atypical plasma cholinesterase	Esters	Relative	Amides
Methemoglobinemia, idiopathic or congenital	Prilocaine	Relative	Other amides or esters
Significant liver dysfunction (ASA class 3 or 4)	Amides	Relative	Amides or esters, but judiciously
Significant renal dysfunction (ASA class 3 or 4)	Amides or esters	Relative	Amides or esters, but judiciously
Significant cardiovascular disease (ASA class 3 or 4)	High concentrations of vasoconstrictors (as in racemic epinephrine gingival retraction cords)	Relative	Local anesthetics with epinephrine concentration of 1:200,000 or 1:100,000, or 3% mepivacaine or 4% prilocaine (nerve blocks)
Clinical hyperthyroidism (ASA class 3 or 4)	High concentrations of vasoconstrictors (as in racemic epinephrine gingival retraction cords)	Relative	Local anesthetics with epinephrine concentration of 1:200,000 or 1:100,000, or 3% mepivacaine or 4% prilocaine (nerve blocks)

ASA, American Society of Anesthesiologists.



• Fig. 4.1 “Bell-shaped” curve.

the mandibular foramen, flare of the ramus, thickness of the cortical plate of bone), such variation may be noted also in the maxilla. Supraperiosteal infiltration, which is usually effective in providing pulpal anesthesia for all maxillary teeth, provides a shorter duration than expected or an inadequate depth of anesthesia when alveolar bone is denser than usual. Where the zygomatic arch is lower (primarily in children, but occasionally in adults), infiltration anesthesia of the maxillary first and second molars may provide a shorter duration or may even fail to provide adequate depth of pulpal anesthesia. In other cases the palatal root of maxillary molars may not be adequately anesthetized by local anesthetic infiltration, even in the presence of normal thickness of the buccal alveolar bone, when that root flares more toward the midline of the palate than is the norm. In the mandible, it is stated that supraperiosteal infiltration is not effective in adults because their cortical plate of bone is too

thick; however, according to the bell-shaped curve, 15% of adult patients should have cortical bone that is thinner, and of those 15% some will have even thinner bone, perhaps allowing mandibular infiltration to be effective. The use of articaine hydrochloride by mandibular infiltration in adults has been demonstrated to be highly effective (and is discussed in detail in [Chapters 15 and 20](#)).²⁻⁴

5. *The duration of clinical anesthesia* is influenced—to various degrees—by the type of injection administered. For all drugs presented, administration of a nerve block provides a longer duration of pulpal and soft tissue anesthesia than is provided by supraperiosteal injection (e.g., infiltration). This assumes that the recommended minimum volume of anesthetic is injected. Less-than-recommended volumes decrease the duration of action. Larger-than-recommended doses do not provide increased duration. For example, a duration of pulpal anesthesia of 10 to 15 minutes may be expected to follow supraperiosteal injection with 4% prilocaine (no vasoconstrictor), whereas a 40- to 60-minute duration is normal following nerve block ([Table 4.3](#)).

Maximum Recommended Doses of Local Anesthetics

Doses of local anesthetic drugs are presented in terms of milligrams of drug per unit of body weight—as

TABLE 4.3 Expected Duration of Pulpal Anesthesia by Type of Injection

Local Anesthetic	Infiltration	Nerve Block
	(min)	(min)
Mepivacaine hydrochloride		
3%, no vasoconstrictor	5–10	20–40
Prilocaine hydrochloride		
4%, no vasoconstrictor	10–15	40–60
Bupivacaine hydrochloride		
0.5% + epinephrine 1:200,000	60	≤360

milligrams per kilogram (mg/kg) or as milligrams per pound (mg/lb). These numbers, similar to the ones presented for duration, reflect expected values because there is a wide range (the bell-shaped curve is also observed here) in patient response to blood levels of local anesthetics (or of any drug).

For patients whose responses to local anesthetic blood levels fall within the middle of the normal distribution curve, administration of a maximum dose based on body weight produces a local anesthetic blood level below the usual threshold for an overdose (toxic) reaction. The response observed if an overdose reaction occurs at that dose is mild (e.g., tremor of the arms and legs, drowsiness). Patients who are hyporesponders to elevated local anesthetic blood levels may not experience any adverse reaction until their local anesthetic blood level is considerably above this “normal” overdose threshold. These patients represent little increased risk when local anesthetics are administered in “usual” dental doses. However, hyperresponders may demonstrate clinical signs and symptoms of local anesthetic overdose at blood levels that are considerably lower than those normally necessary to produce such reactions. To increase safety for all patients during administration of local anesthetics, but especially in this latter group, one should always minimize drug doses, using the smallest clinically effective dose. Recommended volumes of local anesthetics are presented for each injection technique in [Chapters 13 to 15](#).

The MRD of local anesthetics was modified in the sixth edition of this book (2013). In prior editions, both the manufacturer’s MRD and the author’s MRD were presented. In some instances, these doses differed. Where doses differed, those recommended by the author were more conservative than those recommended by the drug’s manufacturer. In this edition of the book, as in the sixth edition, only MRDs that have been approved by the US Food and Drug Administration (FDA) and Health Canada are listed ([Table 4.4](#)).

Maximum doses are unlikely to be reached in most dental patients, especially adults of normal body weight,

TABLE 4.4 Maximum Recommended Doses of Local Anesthetics Available in North America

Local Anesthetic	Maximum Recommended Dose (Food and Drug Administration)		
	mg/kg	mg/lb	mg
Articaine			
With vasoconstrictor	7.0	3.2	None listed
Bupivacaine			
With vasoconstrictor	None listed	None listed	90
With vasoconstrictor (Canada)	2.0	0.9	200
Lidocaine			
With vasoconstrictor	7.0	3.2	500
Mepivacaine			
No vasoconstrictor	6.6	3.0	400
With vasoconstrictor	6.6	3.0	400
Prilocaine			
No vasoconstrictor	8.0	3.6	600
With vasoconstrictor	8.0	3.6	600

Local Anesthetic	Calculation of Milligrams of Local Anesthetic per Dental Cartridge (1.8-mL Cartridge)		
	Percent Concentration	mg/mL	× 1.8 mL = mg/Cartridge
Articaine	4	40	72 ^a
Bupivacaine	0.5	5	9
Lidocaine	2	20	36
Mepivacaine	2	20	36
	3	30	54
Prilocaine	4	40	72

^aCartridges of some drugs in the United States read “1.7 mL each.” The actual volume of all local anesthetic cartridges is approximately 1.76 mL.

for most dental procedures. Two groups of patients, however, have potentially increased risk from overly high local anesthetic blood levels: the smaller, lighter (and well-behaved) child and the debilitated elderly individual. Considerable attention must be given to drug administration in these two groups. The MRD calculated should always be decreased in medically compromised, debilitated, or elderly persons.

Changes in liver function, plasma protein binding, blood volume, and other important physiologic functions influence the manner in which local anesthetics are distributed and biotransformed in the body.⁵ The

net result of these changes is an increased plasma blood level of the drug, which is associated with increased risk of overdose related to the drug. The maximum recommended dose (MRD) of local anesthetics is significantly increased in the presence of decreased liver function or perfusion.⁶ Peak plasma local anesthetic blood levels tend to be higher and to remain so longer in these situations. The calculated drug dose (based on body weight) should be decreased in all “at-risk” individuals (e.g., American Society of Anesthesiologists [ASA] physical status classification system class 3 or 4). Unfortunately, there is no magic formula that can aid in determining the degree of dose reduction for a given patient. It is suggested that the doctor evaluate each patient’s dental care needs and then devise a treatment plan that takes into account that person’s requirement for smaller doses of local anesthetic at every treatment appointment.

A point that has come up in several medicolegal consultations related to overdosage of local anesthetics involves the maximum number of milligrams administered and the effect on the patient. Assume, for example, that the MRD for a local anesthetic in a given patient is 270 mg, and 271 mg is administered to the patient. The thinking among laypersons (and, unfortunately, some health care professionals as well) is that an overdose would definitely occur at any dose exceeding the MRD for the patient. However, this may not be the case. As mentioned, many factors interact to determine how a patient will respond to a drug. When the MRD is exceeded, there is no guarantee that an overdose will occur, only that there is a greater likelihood of its occurrence. Indeed, in certain individuals, an overdose may be seen with doses well below the calculated MRD (hyperresponders to the drug). Another factor in determining whether an overdose will occur is the time over which the local anesthetic dose was administered. If all 271 mg is administered at once, the resulting local anesthetic blood level will be greater than in a situation in which the same dose is administered a little at a time over several hours. These points are discussed in greater detail in Chapter 18.

De Jong,⁷ in his classic textbook *Local Anesthetics* makes the following salient observations: “a word here on ‘safe’ or ‘recommended’ local anesthetic doses, as found on drug package inserts or in reference books. These doses are best estimates, indirectly derived from experimental studies and clinical case reports. Generally, the upper limits tend to be on the safely conservative side of the fence. Considerably higher doses than ‘recommended’ can be (and have been) given if used judiciously.⁸ Conversely, the so-called safe dose may be a gross overdose if placed where not intended. In my (unpublished) experience, for instance, 10 mg of lidocaine or 2.5 mg of bupivacaine produced instant grand mal seizures when injected unintentionally into the vertebral artery. These doses are on the order of 1/50th the recommended upper limit.

• BOX 4.2 Calculation of Maximum Dose and Number of Cartridges (Single Drug)

Patient: 22 years old, healthy, female, 50 kg

Local anesthetic: lidocaine hydrochloride + epinephrine

1:100,000

Lidocaine, 2% = 36 mg per cartridge

Lidocaine, 7.0 mg/kg = 350 mg (maximum recommended dose)

Number of cartridges 350/36 ≈ 9.75

Patient: 40 years old, healthy, male, 90 kg

Local anesthetic: articaine hydrochloride + epinephrine

1:200,000

Articaine, 4% = 72 mg per cartridge

Articaine, 7.0 mg/kg = 630 mg (maximum recommended dose)

Number of cartridges 630/72 ≈ 9.0

Patient: 6 years old, healthy, male, 20 kg

Local anesthetic: mepivacaine hydrochloride, no

vasoconstrictor

Mepivacaine, 3% = 54 mg per cartridge

Mepivacaine, 6.6 mg/kg = 132 mg (maximum recommended dose)

Number of cartridges 130/54 ≈ 2.5

‘Safe’ doses can be either too little or too much, depending on circumstances. Vigilance is the watchword!⁷

Box 4.2 provides examples of how to calculate maximum doses and the number of local anesthetic cartridges to be administered to various patients.

A minor point, but one that has led to some confusion primarily among dental and dental hygiene students, and also doctors and hygienists in practice, is that labeling changes on some cartridges of local anesthetics indicate that the volume of solution contained in the cartridge is 1.7 mL, not the “traditional” 1.8 mL. In fact, dental cartridges did not always contain 1.8 mL of solution. In the late 1990s, during the FDA approval process for articaine, the following question was asked of its manufacturer: “Can you guarantee that each and every cartridge contains at least 1.8 mL of solution?” The answer was “No.” Cartridges are filled mechanically, and very slight variation in volume may be noted from one cartridge to the next. When the manufacturer was asked if it could be guaranteed that each and every cartridge contains at least 1.7 mL of solution, the answer was “Yes.” In fact, the average volume of local anesthetic solution in a dental cartridge in the United States is 1.76 mL.⁹ When the MRD of a local anesthetic for a given patient is calculated, it is advised that a volume of 1.8 mL be used.

A frequently asked question is: “How do I determine the dose of each local anesthetic administered in clinical situations in which more than one drug is necessary?” The answer is again that no guaranteed formula exists for determining this number. One method is simply to ensure that the total dose of both local anesthetics does not exceed the lower of the two maximum doses for each individual drug.

• **BOX 4.3** Calculation of Maximum Dose and Number of Cartridges (Multiple Drugs)
PDF Compressor Free Version

Patient: 45-kg female, healthy

Local anesthetic: mepivacaine, 2%, with levonordefrin 1:20,000

Mepivacaine, 2% = 36 mg per cartridge

Mepivacaine, 6.6 mg/kg = 297 mg (maximum recommended dose)

The patient receives two cartridges (72 mg), but anesthesia is inadequate.

The doctor wishes to change to 4% articaine with epinephrine 1:100,000.

How Much Articaine Can This Patient Receive?

Articaine, 4% = 72 mg per cartridge

Articaine, 7.0 mg/kg = 315 mg (maximum recommended dose)

The total dose of *both* local anesthetics should not exceed the lower of the two calculated doses, or 297 mg.

The patient has received 72 mg (mepivacaine), and thus can still receive 225 mg of articaine.

Therefore 225 mg/72 mg per cartridge is equivalent to 3.0 cartridges of 4% articaine with epinephrine 1:100,000.

For example, a 45-kg (99-lb) patient receiving 4% prilocaine with epinephrine has an MRD calculated as 8.0 mg/kg (3.6 mg/lb) or 360 mg during a procedure that lasts 90 minutes (the approximate elimination half-life of prilocaine). The patient receives two cartridges (144 mg), but anesthesia is inadequate for the treatment to proceed. As is often the case, the doctor blames the lack of anesthesia on the anesthetic drug (“I’ve got a bad batch of local”), not on technique error or unusual patient anatomy, as is more likely. The doctor elects to switch to 2% lidocaine with epinephrine 1:100,000 to provide anesthesia. How does one determine the maximum dose of lidocaine that may be used?

If lidocaine were being administered as the sole drug to this patient, its MRD would be 7.0 mg/kg (3.2 mg/lb) or 315 mg. However, she has already received 144 mg of prilocaine within the past few minutes. The amount of lidocaine suggested is the smaller total maximum dose (which in this case is 315 mg [lidocaine] vs. 360 mg [prilocaine]) minus the dose of prilocaine already administered (144 mg), which permits a dose of 171 mg of lidocaine, or about 4.5 cartridges, to be administered to this patient (Box 4.3).

It is extremely unlikely that a “bad batch” of local anesthetic has been distributed to the doctor. The most common causes for failure to achieve adequate pain control are anatomic variation and faulty technique. (However, blaming failure to obtain adequate pain control on the local anesthetic drug serves to soothe the doctor’s ego.)

The concept of MRD is discussed more fully in Chapter 18.

Clinically available local anesthetics (the amides: articaine, bupivacaine, lidocaine, mepivacaine, and prilocaine) are discussed in detail here. Esters (procaine and propoxycaine) are mentioned in passing, more as a matter of

historical interest than of necessity. Agents available for topical application (topical anesthetics) also are discussed.

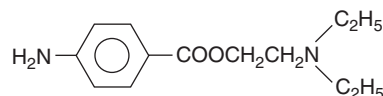
Ester Local Anesthetics

Procaine Hydrochloride

Pertinent Information

Classification. Ester.

Chemical formula. (Diethylamino)ethyl 4-aminobenzoate hydrochloride.



Prepared by. Alfred Einhorn, 1904–5.

Potency. 1 (procaine = 1)

Toxicity. 1 (procaine = 1)

Metabolism. Hydrolyzed rapidly in plasma by plasma pseudocholinesterase.

Excretion. More than 2% unchanged in the urine (90% as *p*-aminobenzoic acid, 8% as diethylaminoethanol).

Vasodilating properties. Produces the greatest degree of vasodilation of all currently used local anesthetics.

pK_a . 8.9.^a

pH of plain solution. 5.0 to 6.5.

pH of vasoconstrictor-containing solution. 3.5 to 5.5.

Onset of action. 6 to 10 minutes.

Effective dental concentration. 2% to 4%.

Anesthetic half-life. 6 minutes.

Topical anesthetic action. Not in clinically acceptable concentrations.

Comments. Procaine hydrochloride, the first synthetic injectable local anesthetic, is no longer available in North America in dental cartridges. However, its proprietary name, Novocain, is synonymous, throughout the world, with dental local anesthesia. Until 1996 procaine was available in dental cartridges in combination with another ester anesthetic, propoxycaine.

Used as the sole local anesthetic agent for pain control in dentistry, as it was from its introduction in 1904 until the introduction of the amide local anesthetic lidocaine in the late 1940s, 2% procaine (plain) provided essentially no pulpal anesthesia and from 15 to 30 minutes of soft tissue anesthesia. This is a result of its profound vasodilating properties. Procaine produces the greatest vasodilatory effect of all clinically used local anesthetics. Thus a clean (e.g., bloodless) surgical field is more difficult to maintain with procaine because of increased bleeding.

^aFor uniformity throughout the text, pK_a values for all local anesthetics have been taken from a single source: Liu SS. Local anesthetics and analgesia. In Ashburn MA, Rice LJ, eds. *The Management of Pain*, New York: Churchill-Livingstone; 1997:141–170. The reader should be aware that these values may differ slightly from the pK_a values in previous editions of this textbook.

Today, procaine is of some importance in the immediate management of inadvertent intra-arterial injection of a drug; its vasodilating properties are useful in relieving arteriospasm.¹⁰

Although extremely uncommon, the incidence of immediate-onset allergy to both procaine and other ester local anesthetics is greater than that to amide local anesthetics.^{11,12}

Metabolized in the blood by plasma cholinesterase, procaine does not exhibit increased toxicity in patients with hepatic dysfunction; however, in patients with altered pseudocholinesterase function, the risk of adverse reactions is increased.¹³

The MRD of procaine used for peripheral nerve blocks is 1000 mg.¹⁴

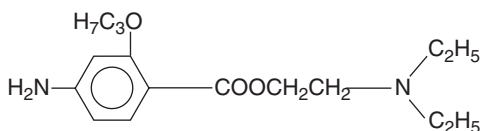
With a dissociation constant (pK_a) of 8.9, procaine has a relatively slow onset of anesthesia (6 to 10 minutes)—a reason for inclusion of propoxycaine in the anesthetic cartridge.

Propoxycaine Hydrochloride

Pertinent Information

Classification. Ester.

Chemical formula. 2-(Diethylamino)ethyl 4-amino-2-propoxybenzoate hydrochloride.



Prepared by. Clinton and Laskowski, 1952.

Potency. 7 to 8 (procaine = 1).

Toxicity. 7 to 8 (procaine = 1).

Metabolism. Hydrolyzed in both plasma and the liver.

Excretion. Via the kidneys; almost entirely hydrolyzed.

Vasodilating properties. Yes, but not as profound as those of procaine.

pK_a . Not available.

pH of plain solution. Not available.

Onset of action. Rapid (2 to 3 minutes).

Effective dental concentration. 0.4%.

Anesthetic half-life. Not available.

Topical anesthetic action. Not in clinically acceptable concentrations.

Comments. Propoxycaine was combined with procaine in solution to provide more rapid onset and a more profound and longer-lasting anesthesia than could be obtained with procaine alone.¹⁵ Propoxycaine was not available alone because its higher toxicity (seven to eight times that of procaine) limited its usefulness as a sole agent.

Procaine Hydrochloride Plus Propoxycaine Hydrochloride

Although no longer manufactured or available in dental cartridges in the United States, the combination of two ester anesthetics, propoxycaine and procaine, was worthy

of consideration for inclusion in a dentist's armamentarium of local anesthetics. It was indicated when the amide local anesthetics were absolutely contraindicated (e.g., because of documented allergy [although this is an extremely unlikely occurrence]) or when several amide local anesthetics failed to provide clinically adequate anesthesia. Until its removal from the US market in January 1996, the combination of procaine and propoxycaine, with the vasoconstrictor norepinephrine, was the only ester local anesthetic available in dental cartridge form. Its proprietary name was Ravocaine.

A dose of 0.4% propoxycaine/2% procaine with levonordefrin 1:20,000 (United States) or with norepinephrine 1:30,000 (Canada) provided approximately 40 minutes of pulpal anesthesia and 2 to 3 hours of soft tissue anesthesia. The use of norepinephrine in local anesthetic solutions is no longer recommended, especially in areas where prolonged ischemia can lead to tissue necrosis. In the oral cavity, this is most likely to be seen in the palate.

The manufacturer's MRD was 3.0 mg/lb body weight, or 6.6 mg/kg body weight, for the adult patient.¹⁶ For children, a dose of 3.0 mg/lb was recommended up to a maximum of five cartridges.¹⁶

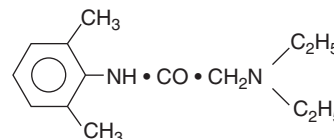
Amide Local Anesthetics

Lidocaine Hydrochloride

Pertinent Information

Classification. Amide.

Chemical formula. 2-Diethylamino-2',6'-acetoxyylidide hydrochloride.



Prepared by. Nils Löfgren, 1943.

FDA approved. November 1948.

Potency. 2 (compared with procaine) (procaine = 1; lidocaine remains the standard of comparison [lidocaine = 1] for all local anesthetics).

Toxicity. 2 (compared with procaine).

Metabolism. In the liver, by the microsomal fixed-function oxidases, to monoethylglycine and xylidide; xylidide is a local anesthetic that is potentially toxic (see Fig. 2.3).¹⁷

Excretion. Via the kidneys; less than 10% unchanged, more than 80% various metabolites.

Vasodilating properties. Considerably less than those of procaine; however, greater than those of prilocaine or mepivacaine.

pK_a . 7.9.

pH of plain solution. Approximately 6.5.

pH of vasoconstrictor-containing solution. Approximately ~3.5.

TABLE
4.5

Lidocaine Hydrochloride

PDF Compressor Free Version

Local Anesthetic (%)	Vasoconstrictor	Duration (minutes)		Maximum Recommended Dose
		Pulpal	Soft Tissue	
2	Epinephrine 1:50,000	60	180–300	7.0 mg/kg 3.6 mg/lb 500 mg absolute maximum
2	Epinephrine 1:100,000	60	180–300	7.0 mg/kg 3.6 mg/lb 500 mg absolute maximum

Onset of action. Rapid (3 to 5 minutes).

Effective dental concentration. 2%.

Anesthetic half-life. 1.6 hours (~90 minutes).

Topical anesthetic action. Yes (in clinically acceptable concentrations [5%]).

Pregnancy classification. B.

Lactation: Safe

Pediatric use. It is difficult to recommend a maximum dose of any drug for pediatric patients because this varies as a function of age and weight. For patients younger than 10 years who have a normal lean body mass and normal body development, the maximum dose may be determined by the application of one of the standard pediatric drug formulas (e.g., Clark's rule) or the patients body weight.¹⁸

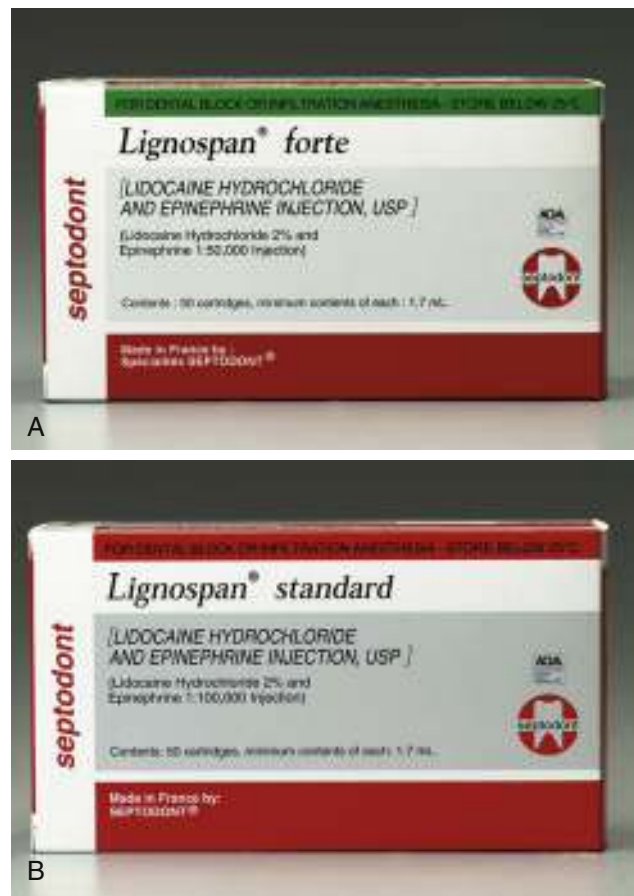Maximum Recommended Dose. The FDA MRD of lidocaine with or without epinephrine is 3.2 mg/lb body weight, or 7.0 mg/kg body weight, for the adult and pediatric patient, not to exceed an absolute maximum dose of 500 mg (Table 4.5).¹⁸

Comments. Lidocaine hydrochloride was synthesized in 1943, and in 1948 became the first amide local anesthetic to be marketed in dental cartridges. Its entry into clinical practice transformed dentistry; it replaced procaine (Novocain) as the drug of choice for pain control. Compared with procaine, lidocaine possesses a significantly more rapid onset of action (3 to 5 minutes vs. 6 to 10 minutes), produces more profound anesthesia, has a longer duration of action, and has greater potency.

Allergy to amide local anesthetics is virtually nonexistent, and true, documented, and reproducible allergic reactions are extremely rare.^{19–24} This is a major clinical advantage of lidocaine (and all amides) over ester-type local anesthetics.¹¹

Within only a few years of its introduction, lidocaine had replaced procaine as the most widely used local anesthetic in both medicine and dentistry—a position it maintains today in most countries. Lidocaine represents the gold standard, the drug against which all new local anesthetics are compared.

In North America, lidocaine hydrochloride is available two formulations: 2% with epinephrine 1:50,000, and 2% with epinephrine 1:100,000 (Fig. 4.2). Lidocaine 2% with epinephrine 1:80,000 is available in the United Kingdom,



• Fig. 4.2 (A) Lidocaine, 2%, with epinephrine 1:50,000. (B) Lidocaine with epinephrine 1:100,000. (Courtesy of Septodont, Inc., Lancaster, PA.)

Australia, and New Zealand. A 2% lidocaine with epinephrine 1:300,000 formulation is available in some countries (although not in North America as of February 2019); 2% lidocaine without epinephrine (2% “plain”) is no longer available in dental cartridges in North America.

Two Percent Lidocaine Hydrochloride Without a Vasoconstrictor (Lidocaine Plain)

Its vasodilating properties severely limit the duration and the depth of pulpal anesthesia (5 to 10 minutes). This vasodilatory effect leads to (1) higher blood levels of lidocaine, with

TABLE
4.6**Lidocaine, 2%, With Epinephrine 1:50,000^{a, b}****PDF Compressor Free Version**

Concentration 2%

Maximum Recommended Dose 7.0 mg/kg

Cartridge Contains 36 mg

Maximum Recommended Dose 3.2 mg/lb

Weight (kg)	Amount (mg)	Cartridges ^c	Weight (lb)	Amount (mg)	Cartridges ^c
10	70	2.0	20	72	2.0
20	140	4.0	40	144	4.0
30	210	6.0 ^d	60	216	6.0 ^d
40	280	6.0 ^d	80	288	6.0 ^d
50	350	6.0 ^d	100	360	6.0 ^d
60	420	6.0 ^d	120	432	6.0 ^d
70	490	6.0 ^d	140	500	6.0 ^d
80	500	6.0 ^d	160	500	6.0 ^d
90	500	6.0 ^d	180	500	6.0 ^d
100	500	6.0 ^d	200	500	6.0 ^d

^aAs with all local anesthetics, the dose differs depending on the area to be anesthetized, the vascularity of the tissues, individual tolerance, and the technique of anesthesia. The lowest dose needed to provide effective anesthesia should be administered.

^bDoses indicated are the maximum suggested for normal healthy individuals (American Society of Anesthesiologists class 1); they should be decreased for debilitated or elderly patients.

^cRounded down to the nearest half-cartridge.

^dTwo hundred micrograms of epinephrine is the dose-limiting factor (1:50,000 contains 36 µg of epinephrine per cartridge).

an attendant increase in the risk of adverse reactions, and (2) increased perfusion in the area of drug deposition. Few clinical indications exist for the use of 2% lidocaine without a vasoconstrictor in the typical dental practice. In August 2011, 2% lidocaine without epinephrine (2% “plain”) in dental cartridges was withdrawn from the dental market in North America. It remains available in multidose vials.

Two Percent Lidocaine With Epinephrine 1:50,000

Inclusion of epinephrine produces a decrease in blood flow (perfusion), leading to decreased bleeding in the area of drug administration caused by the α -stimulating actions of epinephrine. Because of this decrease in perfusion, the local anesthetic is absorbed into the cardiovascular system more slowly (thereby remaining at the site of administration longer, hopefully near the nerve to be blocked), leading to an increase in both the depth and the duration of anesthesia: approximately 60 minutes of pulpal anesthesia and 3 to 5 hours of soft tissue anesthesia (Table 4.6). The resultant blood level of local anesthetic is also decreased. The 1:50,000 epinephrine concentration is equal to 20 µg/mL, or 36 µg of epinephrine per cartridge. For patients weighing more than 45 kg (100 lb), the limiting factor in determining the MRD of this local anesthetic combination is the maximum epinephrine dose of 200 µg for the healthy patient. The MRD for epinephrine-sensitive individuals (e.g., certain cardiovascularly compromised patients [ASA class 3] and clinically hyperthyroid patients

[ASA class 3]) is 40 µg per appointment. This is equivalent to about one cartridge of epinephrine 1:50,000 (see Chapter 22).

In the author’s opinion, the only recommended use of 2% lidocaine with a 1:50,000 epinephrine concentration is for hemostasis (a situation wherein only small volumes are infiltrated directly into the surgical site).

Two Percent Lidocaine With Epinephrine 1:100,000

Administration of 2% lidocaine with epinephrine 1:100,000 decreases blood flow into the area of injection. The duration of action is increased: approximately 60 minutes of pulpal anesthesia and 3 to 5 hours of soft tissue anesthesia (Table 4.7). In addition to the lower blood level of lidocaine, less bleeding occurs in the area of drug administration. The epinephrine dilution is 10 µg/mL, or 18 µg per cartridge. Epinephrine-sensitive patients (see earlier discussion for lidocaine with epinephrine 1:50,000) should be limited to two cartridges of epinephrine 1:100,000 per appointment.

The duration and depth of pulpal anesthesia attained with both lidocaine-epinephrine solutions (1:50,000 and 1:100,000) are equivalent. Each may provide approximately 60 minutes of pulpal anesthesia in normal circumstances and soft tissue anesthesia of 3 to 5 hours’ duration. Indeed, 2% lidocaine with epinephrine 1:200,000 or 1:300,000 provides the same duration of pulpal and soft tissue anesthesia, although not the same level of hemostasis.²⁵

TABLE
4.7Lidocaine, 2%, With Epinephrine 1:100,000^{a-c}

PDF Compressor Free Version

Concentration 2%			Cartridge Contains 36 mg		
Maximum Recommended Dose 7.0 mg/kg			Maximum Recommended Dose 3.2 mg/lb		
Weight (kg)	Amount (mg)	Cartridges ^a	Weight (lb)	Amount (mg)	Cartridges ^a
10	70	2.0	20	72	2.0
20	140	4.0	40	144	4.0
30	210	6.0	60	216	6.0
40	280	7.5	80	288	8.0
50	350	9.5	100	360	10.0
60	420	11.0 ^d	120	432	11.0 ^d
70	490	11.0 ^d	140	500	11.0 ^d
80	500	11.0 ^d	160	500	11.0 ^d
90	500	11.0 ^d	180	500	11.0 ^d
100	500	11.0 ^d	200	500	11.0 ^d

^aAs with all local anesthetics, the dose differs depending on the area to be anesthetized, the vascularity of the tissues, individual tolerance, and the technique of anesthesia. The lowest dose needed to provide effective anesthesia should be administered.

^bDoses indicated are the maximum suggested for normal healthy individuals (American Society of Anesthesiologists class 1); they should be decreased for debilitated or elderly patients.

^cRounded to the nearest half-cartridge.

^dTwo hundred micrograms of epinephrine is the dose-limiting factor (1:100,000 contains 18 µg of epinephrine per cartridge).

In terms of duration and depth of anesthesia for most procedures in a typical dental patient, 2% lidocaine with epinephrine 1:100,000 is preferred to 2% lidocaine with epinephrine 1:50,000. Both formulations provide equal duration and depth, but the 1:100,000 solution contains only half as much epinephrine as the 1:50,000 solution. Although the amount of epinephrine in the 1:50,000 solution is not significant in most patients, ASA class 3 and ASA class 4 risk patients with histories of cardiovascular disorders might prove overly sensitive to these concentrations. Also, an elderly patient is likely to be more hyperresponsive to vasoconstrictors. In these individuals, a more dilute epinephrine formulation (1:100,000 or 1:200,000) should be used.

For hemostasis in procedures in which bleeding is definitely or potentially a problem, 2% lidocaine with epinephrine 1:50,000 is preferred because it decreases bleeding (during periodontal surgery) by 50% compared with a 1:100,000 epinephrine dilution.²⁶ Vasoconstrictors act directly at the site of administration to decrease tissue perfusion, and the 1:50,000 solution provides excellent hemostatic action. The 1:100,000 dilution may also be used for hemostasis, but it is not as effective. Rebound vasodilation occurs with both epinephrine 1:50,000 and epinephrine 1:100,000 as the tissue concentration of epinephrine decreases. Minimum volumes of solution should be administered to provide excellent hemostasis during surgical procedures on soft tissues.

The signs and symptoms of lidocaine toxicity (overdose) may be the same (central nervous system [CNS] stimulation followed by CNS depression) as those described in Chapter 2. However, the stimulatory phase may be brief

or may not develop at all.²⁷ Although muscle tremor and seizures commonly occur with overly high lidocaine blood levels, the first signs and symptoms of lidocaine overdose may include drowsiness, leading to loss of consciousness and respiratory arrest.

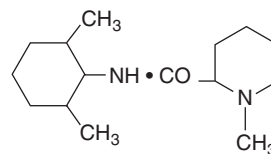
Lidocaine (2%) with epinephrine remains the most used local anesthetic formulation in the dental profession worldwide. A conservatively estimated 1 billion dental cartridges of 2% lidocaine—all formulations—are manufactured annually.

Mepivacaine Hydrochloride

Pertinent Information

Classification. Amide.

Chemical formula. 1-Methyl 2',6'-pipercoloxylidide hydrochloride.



Prepared by. A.F. Ekenstam, 1957; introduced into dentistry in 1960 as a 2% solution containing the synthetic vasopressor levonordefrin, and in 1961 as a 3% solution without a vasoconstrictor. Mepivacaine is available in most countries as a 2% solution with epinephrine 1:100,000.

TABLE
4.8

Mepivacaine Hydrochloride

PDF Compressor Free Version

Local Anesthetic (%)	Vasoconstrictor	Duration (minutes)		Maximum Recommended Dose
		Pulpal	Soft Tissue	
3	None	20: infiltration 40: nerve block	120–180	6.6 mg/kg 3.0 mg/lb 400 mg absolute maximum
2	Levonordefrin	60	180–300	6.6 mg/kg 3.0 mg/lb 400 mg absolute maximum

FDA approved. April 1960.

Potency. 2 (procaine = 1; lidocaine = 2).

Toxicity. 1.5 to 2 (procaine = 1; lidocaine = 2).

Metabolism. In the liver, by microsomal fixed-function oxidases. Hydroxylation and N-demethylation play important roles in the metabolism of mepivacaine.

Excretion. Via the kidneys; approximately 1% to 16% of anesthetic dose is excreted unchanged.

Vasodilating properties. Mepivacaine produces only slight vasodilation. The duration of pulpal anesthesia with mepivacaine without a vasoconstrictor is 20 to 40 minutes (that of lidocaine without a vasoconstrictor is but 5 to 10 minutes; procaine without a vasoconstrictor may produce effects for up to 2 minutes).

pK_a. 7.6.

pH of plain solution. Approximately 5.5 to 6.0.

pH of vasoconstrictor-containing solution. Approximately 4.0.

Onset of action. Rapid (3 to 5 minutes).

Effective dental concentration. 3% without a vasoconstrictor; 2% with a vasoconstrictor.

Anesthetic half-life. 1.9 hours.

Topical anesthetic action. Not in clinically acceptable concentrations.

Pregnancy classification. C.

Lactation: Safe

Pediatric use. The maximum pediatric dose should be carefully calculated.²⁸

Maximum Recommended Dose. The MRD is 6.6 mg/kg body weight, or 3.0 mg/lb body weight, not to exceed 400 mg (Table 4.8).²⁸

Comments. The milder vasodilating property of mepivacaine leads to a longer duration of pulpal anesthesia than is observed with most other local anesthetics when administered without a vasoconstrictor. Plain 3% mepivacaine provides 20 to 40 minutes of pulpal anesthesia (20 minutes via infiltration; 40 minutes via nerve block) and approximately 2 to 3 hours of soft tissue anesthesia.

Three Percent Mepivacaine Without a Vasoconstrictor

This formulation is recommended for patients in whom a vasoconstrictor is contraindicated and for dental

procedures requiring neither lengthy nor profound pulpal anesthesia (Fig. 4.3 and Table 4.9). Plain mepivacaine is commonly used in pediatric patients when the treating doctor is not a pediatric specialist (e.g., general practitioner) and is often quite appropriate in treatment of geriatric patients.

Two Percent Mepivacaine With a Vasoconstrictor, Levonordefrin 1:20,000 or Epinephrine 1:100,000

Mepivacaine with a vasoconstrictor provides depth and duration of pulpal (hard tissue) and total (soft tissue) anesthesia similar to that observed with lidocaine-epinephrine solutions. Pulpal anesthesia of approximately 60 minutes' duration and soft tissue anesthesia of 3 to 5 hours' duration are to be expected (Table 4.10). Mepivacaine is available in the United States in combination with levonordefrin (1:20,000) and elsewhere with epinephrine (1:100,000). Where hemostasis is desired, epinephrine is preferred to levonordefrin.

The incidence of true, documented, and reproducible allergy to mepivacaine, an amide local anesthetic, is virtually nonexistent.

The signs and symptoms of mepivacaine overdose usually follow the more typical pattern of CNS stimulation followed by depression. Although possible, absence of stimulation with immediate CNS depression (e.g., drowsiness and unconsciousness, as is seen more commonly with lidocaine) is rare with mepivacaine.

Mepivacaine is the third most used dental local anesthetic, with approximately 300, 000, 000 dental cartridges manufactured annually.

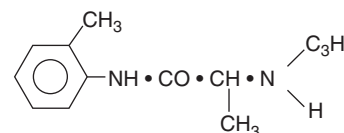
Prilocaine Hydrochloride

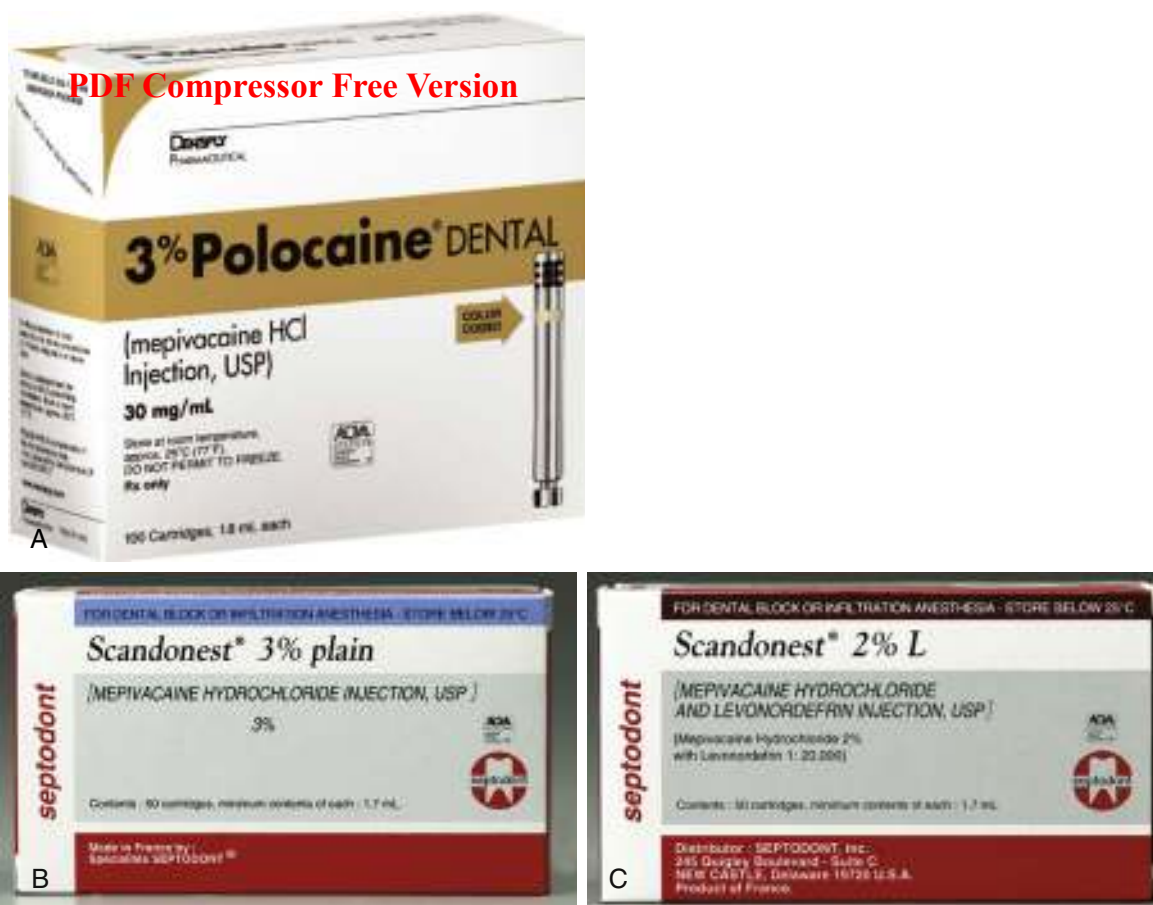Pertinent Information

Classification. Amide.

Other chemical (generic) name. Propitocaine (Japan).

Chemical formula. 2-Propylamino-*o*-propionotoluidide hydrochloride.





• Fig. 4.3 (A and B) Mepivacaine, 3%. (C) Mepivacaine, 2%, with levonordefrin 1:20,000. ([A] Courtesy Dentsply, York, Pennsylvania, United States, [B and C] Courtesy of Septodont, Inc., Lancaster, PA.)

TABLE
4.9

Mepivacaine, 3%, Without a Vasoconstrictor^{a,b}

Concentration 3%			Cartridge Contains 54 mg		
Maximum Recommended Dose 6.6 mg/kg			Maximum Recommended Dose 3.0 mg/lb		
Weight (kg)	Amount (mg)	Cartridges ^c	Weight (lb)	Amount (mg)	Cartridges ^c
10	66	1.0	20	60	1.0
20	132	2.5	40	120	2.0
30	198	3.5	60	180	3.0
40	264	4.5	80	240	4.5
50	330	6.0	100	300	5.5
60	396	7.0	120	360	6.5
70	400	7.5	140	400	7.5
80	400	7.5	160	400	7.5
90	400	7.5	180	400	7.5
100	400	7.5	200	400	7.5

^aAs with all local anesthetics, the dose differs depending on the area to be anesthetized, the vascularity of the tissues, individual tolerance, and the technique of anesthesia. The lowest dose needed to provide effective anesthesia should be administered.

^bDoses indicated are the maximum suggested for normal healthy individuals (American Society of Anesthesiologists class 1); they should be decreased for debilitated or elderly patients.

^cRounded down to the nearest half-cartridge.

TABLE 4.10 Mepivacaine, 2%, With a Vasoconstrictor^{a,b}**PDF Compressor Free Version**

Concentration 2%

Maximum Recommended Dose 6.6 mg/kg

Cartridge Contains 36 mg

Maximum Recommended Dose 3.0 mg/lb

Maximum Recommended Dose 6.6 mg/kg			Maximum Recommended Dose 3.0 mg/lb		
Weight (kg)	Amount (mg)	Cartridges ^c	Weight (lb)	Amount (mg)	Cartridges ^c
10	66	1.5	20	60	1.5
20	132	3.5	40	120	3.0
30	198	5.5	60	180	5.0
40	264	7.0	80	240	6.5
50	330	9.0	100	300	8.0
60	396	11.0	120	360	10.0
70	400	11.0	140	400	11.0
80	400	11.0	160	400	11.0
90	400	11.0	180	400	11.0
100	400	11.0	200	400	11.0

^aAs with all local anesthetics, the dose differs depending on the area to be anesthetized, the vascularity of the tissues, individual tolerance, and the technique of anesthesia. The lowest dose needed to provide effective anesthesia should be administered.

^bDoses indicated are the maximum suggested for normal healthy individuals (American Society of Anesthesiologists class 1); they should be decreased for debilitated or elderly patients.

^cRounded down to the nearest half-cartridge.

Prepared by. Löfgren and Tegnér, 1953; reported in 1960.
FDA approved. November 1965.

Potency. 2 (procaine = 1; lidocaine = 2).

Toxicity. 1 (procaine = 1; lidocaine = 2); 40% less toxic than lidocaine.

Metabolism. The metabolism of prilocaine differs significantly from that of lidocaine and mepivacaine. Because it is a secondary amine, prilocaine is hydrolyzed straight forwardly by hepatic amidases to *o*-toluidine and *N*-propylalanine. Carbon dioxide is a major end product of prilocaine biotransformation. The efficiency of the body's degradation of prilocaine is demonstrated by the extremely small fraction of intact prilocaine recoverable in the urine.²⁹ *o*-Toluidine can induce the formation of methemoglobin, producing methemoglobinemia if large doses are administered. Minor degrees of methemoglobinemia have been observed following both benzocaine and lidocaine administration,^{30,31} but prilocaine consistently reduces the blood's oxygen-carrying capacity, at times sufficiently to cause observable cyanosis.³²⁻³⁴ Limiting the total prilocaine dose to 600 mg (FDA recommendation) avoids symptomatic cyanosis. Methemoglobin blood levels of less than 20% do not usually produce clinical signs or symptoms (which include grayish or slate-blue cyanosis of the lips, mucous membranes, and nail beds and [infrequently] respiratory and circulatory distress). Methemoglobinemia may be reversed within 15 minutes with administration of 1 to 2 mg/kg body weight of 1% methylene blue solution

intravenously over a 5-minute period.³¹ The mechanism of methemoglobin production is discussed in Chapter 10. Prilocaine undergoes biotransformation more rapidly and completely than lidocaine. This occurs not only in the liver but also to a lesser degree in the kidneys and lungs.^{35,36} Plasma levels of prilocaine decrease more rapidly than those of lidocaine.³⁷ Prilocaine is thus considered to be less toxic systemically than comparably potent local anesthetic amides.³⁸ Signs of CNS toxicity after prilocaine administration in humans are briefer and less severe than after the same intravenous dose of lidocaine.³⁹

Excretion. Prilocaine and its metabolites are excreted primarily via the kidneys. Renal clearance of prilocaine is faster than for other amides, resulting in its faster removal from the circulation.⁴⁰

Vasodilating properties. Prilocaine is a vasodilator. It produces greater vasodilation than is produced by mepivacaine but less than that produced by lidocaine and significantly less than that produced by procaine.

pK_a. 7.9.

pH of plain solution. Approximately 6.0 to 6.5.

pH of vasoconstrictor-containing solution. Approximately 4.0.

Onset of action. Slightly slower than that of lidocaine (3 to 5 minutes).

Effective dental concentration. 4%.

Anesthetic half-life. 1.6 hours.

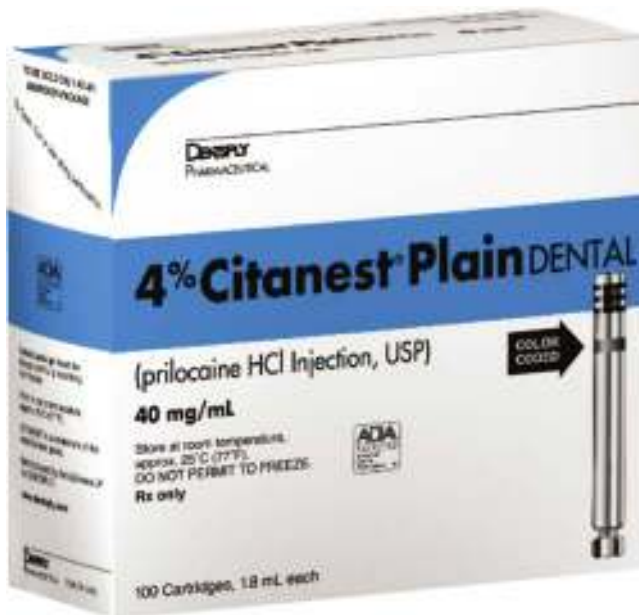Topical anesthetic action. Not in clinically acceptable concentrations.

TABLE 4.11

Prilocaine Hydrochloride

PDF Compressor Free Version

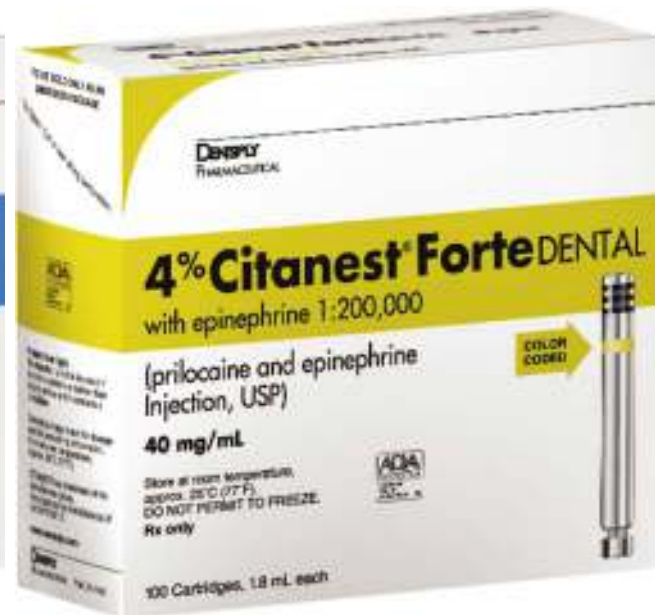Local Anesthetic (%)	Vasoconstrictor	Duration (minute)		Maximum Recommended Dose
		Pulpal	Soft Tissue	
4	None	10–15: infiltration	90–120: infiltration	8.0 mg/kg
		40–60: nerve block	120–240: nerve block	3.6 mg/lb
				600 mg absolute maximum
4	Epinephrine 1:200,000	60–90	180–480	8.0 mg/kg
				3.6 mg/lb
				600 mg absolute maximum



A



B



C



D

• Fig. 4.4 (A and B) Prilocaine, 4%. (C and D) Prilocaine, 4%, with epinephrine 1:200,000. (Courtesy Dentsply, York, Pennsylvania, United States.)

Prilocaine, in its uncharged base form, is an integral part of EMLA cream (eutectic mixture of the local anesthetics lidocaine and prilocaine), a formulation that permits anesthetics to penetrate the imposing anatomic barrier of intact skin. EMLA cream is used to provide topical anesthesia of skin before venipuncture and other painful cosmetic procedures.^{41,42} Oraqix, a noninjectable lidocaine-prilocaine gel, is used successfully to provide pain relief in association with periodontal probing and scaling/root planing when deposited in periodontal pockets,⁴³ for rubber dam placement,⁴⁴ gingival retraction,⁴⁵ and placement of orthodontic temporary anchorage devices.⁴⁶

Pregnancy classification. B.

Nursing mothers. It is not known whether this drug is excreted in human milk. Because many drugs are excreted

in human milk, caution should be exercised when prilocaine is administered to a nursing woman.⁴⁷

Pediatric use. Doses in children should be reduced, commensurate with age, body weight, and physical condition.⁴⁷

Maximum recommended dose. The FDA MRD for prilocaine is 8.0 mg/kg (3.6 mg/lb) body weight for the adult patient, to an MRD of 600 mg (Table 4.11).⁴⁷

Comments. The clinical actions of plain prilocaine (Fig. 4.4) vary significantly with the type of injection technique used. Although true for all anesthetics, the variation between supraperiosteal infiltration and nerve block is more pronounced with plain prilocaine (and plain mepivacaine). Infiltration provides short durations of pulpal (10 to 15 minutes) and soft tissue (1.5 to 2 hours)

TABLE
4.12Prilocaine, 4%, With and Without a Vasoconstrictor^{a,b}

PDF Compressor Free Version

Concentration 4%

Cartridge Contains 72 mg

Maximum Recommended Dose 8.0 mg/kg			Maximum Recommended Dose 3.6 mg/lb		
Weight (kg)	Amount (mg)	Cartridges ^c	Weight (lb)	Amount (mg)	Cartridges ^c
10	80	1.0	20	72	1.0
20	160	2.0	40	144	2.0
30	240	3.0	60	218	3.0
40	320	4.5	80	290	4.0
50	400	5.5	100	362	5.0
60	480	6.5	120	434	6.0
70	560	7.5	140	506	7.0
80	600	8.0	160	578	8.0
90	600	8.0	180	600	8.0
100	600	8.0	200	600	8.0

^aAs with all local anesthetics, the dose differs depending on the area to be anesthetized, the vascularity of the tissues, individual tolerance, and the technique of anesthesia. The lowest dose needed to provide effective anesthesia should be administered.

^bDoses indicated are the maximum suggested for normal healthy individuals (American Society of Anesthesiologists class 1); they should be decreased for debilitated or elderly patients.

^cRounded to the nearest half-cartridge.

anesthesia, whereas regional nerve block (e.g., inferior alveolar nerve block) provides pulpal anesthesia for up to 60 minutes (commonly 40 to 60 minutes) and soft tissue anesthesia for 2 to 4 hours.⁴¹ Thus plain prilocaine is frequently able to provide anesthesia that is equal in duration—although not equal in depth—to that attained with lidocaine or mepivacaine with a vasoconstrictor.

The clinical actions of prilocaine with epinephrine 1:200,000 are not as dependent on anesthetic technique as with other dental local anesthetics. Prilocaine with epinephrine provides lengthy anesthesia while offering a less concentrated epinephrine solution: 1:200,000. Pulpal anesthesia of 60 to 90 minutes' duration and soft tissue anesthesia of 3 to 8 hours' duration are common. The cartridge contains 9 µg of epinephrine; therefore epinephrine-sensitive individuals, such as the ASA class 3 cardiovascular disease patient, may receive up to four cartridges (36 µg) of prilocaine with epinephrine.

In epinephrine-sensitive patients requiring prolonged pulpal anesthesia (≥60 minutes), plain prilocaine or prilocaine with epinephrine 1:200,000 is strongly recommended. It is rapidly biotransformed and, for this reason, is considered to be a safe local anesthetic (e.g., lower toxicity).³⁷

Prilocaine is relatively contraindicated in patients with idiopathic or congenital methemoglobinemia, hemoglobinopathies (sickle cell anemia), anemia, or cardiac or respiratory failure evidenced by hypoxia because methemoglobin levels are increased, decreasing oxygen-carrying

capacity.^{33,34,48} Prilocaine administration is also relatively contraindicated in patients receiving acetaminophen or phenacetin, both of which produce elevations in methemoglobin levels (Table 4.12).

It has been claimed that 4% prilocaine hydrochloride solution (with or without a vasopressor) is associated with a higher risk of paresthesia, primarily of the lingual nerve, than other anesthetic formulations following its administration by inferior alveolar nerve block.^{49,50,51} Although the “evidence” remains anecdotal, it appears that prilocaine, as formulated in North America (as a 4% solution), might be more neurotoxic than other commonly used local anesthetic formulations.⁵² The question of local anesthetic-related paresthesia is discussed in detail in Chapter 17

Articaine Hydrochloride

Pertinent Information

Classification. Hybrid molecule. Classified as an amide; however, it possesses both amide and ester characteristics.

Chemical formula. 3-*N*-Propylaminopropionylamino-2-carbomethoxy-4-methylthiophene hydrochloride.

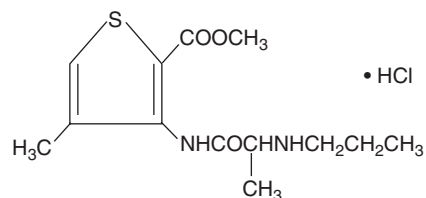


TABLE 4.13 Articaine Hydrochloride
PDF Compressor Free Version

Local Anesthetic (%)	Vasoconstrictor	Duration (minutes)		Maximum Recommended Dose
		Pulpal	Soft Tissue	
4	Epinephrine 1:100,000	60–75	180–360	7.0 mg/kg 3.2 mg/lb No absolute maximum
4	Epinephrine 1:200,000	45–60	120–300	7.0 mg/kg 3.2 mg/lb No absolute maximum

Prepared by. H. Ruschig, G. Ehrhart 1969.

FDA approved. April 2000.

Introduced. 1976 in Germany and Switzerland, 1983 in Canada, 2000 in the United States.

Potency. 1.5 times that of lidocaine; 1.9 times that of procaine.

Toxicity. Similar to that of lidocaine and procaine.

Metabolism. Articaine is the only amide local anesthetic containing a thiophene aromatic ring rather than benzene. Because articaine hydrochloride is the only widely used amide local anesthetic that also contains an ester group, biotransformation of articaine hydrochloride occurs in both plasma (hydrolysis by plasma esterase—similarly to other ester local anesthetics) and liver (hepatic microsomal enzymes—similarly to other amide local anesthetics). The metabolism of articaine hydrochloride is initiated by hydrolysis of the carboxylic acid ester groups to obtain free carboxylic acid.⁵³ Its primary metabolite, articainic acid, is pharmacologically inactive, undergoing additional biotransformation to form articainic acid glucuronide.⁵³ Additional metabolites have been detected in animal studies.⁵⁴ From this point the reaction can follow several pathways: cleavage of carboxylic acid, formation of an acid amino group by internal cyclization, and oxidation.

Excretion. Via the kidneys; approximately 5% to 10% unchanged, approximately 90% metabolites (M_1 at 87%, M_2 at 2%).

Vasodilating properties. Articaine has a vasodilating effect equal to that of lidocaine. Procaine is slightly more vasoactive.

pK_a. 7.8.

pH of plain solution. Not available in North America (4% “plain” articaine hydrochloride is available in Germany).

pH of vasoconstrictor-containing solution. 4.0 to 5.5.

Onset of action. The onset of anesthesia has been shown to be within 1 to 9 minutes of injection of articaine. Pulpal anesthesia lasts approximately 1 hour for infiltrations and up to approximately 2 hours following nerve block.^{55,56}

Effective dental concentration. 4% with epinephrine 1:100,000 or 1:200,000. Articaine hydrochloride is available with epinephrine 1:400,000 in Germany.

Anesthetic half-life. 0.5 hours (27 minutes).⁵⁷

Topical anesthetic action. Not in clinically acceptable concentrations.

Pregnancy classification. C.⁵⁵

Nursing mothers. It is not known whether articaine is excreted in human milk. Because many drugs are excreted in human milk, caution should be exercised when articaine is administered to a nursing woman. When using articaine, nursing mothers may choose to pump and discard breast milk for approximately 4 hours (based on plasma half-life) following an injection of articaine (to minimize infant ingestion) and then resume breastfeeding.⁵⁵

Pediatric use. Safety and efficacy of articaine in pediatric patients below the age of younger than 4 years have not been established. The quantity of articaine hydrochloride in children aged 4 to 16 years to be injected should be determined by the age and weight of the child and the magnitude of the operation. The maximum dose of 4% articaine hydrochloride should not exceed 7 mg/kg.^{55,56}

Maximum recommended dose. The FDA MRD is 7.0 mg/kg body weight, or 3.2 mg/lb body weight, for the adult patient (Tables 4.13 and 4.14).^{55,56}

Comments. Originally known as *carticaine*, the generic nomenclature of this local anesthetic was changed in 1984 to *articaine*. Literature appearing before 1984 should be reviewed under the original name.

Articaine is the only amide anesthetic to possess a thiophene ring as its lipophilic moiety. It has many of the physicochemical properties of other amide and ester local anesthetics, with the exception of the aromatic moiety and the degree of protein binding.

Articaine has been available in Europe since 1976 and in Canada since 1983 in two formulations: 4% with epinephrine 1:100,000 and 4% with epinephrine 1:200,000 (Fig. 4.5). In May 2000 the FDA approved articaine hydrochloride with epinephrine 1:100,000 for marketing in the United States.⁵⁸⁻⁶⁰ The formulation with epinephrine 1:100,000 provides between 60 and 75 minutes of pulpal anesthesia; the 1:200,000 formulation provides approximately 45 to 60 minutes.^{61,62}

Since its introduction into the US dental market in May 2000, articaine has steadily become increasingly

TABLE
4.14Articaine, 4%, With Epinephrine 1:100,000 or 1:200,000^{a,b}

PDF Compressor Free Version

Concentration 4%

Maximum Recommended Dose 7.0 mg/kg

Cartridge Contains 72 mg

Maximum Recommended Dose 3.6 mg/lb

Weight (kg)	Amount (mg)	Cartridges ^c	Weight (lb)	Amount (mg)	Cartridges ^c
10	70	1.0	20	72	1.0
20	140	2.0	40	144	2.0
30	210	3.0	60	216	3.0
40	280	4.0	80	288	4.0
50	350	5.0	100	360	5.0
60	420	6.0	120	432	6.0
70	490	7.0	140	504	7.0
80	560	8.0	160	576	8.0
90	630	9.0	180	648	9.0
100	700	10.0	200	720	10.0

^aAs with all local anesthetics, the dose differs depending on the area to be anesthetized, the vascularity of the tissues, individual tolerance, and the technique of anesthesia. The lowest dose needed to provide effective anesthesia should be administered.

^bDoses indicated are the maximum suggested for normal healthy individuals (American Society of Anesthesiologists 1); they should be decreased for debilitated or elderly patients.

^cRounded to the nearest half-cartridge.



• Fig. 4.5 Articaine, 4%, with epinephrine 1:100,000 (A) and 1:200,000 (B). (Courtesy of Septodont, Inc., Lancaster, PA.)

popular. In 2018 articaine was the second most used dental local anesthetic in the United States (~39.3% market share).⁶³ Articaine, as the most recently marketed dental local anesthetic, has been the subject of intense discussion and of many (anecdotal) claims made by dentists, some good (faster onset, increased success rates; “don’t miss as often”), some bad (increased risk of paresthesia). It has been claimed that articaine is able to diffuse through soft and hard tissues more reliably than other local anesthetics.^{64,65} Clinically, it is claimed that following maxillary buccal infiltration, articaine on occasion may provide palatal soft tissue anesthesia, obviating the need for palatal injection, which, in many hands, is traumatic.⁶⁵

Some initial claims about articaine have been shown to be true, specifically, the significant success of articaine administered by buccal infiltration in the mandible of adult

patients.⁶⁶⁻⁷² This aspect of articaine’s clinical profile is discussed in Chapter 20.

The success of articaine in the United States mirrors its success elsewhere. In Germany, the first country to have articaine (1976), by 1989 it was used by 71.7% of German dentists,⁷³ and by 2010 it commanded 95% of the German dental local anesthetic market.⁷⁴ Articaine has become the leading local anesthetic in Canada, which acquired it in 1983. In the United States, where articaine has been available since June 2000, it commanded 38.4% of the local anesthetic market in 2014, increasing to 39.3% in 2018.⁶³

World wide, articaine is the second most used dental local anesthetic with approximately 600,000,000 cartridges manufactured annually.

Reports of paresthesia following local anesthetic administration became more frequent after the introduction of

articaine into the United States. An overwhelming majority of reported cases occurred following inferior alveolar nerve block and primarily in the form of a paresthesia. The question of paresthesia related to local anesthetic drug administration is addressed in depth in Chapters 17 and 20.

Articaine, like other local anesthetics, can cause methemoglobinemia, particularly in conjunction with methemoglobin-inducing agents. Therefore articaine is relatively contraindicated in patients with congenital or idiopathic methemoglobinemia, or in patients who are receiving treatment with methemoglobin-inducing agents because they are more susceptible to drug-induced methemoglobinemia.⁵⁵ Such reactions had been noted after the intravenous administration of articaine for regional anesthetic purposes; however, no cases have been reported when articaine was administered in the usual manner and volume for dental procedures.

Articaine hydrochloride with epinephrine is contraindicated in persons with known sensitivity to amide-type local anesthetics (few to none) and in persons with sulfite sensitivity (such as some asthmatic patients with allergic-type asthma, as epinephrine-containing local anesthetic formulations contain the antioxidant sodium metabisulfite). Articaine hydrochloride should be used with caution in persons with hepatic disease and significant impairment of cardiovascular function because amide-type local anesthetics undergo biotransformation in the liver and have myocardial depressant properties. Articaine is listed by the FDA as a class C drug during pregnancy. It should be used with caution in women who are nursing because it is not known whether articaine is excreted in milk.^{55,56} When articaine is administered to a nursing woman, the FDA recommends a 4-hour period of “pump and discard” to ensure that the infant does not receive the drug through breast milk.⁵⁵ Administration to children younger than 4 years is not recommended because insufficient data are available to support such use.

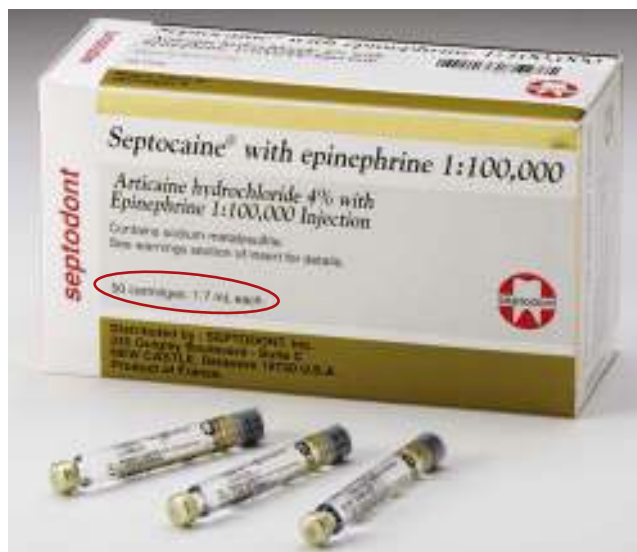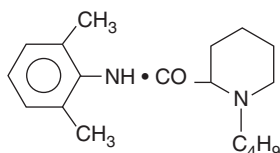
Cartridges of articaine marketed in the United States are listed as containing “1.7 mL” (Fig. 4.6), in contrast to other local anesthetic cartridges, which are labeled as containing “1.8 mL.” Some might interpret this to mean that the cartridge consists of 68 mg. This is incorrect. Articaine hydrochloride cartridges are identical in all ways to other dental cartridges. However, as discussed earlier in this chapter, a change was made to labeling, not to the content of the cartridge.

Bupivacaine Hydrochloride

Pertinent Information

Classification. Amide.

Chemical formula. 1-Butyl-2',6'-pipecoloxylidide hydrochloride; structurally related to mepivacaine except for a butyl group replacing a methyl group.



• Fig. 4.6 Articaine box showing “1.7 mL each.” (Courtesy of Septodont, Inc., Lancaster, PA.)

Prepared by. A.F. Ekenstam, 1957.

FDA approved. October 1972.

Potency. Four times that of lidocaine, mepivacaine, and prilocaine.

Toxicity. Less than four times that of lidocaine and mepivacaine.

Metabolism. Metabolized in the liver by amidases.

Excretion. Via the kidney; 16% unchanged bupivacaine has been recovered from human urine.

Vasodilating properties. Relatively significant: greater than those of lidocaine, prilocaine, and mepivacaine, yet considerably less than those of procaine.

pK_a. 8.1.

pH of plain solution. 4.5 to 6.0.

pH of vasoconstrictor-containing solution. 3.0 to 4.5.

Onset of action. Slower onset than other commonly used local anesthetics (e.g., 6 to 10 minutes).

Effective dental concentration. 0.5%.

Anesthetic half-life. 2.7 hours.

Topical anesthetic action. Not in clinically acceptable concentrations.

Pregnancy classification. C.

Nursing mothers. The FDA states that it is not known whether local anesthetic drugs are excreted in human milk. Because many drugs are excreted in human milk, caution should be exercised when local anesthetics are administered to a nursing woman.^{75,76} Health Canada (equivalent to the US FDA) states that bupivacaine is excreted in the breast milk, but in such small quantities that there is generally no risk of affecting the infant at therapeutic doses.

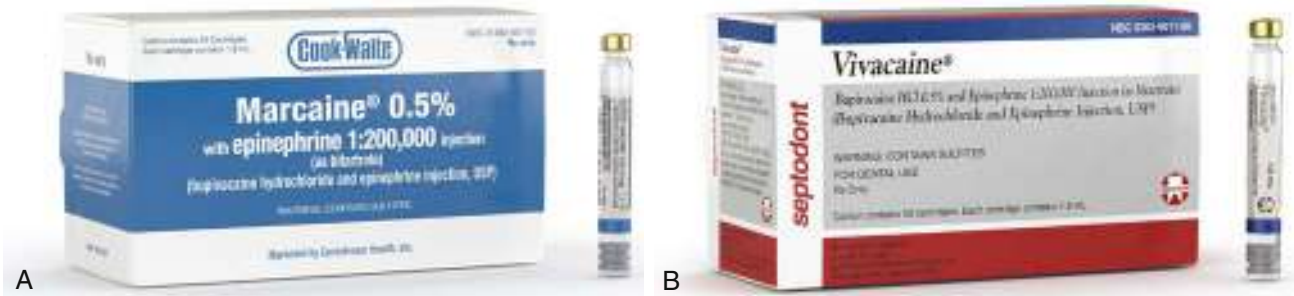Pediatric use. Until further experience is gained in children younger than 12 years, administration of bupivacaine in this age group is not recommended,^{75,76} and the Canadian drug package insert states: “Until further experience is gained, bupivacaine is not recommended for children younger than two years of age.”⁷⁷

TABLE
4.15

Bupivacaine Hydrochloride

PDF Compressor Free Version

Local Anesthetic (%)	Vasoconstrictor	Duration (minutes)		Maximum Recommended Dose
		Pulpal	Soft Tissue	
0.5	Epinephrine 1:200,000	90–180 (≤360)	240–540 (≤720)	United States: none listed Canada: 2.0 mg/kg, 0.9 mg/lb, 200 mg absolute maximum



• **Fig. 4.7** Bupivacaine, 0.5%, with epinephrine 1:200,000. (A) Marcaine. (B) Vivacaine. ([A] Courtesy, Cook-Waite, Carestream Dental LLC, Atlanta, Georgia, United States, [B] Courtesy of Septodont, Inc., Lancaster, PA.)

Maximum recommended dose. The FDA MRD of bupivacaine is 90 mg. There is no recommended dose for bupivacaine based on body weight in the United States (Table 4.15).^{75,76} In Canada, the MRD is 2.0 mg/kg to a maximum of 200 mg.⁷⁷ For children older than 2 years, in Canada the maximum dose of bupivacaine is based on 2.0 mg/kg (0.9 mg/lb).⁷⁷

Comments. Bupivacaine has been available in cartridges since February 1982 in Canada and since July 1983 in the United States. Bupivacaine is available as a 0.5% solution with epinephrine 1:200,000 (Fig. 4.7); there are two primary indications for its use in dentistry:

1. lengthy dental procedures for which pulpal (deep) anesthesia in excess of 90 minutes is necessary (e.g., full mouth reconstruction, implant surgery, extensive periodontal procedures)
2. management of postoperative pain (e.g., endodontic, periodontal, exodontia)

The patient's requirement for postoperative opioid analgesics is considerably lessened when bupivacaine is administered for pain control.⁷⁸ For postoperative pain control after a short surgical procedure (<30 minutes), bupivacaine may be administered at the start of the procedure following administration of the local anesthetic chosen for preprocedural pain management (e.g., articaine, lidocaine, mepivacaine, prilocaine). However, for postoperative pain control after lengthy surgical procedures, it is reasonable to administer bupivacaine at the conclusion of the procedure, just before the patient's release from the dental operating chair.

A protocol for management of postsurgical pain has been developed that is clinically quite effective.^{79–81} It combines

the administration of preoperative and postoperative non-steroidal antiinflammatory drugs with injectable local anesthetics for procedural and postoperative pain management. This surgical pain management protocol is described fully in Chapter 16.

The onset of anesthesia with bupivacaine is commonly delayed for 6 to 10 minutes, which is understandable in view of its pK_a of 8.1. If bupivacaine is being used for pain control *during* a lengthy dental procedure, it may be advisable to initiate procedural pain control with a more rapidly acting amide (e.g., articaine, mepivacaine, lidocaine, prilocaine), allowing the procedure to commence more promptly. This should be followed with the administration of bupivacaine for increased duration of pain control.

Bupivacaine is not recommended in younger patients (younger than 12 years in the United States⁷⁵; younger than 2 years in Canada⁷⁷) or in those for whom the risk of postoperative soft tissue injury produced by self-mutilation is increased, such as physically and mentally disabled persons. Bupivacaine is rarely indicated in children because pediatric dental procedures are usually of short duration and the increased risk of self-inflicted soft tissue injury (e.g. chewing of the lip or tongue) after the child has left the dental office.

ANESTHETICS FOR TOPICAL APPLICATION

Use of topically applied local anesthetics is an important component of the atraumatic administration of intraoral local anesthesia (see Chapter 11). Conventional topical anesthetics are unable to penetrate intact skin but do diffuse through abraded skin (e.g., sunburn) and any mucous membranes.

TABLE 4.16

Effective Concentrations for Injection and Topical Application of Local Anesthetics

Agent	Effective Concentration		Useful as Topical Anesthetic
	Injection (%)	Topical (%)	
Lidocaine	2	2–5	Yes
Mepivacaine	2–3	12–15	No
Procaine	2–4	10–20	No
Tetracaine	0.25–1	0.2–1	Yes

The concentration of a local anesthetic applied topically is typically greater than that of the injectable form of the local anesthetic. This higher concentration facilitates diffusion of the drug through the mucous membrane. Higher concentration also increases the risk of toxicity, both locally to tissues and systemically if the drug is efficiently absorbed.⁸² Because topical anesthetic formulations do not contain vasoconstrictors and local anesthetics have vasodilatory properties, vascular absorption of some topical formulations is rapid, and blood levels may quickly reach those achieved by direct intravenous administration.⁸²

Many injectable local anesthetics are ineffective when applied topically (e.g., articaine hydrochloride, mepivacaine hydrochloride, prilocaine hydrochloride, procaine hydrochloride) because the concentrations necessary to produce anesthesia via topical application are high, with significantly increased overdose and local tissue toxicity potential (Table 4.16).

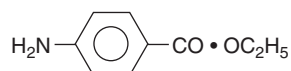
As a general rule, topical anesthetics are effective only on surface tissues (2 to 3 mm). Tissues deep to the area of application are poorly anesthetized, if at all. However, surface anesthesia does allow atraumatic needle penetration of the mucous membrane.^{83,84}

The topical anesthetics benzocaine and lidocaine base (not the hydrochloride form used for injection) are insoluble in water. However, they are soluble in alcohol, propylene glycol, polyethylene glycol, and other vehicles suitable for surface application. The base forms of benzocaine and lidocaine are slowly absorbed into the cardiovascular system and therefore are less likely to produce an overdose reaction following typical dental application.

Some topical anesthetics are marketed in pressurized spray containers. Although they are no more effective than other forms, it is difficult to control the amount of anesthetic expelled and to confine it to the desired site of application. Spray devices that do not deliver measured doses should not be used intraorally.

Benzocaine

Benzocaine (ethyl *p*-aminobenzoate) is an ester local anesthetic:



1. Poor solubility in water.
2. Poor absorption into the cardiovascular system.
3. Systemic toxic (overdose) reactions virtually unknown.
4. Remains at the site of application longer, providing a prolonged duration of action.
5. Not suitable for injection (not water-soluble).
6. Localized allergic reactions may occur after prolonged or repeated use. Although allergic reaction to ester anesthetics is rare, ester local anesthetics are more allergenic than amide local anesthetics.⁸⁵
7. Inhibits the antibacterial action of sulfonamides.⁸⁶
8. Available in the following formulations in numerous doses: aerosol, gel, gel patch, ointment, and solution (Fig. 4.8).

Benzocaine, Butamben, and Tetracaine Hydrochloride

Aerosol, gel, ointment, and solution: benzocaine 140 mg/mL; butamben 20 mg/mL; tetracaine hydrochloride, 20 mg/mL. Proprietary name: Cetacaine (Fig. 4.9)

Cocaine Hydrochloride

Cocaine hydrochloride (benzoylmethylecgonine hydrochloride) occurs naturally as a white crystalline solid that is highly soluble in water:

1. Used exclusively via topical application. Injection of cocaine is contraindicated because of the ready availability of more effective and much less toxic local anesthetics. Cocaine is an ester local anesthetic.
2. Onset of topical anesthetic action is quite rapid, usually occurring within 1 minute.
3. Duration of anesthetic action may be as long as 2 hours.
4. Absorbed rapidly but eliminated slowly (elimination half-life 42 minutes).
5. Undergoes metabolism in the liver and plasma.
6. Unmetabolized cocaine may be found in the urine.
7. Cocaine is the only local anesthetic consistently demonstrated to produce vasoconstriction, which develops as a result of its ability to potentiate the actions of endogenous epinephrine and norepinephrine.⁸⁷ Addition of vasoconstrictors to cocaine is therefore unnecessary and is potentially dangerous, increasing the likelihood of dysrhythmias, including ventricular fibrillation.

PDF Compressor Free Version



• **Fig. 4.8** 20% benzocaine containing topical anesthetic gels. (A and B) available in a variety of 'flavors.' ([A] Courtesy Beutlich Pharmaceuticals, Waukegan, Illinois, United States, [B] Courtesy of Septodont, Inc., Lancaster, PA.)



• **Fig. 4.9** Cetacaine brand of benzocaine, butamben, and tetracaine hydrochloride. (Courtesy Cetylite Inc., Pennsauken, New Jersey, United States.)

8. Classified as a Schedule II drug under the Controlled Substances Act. Repeated use results in psychological dependence and tolerance.
9. Overdose of cocaine is not uncommon following illicit use, primarily because the drug is readily absorbed from mucous membranes and its dosage is not carefully monitored.
10. Clinical manifestations of mild overdose include euphoria, excitement, restlessness, tremor, hypertension, tachycardia, and tachypnea.
11. Clinical manifestations of acute cocaine overdose include excitement, restlessness, confusion, tremor, hypertension, tachycardia, tachypnea, nausea and vomiting, abdominal pain, exophthalmos, and mydriasis; these are followed by depression (CNS, cardiovascular, respiratory) and death from respiratory arrest.
12. It is available in concentrations ranging from 1% to 10%.⁸⁷
13. It is recommended that the concentration of cocaine should not exceed 4% for topical application to oral mucous membranes.
14. Solutions of cocaine are unstable and deteriorate on standing.
15. Because of the extreme abuse potential of cocaine, its use as a topical anesthetic in dentistry is not recommended.
16. Cocaine is occasionally applied topically prior to surgical procedures by otolaryngologists and ophthalmologists.

EMLA (Eutectic Mixture of Local Anesthetics)

EMLA cream (Eutectic Mixture of Local Anesthetics) (lidocaine and prilocaine) is an emulsion in which the oil phase is a eutectic mixture of lidocaine and prilocaine in a ratio of 1:1 by weight. It was designed as a topical anesthetic able to provide surface anesthesia for intact skin (other topical anesthetics do not produce anesthesia on intact skin, they produce it only on abraded skin or mucous membrane), and as such is used primarily before painful procedures such as venipuncture and other needle insertions. Originally marketed for use in pediatrics, EMLA has gained popularity among persons with needle phobia (trypanophobia) and persons in whom other superficial, but painful, procedures are performed (e.g., hair removal).

EMLA use has become almost routine during circumcision,⁸⁸ during leg ulcer débridement,⁸⁹ and during gynecologic procedures.⁹⁰ Because intact skin is a barrier to drug diffusion, EMLA must be applied 1 hour before the procedure. Satisfactory numbing of the skin occurs 1 hour after application, reaches a maximum at 2 to 3 hours, and lasts for 1 to 2 hours after removal.

EMLA is supplied in a 5- or 30-g tube (Fig. 4.10A) or as an EMLA anesthetic disk. The EMLA disk is a white, round, cellulose disk preloaded with EMLA, packaged in protective laminate foil surrounded by adhesive tape.

EMLA is contraindicated for use in patients with congenital or idiopathic methemoglobinemia, children younger than 12 months who are receiving treatment with methemoglobin-inducing agents, and patients with known sensitivity to amide-type local anesthetics or any other component of the product.⁹¹

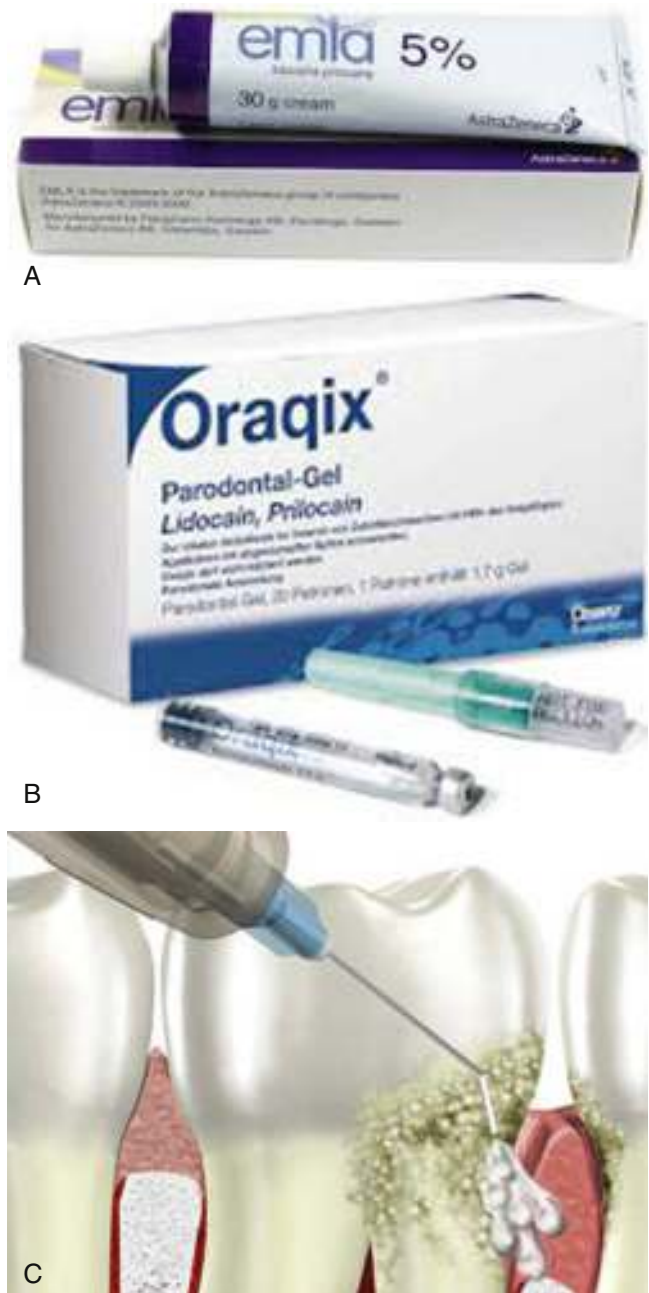Because EMLA is effective in penetrating intact skin, its ability to produce effective topical anesthesia in the oral cavity seems obvious. Although the drug package insert⁹² stated originally that “EMLA is not recommended for use on mucous membranes,” subsequent clinical trials demonstrated satisfactory results.⁹³⁻⁹⁶

Bernardi et al.⁸³ demonstrated statistically significant analgesia in 52 dental patients requiring removal of metal maxillary or mandibular splints used to contain fractures. They concluded that “the analgesic effect[s] of EMLA cream on oral mucosa allow the application of contact anesthesia to be broadened to oral surgery and dentistry, limiting it to those procedures that do not involve deep tissues and only require short-term anesthesia.”⁸³

Munshi et al.⁹⁴ reported on the use of EMLA cream in 30 pediatric patients undergoing a variety of clinical procedures, including extraction of mobile primary teeth and root stumps and pulpal therapy procedures in primary teeth, in which EMLA is used as the sole anesthetic agent. The results show that use of EMLA could eliminate to some extent use of the needle in procedures performed in pediatric dentistry.^{95,96}

Oraqix

The dental formulation of EMLA, Oraqix, is likewise composed of 2.5% lidocaine and 2.5% prilocaine. Application of the periodontal gel (Oraqix) to periodontal pockets



• **Fig. 4.10** (A) EMLA cream. Oraqix delivery system (B) and being used (C). (A) Courtesy Dentsply Sirona, York, Pennsylvania, United States.)

produces an anesthetic effect in 30 seconds. The intensity of anesthesia does not increase beyond 30 seconds. The duration of anesthesia is approximately 20 minutes (range 14 to 27 minutes). Reapplication may be needed to maintain the anesthetic effect for the duration of the planned procedure (see Fig. 4.10B and C).

Indication: The indication for administration of Oraqix is for adults who require localized anesthesia in periodontal pockets during scaling and/or root planing.⁹⁷⁻¹⁰⁰ Oraqix has also been used in prosthodontics for pain management during intraperiodontal gingival retraction¹⁰¹ and to provide palatal anesthesia before palatal needle penetration¹⁰² and, less effectively, placement of orthodontic temporary anchorage devices.¹⁰³

Application: Oraqix should be applied on the gingival margin around the selected teeth with use of the blunt-tipped applicator. The compressed cartridge should be allowed to pass before treatment starts. A longer waiting time does not enhance anesthesia. The anesthetic effect, as assessed by probing of the pocket depths, has a duration of approximately 20 minutes (individual overall range 14 to 31 minutes). If the anesthesia starts to wear off, Oraqix may be reapplied if needed. The MRD of Oraqix in one treatment session is five cartridges.⁹⁷

Lidocaine

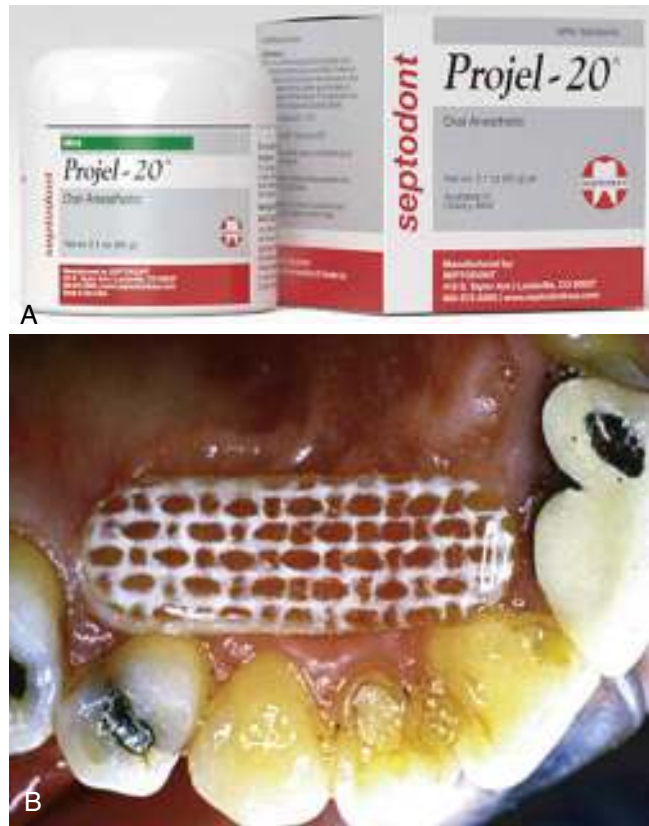
Lidocaine is available in two formulations for topical application: (1) lidocaine base, which is poorly soluble in water, used as a 5% concentration, is indicated for use on mucous membrane, ulcerated, abraded, or lacerated tissue;¹⁰⁴ and (2) lidocaine hydrochloride, its water-soluble preparation, which is used as a 2% concentration. The water-soluble form of lidocaine penetrates tissue more efficiently than the base form. However, systemic absorption of lidocaine hydrochloride is also greater, providing greater risk of toxicity than the base form, which is more commonly used in dentistry:

1. Lidocaine is an amide local anesthetic with an exceptionally low incidence of allergic reactions.
2. The MRD of 5% lidocaine (base) following topical application is 5 g, containing 250 mg (which is equivalent to 300 mg of lidocaine hydrochloride).¹⁰⁴
3. Lidocaine base is available as an ointment, patch, and solution in various dosage forms (Fig. 4.11).

Tetracaine Hydrochloride

Tetracaine hydrochloride (2-dimethylaminoethyl-4-butylaminobenzoate hydrochloride) is a long-duration ester local anesthetic that can be injected or applied topically:

1. It is highly soluble in water.
2. Applied topically, it is five to eight times more potent than cocaine.
3. Its onset of action after topical application is slow.
4. Its duration of action is approximately 45 minutes after topical application.
5. It is metabolized in plasma and the liver by plasma pseudocholinesterase at a slower rate than procaine.
6. A 4% concentration is used for topical application.
7. It is rapidly absorbed through mucous membranes. Its use should be limited to small areas to avoid rapid absorption. Other, more slowly or poorly absorbed agents should be used in lieu of tetracaine when larger areas of topical anesthesia are necessary.
8. The MRD is 20 mg when it is used for topical application. This represents 1 mL of a 2% solution.
9. Caution is urged because of great potential for systemic toxicity.
10. Availability (Canada):
 - a. Aerosol: 0.7 mg/metered spray
 - i. Supracaine



• **Fig. 4.11** Topical anesthetics: lidocaine. (A) Lidocaine ointment. (B) Dentipatch. ([A] Courtesy of Septodont, Inc., Lancaster, PA and [B] Courtesy Noven Pharmaceuticals Inc., Miami, Florida, United States.)

11. Tetracaine (3%) with the vasoconstrictor oxymetazoline has been shown to provide pulpal anesthesia of maxillary nonmolar teeth when administered by aerosol mist into a patient's nares.^{105,106} Use of intranasal local anesthesia for dental pain control is discussed in Chapter 20.

Compounded Local Anesthetics

Compounding is the process by which a pharmacist or doctor combines, mixes, or alters pharmaceuticals or ingredients to create a custom-made medication in accordance with a prescription.¹⁰⁷ Compounded topical anesthetics are neither FDA regulated nor unregulated. Some compounding pharmacies bypass the FDA's drug approval process, which is based on reliable scientific data and ensures that a marketed drug is safe, effective, properly manufactured, and accurately labeled. In December 2006¹⁰⁸ and again in January 2009¹⁰⁹ the FDA issued a public health advisory alert about the potential life-threatening side effects of compounded topical anesthetics. Exposure to high concentrations of local anesthetics can lead to serious adverse reactions, including anesthetic overdose, seizures, irregular heartbeats, and death. At least two deaths have been attributed to the lay use of compounded topical anesthetics.⁴⁶ The compounded topical anesthetic LasergelPlus 10/10 was associated with the death of a 22-year-old woman on January 5, 2005.

The compounded topical anesthetic Photocaine gel was associated with the death of a 25-year-old woman on November 1, 1997. The patient had applied the topical anesthetic to their legs and wrapping them in cellophane before laser hair removal surgery.

In recent years many dentists in the United States have become enamored with compounded topical anesthetic gels. Most commonly the formulation consists of 20% lidocaine, 4% tetracaine, and 2% phenylephrine.¹¹⁰ Other popular compounded topical formulations include Profound and Profound PET. Profound contains 10% lidocaine, 10% prilocaine, and 4% tetracaine.¹¹⁰ It was developed originally for use in soft tissue laser surgery.¹¹¹

Kravitz¹¹⁰ lists the risks associated with compounded topical anesthetics:

- Compounded topical anesthetics are packaged in vials and tubes, which makes accurate dosing difficult.
- The MRD is unknown because compounded topical anesthetics are meant to be custom-produced and used by only one patient.
- Compounded topical anesthetics have a low therapeutic index (there is a narrow difference between the optimal therapeutic dose of these products and the doses at which they become toxic).
- Compounded topical anesthetics may differ in their composition, the quality of the mixture, and the strength of anesthesia.
- Compounded topical anesthetics are often labeled improperly and the labels fail to warn the user of risks and adverse reactions.
- Compounded topical anesthetics regularly include several active anesthetics, often resulting in mixtures of esters and amides.

In 2004 the then-editor of the *Journal of the American Dental Association*, Dr. Marjorie K. Jeffcoat, proffered simple advice to her readers with regard the use of compounded pharmaceuticals: “Don’t do it.”¹¹²

Kravitz continued: “Notwithstanding the recent FDA warnings, there still arguably is a place for doctor-prescribed, doctor-applied compounded topical anesthetics for use on an individualized basis. Until these drugs become federally regulated, however, the large-scale production of some remains an end-run on manufacturing requirements, and their routine use remains a questionable therapeutic practice that may have life-threatening consequences.”¹¹⁰

SELECTION OF A LOCAL ANESTHETIC

Because of the many injectable local anesthetic combinations available, it is sometimes difficult to select an ideal drug for any given patient. Many dentists simply deal with this by using one local anesthetic formulation for any and all procedures, regardless of their duration. For example, the dentist may elect to use 2% lidocaine with epinephrine 1:100,000 for procedures lasting 5 to

TABLE 4.17 Approximate Duration of Pulpal and Soft Tissue Anesthesia for Available Local Anesthetics

Drug Formulation	Duration (min)	
	Pulpal	Soft Tissue
3% mepivacaine (infiltration)	5–10	90–120
4% prilocaine (infiltration)	10–15	60–120
4% prilocaine (nerve block)	40–60	120–240
4% articaine + epinephrine 1:200,000	45–60	180–240
2% lidocaine + epinephrine 1:50,000	60	180–300
2% lidocaine + epinephrine 1:100,000	60	180–300
2% mepivacaine + levonordefrin 1:20,000	60	180–300
2% mepivacaine + epinephrine 1:100,000	60	180–300
4% articaine + epinephrine 1:100,000	60–75	180–300
4% prilocaine + epinephrine 1:200,000	60–90	180–480
0.5% bupivacaine + epinephrine 1:200,000	>90	240–720

10 minutes and for procedures involving 90 minutes of treatment. Although the duration of pulpal anesthesia achievable with this drug in ideal circumstances (middle of the bell-shaped curve) may permit pain-free treatment in both these instances, the patient who requires only 10 minutes of pulpal anesthesia will remain anesthetized unnecessarily for an additional 3 to 5 hours (soft tissues), whereas the patient requiring 90 minutes of pulpal anesthesia will likely experience pain toward the end of the procedure.

A rational approach to selection of an appropriate local anesthetic for a patient includes consideration of several factors: (1) the length of time for which pain control (pulpal and/or soft tissue) is necessary; (2) the need for posttreatment pain control; (3) the need for hemostasis; and (4) whether any contraindications exist to the administration of the selected local anesthetic.¹ Table 4.17 lists local anesthetic formulations currently available in North America according to their expected duration of pulpal and soft tissue anesthesia. Again, it must be noted that these numbers are approximations, and the actual duration of clinical anesthesia may be somewhat longer or shorter than indicated.

A second consideration in the selection of a local anesthetic must be the need for postoperative pain control. A long-duration local anesthetic can be administered when postoperative pain is thought to be a factor. Local anesthetics

providing a shorter duration of soft tissue anesthesia, such as 3% mepivacaine, can be used for nontraumatic procedures. When postoperative pain is expected, 5% mepivacaine (for 8 to 12 hours of soft tissue anesthesia [via nerve block]) is recommended.

For patients in whom self-inflicted soft tissue injury represents a potential risk, a short-duration anesthetic should be considered. These patients include younger children, the older-old (>85 years) patient, and physically or mentally disabled patients, who might accidentally, or purposely, bite or chew the still numb soft tissue of their lips or tongue, and persons unable to miss a meal (e.g., those with type 1 diabetes) because of residual soft tissue anesthesia. For these patients, 3% mepivacaine is recommended for use in short procedures; however, in situations in which these patients require a more profound and/or longer duration of pulpal anesthesia, use of a local anesthetic containing a vasoconstrictor is necessary. The introduction of the local anesthesia reversal agent phentolamine mesylate (Oraverse) has made it possible to significantly shorten the duration of residual soft tissue anesthesia, thereby minimizing the risk of accidental self-inflicted soft tissue injury (e.g., biting of the lip or tongue).¹¹³⁻¹¹⁵ Reversal of soft tissue anesthesia is discussed in [Chapter 20](#).

A third factor in choosing a local anesthetic is the requirement for hemostasis during the procedure. Anesthetic solutions containing epinephrine in a concentration of 1:50,000 or 1:100,000 are recommended, via local infiltration into the surgical site, when hemostasis is considered necessary. More dilute epinephrine formulations (e.g., 1:200,000, 1:400,000) are not effective for hemostasis, nor is levonordefrin or felypressin.

A fourth factor in the selection of a local anesthetic involves the presence of any contraindications to the use of the selected local anesthetic (see [Table 4.2](#)).

Absolute contraindications require that the offending drug(s) is not administered to the patient in any circumstance. The risk of a life-threatening situation is unacceptably elevated. Most absolute contraindications to local anesthetic administration are, in fact, medical contraindications to the delivery of elective dental care (e.g., the patient is too ill to tolerate dentistry—ASA class 4). However, one absolute contraindication to local anesthetic administration does exist: true, documented, and reproducible allergy. Although the incidence of “alleged” local anesthetic allergy is high, true, documented, and reproducible allergy is an extremely rare occurrence with amide local anesthetics. Management of alleged and documented allergy to local anesthetics is discussed in [Chapter 18](#).

In cases of a relative contraindication, it is preferable to avoid administration of the drug in question as the risk of an adverse reaction occurring is increased. An alternative drug that is not contraindicated is recommended. However, if an acceptable alternative is not available, the drug in question may be used, but judiciously, with the minimum dose that will provide adequate pain control administered following patient informed consent, weighing the risks versus the

• BOX 4.4 Factors in Selection of a Local Anesthetic for a Patient

1. Length of time pain control is necessary
2. Potential need for posttreatment pain control
3. Possibility of self-mutilation in the postoperative period
4. Requirement for hemostasis
5. Presence of any contraindications (absolute or relative) to the local anesthetic solution selected for administration

TABLE 4.18 Proprietary Names of Injectable Local Anesthetics in the United States and Canada

	United States	Canada
Articaine hydrochloride	Articadent, Orabloc, Septocaine, Zorcaine	Astracaine, Orabloc, Septanest, Ubesatesin, Ultracaine, Zorcaine
Bupivacaine hydrochloride	Marcaine, Vivacaine	Marcaine, Vivacaine
Lidocaine hydrochloride	Lignospan, Octocaine, Xyllocaine	Lignospan
Mepivacaine hydrochloride	Carbocaine, Isocaine, Polocaine, Scandonest	Polocaine, Scandonest
Prilocaine hydrochloride	Citanest	Citanest

benefits associated with use of that drug. One example of a relative contraindication is the presence of atypical plasma (pseudo)cholinesterase, which decreases the rate of biotransformation of ester local anesthetics. Amides may be used without increased risk in these patients. Contraindications (both absolute and relative) are reviewed in [Chapter 10](#).

[Box 4.4](#) summarizes the criteria used in selection of a local anesthetic for administration to a given patient at a given dental appointment.

[Table 4.18](#) lists the proprietary names of injectable local anesthetics available in the United States (as of February 2019).

The local anesthetic armamentarium for a dentist or dental hygienist should therefore include drugs of differing durations of action, such as:

1. short-duration pulpal anesthetic (~30 minutes)
2. intermediate-duration pulpal anesthetic (~60 minutes)
3. long-duration pulpal anesthetic (≥90 minutes)
4. topical anesthetic for tissue preparation before injection of local anesthetic

A minimum of two drug categories is recommended for most offices. Amides are preferred to esters in almost all situations.

Local anesthetics are the safest (when used properly) and most effective drugs for the prevention and management of pain. Most procedures performed in dental offices all over the world would not be possible, or would be excruciatingly painful, without the use of these remarkable drugs.

References

1. Malamed SF. *Handbook of Local Anesthesia*. 6th ed. St Louis: Mosby; 2013.
2. Meechan JG. Infiltration anesthesia in the mandible. *Dent Clin North Am*. 2010;54:621–629.
3. Kanaa JM, Whitworth JM, Corbett IP, Meechan JG. Articaine buccal infiltration enhances the effectiveness of lidocaine inferior alveolar nerve block. *Int Endodont J*. 2009;42:233–246.
4. Robertson D, Nusstein J, Reader A, Beck M, McCartney M. The anesthetic efficacy of articaine in buccal infiltration of mandibular posterior teeth. *J Am Dent Assoc*. 2007;138:1104–1112.
5. Iwatsubo T, Hirota N, Ooie T, et al. Prediction of in vivo drug metabolism in the human liver from in vitro metabolism data. *Pharmacol Ther*. 1997;73:147–171.
6. Thompson P, Melmon K, Richardson J, et al. Lidocaine pharmacokinetics in advanced heart failure, liver disease, and renal failure in humans. *Ann Intern Med*. 1973;78:499.
7. de Jong RH. Central nervous system effects. In: *Local Anesthetics*. St Louis: Mosby; 1994:273–274.
8. Moore DC, Bridenbaugh LD, Bridenbaugh PO, et al. Bupivacaine. A review of 2,077 cases. *JAMA*. 1970;214:713–718.
9. Haase A, Reader A, Nusstein J, Beck M, Drum M. Comparing anesthetic efficacy of articaine versus lidocaine as a supplemental buccal infiltration of the mandibular first molar after an inferior alveolar nerve block. *J Am Dent Assoc*. 2008;139:1228–1235.
10. Malamed SF. *Sedation: A Guide to Patient Management*. 6th ed. St Louis: Mosby; 2017.
11. Wilson AW, Deacock S, Downie IP, et al. Allergy to local anesthetic: the importance of thorough investigation. *Br Dent J*. 2000;188:320–322.
12. Lukawska J, Caballero MR, Tsabouri S, Dugue P. Hypersensitivity to local anaesthetics—6 facts and 7 myths. *Curr Allergy Clin Immunol*. 2009;22(3):117–120.
13. Rang HP, Dale MM, Ritter JM. Local anaesthetics and other drugs that affect excitable membranes. In: Rang HP, Dale MM, Ritter JM, eds. *Pharmacology*. Edinburgh: Churchill Livingstone; 1995:665–677.
14. Covino BG. Clinical pharmacology of local anesthetic agents. In: Cousins MJ, Bridenbaugh PO, eds. *Neural Blockade in Clinical Anesthesia and Management of Pain*. 2nd ed. Philadelphia: JB Lippincott; 1988.
15. Tainter ML, Wessinger GD, Lee JW. New local anesthetic solutions containing propoxycaine. *J Am Dent Assoc*. 1955;51(1):19–27.
16. Cook-Waite. *Prescribing Information: Ravocaine and Novocain With Levophed*. New York: Cook-Waite, Sterling Winthrop; 1993.
17. Moore PA, Hersh EV. Local anesthetics: pharmacology and toxicity. *Dent Clin North Am*. 2010;54:587–599.
18. Novocol Pharmaceutical of Canada: *Lidocaine 2% and Epinephrine 1:50,000 and 1:100,000 Drug Package Insert*. Cambridge: Novocol Pharmaceutical of Canada; 2013.
19. Brown RS, Paluovi S, Choksi S, et al. Evaluating a dental patient for local anesthesia allergy. *Compend Contin Educ Dent*. 2002;23:125–128, 131–132, 134, 140.
20. Jackson D, Chen AH, Bennett CR. Identifying true lidocaine allergy. *J Am Dent Assoc*. 1994;125:1362–1366.
21. Sindel LJ, deShazo RD. Accidents resulting from local anesthetics: true or false allergy? *Clin Rev Allergy*. 1991;9:379–395.
22. Ball IA. Allergic reactions to lignocaine. *Br Dent J*. 1999;186:524–526.
23. Baluga JC. Allergy to local anaesthetics in dentistry: myth or reality? *Rev Allerg Mex*. 2003;50:176–181.
24. Thyssen JP, Menne T, Elberling J, et al. Hypersensitivity to local anaesthetics—update and proposal of evaluation algorithm. *Contact Derm*. 2008;59:69–78.
25. Young ER, Mason DR, Saso MA, et al. Some clinical properties of Octocaine 200 (2 percent lidocaine with epinephrine 1:200,000). *J Can Dent Assoc*. 1989;55:987–991.
26. Buckley JA, Ciancio SG, McMullen JA. Efficacy of epinephrine concentration in local anesthesia during periodontal surgery. *J Periodontol*. 1984;55:653–657.
27. DeToledo JC. Lidocaine and seizures. *Ther Drug Monit*. 2000;22:320–322.
28. Novocol Pharmaceutical of Canada Inc. *Carbocaine (mepivacaine) drug package insert*. Cambridge, ON: Carestream Health, Inc by Novocol Pharmaceutical of Canada Inc; 2013.
29. Geddes IC. Metabolism of local anesthetic agents. *Int Anesthesiol Clin*. 1967;5:525–549.
30. Severinghaus JW, Xu F-D, Spellman MJ. Benzocaine and methemoglobin: recommended actions. *Anesthesiology*. 1991;74:385–386.
31. Schroeder TH, Dieterich HJ, Muhlbauer B. Methemoglobinemia after maxillary block with bupivacaine and additional injection of lidocaine in the operative field. *Acta Anaesthesiol Scand*. 1999;43:480–482.
32. Wilburn-Goo D, Lloyd LM. When patients become cyanotic: acquired methemoglobinemia. *J Am Dent Assoc*. 1999;130:626–631.
33. Gutenberg LL, Chen JW, Trapp L. Methemoglobin levels in generally anesthetized pediatric dental patients receiving prilocaine versus lidocaine. *Anesth Prog*. 2013;60:99–108.
34. Trapp L, Will J. Acquired methemoglobinemia revisited. *Dent Clin N Amer*. 2010;54:665–675.
35. Akerman B, Astrom A, Ross S, Telc A. Studies on the absorption, distribution and metabolism of labelled prilocaine and lidocaine in some animal species. *Acta Pharmacol Toxicol (Copenh)*. 1966;24:389–403.
36. Geddes IC. The metabolism of prilocaine (Citanest), established by means of C-14 and H3 isotopes. *Anesth Analg (Paris)*. 1967;24:213–224.
37. Akerman B, Astrom A, Ross S, et al. Studies on the absorption, distribution, and metabolism of labeled prilocaine and lidocaine in some animal species. *Acta Pharmacol Toxicol*. 1966;24:389–403.
38. Foldes FF, Molloy R, McNall PG, et al. Comparison of toxicity of intravenously given local anesthetic agents in man. *JAMA*. 1960;172:1493–1498.
39. Englesson S, Eriksson E, Ortengren B. Differences in tolerance to intravenous xylocaine and citanest. *Acta Anaesthesiol Scand Suppl*. 1965;16:141–145.
40. Deriksson E, Granberg PO. Studies on the renal excretion of citanest and xylocaine. *Acta Anaesthesiol Scand Suppl*. 1985;16:79–85.
41. Smith DW, Peterson MR, DeBerard SC. Local anesthesia: topical application, local infiltration, and field block. *Postgrad Med*. 1999;106:57–60, 64–66.
42. Akinturk S, Eroglu A. A clinical comparison of topical piroxicam and EMLA cream for pain relief and inflammation in laser hair removal. *Lasers Med Sci*. 2009;24:535–538.
43. Friskopp J, Huledal G. Plasma levels of lidocaine and prilocaine after application of Oraqix, a new intrapocket anesthetic, in patients with advanced periodontitis. *J Clin Periodontol*. 2001;28:425–429.
44. Yoon RK, Chusid S. Topical anesthesia for rubber dam placement in sealant placement: comparison of lidocaine/prilocaine gel and benzocaine. *Pediatr Dent*. 2009;31:377–381.
45. Kunimatsu T, Yamashita A, Hojo S, Toyoda M, Yoshida K. Usefulness of noninjectable anesthetic gel for intraperiodontal gingival retraction. *Int J Prosthodont*. 2008;21:129–130.

46. Kwong TS, Kusnoto B, Viana G, Evans CA, Watanabe K. The effectiveness of Oraquix versus TAC(a) for placement of orthodontic temporary anchorage devices. *Angle Orthod.* 2011;81:756–759.
47. Novocol Pharmaceutical of Canada Inc. *Citanest (Prilocaine) Drug Package Insert*. York, PA: Novocol Pharmaceutical of Canada Inc for Dentsply Pharmaceutical; 2012.
48. Doko Y, Iranami H, Fujii K, Yamazaki A, Shimogai M, Hatano Y. Severe methemoglobinemia after dental anesthesia: a warning about propitocaine-induced methemoglobinemia in neonates. *J Anesth.* 2010;24:935–937.
49. Haas DA, Lennon D. A 21 year retrospective study of reports of paresthesia following local anesthetic administration. *J Can Dent Assoc.* 1995;61:319–320, 323–326, 329–330.
50. Garisto GA, Gaffen AS, Lawrence HP, et al. Occurrence of paresthesia after dental local anesthetic administration in the United States. *J Am Dent Assoc.* 2010;141:836–844.
51. Piccinni C, Gissi DB, Gabusi A, Montebugnoli L, Poluzzi E. Paraesthesia after local anaesthetics: an analysis of reports to the FDA Adverse Event Reporting System. *Basic Clin Pharmacol Toxicol.* 2015;117:52–56.
52. Pogrel MA. Permanent nerve damage from inferior alveolar nerve blocks—an update to include articaine. *J Calif Dent Assoc.* 2007;35:271–273.
53. van Oss GE, Vree TB, Baars AM, et al. Pharmacokinetics, metabolism, and renal excretion of articaine and its metabolite articaicinic acid in patients after epidural administration. *Eur J Anaesthesiol.* 1989;6:19–56.
54. van Oss GE, Vree TB, Baars AM, et al. Clinical effects and pharmacokinetics of articaicinic acid in one volunteer after intravenous administration. *Pharm Weekbl Sci.* 1988;10:284–286.
55. Septodont. *Septocaine Drug Package Insert*. Louisville: Septodont Inc; 2013.
56. ClinicalKey. Articaine drug monograph. Available at: <https://www.clinicalkey.com>. Accessed January 10, 2018.
57. Vree TB, Baars AM, van Oss GE, et al. High performance liquid chromatography and preliminary pharmacokinetics of articaine and its 2-carboxy metabolite in human serum and urine. *J Chromatogr.* 1988;424:240–444.
58. Malamed SF, Gagnon S, Leblanc D. Safety of articaine: a new amide local anesthetic. *J Am Dent Assoc.* 2001;132:177–185.
59. Malamed SF, Gagnon S, Leblanc D. Articaine hydrochloride in pediatric dentistry: safety and efficacy of a new amide-type local anesthetic. *Pediatr Dent.* 2000;22:307–311.
60. Malamed SF, Gagnon S, Leblanc D. Efficacy of articaine: a new amide local anesthetic. *J Am Dent Assoc.* 2000;131:535–642.
61. Donaldson D, James-Perdok L, Craig BJ, et al. A comparison of Ultracaine DS (articaine HCl) and Citanest Forte (prilocaine HCl) in maxillary infiltration and mandibular nerve block. *J Can Dent Assoc.* 1987;53:38–42.
62. Knoll-Kohler E, Rupprecht S. Articaine for local anaesthesia in dentistry: a lidocaine controlled double blind cross-over study. *Eur J Pain.* 1992;13:59–63.
63. Malamed SF. Local anesthetics: dentistry's most important drugs. American Dental Association Annual Scientific Convention. Honolulu, HI. October 20, 2018.
64. Schulze-Husmann M. *Experimental Evaluation of the New Local Anesthetic Ultracaine in Dental Practice, Doctoral Dissertation*. Bonn: University of Bonn; 1974.
65. Clinical Research Associates, *Clinicians Guide to Dental Products and Techniques*. Septocaine: CRA Newsletter; 2001.
66. Kanaa MD, Whitworth JM, Corbett IP, et al. Articaine buccal infiltration enhances the effectiveness of lidocaine inferior alveolar nerve block. *Int Endod J.* 2009;42:238–246.
67. Meechan JG. Infiltration anesthesia in the mandible. *Dent Clin North Am.* 2010;54:621–629.
68. Yonchak T, Reader A, Beck M, et al. Anesthetic efficacy of infiltrations in mandibular anterior teeth. *Anesth Prog.* 2001;48:55–60.
69. Meechan JG, Ledvinka JI. Pulpal anaesthesia for mandibular central incisor teeth: a comparison of infiltration and intraligamentary injections. *Int Endod J.* 2002;35:629–634.
70. Kanaa MD, Whitworth JM, Corbett IP, et al. Articaine and lidocaine mandibular buccal infiltration anesthesia: a prospective randomized double-blind cross-over study. *J Endod.* 2006;32:296–298.
71. Robertson D, Nusstein J, Reader A, et al. The anesthetic efficacy of articaine in buccal infiltration of mandibular posterior teeth. *J Am Dent Assoc.* 2007;138:1104–1112.
72. Haase A, Reader A, Nusstein J, et al. Comparing anesthetic efficacy of articaine versus lidocaine as a supplemental buccal infiltration of the mandibular first molar after an inferior alveolar nerve block. *J Am Dent Assoc.* 2008;139:1228–1235.
73. Jakobs W. Status of dental anesthesia in Germany. *Anesth Prog.* 1989;36:210–212.
74. GfK HealthCare. *Deutscher Dentalmarkt Jahresbericht (DDM) 2010*, Nuremberg, GfK HealthCare.
75. Septodont Inc. *Vivacaine (Bupivacaine HCl) Drug Package Insert*. Louisville: Septodont Inc; 2013.
76. ClinicalKey. Bupivacaine drug monograph. Available at: <https://www.clinicalkey.com>. Accessed January 14, 2018.
77. Novocol Pharmaceutical of Canada: *Vivacaine (Bupivacaine HCl) Drug Package Insert*. Cambridge: Novocol Pharmaceutical of Canada Inc; 2012.
78. Moore PA. Bupivacaine: a long-lasting local anesthetic for dentistry. *Oral Surg.* 1984;58:369.
79. Acute Pain Management Guideline Panel. *Acute Pain Management: Operative or Medical Procedures and Trauma. Clinical Practice Guideline. AHCPR publication number 92-0032*. Rockville: Agency for Health Care Policy and Research, Public Health Service, US Department of Health and Human Services; 1992.
80. Oxford league table of analgesics in acute pain. Available at: <http://www.medicines.ox.ac.uk/bandolier/booth/painpag/acutrev/analgesics/lftab.html>. Accessed January 21, 2019.
81. Hargreaves KM, Keiser K. Development of new pain management strategies. *J Dent Educ.* 2002;66:113–121.
82. Adriani J, Campbell D. Fatalities following topical application of local anesthetics to mucous membranes. *JAMA.* 1956;162:1527.
83. Jeske AH, Blanton PL. Misconceptions involving dental local anesthesia. Part 2. Pharmacology. *Tex Dent J.* 2002;119:310–314.
84. Rosivack RG, Koenigsberg SR, Maxwell KC. An analysis of the effectiveness of two topical anesthetics. *Anesth Prog.* 1990;37:290–292.
85. Patterson RP, Anderson J. Allergic reactions to drugs and biologic agents. *JAMA.* 1982;248:2637–2645.
86. Alston TA. Antagonism of sulfonamides by benzocaine and chloroprocaine. *Anesthesiology.* 1992;76:375–476.
87. ClinicalKey. Cocaine drug monograph. Available at: www.rcoa.ac.uk/faculty-of-pain-medicine/opioids-aware/oxfor-league-table. Accessed January 22, 2018.
88. Taddio A. Pain management for neonatal circumcision. *Paediatr Drugs.* 2001;3:101–111.
89. Vanscheidt W, Sadjadi Z, Lillieborg S. EMLA anaesthetic cream for sharp leg ulcer debridement: a review of the clinical evidence for analgesic efficacy and tolerability. *Eur J Dermatol.* 2001;11:20–96.
90. Wright VC. Vulvar biopsy: techniques for reducing patient discomfort. *Adv Nurse Pract.* 2001;9:17–60.
91. ClinicalKey. EMLA. Available at: <https://www.clinicalkey.com>. Accessed January 22, 2018.
92. Aspen Pharmacare Canada Inc. Oak Pharmaceuticals. *EMLA (Lidocaine, Prilocaine) Drug Package Insert*. Aspen Pharmacare Canada Inc. Toronto, Ontario; 2017.
93. Bernardi M, Secco F, Benech A. Anesthetic efficacy of a eutectic mixture of lidocaine and prilocaine (EMLA) on the oral mucosa: prospective double-blind study with a placebo. *Minerva Stomatol.* 1999;48:9–43.

94. Munshi AK, Hegde AM, Latha R. Use of EMLA: is it an injection free alternative? *J Clin Pediatr Dent*. 2001;25:215–219.
95. Franz-Monter M, Ranali J, Ramacciato JC, et al. Ulceration of gingival mucosa after topical application of EMLA: report of four cases. *Br Dent J*. 2008;204:133–134.
96. Nayak R, Sudha P. Evaluation of three topical anaesthetic agents against pain: a clinical study. *Indian J Dent Res*. 2006;17:155–160.
97. Dentsply Pharmaceutical. Oraqix (lidocaine and prilocaine periodontal gel) 2.5% / 2.5%. Drug package insert. *Manufactured by Racipharm Karlskoga AB, Karlskoga*. York, PA: Sweden for DENTSPLY Pharmaceutical; 2010.
98. Mayor-Subirana G, Yague-Garcia J, Valmaseda-Castellon E, Arnabat-Dominguez J, Berini-Aytes L, Gay-Escoda C. Anesthetic efficacy of oraqix versus hurracaine and placebo for pain control during non-surgical periodontal treatment. *Med Oral Patol Oral Cir Bucal*. 2014;19:e192–e201.
99. Magnusson I, Jeffcoat MK, Donaldson D, Otterbom IL, Henriksson J. Quantification and analysis of pain in nonsurgical scaling and/or root planning. *J Am Dent Assoc*. 2004;135:1747–1754.
100. Donaldson D, Gelskey SC, Landry RG, Matthews DC, Sandhu HS. A placebo-controlled multi-centered evaluation of an anesthetic gel (Oraqix) for periodontal therapy. *J Clin Periodontol*. 2003;30:171–175.
101. Kunitatsu T, Yamashita A, Hojo S, Toyoda M, Yoshida K. Usefulness of noninjectable anesthetic gel for intraperiodontal gingival retraction. *Int J Prosthodont*. 2008;21:129–130.
102. Al-Melh MA, Andersson L. Reducing pain from palatal needle stick by topical anesthetics: a comparative study between two lidocaine/prilocaine substances. *J Clin Dent*. 2006;19:43–47.
103. Septodont. *Lidocaine Ointment USP 5% Drug Package Insert*. Louisville: Septodont Inc; 2016.
104. Ciancio SG, Marberger AD, Ayoub F, et al. Comparison of 3 intranasal mists for anesthetizing maxillary teeth in adults: a randomized, double-masked, multicenter phase 3 clinical trial. *J Am Dent Assoc*. 2016;147:339–347.
105. Hersh EV, Pinto A, Saraghi M, et al. Double-masked, randomized, placebo-controlled study to evaluate efficacy and tolerability of intranasal K-305 (3% tetracaine plus 0.05% oxymetazoline) in anesthetizing maxillary teeth. *J Am Dent Assoc*. 2016;147:278–287.
106. United States Pharmacopeial Convention: Good compounding practices. In: *The United States Pharmacopeia: USP 28: The National Formulary: NF 23*; by authority of the United States Pharmacopeial Convention Inc, meeting at Washington, April 12–16, 2000, Rockville, 2004, United States Pharmacopeial Convention.
107. US Food and Drug Administration. FDA warns 5 firms to stop compounding topical anesthetic creams. December 6. Available at: <https://www.docguide.com/fda-warns-five-firms-stop-compounding-topical-anesthetic-creams>; 2006. Accessed January 22, 2018.
108. US Food and Drug Administration. FDA public health advisory: life-threatening side effects with the use of skin products containing numbing ingredients for cosmetic procedures. Available at: www.fda.gov/cder/drug/advisory/topical_anesthetics.htm; 2009. Accessed January 22, 2018.
109. Young D. Pharmacies wanted to stop selling compounded topical anesthetics. December 11, 2006. amer S.Health-System Pharmacy; Available at: www.ashp.org/news/2006/12/11/pharmacies_warned_to_stop_selling_compounded_topical_anesthetics. Accessed January 22, 2019.
110. Kravitz ND. The use of compound topical anesthetics: a review. *J Am Dent Assoc*. 2007;138:1333–1339.
111. Graham JW. Profound needle-free anesthesia in orthodontics. *J Clin Orthod*. 2006;40:723–724.
112. Jeffcoat MK. Eye of newt, toe of frog: drug compounding: proceed with caution. *J Am Dent Assoc*. 2004;135:546–548.
113. Hersh EV, Moore PA, Papas AS, et al. Reversal of soft-tissue local anesthesia with phentolamine mesylate in adolescents and adults. *J Am Dent Assoc*. 2008;139:1080–1093.
114. Yagiela JA. What's new with phentolamine mesylate: a reversal agent for local anaesthesia? *SAAD Dig*. 2011;27:3–7.
115. Tavares M, Goodson JM, Studen-Pavlovich D, et al. Reversal of soft-tissue local anesthesia with phentolamine mesylate in pediatric patients. *J Am Dent Assoc*. 2008;139:1095–1104.

The Armamentarium

5

PDF Compressor Free Version

The Syringe

The syringe is one of three essential components of the local anesthetic armamentarium (others include the needle and the cartridge). It is the vehicle whereby the content of the anesthetic cartridge is delivered through the needle to the patient.

Types of Syringes

Eight types of syringes for local anesthetic administration are available for use in dentistry today. They represent a considerable improvement over the local anesthetic syringes formerly used. These various types of syringes are listed in [Box 5.1](#).

Nonaspirating syringes are not discussed except to state that their use unacceptably increases the risk of inadvertent intravascular drug administration. The use of aspirating dental syringes (capable of the aspiration of blood) represents the standard of care.

The American Dental Association criteria for acceptance of local anesthetic syringes include¹:

1. They must be durable and able to withstand repeated sterilization without damage. (If the unit is disposable, it should be packaged in a sterile container.)
2. They should be capable of accepting a wide variety of cartridges and needles of different manufacture, and should permit repeated use.
3. They should be inexpensive, self-contained, lightweight, and simple to use with one hand.
4. They should provide effective aspiration and be constructed so that blood may be easily observed in the cartridge.

Nondisposable Syringes

Breech-Loading, Metallic, Cartridge-Type, Aspirating

The breech-loading, metallic, cartridge-type syringe ([Fig. 5.1](#)) is the most commonly used in dentistry. The term *breech loading* implies that the cartridge is inserted into the syringe from the side of the barrel of the syringe. The needle is attached to the barrel of the syringe at the needle adaptor. The needle then passes into the barrel, where it penetrates the diaphragm of the local anesthetic cartridge. The needle adaptor (screw hub or convertible tip) is removable and is occasionally inadvertently discarded along with the disposable needle.

The aspirating syringe has a device such as a sharp, hook-shaped end (often called the *harpoon*) attached to the piston that is used to penetrate the thick silicone rubber stopper (also called the *bung*) at the opposite end of the cartridge (from the needle). Provided the needle is of adequate gauge, when negative pressure is exerted on the thumb ring by the administrator, blood will enter the needle and be visible in the cartridge if the needle tip rests within the lumen of a blood vessel. Positive pressure applied to the thumb ring forces local anesthetic into the needle lumen and the tissues wherever the needle tip lies. The thumb ring and finger grips give the administrator added control over the syringe. Many syringe manufacturers provide syringes with both “regular” and “small” thumb rings. Wiener et al.² compared “regular” and “petite” syringes used by dental and dental hygiene students and reported that 62.2% preferred the petite syringe as it gave them better control during injections and aspiration ([Fig. 5.2](#)). Most metallic, breech-loading, aspirating syringes are constructed of chrome-plated brass and stainless steel.

Advantages and disadvantages of the metallic, breech-loading, aspirating syringe are listed in [Table 5.1](#).

Breech-Loading, Plastic, Cartridge-Type, Aspirating

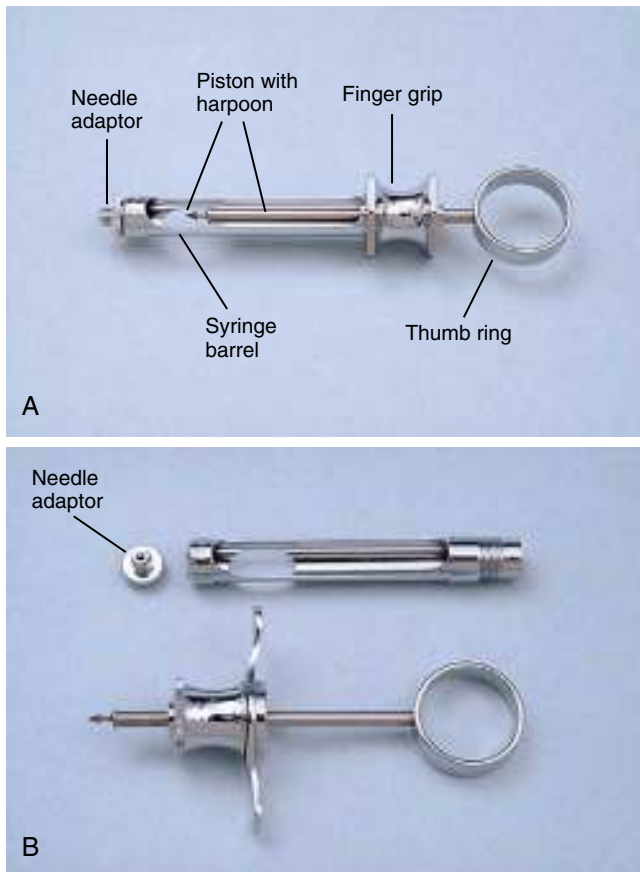
A plastic, reusable, dental aspirating syringe is available that is both autoclavable and chemically sterilizable. With proper care and handling, this syringe may be used for multiple anesthetic administrations before it is discarded. Advantages and disadvantages of the plastic, reusable, aspirating syringe are listed in [Table 5.2](#).

Breech-Loading, Metallic, Cartridge-Type, Self-Aspirating

The potential hazards of intravascular administration of local anesthetics are great and are discussed more fully in [Chapter 18](#). The incidence of positive aspiration may be as high as 10% to 15% with some injection techniques (e.g., inferior alveolar nerve block).³ It is accepted by the dental profession that an aspiration test before administration of a local anesthetic drug is of great importance. Unfortunately, it is abundantly clear that in actual clinical practice, too little attention is paid to this procedure ([Table 5.3](#)).

• BOX 5.1 Syringe Types Available in Dentistry

1. Nondisposable **PDF Compressor Free Version**
 - a. Breech-loading, metallic, cartridge-type, aspirating
 - b. Breech-loading, plastic, cartridge-type, aspirating
 - c. Breech-loading, metallic, cartridge-type, self-aspirating
 - d. Pressure syringe for periodontal ligament injection
 - e. Jet injector (“needle-less” syringe)
2. Disposable syringes
3. “Safety” syringes
4. Computer-controlled local anesthetic delivery systems



• **Fig. 5.1** (A) Breech-loading, metallic, cartridge-type syringe; assembled. (B) Disassembled local anesthetic syringe.

With commonly used breech-loading, metallic or plastic, cartridge-type syringes, an aspiration test must be conducted purposefully by the administrator before or during drug deposition. The key word here is *purposefully*. However, as demonstrated in Table 5.3, many dentists do not purposefully perform an aspiration test before injection of the anesthetic drug.⁴

To increase the ease of aspiration, self-aspirating syringes have been developed (Fig. 5.3). These syringes use the elasticity of the rubber diaphragm in the anesthetic cartridge to obtain the necessary negative pressure for aspiration. The diaphragm rests on a metal projection inside the syringe that directs the needle into the cartridge



• **Fig. 5.2** Harpoon-type aspirating syringes with small and large thumb rings.

TABLE 5.1 Advantages and Disadvantages of the Metallic, Breech-Loading, Aspirating Syringe

Advantages	Disadvantages
Visible cartridge	Weight (heavier than plastic syringe)
Aspiration with one hand	Syringe may be too big for small operators
Autoclavable	Possibility of infection with improper care
Rust resistant	
Long lasting with proper maintenance	

TABLE 5.2 Advantages and Disadvantages of the Plastic, Reusable, Aspirating Syringe

Advantages	Disadvantages
Plastic eliminates metallic, clinical look	Size (may be too big for small operators)
Lightweight: provides better “feel” during injection	Possibility of infection with improper care
Cartridge is visible	Deterioration of plastic with repeated autoclaving
Aspiration with one hand	
Rust resistant	
Long lasting with proper maintenance	
Lower cost	

(Fig. 5.4). Pressure acting indirectly on the cartridge through the plunger shaft distorts (stretches) the rubber diaphragm, producing positive pressure within the anesthetic cartridge. When that pressure is released—by simply releasing thumb pressure on the plunger—sufficient negative pressure develops within the cartridge to permit aspiration. The use of a self-aspirating dental syringe permits easy performance of multiple aspirations throughout the period of local anesthetic deposition.

The self-aspirating syringe, popular in Canada for many years, was introduced into the United States in 1981. After an initial period of enthusiasm in the United States, the popularity of this syringe decreased. Some dentists believed that the self-aspirating syringe did not provide the same

TABLE 5.3

Percentages of Dentists Who Perform Aspiration Test Before Injection

PDF Compressor Free Version
Inferior Alveolar Nerve Block

Frequency	Inferior Alveolar Nerve Block		Maxillary Infiltration	
	Percentage	Cumulative Percentage	Percentage	Cumulative Percentage
Always	63.2		40.2	
Sometimes	14.7	77.9	24.1	64.3
Rarely	9.2	87.1	18.4	82.7
Never	12.9		17.3	



• **Fig. 5.3** Self-aspirating syringe. (Courtesy of Septodont, Inc, Lancaster, PA)



• **Fig. 5.4** A metal projection within the barrel depresses the diaphragm of the local anesthetic cartridge.

reliability of aspiration that was possible with the harpoon-aspirating syringe. It has been demonstrated, however, that this syringe does in fact aspirate blood as reliably as the harpoon-aspirating syringe.⁵⁻⁷ However, Delgado-Molina et al.,⁸ in comparing two self-aspirating syringes with a non-self-aspirating system during inferior alveolar nerve blocks, found the non-self-aspirating system to be more reliable (5.69% positive aspiration) than the two self-aspirating syringes (2.03% and 1.21%).

TABLE 5.4

Advantages and Disadvantages of the Metallic, Self-Aspirating Syringe

Advantages	Disadvantages
Cartridge visible	Weight
Aspiration is easier with small hands	Feeling of “insecurity” for doctors accustomed to harpoon-type syringe
Autoclavable	Finger must be moved from thumb ring to thumb disk to aspirate blood
Rust resistant	Possibility of infection with improper care
Long lasting with proper maintenance	
Piston is scored (indicates volume of local anesthetic administered)	

The major factor influencing ability to aspirate blood is not the syringe but the gauge of the needle being used.⁷ In addition, most doctors using the harpoon-aspirating syringe tend to overaspirate, that is, they retract the thumb ring back too far and with excessive force (and, on occasion, disengage the harpoon from the stopper). These doctors feel more insecure with the self-aspirating syringe. Proper technique of aspiration is discussed in [Chapter 11](#). Advantages and disadvantages of the metallic, self-aspirating syringe are listed in [Table 5.4](#).

Pressure Syringes

(Re)introduced in the late 1970s, pressure syringes brought about a renewed interest in the periodontal ligament (PDL) injection (also known as the *intra-ligamentary injection*). Discussed in [Chapter 15](#), the PDL injection, although usable for any tooth, helped make it possible to achieve more reliable pulpal anesthesia of one isolated mandibular tooth where, in the past, nerve block anesthesia (e.g., inferior alveolar nerve block, Gow-Gates mandibular nerve block), with its attendant prolonged soft tissue (e.g., lingual, lip, chin) anesthesia, was necessary.

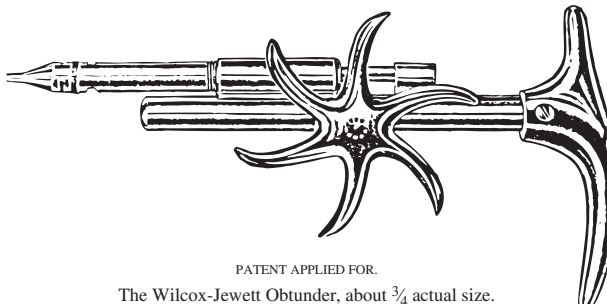
The original pressure devices, Peripress (Universal Dental Implements, Edison, New Jersey, United States) and Ligmaject (IMA Associates, Bloomington, Indiana, United States) ([Fig. 5.5](#)), were modeled after a device that was available in dentistry in 1905—the Wilcox-Jewett obtunder ([Fig. 5.6](#)). These first-generation devices, using a pistol grip, are somewhat larger than the newer, pen-grip devices ([Fig. 5.7](#)).



• **Fig. 5.5** Original design of pressure syringe for periodontal ligament injection, or intraligamentary injection.

THE WILCOX-JEWETT OBTUNDER.

LEE S. SMITH & SON, PITTSBURG.



PATENT APPLIED FOR.
The Wilcox-Jewett Obtunder, about $\frac{3}{4}$ actual size.

• **Fig. 5.6** Pressure syringe (1905) designed for a periodontal injection.



• **Fig. 5.7** Second-generation syringe for periodontal ligament injection.

Although “special” syringes such as these are not necessary for a successful PDL injection, several advantages are associated with their use, not the least of which is the mechanical advantage they provide the administrator, making the local anesthetic easier to administer. This same mechanical advantage, however, makes the injection somewhat “too easy” to administer, leading to “too rapid” injection of the anesthetic solution and patient discomfort both during the injection and later, when the anesthetic has worn off. However, when used slowly, as recommended by manufacturers, pressure syringes are of some benefit in administration of this valuable technique of anesthesia.

Pressure syringes offer advantages over the conventional syringe when used for PDL injections because their trigger delivers a measured dose of local anesthetic and enables

TABLE 5.5 Advantages and Disadvantages of the Pressure Syringe

Advantages	Disadvantages
Measured dose	Easy to inject anesthetic too rapidly
Overcomes tissue resistance	Threatening (original devices)
Nonthreatening (new devices)	
Cartridges protected	

a relatively physically weak administrator to overcome the significant tissue resistance encountered when the PDL injection is administered properly. This mechanical advantage may also prove to be detrimental if the administrator deposits the anesthetic solution too quickly (<20 seconds per 0.2-mL dose). All pressure syringes completely encase the glass dental cartridge with plastic or metal, thereby protecting the patient in the unlikely event that the glass cartridge cracks or shatters during injection. The original pressure syringes looked somewhat threatening, having the appearance of a gun (see Fig. 5.5). Newer devices are smaller and less intimidating.

Table 5.5 lists the advantages and disadvantages of the pressure syringe.

Jet Injector

In 1947 Figge and Scherer⁹ introduced a new approach to parenteral injection—the jet or needle-less injection. This represented the first fundamental change in the basic principles of injection since 1853, when Alexander Wood introduced the hypodermic syringe. The first report of the use of jet injections in dentistry was published in 1958 by Margentis et al.¹⁰ Jet injection is based on the principle that liquids forced through very small openings, called *jets*, at very high pressure can penetrate intact skin or mucous membrane (visualize water flowing through a garden hose whose opening is being crimped). The most frequently used jet injectors in dentistry are the MadaJet (Fig. 5.8) and the Comfort-in needle-free injection system. Previously the Syrijet Mark II jet injector was a favorite, but it is no longer manufactured. Neither MadaJet nor Comfort-in supports the traditional dental local anesthetic cartridge.

The primary purpose of the jet injector is to obtain topical anesthesia before insertion of a needle. In addition, it may be used to obtain mucosal anesthesia of the palate. Regional nerve blocks or supraperiosteal injections are still necessary for complete anesthesia. The jet injector is not an adequate substitute for the more traditional needle and syringe in obtaining pulpal or regional block anesthesia. Additionally, many patients dislike the feeling that accompanies the use of the jet injector, as well as the possible postinjection soreness of soft tissue that may develop even with proper use of the device. Topical anesthetics, applied properly, serve the same purpose as jet injectors at a fraction of the cost (MadaJet XL Dental, US\$550 [March, 2019], Mada Medical Products Incorporated, Carlstadt, New Jersey, United States, <https://www.manta.com/c/mmsr4bv/mada-medical-products-inc>;



• Fig. 5.8 MadaJet.

TABLE 5.6 Advantages and Disadvantages of the Jet Injector

Advantages	Disadvantages
Does not require use of a needle (recommended for persons with needle phobia)	Inadequate for pulpal anesthesia or for regional block
Delivers very small volumes of local anesthetic (0.01–0.2 mL)	Some patients are disturbed by the jolt of the injection.
Used in place of topical anesthetic	Cost
	May damage periodontal tissues

Comfort-in [United States/Australia] US\$260 [March 2019], ASTS Enterprises (Aust) Pty. Ltd., Burwood, Victoria, Australia, <https://www.ast.com.au>) and with minimum risk. Advantages and disadvantages of jet injectors are listed in Table 5.6.

Disposable Syringes

Plastic disposable syringes are available in a variety of sizes with an assortment of needle gauges. Most often they are used for intramuscular or intravenous drug administration, but they may also be used for intraoral injection (Fig. 5.9).

These syringes contain a Luer-Lok screw-on needle attachment with no aspirating tip. Aspiration can be accomplished by pulling back on the plunger of the syringe before or during injection. Because there is no thumb ring, aspiration with the plastic disposable syringe requires the use of both hands. In addition, these syringes do not accept dental cartridges. The needle, attached to the syringe, must be inserted into a vial or cartridge of local anesthetic drug and an appropriate volume of solution must be withdrawn. Care must be taken to avoid contaminating the multiuse vial during this procedure. Two-milliliter and 3-mL syringes with 25- or 27-gauge needles are recommended when the system is used for intraoral local anesthetic administration.

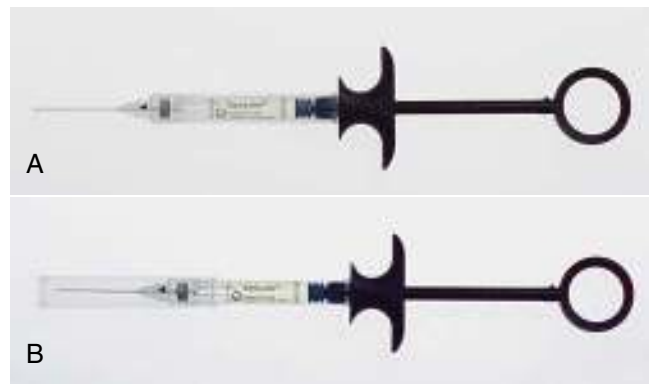The plastic, disposable, non-cartridge-containing syringe is not recommended for routine use. Its use should be considered only when a traditional syringe is not available or cannot be used. This system is also practical when diphenhydramine hydrochloride is used as a local anesthetic in cases of alleged local anesthetic allergy (see Chapter 18).



• Fig. 5.9 Plastic disposable syringe.

TABLE 5.7 Advantages and Disadvantages of the Disposable Syringe

Advantages	Disadvantages
Disposable, single use	Does not accept prefilled dental cartridges
Sterile until opened	Aspiration difficult (requires two hands)
Lightweight (may feel awkward to the first-time user; tactile sensation better)	



• Fig. 5.10 (A) Ultra Safety Plus XL aspirating syringe, ready for injection. (B) Ultra Safety Plus XL aspirating syringe with the needle sheathed to prevent needlestick injury. (Courtesy of Septodont, Inc, Lancaster, PA)

Table 5.7 lists the advantages and disadvantages of the disposable syringe.

Safety Syringes

There has been a movement toward the introduction of *safety syringes* in both medicine and dentistry. Safety syringes minimize the risk of an accidental needlestick injury occurring to a dental health provider with a contaminated needle after administration of a local anesthetic. These syringes possess a sheath that “locks” over the needle when it is removed from the patient’s tissues, minimizing the risk of accidental needlestick (Fig. 5.10).

The UltraSafety Plus XL aspirating syringe system contains a syringe body assembly and a plunger assembly (see Fig. 5.10A). Once the syringe is properly assembled and the injection administered, the syringe may be made “safe” with one hand by gentle movement of the index and middle fingers against the front collar of the guard (see Fig. 5.10B). Once “guarded,” the now contaminated needle is “safe,” so it is virtually impossible for dental health providers to be

TABLE 5.8 Advantages and Disadvantages of the Safety Syringe

Advantages	Disadvantages
Disposable, single use	Requires additional training
Sterile until opened	May feel awkward to a first-time user
Lightweight (better tactile sensation)	

injured with the needle. On completion of the injection, the entire syringe is discarded into the proper receptacle (e.g., sharps container).

Dental safety syringes are designed as single-use items, although they permit reinjection. Reloading the syringe with a second anesthetic cartridge and reinjection with the same syringe is discouraged because this obviates the important safety aspect of the device.

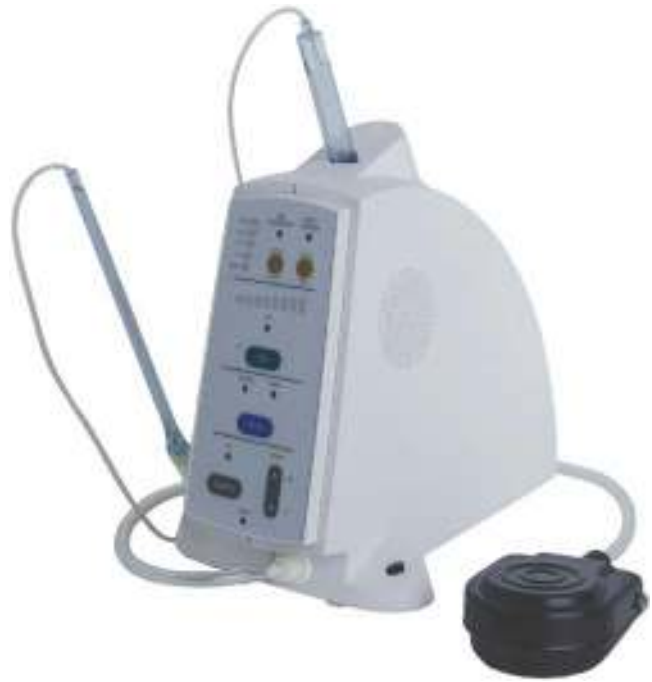In 2000 Cuny et al.¹¹ evaluated four dental safety syringe systems—Safe-Mate needle system (Septodont Inc., New Castle, Delaware, United States, <http://www.septodontusa.com>), Safety Plus syringe (Septodont Inc.), UltraSafe syringe (Septodont Inc.), and Hypo Safety syringe (Dentsply MPL Technologies, Franklin Park, Illinois, United States)—over a 1-year period at a US dental school. Their finding was that using these Food and Drug Administration–approved devices resulted in an initial *increase* in needlestick injuries. They stated that hands-on training, monitoring, and follow-up reminders appeared to be effective in reducing injuries associated with the change from traditional to safety needles. Marketing of the 1-Shot Safety Syringe ceased in October 2006.¹²

Advantages and disadvantages of the safety syringe are listed in Table 5.8.

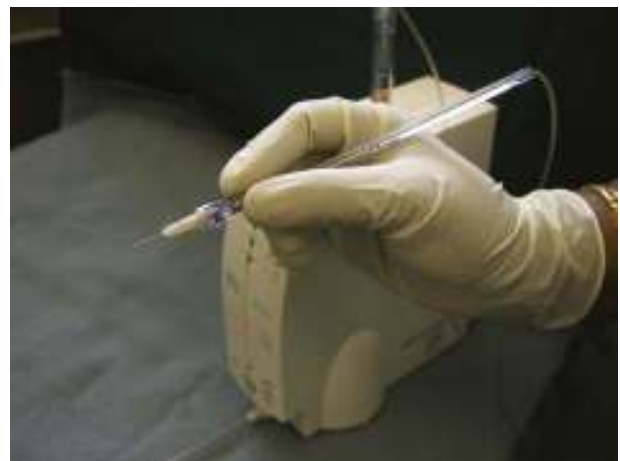
Computer-Controlled Local Anesthetic Delivery Systems

The standard dental syringe described previously is a simple mechanical instrument that dates back to 1853, when Charles Pravaz patented the first syringe.¹³ The dental syringe is a drug-delivery device requiring that the operator simultaneously attempt to control the variables of drug infusion and the movement of a penetrating needle. The operator's inability to precisely control both of these activities during an injection can compromise injection technique. In addition, a traditional syringe is held with a palm-thumb grasp, which is not designed for ideal ergonomics or needle control during the injection. For certain practitioners—those with small hands—just holding a syringe with a full cartridge of anesthetic may be difficult.

In 1997 the first computer-controlled local anesthetic delivery (C-CLAD) system was introduced into dentistry. The Wand (Milestone Scientific Inc., Livingston, New Jersey, United States) was designed to improve on the ergonomics and precision of the dental syringe (Fig. 5.11). This system enabled a dentist or hygienist to precisely manipulate needle placement with fingertip accuracy and deliver the local anesthetic with

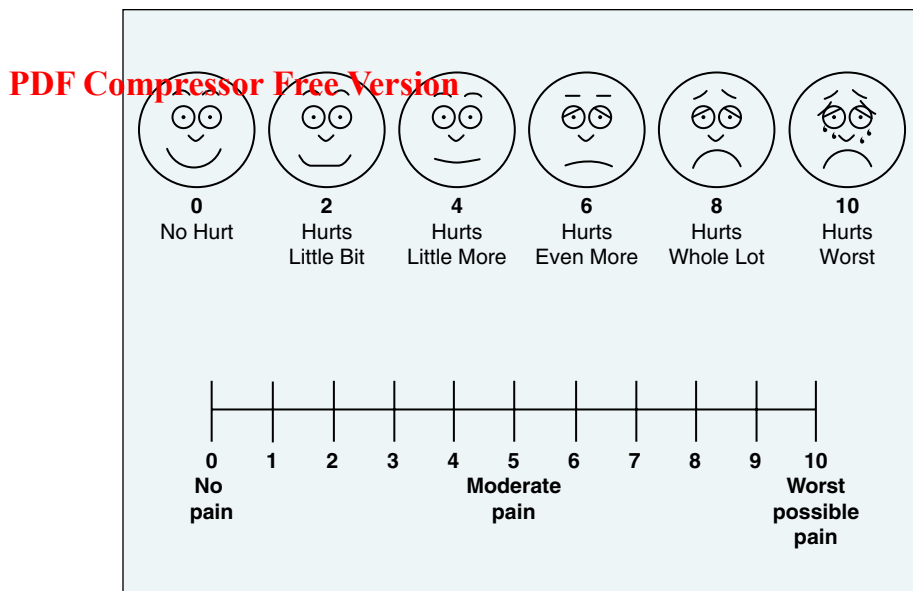


• Fig. 5.11 The STA Wand computer-controlled local anesthetic delivery system.



• Fig. 5.12 The Wand has a lightweight handpiece that provides improved tactile sensation and control.

a foot-activated control (see Fig. 5.11). A lightweight handpiece (Fig. 5.12), held in a pen-like grasp, provides increased tactile sensation and control compared with the traditional syringe. The flow rate of local anesthetic delivery is computer controlled and thus remains consistent from one injection to the next. C-CLAD systems represent a significant change in the manner in which a local anesthetic injection is administered. The operator is now able to focus attention on needle positioning and insertion, allowing the motor in the device to administer the drug at a preprogrammed rate of flow. It is likely that greater ergonomic control coupled with fixed flow rates is responsible for the improved injection experience demonstrated in many clinical studies conducted with C-CLAD devices in dentistry.¹⁴⁻¹⁸ Several clinical trials in medicine have demonstrated measurable benefits of this technology.^{19,20}



• Fig. 5.13 Visual analog scale.

Hochman et al.¹³ were the first to demonstrate a marked reduction in pain perception with injections using C-CLAD systems. Fifty blindfolded dentists participated (they received the injection) in a controlled clinical trial comparing the standard manual syringe with The Wand C-CLAD system for palatal injection. Forty-eight (96%) preferred injections with the C-CLAD system. Overall pain perception was reduced twofold to threefold when compared with the standard manual syringe.

Nicholson et al.¹⁵ conducted a randomized clinical trial using two operators administering four different types of dental injections comparing C-CLAD systems with the standard syringe. Mean injection discomfort ratings were found to be consistently lower when C-CLAD systems were used compared with the manual syringe. Two-thirds of patients preferred that future dental injections be performed with a C-CLAD system. The investigators in the study increasingly preferred to perform all injections with C-CLAD technology.

Perry and Loomer¹⁶ presented data from a single-blind crossover study comparing C-CLAD with traditional syringe delivery of local anesthetic for quadrant scaling and root planing. Twenty participants received the anterior middle superior alveolar (AMSA) nerve block injection (described in Chapter 13). Scores for AMSA computer-controlled injection revealed highly significant differences in favor of the computer-controlled device ($P < .0001$).

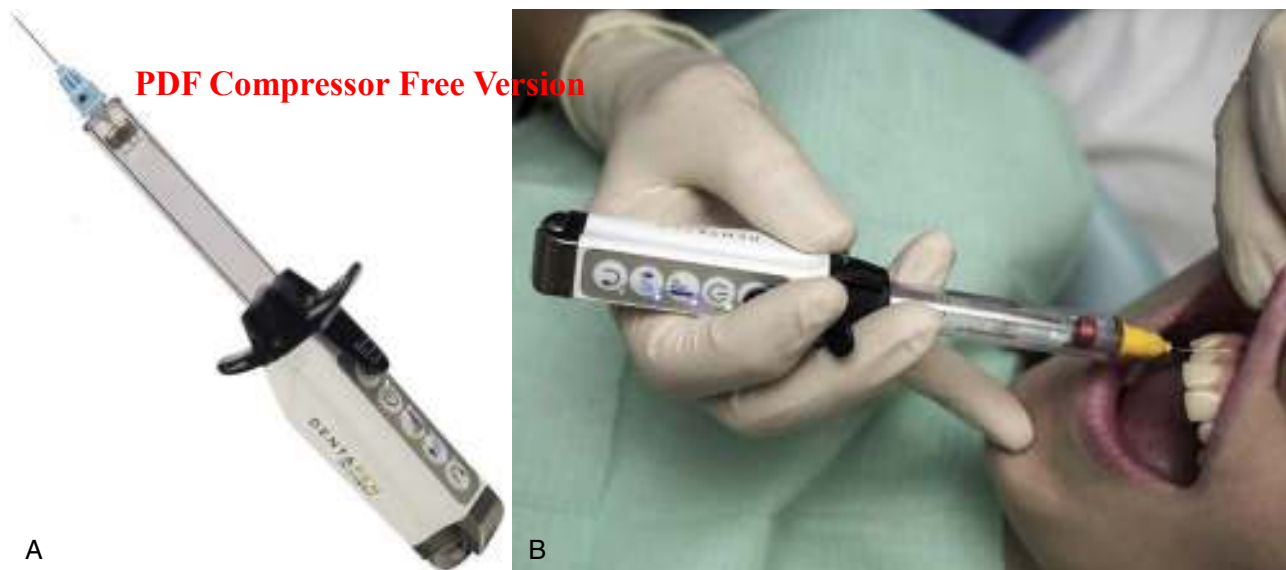Fukayama et al.¹⁷ conducted a controlled clinical trial to evaluate pain perception with a C-CLAD device. Seventeen of 20 participants reported a slight- or no-pain rating on a visual analog scale (VAS) for palatal injections administered with C-CLAD systems (Fig. 5.13). The investigators concluded that “the new system provides comfortable anesthesia for patients and can be a good alternative for conventional manual syringe injection.”

At present, there are several C-CLAD systems available in the North American market: The Wand STA Single Tooth Anesthesia System (Milestone Scientific Inc., Livingston, New Jersey, United States), Calaject (Aseptico Inc., Woodinville, Washington, United States), EZ Flow (Denterprise International Inc., Ormond Beach, Florida, United States), and DentaPen (Fig. 5.14). Another system, the Quick-Sleeper, is marketed in Europe. Similar devices, such as the Anaject, are marketed in Japan (Fig. 5.15).

The Wand STA System

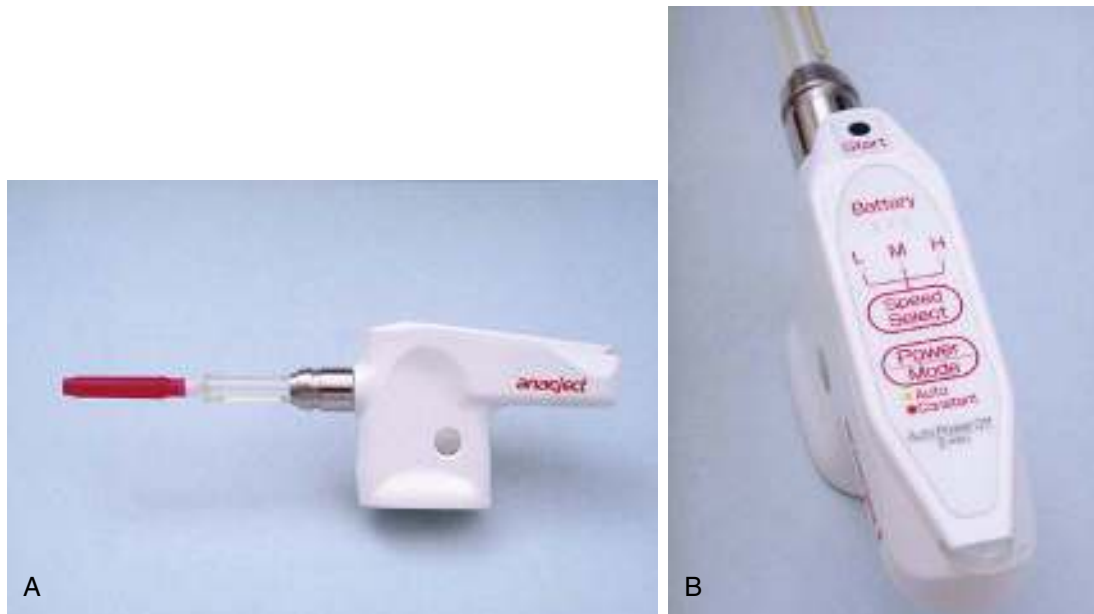
The Wand STA local anesthetic delivery system represents a significant advance in C-CLAD technology (see Fig. 5.11). Introduced in 2007, The Wand STA system is a third-generation C-CLAD instrument representing a new and meaningful innovation for subcutaneous injections performed both in dentistry and in medicine.²¹ The technological advancement is related to the development of what is called *dynamic pressure-sensing technology* (DPS technology).²² DPS technology enables the precise monitoring and control of fluid pressure at the needle tip when a subcutaneous injection is performed. Fluid exit pressure at the needle tip is used to identify a given anatomic location and/or a specific tissue type on the basis of this repeatable finding.²³ Exit-pressure information is provided to the clinician on a continuous basis in the form of spoken and/or audible sounds and visual indicators emitted from The Wand STA instrument, thus providing continuous real-time feedback while a dental injection is performed (Fig. 5.16).²⁴

The Wand STA local anesthetic delivery system can perform all traditional injections, as well as several newer dental injection techniques as previously described with the initial The Wand C-CLAD system. In addition, The Wand STA system offers a unique approach for performing PDL injection using DPS technology.²⁵ The instrument has been designed to identify the precise anatomic location for the PDL injection.²³



PDF Compressor Free Version

• **Fig. 5.14** (A) C-CLAD device, Dentapen. (Juvaplus SA, Switzerland) and (B) Dentapen uses a palm-thumb grasp to hold and operate. (Courtesy of Dentapen.)



• **Fig. 5.15** (A) C-CLAD device, Anaject and (B) Anaject with multiple speed selections. (Courtesy of Sep-todont, Inc, Lancaster, PA)

The Wand STA system audibly and visually “guides” placement of the needle tip into the anatomic entrance of the PDL space through DPS technology. Important to the success of the PDL injection is proper needle placement into the PDL space. Use of a traditional syringe provides little or no information as to correct needle-tip location, so this can be considered a “blinded” approach to PDL injection. In contrast, the DPS technology of The Wand STA system informs the clinician of the status of needle position on the basis of real-time pressure information. This transforms the PDL injection technique into a “guided” technique that can be more easily and accurately performed. Additionally, The Wand STA instrument is capable of generating precise fluid pressures in ranges that are much lower in comparison with

other injection devices. This ability to maintain lower pressures permits the absorption of greater volumes of anesthetic solution safely and effectively through the intraligamentary tissues and surrounding bone.²⁴ Allowing a greater volume of anesthetic to be safely administered results in a longer duration of anesthesia produced by The Wand STA PDL injection compared with PDL injection performed with high-pressure syringes and/or other delivery instruments.²⁶

Ferrari et al.²⁷ published data on 60 patients receiving PDL injection; they compared the STA system versus two other delivery instruments: a high-pressure mechanical syringe (Ligmaject, IMA Associates) and a conventional dental syringe. Electrical pulp testing was used at regular intervals to determine success or failure when each

PDF Compressor Free Version

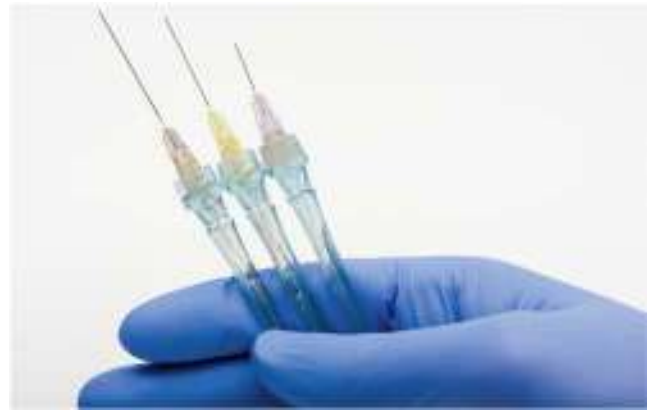

• **Fig. 5.16** Dynamic pressure sensing on the STA Single Tooth Anesthesia System computer-controlled local anesthetic delivery device provides both visual and audible feedback regarding placement of the needle tip during the periodontal ligament (PDL) injection. Horizontal color bars (arrow) indicate pressure at the tip of the needle. Red means pressure is too low. Orange and dark yellow mean increasing pressure but not yet adequate. Light yellow means correct pressure for PDL injection. At this point the STA unit will also provide an audible clue “PDL, PDL, PDL” that the needle tip is properly situated. (© 2018, Milestone Scientific, Inc., All Rights Reserved, Used by Permission.)

instrument was used. Patient subjective pain responses (VAS scores) were recorded after treatment. This study found The Wand STA system to have a success rate of 100% in achieving effective pulpal anesthesia, as well as more rapid onset of anesthesia. The PDL injection in this study was performed as a primary injection for restorative dental care in mandibular teeth. The study also found subjective pain responses of “minimal or no pain” observed in all patients receiving PDL injections with The Wand STA system. In contrast, PDL injections performed with the other two systems were found to have generally higher pain scores throughout testing. The investigators concluded that The Wand STA instrument provided a more predictable, more reliable, and more comfortable PDL injection than a high-pressure mechanical syringe or a conventional dental syringe.²⁷

A series of clinical studies have been published demonstrating the efficacy of C-CLAD devices in subjective pain and disruptive pain behavior in children undergoing dental treatment when compared with a conventional syringe.²⁸⁻³² Additionally, Baghlaf et al.³³ confirmed the earlier work of Ashkenazi et al.,³⁴ demonstrating The Wand STA system can safely and effectively perform a PDL injection on primary teeth. The Wand STA system provides a safe and effective alternative to the mandibular block anesthesia in children that minimizes the risk of self-inflicted soft tissue injury (e.g., lip biting).

The Wand STA system has two basic components: The Wand STA handpiece and The Wand STA drive unit. The



• **Fig. 5.17** The Wand STA handpieces are available with 27-gauge 0.5-½ inch, 30 gauge 1-inch, and 27-gauge 1.25-¼ inch needles.

Wand STA handpiece is a single-use (per patient visit) lightweight handpiece (weighing less than 10 g) (Fig. 5.17). It provides excellent tactile control and use of a more desirable ergonomic grasp. Clinicians have reported that a C-CLAD instrument, such as The Wand STA system, is more comfortable to use and produces fewer musculoskeletal problems over the long term.³⁵

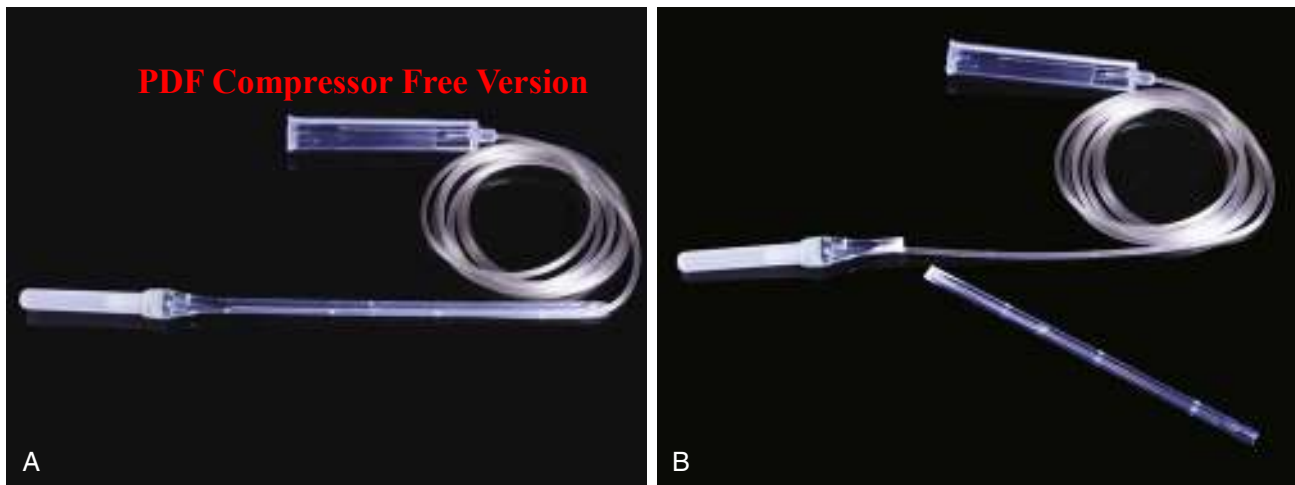
The Wand STA handpieces are available with many standard dental needle sizes: 30-gauge 0.5-inch, 27-gauge 0.5-inch, 30-gauge 1-inch, and 27-gauge 1.25-inch needle lengths. The Wand STA handpiece is a single-use sterilized handpiece (see Fig. 5.17) that is available in two forms: one in which the handpiece has a preattached needle, and one in which a needle needs to be attached at the time of treatment. When The Wand STA PDL injection is performed, it is suggested that a preattached needle handpiece be used. The Wand STA handpiece provides the general benefit of being easier and lighter to hold, allowing greater access and ease of use as compared with the conventional syringe. Additionally, The Wand STA handpiece can be modified to different lengths for greater versatility of use (Fig. 5.18).

The second component of The Wand STA system is the drive unit itself (see Fig. 5.11). The drive unit integrates two cap holders into the base of the unit, thus allowing single-handed recapping of the needle from either side of the unit. New features include automatic purging of anesthetic solution that primes the handpiece before use, automatic plunger retraction after completion of use, and a multicartridge feature that reduces anesthetic waste when more than one anesthetic cartridge is used. The Wand STA system also has a training mode feature that provides clinicians with spoken instructional guidance on its use, thereby minimizing the learning curve when the system is used for the first time.

Advantages and disadvantages of The Wand STA system are listed in Table 5.9.

Dentapen

A recent addition to the C-CLAD armamentarium is the Dentapen (Juvaplus SA, Neuchatel, Switzerland. <https://dentapen.ch>), a battery-operated, handheld device



• **Fig. 5.18** The Wand STA handpiece is lightweight (less than 10 g) (A) and can easily be shortened to aid in administration of some injections (B), such as the anterior middle superior alveolar or other palatal techniques.

TABLE 5.9 Advantages and Disadvantages of The Wand STA Single Tooth Anesthesia System

Advantages	Disadvantages
Dynamic pressure-sensing technology provides continuous real-time feedback when an injection is performed, resulting in a more predictable injection site location	Requires additional armamentarium
Allows the periodontal ligament injection to be used as a predictable primary injection	Requires additional training
Can be used for all traditional injection techniques	
Recommended device for newer injection techniques such as anterior middle superior alveolar nerve block, palatal anterior superior alveolar nerve block, and STA periodontal ligament injection	
Reduces pain-disruptive behavior in children and adults	
Reduces stress for patient	
Reduces stress for operator	

permitting three rates of injection: fast (30 seconds/mL), medium (60 seconds/mL), and slow (90 seconds/mL) (see Fig. 5.14). For PDL injections it incorporates a “ramp-up mode,” where the anesthetic flow increases gradually to provide a painless PDL injection.³⁶

C-CLAD devices allow the comfortable administration of local anesthetics in virtually all areas of the oral cavity. This is of greatest importance in the palate, where the level of patient discomfort can be significant. The nasopalatine nerve block, as well as other palatal injections (e.g., AMSA,³⁷ palatal approach anterior superior alveolar³⁸), can be administered atraumatically (VAS rating 0 to 3) (Table 5.9) in most patients. It is reasonable to conclude that any injection technique with even a remote possibility of being uncomfortable for the patient can be delivered more comfortably with a C-CLAD device.

Care and Handling of Syringes

When properly maintained, metal and plastic reusable syringes are designed to provide long-term service. The following is a summary of manufacturers’ recommendations concerning care of these syringes:

1. After each use, the syringe should be thoroughly washed and rinsed so as to be free of any local anesthetic solution, saliva, or other foreign matter. The syringe should be autoclaved in the same manner as other surgical instruments.
2. After every five autoclavings, the syringe should be dismantled and all threaded joints and the area where the piston contacts the thumb ring and the guide bearing should be lightly lubricated.
3. The harpoon should be cleaned with a brush after each use.
4. Although the harpoon is designed for long-term use, prolonged use will result in decreased sharpness and failure to remain embedded within the stopper of the cartridge. Replacement pistons and harpoons are readily available at low cost.

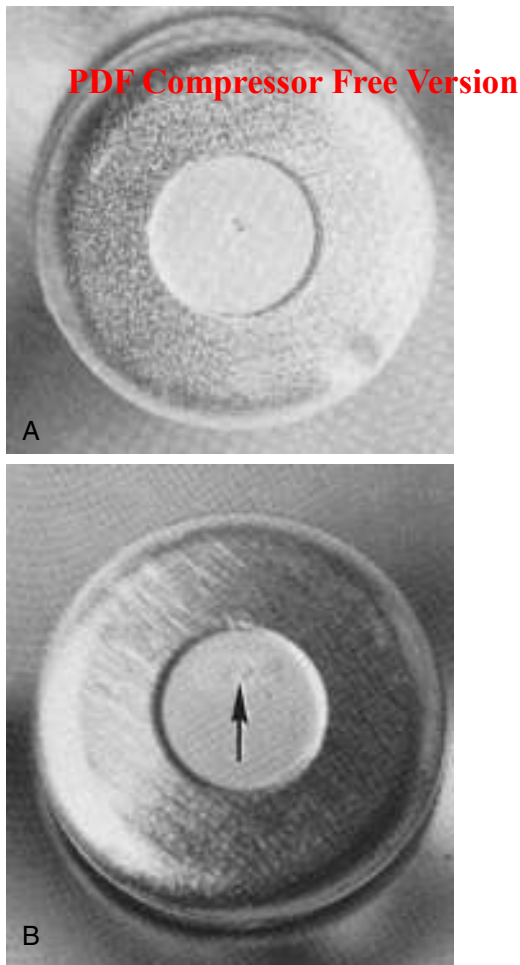
Problems

Leakage During Injection

When a syringe is reloaded with a second local anesthetic cartridge and a needle is already in place, care must be taken to ensure that the needle penetrates the center of the rubber diaphragm. An off-center perforation produces an ovoid puncture of the diaphragm, allowing leakage of the anesthetic solution around the outside of the metal needle and into the patient’s mouth (local anesthetics are unpleasant tasting) (Fig. 5.19). (For further information, see Chapter 7.)

Broken Cartridge

A badly worn syringe may damage the cartridge, leading to breakage. This can also result from a bent harpoon.




• **Fig. 5.19** Eccentric perforation. (A) Centric perforation of the diaphragm by a needle prevents leakage during injection. (B) Off-center perforation (*arrow*) permits leakage of anesthetic solution into the patient's mouth.



• **Fig. 5.20** Bent needle. A needle bent at the proximal end may not perforate the cartridge diaphragm. Pressure on the thumb ring can lead to cartridge breakage.

A needle that is bent at its proximal end ([Fig. 5.20](#)) may not perforate the diaphragm on the cartridge. Positive pressure on the thumb ring increases pressure within the cartridge, which may cause the cartridge to break.



• **Fig. 5.21** Note the bent harpoon of the syringe on the right.

Bent Harpoon

On the harpoon-aspirating syringe, the harpoon must be sharp and straight ([Fig. 5.21](#)). A bent harpoon produces an off-center puncture of the silicone rubber plunger, causing the plunger to rotate as it moves down the glass cartridge. This may result in cartridge breakage.

Disengagement of the Harpoon From the Plunger During Aspiration

Disengagement occurs if the harpoon is dull or if the administrator applies too much pressure to the thumb ring during aspiration. If this happens, the harpoon should be cleansed and sharpened or replaced with a new sharp harpoon. Disengagement is most likely to occur when a 30-gauge dental needle is being used because significant resistance is produced within the needle lumen as aspiration is attempted. A very gentle backward motion of the plunger is all that is necessary for successful aspiration. Forceful action is not necessary. (See the discussion in [Chapter 11](#).)

Surface Deposits

An accumulation of debris, saliva, and disinfectant solution interferes with syringe function and appearance. Deposits, which can resemble rust, may be removed with thorough scrubbing. Ultrasonic cleaning will not harm syringes.

Recommendations

No conclusive evidence indicates that any manufacturer's syringe is superior to syringes from other manufacturers. The ultimate decision in the selection of a syringe must be left to the discretion of the buyer. It is recommended, however, that before purchasing any syringe, the buyer place a full dental cartridge into it and pick up the syringe as if to use it. It should be noted whether the fingers (thumb to other fingers) are stretched maximally, because to aspirate with a harpoon-type syringe, one must be able to pull the thumb ring back several millimeters. If one is not able to do so, reliable aspiration is not possible. Although most syringes available today are of roughly the same dimensions, some variation is noted. Manufacturers market syringes with smaller thumb rings or shorter pistons. These modifications make aspiration easier to accomplish for persons with smaller hands.

The following are additional recommendations:

1. A safety syringe, minimizing the risk of accidental needlestick injury, is recommended for all local anesthetic injections.
2. A self-aspirating syringe is recommended for practitioners with smaller hands.
3. A C-CLAD system permits the atraumatic administration of local anesthetic in virtually all areas of the oral cavity.
4. Any syringe system used must be capable of aspiration. Nonaspirating syringes should never be used for local anesthetic injections.
5. All reusable syringes must be capable of being sterilized.
6. Nonreusable syringes must be disposed of properly.

References

1. Council on Dental Materials and Devices. American National Standards Institute/American Dental Association specification no. 34 for dental cartridge syringes, ISO 9997:1999, 2016. Available at: <https://www.iso.org/standard/20416.html>. Accessed January 30, 2018.
2. Wiener RC, Crout RJ, Sandell J. Local anesthetic syringe ergonomics and student preferences. *J Dent Educ.* 2009;73:518–522.
3. Bartlett SZ. Clinical observations on the effects of injections of local anesthetic preceded by aspiration. *Oral Surg.* 1972;33:520.
4. Malamed SF. *Handbook of Local Anesthesia*. St Louis: Mosby; 1980.
5. Meechan JG, Blair GS, McCabe JF. Local anaesthesia in dental practice. II. A laboratory investigation of a self-aspirating system. *Br Dent J.* 1985;159:109–113.
6. Meechan JG. A comparison of three different automatic aspirating dental cartridge syringes. *J Dent.* 1988;16:40–43.
7. Peterson JK. Efficacy of a self-aspirating syringe. *Int J Oral Maxillofac Surg.* 1987;16:241–244.
8. Delgado-Molina E, Bueno-Lafuente S, Berini-Ayres L, Gay-Escoda C. Comparative study of different syringes in positive aspiration during inferior alveolar nerve block. *Oral Surg Oral Med Oral Pathol Oral Radiol Endod.* 1999;88:557–560.
9. Figge FHJ, Scherer RP. Anatomical studies on jet penetration of human skin for subcutaneous medication without the use of needles. *Anat Rec.* 1947;97:335.
10. Margeris PM, Quarantillo EP, Lindberg RB. Jet injection local anesthesia in dentistry: a report of 66 cases. *US Armed Forces Med J.* 1958;9:625–634.
11. Cuny E, Fredekind RE, Budenz AW. Dental safety needles' effectiveness: results of a one-year evaluation. *J Am Dent Assoc.* 2000;131:1443–1448.
12. USAF Dental Evaluation and Consultation Service: 1Shot™ Safety Syringe. March 2005. Updated October 2006. Available at: http://www.airforcemedicine.af.mil/Portals/1/Documents/DECS/Product_Evaluations/InfectionPrevention_Control/Safety_Devices/1SHOT_Safety_Syringe.pdf?timestamp=1435583802172. Accessed February 5, 2018.
13. Hochman MN, Chiarello D, Hochman CB, et al. Computerized local anesthesia delivery vs. traditional syringe technique. *N Y State Dent J.* 1997;63:24–29.
14. Gibson RS, Allen K, Hutfless S, et al. The Wand vs. traditional injection: a comparison of pain related behaviors. *Pediatr Dent.* 2000;22:458–462.
15. Nicholson JW, Berry TG, Summitt JB, et al. Pain perception and utility: a comparison of the syringe and computerized local injection techniques. *Gen Dent.* 2001;49:167–172.
16. Perry DA, Loomer PM. Maximizing pain control: the AMSA injection can provide anesthesia with few injections and less pain. *Dimensions Dent Hyg.* 2003;1:28–33.
17. Fukayama H, Yoshikawa F, Kohase H, et al. Efficacy of anterior and middle superior alveolar (AMSA) anesthesia using a new injection system: the Wand. *Quintessence Int.* 2003;34:737–741.
18. Tan PY, Vukasin P, Chin ID, et al. The Wand local anesthetic delivery system. *Dis Colon Rectum.* 2001;44:686–689.
19. Landsman A, DeFronzo D, Hedman J, McDonald J. A New System for Decreasing the Level of Injection Pain Associated with Local Anesthesia of a Toe (Abstract). Presented at: Annual Meeting of the American Academy of Podiatric Medicine; 2001.
20. Friedman MJ, Hochman MN. 21st century computerized injection for local pain control. *Compend Contin Educ Dent.* 1997;18:995–1003.
21. Kudo M, Ohke H, Katagiri K, et al. The shape of local anesthetic injection syringes with less discomfort and anxiety: evaluation of discomfort and anxiety caused by various types of local anesthetic injection syringes in high level trait-anxiety people. *J Jpn Dent Soc Anesthesiol.* 2001;29:173–178.
22. Hochman MN, Friedman MJ. In vitro study of needle deflection: a linear insertion technique versus a bi-directional rotation insertion technique. *Quintessence Int.* 2000;31:737–743.
23. Fuhs QM, Walker WA, Gouigh RW, et al. The periodontal ligament injection: histological effects on the periodontium in dogs. *J Endodont.* 1983;9:411–415.
24. Galili D, Kaufman E, Garfunkel AA, et al. Intraligamentary anesthesia: a histological study. *Int J Oral Surg.* 1984;12:511–516.
25. Pashley EL, Nelson R, Pashley DH. Pressures created by dental injections. *J Dent Res.* 1981;60:1742–1748.
26. Albers DD, Ellinger RF. Histologic effects of high-pressure intraligamentary injections on the periodontal ligament. *Quintessence Int.* 1988;19:361–363.
27. Ferrari M, Cagidiaco MC, Vichi A, et al. Efficacy of the computer-controlled injection system STA, the Ligamaject, and the dental syringe for intraligamentary anesthesia in restorative patients. *Int Dent SA.* 2010;11:4–12.
28. Yogesh Kumar TD, John JB, Asokan S, Geetha Priya PR, Punithavathy R, Praburajan V. Behavioral response and pain perception to computer controlled local anesthetic delivery system and cartridge syringe. *J Indian Soc Pedod Prev Dent.* 2015;33:223–228.
29. Yogesh-Kumar TD, Sharath A, John JB. Cartridge syringe vs computer controlled local anesthetic delivery system: pain related behaviour over two sequential visits—a randomized controlled trial. *J Clin Exp Dent.* 2015;7:e513–e518.
30. Kwak EJ, Pang NS, Cho JH, Jung BY, Kim KD, Park W. Computer-controlled local anesthetic delivery for painless anesthesia: a literature review. *J Dent Anesth Pain Med.* 2016;16:81–88.
31. Mittal M, Kumar A, Srivastava D, Sharma P, Sharma S. Pain perception: computerized versus traditional local anesthesia in pediatric patients. *J Clin Pediatr Dent.* 2015;39:470–474.
32. Garret-Bernardin A, Cantile T, D'Antò V. Pain experience and behavior management in pediatric dentistry: a comparison between traditional local anesthesia and the wand computerized delivery system. *Pain Res Manag.* 2017;7941238.
33. Baghlaif K, Alamoudi N, Elashiry E, Farsi N, El Derwi DA, Abdullah AM. The pain-related behavior and pain perception associated with computerized anesthesia in pulpotomies of mandibular primary molars: a randomized controlled trial. *Quintessence Int.* 2015;46:799–806.

34. Ashkenazi M, Bloomer S, Eli I. Effective computerized delivery of intrasulcular anesthetic in primary molars. *J Am Dent Assoc.* 2005;136:1418-1420.
35. Murphy D. *Ergonomics and the Dental Care Worker*. Washington, DC: American Public Health Association; 1998.
36. Juvaplus: Dentapen, Juvaplus SA, Neuchatel. Available at: <https://dentapen.ch>.
37. Friedman MJ, Hochman MN. The AMSA injection: a new concept for local anesthesia of maxillary teeth using a computer-controlled injection system. *Quintessence Int.* 1998;29:297-303.
38. Friedman MJ, Hochman MN. P-ASA block injection: a new palatal technique to anesthetize maxillary anterior teeth. *J Esthet Dent.* 1999;11:23-71.

The Needle

Types of Needle

The needle is the vehicle that permits local anesthetic solution to travel from the dental cartridge into the tissues surrounding the needle tip. Virtually all needles used in dentistry are stainless steel and disposable. Needles manufactured for dental intraoral injections are presterilized and disposable.

Reusable needles should never be used for injections.

Because the needle represents the most dangerous component of the armamentarium, the one most likely to produce accidental injury to the patient or doctor, *safety needles* have been developed.^{1,2} Although safety needles are not yet used to any appreciable degree in dentistry in the United States, it is likely that at some point in the not too distant future their use will become commonplace, if not mandatory.

Needles also represent the most fear-inducing component of the local anesthetic armamentarium for the patient. Fear of needles is termed *trypanophobia*.

Anatomy of a Dental Needle

The needle is composed of a single piece of tubular metal around which is placed a plastic or metal syringe adaptor and the needle hub (Fig. 6.1).

All needles have the following components in common: the bevel, the shaft, the hub, and the cartridge-penetrating end (Fig. 6.2).

Bevel

The *bevel* defines the point or tip of the needle. A variety of bevel types are available on dental needles, including short, medium, long, multibeveled, and scalpel (Fig. 6.3).³ The bevel functions to provide a cutting surface allowing the needle to penetrate mucosa with as little resistance as possible.³ Bevels with less tissue resistance have been shown to increase patient comfort.^{4,5} Jastak et al.⁶ stated that the multibeveled needle produces the most effective puncture, while eliciting the least amount of trauma. The scalpel bevel design allows needle insertion with less tissue displacement, thus requiring less force to penetrate the mucosa.⁷

The scalpel bevel needle is recommended for infiltration and periodontal ligament (PDL) injections. It is not recommended for nerve blocks where the nerve may be directly contacted (e.g., inferior alveolar nerve block).^{3,6}

The greater the angle of the bevel with the long axis of the needle, the greater will be the degree of *deflection* as the needle passes through hydrocolloid (or the soft tissues of the mouth) (Fig. 6.4).^{4,5,8,9} A needle tip centered on the long axis (Fig. 6.5A) will deflect to a lesser extent than a beveled-point needle, whose point is eccentrically situated (see Fig. 6.5B and Table 6.1).

Several needle manufacturers have placed indicators on the plastic or metal hub to help orient the doctor to the position of the bevel during needle insertion and injection of the drug.

Shaft

The *shaft* of the needle is one long piece of tubular metal running from the tip of the needle through the hub, continuing to the piece that penetrates the cartridge (see Fig. 6.1). Two factors to be considered about this component of the needle are the diameter of its lumen (e.g., the needle gauge) and the length of the shaft from point to hub.

The *hub* is a plastic or metal piece through which the needle attaches to the syringe. The interior surface of metal-hubbed needles is prethreaded, as are most but not all plastic-hubbed needles.

The *cartridge-penetrating end* of the dental needle extends through the needle adaptor and perforates the diaphragm of the local anesthetic cartridge. Its blunt end rests within the cartridge.


When one is selecting needles for use in various injection techniques, two factors that must be considered are gauge and length.

Gauge

Gauge refers to the diameter of the lumen of the needle: the smaller the number, the greater the diameter of the lumen. A 30-gauge needle has a smaller internal diameter than a 25-gauge needle. In the United States, needles are color coded by gauge (Fig. 6.6).



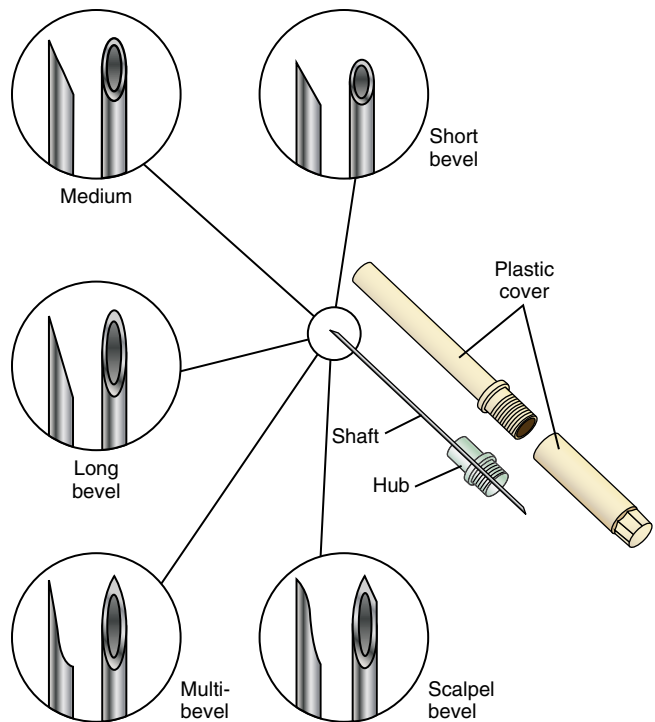
• **Fig. 6.1** Metal disposable needle, dissembled.



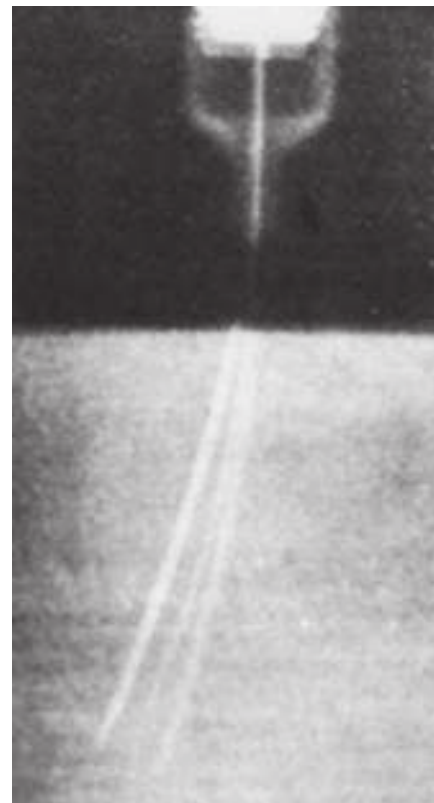• **Fig. 6.2** Components of dental local anesthetic needle. Long needle (top); short needle (bottom).

There is a growing trend toward the use of smaller-diameter (higher-number-gauge) needles, based on the assumption that they are less traumatic to the patient than needles with larger diameters (Table 6.2). This assumption is unwarranted.¹⁰ Hamburg¹¹ demonstrated as far back as 1972 that patients cannot differentiate between 23-, 25-, 27-, and 30-gauge needles. Others have confirmed this finding.^{12,13} A clinical experiment demonstrates this point:

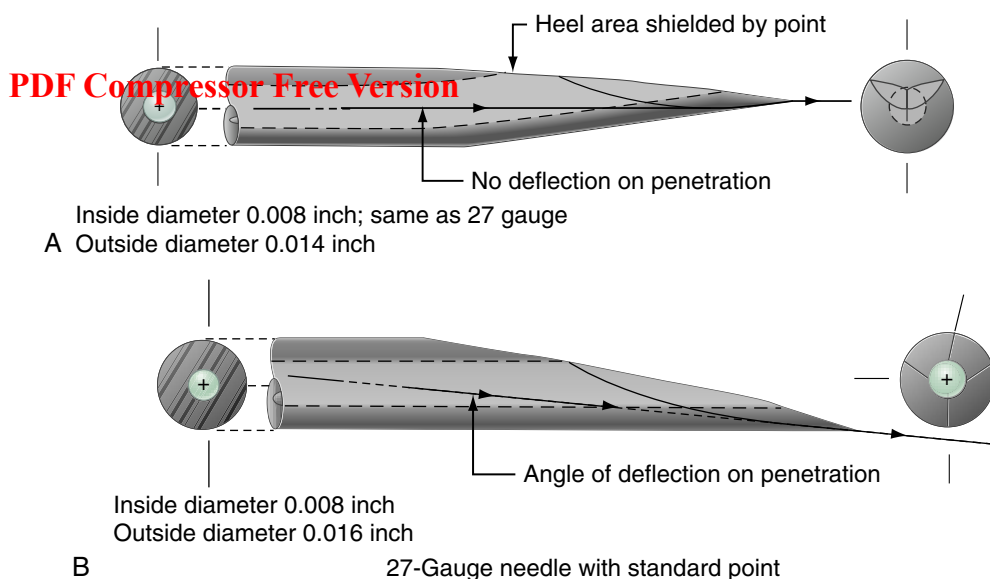
1. Three needles—25-, 27-, and 30-gauge needles—are selected.
2. The buccal mucosa over the maxillary anterior teeth should be dried.
3. No topical anesthetic should be used.
4. The mucosa should be taut.
5. The mucosa should be gently penetrated (about 2 to 3 mm) with each of the three needles without revealing to the patient which needle is being used. A different site should be selected for each penetration.
6. Using the visual analog scale (see Fig. 5.13), have the patient rate his or her perception of each needle penetration.



• **Fig. 6.3** Types of needle bevel. (From Logothetis DD: *Local anesthesia for the dental hygienist*, ed 2, St. Louis, 2017, Mosby)



• **Fig. 6.4** Radiograph demonstrating various degrees of needle deflection with different gauges (from left to right, 30 gauge, 27 gauge, and 25 gauge). (From Robison SF, Mayhew RB, Cowan RD, et al. Comparative study of deflection characteristics and fragility of 25-, 27-, and 30-gauge short dental needles. *J Am Dent Assoc.* 1984;109:920-924.)



• **Fig. 6.5** (A) The tip of a nondeflecting needle is located in the center of the shaft, thereby minimizing deflection as the needle penetrates soft tissues. (B) Conventional dental needle. The needle tip lies at the lower edge of the needle shaft, thereby producing deflection as the needle passes through soft tissue.

TABLE 6.1 Deflection of Needles Inserted in Hydrocolloid Tubes to Their Hubs

	Length (Tip to Hub, mm)	Maximum Tip Deflection (±SD, mm)
25-Gauge long (conventional)	35	7.1 ± 0.81 ^a
27-Gauge long (conventional)	36	8.4 ± 1.2 ^a
27-Gauge short (conventional)	26	4.6 ± 0.97 ^b
28-Gauge long (nondeflecting)	31	1.1 ± 0.82
28-Gauge short (nondeflecting)	22	0.8 ± 0.91

^aA statistically significant difference from the nondeflecting long needle ($P < .01$); $n = 10$ needles in each group.

^bA statistically significant difference from the nondeflecting short needle ($P < .01$); $n = 10$ needles in each group.

SD, Standard deviation.

Data modified from Jeske AH, Boshart BF. Deflection of conventional versus non-deflecting dental needles in vitro. *Anesth Prog.* 1985;32:62–64.

In hundreds of clinical demonstrations of the above, only the rare patient was able to correctly determine the gauge of each needle. The usual response has been that he or she could not discern any difference.

Larger-gauge needles (e.g., 25 gauge, 27 gauge) have distinct advantages over smaller ones (30 gauge) (Box 6.1): less deflection occurs as the needle passes through tissues (Table 6.1 and Fig. 6.4). This leads to *greater accuracy* during insertion of the needle (it goes in a straighter line) and, it is hoped, to increased success rates, especially for those



• **Fig. 6.6** Color coding by needle gauge: 25-gauge, red; 27-gauge, yellow/orange; 30-gauge, blue/lavender. (Courtesy of Septodont, Inc, Lancaster, PA)

techniques in which the depth of soft tissue penetrated is significant (e.g., inferior alveolar, Gow-Gates mandibular, anterior superior alveolar [infraorbital] nerve blocks). *Needle breakage*, although extremely rare today with the use of disposable needles, is even less likely to occur with a larger needle. In a review of reported needle breakage cases, Malamed et al.¹⁴ reported that 95.23% of needles that did break were 30-gauge needles. Numerous authors have demonstrated that *aspiration of blood* is easier and more reliable through a larger lumen.^{15–19} Foldes and McNall¹⁵ reported the following findings based on an unpublished study by Monheim:

1. One hundred percent positive aspirations were achieved from blood vessels with 25-gauge needles.
2. Eighty-seven percent positive aspirations were achieved from blood vessels with 27-gauge needles.
3. Two percent positive aspirations were achieved from blood vessels with 30-gauge needles.

Trapp and Davies²⁰ and Delgado et al.²¹ reported that in vivo human blood may be aspirated through 23-, 25-, 27-, and 30-gauge needles without a clinically significant difference in resistance to flow.

TABLE 6.2 Needle Purchases, US Dentistry, 2006**PDF Compressor Free Version**

Gauge	Length	Data Provided by			
		Sullivan-Schein Inc. (2006)		Septodont Inc. (2006)	
25	Short	<1%	1%	0.6%	3%
	Long	1%		2.3%	
27	Short	10%	42%	13%	38%
	Long	32%		25%	
30	Short	50%	56%	51%	59%
	Extra short	6%		8%	

From Malamed SF, Reed KL, Poorsattar S. Needle breakage: incidence and prevention. *Dent Clin North Am.* 2010;54:745–756.

• BOX 6.1 Advantages of Larger-Gauge Needles Over Smaller-Gauge Needles

1. Less deflection as the needle advances through tissues
2. Greater accuracy of injection
3. Less chance of needle breakage
4. Easier aspiration
5. No perceptual difference in patient comfort

Despite this ambiguity concerning the ability to aspirate blood through needles of various gauges, the use of larger needles (e.g., 25 gauge, 27 gauge) is recommended for any injection technique used in a highly vascular area, or when needle deflection through soft tissue would be a factor. Although blood may be aspirated through all 23-through 30-gauge needles, resistance to aspiration is greater when smaller-gauge needles are used, increasing the likelihood that the metal harpoon will become dislodged from the rubber plunger during aspiration, making the aspiration attempt futile.

Industry standards for needle gauge have been in place for years (Table 6.3); however, variations in internal diameter exist between needle manufacturers. Larger-gauge needles (e.g., 25 gauge, 27 gauge) should be used when the risk of positive aspiration is increased, as during an inferior alveolar, posterior superior alveolar, or mental/incisive nerve block.

The most commonly used (e.g., most often purchased) needles in dentistry are the 30-gauge short and the 27-gauge long needle.¹⁴ The 25-gauge (long or short) needle remains the preferred needle for all injections presenting a high risk of positive aspiration. The 27-gauge needle can be used for all other injection techniques, provided the aspiration percentage is low and tissue penetration depth is not great (increased deflection with this thinner needle). The 30-gauge needle is not specifically recommended for any injection, although it may be used in instances of localized infiltration, as when hemostasis is attained during periodontal therapy.

TABLE 6.3 Specifications for Needle Gauges^a

Gauge	Outer Diameter (mm)	Inner Diameter (mm)
7	4.57	3.81
8	4.19	3.43
10	3.40	2.69
11	3.05	2.39
12	2.77	2.16
13	2.41	1.80
14	2.11	1.60
15	1.83	1.32
16	1.65	1.19
17	1.50	1.04
18	1.27	0.84
19	1.07	0.69
20	0.91	0.58
21	0.81	0.51
22	0.71	0.41
23	0.64	0.33
25	0.51	0.25
26	0.46	0.25
27	0.41	0.20
30	0.31	0.15

^aDental needle gauges in bold.

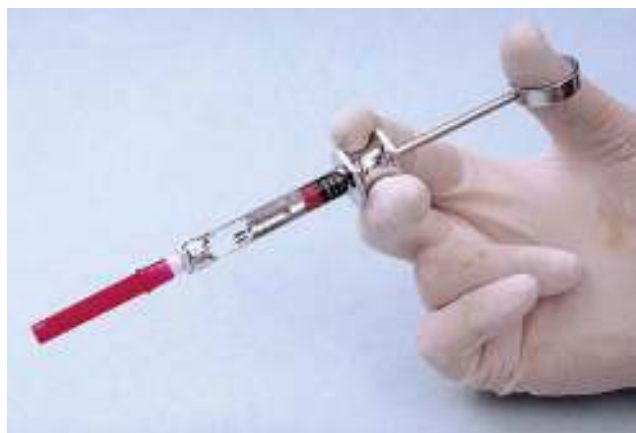Deflection of the needle as it passes through soft tissue is a consideration when a needle must penetrate a greater thickness of soft tissue. On the standard dental needle (see Fig. 6.5B), the tip of the point is eccentrically located. As the needle shaft penetrates soft tissue, the point of the

needle is deflected by the tissue through which it passes. The greater the angle of the bevel, the greater is the degree of needle deflection. Every time a needle is deflected on which the tip of the point is located in the center of the lumen, thereby minimizing deflection as the needle passes through soft tissue (see Fig. 6.5A). Jeske and Boshart⁵ demonstrated the effectiveness of this “nondeflecting” needle (Table 6.1). However, it needs to be demonstrated clinically that a lesser degree of needle deflection occurring as the needle passes through soft tissues actually results in an increased rate of successful anesthesia compared with that observed with standard needles. Over years of use, dentists become accustomed to the deflecting needles they use and gradually modify their injection techniques to accommodate this deflection (they “learn” to make the injections work even with deflection). Changing to a nondeflecting needle might initially lead to lower success rates until the doctor “learns” the new needle.

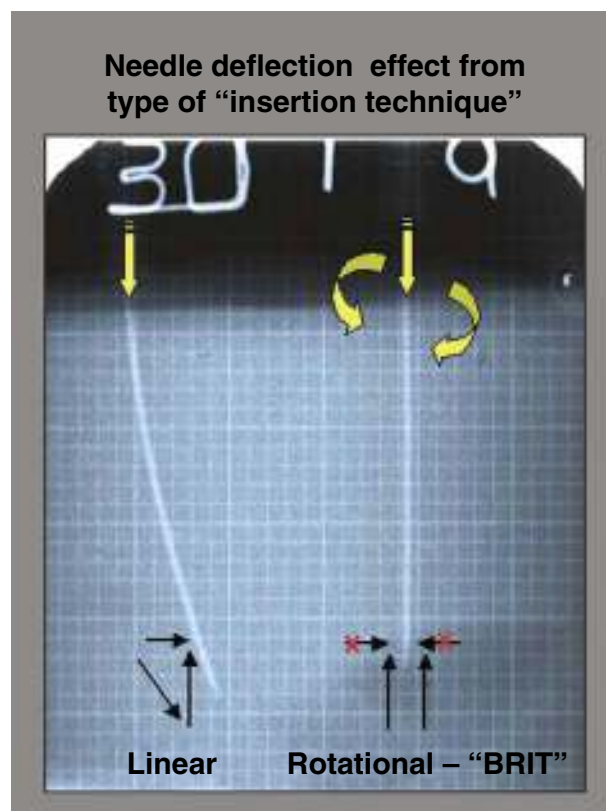
Minimizing Needle Deflection: Birotational Insertion Technique

A new approach to reducing needle deflection has been described.²² Rotational insertion (described as birotational insertion technique [BRIT]), a technique in which the operator rotates the handpiece or needle in a back-and-forth rotational movement while advancing the needle through soft tissue, is similar to techniques used for acupuncture or endodontic instrumentation. Hochman and Friedman²² demonstrated that needle deflection could be virtually eliminated by using a rotational insertion technique during needle advancement. An *in vitro* study of 60 needle insertions into a tissue-like medium was performed with needles of three different gauges to compare rotational insertion versus the traditional linear nonrotating insertion technique. The investigators demonstrated that the deflectional bending of a needle could be minimized or eliminated, regardless of the length or gauge of the needle, as long as the insertion was performed using the BRIT.

Deflection of a needle is a consequence of resultant forces acting on the needle bevel during tissue penetration and advancement. An eccentric pointed beveled needle generates several different forces that act on it during insertion when a nonrotating linear insertion technique is used. A linear insertion technique is the conventional technique used with the traditional dental syringe, which is typically held with a palm-thumb grasp (Fig. 6.7). During this type of insertion, a force perpendicular to the forward directional movement (vector) acts on the surface of the beveled needle, causing the needle to bend (or deflect) in a direction opposite to which the bevel faces (e.g., if the bevel faces “up,” the advancing movement causes a beveled needle to deflect “downward”). The longer the needle length, the more exaggerated the bending or deflection becomes as a result of the greater distance traveled along the deflecting path. The smaller the diameter of the needle, the more exaggerated the bending or deflection, because a smaller-gauge needle is less capable of resisting the deflection or bending force on



• Fig. 6.7 Traditional syringe held in palm-thumb grasp.



• Fig. 6.8 Birotational insertion technique (BRIT).

the surface of the beveled needle tip (e.g., a 30-gauge needle deflects more than a 25-gauge needle).

When the BRIT is used during needle insertion, the perpendicular force that causes deflection is eliminated or “neutralized” from the constant changing of bevel orientation as it is rotated (Fig. 6.8).²² This allows eccentrically beveled needles to travel in a straight path. The traditional handheld syringe requires a palm-thumb grasp (see Fig. 6.7) that does not permit such a technique. A computer-controlled local anesthetic delivery system uses a lightweight handpiece that is held with a “pen-like” or “dart” grasp that is easily rotated.

A subsequent study by Hochman and Friedman²³ demonstrated that the BRIT offers the added benefit of reducing the force necessary for needle penetration and advancement

through tissues. With the BRIT, all resultant forces are directed toward the forward path of insertion because the deflecting or bending force is in the same direction as the rotational insertion technique, as described earlier. This allows forward movement of the needle to occur more efficiently and with less effort (e.g., less force). In addition, rotation of the beveled needle allows the sharp cutting edge to contact the full circumference of the tissue surface, contributing to the reduction in force that is necessary during penetration and advancement. This is not unlike the rotational effect that a surgical drill bit has as it is boring through tissue or bone.

The BRIT has been demonstrated to improve injection techniques because the deflection of a standard needle during insertion is minimized.²⁴

Length

Dental needles are available in three lengths: long, short, and ultrashort. Ultrashort needles are available only as 30-gauge needles. Despite the claim for uniformity of length by manufacturers, significant differences are found (Table 6.4).

The length—measured from hub to tip—of a short needle is between 20 and 25 mm, with a standard of about 20 mm, whereas the dental long needle measures between 30 and 35 mm, with a standard of about 32 mm (Fig. 6.9).

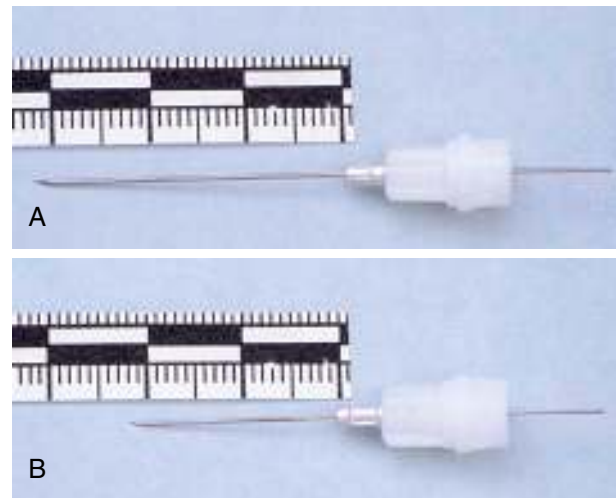
A very important rule concerning needle penetration is that “needles should not be inserted into tissues all the way to their hubs unless this is absolutely necessary for the success of the injection.” This statement has appeared in “standard” local anesthesia textbooks since the early 1900s to mid-1900s.²⁵⁻²⁸ One reason for this precaution is that needle breakage, which although extremely rare, does occur. The weakest portion of the needle (the most rigid, the part receiving the greatest stress during needle advancement through tissues) is at the hub, which is where needle breakage happens. When a needle that is inserted into the soft tissues to its hub breaks, the elastic properties of the tissues permit them to rebound and cover (bury) the needle remnant entirely. Retrieval is usually difficult (as discussed in Chapter 17). If

even a small portion (5 mm or more) of the broken needle shaft remains visible within the oral cavity, it can usually be retrieved easily with a hemostat or pickup forceps.

A long needle is preferred for all injection techniques in which penetration of approximately 20 mm or more of soft tissue (e.g., inferior alveolar, Gow-Gates mandibular, Akinosi-Vazirani mandibular, infraorbital, maxillary [V₂] nerve blocks) is required. Short needles may be used for any injection in any patient who does not require penetration of significant depths of soft tissue (e.g., close to or beyond 20 mm). In pediatric dentistry, use of a short needle is standard until the individual patient’s anatomy mandates change to a long dental needle.

Care and Handling of Needles

Needles available to the dental profession today are presterilized and disposable. With proper care and handling, they should not be the cause of significant difficulties.



• Fig. 6.9 (A) Long dental needle (length approximately 32 mm). (B) Short dental needle (length approximately 20 mm).

TABLE 6.4 Needle Lengths^a in millimeters (mm)

Manufacturer	25 Gauge		27 Gauge		30 Gauge		
	Long	Short	Long	Short	Long	Short	Ultrashort
Industry standard	32	20	32	20			
Manufacturer A	30		30	21	25	21	
Manufacturer B	32 ± 1.5	22 ± 1.5	32 ± 1.5	22 ± 1.5		21 ± 1.5	12 ± 1.0
Manufacturer C			32	21	25	21	
Manufacturer D	35		35	25		25	10
Manufacturer E	32			21		19	

^aAll measurements obtained directly from needle manufacturers.

1. Needles must never be used on more than one patient.
2. Needles should be changed after several (three or four) tissue penetrations. In a compressor file version, stainless steel disposable needles become dulled. Tissue penetration becomes increasingly traumatic with each insertion, producing pain on insertion and soreness when sensation returns after the anesthesia has resolved.
3. Needles should be covered with a protective sheath when not being used to prevent accidental needlestick with a contaminated needle (see the discussion in [Chapter 9](#)).
4. Attention should always be paid to the position of the uncovered needle tip, whether inside or outside the patient's mouth. This minimizes the risk of potential injury to the patient or the administrator.
5. Needles must be properly disposed of after use to prevent possible injury or reuse by unauthorized individuals. Needles can be destroyed in any of the following ways:
 - a. Contaminated needles (as well as all other items contaminated with blood or saliva, such as cartridges) should be disposed of in special "contaminated" or "sharps" containers ([Fig. 6.10](#)).
 - b. Proper use of a self-sheathing ("safety" needle) needle or syringe unit (as discussed in [Chapter 5](#)) minimizes risk of accidental needlestick.
 - c. When needles are to be reused for subsequent injections (a practice that is unique to the dental profession vs. medicine or other health care professions, where repeated injections are rarely administered), recapping is accomplished with a needle-capping device ([Fig. 6.11](#)).
 - d. Contaminated needles should never be discarded into open trash containers.


Summary

In summary, only one local anesthetic needle is necessary in the dental office, the 25-gauge long needle, which can be used for all anesthetic techniques discussed in this text. It provides a rigidity that is not available with higher-gauge (smaller-diameter) needles that is necessary in the PDL and intraseptal injections; it deflects to a lesser degree than smaller-gauge needles and

provides easier and more reliable aspiration. Because patient sensitivity is not increased with the 25-gauge long needle, its value is increased still further. In reality, however, it is practical to have a second needle available—the 25- or 27-gauge short needle—for use in injections in which the thickness of soft tissue to be penetrated is less than 20 mm, and where the risk of positive aspiration is minimal, as well as in areas of the oral cavity where stabilization of a long needle might prove difficult (e.g., maxillary anterior teeth, the palate).



• **Fig. 6.10** (A) Container for disposal of discarded local anesthetic cartridges. (B) "Sharps" container for disposal of contaminated needles.



• **Fig. 6.11** (A) and (B). Various devices to aid in safely recapping used needles.

In previous editions of this textbook this author recommended as the “ideal” local anesthetic needle armamentarium the 25-gauge long and the 27-gauge short needle. However, given the fact that use of the 25-gauge needle is minimal, and although I still prefer the 25-gauge long needle, it is now my recommendation that the “ideal” needle armamentarium is the 27-gauge long needle and the 27-gauge short needle.

Problems With Needles

Pain on Insertion

Use of a dull needle can lead to pain on initial penetration of the mucosa. This pain may be prevented by use of sharp, new, disposable needles, application of a topical anesthetic at the penetration site, and stretching of the tissue before needle insertion. The needle should be changed after three or four penetrations of mucosa if multiple insertions are necessary. The sharpness and structure of the needle bevel is a vital component in reducing pain perception on needle penetration.^{3,30,31} The scalpel design bevel (Fig. 6.12) has been reported to allow needle insertion with less tissue displacement, thus requiring less force to penetrate mucous membrane.^{3,7}

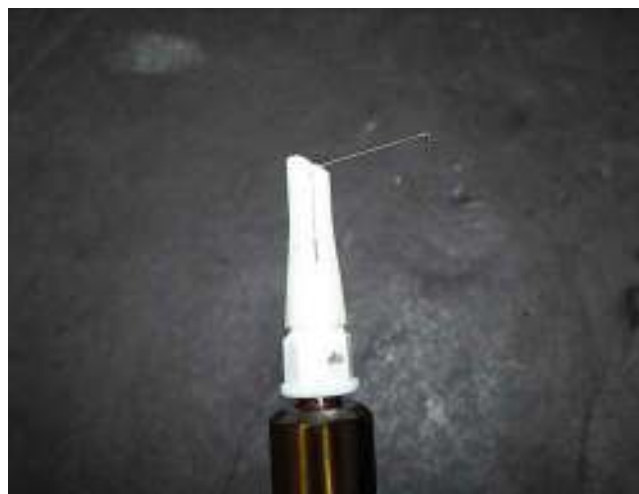Breakage

Bending weakens needles, making them more likely to break on subsequent contact with hard tissues such as bone. Needles should not be bent if they are to be inserted into soft tissue to a depth greater than 5 mm. No injection technique used in dentistry (in which the needle enters soft tissue) requires a needle to be bent for success of the injection. However, many doctors do bend needles on a routine basis. Dr. Greg Tuttle³² has designed the TNN Needle Guide (<http://www.tuttlenumbnow.com>) and an intraosseous anesthetic technique that permits a needle to be bent safely. The bend in the needle occurs along the shaft, not at the hub (Fig. 6.13).

Most often, needles are bent by doctors administering an inferior alveolar nerve block, a posterior superior alveolar nerve block, an intrapulpal injection, an injection into the PDL, or an intraosseous injection. The inferior alveolar nerve block and the posterior superior alveolar nerve block can be easily administered successfully with a straight (unbent) needle (see Chapters 13 and 14). The PDL and intrapulpal injections can usually be administered without bending the needle; however, occasions arise, such as at the distal root of a mandibular second molar (PDL), with root canals in posterior teeth (intrapulpal), or with injection into bone distal to a second molar (intraosseous), in which the injection site is not accessible with a straight needle. In these cases, bending of the needle is essential to success. Because the needle does not enter soft tissue farther than 2 to 4 mm



• Fig. 6.12 Dental needle with scalpel bevel.



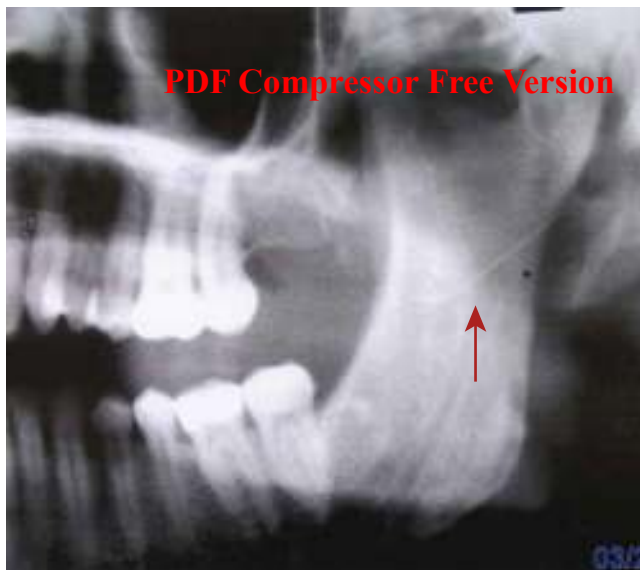
• Fig. 6.13 TNN Needle Guide.

(PDL), or at all (intrapulpal), there is little danger of the needle being not retrievable in the unlikely event that it breaks (Figs. 6.14 and 6.15).

No attempt should be made to change the direction of a needle while it is embedded in tissue. If the direction of a needle must be changed, the needle should first be withdrawn *almost* completely from the tissue and then its direction altered.

No attempts should be made to force a needle against resistance (needles are not designed to penetrate bone). Smaller (30- and 27-gauge) needles are more likely to break than larger (25-gauge) needles. Of 105 broken needle cases this author has examined, 100 involved a 30-gauge short or ultrashort needle (95.24%). The remaining five needles were 27-gauge short needles.¹⁴

Needles recommended for specific injection techniques are presented in the section headed “Recommendations.”



• **Fig. 6.14** Retained broken needle after inferior alveolar nerve block (red arrow).



• **Fig. 6.15** Remainder of retained local anesthetic needle shown in Fig. 6.14.

Pain on Withdrawal

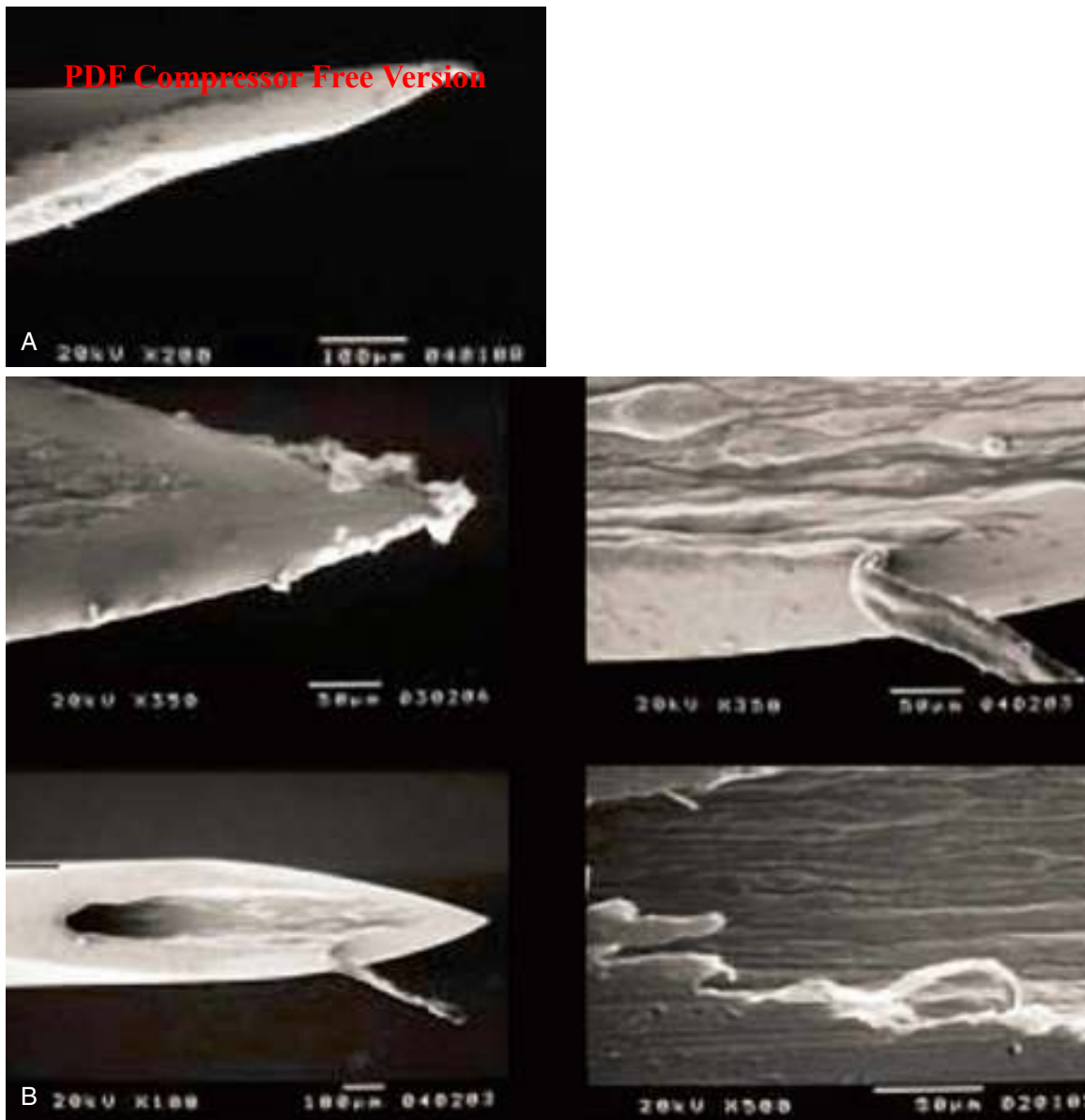
Pain on withdrawal of the needle from tissue can be produced by “fishhook” barbs on the tip or other manufacturing defects in needles (Fig. 6.16). Fishhook barbs may be produced during the manufacturing process, but it is much more likely that they will develop when the needle tip forcefully contacts a hard surface, such as bone (see Fig. 6.16A). A needle should never be forced against resistance. If one is in doubt about the presence of barbs, the needle should be changed between insertions.

Injury to the Patient or Administrator

Penetration of, with resultant injury to, areas of the body with the needle can occur unintentionally. A major cause is inattention by the administrator, although sudden unexpected movement by the patient is also a frequent cause. The needle should remain capped until it is to be used and should be made safe (sheathed or recapped) immediately after withdrawal from the mouth (see Fig. 6.11).

Recommendations

1. Sterile disposable needles should be used.
2. If multiple injections are to be administered, needles should be changed after three or four insertions in a single patient.
3. Needles must never be used on more than one patient.
4. Needles should not be inserted into tissue to their hub unless this is absolutely necessary for success of the injection.
5. The direction of a needle should not be changed while it is still in tissue.
6. A needle should never be forced against resistance.
7. Needles should remain capped until used and should be made safe immediately when withdrawn.
8. Needles should be discarded and destroyed after use to prevent injury or reuse by unauthorized persons.
9. The injection techniques presented in Table 6.5 are listed with their recommended needles (for the adult of average size).



• **Fig. 6.16** Needle barbs. (A) Microscopic view of barb on a dental needle. (B) Microscopic views of irregularities in unused dental needles. (From Espinosa-Sanchez D, Espinosa-Fernandez R. Microscopic assessment of dental needles. Dissertation. University Centre of Health Sciences, Guadalajara University, Guadalajara, Mexico Used with permission.)

TABLE 6.5 Recommended Needles for Injection Techniques

Technique	Needle Gauge	Needle Length
Supraperiosteal (infiltration)	27	Short
Posterior superior alveolar nerve block	27 ^a	Short ^a
Middle superior alveolar nerve block	27	Short
Anterior middle superior alveolar nerve block	27	Short
Palatal approach anterior superior alveolar nerve block	30 ^b	Short
Buccal (long) nerve block	27 ^c	Short
Infiltration for hemostasis	27	Short
Periodontal ligament injection (or intraligamentary injection)	27	Short
Intraseptal injection	27	Short
Intraosseous injection	27	Short
Intrapulpal injection	27	Short
Anterior superior alveolar nerve block (“infraorbital”)	25 or 27	Long
Maxillary (V ₂) nerve block	25 or 27	Long
Inferior alveolar (“mandibular”) nerve block	25 or 27	Long
Gow-Gates mandibular nerve block	25 or 27	Long
Vazirani-Akinosi mandibular nerve block	25 or 27	Long

^aIn earlier editions of this book, the 25-gauge long needle was recommended. As a means of minimizing the risk of hematoma after the posterior superior alveolar injection, a short needle is now recommended. If available, a 25-gauge short needle should be used; where this is not available, the 27-gauge short needle is recommended. (See [Chapter 13](#) for additional discussion.)

^bThe authors of the palatal approach anterior superior alveolar article recommend use of a 30-gauge ultrashort needle.^{17,18}

^cIn most clinical situations, the 25-gauge long needle, used for the inferior alveolar nerve block, is used for the buccal nerve block, which is administered immediately after the inferior alveolar nerve block.

References

- Cuny EJ, Fredekind R, Budenz AW. Safety needles: new requirements of the Occupational Safety and Health Administration bloodborne pathogens rule. *J Calif Dent Assoc.* 1999;27:525–530.
- Cuny E, Fredekind RE, Budenz AW. Dental safety needles “effectiveness”: results of a one-year evaluation. *J Am Dent Assoc.* 2000;131:1143–1148.
- Boynes SG. Evaluating the advances and use of hypodermic needles in dentistry. *Compend Contin Educ Dent.* 2014;35:649–654.
- Aldous JA. Needle deflection: a factor in the administration of local anesthetics. *J Am Dent Assoc.* 1968;77:602–604.
- Jeske AH, Boshart BF. Deflection of conventional versus non-deflecting dental needles in vitro. *Anesth Prog.* 1985;32:62–64.
- Jastak JT, Yagiela JA, Donaldson D. *Local Anesthesia for the Oral Cavity.* Philadelphia: WB Saunders; 1995.
- Steele AC, German MJ, Haas J, et al. An in vitro investigation of the effect of bevel design on the penetration and withdrawal forces of dental needles. *J Dent.* 2013;41:164–169.
- Robison SF, Mayhew RB, Cowan RD, et al. Comparative study of deflection characteristics and fragility of 25-, 27-, and 30-gauge short dental needles. *J Am Dent Assoc.* 1984;109:920–924.
- Delgado-Molina E, Tamarit-Borras M, Berini-Aytes L, et al. Comparative study of two needle models in terms of deflection during inferior alveolar nerve block. *Med Oral Pathol Oral Cir Bucal.* 2009;14:440–444.
- Jeske AH, Blanton PL. Misconceptions involving dental local anesthesia. Part 2. Pharmacology. *Tex Dent J.* 2002;119:310–314.
- Hamburg HL. Preliminary study of patient reaction to needle gauge. *NY State Dent J.* 1972;38:425–426.
- Farsakinan LR, Weine FS. The significance of needle gauge in dental injections. *Compend Contin Educ Dent.* 1991;12:262–268.
- Flanagan T, Wahl MI, Schmitt MM, et al. Size doesn’t matter: needle gauge and injection pain. *Gen Dent.* 2007;55:216–217.
- Malamed SF, Reed KL, Poorsattar S. Needle breakage: incidence and prevention. *Dent Clin North Am.* 2010;54:745–756.
- Foldes FF, McNall PG. Toxicity of local anesthetics in man. *Dent Clin North Am.* 1961;5:257–258.
- Harris S. Aspirations before injection of dental local anesthetics. *J Oral Surg.* 1957;25:299–303.
- Kramer H, Mitton V. Dental emergencies. *Dent Clin North Am.* 1973;17:443–460.
- McClure DB. Local anesthesia for the preschool child. *J Dent Child.* 1968;35:441–448.
- Reed KL, Malamed S, Fonner AM. Local anesthesia part 2: technical considerations. *Anesth Prog.* 2012;59:127–137.
- Trapp LD, Davies RO. Aspiration as a function of hypodermic needle internal diameter in the in-vivo human upper limb. *Anesth Prog.* 1980;27:49–51.
- Delgado-Molina E, Tamarit-Borras M, Berini-Aytes L, et al. Evaluation and comparison of 2 needle models in terms of blood aspiration during truncal block of the inferior alveolar nerve. *J Oral Maxillofac Surg.* 2003;61:1011–1015.
- Hochman MN, Friedman MJ. In vitro study of needle deflection: a linear insertion technique versus a bi-directional rotation insertion technique. *Quintessence Int.* 2000;31:737–743.
- Hochman MN, Friedman MJ. An in vitro study of needle force penetration comparing a standard linear insertion to the new bidirectional rotation insertion technique. *Quintessence Int.* 2001;32:789–796.
- Aboushala A, Kugel G, Efthimiadis N, Krochak M. *Efficacy of a Computer-Controlled Injection System of Local Anesthesia In Vivo* [abstract 2775]. IADR Annual Meeting; 2000.
- Cook-Waite Laboratories Inc. *Manual of Local Anesthesia in General Dentistry.* New York: Rensselaer & Springville; 1936:38.
- Monheim L. *Local Anesthesia and Pain Control in Dental Practice.* St Louis: CV Mosby; 1957:184.
- Allen GD. *Dental Anesthesia and Analgesia (Local and General).* 2nd ed. Baltimore: Williams & Wilkins; 1979:133.

28. Yagiela JA, Jastack JT. *Regional Anesthesia of the Oral Cavity*. St Louis: CV Mosby; 1981:105.
29. Malamed SF, Dill S. In: *Handbook of Local Anesthesia*, 1st ed. St Louis: CV Mosby; 1980:68.
30. Davies RJ. Buffering the pain of local anesthetics: a systematic review. *Emerg Med (Fremantle)*. 2003;15(1):81–88.
31. Farsakinan LR, Weine FS. The significance of needle gauge in dental injections. *Compend Contin Educ Dent*. 1991;12:262–268.
32. Tuttle G. Objections defended. Available at: <http://www.tuttlenumnow.com/objections-defended>. Accessed February 15, 2018.

The Cartridge

The dental cartridge is a glass cylinder containing the local anesthetic drug, among other ingredients. In the United States and in many other countries, the glass cylinder itself can hold 2 mL of solution; however, as prepared today, the dental cartridge contains approximately 1.8 mL of local anesthetic solution. Local anesthetic cartridges list their volume as 1.7 mL (although in actuality they contain approximately 1.76 mL of local anesthetic solution).¹ In other countries, notably the United Kingdom, New Zealand, and Australia, the prefilled dental cartridge contains approximately 2.2 mL of local anesthetic solution; some countries, including France and Japan, have 1-mL dental cartridges (Fig. 7.1).

The dental local anesthetic cartridge is, by common usage, referred to by dental professionals as a *carpule*. *Carpule* is actually a registered trade name for the dental cartridge prepared by Cook-Waite Laboratories, which introduced it into dentistry in 1920. The patent was originally issued by the US Patent Office on August 4, 1925. The patent on the name *carpule* expired on May 6, 2006. *Carpules* no longer exist.

The following is a brief history of the dental anesthetic “carpule.”² Local anesthesia was introduced in 1905 with the synthesis of procaine hydrochloride by Alfred Einhorn (1856–1917) in Germany. The drug was supplied in powder form, so dentists had to mix up a new solution each time they needed it. This process was time-consuming and awkward in the battlefields of World War I. Unfortunately, stock solutions also deteriorated rapidly. Harvey S. Cook, an army surgeon from Indiana, solved this problem by inventing the carpule. He was inspired by the cartridges used in US Army rifles and made the first carpule syringe himself. He fabricated a brass syringe, which locked a double-pointed needle in place, cut the glass tubes, and used pencil erasers as rubber stoppers. Cook spent his evenings sterilizing the solutions and filling the carpules for the next day’s work. His invention revolutionized the delivery system for all types of medication, particularly local anesthesia in dentistry.^{3,4}

In recent years, local anesthetic manufacturers in some countries (but not as of yet in North America) have introduced a local anesthetic cartridge composed of plastic.⁵ Plastic cartridges have several negative features, primarily leakage of solution during injection, the requirement for

considerable force to be applied to the plunger of the syringe (e.g., periodontal ligament [PDL], nasopalatine),⁵ and the fact that the plunger does not “glide” down the plastic cartridge as smoothly as it does down the glass cartridge, leading to sudden spurts of administration of local anesthetic under increased pressure, which can produce pain in the patient. Another problem with plastic cartridges is that they are permeable to air. Exposure to oxygen leads to more rapid degradation of the vasoconstrictor in the cartridge and to a shorter shelf life.⁶

Components

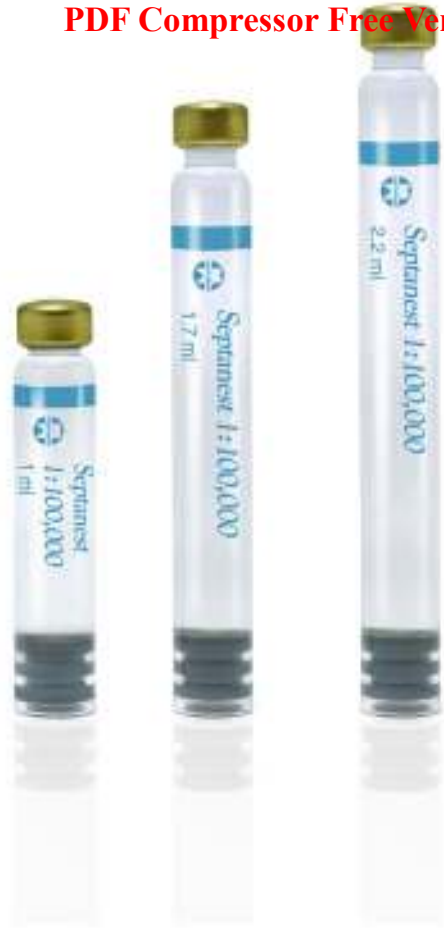The prefilled 1.8-mL dental cartridge consists of four parts (Fig. 7.2):

1. cylindrical glass tube
2. stopper (plunger, bung)
3. aluminum cap
4. diaphragm


The stopper (plunger, bung) is located at the end of the cartridge that receives the harpoon of the aspirating syringe. The sharp harpoon is embedded into the silicone (non-latex-containing) rubber plunger with gentle finger pressure applied to the thumb ring of the syringe. The plunger occupies a little less than 0.2 mL of the volume of the entire cartridge. Today, local anesthetic stoppers are treated with silicone, eliminating both the paraffin and the glycerin that were used in years past. “Sticky stoppers” (stoppers that do not move smoothly down the glass cartridge) are rare today. Recent years have seen a move toward the use of a uniform black rubber stopper in all local anesthetic drug combinations. Virtually gone are the color-coded red, green, and blue stoppers that aided in identification of the drug. When black stoppers are used, a color-coding band, required by the American Dental Association (ADA) since June 2003 for products to receive the ADA Seal of Approval, is found around the glass cartridge (Table 7.1).

In an intact dental cartridge, the stopper is slightly indented from the lip of the glass cylinder (Fig. 7.3). Cartridges whose plungers are flush with or extruded beyond the glass of the cylinder should not be used. This problem is discussed later in this chapter (see “Problems”).

PDF Compressor Free Version



• **Fig. 7.1** Cartridges with volumes of 1.0, 1.8- (1.7-), and 2.2-mL together.



• **Fig. 7.2** (A) Components of the glass dental local anesthetic cartridge. (B) Aluminum cap and latex-free diaphragm.

TABLE 7.1 Color-Coding of Local Anesthetic Cartridges as per the American Dental Association Council on Scientific Affairs

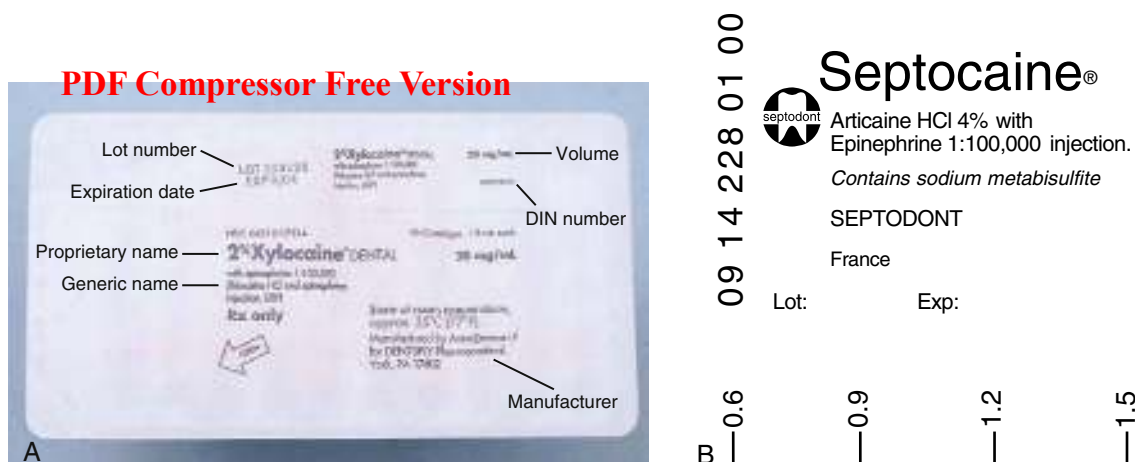
Local Anesthetic Solution	Color of Cartridge Band
4% articaine hydrochloride with epinephrine 1:100,000	Gold
0.5% bupivacaine with epinephrine 1:200,000	Blue
2% lidocaine hydrochloride	Light blue
2% lidocaine hydrochloride with epinephrine 1:50,000	Green
2% lidocaine hydrochloride with epinephrine 1:100,000	Red
3% mepivacaine hydrochloride	Tan
2% mepivacaine hydrochloride with levonordefrin 1:20,000	Brown
4% prilocaine hydrochloride	Blade
4% prilocaine hydrochloride with epinephrine 1:200,000	Yellow



• **Fig. 7.3** Silicone rubber plunger is slightly indented from the rim of the glass.

An aluminum cap is located at the opposite end of the cartridge from the rubber plunger. It fits snugly around the neck of the glass cartridge, holding the thin diaphragm in position. It is silver or gold colored on most cartridges.

The diaphragm is a semipermeable membrane through which the needle penetrates into the cartridge. When properly prepared, the perforation of the needle is centrally located and round, forming a tight seal around the needle. Improper preparation of the needle and cartridge can produce an eccentric puncture with an ovoid hole, which can lead to leakage of the anesthetic solution into the patient's mouth during injection. The diaphragm is a semipermeable membrane that allows any solution in which the dental cartridge is immersed to diffuse into the cartridge, thereby contaminating the local anesthetic solution.



• **Fig. 7.4** (A) Mylar plastic label. (B) Label with volume indicator. (Courtesy of Septodont, Inc, Lancaster, PA)

TABLE 7.2 Composition of Local Anesthetic Solution

Component	Function	“Plain” Local Anesthetic Solution	Vasopressor-Containing Local Anesthetic Solution
Local anesthetic drug (e.g., lidocaine hydrochloride)	Blockade of nerve conduction	•	•
Sodium chloride	Isotonicity of the solution	•	•
Sterile water	Volume	•	•
Vasopressor (e.g., epinephrine, levonordefrin)	Increases depth and duration of anesthesia; decreases absorption of local anesthetic and vasopressor		•
Sodium (meta)bisulfite	Antioxidant		•
Methylparaben ^a	Bacteriostatic agent		

^aMethylparaben is no longer included in single-use dental cartridges of local anesthetic; however, it is found in *all* multidose vials of injectable drugs.
^{*}Present in cartridge.

In the past, persons with latex allergy might have been at increased risk of an allergic reaction when a local anesthetic was administered through a glass cartridge.⁷ However, Shojaei and Haas⁸ stated that although the possibility of an allergic reaction precipitated by latex in the dental local anesthetic cartridge does exist, “there are no reports of studies or cases in which a documented allergy was due to the latex component of cartridges for dental anesthesia.”

In North America, all dental local anesthetic cartridges are now latex-free.

A thin Mylar plastic label applied to all cartridges (Fig. 7.4A) serves to (1) protect the patient and the administrator in the event that the glass cracks and (2) provide specifications about the enclosed drug. In addition, some manufacturers include a volume indicator on their labels, making it easier for the administrator to deposit precise volumes of anesthetic (see Fig. 7.4B).

Cartridge Contents

The composition of the solution found in the dental cartridge differs depending on whether a vasoconstrictor is included (Table 7.2).

The *local anesthetic drug* is the *raison d'être* for the entire dental cartridge. It interrupts the propagated nerve impulse, preventing it from reaching the brain. The drug contained within the cartridge is listed by its percent concentration. The number of milligrams of the local anesthetic drug can be calculated by multiplication of the percent concentration (e.g., 2% = 20 mg/mL) by the volume of fluid in the cartridge: 1.8 mL (United States) or 2.2 mL (United Kingdom). Thus a 1.8-mL cartridge of a 2% solution contains 36 mg (Table 7.3). The local anesthetic drug is stable and is capable of being autoclaved, heated, or boiled without

TABLE 7.3 Calculation of Milligrams per Cartridge

Percent Solution	=	Milligrams per Milliliter	×	Volume of Cartridge	=	Milligrams per Cartridge
0.5	=	5	×	1.8	=	9
1.0	=	10	×	1.8	=	18
2.0	=	20	×	1.8	=	36
3.0	=	30	×	1.8	=	54
4.0	=	40	×	1.8	=	72

breaking down. However, other components of the cartridge (e.g., vasoconstrictor drug, cartridge seals) are more labile and are easily destroyed.

A *vasoconstrictor drug* is included in most anesthetic cartridges to increase safety and the duration and depth of action of the local anesthetic. The pH of dental cartridges containing vasoconstrictors is lower (more acidic) than that of cartridges not containing vasoconstrictors, commonly in the range of 3.3 to 4.5 versus approximately 6.5 for non-vasoconstrictor-containing solutions. Because of this pH difference, plain local anesthetics have a somewhat more rapid onset of clinical action and are more comfortable (less “burning” on injection).⁹⁻¹¹

Cartridges containing a vasoconstrictor also contain an *antioxidant*, most often sodium (meta)bisulfite. Sodium bisulfite prevents oxidation of the vasoconstrictor by oxygen, which can be trapped in the cartridge during manufacture or can diffuse through the semipermeable diaphragm (or the walls of a plastic cartridge) after filling. Sodium bisulfite reacts with oxygen faster than the oxygen is able to destroy the vasoconstrictor. When oxidized, sodium bisulfite becomes sodium bisulfate, having an even lower pH. The clinical relevance of this lies in the fact that increased burning (discomfort) is experienced by the patient on injection of an “older” cartridge of anesthetic with vasoconstrictor compared with a fresher cartridge. Allergy to bisulfites must be considered in the medical evaluation of all patients before local anesthetic is administered (see [Chapter 10](#)).^{12,13}

Sodium chloride is added to the cartridge to make the solution isotonic with the tissues of the body. In the past, isolated instances were reported in which local anesthetic solutions containing too much sodium chloride (hypertonic solutions) produced tissue edema or paresthesia, sometimes lasting for several months, after drug administration.¹⁴ This is no longer a problem.

Distilled water is used as a diluent to provide the volume of solution in the cartridge.

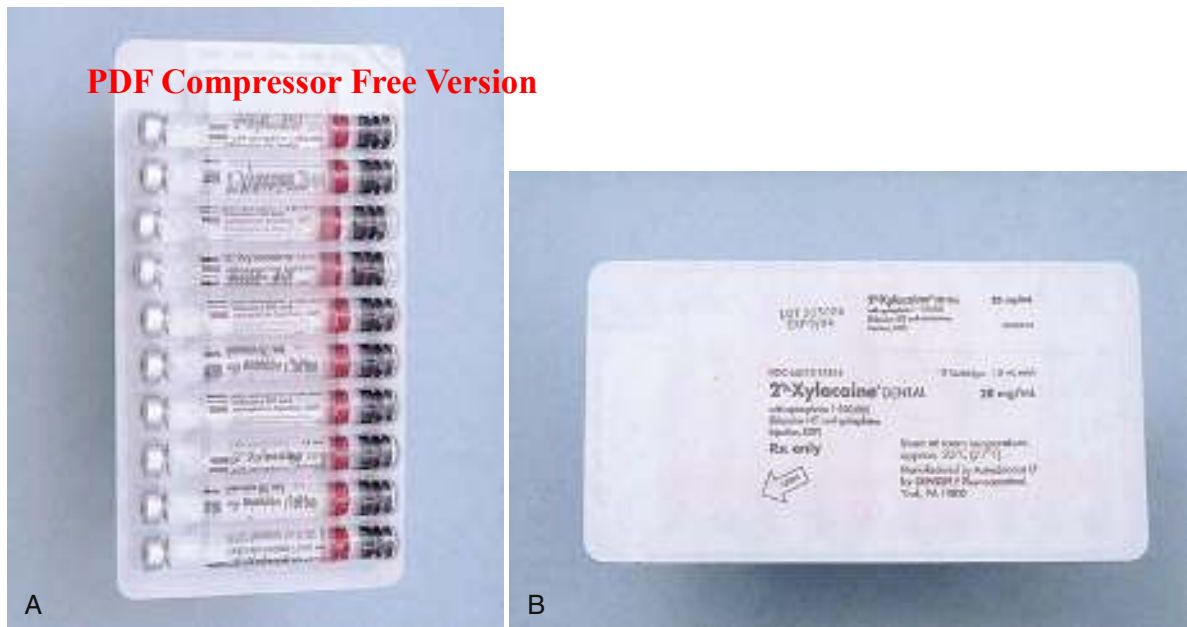
A significant change in cartridge composition in the United States and in many other countries was the removal of *methylparaben*, a bacteriostatic agent. A ruling by the Food and Drug Administration mandated the removal of methylparaben from dental local anesthetic cartridges manufactured after January 1, 1984.¹⁵ Methylparaben

possesses bacteriostatic, fungistatic, and antioxidant properties. It and related compounds (ethylparaben, propylparaben, and butylparaben) are commonly used as preservatives in ointments, creams, lotions, and dentifrices. In addition, paraben preservatives are found in all multiple-dose vials of drugs. Methylparaben is commonly used in a 0.1% concentration (1 mg/mL). Its removal from local anesthetic cartridges was predicated on two facts. First, dental local anesthetic cartridges are single-use items meant to be discarded and not reused. Therefore inclusion of a bacteriostatic agent is unwarranted. Second, repeated exposure to paraben has led to reports of increased allergic reactions in some persons.^{16,17} Responses have been limited to localized edema, pruritus, and urticaria. Fortunately, to date there has not been a systemic allergic reaction to a paraben. Removal of methylparaben has further decreased an already minimal risk of allergy to local anesthetic drugs.

Care and Handling

Local anesthetics are marketed in blister packs of (usually) five packs of 10 cartridges each ([Fig. 7.5](#)). In some countries local anesthetics are still available in tins of 50 cartridges. Although no manufacturer makes any claim of sterility about the exterior surface of the cartridge, bacterial cultures taken immediately on opening a container usually fail to produce any growth. Therefore it seems obvious that extraordinary measures related to cartridge sterilization are unwarranted. Indeed, the glass dental cartridge should not be autoclaved. The seals on the cartridge cannot withstand the extreme temperatures of autoclaving, and the heat-labile vasoconstrictors are destroyed in the process. Plastic cartridges cannot be autoclaved.

Local anesthetic cartridges should be stored in their original container, preferably at room temperature (e.g., 21°C to 22°C), and in a dark place. There is no need to “prepare” a cartridge before it is used: the doctor, dental hygienist, or assistant simply inserts it into the syringe. However, some doctors feel compelled to somehow “sterilize” the cartridge. When this urge strikes, the doctor should apply an alcohol wipe moistened with undiluted 91% isopropyl alcohol or 70% ethyl alcohol to the rubber diaphragm ([Fig. 7.6](#)).



• **Fig. 7.5** (A) Ten local anesthetic cartridges are contained in a sealed blister pack. (B) The back of the blister pack contains information about the drug. (Courtesy Dentsply Sirona.)



• **Fig. 7.6** Preparing local anesthetic cartridge for use by wiping the rubber diaphragm with alcohol.

If a clear plastic cartridge dispenser is used, 1 day's supply of cartridges should be placed with the aluminum cap and diaphragm facing downward (Fig. 7.7). Several (two or three) sterile dry 2- × 2-inch gauze wipes are placed in the center of the dispenser and are moistened with (not immersed in) 91% isopropyl alcohol or 70% ethyl alcohol. No liquid alcohol should be present around the cartridges. Before the syringe is loaded, the aluminum cap and the rubber diaphragm are rubbed against the moistened gauze.

Cartridges should not be permitted to soak in alcohol or other sterilizing solutions because the semipermeable diaphragm allows diffusion of these solutions into the dental cartridge, thereby contaminating it.¹⁸ It is recommended that local anesthetic cartridges be kept in their original container until they are to be used.

Cartridge warmers are unnecessary; occasionally they may produce problems. Overheating the local anesthetic solution can lead to (1) discomfort for the patient during injection and (2) the more rapid degradation of a heat-labile vasoconstrictor (producing a shorter duration




• **Fig. 7.7** Dental local anesthetic cartridge dispenser.

of anesthesia with more burning on injection). It has been demonstrated that after the warmed glass cartridge is removed from the cartridge warmer and is placed in a metal syringe with the solution forced through a fine metal needle, its temperature has decreased almost to room temperature.^{6,9,19,20}

Cartridge warmers, designed to maintain anesthetic solutions at “body temperature,” are not needed and cannot be recommended. Local anesthetics in cartridges maintained at room temperature (20°C to 22°C) do not cause the patient any discomfort on injection into tissues, nor do patients complain of the solution being too cold.²⁰ On the other

PDF Compressor Free Version

**WARNINGS**

DENTAL PRACTITIONERS WHO EMPLOY LOCAL ANESTHETICS IN THEIR OFFICES SHOULD BE WELL VERSED IN DIAGNOSIS AND MANAGEMENT OF EMERGENCIES WHICH MIGHT ARISE FROM THEIR USE. RESUSCITATIVE EQUIPMENT, OXYGEN, AND OTHER RESUSCITATIVE DRUGS SHOULD BE AVAILABLE FOR IMMEDIATE USE.

Reactions resulting in fatality have occurred on rare occasions with the use of local anesthetics, even in the absence of a history of hypersensitivity.

Fig. 7.8 (A) All local anesthetic containers have a product identification package insert, which should be read. (Courtesy of Septodont, Inc, Lancaster, PA) (B) Important information is contained in all package inserts. (Courtesy Dentsply Sirona.)

hand, warmed local anesthetic solutions at 27°C or above have a much greater incidence of being described as too hot or burning on injection.¹⁹

Local anesthetic cartridges should not be left exposed to direct sunlight because some contents may undergo accelerated deterioration. The primary clinical effect of this will be destruction (oxidation) of the vasoconstrictor, with a corresponding (minimal) decrease in the duration of clinical action of the anesthetic solution, along with increased discomfort for the patient, a result of the increase in acidity of the solution as the vasoconstrictor is oxidized.

Included in every package of local anesthetic is an important document: the drug package insert. It contains valuable information about the local anesthetic solution such as dosages, warnings, precautions, and care and handling instructions. All persons involved in the handling or administration of local anesthetics should review this document periodically (Fig. 7.8).

Problems

Occasionally problems develop with cartridges of dental local anesthetics. Although most are minor, producing minor inconvenience to the drug administrator, others are more significant and might prove harmful to the patient:

1. bubble in the cartridge
2. extruded stopper
3. burning on injection
4. sticky stopper
5. corroded cap

6. “rust” on the cap
7. leakage during injection
8. broken cartridge

Bubble in the Cartridge

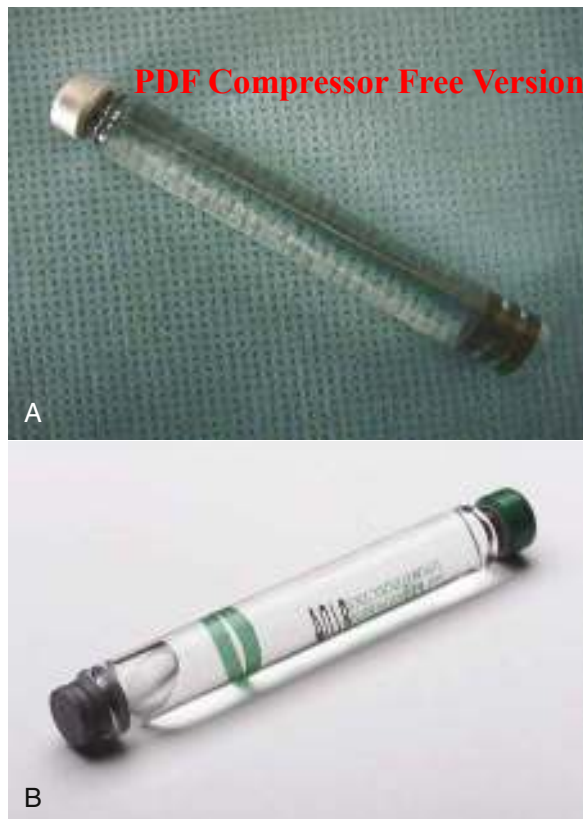
A small bubble of approximately 1- to 2-mm diameter (described as “BB” sized) is frequently found in the dental cartridge. It is composed of nitrogen gas, which is bubbled into the local anesthetic solution during the cartridge-filling process to prevent oxygen from being trapped inside the cartridge, potentially destroying the vasoconstrictor. The nitrogen bubble may not always be visible in a normal cartridge (Fig. 7.9A).

A larger bubble, which may be visible with a plunger that is extruded beyond the rim of the cartridge, is the result of the anesthetic solution being frozen (see Fig. 7.9B). Such cartridges should not be used, since sterility of the solution can no longer be assured. Instead, these cartridges should be returned to their manufacturer for replacement.

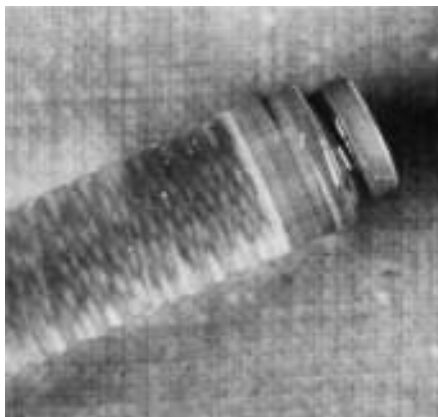Extruded Stopper

The stopper can become extruded when a cartridge is frozen and the liquid inside expands. In this case, the solution can no longer be considered sterile and should not be used for injection. Frozen cartridges can be identified by the presence of a large (>2 mm) bubble, along with an extruded stopper.

An extruded stopper with no bubble is indicative of prolonged storage in a chemical disinfecting



• **Fig. 7.9** (A) Normal cartridge with no bubble or a small BB-sized bubble. Note that the rubber stopper is indented from the glass rim. (B) Local anesthetic cartridge with an extruded stopper and a large bubble caused by freezing.



• **Fig. 7.10** Extruded plunger on local anesthetic cartridge.

solution and diffusion of the solution into the cartridge (Fig. 7.10). Shannon and Wescott²¹ demonstrated that alcohol enters a cartridge through the diaphragm in measurable amounts within 1 day if the diaphragm is immersed in alcohol. Local anesthetic solutions containing alcohol produce an uncomfortable burning on injection. Alcohol in sufficiently high concentration is a neurolytic agent capable of producing long-term paresthesia. The greatest concentration of alcohol reported to date in a dental cartridge is 8%, which is not likely to produce significant long-term nerve injury.

Antirust tablets should not be used in disinfectant solutions. The sodium nitrate (or similar agent) that they contain is capable of releasing metal ions, which have been related to an increased incidence of edema after local anesthetic administration.²³

It should be remembered that small quantities of sterilizing solution can diffuse into a dental cartridge with no visible displacement of the plunger. Care must always be taken in storage of local anesthetic cartridges.

Burning on Injection

A burning sensation on injection of anesthetic solution may be the result of one of the following:

1. normal response to the acidic pH of the drug
2. cartridge containing sterilizing solution
3. overheated cartridge
4. cartridge containing a vasoconstrictor

During the few seconds immediately after deposition of a local anesthetic solution, the patient may complain of a slight sensation of burning. This very normal response is caused by the pH of the local anesthetic solution; it lasts but a second or two, until the anesthetic takes effect, and is noted mainly by sensitive patients when they are receiving local anesthetics containing epinephrine or levonordefrin (pH usually between 3.3 and 4.5).

A more intense burning experienced by the patient on injection is usually the result of the diffusion of disinfecting solution into the dental cartridge and its subsequent injection into oral mucous membranes. Although burning most often is a mere annoyance, the inclusion of disinfecting agents such as alcohol in dental cartridges can lead to more serious sequelae, such as postinjection paresthesia and tissue edema.²¹

Overheating of the solution in a cartridge warmer may produce burning on injection. The (Christmas tree) bulb-type cartridge warmer is most often at fault in this regard. Unless local anesthetic cartridges are unusually cold, there is little justification for use of a cartridge warmer. Local anesthetic solutions injected at room temperature are well tolerated by tissues and patients.^{6,19,20}

Use of a vasoconstrictor-containing local anesthetic solution may be responsible for the sensation of burning on injection. The addition of a vasoconstrictor and an antioxidant (sodium bisulfite) lowers the pH of the solution to approximately 3.3 to 4.5, making it significantly more acidic than solutions not containing a vasoconstrictor (pH about 6.5).^{9-11,22} Patients are more likely to feel the burning sensation with these solutions. A further decrease in the pH of the local anesthetic solution results as sodium bisulfite is oxidized to sodium bisulfate. This response can be minimized by careful checking of the expiration date on all cartridges before use. Conversely, increasing the pH of the anesthetic solution has the effect of making local anesthetic administration considerably more comfortable for the patient.²²⁻²⁶

Sticky Stopper

The “sticky stopper” is caused by the use of silicone as a lubricant and the removal of paraffin as a sealant in the cartridge. In cases where paraffin is still used, difficulty in advancing the stopper may occur because the paraffin hardens on colder days (below 16° C). Use of cartridges at room temperature minimizes this problem; use of silicone-coated stoppers eliminates it. Plastic cartridges are associated with this problem to a greater degree than glass cartridges.

Corroded Cap

The aluminum cap on a local anesthetic cartridge can be corroded if it is immersed in disinfecting solutions that contain quaternary ammonium salts, such as benzalkonium chloride (e.g., “cold” sterilizing solution). These salts are electrolytically incompatible with aluminum. Aluminum-sealed cartridges may be disinfected in 91% isopropyl alcohol or 70% ethyl alcohol. Cartridges with corroded caps must not be used. Corrosion may be easily distinguished from rust, which appears as a red deposit on an intact aluminum cap.

Rust on the Cap

Rust found on a cartridge indicates that at least one cartridge in the tin container has broken or leaked. The “tin” container (actually steel dipped in molten tin) rusts, and the deposit comes off on the cartridges. Cartridges containing rust should not be used. If any cartridge contains a dented cap, or a visible crack, all cartridges in the container must be carefully checked before use. With the introduction of nonmetal packaging (e.g., blister packs), rust is rarely seen anymore.

Leakage During Injection

Leakage of local anesthetic solution into the patient’s mouth during injection occurs if the cartridge and the needle are prepared improperly and the needle puncture of the diaphragm is ovoid and eccentric. Properly placed on the syringe after the cartridge is inserted, the needle produces a centric, round perforation of the diaphragm, which tightly seals itself around the needle. When pressure is applied to the plunger during injection, all of the solution is directed into the lumen of the needle. If the cartridge is placed in a breech-loading syringe *after* the needle has been attached, an eccentric ovoid perforation may occur. With pressure on the plunger, some solution is directed into the lumen of the needle, whereas some may leak out of the cartridge between the needle and the diaphragm and leak into the patient’s mouth (see Fig. 5.19). When a safety syringe is used, it is necessary to insert the cartridge after the needle has been attached; however, because the cartridge slides directly into the syringe, not from the side, leakage during injection is rarely a problem. Verbal and written communications from



• **Fig. 7.11** Local anesthetic cartridge with damaged cap. The glass around the neck of the cartridge should be examined carefully for cracks.

doctors using plastic cartridges indicate that the occurrence of leakage appears to be considerably greater when they are used.

The plastic dental cartridge does not withstand the application of injection pressure as well as the traditional glass cartridge. Meechan et al.⁵ applied pressures equal to those achieved during PDL injection with both glass and plastic local anesthetic cartridges. Leakage of anesthetic occurred in 1.4% of glass cartridges, whereas leakage was noted in 75.1% of plastic cartridges.

Broken Cartridge

The most common cause of cartridge breakage is the use of a cartridge that was cracked or chipped during shipping. Dented metal containers and damaged boxes should be returned to the supplier immediately for exchange. If a broken cartridge is found in a container, all remaining cartridges must be examined for hairline cracks or chips. Two areas that must be examined carefully are the thin neck of the cartridge where it joins the cap (see Fig. 7.11) and the glass surrounding the plunger. Subjecting a cracked cartridge to the pressure of injection often causes the cartridge to shatter or “explode.” If this occurs inside the patient’s mouth, serious sequelae may result from ingestion of glass. It is essential to suction the patient’s mouth thoroughly and consult with a physician or emergency department staff about follow-up therapy before this patient is discharged. The addition of a thin Mylar plastic label to the glass cartridge minimizes such injury. Additionally, if the aluminum “cap” on the cartridge is damaged, the cartridge should not be used, because the underlying glass may have been damaged as well (see Fig. 7.11).

Plastic cartridges do not fracture when subjected to PDL injection pressures.¹

Excessive force used to engage the aspirating harpoon in the stopper has resulted in numerous cases of shattered cartridges (see Fig. 7.12). Although they have not broken in the



• **Fig. 7.12** Cracked glass on dental cartridge.



• **Fig. 7.13** If force is necessary to embed the harpoon in the rubber plunger, the glass face of the syringe should be covered with the hand.

patient's mouth, injury to dental personnel has been reported. Hitting the thumb ring of the syringe in an attempt to engage the harpoon in the rubber stopper should be avoided. If this technique is essential to embed the harpoon in the rubber plunger (as it is with the plastic safety syringe), one hand should be used to cover the entire exposed glass face of the cartridge (Fig. 7.13). Proper preparation of the armamentarium (see Chapter 9) minimizes this risk.

Breakage can also occur as a result of attempting to use a cartridge with an extruded plunger. Extruded plungers can be forced back into the cartridge only with difficulty, if at all. Cartridges with extruded plungers should not be used.

Syringes with bent harpoons may cause cartridges to break (see Fig. 5.21). Bent needles that are no longer patent create a pressure buildup within the cartridge during attempted injection (see Fig. 5.20). No attempt should be made to force local anesthetic solution from a dental cartridge against significant resistance.

Recommendations

1. Dental cartridges are single-use items that must never be used on more than one patient.
2. Cartridges should be stored at room temperature.
3. It is not necessary to warm cartridges before use.
4. Cartridges should not be used beyond their expiration date.
5. Cartridges should be checked carefully for cracks, chips, and the integrity of the stopper and cap before use.

References

1. Haase A, Reader A, Nusstein J, Beck M, Drum M. Comparing anesthetic efficacy of articaine versus lidocaine as a supplemental buccal infiltration of the mandibular first molar after an inferior alveolar nerve block. *J Am Dent Assoc.* 2008;139:1228–1235.
2. Hyson JM Jr, Whitehorne JWA, Greenwood JT. *A history of dentistry in the US Army to World War II.* Washington, DC: Office of The Surgeon General at TMM Publications; 2008:508–509.
3. Asbell MB. *Dentistry: A Historical Perspective.* Bryn Mawr: Dorrance & Co; 1988:178.
4. Lufkin AW. *A History of Dentistry.* Philadelphia: Lea & Febiger; 1948:346–347.
5. Meechan JG, McCabe JF, Carrick TE. Plastic dental anaesthetic cartridges: a laboratory investigation. *Br Dent J.* 1990;169:254–256.
6. Meechan JG, Donaldson D, Kotlicki A. The effect of storage temperature on the resistance to failure of dental local anesthetic cartridges. *J Can Dent Assoc.* 1995;61:143–144.
7. Sussman GL, Beezhold DH. Allergy to latex rubber. *Ann Intern Med.* 1995;122(1):43–46.
8. Shojaei AR, Haas DA. Local anesthetic cartridges and latex allergy: a literature review. *J Can Dent Assoc.* 2002;68(10):622–626.
9. Jeske AH, Blanton PL. Misconceptions involving dental local anesthesia. Part 2, pharmacology. *Tex Dent J.* 2002;119(4):310–314.
10. Wahl MJ, Schmitt MM, Overton DA, Gordon MK. Injection of bupivacaine with epinephrine vs. prilocaine plain. *J Am Dent Assoc.* 2002;133(12):1652–1656.
11. Wahl MJ, Overton DA, Howell J, et al. Pain on injection of prilocaine plain vs. lidocaine with epinephrine: a prospective double-blind study. *J Am Dent Assoc.* 2001;132(10):1396–1401.
12. Seng GF, Gay BJ. Dangers of sulfites in dental local anesthetic solutions: warning and recommendations. *J Am Dent Assoc.* 1986;113:769–770.
13. Perusse R, Goulet JP, Turcotte JY. Contraindications to vasoconstrictors in dentistry. Part II. Hyperthyroidism, diabetes, sulfite sensitivity, cortico-dependent asthma, and pheochromocytoma. *Oral Surg.* 1992;74(5):687–691.
14. Nickel AA. Paresthesia resulting from local anesthetics. *J Oral Maxillofac Surg.* 1984;42(5):279.
15. Cleveland Clinic, Center for Continuing Education. *Pharmacotherapy Update. Allergic Reactions. Did You Know. Volume IV, Number 1.* January/February 2001. <http://www.clevelandclinicmeded.com/medicalpubs/pharmacy/JanFeb2001/allergicreaction.htm>. Accessed 11 November 2018 Accessed February 20, 2018.
16. Wurbach G, Schubert H, Pillipp I. Contact allergy to benzyl alcohol and benzyl paraben. *Contact Dermatitis.* 1993;28(3):187–188.
17. Klein CE, Gall H. Type IV allergy to amide-type anesthetics. *Contact Dermatitis.* 1991;25(1):45–48.
18. Meechan JG, McCabe JF. Effect of different storage methods on the performance of dental local anaesthetic cartridges. *J Dent.* 1992;29:38–43.

19. Volk RJ, Gargiulo AV. Local anesthetic cartridge warmer—first in, first out fresh. *Ill Dent J*. 1984;53(2):92–94.
20. Rogers KB, Furling AF, Markiewicz SW. The effect of warming local anesthetic solutions prior to injection. *Gen Dent*. 1989;37(6):496–499.
21. Shannon IL, Wescott WB. Alcohol contamination of local anesthetic cartridges. *J Acad Gen Dent*. 1974;22:20–21.
22. Moorthy AP, Moorthy SP, O’Neil R. A study of pH of dental local anesthetic solutions. *Br Dent J*. 1984;157(11):394–395.
23. Crose VW. Pain reduction in local anesthetic administration through pH buffering. *J Indiana Dent Assoc*. 1991;70(2):24–25.
24. Hanna MN, Elhassan A, Veloso PM, et al. Efficacy of bicarbonate in decreasing pain on intradermal injection of local anesthetics: a meta-analysis. *Reg Anesth Pain Med*. 2009;34:122–125.
25. Malamed SF, Falkel M. Buffered local anesthetics: the importance of pH and CO₂. *SAAD Dig*. 2013;29:9–17.
26. Malamed SF, Hersh E, Poorsattar S, Falkel M. Faster onset and more comfortable injection with alkalinized 2% lidocaine with epinephrine 1:100,000. *Compend Contin Educ Dent*. 2013;34(Spec No 1):1–11.



Additional Armamentarium

The three major components of the local anesthetic armamentarium—syringe, needle, and cartridge—were discussed in [Chapters 5, 6, and 7](#). Other important items are found in the local anesthetic armamentarium, however, including:

1. topical antiseptic
2. topical anesthetic
3. applicator sticks
4. cotton gauze (2 × 2 inches)
5. hemostat
6. needle-recapping device

Topical Antiseptic

A topical antiseptic may be used to prepare the tissues at the injection site before the initial needle penetration. Its function is to produce a transient decrease in the bacterial population at the injection site, thereby minimizing any risk of postinjection infection.

The topical antiseptic, on an applicator stick, is placed at the site of injection for 15 to 30 seconds. There is no need to place a large quantity on the applicator stick; it should be sufficient just to moisten the cotton portion of the swab.

Available agents include povidone-iodine (Betadine) and thimerosal (Merthiolate). Topical antiseptics containing alcohol (e.g., tincture of iodine, tincture of thimerosal) should not be used because the alcohol produces tissue irritation. In addition, allergy to iodine-containing compounds is common.^{1,2} Before any iodine-containing topical antiseptic is applied to tissues, the patient should be questioned to determine whether adverse reactions to iodine have previously developed.

In a survey of local anesthetic techniques in dental practice,³ 7.9% of dentists mentioned that they always used topical antiseptics before injection, 22.4% sometimes used them, and 69.7% never used them.

Postinjection infections, although extremely rare in dentistry, can and do occur. The routine use of a topical antiseptic can virtually eliminate them. If a topical antiseptic is not available, a sterile gauze wipe should be used to prepare the tissues adequately before injection.

Application of a topical antiseptic is considered an optional step in tissue preparation before intraoral injection.

Topical Anesthetic

Topical anesthetic preparations are discussed in depth in [Chapter 4](#). Their use before initial needle penetration of the mucous membrane is strongly recommended. With proper application, initial penetration of mucous membrane anywhere in the oral cavity can usually be made without the patient's awareness.

For effectiveness, it is recommended that a minimal quantity of topical anesthetic be applied to the end of the applicator stick and placed directly at the site of needle penetration for at least 1 minute, preferably 2 minutes. Gill and Orr⁴ have demonstrated that when topical anesthetics are applied according to the manufacturer's instructions (approximately 10 to 15 seconds), their effectiveness is no greater than that of a placebo, especially for palatal injections. Stern and Giddon⁵ showed that application of a topical anesthetic to mucous membrane for 2 to 3 minutes leads to profound soft tissue analgesia.

A variety of topical anesthetic agents are available for use today. Most contain the ester anesthetic benzocaine. The likelihood of occurrence of allergic reactions to esters, although minimal, is still greater than that to amide topical anesthetics; however, because benzocaine is not absorbed systemically, allergic reactions—when they occur—are normally localized to the site of application. Of the amides, only lidocaine possesses topical anesthetic activity in clinically acceptable concentrations. The risk of overdose with amide topical anesthetics is greater than that with the esters and increases with the area of application of the topical anesthetic. Deaths have occurred from topical local anesthetic overdose in nondental settings when topical local anesthetic is applied over large areas of the body before cosmetic procedures such as tattoos and tattoo removal, dermabrasion, and laser hair removal to minimize pain.^{6,7} On January 16, 2009, the Food and Drug Administration issued a Public Health Advisory alerting consumers that these “skin numbing” creams can cause life-threatening side effects, including irregular heartbeats, seizures, and death.⁸

Topical forms of lidocaine are available as ointments, gels, pastes, and sprays.

EMLA (eutectic mixture of local anesthetics) is a combination of lidocaine and prilocaine in a topical cream



• Fig. 8.1 Disposable nozzle for topical anesthetic spray.

formulation designed to provide surface anesthesia of intact skin. Its primary indications are for use before venipuncture and in pediatric surgical procedures, such as circumcision.^{9,10} EMLA has been used effectively intraorally; however, it is not designed for intraoral administration, so it contains no flavoring agent and is bitter tasting.^{11,12} The dental form of EMLA, Oraqix, is used in lieu of injectable local anesthetics in soft tissue procedures, such as curettage.^{13,14}

Unmetered sprays of topical anesthetics are potentially dangerous and are not recommended for routine use. Because topical anesthetics require greater concentration to penetrate mucous membranes, and because most topical anesthetics are absorbed rapidly into the cardiovascular system, only small measured doses should be administered. Topical anesthetic sprays that deliver a continuous stream of topical anesthetic until being deactivated are capable of delivering overly high doses of the topical anesthetic. If this is absorbed into the cardiovascular system, the resulting anesthetic blood level may approach overdose levels. Metered sprays that deliver a fixed dose with each administration, regardless of the length of time the nozzle is depressed, are preferred for topical formulations that are absorbed systemically. An example of this form of topical anesthetic spray is Xylocaine spray, which delivers 10 mg per administration.

Yet another potential problem with topical anesthetic sprays is difficulty keeping the spray nozzle sterile. This is a very important consideration when the form of topical anesthetic to be used is selected. Most topical anesthetic sprays today come with disposable applicator nozzles (Fig. 8.1).

It must be remembered that some topical anesthetic formulations contain preservatives, such as methylparaben, and other ingredients that may be significant in instances of allergy to local anesthetics.



• Fig. 8.2 Cotton-tipped applicator sticks.

Applicator Sticks

Applicator sticks should be available as part of the local anesthetic armamentarium. They are wooden sticks with a cotton swab at one end. They can be used to apply topical antiseptic and anesthetic solutions to mucous membranes (Fig. 8.2) and compress tissue during palatal injections.

Cotton Gauze

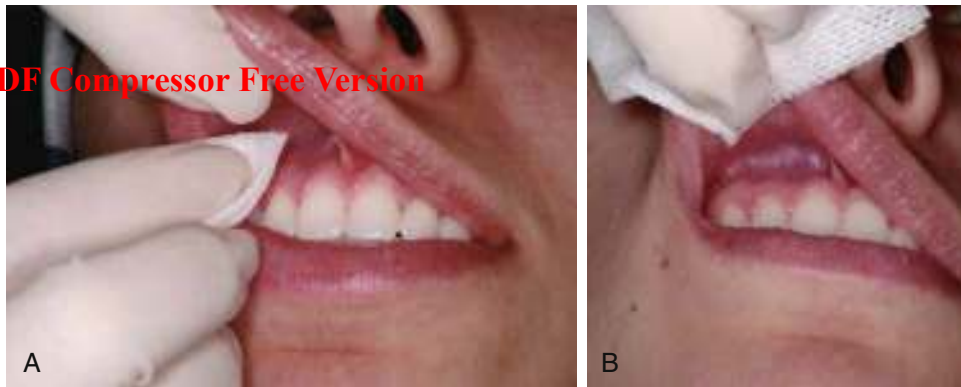
Cotton gauze is included in the local anesthetic armamentarium for (1) wiping the area of injection before needle penetration and (2) drying the mucous membrane to aid in soft tissue retraction for increased visibility.

Many dentists select gauze in lieu of topical antiseptic solution for cleansing the soft tissue at the site of needle penetration. Gauze effectively dries the injection site and removes any gross debris from the area (Fig. 8.3). It is not as effective as the topical antiseptic but is an acceptable substitute.

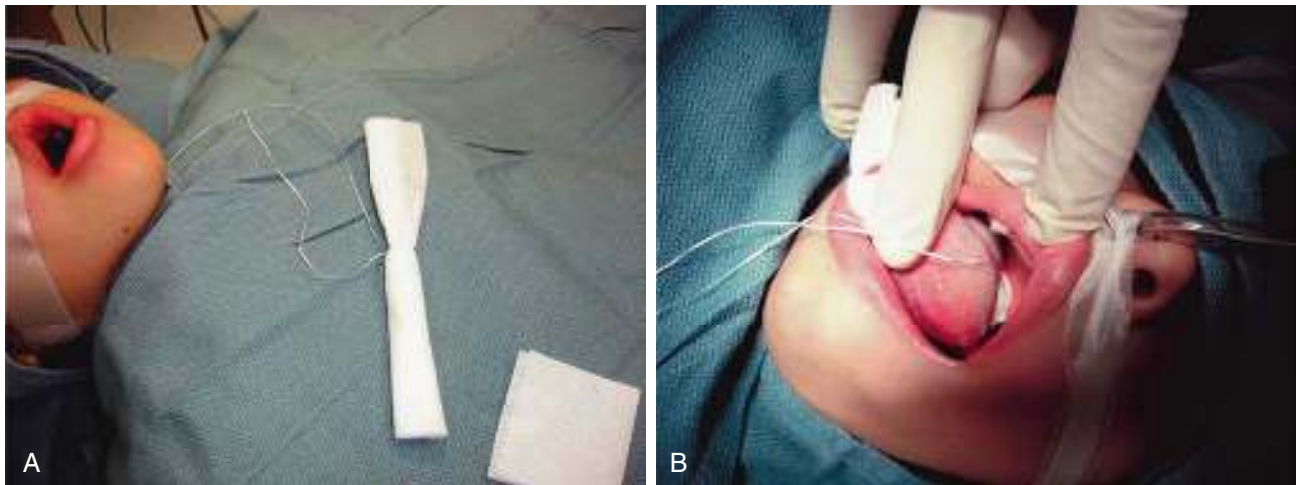
Retraction of lips and cheeks for improved access to, and visibility of, the injection site is important during all intraoral injections. Often this task becomes unnecessarily difficult if these tissues are moist, made even more vexing by the wearing of gloves. Dry cotton gauze makes the tissues easier to grasp and to retract.

A variety of sizes of cotton gauze are available for tissue retraction, but the most practical and the most commonly used is the 2- × 2-inch size. When gauze is placed intraorally to stop bleeding, 2- × 2-inch squares should not be used. Larger, 4- × 4-inch gauze squares are much preferred as they minimize the risk of aspiration of the gauze into the posterior pharynx leading to airway obstruction.^{15,16} Additionally, whenever gauze is placed

PDF Compressor Free Version



• **Fig. 8.3** Sterile gauze is used (A) to wipe the mucous membrane at the site of needle penetration and (B) to aid in tissue retraction if necessary.



• **Fig. 8.4** Floss tied around a gauze square aids easy retrieval.

into and left in the mouth for a period of time, a length of dental floss should be tied around it, so that, if necessary, the gauze may be removed or retrieved from the mouth quickly (Fig. 8.4).

Hemostat

Although not considered an essential element of the local anesthetic armamentarium, a hemostat or pickup forceps should be readily available at all times, chairside, in the dental office. Its primary function in local anesthesia is removal of a needle from the soft tissues of the mouth in the highly unlikely event that the needle breaks off within tissues (Fig. 8.5).

Needle-Recapping Device

Needlestick injuries, although rare, do happen. Most needlestick injuries in the dental profession occur after the injection



• **Fig. 8.5** Hemostat.

has been completed and the administrator of the local anesthetic seeks to recap the needle. Dentistry remains one of the very few health care professions in which a needle may be reused for multiple injections. Although safety syringes (see Chapter 5) are available, their adoption by dentists worldwide has been extremely slow. A needle-recapping device should be available in every room in which injections are administered. (Fig. 8.6)

PDF Compressor Free Version



• Fig. 8.6 Needle-recapping device.

References

1. Bennasar S, Magnier S, Hassan M, et al. Anaphylactic shock and low osmolarity contrast medium. *Arch Pediatr.* 1994;1:155–157.
2. Palobart C, Cros J, Orsel I, et al. Anaphylactic shock to iodinated povidone. *Ann Fr Anesth Reanim.* 2009;28:168–170.
3. Malamed SF. *Handbook of Local Anesthesia.* 1st ed. St Louis: Mosby; 1980.
4. Gill CJ, Orr II DL. A double blind crossover comparison of topical anesthetics. *J Am Dent Assoc.* 1979;98:213–214.
5. Stern I, Giddon DB. Topical anesthesia for periodontal procedures. *Anesth Prog.* 1975;22:105–108.
6. Alster T. Review of lidocaine/tetracaine cream as a topical anesthetic for dermatologic laser procedures. *Pain Ther.* 2013;2:11–19.
7. Berkman S, MacGregor J, Alster T. Adverse effects of topical anesthetics for dermatologic procedures. *Expert Opin Drug Saf.* 2012;11:415–423.
8. FDA issues public health advisory alert of skin numbing products. 19 January 2009. www.ohsonline.com. Accessed 13 November 2018.
9. Fetzer SJ. Reducing venipuncture and intravenous insertion pain with eutectic mixture of local anesthetic: a meta-analysis. *Nurs Res.* 2002;51:119–124.
10. Taddio A. Pain management for neonatal circumcision. *Paediatr Drugs.* 2001;3:101–111.
11. Bernardi M, Secco F, Beneci A. Anesthetic efficacy of a eutectic mixture of lidocaine and prilocaine (EMLA) on the oral mucosa: prospective double-blind study with a placebo. *Minerva Stomatol.* 1999;48:39–43.
12. Munshi AK, Hegde AM, Latha R. Use of EMLA: is it an injection free alternative? *J Clin Pediatr Dent.* 2001;25:215–219.
13. Magnusson I, Jeffcoat MK, Donaldson D, Otterbom IL, Henriksson J. Quantification and analysis of pain in nonsurgical scaling and/or root planning. *J Am Dent Assoc.* 2004;135:1747–1754.
14. Donaldson D, Gelskey SC, Landry RG, Matthews DC, Sandhu HS. A placebo-controlled multi-centered evaluation of an anesthetic gel (Oraqix) for periodontal therapy. *J Clin Periodontol.* 2003;30:171–175.
15. Chen S. *San Diego man dies while getting wisdom teeth pulled.* San Diego: Fox 5; 2013. <http://fox5sandiego.com/2013/04/01/san-diego-man-dies-while-getting-wisdom-teeth-pulled>. Accessed 13 November 2018.
16. Patton-Bey S. Utah college student dies during dentist visit after choking on gauze. *New York Daily News.* October 26, 2016. <http://www.nydailynews.com/news/national/utah-college-student-chokes-gauze-dies-visit-dentist-article-1.2846133>. Accessed 13 November 2018.

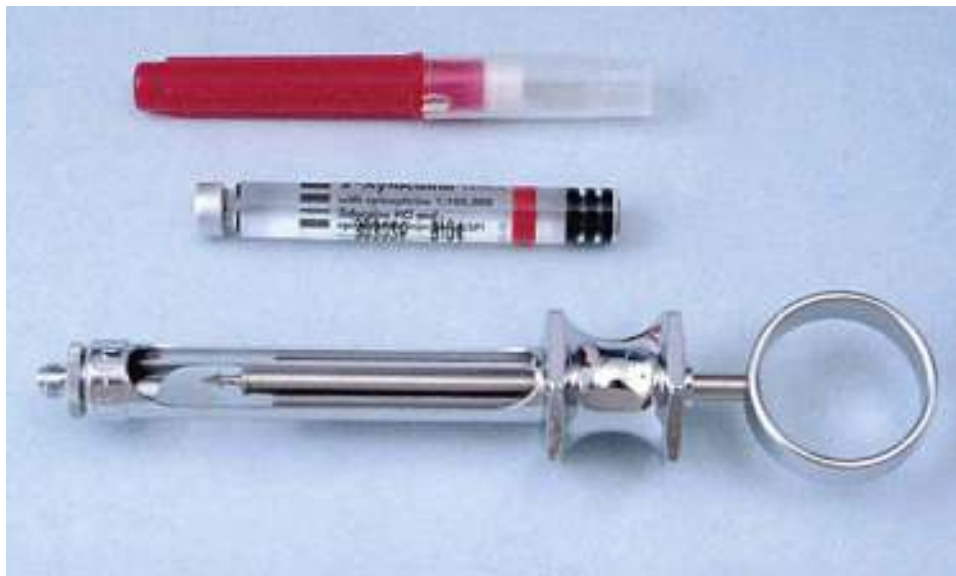Preparation of the Armamentarium

Proper care and handling of the local anesthetic armamentarium can prevent or at least minimize the development of complications associated with the needle, syringe, and cartridge. Many of these were discussed in the preceding chapters. Other complications and minor annoyances may be prevented through proper preparation of the armamentarium.

Breech-Loading, Metallic or Plastic, Cartridge-Type Syringe

1. Remove the sterilized syringe from its container (Fig. 9.1).
2. Retract the piston fully before attempting to load the cartridge (Fig. 9.2).
3. Insert the cartridge, while the piston is fully retracted, into the syringe. Insert the rubber stopper end of the cartridge first (Fig. 9.3).
4. Engage the harpoon. While holding the syringe as if injecting the anesthetic, gently push the piston forward until the harpoon is firmly engaged in the plunger (Fig. 9.4). Excessive force is not necessary. Do *not* hit the piston in an effort to engage the harpoon because this frequently leads to cracked or shattered glass cartridges (Fig. 9.5).
5. Attach the needle to the syringe. Remove the white or clear protective plastic cap from the syringe end of the needle and screw the needle onto the syringe (Fig. 9.6). Most metal- and plastic-hubbed needles are prethreaded, making it easy for them to be screwed onto the syringe; however, some plastic-hubbed syringes are not pre-threaded, requiring the needle to be pushed toward the metal hub of the syringe while being turned.
6. Carefully remove the colored plastic protective cap from the opposite end of the needle and expel a few drops of solution to test for proper flow.
7. The syringe is now ready for use.

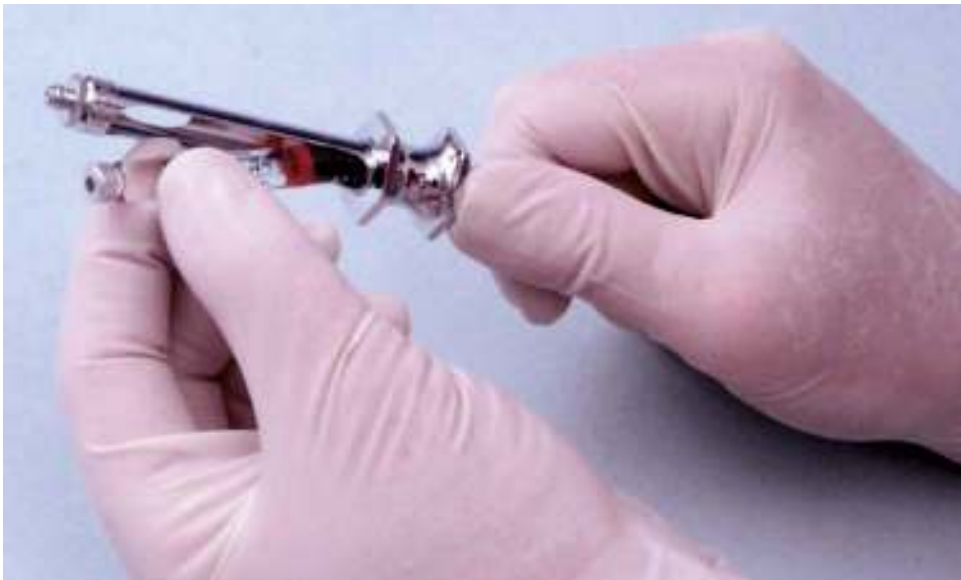Note: It is common practice in dentistry to attach the needle to the syringe before placing the cartridge. This sequence requires hitting the piston hard to engage the harpoon in the rubber stopper—a process that can lead to broken glass cartridges or leakage of anesthetic solution into the patient’s mouth during the injection. The recommended sequence, as already described, virtually eliminates this possibility and should always be used.



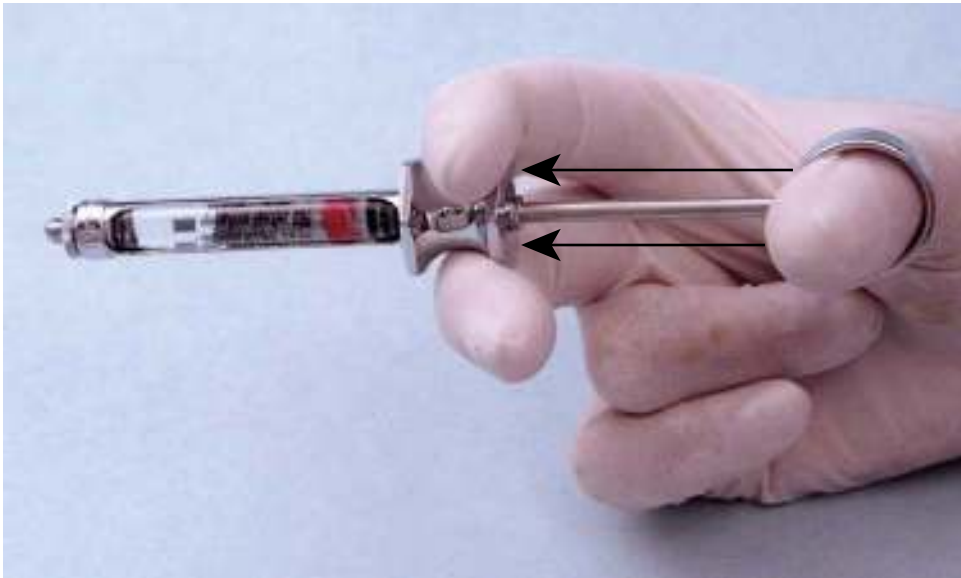• Fig. 9.1 Local anesthetic armamentarium (from top): needle, cartridge, syringe.



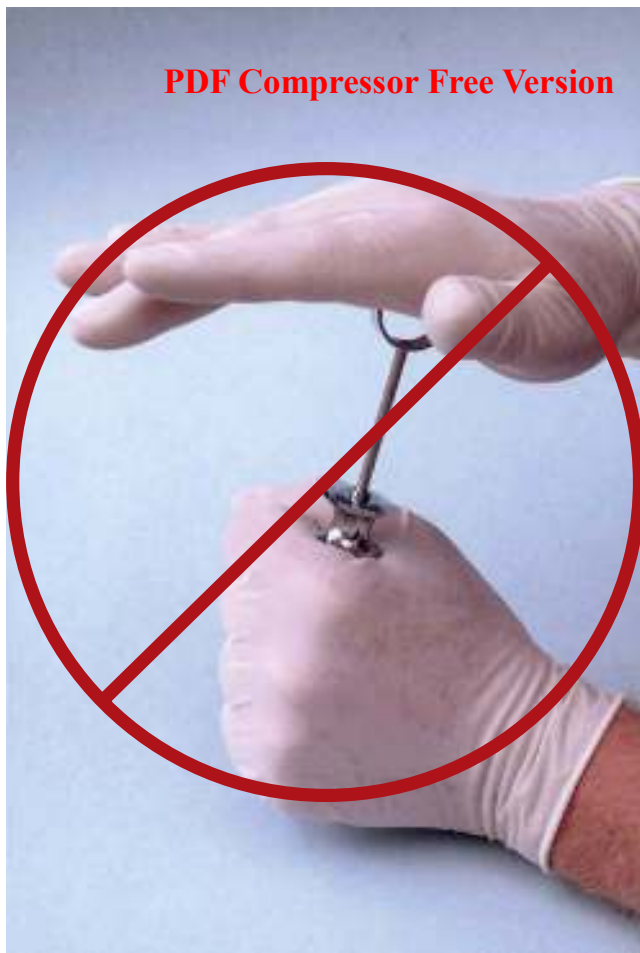• Fig. 9.2 Retract the piston.



• Fig. 9.3 Insert the cartridge.



• Fig. 9.4 Engage the harpoon in the plunger with gentle finger pressure.



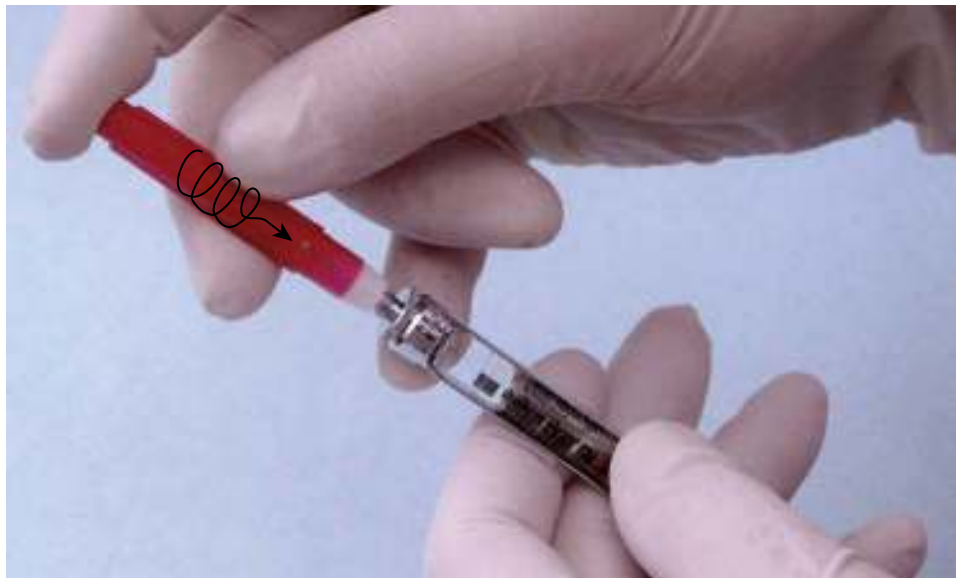
• **Fig. 9.5** Do not exert force on the plunger; the glass may crack.

Recapping the Needle

After removal of the syringe from the patient's mouth, the needle should be recapped immediately. Recapping is one of the two times when health professionals are most likely to be injured (stuck) with a needle (the other common time for needlestick injury is during injection, when a finger of the opposite hand is accidentally stuck with the needle as a result of sudden unexpected patient movement); it is probably the most dangerous time to be stuck because the needle is now contaminated with blood, saliva, and debris. Although a variety of techniques and devices for recapping have been suggested, the technique recommended by most state safety and health agencies is termed the *scoop technique* (Fig. 9.7), in which the uncapped needle is slid into the needle sheath lying on the instrument tray or table. Until a better method is designed, the scoop technique should be used for needle recapping.

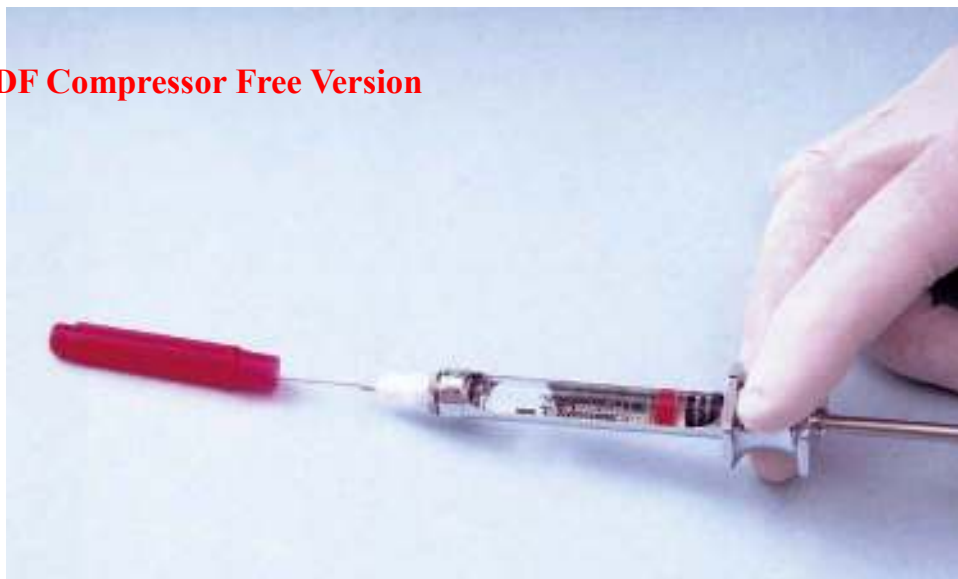Safety needles and syringes for use in dentistry are still in their developmental stage. Most systems currently available for dental use leave much to be desired.

Various needle cap holders are available—commercially made (Fig. 9.8) or self-made (from acrylic)—that hold the cap stationary while the needle is being inserted into it, making recapping somewhat easier to accomplish.



• **Fig. 9.6** If the plastic-hubbed needle is not prethreaded, it must be screwed onto the syringe while simultaneously being pushed into the metal needle adaptor of the syringe.

PDF Compressor Free Version



• Fig. 9.7 “Scoop” technique for recapping a needle after use.



• Fig. 9.8 Plastic needle cap holder.

Unloading the Breech-Loading, Metallic or Plastic, Cartridge-Type Syringe

After administration of the local anesthetic, the following sequence is suggested for removal of the used cartridge:

1. Retract the piston and pull the cartridge away from the needle with your thumb and forefinger as you retract the piston (Fig. 9.9), until the harpoon disengages from the plunger.
2. Remove the cartridge from the syringe by inverting the syringe, permitting the cartridge to fall free (Fig. 9.10).
3. Properly dispose of the used needle. All needles must be discarded after use to prevent injury or intentional misuse by unauthorized persons. Carefully unscrew the now recapped needle, being careful not to accidentally discard

the metal needle adaptor (Fig. 9.11). The use of a sharps container is recommended (Fig. 9.12) for needle disposal.

Placing an Additional Cartridge in a (Traditional) Syringe

On occasion it is necessary to deposit an additional cartridge of local anesthetic solution. To do this, the following sequence is suggested with the metallic or plastic breech-loading syringe:

1. Recap the needle using the scoop (or other appropriate) technique. Remove the needle from the syringe.
2. Retract the piston (disengaging the harpoon from the rubber stopper).
3. Remove the used cartridge.
4. Insert the new cartridge.
5. Embed the harpoon.
6. Reattach the needle.

The estimated time necessary to complete this procedure is 10 to 15 seconds.

Self-Aspirating Syringe

1. Insert the cartridge (as in the preceding instructions).
 2. Attach the needle.
 3. The syringe is now ready for use.^a
- Because of the absence of a harpoon, loading and unloading the self-aspirating syringe are simple procedures.

Ultra Safety Plus XL Safety Syringe

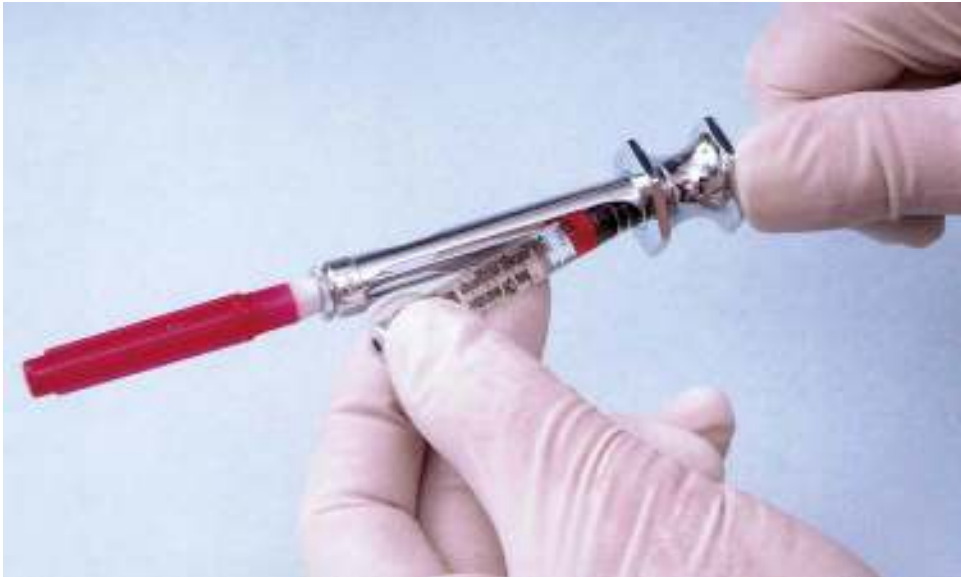Loading the Safety Syringe

1. While gripping the barrel firmly, fully insert the anesthetic cartridge into the open end of the injectable system (Fig. 9.13).

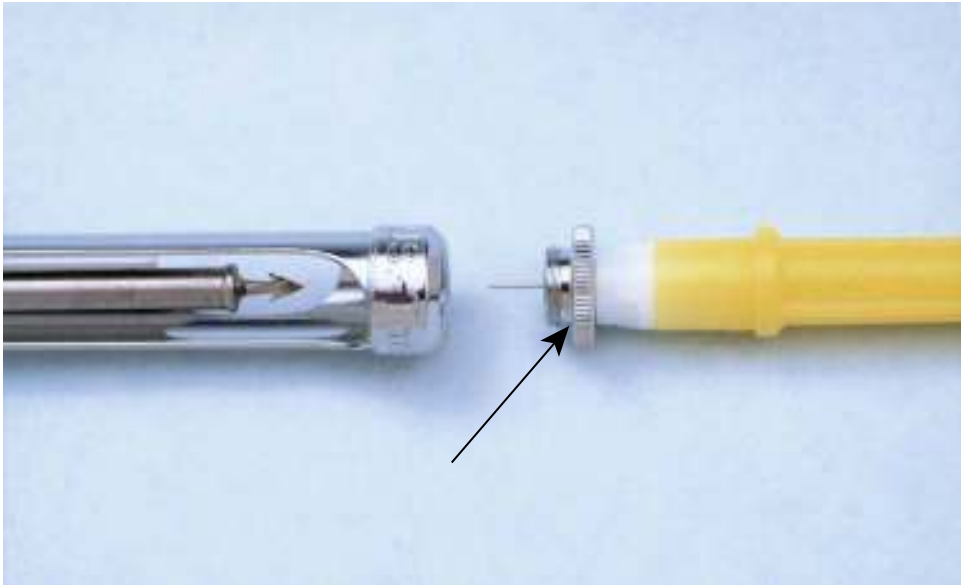
^aFrom Dentsply Sirona www.dentsplysirona.com. This is a portion of the instructions that Dentsply encloses with its syringes.



• Fig. 9.9 Retract the piston.



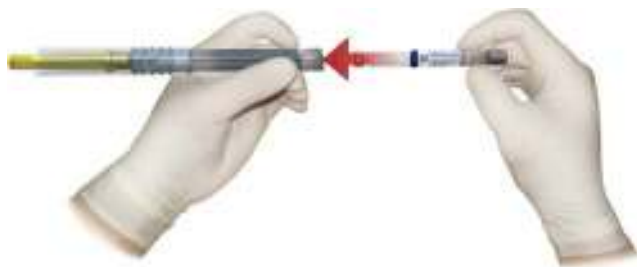• Fig. 9.10 Remove the used cartridge.



• Fig. 9.11 When discarding the needle, check to ensure that the metal needle adaptor from the syringe is not inadvertently discarded also (arrow).



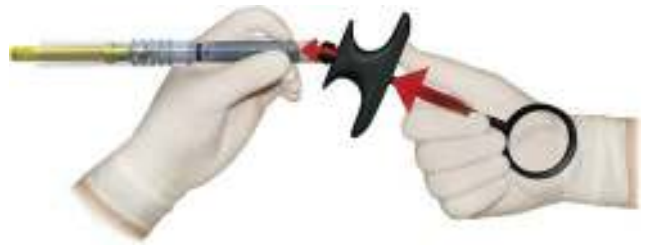• **Fig. 9.12** (A) A sharps container is required for storage of discarded contaminated needles. (B) A separate sealed container is recommended for discarded local anesthetic cartridges.



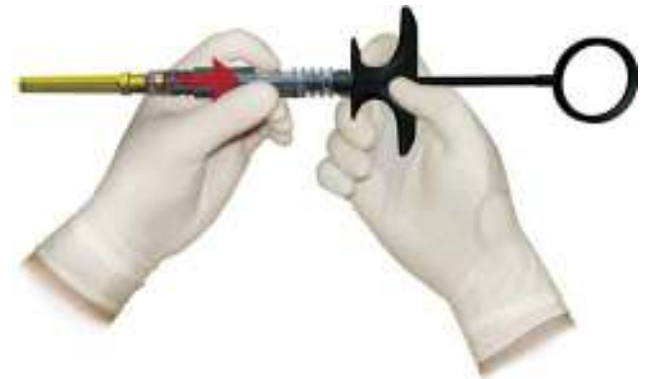• **Fig. 9.13** Insert the local anesthetic cartridge into the safety syringe. (Courtesy of Septodont, Inc, Lancaster, PA.)

2. Grip the plunger handle, putting the thumb behind the finger holder. Introduce the handle tip into the barrel of the injectable system, behind the cartridge (Fig. 9.14).
3. Slide the sheath protecting the needle backward, toward the handle, until it *clicks* (the click is made as the sheath hits the handle and locks the unit together) (Fig. 9.15).
4. All movements now are away from the needle. Remove the needle cap and discard it. The system is now ready to use (Fig. 9.16).^b

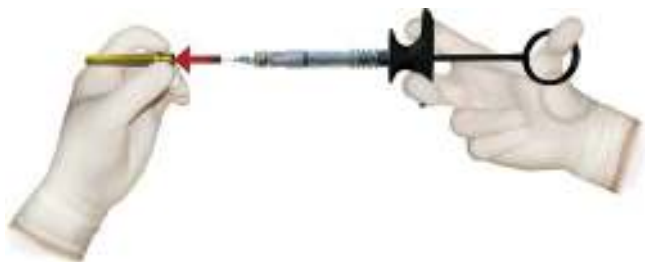^bFrom Septodont Inc., Lancaster, Pennsylvania, United States.



• **Fig. 9.14** Introduce the handle tip into the barrel of the injectable system, behind the cartridge. (Courtesy of Septodont, Inc, Lancaster, PA)



• **Fig. 9.15** While protecting the needle, slide the sheath backward toward the handle until it clicks. (Courtesy of Septodont, Inc, Lancaster, PA.)



• **Fig. 9.16** Remove the needle cap and discard it. (Courtesy of Septodont, Inc, Lancaster, PA.)

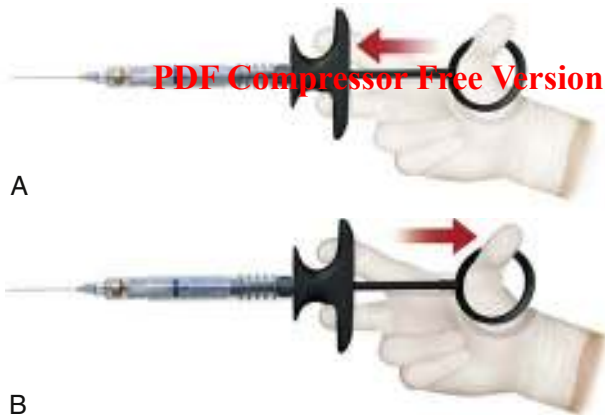Aspiration

Passive Aspiration (Self-Aspiration)

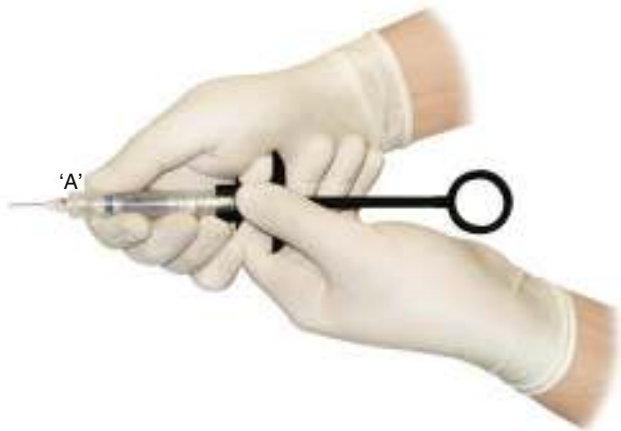At the base of the cartridge barrel of the injectable system, you will see there is a small protuberance. It appears as a blob of glue holding the centered needle, the needle end that penetrates the diaphragm of the cartridge when inserted. At the start of the injection, the diaphragm is pressed against the protuberance; a depression occurs, and when released (injection stopped), the diaphragm moves back away from the protuberance and aspiration occurs (Fig. 9.17A).

Active Aspiration

Active aspiration is obtained by the silicone top of the plunger handle creating a vacuum when, thumb in ring, the practitioner pulls the plunger backward (Fig. 9.17B). The bung



• **Fig. 9.17** (A) Passive aspiration. (B) Active aspiration. (Courtesy of Septodont, Inc, Lancaster, PA.)



• **Fig. 9.18** Move the sheath toward the needle until it reaches the holding position (A) so that the syringe may be used again. (Courtesy of Septodont, Inc, Lancaster, PA)

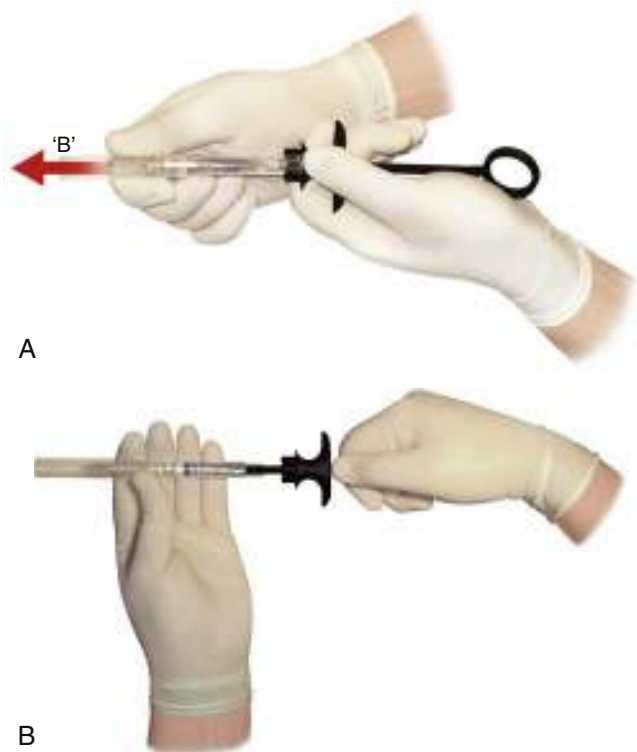
(silicone stopper) follows the plunger tip, providing active aspiration, which is best observed when a minimum of 0.25 to 0.35 mL of solution (providing space) has been expelled or used from the cartridge.

1. When only one cartridge is used.

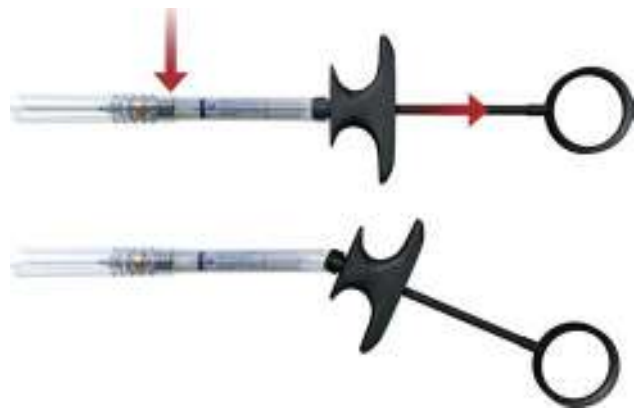Note: During multiple injection procedures using one cartridge, the practitioner may safely retain the syringe for further use by moving the sheath toward the needle until it reaches the holding position (Fig. 9.18). Should you need to insert a second cartridge, follow the procedure from step 3 (following) onward.

To complete the procedure, slide the protective sheath toward the locking position, which is the second notch at the end of the barrel (Fig. 9.19). This has now locked the needle safely in the protective sheath.

2. Remove the plunger handle after use. After you have locked the injectable system in the (B) position, hold the barrel of the injectable system with one hand, and, while using the other hand, place a finger in the ring of the plunger handle and pull the plunger backward until it is fully retracted. After you have fully retracted the plunger,



• **Fig. 9.19** (A) To lock the syringe, slide the protective sheath toward the locking position (B), which is the second notch at the end of the barrel. (B) Locked safety syringe. (Courtesy of Septodont, Inc, Lancaster, PA.)



• **Fig. 9.20** Remove the plunger handle after use. After locking the injectable system in position (see (Fig. 9.19A), hold the barrel of the injectable system with one hand, and while using the other hand, place a finger in the ring of the plunger handle and pull the plunger backward until it is fully retracted. After you have fully retracted the plunger, peel off the handle in one movement. (Courtesy of Septodont, Inc, Lancaster, PA)

peel off the handle in one movement (Fig. 9.20). Now the injectable system can be disposed of safely. The handle can be autoclaved.

3. When a second cartridge is being inserted.

Note: During procedures that require more than one cartridge, retract the sheath to the holding position (A) as a needlestick-prevention device. Should the system be

inadvertently fully locked into position (*B*), no attempt whatsoever should be made to unlock it. Use a new injection system. **PDF Compressor Free Version**

Hold the barrel of the injectable system with one hand, and, while using the other hand, place a finger in the ring of the plunger handle and pull the plunger backward until it is fully retracted. Now that you have fully retracted the plunger, peel off the handle in one movement.

4. Hold the plunger handle of the injection system and pull the grip handle back toward the ring. Now insert

the tip of the plunger into the empty cartridge, which is inside the injectable system. Pull out the cartridge attached to the plunger by the silicone tip, remove the cartridge from the plunger, and dispose of it safely. You are now ready to insert a fresh cartridge and proceed as from step 1.

The Ultra Safety Plus XL Safety Syringe is available with 25-gauge long, 27-gauge long and short, and 30-gauge extra short and short needles.

Techniques of Regional Anesthesia in Dentistry

Physical and Psychological Evaluation

Before starting any dental procedure, the doctor or hygienist must determine whether the patient can tolerate the planned dental procedure in relative safety. If this is not the case, specific treatment modifications necessary to decrease this risk must be determined. This is especially important whenever drugs are to be administered during treatment, such as analgesics, sedatives, inhalation sedation (N₂O-O₂) agents, and local anesthetics. Before administering local anesthetics, the administrator must determine the relative risk presented by the patient. This is important because local anesthetics, like all drugs, exert actions on many parts of the body (see [Chapter 2](#)). The actions of local anesthetics include depressant effects on excitable membranes (e.g., central nervous system [CNS], cardiovascular system [CVS], and myocardium). Because local anesthetics undergo biotransformation primarily in the liver (amides) or blood (esters), the functional status of these systems must be determined before drug administration. Because a small percentage of all injected local anesthetic is excreted in an active (unmetabolized) form in the kidneys, kidney function must be evaluated. Other questions should be asked: Has the patient ever received a local anesthetic for medical or dental care? If so, were any adverse reactions observed?

Most undesirable reactions to local anesthetics are produced not by the drugs themselves but as a response to the act of drug administration.^{1,2} These reactions are commonly psychogenic and have the potential to be life threatening if not recognized and managed promptly. The two most commonly occurring psychogenic reactions are vasodepressor syncope and hyperventilation. Other psychogenically induced reactions noted as a response to local anesthetic administration may include tonic-clonic convulsions, bronchospasm, and angina pectoris.

However, local anesthetics are not absolutely innocuous drugs, nor is the act of local anesthetic administration entirely benign. The doctor must seek to uncover as much information as possible concerning the patient's physical and mental status before administration of a local anesthetic. Fortunately, the means to do so exist in the form of the medical history questionnaire, the dialogue history, and the physical examination of the patient. Adequate use of these tools can lead to an

accurate determination of a patient's physical status and can prevent up to 90% of all life-threatening medical emergencies in dental practice.³

Goals of Physical and Psychological Evaluation

In the following discussion, a comprehensive but easy-to-use program of physical evaluation is described.^{4,5} Used as recommended, it allows the dental team to accurately determine any potential risk presented by the patient before the start of treatment. This system can be used to meet the following goals:

1. to determine the patient's ability to tolerate *physically* the stresses involved in the planned dental treatment
2. to determine the patient's ability to tolerate *psychologically* the stresses involved in the planned dental treatment
3. to determine whether treatment modification is indicated to enable the patient to better tolerate the stresses associated with the dental treatment
4. to determine whether the use of psychosedation is indicated
5. to determine which technique of sedation is most appropriate for the patient
6. to determine whether contraindications exist to (a) the planned dental treatment or (b) any of the drugs to be used

The first two goals involve the patient's ability to tolerate the stress involved in the planned dental care. Stress may be of a physiologic or psychological nature. Patients with underlying medical problems may be less able to tolerate the usual levels of stress associated with various types of dental care. These patients are more likely to experience an acute exacerbation of their underlying medical problem(s) during periods of increased stress. Such disease processes include angina pectoris, seizure disorders, asthma, and sickle cell disease. Although most of these patients will be able to tolerate the planned dental care in relative safety, it is the obligation of the dental team to determine whether a problem does exist and the severity of the problem and to decide how it might impact the proposed dental treatment plan.

Excessive stress can prove detrimental to the non-medically compromised (i.e., “healthy”) patient. Fear, anxiety, and a deep pulse are changes in the homeostasis of the body that may prove detrimental. Many “healthy” patients suffer from fear-related emergencies, including hyperventilation and vasodepressor syncope (also known as *vasovagal syncope* and “fainting”).

The third goal is to determine whether the usual treatment regimen for a patient should be modified to enable the patient to better tolerate the stress of treatment. In some cases a healthy patient will be psychologically unable to tolerate the planned treatment. Treatment may be modified to minimize the stress faced by this patient. The medically compromised patient will also benefit from treatment modification aimed at minimizing stress. The stress-reduction protocols (SRPs) outlined in this chapter are designed to aid the dentist and the hygienist in minimizing treatment-related stress for both healthy and medically compromised patients.

When it is believed that the patient will require some assistance in coping with his or her dental treatment, the use of psychosedation should be considered. The last three goals involve determination of the need for use of psychosedation, selection of the most appropriate technique, and selection of the most appropriate drug(s) for patient management.

Physical Evaluation

The term *physical evaluation* is used to describe the steps involved in fulfilling the aforementioned goals. Physical evaluation in dentistry consists of the following three components:

1. medical history questionnaire
2. physical examination
3. dialogue history

With the information (database) collected from these three steps, the dentist and the hygienist will be better able to (1) determine the physical and psychological status of the patient (establish a risk factor classification for the patient); (2) seek medical consultation, if indicated; and (3) appropriately modify the planned dental treatment, if indicated. Each of the three steps in the evaluation process is discussed in general terms, with specific emphasis placed on its importance in the evaluation of the patient for whom local anesthesia is to be administered.

Medical History Questionnaire

The use of a written, patient-completed medical history questionnaire is a moral and legal necessity in the practice of both medicine and dentistry. Such questionnaires provide the dentist and the hygienist with valuable information about the physical status and in some cases the psychological status of the prospective patient.

Many types of medical history questionnaires are available; however, most are simply modifications of two basic types: the “short” form and the “long” form. The *short-form*

medical history questionnaire provides basic medical history information and is best suited for use by a dentist or hygienist with considerable clinical experience in physical evaluation. When using the short-form history, the dentist or hygienist must have a firm grasp of the appropriate dialogue history required to aid in determination of the relative risk presented by the patient. The dentist or the hygienist should be experienced in the use of techniques of physical evaluation and interpretation of findings. Unfortunately, most dentist offices use the short-form medical history questionnaire or a modification of it primarily as a convenience for their patient and themselves. The *long-form* medical history questionnaire, on the other hand, results in a more detailed database concerning the physical condition of the prospective patient. It is used most often in teaching situations, and is a more ideal instrument for teaching physical evaluation.

In recent years, computer-generated medical history questionnaires have been developed.⁶ These questionnaires permit patients to enter their responses to questions electronically on a computer. Whenever a positive response is given, the computer asks additional questions related to the positive response. In effect, the computer asks the questions called for in the dialogue history.

Any medical history questionnaire can prove to be extremely valuable or entirely worthless. The ultimate value of the questionnaire resides in the ability of the dentist or hygienist to interpret the significance of the answers and to elicit additional information through physical examination and dialogue history.

The prototypical adult health history questionnaire developed by the University of the Pacific (UOP) School of Dentistry in conjunction with MetLife Dental is included as an example of an excellent long-form medical history questionnaire (Fig. 10.1).⁷ Fig. 10.2 shows an example of a pediatric medical history questionnaire.

The UOP health history has been translated into 36 different languages, constituting the languages spoken by 95% of the persons on this planet. The cost of the translation was supported by several organizations, including the California Dental Association, but most extensively by MetLife Dental. The health history (see Fig. 10.1), translations of the health history (Fig. 10.3), the interview sheet (Fig. 10.4), the medical consultation form (Fig. 10.5), and protocols for the dental management of medically complex patients may be found on the UOP website at <http://www.dental.pacific.edu/departments-and-groups/professional-services-and-resources/dental-practice-documents> under “Health History Forms.” Protocols for the management of medically complex patients can be found at the same webpage under “Dental Management Protocols.” Translations of the medical history form can be found at <https://www.metlifelife.com> under “Resource Center,” then “Multi-Language Health History Forms.”

The health history has been translated while keeping the same question numbering sequence. Thus an English-speaking dentist caring for a non-English-speaking patient can ask the patient to complete the health history in his or

MetLife

HEALTH HISTORY
English

University of the Pacific

Patient Name: _____ Patient Identification Number: _____
Birth Date: _____

I. CIRCLE APPROPRIATE ANSWER (leave blank if you do not understand question):

- 1. Yes No Is your general health good?
- 2. Yes No Has there been a change in your health within the last year?
- 3. Yes No Have you been hospitalized or had a serious illness in the last three years?
If YES, why? _____
- 4. Yes No Are you being treated by a physician now? For what? _____
Date of last medical exam? _____ Date of last dental exam _____
- 5. Yes No Have you had problems with prior dental treatment?
- 6. Yes No Are you in pain now?

II. HAVE YOU EXPERIENCED:

- | | |
|---|-----------------------------------|
| 7. Yes No Chest pain (angina)? | 18. Yes No Dizziness? |
| 8. Yes No Swollen ankles? | 19. Yes No Ringing in ears? |
| 9. Yes No Shortness of breath? | 20. Yes No Headaches? |
| 10. Yes No Recent weight loss, fever, night sweats? | 21. Yes No Fainting spells? |
| 11. Yes No Persistent cough, coughing up blood? | 22. Yes No Blurred vision? |
| 12. Yes No Bleeding problems, bruising easily? | 23. Yes No Seizures? |
| 13. Yes No Sinus problems? | 24. Yes No Excessive thirst? |
| 14. Yes No Difficulty swallowing? | 25. Yes No Frequent urination? |
| 15. Yes No Diarrhea, constipation, blood in stools? | 26. Yes No Dry mouth? |
| 16. Yes No Frequent vomiting, nausea? | 27. Yes No Jaundice? |
| 17. Yes No Difficulty urinating, blood in urine? | 28. Yes No Joint pain, stiffness? |

III. DO YOU HAVE OR HAVE YOU HAD:

- | | |
|--|--|
| 29. Yes No Heart disease? | 40. Yes No AIDS |
| 30. Yes No Heart attack, heart defects? | 41. Yes No Tumors, cancer? |
| 31. Yes No Heart murmurs? | 42. Yes No Arthritis, rheumatism? |
| 32. Yes No Rheumatic fever? | 43. Yes No Eye diseases? |
| 33. Yes No Stroke, hardening of arteries? | 44. Yes No Skin diseases? |
| 34. Yes No High blood pressure? | 45. Yes No Anemia? |
| 35. Yes No Asthma, TB, emphysema, other lung diseases? | 46. Yes No VD (syphilis or gonorrhea)? |
| 36. Yes No Hepatitis, other liver disease? | 47. Yes No Herpes? |
| 37. Yes No Stomach problems, ulcers? | 48. Yes No Kidney, bladder disease? |
| 38. Yes No Allergies to: drugs, foods, medications, latex? | 49. Yes No Thyroid, adrenal disease? |
| 39. Yes No Family history of diabetes, heart problems, tumors? | 50. Yes No Diabetes? |

IV. DO YOU HAVE OR HAVE YOU HAD:

- | | |
|------------------------------------|--------------------------------|
| 51. Yes No Psychiatric care? | 56. Yes No Hospitalization? |
| 52. Yes No Radiation treatments? | 57. Yes No Blood transfusions? |
| 53. Yes No Chemotherapy? | 58. Yes No Surgeries? |
| 54. Yes No Prosthetic heart valve? | 59. Yes No Pacemaker? |
| 55. Yes No Artificial joint? | 60. Yes No Contact lenses? |

V. ARE YOU TAKING:

- | | |
|--|---------------------------------|
| 61. Yes No Recreational drugs? | 63. Yes No Tobacco in any form? |
| 62. Yes No Drugs, medications, over-the-counter medicines (including aspirin), natural remedies? | 64. Yes No Alcohol? |

Please list: _____

VI. WOMEN ONLY:

- | | |
|---|--|
| 65. Yes No Are you or could you be pregnant or nursing? | 66. Yes No Taking birth control pills? |
|---|--|

VII. ALL PATIENTS:

67. Yes No Do you have or have you had any other diseases or medical problems NOT listed on this form?
If so, please explain: _____

To the best of my knowledge, I have answered every question completely and accurately. I will inform my dentist of any change in my health and/or medication.

Patient's signature: _____ Date: _____

RECALL REVIEW:

- 1. Patient's signature _____ Date: _____
- 2. Patient's signature _____ Date: _____
- 3. Patient's signature _____ Date: _____

The Health History is created and maintained by the University of the Pacific School of Dentistry, San Francisco, California. Support for the translation and dissemination of the Health Histories comes from MetLife Dental Care.

• **Fig. 10.1** Adult health history questionnaire. (Reprinted with permission from University of the Pacific Arthur A. Dugoni School of Dentistry, San Francisco, California, United States.)

Child's Name: _____ Date of Birth: _____ Age _____ Date: _____
 Address: _____ Telephone: (____) _____
 _____ Telephone: (____) _____

Please circle the appropriate answer.

1. Does your child have a health problem? _____ YES NO
2. Was your child a patient in a hospital? _____ YES NO
3. Date of last physical exam: _____
4. Is your child now under medical care? _____ YES NO
5. Is your child taking medication now? _____ YES NO
If so, for what? _____
6. Has your child ever had a serious illness or operation? YES NO
7. If so, explain: _____
8. Does your child have (or ever had) any of the following diseases?
 - a. Rheumatic fever or rheumatic heart disease _____ YES NO
 - b. Congenital heart disease _____ YES NO
 - c. Cardiovascular disease (heart trouble, heart attack, coronary insufficiency, coronary occlusion, high blood pressure, arteriosclerosis, stroke) _____ YES NO
 - d. Allergy? Food Medicine Other _____ YES NO
 - e. Asthma Hay Fever _____ YES NO
 - f. Hives or a skin rash _____ YES NO
 - g. Fainting spells or seizures _____ YES NO
 - h. Hepatitis, jaundice or liver disease _____ YES NO
 - i. Diabetes _____ YES NO
 - j. Inflammatory rheumatism (painful or swollen joints) _____ YES NO
 - k. Arthritis _____ YES NO
 - l. Stomach ulcers _____ YES NO
 - m. Kidney trouble _____ YES NO
 - n. Tuberculosis (TB) _____ YES NO
 - o. Persistent cough or cough up blood _____ YES NO
 - p. Venereal disease _____ YES NO
 - q. Epilepsy _____ YES NO
 - r. Sickle cell disease _____ YES NO
 - s. Thyroid disease _____ YES NO
 - t. AIDS _____ YES NO
 - u. Emphysema _____ YES NO
 - v. Psychiatric treatment _____ YES NO
 - w. Cleft lip/palate _____ YES NO
 - x. Cerebral palsy _____ YES NO
 - y. Mental retardation _____ YES NO
 - z. Hearing disability _____ YES NO
 - aa. Developmental disability _____ YES NO
If yes, explain: _____
 - bb. Was your child premature? _____ YES NO
If yes, how many weeks _____
 - cc. Other: _____
9. Does your child have to urinate (pass water) more than six times a day? _____ YES NO
10. Is your child thirsty much of the time? _____ YES NO
11. Has your child had abnormal bleeding associated with previous surgery, extractions or accidents? _____ YES NO
12. Does he/she bruise easily? _____ YES NO
13. Has he/she ever required a blood transfusion? _____ YES NO
14. Does he/she have any blood disorders such as anemia, etc.? _____ YES NO
15. Has he/she ever had surgery, x-ray or chemotherapy for a tumor, growth, or other condition? _____ YES NO
16. Does your child have a disability that prevents treatment in a dental office? _____ YES NO
17. Is he/she taking any of the following?
 - a. Antibiotics or sulfa drugs _____ YES NO
 - b. Anticoagulants (blood thinners) _____ YES NO
 - c. Medicine for high blood pressure _____ YES NO
 - d. Cortisone or steroids _____ YES NO
 - e. Tranquilizers _____ YES NO
 - f. Aspirin _____ YES NO
 - g. Dilantin or other anticonvulsant _____ YES NO
 - h. Insulin, tolbutamide, Orinase, or similar drug _____ YES NO
 - i. Any other? _____
18. Is he/she allergic to, or has he/she ever reacted adversely to, any of the following?
 - a. Local anesthetics _____ YES NO
 - b. Penicillin or other antibiotics _____ YES NO
 - c. Sulfa drugs _____ YES NO
 - d. Barbituates, sedatives, or sleeping pills _____ YES NO
 - e. Aspirin _____ YES NO
 - f. Any other? _____
19. Has he/she any serious trouble associated with any previous dental treatment? _____ YES NO
If so, please explain: _____
20. Has your child been in any situation which could expose him/her to x-rays or other ionizing radiators? _____ YES NO
21. Last date of dental examination: _____
22. Has he/she ever had orthodontic treatment (worn braces)? _____ YES NO
23. Has he/she ever been treated for any gum diseases (gingivitis, periodontitis, trenchmouth, pyorrhea)? _____ YES NO
24. Does his/her gums bleed when brushing teeth? _____ YES NO
25. Does he/she grind or clench teeth? _____ YES NO
26. Has he/she often had toothaches? _____ YES NO
27. Has he/she had frequent sores in his/her mouth? _____ YES NO
28. Has he/she had any injuries to his/her mouth or jaws? YES NO
If yes, explain: _____
29. Does he/she have any sores or swellings of his/her mouth or jaws? _____ YES NO
30. Have you been satisfied with your child's previous dental care? _____ YES NO

ADOLESCENT WOMEN:

31. Are you pregnant now, or think you may be? _____ YES NO
32. Do you anticipate becoming pregnant? _____ YES NO
33. Are you taking the pill? _____ YES NO

To the best of my knowledge, all of the preceding answers are true and correct. If my child ever has a change in his/her health or his/her medicines change, I will inform the doctor at the next appointment without fail.

Parents's Signature: _____ Date _____

MEDICAL HISTORY / PHYSICAL EXAMINATION REVIEW

Date	Addition	Student/Faculty Signatures
_____	_____	_____
_____	_____	_____
_____	_____	_____

• Fig. 10.2 Pediatric medical history questionnaire. (From Malamed SF. *Medical Emergencies in the Dental Office*. 7th ed. St Louis: Mosby; 2015)

her own language. The dentist then compares the English health history with the patient's translated health history, scanning the translated version for YES responses. When a YES is found, the dentist is able to look at the question number and match it to the question number on the English version. For example, the dentist would know that a YES response to question 34 on the non-English version is the same as this response to question 34 on the English version, which relates to high blood pressure (HBP). For that matter, a Mandarin Chinese-speaking dentist could use the multilanguage health history with an English-speaking patient and have the same cross-referenced information. A

dentist who speaks Spanish could use the multilanguage health history with a patient who speaks French. With the uniform health history question sequence, these health history translations can serve patients and dentists all around the world.

The health history is divided into sections related to signs and symptoms ("Have you experienced?"), diagnosed diseases ("Do you have or have you had?"), medical treatments (including drugs and other physiologically active compounds), and several miscellaneous questions.

Although both long-form and short-form medical history questionnaires are valuable for determining a patient's

Nombre del paciente: _____ No. de Ident. del Paciente: _____
 Fecha de nacimiento: _____

I. MARQUE CON UN CÍRCULO LA RESPUESTA CORRECTA (Deje en BLANCO si no entiende la pregunta):

1. Sí No ¿Está en buena salud general?
2. Sí No ¿Han habido cambios en su salud durante el último año?
3. Sí No ¿Ha estado hospitalizado/a o ha tenido de una enfermedad grave en los últimos tres años?
 ¿Si Sí, por qué? _____
4. Sí No ¿Se encuentra actualmente bajo tratamiento médico? ¿Para qué? _____
 Fecha de su último examen médico: _____ Fecha de su última cita dental: _____
5. Sí No ¿Ha tenido problemas con algún tratamiento dental en el pasado?
6. Sí No ¿Tiene algún dolor ahora?

II. HA NOTADO:

- | | |
|---|---|
| 7. Sí No ¿Dolor de pecho (angina)? | 18. Sí No ¿Mareos? |
| 8. Sí No ¿Los tobillos hinchados? | 19. Sí No ¿Ruidos o zumbidos en los oídos? |
| 9. Sí No ¿Falta de aliento? | 20. Sí No ¿Dolores de cabeza? |
| 10. Sí No ¿Reciente pérdida de peso, fiebre, sudor en la noche? | 21. Sí No ¿Desmayos? |
| 11. Sí No ¿Tos persistente o tos con sangre? | 22. Sí No ¿Vista borrosa? |
| 12. Sí No ¿Problemas de sangramiento, moretes? | 23. Sí No ¿Convulsiones? |
| 13. Sí No ¿Problemas nasales (sinusitis)? | 24. Sí No ¿Sed excesiva? |
| 14. Sí No ¿Dificultad al tragar? | 25. Sí No ¿Orina con frecuencia? |
| 15. Sí No ¿Diarrea, estreñimiento, sangre en las heces? | 26. Sí No ¿Boca seca? |
| 16. Sí No ¿Vómitos con frecuencia, náuseas? | 27. Sí No ¿Ictericia? |
| 17. Sí No ¿Dificultad al orinar, sangre en la orina? | 28. Sí No ¿Dolor o rigidez en las articulaciones? |

III. TIENE O HA TENIDO:

- | | |
|---|---|
| 29. Sí No ¿Enfermedades del corazón? | 40. Sí No ¿SIDA? |
| 30. Sí No ¿Infarto de corazón, defectos en el corazón? | 41. Sí No ¿Tumores, cáncer? |
| 31. Sí No ¿Soplos en el corazón? | 42. Sí No ¿Artritis, reuma? |
| 32. Sí No ¿Fiebre reumática? | 43. Sí No ¿Enfermedades de los ojos? |
| 33. Sí No ¿Apoplejía, endurecimiento de las arterias? | 44. Sí No ¿Enfermedades de la piel? |
| 34. Sí No ¿Presión sanguínea alta? | 45. Sí No ¿Anemia? |
| 35. Sí No ¿Asma, tuberculosis, enfisema, otras enfermedades pulmonares? | 46. Sí No ¿Enfermedades venéreas (sífilis o gonorrea)? |
| 36. Sí No ¿Hepatitis, otras enfermedades del hígado? | 47. Sí No ¿Herpes? |
| 37. Sí No ¿Problemas del estómago, úlceras? | 48. Sí No ¿Enfermedades renales (riñón), vejiga? |
| 38. Sí No ¿Alergias a remedios, comidas, medicamentos látex? | 49. Sí No ¿Enfermedades de tiroideos o glándulas suprarrenales? |
| 39. Sí No ¿Familiares con diabetes, problemas de corazón, tumores? | 50. Sí No ¿Diabetes? |

VI. TIENE O HA TENIDO:

- | | |
|--|-------------------------------------|
| 51. Sí No ¿Tratamiento psiquiátrico? | 56. Sí No ¿Hospitalizaciones? |
| 52. Sí No ¿Tratamientos de radiación? | 57. Sí No ¿Transfusiones de sangre? |
| 53. Sí No ¿Quimioterapia? | 58. Sí No ¿Cirugías? |
| 54. Sí No ¿Válvula artificial del corazón? | 59. Sí No ¿Marcapasos? |
| 55. Sí No ¿Articulación artificial? | 60. Sí No ¿Lentes de contacto? |

V. ESTÁ TOMANDO:

- | | |
|---|---|
| 61. Sí No ¿Drogas de uso recreativo? | 63. Sí No ¿Tabaco de cualquier tipo? |
| 62. Sí No ¿Remedios, medicamentos, medicamentos sin receta (incluyendo aspirina)? | 64. Sí No ¿Alcohol (bebidas alcohólicas)? |

Liste por favor: _____

VI. SÓLO PARA MUJERES:

- | | |
|--|--|
| 65. Sí No ¿Está o podría estar embarazada o dando pecho? | 66. Sí No ¿Está tomando pastillas anticonceptivas? |
|--|--|

VII. PARA TODOS LOS PACIENTES:

67. Sí No ¿Tiene o ha tenido alguna otra enfermedad o problema médico que NO está en esta cuestionario?

Si la respuesta es afirmativa, explique: _____

Que yo sepa, he respondido completamente y correctamente todas las preguntas. Informaré a mi dentista si hay algún cambio en mi salud y/o en los medicamentos que tomo.

Firma del Paciente _____ Fecha _____

REVISIÓN SUPLEMENTARIA:

- | | |
|-----------------------------|-------------|
| 1. Firma del Paciente _____ | Fecha _____ |
| 2. Firma del Paciente _____ | Fecha _____ |
| 3. Firma del Paciente _____ | Fecha _____ |

The Health History is created and maintained by the University of the Pacific School of Dentistry, San Francisco, California. Support for the translation and dissemination of the Health Histories comes from MetLife Dental Care.

• **Fig. 10.3** Spanish health history questionnaire. (Reprinted with permission from University of the Pacific Arthur A. Dugoni School of Dentistry, San Francisco, California, United States.)

PDF Compressor Free Version

MetLife

HEALTH HISTORY INTERVIEW

University of the Pacific

Patient Name: _____

SIGNIFICANT MEDICAL FINDINGS	DENTAL MANAGEMENT CONSIDERATIONS	DATE
Record below the number and details of any YES response noted on the Health History, plus details of any YES response to questions A through F.	A. yes/no B. yes/no C. yes/no D. yes/no E. yes/no F. yes/no	Cardiovascular Infectious diseases Allergy to medicines Hematologic, bleeding Medications Other medical problems not asked?

Date_____
Doctor's Signature

This Health History Interview form is created and maintained by the University of the Pacific School of Dentistry, San Francisco, California. Support for the translation and dissemination of the Health Histories comes from MetLife Dental Care.

• **Fig. 10.4** Health history interview sheet. (Reprinted with permission from University of the Pacific Arthur A. Dugoni School of Dentistry, San Francisco, California, United States.)

MetLife	MEDICAL CONSULTATION REQUEST	University of the Pacific
PDF Compressor Free Version		
To: Dr. _____	Please complete the form below and return it to	
_____	Dr. _____	
_____	_____	
RE: _____	_____	
_____	_____	
Date of Birth _____	Phone # _____	
	Fax # _____	
Our patient has presented with the following medical problem(s): _____		

The following treatment is scheduled in our clinic: _____		

Most patients experience the following with the above planned procedures:		
bleeding:	• minimal (<50ml)	• significant (>50ml)
stress and anxiety:	• low	• medium • high
_____	_____	_____
Dentist signature	Date	
<hr/>		
PHYSICIAN'S RESPONSE		
Please provide any information regarding the above patient's need for antibiotic prophylaxis, current cardiovascular condition, coagulation ability, and the history and status of infectious diseases. Ordinarily, local anesthesia is obtained with 2% lidocaine, 1:100,000 epinephrine. For some surgical procedures, the epinephrine concentration may be increased to 1:50,000 for hemostasis. The epinephrine dose NEVER exceeds 0.2 mg total.		
CHECK ALL THAT APPLY		
• <u>OK to PROCEED</u> with dental treatment; <u>NO</u> special precautions and <u>NO</u> prophylactic antibiotics are needed.		
• Antibiotic prophylaxis <u>IS</u> required for dental treatment according to the current American Heart Association and/or American Academy of Orthopedic Surgeons guidelines.		
• Other precautions are required (please list): _____		

• <u>DO NOT</u> proceed with treatment. (Please give reason.) _____		

Treatment may proceed on (Date) _____		
• Patient has an infectious disease:		
• AIDS (please provide current lab results)	• Hepatitis, type _____ (acute/carrier)	
• TB (PPD+/active)	• Other (explain) _____	
• Requested relevant medical and/or laboratory information is attached.		
_____	_____	
Physician signature	Date	
<hr/>		
PATIENT CONSENT		
I agree to the release of my medical information to the University of the Pacific School of Dentistry.		
_____	_____	
Patient signature	Date	
This Medical Consultation form is created and maintained by the University of the Pacific School of Dentistry, San Francisco, California. Support for the translation and dissemination of the health histories comes from MetLife Dental Care.		

• **Fig. 10.5** Medical consultation form. (Reprinted with permission from University of the Pacific Arthur A. Dugoni School of Dentistry, San Francisco, California, United States.)

physical condition, one criticism of most available health history questionnaires is the absence of questions related to the patient's attitudes toward dental care. It is recommended therefore that one or more questions be included that relate to this all-important subject:

1. Do you feel very nervous about having dental treatment?
2. Have you ever had a bad experience in the dental office?

Questions 5 and 6 on the UOP medical history questionnaire address these points.

The following is the UOP medical history questionnaire, with a discussion of the significance of each point.

I. Circle Appropriate Answer: (Leave Blank If You Do Not Understand The Question.)

1. Is Your General Health Good?

Comment: General survey questions seek patients' general impression of their health. Studies have demonstrated that a YES response to this question does not necessarily correlate with the patient's actual state of health.⁸

2. Has There Been a Change in Your Health Within the Last Year?

3. Have You Been Hospitalized or Had a Serious Illness in the Last 3 Years?

If YES, Why?

4. Are You Being Treated by a Physician Now? For What?

Date of last medical exam?

Date of last dental exam?

Comment: Questions 2, 3, and 4 seek information regarding recent changes in the patient's physical condition. In all instances of a positive response, an in-depth dialogue history must ensue to determine the precise nature of the change in health status, the type of surgical procedure or illness, and the names of any medications the patient may now be taking to help manage the problem.

5. Have You Had Problems With Prior Dental Treatment?

Comment: Many adults are reluctant to verbally admit to the dentist, hygienist, or assistant their fears about treatment, for fear of being labeled a "baby." This is especially true of young men in their late teens or early twenties; they attempt to "take it like a man" or "grin and bear it" rather than admit their fears. Because the most common fear mentioned by dental patients is fear of injection (the "shot," in their words), all too often such macho behavior results in an episode of vasodepressor syncope. Whereas many such patients will not offer verbal admissions of

fear, many of these same patients will volunteer this information in writing.

6. Are You in Pain Now?

Comment: The primary aim of this question is related to the need for immediate dental care. Its purpose is to determine what prompted the patient to seek dental care. If pain is present, the dentist may need to treat the patient immediately on an emergency basis, whereas in the more usual situation, treatment can be delayed until future visits. This may affect the use of local anesthesia, in that effective pain control can be more difficult to achieve in the presence of infection and chronic, albeit, now acute, pain in the fearful patient.

II. Have You Experienced

7. Chest Pain (Angina)?

Comment: A history of angina (defined, in part, as chest pain brought on by exertion and alleviated by rest) usually indicates the presence of coronary artery disease with attendant ischemia of the myocardium. The risk factor for the typical patient with stable angina is American Society of Anesthesiologists (ASA) physical status classification system class 3 (the ASA physical status classification system is discussed in detail later in this chapter). In the presence of dental fears, sedation is absolutely indicated in the anginal patient. Inhalation sedation with N₂O-O₂ is preferred. Effective pain control—local anesthesia with a vasoconstrictor included—is absolutely indicated. Patients with unstable or recent-onset angina represent an ASA class 4 risk.

8. Swollen Ankles?

Comment: Swollen ankles (pitting edema or dependent edema) indicate possible heart failure (HF). However, varicose veins, pregnancy, and renal dysfunction are other causes of ankle edema. Healthy persons who stand on their feet for long periods (e.g., mail carriers, dental staff members) may develop ankle edema that is not life threatening, merely esthetically unpleasing.

9. Shortness of Breath?

Comment: Although the patient may respond negatively to specific questions (questions 29 to 35 in Section III) regarding the presence of various heart and lung disorders (e.g., angina, HF, pulmonary emphysema), clinical signs and symptoms of heart or lung disease may be evident. A positive response to this question does not always indicate that the patient suffers from such a disease. To more accurately determine the patient's status before the start of dental care, further evaluation is suggested.

10. Recent Weight Loss, Fever, Night Sweats?

Comment: The question is not to intentional weight loss (e.g., dieting). Unexpected weight change may indicate HF, hypothyroidism (increased weight), hyperthyroidism, metastatic cancer, or uncontrolled diabetes mellitus (weight loss), or a number of other disorders. The presence of fever and/or night sweats should be pursued to determine whether they are innocent or perhaps clues to the presence of a more significant problem, such as tuberculosis.

11. Persistent Cough, Coughing Up Blood?

Comment: A positive response mandates an in-depth dialogue history to determine the cause of the persistent cough or hemoptysis (blood-tinged sputum). The most common causes of hemoptysis are bronchitis and bronchiectasis, neoplasms, and tuberculosis.

A chronic cough can indicate active tuberculosis or other chronic respiratory disorders, such as chronic bronchitis. Cough associated with an upper respiratory infection confers an ASA class 2 classification on the patient, whereas chronic bronchitis in a patient who has smoked more than one pack of cigarettes daily for many years may indicate chronic lung disease and confer on the patient an ASA class 3 risk.

12. Bleeding Problems, Bruising Easily?

Comment: Bleeding disorders, such as hemophilia, are associated with prolonged bleeding or frequent bruising and can lead to modification of certain forms of dental therapy (e.g., surgery, technique of local anesthetic administration, venipuncture) and therefore must be made known to the dentist before treatment is begun.

Before a needle is inserted into the vascular soft tissues of the oral cavity, it should be determined whether the patient is at risk of excessive bleeding. In the presence of coagulopathies or other bleeding disorders, injection techniques with a greater incidence of positive aspiration should be avoided, if possible, in favor of supraperiosteal, periodontal ligament, intraosseous, or other techniques less likely to produce bleeding. Techniques that might be avoided when bleeding disorders are present include the maxillary (V_2) nerve block (high tuberosity approach), the posterior superior alveolar nerve block, the inferior alveolar nerve block, and probably both the Gow-Gates mandibular nerve block and the Akinosi-Vazirani mandibular nerve block. Although the latter two techniques have relatively low positive aspiration rates, bleeding following their administration is likely to occur deep in the tissues and therefore may be more difficult to manage. Modifications should be noted in the patient's record.

13. Sinus Problems?

Comment: Sinus problems can indicate the presence of an allergy (ASA class 2), which should be pursued in the

dialogue history, or an upper respiratory tract infection (ASA class 2), such as a common cold. The patient may experience some respiratory distress when placed in a supine position; distress may also be present if a dental dam is used. Specific treatment modifications—postponing treatment until the patient is able to breathe more comfortably, limiting the degree of recline in the dental chair, and foregoing use of a dental dam—are advisable.

14. Difficulty Swallowing?

Comment: Dysphagia, or the inability to swallow, can have many causes. Before the start of any dental treatment, the dentist should seek to determine the cause and severity of the patient's problem.

15. Diarrhea, Constipation, Blood in Stools?

Comment: This is an evaluation to determine whether gastrointestinal (GI) problems are present, many of which require patients to be medicated. Causes of blood in feces can range from benign, self-limiting events to serious life-threatening disease. Common causes include anal fissures, aspirin-containing drugs, bleeding disorders, esophageal varices, foreign-body trauma, hemorrhoids, neoplasms, use of orally administered steroids, the presence of intestinal polyps, and thrombocytopenia.

16. Frequent Vomiting, Nausea?

Comment: A multitude of causes can lead to nausea and vomiting. Medications, however, are among the most common causes of nausea and vomiting.⁹⁻¹¹ Opiates, digitalis, levodopa, and many cancer drugs act on the chemoreceptor trigger zone in the area postrema to induce vomiting. Drugs that frequently induce nausea include nonsteroidal antiinflammatory drugs, erythromycin, cardiac antidysrhythmics, antihypertensive drugs, diuretics, oral antidiabetic agents, oral contraceptives, and many GI drugs, such as sulfasalazine.⁹⁻¹¹

GI and systemic infections, viral and bacterial, are the second most common cause of nausea and vomiting.

17. Difficulty Urinating, Blood in Urine?

Comment: Hematuria, the presence of blood in the urine, requires evaluation to determine the cause; it is potentially indicative of urinary tract infection or obstruction.

18. Dizziness?

Comment: A positive response may indicate chronic postural (orthostatic) hypotension, symptomatic hypotension or anemia, or transient ischemic attack, a form of prestroke. In addition, patients with certain types of seizure disorders, such as the “drop attack,” may report fainting or dizzy spells.

The dentist may be advised to perform further evaluation, including a consultation with the patient's primary care physician. A trial of a beta-blocker represents an ASA class 3 risk, whereas chronic postural hypotension normally represents an ASA class 2 or 3 risk.

19. Ringing in Ears?

Comment: Tinnitus (an auditory sensation in the absence of sound heard in one or both ears, such as ringing, buzzing, hissing, or clicking) is a common side effect of certain drugs, including salicylates, indomethacin, propranolol, levodopa, aminophylline, and caffeine. It may be seen with multiple sclerosis, tumor, and ischemic infarction.

20. Headaches?

Comment: The presence of headache should be evaluated to determine the cause. Common causes include chronic daily headaches, cluster headaches, migraine headaches, and tension-type headaches. If necessary, consultation with the patient's primary care physician is warranted. The drug(s) used by the patient to manage his or her symptoms should be determined because many of these agents can effect clotting of blood that could influence the choice of local anesthetic technique (e.g., avoidance of techniques with a higher positive aspiration rate).

21. Fainting Spells?

Comment: Fainting (vasodepressor syncope) is the most common medical emergency in dentistry. It is most likely to occur during administration of a local anesthetic as a result of needle phobia (trypanophobia¹²). Prior recognition of needle phobia can usually result in prevention of the syncope episode.

22. Blurred Vision?

Comment: Blurred vision is an increasingly common finding as patients age. The leading causes of blurred vision and blindness include glaucoma, diabetic retinopathy, and macular degeneration. Double vision, or diplopia, usually results from extraocular muscle imbalance, the cause of which must be sought. Common causes include damage to third, fourth, or sixth cranial nerves secondary to myasthenia gravis, vascular disturbance, and intracranial tumor.

23. Seizures?

Comment: Seizures are common emergencies in the dental environment. The most likely candidate to have a seizure is the epileptic patient. Even epileptic patients whose seizures are well controlled with antiepileptic drugs may suffer seizures in stressful situations, such as might occur in the dental office. Before starting dental treatment, the dentist must determine the type of seizure, the frequency of occurrence,

and the drug(s) used to prevent the seizure. Treatment modification using SRPs (discussed later in this chapter) is desirable for patients with known seizure disorders. Sedation is highly recommended in the fearful epileptic dental patient as a means of preventing a seizure from developing during treatment. Epileptic patients whose seizures are under control (occur infrequently) are an ASA class 2 risk; those with more frequent seizures represent an ASA class 3 or 4 risk. A classic overdose of local anesthetic manifests itself as tonic-clonic seizure activity.

24. Excessive Thirst?

Comment: Polydipsia, or excessive thirst, is oftentimes seen in diabetes mellitus, diabetes insipidus, and hyperparathyroidism.

25. Frequent Urination?

Comment: Polyuria, or frequent urination, may be benign (too much fluid intake) or may be a symptom of diabetes mellitus, diabetes insipidus, Cushing syndrome, or hyperparathyroidism.

26. Dry Mouth? (Xerostomia)

Comment: Fear is a common cause of a dry mouth, especially in the dental environment. Many other causes of xerostomia are known, including Sjögren syndrome.

27. Jaundice?

Comment: Jaundice, or yellowness of skin, the whites of the eyes, and mucous membranes, is due to deposition of bile pigment resulting from an excess of bilirubin in the blood (hyperbilirubinemia). It is frequently caused by obstruction of bile ducts, excessive destruction of red blood cells (hemolysis), or disturbances in the functioning of liver cells. Jaundice is a sign that might be indicative of a benign problem, such as a gallstone obstructing the common bile duct, or it may be due to pancreatic carcinoma involving the opening of the common bile duct into the duodenum. Because amide local anesthetics undergo primary biotransformation in the liver, the presence of significant hepatic dysfunction (e.g., ASA class 4) may represent a relative or absolute contraindication to administration of these drugs. Articaine hydrochloride, which undergoes biotransformation both in the liver and (primarily) in the blood (by the enzyme plasma cholinesterase), is preferred in this patient population because it has an elimination half-life of 27 minutes (vs. 90 minutes for most other amide local anesthetics).

28. Joint Pain, Stiffness?

Comment: A history of joint pain and stiffness (arthritis) may be associated with long-term use of salicylates (aspirin) or other nonsteroidal antiinflammatory drugs, some of

which may alter blood clotting. Arthritic patients receiving long-term corticosteroid therapy may be at increased risk of acute adrenal insufficiency, especially if the patient has recently stopped taking the steroid. Although the risk is minimal, such patients may require a short course of steroid therapy or a modification (increase) of corticosteroid dose during more stressful dental procedures so that their body is better able to respond to any additional stress that might be associated with the treatment. If any doubt exists as to whether corticosteroid coverage is indicated, consultation with the patient's physician is recommended.

Because of possible difficulties in positioning the patient comfortably, modifications may be necessary to accommodate the patient's physical disability. Most patients receiving corticosteroids are categorized as ASA class 2 or 3 risk depending on the reason for the medication and the degree of disability present. Patients with significantly disabling arthritis are an ASA class 3 risk. Problems secondary to arthritis may require modification in positioning during local anesthetic injection.

III. Do You Have Or Have You Had

29. Heart Disease?

Comment: This is a survey question seeking to detect the presence of any and all types of heart disease. In the presence of a YES answer, the dentist must seek more specific detailed information as to the nature and severity of the problem and a list of any medications taken by the patient to manage the condition. Because many forms of heart disease are exacerbated in the presence of stress, consideration of the SRP becomes increasingly important.

30. Heart Attack, Heart Defects?

Comment: *Heart attack* is the lay term for myocardial infarction (MI). The dentist must determine the time that has elapsed since the patient suffered the MI, the severity of the MI, and the degree of residual myocardial damage to decide whether treatment modifications are indicated. Elective dental care traditionally has been withheld for the first 6 months after an MI,¹³ although recent evidence demonstrates that many patients are able to tolerate stress in as few as 3 to 4 weeks after experiencing an MI.^{14,15} Most post-MI patients are considered to be an ASA class 3 risk 6 months or more after the event; however, a patient who has experienced an MI within 6 months before the planned dental treatment should be considered an ASA class 4 risk until medical consultation with his or her cardiologist is obtained. When little or no residual damage to the myocardium is present, the patient may be considered an ASA class 2 risk after 6 months.

In the case of heart failure the degree of HF (weakness of the “pump”) present must be assessed through the dialogue history. When a patient has a more serious condition,

such as congestive HF or dyspnea (labored breathing) at rest, specific treatment modifications are warranted. In this situation the dentist must consider whether the patient requires supplemental O₂ during treatment. Whereas most HF patients are classified as an ASA class 2 (mild HF without disability) or an ASA class 3 (disability developing with exertion or stress) risk, the presence of dyspnea at rest represents an ASA class 4 risk. Effective pain control is essential in the ASA class 2 or 3 HF patient, but care must be taken in selecting the appropriate drugs and technique to prevent significant increases in the cardiac workload. Local anesthetics containing vasopressors are definitely indicated in these patients because they are more likely to provide successful pain control for dental procedures compared with “plain” local anesthetics. The smallest volume of the lowest epinephrine concentration (1:200,000 in North America) should be used.

In the case of congenital heart lesions, an in-depth dialogue history is required to determine the nature of the lesion and the degree of disability present. Patients can represent an ASA class 2, 3, or 4 risk. The dentist may recommend medical consultation, especially for the pediatric patient, to judge the severity of the lesion. Some dental treatments require prophylactic antibiotics.

31. Heart Murmurs?

Comment: Heart murmurs are common, but not all murmurs are clinically significant. The dentist should determine whether a murmur is functional (nonpathologic, or ASA class 2), whether clinical signs and symptoms of valvular stenosis or regurgitation are present (ASA class 3 or 4), and whether antibiotic prophylaxis is warranted. A major clinical symptom of a significant (organic) murmur is undue fatigue. [Table 10.1](#) provides guidelines for antibiotic prophylaxis for cardiovascular disorders (most recently revised in 2007).¹⁶ [Box 10.1](#) categorizes cardiac problems as to their requirements for antibiotic prophylaxis, and [Box 10.2](#) addresses prophylaxis and dental procedures specifically. As noted in the guidelines, antibiotic prophylaxis is *not* indicated for the administration of routine dental injection techniques through noninfected tissues. Guidelines for antibiotic prophylaxis in orthopedic patients with total joint replacements were published initially in 2003¹⁷ and were last revised in 2010.¹⁸

32. Rheumatic Fever?

Comment: A history of rheumatic fever should prompt the dentist to perform an in-depth dialogue history for the presence of rheumatic heart disease (RHD). In the presence of RHD, antibiotic prophylaxis may be indicated as a means of minimizing the risk of developing subacute bacterial endocarditis. Depending on the severity of the disease and the presence of a disability, RHD patients can be an ASA class 2, 3, or 4 risk. Additional treatment modifications may be advisable.

TABLE 10.1 Antibiotic Prophylaxis 2007^a

PDF Compressor Free Version

Situation	Agent	Adults	Children
Able to take oral medication	Amoxicillin	2 g	50 mg/kg
Unable to take oral medication	Ampicillin	2 g IM or IV	50 mg/kg IM or IV
	Cefazolin or ceftriaxone	1 g IM or IV	50 mg/kg IM or IV
Allergic to penicillins or ampicillin and able to take oral medication	Cephalexin ^{b,c}	2 g	50 mg/kg
	Clindamycin	600 mg	20 mg/kg
	Azithromycin or clarithromycin	500 mg	15 mg/kg
Allergic to penicillins or ampicillin and unable to take oral medication	Cefazolin or ceftriaxone ^c	1 g IM or IV	50 mg/kg IM or IV
	Clindamycin	600 mg IM or IV	20 mg/kg IM or IV

^aSingle dose 30 to 60 minutes before procedure.

^bOr other first- or second-generation oral cephalosporin in equivalent adult or pediatric dose.

^cCephalosporins should not be used in an individual with a history of anaphylaxis, angioedema, or urticaria with penicillins or ampicillin.

IM, Intramuscularly; IV, intravenously.

From Wilson W, Taubert KA, Gewitz M, et al: Prevention of infective endocarditis: guidelines from the American Heart Association: a guideline from the American Heart Association Rheumatic Fever, Endocarditis, and Kawasaki Disease Committee, Council on Cardiovascular Disease in the Young, and the Council on Clinical Cardiology, Council on Cardiovascular Surgery and Anesthesia, and the Quality of Care and Outcomes Research Interdisciplinary Working Group. *Circulation*. 2007;116:1736–1754.

• BOX 10.1 Cardiac Conditions Associated With the Highest Risk of Adverse Outcome From Endocarditis for Which Prophylaxis With Dental Procedures Is Recommended

- Prosthetic cardiac valve
- Previous infective endocarditis
- Congenital heart disease (except for the conditions listed previously, antibiotic prophylaxis is no longer recommended for any form of congenital heart disease)
- Unrepaired cyanotic congenital heart disease, including palliative shunts and conduits
- Completely repaired congenital heart defect with prosthetic material or device, whether placed by surgery or by catheter intervention, during the first 6 months after the procedure (prophylaxis is recommended because endothelialization of prosthetic material occurs within 6 months after the procedure)
- Repaired congenital heart disease with residual defects at the site or adjacent to the site of a prosthetic patch or prosthetic device (which inhibits endothelialization)
- Heart transplant recipients who develop cardiac valvulopathy

33. Stroke, Hardening of Arteries?

Comment: The dentist must pay close attention to stroke, cerebrovascular accident (CVA), or “brain attack” (the term increasingly used to relay to the lay public and health care professionals the urgency needed in prompt management of the person who has experienced a CVA). A patient who has experienced a CVA is at greater risk of experiencing another CVA or a seizure should he or she become hypoxic. The importance of effective pain control, through administration of local anesthetic solutions with vasopressors, cannot

• BOX 10.2 Dental Procedures for Which Endocarditis Prophylaxis Is Recommended for Patients

All dental procedures that involve manipulation of gingival tissue or the periapical region of teeth or perforation of the oral mucosa.

The following procedures and events do not need prophylaxis: routine anesthetic injections through noninfected tissue, taking of dental radiographs, placement of removable prosthodontic or orthodontic appliances, adjustment of orthodontic appliances, placement of orthodontic brackets, shedding of deciduous teeth, and bleeding from trauma to the lips or oral mucosa.

be overstated. Epinephrine concentrations should be minimized (e.g., 1:200,000) but epinephrine should be included in the local anesthetic solution as it increases anesthetic effectiveness (e.g., depth and duration of anesthesia are increased). The dentist should be especially sensitive to the presence of transient cerebral ischemia, a precursor to CVA; transient cerebral ischemia is an ASA class 3 risk. The post-CVA patient is an ASA class 4 risk within 6 months of the CVA, becoming an ASA class 3 risk 6 months or more after the incident (if the recovery is uneventful). In rare cases the post-CVA patient can be an ASA class 2 risk.

34. High Blood Pressure?

Comment: Elevated blood pressure (BP) measurements are frequently encountered in the dental environment secondary to the added stress that many patients associate with a visit to the dental office. With a history of HBP, the dentist must determine the drugs the patient is taking, the potential side effects of those medications, and any possible

interactions with other drugs that might be used during dental treatment. Guidelines for clinical evaluation of risk (ASA categories) are discussed in detail later in this chapter. The SRP is a significant factor in minimizing further elevation in BP during treatment.

35. Asthma, Tuberculosis, Emphysema, Other Lung Disease?

Comment: Determining the nature and severity of respiratory problems is an essential part of patient evaluation. Many acute problems developing in the dental environment are stress related, increasing the workload of the CVS and the O₂ requirements of many tissues and organs in the body. The presence of severe respiratory disease can greatly influence the planned dental treatment and the choice of drugs and technique if sedation is required.

Asthma (bronchospasm) is marked by a partial obstruction of the lower airway. The dentist must determine the nature of the asthma (intrinsic [allergic] vs. extrinsic [nonallergic]), the frequency of acute episodes, causal factors, the method of management of acute episodes, and drugs the patient may be taking to minimize the occurrence of acute episodes. Stress is a common precipitating factor in acute asthmatic episodes. The well-controlled asthmatic patient represents an ASA class 2 risk, whereas the well-controlled but stress-induced asthmatic patient is an ASA class 3 risk. Patients whose acute episodes are frequent and/or difficult to terminate (requiring hospitalization [status asthmaticus]) are ASA class 3 or 4 risk.

With a history of *tuberculosis* the dentist must first determine whether the disease is active or arrested. (Arrested tuberculosis is an ASA class 2 risk.) Medical consultation and dental treatment modification are recommended when such information is not easily determined.

Emphysema is a form of chronic obstructive pulmonary disease (COPD), also called *chronic obstructive lung disease*. The emphysematous patient has a decreased respiratory reserve from which to draw if cells of the body require additional O₂, which they do in stressful situations. Supplemental O₂ therapy during dental treatment is recommended in severe cases of emphysema; however, the severely emphysematous (ASA classes 3 and 4) patient should not receive more than 3 L of O₂ per minute.¹⁹ This flow restriction helps to ensure that the dentist does not eliminate the hypoxic drive, which is the emphysematous patient's primary stimulus for breathing. The emphysematous patient is an ASA class 2, 3, or 4 risk, depending on the degree of disability.

36. Hepatitis, Other Liver Disease?

Comment: Liver diseases may be transmissible (hepatitis A and hepatitis B) and may indicate the presence of hepatic dysfunction. A history of blood transfusion or past or present drug addiction should alert the dentist to a probable increase in the risk of hepatic dysfunction. (Hepatic

dysfunction is a common finding in the parenteral drug abuse patient.) Hepatitis C is responsible for more than 90% of cases of posttransfusion hepatitis, but only 4% of cases are attributable to blood transfusion; up to 50% of cases are related to intravenous drug use. Incubation of hepatitis C averages 6 to 7 weeks. The clinical illness is mild, usually asymptomatic, and characterized by a high rate (>50%) of chronic hepatitis.²⁰ Because most drugs undergo biotransformation in the liver, care must be taken when specific drugs and techniques of administration are selected for the patient with significant hepatic dysfunction. In general, local anesthetics and vasopressors are indicated for use, with consideration of minimizing the dose in patients with severe hepatic dysfunction (e.g., ASA class 4).

37. Stomach Problems, Ulcers?

Comment: The presence of stomach or intestinal ulcers may be indicative of acute or chronic anxiety and the possible use of medications such as tranquilizers, H₁ inhibitors, and antacids. Knowledge of which drugs are taken is important before additional drugs are administered in the dental office. A number of H₁ inhibitors are now over-the-counter drugs. Because many patients do not consider over-the-counter drugs "real" medications, the dentist must specifically question the patient about them. The presence of ulcers does not itself represent increased risk during treatment. In the absence of additional medical problems, the patient may represent an ASA class 1 or 2 risk.

38. Allergies to: Drugs, Foods, Medications, Latex?

Comment: The dentist must evaluate a patient's allergies thoroughly before administering dental treatment or drugs. The importance of this question and its full evaluation cannot be overstated. A complete and vigorous dialogue history must be undertaken before any dental treatment is begun, especially when a presumed or documented history of drug allergy is present. Adverse drug reactions (ADRs) are not uncommon. Many, if not most, ADRs are labeled as "allergy" by the patient and also on occasion by his or her health care professional. However, despite the great frequency with which allergy is reported, true documented and reproducible allergic drug reactions are relatively rare. A recent review of food allergy revealed 30% self-reporting of "food allergy" by the population studied, when the reality is that true food allergy is seen in 8% of children and 5% of adults.²¹

All ADRs must be evaluated thoroughly, especially when the dentist plans to administer or prescribe closely related medications for the patient during dental treatment. Alleged "allergy to Novocain" is frequently reported.

The incidence of true, documented, reproducible allergy to the amide local anesthetics is virtually nil.^{22,23} However, reports of alleged allergy to local anesthetics is common.^{24,25} Thorough investigation of the alleged allergy is essential if

the patient is not to be assigned the label of “allergic to all -caine drugs,” thereby precluding dental (and surgical) care in a normal manner. Coverage in all cases of care under general anesthesia is the alternative in these cases.

Reports of allergy to “epinephrine” or “adrenaline” also must be carefully evaluated. Most often, such reports prove to be simply an exaggerated physiologic response by the patient to the injected epinephrine or, more commonly, to endogenous catecholamine release in response to the act of receiving the injection (the “adrenal squeeze,” as a colleague called it recently).

Two essential questions that must be asked in all instances of alleged allergy are as follows: (1) can you describe your reaction?; (2) how was it managed?

The presence of allergy alone represents an ASA class 2 risk. No emergency situation is as frightening to health care professionals as the acute, systemic allergic reaction known as *anaphylaxis*. Prevention of this life-threatening situation is more gratifying than treatment of anaphylaxis once it develops.

Investigation into a patient’s report of “allergy to local anesthesia” is so important that it is discussed in depth in Chapter 18.

39. Family History of Diabetes, Heart Problems, Tumors?

Comment: Knowledge of family history can assist in determining the presence of a number of disorders that have a hereditary component.

40. AIDS?

Comment: Patients who have a positive test result for human immunodeficiency virus (HIV) are representative of every area of the population. The usual barrier techniques should be used to minimize risk of cross-infection for both the patient and staff members. Patients who are HIV positive are considered an ASA class 2, 3, 4, or 5 risk depending on the current status of their infection.

Proper care and handling of the local anesthetic syringe/needle must be observed, as in all situations, to avoid accidental needlestick injury.

41. Tumors, Cancer?

Comment: The presence or prior existence of cancer of the head or neck may require specific modification of dental therapy. Irradiated tissues have decreased resistance to infection, diminished vascularity, and reduced healing capacity. No specific contraindication exists to administration of drugs for the management of pain or anxiety in these patients; however, techniques of local anesthetic drug administration may, on rare occasion, be contraindicated if the tissues in the area of deposition have been irradiated. Many persons with cancer may be receiving long-term therapy with CNS depressants, such as antianxiety drugs, hypnotics, and opioids.

Consultation with the patient’s oncologist is recommended before dental treatment is begun. Past or current cancer does not necessarily increase ASA risk status. However, patients who are cachectic or hospitalized or are in poor physical condition may represent an ASA class 4 or 5 risk.

42. Arthritis, Rheumatism?

Comment: See *Comment* for question 28.

43. Eye Disease?

Comment: For patients with *glaucoma*, the need to administer a drug that diminishes salivary gland secretions will have to be addressed. Anticholinergics, such as atropine, scopolamine, and glycopyrrolate, are contraindicated in patients with acute narrow-angle glaucoma because these drugs produce an increase in intraocular pressure. Patients with glaucoma are usually an ASA class 2 risk. There is no contraindication to local anesthetic administration with or without vasopressors.

44. Skin Diseases?

Comment: Skin is an elastic, rugged, self-regenerating, protective covering for the body. The skin is also our primary physical presentation to the world, and as such displays a myriad of clinical signs of disease processes, including allergy and cardiac, respiratory, hepatic, and endocrine disorders.²⁶

45. Anemia?

Comment: Anemia is a relatively common adult ailment, especially among young adult women (iron-deficiency anemia). The dentist must determine the type of anemia present. The ability of the blood to carry O₂ or to give up O₂ to other cells is decreased in anemic patients. This decrease can become significant during procedures in which hypoxia is likely to develop. There is no contraindication to local anesthetic administration with or without vasopressors.

Sickle cell anemia is seen exclusively in black patients. Periods of unusual stress or of O₂ deficiency (hypoxia) may precipitate sickle cell crisis. Administration of supplemental O₂ during treatment is strongly recommended for patients with sickle cell disease. Persons with sickle cell trait represent an ASA class 2 risk, whereas those with sickle cell disease are an ASA class 2 or 3 risk.

In addition, congenital or idiopathic methemoglobinemia, although rare, represents a relative contraindication to administration of the amide local anesthetic prilocaine.²⁷

46. VD (Syphilis or Gonorrhea)?

47. Herpes?

Comment: When treating patients with sexually transmitted diseases, dentists and staff members are at risk of

infection. In the presence of oral lesions, elective dental care might be postponed. Standard barrier techniques, such as protective gloves, eye glasses, and masks, provide operators with a degree of (but not total) protection. Such patients usually represent ASA class 2 and 3 risks but may be an ASA class 4 or 5 risk in extreme situations where the disease is in an advanced stage.

48. Kidney, Bladder Disease?

Comment: The dentist should evaluate the nature of the renal disorder. Treatment modifications, including antibiotic prophylaxis, may be appropriate for several chronic forms of renal disease. Functionally anephric patients are an ASA class 3 or 4 risk, whereas patients with most other forms of renal dysfunction may be an ASA class 2 or 3 risk. [Box 10.3](#) shows a sample dental referral letter for a patient receiving long-term hemodialysis treatment as the result of chronic kidney disease.

49. Thyroid, Adrenal Disease?

Comment: The clinical presence of thyroid or adrenal gland dysfunction—hyperfunction or hypofunction—should prompt the dentist to use caution in administering certain drug groups (e.g., epinephrine to hyperthyroid patients, CNS depressants to hypothyroid patients). In most instances, however, the patient has previously seen a physician and has undergone treatment for thyroid disorder by the time he or she seeks dental treatment. In this case the patient is likely to be in a euthyroid state (normal blood levels of thyroid hormone) because of surgical intervention, irradiation, and/or drug therapy. The euthyroid state represents an ASA class 2 risk, whereas clinical signs and symptoms of hyperthyroidism or hypothyroidism represent an ASA class 3 risk or, in rare instances, an ASA class 4 risk. Patients who are clinically hyperthyroid are more likely to hyperrespond to “usual” doses of epinephrine (e.g., develop tachycardia, have elevated BP). Vital signs should be monitored preoperatively, perioperatively, and postoperatively in these situations.

Patients with hypofunctioning adrenal cortices have Addison disease and receive daily replacement doses of glucocorticosteroids. In extremely stressful situations, their body may be unable to respond appropriately, leading to loss of consciousness. Hypersecretion of cortisone, Cushing syndrome, rarely results in an acute life-threatening situation. Consideration of sedation, in the presence of dental anxiety, is recommended.

50. Diabetes?

Comment: A patient who responds positively to this question requires further inquiry to determine the type, severity, and degree of control of his or her diabetic condition. A patient with type 1 diabetes mellitus (insulin-dependent diabetes mellitus [IDDM]) or type 2 diabetes mellitus

• BOX 10.3 Hemodialysis Letter

Dear Doctor:

The patient who bears this note is undergoing long-term hemodialysis because of chronic kidney disease. In providing dental care to this patient, please observe the following precautions:

Dental treatment is most safely done 1 day after the last dialysis treatment or at least 8 hours thereafter. Residual heparin may make hemostasis difficult. (Some patients are receiving long-term anticoagulant therapy.)

We are concerned about bacteremic seeding of the arteriovenous shunt devices and heart valves. We recommend prophylactic antibiotics before and after dental treatment. Antibiotic selection and dosing can be tricky in renal failure.

We recommend 3 g of amoxicillin 1 hour before the procedure and 1.5 g of amoxicillin 6 hours later. For patients with penicillin allergies, 1 g of erythromycin 1 hour before the procedure and 500 mg of erythromycin 6 hours later is recommended.

Sincerely,

(non-IDDM [NIDDM]) is rarely at great risk of diabetes-related complications while receiving dental care or commonly administered dental drugs (e.g., local anesthetics, epinephrine, antibiotics, CNS depressants). The NIDDM patient is usually an ASA class 2 risk; the well-controlled IDDM patient, an ASA class 3 risk; and the poorly controlled IDDM patient, an ASA class 3 or 4 risk.

The greatest concerns during dental treatment relate to the possible effects of the dental care on subsequent eating and the development of hypoglycemia (low blood glucose level). Patients leaving a dental office with residual soft tissue anesthesia, especially in the mandible (e.g., tongue, lips), usually defer eating until sensation returns, a period potentially of 5 hours (lidocaine, mepivacaine, articaine, prilocaine with vasoconstrictor) or more (up to 12 hours) (bupivacaine with a vasoconstrictor). Diabetic patients have to modify their insulin doses if they do not maintain normal eating habits. Administration of the local anesthetic reversal agent phentolamine mesylate at the conclusion of dental treatment can significantly minimize the duration of residual soft tissue anesthesia.^{28,29}

IV. Do You Have Or Have You Had

51. Psychiatric Care?

Comment: The dentist should be aware of any nervousness (in general or specifically related to dentistry) or history of psychiatric care before treating the patient. Such patients may be receiving a number of drugs to manage their disorders that can potentially interact with drugs the dentist uses to control pain and anxiety ([Table 10.2](#)). Medical consultation should be considered in such cases. Extremely fearful patients are an ASA class 2 risk, whereas patients receiving psychiatric care and drug therapy represent an ASA class 2 or 3 risk.

TABLE 10.2 Dental Drug Interactions With Local Anesthetics and Vasopressors^a

PDF Compressor Free Version

Dental Drug	Interacting Drug	Consideration	Action
LAs	Cimetidine, β -adrenergic blocker (propranolol)	Hepatic metabolism of amide LA may be depressed	Use LAs cautiously, especially repeated doses
	Antidysrhythmics (mexiletine, tocainide)	Additive CNS, CVS depression	Use LAs cautiously—keep dose as low as possible to achieve anesthesia
	<i>CNS depressants: alcohol, antidepressants, antihistamines, benzodiazepines, antipsychotics, centrally acting antihypertensives, muscle relaxants, other LAs, opioids</i>	<i>Possible additive or supra-additive CNS, respiratory depression</i>	<i>Consider limiting maximum dose of LAs, especially with opioids</i>
	Cholinesterase inhibitors: antimuscarinics, antiglaucoma drugs	Antimuscarinic drug dose may require adjustment because LA inhibits neuromuscular transmission	Physician consultation
Vasoconstrictors; epinephrine	α -Adrenergic blockers (phenoxylbenzamine, prazosin); antipsychotics (haloperidol, entacapone)	Possible hypotensive response following large dose of epinephrine	Use vasoconstrictor cautiously—as low a dose as possible
	Catecholamine O-methyltransferase inhibitors (tolcapone, entacapone)	May enhance systemic actions of vasoconstrictors	Use vasoconstrictor cautiously—as low a dose as possible
	CNS stimulants (amphetamine, methylphenidate); ergot derivatives (dihydroergotamine, methysergide)	Effects of stimulant or vasoconstrictor may occur	Use vasoconstrictor cautiously—as low a dose as possible
	Cocaine	Effects of vasoconstrictors; can result in cardiac arrest	Avoid use of vasoconstrictor in patient under influence of cocaine
	Digitalis glycosides (digoxin, digitoxin)	Risk of cardiac dysrhythmias	Physician consultation
	Levodopa, thyroid hormones (levothyroxine, liothyronine)	Large doses of either (beyond replacement doses) may risk cardiac toxicity	Use vasoconstrictor cautiously—as low a dose as possible
	Tricyclic antidepressants (amitriptyline, doxepin, imipramine)	May enhance systemic effects of vasoconstrictor	Avoid use of levonordefrin or norepinephrine; use epinephrine cautiously—as low a dose as possible
	<i>Nonselective β-blockers (propranolol, nadolol)</i>	<i>May lead to hypertensive responses, especially to epinephrine</i>	<i>Monitor blood pressure after initial LA injection</i>

^aDrug-drug interactions of greater clinical significance are emboldened for emphasis.

CNS, Central nervous system; CVS, cardiovascular system; LA, local anesthetic.

From Ciancio SG. *AD/PDR Guide to Dental Therapeutics*. 5th ed. Chicago: American Dental Association; 2010.

52. Radiation Treatments?

53. Chemotherapy?

Comment: See *Comment* for question 41.

54. Prosthetic Heart Valve?

Comment: Patients with prosthetic (artificial) heart valves are no longer uncommon. The dentist's primary concern is to determine whether antibiotic prophylaxis is required.

Antibiotic prophylactic protocols were presented earlier in this chapter.¹⁶ The dentist should be advised to consult with the patient's physician (e.g., the cardiologist, the cardiothoracic surgeon) before providing treatment. Patients with prosthetic heart valves usually represent an ASA class 2 or 3 risk. Administration of local anesthetic drugs and vasopressors is indicated for these patients. Antibiotic prophylaxis is not indicated for the administration of routine dental injection techniques through noninfected tissues.¹⁶

55. Artificial Joint?

Comment: More than 1 million total joint replacements are performed annually in the United States.¹⁸ An expert panel of dentists, orthopedic surgeons, and infectious disease specialists convened by the American Dental Association and the American Academy of Orthopaedic Surgeons performed a thorough review of available data to determine the need for antibiotic prophylaxis to prevent hematogenous prosthetic joint infection in dental patients who have undergone total joint arthroplasty. The panel concluded that antibiotic prophylaxis is not recommended for dental patients with pins, plates, and screws, or for those who have undergone total joint replacement. However, dentists should consider antibiotic premedication in a small number of patients who may be at increased risk of the development of hematogenous total joint infection (Table 10.3).¹⁷

56. Hospitalization?

Comment: Determine the reason for hospitalization, the duration of the hospital stay, and any medications prescribed that the patient may currently be taking.

57. Blood Transfusions?

Comment: Determine the reason for the blood transfusion (e.g., prolonged bleeding, accident, type of surgery).

58. Surgeries?

Comment: Determine the nature (elective, emergency) and type of surgery (cosmetic, GI, cardiac, etc.) and the patient's physical status at the present time.

59. Pacemaker?

Comment: Cardiac pacemakers are implanted beneath the skin of the upper chest or the abdomen with pacing wires extending into the myocardium. The most frequent indication for the use of a pacemaker is the presence of a clinically significant dysrhythmia. Fixed-rate pacemakers provide a regular, continuous heart rate regardless of the heart's inherent rhythm, whereas the more commonly used demand pacemaker is activated only when the heart rate falls into an abnormal range. Although there is little indication for antibiotic administration in these patients, medical consultation is suggested before the start of treatment to obtain the specific recommendations of the patient's physician. The patient with a pacemaker is commonly an ASA class 2 or 3 risk during dental treatment.

In recent years, persons who have a significant risk of sudden unexpected death (e.g., cardiac arrest) as a result of electrical instability of the myocardium (e.g., ventricular fibrillation) have had implantable cardioverter-defibrillators placed below the skin of their chest. Medical consultation is strongly recommended for these patients.

TABLE 10.3 Orthopedic Prophylaxis

Patient Type	Condition Placing Patient at Risk
All patients during first 2 years following joint replacement	Not applicable
Immunocompromised/ immunosuppressed patients	Inflammatory arthropathies such as rheumatoid arthritis, systemic lupus erythematosus
Patients with comorbidities ^a	Previous prosthetic joint infection Malnourishment Hemophilia Human immunodeficiency virus infection Insulin-dependent (type 1) diabetes Malignancy

^aPatients potentially at increased risk of experiencing hematogenous total joint infection.

Data from American Dental Association, American Academy of Orthopedic Surgeons: antibiotic prophylaxis for dental patients with total joint replacements. *J Am Dent Assoc.* 2003;134:895–898.

60. Contact Lenses?

Comment: Contact lenses are commonly worn by persons with visual disturbances. Dental considerations for patients with contact lenses include removal of the lenses during administration of any sedation technique. Sedated patients may not close their eyes as frequently as unsedated patients, thereby increasing the likelihood of irritating the sclera and cornea of the eye. This is particularly recommended when inhalation sedation (N₂O-O₂) is used because any leakage of gases from the nasal hood is likely to irritate the eyes.

V. Are You Taking

61. Recreational Drugs?

Comment: Although most patients will not admit to the use of recreational drugs, it is important to ask the question. This becomes particularly important when the dentist is considering the use of CNS-depressant drugs for sedation or local anesthetics with or without a vasoconstrictor, such as epinephrine.

62. Drugs, Medications, Over-the-Counter Medicines (Including Aspirin), Natural Remedies?

Comment: Because many patients make a distinction between the terms *drug* and *medication*, questionnaires should use both terms to determine what drugs (pharmaceutically active substances) a patient has taken. Unfortunately, in today's world, the term *drug* often connotes the illicit use of medications (e.g., opioids). In the minds of

many patients, people “do” drugs but “take” medications for the management of medical conditions. Additionally, natural remedies can interact with medications, which may interact with drugs commonly used in dentistry.^{30,31}

The dentist must be aware of all medications and drugs that their patients take to control and treat medical disorders. Frequently, patients take medications without knowing the condition the medications are designed to treat; many patients do not even know the names of the drugs that they are taking. It is therefore important for dentists to have available one or more means of identifying these medications and of determining their indications, side effects, and potential drug interactions. Many excellent sources are available, including online services, such as ClinicalKey (<https://www.clinicalkey.com>), Lexi-comp (<http://www.wolterskluwercli.com/lexicomp-online/>), and Epocrates (<http://www.epocrates.com>). The *Physicians' Desk Reference (PDR)*,³² both in hard copy and online, offers a picture section that aids in identification of commonly prescribed drugs. The PDR also offers the *Physicians' Desk Reference for Herbal Medicines*.³³ The *ADA Guide to Dental Therapeutics* is another valuable reference for those drugs commonly used in dentistry and for the medications most often prescribed by physicians. Potential complications and drug interactions are stressed.³⁴

Knowledge of the drugs and medications patients are taking permits dentists to identify medical disorders, possible side effects—some of which may be of significance in dental treatment (e.g., postural hypotension)—and possible interactions between those medications and the drugs administered during dental treatment (see [Table 10.2](#)).

63. Tobacco in Any Form?

64. Alcohol?

Comment: Use of tobacco and/or alcohol over extended periods can lead to the development of potentially life-threatening problems, including neoplasms, hepatic dysfunction, and, in women, complications during pregnancy.

VI. Women Only

65. Are You or Could You Be Pregnant or Nursing?

Comment: Pregnancy is a relative contraindication to extensive elective dental care, particularly during the first trimester. Consultation with the patient's obstetrician-gynecologist is recommended before the start of any dental treatment. Administration of local anesthetics with or without epinephrine is acceptable during pregnancy. US Food and Drug Administration pregnancy categories are presented in [Box 10.4](#), and known fetal effects of local anesthetics and vasopressors are presented in [Table 10.4](#).

66. Taking Birth Control Pills?

• BOX 10.4 Food and Drug Administration Pregnancy Categories

- A: Studies have failed to demonstrate a risk to the fetus in any trimester.
- B: Animal reproduction studies have failed to demonstrate a risk to the fetus; no human studies are available.
- C: Given only after risks to the fetus are considered; animal reproduction studies have shown adverse effects on fetus; no human studies are available.
- D: Definite human fetal risks; may be given in spite of risks if needed in life-threatening conditions.
- X: Absolute fetal abnormalities; not to be used at any time during pregnancy because risks outweigh benefits.

From FDA pregnancy risk categories for local anesthetics: B—lidocaine, prilocaine; C—articaine, bupivacaine, mepivacaine. Available at: <https://chemm.nlm.nih.gov/pregnancy/categories.htm>. Accessed 29 November 2018.

TABLE 10.4 Known Fetal Effects of Drugs

Drug	Effect
Anesthetics, local	No adverse effects reported in dentistry
Articaine	No adverse effects reported in dentistry
Bupivacaine	No adverse effects reported in dentistry
Epinephrine	No adverse effects reported in dentistry
Lidocaine	No adverse effects reported in dentistry
Mepivacaine	No adverse effects reported in dentistry
Prilocaine	No adverse effects reported in dentistry

From Malamed SF. Sedation. *A Guide to Patient Management*. 6th ed. St Louis: Mosby; 2018.

VII. All Patients

67. Do You Have or Have You Had Any Other Diseases or Medical Problems NOT Listed on This Form?

Comment: The patient is encouraged to comment on specific matters not previously mentioned. Examples of several possibly significant disorders include acute intermittent porphyria, methemoglobinemia, atypical plasma cholinesterase, and malignant hyperthermia (MH).

To the best of my knowledge, I have answered every question completely and accurately. I will inform my dentist of any change in my health and/or medication.

Comment: This final statement is important from a medicolegal perspective because although instances of purposeful

lying on health histories are rare, they do occur. This statement should be accompanied by the date on which the history was completed and signed by the patient (or parent or guardian if the patient is a minor or is not legally competent) and the dentist who reviews the history. This in effect becomes a contract obliging the patient, parent, or guardian to report any changes in the patient's health or medications. Brady and Martinoff³ demonstrated that a patient's analysis of personal health is frequently overly optimistic, and that pertinent health matters are sometimes not immediately reported.

The medical history questionnaire should be updated on a regular basis, approximately every 3 to 6 months or after any prolonged lapse in treatment. In most instances the entire medical history questionnaire need not be redone. The dentist or dental hygienist need ask only the following questions:

1. Have you experienced any change in your general health since your last dental visit?
2. Are you now under the care of a physician? If so, what is the condition being treated?
3. Are you currently taking any drugs, medications, or over-the-counter products?

If any of these questions elicits a positive response, a detailed dialogue history should follow. For example, a patient may answer that no change has occurred in general health but may want to notify the dentist of a minor change in condition, such as the end of a pregnancy (It's a girl!) or a recent diagnosis of NIDDM or asthma.

In either situation, a written record of having updated the history should be appended to the patient's progress notes or the health history form. When the patient's health status has changed significantly since the last history was completed, the entire history should be redone (e.g., if cardiovascular disease was recently diagnosed in a patient and the patient is managing it with a variety of drugs that he or she was not previously taking).

In reality, most persons do not undergo significant changes in their health with any regularity. Thus one health history questionnaire can remain current for many years. Therefore the ability to demonstrate that a patient's medical history has been updated on a regular basis becomes all the more important.

The medical history questionnaire should be completed in ink. Corrections and deletions are made by the drawing of a single line through the original entry without obliterating it. The change is then added along with the date of the change. The dentist initials the change.

A written notation should be placed in the record whenever a patient reveals significant information during the dialogue history. As an example, when a patient answers affirmatively to the question about a "heart attack," the dentist's notation may read "2016" (the year the MI occurred).

Physical Examination

The medical history questionnaire is quite important to the overall assessment of a patient's physical and psychological

status. However, the questionnaire has limitations. For the questionnaire to be valuable, the patient must (1) be aware of the presence of any medical condition and (2) be willing to share this information with the dentist.

Most patients do not knowingly deceive their dentist by omitting important information from the medical history questionnaire, although cases in which such deception has occurred are on record. A patient seeking treatment for an acutely inflamed tooth decides to withhold from the dentist that he had an MI 2 months earlier because he knows that to tell the dentist this would mean that he would likely not receive the desired treatment (e.g., extraction).

The other factor, a patient's knowledge of his or her physical condition, is a much more likely cause of misinformation on the questionnaire. Most "healthy" persons do not visit their physician regularly for routine checkups. Recent information has suggested that annual physical examination should be discontinued in the younger healthy patient because it has not proved as valuable an aid in preventive medicine as was once thought.³⁵ In addition, most patients simply do not visit their physician on a regular basis, doing so instead whenever they become ill. From this premise, it stands to reason that the true state of the patient's physical condition may be unknown to the patient. Feeling well, although usually a good indicator of health, is not a guarantor of good health.⁸ Many disease entities may be present for a considerable length of time without exhibiting overt signs or symptoms that alert the patient of their presence (e.g., HBP, diabetes mellitus, cancer). When signs and symptoms are present, they are frequently mistaken for other, more benign problems. Although they may answer questions on the medical history questionnaire to the best of their knowledge, patients cannot give a positive response to a question unless they are aware that they have the condition. The first few questions on most history questionnaires refer to the length of time since the patient's last physical examination. The value of the remaining answers, dealing with specific disease processes, can be gauged from the patient's responses to these initial questions.

Because of these problems, which are inherent in the use of a patient-completed medical history questionnaire, the dentist must look for additional sources of information about the physical status of the patient. Physical examination of the patient provides much of this information. This consists of the:

1. monitoring of vital signs
2. visual inspection of the patient
3. function tests, as indicated
4. auscultation of heart and lungs and laboratory tests, as indicated

Minimal physical evaluation for all potential patients should consist of (1) measurement of vital signs, and (2) visual inspection of the patient.

The primary value of the physical examination is that it provides the dentist with important (up-to-the-minute) information concerning the physical condition of the patient immediately before the start of treatment, as

contrasted with the questionnaire, which provides historical (dated) information. The patient should undergo a minimal physical evaluation before the start of any dental treatment. Readings obtained at this time, called *baseline vital signs*, are recorded in the patient's record.

Vital Signs

The six vital signs are:

1. BP
2. heart rate (pulse) and rhythm
3. respiratory rate
4. temperature
5. height
6. weight
 - a. body mass index (BMI)

Vital signs and guidelines for their interpretation follow.

Blood Pressure

Technique

The following technique is recommended for the accurate manual determination of BP.³⁶ A stethoscope and sphygmomanometer (BP cuff) are the required equipment. The most accurate and reliable of these devices is the mercury-gravity manometer. The aneroid manometer, probably the most frequently used, is calibrated to be read in millimeters of mercury (mmHg) and is also quite accurate if well maintained. Rough handling of the aneroid manometer may lead to erroneous readings. It is recommended that the aneroid manometer be recalibrated at least annually by checking it against a mercury manometer. Automatic BP monitors are today commonplace as their accuracy has increased, while their cost has decreased, ranging from well under US\$100 to several thousand dollars. Likewise, their accuracies differ. The use of automatic monitors simplifies the monitoring of vital signs, but dentists should be advised to check the accuracy of these devices periodically (comparing values with those of a mercury or aneroid manometer).

Although mercury manometers are the most accurate, their use has become increasingly rare because they are too bulky for easy carrying, and mercury spills are potentially dangerous.³⁷

Aneroid manometers are easy to use, somewhat less accurate than the mercury manometer, and are more delicate, requiring recalibration at least annually or when dropped or bumped.³⁷

Automatic devices containing all equipment in one unit negate the need for a separate stethoscope and manometer. Most are easy to use, whereas more expensive devices have automatic inflation and deflation systems and readable printouts of both BP and heart rate. As with the aneroid manometer, automatic BP systems are somewhat fragile, requiring recalibration on a regular schedule or when bumped or dropped. Body movements may influence accuracy, and even the most accurate devices do not work on certain people.³⁷

Automatic BP monitors that fit on the patient's wrist are also available and easy to use. However, BP measurements at the wrist may not be as accurate as those taken at the upper arm, and systematic error can occur as a result of differences in the position of the wrist relative to the heart (see later discussion).^{38,39}

For routine preoperative monitoring of BP, the patient should be seated in the upright position. The arm should be at the level of the heart—relaxed, slightly flexed, and supported on a firm surface (e.g., the armrest of the dental chair). The patient should be permitted to sit for at least 5 minutes before the BP recording is taken. This will permit the patient to relax somewhat so that the recorded BP will be closer to the patient's baseline reading. During this time, other nonthreatening procedures may be performed, such as review of the medical history questionnaire.

The BP cuff should be deflated before it is placed on the arm. The cuff should be wrapped evenly and firmly around the arm, with the center of the inflatable portion over the brachial artery and the rubber tubing lying along the medial aspect of the arm. The lower margin of the cuff should be placed approximately 2 to 3 cm (1 inch) above the antecubital fossa (the patient should still be able to flex the elbow with the cuff in place). A BP cuff is too tight if two fingers cannot be placed under the lower edge of the cuff. Too tight a cuff will decrease venous return from the arm, leading to erroneous measurements. A cuff is too loose (a much more common problem) if it may be easily pulled off of the arm with gentle tugging. A slight resistance should be present when a cuff is properly applied.

The radial pulse in the wrist should be palpated and the pressure in the cuff increased rapidly to a point approximately 30 mmHg above the point at which the pulse disappears. The cuff should then be slowly deflated at a rate of 2 to 3 mmHg/s until the radial pulse returns. This is termed the palpatory systolic pressure. Residual pressure in the cuff should be released to permit venous drainage from the arm.

Determination of BP by the more accurate auscultatory method requires palpation of the brachial artery, located on the medial aspect of the antecubital fossa. The earpieces of the stethoscope should be placed facing forward, firmly in the recorder's ears. The diaphragm of the stethoscope must be placed firmly on the medial aspect of the antecubital fossa over the brachial artery. To reduce extraneous noise, the stethoscope should not touch the BP cuff or rubber tubing.

The BP cuff should be rapidly inflated to a level 30 mmHg above the previously determined palpatory systolic pressure. Pressure in the cuff should be gradually released (2 to 3 mm/s) until the first *sound* (a tapping sound) is heard through the stethoscope. This is referred to as the *systolic blood pressure*.

As the cuff deflates further, the sound undergoes changes in quality and intensity. As the cuff pressure approaches the diastolic pressure, the sound becomes dull and muffled and then ceases. The diastolic BP is best indicated as the point

of complete cessation of sound. In some instances, however, complete cessation of sound does not occur—the sound gradually fading. The point at which the sound became muffled is the diastolic pressure. The cuff should be slowly deflated to a point 10 mmHg beyond the point of disappearance and then totally deflated.

Should additional recordings be necessary, a wait of at least 15 seconds is recommended before reinflation of the BP cuff. This permits blood trapped in the arm to leave, providing more accurate readings.

BP is recorded in the patient's record as a fraction: 130/90 R or L (with "R" and "L" referring to the right arm and the left arm, respectively, being the arm on which the BP is recorded).

Common Errors in Technique

Some common errors associated with recording BP lead to inaccurate readings (too high or too low). Lack of awareness of these may lead to unnecessary referral for medical consultation, added financial burden to the patient, and a loss of faith in the dentist.

1. Applying the BP cuff too loosely produces falsely elevated readings. This is probably the most common error in recording BP.⁴⁰
2. Use of the wrong cuff size can result in erroneous readings. A "normal adult" BP cuff placed on an obese arm will produce falsely elevated readings. This same cuff applied to the very thin arm of a child or adult will produce falsely low readings. Sphygmomanometers are available in a variety of sizes. The "ideal" cuff should have a bladder length that is 80% and a width that is at least 40% of the arm's circumference.³⁸ Recommended cuff sizes are presented in Table 10.5.³⁷
3. An auscultatory gap may be present (Fig. 10.6), representing a loss of sound (a period of silence) between systolic and diastolic pressures, with the sound reappearing at a lower level. For example, systolic sounds are noticed at 230 mmHg; however, the sound then disappears at 198 mmHg, reappearing at approximately 160 mmHg. All sound is lost at 90 mmHg. An auscultatory gap occurs between 160 and 198 mmHg. In this situation, if the person recording the BP had not estimated the systolic BP by palpation before auscultation, the cuff might be inflated to some arbitrary pressure (e.g., 165 mmHg). At this level, the recorder would pick up no sound because this lies within the auscultatory gap. Sounds would first be noted at 160 mmHg, with their disappearance at 90 mmHg, levels well within therapy limits (see guidelines for BP in the next subsection). In reality, however, this patient has a BP of 230/90 mmHg, a significantly elevated BP that represents a greater risk to the patient during treatment (this patient is not considered to be a candidate for elective dental care). Although the auscultatory gap occurs only infrequently, the possibility of error may be eliminated by use of the palpatory technique. A palpable pulse *will* be present throughout the gap (appearing in our example at 230 mmHg), although

TABLE 10.5 Recommended Blood Pressure Cuff Sizes

Arm Circumference (cm)	Cuff	Cuff Size (cm)
22–26	Small adult	12 × 22
27–34	Adult	16 × 30
35–44	Large adult	16 × 36
45–52	Adult thigh	16 × 42

From Pickering TG, Hall JE, Appel LJ, et al. Recommendations for blood pressure measurement in humans and experimental animals: part 1: blood pressure measurement in humans: a statement for professionals from the subcommittee of professional and public education of the American Heart Association Council on High Blood Pressure Research. *Hypertension*. 2005;45:142–161.

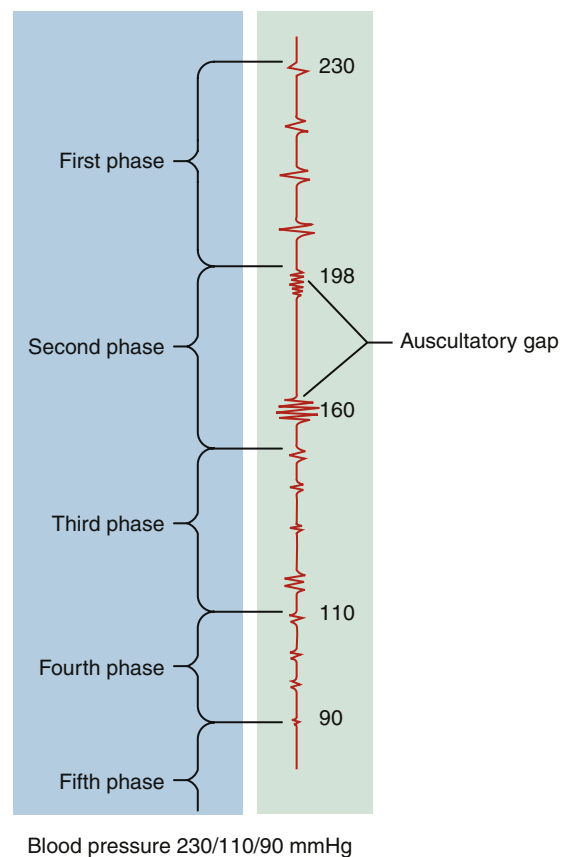


Fig. 10.6 Auscultatory gap. (From Malamed SF. Sedation. *A Guide to Patient Management*. 6th ed. St Louis: Mosby; 2018.)

the sound is not present. Although there is no pathologic significance to its presence, the auscultatory gap is found most often in patients with HBP.

4. The patient may be anxious. Having one's BP recorded may produce anxiety, so-called white coat hypertension,⁴¹ causing transient elevations in BP, primarily the systolic pressure (up to 7.9 mmHg⁴²). For this reason, it is recommended that baseline measurements of vital

signs be obtained at a visit before the start of treatment, perhaps the first office visit, when the patient will only be completing a physical examination. Blood pressure should be within normal limits for the particular patient at this time.

5. BP is based on the Korotkoff sounds (Fig. 10.7) produced by the passage of blood through occluded, partially occluded, or unoccluded arteries. Watching a mercury column or needle on an aneroid manometer for “pulsations” leads to falsely elevated systolic pressures. Pulsations of the needle are noted approximately 10 to 15 mmHg before the first Korotkoff sounds are heard.
6. Use of the left arm or the right arm will produce differences in recorded BP. A difference of greater than 10 mmHg may occur in readings between arms in approximately 20% of patients.⁴³ There is no clear pattern. The difference does not appear to be determined by whether the patient is right-handed or left-handed.⁴³

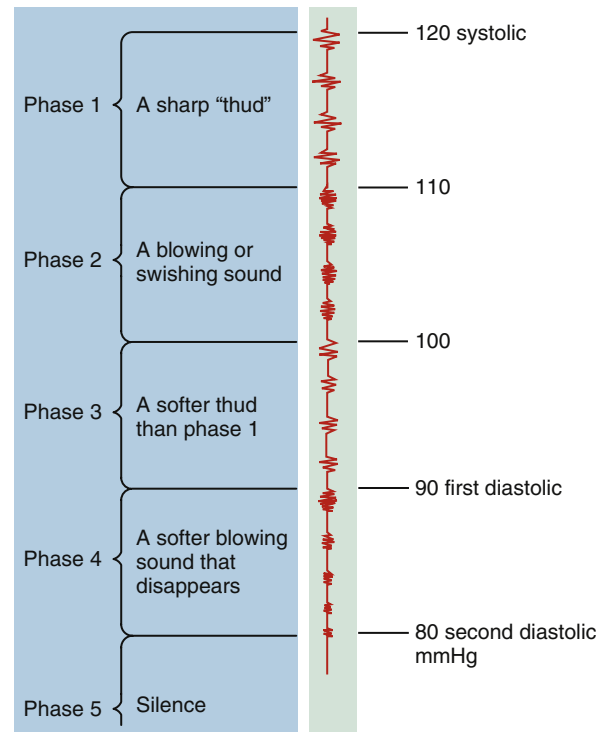
Guidelines for Clinical Evaluation

The University of Southern California (USC) School of Dentistry physical evaluation system is based on the ASA physical status classification system.⁴⁴ It details four risk categories based on a patient’s medical history and physical evaluation. The ASA categories for BP recordings in adults are presented in Table 10.6.^{45,46}

For the adult patient with a baseline BP in the ASA class 1 range (<140/<90 mmHg), it is suggested that the BP be recorded every 6 months unless specific dental procedures demand more frequent monitoring. The parenteral administration of any drug (local anesthesia; intramuscular, intravenous, intranasal, or inhalation sedation; or general anesthesia) mandates the more frequent recording of vital signs.

Patients with BP in the ASA class 2, 3, or 4 category should be monitored more frequently (e.g., at every appointment), as outlined in the guidelines. Patients with known HBP should also have their BP monitored at each visit to determine whether their BP is adequately controlled. It is impossible to gauge a BP by “looking” at a person or by asking, “How do you feel?” The routine monitoring of BP in all patients according to the treatment guidelines will effectively minimize the occurrence of acute complications of HBP (e.g., hemorrhagic CVA).

Still another reason for routine monitoring BP relates to the management of medical emergencies. After the basic steps of management (P→C→A→B) in each emergency, certain specific steps are necessary for definitive treatment (D). Primary among these is monitoring of vital signs, particularly BP. BP recorded during an emergency situation provides an important indicator of the status of the CVS. However, unless a baseline or nonemergency BP measurement was recorded earlier, the BP obtained during the emergency is less relevant. A recording of 80/50 mmHg is less ominous in a patient with a preoperative reading of 100/60 mmHg than if the pretreatment recording was 190/110 mmHg. The absence of BP is always an indication for cardiopulmonary resuscitation.



Blood pressure = 120/90/80 mmHg

• **Fig. 10.7** Korotkoff sounds. (From Malamed SF. *Sedation: A Guide to Patient Management*. 6th ed. St Louis: Mosby; 2018.)

The normal range for BP in younger patients is somewhat lower than that in adults. Table 10.7 presents a normal range of vital signs (including BP) in infants and children.

Heart Rate and Rhythm

Technique

Heart rate (pulse) and rhythm may be measured at any readily accessible artery (Fig. 10.8). Most commonly used for routine measurement are the brachial artery, located on the medial aspect of the antecubital fossa, and the radial artery, located on the radial and ventral aspects of the wrist.

When palpating an artery, one should use the fleshy portions of the index and middle fingers. Gentle pressure must be applied to feel the pulsation. Do not press so firmly that the artery is occluded and no pulsation is felt. The thumb ought not to be used to monitor pulse because it contains a fair-sized artery.

Automatic BP devices and pulse oximeters provide a measurement of the heart rate.

Guidelines for Clinical Evaluation

Three factors should be evaluated while the pulse is monitored:

1. the heart rate (recorded as beats per minute)
 2. the rhythm of the heart (regular or irregular)
 3. the quality of the pulse (thready, weak, bounding, full)
- Heart rate should be evaluated for a minimum of 30 seconds, ideally for 1 minute. The normal resting adult heart rate ranges from 60 to 110 beats per minute. It is often

TABLE 10.6

Guidelines for Blood Pressure (Adult)

PDF Compressor Free Version

American Society of

Blood Pressure (mmHg)	Anesthesiologists Classification	Dental Therapy Consideration
<140 (systolic) and <90 (diastolic)	1	<ol style="list-style-type: none"> 1. Routine dental management 2. Recheck in 6 months unless specific treatment dictates more frequent monitoring
140–159 and/or 90–94	2	<ol style="list-style-type: none"> 1. Recheck blood pressure before dental treatment for three consecutive appointments; if all measurements exceed the guideline levels, medical consultation is indicated 2. Routine dental management 3. Stress reduction protocol as indicated
160–199 and/or 95–114	3	<ol style="list-style-type: none"> 1. Recheck blood pressure in 5 min 2. If blood pressure is still elevated, medical consultation before dental therapy is warranted 3. Routine dental therapy 4. Stress reduction protocol
≥200 and/or ≥115	4	<ol style="list-style-type: none"> 1. Recheck blood pressure in 5 min 2. Immediate medical consultation if blood pressure is still elevated 3. No dental therapy, routine or emergency,^a until elevated blood pressure is corrected 4. Refer to hospital if immediate dental therapy is indicated

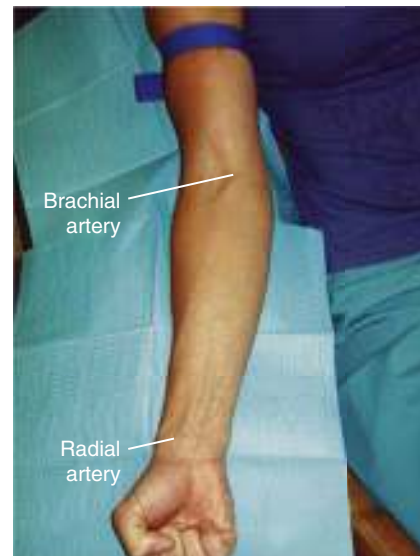
^aWhen the blood pressure of the patient is slightly above the cutoff for category 4 and anxiety is present, inhalation sedation may be used in an effort to reduce the blood pressure (via the elimination of stress).

TABLE 10.7

Normal Vital Signs According to Age

Age	Heart Rate (beats/min)	Blood Pressure (mmHg)	Respiratory Rate (breaths/min)
3–6 months	90–120	70–90/50–65	30–45
6–12 months	80–120	80–100/55–65	25–40
1–3 years	70–110	90–105/55–70	20–30
3–6 years	65–110	95–110/60–75	20–25
6–12 years	60–95	100–120/60–75	14–22
>12 years	55–85	110–135/65–85	12–18

Modified from Hartman ME, Cheifitz IM: Pediatric emergencies and resuscitation. In: Kliegman RM, Stanton BF, St Geme JW III, Schor NF, Behrman RE, eds. *Nelson Textbook of Pediatrics*. 19th ed. Philadelphia: Saunders; 2011.



• **Fig. 10.8** Pulse may be measured at any accessible artery. (From Malamed SF. *Medical Emergencies in the Dental Office*. 7th ed. St Louis: Mosby; 2015.)

lower in a well-conditioned athlete and elevated in the fearful individual. However, clinically significant disease may also produce a slow (bradycardia [<60 per minute]) or rapid (tachycardia [>110 per minute]) heart rate. It is suggested that any heart rate below 60 or above 110 beats per minute (adult) be evaluated (initially via dialogue history). Where no obvious cause is present (e.g., endurance sports, anxiety,

prescription drugs [e.g. β -blockers]), medical consultation should be considered.

The healthy heart maintains a relatively regular rhythm. Irregularities in rhythm should be confirmed and evaluated via dialogue history and/or medical consultation before the start of treatment. The occasional *premature ventricular contraction (PVC)* is so common that it is not necessarily

considered abnormal. PVCs may be produced by smoking, fatigue, stress, various drugs (e.g., epinephrine), and alcohol. Frequent PVCs are associated with aortic disease or ischemic myocardium. However, when PVCs are present at a frequency of five or more per minute, especially if they appear at irregular intervals, medical consultation should definitely be sought. Patients with five or more PVCs per minute are considered to be at greater risk of sudden cardiac death (ventricular fibrillation) and are more likely to have implanted automatic defibrillators.^{47,48} Clinically, PVCs detected by palpation appear as a break in a generally regular rhythm in which a longer-than-normal pause (a “skipped beat”) is noted (“felt”) followed by the resumption of a regular rhythm.

A second disturbance of the pulse is termed *pulsus alternans*.⁴⁹ It is not truly a dysrhythmia, but is a regular heart rate that is characterized by a pulse in which strong and weak beats alternate. It is produced by the alternating contractile force of a diseased left ventricle. Pulsus alternans is observed frequently in severe left ventricular failure, severe arterial HBP, and coronary artery disease. Medical consultation is indicated.

Many other dysrhythmias may be noted by palpation of the pulse. The “irregular irregularity” of *atrial fibrillation* is noted in hyperthyroid patients and warrants pretreatment consultation. *Sinus dysrhythmia* is detected frequently in healthy adolescent patients. It is noted as an increase in the heart rate followed by a decrease in rate that correlates with the breathing cycle (the heart rate increases during inspiration, decreases with expiration). Sinus dysrhythmia is not indicative of any cardiac abnormality and therefore does not require pretreatment consultation.

The quality of the pulse is commonly described as full, bounding, thready, or weak. These adjectives relate to the subjective “feel” of the pulse and are used to describe situations such as a “full bounding” pulse (as noted in severe arterial HBP) or a “weak thready” pulse (often noted in hypotensive patients with signs of shock). Table 10.7 presents the range of normal heart rates in children of various ages.

Technique

Respiratory rate must be determined surreptitiously. Patients aware that their breathing is observed will not breathe normally. It is recommended therefore that respiration be monitored immediately after the heart rate. The observer’s fingers are left on the patient’s radial or brachial pulse after the heart rate has been determined; however, the observer counts respirations (by observing the rise and fall of the chest) instead for a minimum of 30 seconds, ideally for 1 minute.

Guidelines for Clinical Evaluation

Normal respiratory rate for an adult is 14 to 18 breaths per minute. Bradypnea (abnormally slow rate) may be produced by, among other causes, opioid administration, whereas tachypnea (abnormally rapid rate) is seen with fever, fear (e.g., hyperventilation), and alkalosis. The most common change in ventilation noted in the dental environment

is hyperventilation, an abnormal increase in the rate and depth of respiration. It is also seen, but much less frequently in the dental environment, in diabetic acidosis. The most common cause of hyperventilation in dental and surgical settings is extreme psychological stress.

Any significant variation in respiratory rate should be evaluated before treatment. The absence of spontaneous ventilation is always an indication for controlled ventilation (aka “rescue breathing”) ($P \rightarrow A \rightarrow B$). Table 10.7 presents the normal range of respiratory rate at different ages.

BP, heart rate and rhythm, and respiratory rate provide information about the functioning of the cardiorespiratory system. It is recommended that they be recorded as part of the routine physical evaluation for all potential patients. Recording of the remaining vital signs—temperature, height, weight, and BMI—although desirable, may be considered as optional.

Temperature

Technique

Temperature should be monitored orally. The thermometer, sterilized and shaken down, is placed under the tongue of the patient, who has not eaten, smoked, or had anything to drink in the previous 10 minutes. The thermometer remains in the closed mouth for 2 minutes before removal. Disposable thermometers (Fig. 10.9) and digital thermometers (Fig. 10.10) are equally accurate and easy to use. Forehead thermometers are effective when the patient’s behavior will not permit use of an oral thermometer (Fig. 10.11).

Guidelines for Clinical Evaluation


The “normal” oral temperature of 37.0°C (98.6°F) is only an average. The true range of normal is considered to be from 36.11°C to 37.56°C (97°F to 99.6°F). Temperatures vary during the day (by 0.5°F to 2.0°F), with the lowest in the early morning and the highest in the late afternoon.

Fever represents an increase in temperature beyond 37.5°C (99.6°F). Temperatures in excess of 38.33°C (101°F) usually indicate the presence of an active disease process. Evaluation of the cause of the fever is necessary before treatment. When dental or periodontal infection is considered to be a probable cause of elevated temperature, immediate treatment (e.g., incision and drainage, pulpal extirpation, or extraction) and antibiotic and antipyretic therapy are indicated. If the patient’s temperature is 40.0°C (104°F) or higher, pretreatment medical consultation is indicated. The planned treatment should be postponed, if possible, until the cause of the elevated temperature is determined and treated.

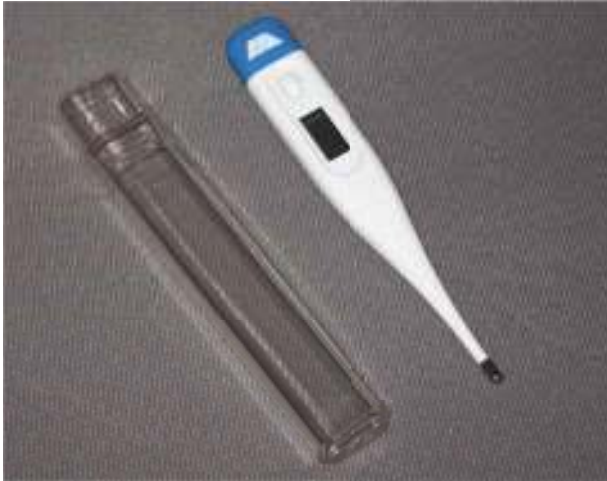Height and Weight

Technique

Patients should be asked to state their height and weight. The range of normal height and weight is quite variable and is available on charts developed by various insurance



• **Fig. 10.9** Disposable thermometer. (From Potter PA, Perry AG. *Fundamentals of Nursing*. 7th ed. St Louis: Mosby; 2009.)



• **Fig. 10.10** Digital thermometer. (Courtesy Sedation Resource, Lone Oak, Texas, United States.)



• **Fig. 10.11** Forehead thermometers are effective when the patient's behavior will not permit use of an oral thermometer. (From Gerdin J. *Health Careers Today*. 7th ed. St Louis: Mosby; 2007.)

companies. New guidelines of the range of normal height and weight have been published (Table 10.8).

Guidelines for Clinical Evaluation

Grossly obese or excessively underweight patients may have an active disease process. Obesity will be noted in various

endocrine disorders, such as Cushing syndrome, whereas extreme loss of weight may be noted in pulmonary tuberculosis, malignancy, and hyperthyroidism. Anorexia nervosa should also be considered in extremely underweight individuals. In all instances where gross obesity or extreme loss of weight is noted, pretreatment medical consultation is recommended.

Excessively tall persons are referred to as *giants*, whereas persons who are decidedly shorter than average are called *dwarfs*. In both instances, endocrine gland dysfunction may be present. Medical consultation is usually not necessary for these patients.

Body Mass Index

BMI is a number calculated based on the weight and height of a person. BMI is a fairly reliable indicator of body fatness for most people and is used primarily as a screening device for weight categories that may be associated with health problems.⁵⁰ BMI does not measure body fat directly, but research has demonstrated that BMI correlates to direct measures of body fat, such as by underwater weighing and dual energy X-ray absorptiometry.^{51,52} BMI is used as a screening tool, not as a diagnostic tool, to identify possible weight problems for adults and children. If BMI indicates excessive weight, the health care provider would perform additional evaluations—such as skinfold thickness measurements, dietary and physical activity evaluations, and family history—to determine if the excessive weight represents a health risk. Overweight and obese individuals are at increased risk of many diseases (comorbidities) and health conditions (Box 10.5).⁵³

BMI ranges (Table 10.9) are based on the relationship between body weight and disease and death.⁵⁴ BMI is calculated in the same way for both adults and children, and is based on the following formulas:

With the metric system the formula for BMI calculation is

$$\text{Weight (kg)} \div [\text{Height (m)}]^2.$$

For pounds and inches the formula for BMI calculation is

$$\text{Weight (lb)} \div [\text{Height (in)}]^2 \times 703.$$

For a patient weighing 70 kg and 170 cm in height, the calculation is

$$70 \div (1.7)^2 = 24.22.$$

For a patient weighing 154 lb and 66 inches in height, the calculation is

$$154 \div (66)^2 \times 703 = 24.85.$$

Guidelines for Clinical Evaluation

For both female and male adults (aged 20 years or older), the standard weight categories are included in Table 10.9. A BMI calculator is presented in Table 10.10.

TABLE 10.8 Acceptable Weight (in Pounds) for Men and Women^a

PDF Compressor Free Version

Height (Inches)	Age (Years)	
	19–34	≥35
60	97–128	108–138
61	101–132	111–143
62	104–137	115–148
63	107–141	119–152
64	111–146	122–157
65	114–150	126–162
66	118–156	130–167
67	121–160	134–172
68	125–164	138–178
69	129–169	142–183
70	132–174	146–188
71	136–179	151–194
72	140–184	155–199
73	144–189	159–205
74	148–195	164–210

^aWeights based on weight without shoes or clothes. Modified from Department of Health & Human Services, Department of Agriculture. *Dietary Guidelines for Americans*. Washington, DC: Department of Health & Human Services/Department of Agriculture; 2005.

• BOX 10.5 Comorbidities Associated With Overweight and Obesity in Adults

High blood pressure
 Dyslipidemia (e.g., elevated LDL cholesterol level; low HDL level)
 Type 2 diabetes
 Coronary artery disease
 Sleep apnea and respiratory problems
 Cerebrovascular accident
 Gallbladder disease
 Osteoarthritis
 Some cancers (endometrial, breast, and colon)

HDL-high density lipoprotein
 LDL-low density lipoprotein
 From Malamed SF. Sedation. *A Guide to Patient Management*. 6th ed. St Louis: Mosby; 2018.

It is estimated that between 5 million and 11 million Americans are morbidly obese—about 1 in 20 people.⁵⁵

The correlation between BMI and body fatness is fairly strong; however, the correlation varies by sex, race, and age.^{56,57} For the same BMI, women tend to have more body fat than men; older people tend to have more body fat than younger adults; and highly trained athletes may have a high BMI because of increased muscle mass rather than increased body fat.⁵⁷

TABLE 10.9 Body Mass Index Classifications

Body Mass Index	Weight Status
<18.5	Underweight
18.5–24.9	Normal
25.0–29.9	Overweight
30.0–39.9	Obese
40.0–49.9	Morbid obesity
≥50	Super morbid obesity

From Malamed SF. *Medical Emergencies in the Dental Office*. 7th ed. St Louis: Mosby; 2015.

BMI is useful in dentistry as a means of determining a patient's potential risk of developing acute medical problems. Persons with BMIs of 30 to 39.9 (obese) would be considered an ASA class 2 or 3 risk, while those with values of 40 or above (morbid obesity) would be considered either ASA class 3 or class 4 after further evaluation of their medical history to determine the presence and severity of the comorbidities associated with obesity (see [Box 10.5](#)).

Visual Inspection of the Patient

Visual observation of the patient provides the dentist with valuable information concerning the patient's medical status and level of apprehension toward the planned treatment. Observation of the patient's posture, body movements, speech, and skin can assist in a diagnosis of possibly significant disorders that may previously have been undetected. The reader is referred to other textbooks for a more detailed discussion of visual inspection of the dental patient.^{26,58,59}

Additional Evaluation Procedures

Following completion of these three steps (medical history questionnaire, measurement of vital signs, and physical examination), it will occasionally be necessary to follow up with additional evaluation for specific medical disorders. This examination may include auscultation of the heart and lungs, testing for urinary or blood glucose levels, retinal examination, function tests for cardiorespiratory status (e.g., breath-holding test, match test), electrocardiographic examination, and blood chemistries. At present, many of these tests are used in dental offices, but they do not represent a standard of care in dentistry.

Dialogue History

After patient information has been collected, the dentist reviews with the patient any positive responses on the questionnaire, seeking to determine the severity of these disorders and any potential risk that they might represent during the planned treatment. This process is termed the *dialogue history*, and it is an integral part of patient evaluation.

TABLE
10.10

Body Mass Index Calculator

PDF Compressor Free Version

Height (Inches)	Weight (lb)															
	100	110	120	130	140	150	160	170	180	190	200	210	220	230	240	250
60	20	21	23	25	27	29	31	33	35	37	39	41	43	45	47	49
61	19	21	23	25	26	28	30	32	34	36	38	40	42	43	45	47
62	18	20	22	24	26	27	29	31	33	35	37	38	40	42	44	46
63	18	19	21	23	25	27	28	30	32	34	35	37	39	41	43	44
64	17	19	21	22	24	26	27	29	31	33	34	36	38	39	41	43
65	17	18	20	22	23	25	27	28	30	32	33	35	37	38	40	42
66	16	18	19	21	23	24	26	27	29	31	32	34	36	37	39	40
67	16	17	19	20	22	23	25	27	28	30	31	33	34	36	38	39
68	15	17	18	20	21	23	24	26	27	29	30	32	33	35	36	38
69	15	16	18	19	21	22	24	25	27	28	30	31	32	34	35	37
70	14	16	17	19	20	22	23	24	26	27	29	30	32	33	34	36
71	14	15	17	18	20	21	22	24	25	26	27	28	30	32	33	35
72	14	15	16	18	19	20	22	23	24	26	27	28	30	31	33	34
73	13	15	16	17	18	20	21	22	24	25	26	28	29	30	32	33
74	13	14	15	17	18	19	21	22	23	24	26	27	28	30	31	32
75	12	14	15	16	17	19	20	21	22	24	25	26	27	29	30	31
76	12	13	15	16	17	18	19	21	22	23	24	26	27	28	29	30

Modified from Malamed SF. *Medical Emergencies in the Dental Office*. 7th ed. St Louis: CV Mosby; 2015, and <https://www.health.harvard.edu/topic/BMI-Calculator>. Accessed October 29, 2013.

The dentist must put to use all available knowledge of the disease to assess the degree of risk to the patient.

Several examples of dialogue history are presented in the following sections. For a more in-depth description of dialogue history for specific disease states, the reader is referred to *Medical Emergencies in the Dental Office*.⁵⁸

In response to a positive reply to the question “Are you diabetic?” the dialogue history that follows includes the following questions:

1. What type of diabetes do you have (insulin-dependent [type 1] or non–insulin-dependent [type 2])?
2. How do you control your diabetes (oral medications or injectable insulin)?
3. How often do you check your blood glucose level, and what are the measurements (monitoring the degree of control of the disease)?

4. Have you ever been hospitalized for your diabetic condition?
The following is a dialogue history to be initiated with a positive reply to angina pectoris:

1. What precipitates your angina?
2. How frequently do you experience anginal episodes?
3. How long do your anginal episodes last?
4. Describe a typical anginal episode.
5. How does nitroglycerin affect the anginal episode?

6. How many tablets or sprays do you normally need to terminate the episode?

7. Are your anginal episodes stable (similar in nature), or has there been a recent change in their frequency, intensity, radiation pattern of pain, or response to nitroglycerin (seeking unstable or preinfarction angina)?

Dialogue history should be completed for every positive response noted on the medical history questionnaire. A written note should be included on the questionnaire that summarizes the patient’s response to the questions. For example, “heart attack” is circled. Written by the dentist next to this on the questionnaire is the statement “June 2016,” implying that the patient stated that the heart attack occurred in June 2016.

Dialogue history related to the administration of local anesthetic in patients with alleged allergy is presented in [Chapter 18](#).

Determination of Medical Risk

Having completed all components of the physical evaluation and a thorough dental examination, the dentist next takes all of this information and answers the following questions:

1. Is the patient capable, physically and psychologically, of tolerating in relative safety the stresses involved in the proposed treatment?

2. Does the patient have a greater risk (of morbidity or death) than normal during this treatment?
3. If the patient has a greater risk, what modifications will be necessary in the planned treatment to minimize this risk?
4. Is the risk too great for the patient to be managed safely as an outpatient in the medical or dental office?

In an effort to answer these questions, the Herman Ostrow School of Dentistry of USC developed a physical evaluation system that attempts to assist the dentist in categorizing patients from the standpoint of risk factor orientation.⁶⁰ Its function is to assign the patient an appropriate risk category so that dental care can be provided to the patient in comfort and with increased safety. The system is based on the ASA physical status classification system, which is described next.

Physical Status Classification System

In 1962 the ASA adopted what is now referred to as the *ASA physical status classification system*.⁶¹ This system represents a means of estimating medical risk presented by a patient undergoing a surgical procedure. The system has been in continual use since 1962, virtually without change, and has proved to be a valuable method of determining surgical and anesthetic risk before the actual procedure.^{61,62} The classification system is as follows:

- Class 1. A healthy patient (no physiologic, physical, or psychological abnormalities).
- Class 2. A patient with mild systemic disease without limitation of daily activities.
- Class 3. A patient with severe systemic disease that limits activity but is not incapacitating.
- Class 4. A patient with incapacitating systemic disease that is a constant threat to life.
- Class 5. A moribund patient not expected to survive 24 hours with or without the operation.
- Class 6. A brain-dead patient whose organs are being removed for donor purposes.

When we adapted this system for use in a typical outpatient dental or medical setting, ASA classes 5 and 6 were eliminated and an attempt was made to correlate the remaining four classifications with possible treatment modifications for dental treatment.⁶⁰ Fig. 10.12 illustrates the USC physical evaluation form on which a summary of the patient's physical and psychological status is presented, along with planned treatment modifications.

In the discussion of the ASA categories to follow, the term *normal* or *usual activity* is used along with the term *distress*. *Normal* or *usual activity* is defined as the ability to climb one flight of stairs or to walk two level city blocks; *distress* is defined as undue fatigue, shortness of breath, or chest pain. Fig. 10.13 illustrates the ASA classification system based on the ability to climb one flight of stairs.

ASA Class 1

A patient in the ASA class 1 category is defined as normal and healthy. After reviewing the available information, the dentist determines that the patient's heart, lungs, liver, kidneys, and CNS are healthy and that his or her BP is below 140/90 mmHg. The patient is not unduly phobic regarding the dental treatment. A patient in the ASA class 1 category is an excellent candidate for elective surgical or dental care, with minimal risk of experiencing an adverse medical event during treatment. Treatment modifications are usually not warranted in this patient group. The ASA class 1 patient represents a green light ("go") for treatment.

ASA Class 2

Patients in the ASA class 2 category have a mild systemic disease or are healthy patients (ASA class 1) who demonstrate extreme anxiety and fear toward dentistry. Patients classified as ASA class 2 are generally somewhat less able to tolerate stress than are patients classified as ASA class 1; however, they are still at minimal risk during dental treatment. An ASA class 2 classification represents a yellow light for the dentist (proceed with caution). Elective dental care is warranted, with minimal increased risk to the patient during treatment. However, the dentist should consider possible treatment modifications.

Examples of ASA class 2 patients are (1) the healthy, pregnant female; (2) a healthy but extremely phobic patient; (3) the patient with a drug allergy or who is atopic (multiple allergies present); (4) the adult patient with systolic BP between 140 and 159 mmHg and/or diastolic BP between 90 and 94 mmHg; (5) the patient with NIDDM (type 2 diabetes); (6) the patient with well-controlled epilepsy (no seizures within the past year); (7) the patient with well-controlled asthma; (8) the patient with a history of hyperthyroid or hypothyroid conditions who is under care and presently in a euthyroid condition; (9) the ASA class 1 patient presenting with upper respiratory tract infections; and (10) the patient with BMI between 30.0 and 39.9 (based on BMI alone).⁶³

ASA Class 3

A patient in the ASA class 3 category has severe systemic disease that limits activity but is not incapacitating. At rest, a patient in the ASA class 3 category does not exhibit signs and symptoms of distress (such as undue fatigue, shortness of breath, and chest pain); however, when stressed, physiologically or psychologically, the patient does exhibit such signs and symptoms. An example is a patient with angina who is pain-free while in the waiting room but develops chest pain when seated in the dental chair. Similarly to ASA class 2, the ASA class 3 classification indicates that the dentist should proceed with caution. Elective dental care is not contraindicated, although the patient is at increased risk during treatment. The dentist should give serious consideration to implementing treatment modifications.

PDF Compressor Free Version

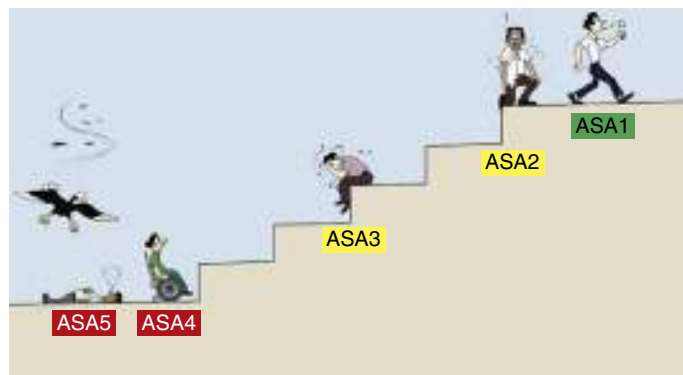
ASA	CURRENT MEDICAL PROBLEMS	CURRENT MEDICATIONS		
II	1	1	BP	HT
III	2	2	PULSE	WT
IV	3	3	RESP.RATE	TEMP
	4	4		

MODIFICATIONS TO THERAPY :	Specific
- General -	

DENTISTRY DIAGNOSTIC SUMMARY : _____	

TREATMENT PLAN SEQUENCE	

• **Fig. 10.12** The Herman Ostrow School of Dentistry of University of Southern California physical evaluation summary form.



ASA Classification

• **Fig. 10.13** American Society of Anesthesiologists (ASA) classification. (Courtesy Dr. Lawrence Day.)

Examples of ASA class 3 patients include (1) the patient with well-controlled IDDM (type 1 diabetes); (2) the patient with symptomatic thyroid disease (hypothyroid or hyperthyroid); (3) the patient who had an MI more than 6 months ago with no residual complications; (4) the patient who had a CVA more than 6 months ago with no residual complications; (5) the adult patient with systolic BP between 160 and 199 mmHg and/or diastolic BP between 95 and 114 mmHg; (6) the patient with epilepsy, but less well controlled (several seizures or more per year); (7) the patient with asthma, less well controlled, stress or exercise induced, and/or a history of hospitalization because of status asthmaticus; (8) the patient with angina pectoris (stable [e.g., angina of exertion] angina); (9) the patient with HF, with orthopnea (more than two pillows) and/or ankle edema; (10) the patient with COPD (emphysema or chronic bronchitis); (11) the patient who is functionally anephric (renal dialysis patients); and (12) the patient with BMI of 40.0 or greater (based on BMI alone).⁶³

ASA Class 4

A patient in the ASA class 4 category has an incapacitating systemic disease that is a constant threat to life. Patients with this classification have a medical problem or problems of greater significance than the planned dental treatment. The dentist should defer elective dental care until the patient’s physical condition has improved to at least an ASA class 3 classification. A patient in the ASA class 4 category exhibits clinical signs and symptoms of disease at rest. This classification represents a red light, a warning that the risk involved in treating the patient is too great to permit elective care. In dental emergencies, such as cases of infection or pain, clinicians should treat patients conservatively in the dental office until their medical condition improves. When possible, emergency treatment should be noninvasive, consisting of drugs such as analgesics for pain and antibiotics for infection. When the dentist believes that immediate intervention is required (e.g., incision and drainage, extraction, pulpal extirpation), it is suggested that the patient receive care in an acute care facility (i.e., a hospital) whenever possible.

Examples of ASA class 4 patients include (1) the patient with unstable angina pectoris (preinfarction angina); (2) the patient who had an MI or stroke within 6 months; (3) the patient who had a CVA less than 6 months ago; (4) the adult patient who has systolic BP of 200 mmHg and/or diastolic BP of 115 mmHg or higher; (5) the patient with uncontrolled dysrhythmias (requires medical consultation before the start of treatment); (6) the patient with severe HF or COPD confining the patient to a wheelchair and/or requiring that the patient receive supplemental O₂ therapy; (7) the patient with uncontrolled epilepsy; (8) the patient with uncontrolled IDDM; and (9) the patient with BMI of 40.0 or greater (in the presence of significant comorbidities).

ASA Class 5

An ASA class 5 classification indicates a moribund patient not expected to survive 24 hours without surgery. Patients in this category almost always are hospitalized and terminally ill. In many institutions, these patients are not to be resuscitated if they experience respiratory or cardiac arrest (they are termed *DNR* ["do not resuscitate"]). Elective dental treatment is contraindicated; however, emergency care in the realm of palliative treatment (i.e., relief of pain and/or infection) may be necessary. An ASA class 5 classification is a red light with regard to dental care.

Examples of ASA class 5 patients include (1) the patient with end-stage cancer; (2) the patient with end-stage heart and/or lung disease; (3) the patient with end-stage hepatic disease; and (4) the patient with end-stage infectious disease.

The ASA physical evaluation system is quite simple to use when a patient has an isolated medical problem. However, many patients are seen with histories of several significant diseases. On these occasions, the dentist must weigh the significance of each disease and make a judgment as to the appropriate ASA category. The system is not meant to be inflexible, but is meant to function as a relative value system based on the dentist's clinical judgment. When the dentist is unable to determine the clinical significance of one or more disease processes, consultation with the patient's physician or other medical or dental colleagues is recommended. In all cases, however, the ultimate decision of whether to treat the patient or to postpone treatment must be made by the treating dentist. Responsibility and liability rest solely in the hands of the dentist who treats, or does not treat, the patient.

Table 10.11 summarizes the ASA physical status classification system as modified for use in dentistry.

Drug-Drug Interactions and Contraindications

Potential drug-drug interactions involving local anesthetics or vasopressors, and three relative contraindications to the administration of local anesthetics—MH (malignant hyperpyrexia), atypical plasma

cholinesterase, and idiopathic or congenital methemoglobinemia—are detailed in the following discussion. A fourth—allergy (an absolute contraindication)—is discussed in Chapter 18.

The importance of each potential interaction is listed in its significance rating as designed by Moore et al.⁶⁴ The rating system is defined in Box 10.6.

Drug-Drug Interactions

Amide Local Anesthetics With Inhibitors of Metabolism (e.g., Cimetidine, Lidocaine) (Significance Rating 5)

The H₂-receptor blocker cimetidine (Tagamet) modifies the biotransformation of lidocaine by competing with it for binding to hepatic oxidative enzymes. Other H₂-receptor blockers, such as ranitidine and famotidine, do not inhibit lidocaine biotransformation.^{65,66} The net result of this interaction with cimetidine is an increase in the half-life of the circulating local anesthetic. With typical dental practice use of local anesthetics, this interaction is clinically of minor significance. The interaction between amide local anesthetics and cimetidine might be of greater clinical significance in the presence of a history of HF (ASA class 3 or greater), where the percentage of cardiac output delivered to the liver falls, while the percentage of cardiac output delivered to the brain increases.⁶⁷ With elevated blood levels of lidocaine secondary to cimetidine, and an increased percentage in blood being delivered to the brain in HF, the risk of local anesthetic overdose is increased. Inhibition of local anesthetic metabolism has little effect on peak plasma levels of the local anesthetic when given as a single injection.⁶⁸ This combination of factors—cimetidine and ASA class 3 plus HF—represents a relative contraindication to the administration of amide local anesthetics. Minimal doses of amide local anesthetics should be administered.

Summation Interactions With Local Anesthetics (Significance Rating 1)

Combinations of local anesthetics may be administered together without unnecessary increase in the risk of development of a toxic reaction (overdose). The toxicity of local anesthetics is additive when they are administered in combination. To minimize this risk, the total dose of all local anesthetics administered should not exceed the lowest of the maximum recommended doses of each of the local anesthetics administered.

Sulfonamides and Esters (Significance Rating 5)

Ester local anesthetics, such as procaine and tetracaine, may inhibit the bacteriostatic action of the sulfonamides. With the uncommon use of sulfonamides today, along with the extremely rare administration of ester local anesthetics in dentistry, this potential drug interaction is unlikely to be noted. As a rule, ester local anesthetics should not be administered to patients receiving sulfonamides.

TABLE 10.11

American Society of Anesthesiologists Physical Status Classification System

PDF Compressor Free Version

Class	Definition	Example	Treatment Recommendations
1	Healthy patient	—	No special precautions
2	Patient with mild systemic disease	Pregnancy, well-controlled type 2 diabetes, epilepsy, asthma, thyroid dysfunction, blood pressure 140–159/90–94 mmHg	Elective care okay; consider treatment modification
3	Patient with severe systemic disease that limits activity but is not incapacitating	Stable angina pectoris, myocardial infarction >6 months ago, cerebrovascular accident >6 months ago, exercise-induced asthma, type 1 diabetes (controlled), epilepsy (less well controlled), symptomatic thyroid dysfunction, blood pressure 160–199/95–114 mmHg	Elective care okay; serious consideration of treatment modification
4	Patient with an incapacitating systemic disease that is a constant threat to life	Unstable angina pectoris, myocardial infarction <6 months ago, uncontrolled seizures, blood pressure >200/>115 mmHg	Elective care contraindicated; emergency care: noninvasive (e.g., drugs) or in a controlled environment
5	Moribund patient not expected to survive for 24 h without an operation	End-stage cancer, end-stage infectious disease, end-stage cardiovascular disease, end-stage hepatic dysfunction	Palliative care

Modified from Malamed SF. Knowing your patient. *J Am Dent Assoc.* 2010;141:3S–7S.

• BOX 10.6 Significance Ratings for Dental Drug Interactions

Rating	Definition
1	Major reactions that are established, probable, or suspected
2	Moderate reactions that are established, probable, or suspected
3	Minor reactions that are established, probable, or suspected
4	Major or minor reactions that are possible
5	Minor reactions that are possible; all reactions that are unlikely

Severity Rating

Major: Potentially life threatening or capable of causing permanent damage

Moderate: Could cause deterioration of patient's clinical status; additional treatment or hospitalization might be necessary

Minor: Mild effects that are bothersome or unnoticed; should not significantly affect therapeutic outcome

Documentation Rating

Established: Proved to occur in well-controlled studies

Probable: Very likely, but not proved clinically

Suspected: Could occur; some good data exist, but more study is needed

Possible: Could occur; data are very limited

Unlikely: Doubtful; there is no consistent and reliable evidence of an altered clinical effect

Local Anesthetics With Opioid Sedation (Significance Rating 1)

Sedation with opioid analgesics may increase the risk of local anesthetic overdose. This is of primary concern in

younger, lighter-weight children. Therefore the dose of local anesthetic should, as always, be minimized.

Local Anesthetic–Induced Methemoglobinemia (Significance Rating 4)

Methemoglobinemia may result when prilocaine is administered in excessive doses.⁶⁹ The risk of local anesthetic–induced methemoglobinemia is discussed later in this chapter.

Vasoconstrictor and Tricyclic Antidepressant (e.g., Levonordefrin and Amitriptyline) (Significance Rating 1)

Tricyclic antidepressants (TCAs) are commonly prescribed in the management of major depression. TCAs may enhance the cardiovascular actions of exogenously administered vasopressors. This enhancement of activity is approximately fivefold to tenfold with levonordefrin and norepinephrine, but is only twofold with epinephrine and phenylephrine.⁷⁰ This interaction has been reported to have resulted in a series of hypertensive crises, one of which led to the death of a patient (after a small dose of norepinephrine [norepinephrine is not available in dental local anesthetics in North America]).⁷¹ Administration of norepinephrine and levonordefrin should be avoided in patients receiving TCAs. Patients receiving epinephrine-containing local anesthetics should be given the smallest effective dose. Yagiela et al.⁷² recommend limiting the epinephrine dose to patients receiving TCAs at a dental appointment to 0.05 mg, or 5.4 mL of a 1:100,000 epinephrine concentration. Commonly prescribed TCAs are listed in Table 10.12.

TABLE
10.12

Antidepressant Medications

PDF Compressor Free Version

Tricyclic Antidepressants	Monoamine Oxidase Inhibitors
Amitriptyline (Elavil)	Isocarboxazid (Marplan)
Nortriptyline (Aventyl, Pamelor)	Phenelzine (Nardil)
Imipramine (Tofranil)	Tranylcypromine (Parnate)
Doxepin (Sinequan)	Trimipramine (Surmontil)
Amoxapine (Asendin)	
Desipramine (Norpramin)	
Protriptyline (Vivactil)	
Clomipramine (Anafranil)	

Vasoconstrictors and Nonselective β -Adrenoceptor Antagonist (β -Blocker) (e.g., Propranolol and Epinephrine) (Significance Rating 1)

Administration of vasopressors in patients being treated with nonselective β -blockers increases the likelihood of a serious elevation in BP accompanied by a reflex bradycardia. Several cases have been reported in the medical literature and appear to be dose related.^{73,74} Reactions have occurred with epinephrine doses ranging from 0.04 to 0.32 mg, the equivalent of the administration of 4 to 32 mL of local anesthetic with a 1:100,000 epinephrine concentration.⁷⁵ Table 10.13 lists both nonselective and cardioselective β -blockers.

Monitoring of preoperative vital signs—specifically, BP, heart rate, and heart rhythm—is strongly recommended for all patients but is especially recommended in patients receiving β -blockers. Remonitoring these vital signs at 5 to 10 minutes after administration of a vasopressor-containing local anesthetic is strongly suggested.

Vasoconstrictor With Hydrocarbon Inhalation Anesthetic (e.g., Halothane or Enflurane and Epinephrine) (Significance Rating 1)

There is an increased possibility of cardiac dysrhythmias when epinephrine is administered to patients receiving certain halogenated general anesthetic gases.^{76,77} Discussion with the anesthesiologist before local anesthetic administration during general anesthesia is suggested.

Vasoconstrictor With Cocaine (Significance Rating 1)

Cocaine is a local anesthetic drug that has significant stimulatory effects on the CNS and CVS. Cocaine stimulates norepinephrine release and inhibits its reuptake in adrenergic nerve terminals, thus producing a state of catecholamine hypersensitivity.^{78,79} Tachycardia and hypertension are frequently observed with cocaine administration, both of which increase cardiac output and myocardial oxygen

TABLE
10.13 β -Adrenoceptor Antagonists (β -Blockers)

Non-Cardioselective β -blockers	Cardioselective β -blockers
	Atenolol (Tenormin)
Carvedilol (Coreg CR)	Betaxolol (Kerlone)
Pindolol (Visken)	Metoprolol (Lopressor)
Timolol (Blocadren)	Acebutolol (Sectral)
Sotalol (Betapace)	Esmolol (Brevibloc)
Nadolol (Corgard)	Bisoprolol (Zebeta)
Propranolol (Inderal, Betachron)	
Labetalol (Normodyne)	

requirements.⁸⁰ When this results in myocardial ischemia, potentially lethal dysrhythmias, anginal pain, MI, or cardiac arrest may ensue.⁸¹⁻⁸³ The risk of such problems is elevated in dentistry when a local anesthetic containing a vasopressor is accidentally administered intravascularly in a patient with already high cocaine blood levels. After intranasal application of cocaine, peak blood levels develop within 30 minutes, and usually disappear after 4 to 6 hours.⁸⁴ Whenever possible, local anesthetics containing vasopressors should not be administered to patients who have used cocaine on the day of their dental appointment.⁸⁵ Unfortunately, it is the rare abuser of cocaine who will volunteer this vital information to the dentist. The use of epinephrine-impregnated gingival retraction cord, although not recommended for use in any dental patient, is absolutely contraindicated in the cocaine abuser.

Administration of local anesthetics to cocaine abusers can also increase the risk of local anesthetic overdose. If there is any suspicion about a patient having used cocaine recently, the patient should be questioned directly. If cocaine has been used within 24 hours of the dental appointment, or if it is suspected that cocaine has been used within 24 hours, the planned dental treatment should be postponed.^{86,87}

Vasoconstrictor With Antipsychotic or Another α -Adrenoceptor Blocker (Significance Rating 4)

α -Adrenoceptor blockers such as phenoxybenzamine and prazosin (Minipress) and antipsychotic drugs such as haloperidol (Haldol) and thioridazine (Mellaril) may produce significant hypotension as a result of overdose. This hypotensive effect may be intensified with large doses of vasoconstrictors. Vasoconstrictors should be used with caution.⁸⁸

Vasoconstrictor With Adrenergic Neuronal Blocker (Significance Rating 4)

Sympathomimetic effects may be enhanced. The vasoconstrictor should be used cautiously.⁸⁹ Phenothiazines are psychotropic drugs usually prescribed for the management of

serious psychotic disorders. The most commonly observed side effect of phenothiazines involving the CVS is postural hypotension. In addition, the vasoconstrictor actions of epinephrine, permitting its milder vasodilating actions to work unopposed. This response is not likely to develop when local anesthetics are administered extravascularly; however, accidental intravascular administration of a vasopressor-containing local anesthetic could lead to hypotension in patients receiving phenothiazines.⁸⁷

Local anesthetics containing vasopressors are not contraindicated in patients receiving phenothiazines; however, it is recommended that the smallest volume of the lowest concentration of vasopressor-containing local anesthetic that is compatible with clinically adequate pain control be administered.

Commonly prescribed phenothiazines include chlorpromazine (Thorazine) and promethazine (Phenergan).

Vasoconstrictor With Thyroid Hormone (e.g., Epinephrine and Thyroxine) (Significance Rating 4)

Summation of effects is possible when thyroid hormones are taken in excess. Vasoconstrictors should be used with caution when clinical signs and symptoms of hyperthyroidism are present.^{90,91}

Vasoconstrictor and Monoamine Oxidase Inhibitors (Significance Rating 5)

Monoamine oxidase inhibitors (MAOIs) are prescribed in the management of major depression, certain phobic-anxiety states, and obsessive-compulsive disorders (Table 10.14).⁸⁷ They are capable of potentiating the actions of vasopressors used in dental local anesthetics by inhibiting their biodegradation by the enzyme monoamine oxidase at the presynaptic neuron level.⁷⁸

Historically, the administration of local anesthetics containing vasopressors has been absolutely contraindicated for patients receiving MAOIs because of the increased risk of hypertensive crisis. However, Yagiela et al.⁷² and Perusse et al.⁸⁷ demonstrated that such an interaction among epinephrine, levonordefrin, norepinephrine, and monoamine oxidase did not occur. Such a response, hypertensive crisis, did develop with phenylephrine, a vasopressor not used at present in dental local anesthetic solutions.

Therefore, it is appropriate to state “there seems to be no restriction, from a theoretical basis, to use local anesthetic with vasoconstrictor other than phenylephrine in patients currently treated with MAOIs.”⁸⁷

For a thorough review of potentially significant drug interactions occurring in dentistry, the reader is referred to the excellent series of articles that appeared in 1999 in the *Journal of the American Dental Association*.^{64,68,92-94}

Most known drug-drug interactions involving local anesthetics or vasopressors occur with CNS and CVS depressants. Whenever a potential drug-drug interaction is known, the doses of local anesthetics should be decreased. There is no formula for the correct degree of reduction. Prudence

TABLE 10.14 Monoamine Oxidase Inhibitors

Generic Name	Proprietary Name
Clorgiline	—
Isocarboxazid	Marplan
Moclobemide	Aurorix
Pargyline	Eutonyl
Phenelzine	Nardil
Selegiline	Deprenyl, Eldepryl
Tranylcypromine	Parnate
Brofaromine	Consonar
Iproniazid	Marsilid
Isoniazid	—
MDMA	—
Fluoxetine	Prozac

dictates, however, that the smallest dose of local anesthetic or vasopressor that is clinically effective should be used.

Knowledge of all drugs and medications, including prescription and nonprescription drugs, as well as herbal remedies, being taken by a patient better enables the doctor to evaluate the patient's overall physical and psychological well-being. Drug references such as ClinicalKey (<https://www.clinicalkey.com>), the *Compendium of Pharmaceuticals and Specialties* (Canada), Lexicomp (<http://www.wolterskluwer CDI.com/lexicomp-online/>), and Epocrates (<http://www.epocrates.com>) are valuable resources for obtaining drug information, including the potential for drug-drug interactions. Current medications should be listed in the dental record.^{5,6}

Malignant Hyperthermia

Malignant hyperthermia (MH; malignant hyperpyrexia) is one of the most intense and life-threatening complications associated with the administration of general anesthesia. It is rare: 1 in 15,000 incidence among children receiving general anesthesia and 1 in 50,000 incidence in adults.⁹⁵ The syndrome is transmitted genetically by an autosomal dominant gene. Reduced penetrance and variable expressivity in siblings in families inheriting the syndrome are also characteristic of its genetic transmission. MH is seen more frequently in males than in females—a finding that increases with increasing age. To date, the youngest reported case of MH occurred in a boy aged 2 months and the oldest occurred in a 78-year-old man.

Reports of MH in North America appear to be clustered in three regions: Toronto (in Canada) and Wisconsin and Nebraska (in the United States). Most persons with MH are functionally normal, the presence of MH becoming known only when the individual is exposed to triggering agents or through specific testing.

For many years it was thought that MH could be triggered when susceptible patients were exposed to amide local anesthetics. Publications by the Malignant Hyperthermia Association of the United States (MHAUS)¹⁰⁰ have demonstrated that amide local anesthetics are not likely to trigger such episodes, thus MH has been recategorized as a relative contraindication.

Causes

All reported cases of MH (associated with drug administration) have developed during the administration of general anesthesia.¹⁰¹ No association with the type of surgical procedure being performed has been noted. Several cases of MH have been reported among patients receiving general anesthesia for dental care, including one case in a dental office.^{102,103}

The anesthetic agents that have been associated with cases of MH are as follows: succinylcholine, halothane, enflurane, isoflurane, desflurane, and sevoflurane.

Two drugs have been associated with a preponderance of MH cases: succinylcholine, a skeletal muscle relaxant (77% of all cases), and the inhalation anesthetic halothane (60%).¹⁰⁴ Of significance to dentistry is the fact that two commonly used (amide) local anesthetics, lidocaine and mepivacaine, were administered along with other potential trigger agents in cases in which MH developed. At one time, a history of documented MH or a high risk of MH was considered to be an absolute contraindication to the administration of all amide local anesthetics. However, recent evidence demonstrates that MH is not a likely occurrence with amide local anesthetics as used in dentistry, and therefore should be considered a relative contraindication. The MHAUS (<https://www.mhaus.org>) has a policy statement on the use of local anesthetics¹⁰⁵: “Based on limited clinical and laboratory evidence, all local anesthetic drugs appear to be safe for MH susceptible individuals.” This statement followed several reports in the literature, including one by Adragna¹⁰⁶ that stated: “After an extensive search of the literature, I have been unable to find any reports of any malignant hyperthermic crisis caused solely by the use of amide local anesthetics without epinephrine.... In fact, lidocaine has been used successfully to treat the arrhythmias of a severe MH reaction and, in fact, lidocaine has been used routinely as a local anesthetic without problems on MHS [MH syndrome] patients in at least one institution.... The question I am posing is clear. Is there any evidence that amide local anesthetics are contraindicated in MHS patients, or is our habit of avoiding them just a habit?” Because MH syndrome has yet to be reported in a situation in which a local anesthetic was the sole drug administered, it is reasonable for the dentist to manage the dental needs of such patients using amide or ester local anesthetics. Prior consultation with the patient’s physician is strongly suggested.

Adriani and Sundin¹⁰⁷ reported that in susceptible patients, MH may be precipitated by factors other than the drugs just listed. These include emotional factors (excitement and stress) and physical factors (mild infection, muscle injury, vigorous exercise, and elevated environmental temperatures). It appears then that the dental office could be a site where the susceptible patient, exposed to excessive stresses such as pain and fear, might exhibit symptoms of MH.

Recognition of the High-Risk Malignant Hyperthermia Patient

No questions on medical history questionnaires currently used in dentistry specifically address MH. The only ones on the health history questionnaire that might elicit this information are:

- Question 56: Do you have, or have you had hospitalization?
- Question 58: Do you have, or have you had surgeries?
- Question 67: Do you have, or have you had any other diseases or medical problems NOT listed on this form?

The patient with MH or a family member at risk will usually volunteer this information to his or her doctor at an early visit.

Family members are usually evaluated for their risk after the occurrence of MH. Initial evaluation involves determination of the blood levels of creatinine kinase (CK).¹⁰⁸ Elevated CK levels are seen when muscle damage has occurred. With an elevated CK level, a second phase of evaluation is required, involving the histologic examination of a biopsy specimen taken from the quadriceps muscle (with the patient under a type of anesthesia known to be safe) and testing of the specimen for an increased contracture response when exposed to halothane and caffeine.

Dental Management of the Malignant Hyperthermia Patient

On disclosure of the presence of MH, or when the risk of its occurrence is high, it is recommended that the dentist contact the patient’s primary care physician to discuss treatment options.

Dental management on an outpatient basis with local anesthetics as the only drugs administered is indicated in most cases, but with higher-risk patients, it might be prudent to conduct such treatment within the confines of a hospital, where immediate emergency care is available should the MH syndrome be triggered. “Normal” doses of amide local anesthetics may be used with little increase in risk.¹⁰⁵ Vasoconstrictors may be included to provide longer periods of pain control or hemostasis.

Box 10.7 lists the MHAUS list of safe anesthetic agents for MH patients.

• **BOX 10.7** Safe Anesthetics for Patients Susceptible to Malignant Hyperthermia
PDF Compressor Free Version

Barbiturates/Intravenous Anesthetics

Diazepam
 Etomidate (Amidate)
 Hexobarbital
 Ketamine (Ketalar)
 Methohexital (Bervital)
 Midazolam
 Narcobarbital
 Propofol (Diprivan)
 Thiopental (Pentothal)

Inhaled Nonvolatile General Anesthetic

Nitrous oxide

Local Anesthetics

Amethocaine
 Articaine
 Bupivacaine
 Dibucaine
 Etidocaine
 Eucaine
 Lidocaine (Xylocaine)
 Levobupivacaine
 Mepivacaine (Carbocaine)
 Procaine (Novocain)
 Prilocaine (Citanest)
 Ropivacaine
 Amylocaine (Stovaine)

Narcotics (Opioids)

Alfentanil (Alfenta)
 Anileridine
 Codeine
 Diamorphine
 Fentanyl (Sublimaze)
 Hydromorphone (Dilaudid)
 Meperidine (Demerol)
 Methadone
 Morphine
 Naloxone
 Oxycodone
 Phenoperidine
 Remifentanyl
 Sufentanil (Sufenta)

Safe Muscle Relaxants

Pipecuronium (Arduan)
 Curare (the active ingredient is tubocurarine)
 Gallamine
 Metocurine
 Mivacurium (Mivacron)
 Doxacurium (Nuromax)
 Cisatracurium (Nimbex)
 Vecuronium (Norcuron)
 Pancuronium (Pavulon)
 Atracurium (Tracrium)
 Rocuronium (Zemuron)

Anxiety-Relieving Medications

Lorazepam (Ativan)
 Prazepam (Centrax)
 Flurazepam (Dalmane)
 Triazolam (Halcion)
 Clonazepam (Klonopin)
 Chlordiazepoxide–clidinium bromide (Librax)
 Chlordiazepoxide (Librium)
 Midazolam (Versed)
 Halazepam (Paxipam)
 Temazepam (Restoril)
 Oxazepam (Serax)
 Clorazepate (Tranxene)
 Diazepam (Valium)

Data from Malignant Hyperthermia Association of the United States. Anesthetic list for MH-susceptible patients. Available at: <http://www.mhaus.org>. Accessed June 2008.

Atypical Plasma Cholinesterase

Choline ester substrates, such as the depolarizing muscle relaxant succinylcholine and the ester local anesthetics, are hydrolyzed in the blood by the enzyme plasma cholinesterase, which is produced in the liver. Hydrolysis of these chemicals is usually quite rapid, their blood levels decreasing rapidly, thereby terminating the drug's action (succinylcholine) or minimizing the risk of overdose (ester local anesthetics).

Approximately 1 in every 2820 persons possesses an atypical form of plasma cholinesterase, transmitted as an inherited autosomal recessive trait.¹⁰⁹ Although many genetic variations of atypical plasma cholinesterase are identifiable, not all produce clinically significant signs and symptoms.

Determination

In most cases the presence of atypical plasma cholinesterase is determined through the patient's response to succinylcholine, a depolarizing skeletal muscle relaxant. Succinylcholine is commonly administered during the induction of general anesthesia to facilitate intubation of the trachea. Apnea is produced for a brief time, with spontaneous ventilation returning as the succinylcholine is hydrolyzed by plasma cholinesterase. When atypical plasma cholinesterase is present, the apneic period is prolonged from minutes to many hours. Patient

management simply involves the maintenance of controlled ventilation until effective spontaneous respiratory efforts return. After recovery, the patient and family members are tested for a serum cholinesterase survey. The dibucaine number is determined from a sample of blood. Normal patients have dibucaine numbers between 66 and 86. Atypical plasma cholinesterase patients exhibiting prolonged response to succinylcholine have dibucaine numbers as low as 20, with other genetic variants exhibiting intermediate values. Patients with low dibucaine numbers are more likely to exhibit prolonged succinylcholine-induced apnea.¹¹⁰

Significance in Dentistry

The presence of atypical plasma cholinesterase should alert the doctor to the increased risk of prolonged apnea in patients receiving succinylcholine during general anesthesia. Also, and of greater significance in the typical ambulatory dental patient not receiving general anesthesia or succinylcholine, is the increased risk of developing elevated blood levels of the ester local anesthetics. Signs and symptoms of local anesthetic overdose are more likely to be noted in these patients, even with "normal" doses. Because injectable ester local anesthetics are rarely used in dentistry anymore, the presence of atypical plasma cholinesterase is a relative contraindication to their administration. Because they undergo biotransformation in

the liver, amide local anesthetics do not present an increased risk of overly high blood levels in these patients. Ester anesthetics may be acutely toxic to the liver and kidneys as a cocarboxinoc-
 PDF Compressor Free Version
 tor, but their doses should be minimized.

Methemoglobinemia

Methemoglobinemia is a condition in which a cyanosis-like state develops in the absence of cardiac or respiratory abnormalities. When the condition is severe, blood appears chocolate brown, and clinical signs and symptoms, including respiratory depression and syncope, may be noted. Death, although unlikely, can result. Methemoglobinemia may occur through inborn errors of metabolism or may be acquired through administration of drugs or chemicals that increase the formation of methemoglobin. The local anesthetic prilocaine has been shown to produce clinically significant methemoglobinemia when administered in large doses to patients with subclinical methemoglobinemia.^{111,112}

Administration of prilocaine to patients with congenital methemoglobinemia or other clinical syndromes in which the oxygen-carrying capacity of blood is reduced should be avoided because of the increased risk of producing clinically significant methemoglobinemia. The topical anesthetic benzocaine can also induce methemoglobinemia, but only when administered in very large doses.^{113,114}

Causes

Iron is normally present in the reduced or ferrous state (Fe^{2+}) in the hemoglobin molecule. Each hemoglobin molecule contains four ferrous atoms, each loosely bound to a molecule of oxygen. In the ferrous state, hemoglobin can carry oxygen that is available to the tissues. Because hemoglobin in the erythrocyte is inherently unstable, it is continuously being oxidized to the ferric form (Fe^{3+}), in which state the oxygen molecule is more firmly attached and cannot be released to the tissues. This form of hemoglobin is called *methemoglobin*. To permit an adequate oxygen-carrying capacity in the blood, an enzyme system is present that continually reduces the ferric form to the ferrous form. In usual clinical situations, approximately 97% to 99% of hemoglobin is found in the more functional ferrous state, and 1% to 3% is found in the ferric state. This enzyme system is known commonly as *methemoglobin reductase* (erythrocyte nucleotide diaphorase), and it acts to reconvert iron from the ferric state to the ferrous state at a rate of 0.5 g/dL per hour, thus maintaining a level of less than 1% methemoglobin (0.15 g/dL) in the blood at any given time. As blood levels of methemoglobin increase, clinical signs and symptoms of cyanosis and respiratory distress become noticeable. In most instances, they are not observed until a methemoglobin blood level of 1.5 to 3.0 g/dL (10% to 20% methemoglobin) is reached.¹¹⁵

Acquired Methemoglobinemia

Although prilocaine can produce elevated methemoglobin levels, other chemicals and substances can also do this, including

acetanilid, aniline derivatives (e.g., crayons, ink, shoe polish, dermatologicals), benzene derivatives, cyanides, methylene blue in large doses, nitrates (antianginals), *p*-aminosalicylic acid, and sulfonamides.²⁶ Sarangi and Kumar¹¹⁶ reported the case of a fatality that occurred because of a chemically induced methemoglobinemia from writing ink. Daly et al.¹¹⁷ reported the case of a child born with 16% methemoglobin (2.3 g/dL) that supposedly resulted because the mother, while still pregnant, had stood with wet bare feet on a bath mat colored with aniline dye. In these situations, nitrates in the pen and dye were absorbed and converted to nitrites, which oxidized the ferrous iron to ferric iron and thus produced methemoglobinemia.

Acquired Methemoglobinemia—Prilocaine

The production of methemoglobin by prilocaine is dose related. Toluene is present in the prilocaine molecule, which as the drug is biotransformed becomes *o*-toluidine, a compound capable of oxidizing ferrous iron to ferric iron and of blocking the methemoglobin reductase pathways. Peak blood levels of methemoglobin develop approximately 3 to 4 hours after drug administration and persist for 12 to 14 hours.

Clinical Signs and Symptoms and Management

Signs and symptoms of methemoglobinemia usually appear 3 to 4 hours after administration of large doses of prilocaine to healthy patients, or of smaller doses in patients with the congenital disorder. Most dental patients will have left the office by this time, thus provoking a worried telephone call to the doctor. Although the signs and symptoms vary with the blood levels of methemoglobin, typically the patient appears lethargic and in respiratory distress; mucous membranes and nail beds will be cyanotic and the skin pale gray (ashen). Diagnosis of methemoglobinemia is made on the presentation of cyanosis unresponsive to oxygen administration and a distinctive brown color of arterial blood.¹⁰⁶ Administration of 100% oxygen does not lead to significant improvement (ferric iron cannot surrender oxygen to tissues). Venous blood (gingival puncture) may appear chocolate brown and will not turn red when exposed to oxygen. Definitive treatment of this situation requires the slow intravenous administration of 1% methylene blue (1.5 mg/kg or 0.7 mg/lb). This dose may be repeated every 4 hours if cyanosis persists or returns. Methylene blue acts as an electron acceptor in the transfer of electrons to methemoglobin, thus hastening conversion of ferric iron to ferrous iron. However, methylene blue, if administered in excess, can itself cause methemoglobinemia.

Another treatment, although not as rapidly acting as methylene blue and therefore not as popular, is the intravenous or intramuscular administration of ascorbic acid (100 to 200 mg/day). Ascorbic acid accelerates the metabolic pathways that produce ferrous iron.

Methemoglobinemia should not develop in a healthy ambulatory dental patient, provided the doses of prilocaine hydrochloride are within recommended limits. The presence of congenital methemoglobinemia remains a relative contraindication to the administration of prilocaine. Although prilocaine may be administered, if absolutely necessary, its dose must be minimized. Whenever possible, alternative local anesthetics should be used.

The maximum recommended dose (Food and Drug Administration) of prilocaine is listed as 8.0 mg/kg (3.6 mg/lb). Methemoglobinemia is unlikely to develop at doses below this level.

References

1. Daublander M, Muller R, Lipp MD. The incidence of complications associated with local anesthesia in dentistry. *Anesth Prog.* 1997;44:132–141.
2. Malamed SF. Managing medical emergencies. *J Am Dent Assoc.* 1993;124:40–53.
3. McCarthy FM. *Essentials of Safe Dentistry for the Medically Compromised Patient.* Philadelphia: WB Saunders; 1989.
4. McCarthy FM. Stress reduction and therapy modifications. *J Calif Dent Assoc.* 1981;9:41–47.
5. McCarthy FM, Malamed SF. Physical evaluation system to determine medical risk and indicated dental therapy modifications. *J Am Dent Assoc.* 1979;99:181–184.
6. Chestnutt IG, Morgan MZ, Hoddell C, Playle R. A comparison of a computer-based questionnaire and personal interviews in determining oral health-related behaviours. *Community Dent Oral Epidemiol.* 2004;32:410–417.
7. Jacobsen PL, Fredeskind R, Budenz AW, et al. *The Medical Health History in Dental Practice: MetLife Quality Resource Guide.* MetLife: Bridgewater; 2003.
8. Brady WF, Martinoff JT. Validity of health history data collected from dental patients and patient perception of health status. *J Am Dent Assoc.* 1980;101:642–645.
9. Jeske AH, ed. *Mosby's Dental Drug Reference.* 9th ed. St Louis: Mosby; 2009.
10. Fukuda K. Intravenous anesthetics. In: Miller RD, ed. *Miller's Anesthesia.* 6th ed. Philadelphia: Elsevier; 2005.
11. Skidmore-Roth L. *Mosby's 2010 Nursing Drug Reference.* St Louis: Mosby; 2010.
12. Hamilton JG. Needle phobia—a neglected diagnosis. *J Fam Pract.* 1995;41:169–175.
13. Gottlieb SO, Flaherty JT. Medical therapy of unstable angina pectoris. *Cardiol Clin.* 1991;9:19–98.
14. Little JW. Ischemic heart disease. In: Little JW, Falace DA, Miller CS, Rhodus NL, eds. *Dental Management of the Medically Compromised Patient.* 9th ed. St Louis: Elsevier Health Sciences; 2017.
15. Shah KB, Kleinman BS, Sami H, et al. Reevaluation of perioperative myocardial infarction in patients with prior myocardial infarction undergoing noncardiac operations. *Anesth Analg.* 1990;71:231–235.
16. Wilson W, Taubert KA, Gewitz M, et al. Prevention of infective endocarditis: guidelines from the American Heart Association: a guideline from the American Heart Association Rheumatic Fever, Endocarditis, and Kawasaki Disease Committee, Council on Cardiovascular Disease in the Young, and the Council on Clinical Cardiology, Council on Cardiovascular Surgery and Anesthesia, and the Quality of Care and Outcomes Research Interdisciplinary Working Group. *J Am Dent Assoc.* 2008;139(suppl):3S–24S.
17. American Dental Association, American Academy of Orthopedic Surgeons. Antibiotic prophylaxis for dental patients with total joint replacements. *J Am Dent Assoc.* 2003;134:895–898.
18. Public Relations Department, American Academy of Orthopedic Surgeons. *Information Statement 1033: Antibiotic Prophylaxis for Bacteremia in Patients With Joint Replacements.* Rosemont: American Academy of Orthopedic Surgeons; 2010.
19. National Collaborating Centre for Chronic Conditions, Chronic Obstructive Pulmonary Disease: National clinical guideline on management of chronic obstructive pulmonary disease in adults in primary and secondary care. *Thorax.* 2004;59(suppl 1):1–232.
20. Yakahane Y, Kojima M, Sugai Y, et al. Hepatitis C virus infection in spouses of patients with type C chronic liver disease. *Ann Intern Med.* 1994;120:748–752.
21. Chafen JJ, Newberry SJ, Riedl MA, et al. Diagnosing and managing common food allergies: a systematic review. *JAMA.* 2010;303:1848–1856.
22. Haas DA. An update on local anesthetics in dentistry. *J Can Dent Assoc.* 2002;68:546–551.
23. Yagiela JA. Injectable and topical local anesthetics. In: *American Dental Association: ADA/PDR Guide to Dental Therapeutics.* 5th ed. Chicago: American Dental Association; 2010.
24. Jackson D, Chen AH, Bennett CR. Identifying true lidocaine allergy. *J Am Dent Assoc.* 1994;125:1362–1366.
25. Shojaei AR, Haas DA. Local anesthetic cartridges and latex allergy: a literature review. *J Can Dent Assoc.* 2002;68:622–626.
26. Ball JW, Dains JE, Flynn JA, Solomon BS, eds. *Seidel's Guide to Physical Examination: An Interprofessional Approach (Mosby's Guide to Physical Examination).* 9th ed. St Louis: CV Mosby; 2019.
27. Gutenberg LL, Chen JW, Trapp L. Methemoglobin levels in generally anesthetized pediatric dental patients receiving prilocaine versus lidocaine versus. *Anesth Prog.* 2013;60:99–108.
28. Hersh EV, Moore PA, Papas AS, et al. Reversal of soft tissue local anesthesia with phentolamine mesylate. *J Am Dent Assoc.* 2008;139:1080–1093.
29. Malamed SF. Reversing local anesthesia. *Inside Dent.* 2008;4:2–3.
30. DerMarderosian A, Beutler JA, eds. *The Review of Natural Products.* St Louis: Drug Facts and Comparisons; 2017.
31. Fetrow CH, Avila JR. *Professional's Handbook of Complementary and Alternative Medicine.* Philadelphia: Lippincott Williams & Wilkins; 2003.
32. *Physicians' Desk Reference.* 71st ed. Oradell: Medical Economics; 2017.
33. Gruenwald J, Brendler T, Jaenicke C, eds. *Physicians' Desk Reference for Herbal Medicines.* Oradell: Medical Economics; 2011.
34. American Dental Association. *ADA/PDR Guide to Dental Therapeutics.* 5th ed. Chicago: Association Dental Association; 2010.
35. Smith DM, Lombardo JA, Robinson JB. The preparticipation evaluation, primary care. *Clin Off Pract.* 1991;18:777–807.
36. Perloff D, Grim C, Flack J, Frolich E, et al. Human blood pressure determination by sphygmomanometry. *J Amer Med Assoc.* 1993;88(5):2460–2470.
37. Pickering TG, Hall JE, Appel LJ, et al. Recommendations for blood pressure measurement in humans and experimental animals: part 1: blood pressure measurement in humans: a statement for professionals from the Subcommittee of professional and public education of the American Heart Association Council on High Blood Pressure Research. *Hypertension.* 2005;45:142–161.
38. Mitchell PT, Parlin RW, Blackburn H. Effect of vertical displacement of the arm on indirect blood pressure measurement. *N Engl J Med.* 1964;271:72–74.
39. Wonka F, Thümmel M, Schöppe A. Clinical test of a blood pressure measurement device with a wrist cuff. *Blood Press Monit.* 1996;361–366.
40. Manning DM, Kuchirka C, Kaminski J. Miscuffing: inappropriate blood pressure cuff application. *Circulation.* 1983;68:763–766.

41. Manning G, Rushton L, Millar-Craig MW. Clinical implications of white coat hypertension: an ambulatory blood pressure monitoring study. *J Human Hypertens*. 1999;13:817.
42. La Batide-Alamore A, Chateletier G, Booric G, et al. Comparison of nurse- and physician-determined clinic blood pressure levels in patients referred to a hypertension clinic: implications for subsequent management. *J Hypertens*. 2000;18:391–398.
43. Lane D, Beevers M, Barnes N, et al. Inter-arm differences in blood pressure: when are they clinically significant? *J Hypertens*. 2002;20:1089–1095.
44. American Society of Anesthesiologists. New classification of physical status. *Anesthesiology*. 1963;24:111.
45. Malamed SF. Blood pressure evaluation and the prevention of medical emergencies in dental practice. *J Prev Dent*. 1980;6:183.
46. Malamed SF: Prevention. In: *Handbook of Medical Emergencies in the Dental Office*. Malamed SF. 7th ed. St Louis: CV Mosby; 2015:43.
47. Ryan TJ, Antman EM, Brooks NH, et al. update: ACC/AHA guidelines for the management of patients with acute myocardial infarction: a report of the American College of Cardiology/American Heart Association Task Force on Practice Guidelines (Committee on Management of Acute Myocardial Infarction). *J Am Coll Cardiol*. 1999;34:890–911.
48. Epstein AE, DiMarco JP, Ellenbogen KA, et al. ACC/AHA/HRS 2008 guidelines for device-based therapy of cardiac rhythm abnormalities: a report of the American College of Cardiology/American Heart Association Task Force on Practice Guidelines (Writing Committee to Revise the ACC/AHA/NASPE 2002 Guideline Update for Implantation of Cardiac Pacemakers and Antiarrhythmia Devices): developed in collaboration with the American Association for Thoracic Surgery and Society of Thoracic Surgeons. *Circulation*. 2008;117:e350–e408.
49. Weber M. Pulsus alternans. A case study. *Crit Care Nurse*. 2003;23(3):51–54.
50. Centers for Disease Control and Prevention. Body mass index. Available from: <http://www.cdc.gov/healthyweight/assessing/bmi/>. Accessed July 30, 2015.
51. Mei Z, Grummer-Strawn LM, Pietrobelli A, et al. Validity of body mass index compared with other body-composition screening indexes for the assessment of body fatness in children and adolescents. *Am J Clin Nutr*. 2002;75:978–985.
52. Garrow JS, Webster J. Quetelet's index (W/H²) as a measure of fatness. *Int J Obesity*. 1985;9:147–153.
53. National Heart, Lung and Blood Institute. *Clinical Guidelines on the Identification, Evaluation, and Treatment of Overweight and Obesity in Adults: The Evidence Report*. Bethesda: National Heart, Lung and Blood Institute; 1996.
54. World Health Organization. *Physical Status: The Use and Interpretation of Anthropometry*. Geneva: World Health Organization; 1995.
55. Sturm R. Increases in morbid obesity in the USA: 2000–2005. *Public Health*. 2007;121:492–496.
56. Prentice AM, Jebb SA. Beyond body mass index. *Obesity Rev*. 2001;2:141–147.
57. Gallagher D, Visser M, Sepulveda D, et al. How useful is BMI for comparison of body fatness across age, sex and ethnic groups? *Am J Epidemiol*. 1996;143:228–239.
58. Malamed SF. Prevention. In: Malamed SF, ed. *Medical Emergencies in the Dental Office*. 7th ed. St Louis: Mosby; 2015.
59. Little JW, Falace DA, Miller CS, Rhodus NL, eds. *Dental Management of the Medically Compromised Patient*. 9th ed. St Louis: Elsevier Health Sciences; 2017.
60. McCarthy FM, Malamed SF. Physical evaluation system to determine medical risk and indicated dental therapy modifications. *J Am Dent Assoc*. 1979;99:181–184.
61. American Society of Anesthesiologists. New classification of physical status. *Anesthesiology*. 1963;24:111.
62. Lagasse RS. Anesthesia safety: model or myth? A review of the published literature and analysis of current original data. *Anesthesiology*. 2002;97:1609–1617.
63. American Society of Anesthesiologists. *ASA physical status classification system*; 2014. <http://www.asahq.org/quality-and-practice-management/standards-guidelines-and-related-resources/asa-physical-status-classification-system>. Accessed March 8, 2018.
64. Moore PA, Gage TW, Hersh EV, et al. Adverse drug interactions in dental practice: professional and educational implications. *J Am Dent Assoc*. 1999;130:17–54.
65. Kishikawa K, Namiki A, Miyashita K, et al. Effects of famotidine and cimetidine on plasma levels of epidurally administered lignocaine. *Anaesthesia*. 1990;45:719–721.
66. Wood M. Pharmacokinetic drug interactions in anaesthetic practice. *Clin Pharmacokinet*. 1991;21:85–307.
67. Wu FL, Razzaghi A, Souney PE. Seizure after lidocaine for bronchoscopy: case report and review of the use of lidocaine in airway anesthesia. *Pharmacotherapy*. 1993;13:12–78.
68. Moore PA. Adverse drug interactions in dental practice: interactions associated with local anesthetics, sedatives and anxiolytics. Part IV of a series. *J Am Dent Assoc*. 1999;130:441–554.
69. Wilburn-Goo D, Lloyd LM. When patients become cyanotic: acquired methemoglobinemia. *J Am Dent Assoc*. 1999;130:26–31.
70. Jastak JT, Yagiela JA. Vasoconstrictors and local anesthesia: a review and rational use. *J Am Dent Assoc*. 1983;107:623–630.
71. Boakes AJ, Laurence DR, Lovel KW, et al. Adverse reactions to local anesthetic vasoconstrictor preparations: a study of the cardiovascular responses to Xylesthesin and Hostcain with nor-adrenaline. *Br Dent J*. 1972;133:137–140.
72. Yagiela JA, Duffin SR, Hunt LM. Drug interactions and vasoconstrictors used in local anesthetic solutions. *Oral Surg*. 1985;59:565–571.
73. Hansbrough JF, Near A. Propranolol-epinephrine antagonism with hypertension and stroke. *Ann Intern Med*. 1980;92:717.
74. Kram J, Bourne HR, Melmon KL, et al. *Propranolol*. *Ann Intern Med*. 1974;80:282.
75. Foster CA, Aston SJ. Propranolol-epinephrine interaction: a potential disaster. *Reconstr Surg*. 1983;72:74–78.
76. Ghoneim MM. Drug interactions in anaesthesia: a review. *Can Anaesthet Soc J*. 1971;18:353–375.
77. Reichle FM, Conzen PF. Halogenated inhalational anaesthetics: best practice and research. *Clin Anaesthesiol*. 2003;17:19–46.
78. Hardman JG, Limbird LE, eds. *Goodman and Gilman's the Pharmacological Basis of Therapeutics*. 10th ed. New York: McGraw-Hill; 2001.
79. Hoffman BB, Lefkowitz RJ, Taylor P. Neurotransmission: the autonomic and somatic motor nervous systems. In: *Goodman and Gilman's the Pharmacological Basis of Therapeutics*. 9th ed. New York: McGraw-Hill; 1996.
80. Benzaquen BS, Cohen V, Eisenberg MJ. Effects of cocaine on the coronary arteries. *Am Heart J*. 2001;142:302–410.
81. Gradman AH. Cardiac effects of cocaine: a review. *Biol Med*. 1988;61:137–141.
82. Vasica G, Tennant CC. Cocaine use and cardiovascular complications. *Med J Austral*. 2002;177:260–262.
83. Hahn IH, Hoffman RS. Cocaine use and acute myocardial infarction. *Emerg Med Clin North Am*. 2001;19:493–510.
84. Myerburg RJ. Sudden cardiac death in persons with normal (or near normal) hearts. *Am J Cardiol*. 1997;79:3–9.
85. Van Dyke D, Barash PG, Jatlow P, et al. Cocaine: plasma concentrations after intranasal application in man. *Science*. 1976;191:859–861.
86. Friedlander AH, Gorelick DA. Dental management of the cocaine addict. *Oral Surg*. 1988;65:45–48.
87. Perusse R, Goulet J-P, Turcotte J-Y. Contraindications to vasoconstrictors in dentistry. Part III. Pharmacologic interactions. *Oral Surg Oral Med Oral Pathol*. 1992;74:592–697.

88. Debruyne FM. Alpha blockers: are all created equal? *Urology*. 2000;56(5 suppl 1):20–22.
89. Emmelin N, Engstrom J. Supersensitivity of salivary glands following treatment with bretteium or guanethidine. *Br J Pharmacol Chemother*. 1961;16:15–319.
90. McDevitt DG, Riddell JG, Hadden DR, et al. Catecholamine sensitivity in hyperthyroidism and hypothyroidism. *Br J Clin Pharmacol*. 1978;6:97–301.
91. Johnson AB, Webber J, Mansell P, et al. Cardiovascular and metabolic responses to adrenaline infusion in patients with short-term hypothyroidism. *Clin Endocrinol*. 1995;43:647–751.
92. Yagiela JA. Adverse drug interactions in dental practice: interactions associated with vasoconstrictors. Part V of a series. *J Am Dent Assoc*. 1999;130:501–709.
93. Hersh EV. Adverse drug interactions in dental practice: interactions involving antibiotics. Part II of a series. *J Am Dent Assoc*. 1999;130:236–251.
94. Haas DA. Adverse drug interactions in dental practice: interactions associated with analgesics. Part III of a series. *J Am Dent Assoc*. 1999;130:397–407.
95. Rosenberg H, Fletcher JE. An update on the malignant hyperthermia syndrome. *Ann Acad Med Singapore*. 1994;23(suppl 6):84–97.
96. Carson JM, Van Sickels JE. Preoperative determination of susceptibility to malignant hyperthermia. *J Oral Maxillofac Surg*. 1982;40:432–435.
97. Gielen M, Viering W. 3-in-1 lumbar plexus block for muscle biopsy in malignant hyperthermia patients: amide local anaesthetics may be used safely. *Acta Anaesthesiol Scand*. 1986;30:581–583.
98. Paasuke RT, Brownell AKW. Amine local anaesthetics and malignant hyperthermia. *Can Anaesth Soc J*. 1986;33:126–129.
99. Ording H. Incidence of malignant hyperthermia in Denmark. *Anesth Analg*. 1985;64:700–704.
100. Malignant Hyperthermia Association of the United States: Anesthetic list for MH-susceptible patients. <https://www.mhaus.org>. Accessed 29 November 2018.
101. Jurkat-Rott K, McCarthy T, Lehmann-Horn F. Genetics and pathogenesis of malignant hyperthermia. *Muscle Nerve*. 2000;23:1–17.
102. Steelman R, Holmes D. Outpatient dental treatment of pediatric patients with malignant hyperthermia: report of three cases. *ASDC J Dent Child*. 1992;59:12–65.
103. Amato R, Giordano A, Patrignani F, et al. Malignant hyperthermia in the course of general anesthesia in oral surgery: a case report. *J Int Assoc Dent Child*. 1981;12:15–28.
104. The European Malignant Hyperpyrexia Group. A protocol for the investigation of malignant hyperpyrexia (MH) susceptibility. *Br J Anaesth*. 1984;56:1267–1269.
105. Malignant Hyperthermia Association of the United States. MHAUS Professional Advisory Council adopts new policy statement on local anesthetics. *Communicator*. 1985;3:4.
106. Adragna MG. Medical protocol by habit: avoidance of amide local anesthetics in malignant hyperthermia susceptible patients. *Anesthesiology*. 1985;62:99–100 (letter).
107. Adriani J, Sundin R. Malignant hyperthermia in dental patients. *J Am Dent Assoc*. 1984;108:180–184.
108. Kaus SJ, Rockoff MA. Malignant hyperthermia. *Pediatr Clin North Am*. 1994;41:121–237.
109. Williams FM. Clinical significance of esterases in man. *Clin Pharmacokinet*. 1985;10:392–403.
110. Abernethy MH, George PM, Herron JL, et al. Plasma cholinesterase phenotyping with use of visible-region spectrophotometry. *Clin Chem*. 1986;32:194–197. 1 Pt 1.
111. Prilocaine-induced methemoglobinemia-Wisconsin, 1993. *MMWR Morb Mortal Wkly Rep*. 1994;43:555–657.
112. Bellamy MC, Hopkins PM, Hallsall PJ, et al. A study into the incidence of methaemoglobinaemia after “three-in-one” block with prilocaine. *Anaesthesia*. 1992;47:1084–1085.
113. Guertler AT, Pearce WA. A prospective evaluation of benzocaine-associated methemoglobinemia in human beings. *Ann Emerg Med*. 1994;24:426–630.
114. Rodriguez LF, Smolik LM, Zbehlik AJ. Benzocaine-induced methemoglobinemia: a report of a severe reaction and review of the literature. *Ann Pharmacother*. 1994;28:543–649.
115. Eilers MA, Garrison TE. General management principles. In: Marx J, Hockberger R, Walls R, eds. *Rosen's Emergency Medicine: Concepts and Clinical Practice*. 5th ed. St Louis: Mosby; 2002.
116. Sarangi MP, Kumar B. Poisoning with writing ink. *Indian Pediatr*. 1994;31:756–857.
117. Daly DJ, Davenport J, Newland MC. Methemoglobinemia following the use of prilocaine. *Br J Anaesth*. 1964;36:737–739.

Basic Injection Technique

Absolutely nothing that is done for patients by their dentist is of greater importance than the comfortable administration of a drug that prevents pain during dental treatment.¹ Yet the very act of administering a local anesthetic commonly induces great anxiety or is associated with pain in the recipient. Patients frequently mention that they would prefer anything to the injection or “shot” (to use the American patients’ term for the local anesthetic injection). Not only can the injection of local anesthetics produce fear and pain, it is also a factor in the occurrence of emergency medical situations. In a review of medical emergencies developing in Japanese dental offices, Matsuura² determined that 54.9% of emergency situations arose either during administration of the local anesthetic or in the 5 minutes immediately after its administration. Most of these emergency situations were directly related to increased stress associated with receipt of the anesthetic (the injection) and were not related to the drug being used. Moreover, in a survey on the occurrence of medical emergencies in dental practices in North America, 4309 dentists responded that a total of more than 30,000 emergency situations had developed in their offices over the previous 10 years.³ Ninety-five percent of respondents stated that they had experienced a medical emergency in their office in that period. More than half of these emergencies (15,407) were vasodepressor syncope (common faint), most of which occurred during or immediately after administration of the local anesthetic.

Local anesthetics can and should be administered in a nonpainful, or atraumatic, manner. Most dental students’ first injections were given to a classmate “patient,” who then gave the same injection to the student who had just given them an injection. Most likely, these students went out of their way to make their injections as painless as possible. At the Herman Ostrow School of Dentistry of the USC, these first injections are usually absolutely atraumatic. Students are routinely surprised by this, some having experienced the more usual (e.g., painful) injection at some time in the past when they were “real” dental patients. Why should there be a difference in dental injections and in the degree of pain between injections administered by an inexperienced beginning student and those given by a more experienced practitioner? All too often, local anesthetic administration

becomes increasingly traumatic for the patient the longer a dentist has been out of school. Can this discouraging situation be corrected?

Local anesthetic administration need not, and should not, be painful. Every one of the local anesthetic techniques presented in the following chapters can be done atraumatically, including the administration of local anesthetics on the palate (*the* most sensitive area in the oral cavity). Several skills and attitudes are required of the drug administrator, the most important of which is empathy. If the administrator truly believes that local anesthetic injections do not have to be painful, then through a conscious or subconscious effort, it is possible to make minor changes in technique that will cause formerly traumatic procedures to be less painful for the patient.

Additionally, the ability to buffer the local anesthetic solution to a more physiologic pH of approximately 7.6 from the pH of 3.5 in the cartridge (of the drug containing a vasoconstrictor) has greatly aided in the process of atraumatic injection.⁴⁻⁶

An atraumatic injection has two components: a technical aspect and a communicative aspect.

◆ Step 1: Use a Sterilized Sharp Needle

The stainless steel disposable needles currently used in dentistry are sharp and rarely produce any pain on insertion or withdrawal. However, because these needles are machine manufactured, occasionally (rarely) a fishhook-type barb may appear on the tip (Fig. 11.1). This results in atraumatic insertion of the needle, followed by painful withdrawal as the barb tears the unanesthetized tissue. This may be avoided by use of sterile 2- × 2-inch gauze. Place the needle tip against the gauze and draw the needle backward. If the gauze is snagged, a barb is present and the needle should not be used. (This procedure is optional and may be omitted if fear of needle contamination is great.)

Disposable needles are sharp on first insertion. However, with each succeeding penetration, their sharpness diminishes. By the third or fourth penetration, the operator can feel an increase in tissue resistance to needle penetration. Clinically, this is evidenced by increased pain on penetration—as the needle tears rather than cuts tissue—and



• Fig. 11.1 Microscopic view of barb on a dental needle.

increased postanesthetic tissue discomfort. Therefore it is recommended that stainless steel disposable needles be changed after every three or four tissue penetrations.

The gauge of the needle should be determined solely by the injection to be administered. Pain caused by needle penetration in the absence of adequate topical anesthesia can be eliminated in dentistry through the use of needles not larger than 25 gauge. Multiple studies have demonstrated that patients cannot differentiate among 25-, 27-, and 30-gauge needles inserted into mucous membranes, even without the benefit of topical anesthesia.⁷⁻⁹ Needles of 23 gauge and larger are associated with increased pain on initial insertion.

◆ Step 2: Check the Flow of Local Anesthetic Solution

After the cartridge has been properly loaded into the syringe, and with the aspirator tip (harpoon) embedded in the silicone rubber stopper (unless a self-aspirating syringe is being used), a few drops of local anesthetic should be expelled from the cartridge. This ensures a free flow of solution when it is deposited at the target area. The stoppers on the anesthetic cartridge are made of a silicone rubber to ensure ease of administration. Only a few drops of the solution should be expelled from the needle to determine whether a free flow of solution occurs.

◆ Step 3: Determine Whether to Warm the Anesthetic Cartridge or Syringe

If the cartridge is stored at room temperature (approximately 22°C, 72°F), there is no reason for a local anesthetic cartridge to be warmed before injection of the anesthetic into soft tissues. The patient will not perceive local anesthetic solution stored at room temperature as too cold or too hot when it is injected.

Most complaints concerning overly warm local anesthetic cartridges pertain to those stored in cartridge warmers heated by a (Christmas tree–type) light bulb. The temperatures within these cartridges frequently become excessive,

leading to patient discomfort and adverse effects on the contents of the cartridge (see Chapter 7).¹⁰

Cartridges stored in refrigerators or other cool areas should be brought to room temperature before use.

Some persons advocate slight warming of the metal syringe before its use. The rationale is that a cold metal object is psychologically more disturbing to the patient than is the same object at room temperature. It is recommended that both the local anesthetic cartridge and the metal syringe be as close to room temperature as possible, preferably without the use of any mechanical devices to achieve this temperature. Holding the loaded metal syringe in the palm of one's hand for 30 seconds before injection warms the metal. Plastic syringes do not pose this problem.

◆ Step 4: Position the Patient

Any patient receiving local anesthetic injections should be in a physiologically sound position before and during the injection.

Vasodepressor syncope (common faint), the most commonly seen medical emergency in dentistry, most often occurs before, during, and, on occasion, immediately after local anesthetic administration. The primary pathophysiologic component of this situation is cerebral ischemia secondary to an inability of the heart to supply the brain with an adequate volume of oxygenated blood. When a patient is seated in an upright position, the usual effect of gravity is such that the blood pressure in cerebral arteries is decreased by 2 mmHg for each inch above the level of the heart.

In the presence of anxiety, blood flow is increasingly directed toward the skeletal muscles at the expense of other organ systems such as the gastrointestinal tract (the “fight-or-flight” response). In the absence of muscular movement (“I can take it like a man!”), the increased volume of blood in skeletal muscles remains there, decreasing venous return to the heart and decreasing the volume of blood available to be pumped by the heart (uphill) to the brain. Decreased cerebral blood flow is evidenced by the appearance of signs and symptoms of vasodepressor syncope (e.g., light-headedness, dizziness, tachycardia, palpitations). If this situation continues, cerebral blood flow declines still further, and consciousness is lost.

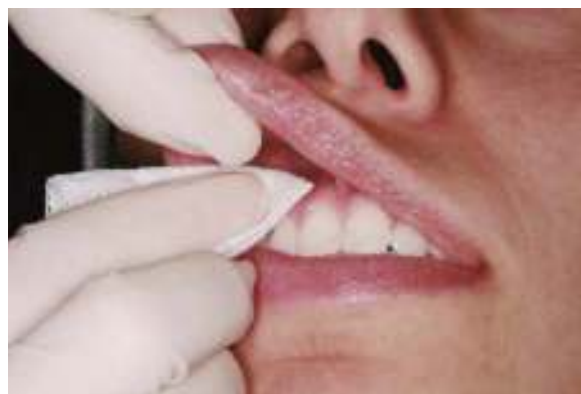To prevent this, it is recommended that during local anesthetic administration, the patient should be placed in a supine position (head and heart parallel to the floor) with the feet elevated slightly (Fig. 11.2). Although this position may vary according to the dentist's and the patient's preference, the patient's medical status, and the specific injection technique, all techniques of regional block anesthesia can be performed successfully with the patient in this physiologic position.

◆ Step 5: Dry the Tissue

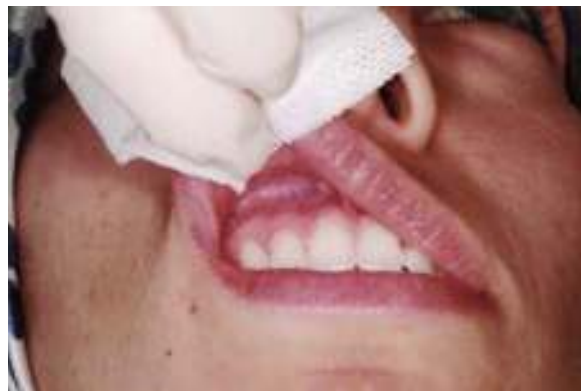A 2- × 2-inch gauze should be used to dry the tissue in and around the site of needle penetration and to remove



• **Fig. 11.2** Physiologic position of patient for receipt of local anesthetic injection.



• **Fig. 11.3** Sterilized gauze is used to gently wipe tissue at site of needle penetration.

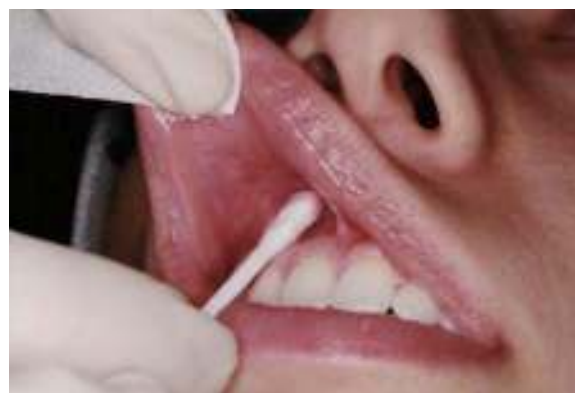

• **Fig. 11.4** Sterilized gauze may also be used as an aid in tissue retraction.

any gross debris (Fig. 11.3). In addition, if the lip must be retracted to attain adequate visibility during the injection, it too should be dried to ease retraction (Fig. 11.4).

◆ Step 6: Apply Topical Antiseptic (Optional)

After the tissues have been dried, a suitable topical antiseptic should be applied at the site of injection. This further decreases the risk of introducing septic materials into the



• **Fig. 11.5** A small quantity of topical anesthetic is placed at the site of needle penetration and is kept in place for at least 1 minute.

soft tissues, producing inflammation, or infection. The antiseptics used include povidone-iodine (Betadine) and thimerosal (Merthiolate). Alcohol-containing antiseptics can cause burning of the soft tissue and should be avoided. (This step is optional; however, the preceding step [step 5] of drying the tissue must not be eliminated.)

◆ Step 7A: Apply Topical Anesthetic

A topical anesthetic is applied after the topical antiseptic. As with the topical antiseptic, it should be applied only at the site of needle penetration. All too often, excessive amounts of topical anesthetic are used on large areas of soft tissue, producing undesirably wide areas of anesthesia (e.g., the soft palate, the pharynx), an unpleasant taste, and, perhaps even more important with some topical anesthetics (such as lidocaine), rapid absorption into the cardiovascular system, leading to higher local anesthetic blood levels, which increase the risk of overdose. Only a small quantity of topical anesthetic should be placed on the cotton applicator stick and applied directly at the injection site (Fig. 11.5).

Topical anesthetics produce anesthesia of the outermost 2 or 3 mm of mucous membrane; this tissue is quite sensitive. Ideally the topical anesthetic should remain in contact with the tissue for 2 minutes to ensure effectiveness.^{11,12} A minimum application time of 1 minute is recommended.

◆ Step 7B: Communicate With the Patient

During the application of topical anesthetic, it is desirable for the administrator to speak to the patient about the reasons it is being used. Tell the patient, “I’m applying a topical anesthetic to the tissue so that the remainder of the procedure will be much more comfortable.” This statement places a positive idea in the patient’s mind concerning the upcoming injection.

Note that the words *injection*, *shot*, *pain*, and *hurt* are not used. These words have a negative connotation; tending to increase a patient’s fears. Their use should be avoided if at all possible. More positive (e.g., less threatening) words can be substituted in their place. “Administer the local anesthetic”

is used in place of “Give an injection” or “Give a shot.” The latter is a particularly poor choice of words and must be avoided. Commonly used words are *freeze* and *freeze*, as in “I’m going to freeze you now.” A statement such as “This will not hurt” should also be avoided. Patients hear only the word *hurt*, ignoring the rest of the statement. The same is true for the word *pain*. An alternative to this is the word *discomfort*. Although their meanings are similar, *discomfort* is much less threatening and produces less fear.

◆ Step 8: Establish a Firm Hand Rest

After removal of the topical anesthetic swab, the prepared local anesthetic syringe should be picked up (see Chapter 9). It is essential to maintain complete control over it at all times. To do so requires a steady hand so that tissue penetration may be accomplished readily, accurately, and without inadvertent nicking of tissues. A firm hand rest is necessary. The types of hand rest differ according to the practitioner’s likes, dislikes, and physical abilities. Persons with long fingers can use finger rests on the patient’s face for many injections; those with shorter fingers may need elbow rests. Figs. 11.6 to 11.8 illustrate various hand and finger rests that can be used to stabilize the local anesthetic syringe.

Any finger or hand rest that permits the syringe to be stabilized without increasing risk to a patient is acceptable. Two techniques to be avoided are (1) using no syringe stabilization of any kind and (2) placing the arm holding the syringe directly onto the patient’s arm or shoulder (Fig. 11.9). In the first situation, it is highly unlikely that a needle can be adequately stabilized without the use of some form of rest. The administrator has less control over the syringe, thereby increasing the possibility of inadvertent needle movement and injury. Resting on a patient’s arm or shoulder is also dangerous and can lead to patient or administrator needlestick injury. If the patient moves during the injection, damage can occur as the needle tip moves around within the mouth. Apprehensive patients, especially children, frequently move their arms during local anesthetic administration.

◆ Step 9: Make the Tissue Taut

The tissues at the site of needle penetration should be stretched before insertion of the needle (Fig. 11.10). This can be accomplished in all areas of the mouth except the palate (where the tissues are naturally quite taut). Stretching of the tissues permits the sharp stainless steel needle to cut through the mucous membrane with minimal resistance. Loose tissues, on the other hand, are pushed and torn by the needle as it is inserted, producing greater discomfort on injection and increased postoperative soreness.

Techniques of distraction are also effective in this regard. Some dentists jiggle the lip as the needle is inserted; others recommend leaving the needle tip stationary and pulling the soft tissues over the needle tip (Fig. 11.11). Devices that are attached to the syringe that produce vibration as

the injection is given are available. Two examples are DentalVibe (BING Innovations LLC, Boca Raton, Florida, United States; Fig. 11.12) and VibraJect (VibraJect LLC, Newport Coast, California, United States; Fig. 11.13). Although nothing is inherently wrong with distraction techniques, there is generally no need for them. Because the administrator should maintain sight of the needle tip at all times, needles should not be inserted blindly into tissues, as is necessitated by some of the distraction techniques (e.g., pulling lip over needle tip).

Proper application of topical anesthetic, taut tissues, and a firm hand rest can produce an unnoticed initial penetration of tissues virtually 100% of the time.

◆ Step 10: Keep the Syringe Out of the Patient’s Line of Sight

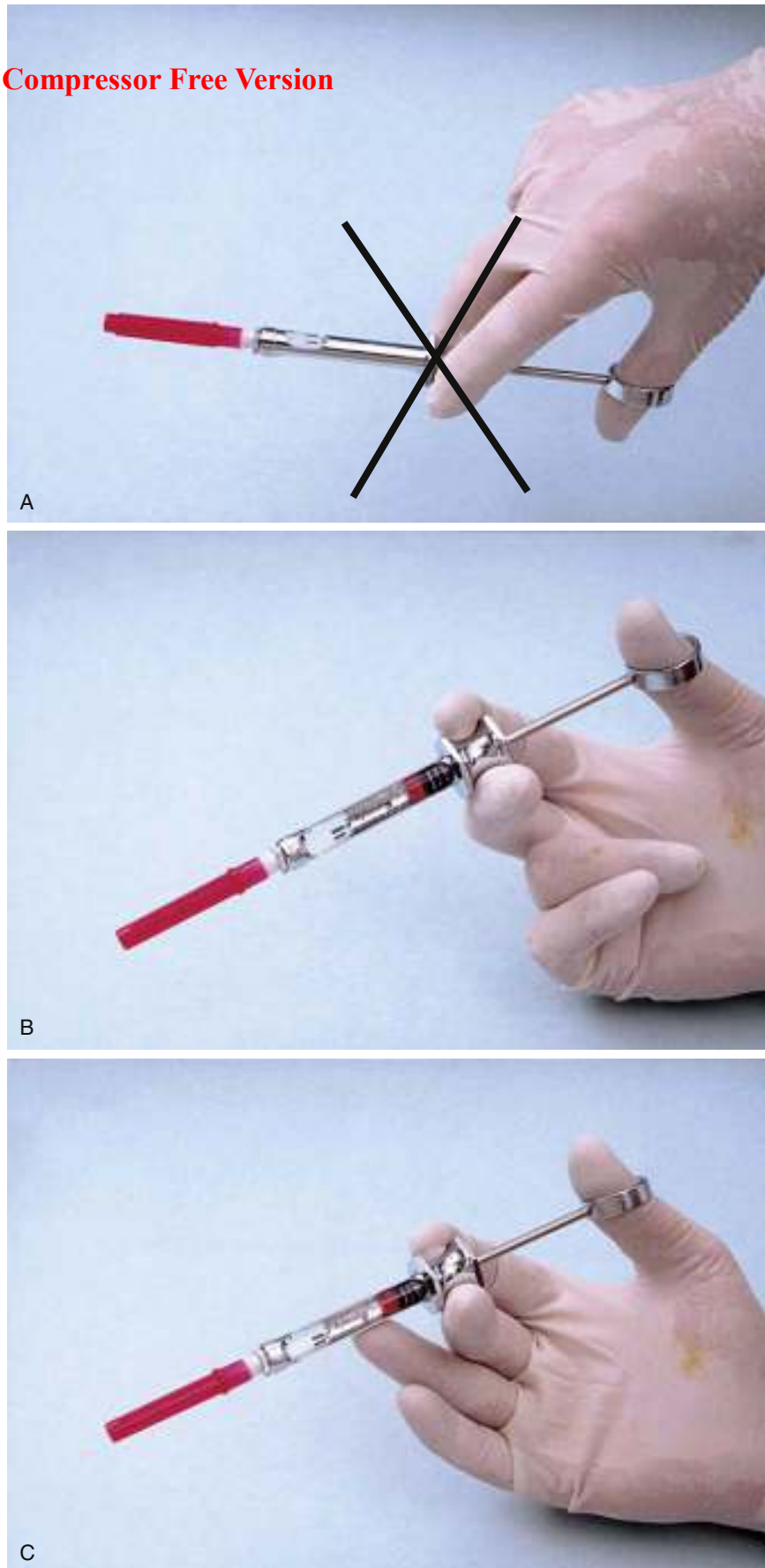
With the tissue prepared and the patient positioned, the assistant should pass the syringe to the administrator out of the patient’s line of sight either behind the patient’s head (Fig. 11.14) or across and in front of the patient (Fig. 11.15). A right-handed practitioner administering a right-sided injection can sit facing the patient or, if administering a left-sided injection, facing in the same direction as the patient. In all cases, it is better if the syringe is not visible to the patient. Proper positioning for left-handed administrators is a mirror image of that for right-handed ones. (Specific recommendations for administrator positioning during local anesthetic injections are discussed in Chapters 13 and 14.)

◆ Step 11A: Insert the Needle Into the Mucosa

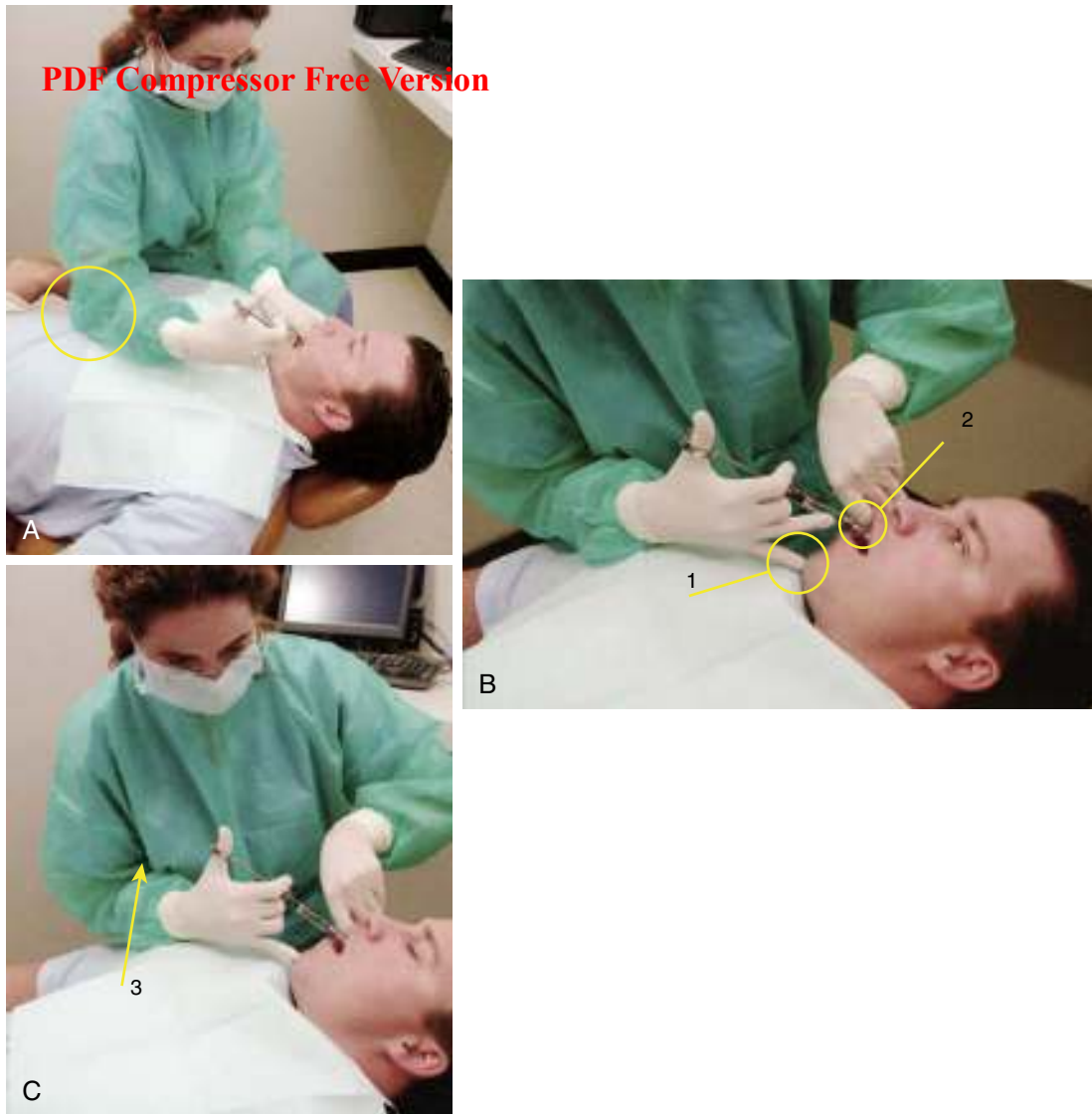With the needle bevel properly oriented (see the specific injection technique for bevel orientation; however, as a general rule, the bevel of the needle should be oriented toward bone), insert the needle gently into the tissue at the injection site (where the topical anesthetic was placed) to the depth of its bevel. With a firm hand rest and adequate tissue preparation, this potentially traumatic procedure is accomplished without the patient ever being aware of it.

◆ Step 11B: Watch and Communicate With the Patient

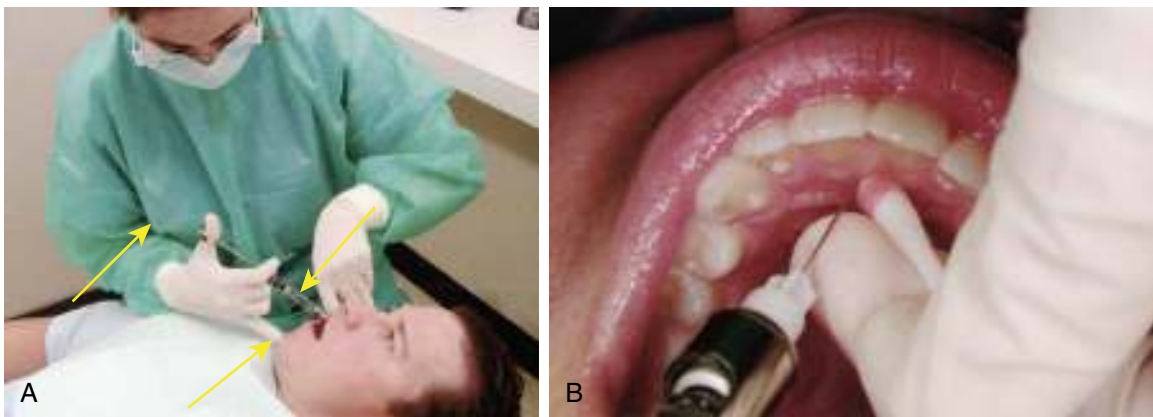
During step 11A the patient should be watched and communicated with; the patient’s face should be observed for evidence of discomfort during needle penetration. Signs such as furrowing of the brow or forehead and blinking of the eyes may indicate discomfort (Fig. 11.16). More frequently, no change will be noticed in the patient’s facial expression at this time (indicating a painless, or atraumatic, needle insertion).

PDF Compressor Free Version

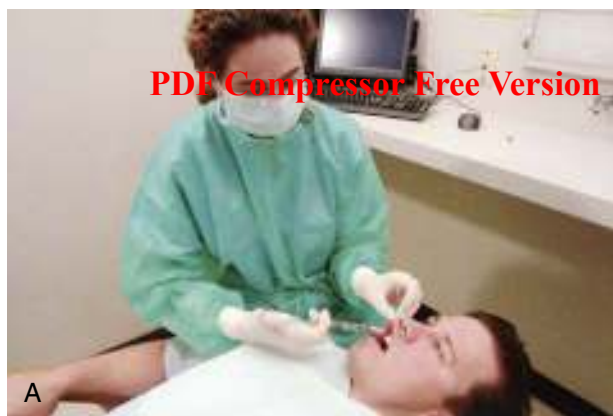• **Fig. 11.6** Hand positions for injections. (A) Palm down: poor control over the syringe; not recommended. (B) Palm up: better control over the syringe because it is supported by the wrist; recommended. (C) Palm up and finger support: greatest stabilization; highly recommended.



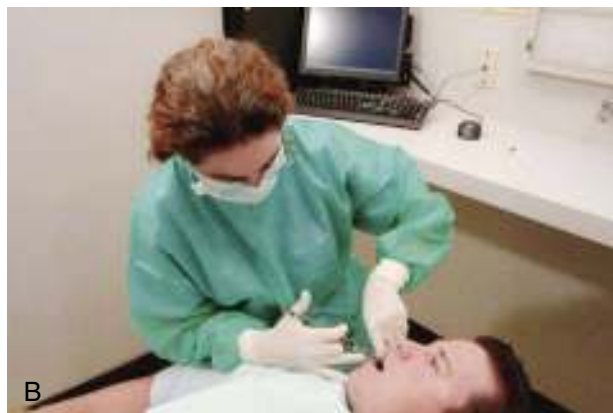• **Fig. 11.7** (A) Use of the patient's chest for stabilization of the syringe during right inferior alveolar nerve block (*circle*). Never use the patient's arm to stabilize a syringe. (B) Use of the chin (*1*) as a finger rest, with the syringe barrel stabilized by the patient's lip (*2*). (C) When necessary, stabilization may be increased by the administrator drawing his or her arm in against his or her chest (*3*).



• **Fig. 11.8** (A) Syringe stabilization for a right posterior superior alveolar nerve block: syringe barrel on the patient's lip, one finger resting on the chin and one on the syringe barrel (*arrows*), upper arm kept close to the administrator's chest to maximize stability. (B) Syringe stabilization for a nasopalatine nerve block: index finger used to stabilize the needle, syringe barrel resting in the corner of the patient's mouth.

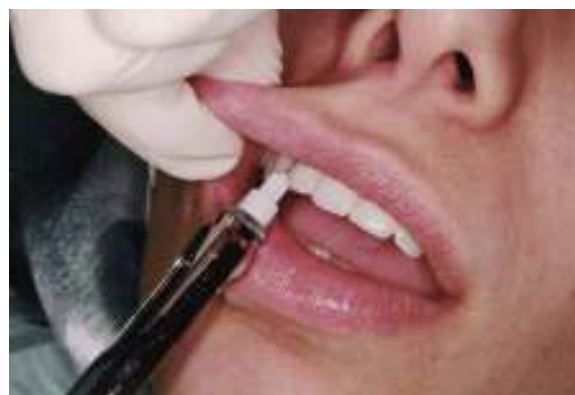

A

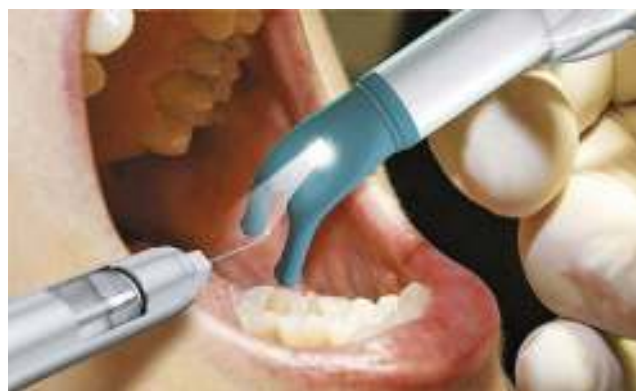

B

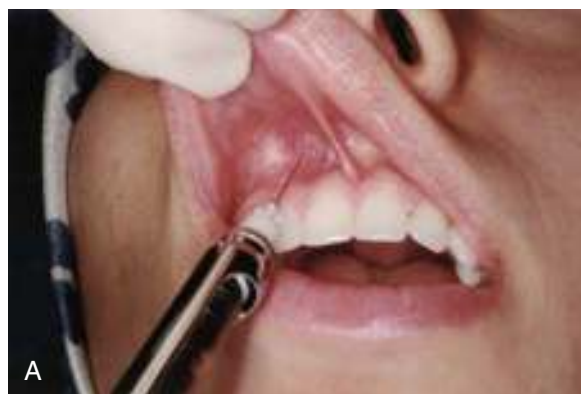- **Fig. 11.9** (A) Incorrect position: no hand or finger rest for stabilization of the syringe. (B) Incorrect position: administrator resting elbow on patient's arm.



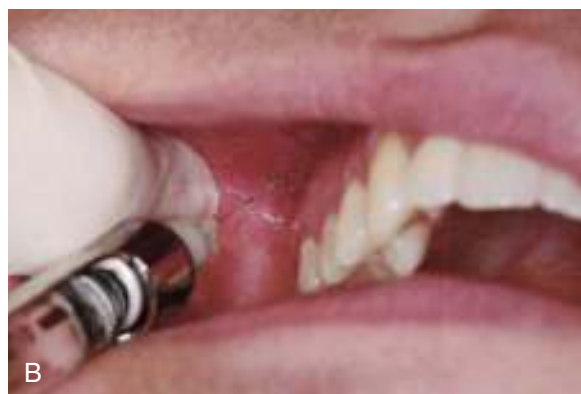- **Fig. 11.11** When soft tissues are pulled over the needle, visualization of the injection site is impaired.



- **Fig. 11.12** DentalVibe.

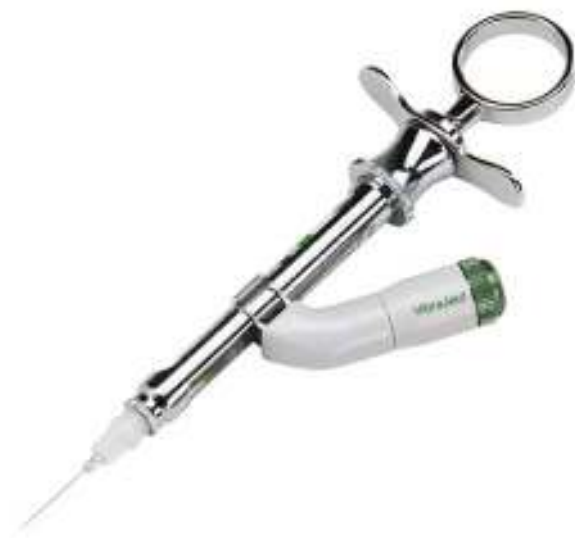

A



B

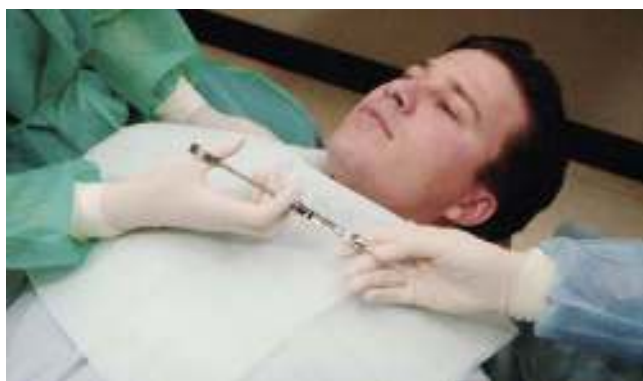- **Fig. 11.10** (A) Tissue at needle penetration site is pulled taut, aiding both visibility and atraumatic needle insertion. (B) Taut tissue provides excellent visibility of the penetration site for a posterior superior alveolar nerve block.



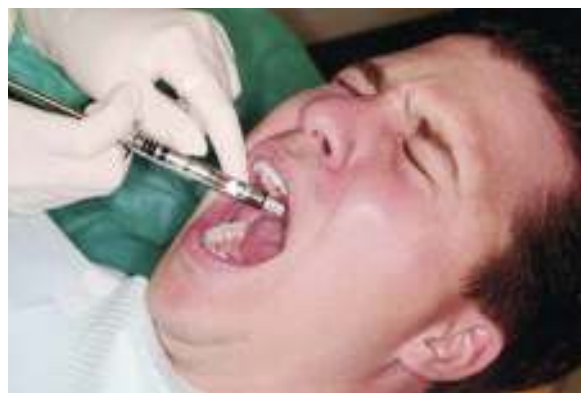- **Fig. 11.13** VibraJect. (Courtesy GoldenDent Inc.)



• **Fig. 11.14** Passing the syringe from the assistant to the administrator behind the patient, out of his or her line of sight.



• **Fig. 11.15** Passing the syringe from the assistant to the administrator below the patient's line of sight.



• **Fig. 11.16** The patient's face should be observed during administration of local anesthetic; any squinting of the eyes or furrowing of the brows, indicating discomfort, should be noted.

The practitioner should communicate with the patient as step 11A is performed. The patient should be told in a positive manner, “I don't expect you to feel this,” as the needle penetrates the tissues. The words “This will not hurt” should be avoided as this is a negative statement, and the patient hears only the word *hurt*.

◆ Step 12: Inject Several Drops of Local Anesthetic Solution (Optional)

◆ Step 13: Slowly Advance the Needle Toward the Target.

Steps 12 and 13 are performed together. The soft tissue in front of the needle may be anesthetized with a few drops of local anesthetic solution. After 2 or 3 seconds are allowed for anesthesia to develop, the needle should be advanced into this area and a little more anesthetic deposited. The needle should then be advanced again. These procedures may be repeated until the needle reaches the desired target area. Use of a buffered local anesthetic will increase patient comfort during injection as a result of (1) the increased pH of the anesthetic solution (7.35 to 7.5) and (2) the presence of CO₂ in the buffered solution. CO₂ possesses anesthetic properties.¹³

In most patients, however, injection of local anesthetic during insertion of the needle toward the target area is entirely unnecessary. Pain is rarely experienced between the surface mucosa and the mucoperiosteum. If patients are asked after injection what they felt as the needle was being advanced through soft tissue (as in an inferior alveolar or posterior superior alveolar nerve block), the usual reply is that they were aware that something was there, but that it did not hurt.

On the other hand, patients who are apprehensive about injections of local anesthetics are likely to react to any sensation as though it were painful. These patients are said to have a lowered pain reaction threshold. Apprehensive patients should be told, “To make you more comfortable, I will deposit a little anesthetic as I advance (the needle) toward the target.” Minimal amounts of the local anesthetic should be injected as the process continues. In an injection such as the inferior alveolar nerve block, for which the average depth of needle insertion is 20 to 25 mm, not more than one-third of a cartridge of local anesthetic should be deposited as the soft tissues are penetrated. Aspiration need not be performed at this stage because of the small amount of anesthetic solution that is being continually deposited over a changing injection site. If a vessel were to be penetrated during this procedure, only one or two drops (<1 mg) of anesthetic would be deposited intravascularly—an innocuous volume. As the needle is advanced further, it leaves the vessel. However, aspiration should always be performed before any significant volume of solution is deposited (steps 15 and 16).

When patients who are more sensitive are being treated, or when local anesthetic is being injected into more sensitive tissues, the use of buffered local anesthetic solutions will be of great benefit in making penetration of soft tissues more comfortable for the patient.

◆ Step 14: Deposit Several Drops of Local Anesthetic Before Touching the Periosteum

PDF Compressor Free Version

In techniques of regional block anesthesia in which the needle touches or comes close to the periosteum, several drops of solution should be deposited just before contact. Periosteum is richly innervated, and contact with the needle tip produces pain. Anesthetizing the periosteum permits atraumatic contact. The regional block injection techniques that require this are the inferior alveolar, Gow-Gates mandibular, and anterior superior alveolar (infraorbital) nerve blocks.

Knowledge of when to deposit the local anesthetic is gained with experience. The depth of penetration of soft tissue at any injection site differs from patient to patient; therefore the periosteum may be contacted inadvertently. However, a keen tactile sense is developed with repetition, enabling the needle to be used gently as a probe. This allows the administrator to detect subtle changes in tissue density as the needle nears bone. With experience and development of this tactile sense, a small volume of local anesthetic solution may be deposited just before gentle contact with the periosteum.

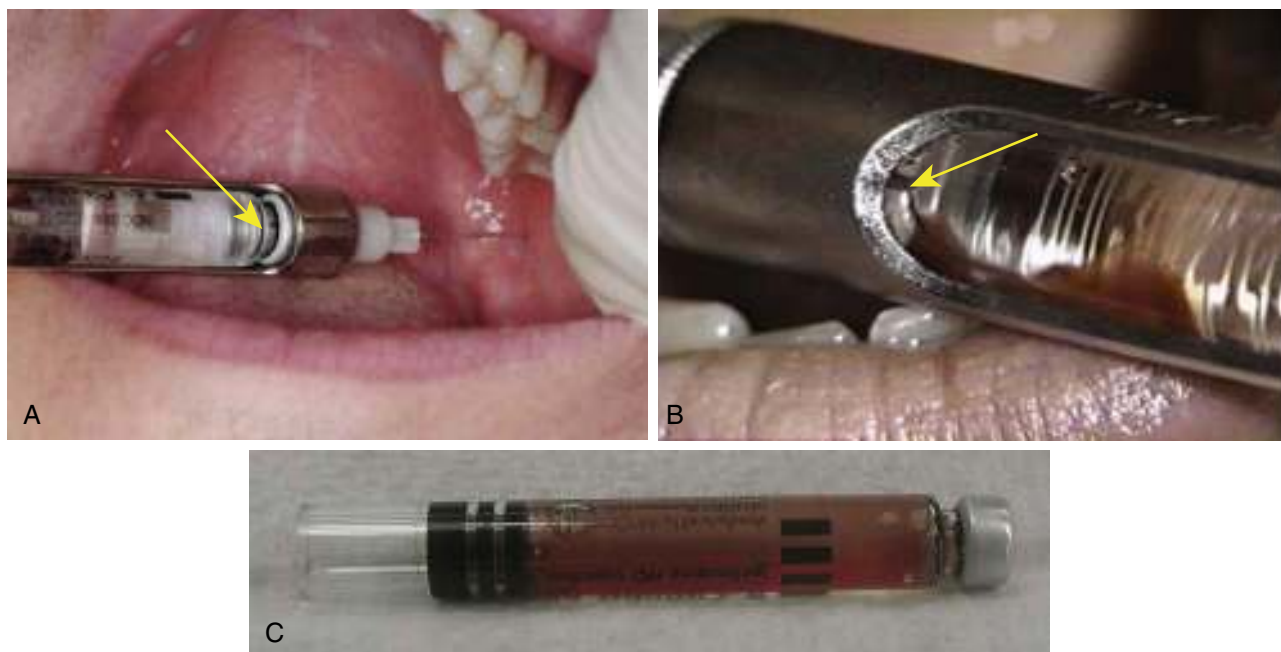
◆ Step 15: Aspirate

Aspiration must always be performed before a volume of local anesthetic is deposited at any site. Aspiration

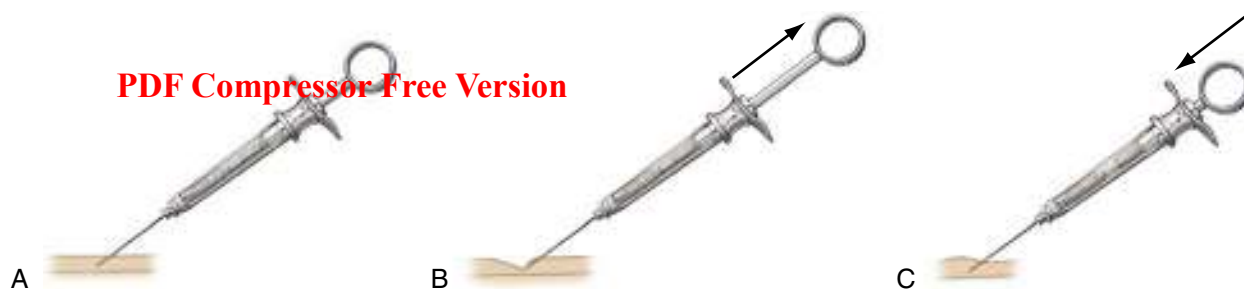dramatically minimizes the possibility of intravascular injection. The goal of aspiration is to determine where the needle tip is situated (within a blood vessel or without). To aspirate, one must create negative pressure within the dental cartridge. The self-aspirating syringe does this whenever the operator stops applying positive pressure to the thumb ring (plunger). With the traditional harpoon-aspirating syringe, the administrator must make a conscious effort to create this negative pressure within the cartridge.

Adequate aspiration requires that the tip of the needle remain unmoved, neither pushed farther into nor pulled out of the tissues, during the aspiration test. Adequate stabilization is mandatory. Neophytes have a tendency to pull the syringe out of the tissue while attempting to aspirate.

When the harpoon-aspirating syringe is used, the thumb ring should be pulled back gently. Movement of only 1 or 2 mm is needed. This produces negative pressure within the cartridge that then translates to the tip of the needle. Whatever is lying in the soft tissues around the needle tip (e.g., blood, tissue [or air, if tested out of the mouth]) will be drawn back into the anesthetic cartridge. By observing the needle end visible within the cartridge for signs of blood return, the administrator can determine whether positive aspiration has occurred. Any sign of blood represents a positive aspiration, and local anesthetic solution should not be deposited at that site (Fig. 11.17). No return at all, or a small air bubble, indicates a negative aspiration. Aspiration



• **Fig. 11.17** (A) Negative aspiration (No blood noticed). With the needle in position at the injection site, the administrator pulls the thumb ring of the harpoon-aspirating syringe 1 or 2 mm. The needle tip should not move. Check the cartridge at the site where the needle penetrates the diaphragm (*arrow*) for a bubble or blood. (B) Positive aspiration. A slight reddish discoloration at the diaphragm end of the cartridge (*arrow*) on aspiration usually indicates venous penetration. Reposition the needle, reaspirate, and, if negative, deposit the solution. (C) Positive aspiration. Bright red blood rapidly filling the cartridge usually indicates arterial penetration. Remove the syringe from the mouth, change the cartridge, and repeat the procedure.



• **Fig. 11.18** (A) Needle tip within blood vessel but bevel abuts the wall of the vein. (B) On aspiration the vein wall is sucked into the needle tip, producing a false negative aspiration test result. (C) Rotating the syringe 45 degrees and reaspirating will provide a true “positive” aspiration in this scenario.

should be performed *at least twice* before the larger volume of local anesthetic is administered (as required by the injection technique being used), with the orientation of the bevel changed (rotate about 45 degrees for the second aspiration test) to ensure that the bevel of the needle is not inside a blood vessel abutting the vessel wall, providing a false negative aspiration (Fig. 11.18). Several additional aspiration tests are suggested during administration of the anesthetic drug. This serves two functions: (1) to slow down the rate of anesthetic administration and (2) to preclude the deposition of large volumes of anesthetic into the cardiovascular system.

A major factor determining whether aspiration can be performed reliably is the gauge of the needle. Larger-gauge needles (e.g., 25 gauge) are recommended more often than smaller-gauge needles (e.g., 27 and 30 gauge) whenever a greater risk of positive aspiration exists.

◆ Step 16A: Slowly Deposit the Local Anesthetic Solution

With the needle in position at the target area and after (two) negative aspirations, the administrator should begin pressing gently on the plunger to start administering the predetermined (for the injection technique) volume of anesthetic. Slow injection is vital for two reasons: (1) of utmost significance is the safety factor (discussed in greater detail in Chapter 18) and (2) slow injection prevents the solution from tearing the tissue into which it is deposited. Kanaa et al.¹⁴ demonstrated that “slow” injection in the inferior alveolar nerve block produced a faster onset and greater efficacy of anesthesia. Rapid injection results in immediate discomfort (for a few seconds) followed by prolonged soreness (days) when the numbness provided by the local anesthetic dissipates later.

Slow injection is defined ideally as the deposition of 1 mL of local anesthetic solution in not less than 60 seconds. Therefore a full 1.8-mL cartridge requires approximately 2 minutes to be deposited. Through slow deposition the solution will diffuse along normal tissue planes without producing discomfort during or following injection.

Most local anesthetic administrators tend to inject these local anesthetics too rapidly. In a survey of 209 dentists, 84% stated that the average time spent to deposit 1.8 mL of local anesthetic solution was less than 20 seconds.¹⁵

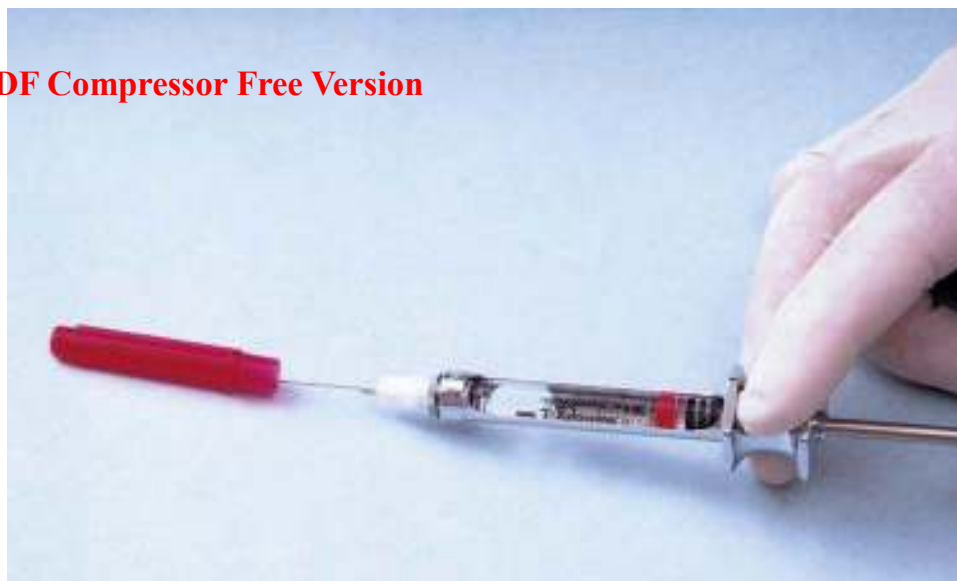In actual clinical practice, it therefore seems highly improbable to expect doctors to change their rate of injection from less than 20 seconds to a safe, comfortable, and more effective 2 minutes per cartridge. A more realistic time span in a clinical situation is 60 seconds for a full 1.8-mL cartridge. This rate of deposition of solution does not produce tissue damage during or after anesthesia and, in the event of accidental intravascular injection, does not produce an extremely serious reaction. Few injection techniques require the administration of 1.8 mL for success.

For many years, the author has used one particular method to slow the rate of injection. After two negative aspirations, he deposits a volume of solution (approximately one-fourth of the total to be deposited) and then aspirates again. If the aspiration is negative, he deposits another one-fourth of the solution, reaspirates, and continues this process until the appropriate volume of solution for the given injection is deposited. This enables him to do two positive things during injection: (1) to reaffirm through multiple negative aspirations that the solution is in fact being deposited extravascularly and (2) to stop the injection for aspiration; this automatically slows the rate of administration thereby minimizing patient discomfort. In the first situation, if positive aspiration occurs after deposition of one-fourth of a cartridge, only 9 mg of a 2% solution, or 13.5 mg of a 3% solution, or 18 mg of a 4% solution will have been deposited intravascularly—doses unlikely to provoke a drug-related adverse reaction. The needle tip should be repositioned, negative aspiration (twice) achieved, and the injection continued. The risk of an adverse reaction secondary to intravascular injection is greatly minimized in this manner.

◆ Step 16B: Communicate With the Patient

The patient should be communicated with during deposition of the local anesthetic. Most patients are accustomed to receiving their local anesthetic injections rapidly. Statements such as “I’m depositing the solution slowly so it will be more

PDF Compressor Free Version



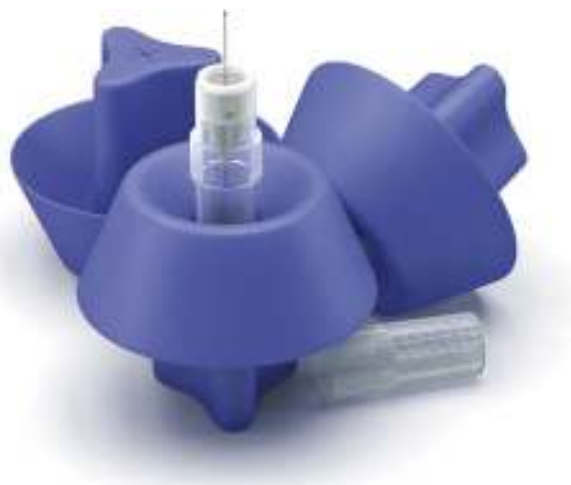• **Fig. 11.19** “Scoop” technique for recapping needle after use.

comfortable for you, but you’re not receiving any more than is usual” or “I’m doing this slowly so it will be more comfortable for you, but you’re not receiving any more than is usual” go far to allay a patient’s apprehension at this time. The second part of the statement is important, because some patients might not realize that there is a fixed volume of anesthetic solution in the syringe. A reminder that they are not receiving any more than is usual is a comfort to the patient.

◆ Step 17: Slowly Withdraw the Syringe

After completion of the injection, the syringe should be slowly withdrawn from the soft tissues and the needle made safe by capping it immediately with its plastic sheath via the scoop technique (Fig. 11.19) or a other safety device (Fig. 11.20).

Concerns about the possibility of needlestick injury and the spread of infection caused by inadvertent sticking with contaminated needles have led to the formulation of guidelines for the recapping of needles for health care providers.¹⁶ It has been demonstrated that the time health professionals are most likely to be injured with needles is when they are recapping the needle after administration of an injection.^{17,18} Following the injection the needle is contaminated with blood, tissue, and saliva. Devices have been marketed to aid the health professional in recapping the needle safely.¹⁹ Needle guards, placed over the needle cap before injection, prevent fingers from being stuck during recapping. Although guidelines are not yet in effect, the following are most often mentioned for preventing accidental needlestick: (1) needles should not be reused;(2) after use, needles should immediately be discarded into a sharps container. This policy, although applicable in almost all nondental hospital situations in which only one injection is administered, is, in many clinical situations, impractical in dentistry, where multiple injections are commonplace.



• **Fig. 11.20** Plastic needle cap holder. (Courtesy of Septodont, Inc, Lancaster, PA)

The “scoop” technique (see Fig. 11.19)—in which the needle cap has been placed on the instrument tray, and after injection the administrator simply slides the needle tip into the cap (without physically touching the cap), scooping up the needle cap—can be used for multiple injections without increased risk. The capped needle is then discarded in a sharps container (Fig. 11.21).

◆ Step 18: Observe the Patient

After completion of the injection, the doctor, hygienist, or assistant should remain with the patient while the anesthetic begins to take effect (and its blood level increases). Most true adverse drug reactions, especially those related to intraorally administered local anesthetics, develop either during the injection or within 5 to 10 minutes of its completion. All too often, reports are



• Fig. 11.21 Sharps container for needle.

heard of situations in which a local anesthetic was administered and the doctor left the patient alone for a few minutes only to return to find the patient unconscious or experiencing a seizure unconscious. Matsuura² reported that 54.9% of all medical emergencies arising in Japanese dental offices developed either during the injection of the local anesthetic or in the 5 minutes immediately after administration. *Patients should not be left unattended after administration of a local anesthetic.*

◆ Step 19: Record the Injection in the Patient's Dental Chart

An entry must be made of the local anesthetic drug used, the vasoconstrictor used (if any), the dose (in milligrams) of the solution(s) used, the needle(s) used, the injection(s) given, and the patient's reaction. For example, in the patient's dental progress notes, the following might be written: *R-IANB, 25-long, 2% lido + 1:100,000 epi, 36 mg. Tolerated procedure well.*

The administrator of local anesthetics who adheres to these steps develops a reputation among patients as a “painless dentist.” It is not possible to guarantee that every injection will be absolutely atraumatic because the reactions of both patients and doctors are far too variable. However, even when they feel some discomfort, patients invariably state that the injection was better than any other they had previously experienced. This should be the goal sought with every local anesthetic injection.

The atraumatic injection technique was developed over many years by Dr. Nathan Friedman and the Department of Human Behavior at the University of Southern California School of Dentistry. These principles are incorporated into this section.

ATRAUMATIC INJECTION TECHNIQUE

1. Use a sterilized sharp needle.
2. Check the flow of local anesthetic solution.
3. Determine whether to warm the anesthetic cartridge or syringe.
4. Position the patient.
5. Dry the tissue.
6. Apply topical antiseptic (optional).
- 7a. Apply topical anesthetic.
- 7b. Communicate with the patient.
8. Establish a firm hand rest.
9. Make the tissue taut.
10. Keep the syringe out of the patient's line of sight.
- 11a. Insert the needle into the mucosa.
- 11b. Watch and communicate with the patient.
12. Inject several drops of local anesthetic solution (optional).
13. Slowly advance the needle toward the target.
14. Deposit several drops of local anesthetic before touching the periosteum.
15. Aspirate twice.
- 16a. Slowly deposit the local anesthetic solution.
- 16b. Communicate with the patient.
17. Slowly withdraw the syringe. Cap the needle and discard it.
18. Observe the patient after the injection.
19. Record the injection in the patient's record.

References

1. de St Georges J. How dentists are judged by patients. *Dent Today*. 2004;23(96):98–99.
2. Matsuura H. Analysis of systemic complications and deaths during dental treatment in Japan. *Anesth Prog*. 1989;36:219–228.
3. Malamed SF. Emergency medicine: preparation and basics of management. *Dent Today*. 2001;20(64):66–67.
4. Hanna MN, Elhassan A, Veloso PM, et al. Efficacy of bicarbonate in decreasing pain on intradermal injection of local anesthetics: a meta-analysis. *Reg Anesth Pain Med*. 2009;34:122–125.
5. Burns CA, Ferris G, Feng C, et al. Decreasing the pain of local anesthesia: a prospective, double-blind comparison of buffered, premixed 1% lidocaine with epinephrine versus 1% lidocaine freshly mixed with epinephrine. *J Am Acad Dermatol*. 2006;54:128–131.
6. Malamed SF, Falkel M. Buffered local anesthetics: the importance of pH and CO₂. *SAAD Dig*. 2013;29:9–17.
7. Mollen AJ, Ficara AJ, Provant DR. Needles—25 gauge versus 27 gauge—can patients really tell? *Gen Dent*. 1981;29:417–418.
8. Flanagan T, Wahl MJ, Schmitt MM, Wahl JA. Size doesn't matter: needle gauge and injection pain. *Gen Dent*. 2007;55:216–217.
9. Benko K, Fiechtl J, Gray-Eurom K, et al. Fixing faces painlessly: facial anesthesia in emergency medicine. *Emerg Med Pract*. 2009;11:1–19.
10. Rogers KB, Fielding AF, Markiewicz SW. The effect of warming local anesthetic solutions before injection. *Gen Dent*. 1989;37:496–499.
11. Gill CJ, Orr DL. A double blind crossover comparison of topical anesthetics. *J Am Dent Assoc*. 1979;98:213.
12. Jeske AH, Blanton PL. Misconceptions involving dental local anesthesia. Part 2. Pharmacology. *Tex Dent J*. 2002;119:310–314.
13. Catchlove RF. The influence of CO₂ and pH on local anesthetic action. *J Pharm Exp Ther*. 1972;181:298–309.

14. Kanaa MD, Meechan JG, Corbett IP, Whitworth JM. Speed of injection influences efficacy of inferior alveolar nerve blocks: a double-blind randomized-controlled trial in volunteers. *J Endod.* 2006;32:919–923.
15. Malamed SF. Results of a survey of 209 dentists. In: *Handbook of Local Anesthesia*. 4th ed. St Louis: Mosby; 1997.
16. Goldwater PN, Law R, Nixon AD, et al. Impact of a recapping device on venipuncture-related needlestick injury. *Infect Control Hosp Epidemiol.* 1989;10:11–25.
17. McCormick RD, Maki DG. Epidemiology of needle-stick injuries in hospital personnel. *Am J Med.* 1981;70:928–932.
18. Berry AJ, Greene ES. The risk of needlestick injuries and needlestick-transmitted diseases in the practice of anesthesiology. *Anesthesiology.* 1992;77:1007–1021.
19. Cuny E, Fredekind RE, Budenz AW. Dental safety needles' effectiveness: results of a one-year evaluation. *J Am Dent Assoc.* 2000;131:1443–1448.

Anatomic Considerations

Trigeminal Nerve

An understanding of the management of pain in dentistry requires thorough knowledge of the fifth cranial nerve (V; Fig. 12.1). The right and left trigeminal nerves provide, among other functions, an overwhelming majority of sensory innervation from teeth, bone, and soft tissues of the oral cavity. The trigeminal nerve is the largest of the 12 cranial nerves. It is composed of a small motor root and a considerably larger (tripartite) sensory root. The motor root supplies the muscles of mastication and other muscles in the region. The three branches of the sensory root supply the skin of the entire face and the mucous membrane of the cranial viscera and oral cavity, except for the pharynx and base of the tongue, as well as the maxillary and mandibular teeth. Table 12.1 summarizes the functions of the trigeminal nerve and the 11 other cranial nerves.

Motor Root

The motor root of the trigeminal nerve arises separately from the sensory root, originating in the motor nucleus within the pons and medulla oblongata (Fig. 12.2). Its fibers, forming a small nerve root, travel anteriorly along with, but entirely separate from, the larger sensory root to the region of the semilunar (or gasserian) ganglion. At the semilunar ganglion the motor root passes in a lateral and inferior direction under the ganglion toward the foramen ovale, through which it leaves the middle cranial fossa along with the third division of the sensory root, the mandibular nerve (Figs. 12.3 and 12.4). Just after leaving the skull the motor root unites with the sensory root of the mandibular division to form a single nerve trunk.

Motor fibers of the trigeminal nerve supply the following muscles:

1. masticatory
 - a. masseter
 - b. temporalis
 - c. pterygoideus medialis
 - d. pterygoideus lateralis
2. mylohyoid
3. anterior belly of the digastric muscle
4. tensor tympani
5. tensor veli palatini

Sensory Root

Sensory root fibers of the trigeminal nerve constitute the central processes of ganglion cells located in the trigeminal (semilunar or gasserian) ganglion. Two ganglia are present, one innervating each side of the face. They are located in the Meckel cavity, on the anterior surface of the petrous portion of the temporal bone (see Fig. 12.3). The ganglia are flat and crescent shaped and measure approximately 1.0×2.0 cm; their convexities face anteriorly and downward. Sensory root fibers enter the concave portion of each crescent, and the three sensory divisions of the trigeminal nerve exit from the convexity:

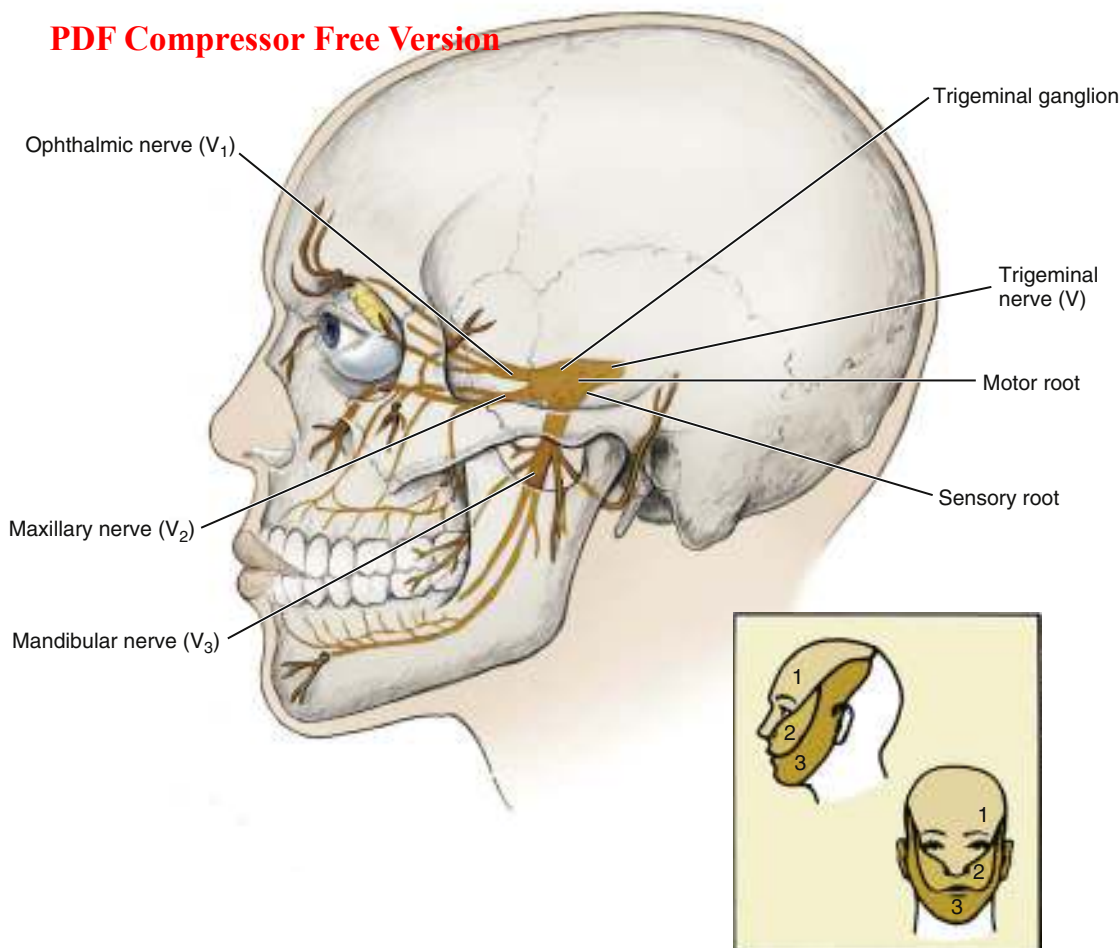
1. The ophthalmic division (V_1) travels anteriorly in the lateral wall of the cavernous sinus to the medial part of the superior orbital fissure, through which it exits the skull into the orbit.
2. The maxillary division (V_2) travels anteriorly and downward to exit the cranium through the foramen rotundum into the upper portion of the pterygopalatine fossa.
3. The mandibular division (V_3) travels almost directly downward to exit the skull, along with the motor root, through the foramen ovale. These two roots then intermingle, forming one nerve trunk that enters the infratemporal fossa.

On exiting the cranium through their respective foramina, the three divisions of the trigeminal nerve divide into a multitude of sensory branches.

Each of the three divisions of the trigeminal nerve is described, but more attention is devoted to the maxillary and mandibular divisions because of their greater importance in pain control in dentistry. Fig. 12.5 illustrates the sensory distribution of the trigeminal nerve.

Ophthalmic Division (V_1)

The ophthalmic division is the first branch of the trigeminal nerve. It is purely sensory and is the smallest of the three divisions. It leaves the cranium and enters the orbit through the superior orbital fissure (Fig. 12.6). The nerve trunk is approximately 2.5 cm long. It supplies the eyeball, conjunctiva, lacrimal gland, parts of the mucous membrane of the nose and paranasal sinuses, and the skin of the forehead, eyelids, and nose. When the ophthalmic nerve (V_1) is paralyzed, the ocular conjunctiva becomes insensitive to touch.



• **Fig. 12.1** The general pathway of the trigeminal or fifth cranial nerve and its motor and sensory roots and three divisions (the inset shows the pattern of innervation for each nerve division). (From Fehrenbach MJ, Herring SW. *Anatomy of the Head and Neck*. 3rd ed. St Louis: Saunders; 2007.)

Just before the ophthalmic nerve passes through the superior orbital fissure, it divides into its three main branches: nasociliary, frontal, and lacrimal nerves.

Nasociliary Nerve

The nasociliary nerve travels along the medial border of the orbital roof, giving off branches to the nasal cavity and ending in the skin at the root of the nose. It then branches into the anterior ethmoidal and external nasal nerves. The internal nasal nerve (from the anterior ethmoidal) supplies the mucous membrane of the anterior part of the nasal septum and the lateral wall of the nasal cavity. The ciliary ganglion contains sensory fibers that travel to the eyeball via the short ciliary nerves. Two or three long ciliary nerves supply the iris and cornea. The infratrochlear nerve supplies the skin of the lacrimal sac and the lacrimal caruncle, the posterior ethmoidal nerve supplies the ethmoidal and sphenoidal sinuses, and the external nasal nerve supplies the skin over the apex (tip) and the ala of the nose.

Frontal Nerve

The frontal nerve travels anteriorly in the orbit, dividing into two branches: supratrochlear and supraorbital. The frontal nerve is the largest branch of the ophthalmic division. The supratrochlear nerve supplies the conjunctiva and skin of the medial aspect of the upper eyelid and the skin over the lower and mesial aspects of the forehead. The supraorbital nerve is sensory to the upper eyelid, the scalp as far back as the parietal bone, and the lambdoidal suture.

Lacrimal Nerve

The lacrimal nerve is the smallest branch of the ophthalmic division. It supplies the lateral part of the upper eyelid and a small adjacent area of skin.

Maxillary Division (V₂)

The maxillary division of the trigeminal nerve arises from the middle of the trigeminal ganglion. Intermediate in size between ophthalmic and mandibular divisions, it is purely sensory in function.

TABLE 12.1 Cranial Nerves

Number	Name	Type	Function
I	Olfactory	Sensory	Smell
II	Optic	Sensory	Vision
III	Oculomotor	Motor	Supplies four of the six extraocular muscles of the eye and the muscle of the upper eyelid
IV	Trochlear	Motor	Innervates the superior oblique muscle (turns eye downward and laterally)
V	Trigeminal	Mixed	
V ₁	Ophthalmic	Sensory	V ₁ : sensory from muscles of forehead
V ₂	Maxillary	Sensory	V ₂ : sensory from lower eyelids, zygoma, and upper lip
V ₃	Mandibular	Sensory and motor	V ₃ : sensory from lateral scalp, skin anterior to ears, lower cheeks, lower lips and anterior aspect of mandible; motor to muscles of mastication (temporalis, masseter, medial and lateral pterygoids, tensor veli palatine and tensor tympani)
VI	Abducens	Motor	Innervates lateral rectus muscle of eye
VII	Facial	Motor	Innervates muscles of facial expression; taste sensation from anterior two-thirds of tongue, hard and soft palates; secretomotor innervation of salivary glands (except parotid) and lacrimal gland
VIII	Auditory (vestibulocochlear)	Sensory	Vestibular branch = equilibrium; cochlear branch = hearing
IX	Glossopharyngeal	Mixed	Taste from posterior third of tongue; secretomotor innervation to parotid gland; motor to stylopharyngeal muscle
X	Vagus	Mixed	Motor to voluntary muscles of pharynx and larynx (except stylopharyngeal); parasympathetic to smooth muscle and glands of pharynx and larynx, and viscera of thorax and abdomen; sensory from stretch receptors of aortic arch and chemoreceptors of aortic bodies; controls muscles for voice and resonance and the soft palate
XI	Accessory	Motor	Motor to sternocleidomastoid and trapezius muscles; innervates muscles of larynx and pharynx
XII	Hypoglossal	Motor	Motor to muscles of tongue and other glossal muscles

Origins

The maxillary nerve passes horizontally forward, leaving the cranium through the foramen rotundum (see Fig. 12.3). The foramen rotundum is located in the greater wing of the sphenoid bone. Once outside the cranium, the maxillary nerve crosses the uppermost part of the pterygopalatine fossa, between the pterygoid plates of the sphenoid bone and the palatine bone. As it crosses the pterygopalatine fossa, it gives off branches to the sphenopalatine ganglion, the posterior superior alveolar (PSA) nerve, and the zygomatic branches. It then angles laterally in a groove on the posterior surface of the maxilla, entering the orbit through the inferior orbital fissure. Within the orbit, it occupies the infraorbital groove and becomes the infraorbital nerve, which courses anteriorly into the infraorbital canal.

The maxillary division emerges on the anterior surface of the face through the infraorbital foramen, where it divides into its terminal branches, supplying the skin of the face, nose, lower eyelid, and upper lip

(Fig. 12.7). The following is a summary of maxillary division innervation:

1. skin
 - a. middle portion of the face
 - b. lower eyelid
 - c. side of the nose
 - d. upper lip
2. mucous membrane
 - a. nasopharynx
 - b. maxillary sinus
 - c. soft palate
 - d. tonsil
 - e. hard palate
3. maxillary teeth and periodontal tissues

Branches

The maxillary division gives off branches in four regions: within the cranium, in the pterygopalatine fossa, in the infraorbital canal, and on the face.

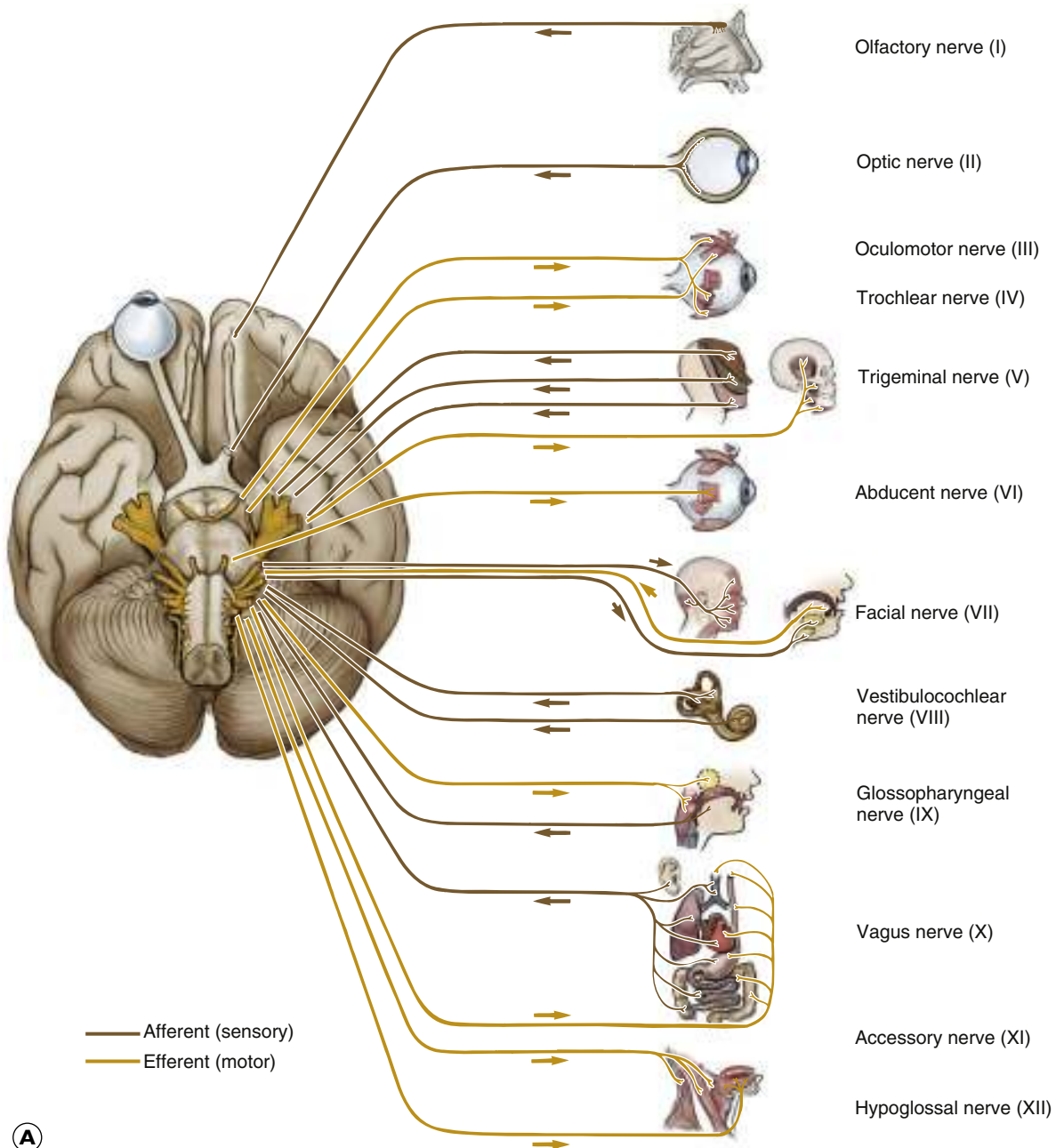
Branch Within the Cranium. Immediately after separating from the trigeminal ganglion, the maxillary division

gives off a small branch, the middle meningeal nerve, which travels with the middle meningeal artery to provide sensory innervation to the dura mater.

Branches in the Pterygopalatine Fossa. After exiting the cranium through the foramen rotundum, the maxillary division crosses the pterygopalatine fossa. In this fossa, several branches are given off (Fig. 12.8): the zygomatic nerve, the pterygopalatine nerves, and the PSA nerve.

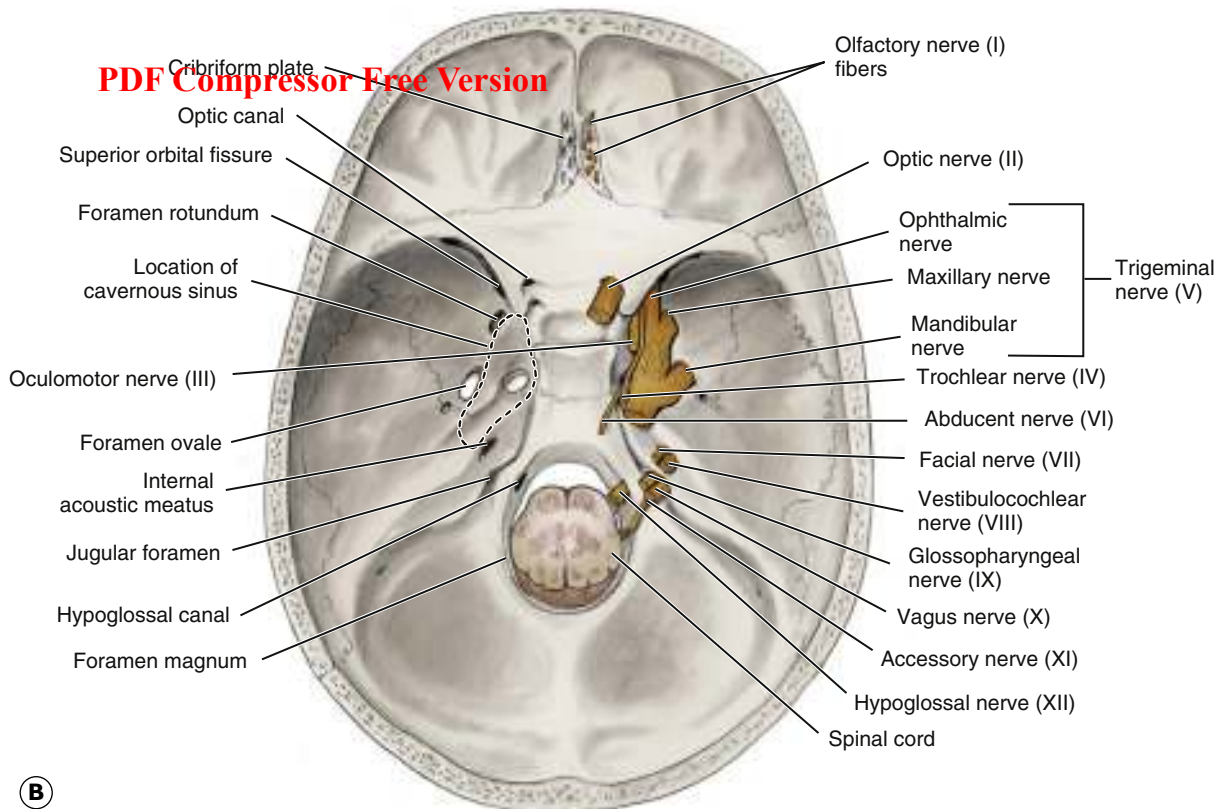
The zygomatic nerve comes off the maxillary division in the pterygopalatine fossa and travels anteriorly, entering the

orbit through the inferior orbital fissure, where it divides into the zygomaticotemporal and zygomaticofacial nerves: the zygomaticotemporal nerve supplies sensory innervation to the skin on the side of the forehead, and the zygomaticofacial nerve supplies the skin on the prominence of the cheek. Just before leaving the orbit, the zygomatic nerve sends a branch that communicates with the lacrimal nerve of the ophthalmic division. This branch carries secretory fibers from the sphenopalatine ganglion to the lacrimal gland.



• **Fig. 12.2** (A) Inferior view of the brain showing cranial nerves and the organs and tissues they innervate. (B) Internal view of the base of the skull showing cranial nerves exiting or entering the skull. (From Fehrenbach MJ, Herring SW. *Anatomy of the Head and Neck*. 3rd ed. St Louis: Saunders; 2007.)

Continued



• Fig. 12.2 cont'd

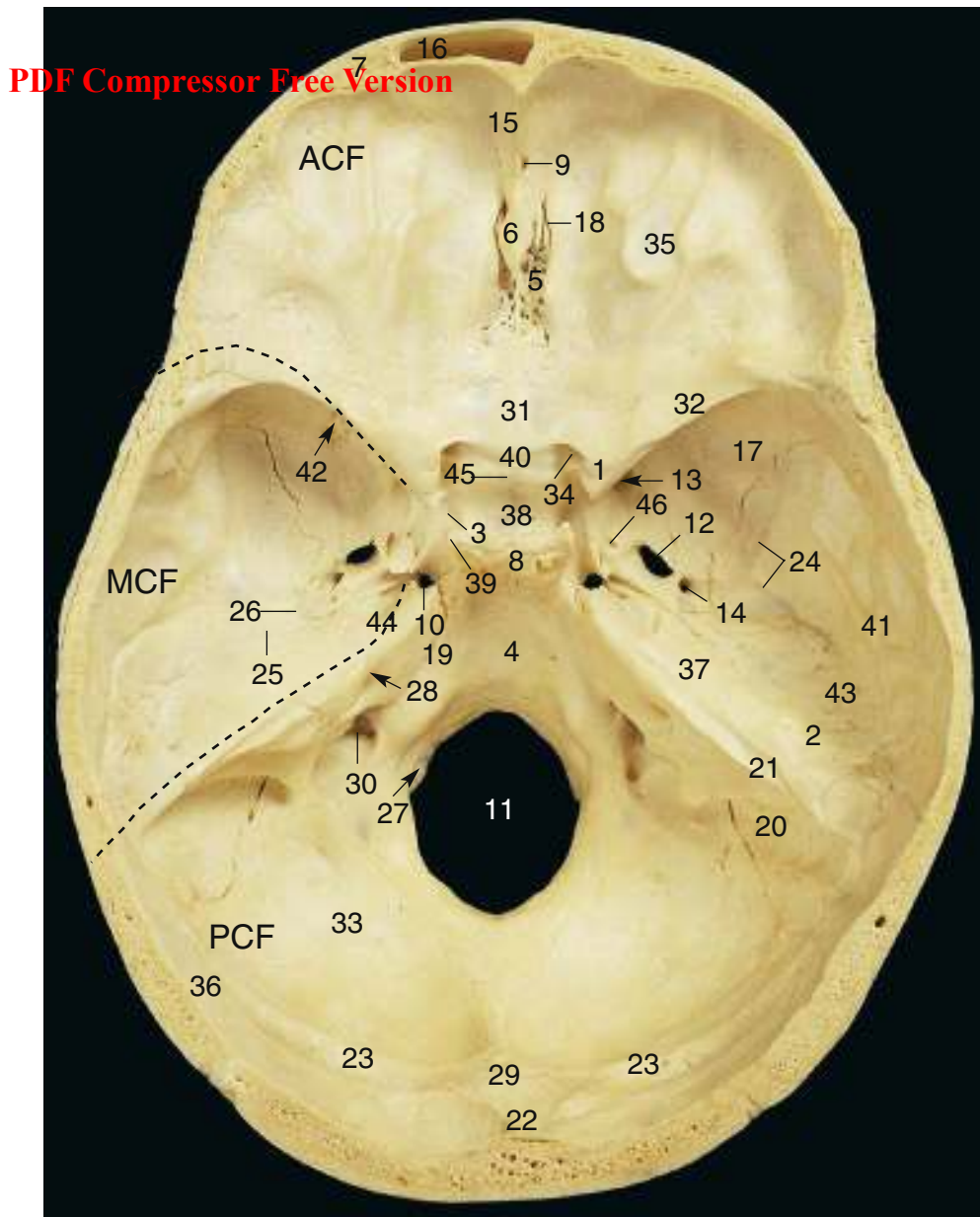
The pterygopalatine nerves are two short trunks that unite in the pterygopalatine ganglion and are then redistributed into several branches. They also serve as a communication between the pterygopalatine ganglion and the maxillary nerve (V_2). Postganglionic secretomotor fibers from the pterygopalatine ganglion pass through these nerves and back along the maxillary nerve to the zygomatic nerve, through which they are routed to the lacrimal nerve and the lacrimal gland.

The branches of the pterygopalatine nerves include those that supply four areas: orbit, nose, palate, and pharynx:

1. The orbital branches supply the periosteum of the orbit.
2. The nasal branches supply the mucous membranes of the superior and middle conchae, the lining of the posterior ethmoidal sinuses, and the posterior portion of the nasal septum. One branch is significant in dentistry, the nasopalatine nerve, which passes across the roof of the nasal cavity downward and forward, where it lies between the mucous membrane and the periosteum of the nasal septum. The nasopalatine nerve continues downward, reaching the floor of the nasal cavity and giving branches to the anterior part of the nasal septum and the floor of the nose. It then enters the incisive canal, through which it passes into the oral cavity via the incisive foramen, located in the midline of the palate about 1 cm posterior to the maxillary central incisors. The right and left nasopalatine nerves emerge together through this foramen and provide sensation to the palatal mucosa in the

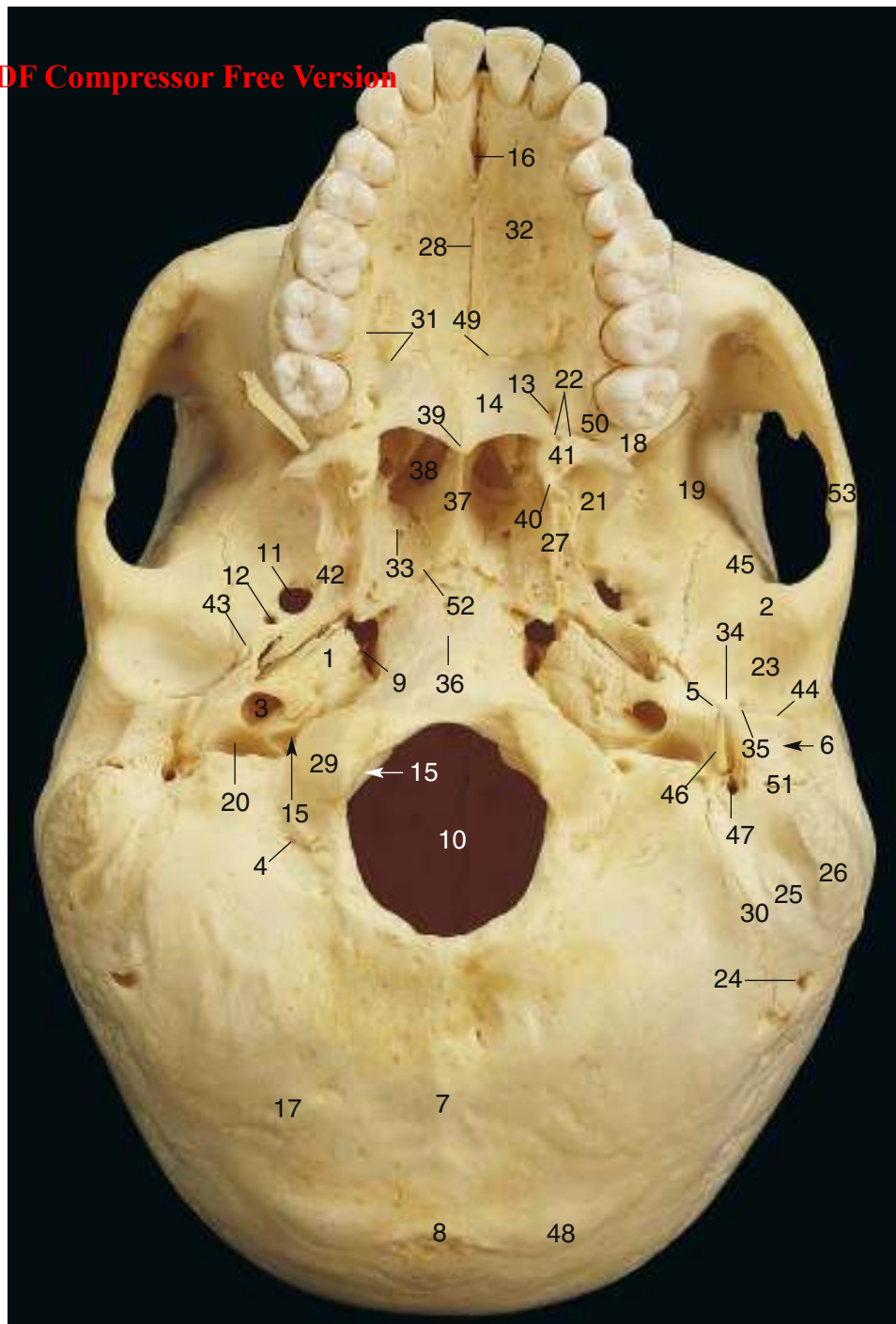
region of the premaxilla (canines through central incisors) (Fig. 12.9).

3. The palatine branches include the greater (or anterior) palatine nerve and the lesser (middle and posterior) palatine nerves (Fig. 12.10). The greater (or anterior) palatine nerve descends through the pterygopalatine canal, emerging on the hard palate through the greater palatine foramen (which is usually located about 1 cm toward the palatal midline, just distal to the second molar). Sicher and DuBrul have stated that the greater palatine foramen may be located 3 to 4 mm in front of the posterior border of the hard palate.¹ The nerve courses anteriorly between the mucoperiosteum and the osseous hard palate, supplying sensory innervation to the palatal soft tissues and bone as far anterior as the first premolar, where it communicates with terminal fibers of the nasopalatine nerve (see Fig. 12.10). It also provides sensory innervation to some parts of the soft palate. The middle palatine nerve emerges from the lesser palatine foramen, along with the posterior palatine nerve. The middle palatine nerve provides sensory innervation to the mucous membrane of the soft palate; the tonsillar region is innervated, in part, by the posterior palatine nerve.
4. The pharyngeal branch is a small nerve that leaves the posterior part of the pterygopalatine ganglion, passes through the pharyngeal canal, and is distributed to the mucous membrane of the nasal part of the pharynx, posterior to the auditory (eustachian) tube.

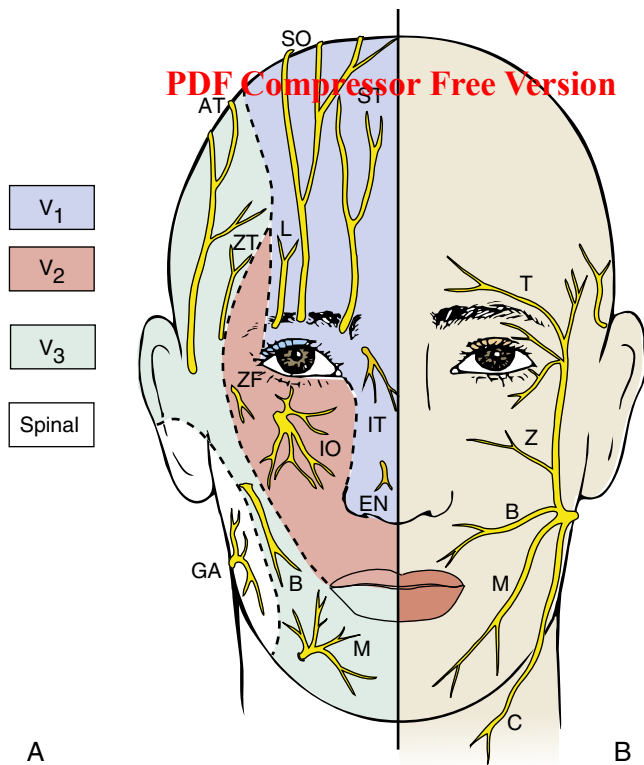


• **Fig. 12.3** Internal Surface of the Base of the Skull (Cranial Fossa). *ACF*, Anterior cranial fossa; *MCF*, middle cranial fossa; *PCF*, posterior cranial fossa; 1, anterior clinoid process; 2, arcuate eminence; 3, carotid groove; 4, clivus; 5, cribriform plate of ethmoid bone; 6, crista galli; 7, diploë; 8, dorsum sellae; 9, foramen cecum; 10, foramen lacerum; 11, foramen magnum; 12, foramen ovale; 13, foramen rotundum; 14, foramen spinosum; 15, frontal crest; 16, frontal sinus; 17, greater wing of sphenoid bone; 18, groove for anterior ethmoidal nerve and vessels; 19, groove for inferior petrosal sinus; 20, groove for sigmoid sinus; 21, groove for superior petrosal sinus; 22, groove for superior sagittal sinus; 23, groove for transverse sinus; 24, grooves for middle meningeal vessels; 25, hiatus and groove for greater petrosal nerve; 26, hiatus and groove for lesser petrosal nerve; 27, hypoglossal canal; 28, internal acoustic meatus; 29, internal occipital protuberance; 30, jugular foramen; 31, jugum of sphenoid bone; 32, lesser wing of sphenoid bone; 33, occipital bone; 34, optic canal; 35, orbital part of frontal bone; 36, parietal bone (postero-inferior angle only); 37, petrous part of temporal bone; 38, pituitary fossa (sella turcica); 39, posterior clinoid process; 40, prechiasmatic groove; 41, squamous part of temporal bone; 42, superior orbital fissure; 43, tegmen tympani; 44, trigeminal impression; 45, tuberculum sellae; 46, venous foramen. (From Abrahams PH, Marks SC Jr, Hutchings RT. *McMinn's Color Atlas of Human Anatomy*. 5th ed. St Louis: Mosby; 2003.)

PDF Compressor Free Version



• **Fig. 12.4** External Surface of the Base of the Skull. 1, Apex of petrous part of temporal bone; 2, articular tubercle; 3, carotid canal; 4, condylar canal (posterior); 5, edge of tegmen tympani; 6, external acoustic meatus; 7, external occipital crest; 8, external occipital protuberance; 9, foramen lacerum; 10, foramen magnum; 11, foramen ovale; 12, foramen spinosum; 13, greater palatine foramen; 14, horizontal plate of palatine bone; 15, hypoglossal (anterior condylar) canal; 16, incisive fossa; 17, inferior nuchal line; 18, inferior orbital fissure; 19, infratemporal crest of greater wing of sphenoid bone; 20, jugular foramen; 21, lateral pterygoid plate; 22, lesser palatine foramina; 23, mandibular fossa; 24, mastoid foramen; 25, mastoid notch; 26, mastoid process; 27, medial pterygoid plate; 28, median palatine (intermaxillary) suture; 29, occipital condyle; 30, occipital groove; 31, palatine grooves and spines; 32, palatine process of maxilla; 33, palatinovaginal canal; 34, petrosquamous fissure; 35, petrotympanic fissure; 36, pharyngeal tubercle; 37, posterior border of vomer; 38, posterior nasal aperture (choana); 39, posterior nasal spine; 40, pterygoid hamulus; 41, pyramidal process of palatine bone; 42, scaphoid fossa; 43, spine of sphenoid bone; 44, squamotympanic fissure; 45, squamous part of temporal bone; 46, styloid process; 47, stylomastoid foramen; 48, superior nuchal line; 49, transverse palatine (palatomaxillary) suture; 50, tuberosity of maxilla; 51, tympanic part of temporal bone; 52, vomerovaginal canal; 53, zygomatic arch. (From Abrahams PH, Marks SC Jr, Hutchings RT. *McMinn's Color Atlas of Human Anatomy*. 5th ed. St Louis: Mosby; 2003.)

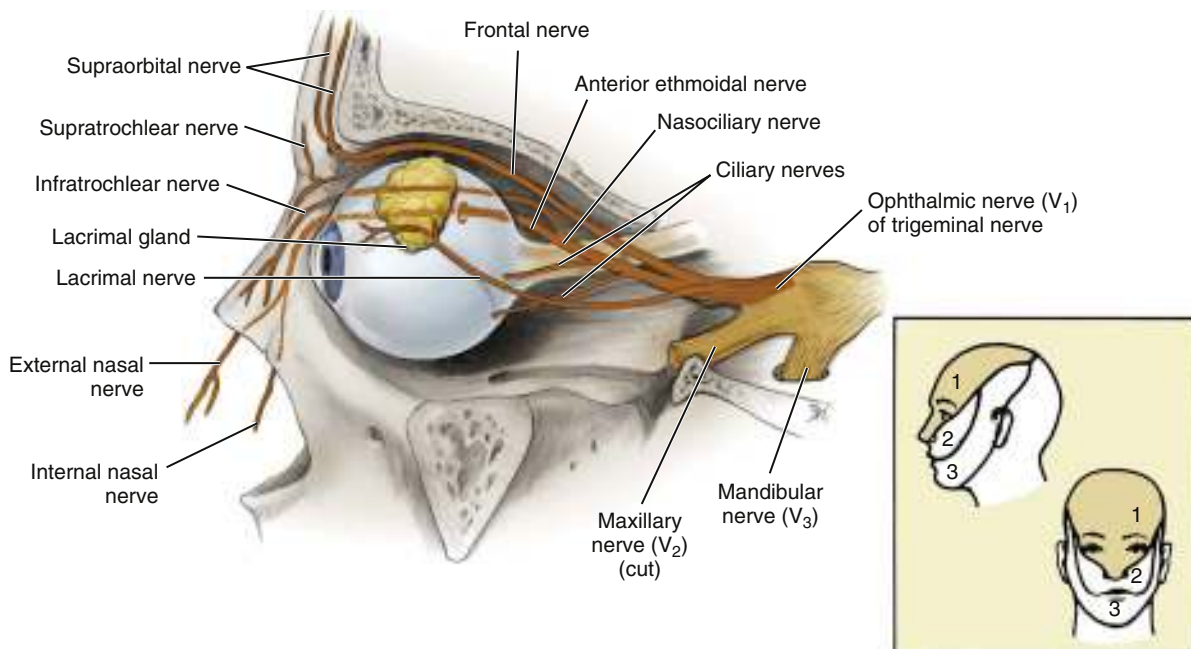


• **Fig. 12.5** (A) Cutaneous nerves of face. Ophthalmic nerve (V_1): external nasal nerve (EN), infratrochlear nerve (IT), lacrimal nerve (L), supraorbital nerve (SO), supratrochlear nerve (ST). Maxillary nerve (V_2): infraorbital nerve (IO), zygomaticofacial nerve (ZF), zygomaticotemporal nerve (ZT). Mandibular nerve (V_3): auriculotemporal nerve (AT), buccal nerve (B), mental nerve (M). Spinal nerve: great auricular nerve (GA). (B) Motor nerves to muscles of facial expression. Facial branches of cranial nerve VII: buccal branches (B), cervical branches (C), mandibular branches (M), temporal branches (T), zygomatic branches (Z). (From Liebgott B. *The Anatomical Basis of Dentistry*. 3rd ed. St Louis: Mosby; 2010.)

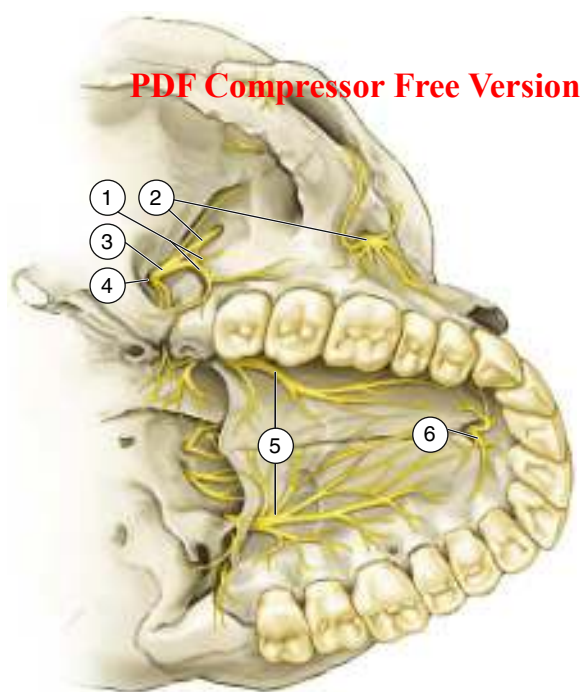
The PSA nerve descends from the main trunk of the maxillary division in the pterygopalatine fossa just before the maxillary division enters the infraorbital canal (see Fig. 12.7). Commonly there are two PSA branches, but on occasion a single trunk arises. Passing downward through the pterygopalatine fossa, they reach the inferior temporal (posterior) surface of the maxilla. When two trunks are present, one remains external to the bone, continuing downward on the posterior surface of the maxilla to provide sensory innervation to the buccal gingiva in the maxillary molar region and adjacent facial mucosal surfaces, whereas the other branch enters the maxilla (along with a branch of the internal maxillary artery) through the PSA canal to travel down the posterior or posterolateral wall of the maxillary sinus, providing sensory innervation to the mucous membrane of the sinus. Continuing downward, this second branch of the PSA nerve provides sensory innervation to the alveoli, periodontal ligaments, and pulpal tissues of the maxillary third, second, and first molars (with the exception [in 28% of patients] of the mesiobuccal root of the first molar).

Branches in the Infraorbital Canal. Within the infraorbital canal the maxillary division (V_2) gives off two branches of significance in dentistry: the middle superior alveolar (MSA) and anterior superior alveolar (ASA) nerves. While it is in the infraorbital groove and canal, the maxillary division is known as the *infraorbital nerve*.

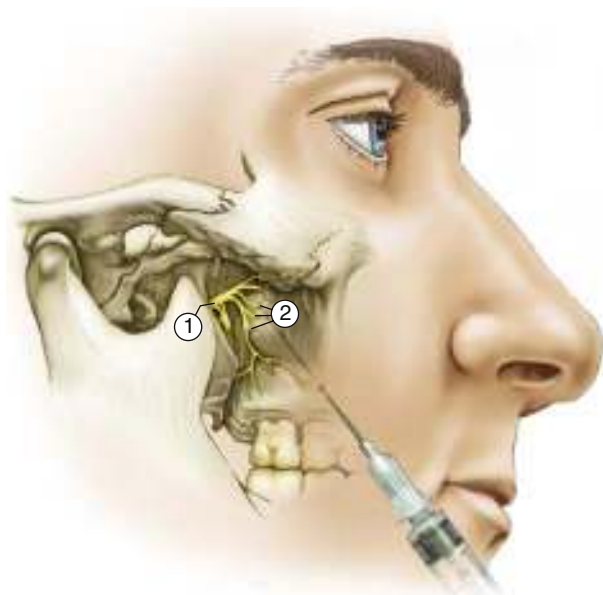The MSA nerve branches off the main nerve trunk (V_2) within the infraorbital canal to form a part of the superior dental plexus,¹ composed of the PSA, MSA, and ASA nerves. The site of origin of the MSA nerve differs, from the posterior portion of the infraorbital canal to the anterior portion, near the infraorbital foramen. The MSA nerve



• **Fig. 12.6** Lateral view of the cutaway orbit with the pathway of the ophthalmic nerve of the trigeminal nerve highlighted. (From Fehrenbach MJ, Herring SW. *Anatomy of the Head and Neck*. 3rd ed. St Louis: Saunders; 2007.)



• **Fig. 12.7** Distribution of the Maxillary Division (V_2). 1, Posterior superior alveolar branches; 2, infraorbital nerve; 3, maxillary nerve; 4, foramen rotundum; 5, greater palatine nerve; 6, nasopalatine nerve. (From Haglund J, Evers H. *Local Anaesthesia in Dentistry*. 2nd ed. Sodertalje: Astra Lakemedel.)



• **Fig. 12.8** Branches of the Maxillary Nerve (V_2) in the Pterygopalatine Fossa. 1, Maxillary nerve; 2, posterior superior alveolar branches. (From Haglund J, Evers H. *Local Anaesthesia in Dentistry*. 2nd ed. Sodertalje: Astra Lakemedel.)

provides sensory innervation to the two maxillary premolars and, perhaps, to the mesiobuccal root of the first molar and periodontal tissues, buccal soft tissue, and bone in the premolar region. Traditionally it has been stated that the MSA nerve is absent in 30%² to 54%³ of individuals. Loetscher

and Walton⁴ found the MSA nerve to be present in 72% of the specimens they examined. In its absence, its usual innervations are provided by either the PSA or the ASA nerve, most frequently the latter.¹

The ASA nerve, a relatively large branch, is given off the infraorbital nerve (V_2) approximately 6 to 10 mm before the latter exits the infraorbital foramen. Descending within the anterior wall of the maxillary sinus, it provides pulpal innervation to the central and lateral incisors and the canine, and sensory innervation to the periodontal tissues, buccal bone, and mucous membranes of these teeth (Fig. 12.11).

The ASA nerve communicates with the MSA nerve and gives off a small nasal branch that innervates the anterior part of the nasal cavity, along with branches of the pterygopalatine nerves. In persons without an MSA nerve, the ASA nerve frequently provides sensory innervation to the premolars and occasionally to the mesiobuccal root of the first molar.

The actual innervation of individual roots of all teeth, bone, and periodontal structures in both the maxilla and the mandible derives from terminal branches of larger nerves in the region. These nerve networks are termed the *dental plexus*.

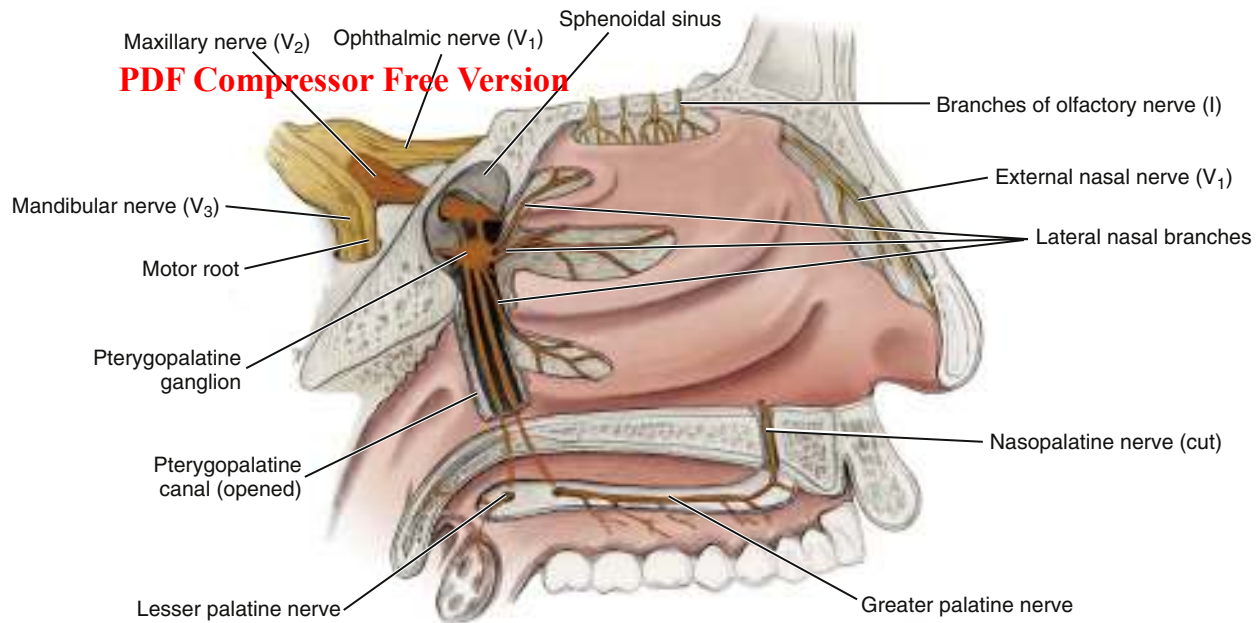
The superior dental plexus is composed of smaller nerve fibers from the three superior alveolar nerves (and in the mandible, from the inferior alveolar nerve). Three types of nerves emerge from these plexuses: dental nerves, interdental branches, and interradicular branches. Each is accompanied along its pathway by a corresponding artery.

The dental nerves are those that enter a tooth through the apical foramen, dividing into many small branches within the pulp. Pulpal innervation of all teeth is derived from dental nerves. Although in most instances one easily identifiable nerve is responsible, in some cases (usually the maxillary first molar) more than one nerve is responsible.

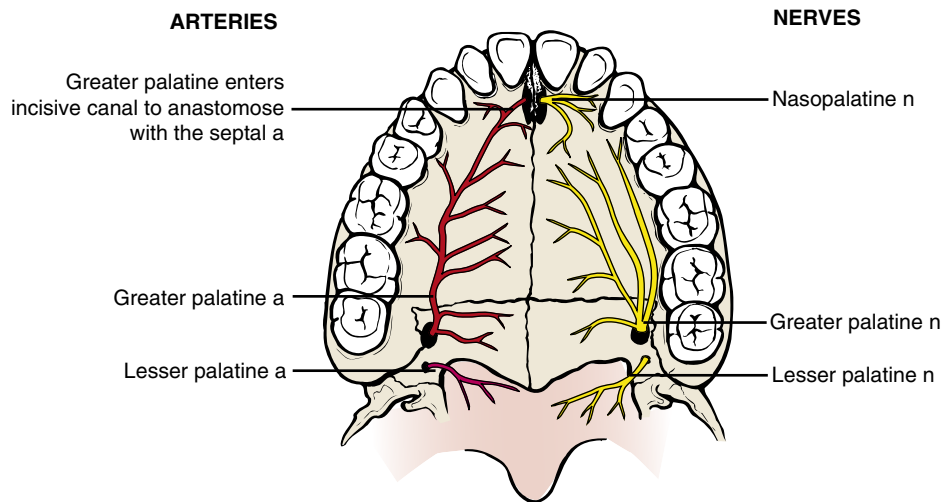
The interdental branches (also termed *perforating branches*) travel through the entire height of the interdental septum, providing sensory innervation to the periodontal ligaments of adjacent teeth through the alveolar bone. They emerge at the height of the crest of the interalveolar septum and enter the gingiva to innervate the interdental papillae and the buccal gingiva.

The interradicular branches traverse the entire height of the interdental or interalveolar septum, providing sensory innervation to the periodontal ligaments of adjacent roots. They terminate in the periodontal ligament at the root furcations.

Branches on the Face. The infraorbital nerve emerges through the infraorbital foramen onto the face to divide into its terminal branches: inferior palpebral, external nasal, and superior labial. The inferior palpebral branches supply the skin of the lower eyelid with sensory innervation, the external nasal branches provide sensory innervation to the skin on the lateral aspect of the nose, and the superior labial branches provide sensory innervation to the skin and mucous membranes of the upper lip.



• **Fig. 12.9** Medial view of the lateral nasal wall and the opened pterygopalatine canal highlighting the maxillary nerve and its palatine branches. The nasal septum has been removed, thus severing the nasopalatine nerve. (From Fehrenbach MJ, Herring SW. *Anatomy of the Head and Neck*. 3rd ed. St Louis: Saunders; 2007.)



• **Fig. 12.10** Blood and Sensory Nerve Supply to Hard and Soft Palate. *a*, Artery; *n*, nerve. (From Liebgott B. *The Anatomical Basis of Dentistry*. 3rd ed. St Louis: Mosby; 2010.)

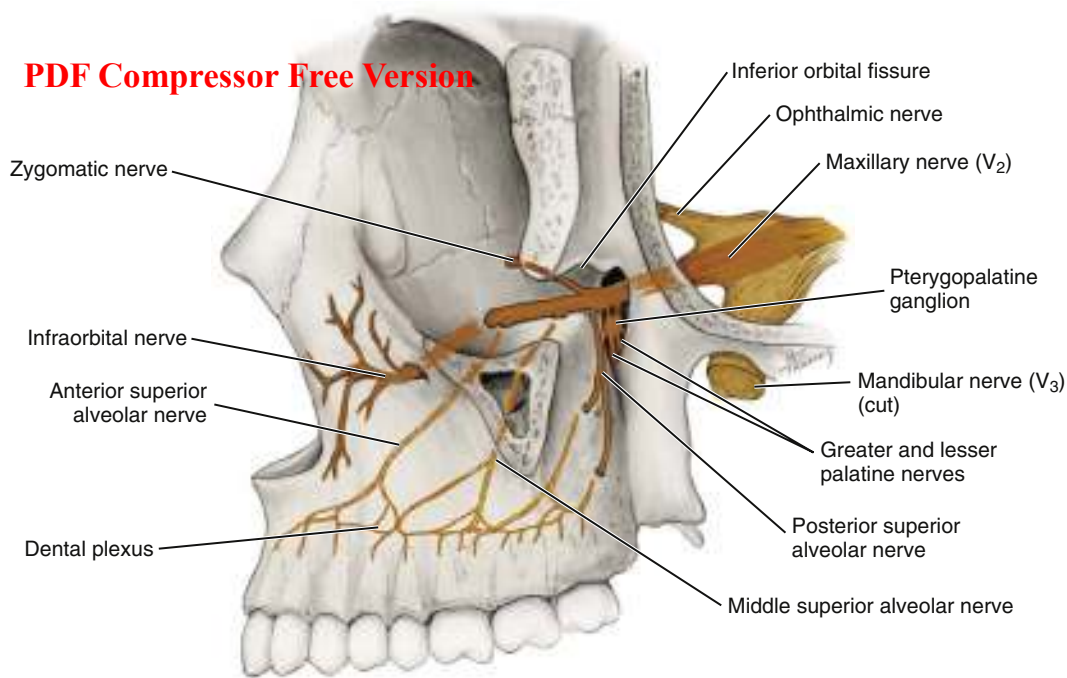
Although anesthesia of these nerves is not necessary for adequate pain control during dental treatment, they are frequently blocked in the process of performing other anesthetic procedures.

Summary

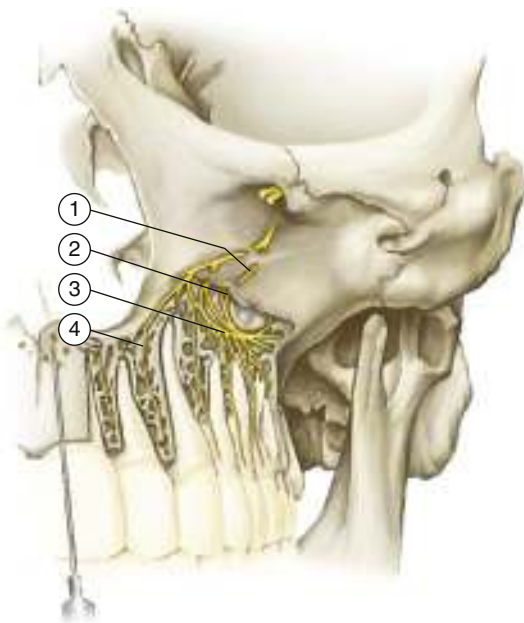
The following is a summary of the branches of the maxillary division (*italicized nerves denote those of special significance in dental pain control*):

1. branches within the cranium
 - a. middle meningeal nerve
2. branches within the pterygopalatine fossa

- a. zygomatic nerve:
 - i. zygomaticotemporal nerve
 - ii. zygomaticofacial nerve
- b. pterygopalatine nerves
 - i. orbital branches
 - ii. nasal branches
nasopalatine nerve
 - iii. palatine branches
greater (anterior) palatine nerve
lesser (middle and posterior) palatine nerves
 - iv. pharyngeal branch
- c. *PSA nerve*



• **Fig. 12.11** Lateral view of the skull (a portion of the lateral wall of the orbit has been removed) with the branches of the maxillary nerve highlighted. (From Fehrenbach MJ, Herring SW. *Anatomy of the Head and Neck*. 3rd ed. St Louis: Saunders; 2007.)



• **Fig. 12.12** Anterior Superior Alveolar (Asa) Nerve (Bone Over the Nerves Removed). 1, Branches of the ASA nerve; 2, superior dental plexus; 3, dental branches; 4, interdental and interradicular branches. (From Haglund J, Evers H. *Local Anaesthesia in Dentistry*. 2nd ed. Sodertalje: Astra Lakemedel.)

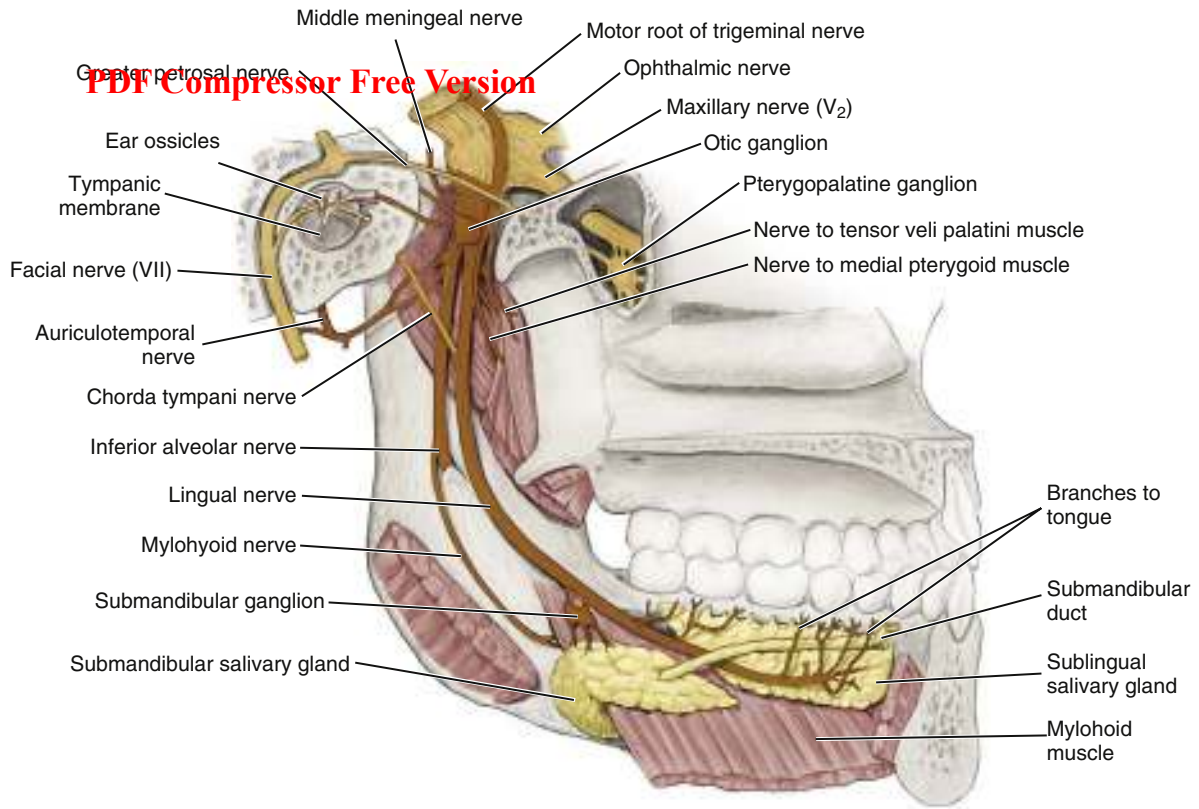
3. branches within the infraorbital canal
 - c. *MSA nerve*
 - d. *ASA nerve* (Fig. 12.12)
4. branches on the face
 - a. inferior palpebral branches
 - b. external nasal branches
 - c. superior labial branches

Mandibular Division (V_3)

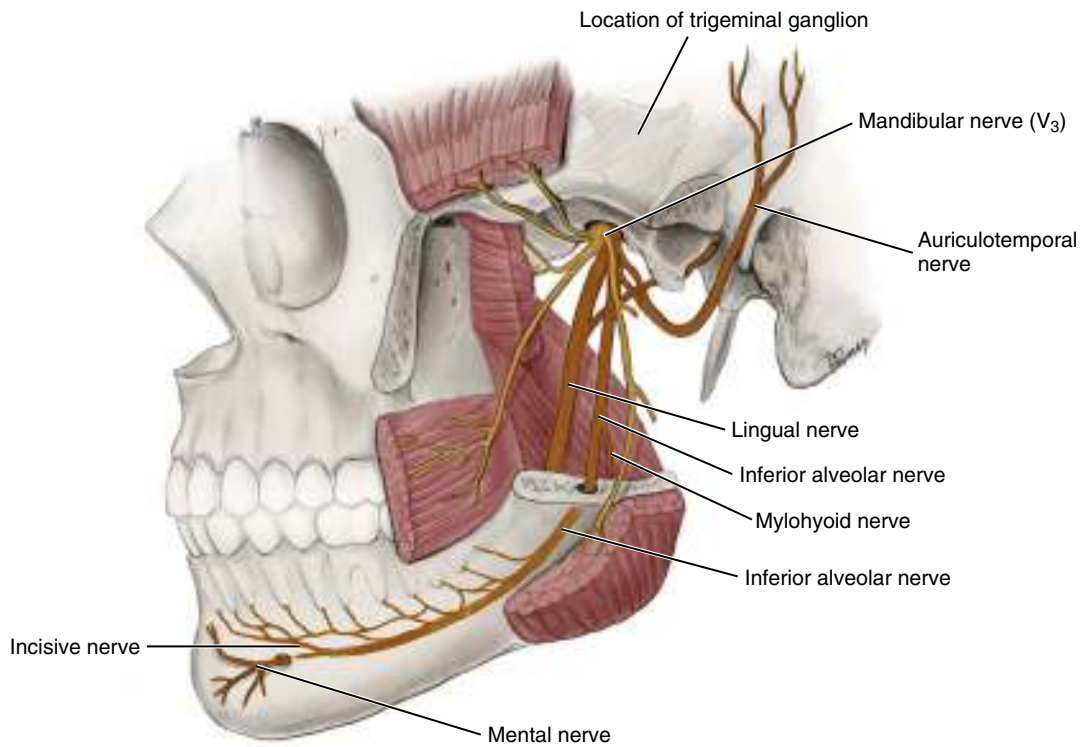
The mandibular division is the largest branch of the trigeminal nerve. It is a mixed nerve with two roots: a large sensory root and a smaller motor root (the latter representing the entire motor component of the trigeminal nerve). The sensory root of the mandibular division originates at the inferior angle of the trigeminal ganglion, whereas the motor root arises in motor cells located in the pons and medulla oblongata. The two roots emerge from the cranium separately through the foramen ovale, the motor root lying medial to the sensory. They unite just outside the skull and form the main trunk of the third division. This trunk remains undivided for only 2 to 3 mm before it splits into a small anterior and a large posterior division (Figs. 12.13 and 12.14).

The areas innervated by the mandibular division are:

1. sensory root
 - a. skin
 - i. temporal region
 - ii. auricula
 - iii. external auditory meatus
 - iv. cheek
 - v. lower lip
 - vi. lower part of the face (chin region)
 - b. mucous membrane
 - i. cheek
 - ii. tongue (anterior two thirds)
 - iii. mastoid cells
 - c. mandibular teeth and periodontal tissues
 - d. bone of the mandible
 - e. temporomandibular joint
 - f. parotid gland



• **Fig. 12.13** Medial view of the mandible with the motor and sensory branches of the mandibular nerve highlighted. (From Fehrenbach MJ, Herring SW. *Anatomy of the Head and Neck*. 3rd ed. St Louis: Saunders; 2007.)



• **Fig. 12.14** The pathway of the posterior trunk of the mandibular nerve of the trigeminal nerve is highlighted. (From Fehrenbach MJ, Herring SW. *Anatomy of the Head and Neck*. 3rd ed. St Louis: Saunders; 2007.)

2. motor root
 - a. masticatory muscles
 - i. masseter
 - ii. temporalis
 - iii. pterygoideus medialis
 - iv. pterygoideus lateralis
 - b. mylohyoid
 - c. anterior belly of the digastric muscle
 - d. tensor tympani
 - e. tensor veli palatini

Branches

The third division of the trigeminal nerve gives off branches in three areas: from the undivided nerve, and from the anterior and posterior divisions.

Branches From the Undivided Nerve. On leaving the foramen ovale, the main undivided nerve trunk gives off two branches during its 2- to 3-mm course. These are the nervus spinosus (meningeal branch of the mandibular nerve) and the medial pterygoid nerve. The nervus spinosus reenters the cranium through the foramen spinosum along with the middle meningeal artery to supply the dura mater and mastoid air cells. The medial pterygoid nerve is a motor nerve to the medial (internal) pterygoid muscle. It gives off small branches that are motor to the tensor veli palatini and the tensor tympani.

Branches From the Anterior Division. Branches from the anterior division of the mandibular nerve (V_3) provide motor innervation to the muscles of mastication and sensory innervation to the mucous membrane of the cheek and the buccal mucous membrane of the mandibular molars.

The anterior division is significantly smaller than the posterior division. It runs forward under the lateral (external) pterygoid muscle for a short distance and then reaches the external surface of that muscle by passing between its two heads or, less frequently, by winding over its upper border. From this point, it is known as the *buccal nerve*. Although under the lateral pterygoid muscle, the buccal nerve gives off several branches: the deep temporal nerves (to the temporal muscle) and the masseter and lateral pterygoid nerves (providing motor innervation to the respective muscles).

The buccal nerve, also known as the *buccinator nerve* and (incorrectly) the *long buccal nerve*, usually passes between the two heads of the lateral pterygoid to reach the external surface of that muscle. It then follows the inferior part of the temporal muscle and emerges under the anterior border of the masseter muscle, continuing in an anterolateral direction. At the level of the occlusal plane of the mandibular third or second molar, it crosses in front of the anterior border of the ramus and enters the cheek through the buccinator muscle. Sensory fibers are distributed to the skin of the cheek. Other fibers pass into the retromolar triangle, providing sensory innervation to the buccal gingiva of the mandibular molars and the mucobuccal fold in that region. The buccal nerve does not innervate the buccinator muscle; the facial nerve does. Nor does it provide sensory innervation to the lower lip or the corner of the mouth. This is significant because some doctors do not administer the “long” buccal injection immediately after completing the inferior alveolar nerve block until the patient’s lower lip has become numb. Their thinking is that

the buccal nerve block will provide anesthesia to the lower lip and therefore might lead them to believe that their inferior alveolar nerve block has been successful, when in fact it has been missed. Such concern is unwarranted. The buccal nerve block may be administered immediately after completion of the inferior alveolar nerve block.

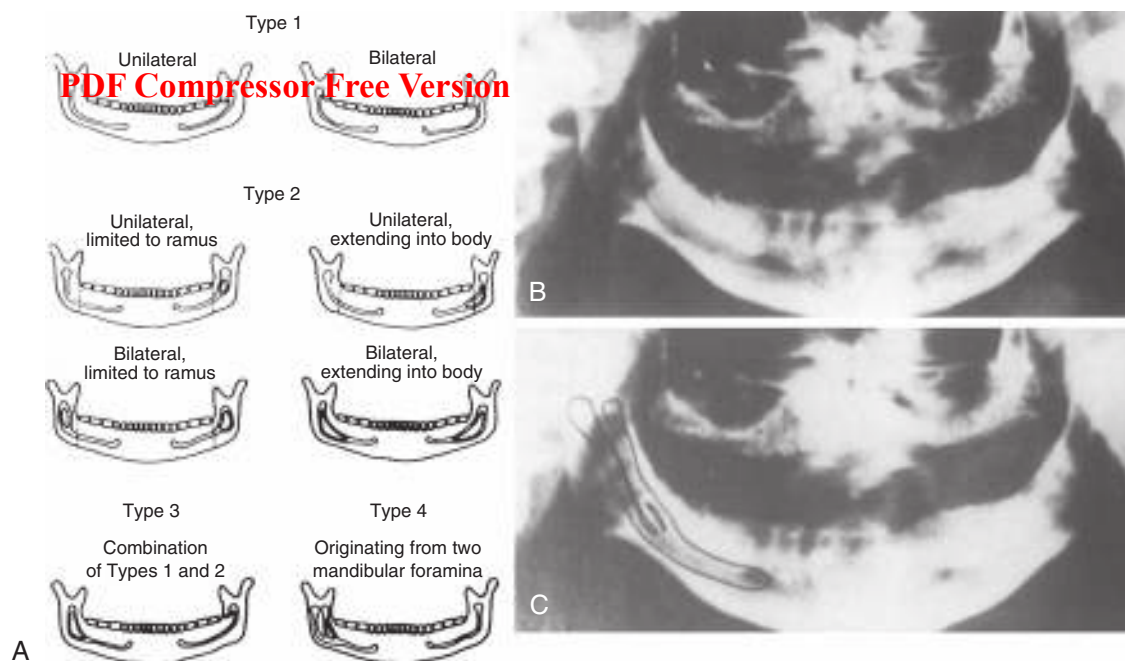
Anesthesia of the buccal nerve is important for dental procedures requiring soft tissue manipulation on the buccal surface of the mandibular molars.

Branches of the Posterior Division. The posterior division of the mandibular nerve (V_3) is primarily sensory with a small motor component. It descends for a short distance downward and medial to the lateral pterygoid muscle, at which point it branches into the auriculotemporal, lingual, and inferior alveolar nerves.

The auriculotemporal nerve is not profoundly significant in dentistry. It traverses the upper part of the parotid gland and then crosses the posterior portion of the zygomatic arch. It gives off a number of branches, all of which are sensory. These include a communication with the facial nerve, providing sensory fibers to the skin over areas of innervation of the following motor branches of the facial nerve: zygomatic, buccal, and mandibular; a communication with the otic ganglion, providing sensory, secretory, and vasomotor fibers to the parotid gland; the anterior auricular branches, supplying the skin over the helix and tragus of the ear; branches to the external auditory meatus, innervating the skin over the meatus and the tympanic membrane; articular branches to the posterior portion of the temporomandibular joint; and superficial temporal branches, supplying the skin over the temporal region.¹⁻⁶

The lingual nerve is the second branch of the posterior division of the mandibular nerve. It passes downward medial to the lateral pterygoid muscle and, as it descends, lies between the ramus and the medial pterygoid muscle in the pterygomandibular space. It runs anterior and medial to the inferior alveolar nerve, whose path it parallels. It then continues downward and forward, deep to the pterygomandibular raphe and below the attachment of the superior constrictor of the pharynx, to reach the side of the base of the tongue slightly below and behind the mandibular third molar (see Figs. 12.13 and 12.14). Here it lies just below the mucous membrane in the lateral lingual sulcus, where it is so superficial in some persons that it may be seen just below the mucous membrane. It then proceeds anteriorly across the muscles of the tongue, looping downward and medial to the submandibular (Wharton) duct to the deep surface of the sublingual gland, where it breaks up into its terminal branches.

The lingual nerve is the sensory tract to the anterior two-thirds of the tongue. It provides both general sensation and gustation (taste) for this region. It is the nerve that supplies fibers for general sensation, whereas the chorda tympani (a branch of the facial nerve) supplies fibers for taste. In addition, the lingual nerve provides sensory innervation to the mucous membranes of the floor of the mouth and the gingiva on the lingual aspect of the mandible. The lingual nerve is the nerve most commonly



• **Fig. 12.15** (A) Variations in bifid mandibular canals. (B and C) Radiographs of a type 4 bifid mandibular canal (B) on the patient's right; [C] outlined. (From Langlais RP, Broadus R, Glass BJ. Bifid mandibular canals in panoramic radiographs. *J Am Dent Assoc.* 1985;110:923–926.)

associated with cases of paresthesia (prolonged or permanent sensory nerve damage).

The inferior alveolar nerve is the largest branch of the mandibular division (see Fig. 12.14). It descends medial to the lateral pterygoid muscle and lateroposterior to the lingual nerve, to the region between the sphenomandibular ligament and the medial surface of the mandibular ramus, where it enters the mandibular canal at the level of the mandibular foramen. Throughout its path, it is accompanied by the inferior alveolar artery (a branch of the internal maxillary artery) and the inferior alveolar vein. The artery lies just anterior to the nerve. The nerve, artery, and vein travel anteriorly in the mandibular canal as far forward as the mental foramen, where the nerve divides into its terminal branches: the incisive nerve and the mental nerve.

Bifid (from the Latin meaning “cleft into two parts”) inferior alveolar nerves and mandibular canals have been observed radiographically and categorized by Langlais et al.⁵ Among 6000 panoramic radiographs studied, bifid mandibular canals were evident in 0.95%. The bifid mandibular canal is clinically significant in that it increases the difficulty of achieving adequate anesthesia in the mandible through conventional techniques. This is especially so in the type 4 variation (Fig. 12.15), in which two separate mandibular foramina are present on each side of the mouth.

The mylohyoid nerve branches from the inferior alveolar nerve before entry of the latter into the mandibular canal (see Figs. 12.13 and 12.14). It runs downward and forward in the mylohyoid groove on the medial surface of the ramus and along the body of the mandible to reach the mylohyoid muscle. The mylohyoid nerve is a mixed nerve, being motor to the mylohyoid muscle and the anterior belly of

the digastric muscle. It is thought to contain sensory fibers that supply the skin on the inferior and anterior surfaces of the mental protuberance. It may also provide sensory innervation to the mandibular incisors. Evidence suggests that the mylohyoid nerve may also be involved in supplying pulpal innervation to portions of the mandibular molars in some persons, usually the mesial root of the mandibular first molar.⁶

Once the inferior alveolar nerve enters the mandibular canal, it travels anteriorly along with the inferior alveolar artery and vein. The dental plexus serves the mandibular posterior teeth, entering through their apices and providing pulpal innervation. Other fibers supply sensory innervation to the buccal periodontal tissues of these same teeth.

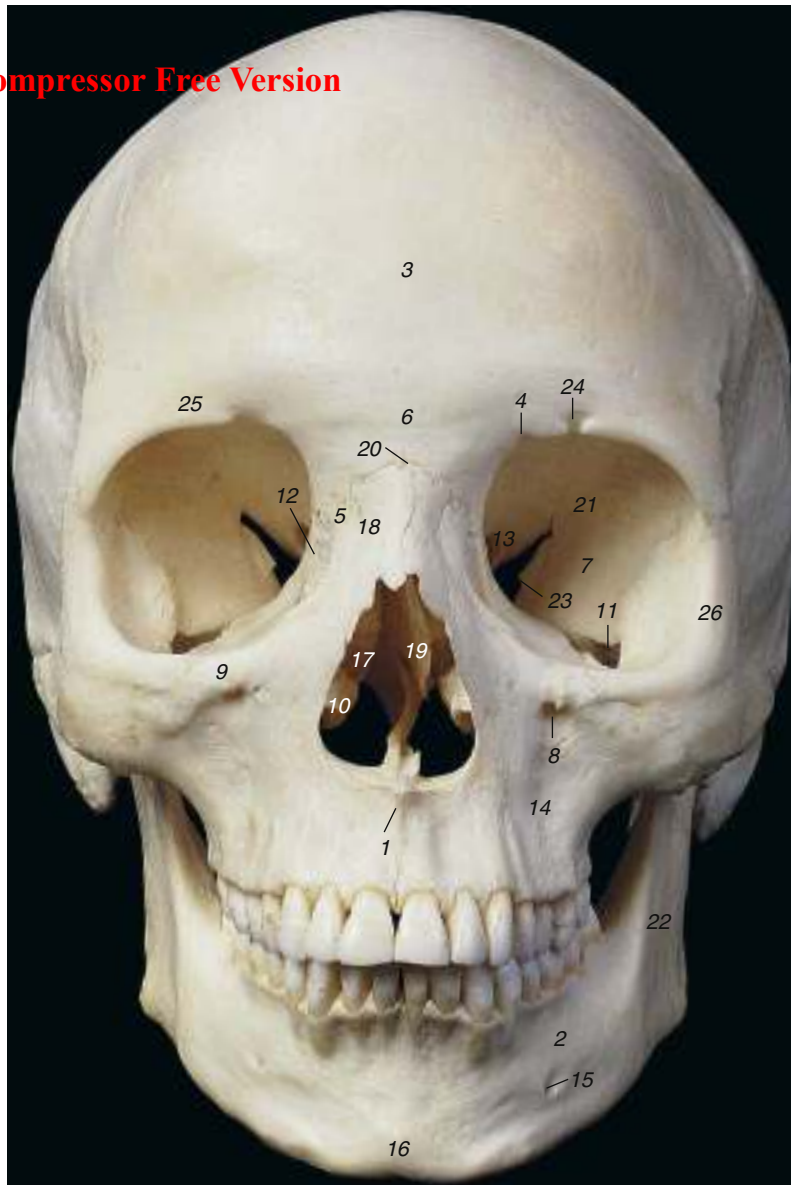
The inferior alveolar nerve divides into its two terminal branches: the incisive nerve and the mental nerve at the mental foramen (see Fig. 12.14). The incisive nerve remains within the mandibular canal and forms a nerve plexus that innervates the pulpal tissues of the mandibular first premolar, canine, and incisors via the dental branches. The mental nerve exits the canal through the mental foramen and divides into three branches that innervate the skin of the chin and the skin and mucous membrane of the lower lip.

Summary

The following outline summarizes the branches of the mandibular division (italicized nerves denote those especially significant in dental pain control):

1. undivided nerve
 - a. *nervus spinosus*
 - b. nerve to the medial pterygoid muscle

PDF Compressor Free Version



• **Fig. 12.16** Anterior View of the Skull. 1, Anterior nasal spine; 2, body of mandible; 3, frontal bone; 4, frontal notch; 5, frontal process of maxilla; 6, glabella; 7, greater wing of sphenoid bone; 8, infraorbital foramen; 9, infraorbital margin; 10, inferior nasal concha; 11, inferior orbital fissure; 12, lacrimal bone; 13, lesser wing of sphenoid bone; 14, maxilla; 15, mental foramen; 16, mental protuberance; 17, middle nasal concha; 18, nasal bone; 19, nasal septum; 20, nasion; 21, orbit (orbital cavity); 22, ramus of mandible; 23, superior orbital fissure; 24, supraorbital foramen; 25, supraorbital margin; 26, zygomatic bone. (From Abrahams PH, Marks SC Jr, Hutchings RT. *McMinn's Color Atlas of Human Anatomy*. 5th ed. St Louis: Mosby; 2003.)

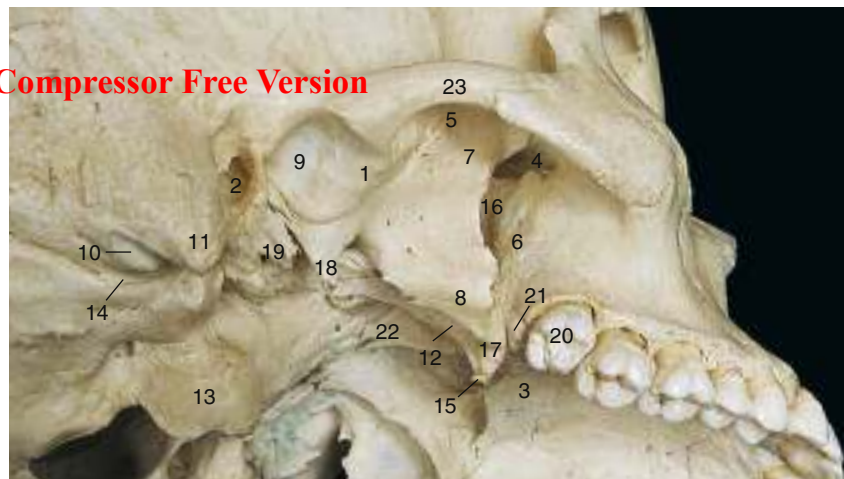
2. divided nerve
 - a. anterior division
 - i. nerve to the lateral pterygoid muscle
 - ii. nerve to the masseter muscle
 - iii. nerve to the temporal muscle
 - iv. *buccal nerve*
 - b. posterior division
 - i. auriculotemporal nerve
 - ii. *lingual nerve*
 - iii. *mylohyoid nerve*
 - iv. *inferior alveolar nerve: dental branches*
 - v. *incisive branch: dental branches*
 - vi. *mental nerve*

Osteology: Maxilla

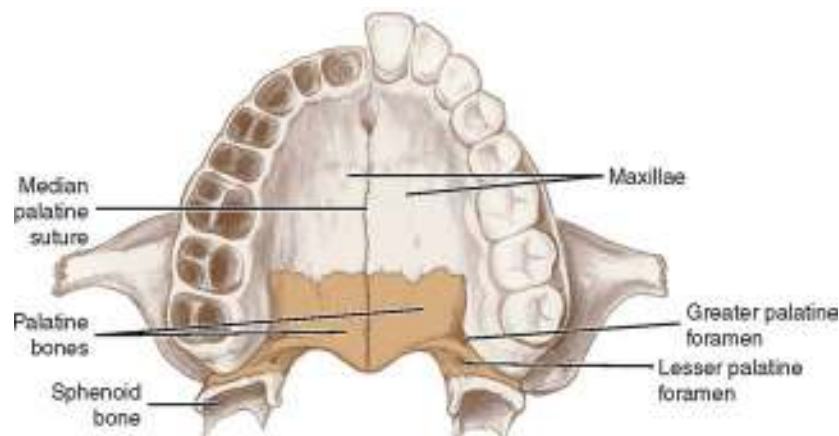
In addition to the neuroanatomy of pain control in dentistry, one should be aware of the relationship of these nerves to the osseous and soft tissues through which they course.

The maxilla (more properly, the right and left maxillae) is the largest bone of the face, excluding the mandible. Its anterior (or facial) surface (Fig. 12.16) is directed both forward and laterally. At its inferior borders are a series of eminences that correspond to the roots of the maxillary teeth. The most prominent is usually found over the canine tooth and is often referred to as the *canine eminence*. Superior to

PDF Compressor Free Version



• **Fig. 12.17** Infratemporal Aspect of the Maxilla. 1, Articular tubercle; 2, external acoustic meatus; 3, horizontal plate of palatine bone; 4, inferior orbital fissure; 5, infratemporal crest; 6, infratemporal (posterior) surface of maxilla; 7, infratemporal surface of greater wing of sphenoid bone; 8, lateral pterygoid plate; 9, mandibular fossa; 10, mastoid notch; 11, mastoid process; 12, medial pterygoid plate; 13, occipital condyle; 14, occipital groove; 15, pterygoid hamulus; 16, pterygomaxillary fissure and pterygopalatine fossa; 17, pyramidal process of palatine bone; 18, spine of sphenoid bone; 19, styloid process and sheath; 20, third molar tooth; 21, tuberosity of maxilla; 22, vomer; 23, zygomatic arch. (Data from Abrahams PH, Marks SC Jr, Hutchings RT. *McMinn's Color Atlas of Human Anatomy*. 5th ed. St Louis: Mosby; 2003.)



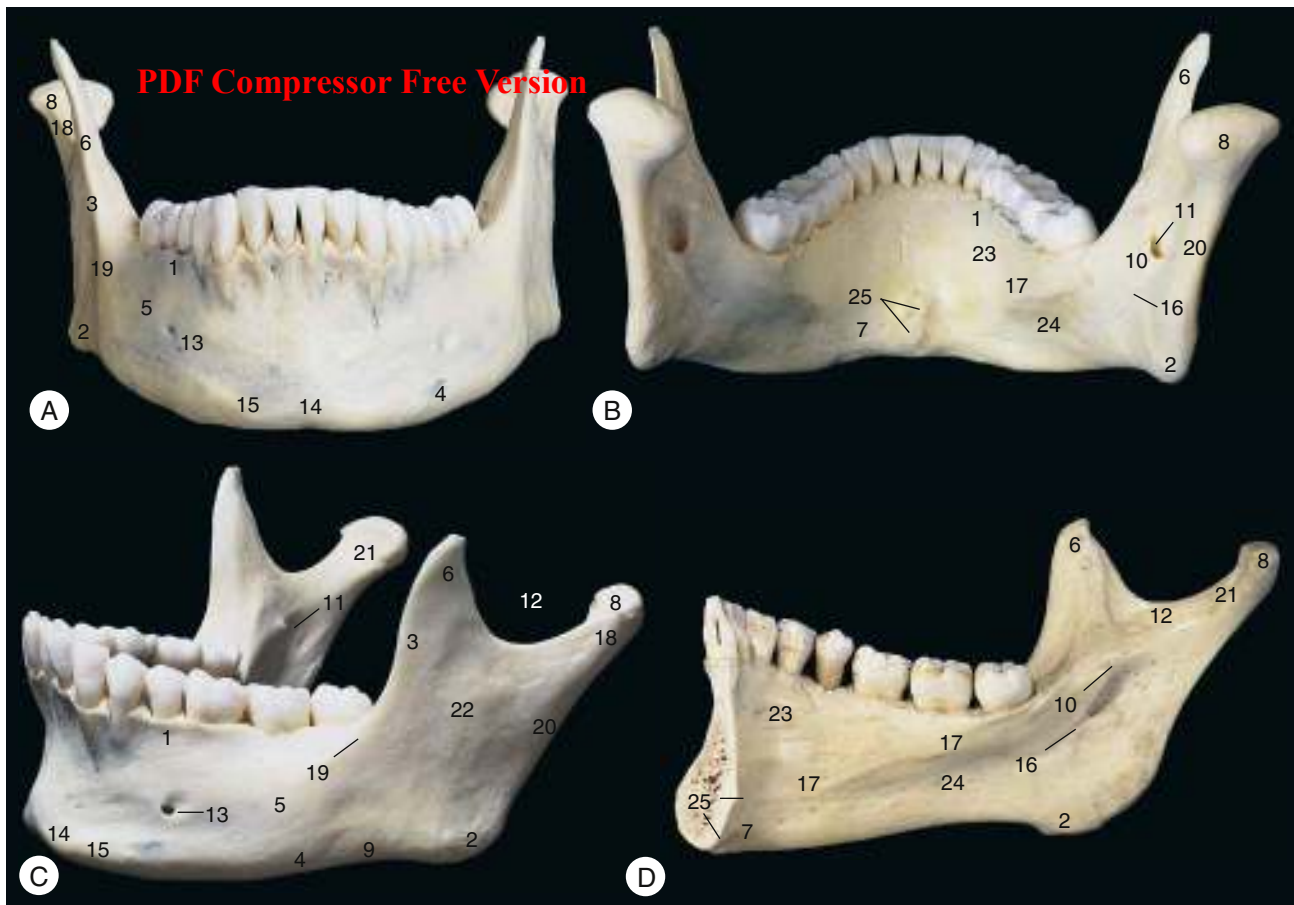
• **Fig. 12.18** Inferior View of the Hard Palate. (From Fehrenbach MJ, Herring SW. *Illustrated Anatomy of the Head and Neck*. 2nd ed. Philadelphia: WB Saunders; 2002.)

the canine fossa (located just distal to the canine eminence) is the infraorbital foramen, through which blood vessels and terminal branches of the infraorbital nerve emerge. Bone in the region of the maxillary teeth is commonly of the more porous cancellous variety, leading to a significantly greater incidence of clinically adequate anesthesia than in areas where denser cortical bone is present, such as in the mandible. In many areas, bone over the apices of the maxillary teeth is tissue-paper thin or shows evidence of dehiscence.

The inferior temporal surface of the maxilla is directed backward and laterally (Fig. 12.17). Its posterior surface is pierced by several alveolar canals that transmit the PSA nerves and blood vessels. The maxillary tuberosity, a rounded eminence, is found on the inferior posterior surface. On the superior surface is a groove, directed laterally and slightly

superiorly, through which the maxillary nerve passes. This groove is continuous with the infraorbital groove.

The palatal processes of the maxilla are thick horizontal projections that form a large portion of the floor of the nose and the roof of the mouth. The bone here is considerably thicker anteriorly than posteriorly. Its inferior (or palatal) surface constitutes the anterior three-fourths of the hard palate (Fig. 12.18). Many foramina (passages for nutrient blood vessels) perforate it. Along its lateral border, at the junction with the alveolar process, is a groove through which the anterior palatine nerve passes from the greater palatine foramen. In the midline in the anterior region is the funnel-shaped opening of the incisive foramen. Four canals are located in this opening: two for the descending palatine arteries and two for the nasopalatine nerves. In many skulls, especially those of persons below 6 years of age, a fine suture



• **Fig. 12.19** The mandible (A) from the front, (B) from behind and above, and (C) from the left and front, and (D) internal view from the left. 1, Alveolar part; 2, angle; 3, anterior border of ramus; 4, base; 5, body; 6, coronoid process; 7, digastric fossa; 8, head; 9, inferior border of ramus; 10, lingula; 11, mandibular foramen; 12, mandibular notch; 13, mental foramen; 14, mental protuberance; 15, mental tubercle; 16, mylohyoid groove; 17, mylohyoid line; 18, neck; 19, oblique line; 20, posterior border of ramus; 21, pterygoid fovea; 22, ramus; 23, sublingual fossa; 24, submandibular fossa; 25, superior and inferior mental spines (genial tubercles). (From Abrahams PH, Marks SC Jr, Hutchings RT. *McMinn's Color Atlas of Human Anatomy*. 5th ed. St Louis: Mosby; 2003.)

line extends laterally from the incisive foramen to the border of the palatine process by the canine teeth. The small area anterior to this suture is termed the *premaxilla*.

The horizontal plate of the palatine bone forms the posterior fourth of the hard palate. Its anterior border articulates with the palatine process of the maxilla, and its posterior border serves as the attachment for the soft palate. Foramina are present on its surface, representing the lower end of the pterygopalatine canal, through which descending palatine blood vessels and the anterior palatine nerve run.

Osteology: Mandible

The mandible is the largest and strongest bone of the face. It consists of a curved horizontal portion (the body) and two perpendicular portions (the rami). The buccal cortical plate of the adult mandible most often is sufficiently dense so as to preclude effective infiltration of anesthesia in its vicinity.⁷

The external (lateral) surface of the body of the mandible is marked in the midline by a faint ridge, an indication of

the symphysis of the two pieces of bone from which the mandible is created (Fig. 12.19A and C). The bone that forms the buccal and lingual alveolar processes in the anterior region (incisors) is usually less dense than that over the posterior teeth, permitting infiltration (supraperiosteal) anesthesia to be used with some expectation of success.^{8,9} In the region of the second premolar on each side, midway between the upper and lower borders of the body, lies the mental foramen. Phillips et al.¹⁰ in an evaluation of 75 dry, adult human mandibles determined that the usual position of the mental foramen is below the crown of the second premolar. The mental nerve, artery, and vein exit the mandibular canal here. Bone along this external surface of the mandible is commonly thick cortical bone.

The lingual border of the body of the mandible is concave from side to side (Fig. 12.19B and D). Extending upward and backward is the mylohyoid line, giving origin to the mylohyoid muscle. Bone along the lingual aspect of the mandible is usually quite thick; however, in approximately 68% of mandibles, lingual foramina are located

in the posterior (molar) region.¹¹ The function of these foramina is as yet unclear, but some may contain sensory fibers from the trigeminal nerve that innervate the mandibular molars.² In addition, bone on the lingual surface of the incisor teeth frequently demonstrates multiple small perforations, perhaps explaining recent clinical trials in which mandibular lingual infiltration had significant success in providing pulpal anesthesia.⁸

The lateral surface of each ramus is flat, composed of dense cortical bone, and provides attachment for the masseter muscle along most of its surface (see Fig. 12.19C). The medial surface (see Fig. 12.19D) contains the mandibular foramen, located roughly halfway between the superior and inferior borders and two-thirds to three-fourths the distance from the anterior border of the ramus to its posterior border.¹² Other studies of the anteroposterior location of the mandibular foramen have provided differing locations. Hayward et al.¹³ found the foramen most often in the third quadrant from the anterior part of the ramus, Monheim¹⁴ found it at the midpoint of the ramus, and Hetson et al.¹⁵ located it 55% distal to the anterior ramus (range, 44.4% to 65.5%). The mandibular canal extends obliquely downward and anteriorly within the ramus. It then courses horizontally forward in the body, distributing small dental branches to the mandibular teeth posterior to the mental foramen. The mandibular foramen is the point through which the inferior alveolar nerve, artery, and vein enter the mandibular canal. The height of this foramen varies greatly, ranging from 1 to 19 mm or more above the level of the occlusal plane.¹³ A prominent ridge, the lingula mandibulae, lies on the anterior margin of the foramen. The lingula serves as an attachment for the sphenomandibular ligament. At the lower end of the mandibular foramen, the mylohyoid groove begins, coursing obliquely downward and anteriorly. In this groove lie the mylohyoid nerve and vessels.

Bone along the lingual surface of the mandible is usually dense (see Fig. 12.19D). On rare occasions, bone over the lingual aspect of the third molar roots is less dense, permitting a greater chance that supraperiosteal anesthesia will be successful. However, the proximity of the lingual nerve to this site leads to caution against attempting lingual infiltration in the area of the mandibular molars.

The superior border of the ramus has two processes: the coronoid anteriorly and the condylar posteriorly. Between these two processes is a deep concavity, the mandibular (sigmoid) notch. The coronoid process is thinner than the condylar process. Its anterior border is concave—the coronoid notch. The coronoid notch is a landmark for determining the height of needle penetration in the inferior alveolar nerve block technique. The condylar process is thicker than the coronoid process. The condylar head, the thickened

articular portion of the condyle, sits atop the constricted neck of the condyle. The condylar neck is flattened front to back. The attachment for the external pterygoid muscle is on its anterior surface.

When cut horizontally at the level of the mandibular foramen, the ramus of the mandible can be seen to be thicker in its anterior region than it is posteriorly. This is of clinical importance during the inferior alveolar nerve block. The thickness of soft tissues between needle penetration and the osseous tissues of the ramus at the level of the mandibular foramen averages about 20 to 25 mm. Because of increased thickness of bone in the anterior third of the ramus, the thickness of soft tissue is decreased accordingly (approximately 10 mm). Knowing the depth of penetration of soft tissue before contacting osseous tissues can aid the administrator in determining correct positioning of the needle tip.

References

1. DuBrul EL. *Sicher's Oral Anatomy*. 7th ed. St Louis: Mosby; 1980.
2. Heasman PA. Clinical anatomy of the superior alveolar nerves. *Br J Oral Maxillofac Surg*. 1984;22:439–447.
3. McDaniel WL. Variations in nerve distributions of the maxillary teeth. *J Dent Res*. 1956;35:916–921.
4. Loetscher CA, Walton RE. Patterns of innervation of the maxillary first molar: a dissection study. *Oral Surg*. 1988;65:86–90.
5. Langlais RP, Broadus R, Glass BJ. Bifid mandibular canals in panoramic radiographs. *J Am Dent Assoc*. 1985;110:923–926.
6. Frommer J, Mele FA, Monroe CW. The possible role of the mylohyoid nerve in mandibular posterior tooth sensation. *J Am Dent Assoc*. 1972;85:113–117.
7. Blanton PL, Jeske AH. The key to profound local anesthesia: neuroanatomy. *J Am Dent Assoc*. 2003;134:753–760.
8. Yonchak T, Reader A, Beck M, et al. Anesthetic efficacy of infiltrations in mandibular anterior teeth. *Anesth Prog*. 2001;48:55–60.
9. Meechan JG, Ledvinka JI. Pulpal anaesthesia for mandibular central incisor teeth: a comparison of infiltration and intraligamentary injections. *Int Endod J*. 2002;35:629–634.
10. Phillips JL, Weller N, Kulild JC. The mental foramen. Part III. Size and position on panoramic radiographs. *J Endodont*. 1992;18:383–386.
11. Shiller WR, Wiswell OB. Lingual foramina of the mandible. *Anat Rec*. 1954;119:387–390.
12. Bremer G. Measurements of special significance in connection with anesthesia of the inferior alveolar nerve. *Oral Surg*. 1952;5:966–988.
13. Hayward J, Richardson ER, Malhotra SK. The mandibular foramen: its anteroposterior position. *Oral Surg*. 1977;44:837–843.
14. Monheim LM. *Local Anesthesia and Pain Control in Dental Practice*. 4th ed. St Louis: Mosby; 1969.
15. Hetson G, Share J, Frommer J, et al. Statistical evaluation of the position of the mandibular ramus. *Oral Surg*. 1988;65:32–34.

Techniques of Maxillary Anesthesia

Several general methods of obtaining pain control with local anesthetics are available. The site of deposition of the drug relative to the area of operative intervention determines the type of injection administered. Three major types of local anesthetic injection can be differentiated: local infiltration, field block, and nerve block.

Local Infiltration

Small terminal nerve endings in the area of the dental treatment are flooded with local anesthetic solution. An incision is then made (or treatment is performed) in the same area in which the local anesthetic has been deposited (Fig. 13.1). An example of local infiltration is the administration of a local anesthetic into an interproximal papilla before root planing. The term *infiltration* is in common usage in dentistry to define an injection in which the local anesthetic solution is deposited at or above the apex of the tooth to be treated. Although technically incorrect—this technique is a *field block* (see following)—the common term will continue to be used for this type of injection.

Field Block

Local anesthetic is deposited near the larger terminal nerve branches so the anesthetized area will be circumscribed, preventing the passage of impulses from the tooth to the central nervous system. An incision is then made (or treatment is performed) in an area away from the site of injection of the anesthetic (Fig. 13.2). Maxillary injections administered above the apex of the tooth to be treated are properly termed *field blocks* (although common usage identifies them as *infiltration* or *supraperiosteal injections*).

Nerve Block

Local anesthetic is deposited close to a main nerve trunk, usually at a distance from the site of operative intervention (Fig. 13.3). Posterior superior alveolar, inferior alveolar, and nasopalatine injections are examples of maxillary nerve blocks.

Discussion

Technically, the injection commonly referred to in dentistry as a local infiltration is a field block because anesthetic solution is deposited at or above the apex of the tooth to be treated. Terminal nerve branches to pulpal and soft tissues distal to the injection site are anesthetized.

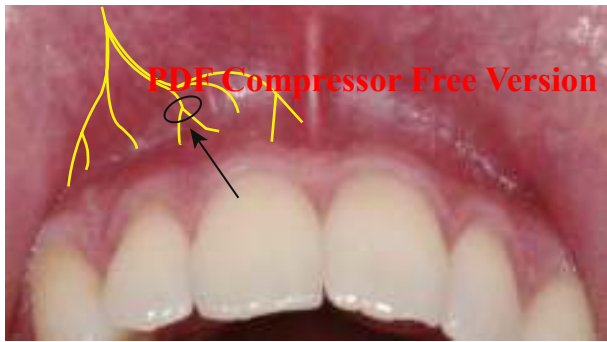Field block and nerve block may be distinguished by the extent of anesthesia achieved. In general, field blocks are more circumscribed, involving tissues in and around one or two teeth, whereas nerve blocks affect a larger area (e.g., that observed after inferior alveolar or anterior superior alveolar nerve block).

The type of injection administered for a given treatment is determined by the extent of the operative area. For management of small, localized areas, as in providing hemostasis for soft tissue procedures, infiltration anesthesia may suffice. When two or three teeth are being restored, field block is indicated, whereas for pain control in quadrant dentistry, regional block anesthesia is recommended.

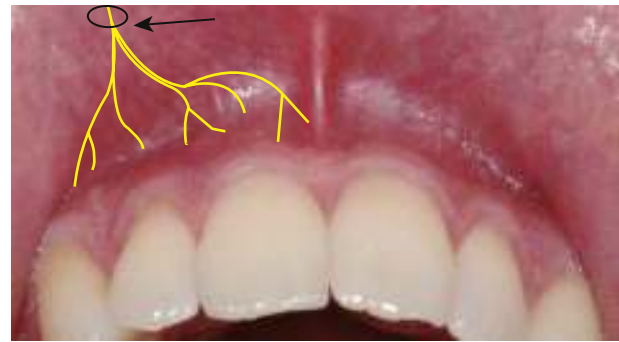
Maxillary Injection Techniques

Numerous injection techniques are available to provide clinically adequate anesthesia of the teeth and soft and hard tissues in the maxilla. Selection of the specific technique to be used is determined, in large part, by the nature of the treatment to be provided. The following techniques are available:

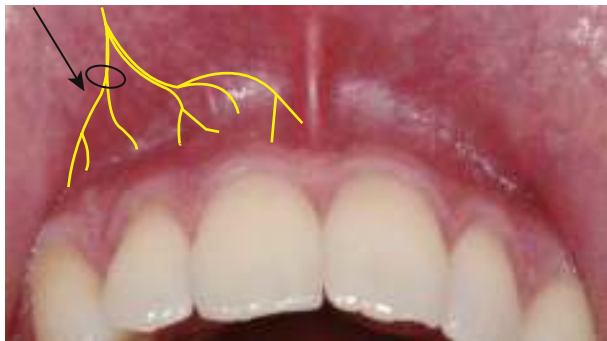1. supraperiosteal (infiltration), recommended for limited treatment protocols;
2. periodontal ligament (PDL; intraligamentary) injection, recommended as an adjunct to other techniques or for limited treatment protocols;
3. intraseptal injection, recommended primarily for periodontal surgical techniques;
4. intracrestal injection, recommended for single teeth (primarily mandibular molars) when other techniques have failed;
5. intraosseous injection, recommended for single teeth (primarily mandibular molars) when other techniques have failed;



• **Fig. 13.1** Local infiltration. The area of treatment is flooded with local anesthetic. An incision is made into the same area (*arrow*).



• **Fig. 13.3** Nerve block. Local anesthetic is deposited close to the main nerve trunk, located at a distance from the site of incision (*arrow*).



• **Fig. 13.2** Field block. Local anesthetic is deposited near the larger terminal nerve endings (*arrow*). An incision is made away from the site of injection.

6. posterior superior alveolar (PSA) nerve block, recommended for management of several molar teeth in one quadrant;
7. middle superior alveolar (MSA) nerve block, recommended for management of premolars in one quadrant;
8. anterior superior alveolar (ASA) nerve block, recommended for management of anterior teeth in one quadrant;
9. maxillary (V_2 , second division) nerve block, recommended for extensive buccal, palatal, and pulpal management in one quadrant;
10. greater (anterior) palatine nerve block, recommended for palatal soft and osseous tissue treatment distal to the canine in one quadrant;
11. nasopalatine nerve block, recommended for palatal soft and osseous tissue management from canine to canine bilaterally;
12. anterior middle superior alveolar (AMSA) nerve block, recommended for extensive management of anterior teeth and palatal and buccal soft and hard tissues;
13. palatal approach ASA (P-ASA) nerve block, recommended for treatment of maxillary anterior teeth and their palatal and facial soft and hard tissues.

Supraperiosteal, PDL, intraseptal, and intraosseous injections are appropriate for administration in both the maxilla and the mandible. Because of the great success of supraperiosteal injection in the maxilla, it is discussed in

this chapter. PDL, intraseptal, intracrestal, and intraosseous injections, supplemental injections of considerably greater importance in the mandible, are described in Chapter 15.

Teeth and Buccal Soft and Hard Tissues

Supraperiosteal Injection

The supraperiosteal injection, more commonly (but incorrectly) called *local infiltration*, is the most frequently used technique for obtaining pulpal anesthesia in maxillary teeth. Although it is a simple procedure with a high success rate, there are several valid reasons for using other techniques (e.g., regional nerve blocks) whenever more than two or three teeth are involved in treatment.

Multiple supraperiosteal injections necessitate multiple needle penetrations, each with the potential to produce pain, either during the procedure or after the anesthetic effect has resolved, or damage, either permanent or transient, to the involved tissues (blood vessels, nerves). In addition, and perhaps even more important, use of supraperiosteal injections for pulpal anesthesia on multiple teeth requires administration of a larger volume of local anesthetic, with an attendant increase (although usually minor in adults) in the risk of systemic and local complications.

The supraperiosteal injection is indicated whenever dental procedures are confined to a relatively circumscribed area in the maxillary or mandibular incisor region.

Other Common Names

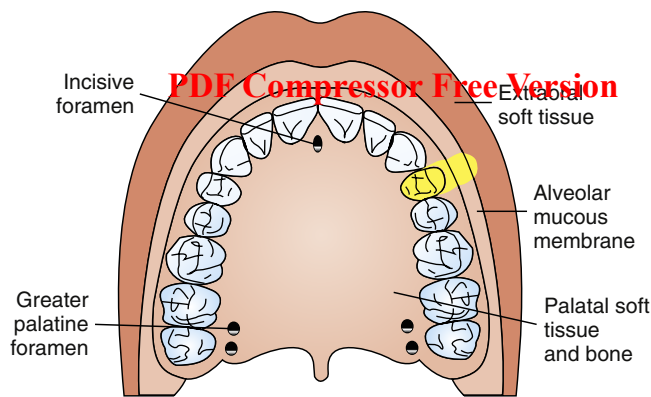
Local infiltration, paraperiosteal injection.

Nerves Anesthetized

Large terminal branches of the dental plexus.

Areas Anesthetized

The entire region innervated by the large terminal branches of this plexus: pulp and root area of the tooth, buccal periosteum, connective tissue, and mucous membrane (Fig. 13.4).



• **Fig. 13.4** Suprapariosteal injection in the anterior region of the maxilla. Note the area anesthetized (yellow).

Indications

1. Pulpal anesthesia of the maxillary teeth when treatment is limited to one or two teeth
2. Soft tissue anesthesia when indicated for surgical procedures in a circumscribed area

Contraindications

1. Infection or acute inflammation in the area of injection.
2. Dense bone covering the apices of teeth (can be determined only by trial and error; most likely over the permanent maxillary first molar in children, as its apex may be located beneath the zygomatic bone, which is relatively dense). The apex of an adult's central incisor may also be located beneath denser bone (e.g., of the nose), thereby increasing the failure rate (although not significantly).

Advantages

1. High success rate (>95%)
2. Technically easy injection
3. Usually entirely atraumatic

Disadvantages

Not recommended for large areas because of the need for multiple needle insertions and the necessity to administer larger total volumes of local anesthetic.

Positive Aspiration

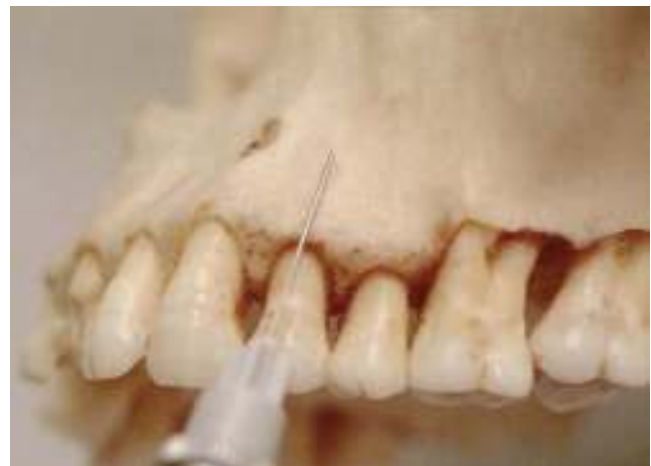Negligible, but possible (<1%).

Alternatives

PDL injection, intraosseous injection, regional nerve block.

Technique

1. A 27-gauge short needle is recommended.
2. Area of insertion: height of the mucobuccal fold above the apex of the tooth being anesthetized.
3. Target area: apical region of the tooth to be anesthetized.
4. Landmarks:
 - a. Mucobuccal fold.
 - b. Crown of the tooth.
 - c. Root contour of the tooth.



• **Fig. 13.5** The syringe should be held parallel to the long axis of the tooth and inserted at the height of the mucobuccal fold over the tooth.

5. Orientation of the bevel^a: toward bone.
6. Procedure:
 - a. Prepare tissue at the injection site:
 - i. Clean it with sterile dry gauze.
 - ii. Apply topical antiseptic (optional).
 - iii. Apply topical anesthetic for a minimum of 1 minute.
 - b. Orient the needle so the bevel faces bone.
 - c. Lift the lip, pulling the tissue taut, if possible using a mouth mirror (to minimize the risk of accidental needle-stick injury to the administrator).
 - d. Hold the syringe parallel to the long axis of the tooth (Fig. 13.5).
 - e. Insert the needle into the height of the mucobuccal fold over the target tooth.
 - f. Advance the needle until its bevel is at or above the apical region of the tooth (Table 13.1). In most instances the depth of penetration is only a few millimeters. Because the needle is in soft tissue (not touching bone), there should be no resistance to its advancement, nor should there be any patient discomfort with this injection.
 - g. Aspirate twice, rotating level 90° between aspirations.
 - i. If negative, deposit approximately 0.6 mL (one-third of a cartridge) slowly over 20 seconds. (Do not allow the tissues to balloon.)
 - h. Slowly withdraw the syringe.
 - i. Make the needle safe.
 - j. Wait 3 to 5 minutes before commencing the dental procedure.

^aBevel orientations are specified for all injection techniques in Chapters 13 and 14. The orientation of the needle bevel is not a significant factor in the success or failure of an injection technique, and these recommendations need not be rigidly adhered to; yet there will be a fuller expectation of successful anesthesia if they are followed, provided all other technical and anatomic principles are maintained. In general, whenever possible, the bevel of the needle should be facing toward bone; then, in the unlikely event that the needle comes into contact with bone, the bevel will slide over the periosteum, provoking minor discomfort but not tearing the periosteum. If the bevel faces away from bone, the sharp point of the needle would contact the periosteum, tearing it and leading to a more painful (subperiosteal) injection. Postinjection discomfort is considerably greater with subperiosteal injections than with suprapariosteal injections.

TABLE 13.1 Average Tooth Length

PDF Compressor Free Version

	Length of Crown (mm)	+	Length of Root (mm)	=	Length of Tooth (mm)
Maxillary					
Central incisors	11.6		12.4		24.0
Lateral incisors	9.0–10.2		12.3–13.5		22.5
Canines	10.9		16.1		27.0
First premolars	8.7		13.0		21.7
Second premolars	7.9		13.6		21.5
First molars	7.7		13.6		21.3
Second molars	7.7		13.4		21.1
Third molars	Extremely variable		Extremely variable		Extremely variable
Mandibular					
Central incisors	9.4		12.0		21.4
Lateral incisors	9.9		13.3		23.2
Canines	11.4		14.0		25.4
First premolars	7.5–11.0		11.0–16.0		18.5–27.0
Second premolars	8.5		14.7		23.2
First molars	8.3		14.5		22.8
Second molars	8.1		14.7		22.8
Third molars	Extremely variable		Extremely variable		Extremely variable

Signs and Symptoms

1. Subjective: feeling of numbness in the area of administration
2. Objective: use of a “freezing spray” (e.g., Endo-Ice) or an electric pulp tester (EPT) with no response from the tooth with maximal EPT output (80/80)
3. Absence of pain during treatment

Safety Features

1. Minimal risk of intravascular administration
2. Slow injection of anesthetic; aspiration (x2)

Precautions

Supraperiosteal injection is not recommended for larger areas of treatment. The greater number of tissue penetrations increases the possibility of pain both during and after the injection, and the larger volume of solution administered increases the possibility of local anesthetic overdose (in lighter-weight patients) and postinjection pain. Additionally, needle puncture of tissue can lead to permanent or transient damage to structures in the area, such as blood vessels (hematoma) and nerves (paresthesia).

Failures of Anesthesia

1. Needle tip lies below the apex (along the root) of the tooth (see Table 13.1). Depositing anesthetic solution below the apex of a maxillary tooth results in

excellent soft tissue anesthesia but poor or absent pulpal anesthesia.

2. Needle tip lies too far from the bone (solution deposited in buccal soft tissues). To correct this, redirect the needle closer to the periosteum.

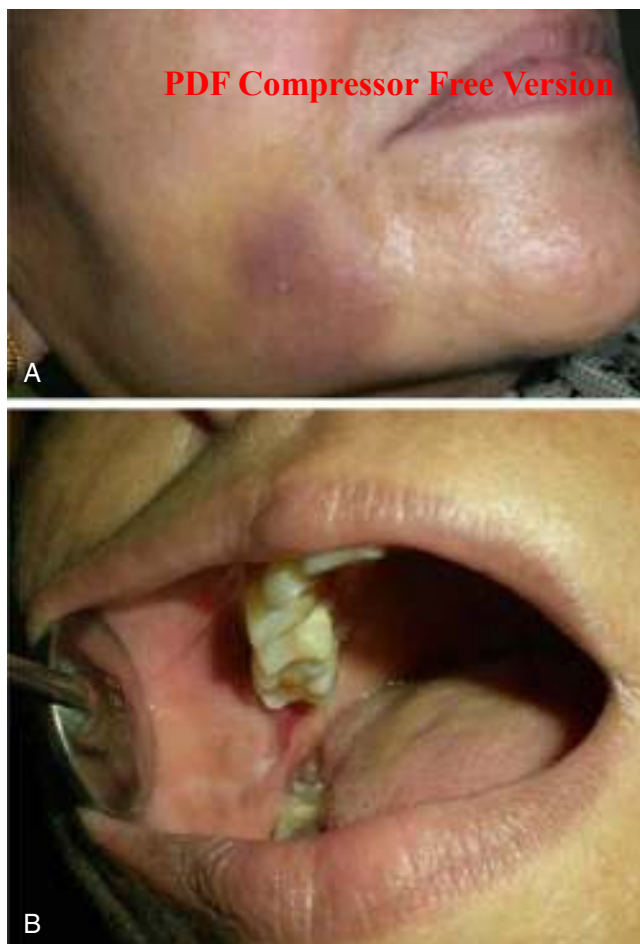Complications

Pain on needle insertion with the needle tip against the periosteum. To correct this, withdraw the needle and reinsert it farther from the periosteum.

Posterior Superior Alveolar Nerve Block

The PSA nerve block is a commonly used dental nerve block. Although it is a highly successful technique (>95%), several issues should be weighed when its use is considered. These include the extent of anesthesia produced and the potential for hematoma formation.

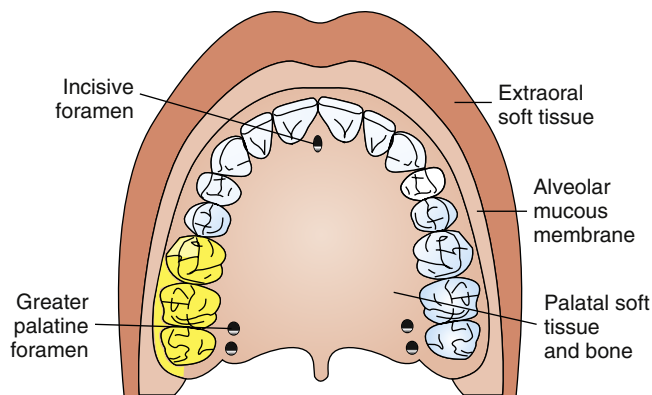
When used to achieve pulpal anesthesia, the PSA nerve block is effective for the maxillary third, second, and first molars (first molar in 77% to 100% of patients).¹ However, the mesiobuccal root of the maxillary first molar is not consistently innervated by the PSA nerve. In a dissection study by Loetscher et al.¹ the MSA nerve provided sensory innervation to the mesiobuccal root of the maxillary first molar in 28% of specimens examined. Therefore a second



• **Fig. 13.6** Hematoma subsequent to PSA nerve block. (A) Extraoral; (B) Intraoral.

injection, usually suprapariosteal, is indicated after the PSA nerve block when effective anesthesia of the first molar does not develop. Loetscher et al.¹ concluded by stating that the PSA nerve usually provides sole pulpal innervation to the maxillary first molar, and that a single PSA nerve block usually provides clinically adequate pulpal anesthesia.

The risk of a potential complication must be considered whenever the PSA nerve block is used. Insertion of the needle too far distally may lead to a temporarily (10 to 14 days) unesthetic hematoma (Fig. 13.6).² When the PSA nerve block is to be administered, one must always consider the patient's skull size when determining the depth of soft tissue penetration. An "average" depth of penetration in a patient with a smaller-than-average-sized skull may produce a hematoma, whereas a needle inserted "just right" in a larger-skulled patient might not provide anesthesia of any teeth. As a means of decreasing the risk of hematoma formation after a PSA nerve block, use of a "short" dental needle is recommended for all but the largest of patients. Because the average depth of soft tissue penetration from the insertion site (the mucobuccal fold over the maxillary second molar) to the area of the PSA nerves is 16 mm, a short dental needle (~20 mm) can be successfully and safely used. Overinsertion of the needle is less likely to occur, thereby minimizing



• **Fig. 13.7** Area anesthetized by a posterior superior alveolar nerve block.

the risk of hematoma. A 27-gauge short needle is recommended as long as aspiration is performed carefully, and the local anesthetic is injected slowly. One must remember to aspirate several times before and during drug deposition during PSA nerve block to avoid inadvertent intravascular injection.

Other Common Names

Tuberosity block, zygomatic block.

Nerves Anesthetized

PSA nerve and branches.

Areas Anesthetized

1. Pulp of the maxillary third, second, and first molars (entire 1st molar = 72% success rate; mesiobuccal root of the maxillary first molar not anesthetized = 28% of PSA nerve blocks)
2. Buccal periodontium and bone overlying these teeth (Fig. 13.7).

Indications

1. When treatment involves two or more maxillary molars
2. When suprapariosteal injection is contraindicated (e.g., with infection or acute inflammation)
3. When suprapariosteal injection has proved ineffective

Contraindication

When the risk of hemorrhage is too great (as with a hemophiliac; patients taking drugs that can increase bleeding such as coumadin or clopidogrel (Plavix)), in which case a suprapariosteal or PDL injection is recommended.

Advantages

1. Atraumatic. When administered properly, no pain is experienced by the patient receiving the PSA nerve block because of the relatively large area of soft tissue into which the local anesthetic is deposited and the fact that bone is not contacted.
2. High success rate (>95%).
3. Minimum number of necessary injections:
 - a. One injection compared with the option of three infiltrations.

4. Minimizes the total volume of local anesthetic solution administered:
 - a. The equivalent volume of the anesthetic solution for three suprapariosteal injections is 1.8 mL.

Disadvantages

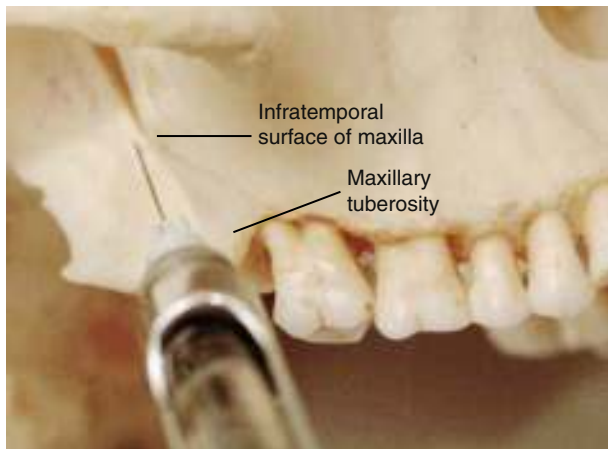
1. Risk of hematoma, which is usually diffuse and also discomfiting and visually embarrassing to the patient (Fig. 13.6)
2. Technique somewhat arbitrary: no bony landmarks during insertion
3. Second injection necessary for treatment of the first molar (mesiobuccal root) in 28% of patients

Positive Aspiration

Approximately 3.1%.

Alternatives

1. Supraperiosteal or PDL injections for pulpal and root anesthesia

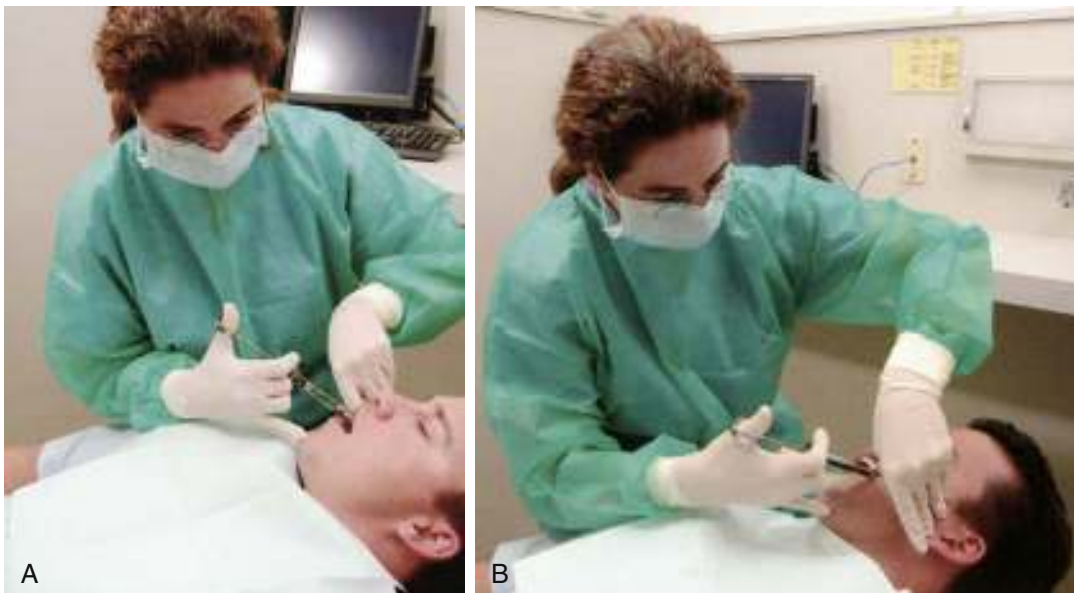

• Fig. 13.8 Needle at the target area for a posterior superior alveolar nerve block.

2. Infiltrations for the buccal periodontium and hard tissues
3. Maxillary nerve block

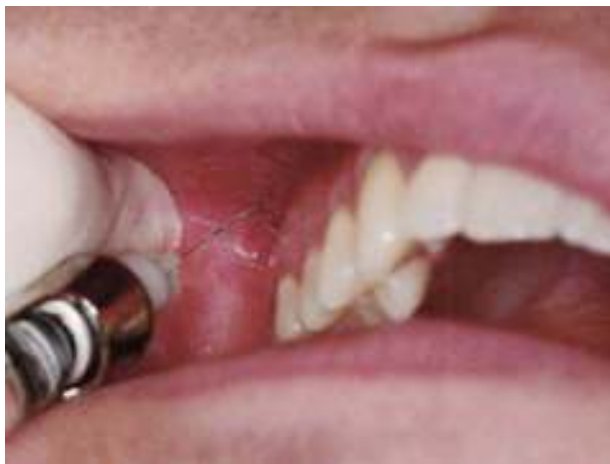Technique

1. A 27-gauge short needle is recommended.
2. Area of insertion: height of the mucobuccal fold above the maxillary second molar.
3. Target area: PSA nerve—posterior, superior, and medial to the posterior border of the maxilla (Fig. 13.8).
4. Landmarks:
 - a. Mucobuccal fold.
 - b. Maxillary tuberosity.
 - c. Zygomatic process of the maxilla.
5. Orientation of the bevel: toward bone during the injection. If bone is accidentally touched, the sensation is less unpleasant.
6. Procedure:
 - a. Assume the correct position (Fig. 13.9):
 - i. For a left PSA nerve block, a right-handed administrator should sit at the 10 o'clock position facing the patient.
 - ii. For a right PSA nerve block, a right-handed administrator should sit at the 8 o'clock position facing the patient.
 - b. Prepare the tissues at the height of the mucobuccal fold for penetration:
 - i. Dry with sterile gauze.
 - ii. Apply a topical antiseptic (optional).
 - iii. Apply topical anesthetic for a minimum of 1 minute.
 - c. Orient the bevel of the needle toward bone.
 - d. Partially open the patient's mouth, pulling the mandible to the side of injection.
 - e. Retract the patient's cheek (for visibility), if possible using a mouth mirror (to minimize the risk of accidental needlestick injury to the administrator).
 - f. Pull the tissues at the injection site taut.
 - g. Insert the needle into the height of the mucobuccal fold over the second molar (Fig. 13.10).

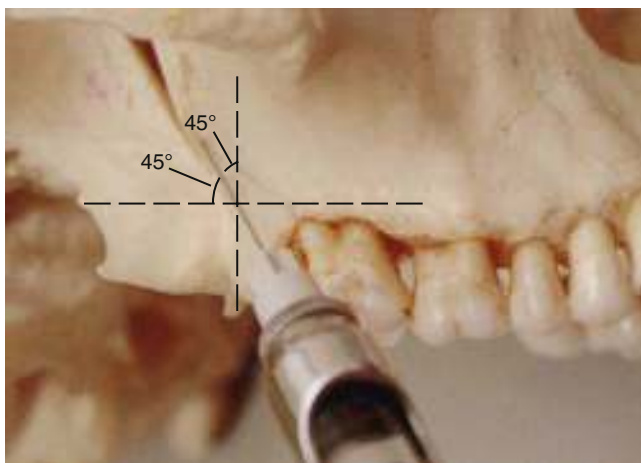


• Fig. 13.9 Position of the administrator for (A) right and (B) left posterior superior alveolar nerve block.

- h. Advance the needle slowly in an upward, inward, and backward direction (Fig. 13.11) in one movement (not three): **PDF Compressor Free Version**
 - i. Upward: superiorly at a 45-degree angle to the occlusal plane.
 - ii. Inward: medially toward the midline at a 45-degree angle to the occlusal plane (Fig. 13.12).
 - iii. Backward: posteriorly at a 45-degree angle to the long axis of the second molar.
- i. Slowly advance the needle through soft tissue:
 - i. There should be no resistance and therefore no discomfort to the patient.
 - ii. If resistance (bone) is felt, the angle of the needle in toward the midline is too great.
 - a. Withdraw the needle slightly (but do not remove it entirely from the tissues) and bring the syringe barrel closer to the occlusal plane.
 - b. Readvance the needle.
- j. Advance the needle to the desired depth (see Fig. 13.12).
 - i. In an adult of normal size, penetration to a depth of 16 mm places the needle tip in the immediate vicinity of the foramina through which the PSA nerves enter the posterior surface of the maxilla. When a long needle



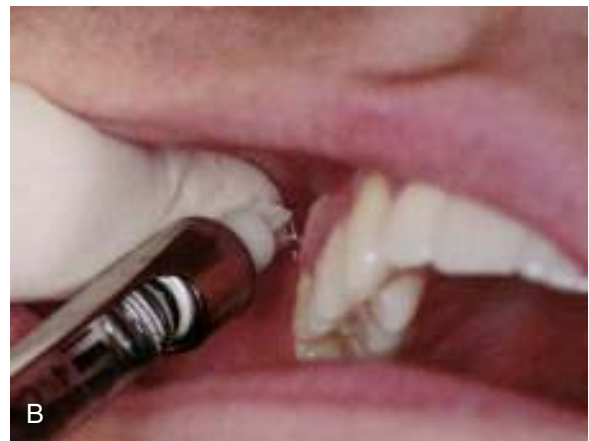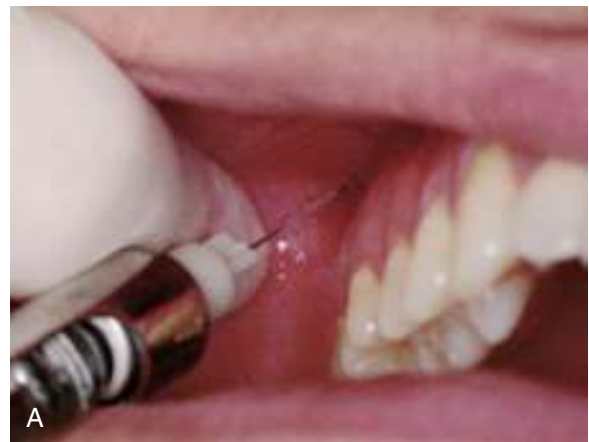• **Fig. 13.10** Posterior superior alveolar nerve block. Tissue retracted at the site of penetration. Note the orientation of the needle: inward, upward, backward.



• **Fig. 13.11** Advance the needle upward, inward, and backward.

is used (average length, 32 mm), it is inserted half its length into the tissue. With a short needle (average length, 20 mm), approximately 4 mm should remain visible. Use of a short needle minimizes the risk of overinsertion with possible hematoma formation.

- ii. For smaller adults and children, it is prudent to halt the advance of the needle short of its usual depth of penetration to avoid a possible hematoma caused by overinsertion. Penetrating to a depth of 10 to 14 mm places the needle tip in the target area in most smaller-skulled patients.
- Note: The goal is to deposit local anesthetic close to the PSA nerves, located posterosuperior and medial to the maxillary tuberosity.*
- k. Aspirate in two planes.
 - i. Rotate the syringe barrel (needle bevel) 90° and reaspirate.
 - l. If both aspirations are negative:
 - i. Slowly, over 30 to 60 seconds, deposit 0.9 to 1.8 mL of anesthetic solution.
 - ii. Aspirate several additional times (in one plane) during drug administration.
 - iii. The PSA injection is normally atraumatic because of the large tissue space available to accommodate the anesthetic solution and the fact that bone is not touched.



• **Fig. 13.12** (A) With a “long” dental needle (>32 mm in length) in an average-sized adult, the depth of penetration is half its length. Use of a “long” needle for posterior superior alveolar nerve block increases the risk of overinsertion and hematoma. (B) Posterior superior alveolar nerve block using a “short” dental needle (~20 mm in length). Overinsertion is less likely.

- m. Slowly withdraw the syringe.
- n. Make the needle safe.
- o. Wait a minimum of 3 to 5 minutes before commencing the dental procedure.

Signs and Symptoms

1. Subjective: usually none; the patient has difficulty reaching this region to determine the extent of anesthesia.
2. Objective: use of a freezing spray (e.g., Endo-Ice) or an EPT with no response from the tooth with maximal EPT output (80/80).
3. Absence of pain during treatment.

Safety Features

1. Slow injection, repeated aspirations.
2. No anatomic safety features to prevent overinsertion of the needle; therefore careful observation is necessary.

Precaution

The depth of needle penetration should be checked: overinsertion (too deep) increases the risk of hematoma; a little too shallow might still provide adequate anesthesia.

Failures of Anesthesia

1. Needle too lateral. To correct this, redirect the needle tip medially (see complication 2).
2. Needle not high enough. To correct this, redirect the needle tip superiorly.
3. Needle too far posterior. To correct this, withdraw the needle to the proper depth.

Complications

1. Hematoma:
 - a. This is commonly produced by insertion of the needle too far posteriorly into the pterygoid plexus of veins. In addition, the maxillary artery may be perforated (rarely). Use of a short needle minimizes the risk of pterygoid plexus puncture.
 - b. A visible intraoral hematoma develops within several minutes, usually noted in the buccal tissues of the mandibular region (see Chapter 17).
 - i. There is no easily accessible intraoral area to which pressure can be applied to stop the hemorrhage.
 - ii. Bleeding continues until the pressure of extravascular blood is equal to or greater than that of intravascular blood.
2. Mandibular anesthesia:
 - a. The mandibular division of the fifth cranial nerve (V_3) is located lateral to the PSA nerves. Deposition of local anesthetic lateral to the desired location may produce various degrees of mandibular anesthesia. Most often, when this occurs, patients mention that their tongue and perhaps their lower lip are anesthetized.

Middle Superior Alveolar Nerve Block

The MSA nerve is present in about 28% of the population, thereby limiting the clinical usefulness of the MSA nerve block. However, when the ASA nerve block fails to provide

pulpal anesthesia distal to the maxillary canine, the MSA nerve block is indicated for procedures on premolars and the mesiobuccal root of the maxillary first molar. The success rate of the MSA nerve block is high.

Nerves Anesthetized

MSA nerve and terminal branches.

Areas Anesthetized

1. Pulp of the maxillary first and second premolars, mesiobuccal root of the first molar
2. Buccal periodontal tissues and bone over these same teeth (Fig. 13.13)

Indications

1. Where the ASA nerve block fails to provide pulpal anesthesia distal to the maxillary canine
2. Dental procedures involving both maxillary premolars only

Contraindications

1. Infection or inflammation in the area of injection or needle insertion or drug deposition.
2. Where the MSA nerve is absent, innervation is through the ASA nerve; branches of the ASA innervating the premolars and the mesiobuccal root of the first molar can be anesthetized by means of the MSA technique.

Advantages

Minimizes the number of injections and the volume of solution.

Disadvantages

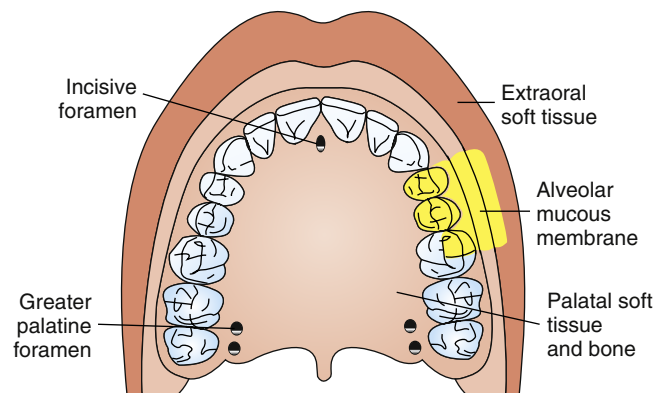
None.

Positive Aspiration

Negligible (<3%).

Alternatives

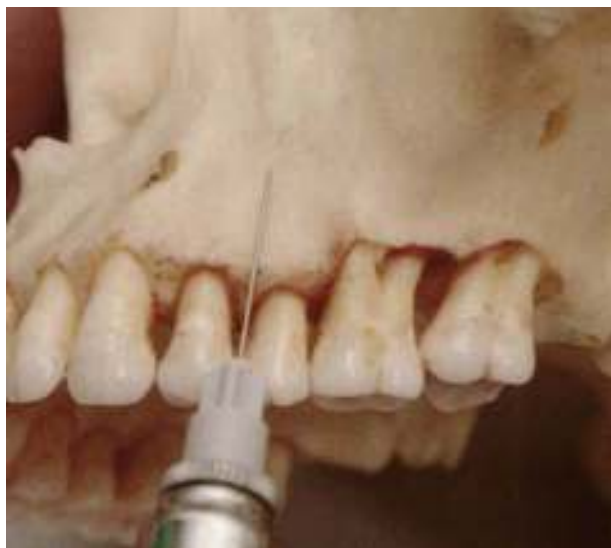1. Local infiltration (supraperiosteal), PDL, intraosseous injections
2. ASA nerve block for the first and second premolar and the mesiobuccal root of the first molar



• Fig. 13.13 Area anesthetized by a middle superior alveolar nerve block.

Technique

1. A 27-gauge short needle is recommended.
2. Area of insertion: between the mucobuccal fold above the maxillary second premolar.
3. Target area: maxillary bone above the apex of the maxillary second premolar (Fig. 13.14).
4. Landmark: mucobuccal fold above the maxillary second premolar.
5. Orientation of the bevel: toward bone.
6. Procedure:
 - a. Assume the correct position (Fig. 13.15):
 - i. For a right MSA nerve block, a right-handed administrator should face the patient from the 10 o'clock position.
 - ii. For a left MSA nerve block, a right-handed administrator should face the patient directly from the 8 or 9 o'clock position.
 - b. Prepare the tissues at the site of injection:
 - i. Dry with sterile gauze.
 - ii. Apply topical antiseptic (optional).
 - iii. Apply topical anesthetic for a minimum of 1 minute.
 - c. Stretch the patient's upper lip to make the tissues taut and to gain visibility, if possible using a mouth mirror (to minimize the risk of accidental needle stick injury to the administrator).
 - d. Insert the needle into the height of the mucobuccal fold above the second premolar with the bevel directed toward bone.
 - e. Penetrate the mucous membrane and slowly advance the needle until its tip is located well above the apex of the second premolar (Fig. 13.16).
 - f. Aspirate in two planes.
 - g. Slowly deposit 0.9 to 1.2 mL (one-half to two-thirds of cartridge) of solution (approximately 30 to 40 seconds).
 - h. Withdraw the syringe and make the needle safe.
 - i. Wait a minimum of 3 to 5 minutes before commencing dental therapy.



• **Fig. 13.14** Position of needle between maxillary premolars for a middle superior alveolar nerve block.

Signs and Symptoms

1. Subjective: upper lip numb
2. Objective: use of a freezing spray (e.g., Endo-Ice) or an EPT with no response from the tooth with maximal EPT output (80/80)
3. Absence of pain during treatment

Safety Feature

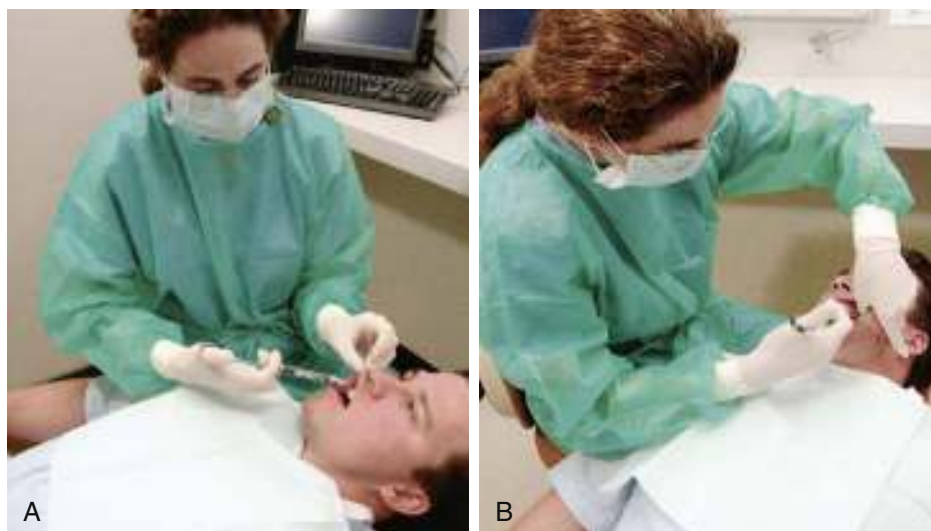Relatively avascular area, anatomically safe.

Precautions

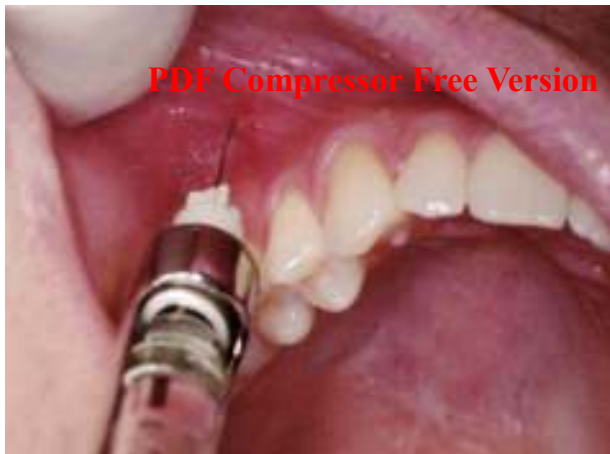To prevent pain, do not insert the needle too close to the periosteum and do not inject anesthetic too rapidly; the MSA injection should be an atraumatic injection.

Failures of Anesthesia

1. Anesthetic solution is not deposited high above the apex of the second premolar.



• **Fig. 13.15** Position of the administrator for a right middle superior alveolar nerve block (A) and left middle superior alveolar nerve block (B).



• **Fig. 13.16** Needle penetration for a middle superior alveolar nerve block.

- a. To correct this, check radiographs and increase the depth of penetration.
2. Solution is deposited too far from the maxillary bone with the needle placed in tissues lateral to the height of the mucobuccal fold.
 - a. To correct this, reinsert the needle at the height of the mucobuccal fold.
3. Bone of the zygomatic arch at the site of injection prevents the diffusion of anesthetic.
 - a. To correct this, use the suprapariosteal, ASA, or PSA injection in place of the MSA injection.

Complications (Rare)

A hematoma may develop at the site of injection. Apply pressure with sterile gauze over the site of swelling and discoloration for a minimum of 60 seconds.

Anterior Superior Alveolar Nerve Block (Infraorbital Nerve Block)

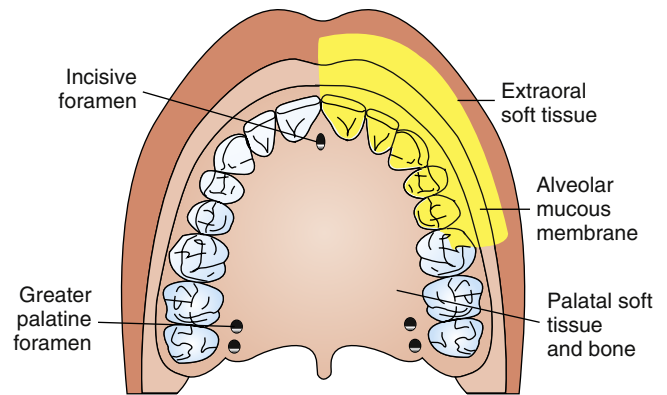
The ASA nerve block does not enjoy the popularity of the PSA nerve block, primarily because there is a general lack of experience with this highly successful and extremely safe technique. It provides profound pulpal and buccal soft tissue anesthesia from the maxillary central incisor through the premolars, (premolars 72%).

Used in place of suprapariosteal injection, the ASA nerve block necessitates a smaller volume of local anesthetic solution to achieve equivalent anesthesia: 0.9 to 1.2 mL versus 3.0 mL for suprapariosteal injections of the same teeth.

Generally speaking, the major factor inhibiting dentists from using the ASA nerve block is fear of injury to the patient's eye. Fortunately, this fear is unfounded. Adherence to the following protocol produces a high success rate devoid of complications and adverse side effects.

Other Common Name

Infraorbital nerve block (technically, the infraorbital nerve block provides anesthesia of the soft tissues of the anterior portion of the face, not to the teeth or intraoral soft and hard tissues; therefore it is inaccurate to call the ASA nerve



• **Fig. 13.17** Anterior superior alveolar nerve block, showing area anesthetized, (Premolars 72% success when MSA nerve is present).

block the infraorbital nerve block when anesthesia of teeth is the desired goal).

Nerves Anesthetized

1. Anterior superior alveolar nerve
2. MSA nerve
3. Infraorbital nerve
 - a. Inferior palpebral
 - b. Lateral nasal
 - c. Superior labial

Areas Anesthetized

1. Pulp of the maxillary central incisor through the canine on the injected side
2. In about 72% of patients, pulp of the maxillary premolars and mesiobuccal root of the first molar
3. Buccal (labial) periodontium and bone of these same teeth
4. Lower eyelid, lateral aspect of the nose, upper lip (Fig. 13.17)

Indications

1. Dental procedures involving more than two maxillary anterior teeth (incisors through premolars) and their overlying buccal tissues.
2. Inflammation or infection (which contraindicates suprapariosteal injection): If a cellulitis is present, the maxillary nerve block may be indicated in lieu of the ASA nerve block.
3. When suprapariosteal injections have been ineffective because of dense cortical bone.

Contraindications

1. Discrete treatment areas (one or two teeth only; suprapariosteal injection preferred).
2. Hemostasis of localized areas, when desirable, cannot be adequately achieved with this injection; local infiltration into the treatment area is indicated.

Advantages

1. Comparatively simple technique
2. Comparatively safe; minimizes the volume of solution used and the number of needle punctures necessary to achieve anesthesia

Disadvantages

1. Psychological:
 - a. Administrator: The patient's initial fear of the patient's eye (with experience confidence in the technique is achieved).
 - b. Patient: An extraoral approach to the infraorbital nerve may prove disturbing; however, intraoral techniques are rarely a problem.
2. Anatomic: difficulty defining landmarks (rare).

Positive Aspiration

Negligible (0.7%).

Alternatives

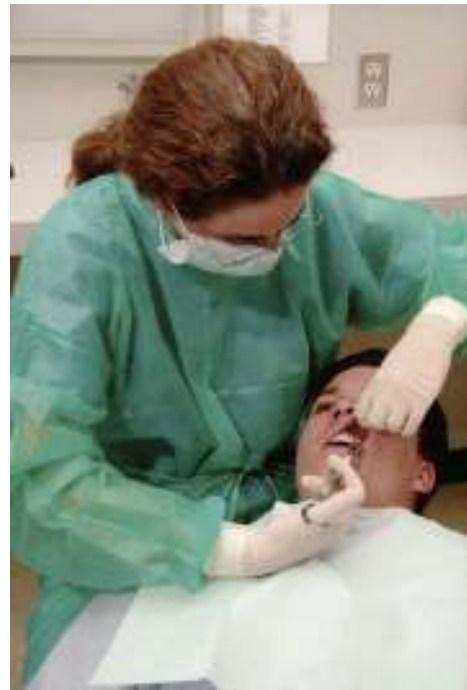1. Supraperiosteal, PDL, or intraosseous injection for each tooth
2. Infiltration for the periodontium and hard tissues
3. Maxillary nerve block

Technique

1. A 25- or 27-gauge long needle is recommended, although a 27-gauge short needle also may be used, especially for children and smaller adults.
2. Area of insertion: height of the mucobuccal fold directly over the first premolar.

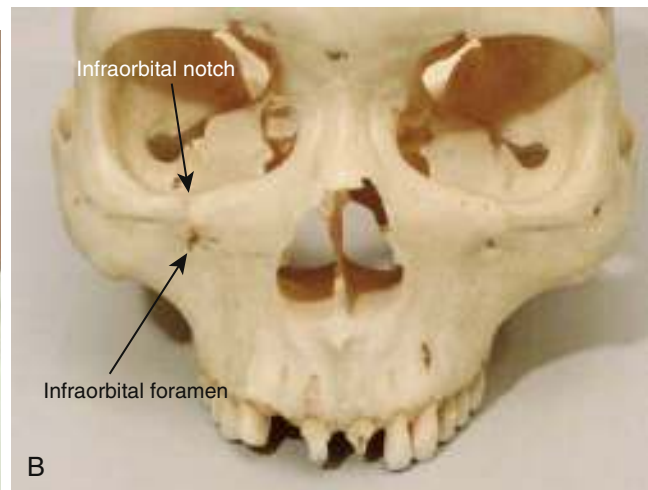
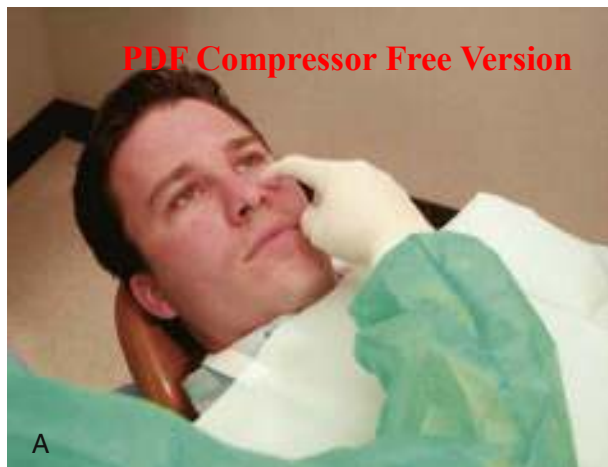Note: The needle may be inserted into the height of the mucobuccal fold over any tooth from the second premolar anteriorly to the central incisor. The ensuing path of penetration is toward the target area, the infraorbital foramen. The first premolar usually provides the shortest route to this target area.

3. Target area: infraorbital foramen (below the infraorbital notch).
4. Landmarks:
 - a. Mucobuccal fold.
 - b. Infraorbital notch.
 - c. Intraorbital foramen.
5. Orientation of the bevel: toward bone.
6. Procedure:
 - a. Assume the correct position (Fig. 13.18). For a right or left infraorbital nerve block, a right-handed administrator should sit at the 10 o'clock position, directly facing the patient or facing in the same direction as the patient.
 - b. Position the patient supine (much preferred) or semisupine with the neck extended slightly. If the patient's neck is not extended, the patient's chest may interfere with the syringe barrel.
 - c. Prepare the tissues at the injection site (height of the mucobuccal fold) for penetration:
 - i. Dry with sterile gauze.
 - ii. Apply topical antiseptic (optional).
 - iii. Apply topical anesthetic for a minimum of 1 minute.
 - d. Locate the infraorbital foramen (Fig. 13.19):
 - i. Feel the infraorbital notch.
 - ii. Move your finger downward from the notch, applying gentle pressure to the tissues.
 - iii. The bone immediately inferior to the notch is convex (felt as an outward bulge). This represents the lower border of the orbit and the roof of the infraorbital foramen (see Fig. 13.19B).

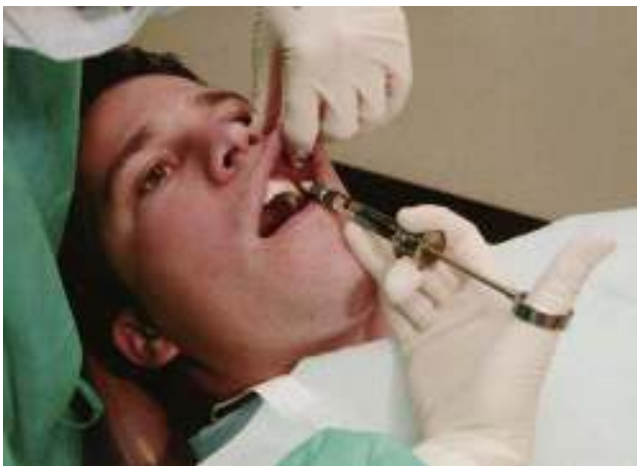

• **Fig. 13.18** Position of the administrator for a right or left anterior superior alveolar nerve block. The patient's head should be turned slightly to improve visibility.

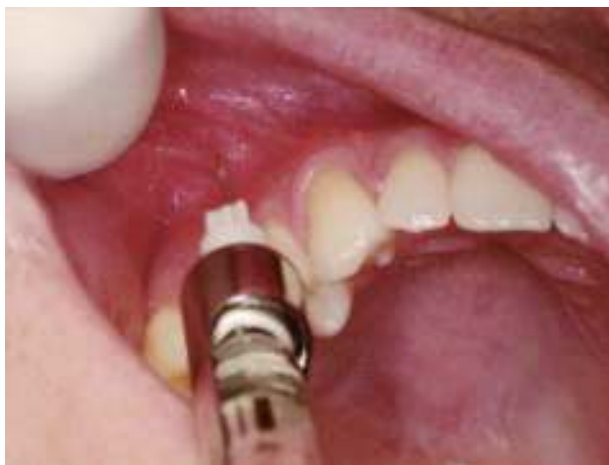- iv. As your finger continues inferiorly, a concavity is felt; this is the infraorbital foramen.
 - v. While applying pressure, feel the outlines of the infraorbital foramen at this site. The patient senses a mild soreness when the foramen is palpated as the infraorbital nerve is pressed against bone.
- e. Maintain your finger on the foramen or mark the skin at the site (Fig. 13.20).
- f. Retract the lip, pulling the tissues in the mucobuccal fold taut and increasing visibility. Sterile gauze (2- × 2-inches) placed beneath your gloved finger aids in retraction of the lip during the ASA injection. If possible, use a mouth mirror to minimize the risk of accidental needlestick injury to the administrator.
- g. Insert the needle into the height of the mucobuccal fold over the first premolar with the bevel facing bone (Fig. 13.21).
- h. Orient the syringe toward the infraorbital foramen.
 - i. The needle should be held parallel to the long axis of the tooth as it is advanced, to avoid premature contact with bone (Fig. 13.22).
- j. Advance the needle slowly until bone is gently contacted:
 - i. The point of contact should be the upper rim of the infraorbital foramen.
 - ii. The general depth of needle penetration is 16 mm for an adult of average height (equivalent to about half the length of a long needle).
 - iii. The depth of penetration differs, of course. In a patient with a high (deep) mucobuccal fold or a low infraorbital foramen, less tissue penetration is necessary than in a patient with a shallow mucobuccal fold or a high infraorbital foramen.
 - iv. A preinjection approximation of the depth of penetration can be made by placing one finger on the



• **Fig. 13.19** (A) Palpate the infraorbital notch. (B) Location of the infraorbital foramen in relation to the infraorbital notch.



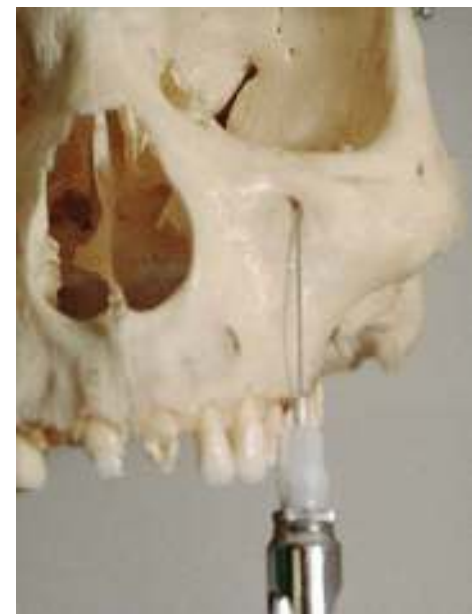• **Fig. 13.20** Using a finger over the foramen, lift the lip, and hold the tissues in the mucobuccal fold taut.



• **Fig. 13.21** Insert the needle for anterior superior alveolar nerve block in the mucobuccal fold over the maxillary first premolar.

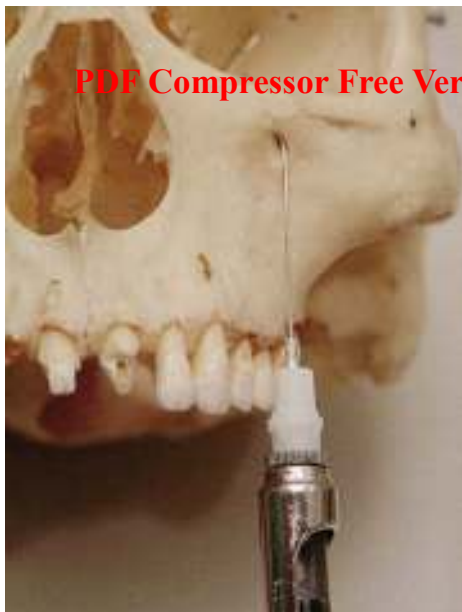infraorbital foramen and another on the injection site in the mucobuccal fold and estimating the distance between them.

- k. Before injecting the anesthetic solution, check for:
 - i. Depth of needle penetration (adequate to reach the foramen).



• **Fig. 13.22** Advance the needle parallel to the long axis of the tooth to preclude prematurely contacting bone. Note how the bone of the maxilla becomes concave between the root eminence and the infraorbital foramen (note the shadow).

- ii. Any lateral deviation of the needle from the infraorbital foramen (correct this before injecting solution).
- iii. Orientation of the bevel (facing bone).
- l. Position the needle tip during injection with the bevel facing into the infraorbital foramen and the needle tip touching the roof of the foramen (**Fig. 13.23**).
- m. Aspirate in two planes.
- n. Slowly deposit 0.9 to 1.2 mL (over 30 to 40 seconds). Little or no swelling should be visible as the solution is deposited. If the needle tip is properly inserted at the opening of the foramen, solution is directed toward the foramen.
 - i. The administrator is able to “feel” the anesthetic solution as it is deposited beneath the finger on the foramen if the needle tip is in the correct position. At the conclusion of the injection, the foramen should no longer be palpable (because of the volume of anesthetic in this position).



• **Fig. 13.23** Position of the needle tip before deposition of local anesthetic at the infraorbital foramen.

At this point the infraorbital nerve block (providing anesthesia of the soft tissues on the anterior portion of the face and the lateral aspect of the nose) is complete. To transform it into the ASA nerve block (providing anesthesia of the teeth and their supporting structures), do the following:

1. Maintain firm pressure with your finger over the injection site both during the injection and for at least 1 minute after the injection (to increase the diffusion of local anesthetic solution into the infraorbital foramen).
2. Withdraw the syringe slowly and immediately make the needle safe.
3. Maintain direct finger pressure over the injection site for a minimum of 1 minute, preferably 2 minutes, after injection.
4. Wait a minimum of 3 to 5 minutes after completion of the injection before commencing the dental procedure.

Signs and Symptoms

1. Subjective: tingling and numbness of the lower eyelid, side of the nose, and upper lip indicate anesthesia of the infraorbital nerve, not the ASA or MSA nerve (soft tissue anesthesia develops almost instantly as the anesthetic is being administered).
2. Subjective and objective: numbness in the teeth and soft tissues along the distribution of the ASA and MSA nerves (developing within 3 to 5 minutes if pressure is maintained over the injection site).
3. Objective: use of a freezing spray (e.g., Endo-Ice) or an EPT with no response from the tooth with maximal EPT output (80/80).
4. Absence of pain during treatment.

Safety Features

1. Needle contact with bone at the roof of the infraorbital foramen prevents inadvertent overinsertion and possible puncture of the orbit.

2. A finger positioned over the infraorbital foramen helps direct the needle toward the foramen:
 - a. The needle should not be palpable. If it is felt, then its path is too superficial (away from the bone). If this occurs, withdraw the needle slightly and redirect it toward the target area.
 - b. In most patients it is not possible to palpate the needle through soft tissues over the foramen unless it is too superficial. However, in some patients with less well-developed facial musculature, a properly positioned needle may be palpable.

Precautions

1. For pain on insertion of the needle and tearing of the periosteum, reinsert the needle in a more lateral (away from bone) position, or deposit solution as the needle advances through soft tissue.
2. To prevent overinsertion of the needle, estimate the depth of penetration before injection (review the procedure), and exert finger pressure over the infraorbital foramen.
 - a. Overinsertion is unlikely because of the rim of bone that forms the superior rim of the infraorbital foramen. The needle tip contacts this rim.

Failures of Anesthesia

1. Needle contacting bone below (inferior to) the infraorbital foramen: Anesthesia of the lower eyelid, lateral side of the nose, and upper lip may develop with little or no dental anesthesia; a bolus of solution may be felt beneath the skin in the area of deposition, which lies at a distance from the infraorbital foramen (which is still palpable after the local anesthetic solution has been injected). These are, by far, the most common causes of anesthetic failure within the distribution of the ASA nerve. In essence, a failed ASA is a suprapariosteal injection over the first premolar. To correct this:
 - a. Keep the needle in line with the infraorbital foramen during penetration. Do not direct the needle toward bone.
 - b. Estimate the depth of penetration before injecting anesthetic.
2. Needle deviation medial or lateral to the infraorbital foramen. To correct this:
 - a. Direct the needle toward the foramen immediately after inserting it and before advancing it through the tissue.
 - b. Recheck needle placement before aspirating and depositing the anesthetic solution.

Complications

Hematoma (rare) may develop across the lower eyelid and the tissues between it and the infraorbital foramen. To manage this, apply pressure on the soft tissue over the foramen for 2 to 3 minutes. Hematoma is extremely rare because pressure is routinely applied to the injection site both during and after administration of the ASA nerve block.

Palatal Anesthesia

Anesthesia of the hard palate is necessary for dental procedures involving manipulation of palatal soft or hard tissues.

For many dental patients, palatal injections are a very traumatic experience. For many dentists, administration of palatal anesthesia is a traumatic experience for their patients they perform in dentistry.³ Indeed, many dentists and dental hygienists advise their patients that they expect them to feel pain (dental professionals usually use the term *discomfort* rather than *pain* when describing painful procedures) during palatal injections! Forewarning the patient about procedural pain permits the patient to become more prepared psychologically (“psych themselves up”) and relieves the administrator of responsibility when the pain occurs. When the patient acknowledges the existence of pain, the administrator can console the patient with a shrug of the shoulders and a kind word, once again confirming to both the patient and the administrator that palatal injections always hurt.

However, palatal anesthesia can be achieved atraumatically. At best, patients are unaware of the needle penetration of soft tissues and deposition of the local anesthetic solution (they will not even feel it). At worst, when the following techniques are adhered to, patients state that although they still were somewhat uncomfortable, this palatal injection was the least painful they had ever received.

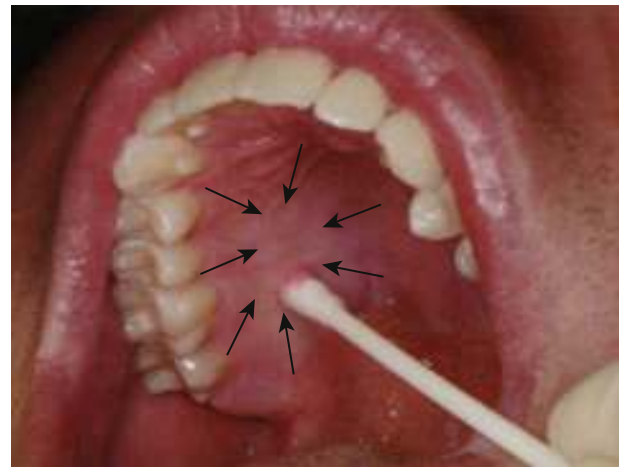With the introduction of computer-controlled local anesthetic delivery (C-CLAD) systems (The Wand, Comfort Control Syringe, and STA Single Tooth Anesthesia System [see Chapter 5]), delivery of atraumatic palatal injections has become even more simplified.⁴⁻⁷

The steps in the atraumatic administration of palatal anesthesia are:

1. Provide adequate topical anesthesia at the site of needle penetration.
2. Use pressure anesthesia at the site both before and during needle insertion and the deposition of solution.
3. Maintain control over the needle.
4. Deposit the anesthetic solution slowly.
5. Trust in yourself...that you can complete the procedure atraumatically.

Adequate topical anesthesia at the injection site can be provided by allowing topical anesthetic to remain in contact with the soft tissues for at least 2 minutes. The palate is the one area in the mouth where the cotton swab must be held in position by the administrator the entire time.

Pressure anesthesia can be produced at the site of injection by application of considerable pressure to tissues adjacent to the injection site with a firm object, such as the cotton applicator stick previously used to apply the topical anesthetic. Other objects, such as the handle of a mouth mirror, are used by some, but because these objects are metal or plastic, they are more likely to hurt the patient. The goal is to produce anesthesia of the soft tissues through use of the gate control theory of pain.⁸ The applicator stick should be pressed firmly enough to produce ischemia (blanching) of the normally pink tissues at the penetration site and a feeling of intense pressure (dull and tolerable, not sharp and painful) (Fig. 13.24). Pressure anesthesia should be maintained during penetration of the soft tissues with the needle and must be maintained throughout the time the needle remains in the palatal soft tissues.



• Fig. 13.24 Note ischemia (arrows) of palatal tissues produced by pressure from the applicator stick.

Control over the needle is probably of greater importance in palatal anesthesia than in other intraoral injections. To achieve this control, the administrator must secure a firm hand rest. Several positions are illustrated in Chapter 11. When palatal anesthesia is administered, it is possible on occasion to stabilize the needle with both hands (Fig. 13.25). Perfection of this technique is attained only with experience.

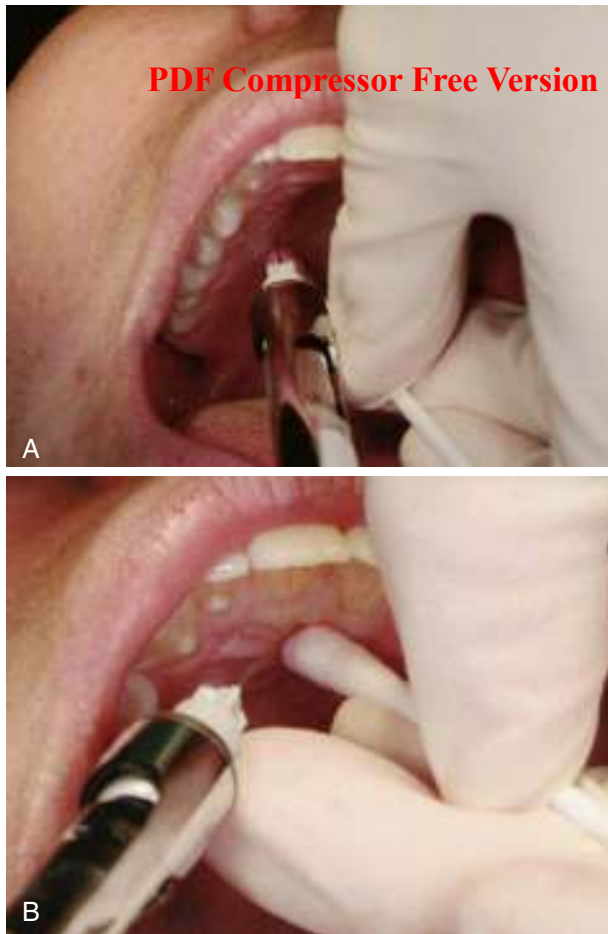
A 27-gauge short needle is recommended for palatal injection techniques because patients are unable to distinguish the “feel” between a 27- and a 30-gauge needle.⁹

Slow deposition of the local anesthetic is important in all injection techniques, not only as a safety feature but also as a means of providing an atraumatic injection. Because of the density of the palatal soft tissues and their firm adherence to underlying bone, slow deposition is of even greater importance here. Rapid injection of the solution produces high tissue pressure, which tears the palatal soft tissues and leads to both pain on injection and localized soreness when the anesthetic actions are terminated. Slow injection of the local anesthetic is not uncomfortable for the patient.

Probably the most important factor in providing an atraumatic palatal injection is the belief by the administrator that it can be done painlessly; from this belief, special care is then taken to minimize discomfort to the patient; this generally results in a more comfortable palatal injection.

Better yet is the ability to achieve a degree of palatal soft tissue anesthesia without the need for injection. The introduction in 2016 of an intranasal local anesthetic mist (3% tetracaine with 0.05% oxymetazoline, Kovanaze) provides a degree of palatal soft tissue anesthesia in the region from the second premolar to the opposite second premolar when administered bilaterally.¹⁰ The intranasal local anesthetic mist is reviewed in depth in Chapter 19

Five palatal injections are described. Three—the anterior (or greater) palatine nerve block, providing anesthesia of the posterior portions of the hard palate; the nasopalatine nerve block, producing anesthesia of the anterior hard palate; and local infiltration of the hard palate—are used primarily to



• **Fig. 13.25** Stabilization of the needle for (A) greater palatine and (B) nasopalatine nerve block. With both injections, the barrel of the syringe should rest against the patient's lower lip.

achieve soft tissue anesthesia and hemostasis before surgical procedures. None provide any pulpal anesthesia of the maxillary teeth. The recently introduced AMSA and P-ASA techniques provide extensive areas of pulpal and palatal anesthesia.^{5,6,11}

Greater Palatine Nerve Block

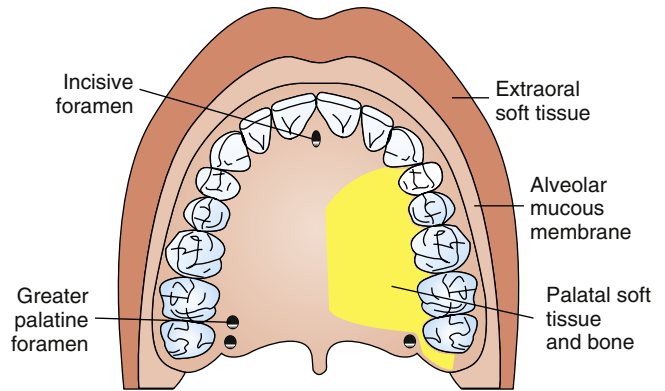
The greater palatine nerve block is useful for dental procedures involving the palatal soft tissues distal to the canine. Minimum volumes of solution (0.45 to 0.6 mL) provide profound hard and soft tissue anesthesia. Although potentially traumatic, the greater palatine nerve block is less so than the nasopalatine nerve block because tissues surrounding the greater palatine foramen are not as firmly adherent to bone and therefore are better able to accommodate the recommended volume of anesthetic solution.

Other Common Name

Anterior palatine nerve block.

Nerve Anesthetized

Greater palatine nerve.



• **Fig. 13.26** Area anesthetized by a greater palatine nerve block.

Areas Anesthetized

The posterior portion of the hard palate and its overlying soft tissues, anteriorly as far as the first premolar and medially to the midline (Fig. 13.26).

Indications

1. When palatal soft tissue anesthesia is necessary for restorative therapy on more than two teeth (e.g., with subgingival restorations, with insertion of matrix bands subgingivally)
2. For pain control during periodontal or oral surgical procedures involving the palatal soft and hard tissues

Contraindications

1. Inflammation or infection at the injection site
2. Smaller areas of therapy (one or two teeth)

Advantages

1. Minimizes needle penetrations and volume of solution
2. Minimizes patient discomfort

Disadvantages

1. No hemostasis except in the immediate area of injection
2. Potentially traumatic

Positive Aspiration

Less than 1%.

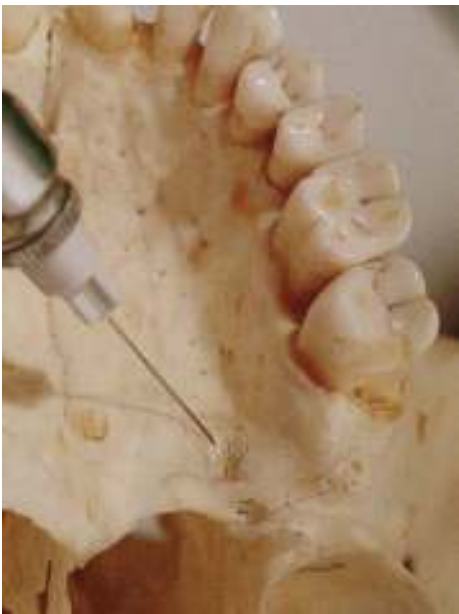Alternatives

1. Local infiltration into specific regions
2. Maxillary nerve block

Technique

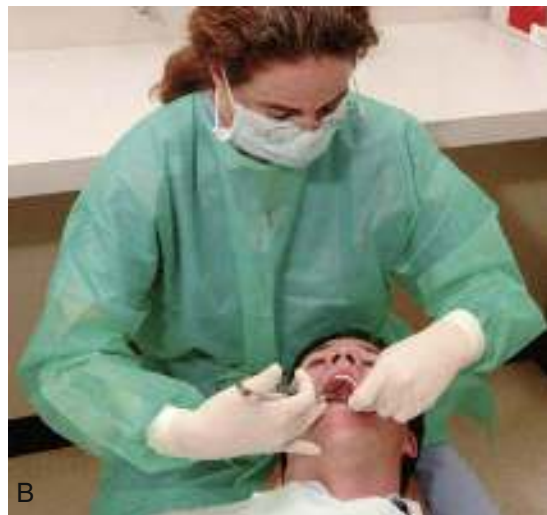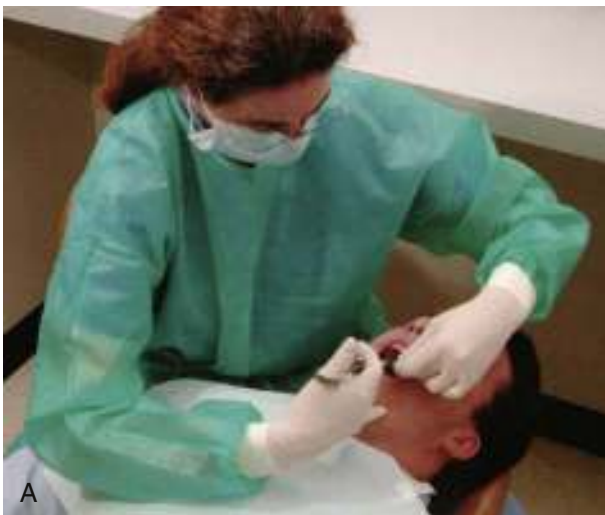1. A 27-gauge short needle is recommended.
2. Area of insertion: soft tissue slightly anterior to the greater palatine foramen.
3. Target area: greater (anterior) palatine nerve as it passes anteriorly between soft tissues and bone of the hard palate (Fig. 13.27).
4. Landmarks: greater palatine foramen and junction of the maxillary alveolar process and palatine bone.

5. Path of insertion: advance the syringe from the opposite side of the mouth at a right angle to the target area.
6. Orientation of the bevel and the point of the needle.
7. Procedure:
 - a. Assume the correct position (Fig. 13.28):
 - i. For a right greater palatine nerve block, a right-handed administrator should sit facing the patient at the 7 or 8 o'clock position.
 - ii. For a left greater palatine nerve block, a right-handed administrator should sit facing in the same direction as the patient at the 11 o'clock position.
 - b. Ask the patient, who is in a supine position (Fig. 13.29A), to do the following:
 - i. Open the mouth wide.
 - ii. Extend the neck.
 - iii. Turn the head to the left or right (for improved visibility).



• Fig. 13.27 Target area for a greater palatine nerve block.

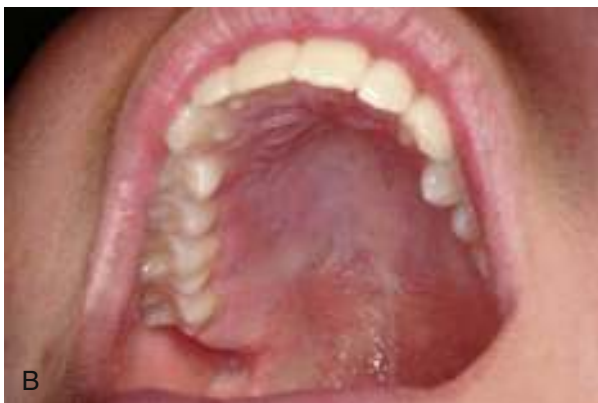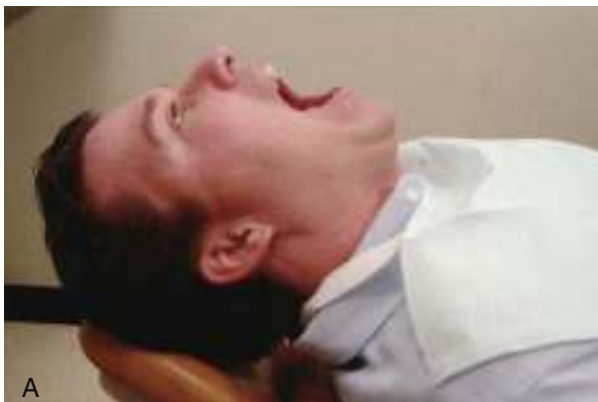- c. Locate the greater palatine foramen (see Fig. 13.29B and Table 13.2):
 - i. Place a cotton swab at the junction of the maxillary alveolar process and the hard palate.
 - ii. Start in the region of the maxillary first molar by pressing firmly into the tissues with the swab. While maintaining pressure, continue to move the swab posteriorly.
 - iii. The swab “falls” into the depression created by the greater palatine foramen (Fig. 13.30).
 - iv. The foramen is most frequently located distal to the maxillary second molar, but it may be located anterior or posterior to its usual position. (See “Maxillary Nerve Block,” p. 233).
- d. Prepare the tissue at the injection site, just 1 to 2 mm anterior to the greater palatine foramen:
 - i. Clean and dry it with sterile gauze.
 - ii. Apply topical antiseptic (optional).
 - iii. Apply topical anesthetic for 2 minutes.
- e. After 2 minutes of topical anesthetic application, move the swab posteriorly so it is directly over the greater palatine foramen.
 - i. Apply considerable pressure at the area of the foramen with the swab in the left hand (if right-handed).
 - ii. Note the ischemia (whitening of the soft tissues) at the injection site.
 - iii. Apply pressure for a minimum of 30 seconds, and while doing this proceed to the following steps.
- f. Direct the syringe into the mouth from the opposite side with the needle approaching the injection site at a right angle (Fig. 13.31).
- g. Place the bevel (not the point) of the needle gently against the blanched (ischemic) soft tissue at the injection site. It must be well stabilized to prevent accidental penetration of the tissues.
- h. With the bevel lying against the tissue:
 - i. Apply enough pressure to bow the needle slightly.
 - ii. Deposit a small volume of anesthetic. The solution is forced against the mucous membrane, and a droplet forms (Fig. 13.32).
- i. Straighten the needle and permit the bevel to penetrate mucosa.



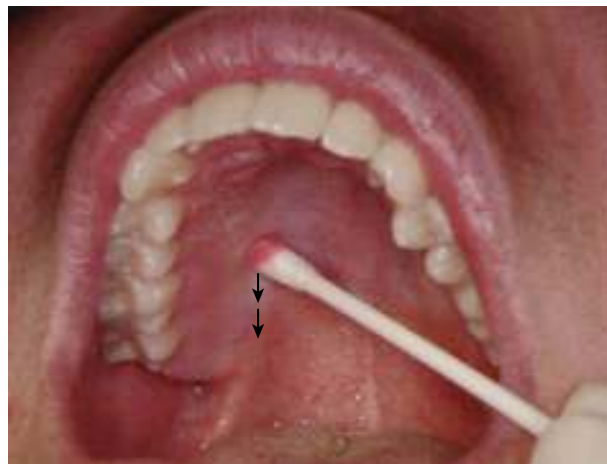• Fig. 13.28 Position of the administrator for (A) right and (B) left greater palatine nerve block.

- i. Continue to deposit small volumes of anesthetic throughout the procedure.
- ii. Ischemia spreads into adjacent tissue as the anesthetic (usually with a vasoconstrictor) is deposited (Figs. 13.33 and 13.34).
- j. Continue to apply pressure anesthesia throughout the deposition of the anesthetic solution (see Fig. 13.33). Ischemia spreads as the vasoconstrictor decreases tissue perfusion.
- k. Slowly advance the needle until palatine bone is gently contacted.
 - i. The depth of penetration is usually about 5 mm.

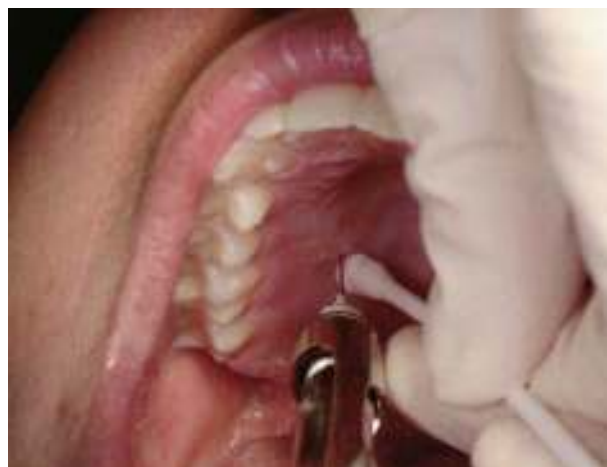- ii. Continue to deposit small volumes of anesthetic. As the tissue is entered, a slight increase in resistance to the deposition of solution may be noted; this is entirely normal in the greater palatine nerve block.
 - l. Aspirate in two planes.
 - m. If negative, slowly deposit (30 second minimum) not more than one-fourth to one-third of a cartridge (0.45 to 0.6 mL).
 - n. Withdraw the syringe.
 - o. Make the needle safe.
 - p. Wait 2 to 3 minutes before commencing the procedure.



• Fig. 13.29 (A) Patient position for a greater palatine nerve block. (B) Administrator's view of the hard palate when the patient is properly positioned.



• Fig. 13.30 A cotton swab is pressed against the hard palate at the junction of the maxillary alveolar process and palatal bone. The swab is slowly moved distally (arrows) until a depression in the tissue is felt. This is the greater (anterior) palatine foramen.



• Fig. 13.31 Note the angle of needle entry into the mouth. The insertion is into ischemic tissues slightly anterior to the applicator stick. The barrel of the syringe is stabilized by the corner of the mouth and the teeth.

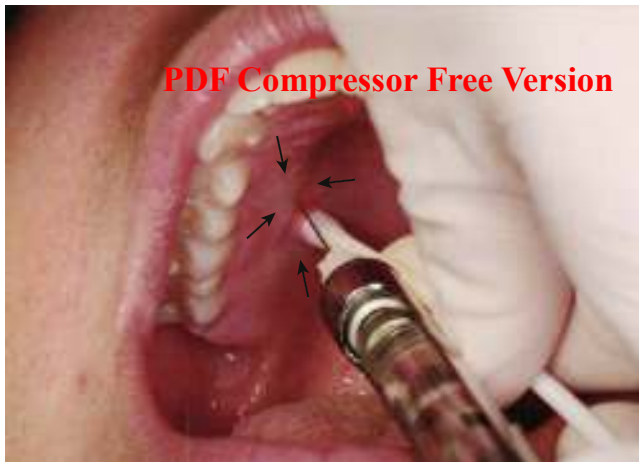TABLE 13.2 Location of the Greater Palatine Foramen^a

Location	No.	Percentage
Anterior half second molar	0	0
Posterior half second molar	63	39.87
Anterior half third molar	80	50.63
Posterior half third molar	15	9.49

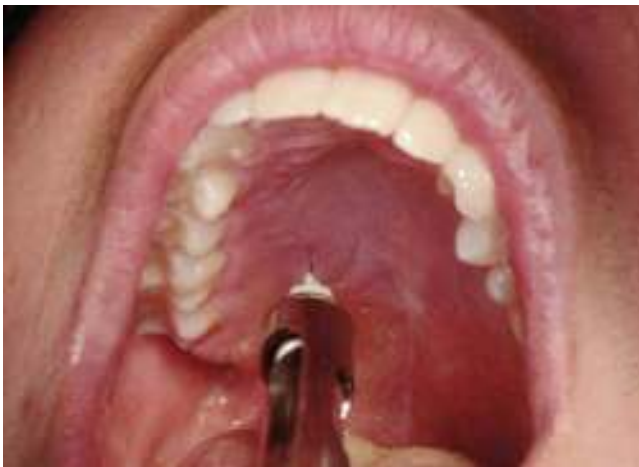^aMeasurements from 158 skulls with the maxillary second and third molars present.
 From Malamed SF, Trieger N. Intraoral maxillary nerve block: an anatomical and clinical study. *Anesth Prog.* 1983;30:44–48.



• Fig. 13.32 Prepuncture technique: bevel of needle placed on soft tissue; pressure exerted by cotton applicator stick; local anesthetic solution deposited before needle enters tissues.



• **Fig. 13.33** Note the spread of ischemia (*arrows*) as the anesthetic is deposited.



• **Fig. 13.34** The cotton swab is removed when the deposition of solution ceases.

Signs and Symptoms

1. Subjective: numbness in the posterior portion of the palate
2. Objective: no pain during dental therapy

Safety Features

1. Contact with bone
2. Aspiration

Precautions

Do not enter the greater palatine canal. Although this is not hazardous, there is no reason to enter the canal for this technique to be successful.

Failures of Anesthesia

1. The greater palatine nerve block is not technically difficult to administer; failures are rare. The incidence of success is well above 95%.
2. If local anesthetic is deposited too far anterior to the foramen, adequate soft tissue anesthesia may not occur in the palatal tissues posterior to the site of injection (partial success).

3. Anesthesia on the palate in the area of the maxillary first premolar may prove inadequate because of overlapping fibers from the nasopalatine nerve (partial success).
 - a. To correct this, local infiltration may be necessary as a supplement in the area of inadequate anesthesia.

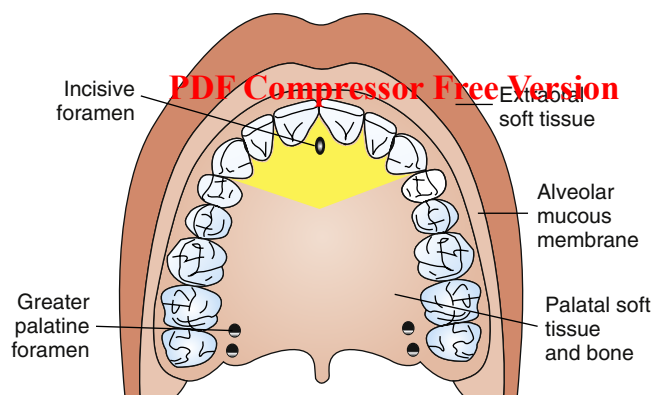
Complications

1. Few of significance.
2. Ischemia and necrosis of soft tissues when highly concentrated vasoconstrictor solution (e.g., 1:50,000) is used repeatedly for hemostasis over a prolonged period.
 - a. Norepinephrine should never be used for hemostasis on the palatal soft tissues (norepinephrine is not available in dental local anesthetics in the United States or Canada).
3. Hematoma is possible but rare because of the density and firm adherence of palatal tissues to underlying bone.
4. Some patients may be uncomfortable if their soft palate becomes anesthetized; this is a distinct possibility when the middle palatine nerve exits near the injection site.

Nasopalatine Nerve Block

Nasopalatine nerve block is an invaluable technique for palatal pain control in that, with administration of a minimum volume of anesthetic solution (maximally one-quarter of a cartridge), a wide area of palatal soft tissue anesthesia is achieved, thereby minimizing the need for multiple palatal injections. Unfortunately, the nasopalatine nerve block has the distinction of being a potentially highly traumatic (e.g., painful) injection. The intranasal local anesthetic mist provides excellent anesthesia of the nasopalatine area, obviating the need for injection (see [Chapter 20](#)). With no other injection technique is the need for strict adherence to the protocol of atraumatic injection more important than with the nasopalatine nerve block. Two approaches to this injection are presented. Readers should become familiar with both techniques and then use the one with which they feel more comfortable (e.g., that works best in their hands).

The first approach involves only one tissue penetration, lateral to the incisive papilla on the palatal aspect of the maxillary central incisors. The soft tissue in this area is dense, firmly adherent to underlying bone, and quite sensitive; these three factors combine to increase patient discomfort during injection. The second approach was recommended by a number of readers of earlier editions of this book. It involves three needle punctures but, when performed properly, is significantly less traumatic than the more direct one-puncture technique. In it, the labial soft tissues between maxillary central incisors are anesthetized (injection 1), and then the needle is directed from the labial aspect through the interproximal papilla between the central incisors toward the incisive papilla on the palate to anesthetize the superficial tissues in this area (injection 2). A third injection, directly into the now partially anesthetized palatal soft tissues overlying the nasopalatine nerve, is necessary. Although the single-needle puncture technique may be preferred whenever possible, the second approach can produce effective nasopalatine anesthesia with a minimum of discomfort.



• Fig. 13.35 Area anesthetized by a nasopalatine nerve block.

Other Common Names

Incisive nerve block (thus confusion with the “other” incisive nerve block in the mandible that is described in Chapter 14), sphenopalatine nerve block.

Nerves Anesthetized

Nasopalatine nerves bilaterally.

Areas Anesthetized

Anterior portion of the hard palate (soft and hard tissues) bilaterally from the mesial aspect of the right first premolar to the mesial aspect of the left first premolar (Fig. 13.35).

Indications

1. When palatal soft tissue anesthesia is necessary for restorative treatment on more than two teeth (e.g., subgingival restorations, insertion of matrix bands subgingivally)
2. For pain control during periodontal or oral surgical procedures involving palatal soft and hard tissues

Contraindications

1. Inflammation or infection at the injection site
2. Smaller area of therapy (one or two teeth)

Advantages

1. Minimizes needle penetrations and volume of solution
2. Minimal patient discomfort from multiple needle penetrations

Disadvantages

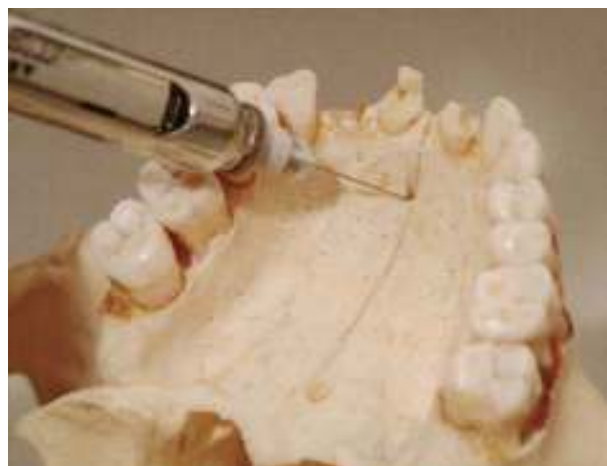1. No hemostasis except in the immediate area of injection.
2. Potentially the most traumatic intraoral injection; however, the protocol for an atraumatic injection or use of a C-CLAD system or a buffered local anesthetic solution can minimize or entirely eliminate discomfort.

Positive Aspiration

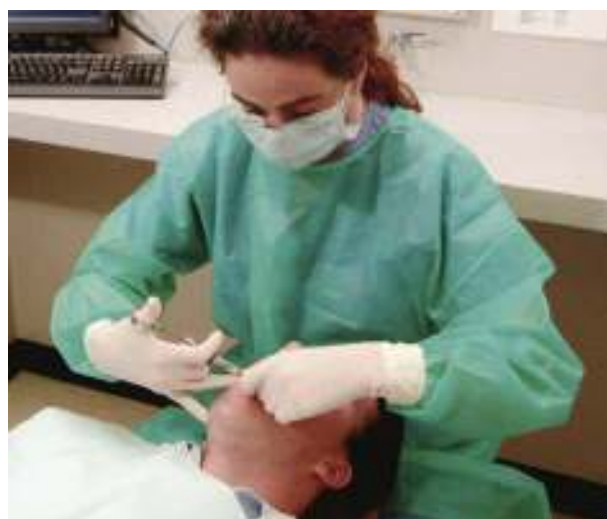Less than 1%.

Alternatives

1. Local infiltration into specific regions
2. Maxillary nerve block (unilateral only)



• Fig. 13.36 Target area for a nasopalatine nerve block.

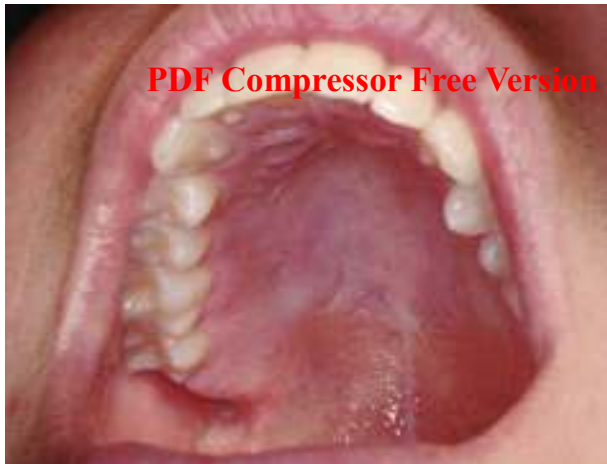

• Fig. 13.37 Position of the administrator for a nasopalatine nerve block.

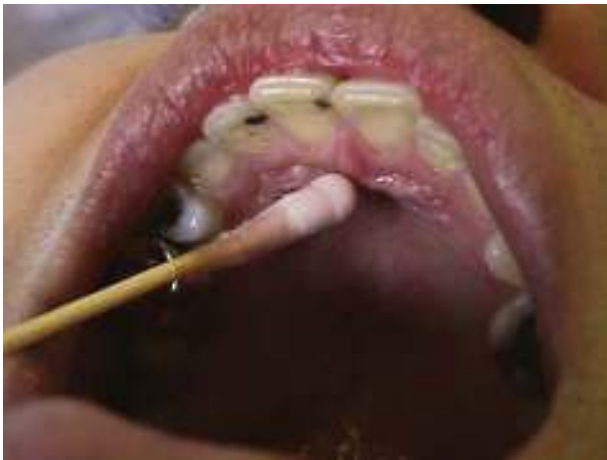3. AMSA nerve block (unilateral only)
4. Intra nasal local anesthetic mist (see Chapter 20)

Technique: Single-Needle Penetration of the Palate

1. A 27-gauge short needle is recommended.
2. Area of insertion: palatal mucosa just lateral to the incisive papilla (located in the midline behind the central incisors); the tissue here is more sensitive than other palatal mucosa.
3. Target area: incisive foramen, beneath the incisive papilla (Fig. 13.36).
4. Landmarks: central incisors and incisive papilla.
5. Path of insertion: approach the injection site at a 45-degree angle toward the incisive papilla.
6. Orientation of the bevel: toward the palatal soft tissues (review the procedure for the basic palatal injection).
7. Procedure:
 - a. Sit at the 9 or 10 o'clock position facing in the same direction as the patient (Fig. 13.37).
 - b. Request the patient to do the following:
 - i. Open the mouth wide.
 - ii. Extend the neck.

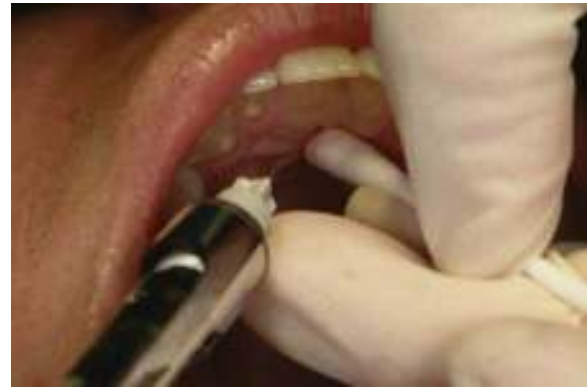

• **Fig. 13.38** Palate when the patient is positioned properly.



• **Fig. 13.39** Topical anesthetic is applied lateral to the incisive papilla for 2 minutes, and then pressure is applied directly to the incisive papilla.

- iii. Turn the head to the left or right, as needed, for improved visibility (Fig. 13.38).
- c. Prepare the tissue just lateral to the incisive papilla (Fig. 13.39):
 - i. Clean and dry it with sterile gauze.
 - ii. Apply topical antiseptic (optional).
 - iii. Apply topical anesthetic for 2 minutes.
- d. After 2 minutes of topical anesthetic application, move the swab directly onto the incisive papilla (see Figs. 13.39 and 13.40).
 - i. With the swab in your left hand (if right-handed), apply pressure to the area of the papilla.
 - ii. Note ischemia at the injection site.
- e. Place the bevel against the ischemic soft tissues at the injection site. The needle must be well stabilized to prevent accidental penetration of tissues (see Fig. 13.40).
- f. With the bevel lying against the tissue:
 - i. Apply enough pressure to bow the needle slightly.
 - ii. Deposit a small volume of anesthetic. The solution will be forced against the mucous membrane.
- g. Straighten the needle and permit the bevel to penetrate the mucosa.
 - i. Continue to deposit small volumes of anesthetic throughout the procedure.



• **Fig. 13.40** Pressure is maintained until the deposition of solution is completed. Needle penetration is just lateral to the incisive papilla.

- ii. Observe ischemia spreading into adjacent tissues as solution is deposited.
- h. Continue to apply pressure with the cotton applicator stick while injecting the anesthetic.
- i. Slowly advance the needle toward the incisive foramen until bone is gently contacted (see Fig. 13.36).
 - i. The depth of penetration is normally not greater than 5 mm.
 - ii. Deposit small volumes of anesthetic while advancing the needle. As the tissue is entered, resistance to the deposition of solution is significantly increased; this is normal with the nasopalatine nerve block.
- j. Withdraw the needle 1 mm (to prevent subperiosteal injection). The bevel now lies over the center of the incisive foramen.
- k. Aspirate in two planes.
 - l. If negative, slowly deposit (minimum of 15 to 30 seconds) not more than one-fourth of a cartridge (0.45 mL).
 - i. In some patients it is difficult to deposit 0.45 mL of anesthetic solution in this injection. Injection of anesthetic can cease when the area of ischemia noted at the injection site has expanded from that produced by the application of pressure alone.
- m. Slowly withdraw the syringe.
- n. Make the needle safe.
- o. Wait 2 to 3 minutes before commencing the dental procedure.

Signs and Symptoms

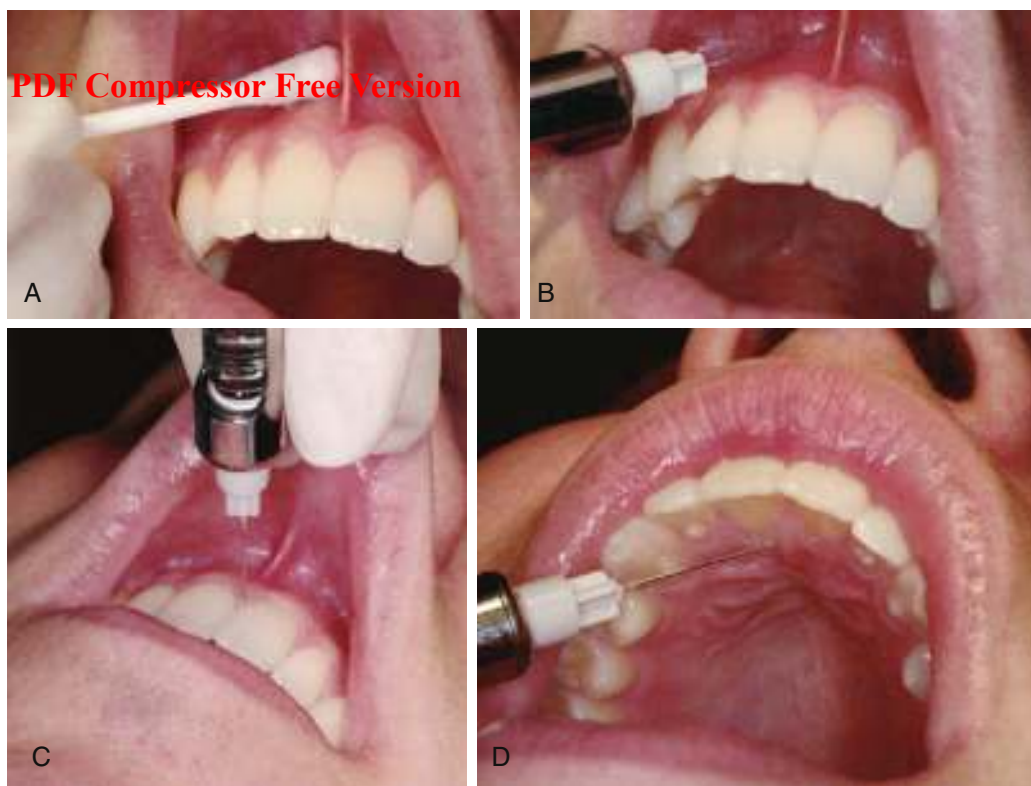
1. Subjective: numbness in the anterior portion of the palate
2. Objective: no pain during dental therapy

Safety Features

1. Contact with bone
2. Aspiration

Precautions

1. Against pain:
 - a. Do not insert the needle directly into the incisive papilla (quite painful).
 - b. Do not deposit solution too rapidly.
 - c. Do not deposit too much solution.



• **Fig. 13.41** (A) Topical anesthetic is applied to the mucosa of the frenum. (B) First injection, into the labial frenum. (C) Second injection, into the interdental papilla between the central incisors. (D) Third injection, insert needle lateral to the incisive papilla to provide the desired area of anesthesia.

2. Against infection:

- a. If the needle is advanced more than 5 mm into the incisive canal and the floor of the nose is entered accidentally, infection can result. There is no reason for the needle to enter the incisive canal during a nasopalatine nerve block.

Failures of Anesthesia

1. Highly successful injection (>95% incidence of success).
2. Unilateral anesthesia:
 - a. If solution is deposited on one side of the incisive canal, unilateral anesthesia may develop.
 - b. To correct this, reinsert the needle into the already anesthetized tissue and reinject solution into the unanesthetized area.
3. Inadequate palatal soft tissue anesthesia in the area of the maxillary canine and first premolar:
 - a. If fibers from the greater palatine nerve overlap those of the nasopalatine nerve, anesthesia of the soft tissues palatal to the canine and the first premolar could be inadequate.
 - b. To correct this, local infiltration may be necessary as a supplement in the area inadequately anesthetized.

Complications

1. Few of significance.
2. Hematoma is possible but extremely rare because of the density and firm adherence of palatal soft tissues to bone.
3. Necrosis of soft tissues is possible when highly concentrated vasoconstrictor solution (e.g., 1:50,000

epinephrine) is used repeatedly for hemostasis over a prolonged period.

4. Because of the density of soft tissues, anesthetic solution may “squirt” back out the needle puncture site during administration or after needle withdrawal. (This is of no clinical significance. However, do not let it surprise you into uttering a statement such as “Whoops!” that might frighten the patient.)

Technique: Multiple Needle Penetrations

1. A 27-gauge short needle is recommended.
2. Areas of insertion:
 - a. Labial frenum in the midline between the maxillary central incisors (Fig. 13.41B).
 - b. Interdental papilla between the maxillary central incisors (see Fig. 13.41C).
 - c. If needed, palatal soft tissues lateral to the incisive papilla (see Fig. 13.41D).
3. Target area: incisive foramen, beneath the incisive papilla.
4. Landmarks: central incisors and incisive papilla.
5. Path of insertion:
 - a. First injection: infiltration into the labial frenum.
 - b. Second injection: needle held at a right angle to the interdental papilla.
 - c. Third injection: needle held at a 45-degree angle to the incisive papilla.
6. Orientation of the bevel:
 - a. First injection: bevel toward bone.
 - b. Second injection: bevel orientation not relevant.
 - c. Third injection: bevel orientation not relevant.

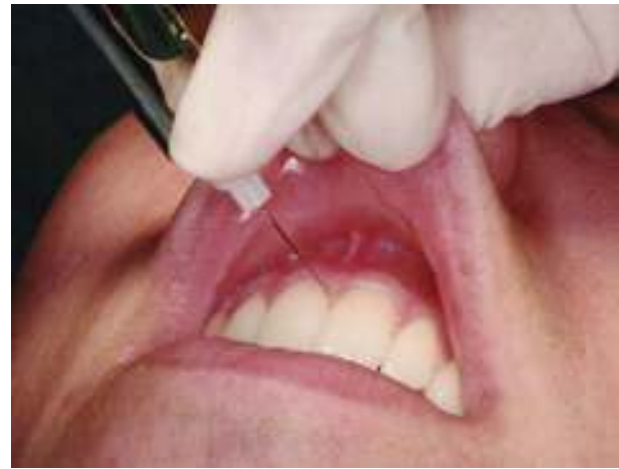7. Procedure:

a. *First injection:* infiltration of 0.3 mL into the labial frenum (see Fig. 13.41B).

- i. Prepare the tissue at the injection site:
 - a. Clean and dry it with sterile gauze.
 - b. Apply topical antiseptic (optional).
 - c. Apply topical anesthetic for 1 minute (Fig. 13.41A).
- ii. Retract the upper lip to stretch tissues and improve visibility (be careful not to overstretch the frenum). If possible use a mouth mirror to minimize the risk of accidental needlestick injury to the administrator.
- iii. Gently insert the needle into the frenum and deposit 0.3 mL of anesthetic in approximately 15 seconds. (The tissue may balloon as solution is injected. This is normal.)
- iv. Anesthesia of soft tissue develops immediately. The aim of this first injection is to anesthetize the interdental papilla between the two central incisors.

b. *Second injection:* penetration through the labial aspect of the papilla between the maxillary central incisors toward the incisive papilla (see Fig. 13.41C).

- i. Retract the upper lip gently to increase visibility (do not overstretch the labial frenum). If possible use a mouth mirror to minimize the risk of accidental needlestick injury to the administrator.
- ii. A right-handed administrator should sit at the 11 or 12 o'clock position facing in the same direction as the patient. Tilt the patient's head toward the right to provide a proper angle for needle penetration.
- iii. Holding the needle at a right angle to the interdental papilla, insert it into the papilla just above the level of crestal bone.
 - a. Direct it toward the incisive papilla (on the palatal side of the interdental papilla).
 - b. Soft tissues on the labial surface have been anesthetized by the first injection, so there is no discomfort. However, as the needle penetrates toward the unanesthetized palatal side, it is necessary to administer minute amounts of local anesthetic to prevent discomfort.
 - c. With the patient's head extended backward, you can see the ischemia produced by the local anesthetic and (on occasion) can see the needle tip as it nears the palatal aspect of the incisive papilla. Care must be taken to avoid the needle exiting through the papilla into the oral cavity on the palatal side.
- iv. Aspirate in two planes when ischemia is noted in the incisive papilla or when the needle tip becomes visible just beneath the tissue surface. If negative, administer no more than 0.3 mL of anesthetic solution in approximately 15 seconds. There is considerable resistance to the deposition of solution but no patient discomfort.
- v. Stabilization of the syringe in this second injection is somewhat awkward, but critical. Use of a finger from the other hand to stabilize the needle is recommended (Fig. 13.42). However, the syringe barrel must be held such that it remains within the patient's line of sight; this is potentially disconcerting to some patients.
- vi. Slowly withdraw the syringe.
- vii. Make the needle safe.



• Fig. 13.42 Use a finger of the opposite hand to stabilize the syringe during the second injection.

- viii. Anesthesia within the distribution of the right and left nasopalatine nerves usually develops in a minimum of 2 to 3 minutes.
- ix. If the area of clinically effective anesthesia proves to be less than adequate (as frequently happens), proceed to the third injection.
- c. *Third injection:*
 - i. Dry the tissue just lateral to the incisive papilla.
 - ii. Ask the patient to open the mouth wide.
 - iii. Extend the patient's neck.
 - iv. Place the needle into soft tissue adjacent to the (diamond-shaped) incisive papilla, aiming toward the most distal portion of the papilla.
 - v. Advance the needle until contact is made with bone.
 - vi. Withdraw the needle 1 mm to avoid subperiosteal injection.
 - vii. Aspirate in two planes.
 - viii. If negative, slowly deposit not more than 0.3 mL of anesthetic in approximately 15 seconds. *Note: Use of topical and pressure anesthesia is unnecessary in the second and third injections because the tissues being penetrated by the needle are already anesthetized (by the first and second injections, respectively).*
 - ix. Withdraw the syringe.
 - x. Make the needle safe.
 - xi. Wait a minimum of 2 to 3 minutes for the onset of anesthesia before beginning dental treatment.

Signs and Symptoms

1. Subjective: numbness of the upper lip (in the midline) and the anterior portion of the palate
2. Objective: no pain during dental therapy

Safety Features

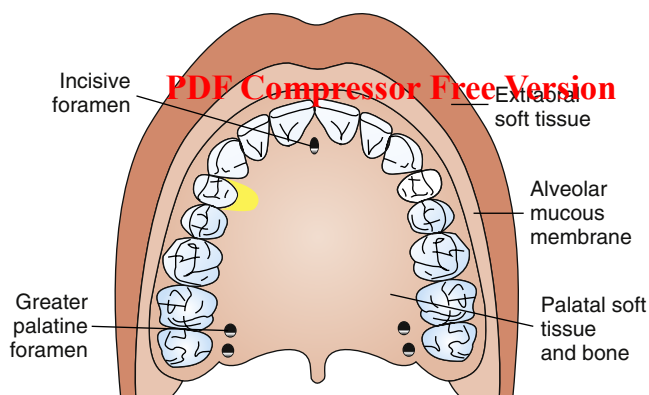
1. Aspiration
2. Contact with bone (third injection)

Advantage

Entirely or relatively atraumatic.

Disadvantages

1. Requires multiple injections (three)
2. Difficult to stabilize the syringe during the second injection



• **Fig. 13.43** Area anesthetized by a palatal infiltration.

3. Syringe barrel usually within the patient's line of sight during the second injection

Precautions

1. Against pain: If each injection is performed as recommended, the entire technique should be atraumatic.
2. Against infection: On the third injection, do not advance the needle into the incisive canal. With accidental penetration of the nasal floor, the risk of infection is increased.

Failures of Anesthesia

1. A highly successful (>95%) injection.
2. Inadequate anesthesia of palatal soft tissues around the canine and first premolar because of overlapping fibers from the greater palatine nerve.
 - a. To correct this, local infiltration may be necessary as a supplement in the area.

Complications

1. Few of significance.
2. Necrosis of soft tissues is possible when a highly concentrated vasoconstrictor solution (e.g., 1:50,000) is used for hemostasis over a prolonged period.
3. Interdental papillae between the maxillary incisors are sometimes tender for several days after injection.

Local Infiltration of the Palate

Other Common Names

None.

Nerves Anesthetized

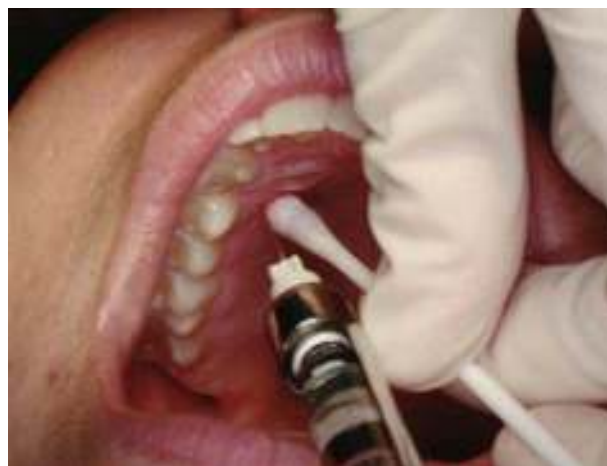Terminal branches of the nasopalatine and greater palatine nerves.

Areas Anesthetized

Soft tissues in the immediate vicinity of the injection (Fig. 13.43).

Indications

1. Primarily to achieve hemostasis during surgical procedures
2. Palatogingival pain control when limited areas of anesthesia are necessary for application of a rubber



• **Fig. 13.44** Area of insertion and target area for a palatal infiltration.

dam clamp, packing of retraction cord in the gingival sulcus, or operative procedures on not more than two teeth

Contraindications

1. Inflammation or infection at the injection site
2. Pain control in soft tissue areas involving more than two teeth

Advantages

1. Provides acceptable hemostasis when a vasoconstrictor is used
2. Provides a minimum area of numbness

Disadvantage

Potentially traumatic injection.

Positive Aspiration

Negligible.

Alternatives

1. For hemostasis: none
2. For pain control: nasopalatine or greater palatine nerve block, AMSA nerve block, maxillary nerve block

Technique

1. A 27-gauge short needle is recommended.
2. Area of insertion: the attached gingiva 5 to 10 mm from the free gingival margin (Fig. 13.44).
3. Target area: gingival tissues 5 to 10 mm from the free gingival margin.
4. Landmark: gingival tissue in the estimated center of the treatment area.
5. Pathway of insertion: approaching the injection site at a 45-degree angle.
6. Orientation of the bevel: toward palatal soft tissues.
7. Procedure:
 - a. A right-handed administrator should sit at the 10 o'clock position:
 - i. Face toward the patient for palatal infiltration on the right side.

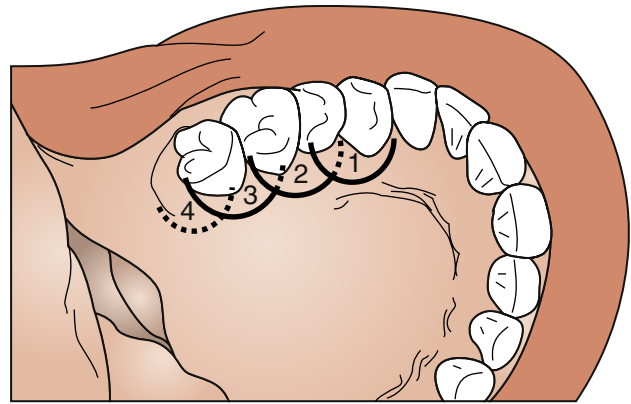
- ii. Face in the same direction as the patient for palatal infiltration on the left side.
- b. Ask the patient to do the following:
 - i. Open the mouth wide.
 - ii. Extend the neck.
 - iii. Turn the head to the left or right, as needed, for improved visibility.
- c. Prepare the tissue at the site of injection:
 - i. Clean and dry it with sterile gauze.
 - ii. Apply topical antiseptic (optional).
 - iii. Apply topical anesthetic for 2 minutes.
 - iv. After 2 minutes of topical anesthetic application, place the swab on the tissue immediately adjacent to the injection site.
 1. With the swab in your left hand (if right-handed), apply pressure to the palatal soft tissues.
 2. Observe the ischemia at the injection site.
- e. Place the bevel of the needle against the ischemic soft tissue at the injection site. The needle must be well stabilized to prevent accidental penetration of tissues.
- f. With the bevel lying against tissue:
 - i. Apply enough pressure to bow the needle slightly.
 - ii. Deposit a small volume of local anesthetic. The solution is forced against the mucous membrane, forming a droplet.
- g. Straighten the needle and permit the bevel to penetrate mucosa.
 - i. Continue to deposit small volumes of local anesthetic throughout this procedure.
 - ii. Ischemia of the tissues spreads as additional anesthetic is deposited. (When this injection is used for hemostasis, the vasoconstrictor in the local anesthetic produces intense ischemia of tissues.)
- h. Continue to apply pressure with the cotton applicator stick throughout the injection.
- i. Continue to advance the needle and deposit anesthetic until bone is gently contacted. Tissue thickness is only 3 to 5 mm in most patients.
- j. If hemostasis is the goal in this technique, continue to administer solution until ischemia encompasses the surgical site. In usual practice, 0.2 to 0.3 mL of solution is adequate.
- k. For hemostasis of larger surgical sites:
 - i. Remove the needle from the first injection site.
 - ii. Place it in the new injection site at the periphery of the previously anesthetized tissue (Fig. 13.45).
 - iii. Penetrate the tissues and deposit anesthetic as in step j. Use of topical anesthetic may be omitted for subsequent injections because the tissue penetrated is already anesthetized.
 - iv. Continue this overlapping procedure until adequate hemostasis develops over the entire surgical area.
 1. Withdraw the syringe.
- m. Make the needle safe.
- n. Commence the dental procedure immediately.

Signs and Symptoms

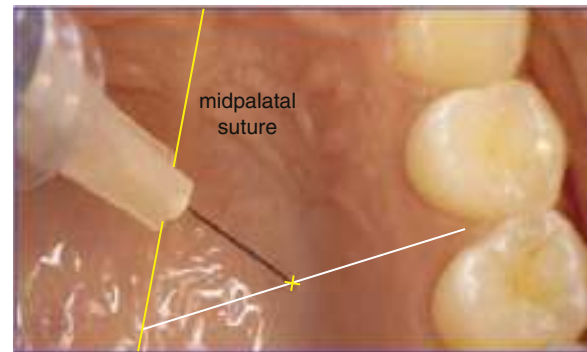
1. Subjective: numbness, ischemia of the palatal soft tissues
2. Objective: no pain during dental therapy

Safety Features

Anatomically safe area for injection.



• Fig. 13.45 Overlapping of sequential palatal infiltrations and needle penetration sites.



• Fig. 13.46 Location of injection site for anterior middle superior alveolar nerve block.

Precaution

Highly traumatic procedure if performed improperly.

Failure of Hemostasis

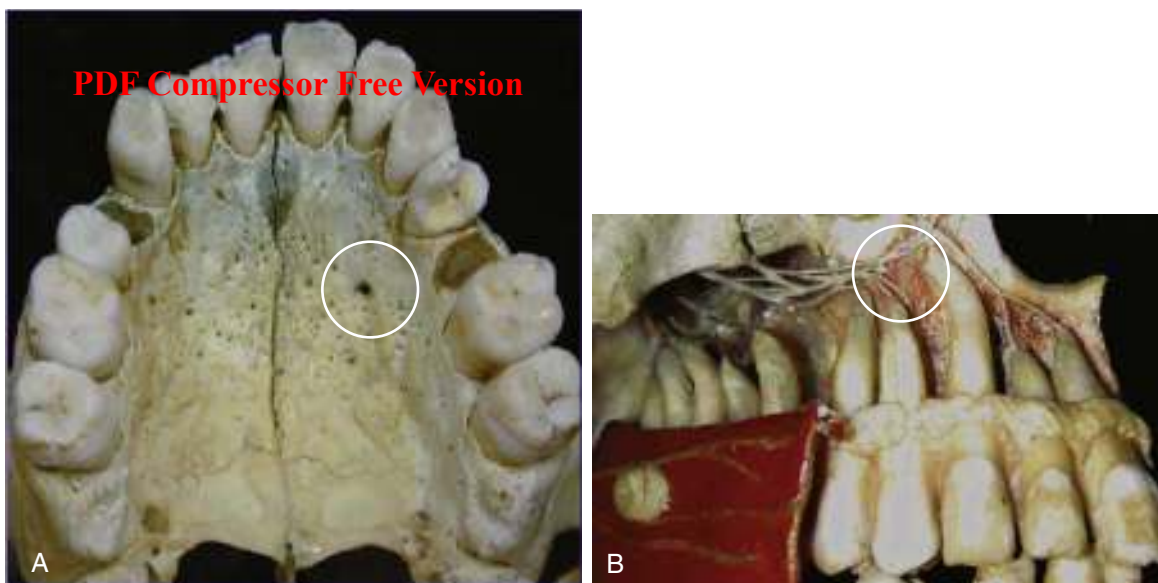
The percentage of success is higher if a vasoconstrictor is included in the anesthetic solution; however, inflamed tissues may continue to hemorrhage despite the use of a vasoconstrictor.

Complications

1. Few of significance.
2. Necrosis of soft tissues may be observed when a highly concentrated vasoconstrictor solution (e.g., 1:50,000) is used for hemostasis repeatedly over a prolonged period.

Anterior Middle Superior Alveolar Nerve Block

The AMSA nerve block injection is a recently described maxillary nerve block injection. It was first reported by Friedman and Hochman^{4,5} during development of a C-CLAD system. This technique provides pulpal anesthesia of multiple maxillary teeth (incisors, canine, and premolars) from a single injection site on the hard palate about halfway along an imaginary line connecting the midpalatal suture to the free gingival margin. The line is located at the contact point between the first and second premolars (Fig. 13.46).

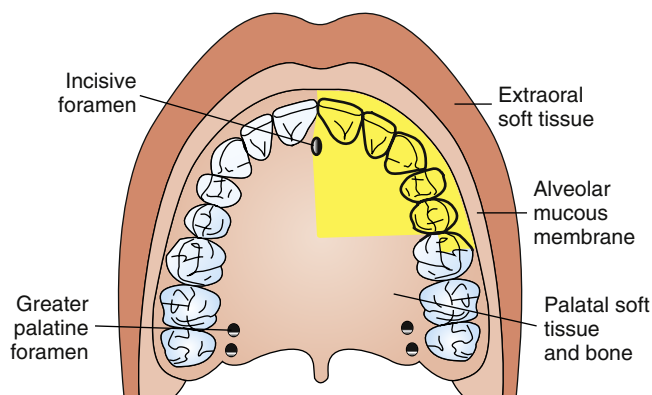


• **Fig. 13.47** Anatomy of anterior middle superior alveolar nerve block. (A) Palatal aspect: local anesthetic injected in the area of the circle. (B) Buccal aspect: local anesthetic injected on palatal side in the area of the circle.

Because the local anesthetic is deposited on the palate, the muscles of facial expression and the upper lip are not anesthetized. A minimal volume of local anesthetic is necessary to provide pulpal anesthesia from the central incisor to the second premolar on the side of the injection. The AMSA nerve block can be administered with little to no pain following the basic atraumatic palatal injection techniques previously described. Use of a C-CLAD system definitely aids in atraumatic administration of this injection.

The AMSA nerve block is most accurately described as a field block of the terminal branches (subneural dental plexus) of the ASA nerve, which innervates the incisors to the premolar teeth. Although studies suggest that the MSA nerve may be absent in a high percentage of individuals, a complete subneural dental plexus must be present to provide innervation to the premolars and incisor teeth in all patients. It is this subneural dental plexus of the ASA nerve that is anesthetized in the AMSA nerve block. Two anatomic structures, the nasal aperture and the maxillary sinus, cause the convergence of branches of the ASA and MSA nerves and associated subneural dental plexus in the region of the apices of the premolars (Fig. 13.47). The injection site is at this region of convergence of these neural structures. Depositing a sufficient volume of local anesthetic allows it to diffuse through nutrient canals and porous cortical bone on the palate to envelop the concentrated subneural dental plexus at this location.

The AMSA nerve block may be particularly useful for esthetic-restorative (cosmetic) dental procedures in which the dentist wishes to evaluate the smile line during treatment.⁶ In addition, this injection has been found to be very useful for periodontal scaling and root planing of the maxillary region.¹³ It provides profound soft tissue anesthesia and anesthesia of the attached gingiva of associated teeth. Perry and Loomer¹³ demonstrated a patient preference for the AMSA nerve block compared with supraperiosteal infiltration injection. Patients found the AMSA nerve block to be as effective as multiple maxillary infiltrations in the maxilla.



• **Fig. 13.48** Area anesthetized by an anterior middle superior alveolar nerve block.

Several important procedures should be followed to perform this injection comfortably. These techniques are most easily accomplished when performed with a C-CLAD system; however, this injection has also been successful when a standard aspirating dental syringe is used.

Other Common Name

Palatal approach AMSA nerve block.

Nerves Anesthetized

1. ASA nerve
2. MSA nerve, when present
3. Subneural dental nerve plexus of the ASA and MSA nerves

Areas Anesthetized

1. Pulpal anesthesia of the maxillary incisors, canines, and premolars (Fig. 13.48)
2. Buccal attached gingiva of these same teeth
3. Attached palatal tissues from midline to free gingival margin on associated teeth

Indications

1. Is more easily performed with a C-CLAD system
2. When dental procedures involving multiple maxillary anterior teeth or soft tissues are to be performed
3. When anesthesia of multiple maxillary anterior teeth is desired from a single-site injection
4. When scaling and root planing of the anterior teeth are to be performed
5. When anterior cosmetic procedures are to be performed and a smile-line assessment is important for a successful outcome
6. When a facial approach supraperiosteal injection has been ineffective because of dense cortical bone

Contraindications

1. Patients with unusually thin palatal tissues
2. Patients unable to tolerate the 3- to 4-minute administration time
3. Procedures requiring longer than 90 minutes

Advantages

1. Provides anesthesia of multiple maxillary teeth with a single injection
2. Comparatively simple technique
3. Comparatively safe; minimizes the volume of anesthetic and the number of punctures required compared with traditional maxillary infiltrations of these teeth
4. Allows effective soft tissue and pulpal anesthesia for periodontal scaling and root planing of associated maxillary teeth
5. Allows an accurate smile-line assessment to be performed after anesthesia has occurred, which may be helpful during cosmetic dentistry procedures
6. Eliminates the postoperative inconvenience of numbness to the upper lip and muscles of facial expression
7. Can be performed comfortably with a C-CLAD system

Disadvantages

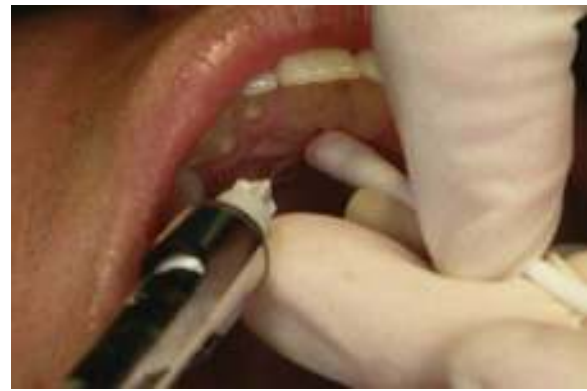1. Requires a slow administration (0.5 mL/min).
2. Can cause operator fatigue with a manual syringe because of extended injection time.
3. May be uncomfortable for the patient if administered improperly.
4. May need supplemental anesthesia for central and lateral incisor teeth.
5. May cause excessive ischemia if administered too rapidly.
6. Use of local anesthetic containing epinephrine with a concentration of 1:50,000 is contraindicated.

Positive Aspiration

Less than 1%.

Alternatives

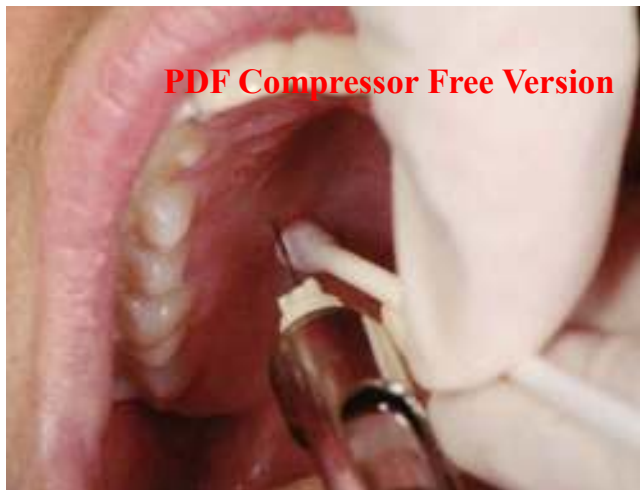1. Multiple supraperiosteal or PDL injections for each tooth
2. ASA and MSA nerve blocks
3. Maxillary nerve block



• Fig. 13.49 Prepuncture technique.

Technique

1. A 27-gauge short needle is recommended.
2. Area of insertion: On the hard palate about halfway along an imaginary line connecting the midpalatal suture to the free gingival margin. The location of the line is at the contact point between the first and second premolars (Fig. 13.46).
3. Target area: palatal bone at injection site.
4. Landmarks: the intersecting point midway along a line from the midpalatine suture to the free gingival margin intersecting the contact point between the first and second premolars.
5. Orientation of the bevel: The bevel of the needle is placed “face down” against the epithelium. The needle is typically held at a 45-degree angle to the palate.
6. Procedure:
 - a. Sit at the 9 or 10 o'clock position facing the same direction as the patient.
 - b. Position the patient supine with slight hyperextension of the head and neck so you can visualize the nasopalatine papilla more easily.
 - c. Use preparatory communication to inform the patient that the injection may take several minutes to administer, and that it may produce a sensation of firm pressure in the palate.
 - d. Use comfortable arm and finger rests to avoid fatigue during the extended administration time.
 - e. Use of a C-CLAD system is suggested because it makes this injection easier to administer.
 - f. Initial orientation of the bevel is “face down” toward the epithelium, while the needle is held at approximately a 45-degree angle with a tangent to the palate.
 - g. The final target is the bevel in contact with the palatal bone.
 - h. A prepuncture technique can be used. Apply the bevel of the needle toward the palatal tissue. Place a sterile cotton applicator on top of the needle tip (Fig. 13.49). Apply light pressure on the cotton applicator to create a “seal” of the needle bevel against the outer surface. Initiate delivery of the local anesthetic to the surface of the epithelium. The objective is to force the solution through the outer epithelium into the surface tissue. The cotton applicator provides stabilization of the needle and prevents any excess local anesthetic solution from dripping into the patient’s mouth. When a C-CLAD system is



• **Fig. 13.50** Anterior middle superior alveolar nerve block. Note syringe angulation from the opposite side of the mouth.

used, a slow rate of delivery (approximately 0.5 mL/min) is maintained during the entire injection. Maintain this position and pressure on the surface of the epithelium for 8 to 10 seconds.

- i. An “anesthetic pathway technique” can be used. Very slowly advance the needle tip into the tissue. Rotation of the needle allows the needle to penetrate the tissue more efficiently.¹⁴ Advance the needle 1 to 2 mm every 4 to 6 seconds while administering the anesthetic solution at the recommended slow rate. Attempt to not expand the tissue or advance the needle too rapidly if you are performing this with a manual syringe. Use of a C-CLAD system makes this process considerably easier to perform.
- j. After initial blanching is observed (approximately 30 seconds), pause for several seconds to allow the onset of superficial anesthesia.
- k. Continue the slow insertion into the palatal tissue. Orientation of the handpiece should be from the contralateral premolars (Fig. 13.50). The needle is advanced until contact with bone occurs.
- l. Ensure that needle contact is maintained with the bony surface of the palate. The bevel of the needle should face the surface of the bone.
- m. Aspirate in two planes.
- n. Anesthetic is delivered at a rate of approximately 0.5 mL per minute during the injection for a total dose of approximately 1.4 to 1.8 mL.
- o. Advise the patient that he or she will experience a sensation of firm pressure.

Signs and Symptoms

1. Subjective: a sensation of firmness and numbness is experienced immediately on the palatal tissues.
2. Subjective: numbness of the teeth and associated soft tissues extends from the central incisor to the second premolar on the side of the injection.
3. Objective: blanching of the soft tissues (if a vasoconstrictor is used) of the palatal and facial attached gingiva is evident, extending from the central incisor to the premolar region.

4. Objective: use of a freezing spray (e.g., Endo-Ice) or an EPT with no response from teeth with maximal EPT output (80/80).
5. Objective: absence of pain during treatment.
6. Objective: no anesthesia of the face and upper lip occurs. *Note: In some patients an additional injection may be necessary to anesthetize the central incisor teeth. This can be provided from a palatal approach or as individual PDL injections.*

Safety Features

1. Contact with bone
2. Low risk of positive aspiration
3. Slow insertion of needle (1 to 2 mm every 4 to 6 seconds)
4. Slow administration of local anesthetic (0.5 mL/min)
5. Less anesthetic required than if traditional injections are used

Precautions

1. Against pain:
 - a. Extremely slow insertion of needle
 - b. Slow administration during insertion with simultaneous administration of anesthetic solution
 - c. C-CLAD device recommended
2. Against tissue damage:
 - a. Avoid excessive ischemia by avoiding local anesthetics containing vasoconstrictors with a concentration of 1:50,000.
 - b. Avoid multiple infiltrations of local anesthetic with a vasoconstrictor in the same area at a single appointment.

Failure of Anesthesia

1. May need supplemental anesthesia for central and lateral incisors
 - a. Adequate volume of anesthetic may not reach dental branches.
 - b. To correct this, add additional anesthetic solution or perform an additional dental injection in proximity to these teeth from the palatal approach.

Complications

1. Palatal ulcer at injection site developing 1 to 2 days post-operatively:
 - a. Self-limiting.
 - b. Heals in 5 to 10 days.
 - c. Prevention includes slow administration to avoid excessive ischemia.
 - d. Avoid excessive concentrations of a vasoconstrictor (e.g., 1:50,000).
 - e. Avoid multiple infiltrations of local anesthetic with a vasoconstrictor in the same area at a single appointment.
2. Unexpected contact with the nasopalatine nerve.
3. Density of tissues at injection site causing squirt back of anesthetic and bitter taste. To prevent this:
 - a. Aspirate while withdrawing the syringe from tissue.
 - b. Pause for 3 to 4 seconds before withdrawing the needle to allow pressure to dissipate.
 - c. Instruct the assistant to suction any excess anesthetic that escapes during administration.

Palatal Approach Anterior Superior Alveolar Nerve Block

PDF Compressor Free Version

The P-ASA injection, as with the AMSA nerve block, was defined by Friedman and Hochman in conjunction with the clinical use and development of a C-CLAD system in the mid-1990s.^{5,6,11} The P-ASA nerve block shares several common elements with the nasopalatine nerve block but differs sufficiently to be considered a distinct injection. The P-ASA nerve block uses a similar tissue point of entry (lateral aspect of the incisive papilla) as the nasopalatine injection but differs in its final target (i.e., the needle positioned within the incisive canal). The volume of anesthetic recommended for the P-ASA nerve block is 1.4 to 1.8 mL, administered at a rate of 0.5 mL per minute.

The distribution of anesthesia differs between these injections as well. Nasopalatine nerve block provides anesthesia of the anterior palatal gingiva and mucoperiosteum and is recommended for surgical procedures on the anterior palate. It may also serve as a supplemental technique for achieving pulpal anesthesia of the incisor teeth. In contrast, the P-ASA nerve block is recommended as a primary method for achieving bilateral pulpal anesthesia of the anterior six maxillary teeth (incisors and canines). The P-ASA nerve block provides profound soft tissue anesthesia of the gingiva and mucoperiosteum in the region of the anterior palatal one-third innervated by the nasopalatine nerve. In addition, soft tissue anesthesia of the facial attached gingiva of the six anterior teeth is noted. Therefore the P-ASA nerve block is an attractive alternative for pain control for scaling and root planing, esthetic-restorative (dental) cosmetic procedures, and minor surgical procedures involving the premaxilla region. The P-ASA injection can be noted as the first dental injection to produce bilateral pulpal anesthesia from a single injection as its primary objective, making this a unique characteristic of this injection technique.

It is well documented in the dental literature that subjective pain associated with injections into the nasopalatine region is typically associated with a significant degree of discomfort when performed with a manual syringe.¹⁵⁻¹⁷ The introduction of C-CLAD systems has demonstrated that injections even into the dense, highly innervated tissues of the palate can be performed predictably with little or no pain.¹⁸ The P-ASA injection may be performed with a traditional syringe; however, a comfortable injection is more easily achieved with a C-CLAD system.^{4,19-21}

The P-ASA injection is useful when anesthesia of the maxillary anterior teeth is desired, without collateral anesthesia of the lips and muscles of facial expression. It has been shown to be desirable during scaling and root planing of the anterior teeth. It is also beneficial when anterior esthetic dentistry procedures are to be performed. The smile line and the interrelationships between lips, teeth, and soft tissues cannot be accurately assessed when a traditional (mucobuccal fold) approach to anesthesia is used, because of paralysis of the muscles of the upper lip. The palatal approach allows anesthesia to be limited to the subneural plexus for the maxillary anterior teeth and the nasopalatine nerve.

The minimum volume for this injection is 1.8 mL delivered at a slow rate of 0.5 mL/min.

Other Common Name

Palatal approach maxillary anterior field block.

Nerves Anesthetized

1. Nasopalatine nerve
2. Anterior branches of the ASA nerve

Areas Anesthetized

1. Pulp of the maxillary central incisors, the lateral incisors, and (to a lesser degree) the canines (Fig. 13.51)
2. Facial periodontal tissue associated with these same teeth
3. Palatal periodontal tissue associated with these same teeth

Indications

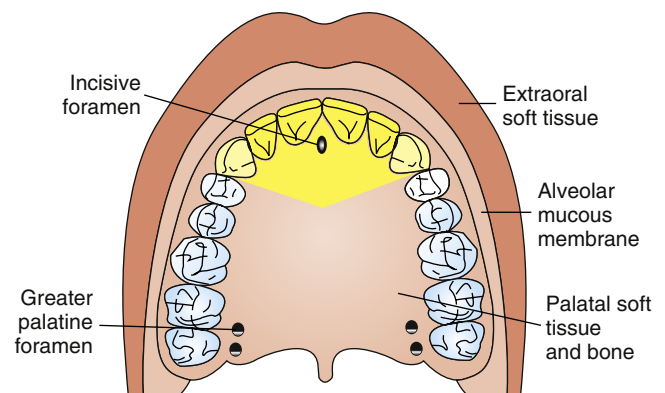
1. When dental procedures involving the maxillary anterior teeth and soft tissues are to be performed
2. When bilateral anesthesia of the maxillary anterior teeth is desired from a single-site injection
3. When scaling and root planing of the anterior teeth are to be performed
4. When anterior cosmetic procedures are to be performed and a smile-line assessment is important for a successful outcome
5. When a traditional facial approach supraperiosteal injection has been ineffective because of dense cortical bone

Contraindications

1. Patients with extremely long canine roots may not achieve profound anesthesia of these teeth from a palatal approach alone.
2. Patients who cannot tolerate the 3- to 4-minute administration time.
3. Procedures requiring longer than 90 minutes.

Advantages

1. Provides bilateral maxillary anesthesia from a single injection site
2. Comparatively simple technique to perform



• Fig. 13.51 Area anesthetized by a palatal approach anterior superior alveolar nerve block.

3. Comparatively safe; minimizes the volume of anesthetic and the number of punctures necessary compared with traditional methods.
4. Allows accurate smile-line assessment to be performed after anesthesia has occurred, which may be useful during cosmetic dentistry procedures
5. Eliminates the postoperative inconvenience of numbness to the upper lip and muscles of facial expression
6. Can be performed comfortably with a C-CLAD system

Disadvantages

1. Requires slow administration (0.5 mL/min).
2. Operator fatigue with a manual syringe because of extended injection time.
3. May be uncomfortable for the patient if administered improperly.
4. May require supplemental anesthesia for canine teeth.
5. May cause excessive ischemia if administered too rapidly.
6. Use of local anesthetic containing epinephrine with a concentration of 1:50,000 is contraindicated.

Positive Aspiration

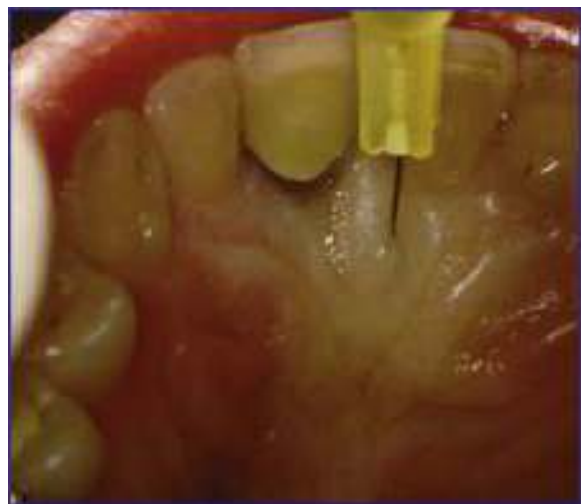Less than 1% (assumed from data on nasopalatine block).

Alternatives

1. Supraperiosteal or PDL injections for each tooth
2. Right and left (bilateral) ASA nerve blocks
3. Right and left (bilateral) maxillary nerve blocks

Technique

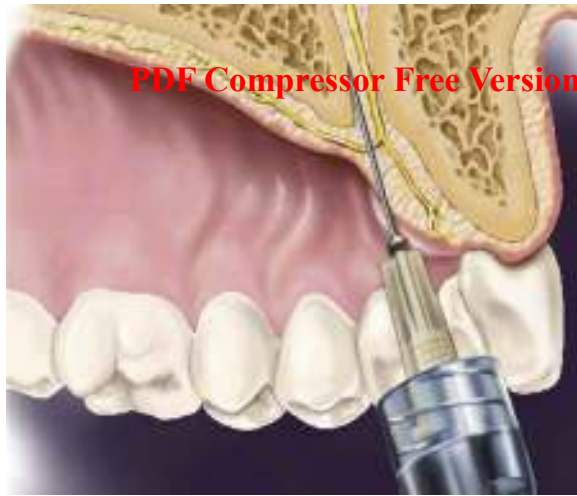1. A 27-gauge short needle is recommended.
2. Area of insertion: just lateral to the incisive papilla in the papillary groove (Fig. 13.52).
3. Target area: nasopalatine foramen.
4. Landmarks: nasopalatine papilla.
5. Orientation of the bevel: The bevel of the needle is placed “face down” against the epithelium. The needle is typically held at a 45-degree angle to the palate.



• **Fig. 13.52** Area of needle insertion for a palatal approach anterior superior alveolar nerve block.

6. Procedure:

- a. Sit at the 9 or 10 o'clock position facing in the same direction as the patient.
- b. Position the patient supine with slight hyperextension of the head and neck so you can visualize the nasopalatine papilla more easily.
- c. Use preparatory communication to inform the patient that the injection may take several minutes to administer and may produce a sensation of firm pressure in the palate.
- d. Use comfortable arm and finger rests to prevent fatigue during the extended administration time.
- e. Use of a C-CLAD system makes this injection easier to administer.
- f. Initial orientation of bevel is “face down” against the epithelium, while the needle is held at approximately a 45-degree angle with a tangent to the palate.
- g. A prepuncture technique can be used. Place the bevel of the needle against the palatal tissue. Place a sterile cotton applicator on top of the needle tip (see Fig. 13.49). Apply light pressure on the cotton applicator to create a “seal” of the needle bevel against the outer surface. Initiate delivery of the anesthetic solution to the surface of the epithelium. The objective is to force the solution through the outer epithelium into the tissue. Allow anesthetic solution to be delivered through the layer of the outer epithelium. The cotton applicator provides stabilization of the needle and prevents any excess dripping of anesthetic solution into the patient's mouth. When a C-CLAD device is used, a slow rate of delivery (approximately 0.5 mL/min) is maintained throughout injection. Maintain this position and pressure on the surface of the epithelium for 8 to 10 seconds.
- h. An anesthetic pathway technique can be used. Very slowly advance the needle into the tissue. Rotation of the needle allows it to penetrate the tissue more efficiently. Advance the needle 1 to 2 mm every 4 to 6 seconds while administering the anesthetic solution at the recommended (slow) rate. Avoid expanding the tissue or advancing the needle too rapidly if you are performing the P-ASA nerve block with a traditional syringe. It is at this step where a C-CLAD system makes the process easier to achieve.
- i. After initial blanching is observed (approximately 30 seconds), pause for several seconds to permit the onset of superficial anesthesia.
- j. Continue the slow insertion into the nasopalatine canal. The orientation of the needle should be parallel to the long axis of the central incisors. The needle is advanced to a depth of 6 to 10 mm (Fig. 13.53). *Note: If resistance is encountered before the final depth of penetration is reached, do not force the needle forward. Withdraw it slightly and reorient it to minimize the risk of penetration of the floor of the nose.*
- k. Ensure that the needle is in contact with the inner bony wall of the canal. (A well-defined nasopalatine canal may not be present in some patients.)
- l. Aspirate in two planes within the canal space to avoid intravascular injection.
- m. Anesthetic is delivered at a rate of approximately 0.5 mL per minute during the injection to a total volume of 1.4 to 1.8 mL. Advise the patient that he or she will experience a sensation of firm pressure. *Note: It has been*



• **Fig. 13.53** Orientation of the syringe for a palatal approach anterior superior alveolar nerve block.

reported that in a small percentage of cases needle insertion can stimulate the nasopalatine nerve (similar to contacting a nerve during an inferior alveolar block). This may be an unsettling surprise to the patient (and the administrator) if it occurs. Reassure the patient with verbal support that this is not uncommon and is not a problem. If this should occur, reposition the needle and continue to administer the anesthetic before advancing farther.

Signs and Symptoms

1. Subjective: a sensation of firmness and anesthesia is immediately experienced in the anterior palate.
2. Subjective: numbness of the teeth and associated soft tissues extends from the right to the left canine.
3. Objective: ischemia (blanching) of the soft tissues (if a vasoconstrictor is used) of the palatal and the facial attached gingiva is evident extending from the right to the left canine region.
4. Objective: use of a freezing spray (e.g., Endo-Ice) or an EPT with no response from teeth with maximal EPT output (80/80).
5. Objective: absence of pain during treatment.
6. Objective: no anesthesia of the face and upper lip occurs.

Note: In patients with long canine roots, additional local anesthetic may be needed. This can be provided through a palatal approach at a point that approximates the canine root tips.

 - a. In rare instances a facial approach (traditional) supra-periosteal injection may be necessary for the canine teeth.

Safety Features

1. Contact with bone
2. Minimal aspiration rate
3. Slow needle insertion (1 to 2 mm every 4 to 6 seconds)
4. Slow administration (0.5 mL/min) of local anesthetic
5. Less anesthetic volume than necessary if administered via traditional injections

Precautions

1. Against pain:
 - a. Extremely slow insertion.
 - b. Slow administration during insertion with simultaneous administration of anesthetic solution (creating an anesthetic pathway).
 - c. Consider use of a C-CLAD system.
2. Against tissue damage:
 - a. Avoid excessive ischemia by not using drugs containing epinephrine in a concentration of 1:50,000.
 - b. Avoid multiple infiltrations of local anesthetic with a vasoconstrictor in the same area at a single appointment.

Failure of Anesthesia

1. Highly successful injection for maxillary incisors.
2. When failure does occur, may need additional dental injection in patients whose canines have long roots:
 - a. Adequate volume of anesthetic may not reach dental branches.
 - b. To correct this, add additional anesthetic or perform an additional dental injection in proximity to the canine teeth from the palatal approach.
3. Unilateral anesthesia:
 - a. Look for bilateral blanching.
 - b. To correct this, administer additional anesthetic.

Complications

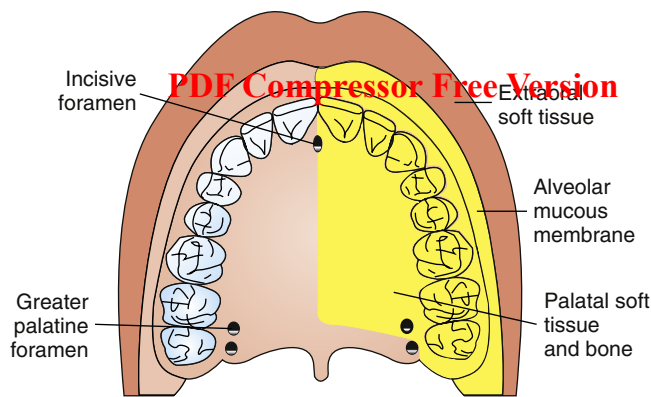
1. Palatal ulcer at injection site developing 1 to 2 days post-operatively:
 - a. Self-limiting.
 - b. Heals in 5 to 10 days.
 - c. Prevention includes slow administration to avoid excessive ischemia.
 - d. Avoid excessive concentrations of a vasoconstrictor (e.g., 1:50,000).
2. Unexpected contact with the nasopalatine nerve.
3. Density of soft tissues at injection site causing squirt back of anesthetic and bitter taste. To prevent this:
 - a. Aspirate while withdrawing the syringe from tissue.
 - b. Pause for 3 to 4 seconds before withdrawing the needle to allow pressure to dissipate.
 - c. Instruct the assistant to suction any excess anesthetic that escapes during administration.

Maxillary Nerve Block

The maxillary (second division or V₂) nerve block is an effective method of achieving profound anesthesia of a hemimaxilla. It is useful in procedures involving quadrant dentistry and in extensive surgical procedures. Two approaches are presented. Both are effective, and the author does not maintain a preference for either one. Major difficulties with the greater palatine canal approach involve locating the canal and negotiating its length successfully. The major difficulty in the high-tuberosity approach is a higher incidence of hematoma.

Other Common Names

Second division nerve block, V₂ nerve block.



• Fig. 13.54 Areas anesthetized by a maxillary nerve block.

Nerve Anesthetized

Maxillary division of the trigeminal nerve.

Areas Anesthetized

1. Pulpal anesthesia of the maxillary teeth on the side of the block (Fig. 13.54)
2. Buccal periodontium and bone overlying these teeth
3. Soft tissues and bone of the hard palate and part of the soft palate, medial to midline
4. Skin of the lower eyelid, side of the nose, cheek, and upper lip

Indications

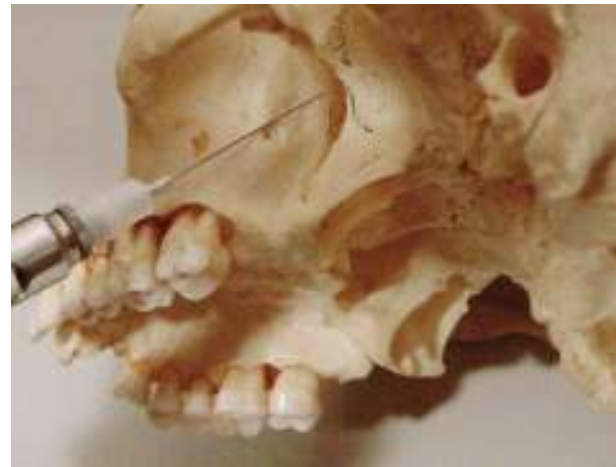1. Pain control before extensive oral surgical, periodontal, or restorative procedures requiring anesthesia of the entire maxillary division
2. When tissue inflammation or infection precludes the use of other regional nerve blocks (e.g., PSA, ASA, AMSA, P-ASA nerve blocks) or suprapariosteal injection
3. Diagnostic or therapeutic procedures for neuralgias or tics of the second division of the trigeminal nerve

Contraindications

1. Inexperienced administrator.
2. Pediatric patients.
 - a. More difficult because of smaller anatomic dimensions.
 - b. A cooperative patient is needed.
 - c. Usually unnecessary in children because of the high success rate of other regional block techniques.
3. Uncooperative patients.
4. Inflammation or infection of tissues overlying the injection site.
5. When hemorrhage is risky (e.g., in a person with hemophilia or patient on anticoagulant drugs).
6. In the greater palatine canal approach: inability to gain access to the canal; bony obstructions may be present in 5% to 15% of canals.

Advantages

1. Atraumatic injection via the high-tuberosity approach.
2. High success rate (>95%).



• Fig. 13.55 Maxillary nerve block, high-tuberosity approach.

3. Positive aspiration is less than 1% (greater palatine canal approach).
4. Minimizes the number of needle penetrations necessary for successful anesthesia of the hemimaxilla (minimum of four via PSA, ASA, infraorbital, greater palatine, and nasopalatine nerve blocks).
5. Minimizes total volume of local anesthetic solution injected to 1.8 mL versus 2.7 mL.
6. Neither the high-tuberosity approach nor the greater palatine canal approach is usually traumatic.

Disadvantages

1. Risk of hematoma, primarily with the high-tuberosity approach.
2. The high-tuberosity approach is relatively arbitrary. Overinsertion is possible because of the absence of bony landmarks if proper technique is not followed.
3. Lack of hemostasis. If necessary, this necessitates infiltration of small volumes of vasoconstrictor-containing local anesthetic at the surgical site.
4. Pain: the greater palatine canal approach is potentially (although not usually) traumatic.

Alternatives

To achieve the same distribution of anesthesia present with a maxillary nerve block, *all* of the following must be administered:

1. PSA nerve block
2. ASA nerve block
3. Greater palatine nerve block
4. Nasopalatine nerve block

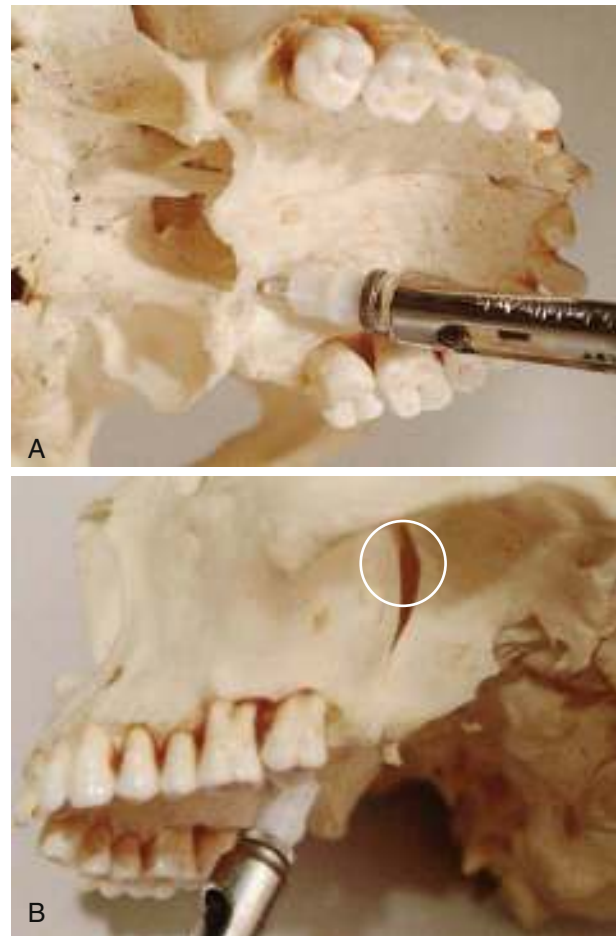
Technique: High-Tuberosity Approach (Fig. 13.55)

1. A 25-gauge long needle is recommended. A 27-gauge long is acceptable.
2. Area of insertion: height of the mucobuccal fold above the distal aspect of the maxillary second molar.

3. Target area:
 - a. Maxillary nerve as it passes through the pterygopalatine fossa. **PDF Compressor Free Version**
 - b. Superior and medial to the target area of the PSA nerve block.
4. Landmarks:
 - a. Mucobuccal fold at the distal aspect of the maxillary second molar.
 - b. Maxillary tuberosity.
 - c. Zygomatic process of the maxilla.
5. Orientation of the bevel: toward bone.
6. Procedure:
 - a. Measure the length of a long needle from the tip to the hub (average is 32 mm, but differs with the manufacturer).
 - b. Assume the correct position.
 - i. For a left high-tuberosity injection, a right-handed administrator should sit at the 10 o'clock position facing the patient (see Fig. 13.9A).
 - ii. For a right high-tuberosity injection, a right-handed administrator should sit at the 8 o'clock position facing the patient (see Fig. 13.9B).
 - c. Position the patient supine or semisupine for the right or left block.
 - d. Prepare the tissue in the height of the mucobuccal fold at the distal of the maxillary second molar:
 - i. Dry it with sterile gauze.
 - ii. Apply topical antiseptic (optional).
 - iii. Apply topical anesthetic.
 - e. Partially open the patient's mouth; pull the mandible toward the side of injection.
 - f. Retract the cheek in the injection area, if possible using a mouth mirror (to minimize the risk of accidental needlestick injury to the administrator).
 - g. Pull the tissues taut.
 - h. Place the needle into the height of the mucobuccal fold over the maxillary second molar.
 - i. Advance the needle slowly in an upward, inward, and backward direction as described for the PSA nerve block (p. 207).
 - j. Advance the needle to a depth of 30 mm.
 - i. No resistance to needle penetration should be felt. If resistance is felt, the angle of the needle in toward the midline is too great.
 - ii. At this depth (30 mm) the needle tip should lie in the pterygopalatine fossa in proximity to the maxillary division of the trigeminal nerve.
 - k. Aspirate in two planes.
 - i. Rotate the syringe (needle bevel) one-fourth of a turn and reaspirate.
 - ii. If negative:
 - a. Slowly (more than 60 seconds) deposit 1.8 mL.
 - b. Aspirate several times during injection.
 - l. Withdraw the syringe.
 - m. Make the needle safe.
 - n. Wait a minimum of 3 to 5 minutes before commencing the dental procedure.

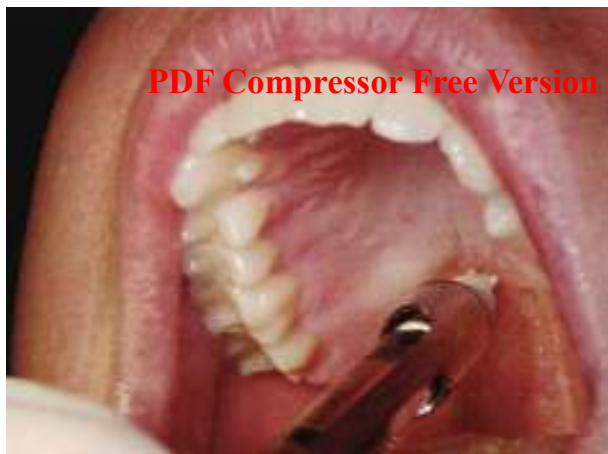Technique: Greater Palatine Canal Approach (Fig. 13.56)

1. A 25-gauge long needle is recommended. A 27-gauge long needle is also acceptable.
2. Area of insertion: palatal soft tissue directly over the greater palatine foramen.



• **Fig. 13.56** (A) Maxillary nerve block, greater palatine canal approach. Note the direction of the needle and the syringe barrel into the canal. (B) Second-division nerve block (V_2), greater palatine canal approach. Note the location of the needle tip in the pterygopalatine fossa (circle).

3. Target area: the maxillary nerve as it passes through the pterygopalatine fossa; the needle passes through the greater palatine canal to reach the pterygopalatine fossa.
4. Landmark: greater palatine foramen, junction of the maxillary alveolar process and the palatine bone.
5. Orientation of the bevel: toward palatal soft tissues.
6. Procedure:
 - a. Measure the length of a long needle from the tip to the hub (average is 32 mm, but differs with the manufacturer).
 - b. Assume the correct position:
 - i. For a right greater palatine canal V_2 block, sit facing toward the patient at the 7 or 8 o'clock position.
 - ii. For a left greater palatine canal V_2 block, sit facing in the same direction as the patient at the 10 or 11 o'clock position.
 - c. Ask the patient, who is supine, to do the following:
 - i. Open the mouth wide.
 - ii. Extend the neck.
 - iii. Turn the head to the left or right (to improve visibility).
 - d. Locate the greater palatine foramen:
 - i. Place a cotton swab at the junction of the maxillary alveolar process and the hard palate.
 - ii. Start in the region of the second molar by pressing firmly into the tissues with the swab. While maintaining pressure, continue to move the swab posteriorly.



• **Fig. 13.57** Maxillary nerve block, greater palatine canal approach.

- iii. The swab “falls” into the depression created by the greater palatine foramen.
- iv. The foramen is most frequently located at the distal aspect of the maxillary second molar (see [Table 13.2](#)).
- e. Prepare the tissues directly over the greater palatine foramen.
 - i. Clean and dry them with sterile gauze.
 - ii. Apply topical antiseptic (optional).
 - iii. Apply topical anesthetic for 2 minutes.
- f. After 2 minutes of topical anesthetic application, move the swab posteriorly so it lies just behind the greater palatine foramen.
 - i. Apply pressure to the tissue with the cotton swab, held in the left hand (if right-handed).
 - ii. Note ischemia at the injection site.
- g. Direct the syringe into the mouth from the opposite side with the needle approaching the injection site at a right angle ([Fig. 13.57](#)).
- h. Place the bevel against the ischemic soft tissue at the injection site. The needle must be well stabilized to prevent accidental penetration of the tissues.
 - i. With the bevel lying against the tissue:
 - i. Apply enough pressure to bow the needle slightly.
 - ii. Deposit a small volume of local anesthetic. The solution is forced against the mucous membrane, forming a droplet.
 - j. Straighten the needle and permit the bevel to penetrate the mucosa.
 - i. Continue to deposit small volumes of anesthetic throughout the procedure.
 - ii. Ischemia spreads into adjacent tissues as the anesthetic is deposited.
- k. Continue to apply pressure with the cotton applicator stick during this part of the procedure. *The greater palatine nerve block is now complete.*
- l. Probe gently for the greater palatine foramen.
 - i. The patient feels no discomfort because of the previously deposited anesthetic solution.
 - ii. The angle of the needle and syringe may be changed if needed.
 - iii. The needle usually must be held at a 45-degree angle to facilitate entry into the greater palatine foramen ([Table 13.3](#)).
- m. After location of the foramen, very slowly advance the needle into the greater palatine canal to a depth of 30 mm. Approximately 5% to 15% of greater palatine

TABLE 13.3 Angle of the Greater Palatine Foramen to the Hard Palate

Angle (degrees)	No. (N = 199)	Percentage
20–22.5	2	1.005
25–27.5	4	2.01
30–32.5	18	9.045
35–37.5	28	14.07
40–42.5	25	12.56
45–47.5	34	17.08
50–52.5	34	17.08
55–57.5	29	14.57
60–62.5	17	8.54
65–67.5	7	3.51
70	1	0.50

From Malamed SF, Trieger N. Intraoral maxillary nerve block: an anatomical and clinical study. *Anesth Prog.* 1983;30:44–48.

canals have bony obstructions that prevent passage of the needle.

- i. Never attempt to force the needle against resistance.
- ii. If resistance is felt, withdraw the needle slightly and slowly attempt to advance it at a different angle.
- iii. If the needle cannot be advanced farther and the depth of penetration is almost adequate, continue with the next steps; however, if the depth is considerably deficient, withdraw the needle and discontinue the attempt.
- n. Aspirate in two planes.
 - i. Rotate the needle one-fourth of a turn and reaspirate.
 - ii. If negative, slowly deposit 1.8 mL of solution over a minimum of 1 minute.
- o. Withdraw the syringe.
- p. Make the needle safe.
- q. Wait a minimum of 3 to 5 minutes before commencing the dental procedure.

Signs and Symptoms

1. Subjective: pressure behind the upper jaw on the side being injected; this usually subsides rapidly, progressing to tingling and numbness of the lower eyelid, side of the nose, and upper lip.
2. Subjective: sensation of numbness in the teeth and buccal and palatal soft tissues on the side of injection.
3. Objective: use of a freezing spray (e.g., Endo-Ice) or an EFT with no response from teeth with maximal EPT output (80/80).
4. Objective: absence of pain during treatment.

Safety Feature

Careful adherence to technique.

Precautions

1. Pain on insertion of the needle, primarily with the greater palatine canal approach. Prevent this by use of an atraumatic palatal injection protocol.
2. Overinsertion of the needle. This can occur with both approaches (although much less likely with the greater palatine canal approach). Prevent this through careful adherence to the protocol.
3. Resistance to needle insertion in the greater palatine canal approach; never try to advance a needle against resistance.

Failures of Anesthesia

1. Partial anesthesia; may result from underpenetration by needle. To correct this, reinsert the needle to the proper depth and reinject solution.
2. Inability to negotiate the greater palatine canal. To correct this:
 - a. Withdraw the needle slightly and reangulate it.
 - b. Reinsert the needle carefully to the proper depth.
 - c. If you are unable to bypass the obstruction easily, withdraw the needle and terminate the injection.
 - i. The high-tuberosity approach may prove more successful in this situation.
 - d. The greater palatine canal approach is usually successful if the long dental needle has been advanced at least two-thirds of its length into the canal.

Complications

1. Hematoma develops rapidly if the maxillary artery is punctured during maxillary nerve block via the high-tuberosity approach (see the complications of PSA nerve block, p. 207).
2. Penetration of the orbit may occur during a greater palatine foramen approach if the needle goes in too far; this is more likely to occur in the smaller-than-average skull.
3. Complications produced by injection of local anesthetic into the orbit include^b:
 - a. Volume displacement of the orbital structures, producing periorbital swelling and proptosis.
 - b. Regional block of the sixth cranial nerve (abducens nerve), producing diplopia.
 - c. Classic retrobulbar block, producing mydriasis, corneal anesthesia, and ophthalmoplegia.
 - d. Possible optic nerve block with transient loss of vision (amaurosis).
 - e. Possible retrobulbar hemorrhage.
 - f. To prevent intraorbital injection, strictly adhere to the protocol and modify your technique for the smaller patient.
4. Penetration of the nasal cavity:
 - a. If the needle deviates medially during insertion through the greater palatine canal, the paper-thin medial wall of the pterygopalatine fossa may be penetrated with the needle entering the nasal cavity.
 - i. On aspiration, large amounts of air appear in the cartridge.
 - ii. On injection, the patient complains that local anesthetic solution is running down his or her throat.

^b It was reported that complications a, b, and c were most common after intraorbital injection; complications d and e were never encountered.^{22,23}

TABLE 13.4 Maxillary Teeth and Available Local Anesthetic Techniques

Teeth	Pulpal Anesthesia	Soft Tissue Anesthesia	
		Buccal	Palatal
Incisors	ASA	ASA	Nasopalatine
	Infiltration	Infiltration	Infiltration
	Intranasal local anesthetic mist		Intranasal local anesthetic mist
	AMSA	AMSA	AMSA
	P-ASA	P-ASA	P-ASA
	V ₂	V ₂	V ₂
Canines	ASA	ASA	Nasopalatine
	Infiltration	Infiltration	Infiltration
	Intranasal local anesthetic mist		Intranasal local anesthetic mist
	AMSA	AMSA	AMSA
	P-ASA	P-ASA	P-ASA
	V ₂	V ₂	V ₂
Premolars	ASA	ASA	Greater palatine
	Infiltration	Infiltration	Infiltration
	Intranasal local anesthetic mist		Intranasal local anesthetic mist
	MSA	MSA	AMSA
	AMSA	AMSA	V ₂
	V ₂	V ₂	
Molars	PSA	PSA	Greater palatine
	Infiltration	Infiltration	Infiltration
	V ₂	V ₂	V ₂

AMSA, Anterior middle superior alveolar; ASA, anterior superior alveolar nerve block; MSA, middle superior alveolar; P-ASA, palatal approach-anterior superior alveolar; PSA, posterior superior alveolar.

- iii. To prevent this, keep the patient's mouth wide open and take care during penetration that the advancing needle stays in the correct plane.
- iv. Also to prevent this, do not force the needle if resistance is encountered.

Table 13.4 summarizes the indications for maxillary local anesthesia. Table 13.5 includes volumes of solutions recommended for maxillary injections.

Summary

Providing clinically adequate anesthesia in the maxilla is rarely a problem. The typically thin and porous bone of the maxilla permits the ready diffusion of local anesthetic to the

TABLE 13.5 Recommended Volumes of Local Anesthetic for Maxillary Techniques

Technique	Volume (mL) (>30 kg)
Supraperiosteal (infiltration)	0.6
Posterior superior alveolar	0.9–1.8
Middle superior alveolar	0.9–1.2
Anterior superior alveolar (infraorbital)	0.9–1.2
Anterior middle superior alveolar	1.4–1.8
Palatal approach anterior superior alveolar	1.4–1.8
Greater (anterior) palatine	0.45–0.6
Nasopalatine	0.45 (maximum)
Palatal infiltration	0.2–0.3
Maxillary (V ₂) nerve block	1.8

apex of the tooth to be treated. For this reason, many dentists rely solely on supraperiosteal (or “infiltration”) anesthesia for most treatment in the maxilla.

It is only on rare occasions that difficulty arises with maxillary pain control. Most notable, of course, is the pulpally involved tooth; because of infection or inflammation, the use of supraperiosteal anesthesia is contraindicated or ineffective in treating this tooth. In non-pulpally involved teeth, the most often observed problems in attaining adequate pulpal anesthesia via supraperiosteal injection develop in the central incisor (whose apex may lie beneath the denser bone and cartilage of the nose), the canine (whose root length may be considerable, with local anesthetic deposited below the apex), and maxillary molars (whose buccal root apices may be covered by denser bone of the zygomatic arch—a problem more often noted in patients aged 6 to 8 years and whose palatal root may flare more toward the palatal midline than “normal,” making the distance that local anesthetic must diffuse too great). In such situations the use of regional nerve block anesthesia is essential for clinical success in pain control. In reality, two safe and simple nerve blocks—the PSA and ASA nerve blocks—enable dental care to be provided painlessly in virtually all patients.

Palatal anesthesia, although commonly thought of as being highly traumatic, can be provided in most cases with little or no discomfort to the patient. The recent introduction of the intranasal local anesthetic mist allows pulpal anesthesia of maxillary nonmolar teeth and anesthesia of soft tissue on the palatal aspect of these teeth.

References

- Loetscher CA, Melton DC, Walton RE. Injection regimen for anesthesia of the maxillary first molar. *J Am Dent Assoc.* 1988;117:337–340.
- Gupta N, Singh K, Sharma S. Hematoma—a complication of the posterior superior alveolar nerve block. *J Dent Probl Solut.* 2015;2:15–16.
- Frazer M. Contributing factors and symptoms of stress in dental practice. *Br Dent J.* 1992;173:211.
- Friedman MJ, Hochman MN. A 21st century computerized injection system for local pain control. *Compend Contin Educ Dent.* 1997;18:995–1000, 1002–1003, quiz 1004.
- Friedman MJ, Hochman MN. The AMSA injection: a new concept for local anesthesia of maxillary teeth using a computer-controlled injection system. *Quintessence Int.* 1998;29:297–303.
- Lee S, Reader A, Nusstein J, et al. Anesthetic efficacy of the anterior middle superior alveolar (AMSA) injection. *Anesth Prog.* 2004;51:80–89.
- Yogesh Kumar TD, John JB, Asokan S, Geetha Priya PR, Punithavathy R, Praburajan V. Behavioral response and pain perception to computer controlled local anesthetic delivery system and cartridge system. *J Indian Soc Pedod Prev Dent.* 2015;33:223–228.
- Melzack R. *The Puzzle of Pain.* New York: Basic Books; 1973.
- Jeske AH, Blanton PL. Misconception involving dental local anesthesia. Part 2. Pharmacology. *Tex Dent J.* 2002;119:296–300, 302–304, 306–307.
- Hersh EV, Pinto A, Saraghi M, et al. Double-masked, randomized, placebo-controlled study to evaluate the efficacy and tolerability of intranasal K-305 (3% tetracaine plus 0.05% oxymetazoline) in anesthetizing maxillary teeth. *J Am Dent Assoc.* 2016;147:278–287.
- Friedman MJ, Hochman MN. P-ASA block injection: a new palatal technique to anesthetize maxillary anterior teeth. *J Esthet Dent.* 1999;11:63–71.
- Deleted in Review.
- Perry DA, Loomer PM. Maximizing pain control: the AMSA injection can provide anesthesia with few injections and less pain. *Dimens Dent Hyg.* 2003;49:28–33.
- Hochman MN, Friedman MJ. In vitro study of needle deflection: a linear insertion technique versus a bidirectional rotation insertion technique. *Quintessence Int.* 2000;31:33–39.
- Malamed SF. *Handbook of Local Anesthesia.* 5th ed. St Louis: Mosby; 2004.
- Jastak JT, Yagiela JA, Donaldson D. *Local Anesthesia of the Oral Cavity.* Philadelphia: WB Saunders; 1995.
- McArdle BF. Painless palatal anesthesia. *J Am Dent Assoc.* 1997;128:647.
- Nicholson JW, Berry TG, Summitt JB, et al. Pain perception and utility: a comparison of the syringe and computerized local injection techniques. *Gen Dent.* 2001;49:167–172.
- Hochman MN, Chiiarello D, Hochman C, et al. Computerized local anesthesia vs. traditional syringe technique: subjective pain response. *NY State Dent J.* 1997;63:24–29.
- Nicholson JW, Berry TG, Summitt JB, et al. Pain perception and utility: a comparison of the syringe and computerized local injection techniques. *Gen Dent.* 2001;49:167–172.
- Fukayama H, Yoshikawa F, Kohase H, et al. Efficacy of AMSA anesthesia using a new injection system, the Wand. *Quintessence Int.* 2003;34:537–541.
- Malamed SF, Trieger N. Intraoral maxillary nerve block: an anatomical and clinical study. *Anesth Prog.* 1983;30:44–48.
- Poore TE, Carney FMT. Maxillary nerve block: a useful technique. *J Oral Surg.* 1973;31:749–755.

Techniques of Mandibular Anesthesia

Providing effective pain control is one of the most important aspects of dental care. Indeed, patients rate a dentist “who does not hurt” and one who can “give painless injections” as meeting the second and first most important criteria used in evaluating dentists.¹ Unfortunately, the ability to obtain consistently profound anesthesia for dental procedures in the mandible has proved extremely elusive. This is even more of a problem when infected teeth are involved, primarily mandibular molars. Anesthesia of maxillary teeth on the other hand, although on occasion difficult to achieve, is rarely an insurmountable problem. The reasons for this include the fact that the cortical plate of bone overlying maxillary teeth is normally quite thin, thus allowing the local anesthetic drug to more readily diffuse when administered by supraperiosteal injection (infiltration). Additionally, relatively simple nerve blocks, such as the posterior superior alveolar, middle superior alveolar, anterior superior alveolar (infraorbital), and anterior middle superior alveolar nerve blocks,² are available as alternatives to infiltration.

It is commonly stated that the significantly higher failure rate for mandibular anesthesia is related to the thickness of the cortical plate of bone in the adult mandible. Indeed, it is generally acknowledged that mandibular infiltration is successful in cases where the patient has a full primary dentition.^{3,4} Once a mixed dentition develops, it is a general rule of teaching that the mandibular cortical plate of bone has thickened to the degree that infiltration might not be effective, leading to the recommendation that “mandibular block” techniques should now be used.⁵

A second difficulty with the traditional Halsted approach to the inferior alveolar nerve (i.e., “mandibular block,” or inferior alveolar nerve block [IANB]) is the absence of consistent landmarks. Multiple authors have described numerous approaches to this often elusive nerve.⁶⁻⁸ Reported failure rates for the IANB are commonly high, ranging from 31% and 41% in mandibular second and first molars to 42%, 38%, and 46% in second and first premolars and canines, respectively,⁹ and 81% in lateral incisors.¹⁰

Not only is the inferior alveolar nerve elusive but studies using ultrasound¹¹ and radiography^{12,13} to accurately locate the inferior alveolar neurovascular bundle or the mandibular foramen revealed that accurate needle location did not guarantee successful pain control.¹⁴ The central core theory

best explains this problem.^{15,16} Nerves on the outer aspect of the nerve bundle (mantle fibers) supply the molar teeth, while nerves on the inside (core fibers) supply incisor teeth. Therefore the local anesthetic solution deposited near the inferior alveolar nerve (IAN) may diffuse and block the outermost fibers but not those located more centrally, leading to incomplete mandibular anesthesia.

This difficulty in achieving mandibular anesthesia has, over the years, led to the development of alternative techniques to the traditional (Halsted approach) IANB. These have included the Gow-Gates mandibular nerve block,¹⁷ the Akinosi-Vazirani closed-mouth mandibular nerve block,^{18,19} periodontal ligament (PDL; intraligamentary) injection,^{20,21} intraosseous anesthesia,^{22,23} and, most recently, use of buffered local anesthetics.²⁴ Although all maintain some advantages over the traditional Halsted approach, none are without their faults and contraindications.

Six nerve blocks are described in this chapter. Two of these—involving the mental and buccal nerves—provide regional anesthesia of soft tissues only and have exceedingly high success rates. In both instances, the nerve anesthetized lies directly beneath the soft tissues, not encased in bone. The four remaining nerve blocks—inferior alveolar, incisive, Gow-Gates mandibular, and Vazirani-Akinosi (closed-mouth) mandibular nerve blocks—provide regional anesthesia of the pulps of some or all of the mandibular teeth in a quadrant. Three other injections of importance in mandibular anesthesia—PDL, intraosseous, and intra-septal injections—are described in [Chapter 15](#). Although these supplemental techniques can be used successfully in the maxilla or the mandible, their greatest utility lies in the mandible, because in the mandible, they can provide pulpal anesthesia of a single tooth without providing the accompanying lingual and extraoral facial soft tissue anesthesia that occurs with other mandibular nerve block techniques.

The success rate of the IANB is considerably lower than that of most other nerve blocks. Because of anatomic considerations in the mandible (primarily the density of bone), the administrator must accurately deposit local anesthetic solution as close to the target nerve as possible without the needle coming into contact with it. The IANB has a significantly lower success rate because of two factors—anatomic variation in the height of the mandibular foramen on the

lingual aspect of the ramus, and the greater depth of soft tissue penetration necessary—that lead to greater inaccuracy. Fortunately, the Gow-Gates nerve block provides pulpal anesthesia of the teeth anterior to the mental foramen (e.g., incisors, canines, first premolars, and, in most instances, second premolars). The incisive nerve block is a valuable alternative to the IANB when treatment is limited to premolar, canine, or incisor teeth. To achieve anesthesia of mandibular molars, however, the IAN must be anesthetized, and this frequently entails (with all its attendant disadvantages) a lower incidence of successful anesthesia.

The third injection technique that provides pulpal anesthesia of mandibular teeth, the Gow-Gates mandibular nerve block, is a true mandibular nerve block injection, providing regional anesthesia of virtually all sensory branches of the mandibular division of the trigeminal nerve (V_3). The Gow-Gates mandibular nerve block may be thought of as a (very) high IANB. When it is used, two benefits are seen: (1) the problems associated with anatomic variations in the height of the mandibular foramen are obviated and (2) anesthesia of the other sensory branches of V_3 (e.g., the lingual, buccal, and mylohyoid nerves) is usually attained along with that of the inferior alveolar nerve. With proper adherence to protocol (and experience using this technique), a success rate in excess of 95% can be achieved.

Another V_3 nerve block, the closed-mouth mandibular nerve block, is included in this discussion, primarily because it allows the doctor to achieve clinically adequate anesthesia in an extremely difficult situation—one in which a patient has limited mandibular opening as a result of infection, trauma, or postinjection trismus. It is also known as the *Vazirani-Akinosi technique* (after the two doctors who developed it independently of each other).^{18,19} Some practitioners use it routinely for anesthesia in the mandibular arch. The closed-mouth technique is described mainly because with experience it can provide a success rate of more than 80% in situations (extreme trismus) in which the inferior alveolar and Gow-Gates nerve blocks have little or no likelihood of success.

In ideal circumstances the individual who is to administer the local anesthetic should be familiar with each of these techniques. The more of these techniques at one's disposal with which to attain mandibular anesthesia, the less likely it is that a patient will be dismissed from an office as a result of inadequate pain control. More realistically, however, the administrator should become proficient in at least one of these procedures and should have a working knowledge of the others to be able to use them with a good expectation of success should the appropriate situation arise.

Recent work with mandibular infiltration in adult patients with the local anesthetic articaine hydrochloride has demonstrated significant rates of success in mandibular anterior teeth in lieu of nerve block injection.²⁷⁻²⁹ When articaine hydrochloride is administered by buccal infiltration in the adult mandible following IANB, success rates are even greater.²⁵⁻²⁸ The concept of mandibular infiltration in adult patients is discussed in depth in [Chapter 20](#).

Inferior Alveolar Nerve Block

The IANB, commonly (but inaccurately) referred to as the *mandibular nerve block*, is the second most frequently used (after infiltration) and possibly the most important injection technique in dentistry. Unfortunately, it also proves to be the most frustrating, with the highest percentage of clinical failures even when administered properly.⁶⁻¹⁰

It is an especially useful technique for quadrant dentistry. A supplemental block (buccal nerve) is needed only when soft tissue anesthesia in the buccal posterior region is necessary. On rare occasions a supraperiosteal injection (infiltration) may be needed in the lower incisor region to correct partial anesthesia caused by the overlap of sensory fibers from the contralateral side. A PDL injection might be necessary when isolated portions of mandibular teeth (usually the mesial root of a mandibular first molar) remain sensitive after an otherwise successful IANB. Intraosseous anesthesia is a supplemental technique used, usually on molars, when the IANB has proven ineffective, primarily when the tooth is pulpally involved.

Administration of bilateral IANBs is rarely indicated in dental treatments other than bilateral mandibular surgical procedures. They produce soft tissue anesthesia, which usually persists for several hours after injection (the duration is dependent on the particular local anesthetic used and, to a degree, the type of injection administered). Patients feel unable to swallow (they can) and, because of the absence of all sensation, are more likely to self-inflict injury to the anesthetized soft tissues. Additionally, residual soft tissue anesthesia affects the patient's ability to speak. When possible, it is preferable to treat the entire right or left side of a patient's oral cavity (maxillary and mandibular) at one appointment rather than administer a bilateral IANB. Patients are much more capable of handling the posttreatment discomfort (e.g., feeling of anesthesia) associated with bilateral maxillary anesthesia than with bilateral mandibular anesthesia.

One situation in which bilateral mandibular anesthesia is frequently used involves the patient who presents with 6, 8, or 10 lower anterior teeth (e.g., canine to canine; premolar to premolar) requiring restorative or soft tissue procedures. Two excellent alternatives to bilateral IANBs are bilateral incisive nerve blocks (where lingual soft tissue anesthesia is not necessary) and unilateral IANBs on the side that has the greater number of teeth requiring restoration or that requires the greater degree of lingual intervention, combined with an incisive nerve block on the opposite side. It must be remembered that the incisive nerve block does not provide lingual soft tissue anesthesia; thus lingual infiltration may be necessary. The buccal infiltration of articaine hydrochloride in the mandibular incisor region has been associated with considerable success in providing pulpal anesthesia.²⁵

In the following description of the IANB, the injection site is noted to be slightly higher than that usually depicted.

Other Common Name

Mandibular block.

Nerves Anesthetized

1. Inferior alveolar nerve, a branch of the posterior division of the mandibular division of the trigeminal nerve (V_3)
2. Incisive nerve
3. Mental nerve
4. Lingual nerve (commonly)

Areas Anesthetized

1. Mandibular teeth to the midline (Fig. 14.1)
2. Body of the mandible, inferior portion of the ramus
3. Buccal mucoperiosteum, mucous membrane anterior to the mental foramen (mental nerve)
4. Anterior two-thirds of the tongue and floor of the oral cavity (lingual nerve)
5. Lingual soft tissues and periosteum (lingual nerve)

Indications

1. Procedures on multiple mandibular teeth in one quadrant
2. When buccal soft tissue anesthesia (anterior to the mental foramen) is necessary
3. When lingual soft tissue anesthesia is necessary

Contraindications

1. Infection or acute inflammation in the area of injection (rare)
2. Patients who are more likely to bite their lip or tongue (e.g., a very young child or a physically or mentally handicapped adult or child)

Advantages

One injection provides a wide area of anesthesia (useful for quadrant dentistry).

Disadvantages

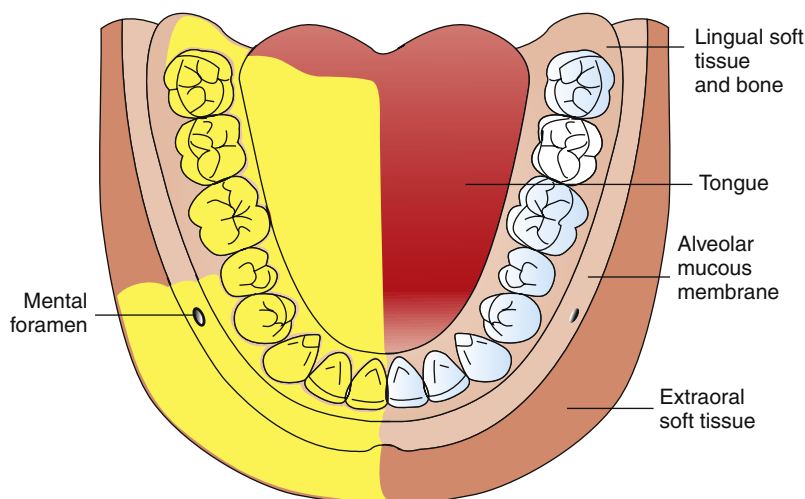
1. Wide area of anesthesia (not indicated for localized procedures)
2. Rate of inadequate anesthesia (31% to 81%)⁹
3. Intraoral landmarks not consistently reliable
4. Positive aspiration (10% to 15%, highest of all intraoral injection techniques)
5. Lingual and lower-lip anesthesia, discomfiting to many patients and possibly dangerous (self-inflicted soft tissue trauma) for certain individuals
6. Partial anesthesia possible where a bifid IAN and bifid mandibular canals are present; cross-innervation in lower anterior region³⁰

Positive Aspiration

Ranges from 10% to 15%.

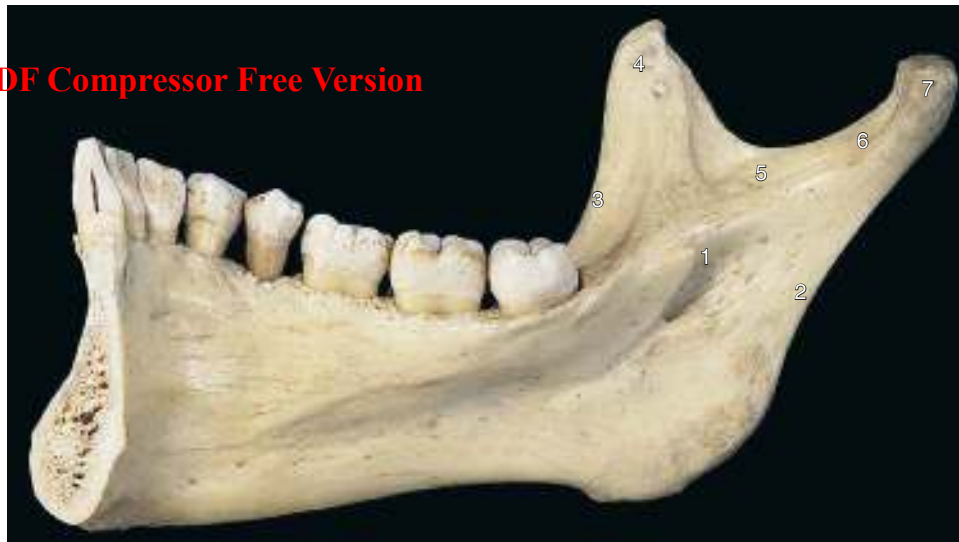Alternatives

1. Mental nerve block, for buccal soft tissue anesthesia anterior to the first molar
2. Incisive nerve block, for pulpal and buccal soft tissue anesthesia of teeth anterior to the mental foramen (usually second premolar to central incisor)
3. Supraperiosteal injection, for pulpal anesthesia of the central and lateral incisors, and sometimes the premolars and molars (discussed fully in Chapter 20)
4. Gow-Gates mandibular nerve block
5. Vazirani-Akinosi mandibular nerve block
6. PDL injection for pulpal anesthesia of any mandibular tooth
7. Intraosseous injection for pulpal and soft tissue anesthesia of any mandibular tooth, but especially molars
8. Intraseptal injection for pulpal and soft tissue anesthesia of any mandibular tooth



• Fig. 14.1 Area anesthetized by an inferior alveolar nerve block.

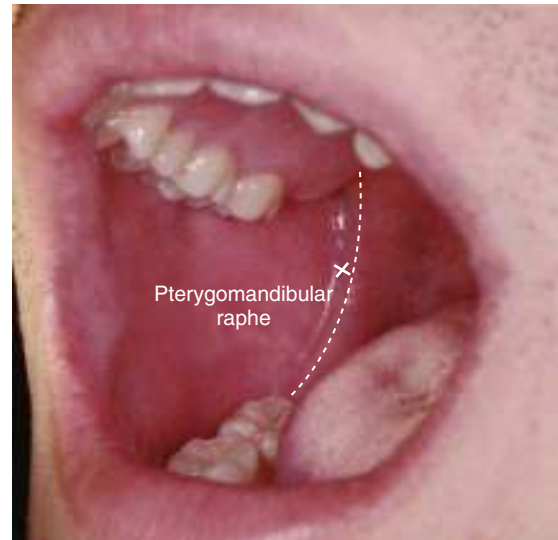
PDF Compressor Free Version



• **Fig. 14.2** Osseous landmarks for inferior alveolar nerve block. 1, Lingula; 2, distal border of ramus; 3, coronoid notch; 4, coronoid process; 5, sigmoid (mandibular) notch; 6, neck of condyle; 7, head of condyle.

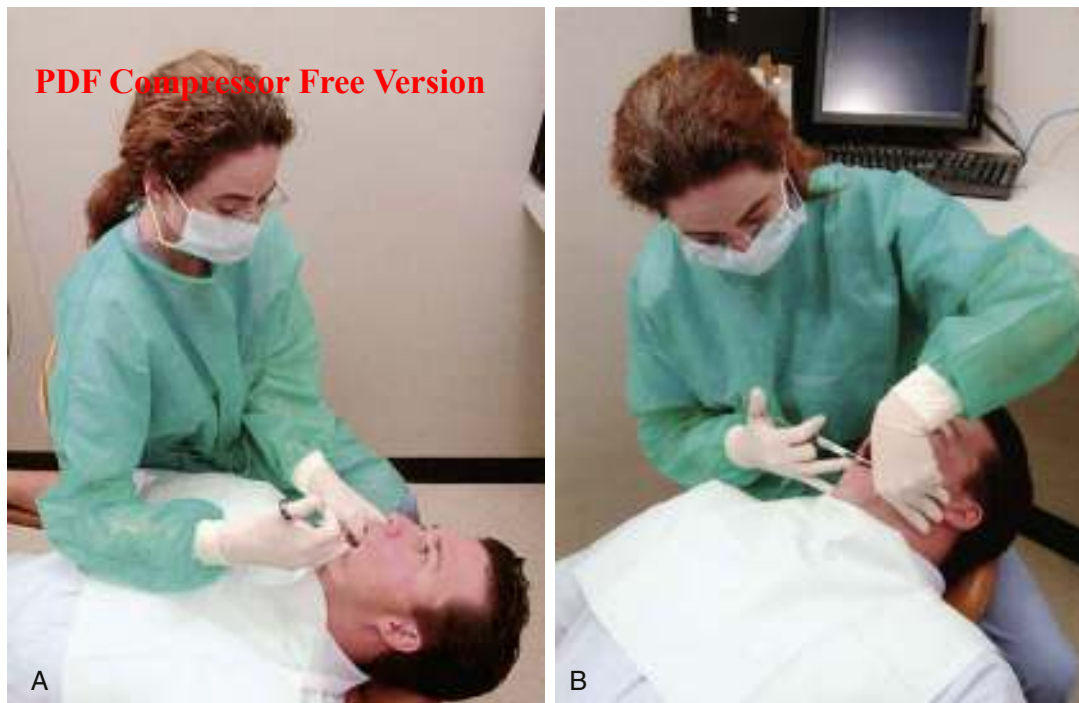Technique

1. A long dental needle is recommended for the adult patient or any pediatric patient where the soft tissue depth at the injection site is approximately 20 mm. A 25-gauge long needle is preferred; a 27-gauge long is acceptable.
2. Area of insertion: mucous membrane on the medial (lingual) side of the mandibular ramus, at the intersection of two lines—one horizontal, representing the height of needle insertion, the other vertical, representing the anteroposterior plane of injection.
3. Target area: inferior alveolar nerve as it passes downward toward the mandibular foramen but before it enters into the foramen.
4. Landmarks (Figs. 14.2 and 14.3):
 - a. Coronoid notch (greatest concavity on the anterior border of the ramus).
 - b. Pterygomandibular raphe (vertical portion).
 - c. Occlusal plane of the mandibular posterior teeth.
5. Orientation of the needle bevel: less critical than with other nerve blocks, because the needle approaches the IAN at roughly a right angle.
6. Procedure:
 - a. Assume the correct position:
 - i. For a right IANB, a right-handed administrator should sit at the 8 o'clock position facing the patient (Fig. 14.4A).
 - ii. For a left IANB, a right-handed administrator should sit at the 10 o'clock position facing in the same direction as the patient (see Fig. 14.4B).
 - b. Position the patient supine (recommended) or semisupine (if necessary). The mouth should be opened wide to allow greater visibility of, and access to, the injection site.
 - c. Prepare tissue at the injection site:
 1. Dry it with sterile gauze.
 2. Apply topical antiseptic (optional).
 3. Apply topical anesthetic for 1 to 2 minutes.



• **Fig. 14.3** The posterior border of the mandibular ramus can be approximated intraorally by use of the pterygomandibular raphe as it turns superiorly toward the maxilla.

- d. Place the barrel of the syringe in the corner of the mouth on the contralateral side (Figs. 14.5 and 14.6).
 - e. Locate the needle penetration (injection) site.
- Three parameters must be considered during administration of an IANB: (1) the height of the injection, (2) the anteroposterior placement of the needle (which helps to locate a precise needle entry point), and (3) the depth of penetration (which determines the location of the inferior alveolar nerve).
1. Height of injection: Place the index finger or the thumb of your left hand in the coronoid notch.
 - a. An imaginary line extends posteriorly from the fingertip in the coronoid notch to the deepest part of the pterygomandibular raphe (as it turns vertically upward toward the maxilla), determining the height of injection. This imaginary line should be parallel to

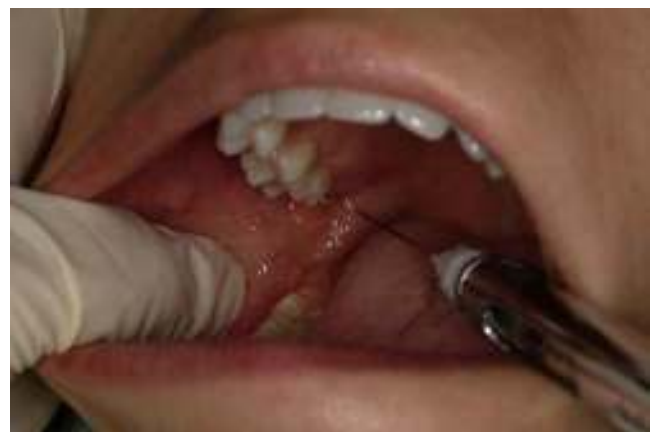

• **Fig. 14.4** Position of the administrator for a right inferior alveolar nerve block (A) and left inferior alveolar nerve block (B).

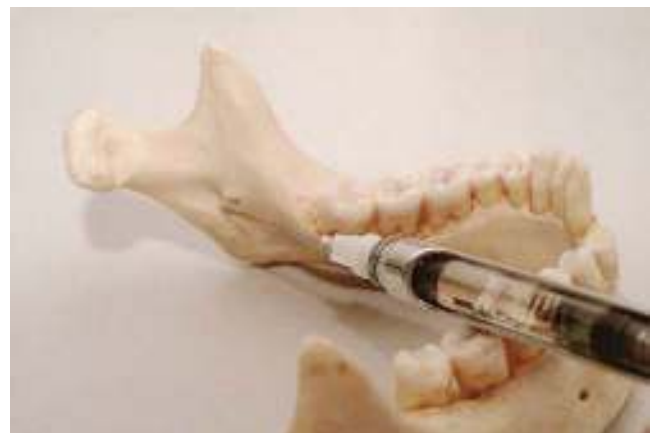the occlusal plane of the mandibular molar teeth. In most patients, this line lies 6 to 10 mm above the occlusal plane.

- b. The finger on the coronoid notch is used to pull the tissues laterally, stretching them over the injection site, making them taut, and enabling needle insertion to be less traumatic, while providing better visibility. If possible, use a mouth mirror to minimize the risk of accidental needlestick injury to the administrator.
- c. The needle insertion point lies three-fourths of the anteroposterior distance from the coronoid notch back to the deepest part of the pterygomandibular raphe: The line should begin at the midpoint of the notch and terminate at the deepest (most posterior) portion of the pterygomandibular raphe as the raphe bends vertically upward toward the palate.
- d. The posterior border of the mandibular ramus can be approximated intraorally by use of the pterygomandibular raphe as it bends vertically upward toward the maxilla (see Fig. 14.3).^a
- e. An alternative method of approximating the length of the ramus is to place your thumb on the coronoid notch and your index finger extraorally on the posterior border of the ramus and estimate the distance between these points. However, many practitioners (including this author) have difficulty envisioning the width of the ramus in this manner.

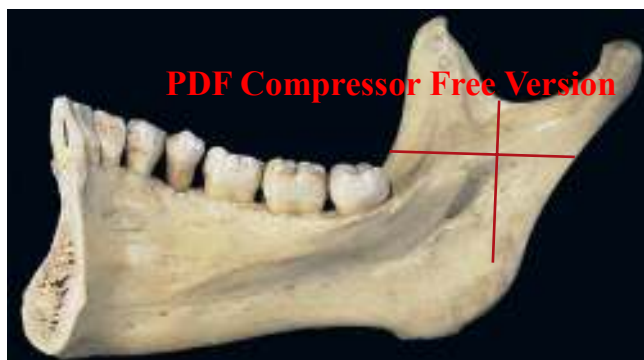^aThe pterygomandibular raphe continues posteriorly in a horizontal plane from the retromolar pad before turning vertically toward the palate; only the vertical portion of the pterygomandibular raphe is used as an indicator of the posterior border of the ramus.



• **Fig. 14.5** Note the placement of the syringe barrel at the corner of the mouth, usually corresponding to the premolars. The needle tip gently touches the most distal end of the pterygomandibular raphe.

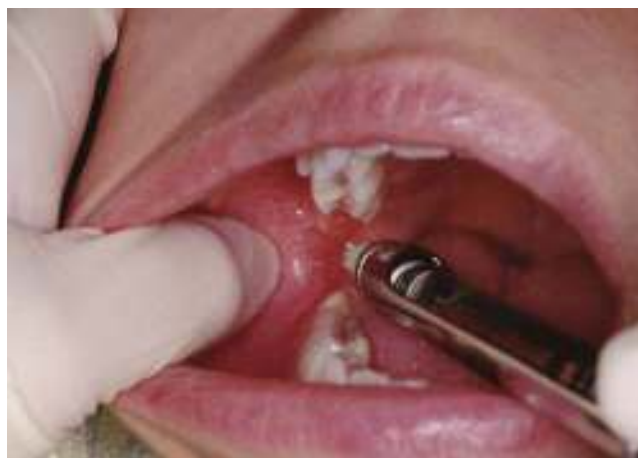

• **Fig. 14.6** Placement of the needle and syringe for an inferior alveolar nerve block.

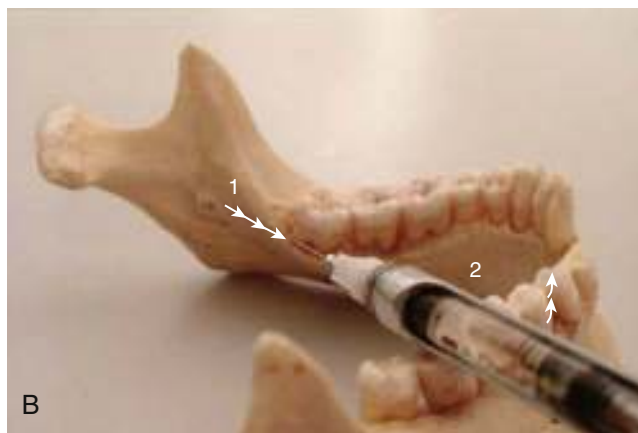
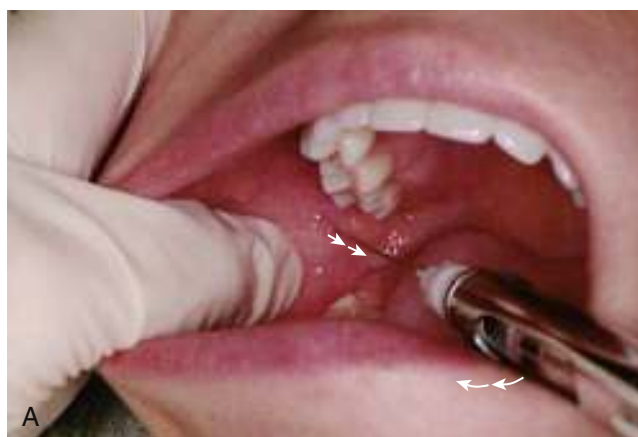
• **Fig. 14.7** Needle insertion is at the point of intersection of horizontal and vertical lines

2. Anteroposterior site of injection: Needle penetration occurs at the intersection of two points. (Fig. 14.7):
 - a. Point 1 falls along the horizontal line from the coronoid notch to the deepest part of the pterygomandibular raphe as it ascends vertically toward the palate as just described.
 - b. Point 2 is on a vertical line through point 1 about three-fourths of the distance from the anterior border of the ramus. This determines the anteroposterior site of the injection.
3. Penetration depth: In the third parameter of the IANB, bone should be contacted. Slowly advance the needle until you can feel it contact bone.
 - a. For most patients, it is not necessary to inject any local anesthetic solution as soft tissue is penetrated.
 - b. For anxious or sensitive patients, it may be advisable to deposit small volumes as the needle is advanced. Buffered local anesthetic solutions are recommended as they decrease the patient's sensitivity during needle advancement.
 - c. The average depth of penetration to bony contact, in the adult, is 20 to 25 mm, approximately two-thirds to three-fourths the length of a long dental needle (Fig. 14.8).
 - d. The needle tip should now be located slightly superior to the mandibular foramen (where the IAN enters [disappears into] bone). The foramen can neither be seen nor be palpated clinically.
 - e. If bone is contacted too soon (less than half the length of a long dental needle in an adult), the needle tip is usually located too far anteriorly (laterally) on the ramus. To correct this (Fig. 14.9):
 - i. Withdraw the needle slightly but do not remove it from the tissue.
 - ii. Bring the syringe barrel more toward the front of the mouth, over the canine or lateral incisor on the contralateral side.
 - iii. Redirect the needle until a more appropriate depth of insertion is obtained. The needle tip is now located more posteriorly in the mandibular sulcus.

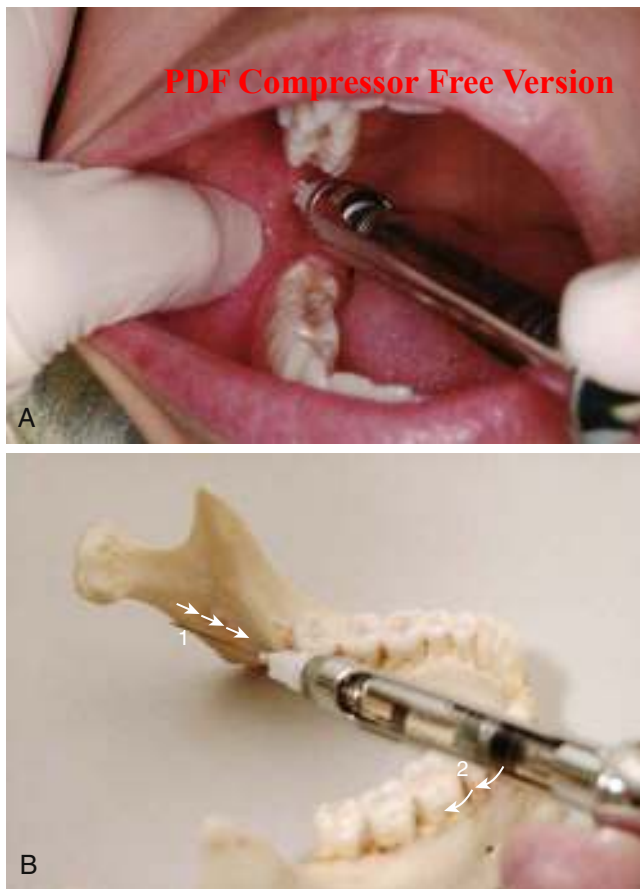

• **Fig. 14.8** Inferior alveolar nerve block. The depth of penetration is 20 to 25 mm (two-thirds to three-fourths the length of a long needle).



• **Fig. 14.9** (A) The needle is located too far anteriorly (laterally) on the ramus. (B) To correct this, withdraw it slightly from the tissues (1) and bring the syringe barrel anteriorly toward the lateral incisor or canine (2); reinsert the needle to proper depth.

- f. If bone is not contacted, the needle tip is usually located too far posterior (medial) (Fig. 14.10). To correct this:
 - i. Withdraw it slightly in tissue (leaving approximately one-fourth of its length in tissue) and reposition the syringe barrel more posteriorly (over the mandibular molars).
 - ii. Continue needle insertion until contact with bone is made at an appropriate depth (20 to 25 mm).



• **Fig. 14.10** (A) Overinsertion with no contact of bone. The needle is usually posterior (medial) to the ramus. (B) To correct this, withdraw it slightly from the tissues (1) and reposition the syringe barrel over the molars (2); reinsert the needle.

- d. Insert the needle. When bone is contacted, withdraw approximately the needle by 1 mm to prevent subperiosteal injection.
- e. Aspirate in two planes. If negative, slowly deposit 1.5 mL of anesthetic over a minimum of 60 seconds. (Because of the high incidence of positive aspiration and the natural tendency to deposit solution too rapidly, the sequence of slow injection, reaspiration, slow injection, and reaspiration is strongly recommended.)
- f. Slowly withdraw the syringe, and when approximately half its length remains within tissues, reaspirate. If negative, deposit a portion of the remaining solution (0.2 mL) to anesthetize the lingual nerve.
 - i. In most patients, this deliberate injection for lingual nerve anesthesia is not necessary because local anesthetic from the IANB anesthetizes the lingual nerve.
- g. Withdraw the syringe slowly and make the needle safe.
- h. After approximately 20 seconds, return the patient to a comfortably upright or semiupright position.
- i. Wait 3 to 5 minutes before testing for pulpal anesthesia.
- j. Following completion of the IANB, the author strongly recommends the infiltration of approximately 0.6 to 0.9 mL of articaine hydrochloride (preferably buffered) in the buccal fold at the apex of each mandibular tooth to be treated. This has

been demonstrated to increase the success rate of IANBs (as well as other “mandibular” nerve blocks).²⁹ (See [Chapter 20](#) for a more detailed discussion of buffered local anesthetic solutions.)

Signs and Symptoms

1. Subjective: Tingling or numbness of the lower lip indicates anesthesia of the mental nerve, a terminal branch of the inferior alveolar nerve. This is a good indication that the IAN is anesthetized, although it is not a reliable indicator of the depth of anesthesia. Soft tissue anesthesia is *never* a guarantee of pulpal anesthesia.
2. Subjective: Tingling or numbness of the tongue indicates anesthesia of the lingual nerve, a branch of the posterior division of V_3 . It usually accompanies IANB but may be present without anesthesia of the inferior alveolar nerve.
3. Objective: Use of a freezing spray (e.g., Endo-Ice) or an electric pulp tester (EPT) with no response to maximal output (80/80) on two consecutive tests at least 2 minutes apart serves as a “guarantee” (~99%) of successful pulpal anesthesia in nonpulpitic teeth.^{27,31,32}
4. Objective: No pain is felt during dental therapy.

Safety Feature

The needle contacts bone, preventing overinsertion with its attendant complications.

Precautions

1. Do not deposit local anesthetic if bone is not contacted. The needle tip may be resting within the parotid gland near the facial nerve (cranial nerve VII), and a transient blockade (paralysis) of the facial nerve may develop if local anesthetic solution is deposited.
2. Avoid pain by not contacting bone too forcefully.

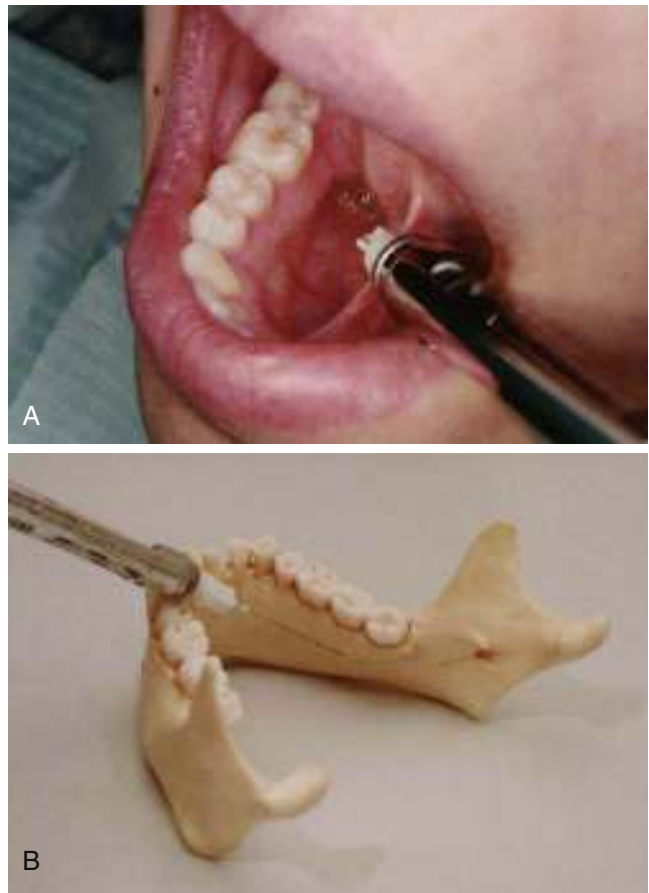
Failures of Anesthesia

The most common causes of absent or incomplete IANB are:

1. Deposition of anesthetic too low (below the mandibular foramen). To correct this, reinject anesthetic at a higher site (approximately 5 to 10 mm above the previous site).
2. Deposition of the anesthetic too far anteriorly (laterally) on the ramus. This is diagnosed by lack of anesthesia except at the injection site and by the minimum depth of needle penetration before contact with bone (e.g., the [long] needle is usually less than halfway into tissue). To correct this, redirect the needle tip posteriorly.
3. Accessory innervation to the mandibular teeth:
 - a. The primary symptom is isolated areas of incomplete pulpal anesthesia encountered in the mandibular molars (most commonly the mesial portion of the mandibular first molar).
 - b. Although it has been postulated that several nerves provide the mandibular teeth with accessory sensory innervation (e.g., the cervical accessory and

mylohyoid nerves), current thinking supports the mylohyoid nerve as the prime candidate.³³⁻³⁵ The Gow-Gate mandibular block, which only blocks the mylohyoid nerve, is not associated with problems of accessory innervation (unlike the IANB, which normally does not block the mylohyoid nerve).

- c. To correct this:
 - i. Technique 1:
 - a. Use a 25-gauge (or 27-gauge) long needle.
 - b. Retract the tongue toward the midline with a mirror handle or tongue depressor to provide access and visibility to the lingual border of the body of the mandible (Fig. 14.11).
 - c. Place the syringe in the corner of mouth on the opposite side and direct the needle tip to the apical region of the tooth immediately posterior to the tooth in question (e.g., the apex of the second molar if the first molar is the problem).
 - d. Penetrate the soft tissues and advance the needle until bone (e.g., the lingual border of the body of the mandible) is contacted. Topical anesthesia is unnecessary if lingual anesthesia is already present. The depth of penetration to bone is 3 to 5 mm.
 - e. Aspirate in two planes. If negative, slowly deposit approximately 0.6 mL (one-third of a cartridge) of anesthetic (in about 20 seconds).
 - f. Withdraw the syringe and make the needle safe.
 - ii. Technique 2. In any situation in which partial anesthesia of a tooth occurs, a PDL or intraosseous injection may be administered; both techniques have a high expectation of success. (See Chapter 15 for discussion of PDL and intraosseous injection techniques.)
 - d. Whenever a bifid IAN is detected on the radiograph, incomplete anesthesia of the mandible may develop after IANB.³⁰ In many such cases, a second mandibular foramen, located more inferiorly, exists. To correct this, deposit a volume of solution inferior to the normal anatomic landmark.
4. Incomplete anesthesia of the central or lateral incisors:
- a. This may comprise isolated areas of incomplete pulpal anesthesia.
 - b. Often this is caused by overlapping fibers of the contralateral inferior alveolar nerve, although it may also arise (rarely) from innervation from the mylohyoid nerve.
 - c. To correct this:
 - i. Technique 1
 - a. Infiltrate 0.9 mL of local anesthetic solution supraperiosteally into the mucobuccal fold below the apex of the tooth in question (Fig. 14.12). This is generally highly effective in the central and lateral incisor teeth because of the many small nutrient canals in the cortical bone near the region of the incisive fossa. The local anesthetic articaine hydrochloride appears to have the greatest success.^{25,36}
 - b. A 27-gauge short needle is recommended.



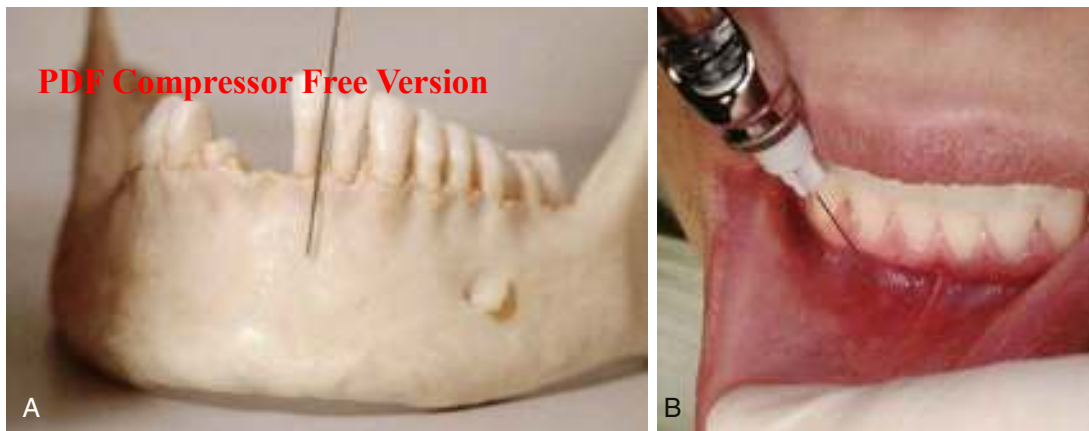
• **Fig. 14.11** (A) Retract the tongue to gain access to and increase the visibility of, the lingual border of the mandible. (B) Direct the needle tip below the apical region of the tooth immediately posterior to the tooth in question.

- c. Direct the needle tip toward the apical region of the tooth in question. Topical anesthesia is not necessary if mental nerve anesthesia is present.
- d. Aspirate in two planes.
- e. If negative, slowly deposit 0.9 mL of local anesthetic solution in approximately 30 seconds.
- f. Wait about 5 minutes before starting the dental procedure.

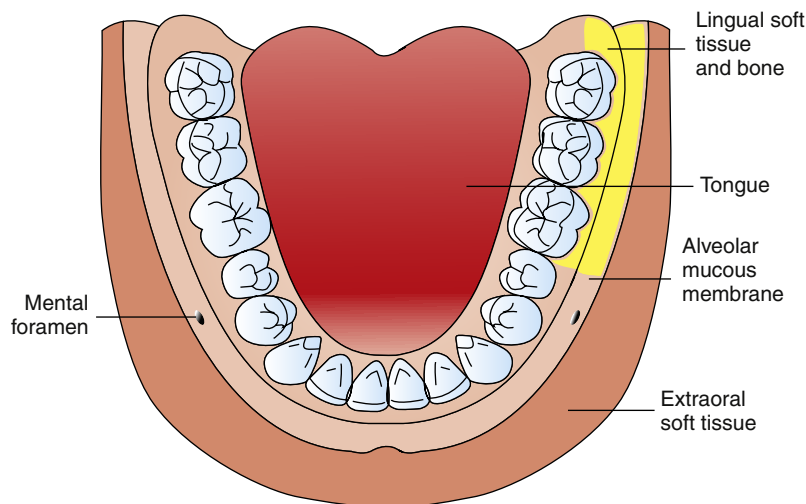
2. Technique 2. As an alternative, PDL injection may be used. PDL injection has great success in the mandibular anterior region.

Complications

1. Hematoma (rare):
 - a. Swelling of tissues on the medial side of the mandibular ramus after the deposition of anesthetic.
 - b. Management: apply pressure to the area for a minimum of 3 to 5 minutes.
2. Trismus:
 - a. Muscle soreness or limited opening of mandible:
 - i. A slight degree of soreness when opening the mandible is extremely common after IANB (after anesthesia has dissipated).
 - ii. More severe soreness associated with limited mandibular opening is rare.



• **Fig. 14.12** With suprapariosteal injection, the needle tip is directed toward the apical region of the tooth in question. (A) On a skull. (B) In the mouth.



• **Fig. 14.13** Area anesthetized by a buccal nerve block.

- b. Causes and management of limited mandibular opening after injection are discussed in [Chapter 17](#).
3. Transient facial paralysis (facial nerve anesthesia):
 - a. Produced by the deposition of local anesthetic into the body of the parotid gland, blocking cranial nerve VII (facial nerve), a motor nerve to the muscles of facial expression. Signs and symptoms include an inability to close the lower eyelid and drooping of the upper lip on the affected side.
 - b. Management of transient facial nerve paralysis is discussed in [Chapter 17](#).

Buccal Nerve Block

The buccal nerve is a branch of the anterior division of V_3 and consequently is not anesthetized during IANB. Nor is anesthesia of the buccal nerve necessary for most restorative dental procedures. The buccal nerve provides sensory innervation to the buccal soft tissues adjacent to the mandibular molars only. The sole indication for administration of a buccal nerve block therefore is when manipulation of these tissues is contemplated (e.g., with scaling or curettage, the placement of a rubber dam clamp on soft tissues, the removal of subgingival caries, subgingival tooth preparation,

the placement of a gingival retraction cord, or the placement of matrix bands).

It is common for the buccal nerve block to be routinely administered after IANB, even when buccal soft tissue anesthesia in the molar region is not required. There is absolutely no indication for this injection in such a situation.

The buccal nerve block, commonly—but incorrectly—referred to as the *long buccal nerve block*, has a success rate approaching 100%. The reason for this is that the buccal nerve is readily accessible to the local anesthetic as it lies immediately beneath the mucous membrane, not buried within bone.

Other Common Names

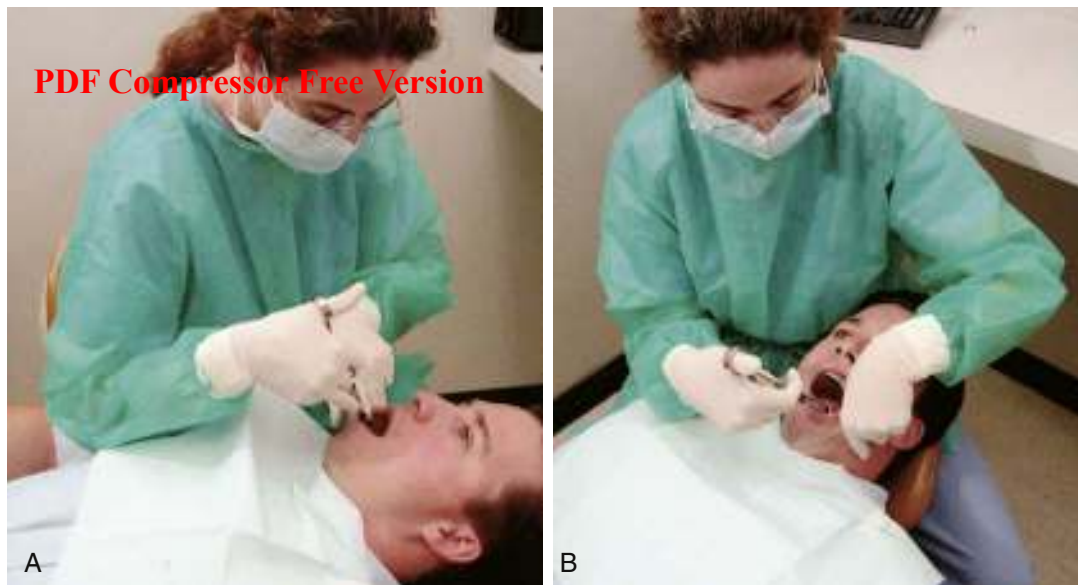
Long buccal nerve block, buccinator nerve block.

Nerve Anesthetized

Buccal nerve (a branch of the anterior division of V_3).

Area Anesthetized

Soft tissues and periosteum buccal to the mandibular molar teeth ([Fig. 14.13](#)).



• **Fig. 14.14** Position of the administrator for a right buccal nerve block (A) and left buccal nerve block (B).

Indication

When buccal soft tissue anesthesia is necessary for dental procedures in the mandibular molar region.

Contraindication

Infection or acute inflammation in the area of injection.

Advantages

1. High success rate
2. Technically easy

Disadvantages

Potential for pain if the needle contacts the periosteum during injection.

Positive Aspiration

0.7%.

Alternatives

1. Buccal infiltration
2. Gow-Gates mandibular nerve block
3. Vazirani-Akinosi mandibular nerve block
4. PDL injection
5. Intraosseous injection
6. Intraseptal injection

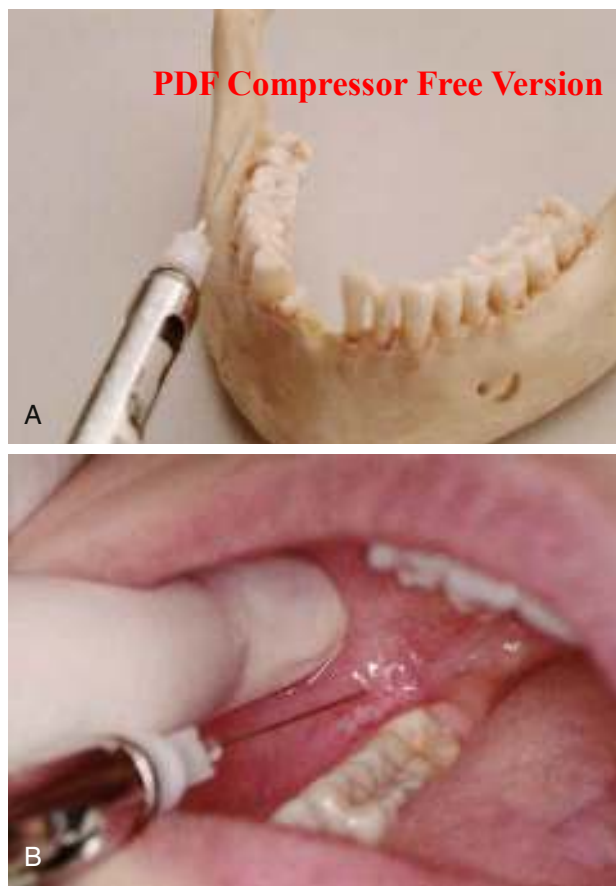
Technique

1. A 25- or 27-gauge long needle is recommended. This is most often used because the buccal nerve block is usually administered immediately after an IANB. A long needle

is recommended because of the posterior deposition site, not the depth of tissue insertion (which is minimal).

2. Area of insertion: mucous membrane distal and buccal to the most distal molar tooth in the arch.
3. Target area: buccal nerve as it passes over the anterior border of the ramus.
4. Landmarks: mandibular molars, mucobuccal fold.
5. Orientation of the bevel: toward bone during the injection.
6. Procedure:
 - a. Assume the correct position.
 - i. For a right buccal nerve block, a right-handed administrator should sit at the 8 o'clock position directly facing the patient (Fig. 14.14A).
 - ii. For a left buccal nerve block, a right-handed administrator should sit at 10 o'clock facing in the same direction as the patient (see Fig. 14.14B).
 - b. Position the patient supine (recommended) or semisupine.
 - c. Prepare the tissues for penetration distal and buccal to the most posterior molar^b:
 1. Dry them with sterile gauze.
 2. Apply topical anesthetic for 1 to 2 minutes.
 3. Apply topical antiseptic (optional).
 - d. With your left index finger (if right-handed), pull the buccal soft tissues in the area of injection laterally so that visibility will be improved. Taut tissues permit an atraumatic needle penetration. If possible, use a mouth mirror to minimize the risk of accidental needlestick injury to the administrator.
 - e. Direct the syringe toward the injection site with the bevel facing down toward bone and the syringe aligned parallel to the occlusal plane on the side of injection but buccal to the teeth (Fig. 14.15A).

^bBecause the buccal nerve block most often immediately follows an inferior alveolar nerve block, steps 1, 2, and 3 of tissue preparation usually are completed before the inferior alveolar block.



• **Fig. 14.15** Syringe alignment. (A) Parallel to the occlusal plane on the side of injection but buccal to it. (B) Distal and buccal to the last molar.

- f. Penetrate mucous membrane at the injection site, distal and buccal to the last molar (see Fig. 14.15B).
- g. Advance the needle slowly until mucoperiosteum is gently contacted.
 - i. To prevent pain when the needle contacts mucoperiosteum, deposit a few drops of local anesthetic just before contact.
 - ii. The depth of penetration is seldom more than 2 to 4 mm, and usually only 1 or 2 mm.
- h. Aspirate, in two planes.
- i. If negative, slowly deposit 0.3 mL (approximately one-eighth of a cartridge) over 10 seconds.
 - i. If tissue at the injection site balloons (becomes swollen during injection), stop depositing solution.
 - ii. If solution runs out the injection site (back into the patient's mouth) during deposition:
 - a. Stop the injection.
 - b. Advance the needle tip deeper into the tissue.^c
 - c. Reaspirate.
 - d. Continue the injection.
- j. Withdraw the syringe slowly and immediately make the needle safe.
- k. Wait approximately 3 to 5 minutes before commencing the planned dental procedure.

^cIf an inadequate volume of solution remains in the cartridge, it may be necessary to remove the syringe from the patient's mouth and reload it with a new cartridge.

Signs and Symptoms

1. Because of the location and small size of the anesthetized area, the patient rarely experiences any subjective symptoms.
2. Objective: instrumentation in the anesthetized area without pain indicates satisfactory pain control.

Safety Features

1. Needle contacts bone, therein preventing overinsertion
2. Minimum positive aspiration rate

Precautions

1. Pain on insertion from contacting unanesthetized periosteum. This can be prevented by depositing a few drops of local anesthetic before touching the periosteum.
2. Local anesthetic solution not being retained at the injection site. This generally means that needle penetration is not deep enough, the bevel of the needle is only partially in the tissues, and solution is escaping during the injection.
 - a. To correct this:
 - i. Stop the injection.
 - ii. Insert the needle to a greater depth.
 - iii. Reaspirate.
 - iv. Continue the injection.

Failures of Anesthesia

Rare with the buccal nerve block: inadequate volume of anesthetic retained in the tissues.

Complications

1. Few of any consequence.
2. Hematoma (bluish discoloration and tissue swelling at the injection site). Blood may exit the needle puncture point into the buccal vestibule. To treat this, apply pressure with gauze directly to the area of bleeding for a minimum of 3 minutes.

Mandibular Nerve Block: The Gow-Gates Technique

Successful anesthesia of the mandibular teeth is more difficult to achieve than anesthesia of maxillary structures. Primary factors for this failure are the greater anatomic variation in the mandible and the need for deeper soft tissue penetration. In 1973, George Albert Edwards Gow-Gates (1910–2001),³⁷ a general practitioner of dentistry in Australia, described a new approach to mandibular anesthesia. He had used this technique in his practice for approximately 30 years, with an astonishingly high success rate (approximately 99% in his experienced hands).

The Gow-Gates technique is a true mandibular nerve block because it provides sensory anesthesia of virtually the entire distribution of V_3 . The inferior alveolar, lingual,

mylohyoid, mental, incisive, auriculotemporal, and buccal nerves all are blocked with the Gow-Gates injection.

Significant advantages of the Gow-Gates over IANB include its higher success rate, its lower incidence of positive aspiration (approximately 2% vs. 10% to 15% with the IANB),^{37,38} and the absence of problems with accessory sensory innervation to the mandibular teeth.

The only apparent disadvantage is a relatively minor one: An administrator experienced with the IANB may feel uncomfortable while learning the Gow-Gates mandibular nerve block. Indeed, the incidence of unsuccessful anesthesia with Gow-Gates mandibular nerve block may be as high as (if not higher than) that for the IANB until the administrator gains clinical experience with it. Following this “learning curve,” success rates greater than 95% are common. A new student of local anesthesia usually does not encounter as much difficulty with the Gow-Gates mandibular nerve block as the more experienced administrator. This is a result of the strong bias of the experienced administrator to deposit the anesthetic drug “lower” (e.g., in the “usual” place). Two approaches are suggested for becoming comfortable with the Gow-Gates mandibular nerve block technique. The first is to begin to use the technique on all patients requiring mandibular anesthesia. Allow at least 1 to 2 weeks to gain clinical experience. The second approach is to continue using the conventional IANB, but to use the Gow-Gates mandibular nerve block technique when clinically inadequate anesthesia occurs. Reanesthetize the patient using the Gow-Gates mandibular nerve block. Although experience is accumulated more slowly with this latter approach, its effectiveness is more dramatic because patients who were previously difficult to anesthetize now may be more easily managed.

The Gow-Gates mandibular nerve block has now been “available” for approximately 45 years (since publication of the initial article in 1973³⁷). In a 2007 survey of Harvard School of Dental Medicine graduates from 2000 through 2006, Johnson et al.³⁹ reported that between 3.7% and 16.1% of clinicians trained in the Gow-Gates mandibular nerve block technique used it as their primary mandibular technique and

that between 35.4% and 56.3% never used the technique. They concluded that, in the study population, formal clinical training in the Gow-Gates mandibular nerve block technique led to a small but significant increase in its current primary utilization.³⁹ Once a doctor becomes comfortable with the Gow-Gates mandibular nerve block technique its success rate will be higher than that of the traditional IANB.^{40,41}

Other Common Names

Gow-Gates technique, third division nerve block, V₃ nerve block.

Nerves Anesthetized

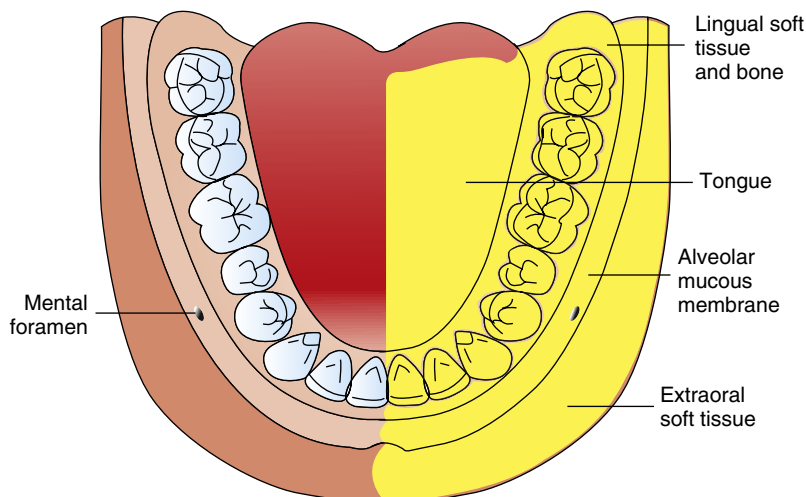
1. Inferior alveolar nerve
2. Mental nerve
3. Incisive nerve
4. Lingual nerve
5. Mylohyoid nerve
6. Auriculotemporal nerve
7. Buccal nerve (in 75% of patients)

Areas Anesthetized

1. Mandibular teeth to the midline (Fig. 14.16)
2. Buccal mucoperiosteum and mucous membranes on the side of injection
3. Anterior two-thirds of the tongue and floor of the oral cavity
4. Lingual soft tissues and periosteum
5. Body of the mandible, inferior portion of the ramus
6. Skin over the zygoma, posterior portion of the cheek, and temporal regions

Indications

1. Multiple procedures on mandibular teeth
2. When buccal soft tissue anesthesia, from the third molar to the midline, is necessary



• Fig. 14.16 Area anesthetized by the Gow-Gates mandibular nerve block.

3. When lingual soft tissue anesthesia is necessary
4. When a conventional IANB is unsuccessful

PDF Compressor Free Version

Contraindications

1. Infection or acute inflammation in the area of injection (rare)
2. Patients who might bite their lip or their tongue, such as young children and physically or mentally handicapped adults
3. Patients who are unable to open their mouth wide (e.g., trismus)

Advantages

1. Requires only one injection; a buccal nerve block is usually unnecessary (accessory innervation has been blocked)
2. High success rate (>95%), with experience
3. Minimum aspiration rate (~2%)
4. Few postinjection complications (e.g., trismus)
5. Provides successful anesthesia where a bifid IAN and bifid mandibular canals are present

Disadvantages

1. Lingual and lower-lip anesthesia is uncomfortable for many patients and is possibly dangerous for certain individuals.
2. The time to onset of anesthesia is somewhat longer than with an IANB, primarily because of the size of the nerve trunk being anesthetized and the distance of the nerve trunk from the deposition site (approximately 5 to 10 mm).
3. There is a learning curve with the Gow-Gates mandibular nerve block technique. Clinical experience is necessary to truly learn the technique and to fully take advantage of its greater success rate. This learning curve may prove frustrating for some persons.

Positive Aspiration

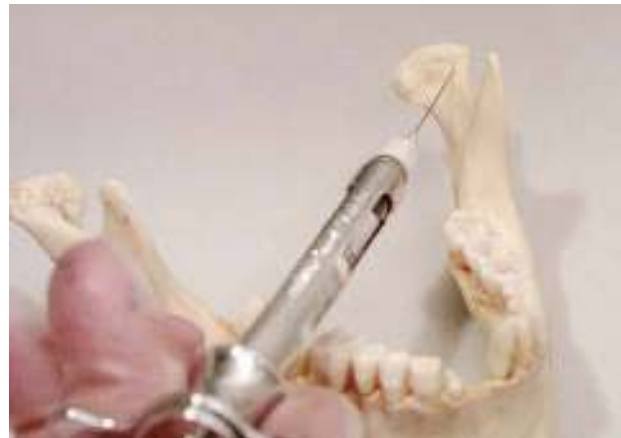Approximately 2%.

Alternatives

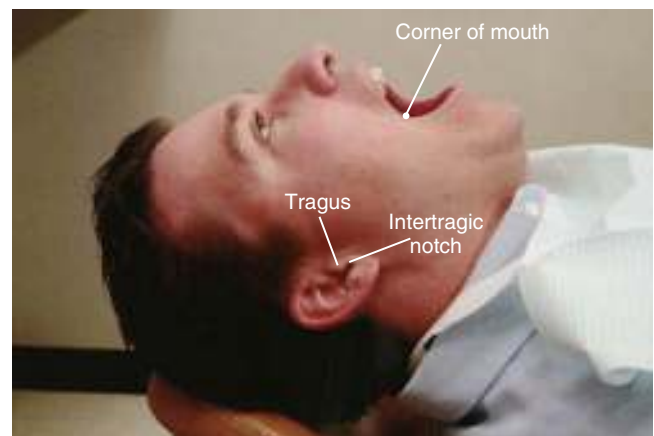
1. IANB and buccal nerve block
2. Vazirani-Akinosi closed-mouth mandibular block
3. Incisive nerve block: pulpal and buccal soft tissue anterior to the mental foramen
4. Mental nerve block: buccal soft tissue anterior to the first molar
5. Buccal nerve block: buccal soft tissue from the third to the mental foramen region
6. Supraperiosteal injection (infiltration): using (buffered) articaine hydrochloride, depositing 0.6 to 0.9 mL in the buccal fold adjacent to the tooth to be treated) (see [Chapter 9](#) for a discussion)
7. Intraosseous technique (see [Chapter 15](#) for a discussion)
8. PDL injection technique (see [Chapter 15](#) for a discussion)

Technique

1. A 25- or 27-gauge long needle recommended.
2. Area of insertion: mucous membrane on the mesial aspect of the mandibular ramus, on a line from the intertragic notch to the corner of the mouth, just distal to the maxillary second molar.
3. Target area: lateral side of the condylar neck, just below the insertion of the lateral pterygoid muscle ([Fig. 14.17](#)).
4. Landmarks:
 - a. Extraoral:
 - i. The intertragic notch (lower border of the tragus). The correct landmark is the center of the external auditory meatus, which is concealed by the tragus; therefore its lower border is adopted as a visual aid ([Fig. 14.18](#)).
 - ii. Corner of the mouth on the contralateral side.
 - b. Intraoral:
 - i. Height of injection established by placement of the needle tip just below the mesiolingual (mesio-palatal) cusp of the maxillary second molar ([Fig. 14.19A](#)).

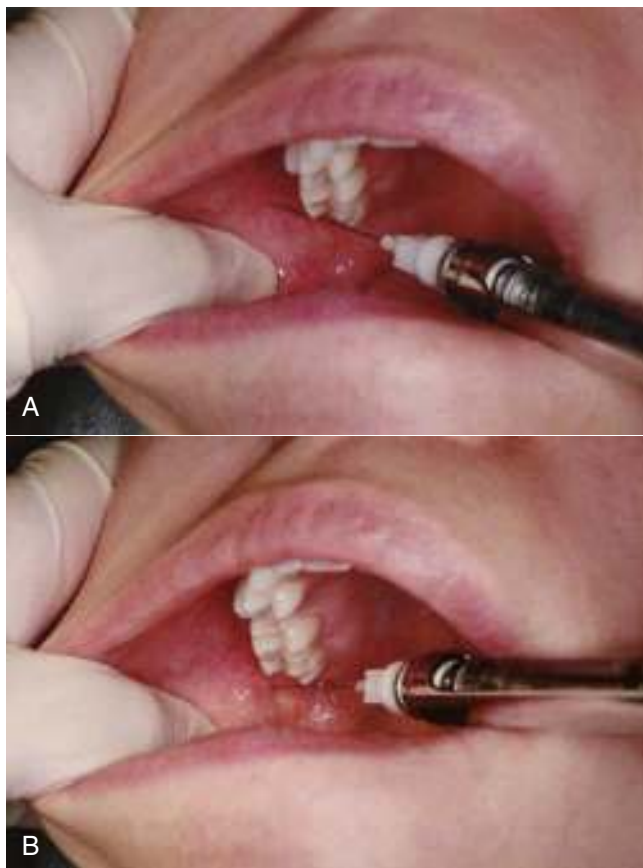


• **Fig. 14.17** Target area for a Gow-Gates mandibular nerve block—neck of the condyle.



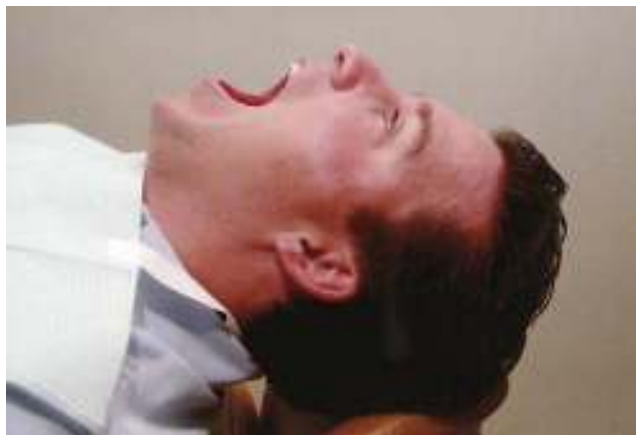• **Fig. 14.18** Extraoral landmarks for a Gow-Gates mandibular nerve block.

- ii. Penetration of soft tissues just distal to the maxillary second molar at the height established in the preceding step.
5. Orientation of the bevel: not critical.
6. Procedure:
- a. Assume the correct position.
 - i. For a right Gow-Gates mandibular nerve block, a right-handed administrator should sit at the 8 o'clock position facing the patient.
 - ii. For a left Gow-Gates mandibular nerve block, a right-handed administrator should sit at the 10 o'clock position facing the same direction as the patient.
 - iii. These are the same positions used for a right and a left IANB (see Fig. 14.4).
 - b. Position the patient (Fig. 14.20):
 - i. Supine is recommended, although semisupine may also be used.
 - ii. Ask the patient to extend his or her neck and to open his or her mouth wide for the duration of the technique. The condyle then assumes a more frontal position and is closer to the mandibular nerve trunk.
 - c. Locate the extraoral landmarks:
 - i. Intertragic notch.
 - ii. Corner of the mouth on the contralateral side.
 - d. Place your left index finger or thumb on the coronoid notch; determination of the coronoid notch is not



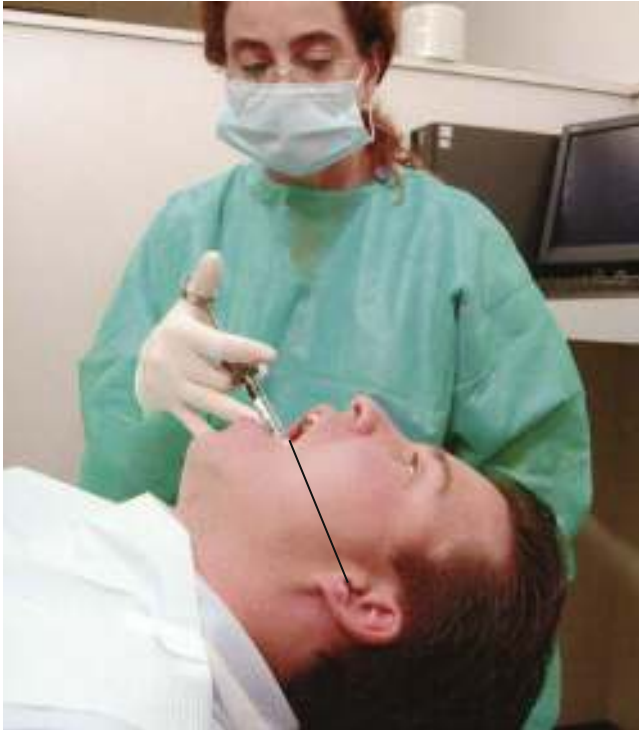• **Fig. 14.19** Intraoral landmarks for a Gow-Gates mandibular block. The tip of the needle is placed just below the mesiolingual cusp of the maxillary second molar (A) and is moved to a point just distal to the molar (B), maintaining the height established in the preceding step. This is the insertion point for the Gow-Gates mandibular nerve block.

- essential to the success of the Gow-Gates mandibular nerve block, but in the author's experience, palpation of this familiar intraoral landmark provides a sense of security, enables the soft tissues to be retracted, and aids in determination of the site of needle penetration.
- e. Visualize the intraoral landmarks:
 - i. Mesiolingual (mesiopalatal) cusp of the maxillary second molar.
 - ii. Needle penetration site is just distal to the maxillary second molar at the height of the tip of its mesiolingual cusp.
 - f. Prepare tissues at the site of penetration:
 - i. Dry tissues with sterile gauze.
 - ii. Apply topical antiseptic (optional).
 - iii. Apply topical anesthetic for minimum of 1 minute.
 - g. Stretch the tissues on the lingual aspect of the ramus, making them taut. If possible, use a mouth mirror to minimize the risk of accidental needlestick injury to the administrator.
 - h. Direct the syringe (held in your right hand) toward the site of injection from the corner of the mouth on the opposite side (as in IANB).
 - i. Insert the needle gently into tissues at the injection site just distal to the maxillary second molar at the height of its mesiolingual (mesiopalatal) cusp.
 - j. Align the needle with the plane extending from the corner of the mouth on the opposite side to the intertragic notch on the side of injection. It should be parallel to the angle between the ear and the face (Fig. 14.21).
 - k. Direct the syringe toward the target area on the tragus.
 - i. The syringe barrel lies in the corner of the mouth over the premolars, but its position may vary from molars to incisors, depending on the divergence of the ramus as assessed by the angle of the ear to the side of the face (Fig. 14.22).
 - ii. The height of insertion above the mandibular occlusal plane is considerably greater (10 to 25 mm, depending on the patient's size) than that for the IANB.
 - iii. When a maxillary third molar is present in a normal occlusion, the site of needle penetration is just distal to that tooth.



• **Fig. 14.20** Position of the patient for a Gow-Gates mandibular nerve block.

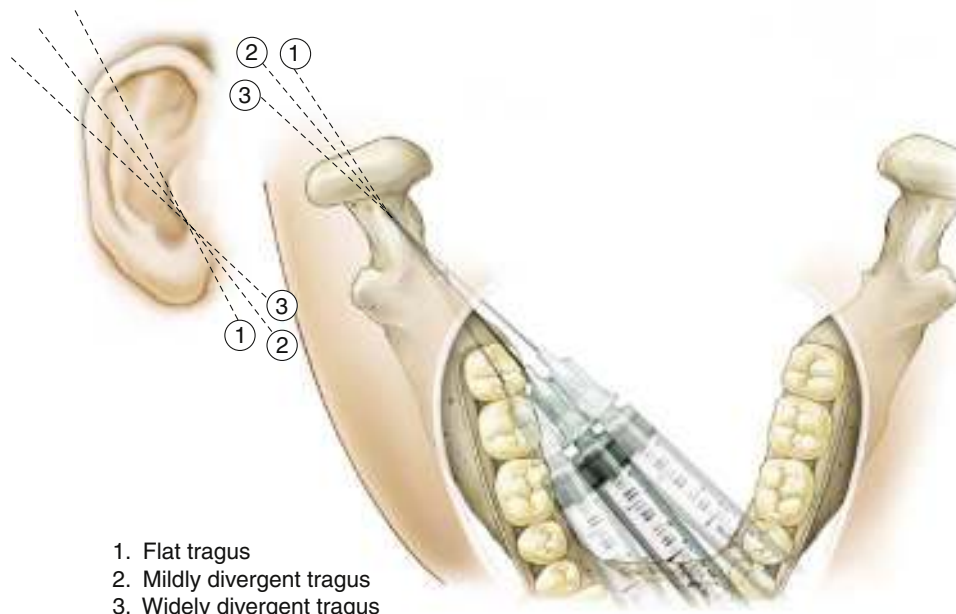
- i. Slowly advance the needle until bone is contacted.
 - i. Bone contacted is the neck of the condyle.
 - ii. The average distance from the skin to bone is 25 mm. Some variation is observed. For a given patient, the depth of soft tissue penetration with the Gow-Gates mandibular nerve block approximates that with the IANB.
 - iii. If bone is not contacted. The most common cause of failure to contact bone are:
 - a. Once the patient closes their mouth even slightly, two negatives occur: (1) the thickness of



• **Fig. 14.21** The barrel of the syringe and the needle are held parallel to a line connecting the corner of the mouth and the intertragic notch.

soft tissue increases and (2) the condyle moves in a distal direction. Both of these make it more difficult to locate the condylar neck with the needle. This occurs most often when the administrator is still “learning” the Gow-Gates mandibular nerve block technique and is tentative in advancing the needle toward the target area. If bone is not contacted, withdraw the needle slightly, ask the patient to open his or her mouth wider, and readvance the needle until bone is contacted.

- b. Medial deflection of the needle. Move the barrel of the syringe somewhat more distally, thereby angulating the needle tip anteriorly, and readvance the needle until contact with bone is made.
- iv. If bone is not contacted, do not deposit any local anesthetic.
- m. Withdraw the needle 1 mm.
- n. Aspirate in two planes.
- o. If positive, withdraw the needle slightly, angle it superiorly, reinsert, reaspirate, and, if now negative, deposit the solution. Positive aspiration usually occurs in the internal maxillary artery, which is located inferior to the target area. The positive aspiration rate with the Gow-Gates mandibular nerve block technique is approximately 2%.^{37,38}
- p. If negative, slowly deposit 1.8 mL of solution over 60 to 90 seconds. Gow-Gates originally recommended that 3 mL of anesthetic be deposited.³⁷ However, experience with the Gow-Gates mandibular nerve block shows that 1.8 mL is usually adequate to provide clinically acceptable anesthesia in virtually all cases. When partial anesthesia develops after administration of 1.8 mL, a second injection of approximately 1.2 mL is recommended.
- q. Withdraw the syringe and make the needle safe.
- r. Have the patient keep his or her mouth open for 1 to 2 minutes after the injection to permit diffusion of the anesthetic solution. Use of a bite block will aid the patient in keeping the mouth open.



1. Flat tragus
2. Mildly divergent tragus
3. Widely divergent tragus

• **Fig. 14.22** The location of the syringe barrel depends on the divergence of the tragus.

- s. After completion of the injection, return the patient to the upright or semiupright position.
- t. Wait a minimum of 2 minutes for a successful anesthesia (using a freezing spray, such as Endo-Ice, or an EPT). Onset of anesthesia with the Gow-Gates mandibular nerve block may be somewhat slower, requiring 5 minutes or longer for the following reasons:
 - i. Greater diameter of the nerve trunk at the site of injection.
 - ii. Distance (5 to 10 mm) from the anesthetic deposition site to the nerve trunk.

Signs and Symptoms

1. Subjective: Tingling or numbness of the lower lip indicates anesthesia of the mental nerve, a terminal branch of the inferior alveolar nerve. It is also a good indication that the IAN may be anesthetized.
2. Subjective: Tingling or numbness of the tongue indicates anesthesia of the lingual nerve, a branch of the posterior division of the mandibular nerve. It is always present in a successful Gow-Gates mandibular nerve block.
3. Objective: use of a freezing spray (e.g., Endo-Ice) or an EPT with no response to maximal output (80/80) on two consecutive tests at least 2 minutes apart serves as a “guarantee” (~99%) of successful pulpal anesthesia in nonpulpitic teeth.^{27,31,32}
4. Objective: no pain is felt during dental therapy.

Safety Features

1. Needle contacting bone, thereby preventing overinsertion
2. Very low positive aspiration rate (2%); minimizes the risk of intravascular injection (the internal maxillary artery lies inferior to the injection site)

Precautions

If bone is not contacted, do not deposit any local anesthetic:

1. Withdraw the needle slightly.
2. Ask the patient to open his or her mouth wider.
3. Reinsert the needle. Make gentle contact with bone.
4. Withdraw the needle 1 mm and aspirate in two planes.
5. Inject if aspirations are negative.

Failures of Anesthesia

Rare with the Gow-Gates mandibular nerve block once the administrator has become familiar with the technique:

1. Too little volume. The greater diameter of the mandibular nerve may require a larger volume of anesthetic solution. Deposit up to 1.2 mL in a second injection if the depth of anesthesia is inadequate after the initial 1.8 mL.
2. Anatomic difficulties. Do not deposit anesthetic unless bone is contacted.

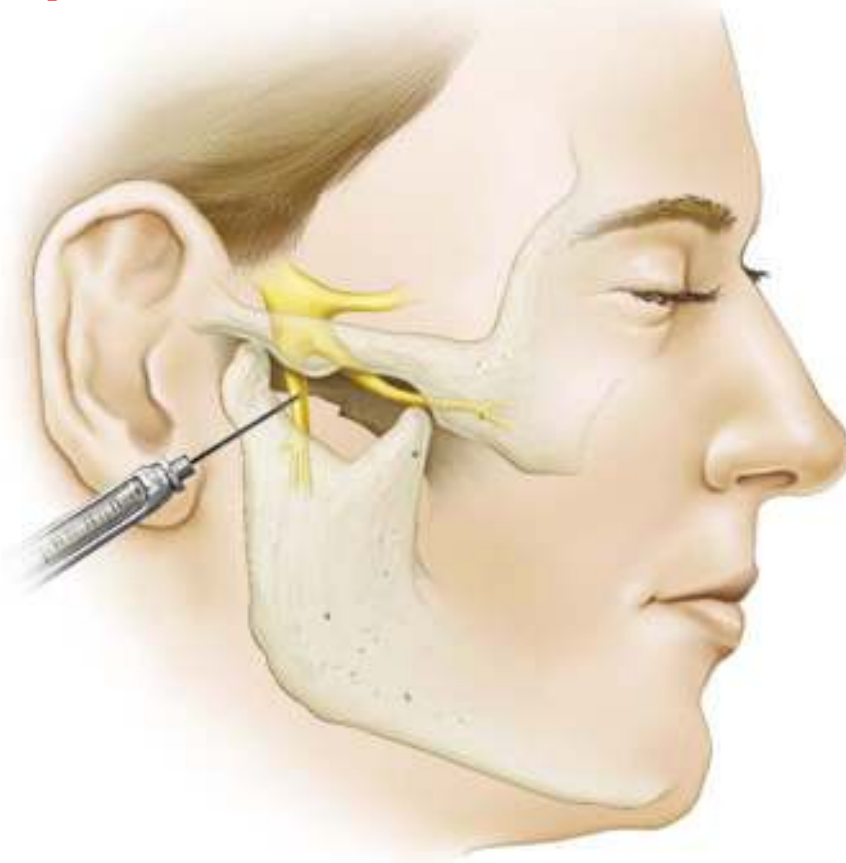
Complications

1. Hematoma (<2% incidence of positive aspiration)
2. Trismus (extremely rare)
3. Temporary paralysis of cranial nerves III, IV, and VI. In a case of cranial nerve paralysis after a right Gow-Gates mandibular nerve block, diplopia, right-sided blepharoptosis, and complete paralysis of the right eye persisted for 20 minutes after the injection. This occurred after the accidental rapid intravenous administration of local anesthetic.⁴² Fa et al.⁴³ reported transit occurrence of diplopia following Gow-Gates mandibular nerve block. The recommendations of Gow-Gates include placing the needle on the lateral side of the anterior surface of the condyle, aspirating carefully, and depositing local anesthetic solution slowly.^{37,38} If bone is not contacted, anesthetic solution should not be administered.
4. Middle ear problems. Brodsky and Dower⁴⁴ reported a case of transient middle ear problems following administration of the Gow-Gates mandibular nerve block. Over the course of 10 days, the patient complained of inner ear pressure, inability to equilibrate ear pressure, decreased hearing, pain, and severe headache before returning to normal without further complaints and complications. The cause of the complication was considered to be either hematoma, a technique problem causing trauma and inflammation, an anatomic variation, or any combination of these.

Vazirani-Akinosi Closed-Mouth Mandibular Block

The introduction of the Gow-Gates mandibular nerve block in 1973 spurred interest in alternative methods of achieving anesthesia in the lower jaw. In 1977, Dr. Joseph Akinosi reported on a closed-mouth approach to mandibular anesthesia.¹⁹ Earlier, in 1960, Dr. Sundar Vazirani had published an article describing a technique that was quite similar to that of Akinosi.¹⁸ Both are credited with this closed-mouth mandibular block technique, variously called the *Akinosi-Vazirani technique* or the *Vazirani-Akinosi technique*. Although this technique can be used whenever mandibular anesthesia is desired, its primary indication remains those situations where limited mandibular opening precludes the use of other mandibular injection techniques. Such situations include the presence of spasm of the muscles of mastication (trismus) on one side of the mandible after numerous attempts at IANB, as might occur with a “hot” mandibular molar (symptomatic irreversible pulpitis). In this instance, multiple injections may have been necessary to provide anesthesia adequate to extirpate the pulpal tissues of the involved mandibular molar. When the anesthetic effect resolves hours later, the muscles into which the anesthetic solution was deposited become tender, producing some discomfort on opening the jaw. During a period of sleep, when the muscles are not in use, the muscles go into spasm (the same way one’s leg muscles might go into spasm after strenuous exercise, making it difficult to stand or walk the next morning), leaving the patient with significantly reduced occlusal opening in the morning.

PDF Compressor Free Version



• **Fig. 14.23** Extraoral mandibular block using a lateral approach through the sigmoid notch. (Redrawn from Bennett CR: *Monheim's local anesthesia and pain control in dental practice*, ed 6, St Louis, 1978, Mosby.)

The management of trismus is reviewed in [Chapter 17](#).

If it is necessary to continue dental care in the patient with significant trismus, the options for providing mandibular anesthesia are extremely limited. Inferior alveolar and Gow-Gates mandibular nerve blocks cannot be attempted when significant trismus is present. Extraoral mandibular nerve blocks can be attempted and, indeed, possess a significantly high success rate in experienced hands. Extraoral mandibular blocks can be administered through the sigmoid notch or inferiorly from the chin ([Fig. 14.23](#)).^{45,46} Because the mandibular division of the trigeminal nerve provides motor innervation to the muscles of mastication, a third division (V_3) block will relieve trismus that is produced secondary to muscle spasm. (Trismus may also result from other causes.) Although dentists can administer extraoral nerve blocks, few in clinical practice actually do so. The Vazirani-Akinosi technique is an intraoral approach to providing both anesthesia and motor blockade in cases of severe unilateral trismus.

In 1992 Wolfe described a modification of the original Vazirani-Akinosi technique.⁴⁷ The technique described was

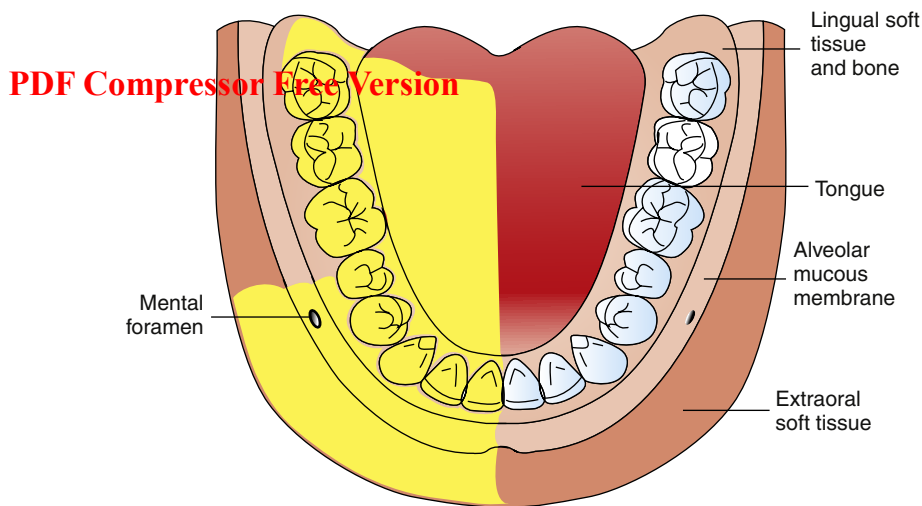
identical to the original technique except that Wolfe recommended bending the needle at a 45-degree angle to enable it to remain close to the medial (lingual) side of the mandibular ramus as the needle is advanced through the tissues. Because the potential for needle breakage is increased when the needle bent, bending any needle that is to be inserted into tissues to any significant depth cannot be recommended by this author. The Vazirani-Akinosi closed-mouth mandibular block can be administered successfully without bending the needle.

Other Common Names

Akinosi technique, closed-mouth mandibular nerve block, tuberosity technique.

Nerves Anesthetized

1. Inferior alveolar nerve
2. Incisive nerve
3. Mental nerve
4. Lingual nerve
5. Mylohyoid nerve



• **Fig. 14.24** Area anesthetized by a Vazirani-Akinosi closed-mouth mandibular nerve block.

Areas Anesthetized

1. Mandibular teeth to the midline (Fig. 14.24)
2. Body of the mandible and inferior portion of the ramus
3. Buccal mucoperiosteum and mucous membrane anterior to the mental foramen
4. Anterior two-thirds of the tongue and floor of the oral cavity (lingual nerve)
5. Lingual soft tissues and periosteum (lingual nerve)

Indications

1. Limited mandibular opening
2. Multiple procedures on mandibular teeth
3. Inability to visualize landmarks for IANB (e.g., because of large tongue)

Contraindications

1. Infection or acute inflammation in the area of injection (rare)
2. Patients who might bite their lip or their tongue, such as young children and physically or mentally handicapped adults
3. Inability to visualize or gain access to the lingual aspect of the ramus

Advantages

1. Relatively atraumatic
2. Patient need not be able to open the mouth.
3. Fewer postoperative complications (e.g., trismus)
4. Lower aspiration rate (<10%) than with the IANB
5. Provides successful anesthesia where a bifid IAN and bifid mandibular canals are present

Disadvantages

1. Difficult to visualize the path of the needle and the depth of insertion

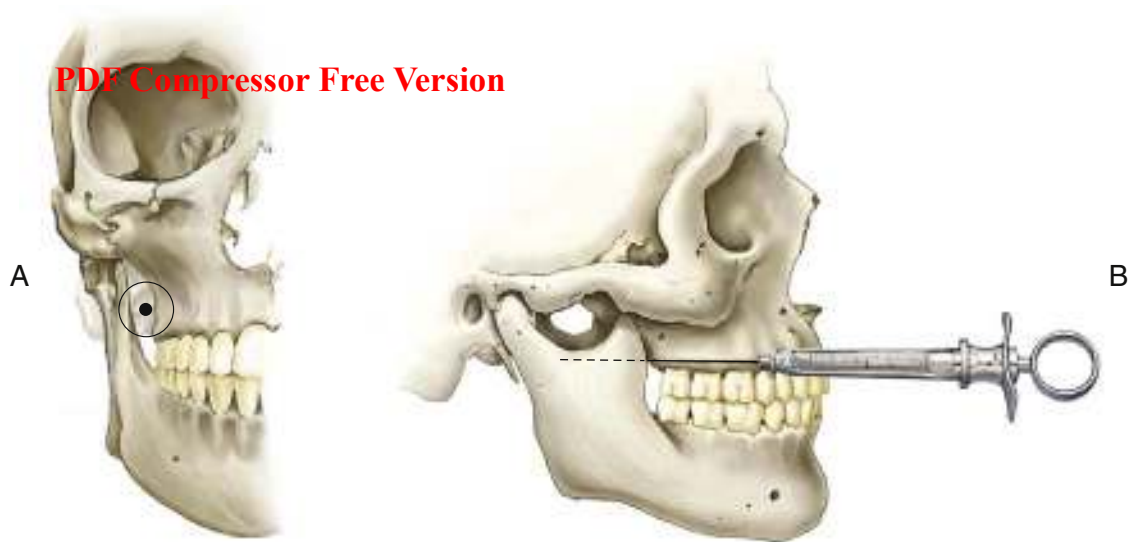2. No bony contact; depth of penetration somewhat arbitrary
3. Potentially traumatic if the needle is too close to the periosteum

Alternatives

No intraoral nerve blocks are available. If a patient is unable to open his or her mouth because of trauma, infection, or postinjection trismus, no other suitable intraoral techniques are available. The extraoral mandibular nerve block may be used when the doctor is well versed in the procedure.

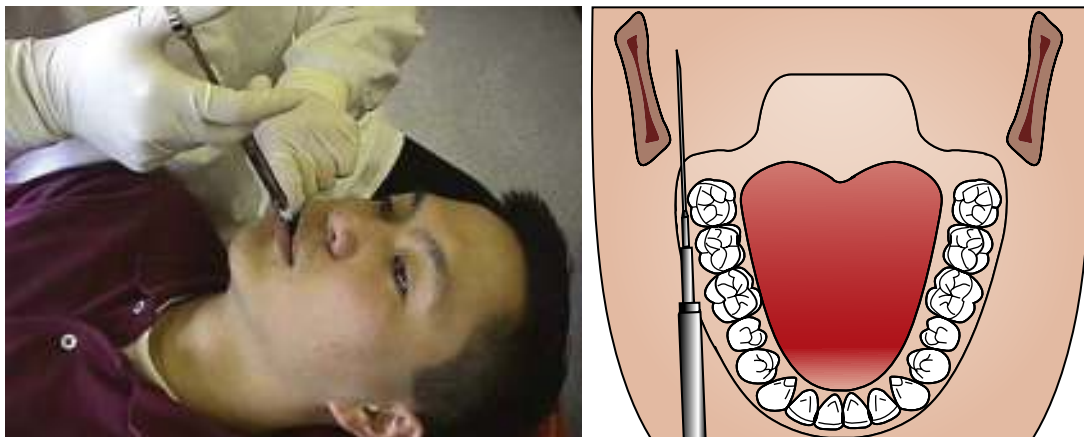
Technique

1. A 25-gauge long needle is recommended (although a 27-gauge long may be preferred in patients whose ramus flares laterally more than usual).
2. Area of insertion: soft tissue overlying the medial (lingual) border of the mandibular ramus directly adjacent to the maxillary tuberosity at the height of the mucogingival junction adjacent to the maxillary third molar (Fig. 14.25).
3. Target area: soft tissue on the medial (lingual) border of the ramus in the region of the inferior alveolar, lingual, and mylohyoid nerves as they run inferiorly from the foramen ovale toward the mandibular foramen (the height of injection with the Vazirani-Akinosi closed-mouth mandibular nerve block being below that of the Gow-Gates mandibular nerve block but above that of the IANB).
4. Landmarks:
 - a. Mucogingival junction of the maxillary third (or second) molar.
 - b. Maxillary tuberosity.
 - c. Coronoid notch on the mandibular ramus.
5. Orientation of the bevel (bevel orientation in the closed-mouth mandibular block is very important): the bevel *must* be oriented away from the bone of the mandibular ramus (e.g., bevel faces toward the midline).



PDF Compressor Free Version

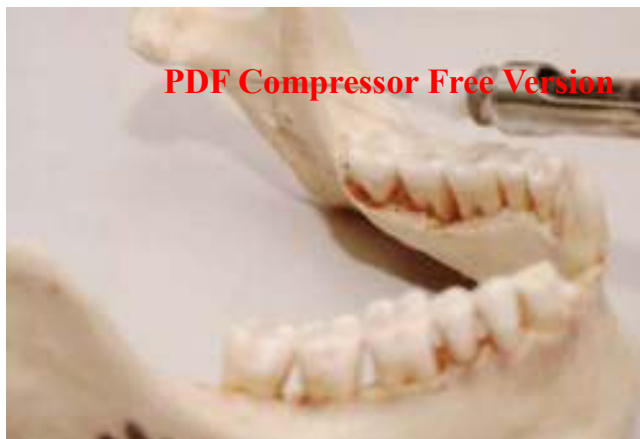• **Fig. 14.25** (A) Area of needle insertion for a Vazirani-Akinosi closed-mouth mandibular nerve block. (B) Hold the syringe and needle at the height of the mucogingival junction above the maxillary third molar. (Redrawn from Gustainis JF, Peterson LJ: An alternative method of mandibular nerve block, *J Am Dent Assoc* 103:33–36, 1981.)



• **Fig. 14.26** Vazirani-Akinosi closed-mouth mandibular nerve block. The barrel of the syringe is held parallel to the maxillary occlusal plane with the needle at the level of the mucogingival junction of the second or third maxillary molar.

6. Procedure:

- a. Assume the correct position. For a right or a left Vazirani-Akinosi closed-mouth mandibular nerve block, a right-handed administrator should sit at the 8 o'clock position facing the patient.
- b. Position the patient supine (recommended) or semisupine.
- c. Place your left index finger or thumb on the coronoid notch, reflecting the tissues on the medial aspect of the ramus laterally. Reflecting the soft tissues aids in visualization of the injection site and decreases trauma during needle insertion.
- d. Visualize landmarks:
 - i. Mucogingival junction of the maxillary third or second molar.
 - ii. Maxillary tuberosity.
- e. Prepare the tissues at the site of penetration:
 - i. Dry them with sterile gauze.
 - ii. Apply topical antiseptic (optional).
 - iii. Apply topical anesthetic for minimum of 1 minute.
- f. Ask the patient to occlude his or her teeth gently with the cheeks and muscles of mastication relaxed.
- g. Reflect the soft tissues on the medial border of the ramus laterally. If possible, use a mouth mirror to minimize the risk of accidental needlestick injury to the administrator.
- h. The barrel of the syringe is held parallel to the maxillary occlusal plane, with the needle at the level of the mucogingival junction of the maxillary third (or second) molar (Fig. 14.25).
- i. Direct the needle posteriorly and slightly laterally, so it advances at a tangent to the posterior maxillary alveolar process and parallel to the maxillary occlusal plane.
- j. Orient the bevel away from the mandibular ramus; thus as the needle advances through tissues, needle deflection occurs toward the ramus and the needle remains close to the IAN (Fig. 14.26).



• **Fig. 14.27** Advance the needle posteriorly into tissues on the medial side of the mandibular ramus.

- k. Advance the needle 25 mm into tissue (for an average-sized adult). This distance is measured from the maxillary tuberosity. The tip of the needle should lie in the midportion of the pterygomandibular space, close to the branches of V_3 (Fig. 14.27).
- l. Aspirate in two planes.
- m. If negative, deposit 1.5 to 1.8 mL of anesthetic solution in approximately 60 seconds.
- n. Withdraw the syringe slowly and immediately make the needle safe.
- o. After the injection, return the patient to an upright or semiupright position.
- p. Motor nerve paralysis develops as quickly as, if not more quickly than, sensory anesthesia. The patient with trismus begins to notice increased ability to open the jaws shortly after the deposition of anesthetic.
- q. Anesthesia of the lip and tongue is noted to start in about 1 to 1.5 minutes; the dental procedure can usually start within 5 minutes.
- r. When motor paralysis is present but sensory anesthesia is inadequate to permit the dental procedure to begin, since the patient can now open his or her jaw, perform an IANB, Gow-Gates mandibular nerve block, incisive nerve block, PDL, or intraosseous injection or infiltrate articaine hydrochloride into the buccal fold adjacent to the tooth to be treated.

Signs and Symptoms

1. Subjective: Tingling or numbness of the lower lip indicates anesthesia of the mental nerve, a terminal branch of the inferior alveolar nerve, which is a good sign that the IAN has been anesthetized.
2. Subjective: Tingling or numbness of the tongue indicates anesthesia of the lingual nerve, a branch of the posterior division of the mandibular nerve.
3. Objective: Use of a freezing spray (e.g., Endo-Ice) or an EPT with no response to maximal output (80/80) on two consecutive tests at least 2 minutes apart serves as a “guarantee” (~99%) of successful pulpal anesthesia in nonpulpitic teeth.^{27,31,32}
4. Objective: No pain is felt during dental therapy.

Safety Feature

Decreased risk of positive aspiration (compared with the IANB).

Precaution

Do not overinsert the needle (>25 mm). Decrease the depth of penetration in smaller patients; the depth of insertion will vary with the anteroposterior width of the patient’s ramus.

Failures of Anesthesia

1. Almost always because of failure to appreciate the flaring nature of the ramus. If the needle is directed medially, it rests medial to the sphenomandibular ligament in the pterygomandibular space, and the injection fails. This occurs more commonly when a right-handed administrator uses the left-side Vazirani-Akinosi injection (or a left-handed administrator uses the right-side Vazirani-Akinosi injection). It may be prevented by directing the needle tip parallel to the lateral flare of the ramus and by using a 27-gauge needle in place of a 25-gauge needle.
2. Needle insertion point too low. To correct this, insert the needle at or slightly above the level of the mucogingival junction of the last maxillary molar. The needle also must remain parallel to the occlusal plane as it advances through the soft tissues.
3. Underinsertion or overinsertion of the needle. Because no bone is contacted in the Vazirani-Akinosi technique, the depth of soft tissue penetration is somewhat arbitrary. Akinosi recommended a penetration depth of 25 mm in the average-sized adult, measuring from the maxillary tuberosity. In smaller or larger patients, this depth of penetration should be altered.

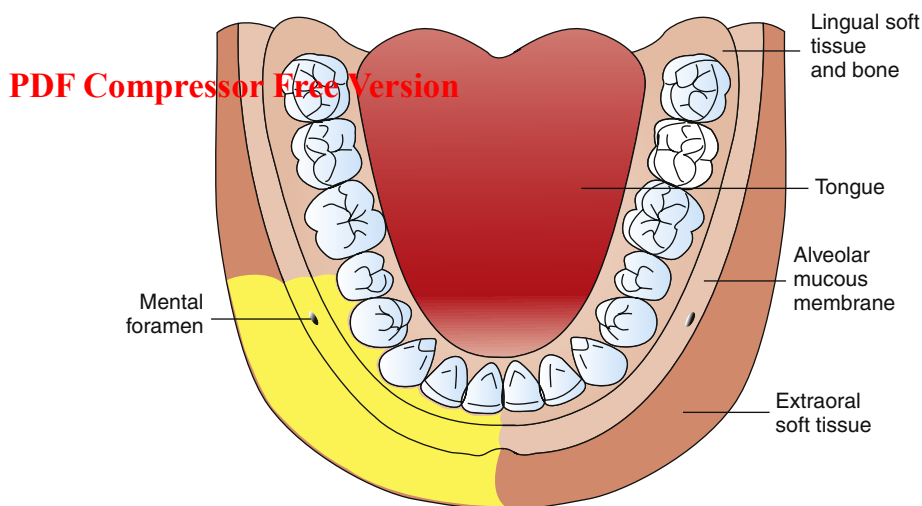
Complications

1. Hematoma (<10%)
2. Trismus (rare)
3. Transient facial nerve (VII) paralysis:
 - a. This is caused by overinsertion and injection of the local anesthetic solution into the body of the parotid gland.
 - b. It can be prevented by modification of the depth of needle penetration based on the length of the mandibular ramus. The 25-mm depth of penetration is average for a normal-sized adult.

Once learned, the Akinosi-Vazirani closed-mouth mandibular block technique has success rates that are comparable to those of the Gow-Gates mandibular nerve block and conventional IANB.^{48,49}

Mental Nerve Block

The mental nerve is a terminal branch of the inferior alveolar nerve. Exiting the mental foramen at or near the apices



• Fig. 14.28 Area anesthetized by mental nerve block.

of the mandibular premolars, it provides sensory innervation to the buccal soft tissues lying anterior to the foramen and the soft tissues of the lower lip and chin on the side of injection.

For most dental procedures, there is very little indication for use of the mental nerve block. Indeed, of the techniques described in this chapter, the mental nerve block is the least frequently used. It is used primarily for buccal soft tissue procedures, such as suturing of lacerations or biopsies. Its success rate approaches 100% because of the ease of accessibility to the nerve.

Other Common Names

None.

Nerve Anesthetized

Mental nerve, a terminal branch of the inferior alveolar nerve.

Areas Anesthetized

Buccal mucous membranes anterior to the mental foramen (around the second premolar) to the midline and skin of the lower lip (Fig. 14.28) and chin.

Indication

When buccal soft tissue anesthesia is necessary for procedures in the mandible anterior to the mental foramen, such as:

1. soft tissue biopsies
2. suturing of soft tissues

Contraindication

Infection or acute inflammation in the area of injection.

Advantages

1. High success rate
2. Technically easy
3. Usually entirely atraumatic

Disadvantage

Hematoma.

Positive Aspiration

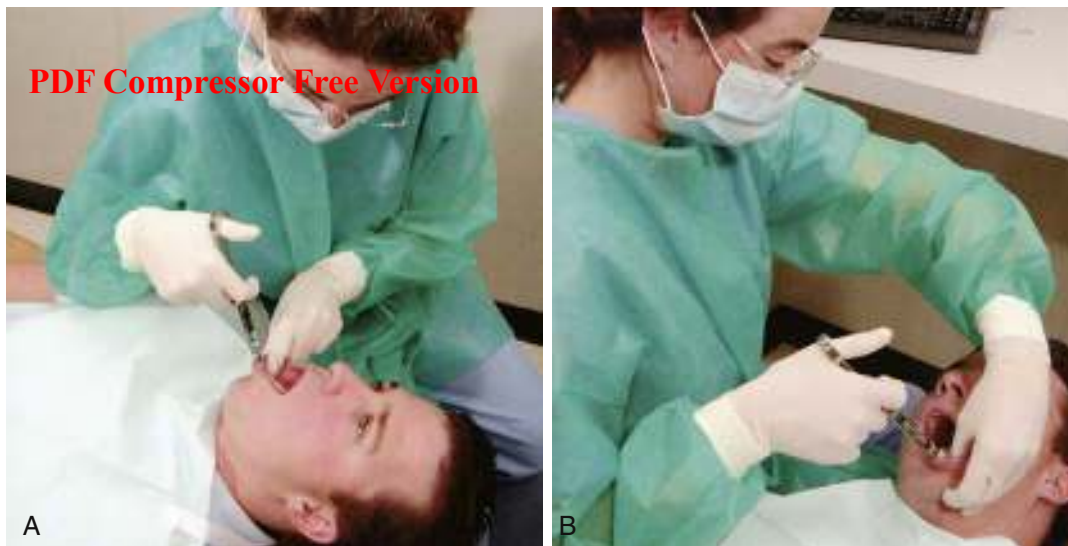
Approximately 5.7%.

Alternatives

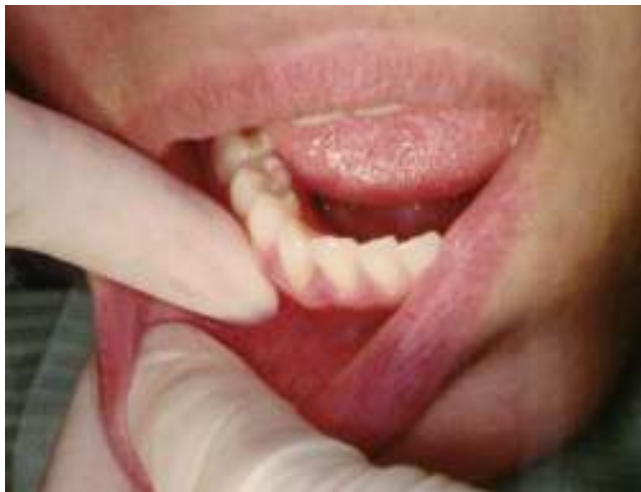1. Local infiltration
2. IANB
3. Gow-Gates mandibular nerve block
4. Vazirani-Akinosi closed-mouth mandibular nerve block

Technique

1. A 25- or 27-gauge short needle is recommended.
2. Area of insertion: mucobuccal fold at or just anterior to the mental foramen.
3. Target area: mental nerve as it exits the mental foramen (usually located between the apices of the first and second premolars).
4. Landmarks: mandibular premolars and mucobuccal fold.
5. Orientation of the bevel: toward bone during the injection.
 - a. Assume the correct position:
 - i. For a right or left mental nerve block, a right-handed administrator should sit comfortably in front of the patient so that the syringe may be placed into the mouth below the patient's line of sight (Fig. 14.29).
 - b. Position the patient:
 - i. Supine is recommended, but semisupine is acceptable.



• **Fig. 14.29** Position of the administrator for a right mental/incisive nerve block (A) and left mental/incisive nerve block (B).



• **Fig. 14.30** Locate the mental foramen by moving the fleshy pad of your finger anteriorly until the bone beneath becomes irregular and somewhat concave.

- ii. Have the patient partially close their mouth. This permits greater access to the injection site.
- c. Locate the mental foramen.
 - i. Place your index finger in the mucobuccal fold and press against the body of the mandible in the first molar area.
 - ii. Move your finger slowly anteriorly until the bone beneath your finger feels irregular and somewhat concave (Fig. 14.30).
 - a. The bone posterior and anterior to the mental foramen is smooth; however, the bone immediately around the foramen is rougher to the touch.
 - b. The mental foramen usually is found around the apex of the second premolar. However, it may be found anterior or posterior to this site.

The patient may comment that finger pressure in this area produces soreness as the mental nerve is compressed against bone.

- iii. If radiographs are available, the mental foramen may be located easily (Fig. 14.31).
- d. Prepare tissue at the site of penetration.
 - i. Dry it with sterile gauze.
 - ii. Apply topical antiseptic (optional).
 - iii. Apply topical anesthetic for minimum of 1 minute.
- e. With your left index finger, pull the lower lip and buccal soft tissues laterally, if possible using a mouth mirror (to minimize the risk of accidental needle stick injury to the administrator).
 - i. Visibility is improved.
 - ii. Taut tissues permit atraumatic penetration.
- f. Orient the syringe with the bevel directed toward bone.
- g. Penetrate the mucous membrane at the injection site, at the canine or first premolar, directing the syringe toward the mental foramen (Fig. 14.32).
- h. Advance the needle slowly until the foramen is reached. The depth of penetration is 5 to 6 mm. For the mental nerve block to be successful, there is no need to enter the mental foramen or to contact bone.
 - i. Aspirate in two planes.
 - j. If negative, slowly deposit 0.6 mL (approximately one-third of a cartridge) over 20 seconds. If tissue at the injection site balloons (swells as the anesthetic is injected), stop the deposition and remove the syringe.
 - k. Withdraw the syringe and immediately make the needle safe.
 - i. Wait 2 to 3 minutes before commencing the procedure.

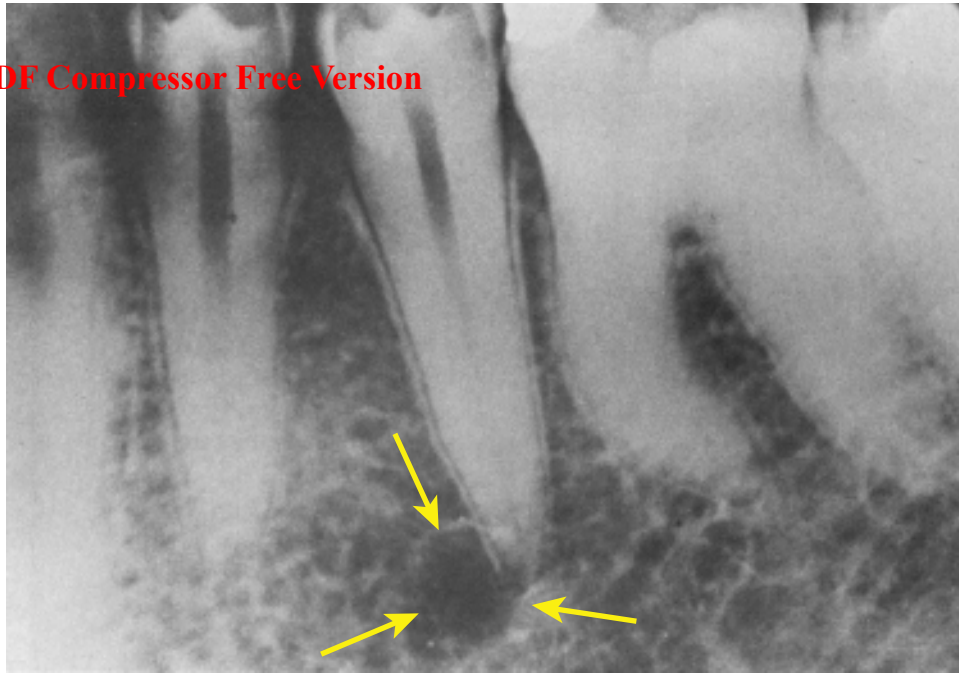
Signs and Symptoms

1. Subjective: tingling or numbness of the lower lip
2. Objective: no pain during treatment

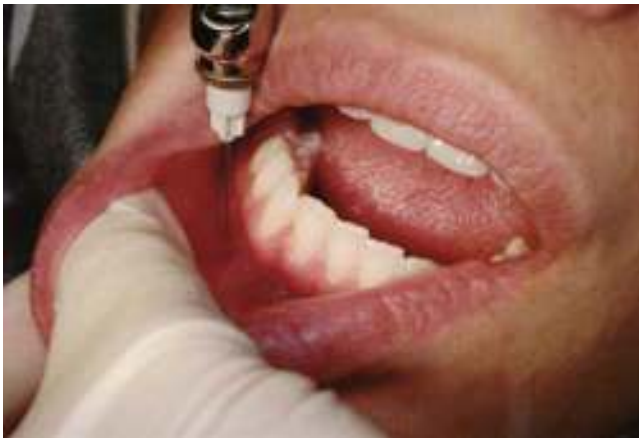Safety Feature

The region is anatomically “safe.”

PDF Compressor Free Version



• **Fig. 14.31** Radiographs can assist in locating the mental foramen (arrows). (Courtesy Dr. Robert Ziehm.)



• **Fig. 14.32** Mental nerve block—needle penetration site.

Precautions

Striking the periosteum produces discomfort. To prevent this, avoid contact with the periosteum or deposit a small amount of solution before contacting the periosteum.

Failures of Anesthesia

Rare with the mental nerve block.

Complications

1. Few of consequence.
2. Hematoma (bluish discoloration and tissue swelling at the injection site). Blood may exit the needle puncture point into the buccal fold. To treat this, apply pressure with gauze directly to the area of bleeding for at least 2 minutes (see Fig. 17.2).

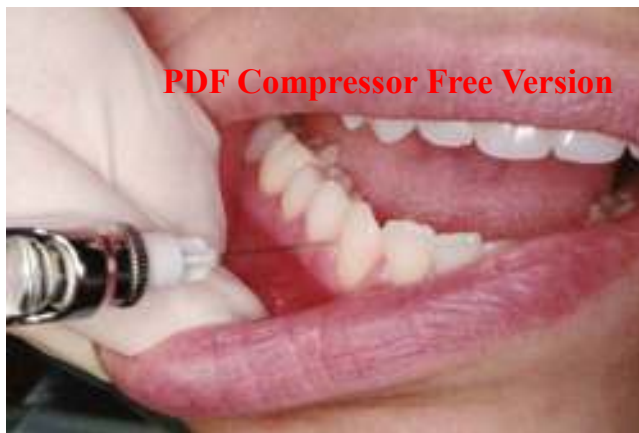3. Paresthesia of lip and/or chin. Contact of the needle with the mental nerve as it exits the mental foramen may lead to the sensation of an “electric shock” or to various degrees of paresthesia (rare).

Incisive Nerve Block

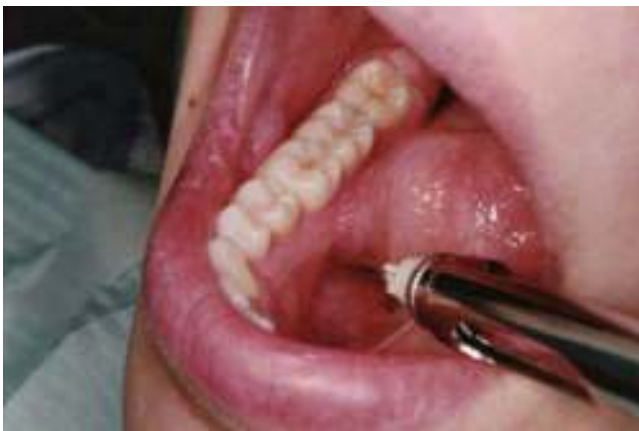The incisive nerve is a terminal branch of the inferior alveolar nerve. Originating as a direct continuation of the IAN at the mental foramen, the incisive nerve travels anteriorly in the incisive canal, providing sensory innervation to those teeth located anterior to the mental foramen. The nerve is always anesthetized when an inferior alveolar or mandibular nerve block is successful; therefore the incisive nerve block is not necessary when these blocks are administered.

The premolars, canine, and lateral and central incisors, including their buccal soft tissues and bone, are anesthetized when the incisive nerve block is administered.^d An important indication for the incisive nerve block is when the procedure contemplated involves both the right side and the left side of the mandible. It is this author's belief that bilateral inferior alveolar or mandibular nerve blocks are seldom needed (except in the case of bilateral surgical procedures in the mandible) because of the degree of discomfort and the inconvenience experienced by the patient both during and after the procedure. Where dental treatment involves bilateral procedures on mandibular premolars and anterior teeth, bilateral incisive nerve blocks can be administered. Pulpal, buccal soft tissue, and osseous anesthesia is readily obtained. Lingual soft tissues are not anesthetized with this block. If lingual soft tissues in very isolated areas require

^dThe second premolar may not be anesthetized with this technique if the mental foramen lies beneath the first premolar.



• **Fig. 14.33** To obtain lingual anesthesia after the incisive nerve block, insert the needle interproximally from buccal and deposit anesthetic as the needle is advanced toward lingual.



• **Fig. 14.34** Retract the tongue to gain access to, and increase the visibility of, the lingual border of the mandible.

anesthesia, local infiltration can be readily accomplished by advancement of a 27-gauge short needle through the interdental papillae on both the mesial aspect and the distal aspect of the tooth being treated. Because the buccal soft tissues are already anesthetized (incisive nerve block), the penetration is atraumatic. Local anesthetic solution should be deposited as the needle is advanced through the tissue toward the lingual side of the mandible (Fig. 14.33). This technique provides lingual soft tissue anesthesia adequate for deep curettage, root planing, and subgingival preparations. Where there is a significant requirement for lingual soft tissue anesthesia, an IANB or Gow-Gates mandibular nerve block should be administered on that side, with the incisive nerve block administered on the contralateral side. In this manner, the patient does not have to endure bilateral anesthesia of the tongue, which is a very disconcerting experience for many patients.

Another method of obtaining lingual anesthesia after the incisive nerve block is to administer a partial lingual nerve block (Fig. 14.34). Using a 25-gauge long needle, deposit 0.3 to 0.6 mL of local anesthetic under the lingual mucosa just distal to the last tooth to be treated. This provides lingual soft tissue anesthesia adequate for any dental procedure in this area.

The danger in this procedure is that the lingual nerve may be inadvertently contacted by the needle, inducing the sensation of an “electric shock” or various degrees of paresthesia.

It is not necessary for the needle to enter the mental foramen for an incisive nerve block to be successful. The first edition of this book and other textbooks on local anesthesia for dentistry recommended insertion of the needle into the foramen.^{46,50,51} At least two disadvantages are associated with the needle entering the mental foramen: (1) the administration of an incisive nerve block becomes technically more difficult and (2) the risk of traumatizing the mental or incisive nerves and their associated blood vessels is increased. As described in the following sections, for the incisive nerve block to be successful, the anesthetic should be deposited just outside the mental foramen and, under pressure, directed into the foramen. Indeed, the incisive nerve block may be considered the mandibular equivalent of the anterior superior alveolar nerve block, with the mental nerve block the equivalent of the infraorbital nerve block. Both of the disadvantages just mentioned are minimized by not entering the mental foramen.

Other Common Name

Mental nerve block (inappropriate when pulpal anesthesia is the desired goal).

Nerves Anesthetized

Mental and incisive nerves.

Areas Anesthetized

1. Buccal mucous membrane anterior to the mental foramen, usually from the second premolar to the midline (Fig. 14.35)
2. Lower lip and skin of the chin
3. Pulpal nerve fibers to the premolars, canine, and incisors

Indications

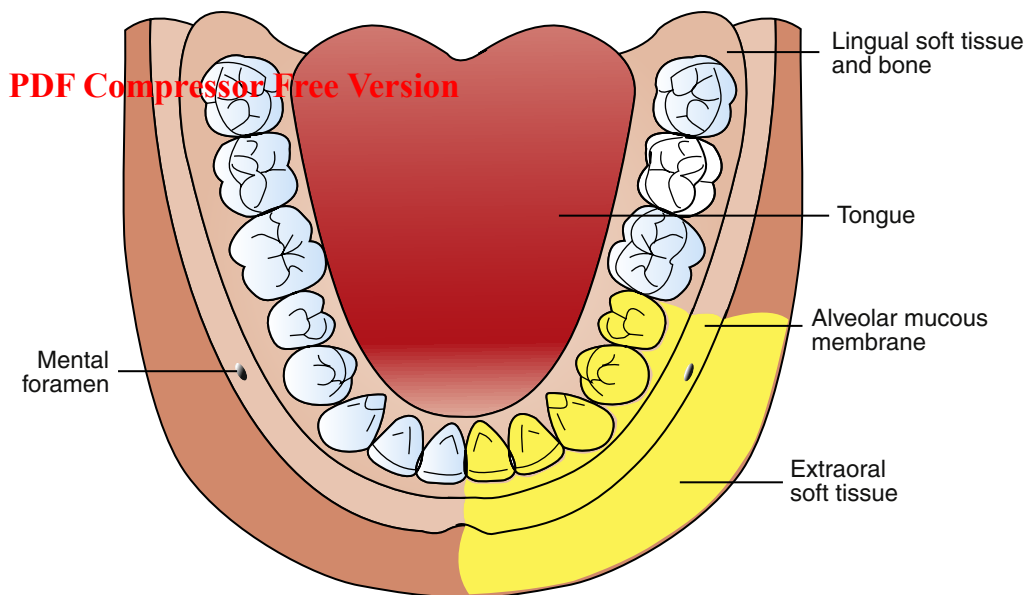
1. Dental procedures requiring pulpal anesthesia of mandibular teeth anterior to the mental foramen-
2. When IANB is not indicated:
 - a. When 6, 8, or 10 anterior teeth (e.g., canine to canine or premolar to premolar) are treated, the incisive nerve block is recommended in place of bilateral IANBs.

Contraindication

Infection or acute inflammation in the area of injection.

Advantages

1. Provides pulpal and osseous anesthesia without lingual anesthesia (lingual anesthesia is uncomfortable and unnecessary for many patients); useful in place of bilateral IANBs
2. High success rate



• Fig. 14.35 Area anesthetized by an incisive nerve block.

Disadvantages

1. Does not provide lingual anesthesia. The lingual tissues must be injected as described earlier if anesthesia is desired.
2. Partial anesthesia may develop at the midline because of nerve fiber overlap with the opposite side (extremely rare). Local infiltration of 0.9 mL of local anesthetic (preferably [buffered] articaine hydrochloride) in the buccal fold by the mandibular central incisors may be necessary for complete pulpal anesthesia to be obtained.

Positive Aspiration

Approximately 5.7%.

Alternatives

1. Local infiltration for buccal soft tissues and pulpal anesthesia of the central and lateral incisors
2. IANB
3. Gow-Gates mandibular nerve block
4. Vazirani-Akinosi mandibular nerve block
5. Periodontal ligament injection

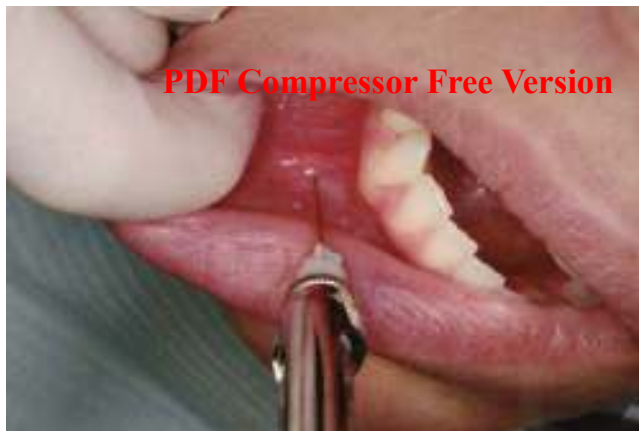Technique

1. A 27-gauge short needle is recommended.
2. Area of insertion: mucobuccal fold at or just anterior to the mental foramen.
3. Target area: mental foramen, through which the mental nerve exits and inside of which the incisive nerve is located.
4. Landmarks: Mandibular premolars and mucobuccal fold.
5. Orientation of the bevel: toward bone during the injection.
6. Procedure:

- a. Assume the correct position:
 - i. For a right or left incisive nerve block and a right-handed administrator, sit comfortably in front of the patient so that the syringe may be placed into the mouth below the patient's line of sight (see Fig. 14.29).
- b. Position the patient:
 - i. Supine is recommended, but semisupine is acceptable.
 - ii. Request that the patient partially close their mouth; this allows easier access to the injection site.
- c. Locate the mental foramen:
 - i. Place your thumb or index finger in the mucobuccal fold against the body of the mandible in the first molar area.
 - ii. Move it slowly anteriorly until you feel the bone become irregular and somewhat concave.
 - a. The bone posterior and anterior to the mental foramen feels smooth; however, the bone immediately around the foramen feels rougher.
 - b. The mental foramen is usually found at the apex of the second premolar; however, it may be found anterior or posterior to this site.

The patient may comment that finger pressure in this area produces soreness as the mental nerve is compressed against bone.

 - iii. If radiographs are available, the mental foramen may be located easily (see Fig. 14.31).
- d. Prepare tissues at the site of penetration:
 - i. Dry them with sterile gauze.
 - ii. Apply topical antiseptic (optional).
 - iii. Apply topical anesthetic for minimum of 1 minute.
- e. With your left index finger, pull the lower lip and buccal soft tissue laterally (Fig. 14.36). If possible, use a mouth mirror to minimize the risk of accidental needle stick injury to the administrator.
 - i. Visibility is improved.
 - ii. Taut tissues permit atraumatic penetration.

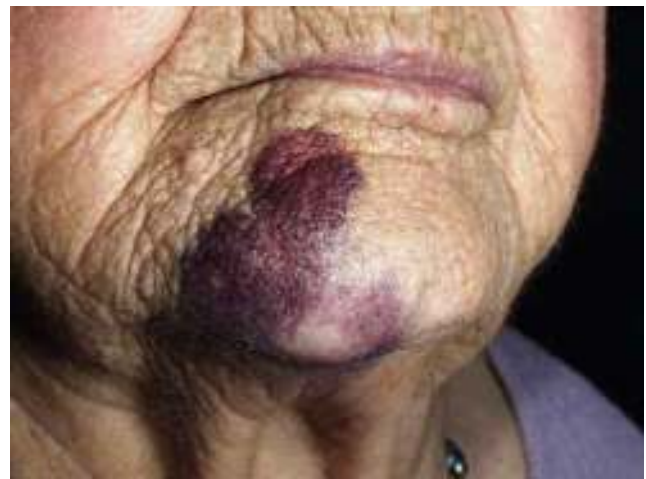

• **Fig. 14.36** Retract the lip to improve access and permit atraumatic needle insertion.

- f. Orient the syringe with the bevel toward bone.
- g. Penetrate mucous membrane at the canine or first premolar, directing the needle toward the mental foramen (Fig. 14.36).
- h. Advance the needle slowly until the mental foramen is reached. The depth of penetration is 5 to 6 mm. The needle tip should lie just outside the mental foramen. There is no need to enter the mental foramen for the incisive nerve block to be successful.
- i. Aspirate in two planes.
- j. If negative, slowly deposit 0.6 mL (approximately one-third of a cartridge) over 20 seconds.
 - i. During the injection, maintain gentle finger pressure directly over the injection site to increase the volume of solution entering the mental foramen. This may be accomplished with intraoral or extraoral pressure.
 - ii. Tissues at the injection site should balloon, but very slightly.
- k. Withdraw the syringe and immediately make the needle safe.
- l. Continue to apply pressure at the injection site, either intraorally or extraorally, for 2 minutes.
- m. Wait 3 to 5 minutes before commencing the dental procedure.
 - i. Anesthesia of the mental nerve (lower lip, buccal soft tissues) is observed within seconds of the deposition.
 - ii. Anesthesia of the incisive nerve requires additional time.

Signs and Symptoms

1. Subjective: Tingling or numbness of the lower lip.
2. Objective: Use of a freezing spray (e.g., Endo-Ice) or an EPT with no response to maximal output (80/80) on two consecutive tests at least 2 minutes apart serves as a “guarantee” (~99%) of successful pulpal anesthesia in nonpulpitic teeth.^{27,31,32}
3. Objective: No pain is felt during dental therapy.



• **Fig. 14.37** Hematoma that developed after bilateral mental nerve blocks.

Safety Feature

Anatomically “safe” region.

Precaution

Usually an atraumatic injection unless the needle contacts periosteum or solution is deposited too rapidly.

Failures of Anesthesia

1. Inadequate volume of anesthetic solution in the mental foramen, with subsequent lack of pulpal anesthesia. To correct this, reinject anesthetic solution into the proper region and apply pressure to the injection site.
2. Inadequate duration of pressure after injection. It is necessary to apply firm pressure over the injection site for a minimum of 2 minutes to force the local anesthetic into the mental foramen and provide anesthesia of the second premolar, which may be distal to the foramen. Failure to achieve anesthesia of the second premolar is usually caused by inadequate application of pressure after the injection.

Complications

1. Few of any consequence.
2. Hematoma (bluish discoloration and tissue swelling at injection site). Blood may exit the needle puncture site into the buccal fold (Fig. 14.37). To treat this, apply pressure with gauze directly to the area for 2 minutes. This is rarely a problem because a proper incisive nerve block protocol includes the application of pressure at the injection site for 2 minutes.
3. Paresthesia of lip and/or chin. Contact of the needle with the mental nerve as it exits the mental foramen may lead to the sensation of an “electric shock” or to various degrees of paresthesia (rare).

Table 14.1 summarizes the various injection techniques applicable for mandibular teeth. Table 14.2 summarizes the recommended volumes for the various injection techniques.

TABLE
14.1

Mandibular Teeth and Available Local Anesthetic Techniques

PDF Compressor Free Version

Teeth	Pulpal Anesthesia	Soft Tissue Anesthesia	
		Buccal	Lingual
Incisors	Incisive	Inferior alveolar	Inferior alveolar
	Inferior alveolar	Gow-Gates	Gow-Gates
	Gow-Gates	Vazirani-Akinosi	Vazirani-Akinosi
	Vazirani-Akinosi	Incisive	Periodontal ligament injection
	Periodontal ligament	Intraseptal	Intraseptal
	Intraseptal	Mental	Infiltration
	Intraosseous	Periodontal ligament	Intraosseous
	Infiltration (buccal infiltration with articaine hydrochloride)	Infiltration	Infiltration
		Intraosseous	
Canines	Inferior alveolar	Inferior alveolar	Inferior alveolar
	Gow-Gates	Gow-Gates	Gow-Gates
	Vazirani-Akinosi	Vazirani-Akinosi	Vazirani-Akinosi
	Incisive	Incisive	Periodontal ligament
	Periodontal ligament	Periodontal ligament	Intraseptal
	Intraseptal	Intraseptal	Infiltration
	Intraosseous	Intraosseous	Intraosseous
	Infiltration (buccal infiltration with articaine hydrochloride)	Infiltration	Infiltration
		Mental	
Premolars	Inferior alveolar	Inferior alveolar	Inferior alveolar
	Gow-Gates	Gow-Gates	Gow-Gates
	Vazirani-Akinosi	Vazirani-Akinosi	Vazirani-Akinosi
	Incisive	Incisive	Periodontal ligament
	Periodontal ligament	Periodontal ligament	Intraseptal
	Intraseptal	Intraseptal	Intraosseous
	Intraosseous	Intraosseous	Infiltration
	Infiltration (buccal infiltration with articaine hydrochloride)	Infiltration	Infiltration
		Mental	
Molars	Inferior alveolar	Inferior alveolar	Inferior alveolar
	Gow-Gates	Gow-Gates	Gow-Gates
	Vazirani-Akinosi	Vazirani-Akinosi	Vazirani-Akinosi
	Periodontal ligament	Periodontal ligament	Periodontal ligament
	Intraseptal	Intraseptal	Intraseptal
	Intraosseous	Intraosseous	Intraosseous
	Infiltration (buccal infiltration with articaine hydrochloride)	Infiltration	Infiltration

TABLE 14.2 Recommended Volumes of Local Anesthetic Solution for Mandibular Injection Techniques

Technique	Volume (mL)
Inferior alveolar	1.5
Buccal	0.3
Gow-Gates	1.8–3.0
Vazirani-Akinosi	1.5–1.8
Mental	0.6
Incisive	0.6–0.9
Infiltration	0.6–0.9

References

- De St Georges J. How dentists are judged by patients. *Dent Today*. 2004;23(96):98–99.
- Friedman MJ, Hochman MN. The AMSA injection: a new concept for local anesthesia of maxillary teeth using a computer-controlled injection system. *Quintessence Int*. 1998;29:297–303.
- Oulis CJ, Vadiakis GP, Vasilopoulou A. The effectiveness of mandibular infiltration compared to mandibular block anesthesia in treating primary molars in children. *Pediatr Dent*. 1996;18:301–305.
- Sharaf AA. Evaluation of mandibular infiltration versus block anesthesia in pediatric dentistry. *J Dent Child*. 1997;64:276–281.
- Soxman J, Malamed SF. Local anesthesia for the pediatric patient. In: Soxman JA, ed. *Handbook of Clinical Techniques in Pediatric Dentistry*. Ames: John Wiley & Sons; 2015.
- Bennett CR. Techniques of regional anesthesia and analgesia. In: Bennett CR, ed. *Monheim's Local Anesthesia and Pain Control in Dental Practice*. 7th ed. St Louis: CV Mosby; 1984.
- Evers H, Haegerstam G. Anaesthesia of the lower jaw. In: Evers H, Haegerstam G, eds. *Introduction to Dental Local Anaesthesia*. Fribourg: Mediglobe SA; 1990.
- Trieger N. New approaches to local anesthesia. In: *Pain Control*. 2nd ed. St Louis: CV Mosby; 1994.
- Stepovich MJ. Success and failure rates by arch, teeth, and local anesthetic agent for inferior alveolar nerve blocks and infiltrations, white paper. A meta-data analysis of 38 clinical trial reports. info@onpharma.com.
- Kanaa MD, Whitworth JM, Corbett IP, et al. Articaine buccal infiltration enhances the effectiveness of lidocaine inferior alveolar nerve block. *Int Endod J*. 2009;42:238–246.
- Hannan L, Reader A, Nist R, et al. The use of ultrasound for guiding needle placement for inferior alveolar nerve blocks. *Oral Surg Oral Med Oral Pathol Oral Radiol Endod*. 1999;87:658–665.
- Berns JM, Sadove MS. Mandibular block injection: a method of study using an injected radiopaque material. *J Am Dent Assoc*. 1962;65:736–745.
- Galbreath JC. Tracing the course of the mandibular block injection. *Oral Surg Oral Med Oral Pathol*. 1970;30:571–582.
- Reader A. *Taking the Pain Out of Restorative Dentistry and Endodontics: Current Thoughts and Treatment Options to Help Patients Achieve Profound Anesthesia*. Endodontics: colleagues for excellence winter 2009. Chicago: American Association of Endodontists; 2009.
- DeJong RH. *Local Anesthetics*. St Louis: CV Mosby; 1994: 110–111.
- Strichartz G. Molecular mechanisms of nerve block by local anesthetics. *Anesthesiology*. 1976;45:421–444.
- Gow-Gates GA. Mandibular conduction anesthesia: a new technique using extraoral landmarks. *Oral Surg Oral Med Oral Pathol*. 1973;36:321–328.
- Vazirani SJ. Closed mouth mandibular nerve block: a new technique. *Dent Dig*. 1960;66:10–13.
- Akinosi JO. A new approach to the mandibular nerve block. *Br J Oral Surg*. 1977;15:83–87.
- Walton RE, Abbott BJ. Periodontal ligament injection: a clinical evaluation. *J Am Dent Assoc*. 1981;103:571–575.
- Malamed SF. The periodontal ligament (PDL) injection: an alternative to inferior alveolar nerve block. *Oral Surg*. 1982;53:117–121.
- Coggins R, Reader A, Nist R, et al. Anesthetic efficacy of the intraosseous injection in maxillary and mandibular teeth. *Oral Surg Oral Med Oral Pathol*. 1996;81:634–641.
- Sixou JL, Barbosa-Rogier ME. Efficacy of intraosseous injections of anesthetic in children and adolescents. *Oral Surg Oral Med Oral Pathol Oral Radiol Endod*. 2008;106:173–178.
- Whitcomb M, Drum M, Reader A, et al. A prospective, randomized, double-blind study of the anesthetic efficacy of sodium bicarbonate buffered 2% lidocaine with 1:100,000 epinephrine in inferior alveolar nerve blocks. *Anesth Prog*. 2010;57:59–66.
- Meechan JG, Ledvinka JI. Pulpal anaesthesia for mandibular central incisor teeth: a comparison of infiltration and intraligamentary injections. *Int Endod J*. 2002;35:629–634.
- Kanaa MD, Whitworth JM, Corbett IP, et al. Articaine and lidocaine mandibular buccal infiltration anesthesia: a prospective randomized double-blind cross-over study. *J Endod*. 2006;32:296–298.
- Robertson D, Nusstein J, Reader A, et al. The anesthetic efficacy of articaine in buccal infiltration of mandibular posterior teeth. *J Am Dent Assoc*. 2007;138:1104–1112.
- Haase A, Reader A, Nusstein J, et al. Comparing anesthetic efficacy of articaine versus lidocaine as a supplemental buccal infiltration of the mandibular first molar after an inferior alveolar nerve block. *J Am Dent Assoc*. 2008;139:1228–1235.
- Kanaa MD, Whitworth JM, Corbett IP, et al. Articaine buccal infiltration enhances the effectiveness of lidocaine inferior alveolar nerve block. *Int Endod J*. 2009;42:238–246.
- Langlais RP, Broadus R, Glass BJ. Bifid mandibular canals in panoramic radiographs. *J Am Dent Assoc*. 1985;110:923–926.
- Dreven LJ, Reader A, Beck M, et al. An evaluation of the electric pulp tester as a measure of analgesia in human vital teeth. *J Endod*. 1987;13:233–238.
- Certosimo AJ, Archer RD. A clinical evaluation of the electric pulp tester as an indicator of local anesthesia. *Oper Dent*. 1996; 21:25–30.
- Wilson S, Johns PI, Fuller PM. The inferior alveolar and mylohyoid nerves: an anatomic study and relationship to local anesthesia of the anterior mandibular teeth. *J Am Dent Assoc*. 1984;108: 350–352.
- Frommer J, Mele FA, Monroe CW. The possible role of the mylohyoid nerve in mandibular posterior tooth sensation. *J Am Dent Assoc*. 1972;85:113–117.
- Roda RS, Blanton PL. The anatomy of local anesthesia. *Quintessence Int*. 1994;25:27–38.
- Meechan JG. Infiltration anesthesia in the mandible. *Dent Clin N Am*. 2010;54:621–629.

37. Gow-Gates GAE. Mandibular conduction anesthesia: a new technique using extraoral landmarks. *Oral Surg.* 1973;36:321–328. **PDF Compressor Free Version**
38. Malamed SF. The Gow-Gates mandibular block: evaluation after 4275 cases. *Oral Surg.* 1981;51:463.
39. Johnson TM, Badovinac R, Shaefer J. Teaching alternatives to the standard inferior alveolar nerve block in dental education: outcomes in clinical practice. *J Dent Educ.* 2007;71:1145–1152.
40. Zandi M, Seyedzadeh Sabounchi S. Design and development of a device for facilitation of Gow-Gates mandibular block and evaluation of its efficacy. *Oral Maxillofac Surg.* 2008;12:149–153.
41. Kohler BR, Castellon L, Laissle G. Gow-Gates technique: a pilot study for extraction procedures with clinical evaluation and review. *Anesth Prog.* 2008;55:2–8.
42. Fish LR, McIntire DN, Johnson L. Temporary paralysis of cranial nerves III, IV, and VI after a Gow-Gates injection. *J Am Dent Assoc.* 1989;119:127–130.
43. Fa BA, Speaker SR, Budenz AW. Temporary diplopia after Gow-Gates injection: case report and review. *Anesth Prog.* 2016;63:139–146.
44. Brodsky CD, Dower JS Jr. Middle ear problems after a Gow-Gates injection. *J Am Dent Assoc.* 2001;132:420–424.
45. Murphy TM. Somatic blockade. In: Cousins MJ, Bridenbaugh PO, eds. *Neural Blockade in Clinical Anesthesia and Management of Pain.* Philadelphia: JB Lippincott; 1980.
46. Bennett CR. *Monheim's Local Anesthesia and Pain Control in Dental Practice.* 6th ed. St Louis: Mosby; 1978.
47. Wolfe SH. The Wolfe nerve block: a modified high mandibular nerve block. *Dent Today.* 1992;11:34–37.
48. Mishra S, Tripathy R, Sabhlok S, Panda PK, Patnaik S. Comparative analysis between conventional mandibular nerve block and Akinosi-Vazirani closed mouth mandibular nerve block technique. *Int J Adv Res Technol.* 2012;1:1–6.
49. Yu F, Xiao Y, Liu H, Wu F, et al. Evaluation of three anesthesia methods for pain management during mandibular third molar extraction: a meta-analysis. *Sci Rep.* 2017;7:40987.
50. Malamed SF. *Handbook of Local Anesthesia.* St Louis: Mosby; 1980.
51. Jastak JT, Yagiela JA, Donaldson D. *Local Anesthesia of the Oral Cavity.* Philadelphia: WB Saunders; 1995.

Supplemental Injection Techniques

In this chapter a number of injections are described that are used in specialized clinical situations. Some may be used as the sole technique for pain control in certain types of dental treatment. For example, the periodontal ligament (PDL), intraosseous, and intraseptal injection techniques provide effective pulpal anesthesia for a single tooth without the need for other injections. On the other hand, use of an intrapulpal injection is almost always reserved for situations in which other injection techniques have failed or are contraindicated for use. The PDL, intraosseous, and intraseptal injection techniques also are frequently used to supplement failed or only partially successful traditional injection techniques.

The effectiveness of mandibular infiltration in adults with the local anesthetic articaine hydrochloride has helped make the achievement of clinically profound mandibular anesthesia more consistently reliable.

The ability to provide pulpal anesthesia in circumscribed areas of the mandible without the need for nerve blocks (e.g., inferior alveolar nerve block [IANB], Gow-Gates mandibular nerve block) is valuable when these nerve blocks fail to provide the depth of anesthesia required for painless dentistry.

Intraosseous Anesthesia

Intraosseous anesthesia involves the deposition of local anesthetic solution into the cancellous bone that supports the teeth. Although not new (intraosseous anesthesia dates back to the early 1900s), a resurgence of interest in this technique in dentistry has occurred over the past 15 years.¹⁻⁵ Three techniques are discussed here, two of which—the PDL injection and the intraseptal injection—are modifications of traditional intraosseous anesthesia.

Periodontal Ligament Injection

Because of the thickness of the cortical plate of bone in most patients and in most areas of the mandible, it is not possible to achieve profound pulpal anesthesia for a solitary tooth in the adult mandible with the techniques described in Chapter 14. An exception to this is the mandibular incisor region, where Certosimo and Archer⁶ demonstrated a 97% success rate for pulpal anesthesia following infiltration


of 0.9 mL of articaine hydrochloride (with epinephrine 1:100,000) on *both* the buccal and the lingual aspects of the teeth. Buccal infiltration of articaine hydrochloride also provides considerable success in mandibular molars as well.^{7,8} Mandibular infiltration is reviewed later in this chapter and in depth in Chapter 20.

An old technique has been repopularized. The PDL injection (also known as the *intra*ligamentary injection) was originally described as the *peridental injection* in local anesthesia textbooks dating from 1912 to 1923.^{9,10}

The peridental injection was not well received in those early years because it was claimed that the risk of producing blood-borne infection and septicemia was too great to warrant its use in patients. The technique never became popular but was used clinically by many doctors, although it was not referred to as the *peridental technique*. In clinical situations in which an IANB failed to provide adequate pulpal anesthesia for the first molar (usually its mesial root), the doctor inserted a needle along the long axis of the mesial root as far apically as possible and deposited a small volume of local anesthetic solution under pressure. This invariably provided effective pain control.

It was not until the early 1980s that the PDL injection regained popularity. Credit for increased interest in this approach must go to the manufacturers of syringe devices designed to make the injection easier to administer. The original devices—the Peripress (Universal Dental, Boyerstown, Pennsylvania, United States) and the Ligmaject (IMA Associates, Largo, Florida, United States) (Fig. 15.1)—provide a mechanical advantage that allows the administrator to deposit the anesthetic more easily (and sometimes too easily). They appear similar to the Wilcox-Jewett obtunder (Fig. 15.2), which was widely advertised to the dental profession in a 1905 catalog, *Dental Furniture, Instruments, and Materials*, perhaps reconfirming the adage that there is “nothing new under the sun.”¹¹

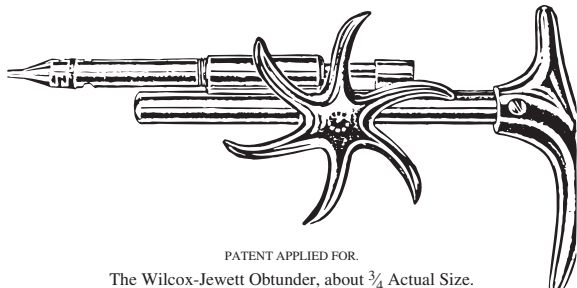
Why has the PDL (née peridental) injection enjoyed a renewal of popularity? Perhaps it is because the primary thrust of advertising for the new syringes focused on being able to “avoid the mandibular block” injection with the PDL injection technique, a concept to which the dental profession is receptive given the fact that virtually all dentists have experienced periods when they have been unable to achieve adequate anesthesia with the traditional IANB (a “mandibular slump”).



• **Fig. 15.1** (A) Original pressure syringe designed for a periodontal ligament injection. (B) Second-generation syringe for a periodontal ligament injection.

THE WILCOX-JEWETT OBTUNDER.

LEE S. SMITH & SON, PITTSBURG.



PATENT APPLIED FOR.
The Wilcox-Jewett Obtunder, about $\frac{3}{4}$ Actual Size.

• **Fig. 15.2** Pressure syringe (1905) designed for a periodontal injection.

The PDL injection may also be used successfully in the maxillary arch; however, with the ready availability of other highly effective and atraumatic techniques, such as the supraperiosteal (infiltration) injection, drugs such as articaine hydrochloride to provide single-tooth pulpal anesthesia, and the recently released intranasal local anesthetic mist, there has been little compelling reason for use of the PDL injection in the upper jaw (although there is absolutely no other reason not to recommend it in this area). Possibly the greatest potential benefit of the PDL injection lies in the fact that it provides pulpal and soft tissue anesthesia in a localized area (one tooth) of the mandible without producing extensive soft tissue (e.g., tongue and lower lip) anesthesia as well. Virtually all dental patients prefer this technique to any of the “mandibular nerve blocks.” In a clinical trial, Malamed¹² reported that 74% of patients preferred the PDL injection primarily because of its lack of lingual and labial soft tissue anesthesia. It is interesting that those who preferred

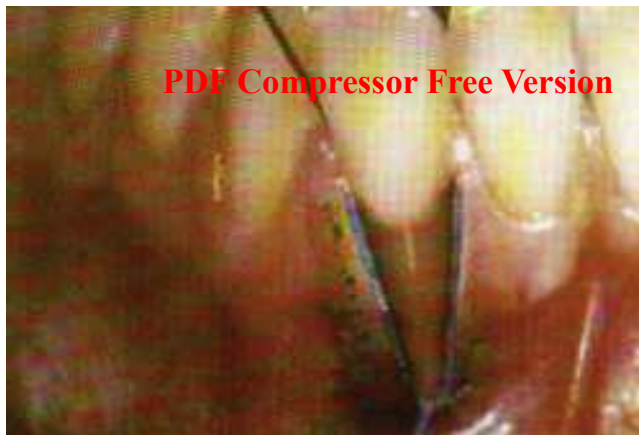the IANB did so for an important reason: With the IANB, once the lip and tongue became numb, patients were able to relax, knowing that the remainder of their dental treatment would not hurt (usually, since soft tissue anesthesia is *never* a guarantee of pulpal anesthesia). Without lingual and labial soft tissue anesthesia in the PDL injection technique, patients were unable to fully relax because they were never certain that they had been adequately anesthetized.

With the introduction of computer-controlled local anesthetic delivery devices (C-CLADs) such as The Wand STA Single Tooth Anesthesia System, the PDL injection has been shown to be of particular importance in the treatment of the pediatric dental patient. Numerous studies over the past 2 decades have demonstrated that use of the PDL injection in conjunction with a C-CLAD device markedly reduces subjective pain and disruptive pain behavior when children are being treated.¹³⁻²³ This combination has a particular advantage when compared with other techniques as it eliminates the risk of self-inflicted soft tissue injury (lip and tongue biting) that can be associated with either IANB or buccal infiltration anesthesia in children as well as minimizing behavior issues.

Primary indications for the PDL injection include (1) the need for anesthesia of but one or two mandibular teeth in a quadrant, (2) treatment of isolated teeth in both mandibular quadrants (to avoid bilateral IANB), (3) treatment of children (because residual soft tissue anesthesia increases the risk of self-inflicted soft tissue injury), (4) treatment in which nerve block anesthesia is contraindicated (e.g., in patients with hemophilia and other patients with coagulopathies), and (5) its use as a possible aid in the diagnosis (e.g., localization) of mandibular pain.

Contraindications to the PDL injection include infection or severe inflammation at the injection site. In 1984 Brannstrom et al.²⁴ reported the development of enamel hypoplasia or hypomineralization or both in 15 permanent teeth after administration of the PDL injection on primary molars. Subsequent research and clinical experience has shown that use of a PDL injection on a primary tooth with a permanent tooth developing below it is not a contraindication to its administration.^{25,26} Ashkenazi et al.¹⁶ demonstrated that with use of a C-CLAD device with a controlled low-pressure administration, the risks of enamel hypoplasia and/or hypomineralization are not as high as previously reported. For those instances when a PDL injection is recommended for the primary dentition, a C-CLAD instrument is recommended.

Several concerns have been expressed about this technique, most of which were addressed in a status report on the PDL injection in by the American Dental Association 1983.²⁷ Two of these concerns involve (1) the effect of injection and deposition of the local anesthetic under pressure into the confined space of the PDL and (2) the effect of the drug or vasoconstrictor on pulpal tissues. Walton and Garnick²⁸ concluded that the PDL injection (administered with a conventional syringe) causes slight damage to tissues in the region of needle penetration only. Apical areas appeared normal; the epithelial and connective tissue attachment to enamel and cementum



• **Fig. 15.3** Periodontal ligament injection is intraosseous. Note the dispersion of ink into surrounding bone.

was not disturbed by the needle puncture; slight resorption of nonvital bone occurred in the crestal regions, forming a wedge-shaped defect; soft tissue damage was minimal. Importantly, the disruption of tissue that did occur showed repair in 25 days, with absence of inflammation and with the formation of new bone in the regions of resorption; and injection of the solution was not in itself damaging. The damage produced by needle penetration alone (no drug administered) appeared similar to that seen when a drug had been deposited with the injection. Walton and Garnick²⁸ concluded that the PDL injection is safe for the periodontium. In addition, no evidence to date suggests that inclusion of a vasoconstrictor in the local anesthetic solution has any detrimental effect on pulpal microcirculation after the PDL injection.

It appears that the mechanism whereby local anesthetic solution reaches the periapical tissues with the PDL injection consists of diffusion apically and into the marrow spaces surrounding the teeth. The solution is not forced apically through the periodontal tissues, a procedure that might lead to avulsion of a tooth because of the increased hydrostatic pressure exerted in a confined space.²⁹ The PDL injection appears to produce anesthesia in much the same way as intraosseous and intraseptal injections—by diffusion of anesthetic solution apically through marrow spaces in the intraseptal bone (Fig. 15.3).^{26,30}

Postinjection complications are also of concern with the PDL injection. Reported complications have included mild to severe postoperative discomfort, swelling and discoloration of soft tissues at the injection site, and prolonged ischemia of the interdental papilla, followed by sloughing and exposure of crestal bone.^{31,32} Some of these complications result directly from poor operator technique, lack of familiarity with the pressure syringe, and injection of excessive volumes of local anesthetic into the PDL. The most frequently voiced postinjection complications are mild discomfort and sensitivity to biting and percussion for 2 or 3 days. The most common causes of postinjection discomfort are (1) too rapid injection (producing edema and slight extrusion of the tooth, thus sensitivity on biting) and (2) injection of excessive volumes of local anesthetic into the site.

Before the PDL technique is described, it must be mentioned that although “special” PDL syringes can be used effectively and safely, usually there is no need for them. A conventional local anesthetic syringe is equally effective in providing PDL anesthesia. Use of a conventional syringe requires that the administrator apply significant force to deposit the local anesthetic into the periodontal tissues. Virtually all doctors and hygienists are able to produce PDL anesthesia successfully without a special PDL syringe. Only when a doctor or a hygienist is unable to achieve adequate PDL anesthesia with a conventional syringe should use of a PDL syringe be considered.

Arguments against use of a conventional syringe for PDL injections (and my rebutsals) include:

1. It is too difficult to administer the solution with a conventional syringe.

Comment: Slow administration of the local anesthetic makes the PDL injection atraumatic. Improper use of the PDL syringe (fast injection) produces both immediate and postinjection pain.

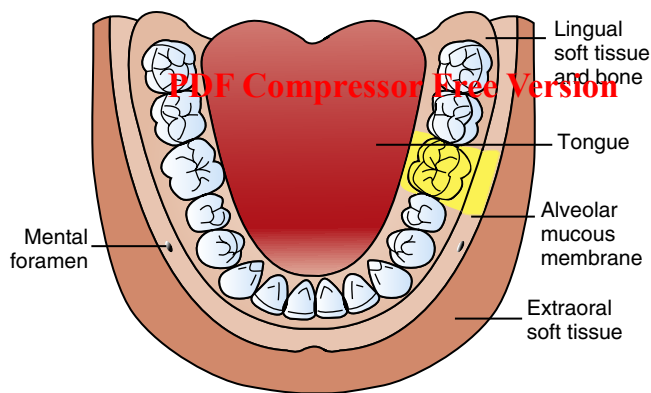
2. The extreme pressure applied to the glass may shatter the cartridge. PDL syringes have a metal or plastic covering for the glass cartridge, thereby protecting the patient from shards of glass should the cartridge shatter during injection.

Comment: Although I have read and heard of cartridges shattering during PDL injection, I have yet to experience this. However, the risk can be minimized in several ways: Because only small volumes of solution are injected (0.2 mL per root), a full, 1.8-mL cartridge is not necessary. Eliminate all but about 0.6 mL of solution before starting the PDL injection. This minimizes the area of glass being subjected to increased pressures, decreasing the risk of breakage. In addition, glass cartridges have a thin Mylar plastic label that covers most or all of the glass (see Fig. 7.4). If a cartridge breaks, the glass will not shatter but will be contained by the plastic covering.

3. Many manufacturers of PDL syringes recommend use of 30-gauge short or ultrashort needles in this technique.

Comment: In my early experience with the PDL technique, I used a 30-gauge needle only to find that whenever pressure was applied to it (as when pushing it apically into the PDL), the 30-gauge needle bent easily. It was too fragile to withstand the force applied to it without bending. PDL injection failure rates were excessive. A 30-gauge ultrashort needle was manufactured specifically for use with this injection technique (10 mm in length). Although somewhat more effective than a 30-gauge short needle, there is no need to use a “special” needle for this injection. I have had great clinical success, with no increase in patient discomfort, using the more readily available 27-gauge short needle.

In summary, the PDL injection is an important component of the armamentarium of local anesthetic techniques for providing mandibular and, to a lesser degree, maxillary pain control.



• **Fig. 15.4** Area anesthetized by a periodontal ligament injection.

- The PDL injection administered with a conventional or PDL syringe is painful.

Comment: Use of a C-CLAD device for administration of painless PDL injections has been strongly advocated.³³ Many dentists have related to me that their PDL injections, although effective in providing anesthesia, are painful to the patient during administration. Although this has not been my experience, there are enough reports to convince me that many doctors believe this to be so. Use of a C-CLAD device does enable the PDL injection to be delivered painlessly (e.g., 0 to 1 on a visual analog scale [VAS]). The PDL technique using a C-CLAD device is described later.

Other Common Names

Peridental (original name) injection, intraligamentary injection.

Nerves Anesthetized

Terminal nerve endings at the site of injection and at the apex of the tooth.

Areas Anesthetized

Bone, soft tissue, and apical and pulpal tissues in the area of injection (Fig. 15.4).

Indications

- Pulpal anesthesia of one or two teeth in a quadrant
- Treatment of isolated teeth in two mandibular quadrants (to avoid bilateral IANB)
- Patients for whom residual soft tissue anesthesia is undesirable
- Situations in which regional block anesthesia is contraindicated
- As a possible aid in the diagnosis of pulpal discomfort
- As an adjunctive technique after nerve block anesthesia if partial anesthesia is present

Contraindications

- Infection or inflammation at the site of injection
- Patients who requires “numb” sensation for their psychological comfort

Advantages

- There is no anesthesia of the lip, tongue, and other soft tissues, thus facilitating treatment in multiple quadrants during a single appointment.
- Minimum dose of local anesthetic necessary to achieve anesthesia (~0.2 mL per root).
- An alternative to partially successful regional nerve block anesthesia.
- Rapid onset of profound pulpal and soft tissue anesthesia (30 seconds).
- Less traumatic than conventional block injections.
- Well suited for procedures in children, extractions, and periodontal and endodontic single-tooth and multiple-quadrant procedures.

Disadvantages

- Proper needle placement is difficult to achieve in some areas (e.g., distal to the second or third molar).
- Leakage of local anesthetic solution into the patient’s mouth produces an unpleasant taste.
- Excessive pressure or overly rapid injection may break the glass cartridge.
- A special syringe may, on occasion, be necessary.
- Excessive pressure can produce focal tissue damage.
- Postinjection discomfort may persist for several days.
- The potential for extrusion of a tooth exists if excessive pressure or volumes are used.

Positive Aspiration

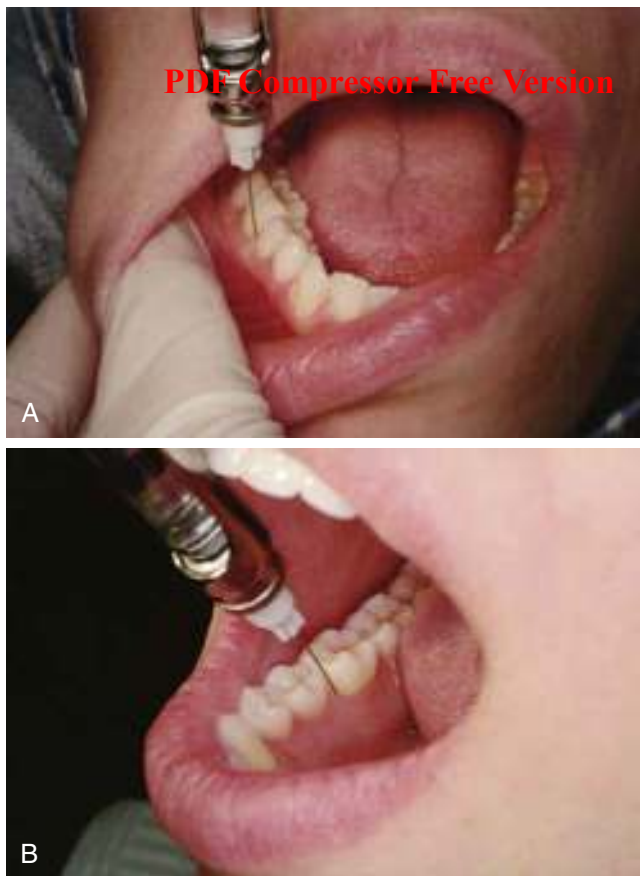Zero percent.

Alternative

Supraperiosteal injection for the entire maxilla and mandibular incisor region. The infiltration of articaine hydrochloride in the mandibular molar region has a significantly high success rate.

Technique

- A 27-gauge short needle is recommended.
- Area of insertion: long axis of the tooth to be treated on its mesial or distal root (one-rooted tooth) or on the mesial and distal roots (of a multirouted tooth) interproximally (Fig. 15.5).
- Target area: depth of the gingival sulcus. The needle is wedged between the root of the tooth and the interproximal bone.
- Landmarks:
 - Root(s) of the tooth.
 - Periodontal tissues.
- Orientation of the bevel: although not significant to the success of the technique, it is recommended that the bevel of the needle face toward the root to permit easy advancement of the needle in an apical direction.
- Procedure:
 - Assume the correct position (this differs significantly with PDL injections for different teeth). Sit comfortably, have adequate visibility of the injection site, and



• **Fig. 15.5** Area of insertion for a periodontal ligament injection. (A) Buccal. (B) Lingual.

maintain control over the needle. It may be necessary to bend the needle to achieve the proper angle, especially on the distal aspects of second and third molars.^a

- b. Position the patient supine or semisupine, with the head turned to maximize access and visibility.
- c. Stabilize the syringe and direct it along the long axis of the root to be anesthetized. If possible, use a mouth mirror to minimize the risk of accidental needlestick injury to the administrator.
 - i. The bevel faces the root of the tooth.
 - ii. If interproximal contacts are tight, the syringe should be directed from the lingual or buccal surface of the tooth but maintained as close to the long axis as possible.
 - iii. Stabilize the syringe and your hand against the patient's teeth, lips, or face.
- d. With the bevel of the needle on the root, advance the needle apically until resistance is met.
- e. Deposit 0.2 mL of local anesthetic solution in a minimum of 20 seconds.

^aAlthough the author dislikes bending needles for most injections, it may become necessary for the success of the PDL and intrapulpal injections to bend the needle to gain access to certain areas of the oral cavity. Because the needle does not enter tissues more than a few millimeters, bending it is not as risk-prone as when the needle enters soft tissue more completely (to its hub).

- i. When using a conventional syringe, note that the thickness of the rubber stopper in the local anesthetic cartridge is equal to 0.2 mL of solution. This may be used as a gauge for the volume of local anesthetic to be administered.
 - ii. With a PDL syringe, each squeeze of the "trigger" provides a volume of 0.2 mL.
- f. There are two important indicators of success of the injection:
 - i. Significant resistance to the deposition of local anesthetic solution. This is especially noticeable when the conventional syringe is used; resistance is similar to that felt with the nasopalatine injection and is thought to be the reason for reports of PDL injections being painful.

The local anesthetic should not flow back into the patient's mouth. If this happens, repeat the injection at the same site but from a different angle. Two-tenths of a milliliter of solution must be deposited and must remain within the tissues for the PDL to be effective. Meechan²⁶ has suggested, as a means of preventing leakage of the anesthetic into the patient's mouth on withdrawal of the needle, that the needle be left in the PDL injection site for approximately 10 seconds after deposition of the local anesthetic to permit the drug to diffuse into bone.
 - ii. Ischemia of the soft tissues adjacent to the injection site. (This is noted with all local anesthetic solutions but is more prominent with vasoconstrictor-containing local anesthetics.)
 - g. If the tooth has only one root, remove the syringe from the tissue and cap the needle. Dental treatment may usually start within 30 seconds.
 - h. If the tooth is multirooted, remove the needle and repeat the procedure on the other root(s).

Signs and Symptoms

1. Subjective: There are no signs that absolutely assure adequate anesthesia; the anesthetized area is quite circumscribed. When the following two signs are present, there is an excellent chance that profound anesthesia is present:
 - a. Ischemia of soft tissues at the injection site.
 - b. Significant resistance to injection of solution (with a traditional syringe).
2. Objective: use of a freezing spray (e.g., Endo-Ice) or an electric pulp tester (EPT) with no response from the tooth with maximal EPT output (80/80).

Safety Feature

Intravascular injection is extremely unlikely to occur.

Precautions

1. Keep the needle against the tooth to prevent overinsertion into soft tissues on the lingual aspect.
2. Do not inject anesthetic solution too rapidly (minimum 20 seconds for 0.2 mL).
3. Do not inject too much solution (0.2 mL per root retained within tissues).
4. Do not inject anesthetic solution directly into infected or highly inflamed tissues.

Failures of Anesthesia

1. Periapical infection. The pH and vascularity changes at the apex and PDL. **PDF Compressor Free Version** Use of the PDL injection is not contraindicated in the presence of apical disease, but its success may be minimized.
2. Solution not retained. In this case, remove the needle and reenter at a different site(s) until 0.2 mL of local anesthetic is deposited and retained in the tissues.
3. Each root must be anesthetized with approximately 0.2 mL of solution.

Complications

1. Pain during insertion of the needle.
 - Cause 1: the needle tip is in soft tissues. To correct this, keep the needle against tooth structure.
 - Cause 2: the tissues are inflamed. To correct this, avoid use of the PDL technique or apply a small amount of topical anesthetic for a minimum of 1 minute before injection.
2. Pain during injection of solution.
 - Cause: too rapid injection of local anesthetic solution. To correct this, slow down the rate of injection to a minimum 20 seconds for a 0.2 mL solution, regardless of the syringe being used.
3. Postinjection pain.
 - Cause: too rapid injection, excessive volume of solution, too many tissue penetrations. (The patient usually complains of soreness and premature contact when occluding.) To correct this, manage the pain symptomatically with warm saline rinses and mild analgesics, if necessary (usually resolves within 2 to 3 days).

Duration of Expected Anesthesia

The duration of pulpal anesthesia obtained with a successful PDL injection is quite variable and is not related to the drug administered. Administration of lidocaine with epinephrine 1:100,000, for example, provides pulpal anesthesia ranging in duration from 5 to 55 minutes. The PDL injection may be repeated if necessary to permit completion of the dental procedure. It appears that the volume of anesthetic solution used with the PDL injection is too small to provide the usually expected duration of anesthesia of the drug. The question of anesthetic volume is discussed further in the following description of PDL injections given with a C-CLAD device.

The Wand STA Single Tooth Anesthesia System Periodontal Ligament Injection

The technique used to perform the PDL injection, as described previously, has remained relatively unchanged since it was first introduced in the early 1900s.³⁴ A variety of mechanical syringes have been developed throughout the years to enable high pressures to be generated

during the administration of anesthetic solution into these tissues.³⁵ These mechanical syringes produce considerably high pressures, thereby creating a pressure gradient to promote diffusion of anesthetic solution from the coronal region of the crestal bone to the apex of the tooth. The anesthetic solution diffuses through the cortical and medullary bone to eventually surround or envelope the neurovascular bundle at the apex of a tooth.^{36,37} This localized “bathing” of the nerve entering the apex of a tooth provides anesthesia of a single tooth without the often-undesirable collateral anesthesia of the lip and tongue. Additionally, this localized administration has a rapid onset because of the localized nature of the injection technique. With the production of high pressures, only a small volume (typically 0.2 to 0.4 mL) can be injected and absorbed.²⁶ Patients routinely report moderate to severe discomfort when injections are performed with high-pressure syringe techniques.³⁸⁻⁴⁰

With the introduction of The Wand STA Single Tooth Anesthesia System C-CLAD device, a change in the basic concepts related to performing the PDL injection occurred as a result of the mechanical and technological differences between a hand-driven manual syringe and a computer-regulated electromechanical instrument.⁴¹ The difference between The Wand STA system and a hand-driven syringe is that in the former a precisely regulated flow rate and controlled low-pressure injection are used to perform the PDL injection.⁴² These fundamental differences in fluid dynamics have led to the following clinically relevant changes: a consistent and measurable reduction in patient pain perception,^{43,44} a histologically demonstrated reduction in tissue damage, and the ability to administer larger volumes of anesthetic safely and effectively when the PDL injection is performed.⁴⁵ The ability to administer a larger volume of anesthetic solution results in an increased duration of effective dental local anesthesia.⁴⁶ In addition, The Wand STA system incorporates new technology that allows the PDL injection to be performed as a “guided” injection by providing real-time feedback during positioning of the needle in the intended target area, thereby increasing the efficacy and predictability of PDL injection.^{41,47}

The STA system precisely regulates and measures fluid pressure at the needle tip while a subcutaneous injection is performed, providing the clinician with continuous real-time audible and visual feedback during the injection.⁴⁷

Clinical studies in medicine and dentistry have demonstrated that use of real-time exit-pressure sensing allows identification of a specific tissue type related to objective measurement of tissue density (i.e., tissue compliance) while a subcutaneous injection is performed.^{42,48,49} One study led researchers to use this technology to more accurately identify tissue type and to perform the epidural nerve block technique commonly used for obstetric and surgical procedures of the lower extremities.⁴⁹ Hochman et al.⁴² published the results of a clinical study in which more than 200 dental

injections were given using dynamic pressure-sensing (DPS) technology to differentiate specific tissues of the oral cavity: PDL, attached gingiva, and free gingival and alveolar tissues. They concluded that specific tissue types require a specific pressure range with a given flow rate to be used to perform a safe and effective dental injection.

The STA instrument provides continuous audible and visual feedback to the clinician as the dental needle is introduced into the tissues during the injection. This system has a visual pressure-sensing scale on the front of the unit that is composed of a series of light-emitting diode (LED) lights (red, yellow, and green) (Fig. 15.6A–C). Red indicates minimal pressure at the needle tip, yellow indicates mild to moderate pressure, and green indicates moderate tissue pressure indicative of the PDL space. PDL tissue may be identified at pressures of the yellow LED that are representative of the mild to moderate pressure range and at the green LED representative of the high pressure range as well.⁴¹

Through auditory feedback, the clinician becomes aware of how to maintain correct needle-to-intraligamentary position throughout the injection. Auditory feedback consists of a series of sounds with a pressure-sensing scale composed of ascending tones to guide the clinician. When the clinician hears the ascending sequence, this indicates that the pressure is rising. When the PDL is identified, the letters *PDL* are spoken, indicating that correct needle position has been achieved. Maintaining a consistent level of light to moderate force on the needle is a necessary process for a successful injection. Audible and visual feedback provides this important information. When the STA PDL injection is performed, it is not uncommon for the clinician to reposition the needle to find the optimal position within PDL tissues, allowing a high degree of predictability and accuracy when this injection is performed. This transforms the “blind” syringe approach, described earlier, into an objective method of locating and maintaining correct needle position when performing the PDL injection.

Ferrari et al.⁴⁴ published data on 60 patients in whom they compared the STA system with two standard PDL hand-driven manual syringes: a high-pressure mechanical syringe (Ligmaject) and a conventional dental syringe. Electric pulp testing was performed on all tested teeth at regular intervals to determine success or failure of these different instruments and the techniques used. In addition to electric pulp testing results, subjective pain responses of the patient were recorded after treatment. Ferrari et al. reported a success rate of 100% for The Wand STA system. In addition, a rapid onset of anesthesia was observed. In this study, the PDL injection was performed as the primary injection for restorative dental care in mandibular teeth. Ferrari et al. reported subjective pain responses of “minimal or no pain” in all patients receiving the PDL injection performed with The Wand STA device. In contrast, injections performed with the other two systems (high-pressure mechanical syringe and

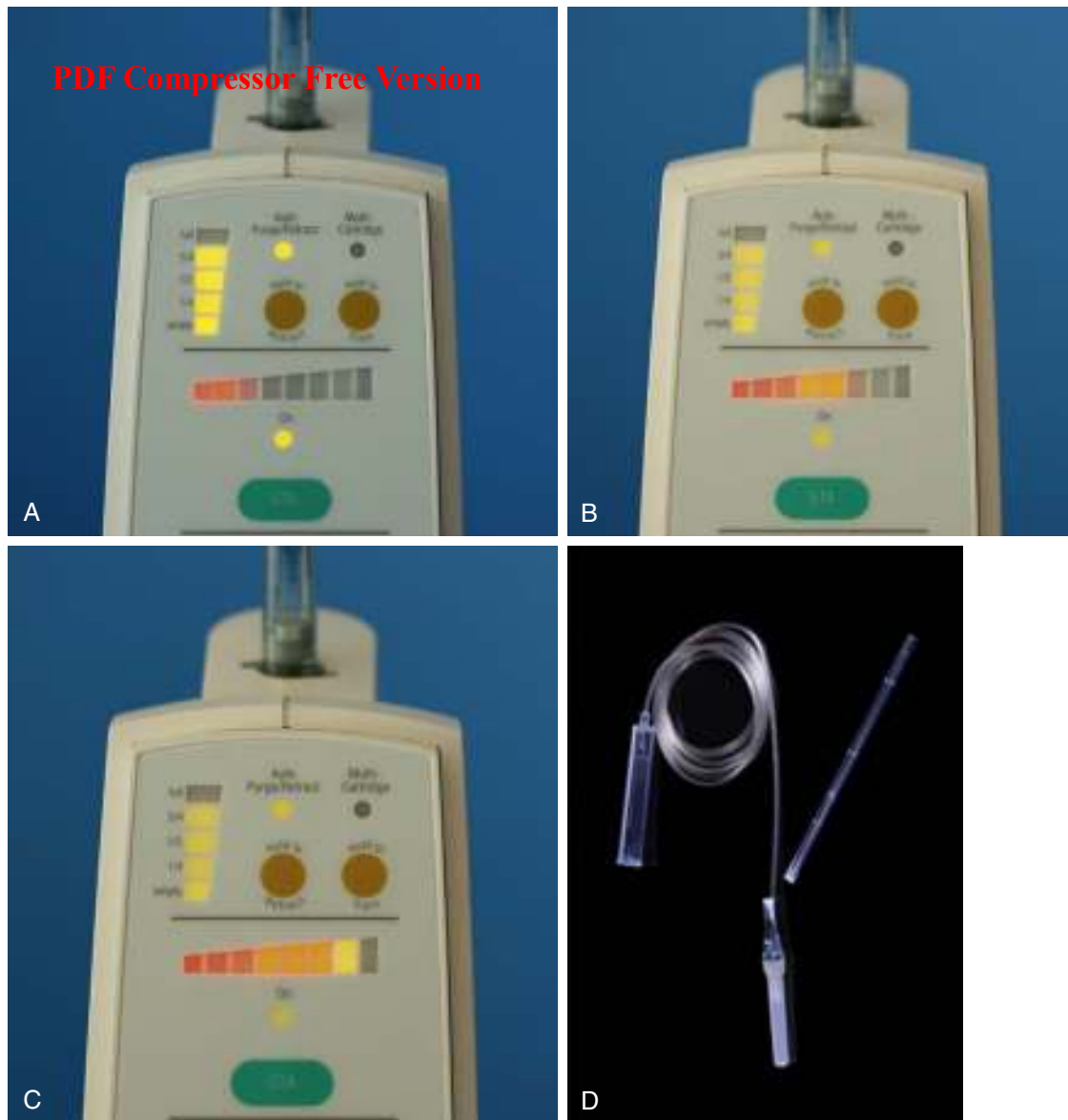conventional syringe) were found to result in higher pain scores throughout testing and required repeated attempts to achieve a successful outcome. Ferrari et al. concluded The Wand STA system resulted in a more predictable, more reliable, and more comfortable anesthesia technique than the high-pressure mechanical syringe and/or the conventional dental syringe.

Pediatric Use

Brannstrom et al.²⁴ reported on the use of a high-pressure PDL injection to anesthetize 16 monkey primary teeth. Hypoplasia or hypomineralization defects developed on 15 of the permanent teeth, but none developed in controls. The PDL injection, when delivered by a hand-driven mechanical syringe, produces uncontrolled high pressures and is associated with damage to the periodontal tissues.⁵⁰

In 2010 Ashkenazi et al.⁴³ published the first long-term, clinical controlled study using a low-pressure PDL injection with the STA system with DPS technology. The study population consisted of 78 children (aged 4.1 to 12.8 years) who received STA PDL injections in 166 primary molar teeth. Teeth receiving conventional dental anesthesia or that were not anesthetized by local anesthesia served as controls. After reviewing data collected between 1999 and 2007, Ashkenazi et al. concluded that performing the PDL injection using a low-pressure C-CLAD injection instrument, specifically The Wand STA system with DPS, did not produce damage to the underlying developing permanent tooth bud and was deemed safe and effective. The same authors, in another study, demonstrated that children exhibited minimal disruptive pain-related behavior and minimal levels of dental-related stress during and immediately after STA PDL anesthesia.¹⁶ These findings represent a new perspective on dental local anesthesia and the treatment of primary teeth of the pediatric patient.

In the past 5 years a series of studies have been published that have further validated the use of The Wand STA system to perform a PDL injection in the primary dentition.¹⁷⁻²³ These studies taken together have conclusively demonstrated both the safety and the efficacy of performing a PDL injection on primary teeth when it is performed with a C-CLAD system. Garret-Bernardin et al.²¹ conducted a controlled study with a crossover split-mouth design involving 67 patients (aged 7 to 15 years). Each patient received both types of injections, one with a C-CLAD device (The Wand STA system) and one with a traditional syringe. A PDL injection was performed with The Wand STA system, and a traditional injection was performed according to the standard technique with the conventional syringe. The child’s pain perception was assessed with use of a VAS and the patient expressed his/her level of satisfaction on a scale from 0 to 10. The Wand STA system resulted in significantly lower pain ratings versus the conventional syringe. A mean reduction of 1.09 VAS



• **Fig. 15.6** Dynamic pressure sensing on the STA Single Tooth Anesthesia computer-controlled local anesthetic delivery device provides both visual and audible feedback regarding placement of the needle tip during the periodontal ligament (PDL) injection. Horizontal color bars indicate pressure at the tip of the needle. (A) Red—pressure is too low. (B) Orange and dark yellow—increasing pressure but not yet adequate. (C) Light yellow—correct pressure for PDL injection. At this point (C) the STA unit will also provide an audible clue “PDL, PDL, PDL” that the needle tip is properly situated. The Wand STA handpiece is lightweight (less than 10 g) and can easily be shortened to aid in administration of some injections (D), such as the anterior middle superior alveolar or other palatal techniques. (© 2018, Milestone Scientific, Inc., All Rights Reserved, Used by Permission.)

point with The Wand STA system compared with the traditional syringe ($P = .0003$). Patient level of satisfaction demonstrated that 29 patients showed a higher satisfaction with The Wand STA system, whereas only 12 had a higher satisfaction level with the traditional anesthesia. In conclusion, Garret-Bernardin et al. stated that The Wand STA system can provide less painful injections (PDL injection) when compared with conventional local anesthesia in pediatric patients and it was better tolerated compared with a traditional syringe.

Yogesh-Kumar et al.¹⁸ conducted a randomized controlled crossover study involving 120 children, aged 7 to 11 years. Patients were randomized into two groups: group A, injection with a C-CLAD device (The Wand STA system) during the first visit; group B, injection with a cartridge syringe during the first visit. Each patient in both groups received a second injection performed with the syringe system not used during the first session (i.e., a crossover design). Children who received injections with the C-CLAD device showed a significant decrease

($P < .002$) in pain perception, as seen by facial image scale scores, when compared with the cartridge group (1.42 vs. 1.70, respectively).¹⁷ In a study of children's behavior, 71 children (64%) showed better behavioral response while receiving C-CLAD injections. Thirteen children (12%) demonstrated better behavioral response with cartridge syringe injections. Twenty-six children (26%) showed similar behavioral response during both modes of local anesthetic administration. Thirty-eight children preferred to receive local anesthesia with the C-CLAD device, whereas only six children preferred cartridge syringe injections.¹⁸ Yogesh-Kumar et al. concluded that the use of a C-CLAD device (The Wand STA system) can be considered as a reliable step toward achieving an enhanced behavioral response in children and should be considered as a means of improving the treatment of the pediatric dental patient.

Perugia et al.²³ undertook a study to compare pain perception and time of onset and duration of anesthesia between PDL injection performed with a C-CLAD device (The Wand STA system) and conventional infiltration anesthesia with a conventional syringe. Fifty patients were enrolled. Two groups of 25 patients were formed and assigned to receive either The Wand STA PDL injection or traditional anesthetic infiltration. In both the maxilla and the mandible, the sample teeth were primary and permanent molars, requiring restorative treatments or extractions. Disruptive pain behavior was correlated with pain response, and the results revealed that 88% of the patients treated with the conventional syringe showed a disruptive behavior attributed to pain perception, whereas 0% showed disruptive behavior due to pain perception when the anesthesia was administered with C-CLAD technology. For primary teeth, the onset of anesthesia at the time of completion of the injection and at 10 minutes demonstrated positive responses of 66.67% for the conventional injection group and 93.33% in The Wand STA PDL injection group. With respect to the duration of anesthesia, the effectiveness of the conventional technique decreased to 72% at 40 minutes, while the effectiveness of the C-CLAD injection technique was 96% at 10 minutes and remained constant throughout measurement times of 20 minutes and 40 minutes. This study demonstrated the safety and the efficacy of using a C-CLAD device (The Wand STA system) to result in a faster onset, a more predictable outcome, and a longer duration of anesthesia for the PDL injection in children. The treatment of either primary molar teeth with a The Wand STA PDL injection resulted in reduced disruptive pain behavior that correlated with a reduced pain response when compared with the conventional technique using a conventional syringe.²³

The PDL injection performed with The Wand STA system is a single-tooth injection technique that provides a level of safety, comfort, and predictability previously unattainable. The system provides the clinician with multiple

benefits that cannot be achieved with use of a manually driven conventional syringe, a pistol-grip high-pressure syringe, or other C-CLAD instruments.

Other Common Names

Peridental (original name) injection, intraligamentary injection.

Nerves Anesthetized

Terminal nerve endings at the site of injection and at the apex of the tooth.

Areas Anesthetized

Bone, soft tissue, and apical and pulpal tissues in the area of the injection.

Indications

1. Pulpal anesthesia of one or two teeth in a quadrant.
2. Treatment of isolated teeth in two mandibular quadrants (to avoid bilateral IANB).
3. Patients for whom residual soft tissue anesthesia is undesirable.
4. Pediatric dental patient in treatment of the primary dentition.
 - a. A recent study reported that use of a C-CLAD system does not present the previous risk of enamel hypoplasia that was reported with a manually driven syringe, and that use of a C-CLAD system does not adversely affect the developing permanent tooth when PDL injection is performed.⁴³
5. Situations in which regional block anesthesia is contraindicated.
6. As a possible aid in diagnosis of pulpal discomfort.
7. As an adjunctive technique after nerve block anesthesia if partial anesthesia is present.

Contraindications

1. Infection or inflammation at the site of injection
2. Patients who require a "numb" sensation for psychological comfort

Advantages

1. The Wand STA C-CLAD device with DPS technology provides an objective means by which to identify the correct target location to perform a PDL injection, improving the predictability of this injection when compared with previous techniques and instruments.
2. The Wand STA C-CLAD device uses a controlled low-pressure fluid dynamic that has been shown to reduce the risk of tissue injury and to minimize subjective pain responses.
3. The Wand STA C-CLAD device, through use of a controlled low-pressure fluid dynamic, allows a greater volume of anesthetic solution (0.45 to 0.90 mL) to be safely administered, thereby increasing the effective working time of this PDL injection (30 to 45 minutes).

- The Wand STA C-CLAD device with DPS technology can detect excessive pressure and can safeguard the patient and operator.

Disadvantages

- Requires the use of a specialized C-CLAD instrument and associated costs of purchase and use
- Requires additional training

Positive Aspiration

Zero percent.

Technique

- A Wand STA bonded handpiece with a 30-gauge 0.5-inch needle.
- Set the Wand STA instrument to the STA mode.
- Area of insertion:
 - The needle should be placed at a 45-degree angle to the long axis of the tooth with the bevel of the needle facing the root of the tooth.
 - When a PDL injection is performed it is recommended that both a distal and a mesial site on the tooth be used with the exception of mandibular incisors, where only a distolingual site is needed.
 - Start with the distal aspect of the tooth.
 - The injection can be performed anywhere from the lingual line angle to the interproximal contact for each root.
 - The injection can be performed anywhere from the lingual line angle to the interproximal contact for each site.
- To improve accessibility in difficult areas, shorten The Wand STA handpiece by breaking off a section of the handle. This will allow easier access (Fig. 15.6D). If possible, use a mouth mirror to minimize the risk of accidental needlestick injury to the administrator.
- Place the needle very slowly into the gingival sulcus as if it were a periodontal probe, while simultaneously initiating the ControlFlo flow rate (0.005 mL/s). Advance the needle slowly into the sulcus, advancing it gently until resistance is encountered. The tip of the needle will penetrate the attachment at the base of the sulcus and make contact with the entrance to the PDL space.
- The ControlFlo flow rate can be initiated by pressing on the foot control; after three audible beeps, the unit will announce "Cruise." Once "Cruise" is heard, your foot may be removed from the foot control. The Wand STA system will continue the flow of anesthetic solution.
- Once resistance is felt, movement of the needle needs to be minimized for 10 to 15 seconds as the DPS technology analyzes the location of the needle tip.
- As The Wand STA system senses pressure building, you will see a sequential illumination of LED lights on the front of the unit. The visual pressure-sensing scale consists of a series of red, yellow, and green LED lights. If after 20 to 30 seconds pressure does not build, the needle will need to be relocated. The Wand STA system also provides audible pressure feedback, with a series of three ascending tones indicating that the system is detecting pressure at the needle tip.
- After 20 to 30 seconds with the needle tip in the correct location, the STA system will announce "P-D-L, P-D-L." This is followed by a series of two longer "beeps," indicating that proper pressure is being maintained, and that you have identified the correct needle tip position for the PDL injection.
- It is important to note that a successful PDL injection may occur when the LED lights are in green or high yellow zones. It is necessary to maintain the LED light indicators throughout the injection process to achieve success. Note that you will not hear the audible spoken word *PDL* in the yellow zone.
- Deposit 0.45 to 0.90 mL of local anesthetic per site.
- Excessive force on the handpiece can block the flow of local anesthetic, resulting in a partially or completely unsuccessful PDL injection.

Signs and Symptoms

- Indicators of success:
 - Subjective: There are no signs that absolutely assure adequate anesthesia; the anesthetized area is quite circumscribed. When the following signs are present, there is an excellent chance that profound anesthesia is present:
 - Subjective: ischemia of soft tissues at the injection site.
 - Subjective: maintenance of high yellow and green LED zones on the front of the STA drive unit throughout the injection process.
 - Objective: use of a freezing spray (e.g., Endo-Ice) or an EPT with no response from the tooth with maximal EPT output (80/80).

Safety Feature

The Wand STA system DPS technology precisely regulates and monitors fluid exit pressures within the tissues, thereby preventing buildup of excessive pressure and ensuring a safe and effective controlled flow rate of local anesthetic solution.

Precautions

- Maintain direct vision of the needle as it enters the sulcus of the tooth.
- Advance the needle into the entrance to the PDL space. Maintain the needle along the long axis of the tooth, with its bevel facing the root surface, to ensure that the needle is inserted into the entrance to the PDL space at the level of the crest of bone.
- Do not use excessive force on The Wand STA handpiece to force the needle into the PDL space.
- Do not inject anesthetic solution directly into infected or highly inflamed tissues.

Failures of Anesthesia

- Infected or inflamed tissues. The pH and vascularity changes at the apex of, and periodontal tissues surrounding, infected teeth minimize the effectiveness of the local anesthetic.

2. Inability to establish proper needle position and therefore cannot generate adequate pressures with the Wand STA system. **PDF Compressor File Version**
In this case, remove the needle and reenter at a different site(s) until The Wand STA system can generate and maintain the proper DPS outcome.
3. Excessive force on The Wand STA handpiece may cause the needle to become clogged. The Wand STA system will issue a verbal alert by announcing *overpressure* and *relocate*.

Complications

1. Pain during insertion of the needle.
Cause: the needle is inserted into the sulcus too rapidly or too deeply. To correct this, enter and move the needle very slowly into the sulcus while simultaneously initiating the slow flow-rate (ControlFlo flow-rate) of the local anesthetic solution.
2. Inability to establish proper needle position and therefore cannot generate adequate moderate to high pressure in the yellow or green LED pressure zones with the wand STA system.
Cause 1: have not located the entrance to the intraligamentary tissue (PDL space). To correct this, relocate the needle.
Cause 2: have not allowed adequate time (10 to 20 seconds) for back-pressure and analysis of DPS technology to occur. To correct this, position the needle and allow 10 to 20 seconds for the ascending tones and sequential illumination of the LED lights.
3. Overpressure announcement by The Wand STA system.
Cause 1: excessive hand force on The Wand STA handpiece can force the needle into the bone, resulting in obstruction of flow of the anesthetic solution at the needle tip. To correct, this restart The Wand STA system and use gentler forward hand pressure when placing the needle into the sulcus.
Cause 2: clogged needle tip from plaque or dental calculus. To correct this, stop, remove the needle, and restart, verifying that local anesthetic solution is flowing from the tip of the needle before reentry into PDL tissues.
4. Postinjection pain or tissue necrosis.
Cause 1: excessive volume of anesthetic solution was used.
To correct this, limit the volume of anesthetic solution.
Cause 2: too many tissue penetrations with the needle and/or excessive forward hand force placed on the needle, causing mechanical trauma to the tissues. To correct this, limit the number of needle entries to a given site and use a moderate amount of forward hand pressure on The Wand STA handpiece.

Suggested Drug/Volume

1. Four percent articaine hydrochloride with epinephrine 1:200,000.
 - a. Adult:
 - i. Drug volume no greater than 0.45 mL (one-fourth of a cartridge) is suggested for a single site of the mandibular incisors.

- ii. Drug volume no greater than 0.9 mL (half of a cartridge) is suggested for all other teeth consisting of two separate sites per tooth.
 - b. Child (up to 30 kg):
 - a. Drug volume no greater than 0.23 mL (one-eighth of a cartridge) is suggested for a single site of the primary mandibular incisors.
 - b. Drug volume no greater than 0.45 mL (one-fourth of a cartridge) is suggested for all other primary teeth using two separate sites per tooth.
2. Two percent lidocaine hydrochloride with epinephrine 1:100,000.
 - a. Adult:
 - i. Drug volume no greater than 0.9 mL (half of a cartridge) is suggested for a single site of the mandibular incisors.
 - ii. Drug volume no greater than 1.8 mL (one cartridge) is suggested for all other teeth consisting of two separate sites per tooth.
 - b. Child (up to 30 kg):
 - i. Drug volume no greater than 0.45 mL (one-fourth of a cartridge) is suggested for a single site of the primary mandibular incisors.
 - ii. Drug volume no greater than 0.9 mL (half of a cartridge) is suggested for all other primary teeth using two separate sites per tooth.

Duration of Expected Anesthesia

The expected pulpal anesthesia duration is directly correlated with the volume of local anesthetic solution administered. The recommended doses provide pulpal anesthesia ranging from 30 to 45 minutes. The PDL injection may be repeated if necessary to permit completion of the dental procedure.

Advantages and disadvantages of The Wand STA system are presented in [Box 15.1](#).

Intraseptal Injection

The intraseptal injection is similar in technique and design to the PDL injection. It is included for discussion as it is useful in providing osseous and soft tissue anesthesia and hemostasis for periodontal curettage⁵¹ and surgical flap procedures, as well as minor restorative procedures in mandibular posterior teeth.⁵² In addition, it may be effective when the condition of periodontal tissues in the gingival sulcus precludes use of the PDL injection (e.g., infection, acute inflammation). Saadoun and Malamed⁵¹ and Talesh and Kahnamouii⁵² have shown that the path of diffusion of the anesthetic solution is through medullary bone, as in the PDL injection.

Other Common Names

Crestal anesthesia.

Nerves Anesthetized

Terminal nerve endings at the site of injection and in adjacent soft and hard tissues.

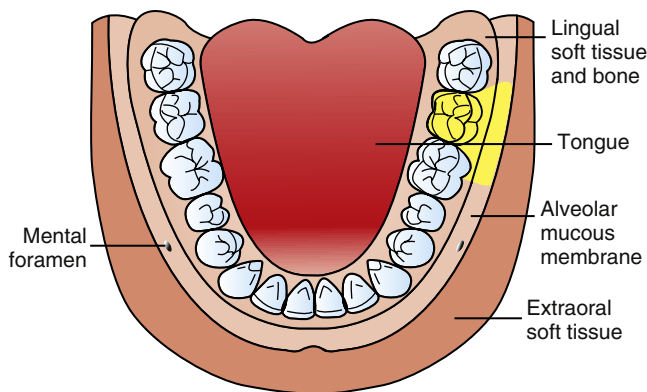
• **BOX 15.1** Advantages and Disadvantages of The Wand STA Single Tooth Anesthesia System
PDE Compressor Free Version

Advantages

Dynamic pressure-sensing (DPS) technology provides continuous real-time feedback when an injection is performed, resulting in a more predictable injection. Allows the periodontal ligament injection to be used as a predictable primary injection. Allows all traditional injections techniques to be performed. Allows newer injection techniques— anterior middle superior alveolar, palatal approach anterior superior alveolar, and STA intraligamentary injections—to be performed. Reduces pain-disruptive behavior in children and adults. Reduces stress for patient. Reduces stress for operator.

Disadvantages

Requires additional armamentarium
 Cost



• **Fig. 15.7** Area anesthetized by an intraseptal injection.

Areas Anesthetized

Bone, soft tissue, root structure in the area of injection (Fig. 15.7).

Indication

When both pain control and hemostasis are desired for soft tissue and osseous periodontal treatment or for minor restorative procedures on mandibular posterior teeth.

Contraindication

Infection or severe inflammation at the injection site.

Advantages

1. Lack of lip and tongue anesthesia (appreciated by most patients)
2. Minimum volumes of local anesthetic necessary
3. Minimized bleeding during the surgical procedure
4. Atraumatic
5. Immediate onset of action (<30 seconds)
6. Few postoperative complications

7. Useful on periodontally involved teeth (avoids infected pockets)

Disadvantages

1. Multiple tissue punctures may be necessary.
2. Bitter taste of the anesthetic drug (if leakage occurs).
3. Relatively short duration of pulpal anesthesia; limited area of soft tissue anesthesia (may necessitate reinjection).
4. Clinical experience necessary for success.

Positive Aspiration

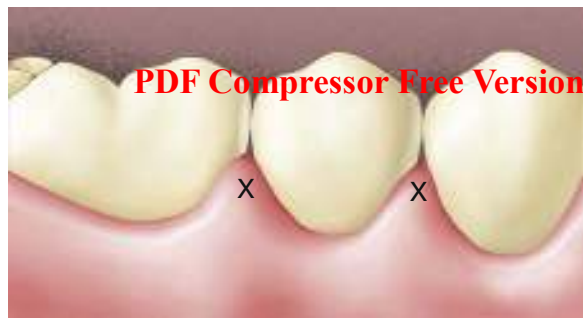Zero percent.

Alternatives

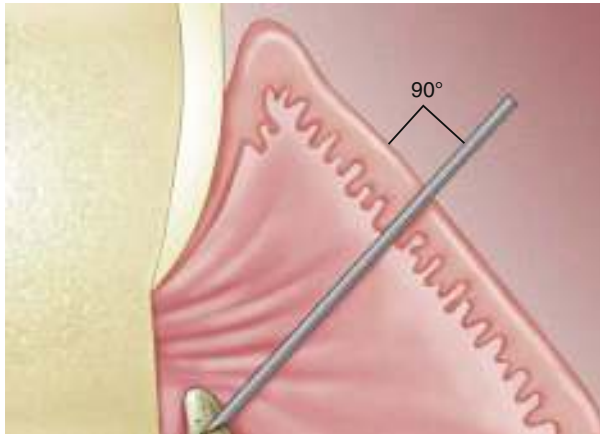
1. PDL injection in the absence of infection or severe periodontal involvement
2. Intraosseous anesthesia
3. Regional nerve block with local infiltration for hemostasis

Technique

1. A 27-gauge short needle is recommended.
2. Area of insertion: center of the interdental papilla adjacent to the tooth to be treated (Fig. 15.8).
3. Target area: center of the interdental papilla adjacent to the tooth to be treated.
4. Landmarks: papillary triangle, about 2 mm below the tip, equidistant from adjacent teeth.
5. Orientation of the bevel: not significant, although Saadoun and Malamed⁵¹ recommend toward the apex.
6. Procedure:
 - a. Assume the correct position, which varies significantly from tooth to tooth. The administrator should be comfortable, have adequate visibility of the injection site, and maintain control over the needle.
 - b. Position the patient supine or semisupine with the head turned to maximize access and visibility.
 - c. Prepare tissue at the site of penetration:
 - i. Dry it with sterile gauze.
 - ii. Apply topical antiseptic (optional).
 - iii. Apply topical anesthetic for minimum of 1 minute.
 - d. Stabilize the syringe and orient the needle correctly (Fig. 15.9). If possible, use a mouth mirror to minimize the risk of accidental needle stick injury to the administrator.
 - i. Frontal plane: 45 degrees to the long axis of the tooth.
 - ii. Sagittal plane: at a right angle to the soft tissue.
 - iii. Bevel facing the apex of the tooth.
 - e. Slowly inject a few drops of local anesthetic as the needle enters soft tissue and advance the needle until contact with bone is made.
 - f. While applying pressure to the syringe, push the needle slightly deeper (1 to 2 mm) into the interdental septum.
 - g. Deposit 0.4 mL of local anesthetic in not less than 20 seconds.
 - i. With a conventional syringe, the thickness of the rubber plunger is equivalent to 0.2 mL.



• Fig. 15.8 Area of insertion for an intraseptal injection.



• Fig. 15.9 Orientation of the needle for an intraseptal injection.

- h. Two important items indicate success of the intraseptal injection:
 - i. Significant resistance to the deposition of solution.
 - a. This is especially noticeable when a conventional syringe is used. Resistance is similar to that felt with nasopalatine and PDL injections.
 - b. Anesthetic solution should not come back into the patient's mouth. If this occurs, repeat the injection with the needle slightly deeper.
 - ii. Ischemia of soft tissues adjacent to the injection site (although noted with all local anesthetic solutions, this is more prominent with local anesthetics containing a vasoconstrictor).
- i. Repeat the injection as needed during the surgical procedure.

Signs and Symptoms

1. As with the PDL injection, no objective symptoms ensure adequate anesthesia. The anesthetized area is too circumscribed.
2. Subjective: ischemia of soft tissues is noted at the injection site.
3. Subjective: resistance to the injection of solution is felt.

Safety Feature

Intravascular injection is extremely unlikely to occur.

Precautions

1. Do not inject anesthetic solution into infected tissue.

2. Do not inject anesthetic solution rapidly (not faster than 20 seconds).
3. Do not inject too much solution (0.4 mL per site).

Failures of Anesthesia

1. Infected or inflamed tissues. Changes in tissue pH minimize the effectiveness of the local anesthetic.
2. Solution not retained in tissue. To correct this, advance the needle further into the septal bone and readminister 0.4 mL.

Complication

Postinjection pain is unlikely to develop because the injection site is within the area of surgical treatment. Saadoun and Malamed⁵¹ demonstrated that postsurgical periodontal discomfort after the use of intraseptal anesthesia is no greater than after a regional nerve block. Talesh and Kahnamousii⁵² reported that 50% of crestal anesthesia patients complained of mild gingival soreness of no more than 1 day. They stated that most patients receiving crestal anesthesia were pleased with not having discomfort and incapacitation often experienced with IANB anesthesia. By the end of 3-month follow-up, no problem that could be attributed to crestal anesthesia was found.⁵²

Duration of Expected Anesthesia

The duration of osseous and soft tissue anesthesia is variable after an intraseptal injection. Using an epinephrine concentration of 1:50,000, Saadoun and Malamed⁵¹ found pain control and hemostasis adequate for completion of the planned procedure without reinjection in most patients. However, some patients require a second intraseptal injection.

Talesh and Kahnamousii, comparing crestal anesthesia with IANB for restorative procedures on mandibular posterior teeth found the duration of pulpal anesthesia following crestal anesthesia to be approximately 23 minutes, compared with 32 minutes for the IANB (Table 15.1). The crestal anesthesia injection was more comfortable for the patient (VAS score 1.54 for crestal anesthesia, VAS score 3.44 for IANB). Perhaps of greatest significance is the volume of local anesthetic required to provide pulpal anesthesia: 0.4 mL versus 1.99 mL for IANB. Success rates for all teeth evaluated were higher for crestal anesthesia than for IANB (Table 15.2).

Intraosseous Injection

Deposition of local anesthetic solution into the interproximal bone between two teeth has been practiced in dentistry since the start of the 20th century.³⁵ Originally, intraosseous anesthesia necessitated the use of a half-round burr to provide entry into interseptal bone that had been surgically exposed. Once the hole had been made, a needle would be inserted into this hole and local anesthetic deposited.

The PDL and intraseptal injections previously described are variations of intraosseous injection. With the PDL injection, local anesthetic enters interproximal bone through the

TABLE 15.1 Intraseptal (Crestal) Anesthesia Compared With Inferior Alveolar Nerve Block

	Intraseptal (Crestal) Anesthesia	Inferior Alveolar Nerve Block	<i>P</i>
Onset (s)	7.00 ± 0.71	3.30 ± 0.67	<.001
Duration (min)	23.10 ± 2.13	32.10 ± 2.02	<.05
Pain (visual analog scale)	1.54 ± 0.18	3.44 ± 0.22	<.001
Volume (mL)	0.4 ± 2.07	1.99	

Data from Talesh KT, Kahnamouii SS. Application of crestal anesthesia for treatment of class 1 caries in posterior mandibular teeth. *J Dent Res Dent Clin Dent Prospect.* 2011;5:17–22.

TABLE 15.2 Rate of Success Achieved by Intraseptal (Crestal) Anesthesia and Inferior Alveolar Nerve Block Techniques

Tooth	Intraseptal (Crestal) Anesthesia	Inferior Alveolar Nerve Block
First premolar	96% (<i>n</i> = 16)	82% (<i>n</i> = 17)
Second premolar	98% (<i>n</i> = 26)	83% (<i>n</i> = 21)
First molar	100% (<i>n</i> = 52)	85% (<i>n</i> = 45)
Second molar	100% (<i>n</i> = 40)	88% (<i>n</i> = 36)
Third molar	100% (<i>n</i> = 19)	93 (<i>n</i> = 15)

Data from Talesh KT, Kahnamouii SS. Application of crestal anesthesia for treatment of class 1 caries in posterior mandibular teeth. *J Dent Res Dent Clin Dent Prospect.* 2011;5:17–22.

periodontal tissues surrounding a tooth, whereas in intraseptal injection, the needle is embedded into the interproximal (crestal) bone without the use of a burr.

In recent years the technique has been modified with the introduction of several devices that simplify the procedure. The Stabident system was introduced, followed later by the X-Tip.

The Stabident system comprises a slow-speed handpiece-driven perforator, a solid 27-gauge wire with a beveled end that when activated drills a small hole through the cortical plate. The anesthetic solution is delivered to cancellous bone through the 27-gauge ultrashort injector needle placed into the hole made by the perforator (Fig. 15.10).⁵³

Experience with the intraosseous technique has shown that perforation of the interproximal bone is almost always entirely atraumatic. However, some persons initially had difficulty placing the needle of the local anesthetic syringe back into the previously drilled hole in the interproximal bone. Introduction of the X-Tip eliminated this problem.

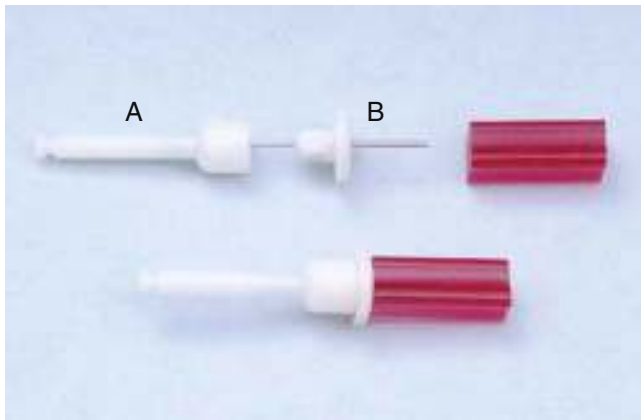
The X-Tip anesthesia delivery system consists of an X-Tip that separates into two parts: the drill and the guide sleeve component (Fig. 15.11). The drill (a special hollow needle) leads the guide sleeve through the cortical plate, whereupon it is separated and withdrawn. The remaining guide sleeve is designed to accept a 27-gauge needle to inject the anesthetic solution. The guide sleeve is removed after the intraosseous injection is complete.

The intraosseous injection technique can provide anesthesia of a single tooth or multiple teeth in a quadrant. To a significant degree, the area of anesthesia is dependent on both the site of injection and the volume of local anesthetic deposited. It is recommended that 0.45 to 0.6 mL of anesthetic be administered when treatment is to be confined to not more than one or two teeth. Greater volumes (up to 1.8 mL) may be required when treatment of multiple teeth in one quadrant is planned. The intraosseous injection may be used when six or eight mandibular anterior teeth (e.g., first premolar to first premolar bilaterally) are treated. Bilateral intraosseous injections are necessary; the perforation being made between the canine and the first premolar on both sides. This provides pulpal anesthesia of eight teeth. It should be remembered, however, that the incisive nerve block provides pulpal anesthesia of these same teeth without the need for perforation of bone.

Because intraosseous injections deposit local anesthetic into a vascular site, it is suggested that the volume of local anesthetic delivered be kept to the recommended minimum to avoid possible overdose.⁵⁴ In addition, because of the high incidence of palpitation (conscious awareness of a rapid heartbeat) noted when vasopressor-containing local anesthetics are used, a “plain” local anesthetic is recommended, if possible, in the intraosseous injection. Transient tachycardia has been reported following intraosseous injections with



• **Fig. 15.10** Intraosseous anesthesia: Stabident. Components: needle (A); perforator (B).



• **Fig. 15.11** Intraosseous anesthesia: X-Tip. Components: drill (A); guide sleeve (B).

epinephrine- or levonordefrin-containing local anesthetic solutions between 46% and 93% of the time.⁵⁵⁻⁵⁷ The use of a plain solution such as 3% mepivacaine does not lead to a significant increase in heart rate.^{58,59} However, discussion with endodontists who use intraosseous injection frequently for management of symptomatic irreversible pulpitis in mandibular molars indicates that the quality and depth of anesthesia are not as great when plain local anesthetics are used. It is suggested that when epinephrine is included in the local anesthetic solution that the smallest volume of the least concentrated epinephrine solution be administered (e.g., 1:200,000)

Other Common Names

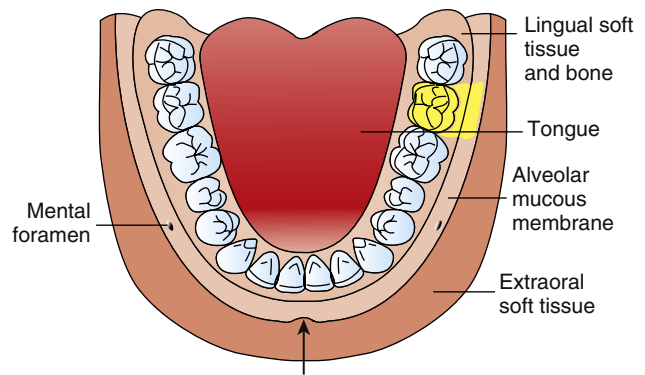
None.

Nerves Anesthetized

Terminal nerve endings at the site of injection and in adjacent soft and hard tissues.

Areas Anesthetized

Bone, soft tissue, and root structure in the area of injection (Fig. 15.12).



• **Fig. 15.12** Area anesthetized by intraosseous injection.

Indication

Pain control for dental treatment on single or multiple teeth in a quadrant.

Contraindication

Infection or severe inflammation at the injection site.

Advantages

1. Lack of lip and tongue anesthesia (appreciated by most patients)
2. Atraumatic
3. Immediate onset of action (<30 seconds)
4. Few postoperative complications

Disadvantages

1. Usually requires a special device (e.g., Stabident system, X-Tip), although intraosseous anesthesia can be administered with a traditional half-round burr
2. Bitter taste of the anesthetic drug (if leakage occurs)
3. Occasional (rare) difficulty in placing the anesthetic needle into a predrilled hole (primarily in mandibular second and third molar regions)
4. High incidence of palpitation when a vasopressor-containing local anesthetic is used

Positive Aspiration

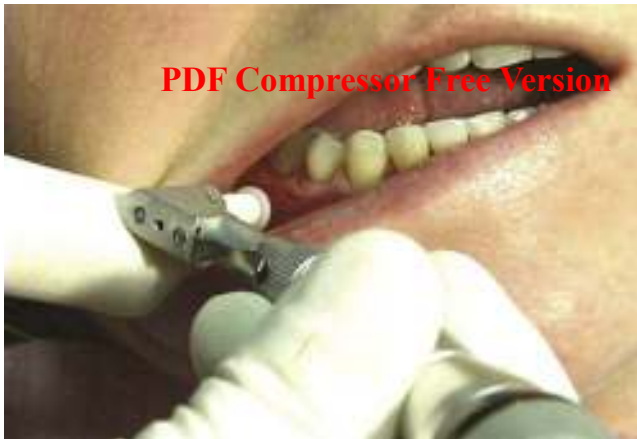Minimal. Approximately 1% to 3%.

Alternatives

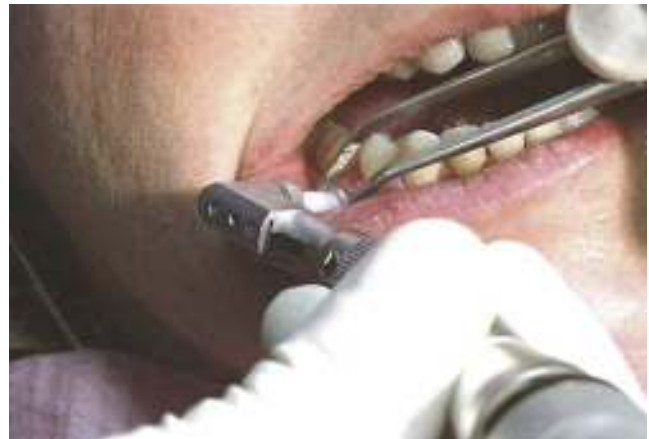1. PDL injection, in the absence of infection or severe periodontal involvement
2. Intraseptal injection
3. Supraperiosteal injection
3. Regional nerve block

Technique

1. Selection of site for injection.
 - a. Lateral perforation:
 - i. At a point 2 mm apical to the intersection of lines drawn horizontally along the gingival margins of the teeth and a vertical line through the interdental papilla.



• **Fig. 15.13** Drill hole using a gentle “pecking” motion.

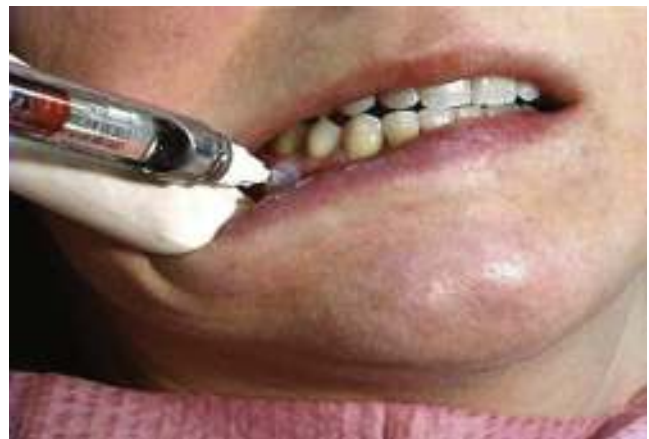

• **Fig. 15.14** Hold the guide sleeve in place as the drill is withdrawn.

- ii. The site should be located *distal* to the tooth to be treated, if possible, although this technique provides anesthesia in most cases when anesthetic is injected anterior to the tooth being treated.
- iii. Avoid injecting anesthetic in the mental foramen area (increased risk of nerve damage).
- b. Vertical perforation (for edentulous areas):
 - i. Perforate at a point on the alveolar crest mesial or distal to the treatment area (also called the *crestal anesthesia technique*).

2. Technique:

- a. Remove the X-Tip from its sterile vial.
 - i. Hold the protective cover as you insert the X-Tip onto the slow-speed handpiece (20,000 rpm).
- b. Prepare soft tissues at the perforation site:
 - i. Prepare tissue at the injection site with 2- × 2-inch sterile gauze.
 - ii. Apply topical anesthetic to the injection site for a minimum of 1 minute.
 - iii. Place the bevel of the needle against gingiva, injecting a small volume of local anesthetic until blanching occurs.
 - iv. Check soft tissue anesthesia using cotton pliers (cotton pliers leave a slight dimple marking of the perforation site).
 - v. Inject a few drops of local anesthetic into the dimple.
- c. Perforation of the cortical plate:
 - i. While holding the perforator perpendicular to the cortical plate, gently push the perforator through the attached gingiva until its tip rests against bone (without activating the handpiece).
 - ii. Activate the handpiece, using a gentle “pecking” motion on the perforator until a sudden loss of resistance is felt. Cortical bone will be perforated within 2 seconds (**Fig. 15.13**). Pecking motion minimizes overheating of the bone, which can lead to postinjection pain, swelling, or exudate. This has been noted to develop in about 5% of patients receiving intraosseous injections.^{60,61}
 - iii. Hold the guide sleeve in place as the drill is withdrawn (**Fig. 15.14**). Withdraw the perforator and dispose of it safely (sharps container). The guide sleeve remains in place until you are certain you have adequate anesthesia.



• **Fig. 15.15** Insert the needle into the guide sleeve and inject local anesthetic solution.

- d. Injection into cancellous bone:
 - i. It is easy to insert the needle into the hole when a short needle is used (**Fig. 15.15**).
 - ii. Press the tapered needle gently against the guide sleeve to minimize local anesthetic leakage.
 - a. Compress a cotton roll or 2- × 2-inch sterile gauze against the mucosa to absorb any excess local anesthetic.
 - iii. Slowly and gently inject the local anesthetic solution.
- e. The recommended doses for the X-Tip are the same for each local anesthetic solution as is recommended for other injections.
- f. For Stabident doses, see **Table 15.3**.

Signs and Symptoms

1. Subjective: ischemia of soft tissues at the injection site
2. Objective: use of freezing spray (e.g., Endo-Ice) or an EPT with no response from the tooth with maximal EPT output (80/80)

Safety Feature

Intravascular injection is extremely unlikely, although the area into which anesthetic is injected is quite vascular. Slow injection of the recommended volume of

TABLE 15.3 Stabident Doses

To Anesthetize	Injection Site	Dose (1.8-mL Cartridges)
Stabident Mandibular Doses		
One tooth	Immediately distal <i>or</i> immediately mesial	One-quarter to one-third
Two adjacent teeth	Between the two teeth <i>or</i> immediately distal to the more distal tooth	One-third to half
Three adjacent teeth	Immediately distal to the middle tooth	Half
Six front teeth plus the first premolars (i.e., total of eight teeth)	Give two injections, one on each side, between the canine and the first premolar	Half on each side (total of one)
Stabident Maxillary Doses		
One tooth	Immediately distal <i>or</i> immediately mesial	One-quarter
Two adjacent teeth	Between the two teeth	One-quarter
Four adjacent teeth (e.g., 1, 2, 3, and 4)	Midway (e.g., two teeth distal and two teeth mesial to the injection site)	Half
Up to eight teeth on one side	Midway (e.g., four teeth distal and four teeth mesial to the injection site)	One

From www.stabident.com.

solution is important to keeping intraosseous anesthesia safe.

Precautions

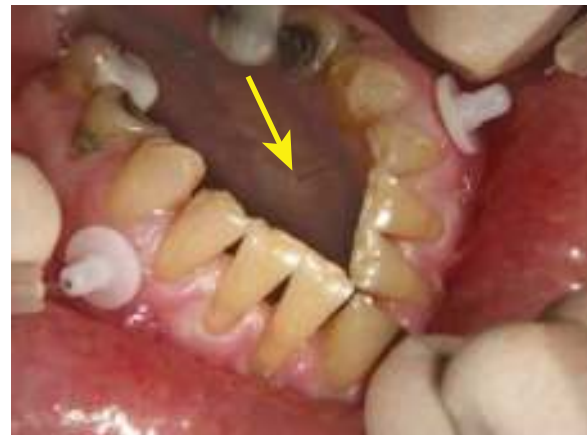1. Do not inject anesthetic into infected tissue.
2. Do not inject anesthetic rapidly.
3. Do not inject too much solution (see recommended doses in [Table 15.3](#)).
4. Do not use a vasopressor-containing local anesthetic unless necessary, and then only 1:200,000 or 1:100,000 concentration. Avoid use of epinephrine 1:50,000.

Failures of Anesthesia

1. Infected or inflamed tissues. Changes in tissue pH minimize the effectiveness of the anesthetic.
2. Inability to perforate cortical bone. If cortical bone is not perforated within 2 seconds, it is recommended that drilling be stopped and an alternative site be used.

Complications

1. Palpitation: This reaction frequently occurs when a vasopressor-containing local anesthetic is used. To minimize its occurrence, use a “plain” local anesthetic, if possible, or the most dilute epinephrine concentration available (e.g., 1:200,000).
2. Postinjection pain is unlikely (~5%) after intraosseous anesthesia.^{60,61} The use of mild analgesics (nonsteroidal antiinflammatory drugs) is recommended if discomfort occurs in the postinjection period.
3. Fistula formation at the site of perforation has been reported on occasions. In most instances, this can be prevented by use of a gentle “pecking” motion with the



• **Fig. 15.16** Accidental perforation of lingual plate (arrow).

handpiece as the perforator goes through the cortical plate of bone. Application of constant pressure against the bone presumably leads to the buildup of heat, with possible bony necrosis and fistula formation.

4. Separation of the perforator or cannula is rare but is reported to occur in approximately 1% of intraosseous injections.⁶² The metal shaft of the burr or cannula separates and remains in bone. It is usually easy to remove with a hemostat.
5. Perforation of lingual plate of bone ([Fig. 15.16](#)). This is prevented by proper technique.

Duration of Expected Anesthesia

Pulpal anesthesia of between 15 and 30 minutes can be expected. If a vasopressor-containing solution is used, the duration approaches 30 minutes. If a plain solution is used,

a 15-minute duration is usual. The depth of anesthesia is greater with a vasopressor-containing local anesthetic.

PDF Compressor Free Version

Intrapulpal Injection

Obtaining profound anesthesia in the presence of irreversible pulpitis was a significant problem before the rediscovery of intraosseous anesthesia. It is noted to develop in between 5% and 10% of mandibular posterior teeth following IANB and supplemental injections, even when they are repeated.⁵³ Specifically, the problem occurred with mandibular molars, because few alternative anesthetic techniques were available with which the doctor could obtain profound anesthesia. Maxillary teeth are usually anesthetized with a supraperiosteal injection or a nerve block such as the posterior superior alveolar, anterior superior alveolar, anterior middle superior alveolar, or (rarely) maxillary (second division; V₂) nerve block. Mandibular teeth anterior to the molars are anesthetized with the incisive nerve block. Anesthesia of mandibular molars, however, is commonly limited to nerve block anesthesia, which may prove to be ineffective in the presence of infection and inflammation. A suggested protocol for obtaining profound pulpal anesthesia in symptomatic irreversible pulpitis is described in [Chapters 16 and 19](#).

Deposition of local anesthetic directly into the coronal portion of the pulp chamber of a pulpally involved tooth provides effective anesthesia for pulpal extirpation and instrumentation where other techniques have failed. The intrapulpal injection may be used on any tooth when difficulty in providing profound pain control exists, but from a practical view, it is necessary most commonly on mandibular molars.

The intrapulpal injection provides pain control through both the pharmacologic action of the local anesthetic and applied pressure. This technique may be used once the pulp chamber is exposed surgically or pathologically.

Its major drawback is the need to insert the needle directly into a vital, and very sensitive, pulp. The intrapulpal injection is frequently moderately to intensely painful.^{63,64}

Other Common Names

None.

Nerves Anesthetized

Terminal nerve endings at the site of injection in the pulp chamber and canals of the involved tooth.

Areas Anesthetized

Tissues within the injected tooth.

Indication

When pain control is necessary for pulpal extirpation or other endodontic treatment in the absence of adequate anesthesia following repeated attempts with other techniques.

Contraindication

None. The intrapulpal injection may be the only local anesthetic technique available in some clinical situations.

Advantages

1. Lack of lip and tongue anesthesia (appreciated by most patients)
2. Minimum volumes of anesthetic solution necessary
3. Immediate onset of action
4. Very few postoperative complications

Disadvantages

1. Traumatic: the intrapulpal injection is associated with a brief period of pain as anesthetic is deposited.
2. Bitter taste of the anesthetic drug (if leakage occurs).
3. Relatively short duration of action (15 to 20 minutes).⁵⁶
4. May be difficult to enter certain root canals (bending of the needle may be necessary).
5. A small opening into the pulp chamber is needed for optimum effectiveness. Large areas of decay make it more difficult to achieve profound anesthesia with the intrapulpal injection.

Positive Aspiration

Zero percent.

Alternatives

Intraosseous injection. However, when intraosseous injection fails, intrapulpal injection may be the only viable alternative to provide clinically adequate pain control.

Technique

1. Insert a 25- or 27-gauge short or long needle into the exposed pulp chamber or the root canal as needed ([Fig. 15.17](#)).
2. Ideally, wedge the needle firmly into the pulp chamber or root canal. Occasionally the needle does not fit snugly into the canal. In this situation the anesthetic can be deposited in the chamber or canal. Anesthesia in this case is produced only by the pharmacologic action of the local anesthetic; there is no pressure anesthesia.
3. Deposit anesthetic solution under pressure. A small volume of anesthetic (0.2 to 0.3 mL) is necessary for successful intrapulpal anesthesia if the anesthetic remains within the tooth. In many situations, the anesthetic simply flows back out of the tooth into the aspirator (vacuum) tip.
4. Resistance (back pressure) to injection of the drug should be felt and is important for the success of the injection.
5. Bend the needle, if necessary, to gain access to the pulp chamber ([Fig. 15.17](#)). Although there is an increased risk of breakage with a bent needle, this is not a problem during intrapulpal anesthesia, because the needle is inserted into the tooth itself, not into soft tissues. In addition, 25- and 27-gauge needles rarely break (see [Chapter 6](#)). Retrieval is relatively simple if the needle breaks.
6. When the intrapulpal injection is performed properly, a brief period of sensitivity (ranging from mild to very painful) usually accompanies the injection. Pain relief usually occurs immediately thereafter, permitting instrumentation to proceed atraumatically.
7. Instrumentation may begin approximately 30 seconds after the injection is given.



• **Fig. 15.17** The needle may have to be bent to gain access to a canal. (Modified from Cohen S, Burns RC. *Pathways of the pulp*. 8th ed. St Louis: Mosby; 2001.)

Signs and Symptoms

1. As with PDL, intraseptal, and intraosseous injections, no subjective symptoms ensure adequate anesthesia. The area is too circumscribed.
2. Objective: the endodontically involved tooth may be treated painlessly.

Safety Features

1. Intravascular injection is extremely unlikely to occur.
2. Small volumes of anesthetic are administered.

Precautions

1. Do not inject anesthetic into infected tissue.
2. Do not inject anesthetic rapidly (not <20 seconds).
3. Do not inject too much solution (0.2 to 0.3 mL).

Failures of Anesthesia

1. Infected or inflamed tissues. Changes in tissue pH minimize the effectiveness of the anesthetic. However, intrapulpal anesthesia invariably works to provide effective pain control.
2. Solution not retained in tissue. To correct this, try to advance the needle farther into the pulp chamber or root canal, and readminister 0.2 to 0.3 mL of anesthetic drug.

Complication

Discomfort during the injection of anesthetic. The patient may experience a brief period of intense discomfort as the injection of the anesthetic drug is started. Within a second (literally), the tissue is anesthetized and the discomfort ceases. The prior administration of inhalation sedation (nitrous oxide and oxygen) can help minimize or alter the feeling experienced.

Duration of Expected Anesthesia

The duration of anesthesia is variable after intrapulpal injection, usually between 15 and 20 minutes.⁵³ In most instances the duration is adequate to permit atraumatic extirpation of the pulpal tissues.

Summary

A number of successful and (usually) atraumatic supplemental injection techniques are available to be used in lieu of, or as a supplement to, unsuccessful traditional injection techniques. The availability of these techniques minimizes the chances of a patient being unable to be treated due to a lack of profound anesthesia.

References

1. Masselink BH. The advent of painless dentistry. *Dent Cosmos*. 1910;52:868–872.
2. Magnes GD. Intraosseous anesthesia. *Anesth Prog*. 1968;15:264–267.
3. Klebber CH. Intraosseous anesthesia: implications, instrumentation and techniques. *J Am Dent Assoc*. 2003;134:487–491.
4. Brown R. Intraosseous anesthesia: a review. *J Calif Dent Assoc*. 1999;27:785–792.
5. Weathers A Jr. Taking the mystery out of endodontics, part 6. Painless anesthesia for the “hot” tooth. *Dent Today*. 1999;18:90–93.
6. Certosimo AJ, Archer RD. A clinical evaluation of the electric pulp tester as an indicator of local anesthesia. *Oper Dent*. 1996;21:25–30.
7. Robertson D, Nusstein J, Reader A, et al. The anesthetic efficacy of articaine in buccal infiltration of mandibular posterior teeth. *J Am Dent Assoc*. 2007;138:1104–1112.
8. Kanaa MD, Whitworth JM, Corbett IP, et al. Articaine and lidocaine mandibular buccal infiltration anesthesia: a prospective randomized double-blind cross-over study. *J Endod*. 2006;32:296–298.
9. Prinz H. Peridental anesthesia, in Dental Summary. In: Bethel LP, ed. Vol. 32. Toledo: Ranson & Randolph; 1912:167.
10. Fischer G. *Local Anesthesia in Dentistry*. 3rd ed. Philadelphia: Lea & Febiger; 1923:197.
11. Lee S, Smith & Son. *Illustrated Catalogue of Dental Furniture, Instruments, and Materials*. 4th ed. Pittsburgh: Lee S Smith & Son; 1905.
12. Malamed SF. The periodontal ligament (PDL) injection: an alternative to inferior alveolar nerve block. *Oral Surg*. 1982;53:117–121.
13. Gibson RS, Allen K, Hutfless S, et al. The Wand vs. traditional injection: a comparison of pain related behaviors. *Ped Dent*. 2000;22:458–462.
14. Allen KD, Kotil D, Larzelere RE, Hutfless S, Beiraghi S. Comparison of a computerized anesthesia device with a traditional syringe in preschool children. *Pediatr Dent*. 2002;24:315–320.
15. Öztas N, Ulusu T, Bodur H, et al. The Wand in pulp therapy: an alternative to inferior alveolar nerve block. *Quintessence Int*. 2005;36:559–564.
16. Ashkenazi M, Bloomer S, Eli I. Effective computerized delivery of intrasulcular anesthetic in primary molars. *J Am Dent Assoc*. 2005;136:1418–1425.
17. Yogesh-Kumar TD, John JB, Asokan S, Geetha Priya PR, Punithavathy R, Praburajan V. Behavioral response and pain perception to computer controlled local anesthetic delivery system and cartridge syringe. *J Indian Soc Pedod Prev Dent*. 2015;33:223–228.
18. Yogesh-Kumar TD, Asokan S, John BJ, Pollachi-Ramakrishnan GP, Ramachandran P, Vilvanathan P. Cartridge syringe vs computer controlled local anesthetic delivery system: pain related behaviour over two sequential visits—a randomized controlled trial. *J Clin Exp Dent*. 2015;7:e513–e518.

19. Kwak EJ, Pang NS, Cho JH, Jung BY, Kim KD, Park W. Computer-controlled local anesthetic delivery for painless anesthesia: a literature review. *J Dent Anesth Pain Med*. 2016;16:81–88.
20. Mittal M, Kumar A, Srivastava D, Sharma P, Sharma S. Pain perception: computerized versus traditional local anesthesia in pediatric patients. *J Clin Pediatr Dent*. 2015;39:470–474.
21. Garret-Bernardin A, Cantile T, D'Antò V, et al. Pain experience and behavior management in pediatric dentistry: a comparison between traditional local anesthesia and the Wand computerized delivery system. *Pain Res Manag*. 2017;2017:7941238.
22. Baghlaif K, Alamoudi N, Elashiry E, Farsi N, El Derwi DA, Abdullah AM. The pain-related behavior and pain perception associated with computerized anesthesia in pulpotomies of mandibular primary molars: a randomized controlled trial. *Quintessence Int*. 2015;46(9):799–806.
23. Perugia C, Bartolino M, Docimo R. Comparison of single tooth anaesthesia by computer-controlled local anaesthetic delivery system (C-CLADS) with a supraperiosteal traditional syringe injection in paediatric dentistry. *Eur J Pediatr Dent*. 2017;18:221–225.
24. Brannstrom M, Lindskog S, Nordenvall KJ. Enamel hypoplasia in permanent teeth induced by periodontal ligament anesthesia of primary teeth. *J Am Dent Assoc*. 1984;109:735–736.
25. Tagger E, Tagger M, Sarnat H, Mass E. Periodontal ligament injection in the dog primary dentition: spread of local anaesthetic solution. *Int J Paediatr Dent*. 1994;4:159–166.
26. Meechan JG. Supplementary routes to local anaesthesia. *Int Endod J*. 2002;35:885–896.
27. Council on Dental Materials, Instruments, and Equipment. Status report: the periodontal ligament injection. *J Am Dent Assoc*. 1983;106:222–224.
28. Walton RE, Garnick JJ. The periodontal ligament injection: histologic effects on the periodontium in monkeys. *J Endodont*. 1982;8:22–26.
29. Nelson PW. Injection system. *J Am Dent Assoc*. 1981;103:692.
30. Shepherd PA, Eleazer PD, Clark SJ, et al. Measurement of intraosseous pressures generated by the Wand, high-pressure periodontal ligament syringe, and the Stabident system. *J Endodont*. 2001;27:381–384.
31. Wong JK. Adjuncts to local anesthesia: separating fact from fiction. *Can Dent Assoc*. 2001;67:391–397.
32. Quinn CL. Injection techniques to anesthetize the difficult tooth. *J Calif Dent Assoc*. 1998;26:665–667.
33. Hochman M, Chiarello D, Hochman C, et al. Computerized local anesthesia vs. traditional syringe technique: subjective pain response. *NY State Dent J*. 1997;63:24–29.
34. Cassamani C. *Une Nouvelle Technique D'anesthesia Intraligamentaire* [PhD thesis]. Paris; 1924.
35. Fischer G. *Local Anesthesia in Dentistry*. 4th ed. Philadelphia: Lea & Febiger; 1933.
36. Hoffmann-Axtheim W. *History of Dentistry*. Chicago: Quintessence; 1981.
37. Dreyer WP, van Heerden JD, de V Joubert JJ. The route of periodontal ligament injection of local anesthetic solution. *J Endodont*. 1983;9:471–474.
38. Walton RE, Abbott BJ. Periodontal ligament injection: a clinical evaluation. *J Am Dent Assoc*. 1981;103:571–575.
39. Meechan JG. Intraligamentary anaesthesia. *J Dent*. 1992;20:325–332.
40. Smith GN, Walton RE, Abbott BJ. Clinical evaluation of periodontal ligament anesthesia using a pressure syringe. *J Am Dent Assoc*. 1983;107:953–956.
41. Hochman MN. Single-tooth anesthesia: pressure sensing technology provides innovative advancement in the field of dental local anesthesia. *Compend Contin Educ Dent*. 2007;28:186–193.
42. Hochman MN, Friedman MF, Williams WP, et al. Interstitial pressure associated with dental injections: a clinical study. *Quintessence Int*. 2006;37:469–476.
43. Ashkenazi M, Blumer S, Eli I. Effect of computerized delivery intraligamentary injection in primary molars on their corresponding permanent tooth buds. *Int J Paediatr Dent*. 2010;20:270–275.
44. Ferrari M, Cagidiaco MC, Vichi A, et al. Efficacy of the computer-controlled injection system STA, the Ligamaject, and the dental syringe for intraligamentary anesthesia in restorative patients. *Int Dent SA*. 2010;11:4–12.
45. Froum SJ, Tarnow D, Caiazzo A, et al. Histologic response to intraligament injections using a computerized local anesthetic delivery system: a pilot study in mini-swine. *J Periodontol*. 2000;71:1453–1459.
46. Berlin J, Nusstein J, Reader A, et al. Efficacy of articaine and lidocaine in a primary intraligamentary injection administered with a computer controlled local anesthetic delivery system. *Oral Surg Oral Med Oral Pathol Oral Radiol Endod*. 2005;99:361–366.
47. Hochman MN. Computer controlled drug delivery system with dynamic pressure sensing. *US Patent*. 2006;618(7):409.
48. Ghelber O, Gebhard R, Szmuk P, et al. Identification of the epidural space: a pilot study of a new technique. *Anesth Analg*. 2005;22:S255.
49. Ghelber O, Gebhard RE, Vora S, et al. Identification of the epidural space using pressure measurement with the CompuFlo injection pump: a pilot study. *Reg Anesth Pain Med*. 2008;33:346–352.
50. Pertot WJ, Dejou J. Bone and root resorption: effects of the force developed during periodontal ligament injections in dogs. *Oral Surg Oral Med Oral Pathol*. 1992;74:357–365.
51. Saadoun A, Malamed SF. Intraseptal anesthesia in periodontal surgery. *J Am Dent Assoc*. 1985;111:249–256.
52. Talesh KT, Kahn mouii SS. Application of crestal anesthesia for treatment of class I caries in posterior mandibular teeth. *J Dent Res Dent Clin Dent Prospect*. 2011;5:17–22.
53. Reader A. Intraosseous anesthesia. Bonus material F. In: *Taking the Pain Out of Restorative Dentistry and Endodontics: Current Thoughts and Treatment Options to Help Patients Achieve Profound Anesthesia. Endodontics: Colleagues for Excellence Winter 2009*. Chicago: American Association of Endodontists; 2009.
54. Leonard M. The efficacy of an intraosseous injection system of delivering local anesthetic. *J Am Dent Assoc*. 1995;126:81–86.
55. Stabile P, Reader A, Gallatin E, Beck M, Weaver J. Anesthetic efficacy and heart rate effects of the intraosseous injection of 1.5% etidocaine (1:200,000 epinephrine) after an inferior alveolar nerve block. *Oral Surg Oral Med Oral Pathol Oral Radiol Endod*. 2000;89:407–411.
56. Bigby J, Reader A, Nusstein J, Beck M, Weaver J. Articaine for supplemental intraosseous anesthesia in patients with irreversible pulpitis. *J Endodont*. 2006;32:1044–1047.
57. Guglielmo A, Reader A, Nist R, Beck M, Weaver J. Anesthetic efficacy and heart rate effects of the supplemental intraosseous injection of 2% mepivacaine with 1:20,000 levonordefrin. *Oral Surg Oral Med Oral Pathol Oral Radiol Endod*. 1999;87:284–293.
58. Gallatin E, Stabile P, Reader A, Nist R, Beck M. Anesthetic efficacy and heart rate effects of the intraosseous injection of 3% mepivacaine after an inferior alveolar nerve block. *Oral Surg Oral Med Oral Pathol Oral Radiol Endod*. 2000;89:83–87.

59. Replogle K, Reader A, Nist R, et al. Cardiovascular effects of intraosseous injections of 2% lidocaine with 1:100,000 epinephrine and 3% benzocaine. *J Am Dent Assoc*. 1999;130:649–657.
60. Coggins R, Reader A, Nist R, Beck M, Meyers WJ. Anesthetic efficacy of the intraosseous injection in maxillary and mandibular teeth. *Oral Surg Oral Med Oral Pathol Oral Radiol Endod*. 1996;81:634–641.
61. Gallatin E, Nusstein J, Reader A, Beck M, Weaver J. A comparison of injection pain and postoperative pain of two intraosseous anesthetic techniques. *Anesth Prog*. 2003;50:111–120.
62. Nusstein J, Kennedy S, Reader A, Beck M, Weaver J. Anesthetic efficacy of the supplemental X-Tip intraosseous injection in patients with irreversible pulpitis. *J Endod*. 2003;29:724–728.
63. Nusstein J, Reader A, Nist R, Beck M, Meyers WJ. Anesthetic efficacy of the supplemental intraosseous injection of 2% lidocaine with 1:100,000 epinephrine in irreversible pulpitis. *J Endod*. 1998;24:487–491.
64. Miles T. Dental pain: self-observations by a neurophysiologist. *J Endod*. 1993;19:613–615.

Anesthetic Considerations in Dental Specialties

The techniques of local anesthesia described previously in part 4 of the book are valuable to doctors in virtually all areas of dental practice. However, specific needs and problems are associated with pain control in particular areas of dentistry. This chapter discusses the dental specialties listed below and their peculiar needs in the area of pain control:

- endodontics
- pediatric dentistry
- periodontics
- oral and maxillofacial surgery
- fixed prosthodontics
- long-duration anesthesia (postsurgical pain control)
- dental hygiene

Endodontics

Effects of Inflammation on Local Anesthesia

Inflammation and infection lower tissue pH, altering the ability of a local anesthetic to provide clinically adequate pain control. Local anesthetics are weak bases (pK_a 7.5 to 9.5) that are not water soluble. Combined with hydrochloric acid (HCl), local anesthetics are injected in their acid-salt form (e.g., lidocaine hydrochloride), improving their water solubility and stability. The pH of a “plain” local anesthetic is approximately 6.5, and the pH of one containing a vasoconstrictor is approximately 3.5. In an acidic solution, hydrogen ions (H^+) are “floating around.” If we abbreviate the anesthetic drug as RN (the un-ionized form of the local anesthetic), then some of these RN molecules will attach to an H^+ , forming the cationic form of the local anesthetic (RNH^+). The more acidic the anesthetic solution, the greater the number of H^+ ions available, and the greater the percentage of RNH^+ found in the solution. Because only the RN ionic form is lipid soluble and able to cross the lipid-rich nerve membrane, the more acidic the anesthetic solution and the tissue into which it is injected, the lower the percentage of RN, leading to a slower onset and less profound level of the resultant anesthesia.

Once the anesthetic solution has been injected, its pH is slowly increased toward the body’s normal pH of approximately 7.4 by tissue fluid buffers. As the local anesthetic becomes less acidic, RNH^+ ions lose H^+ , becoming un-ionized RN molecules (according to the Henderson-Hasselbalch equation; see [Chapter 1](#)), which now are able to diffuse across the nerve membrane to the interior of the nerve, where they eventually block the influx of Na^+ ions in sodium channels.

Pulpal and periapical inflammation or infection can cause significant alterations in tissue pH in the affected region, including decreased pH and increased vascularity. Nekoofar et al.¹ established the mean pH of pus obtained from periapical abscesses of 40 patients as 6.68 ± 0.324 , with a range between 6.0 and 7.3. Increased acidity has several negative aspects.² It severely limits the formation of RN, increasing the formation of RNH^+ . RN molecules that do diffuse into the nerve find a normal tissue pH of 7.4 within the nerve and reequilibrate into RN and RNH^+ forms. This RNH^+ forms is then able to enter and block sodium channels, blocking nerve conduction. But with fewer total anesthetic molecules (RN and RNH^+) diffusing into the nerve, there is a greater likelihood that incomplete anesthesia will develop. The overall effect of ion entrapment is to delay the onset of anesthesia and possibly interfere with nerve blockade.³ Ion entrapment changes the products of inflammation, so they inhibit anesthesia by directly affecting the nerve. Brown² demonstrated that inflammatory exudates enhance nerve conduction by lowering the response threshold of the nerve, which may inhibit local anesthesia. This causes blood vessels in the region of inflammation to become unusually dilated, allowing more rapid removal of the anesthetic from the site of injection. This leads to an increased possibility that resultant local anesthetic blood levels will be elevated (from those seen in normal tissue).³

Although there are no magic bullets for attaining profound pain control in teeth requiring pulpal extirpation, several methods may increase the likelihood of success. First, administer the local anesthetic at a site distant from the area of inflammation. It is undesirable to inject anesthetic

solutions into infected tissue because this may cause the infection to spread to uninvolved regions.^{4,5} Administration of local anesthetic in the pulp space of the involved tooth is more likely to provide adequate pain control because of the existence of normal tissue conditions. Therefore regional nerve block anesthesia is a major factor in pain control for the pulpally involved tooth. Second, use a buffered local anesthetic solution. Administration of a solution of local anesthetic with a pH of approximately 7.4 increases the percentage of the RNH⁺ form approximately 6000-fold (lidocaine hydrochloride with epinephrine at pH 3.5 contains 0.004% RN and at pH 7.4 it contains 24.03% RN). In preliminary studies involving non-pulpally involved teeth, 71% of patients receiving a buffered local anesthetic achieved successful pulpal anesthesia within 2 minutes, versus 6 minutes 37 seconds for unbuffered local anesthetic.⁶ A number of clinical trials assessing the efficacy of buffered local anesthetics in mandibular teeth with symptomatic irreversible pulpitis (SIP) have been published.⁷⁻⁹ Unfortunately the results have not demonstrated significant increases in success. The subject of local anesthetic buffering is discussed in [Chapter 20](#).

Methods of Achieving Anesthesia

The following techniques are recommended for providing pain control in pulpally involved teeth: local infiltration, regional nerve block, intraosseous injection, intraseptal injection, periodontal ligament (PDL) injection, and intrapulpal injection. The use of buffered local anesthetics and the administration of articaine hydrochloride by infiltration in the mandible are also recommended. The order in which these techniques are discussed is the typical sequence in which, as per the author, they are normally used to achieve pain control when one seeks to extirpate pulpal tissues.

Maxillary Teeth

1. Local infiltration (supraperiosteal injection). Local infiltration is commonly used to provide pulpal anesthesia in maxillary teeth. It is usually effective in endodontic procedures when severe inflammation or infection is not present. Local infiltration should not be attempted in a region where infection is obviously (clinically or radiographically) present because of the possible spread of infection to other regions and a greatly decreased rate of success. When infection is present, other techniques of pain control should be relied on. Infiltration anesthesia is often effective at subsequent endodontic visits if adequate débridement and shaping of the canals have been previously accomplished.

The use of local anesthesia during subsequent visits, for débridement and shaping and filling of the canals is strongly recommended. Miles¹⁰ (a neurophysiologist) poignantly described the history of his endodontic experience in 1993. He describes his feelings during treatment subsequent to pulpal extirpation in [Box 16.1](#).

• BOX 16.1 Dental Pain: Self-Observations by a Neurophysiologist

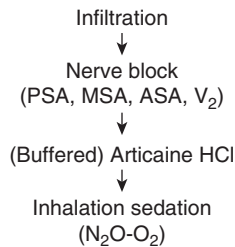
"It is worth noting this patient's response to having his root canals instrumented with and without anesthesia. With full anesthesia, the author was quite relaxed and was aware only of a general vibratory sensation as the canals were reamed: doubtless this sensation was caused by bony transmission of the vibration to receptors located outside the range of the anesthetic block. However, at the second appointment, when reaming was resumed without anesthesia, this patient experienced several sharp jabs of pain when remnants of vital tissue were curetted away. This led to a feeling of acute apprehension for this stage of the procedure. Perhaps this apprehension was amplified by the patient's knowledge that the tip of the reamer was approaching the apex, and that if (it) were inadvertently advanced by half a millimeter or so, the resulting sensation would be very painful sensation. It is possible, therefore, that this concern may then be less vivid to a lay patient. However, if this second stage of the endodontic procedure is regularly associated with pain, even if this consists only of a couple of brief jabs, it may be possible to ensure a pain-free experience without widespread anesthesia by slowly spinning local anesthetic down the root canal to a point just short of where the reamer evoked the pain. This possibility should be investigated.

The point of this discussion is that a clinician is most likely to retain the patient's confidence and cooperation by meticulous anesthesia at all stages of the procedure, particularly as a relaxed patient will also feel less pain."

2. Regional nerve block. Regional nerve block anesthesia is recommended in cases where infiltration anesthesia may be ineffective or contraindicated. The techniques are discussed in detail in [Chapter 13](#). Regional nerve block, the anterior superior alveolar (ASA), middle superior alveolar, posterior superior alveolar (PSA), anterior middle superior alveolar, and V₂ block, is likely to be effective because the anesthetic solution is deposited at a distance from the inflammation, where tissue pH and other factors are more normal.
3. Articaine hydrochloride. Meta-analyses comparing lidocaine hydrochloride with articaine hydrochloride have shown articaine's effectiveness by maxillary infiltration to be 3.81 times that of lidocaine.¹¹
4. Buffered local anesthetic solution. Although clinical trials with the administration of buffered local anesthetic solutions in mandibular teeth with SIP have failed to demonstrate any significant advantage,⁷⁻⁹ the use of buffered local anesthetics—in almost all clinical situations, not only endodontics—is highly recommended by this author (see [Chapter 20](#)).¹²
5. Inhalation sedation. The use of inhalation sedation with nitrous oxide and oxygen (N₂O-O₂) is suggested for two reasons: (1) it allays a patient's apprehension during what, in their mind at least, is a painful procedure and (2) N₂O-O₂ raises the pain reaction threshold of the patient, modulating their response to painful stimuli.

[Box 16.2](#) illustrates the recommended sequence for achieving pain control in pulpally involved maxillary teeth.

• **BOX 16.2** Recommended Sequence for Achieving Pain Control in Maxillary Pulpally Involved Teeth



Achieving clinically adequate pain control for endodontic procedures in the maxillary arch is not as significant a challenge as it is in the mandible, particularly when molar teeth are involved.

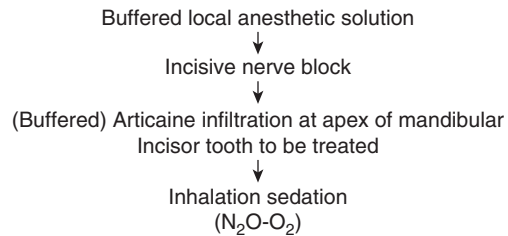
Mandibular Teeth

1. Use of buffered local anesthetic solutions for all injections (see [Chapter 20](#)).
2. Nerve block anesthesia—the inferior alveolar nerve block (IANB), Gow-Gates mandibular nerve block, Vazirani-Akinosi closed-mouth mandibular nerve block, and incisive nerve block—is commonly used initially when one is seeking pulpal anesthesia for mandibular teeth. In most instances, it is successful in providing clinically adequate anesthesia permitting painless extirpation of the pulp tissues; however, in the presence of acute inflammation (e.g., SIP), success rates are significantly lower.^{13,14}
3. Buccal infiltration of (buffered) articaine (0.6 to 0.9 mL) at the apex of tooth to be treated (see [Chapter 20](#)). Clinical trials in both mandibular posterior¹⁵ and anterior teeth¹⁶ have demonstrated the efficacy of articaine by mandibular infiltration.

Mandibular Teeth at or Anterior to the Mental Foramen

1. Incisive nerve block (see [Chapter 14](#)). Deposition of 0.6 mL of (buffered) local anesthetic solution outside the mental foramen and then application of firm digital pressure for minimally 1 minute, preferably 2 minutes, provides pulpal anesthesia to the mandibular premolars, canine, and incisor teeth with a high degree of success.
 - a. When mandibular incisors are to be treated, the buccal infiltration of 0.6 to 0.9 mL of (buffered) articaine is recommended. Meechan¹⁶ has demonstrated its effectiveness (unbuffered articaine) in non-pulpally involved teeth. This should be done following IANB, Gow-Gates mandibular nerve block, Vazirani-Akinosi closed-mouth mandibular nerve block, or incisive nerve block as well.
2. [Box 16.3](#) illustrates the recommended sequence for achieving pain control in pulpally involved mandibular teeth at or anterior to the mental foramen.

• **BOX 16.3** Recommended Sequence for Achieving Pain Control in Pulpally Involved Mandibular Teeth at or Anterior to the Mental Foramen



• **BOX 16.4**

Soft tissue anesthesia is

NEVER

a guarantee of pulpal anesthesia

Mandibular Molars

In the presence of SIP, mandibular molars are the most difficult teeth to anesthetize effectively.¹⁷ In a survey of 121 dentists, Stagiailo¹⁷ reported that 55% encountered difficulty in achieving successful pulpal anesthesia “often” or “sometimes” in non-pulpally involved mandibular molars. When treating “exacerbated chronic pulpitis” or SIP, 69% and 74%, respectively, failed to achieve successful pulpal anesthesia “almost always” “often,” or “sometimes.” Click et al.¹⁸ reported that following a “successful” Gow-Gates mandibular nerve block—using the presence of lip anesthesia as a criterion for success—93% of patients had lip anesthesia, yet only 35% had successful pulpal anesthesia ([Box 16.4](#)).

When infected mandibular molar teeth are being treated, it is recommended that steps 1, 2, and 3 in the section “Mandibular teeth”) be used initially.

The question of what volume of local anesthetic should be administered by nerve block has been assessed in several clinical trials with conflicting results.¹⁹⁻²¹ Comparing 1.8 mL and 3.6 mL of 2% lidocaine with epinephrine 1:100,000, Fowler and Reader¹⁹ in 2013 concluded that “for patients presenting with irreversible pulpitis, success was not significantly different between a 3.6-mL volume and a 1.8-mL volume of 2% lidocaine with 1:100,000 epinephrine. The success rates (28% to 39%) with either volume were not high enough to ensure complete pulpal anesthesia.” In 2015 the same group reported that “the incidence of missed IANBs in asymptomatic patients was 6.3% for 1 cartridge (1.8 mL); and 3.8% for 2 cartridges (3.6 mL) lidocaine 1:100,000. The incidence of missed IANBs

in SIP patients was 7.7% for 1 cartridge (1.8 mL); and 2.3% for 2 cartridges (3.6 mL) lidocaine 1:100,000.²⁰ Abazarpoor et al.²¹ using either 1.8 mL of 4% articaine with epinephrine 1:100,000 by IANB in SIP concluded that “3.6 mL articaine provided significantly higher success rate (77%) of IANBs compared with 1.8 mL of the same anesthetic solution (25.5%), although neither group had 100% successful anesthesia. Increasing the volume of articaine provided significantly higher success rates of IANBs in mandibular 1st molar teeth with SIP but did not result in 100% anesthetic success.”

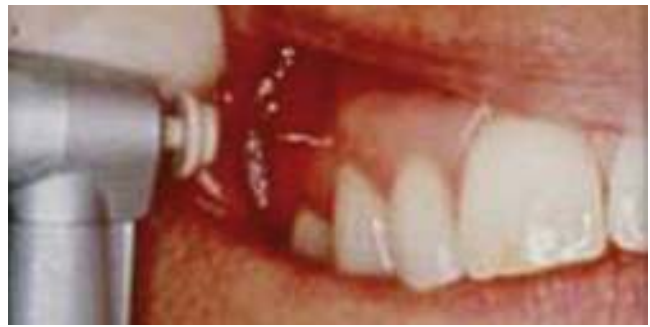It is this authors recommendation that when one is seeking to extirpate the pulpal tissues of mandibular molars with SIP that a nerve block (step 2 above) be administered with 3.6 mL of, preferably, (buffered) 4% articaine with epinephrine 1:100,000.

As important as the administration of inhalation sedation is for endodontic procedures in the maxilla (see step 5 in the section “Maxillary teeth”), its use during attempts at extirpating the pulpal tissues in mandibular molars with SIP is of greater importance. In comparing inhalation sedation with placebo (room air plus oxygen), Stanley et al.²³ reported “the results showed that N₂O-O₂ sedation (30% to 50%) did increase the success of an IAN [inferior alveolar nerve] block (50% vs. 28% placebo) and therefore might be a useful technique to add to the armamentarium used in the treatment of teeth with symptomatic irreversible pulpitis (i.e., in addition to using supplemental anesthesia). Furthermore, if a patient were to present with irreversible pulpitis of a mandibular tooth and severe anxiety and requesting sedation, this study points to the possibility that N₂O-O₂ sedation might be preferable to oral sedation with triazolam. With N₂O-O₂ sedation the dose is titratable, the patient would not require a driver to accompany them, and they would not be sedated beyond the length of the treatment appointment.

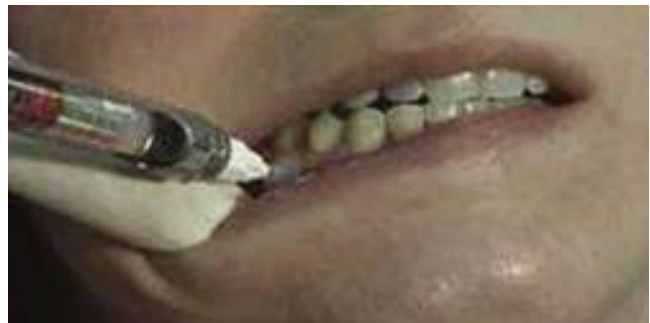Studies with oral sedation concluded that “for mandibular posterior teeth, triazolam in a sublingual dose of 0.25 mg will not result in an increase in success of the IAN [inferior alveolar nerve] block in patients with irreversible pulpitis. When using conscious sedation, profound local anesthesia will still be required as the principal means of eliminating the sensation of pain during endodontic treatment in patients with irreversible pulpitis.”²³

In the absence of anesthesia profound enough to permit painless access to the pulp chamber of mandibular teeth, the following techniques are recommended (intraosseous, intraseptal, and PDL injections can be used interchangeably):

1. Intraosseous injection. Intraosseous injection has experienced a resurgence of enthusiasm in recent years.²⁴⁻³² Intraosseous injections can provide anesthesia profound enough to allow painless access to the pulp chamber for removal of pulpal tissue in most situations. The intraosseous technique is described in [Chapter 15](#) and is reviewed here ([Figs. 16.1 and 16.2](#)):
 - a. Apply topical anesthetic at the site of the injection to anesthetize the soft tissue.



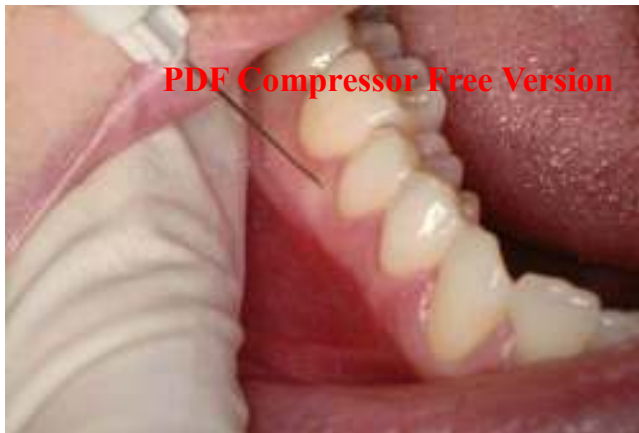• **Fig. 16.1** Stabident intraosseous injection technique.



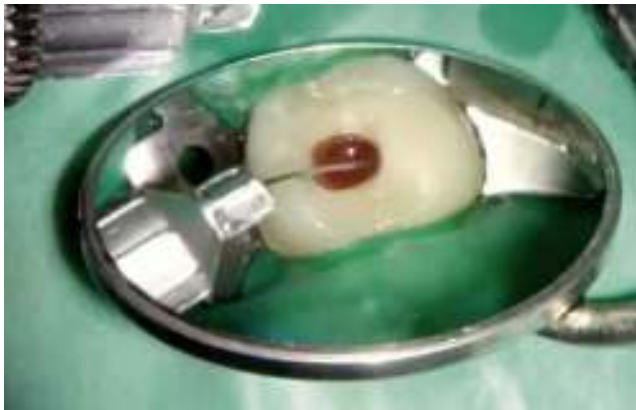• **Fig. 16.2** X-Tip intraosseous injection technique.

- b. While holding the perforator perpendicular to the cortical plate, gently push it through the attached gingiva until its tip rests against bone.
 - c. Activate the handpiece and apply pressure on the perforator in a “pecking” motion until a sudden loss of resistance is felt.
 - d. Withdraw the perforator and dispose of it safely.
 - e. Insert the local anesthetic needle into the hole and deposit the volume of local anesthetic appropriate for the procedure (see [Table 15.3](#)).
2. Intraseptal injection. This is a variation of intraosseous and PDL injections and may be used as an alternative to these techniques. It is more successful in younger patients because of decreased bone density. Intraseptal anesthesia is described in [Chapter 15](#) and proceeds as follows³³:
 - a. Anesthetize the soft tissues at the injection site via local infiltration.
 - b. Insert a 27-gauge short needle into the intraseptal bone distal to the tooth to be anesthetized ([Fig. 16.3](#)).
 - c. Advance the needle firmly into the cortical plate of bone.
 - e. Inject about 0.2 mL of anesthetic.

Considerable resistance must be encountered as the anesthetic is being deposited. If administration of the anesthetic is easy, the needle tip is most likely in soft tissue, not in bone.
3. PDL Injection. The PDL injection may be an effective method of providing anesthesia in pulpally involved teeth if infection and severe inflammation are not present. This technique is discussed in [Chapter 15](#). A 27-gauge short needle is firmly placed between the interproximal bone and the tooth to be anesthetized. The bevel of the needle should face the tooth (although bevel orientation is not critical for success). It is appropriate to bend the needle



• **Fig. 16.3** For the intraosseous injection, a 27-gauge short needle is inserted into the intraosseous bone distal to the tooth to be anesthetized.



• **Fig. 16.4** Intrapulpal injection.

if necessary to gain access. A small volume (0.2 mL) of local anesthetic is deposited under pressure for each root of the tooth. It may be necessary to repeat the PDL injection on all four sides of the tooth. Computer-controlled local anesthetic delivery devices enable the PDL injection to be administered more successfully and more comfortably than an injection given with a traditional dental local anesthetic syringe.

4. Intrapulpal injection. In about 5% to 10% of mandibular posterior teeth with SIP, supplemental injections, even when repeated, do not produce profound anesthesia; pain persists when the pulp is entered. This is an indication for an intrapulpal injection.³⁴ The intrapulpal injection provides pain control both by the pharmacologic action of the local anesthetic and by applied pressure. This technique may be used once the pulp chamber is exposed surgically or pathologically. The technique is described in Chapter 15 (Fig. 16.4).

When intrapulpal injections are administered properly, a brief period of sensitivity, ranging from mild to severe, may accompany the injection.¹⁰ Clinical pain relief follows almost immediately, permitting instrumentation to proceed atraumatically.

With the growing popularity of intraosseous anesthesia, the need for intrapulpal injection to provide profound pain control in cases of irreversible pulpitis has decreased.

Today there are but few occasions when all of the techniques discussed fail to provide clinically acceptable pain control, and intrapulpal anesthesia cannot be attempted until the pulp is exposed. The following sequence of treatment may be of value on these rare occasions:

1. Use slow-speed high-torque instrumentation (which usually is less traumatic than the high-speed low-torque option).
2. Use (minimal or moderate) sedation (which helps decrease the patient's response to painful stimuli). N₂O-O₂ inhalation sedation is a readily available, safe, and highly effective method of relaxing a patient and elevating his or her pain reaction threshold.
3. If, after the preceding steps, the pulp chamber is opened, administer direct intrapulpal anesthesia. This is usually effective despite the brief period of pain associated with intrapulpal administration.
4. If a high level of pain persists and it still is not possible to enter the pulp chamber, then the following sequence should be considered:
 - a. Place a cotton pellet saturated with local anesthetic loosely on the pulpal floor of the tooth.
 - b. Wait 30 seconds; then press the pellet more firmly into the dentinal tubules or the area of pulpal exposure. This area may be sensitive initially but should become insensitive within 2 to 3 minutes.
 - c. Remove the pellet and continue use of the slow-speed drill until pulpal access is gained; then perform direct injection into the pulp.

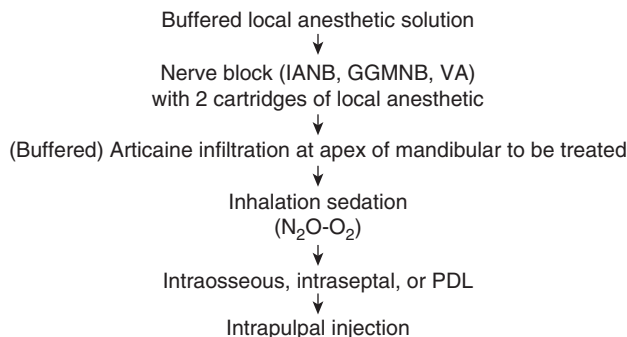
With most endodontic procedures, difficulty in providing adequate anesthesia occurs only at the initial appointment. Once the pulp tissue has been extirpated, the need for pulpal anesthesia disappears. Soft tissue anesthesia may be necessary at ensuing appointments for comfortable placement of the rubber dam clamp, but if adequate tooth structure remains, this may not be necessary. Some patients do respond unfavorably to instrumentation of their root canals, even following thorough débridement of the canals.¹⁰ If this occurs, infiltration with (buffered) articaine hydrochloride and/or local anesthetic administration into the root canal itself may be used. Apply a small amount of topical anesthetic ointment onto the file or reamer before inserting it into the canal. This helps desensitize the periapical tissues during instrumentation of the canals. As patients may react to filling of the canals, local anesthesia should be considered before this stage of treatment is started.

Box 16.5 illustrates the recommended sequence for achieving pain control in pulpally involved mandibular molar teeth.

Pediatric Dentistry

Pain control is one of the most important aspects of behavioral management in children undergoing dental treatment, yet the main reason children give for fear of going

• **BOX 16.5** Recommended Sequence for Achieving Pain Control in Pulpally Involved Mandibular Molar Teeth



to the dentist is the fear of the injection.³⁵ Anxiety is the biggest predictor of poor pain control.³⁶ Unpleasant childhood experiences have made many adults acutely phobic with regard to dental treatment. Today, however, many local anesthetic drugs are available to make pain management relatively easy. Special concerns in pediatric dentistry relevant to local anesthetics include anesthetic overdose (toxic reaction), self-inflicted soft tissue injury related to the prolonged duration of soft tissue anesthesia, and technique variations related to the smaller skulls and differing anatomy of younger patients.

Local Anesthetic Overdose

Overdose from a drug occurs when the blood level in its target organ(s) becomes excessive (see [Chapter 18](#)). Undesirable effects resulting from overly high local anesthetic blood levels may be caused by intravascular injection or the administration of large volumes of the drug. Local anesthetic overdose (also known as *toxicity*) occurs when the blood level of the drug in the brain or myocardium—the target organs for local anesthetics—becomes too high. Therefore local anesthetic overdose relates to the volume of drug reaching the cerebrovascular and cardiovascular systems and to the blood volume of the patient. Once the blood level of a drug reaches overdose levels, the drug exerts unwanted and possibly deleterious systemic actions that are consistent with its pharmacologic properties. Local anesthetic overdose produces a progressive depression of the central nervous system and cardiovascular system, with reactions ranging from mild tremor to tonic-clonic convulsions (central nervous system), or from a slight decrease in blood pressure and cardiac output to cardiac arrest (cardiovascular system).

Disproportionately high numbers of deaths and serious morbidities caused by local anesthetic overdose have occurred in children, leading to the assumption that local anesthetics are more toxic in children than in adults.^{37,38} This is untrue; it is the safety margin of local anesthetics in

small children (e.g., lighter weight) that is lower than it is in adult. Given an equal dose of a local anesthetic, a healthy adult patient with a larger body weight and greater blood volume will have a lower blood level of anesthetic than of a child patient of lesser weight and smaller blood volume. Blood volume, to a large degree, relates to body weight: the greater the body weight, the greater the blood volume (except in cases of marked obesity).

Maximum recommended doses (MRDs) of all drugs administered by injection should be calculated—before being administered—by body weight and should not be exceeded, unless it is absolutely essential to do so.³⁸ For example, two cartridges of 3% mepivacaine (54 mg per cartridge) exceed the MRD for a 15-kg (33-lb) child of 66 mg. Unfortunately, lack of awareness of maximum doses has led to fatalities in children.³⁹⁻⁴³ The ease with which a lighter-weight child may be overdosed with local anesthetics is compounded by the practice of multiple-quadrant dentistry and the concomitant use of sedative drugs (especially opioids).³⁷ Chicka et al.,⁴⁴ in reviewing malpractice insurance claims involving anesthesia for pediatric patients, found that 41% of the claims involved local anesthetic overdose. Of those claims, 43% occurred when local anesthetic was the only drug administered. When treating a smaller child, the dentist must maintain strict adherence to MRDs ([Table 16.1](#)) and should anesthetize only the one quadrant that is being treated at that time.

In discussing MRDs, de Jong⁴⁵ states “a word about ‘safe’ or ‘recommended’ local anesthetic doses, as found on drug package inserts or in reference books: These doses are best estimates, indirectly derived from experimental studies and clinical case reports. Generally, the upper limits tend to be on the safely conservative side of the fence. Considerably higher doses than ‘recommended’ can be (and have been) given if used judiciously. Conversely, the so-called safe dose may be a gross overdose if placed where not intended. In my (unpublished) experience, for instance, 10 mg lidocaine or 2.5 mg bupivacaine produced instant grand mal seizures when injected unintentionally into the vertebral artery. ‘Safe’ doses can thus be either too little or too much, depending on circumstances. VIGILANCE is the watchword!”

Cheatham et al.⁴⁶ surveyed 117 dentists who regularly treated children about their local anesthetic use. They found that the lighter the weight of the patient, the more likely the doctor was to administer an overly large dose of the local anesthetic, based on milligrams per kilogram of body weight. For example, a 13-kg (~28.5-lb) patient should receive no more than 91 mg of lidocaine (based on an MRD of 7.0 mg/kg). The range of doses administered by dentists treating children was 0.9 to 19.3 mg/kg. As the patient’s weight increased, the number of milligrams per pound or kilogram reached lower and safer levels, the maximum of the range falling to 12.6 mg/kg in the 20-kg (44-lb) patient and to 7.2 mg/kg in the 35-kg (77-lb) patient. The mean dose of local anesthetic also fell when the patient’s weight increased, from 5.4 mg/kg in the

TABLE 16.1 Maximum Recommended Doses of Local Anesthetics as per the US Food and Drug Administration**PDF Compressor Free Version**

Drug	Formulation	Food and Drug Administration Maximum Recommended Dose (mg)	Dose	
			mg/kg	mg/lb
Articaine	4% with epinephrine	None recommended	7.0	3.2
Lidocaine	2% with epinephrine	500	7.0	3.2
Mepivacaine	3% plain (no vasoconstrictor)	400	6.6	3.0
Mepivacaine	2% with levonordefrin	400	6.6	3.0
Prilocaine	4% plain (no vasoconstrictor)	600	8.0	3.6
Prilocaine	4% with epinephrine	600	8.0	3.6
Bupivacaine	0.5% with epinephrine	90	None recommended	None recommended

TABLE 16.2 Local Anesthetic Administration by Dentists Who Treat Children (N = 117)

Patient		Mean Dose		Range		Maximum Recommended Dose (mg/kg)
Age (Years)	Weight (kg)	mg	mg/kg	mg	mg/kg	
2	13	69.9	5.4	12–252	0.9–19.3	Lidocaine 7.0 Mepivacaine 6.6
5	20	96.5	4.8	18–252	0.9–12.6	
10	35	135	3.8	36–252	1.0–7.2	

Modified from Cheatham BD, Primosch RE, Courts FJ. A survey of local anesthetic usage in pediatric patients by Florida dentists. *J Dent Child.* 1992;59:401–407.

13-kg patient to 4.8 mg/kg in the 20-kg patient to 3.8 mg/kg in the 35-kg patient (Table 16.2).

Administration of large volumes of local anesthetic is not necessary when one seeks pain control in younger patients. Because of anatomic differences (see the following discussion in “Techniques of Local Anesthesia in Pediatric Dentistry”), smaller volumes of local anesthetics will provide the depth and duration of pain control usually necessary to successfully complete planned dental treatment in lighter-weight patients.

Because all injectable local anesthetics are inherently vasodilators, leading to more rapid vascular uptake and a shorter duration of pulpal anesthesia, it is strongly recommended that a vasoconstrictor be included in the local anesthetic solution unless there is a compelling reason for it to be excluded.⁴⁷ Many treatment appointments in pediatric dentistry do not exceed 30 minutes in duration; therefore the use of a vasoconstrictor-containing local anesthetic is considered unnecessary and unwarranted. It is thought that increased duration of soft tissue anesthesia, especially after IANB, increases the risk of self-inflicted soft tissue injury. A non-vasoconstrictor-containing local anesthetic is frequently used (most often 3% mepivacaine). Providing 20 to 40 minutes of pulpal anesthesia, mepivacaine (3%) is considered the appropriate drug for this group of patients. This is true, provided that the dental treatment is confined to one quadrant per visit.

However, when multiple quadrants are to be treated (and receive local anesthesia) on a smaller, lighter-weight patient in a single visit, administration of a “plain” drug into multiple injection sites increases the potential risk of overdose. Use of a local anesthetic containing a vasoconstrictor is strongly recommended whenever multiple quadrants are anesthetized in the smaller pediatric patient. In a 1992 survey, 69% of doctors treating children administered lidocaine with epinephrine as their primary anesthetic (Table 16.3).⁴⁶ With the introduction of articaine hydrochloride in the United States (June 2000), a more recent survey (2012) of local anesthetic use among general and pediatric dentists showed that lidocaine 2% with epinephrine remains the preferred drug for approximately 77% but that articaine 4% with epinephrine is making inroads, with about 17% reporting it to be their preferred local anesthetic in children.⁴⁷ Interestingly, 16% of general dentists and 10% of pediatric dentists listed articaine as their preferred local anesthetic in patients aged 2 to 3 years, even though the administration of articaine is not recommended in patients younger than 4 years.⁴⁹ Wright et al.⁵⁰ in a retrospective study of local anesthesia records in two pediatric dental offices found a total of 211 patients under 4 years of age who received a total of 240 doses of articaine. No adverse systemic adverse reactions were noted in the records or known to the clinicians.

Factors increasing the risk of local anesthetic overdosage in younger patients are presented in [Box 16.6](#).⁵¹

PDF Compressor Free Version

Complications of Local Anesthesia

Self-inflicted soft tissue injury—accidental biting or chewing of the lip, tongue, or cheek—is a complication associated

TABLE 16.3 Local Anesthetic Choice by Dentists Who Treat Children (N = 117)

Anesthetic Formulation	Percentage Using the Formulation
2% lidocaine + epinephrine 1:100,000	69
3% mepivacaine	11
2% lidocaine	8
2% mepivacaine + levonordefrin 1:20,000	8
Other anesthetics	4

Modified from Cheatham BD, Primosch RE, Courts FJ. A survey of local anesthetic usage in pediatric patients by Florida dentists. *J Dent Child.* 1992;59:401–407.

• BOX 16.6 Factors Adding to Increased Risk of Local Anesthetic Overdose in Younger Patients

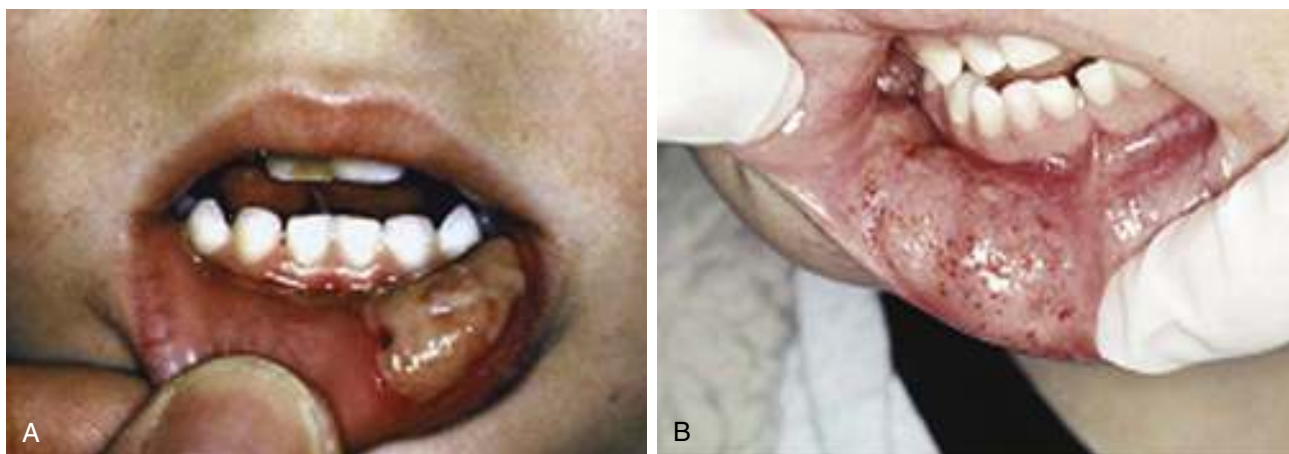
1. Treatment plan: all four quadrants treated using local anesthetic in one visit
2. Local anesthetic administered is a plain (no vasopressor) solution
3. Full cartridges (1.8 mL) administered with each injection
4. Local anesthetic administered to all four quadrants at one time
5. Exceeding the maximum dose based on patient's body weight

with residual soft tissue anesthesia ([Fig. 16.5](#)). Soft tissue anesthesia lasts considerably longer than pulpal anesthesia and may persist for 4 hours or more after local anesthetic administration. Fortunately, most patients do not encounter problems related to prolonged soft tissue anesthesia, but most of those who do are younger, the oldest old (>85 years), or mentally or physically disabled patients. Problems related to soft tissue anesthesia most often involve the lower lip. Much less frequently, the tongue is injured, and rarely, the upper lip is involved.

College et al.⁵² reported an 18% incidence of self-inflicted soft tissue injury in patients younger than 4 years receiving IANB. From 4 to 7 years, the rate was 16%, from 8 to 11 years, it was 13%, and from 12 years on, it was 7%.

Several preventive measures can be implemented:

1. Select a local anesthetic with a duration of action appropriate for the length of the planned procedure. Some local anesthetics provide pulpal anesthesia of adequate duration (20 to 40 minutes) for restorative procedures in children, with a relatively short duration of soft tissue anesthesia (1 to 3 hours, instead of 4 or 5 hours) ([Table 16.4](#)). It should be kept in mind, however, that investigators have not demonstrated a relationship between the use of plain local anesthetics and a reduction in soft tissue trauma. The clinician must consider the advisability of using a local anesthetic containing a vasoconstrictor when treating multiple quadrants in view of the decreased margin of safety of local anesthetics in smaller children.
2. Administer phentolamine mesylate (OraVerse) at the conclusion of the traumatic portion of the dental procedure. Discussed more completely in [Chapter 20](#), phentolamine mesylate is an α -adrenergic antagonist that, when injected into the site where local anesthetic with a vasoconstrictor was previously deposited, produces vasodilation, increasing blood flow through the area, thereby increasing the speed with which the local anesthetic drug diffuses away from the injection site and out of the nerve. The duration of residual soft tissue anesthesia is significantly reduced. Phentolamine mesylate has been



• **Fig. 16.5** Lip trauma caused by biting while the area was anesthetized.

approved by the Food and Drug Administration for use in patients aged 3 years or older.^{53,54}

3. Advise both the patient and the parent/guardian about the possibility of injury if the patient bites, sucks, or chews on the lips, tongue, or cheeks, or ingests hot substances while anesthesia persists. These instructions are given with the parent/guardian present.
4. Some doctors reinforce the verbal warning to the patient and the adult by placing a cotton roll in the mucobuccal fold (held in position by dental floss through the teeth) if soft tissue anesthesia is still present at the time of the patient's discharge.
5. A sticker, reminding the child not to bite or suck on his/her lip/cheek or tongue, can be placed on the child's shirt on the same side as the anesthetized lip or tongue.

Management of self-inflicted soft tissue trauma consists of reassuring the patient, allowing time for anesthetic effects to diminish, and coating the involved area with a lubricant (petroleum jelly) to help prevent drying, cracking, and pain.

Techniques of Local Anesthesia in Pediatric Dentistry

Local anesthetic techniques used in children do not differ greatly from those in adults. However, the skulls of children do have some anatomic differences from those of adults. For instance, maxillary and mandibular bone in children is generally less dense, which works to the dentist's advantage (Fig. 16.6). Decreased bone density allows more rapid and complete diffusion of the anesthetic solution. Also, children are smaller; thus standard injection techniques can usually be completed with decreased depth of needle penetration and a smaller volume of local anesthetic.

Maxillary Anesthesia

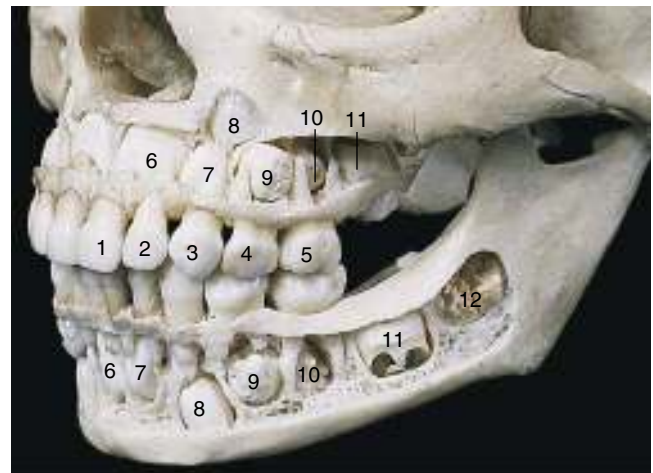
All primary teeth and permanent molars can be anesthetized by *supraperiosteal infiltration* in the mucobuccal fold. The PSA nerve block is rarely necessary because of the effectiveness of infiltration in children. However, in some individuals, the morphology of the bone surrounding the apex of the permanent first molar does not permit effective infiltration of local anesthetic because the zygomatic process lies closer to the alveolar bone in children. A PSA nerve block may be warranted in this clinical situation. A 27-gauge short dental

needle should be used and the depth of needle penetration should be modified to meet the smaller dimensions of the pediatric patient, to minimize the risk of overinsertion leading to hematoma. As an alternative to the PSA nerve block, Rood⁵⁵ has suggested using buccal infiltrations on both the mesial and distal aspects of the maxillary first molar to avoid a prominent zygomatic process. The ASA nerve block also can be used in children, as long as it is realized that the depth of penetration is probably just slightly greater than with a supraperiosteal injection (because of the lesser height of the maxillae in children).

As supraperiosteal infiltration has a very high success rate, there are few indications for the PSA or ASA nerve block in very young children.

Occasionally a maxillary tooth remains sensitive after a supraperiosteal injection because of accessory innervation from the palatal nerves⁵⁶ or widely flared palatal roots. Palatal anesthesia can be achieved in children through the nasopalatine and greater (anterior) palatine nerve blocks. The technique for a *nasopalatine nerve block* proceeds exactly as described in Chapter 13. That for a *greater palatine nerve block* is as follows: The administrator visualizes a line from the gingival border of the most posterior molar that has erupted to the midline. The needle is inserted from the opposite side of the mouth, distal to the last molar, bisecting this line. If the child has only primary dentition, the needle is inserted approximately 10 mm posterior to the distal surface of the second primary molar, bisecting the line drawn toward the midline.

An *intrapapillary injection* can also be used to achieve palatal anesthesia in young children. Once buccal anesthesia



• **Fig. 16.6** Upper and lower jaws in a 4-year-old child with erupted primary teeth and unerupted permanent teeth. 1, First (central) incisor of primary dentition; 2, second (lateral) incisor of primary dentition; 3, canine of primary dentition; 4, first molar of primary dentition; 5, second molar of primary dentition; 6, first (central) incisor of permanent dentition; 7, second (lateral) incisor of permanent dentition; 8, canine of permanent dentition; 9, first premolar of permanent dentition; 10, second premolar of permanent dentition; 11, first molar of permanent dentition; 12, second molar of permanent dentition. (From Abrahams PH, Marks SC Jr, Hutchings RT. *McMinn's color atlas of human anatomy*. 5th ed. St Louis: Mosby; 2003.)

TABLE 16.4 Relative Durations of Pulpal and Soft Tissue Anesthesia

Drug	Approximate Duration of Pulpal Anesthesia (min)	Approximate Duration of Soft Tissue Anesthesia (h)
Mepivacaine, plain	20–40	3–4
Prilocaine, plain	10 (infiltration)	1.5–2

is effective, the needle (27-gauge short needle) is inserted horizontally into the buccal papilla just above the interdental septum. The needle is then directed toward the palatal side. This should cause ischemia of the soft tissue.⁵⁷

Mandibular Anesthesia

Supraperiosteal infiltration is usually effective in providing pain control in mandibular primary teeth.⁵⁸⁻⁶⁰ Sharaf⁵⁸ reported that buccal infiltration anesthesia in the mandible in 80 children (aged 3 to 9 years) was as effective as IANB in all situations, except when pulpotomy was performed on the primary second molar. This was the result of decreased density of bone in the mandible in younger children. The success rate of mandibular infiltration anesthesia decreases somewhat for primary mandibular molars as the child becomes older. The technique of supraperiosteal infiltration in the mandible is the same as in the maxilla. The tip of the needle is directed toward the apex of the tooth, in the mucobuccal fold, and approximately one-fourth to one-third of a cartridge (0.45 to 0.6 mL) is slowly deposited.

The IANB has a greater success rate in children than in adults because of the location of the mandibular foramen. The mandibular foramen in children lies distal and more inferior to the occlusal plane. Benham⁶¹ demonstrated that the mandibular foramen lies at the height of the occlusal plane in children and extends an average of 7.4 mm above the occlusal plane in adults. He also found that there is no age-related difference as to the anteroposterior position of the foramen on the ramus.

The technique for an IANB is essentially identical for adults and children. The syringe barrel is placed in the corner of the mouth on the opposite side. The average depth of penetration to bone is approximately 15 mm, although this may vary significantly with the size of the mandible and the age of the patient. As with the adult, bone should be contacted before any solution is deposited. In general, the more inferior location of the mandibular foramen in children provides a greater opportunity for successful anesthesia. "Too low" injections are more likely to be successful. In clinical situations the success rate for well-behaved children usually exceeds 90% to 95%.

Because of the decreased thickness of soft tissue overlying the inferior alveolar nerve (about 15 mm), a 25- or 27-gauge short needle may be recommended for the IANB in younger, smaller patients. This should be changed to a long needle once the patient is of sufficient size that a short needle does not reach the injection site without entering tissue almost to its hub.

The buccal nerve may be anesthetized if anesthesia of the buccal tissues in the permanent molar region is necessary. The needle tip is placed distal and buccal to the most posterior tooth in the arch. Approximately 0.2 to 0.3 mL of solution is deposited.

The *Vazirani-Akinosi* and *Gow-Gates mandibular nerve blocks* can also be used in children. Akinosi⁶² advocates the use of short needles with this technique in children. He states

that the technique appears less reliable in children, which he relates to the difficulty of judging the depth of penetration necessary in a growing child. The Gow-Gates mandibular nerve block can be used successfully in children.⁶³ However, such injections are rarely necessary in pediatric dentistry because of the effectiveness of mandibular infiltration (when the dentition is composed entirely of primary teeth) and the relative ease with which one can achieve IANB and incisive nerve block.

The *incisive nerve block* provides pulpal anesthesia for the five primary mandibular teeth in a quadrant. Deposition of anesthetic solution outside the mental foramen with application of finger pressure for 2 minutes provides a very high degree of success. The mental foramen is usually located between the two primary mandibular molars. A volume of 0.45 mL (one-fourth of a cartridge) is suggested in younger patients.

The *PDL injection* has been well accepted in pediatric dentistry and can be used as an alternative to supraperiosteal injection. It provides the doctor with the means to achieve anesthesia of proper depth and duration on one tooth, without unwanted residual soft tissue anesthesia. The PDL injection is also useful when a child has discrete carious lesions in multiple quadrants. See [Chapter 15](#) for a complete discussion of the technique for the PDL injection. It is recommended that the described technique be scrupulously adhered to, to avoid physiologic (pain) and psychological (fear) trauma to the patient.

Local Anesthetic Selection in Pediatric Dentistry

The use of the long-duration local anesthetic bupivacaine (0.5%) with epinephrine 1:200,000 is rarely indicated in younger pediatric patients. The extended duration of soft tissue anesthesia (approximately 9 to 12 hours following nerve block techniques) associated with its administration increases the risk of self-inflicted soft tissue injury substantially.

Short-duration local anesthetic solutions (e.g., 3% mepivacaine, 4% prilocaine without a vasoconstrictor) are excellent selections when the planned dental procedure is limited to but one quadrant in the appointment.

Intermediate-duration local anesthetics are most commonly used when two or more quadrants of treatment are scheduled and/or when more invasive procedures are contemplated (e.g., pulpotomy).

Periodontics

Special requirements for local anesthesia in periodontal procedures center on the use of vasoconstrictors to provide hemostasis and the use of long-duration local anesthetics for postoperative pain control. Postsurgical pain management, including the use of long-duration anesthesia in combination with nonsteroidal antiinflammatory drugs (NSAIDs), is discussed as a separate subject later in this chapter.

Soft tissue manipulation and surgical procedures are associated with hemorrhage, especially when the tissues involved are not anesthetized. The use of local anesthetics without vasoconstrictors is counterproductive because the vasodilating property of the local anesthetic increases bleeding in the region of the injection.⁶⁴ Vasoconstrictors are added to counteract this undesirable property of local anesthetics.

The pharmacology of vasoconstrictors is more completely discussed in Chapter 3. As a review, vasoconstrictors produce arterial smooth muscle contraction through direct stimulation of α receptors located in the wall of the blood vessel. Consequently, it follows that local anesthetics with vasoconstrictors used for hemostasis must be injected directly into the region where the bleeding is to occur.

Pain control for periodontal procedures should be achieved through nerve block techniques, including posterior superior alveolar nerve block, IANB, and infraorbital nerve block. Saadoun³³ has shown that the intraseptal technique is very effective for periodontal flap surgical procedures. It decreases the total volume of administered anesthetic and the volume of blood lost during the procedure. Local anesthetic solutions used for nerve blocks should include a vasoconstrictor in a concentration not greater than 1:100,000 for epinephrine or 1:20,000 for levonordefrin. An epinephrine concentration of 1:50,000 is not recommended for pain control because depth, duration, and success rates are no greater than those seen with anesthetics containing epinephrine 1:100,000 or 1:200,000.

Epinephrine is the drug of choice for local hemostasis. Norepinephrine (which is not available in North America in dental local anesthetics but is available in some other countries) can produce marked ischemia, which can lead to tissue necrosis and sloughing. Norepinephrine is not recommended for use in hemostasis.^{65,66} Epinephrine is most commonly used for hemostasis in a concentration of 1:50,000 (0.2 mg/mL). Generally, small volumes (not exceeding 0.1 mL) are deposited when used for hemostasis. Epinephrine also provides excellent hemostasis in a concentration of 1:100,000, although surgical bleeding is inversely proportional to the concentration of vasoconstrictor administered. When a “plain” local anesthetic is infiltrated (e.g., 3% mepivacaine) during periodontal surgery, blood loss is two to three times that noted when 2% lidocaine with epinephrine 1:100,000 is administered.⁶⁷ Buckley et al.⁶⁸ demonstrated that use of a 1:50,000 epinephrine concentration produced a 50% decrease in bleeding during periodontal surgery from that seen with a 1:100,000 concentration (with 2% lidocaine). However, epinephrine is a drug with systemic effects and some undesirable local effects. Studies have shown that even the small volumes of epinephrine used in dentistry can significantly increase the concentrations of plasma catecholamine and can alter cardiac function.⁶⁹ Therefore it is prudent to administer the smallest volume of the least concentrated form of epinephrine that provides clinically effective hemostasis. Moore et al.⁷⁰ compared the hemostatic efficacy of 4% articaine with epinephrine 1:100,000

and 4% articaine with epinephrine 1:200,000 during periodontal surgery. Significant differences were found between 4% articaine with epinephrine 1:100,000 and 4% articaine with epinephrine 1:200,000 in the surgeons' ability to visualize the surgical field. Surgeons rated the surgical field as “clear” 83.3% of time with 4% articaine with epinephrine 1:100,000 and 59.5% of the time with 4% articaine with epinephrine 1:200,000 ($P = .008$). Additionally, the volume of blood loss was 54.9 mL (± 36.0 mL) for 4% articaine with epinephrine 1:100,000 and 70.2 mL (± 53.0 mL) for 4% articaine with epinephrine 1:200,000 ($P = .018$). They concluded that although both 4% articaine with epinephrine 1:100,000 and 4% articaine with epinephrine 1:200,000 provided excellent surgical pain control, 4% articaine with epinephrine 1:100,000 had the additional therapeutic advantage of providing better visualization of the surgical field and less bleeding.

As tissue levels of epinephrine decrease after its injection for hemostasis, a rebound vasodilation develops. Sveen⁶⁷ demonstrated that postsurgical bleeding (at 6 hours) occurred in 13 of 16 patients (81.25%) receiving 2% lidocaine with epinephrine for surgical removal of a third molar, whereas none of 16 patients who underwent surgery with 3% mepivacaine bled at 6 hours after surgery. Bleeding interfered with postoperative healing in 9 of 16 patients (56.25%) receiving lidocaine with epinephrine, compared with 25% of patients receiving no epinephrine. Evidence also suggests that the use of epinephrine in local anesthetics during surgery may produce an increase in postoperative pain.⁷¹

Many doctors use a 30-gauge short needle to deposit anesthetics for hemostasis. Their rationale is that the thinner needle produces a smaller defect (puncture) in the tissue. If a small puncture is important, then a 30-gauge needle should be used, but only for this purpose (hemostasis). A 30-gauge short needle should not be used if there is the possibility of positive aspiration of blood, or if any depth of soft tissue must be penetrated. Aspiration of blood through a 30-gauge needle is difficult (although possible).⁷² A 27-gauge needle can be used for local infiltration to achieve hemostasis when vascularity is a problem, or in any other area of the oral cavity without an increase in patient discomfort.

Oral and Maxillofacial Surgery

Pain control during surgical procedures is achieved through administration of local anesthetics, given alone or in combination with inhalation sedation, intravenous sedation, or general anesthesia. As is the case with periodontal surgery, long-duration local anesthetics play an important role in postoperative pain control and are discussed separately.

Local anesthetic techniques used in oral surgery do not differ from those used in nonsurgical procedures. Therefore it should be expected that instances of partial or incomplete anesthesia will occur. Oral and maxillofacial surgeons frequently treat patients who have received

intravenous sedation or general anesthesia before the start of surgery. These techniques act to modify the patient's reaction to, and therefore reduce the need for, anesthesia in the number of reported instances of inadequate local anesthesia.

Local anesthesia is routinely administered to patients undergoing general anesthesia for third molar extractions. The reasons for this are:

1. General anesthesia does not prevent pain. General anesthesia prevents the patient from responding outwardly to painful stimulation. Blood pressure, heart rate, and respiratory rate respond to surgical stimulation (they increase).
2. Pain control through local anesthetic administration during surgery permits less exposure to general anesthetic agents, allowing a faster postanesthetic recovery and minimizing drug-related complications.
3. Hemostasis is possible if a vasoconstrictor is included.
4. Residual local anesthesia in the postoperative period aids in postsurgical pain control.

The volume of drug and the rate at which it is administered are important in all areas of dental practice but are probably most important during extraction of teeth from multiple quadrants. When four third molars are extracted, effective pain control must be obtained in all four quadrants. This requires multiple injections of local anesthetics, which usually occur within a relatively short time. Four cartridges or more of local anesthetic are frequently administered.^a The rate at which these local anesthetics is administered must be closely monitored to lessen the occurrence of complications. Complications arising from rapid administration of local anesthetic include any of the following:

1. increased pain during injection
2. increased risk of a serious overdose reaction if the local anesthetic is administered intravascularly (the speed of intravascular drug administration significantly affects the clinical manifestations of toxicity)
3. postanesthetic pain caused by tissue trauma during the injection

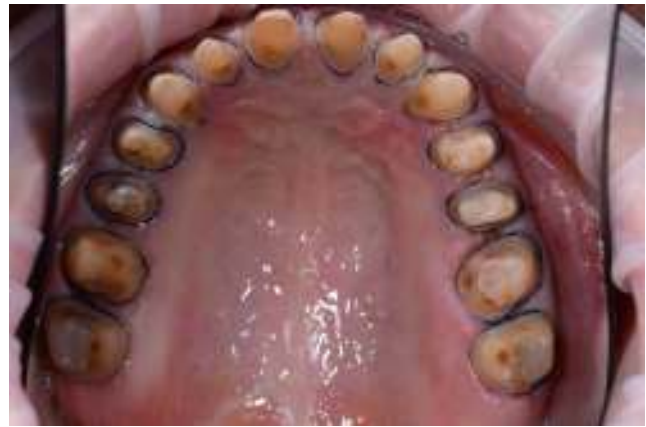These complications and their prevention, recognition, and management are discussed in greater detail in [Chapters 17 and 18](#).

In some persons the inferoposterior border of the mandible is not innervated by the trigeminal nerve. Any of the mandibular nerve blocks described in [Chapter 14](#) provide only partial anesthesia in this situation. The PDL or

^aTypical local anesthetic injections for extraction of four third molars include:

1. right and left inferior alveolar nerve blocks, 1.8 mL for each (3.6 mL)
2. right and left posterior superior alveolar nerve blocks or suprapariosteal infiltration over each third molar, 1.3 to 1.8 mL for each (2.6 to 3.6 mL)
3. right and left palatal infiltration over the maxillary third molars, 0.45 mL for each, or right and left greater palatine nerve block, 0.45 mL for each (0.09 mL)

Total volume of local anesthetic: 8.1 mL or 162 mg for a 2% solution, 243 mg for a 3% solution, or 324 mg for a 4% solution.



• **Fig. 16.7** Extensive treatment area in fixed prosthodontics requires administration of nerve blocks as opposed to infiltration. (Photograph courtesy Dr. Terry Donovan.)

intraosseous injection (see [Chapter 15](#)) usually corrects the lack of pain control in this circumstance.

Fixed Prosthodontics

When preparing a tooth for full coverage (crown or bridge), it is necessary to place a provisional restoration over the prepared tooth. Although achieving pain control might not be difficult at the initial visit, it may be difficult at subsequent visits to adequately anesthetize the prepared tooth. The reason for this is probably the provisional restoration. Overly high restorations produce traumatic occlusion, which can lead to considerable sensitivity after about 1 day. Poorly adapted gingival margins develop microleakage, also causing sensitivity. Preparation of the tooth itself can cause sensitivity, through desiccation of tooth structure, possible pulpal involvement, and periodontal irritation. The longer these sources of irritation are present, the greater the trauma to the tooth is likely to be, and the more difficult it is to achieve adequate anesthesia. Usually a regional nerve block is effective. Supraperiosteal injections generally do not provide adequate pain control in these situations (depth may be adequate, but duration is considerably shorter than that usually expected from the drug).

One additional consideration in fixed prosthodontics occurs when a large case (e.g., full arch) is being prepared in the maxilla ([Fig. 16.7](#)). It commonly takes a considerable length of time to prepare multiple teeth, pack two cords around each tooth, make impressions, and prepare provisional restorations. Anesthesia (infiltration) commonly does not last as long as with a mandibular block technique. Use of maxillary nerve blocks, such as PSA, ASA, and V₂ nerve blocks, is recommended (see [Chapter 13](#)).

Long-Duration Local Anesthesia

Prolonged Dental or Surgical Procedures

Several specialty areas of dental practice require longer-than-usual pulpal and soft tissue anesthesia. These include fixed prosthodontics, oral surgery, and periodontics. During

longer procedures (2 hours or more) an adequate duration of pulpal anesthesia may be difficult to achieve with more commonly used local anesthetics such as articaine, mepivacaine, and prilocaine. Bupivacaine is a long-acting local anesthetic that can then be used. It is discussed more completely in [Chapter 4](#).

Bupivacaine, a homologue of mepivacaine, has a long duration of clinical effectiveness when used for regional nerve block. Its duration of action when administered by supraperiosteal injection, although still long, is somewhat shorter (shorter even than that of lidocaine with epinephrine).⁷³ Its postoperative analgesic period lasts an average of 8 to 9 hours in the mandible and more than 5 hours in the maxilla following nerve block.

Bupivacaine is available with a vasoconstrictor (epinephrine 1:200,000). It is interesting to note that the addition of a vasoconstrictor to bupivacaine does not prolong its duration of action.⁷⁴

Postsurgical Management of Pain

Frequently, after extensive surgical procedures, patients experience intense pain when the local anesthetic effect dissipates. It was, and still is in many cases, common practice to treat postsurgical pain through administration of opioid analgesics. However, opioids have a high incidence of undesirable side effects, such as nausea, vomiting, constipation, respiratory depression, and postural hypotension, especially in ambulatory patients.⁷⁵ Addiction to opioids, the so-called opioid epidemic, is yet another reason to avoid their use following dental surgery.⁷⁶ Additionally, opioid analgesics are not very effective in the management of pain following dental surgery.⁷⁷

Long-acting local anesthetics administered by nerve block to surgical patients offer a means of providing successful postoperative pain control with minimal risk of developing adverse reactions. An advantage of using long-duration local anesthetics is their longer postoperative analgesia, which leads to a reduced need for the administration of postoperative opioid analgesic drugs.⁷⁸ Dentists often use an intermediate-acting local anesthetic such as articaine, lidocaine, mepivacaine, or prilocaine with a vasoconstrictor for the surgical procedure, administering a long-acting local anesthetic just prior to the completion of the surgery. Danielsson et al.⁷³ compared bupivacaine, etidocaine, and lidocaine with regard to their effects on postoperative pain, and found that both bupivacaine and etidocaine were more effective in controlling postoperative pain when compared with lidocaine. They also reported that bupivacaine was more effective than etidocaine in providing postoperative analgesia, and that patients receiving bupivacaine used significantly fewer analgesics.

It is pertinent to note that there appears to be a difference between etidocaine and bupivacaine with respect to their ability to provide adequate hemostasis, even though they contain the same concentration of a vasoconstrictor (1:200,000). Danielsson et al.⁷⁴ noted that bupivacaine provided adequate

hemostasis in 90% but that etidocaine provided adequate hemostasis in only 75% of procedures. It is possible that a higher concentration of local anesthetic may necessitate a higher concentration of a vasoconstrictor to provide comparable hemostasis. Also keep in mind the different vasodilating properties of the solutions.⁷⁹ Etidocaine hydrochloride is not available in dental cartridges in North America.

Protocol for Perioperative and Postoperative Pain Control in Surgical Patients

Postoperative pain associated with most uncomplicated dental surgical procedures is mild and is well managed by oral administration of NSAIDs such as aspirin and ibuprofen.⁷⁷ Preoperative administration of NSAIDs appears to delay the onset of postoperative pain and to lessen its severity.^{78,80} When a patient is unable to tolerate aspirin or other NSAIDs, acetaminophen can provide acceptable analgesia.⁷⁷

Other dental surgical procedures, such as removal of bony impactions and osseous periodontal or endodontic surgery, are more traumatic and are typically associated with more intense and prolonged postoperative pain. The onset of such pain can be delayed by the presurgical administration of an oral or intranasal NSAID followed by administration of a long-acting local anesthetic (bupivacaine) by nerve block at the completion of surgery.⁸⁰

Number Needed to Treat: The Oxford League Table of Analgesic Efficacy

The Oxford League table of analgesic efficacy presents a meta-analysis of randomized, double-blind, single-dose, placebo-controlled studies in patients with moderate to severe postoperative dental, orthopedic, gynecologic, and general surgical pain.⁷⁷ Analgesic efficacy is expressed as the number needed to treat (NNT), the number of patients who need to receive the active drug for one patient to achieve at least 50% relief of pain compared with placebo over a 4- to 6-hour treatment period.^{81,82} The “ideal” analgesic would have an NNT of 1, meaning that every patient receiving that dose of the drug would have effective postsurgical pain relief as defined previously. The most effective analgesics have an NNT of just over 2 ([Table 16.5](#)). Effective pain relief for dental surgery can normally be achieved with oral nonopioids, NSAIDs, coxibs, and combinations of acetaminophen (paracetamol) and codeine.⁷⁷

The NNT is treatment specific, which is useful for comparison of relative efficacy. Because NNT comparisons are against placebo, an NNT of 2 means that 50 of 100 patients will get at least 50% relief specifically because of the treatment. Another 20 will have a placebo response giving them at least 50% relief. With ibuprofen, 400 mg, therefore, about 70 of 100 in total will have effective pain relief. For comparison, with intramuscular morphine, 10 mg, about 53% of patients get more than 50% pain relief.⁷⁷

As noted in [Table 16.5](#), few, if any, analgesics are better than NSAIDs for acute pain. All NSAIDs in the Oxford

TABLE 16.5 Oxford League Table of Analgesic Efficacy (Drugs Available in the United States and Canada) PDF Compressor Free Version

Analgesic and Dose (mg)	Number Needed to Treat	Percentage of Patients With at Least 50% Pain Relief
Ibuprofen, 600/800	1.7	86
Ketorolac, 20	1.8	57
Ketorolac, 60 (IM)	1.8	56
Diclofenac, 100	1.8	69
Piroxicam, 40	1.9	80
Celecoxib, 400	2.1	52
Acetaminophen, 1000 + Codeine, 60	2.2	57
Oxycodone IR, 5 + Acetaminophen, 500	2.2	60
Oxycodone IR, 15	2.3	73
Aspirin, 1200	2.4	61
Ibuprofen, 400	2.4	55
Oxycodone IR, 10 + Acetaminophen, 1000	2.6	67
Naproxen, 400/440	2.7	51
Piroxicam, 20	2.7	63
Meperidine, 100 (IM)	2.9	54
Tramadol, 150	2.9	48
Morphine, 10 (IM)	2.9	50
Ketorolac, 30 (IM)	3.4	53
Placebo	NA	18

Acetaminophen is also known as *paracetamol*.

IM, Intramuscular; IR, immediate release.

Modified from Oxford league table of analgesics in acute pain. Available at: <http://www.medicinesox.ac.uk/bandolier/booth/painpag/acutrev/analgesics/leagtab.html>. 2007. Accessed October 6, 2011.

League table of analgesic efficacy have NNTs of 1.6 to 3.0. Alternative analgesics, such as codeine, 60 mg, and tramadol, 50 mg, have NNTs of 16 and 8, respectively. Parenteral morphine, 10 mg, and meperidine, 100 mg, have an NNT of 2.9.^{77,83} Acetaminophen (paracetamol), administered orally at a dose of 1000 mg, has an NNT of almost 4. When combined with codeine, 60 mg, its NNT decreases to 2.2. Ibuprofen, 400 mg, with an NNT of 2.4 and diclofenac, 50 mg, and rofecoxib, 50 mg, with an NNT of about 2.3 are better. NSAIDs generally do well with a lower NNT.⁷⁷

For effective postsurgical pain management (i.e., no breakthrough pain), it is important to maintain a therapeutic

• BOX 16.7 Pain Control Regimen in Surgical Procedures

Preoperative: Administer one oral dose of nonsteroidal antiinflammatory drug, minimally 1 h before the scheduled surgical procedure. (e.g., ibuprofen, 800 mg per os).

Perioperative: Administer local anesthetic of adequate duration for procedure (articaine, lidocaine, mepivacaine, prilocaine with a vasopressor).

If surgery of up to 30 min duration is planned, immediately follow initial local anesthetic injection with long-acting local anesthetic (bupivacaine with epinephrine) by appropriate nerve block.

If a longer-duration surgical procedure is planned, at the conclusion of the surgical procedure reinject long-acting local anesthetic (bupivacaine with epinephrine) by appropriate nerve block.

Postoperative: Have the patient continue to take the oral nonsteroidal antiinflammatory drug on a timed basis by the clock (e.g., twice, three times, or four times daily) for the number of days considered necessary by the surgeon.

Contact patient via telephone on the evening of the surgery to review postoperative instructions and determine the level of comfort. If considerable pain is present, prescribe an oral opioid, such as codeine, in addition to the nonsteroidal antiinflammatory drug.

blood level of the analgesic via time-based dosage administration of the appropriate oral analgesic. A therapeutic dose of the drug (e.g., ibuprofen, 600 mg) should be administered every 4 to 6 hours—by the clock. The drug package insert for ibuprofen states the following regarding its administration for mild to moderate dental pain:⁸⁴

Oral dosage: Adults: 400 mg PO every 4 to 6 hours as needed. Doses greater than 400 mg have not provided greater relief of pain. Elderly: See adult dosage; as elderly patients may be at a higher risk of adverse events, treat with the lowest effective dose and shortest possible duration. Adolescents: 400 mg PO every 4 to 6 hours as needed. Doses greater than 400 mg have not provided greater relief of pain.

Despite the statement provided previously regarding larger doses than 400 mg of ibuprofen, the Oxford League table of analgesic efficacy clearly shows that 600 mg ibuprofen (NNT of 1.7) is more efficacious than 400 mg ibuprofen (NNT of 2.4).

Box 16.7 outlines a recommended protocol for the management of intraoperative and postoperative pain associated with dental surgical procedures.⁵¹ Dionne RA et al. presents a similar protocol for dental pain designed to minimize opioid misuse or abuse.⁸⁵ (See Table 3 in their article.) Common NSAIDs and their recommended doses are listed in Table 16.6.

Dental Hygiene

In 1997 when the fourth edition of this textbook was published, registered dental hygienists in 20 states in the United States and several provinces in Canada were permitted to administer local anesthesia to dental patients. This number increased to 32 in 2003 and today (2018) stands at 45 (Fig. 16.8).⁸⁶ Inclusion of this expanded

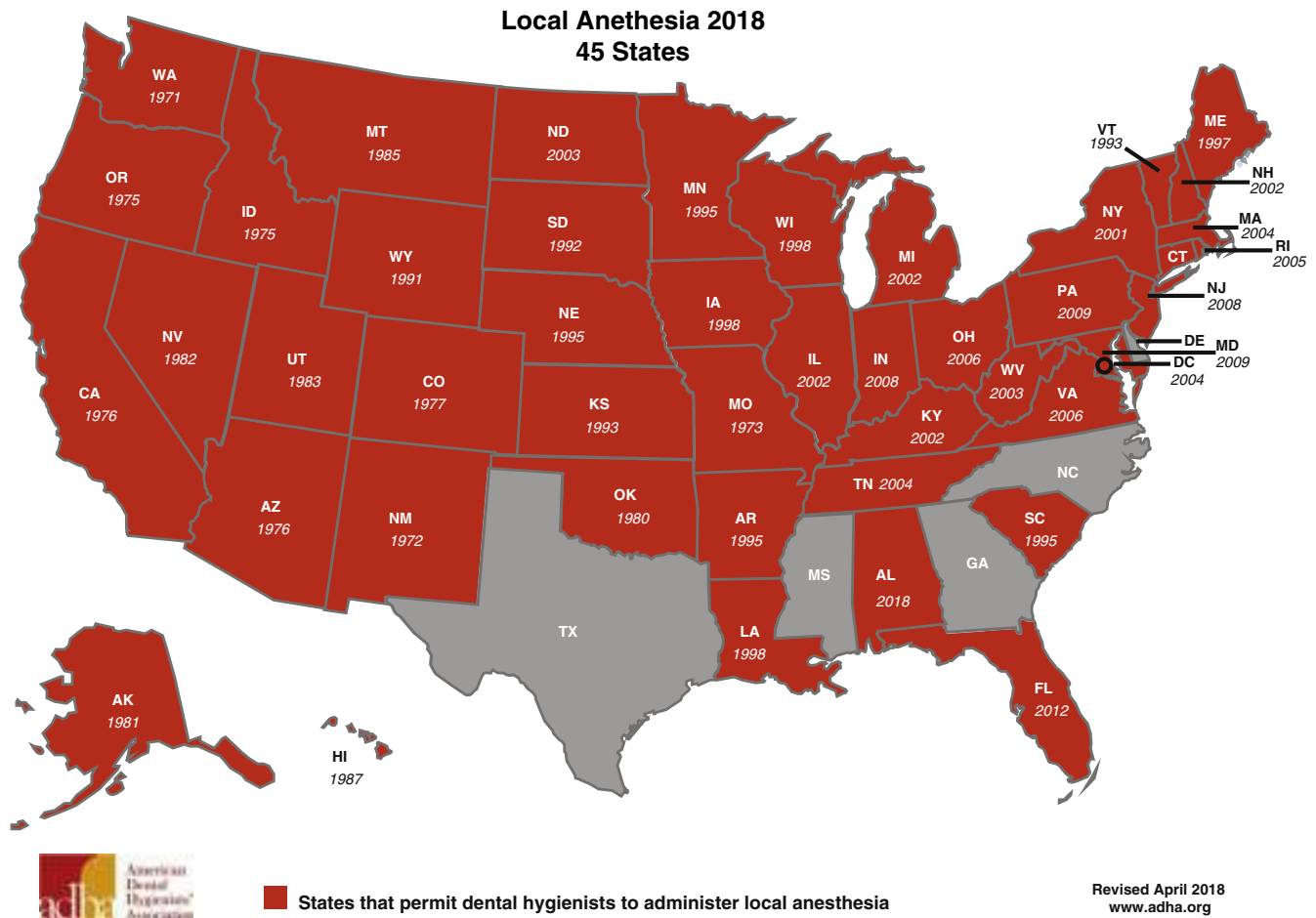
TABLE 16.6 Nonsteroidal Antiinflammatory Drugs

PDF Compressor Free Version

Generic Name	Proprietary Name	Availability (mg)	Dosage Regimen
Ibuprofen	Advil, Caldolor, Motrin, and others	100, 200, 400, 600, 800	Adults: 400 mg PO every 4–6 h as needed
Ketorolac	Toradol	10	10 mg PO every 4–6 h. Maximum 40 mg/day Start 20 mg PO × 1 if <65 years and >50 kg <i>Note:</i> PO only for patients who received parenteral treatment; duration of combined PO/IM/IV treatment not to exceed 5 days
Diclofenac potassium	Cambia, Cataflam, Zipsor	50	50 mg PO three times daily Start 100 mg PO × 1; 200 mg/day first 24 h only, 150 mg/day thereafter. Maximum 200 mg/day
Celecoxib	Celebrex	50, 100, 200, 400	Start 400 mg PO × 1, then 200 mg PO twice daily
Naproxen sodium	Aleve, Anaprox, Menstridol, Naprelan	220, 275, 550	220–550 mg PO every 12 h. Maximum 1100 mg/day
Tramadol	ConZip, Rybix ODT, Ryzolt, Ultram. Ultram ER	50, ER tablet: 100, 200, 300	50–100 mg PO every 4–6 h. Maximum 400 mg/day

ER, Extended release, IM, intramuscular; IV, intravenous; PO, per os.

Data from www.clinicalkey.com. Search for NSAIDs. Accessed 13 December 2018.



• **Fig. 16.8** Local anesthesia 2018. (From American Dental Hygienists' Association. https://www.adha.org/resources-docs/7521_Local_Anesthesia_by_State.pdf. Accessed 13 December 2018.)

function in the Dental Practice Act in these areas has proved of great benefit to the hygienist, doctor, and dental patient.^{87,88} **PDF Compressor Free Version**

Although not all patients need local anesthesia for scaling, root planing, and subgingival curettage, many do. The periodontal tissues being treated are normally sensitive to stimuli and are even more so when inflammation is present. Such is frequently the case when a patient is treated by the dental hygienist.

The hygienist who is permitted to administer local anesthetics to dental patients requires the same technique armamentarium as the doctor. Regional block anesthesia, especially in the maxilla (PSA or ASA nerve block), is an integral part of the hygienist's anesthetic armamentarium because hygienists usually treat sextants or quadrants during a single appointment. The dental hygiene patient requires the same depth of anesthesia as is attained by the doctor doing restorative dentistry or surgery. Root planing without discomfort requires pulpal anesthesia, along with soft tissue and osseous anesthesia.⁸⁷ More than 70% of respondents to a survey on dental hygiene patients' need for pain control reported that their patients needed anesthesia but did not receive it.⁸⁸

Feedback from dentists whose hygienists administer local anesthesia has been uniformly positive; negative comments have been extremely rare.⁸⁹ Dental patients themselves are aware of the difference between local anesthesia administered by the dental hygienist and that administered by the dentist. They frequently comment on the lack of discomfort when the hygienist injects the local anesthetic. Be it a slower rate of administration, greater attention to the details of atraumatic injection technique, or greater empathy, it works.

References

- Nekoofar MH, Namazikhah MS, Sheykhrezae MS, et al. pH of pus collected from periapical abscesses. *Int Endod J*. 2009;42:534–538.
- Brown RD. The failure of local anaesthesia in acute inflammation. *Br Dent J*. 1981;151:47–51.
- Vandermeulen E. Pain perception, mechanisms of action of local anesthetics and possible causes of failure. *Rev Belg Med Dent*. 2000;55:19–40.
- Kitay D, Ferraro N, Sonis ST. Lateral pharyngeal space abscess as a consequence of regional anesthesia. *J Am Dent Assoc*. 1991;122:56–59.
- Connor JP, Edelson JG. Needle tract infection: a case report. *Oral Surg*. 1988;65:401–403.
- Malamed SF, Hersh E, Poorsattar S, Falkel M. Faster onset and more comfortable injection with alkalized 2% lidocaine with epinephrine 1:100,000. *Compend Contin Educ Dent*. 2013;34(Spec No 1):1–11.
- Harreld TK, Fowler S, Drum M, Reader A, Nusstein J, Beck M. Efficacy of a buffered 4% lidocaine formulation for incision and drainage: a prospective, randomized, double-blind study. *J Endod*. 2015;41:1583–1588.
- Schellenberg J, Drum M, Reader A, Nusstein J, Fowler S, Beck M. Effect of buffered 4% lidocaine on the success of the inferior alveolar nerve block in patients with symptomatic irreversible pulpitis: a prospective, randomized, double-blind study. *J Endod*. 2015;41:791–796.
- Saatchi M, Khademi A, Baghaei B, Noormohammadi H. Effect of sodium bicarbonate-buffered lidocaine on the success of inferior alveolar nerve block for teeth with symptomatic irreversible pulpitis: a prospective, randomized double-blind study. *J Endod*. 2015;41:33–35.
- Miles T. Dental pain: self-observations by a neurophysiologist. *J Endod*. 1993;19:613–615.
- Powell V. Articaine is superior to lidocaine in providing pulpal anesthesia. *J Am Dent Assoc*. 2012;143:897–898.
- Malamed SF, Falkel M. Buffered local anesthetics: the importance of pH and CO₂. *SAAD Dig*. 2013;29:9–17.
- Claffey E, Reader A, Nusstein J, Beck M, Weaver J. Anesthetic efficacy of articaine for inferior alveolar nerve blocks in patients with irreversible pulpitis. *J Endod*. 2004;30:568–571.
- Cohen HP, Cha BY, Spangberg LSW. Endodontic anesthesia in mandibular molars: a clinical study. *J Endod*. 1993;19:370–373.
- Robertson D, Nusstein J, Reader A. The anesthetic efficacy of articaine in buccal infiltration of mandibular posterior teeth. *J Am Dent Assoc*. 2007;138:1104–1112.
- Meechan JG, Ledvinka JI. Pulpal anesthesia for mandibular central incisor teeth: a comparison of infiltration and intraligamentary injections. *Int Endod J*. 2002;35:629–634.
- Stiagailo SV. Local anesthesia failure problems in conservative dental therapy clinic. *Stomatologija*. 2006;85:6–10.
- Click V, Drum M, Reader A, Nusstein J, Beck M. Evaluation of the Gow-Gates and Vazirani-Akinosi techniques in patients with symptomatic irreversible pulpitis: a prospective randomized study. *J Endod*. 2015;41:16–21.
- Fowler S, Reader A. Is a volume of 3.6 mL better than 1.8 mL for inferior alveolar nerve block in patients with symptomatic irreversible pulpitis? *J Endod*. 2013;39:970–972.
- Fowler S, Reader A, Beck M. Incidence of missed inferior alveolar nerve blocks in vital asymptomatic subjects and in patients with symptomatic irreversible pulpitis. *J Endod*. 2015;41:637–639.
- Abazarpour R, Pariookh M, Nakhaee N, Abbott PV. A comparison of different volumes of articaine for inferior alveolar nerve block for molar teeth with symptomatic irreversible pulpitis. *J Endod*. 2015;41:1408–1411.
- Stanley W, Drum M, Nusstein J, Reader A, Beck M. Effect of nitrous oxide on the efficacy of the inferior alveolar nerve block in patients with symptomatic irreversible pulpitis. *J Endod*. 2012;38:565–569.
- Lindemann M, Reader A, Nusstein J, Drum M, Beck M. Effect of sublingual triazolam on the success of inferior alveolar nerve block in patients with irreversible pulpitis. *J Endod*. 2008;34:1167–1170.
- Coggins R, Reader A, Nist R, et al. Anesthetic efficacy of the intraosseous injection in maxillary and mandibular teeth. *Oral Surg Oral Med Oral Pathol Oral Radiol Endodont*. 1996;81:634–641.
- Reisman D, Reader A, Nist R, et al. Anesthetic efficacy of the supplemental intraosseous injection of 3% mepivacaine in irreversible pulpitis. *Oral Surg Oral Med Oral Pathol Oral Radiol Endodont*. 1997;84:676–682.
- Leonard M. The efficacy of an intraosseous injection system of delivering local anesthetic. *J Am Dent Assoc*. 1995;126:11–86.
- Coury KA. Achieving profound anesthesia using the intraosseous technique. *Tex Dent J*. 1997;114:34–39.
- Nusstein J, Reader A, Nist R, et al. Anesthetic efficacy of the supplemental intraosseous injection of 2% lidocaine with 1:100,000 epinephrine in irreversible pulpitis. *J Endodont*. 1998;24:478–491.

29. Quinn CL. Injection techniques to anesthetize the difficult tooth. *J Calif Dent Assoc.* 1998;26:665–667.
30. Parente SA, Phillips RW, Herman WW, et al. Anesthetic efficacy of the supplemental intraosseous injection for teeth with irreversible pulpitis. *J Endodont.* 1998;24:826–828.
31. Brown R. Intraosseous anesthesia: a review. *J Calif Dent Assoc.* 1999;27:785–792.
32. Weathers Jr A. Taking the mystery out of endodontics. Part 6. Painless anesthesia for the “hot” tooth. *Dent Today.* 1999;18:90–93.
33. Saadoun AP, Malamed SF. Intraseptal anesthesia in periodontal surgery. *J Am Dent Assoc.* 1985;111:249–256.
34. Reader A. Intraosseous anesthesia. Bonus material F. In: *Taking the Pain out of Restorative Dentistry and Endodontics: Current Thoughts and Treatment Options to Help Patients Achieve Profound Anesthesia. Endodontics: Colleagues for Excellence Winter 2009.* Chicago: American Association of Endodontists; 2009.
35. Alsarheed M. Children’s perception of their dentists. *Eur J Dent.* 2011;5:186–190.
36. Nakai Y, Milgrom P, Mancl L, et al. Effectiveness of local anesthesia in pediatric dental practice. *J Am Dent Assoc.* 2000;131:1699–1705.
37. Goodsen JM, Moore PA. Life-threatening reactions after pedodontic sedation: an assessment of narcotic, local anesthetic, and antiemetic drug interaction. *J Am Dent Assoc.* 1983;107:239–245.
38. Moore PA. Preventing local anesthesia toxicity. *J Am Dent Assoc.* 1992;123:60–64.
39. Berquist HC. The danger of mepivacaine 3% toxicity in children. *Can Dent Assoc J.* 1975;3:13.
40. Malamed SF. Morbidity, mortality and local anesthesia. *Prim Dent Care.* 1999;6:11–15.
41. American Academy on Pediatric Dentistry Council on Clinical Affairs. Guideline on appropriate use of local anesthesia for pediatric dental patients. *Pediatr Dent.* 2008–2009;30(suppl 7):134–139.
42. Meechan JG, Rood JP. Adverse effects of dental local anaesthesia. *Dent Update.* 1997;24:315–318.
43. Davis MJ, Vogel LD. Local anesthetic safety in pediatric patients. *NY State Dent J.* 1996;62:22–35.
44. Chicka MC, Dembo JB, Mathu-Muju KR, et al. Adverse events during pediatric dental anesthesia and sedation: a review of closed malpractice insurance claims. *Pediatr Dent.* 2012;3:231–238.
45. de Jong RH. Central nervous system effects. In: *Local Anesthetics.* St. Louis: Mosby; 1994:273–274.
46. Cheatham BD, Primosch RE, Courts FJ. A survey of local anesthetic usage in pediatric patients by Florida dentists. *J Dent Child.* 1992;59:401–407.
47. Yagiela JA. Regional anesthesia for dental procedures. *Int Anesthesiol Clin.* 1989;27:28–82.
48. Brickhouse TH, Unkel JH, Webb MD, et al. Articaine use in children among dental practitioners. *Pediatr Dent.* 2008;30:516–521.
49. Septodont. *Septocaine (Articaine HCL) Drug Package Insert.* Louisville: Septodont Inc; 2012.
50. Wright G: The use of articaine local anesthesia in children under 4 years of age—a retrospective study. *Anesth Prog.* 1989;36:268–271.
51. Malamed SF. Local anesthetics: dentistry’s most important drugs. *J Am Dent Assoc.* 1994;125:1571–1576.
52. College C, Feigal R, Wandera A, et al. Bilateral versus unilateral mandibular block anesthesia in a pediatric population. *Pediatr Dent.* 2000;22:453–457.
53. Woolson M: FDA approves OraVerse for pediatric dental patients 3 years and older. Available at: <http://www.septodontusa.com/news-events/company-highlights/fda-approves-oraverse-for-pediatric-dental-patients-3-years-and>. Accessed April 20, 2018.
54. Tavares M, Goodson JM, Studen-Pavlovich D, et al. Reversal of soft tissue anesthesia with phentolamine mesylate in pediatric patients. *J Am Dent Assoc.* 2008;139:1095–1104.
55. Rood JP. Notes on local analgesia for the child patient. *Dent Update.* 1981;8:377–381.
56. Kaufman L, Sowray JH, Rood JP. *General Anaesthesia, Local Analgesia, and Sedation in Dentistry.* Oxford: Blackwell Scientific; 1982.
57. O’Sullivan VR, Holland T, O’Mullane DM, et al. A review of current local anaesthetic techniques in dentistry for children. *J Irish Dent Assoc.* 1986;32:17–27.
58. Sharaf AA. Evaluation of mandibular infiltration versus block anesthesia in pediatric dentistry. *ASDC J Dent Child.* 1997;64:276–281.
59. Oulis CJ, Vadiakis GP, Vasilopoulou A. The effectiveness of mandibular infiltration compared to mandibular block anesthesia in treating primary molars in children. *Pediatr Dent.* 1996;18:301–305.
60. Soxman JA, Malamed SF. Local anesthesia for the pediatric patient. In: Soxman JA, ed. *Handbook of Clinical Techniques in Pediatric Dentistry.* Ames: John Wiley & Sons Inc; 2015:7–12.
61. Benham NR. The cephalometric position of the mandibular foramen with age. *J Dent Child.* 1976;43:233–237.
62. Akinosi JO. A new approach to the mandibular nerve block. *Br J Oral Surg.* 1977;15:83–87.
63. Yamada A, Jastak JT. Clinical evaluation of the Gow-Gates block in children. *Anesth Prog.* 1981;28:106–109.
64. Davenport RE, Porcelli RJ, Iacono VJ, et al. Effects of anesthetics containing epinephrine on catecholamine levels during periodontal surgery. *J Periodontol.* 1990;61:553–558.
65. van der Bijl P, Victor AM. Adverse reactions associated with norepinephrine in dental local anesthesia. *Anesth Prog.* 1992;39:37–89.
66. Jakob W. Local anaesthesia and vasoconstrictive additional components. *Newslett Int Fed Dent Anesthesiol Soc.* 1989;2:1.
67. Sveen K. Effect of the addition of a vasoconstrictor to local anesthetic solution on operative and postoperative bleeding, analgesia and wound healing. *Int J Oral Surg.* 1979;8:301–306.
68. Buckley JA, Ciancio SG, McMullen JA. Efficacy of epinephrine concentration in local anesthesia during periodontal surgery. *J Periodontol.* 1984;55:653–657.
69. Jastak JT, Yagiela JA. Vasoconstrictors and local anesthesia; a review and rationale for use. *J Am Dent Assoc.* 1983;107:623–630.
70. Moore PA, Doll B, Delie RA, et al. Hemostatic and anesthetic efficacy of 4% articaine HCl with 1:200,000 epinephrine and 4% articaine HCl with 1:100,000 epinephrine when administered intraorally for periodontal surgery. *J Periodontol.* 2007;78:247–253.
71. Skoglund LA, Jorkjend L. Postoperative pain experience after gingivectomies using different combinations of local anesthetic agents and periodontal dressings. *J Clin Periodontol.* 1991;18:204–209.
72. Trapp LD, Davies RO. Aspiration as a function of hypodermic needle internal diameter in the in-vivo human upper limb. *Anesth Prog.* 1980;27:49–51.
73. Danielsson K, Evers H, Nordenram A. Long-acting local anesthetics in oral surgery: an experimental evaluation of bupivacaine and etidocaine for oral infiltration anesthesia. *Anesth Prog.* 1985;32:65–68.

74. Danielsson K, Evers H, Holmlund A, et al. Long-acting local anaesthetics in oral surgery. *Int J Oral Maxillofac Surg.* 1986;15:119–126.
75. Yaksh T, Wallace M. Opioids, analgesia, and pain management. In: Brunton L, Hilal-Dandan R, Knollmann B, eds. *Goodman & Gilman's the Pharmacological Basis of Therapeutics*. 13th ed. New York: McGraw-Hill Education; 2018:355–386.
76. Olsen Y. The CDC guideline on opioid prescribing. Rising to the challenge. *J Am Med Assoc.* 2016;315:1577–1579.
77. Oxford league table of analgesics in acute pain. Available at: <http://www.bandolier.org.uk/booth/painpag/Acutrev/Analgesics/Leagtab.html>; 2007. Accessed April 19, 2018.
78. Jackson DL, Moore PA, Hargreaves KM. Pre-operative non-steroidal anti-inflammatory medication for the prevention of postoperative dental pain. *J Am Dent Assoc.* 1989;119:641–647.
79. Linden ET, Abrams H, Matheny J, et al. A comparison of post-operative pain experience following periodontal surgery using two local anesthetic agents. *J Periodontol.* 1986;57:637–642.
80. Acute Pain Management Guideline Panel. *Acute Pain Management: Operative or Medical Procedures and Trauma. Clinical Practice Guideline, AHCPR Publication no. 92-0032*. Rockville: Agency for Health Care Policy and Research, Public Health Service, US Department of Health and Human Services; 1992.
81. Cook RJ, Sackett DL. The number needed to treat: a clinically useful measure of treatment effect. *BMJ.* 1995;310:452–454.
82. McQuay HJ, Moore RA. Using numerical results from systematic reviews in clinical practice. *Ann Int Med.* 1997;126(9):712–720.
83. Ong CKS, Lirk P, Tan CH, et al. An evidence-based update on nonsteroidal anti-inflammatory drugs. *Clin Med Res.* 2007;5:19–34.
84. ClinicalKey. Ibuprofen monograph. Indications—dosage. 2018. Available at: <https://www.clinicalkey.com>. Accessed April 20, 2018.
85. Dionne RA, Gordon SM, Moore PA. Prescribing opioid analgesics for acute dental pain: time to change clinical practices in response to evidence and misperceptions. *Compend Contin Educ Dent.* 2016;37:372–378.
86. American Dental Hygienists' Association. Available at: https://www.adha.org/resources-docs/7521_Local_Anesthesia_by_State.pdf. 2018. Accessed 13 December 2018.
87. Sisty-LePeau N, Boyer EM, Lutjen D. Dental hygiene licensure specifications on pain control procedures. *J Dent Hyg.* 1990;64:179–185.
88. Sisty-LePeau N, Nielson-Thompson N, Lutjen D. Use, need and desire for pain control procedures by Iowa hygienists. *J Dent Hyg.* 1992;66:137–146.
89. DeAngelis S, Goral V. Utilization of local anesthesia by Arkansas dental hygienists, and dentists' delegation/satisfaction relative to this function. *J Dent Hyg.* 2000;74:196–204.

Complications, Legal Considerations, Questions, and the Future

Local Complications

A number of potential complications are associated with the administration of local anesthetics. For purposes of convenience, these complications may be separated into those that occur locally—in the region of the injection—and those that are systemic. Systemic complications associated with the administration of local anesthesia are discussed in [Chapter 18](#), and include overdosage (toxic reaction), allergy, and psychogenic reactions. The following localized complications are described in this chapter:

- needle breakage
- prolonged anesthesia (paresthesia)
- facial nerve paralysis
- ocular complications
- trismus
- soft tissue injury
- hematoma
- pain on injection
- burning on injection
- infection
- edema
- sloughing of tissues
- postanesthetic intraoral lesions

It must be emphasized that with any complication associated with the administration of a local anesthetic, a written entry should be placed in the patient's dental record. For complications that become chronic, a note should appear whenever the patient is reevaluated.

Needle Breakage

Since the introduction of non-reusable, stainless steel dental local anesthetic needles, needle breakage has become an extremely rare complication of dental local anesthetic injections ([Fig. 17.1](#)). Pogrel¹ has estimated the risk of needle breakage among northern California dentists at 1 in 14 million inferior alveolar nerve blocks (IANBs). In the United States, 1.43 million boxes of dental needles (100 needles per box; 143,000,000 needles) were sold by one needle manufacturer in 2004, 1.56 million boxes in 2005, and 1.43 million boxes in 2006.² Reports of broken dental needles in the published literature appear only infrequently, but appear they do. A MEDLINE search for broken dental needles from 1951 through February 2010 uncovered 26 published

reports of broken dental needles, including their cause and management.^{1,3-27} Review of 20 of these reports, for which information regarding needle gauge and length and technique of anesthesia used is available, reveals that 15 were for IANB and 5 were for posterior superior alveolar (PSA) nerve block. All five PSA reports described adult patients, whereas 9 of the 15 broken needle reports following IANB occurred in children. Needle gauge and/or length was presented in 11 articles. Ten of the 11 needles were 30-gauge short needles; only one case reported long needle breakage (27-gauge needle) with the needle remaining in the tissues.¹²

Pogrel¹ reported on 16 patients whom he evaluated over a 25-year period (1983 to 2008) following needle breakage. Fifteen patients had received IANB, one had received a PSA nerve block. Thirteen of the 16 needles were 30-gauge short needles and 3 were 27-gauge short needles.

Independent of the cited literature, this author is aware of 51 cases that progressed to litigation in which broken dental needle fragments remained within the soft tissues of the patient receiving the injection.²⁸ Fifty of these events involved 30-gauge short needles; a 27-gauge short needle was involved in the other case. All but one involved administration of an IANB. A PSA nerve block was used in the other case.

A manufacturer of dental local anesthetic needles reported that over a 6-year period (1997 to 2002), 27 doctors contacted the company reporting instances of broken dental needles. All incidents involved 30-gauge short needles.²⁹

Long dental needles most likely have broken during injection. However, because the long needle is unlikely to have been inserted its full length (approximately 32 mm) into soft tissue, some portion of the needle would remain visible in the patient's mouth, allowing easy retrieval of the fragment with a hemostat. Litigation does not occur in such incidents.

[Table 17.1](#) summarizes the accumulated findings presented to this point.³⁰ Although some reports may have been duplicated, the factual information clearly identifies commonalities in most cases: use of 30-gauge short or ultra-short needles in injection techniques in which the needle is inserted to its hub ("hubbing the needle"). All reported cases involved the IANB or PSA nerve block. In all situations in which it is mentioned, needle fracture occurred at

the hub—never along the shaft of the needle (Fig. 17.2). Additional factors include (1) intentional bending of the needle by the doctor (Fig. 17.3), (2) sudden unexpected movement by the patient while the needle is still embedded in tissue (primarily in children), and (3) forceful contact with bone.

The exact cause of needle breakage is rarely discernible. In cases in which the needle has been surgically retrieved and/or forensic metallurgists have examined the hub of the needle, in some cases using scanning electron microscopy, no evidence has revealed manufacturing defects in the needle (Fig. 17.4).

Problem

Needle breakage per se is not a significant problem if the needle can be removed without surgical intervention. Ready access to a hemostat enables the doctor or the assistant to grasp the visible proximal end of the needle fragment and remove it from the soft tissue.


Where the needle has been inserted to its hub and the soft tissue has dimpled under pressure from the syringe, the broken fragment will not be visible when the syringe is withdrawn from the patient’s mouth. The needle fragment remaining in the tissue poses a risk of

serious damage being inflicted on the soft tissues and surrounding structures (e.g., nerve, blood vessels) for as long as the fragment remains. Although it is not a common occurrence, needle fragments can migrate, as illustrated by the series of panoramic films taken at 3-month intervals in Fig. 17.5.

Management

Management of the broken dental needle involves immediate referral of the patient to an appropriate specialist (e.g., an oral and maxillofacial surgeon) for evaluation and possible attempted retrieval. Conventional management involves locating the retained fragment through panoramic and computed tomographic scanning.²⁵

More recently, three-dimensional computed tomographic scanning has been recommended to identify the location of the retained needle fragment.^{1,31} A surgeon in the operating theater then removes the retained needle fragment with the patient under general anesthesia (Fig. 17.6).



• Fig. 17.1 Metal disposable needle, disassembled.



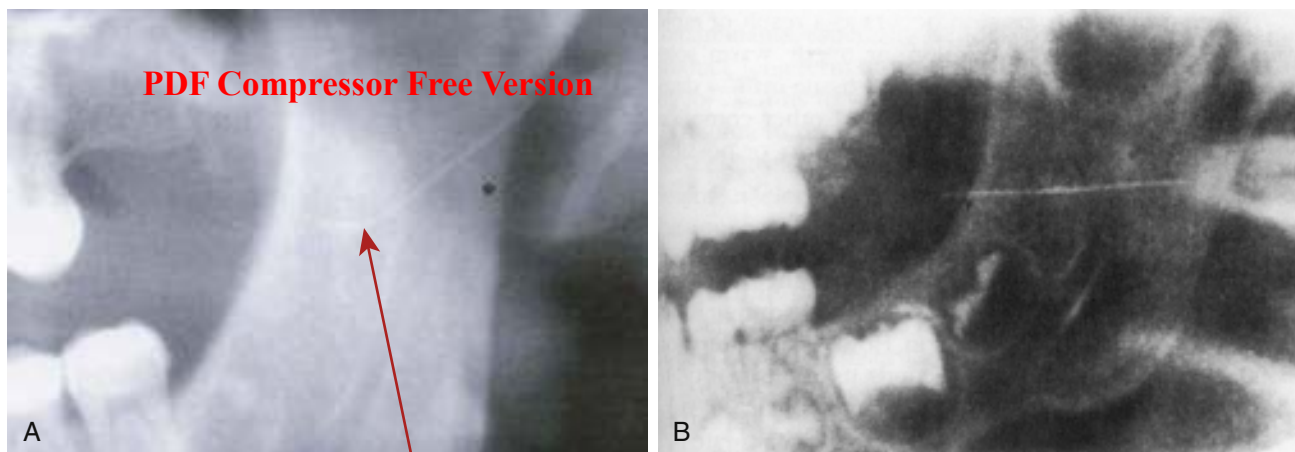
• Fig. 17.2 Hub of broken needle.

TABLE 17.1 Summary of Reports of Broken Dental Needles

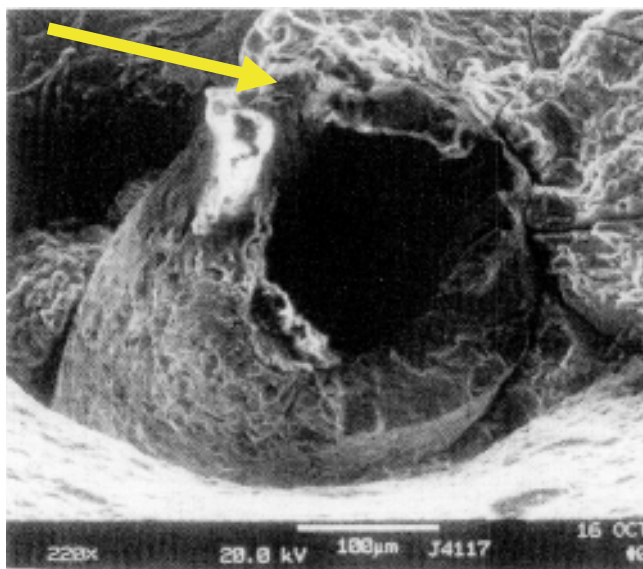
	Inferior Alveolar Nerve Block	Posterior Superior Alveolar Nerve Block	30-Gauge Needle	27-Gauge Needle
Individual citations	15	5	10	1
Pogrel ²¹	15	1	13	3
Malamed	32	1	33	1
Reed	17	0	17	0
Manufacturer	NA	NA	27	0
Total	79	7	100	5

NA, Not applicable.

From Malamed SF, Reed K, Poorsattar S. Needle breakage: incidence and prevention. *Dent Clin N Am.* 2010;54:745–756.



• **Fig. 17.3** (A) Radiograph of a broken dental needle (note the bend in the needle: arrow). (B) Radiograph of a broken dental needle in the pterygomandibular space. ([B] From Marks RB, Carlton DM, McDonald S. Management of a broken needle in the pterygomandibular space: report of a case. *J Am Dent Assoc.* 1984;109:263–264.)



• **Fig. 17.4** Scanning electron microscopy image of a broken dental needle. The yellow arrow at the 11 o'clock position indicates the area where the needle was bent superiorly before injection, per court testimony of a forensic metallurgist.

Prevention

Although rare, dental needle breakage does occur. Review of the literature and personal experience of the author bring into focus several commonalities, which, when avoided, can minimize the risk of needle breakage with the fragment being retained. These include the following:

- Do not use short needles for IANB in adults or larger children (length should be determined by the soft tissue thickness of each individual patient).
- Do not use 30-gauge needles for IANB in adults or children.
- Do not bend needles when inserting them into soft tissue.
- Do not insert a needle into soft tissue to its hub, unless it is absolutely essential for the success of the injection.

- Observe extra caution when inserting needles in younger, immature, children or in extremely phobic adult or child patients as they are more apt to make sudden unexpected movements.

Prolonged Anesthesia or Paresthesia

On occasion, a patient reports feeling numb (“frozen”) many hours or days after a local anesthetic injection. Normal distribution of patient response to drugs allows for the rare individual (e.g., the hyper-hyperreactor) who may experience prolonged soft tissue anesthesia after local anesthetic administration that persists for many hours longer than expected. This is not a problem.

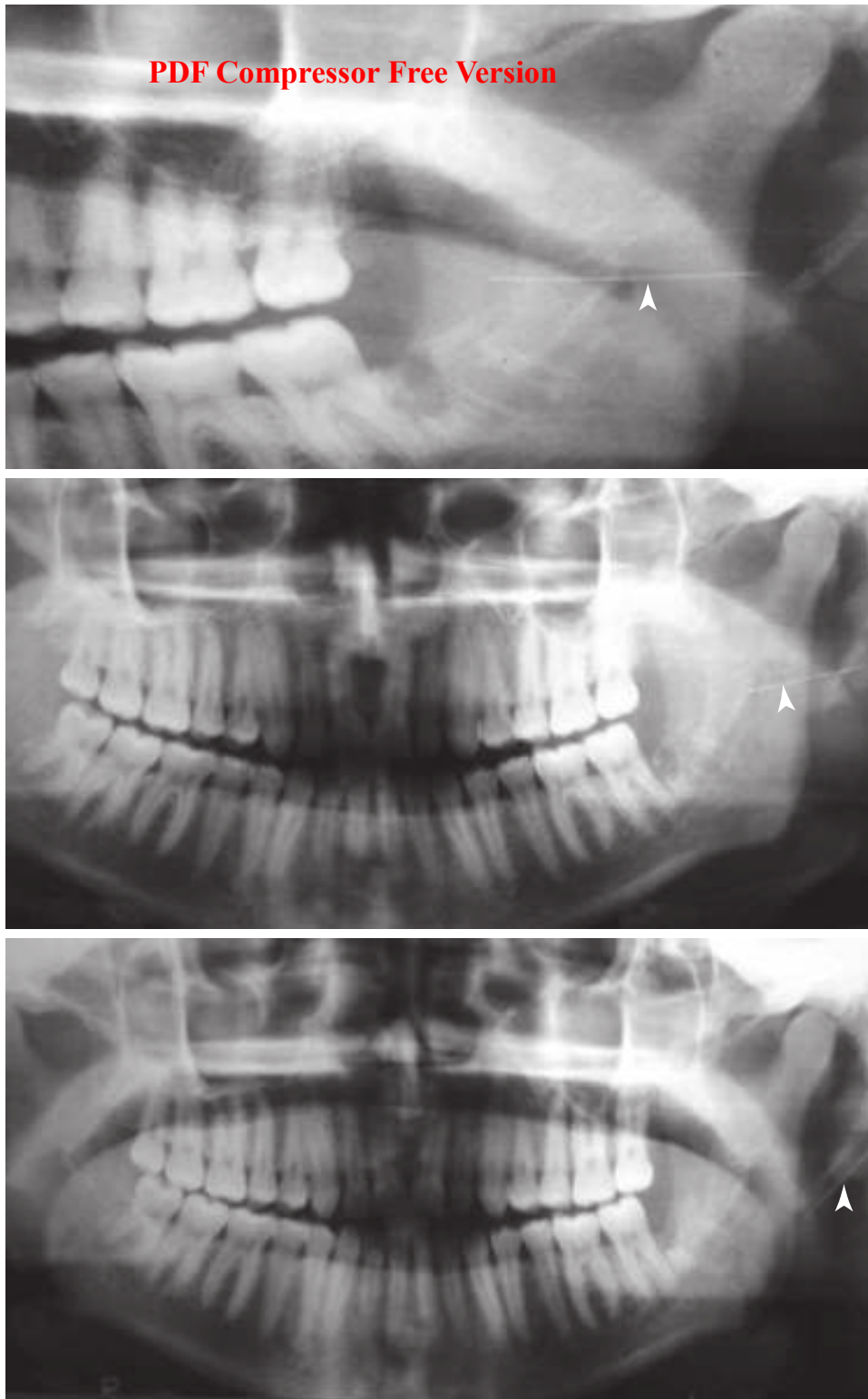
When anesthesia persists for days, weeks, or months, the potential for the development of problems is increased. Paresthesia or persistent anesthesia is a disturbing yet often unpreventable complication of local anesthetic administration. Paresthesia is one of the most frequent causes of dental malpractice litigation.

A patient’s clinical response to this can be profuse and varied, including sensations of numbness, swelling, tingling, and itching. Associated oral dysfunction, including tongue biting, drooling, loss of taste, and speech impediment, may be noted.³²⁻³⁵

Paresthesia is defined as persistent anesthesia (anesthesia well beyond the expected duration), or altered sensation well beyond the expected duration of anesthesia. In addition, the definition of paresthesia should include hyperesthesia and dysesthesia, in which the patient experiences both pain and numbness.³⁶

Causes

Trauma to any nerve may lead to paresthesia. Paresthesia is a common complication of oral surgical procedures and mandibular dental implants.^{33,37-39} In an audit of 741 mandibular third molar extractions, Bataineh³⁹ found postoperative



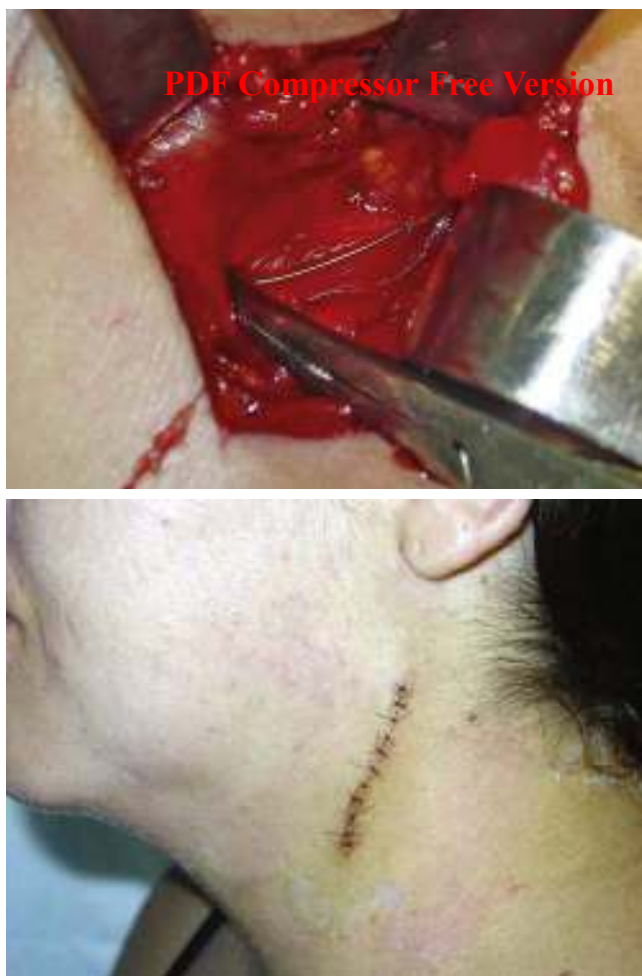• **Fig. 17.5** Needle fragments can migrate as shown in the series of panoramic films taken at 3-month intervals. (Courtesy Dr. Carlos Elias De Freitas. From Malamed SF, Reed KR, Poorsattar S. Needle breakage: incidence and prevention. *Dent Clin N Am.* 2010;54:745–756.)

lingual nerve anesthesia in 2.6% of patients; the rate of inferior alveolar nerve paresthesia was 3.9%, developing in 9.8% of patients younger than 20 years. Also, a significant correlation was noted between the incidence of paresthesia and the experience of the administrator.

Injection of a local anesthetic solution contaminated by alcohol or sterilizing solution near a nerve produces

irritation, resulting in edema and increased pressure in the region of the nerve, leading to paresthesia. These contaminants, especially alcohol, are neurolytic and can produce long-term trauma to the nerve (paresthesia lasting for months to years).

Trauma to the nerve sheath can be produced by the needle during injection. Many patients report the sensation of



• **Fig. 17.6** Surgical excision of needle fragment (see the patient from Fig. 17.5). (Courtesy Dr. Carlos Elias De Freitas CVM. From Malamed SF, Reed KR, Poorsattar S. Needle breakage: incidence and prevention. *Dent Clin N Am.* 2010;54:745–756.)

an “electric shock” or “zap” throughout the distribution of the involved nerve as the injection is being administered. Although it is exceedingly difficult (and highly unlikely) to actually sever a nerve trunk or even its fibers with the small needles used in dentistry, trauma to a nerve produced by contact with the needle is all that may be needed to produce paresthesia.^{33,34} Insertion of a needle into a foramen, as in the second division (maxillary) nerve block via the greater palatine foramen, also increases the likelihood of nerve injury.

Hemorrhage into or around the neural sheath is another cause. Bleeding increases pressure on the nerve, leading to paresthesia.^{32-34,36}

Edema following surgical procedures is another potential cause of paresthesia, as the pressure of the edematous fluid compresses the nerve.

The local anesthetic solution itself may contribute to the development of paresthesia after local anesthetic injection.⁴⁰ Haas and Lennon³² took a retrospective look at paresthesia after injection of local anesthetic in dentistry in the province of Ontario, Canada, over a 20-year period (1973 to 1993).

Their report included voluntary submissions by dentists to their insurance carriers for claims of paresthesia. Only cases where no surgery was performed were considered. One hundred forty-three cases of paresthesia unrelated to surgery were reported in this period. All reported cases involved the inferior alveolar nerve or the lingual nerve or both, with anesthesia of the tongue reported most often, followed by anesthesia of the lip. Pain (hyperesthesia) was reported by 22% of patients. Paresthesia was reported more often after administration of a 4% local anesthetic—prilocaine hydrochloride and articaine hydrochloride. Observed frequencies of paresthesia after administration of articaine hydrochloride and prilocaine hydrochloride were greater than expected, based on the distribution of local anesthetic use in Ontario in 1993.³² According to Haas and Lennon³² the incidence of paresthesia resulting from all local anesthetics is approximately 1 in 785,000; for 0.5%, 2%, and 3% local anesthetics, it is approximately 1 in 1,250,000; and for 4% local anesthetics, it is approximately 1 in 485,000.

In 2006 Hillerup and Jensen⁴¹ in Denmark, reviewing insurance claims, suggested that articaine should not be used for IANB because it had, in their opinion, a greater propensity for paresthesia. Yet, of the 54 case reports of paresthesia reviewed, 42 (77%) involved not the inferior alveolar nerve but the lingual nerve (see later discussion) (Table 17.2).

In response to Hillerup and Jensen’s article, the Pharmacovigilance Working Committee of the European Union reviewed reports of paresthesia associated with articaine and other local anesthetics in 57 countries, estimating that the number of patients treated with articaine is approximately 100 million annually.⁴² Their published report (October 30, 2006) states the following: “This investigation is a follow-up to an inquiry initiated in 2005. This enquiry resulted from suspicions that were raised in Denmark, that a local anesthetic, articaine, was responsible for an increased risk of nerve injuries compared with the risk associated with other local anesthetics (mepivacaine, prilocaine, lidocaine).” The report concluded: “Regarding articaine, the conclusion is that [the] safety profile of the drug has not significantly evolved since its initial launch (1999 in Denmark). Thus, no medical evidence exists to prohibit the use of articaine according to the current guidelines listed in the summary of product characteristics.”⁴² “All local anesthetics may cause nerve injury (they are neurotoxins). The occurrence of sensory impairment is apparently slightly more frequent following use of articaine and prilocaine. However, considering the number of patients treated, sensory impairments rarely occur. For example, the incidence of sensory impairment following the use of articaine is estimated to be 1 case in 4.6 million treated patients.” Further they report, “Nerve injuries may result from several incidents: mechanical injury because of needle insertion; direct toxicity from the drug; and neural ischaemia.”⁴²

In 2007 Pogrel⁴³ reported the first clinical evaluation of cases of paresthesia in nonsurgical cases. Evaluation of 57 cases of paresthesia following local anesthetic administration

TABLE
17.2

Distribution of Analgesic Solution and Nerve Affected, Including 54 Nerve Injuries in 52 Patients

	Inferior Alveolar Nerve	Lingual Nerve	Sum
Articaine (4%)	5	24	29 (54%)
Prilocaine (3%)	4	6	10 (19%)
Lidocaine (2%)	3	7	10 (19%)
Mepivacaine (3%)	0	4	4 (7%)
Mepivacaine (3%) + articaine (4%)	0	1	1 (2%)
Number of nerve injuries	12	42	54 (100%)

From Hillerup S, Jensen R. Nerve injury caused by mandibular block analgesia. *Int J Oral Maxillofac Surg*. 2006;35:437–443.

TABLE
17.3

Summary of Incidence of Reported Nerve Injury From 2003 to 2011

Anesthetic	Ratio (1.0 Expected)	
	2007 ⁴³	2012 ⁴⁴
Lidocaine hydrochloride	0.64	0.5
Articaine hydrochloride	1.19	0.97
Prilocaine hydrochloride	4.96	2.2
Mepivacaine hydrochloride	Not reported	3.25

Modified from Pogrel MA. Permanent nerve damage from inferior alveolar nerve blocks—an update to include articaine. *J Calif Dent Assoc*. 2007;35:271–273; and Pogrel MA. Permanent nerve damage from inferior alveolar nerve blocks—a current update. *J Calif Dent Assoc*. 2012;40:795–797.

(over a 3-year period, 2003 to 2005) revealed that lidocaine was responsible for 35% of cases, articaine for 29.8%, and prilocaine for 29.8%. He presented the following as the reason for his research and writing of the article: “We were aware of the discussion in dental circles as to the use of articaine for inferior alveolar nerve blocks and are aware of recommendations suggesting that it not be used for IANBs. This was the predominant reason for submitting this paper at this time.”⁴³

In 2012 Pogrel⁴⁴ reported on an additional 41 patients he evaluated from 2006 through 2011. He concluded: “of the cases referred, it would appear that despite the fact that articaine may be used less for inferior alveolar blocks than it was and used more for infiltrations because of its great penetrating power, it is still causing cases of permanent inferior alveolar and lingual nerve damage, which is proportionate to its market share.”⁴⁴

All local anesthetics *are* neurotoxic. If all local anesthetics were equally neurotoxic, then the percentage of reported cases of paresthesia for any given drug should be equal to its percentage of market share. For example, if a drug had a 30% market share, it should then account for 30% of the reported cases of paresthesia—a 1:1 ratio (reported as 1.0).

From Pogrel’s statistics,^{43,44} lidocaine, with 54% market share and 35% of the reported cases of paresthesia, had a ratio of 0.64 in 2007 and 0.5 in 2012—better than expected. Prilocaine, on the other hand, with a 6% market share, had 29.8% of the reported cases—a ratio of 4.96 in 2007) and 3.25 in 2012. Articaine, with 25% market share at the time, had 29.8% of the reported cases—a ratio of 1.19 in 2007 and 0.97 in 2012. Mepivacaine, reported in 2012 had 11% of the reported cases of paresthesia and a ratio of 2.2. Table 17.3 summarizes Pogrel’s two articles.^{43,44}

Pogrel concluded that “using our previous assumption that approximately half of local anesthetic used is for inferior alveolar nerve blocks, then on the figures we have generated from our clinic, we do not see disproportionate nerve involvement for articaine.”⁴³

In his discussion, Pogrel also noted that “many of the reports to outside agencies do not report whether the paresthesia was temporary or permanent, and because it is known that most of the paresthesias are temporary and do eventually recover, only reports of persistent issues for nine months or longer should be considered permanent.”⁴⁴

In July 2010, Garisto et al.⁴⁵ reported on the occurrence of paresthesia after dental local anesthetic administration in the United States. Data were gathered from the US Food

TABLE 17.4 Incidences of Paresthesia Reported to the Adverse Event Reporting System From 1997 to 2008

Anesthetic	Incidence
Mepivacaine	1 in 623,112,900
Lidocaine	1 in 181,076,673
Bupivacaine	1 in 124,286,050
Overall	1 in 13,800,970
Articaine	1 in 4,159,848
Prilocaine	1 in 2,070,678
Being struck by lightning (annual risk)	1 in 328,000 to 1 in 700,000

Data derived and modified from Garisto GA, Gaffen AS, Lawrence HP, et al. Occurrence of paresthesia after dental local anesthetic administration in the United States. *J Am Dent Assoc.* 2010;141:836–844.

and Drug Administration (FDA) Adverse Event Reporting System (AERS). Over an almost 11-year reporting period (November 1997 to August 2008), 248 cases of paresthesia following dental local anesthesia were reported, of which 94.5% involved IANB. Of the reported cases, 89.0% involved only the lingual nerve. Table 17.4 reports the incidence of paresthesia calculated for each dental local anesthetic. As a comparison, the reported risk of being struck by lightning in a given year in the United States is between 1 in 328,000⁴⁶ and 1 in 700,000.⁴⁷

One hundred eight of the 248 cases of paresthesia were reported as having resolved completely over a range of from 1 day to 736 days. Confirmed resolution occurred in 34 of the 108 cases (31.4%). Of these, 25 resolved within 2 months, and the remaining 9 resolved within 240 days.⁴⁵

However, the report by Garisto et al. relied on data from the AERS. The FDA website for AERS displays the following warning: “AERS data do have limitations. First, there is no certainty that the reported event was actually caused by the product. FDA does not require that a causal relationship between a product and event be proven, and reports do not always contain enough detail to properly evaluate an event. Further, FDA does not receive all adverse event reports that occur with a product. Many factors can influence whether or not an event will be reported, such as the time a product has been marketed and publicity about an event. Therefore, AERS cannot be used to calculate the incidence of an adverse event in the U.S. population.”⁴⁸

A meta-analysis of the efficacy and safety of articaine versus lidocaine, published in 2010, concluded that “this systematic review supports the argument that articaine as compared with lignocaine provides a higher rate of anesthetic success, with comparable safety to lignocaine when used as infiltration or blocks for routine dental treatments.”⁴⁹

All Injections Are Blind

As of December 2018, although articaine hydrochloride, in most countries, including Canada and the United States, is either the first or second most used dental local anesthetic,^{50,51} the “controversy” occasionally flares anew. Proponents of one side of the argument adamantly believe that 4% local anesthetics do carry a greater risk of paresthesia, be it transient or permanent, but others believe, as adamantly, that other factors are usually involved, primarily mechanical trauma, especially when the paresthesia involves only the lingual nerve, as is the case in 89% of the cases cited by Garisto et al.⁴⁵

So, what should the doctor do? As with all procedures under consideration for use by a doctor, as well as with any drugs being considered for administration, the doctor must weigh the benefit to be gained from use of the drug or therapeutic procedure against the risks involved in its use. Only when, in the mind of the treating doctor, the benefit to be gained clearly outweighs its risk should the drug or the procedure be used.

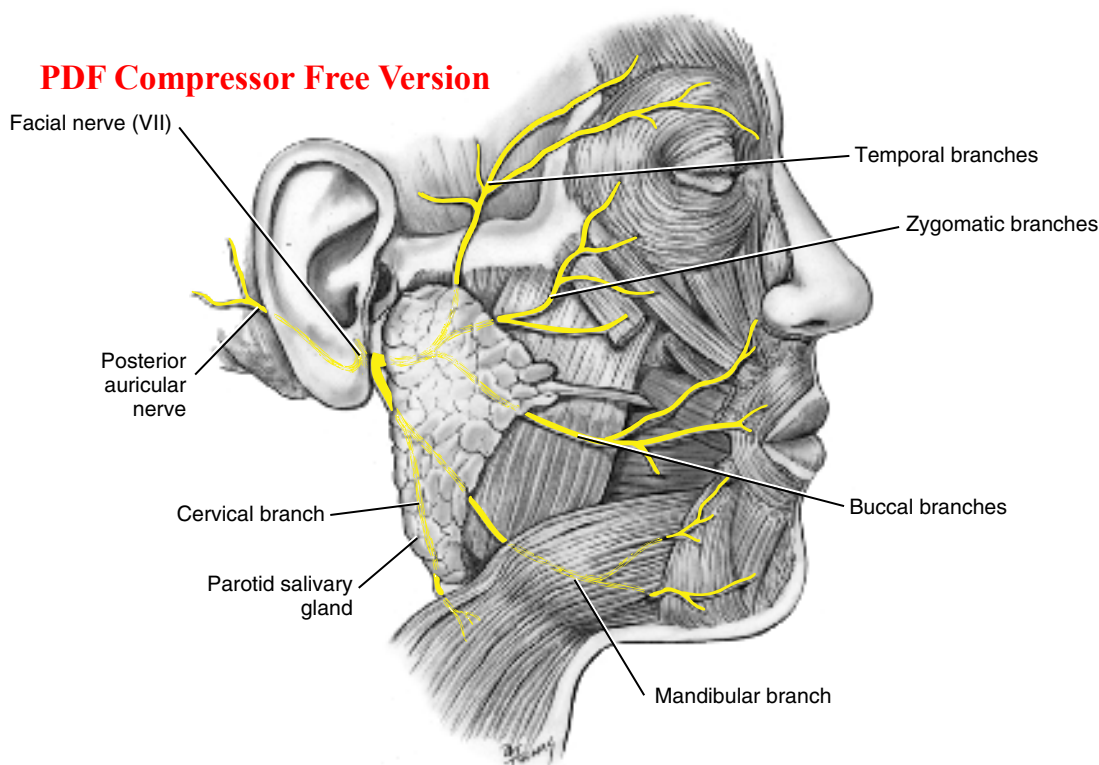
Problem

Persistent anesthesia, rarely total, in most cases partial, and in most cases transient, can lead to self-inflicted soft tissue injury. Biting or thermal or chemical insult can occur without a patient’s awareness until the process has progressed to a serious degree. When the lingual nerve is involved, the sense of taste (via the chorda tympani nerve) may also be impaired.

In some instances, loss of sensation (paresthesia) is not the clinical manifestation of nerve injury. Hyperesthesia (an increased sensitivity to noxious stimuli) and dysesthesia (a painful sensation occurring to usually nonnoxious stimuli) may also be noted. Haas and Lennon³² reported that pain was present in 22% of the 143 cases of paresthesia that they reviewed.

Prevention

Strict adherence to the injection protocol and proper care and handling of dental cartridges help minimize the risk of paresthesia. Nevertheless, cases of paresthesia will still occur in spite of care taken during the injection. Whenever a needle is inserted into soft tissues, anywhere in the body, in an attempt to deposit a drug (e.g., local anesthetic) as close to a nerve as possible without actually contacting it, it is simply a matter of time before such contact does occur. As Pogrel opined: “It is reasonable to suggest that during a career, each dentist may encounter at least one patient with an inferior alveolar nerve block resulting in permanent nerve involvement. The mechanisms are unknown and there is no known prevention or treatment.”³³



• Fig. 17.7 Facial nerve distribution.

Management

Nichel⁵² reported that most paresthesias resolve within approximately 8 weeks without treatment.^{53,54} Only when damage to the nerve is severe will the paresthesia be permanent, and this occurs only rarely.

In most situations the degree of paresthesia is minimal, with the patient retaining most of the sensory function to the affected area. Therefore the risk of self-inflicted tissue injury is minimal.

Garisto et al.⁴⁵ in reviewing 248 reports of paresthesia had data on resolution in 108 cases. The period of resolution ranged from as short as 1 day to as long as 736 days. Confirmed resolution of paresthesia was reported in 34 of the 108 cases (31.4%). Of the 34 cases that did resolve, 25 did so within 2 months; the remaining 9 cases resolved within 240 days.

In phase 3 clinical trials comparing 4% articaine hydrochloride with epinephrine 1:100,000 ($N = 882$) with 2% lidocaine with epinephrine 1:100,000 ($N = 443$), Malamed et al.⁵⁵ reported the total number of participants who reported these symptoms (paresthesia) 4 to 8 days after the procedure was 8 (1%) for the articaine group and 5 (1%) for the lidocaine group. Although more articaine patients than lidocaine patients were believed by the investigators to have drug-related symptoms, in five cases (four with articaine, one with lidocaine), the symptoms did not begin on the day of study drug administration, suggesting that they were caused by the (dental) procedure rather than the anesthetic.

In cases for which resolution dates were available, it was determined that the duration of these events was less than 1 day to 18 days after the procedure. In all cases, the paresthesia ultimately resolved.

McCarthy⁵⁶ and Orr⁵⁷ have recommended the following time-honored sequence in managing the patient with a persistent sensory deficit after local anesthesia:

1. Be reassuring. The patient usually telephones the office the day after the dental procedure complaining that some area of the mouth is still “numb.”
 - a. Speak with the patient personally. Do not relegate the duty to an auxiliary. Remember that if patients cannot get through to speak to their doctor, they can always get the doctor’s attention through litigation.
 - b. Explain that paresthesia is not uncommon after local anesthetic administration. Sisk et al.⁵⁸ reported that paresthesia may develop in up to 22% of patients in very select circumstances.
 - c. Arrange an appointment to examine the patient.
 - d. Record the incident in the dental record. Thorough record keeping can be of paramount importance in the event of litigation.
2. Examine the patient in person.
 - a. Determine the degree and extent of paresthesia.
 - b. Explain to the patient that paresthesia normally persists for at least 2 months before resolution begins, and that it may last up to a year or longer.
 - c. “Tincture of time” (e.g., observation) is the recommended treatment, although microneurosurgery might, in some instances, be considered as an option,

regarding which Pogrel writes: “Although surgical correction is available in some cases, the results are suboptimal.”

- d. Record all findings in the patient’s record using the patient’s own descriptors, such as “hot,” “cold,” “painful,” “tingling,” “increasing,” “decreasing,” and “staying the same.”
 - e. Suggest that simple observation for 1 to 2 months is recommended, but on that same day offer to send the patient for a second opinion to an oral and maxillofacial surgeon, who will be able to map out the affected area and will be able to perform the surgical repair, if that is deemed necessary.
 - f. If surgical repair is suggested by this first consultant, a second opinion should be obtained from another oral and maxillofacial surgeon. It is generally deemed appropriate to observe the situation for minimally 1 to 2 months before considering the surgical option although Pogrel has stated “the chances of a good result may be better if surgery is performed early after the nerve injury, preferably within 10 weeks.”⁶⁰
3. Reschedule the patient for examination every 2 months for as long as the sensory deficit persists.
 4. Dental treatment may continue—if both the doctor and the patient are comfortable doing so—but administration of local anesthetic into the region of the previously traumatized nerve should be avoided. Alternative local anesthetic techniques should be used if possible.
 5. It would be advisable to contact your liability insurance carrier should the paresthesia persist without evident resolution beyond 1 to 2 months.

Facial Nerve Paralysis

The seventh cranial nerve carries motor impulses to the muscles of facial expression, of the scalp and external ear, and of other structures. Paralysis of some of its terminal branches occurs whenever an infraorbital nerve block is administered, or when maxillary canines are infiltrated. Muscle droop is also observed when, occasionally, motor fibers are anesthetized by inadvertent deposition of local anesthetic into their vicinity. This may occur when anesthetic is introduced into the deep lobe of the parotid gland, through which terminal portions of the facial nerve extend (Fig. 17.7).

The facial nerve branches and the muscles they innervate are as follows:

1. temporal branches
 - a. frontalis
 - b. orbicularis oculi
 - c. corrugator supercilii
2. zygomatic branches
 - a. orbicularis oculi
3. buccal branches: supplying the region inferior to the eye and around the mouth
 - a. procerus
 - b. zygomaticus

- c. levator labii superioris
 - d. buccinator
 - e. orbicularis oris
4. mandibular branch: supplying muscles of the lower lip and chin
 - a. depressor anguli oris
 - b. depressor labii inferioris
 - c. mentalis

Cause

Transient facial nerve paralysis is commonly caused by the introduction of local anesthetic into the capsule of the parotid gland, which is located at the posterior border of the mandibular ramus, clothed by the medial pterygoid and masseter muscles.^{36,58,61-63} Directing the needle posteriorly or inadvertently deflecting it in a posterior direction during an IANB, or overinsertion during a Vazirani-Akinosi nerve block, may place the tip of the needle within the body of the parotid gland. If local anesthetic is deposited, transient paralysis can result. The duration of the paralysis will equal that of the soft tissue anesthesia associated with the drug.

Problem

Loss of motor function to the muscles of facial expression produced by local anesthetic deposition is normally transitory. It lasts no longer than several hours, depending on the local anesthetic formulation used, the volume injected, and proximity to the facial nerve. Usually, minimal or no sensory loss occurs.

During this time the patient has unilateral paralysis and is unable to use these muscles (see Fig. 17.8). The primary problem associated with transient facial nerve paralysis is cosmetic: the person’s face appears lopsided. No treatment is known, other than waiting for resolution of the drug’s effect.

A secondary problem is that the patient is unable to voluntarily close one eye. The protective lid reflex of the eye is abolished. Winking and blinking become impossible. The cornea, however, does retain its innervation; thus if it is irritated, the corneal reflex is intact, and tears lubricate the eye.

Prevention

Transient facial nerve paralysis is almost always preventable by adhering to protocol with the IANB and the Vazirani-Akinosi nerve block (as described in Chapter 14), although in some situations, branches of the facial nerve may lie close to the site of local anesthetic deposition in the IANB and the Vazirani-Akinosi nerve block.

A needle tip that comes in contact with bone (medial aspect of the ramus) before depositing local anesthetic solution essentially precludes the possibility that anesthetic will be deposited into the body of the parotid gland during an IANB. If the needle deflects posteriorly during this nerve block and bone is not contacted, the needle should



• **Fig. 17.8** Facial nerve paralysis. Inability to close eyelid (A) and drooping of lip on affected side (patient's left) (B).

be withdrawn almost entirely from the soft tissues, the barrel of the syringe brought posteriorly (thereby directing the needle tip more anteriorly), and the needle readvanced until it contacts bone.

Because no contact is made with bone during the Vazirani-Akinosi nerve block, overinsertion of the needle, either absolute (>25 mm) or relative (25 mm in a smaller patient), should be avoided, if possible.

Management

Within seconds to minutes after deposition of local anesthetic into the parotid gland, the patient senses weakening of the muscles on the affected side of the face. Sensory anesthesia is not present in this situation. Management includes the following:

1. Reassure the patient. Explain that the situation is transient, lasting several hours, and will resolve without residual effect. Mention that it is produced by the normal action of local anesthetic drugs on the facial nerve, which is a motor nerve to the muscles of facial expression.
2. Contact lenses should be removed until muscular movement returns.
3. An eye patch should be applied to the affected eye until muscle tone returns. If resistance is offered by the patient, advise the patient to manually close the affected eyelid periodically to keep the cornea lubricated.
4. Record the incident in the patient's record.
5. Although no contraindication is known to reinjecting the patient to achieve mandibular anesthesia, it may be prudent to forego further dental care in the affected quadrant at this appointment.

Ocular Complications

Following injection, local anesthetics diffuse in all directions along a concentration gradient. For injection in the oral

TABLE 17.5 Ocular Complications Associated With Intraoral Local Anesthetic Administration

Amaurosis
Blindness
Diplopia (double vision)
Endophthalmitis
Globe penetration
Horner syndrome (blepharoptosis, miosis, anhidrosis, hemifacial flushing, conjunctival injection and enophthalmos)
Impaired visual acuity (double vision)
Mydriasis (dilation of the pupil)
Ophthalmoplegia (internal or external, partial or total)
Ptosis
Strabismus (convergent or divergent)

From Alamanos C, Raab P, Gamulescu A, Behr M. Ophthalmologic complications after administration of local anesthesia in dentistry: a systematic review. *Oral Surg Oral Med Oral Pathol Oral Radiol.* 2016;121:e39–e350.

cavity our desired goal is for the local anesthetic to diffuse into and block nerve conduction from the site of deposition to the brain. The eyes are located relatively close to the mouth, specifically the maxilla, and the diffusing local anesthetic can, on rare occasion, affect the function of nerves around the eyes, producing ocular complications.

Alamanos et al.⁶⁴ in a systematic review reported on 89 cases of ocular complications associated with intraoral injection of local anesthetics. Reviewing literature from 1954 to 2013, they found 65 case reports and one case series (24 cases) for a total of 89 reports of ocular complications following intraoral dental injections. These ocular complications are listed in Table 17.5. Ninety-two percent of the complications were transient. The time for the resolution of a transient ocular complication was more than 6 hours in 25% of the patients. The remainder of the transient cases resolved spontaneously more quickly. Four

of the six patients with permanent complications (8%) developed vision impairment (permanent damage of the optic pathway).⁶⁴ Two patients and the author also developed an isolated fixed pupil (iridoplegia) that manifested itself clinically as anisocoria (unequal pupil size). Complete permanent blindness had not been reported in the reviewed data.⁶⁴ In their review of the anesthetic techniques used, Alamanos et al.⁶⁴ reported that the Gow-Gates mandibular nerve block was associated with only diplopia, whereas vision impairment was associated more often with IANBs than with PSA nerve blocks. The distribution of ocular complications by arch was 46 following maxillary injection and 42 following mandibular injection. The drug most frequently administered when ocular complications occurred was “by far” lidocaine (also the most used local anesthetic in dentistry). There are reports in the literature of permanent^{65,66} and transient blindness^{67,68} occurring subsequent to dental local anesthetic injections.

Anatomic Basis of Ocular Complications

1. Diffusion of the anesthetic drug through myofascial spaces or bony openings. Sved et al.⁶⁹ reported a high incidence of diplopia (35.6%) after second division trigeminal blocks (V2) via the greater palatine canal approach. They assumed that the anesthetic solution diffuses through the inferior orbital fissure to affect the extraocular muscles. Ocular complications following mandibular injections were theorized to be a result of the local anesthetic solution being deposited into the area of the upper cervical or stellate ganglia.
2. Inadvertent intraarterial injection of the local anesthetic. Although felt by this author to be highly improbable—as arteries have muscular walls that respond to stimulation by going into spasm—it has been theorized that the combination of an intra-arterial injection and an anatomic variation of the internal maxillary and middle meningeal arteries may direct the anesthetic solution to the ophthalmic artery and from there to the central retinal artery. The vasoconstrictor could then interrupt the blood supply to the retina, resulting in visual phenomena (phosphenes) or blindness, depending on the duration and the degree of vasoconstriction.⁷⁰ Alamanos et al.⁶⁴ posit that an intra-arterial route of the anesthetic solution could cause systemic symptoms, skin and mucosal blanching, sensory deficits, vision loss, and parasympathetic denervation.
3. Inadvertent intravenous injection of the local anesthetic.
4. Direct trauma (“scraping”) of the periarterial sympathetic plexus. Such trauma sets up a sympathetic impulse that travels to the orbit. This impulse may account for the transient irradiating pain that can sometimes be experienced during an injection and for the blanching of the skin or mucosa.

Management of Ocular Complications

Each case involving an ocular complication following intraoral local anesthetic administration should be evaluated individually.⁶⁴ It is recommended that consultation with an ophthalmologist be obtained whenever there is uncertainty as to the cause.

The data reviewed by Alamanos et al.⁶⁴ showed that diplopia and strabismus always have a transient character and that 75% of the cases resolve within 6 hours. Therefore in conditions such as convergent strabismus or binocular diplopia, at least until the anesthetic effect resolves, a “wait and observe” approach is recommended; supportive measures, such as patient reassurance and patching of the affected eye, should be undertaken, as monocular vision is devoid of distance-judging capability, making it more dangerous for the patient to operate a motor vehicle.⁶⁴

Trismus

Trismus, from the Greek *trismos*, is defined as a prolonged, tetanic spasm of the jaw muscles by which the normal opening of the mouth is restricted (locked jaw). This designation was originally used only in tetanus, but because an inability to open the mouth may be seen in a variety of other conditions, the term is currently used in restricted jaw movement, regardless of the cause.⁷¹ Although postinjection pain is the most common local complication of local anesthesia, trismus can become one of the more chronic and complicated problems to manage.⁷²⁻⁷⁴

Causes

Trauma to muscles or blood vessels in the infratemporal fossa is the most common causative factor in trismus associated with dental injection of local anesthetics.

Local anesthetic solutions into which alcohol or cold sterilizing solutions have diffused produce irritation of tissues (e.g., muscle), potentially leading to trismus. Local anesthetics have been demonstrated to be slightly myotoxic to skeletal muscles, especially considering the highly acidic pH of solutions containing a vasoconstrictor (pH ~3.5 to 4.4). The injection of local anesthetic solution intramuscularly or supramuscularly leads to a rapidly progressive necrosis of exposed muscle fibers.⁷⁵⁻⁷⁷

Hemorrhage is another cause of trismus. Large volumes of extravascular blood can produce tissue irritation, leading to muscle dysfunction as the blood is slowly resorbed (over approximately 2 weeks). Low-grade infection after injection can also cause trismus.⁷⁸

Every needle insertion produces some damage to the tissue through which it passes. It stands to reason, then, that multiple needle penetrations correlate with a greater incidence of postinjection trismus. In addition, Stacy and Hajjar⁷⁹ found that of 100 needles used for the administration of IANB, 60% were barbed on removal from the tissues. The barb occurred when the needle came into contact with the medial aspect of the mandibular ramus.

Withdrawal of the needle from tissue increased the likelihood of involvement of the lingual or inferior alveolar nerve (e.g., paresthesia and numbness).

Excessive volumes of local anesthetic solution deposited into a restricted area produce distention of tissues, which may lead to postinjection trismus. This is more common after multiple missed IANBs.

Problem

Although the limitation of movement associated with postinjection trismus is usually minor, it is possible for much more severe limitation to develop. The average interincisal opening in cases of trismus is 13.7 mm (range, 5 to 23 mm).⁷⁶ The average normal interincisal opening for males is 44.8 (± 9.4) mm and for females is 39.2 (± 10.8) mm.⁸⁰ Stone and Kaban⁸¹ reported four cases of severe trismus after multiple IANBs or PSA nerve blocks, three of which required surgical intervention. Before surgery, patients had limited mandibular openings of approximately 2 mm, despite usual treatment regimens.

In the acute phase of trismus, pain produced by hemorrhage leads to muscle spasm and limitation of movement.^{82,83} The second, or chronic, phase usually develops if treatment is not begun. Chronic hypomobility occurs secondary to organization of the hematoma, with subsequent fibrosis and scar contraction.⁸⁴ Infection may produce hypomobility through increased pain, increased tissue reaction (irritation), and scarring.⁷⁸

Prevention

1. Use a sharp, sterile, disposable needle.
2. Properly care for and handle dental local anesthetic cartridges.
3. Use an aseptic technique. Contaminated needles should be changed immediately.
4. Practice the atraumatic insertion and injection technique.
5. Avoid repeated injections and multiple insertions into the same area by gaining knowledge of anatomy and proper technique. Use regional nerve blocks instead of local infiltration (supraperiosteal injection) wherever possible and rational.
6. Use minimum effective volumes of local anesthetic. Refer to specific technique protocols for recommendations. (Chapters 13-15)

Trismus is not always preventable.

Management

In most instances of trismus the patient reports pain and some difficulty opening his or her mouth on the day *after* dental treatment in which a PSA nerve block or, more commonly, an IANB was administered. Hinton et al.⁷⁶ reported that the onset of trismus occurred 1 to 6 days after treatment (average, 2.9 days). The degree of discomfort and dysfunction differs but is usually mild.

With mild pain and dysfunction, the patient reports minimum difficulty opening his or her mouth. Arrange

an appointment for examination. In the interim, prescribe heat therapy, warm saline rinses, analgesics, and, if necessary, muscle relaxants to manage the initial phase of muscle spasm.^{85,86} Heat therapy consists of applying hot, moist towels to the affected area for approximately 20 minutes every hour. For a warm saline rinse, a teaspoon of salt is added to a 12-ounce glass of warm water; the rinse is held in the mouth on the involved side (and spit out) to help relieve the discomfort of trismus. Orally administered aspirin (325 mg) or ibuprofen (600 mg) is usually adequate as an analgesic in managing pain associated with trismus. Their antiinflammatory properties are also beneficial. Diazepam (approximately 10 mg twice daily) or another benzodiazepine is used for muscle relaxation if deemed necessary.

The patient should be advised to initiate physiotherapy consisting of opening and closing the mouth, as well as lateral excursions of the mandible, for 5 minutes every 3 to 4 hours. Chewing gum (sugarless, of course!) is yet another means of providing lateral movement of the temporomandibular joint.

Record the incident, findings, and treatment in the patient's dental record. Avoid further dental treatment in the involved region until symptoms resolve and the patient is more comfortable.

If continued dental care in the area is urgent, as with a painful infected tooth, it may prove difficult to achieve effective pain control when trismus is present. The Vazirani-Akinosi mandibular nerve block usually provides relief of the motor dysfunction, permitting the patient to open his or her mouth, allowing administration of the appropriate injection for clinical pain control, if needed.

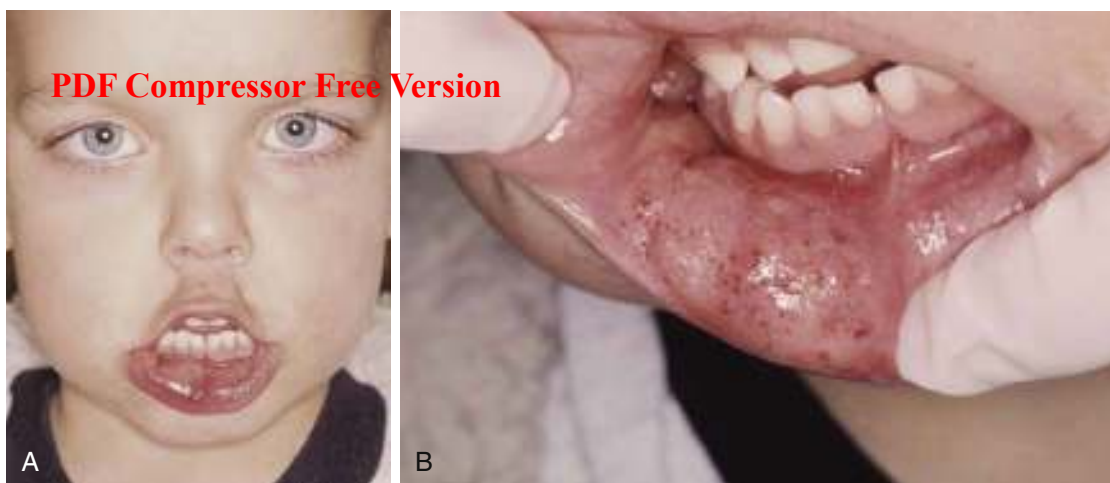
In virtually all cases of trismus related to intraoral injections that are managed as described, patients report improvement of their condition within 48 to 72 hours. Therapy should be continued until the patient is symptom free. If pain and dysfunction continue unabated beyond 48 hours, consider the possibility of infection. Antibiotics should be added to the treatment regimen described and their use should be continued for 7 days. Complete recovery from injection-related trismus takes about 6 weeks (range, 4 to 20 weeks).⁷⁶

For severe pain or dysfunction, if no resolution is noted within 2 or 3 days without antibiotics or within 5 to 7 days with antibiotics, or if the ability to open the mouth has become limited, the patient should be referred to an oral and maxillofacial surgeon for evaluation. Other therapies, including the use of ultrasound or appliances, are available for use in these situations.^{87,88}

Temporomandibular joint involvement is rare in the first 4 to 6 weeks after injection. Surgical intervention to correct chronic dysfunction may be indicated in some instances.^{76,81}

Soft Tissue Injury

Self-inflicted trauma to the lips and tongue is frequently caused by the patient inadvertently biting or chewing these tissues while still anesthetized (see Fig. 17.9).



• **Fig. 17.9** Traumatized lip caused by inadvertent biting while it was still anesthetized.

Cause

Trauma occurs most frequently in younger children, in mentally or physically disabled children or adults, and in older-old patients (older than 85 years); however, it occurs in patients of all ages. The primary reason is that soft tissue anesthesia lasts significantly longer than does pulpal anesthesia. Dental patients receiving local anesthetic during their treatment are usually dismissed from the dental office with residual soft tissue numbness. (See the discussion in [Chapter 20](#) of phentolamine mesylate, the local anesthesia reversal agent.)

Problem

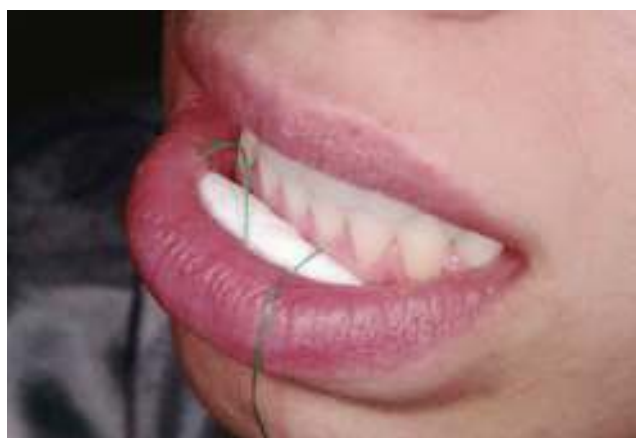Trauma to anesthetized tissues can lead to swelling and significant pain when the anesthetic effects resolve. A young child or a handicapped individual may have difficulty coping with the situation, and this may lead to behavioral problems. The possibility that infection will develop is remote in most instances.

Prevention

A local anesthetic of appropriate duration should be selected if dental appointments are brief. (Refer to the discussion of lip chewing and duration of anesthesia for specific drugs, p. 296.)

A cotton roll can be placed in the buccal or labial fold between the lips and the teeth if they are still anesthetized at the time of discharge. The cotton roll is secured with dental floss wrapped around the teeth (to prevent inadvertent aspiration of the roll) ([Fig. 17.10](#)).

Warn the patient and the guardian against eating, drinking hot fluids, and biting of the lips or tongue to test for anesthesia. A self-adherent warning sticker may be used for children ([Fig. 17.11](#)).



• **Fig. 17.10** Cotton roll placed between lips and teeth, secured with dental floss, minimizes the risk of accidental mechanical trauma to anesthetized tissues.



• **Fig. 17.11** Self-adherent warning sticker to help prevent accidental trauma to anesthetized tissues in children.

Management

Management of the hematoma is self-limiting. Tissue injury secondary to lip or tongue biting or chewing is symptomatic:

1. analgesics (e.g., age-appropriate dose of ibuprofen) for pain, as necessary;
2. antibiotics, as necessary, in the unlikely situation that infection results;
3. lukewarm saline rinses to aid in decreasing any swelling that may be present;
4. petroleum jelly or other lubricant to cover a lip lesion and minimize irritation.

Hematoma

The effusion of blood into extravascular spaces can be caused by inadvertent nicking of a blood vessel (artery or vein) during administration of a local anesthetic. A hematoma that develops subsequent to nicking of an artery usually increases rapidly in size until management is instituted because of the significantly greater pressure of blood within an artery. Nicking of a vein may or may not result in the formation of a hematoma. Tissue density surrounding the injured vessel is a determining factor. The denser the surrounding tissues (e.g., palate), the less likely a hematoma is to develop, but in looser tissue (e.g., infratemporal fossa), large volumes of blood may amass before a swelling is ever noted and therapy instituted, as is commonly the case when a hematoma develops following a PSA nerve block.

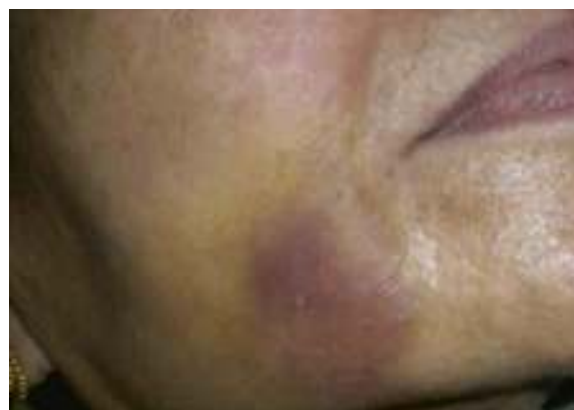Cause

Because of the density of tissue in the hard palate and its firm adherence to bone, a hematoma rarely develops after a palatal injection. A rather large hematoma may result from arterial or venous puncture after a PSA nerve block or an IANB. The tissues surrounding these vessels more readily accommodate significant volumes of blood. The blood effuses from vessels until extravascular pressure exceeds intravascular pressure, or until clotting occurs. Hematomas that occur after the IANB are usually visible only intraorally, whereas hematomas that occur after the PSA nerve block are visible extraorally (Fig. 17.12).

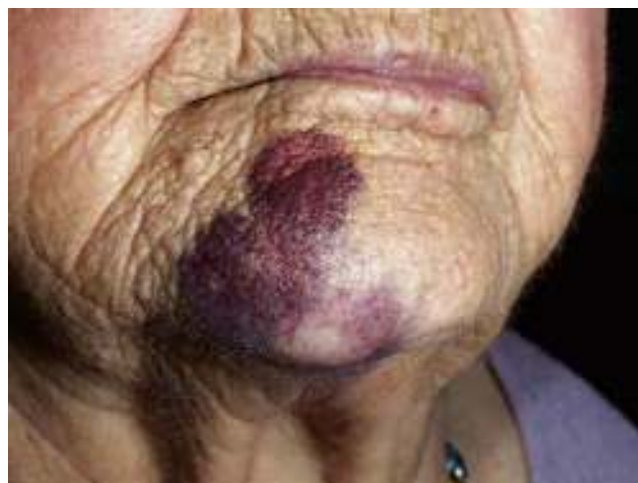Problem

A hematoma rarely produces significant problems, aside from the resulting “bruise,” which may or may not be visible extraorally. Possible complications of hematoma include trismus and pain. Swelling and discoloration of the region usually subside gradually, with complete resolution occurring between 7 and 21 days.

A hematoma constitutes an inconvenience to the patient and an embarrassment to the person administering the drug (Figs. 17.12 and 17.13).



• Fig. 17.12 Hematoma following posterior superior alveolar nerve block.



• Fig. 17.13 Hematoma that developed after mental nerve block.

Prevention

1. Knowledge of the normal anatomy involved in the proposed injection is important, although keep in mind that “normal” anatomy may differ considerably from patient to patient. Certain techniques are associated with a greater risk of a visible hematoma. The PSA nerve block is the most common, followed by the mental/incisive nerve block and the IANB.
2. Modify the injection technique as dictated by the patient’s anatomy. For example, the depth of penetration for a PSA nerve block may be decreased in a patient with smaller facial characteristics.^{89,90}
3. Use a short needle (27-gauge short needle is recommended) for the PSA nerve block to decrease the risk of hematoma that is commonly a result of needle over-insertion.
4. Minimize the number of needle penetrations into tissue.
5. Never use a needle as a probe in tissues.

Hematoma is not always preventable. Whenever a needle is inserted into tissue, the risk of inadvertent puncturing of a blood vessel is present.

Management

Immediate **PDF Compressor Free Version**

When swelling becomes evident during or immediately after a local anesthetic injection, direct pressure should be applied to the site of bleeding. No discoloration will be seen at the onset of a hematoma as the blood is relatively deep within the soft tissues. For most injections the blood vessel is located between the surface of the mucous membrane and the bone; localized pressure should be applied for a minimum of 2 minutes. This effectively stops the bleeding.

Inferior Alveolar Nerve Block

Pressure is applied to the medial aspect of the mandibular ramus. Clinical manifestations of the hematoma, which are visible intraorally, include possible tissue discoloration and probable tissue swelling on the medial (lingual) aspect of the mandibular ramus.

Anterior Superior Alveolar (Infraorbital) Nerve Block

Pressure is applied to the skin directly over the infraorbital foramen. The immediate clinical manifestation is development of a soft tissue “lump” below the lower eyelid. Discoloration will develop with several hours. Hematoma is unlikely to occur when the technique for anterior superior alveolar nerve block described in [Chapter 13](#) is used, as the application of pressure at the injection site throughout drug administration and for a period of at least 1 to 2 minutes thereafter is recommended.

Incisive (Mental) Nerve Block

Pressure is placed directly over the mental foramen, externally on the skin or intraorally on the mucous membrane. The initial clinical manifestation is an almost immediate swelling in the mucobuccal fold in the region of the mental foramen, followed in several hours by discoloration of the skin of the chin in the area of the mental foramen (see [Fig. 17.13](#)). As with the anterior superior alveolar nerve block, pressure applied during administration of the drug and for a minimum of 1 to 2 minutes following administration effectively minimizes the risk of hematoma formation during incisive (but not mental) nerve block.

Buccal Nerve Block or Any Palatal Injection

Place pressure at the site of bleeding. In these injections the clinical manifestations of hematoma are usually visible only within the mouth.

Posterior Superior Alveolar Nerve Block

The PSA nerve block usually produces the largest and most esthetically unappealing hematoma. The infratemporal fossa, into which bleeding occurs, can accommodate a large volume of blood. The hematoma is usually not recognized until a colorless swelling appears on the side of the face around the temporomandibular joint area (usually a few minutes after the injection is completed). It progresses over

a period of days, extending inferiorly and anteriorly toward the lower anterior region of the cheek. It is difficult to apply pressure to the site of bleeding in this situation because of the location of the involved blood vessels. It is also relatively difficult to apply pressure directly to the PSA artery (the primary source of bleeding), the facial artery, and the pterygoid plexus of veins. They are located posterior, superior, and medial to the maxillary tuberosity. Bleeding normally ceases when external pressure on the vessels exceeds internal pressure, or when clotting occurs. Digital pressure can be applied to the soft tissues in the mucobuccal fold as far distally as can be tolerated by the patient (without eliciting a gag reflex). Apply pressure in a medial and superior direction. If available, ice should be applied (extraorally) to increase pressure on the site and help to constrict the punctured vessel.

Subsequent

The patient may be discharged once bleeding stops. Inscribe a note concerning the hematoma in the patient's dental record. Advise the patient about possible soreness and limitation of movement (trismus). If either of these develops, begin treatment as described for trismus. Discoloration will likely occur as a result of extravascular blood elements; it is gradually resorbed over 7 to 21 days.

If soreness develops, advise the patient to take an analgesic such as aspirin or another nonsteroidal antiinflammatory drug. Do not apply heat to the area for at least 4 to 6 hours after the incident. Heat produces vasodilation, which may further increase the size of the hematoma if applied too soon. Heat may be applied to the region beginning the next day. It serves as an analgesic, and its vasodilating properties may increase the rate at which blood elements are resorbed, although the latter benefit is debatable. The patient should apply moist heat to the affected area for 20 minutes every hour.

Ice may be applied to the region immediately on recognition of a developing hematoma. Ice acts as both an analgesic and a vasoconstrictor, and it may aid in minimizing the size of the hematoma. Time (tincture of time) is the most important element in managing a hematoma. With or without treatment a hematoma will be present for 7 to 21 days. Avoid additional dental therapy in the region until symptoms and signs resolve.

Pain on Injection

Pain on injection of a local anesthetic can best be prevented through careful adherence to the basic protocol of atraumatic injection (see [Chapter 11](#)).

Causes

1. Careless injection technique and a callous attitude (“Palatal injections always hurt” or “This will hurt a little”) all too often become self-fulfilling prophecies.
2. A needle can become dull following multiple insertions.

3. Rapid deposition of the local anesthetic solution is more uncomfortable than slow deposition and may cause tissue damage. **PDF Compressor Free Version**
4. Needles with barbs (from impaling bone) may produce pain as they are withdrawn from tissue.⁷⁹

Problem

Pain on injection increases patient anxiety and may lead to sudden unexpected movement, increasing the risk of needle breakage, traumatic soft tissue injury to the patient, or needlestick injury to the administrator.

Prevention

1. Adhere to proper techniques of injection, both anatomic and psychological.
2. Use sharp needles.
3. Use topical anesthetic properly before injection.
4. Use sterile local anesthetic solutions.
5. Inject local anesthetics slowly. The ideal rate is 1.0 mL per minute; the recommended rate is 1.8 mL or a 2.2-mL cartridge over 1 minute.
6. Make certain that the temperature of the solution is correct. A solution that is too hot or too cold may be more uncomfortable than one at room temperature.
7. Buffered local anesthetics, at a pH of approximately 7.4, have been demonstrated to be more comfortable on administration.⁹⁰⁻⁹² Buffering of local anesthetics is discussed further in [Chapter 20](#).

Management

No management is necessary. However, steps should be taken to prevent the recurrence of pain associated with the injection of local anesthetics.

Burning on Injection

Causes

A burning sensation that occurs during injection of a local anesthetic is not uncommon. Several potential causes are known.

The primary cause of a mild burning sensation is the pH of the solution being deposited into the soft tissues. The pH of “plain” local anesthetics (i.e., no vasopressor included) is approximately 6.5, whereas solutions that contain a vasopressor are considerably more acidic (around 3.5 to 4.5). Wahl et al.⁹³ compared the pain on injection of plain prilocaine versus lidocaine with epinephrine (1:100,000) and found no statistical difference in patient perception; however, when bupivacaine with epinephrine (1:200,000) was compared with plain prilocaine, significantly more pain was reported by patients receiving bupivacaine.⁹⁴

Rapid injection of local anesthetic, especially in the denser, more adherent tissues of the palate, produces a burning sensation.

Contamination of local anesthetic cartridges can result when they are stored in alcohol or other sterilizing solutions, leading to diffusion of these solutions into the cartridge. Cartridges stored in cartridge warmers (warmed to normal body temperature) are usually considered “too hot” by the patient.

Problem

Although usually transient, the sensation of burning on injection of a local anesthetic indicates that tissue irritation or damage is occurring. If this is caused by the pH of the solution, it rapidly disappears as the anesthetic action develops. Usually no residual sensitivity is noted when the anesthetic action ends.

When a burning sensation occurs as a result of rapid injection, a contaminated solution, or an overly warm solution, the likelihood that tissue may be damaged is greater, and subsequent complications, such as postanesthetic trismus, edema, or possible paresthesia, are reported.

Prevention

By buffering the local anesthetic solution to a pH of approximately 7.4 immediately before administration, it is possible to eliminate the burning sensation that some patients experience during injection of a local anesthetic solution containing a vasopressor.⁹⁰⁻⁹²

Slowing the speed of injection also helps. The ideal rate of injectable drug administration is 1 mL per minute. Do not exceed the recommended rate of 1.8 mL per minute.

The cartridge of anesthetic should be stored at room temperature in the container (blister pack or tin) in which it was shipped, or in a suitable container without alcohol or other sterilizing agents. (See [Chapter 7](#) for proper care and handling of dental cartridges.)

Management

Because most instances of burning on injection are transient and do not lead to prolonged tissue involvement, formal treatment is usually not indicated. In those few situations in which postinjection discomfort, edema, or paresthesia becomes evident, management of the specific problem is indicated.

Infection

Infection subsequent to local anesthetic administration in dentistry is an extremely rare occurrence since the introduction of single-use sterile needles and glass cartridges.

Causes

The major cause of postinjection infection is contamination of the needle before administration of the anesthetic. Contamination of a needle always occurs when the needle

touches mucous membrane in the oral cavity. This cannot be prevented, nor is it a significant problem because the normal bacterial flora of the oral cavity is not a source of tissue infection.

Improper technique in the handling of local anesthetic equipment and improper tissue preparation for injection are other possible causes of infection.

Injecting Local Anesthetic Solution Into an Area of Infection

As discussed in the section on local anesthetic requirements in endodontics in Chapter 16, local anesthetics are considerably less effective when injected into infected tissues. However, if they are deposited under pressure, as in the periodontal ligament injection, the force of their administration might transport bacteria into adjacent, healthy tissues, thereby spreading infection.

Problem

Contamination of needles or solutions may cause a low-grade infection when the needle or solution is placed in deeper tissue. This may lead to trismus if it is not recognized and proper treatment is not initiated.⁶¹

Prevention

1. Use sterile disposable needles.
2. Proper care and handling of needles. Take precautions to avoid contamination of the needle through contact with nonsterile surfaces; avoid multiple injections with the same needle, if possible.
3. Proper care and handling of local anesthetic cartridges.
 - a. Use a cartridge only once (one patient).
 - b. Store cartridges aseptically in their original container, covered at all times.
 - c. Cleanse the diaphragm with a sterile disposable alcohol wipe immediately before use if considered necessary.
4. Properly prepare the tissues before penetration. Dry them and apply topical antiseptic (optional).

Management

Low-grade infection, which is rare, is seldom recognized immediately. The patient usually reports postinjection pain and dysfunction (e.g., trismus) 1 day or more after their dental treatment. Overt signs and symptoms of infection occur rarely. Immediate treatment consists of those procedures used to manage trismus: heat and analgesic if needed, muscle relaxant if needed, and physiotherapy. Trismus produced by factors other than infection normally responds with resolution or reduction within several days. If signs and symptoms of trismus do not begin to respond to conservative therapy within 3 days, the possibility of a low-grade infection should be entertained and a 7- to 10-day course of antibiotic therapy should be started. Prescribe 29 (or 41, if 10 days) tablets of penicillin V (250-mg tablets).

The patient takes 500 mg immediately and then 250 mg four times a day until all tablets have been taken. Erythromycin may be substituted if the patient is allergic to penicillin.

Record the progress and management of the patient in the dental record.

Edema

Swelling of tissues is not a syndrome but it is a clinical sign of the presence of some disorder.

Causes

1. Trauma during injection.
2. Infection.
3. Allergy: angioedema is a possible response to ester-type topical anesthetics in an allergic patient (localized tissue swelling occurs as a result of vasodilation secondary to histamine release).
4. Hemorrhage (effusion of blood into soft tissues produces swelling).
5. Injection of irritating solutions (alcohol-containing cartridges or cold sterilizing solution-containing cartridges).
6. *Hereditary angioedema* is a condition characterized by the sudden onset of brawny nonpitting edema affecting the face, extremities, and mucosal surfaces of the intestine and respiratory tract, often without obvious precipitating factors. Tissue manipulation within the oral cavity, including local anesthetic administration, may precipitate an attack. Lips, eyelids, and the tongue are often involved.⁹⁵ Karlis et al.⁹⁶ noted that 15% to 33% of untreated angioedema patients died of acute airway obstruction as a result of laryngeal edema.

Problem

Edema related to local anesthetic administration is seldom of sufficient intensity to produce significant problems such as airway obstruction. Most instances of local anesthetic-related edema result in pain and dysfunction of the region and embarrassment for the patient.

Angioneurotic edema produced by a topical anesthetic in an allergic individual, although exceedingly rare, can compromise the airway. Edema of the tongue, pharynx, or larynx may develop, and is a potentially life-threatening situation that requires vigorous management (including activation of emergency medical services).⁹⁷

Prevention

1. Proper care and handling of the local anesthetic armamentarium.
2. Use atraumatic injection technique.
3. Complete an adequate medical evaluation of the patient before drug administration.

Management

The management of edema is aimed at reducing the swelling as quickly as possible and on the cause of the edema. When produced by traumatic injection or by introduction of irritating solutions, edema is usually of minimal degree and resolves in several days without formal therapy. In this and all situations in which edema is present, it may be necessary to prescribe analgesics for management of pain.

After hemorrhage, edema resolves more slowly (over 7 to 21 days) as extravasated blood elements are resorbed into the vascular system. If signs of hemorrhage (e.g., bluish discoloration progressing to green, yellow, and other colors) are evident, management follows that previously discussed for hematoma.

Edema produced by infection does not resolve spontaneously but may become progressively more intense if untreated. If signs and symptoms of infection (pain, mandibular dysfunction, edema, warmth) do not appear to resolve within 3 days, antibiotic therapy should be instituted as outlined previously.

Allergy-induced edema is potentially life threatening. Its degree and location are highly significant. If swelling develops in buccal soft tissues and there is absolutely no airway involvement, treatment consists of immediate intramuscular injection (in the vastus lateralis muscle) of 50 mg (adult) or 25 mg (child up to 30 kg) followed by a 3-day course of oral histamine blocker therapy and consultation with an allergist to determine the precise cause of the edema.

If edema occurs in any area where it compromises breathing, treatment consists of the following:

1. P (position): if unconscious, the patient is placed supine.
2. C-A-B (circulation, airway, breathing): basic life support is administered, as needed.
3. D (definitive treatment): emergency medical services (e.g., 9-1-1) are summoned.
4. Epinephrine is administered: 0.3 mg (0.3 mL of a 1:1000 epinephrine solution) for weight greater than 30 kg, 0.15 mg (0.15 mL of a 1:1000 epinephrine solution) for weight between 15 and 30 kg, IM in the vastus lateralis every 5 minutes until respiratory distress resolves.
5. Histamine blocker is administered intramuscularly or intravenously.
6. Corticosteroid is administered intramuscularly or intravenously.
7. Preparation is made for cricothyrotomy if total airway obstruction appears to be developing. This is extremely rare but is the reason for summoning emergency medical services as quickly as possible.
8. The patient's condition is thoroughly evaluated before his or her next appointment to determine the cause of the reaction.

Sloughing of Tissues

Prolonged irritation or ischemia of gingival soft tissues may lead to a number of unpleasant complications, including epithelial desquamation and sterile abscess.

Causes

Epithelial Desquamation

1. Application of a topical anesthetic to the gingival tissues for a prolonged period
2. Heightened sensitivity of the tissues to either topical or injectable local anesthetic

Sterile Abscess

1. Secondary to prolonged ischemia resulting from the use of a local anesthetic with a vasoconstrictor (usually norepinephrine)
2. Usually develops on the hard palate

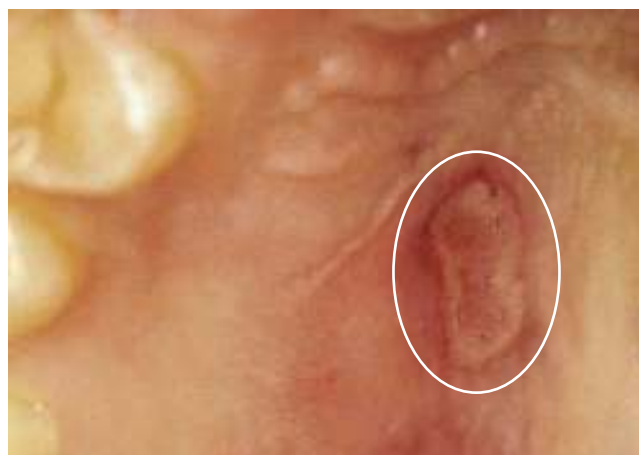Problem

Pain, at times severe, may be a consequence of epithelial desquamation or a sterile abscess. It is remotely possible that infection may develop in these areas.

Prevention

Use topical anesthetics as recommended. Allow the solution to contact the mucous membranes for 1 to 2 minutes to maximize its effectiveness and minimize toxicity.

When you are using vasoconstrictors for hemostasis, do not use overly concentrated solutions. Norepinephrine (Levophed) 1:30,000 is the agent most likely to produce ischemia of sufficient duration to cause tissue damage and a sterile abscess. Norepinephrine is not available in any dental local anesthetic solution in North America. Epinephrine (1:50,000) may also produce this problem if repeated injections of the solution occur whenever ischemia resolves, over a long period (e.g., several hours). The palatal tissues are likely the only place in the oral cavity where this phenomenon is likely to arise (Fig. 17.14).



• **Fig. 17.14** Sloughing of tissue on the palate (circle) caused by prolonged ischemia secondary to the use of a local anesthetic with a high concentration (1:50,000) of epinephrine.

Management

Usually no formal management is necessary. Epithelial desquamation or sterile abscess. Be certain to reassure the patient of this fact.

Management may be symptomatic. For pain, analgesics, such as aspirin or another nonsteroidal antiinflammatory drug and a topically applied ointment (triamcinolone ointment; Orabase), are recommended to minimize irritation to the area. Epithelial desquamation resolves within a few days; the course of a sterile abscess may run 7 to 10 days. Record data in the patient's record.

Postanesthetic Intraoral Lesions

Patients occasionally report that approximately 2 days after an intraoral injection of local anesthetic, ulcerations developed in their mouth, primarily around the site(s) of the injection(s). The primary initial symptom is pain, usually of a relatively intense nature.

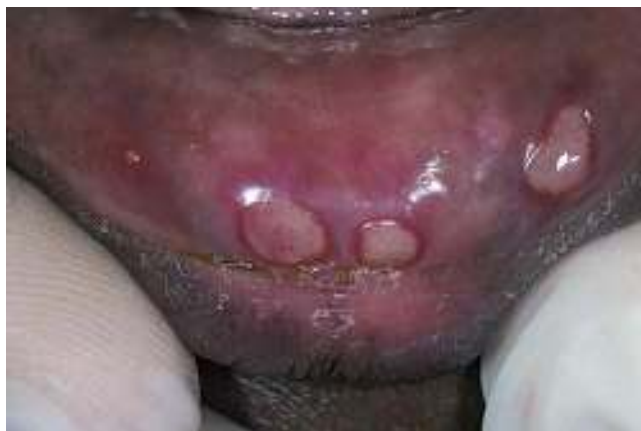Cause

Recurrent aphthous stomatitis or herpes simplex can occur intraorally after a local anesthetic injection or after any trauma to the intraoral tissues.

Recurrent aphthous stomatitis (recurrent aphthous ulceration) is the most common oral mucosal disease known in humans.⁹⁸ Recurrent aphthous stomatitis is more frequently observed than herpes simplex, typically developing on gingival tissues that are not attached to underlying bone (e.g., movable tissue), such as the buccal vestibule (Fig. 17.15).

Herpes simplex can develop intraorally, although more commonly it is observed extraorally. It is viral in origin and becomes manifest as small bumps on tissues that are attached to underlying bone (e.g., fixed) such as the soft tissue of the hard palate (Fig. 17.16).

Trauma to tissues caused by a needle, a local anesthetic solution, a cotton swab, or any other instrument (e.g.,



• **Fig. 17.15** Aphthous stomatitis. (From Eisen D, Lynch D. *The Mouth: Diagnosis and Treatment*. St Louis: Mosby; 1998.)

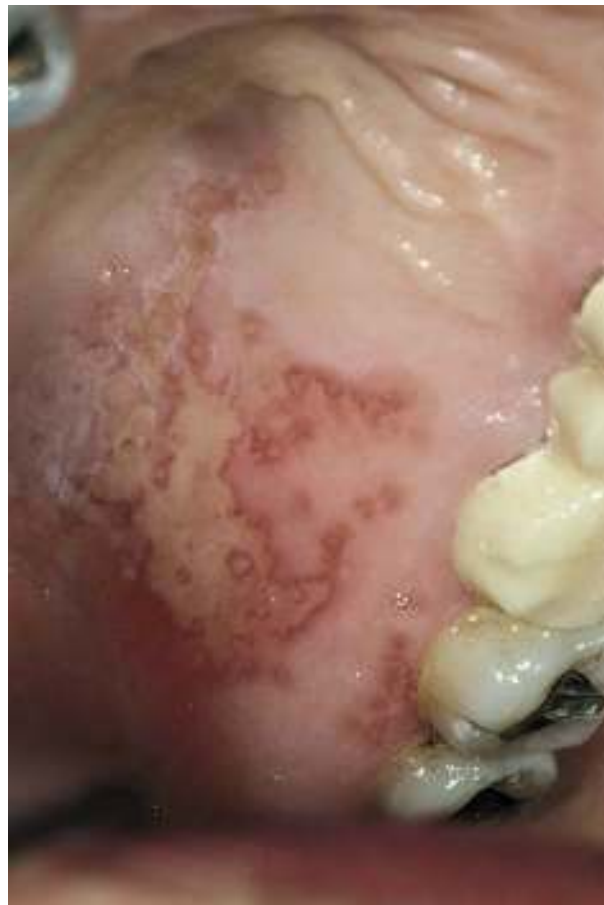rubber dam clamp, handpiece) may activate the latent form of the disease process that was present in the tissues before the injection.

Problem

The patient describes acute sensitivity in the ulcerated area and may consider that the tissue has become infected as a result of the local anesthetic injection they received; however, the risk of a secondary infection developing in this situation is minimal.

Prevention

Unfortunately there are no means of preventing these intraoral lesions from developing in susceptible patients. Extraoral herpes simplex, on occasion, may be prevented or its clinical manifestations minimized if it is treated in its prodromal phase. The prodrome consists of a mild burning or itching sensation at the site where the virus is present (e.g., lip). Antiviral agents, such as acyclovir, applied four times daily to the affected area may effectively minimize the acute phase of this process.



• **Fig. 17.16** Intraoral lesion (herpes simplex) on the palate. (From Eisen D, Lynch D. *The Mouth: Diagnosis and Treatment*. St Louis: Mosby; 1998.)

Management

Primary management is to relieve the initial symptom, developing approximately 2 days after injection. Reassure the patient that the situation is not caused by a bacterial infection secondary to the local anesthetic injection, but is an exacerbation of a process that was present, in latent form, in the tissues before injection. Most of these patients have experienced this response before and are resigned to it happening again.

No management is necessary if the pain is not severe. However, if pain causes the patient to complain, treatment can be instituted, usually with various degrees of success. The objective is to keep the ulcerated areas covered or anesthetized.

Topical anesthetic solutions (e.g., viscous lidocaine) may be applied as needed to the painful areas. A mixture of equal amounts of diphenhydramine (Benadryl) and milk of magnesia rinsed in the mouth effectively coats the ulcerations and provides relief from pain. Orabase, a protective paste, without triamcinolone acetonide (Kenalog) can provide a degree of pain relief. Triamcinolone acetonide, a corticosteroid, is not recommended because its antiinflammatory actions increase the risk of viral or bacterial involvement. A tannic acid preparation (Zilactin) can be applied topically to the lesions extraorally or intraorally (dry the tissues first). Studies from the University of Alabama have demonstrated that most patients achieve substantial pain relief for up to 6 hours.^{99,100}

The ulcerations usually last 7 to 10 days with or without treatment. Add all necessary information to the patient's record.

References

- Pogrel MA. Broken local anesthetic needles: a case series of 16 patients, with recommendations. *J Am Dent Assoc.* 2009;140:1517–1522.
- Septodont. *Septodont Reported Wholesale Sales.* Newark: Septodont; 2006.
- Amies AB. Broken needles. *Aust Dent J.* 1951;55:403–406.
- Muller EE, Lernoud R. Surgical extraction of needles broken during local anesthesia of the mandibular nerve. *Acta Odontol Venez.* 1967;5:229–237.
- Dudani IC. Broken needles following mandibular injections. *J Indian Dent Assoc.* 1971;43:14–17.
- Kennett S, Curran JB, Jenkins GR. Management of a broken hypodermic needle: report of a case. *J Can Dent Assoc.* 1972;38:414–416.
- Kennett S, Curran JB, Jenkins GR. Management of a broken hypodermic needle: report of a case. *Anesth Prog.* 1973;20:48–50.
- Bump RL, Roche WC. A broken needle in the pterygomandibular space: report of a case. *Oral Surg Oral Med Oral Pathol.* 1973;36:750–752.
- Hai HK. Retrieval of a broken hypodermic needle: a new technique of localizing. *Singapore Dent J.* 1983;8:27–29.
- Orr DL 2nd. The broken needle: report of case. *J Am Dent Assoc.* 1983;107:603–604.
- Marks RB, Carlton DM, McDonald S. Management of a broken needle in the pterygomandibular space: report of case. *J Am Dent Assoc.* 1984;109:263–264.
- Burke RH. Management of a broken anesthetic needle. *J Am Dent Assoc.* 1986;112:209–210.
- Fox IJ, Belfiglio EJ. Report of a broken needle. *Gen Dent.* 1986;34:102–106.
- Pietruszka JF, Hoffman D, McGivern BE Jr. A broken dental needle and its surgical removal: a case report. *NY State Dent J.* 1986;52:28–31.
- Chaikin L. Broken needles. *NY State Dent J.* 1987;53(8).
- Burgess JO. The broken dental needle—a hazard. *Spec Care Dentist.* 1986;8:71–73.
- Ho KH. A simple technique for localizing a broken dental needle in the pterygomandibular region. *Aust Dent J.* 1988;33:308–309.
- Mima T, Shirasuna K, Morioka S, et al. A broken needle in the pterygomandibular space. *Osaka Daigaku Shigaku Zasshi.* 1989;34:418–422.
- McDonogh T. An unusual case of trismus and dysphagia. *Br Dent J.* 1996;180:465–466.
- Bhatia S, Bounds G. A broken needle in the pterygomandibular space: report of a case and review of the literature. *Dent Update.* 1998;25:35–37.
- Bedrock RD, Skigen A, Dolwick MF. Retrieval of a broken needle in the pterygomandibular space. *J Am Dent Assoc.* 1999;130:685–687.
- Faura-Sole M, Sanchez-Garces MA, Berini-Aytes L, et al. Broken anesthetic injection needles: report of 5 cases. *Quintessence Int.* 1999;30:461–465.
- Dhanrayani PJ, Jonaidel O. A forgotten entity: 'broken needle while inferior dental block'. *Dent Update.* 2000;27:101.
- Murray M. A forgotten entity: 'broken needle while administering inferior dental block'. *Dent Update.* 2000;27:306.
- Zeltser R, Cohen C, Casap N. The implications of a broken needle in the pterygomandibular space: clinical guidelines for prevention and retrieval. *Pediatr Dent.* 2002;24:153–156.
- Thompson M, Wright S, Cheng LH, et al. Locating broken dental needles. *Int J Oral Maxillofac Surg.* 2003;32:642–644.
- Baart JA, van Amerongen WE, de Jong KJ, et al. Needle breakage during mandibular block anaesthesia: prevention and retrieval. *Ned Tijdschr Tandheelkd.* 2006;113:520–523.
- Malamed SF, Reed K, Poorsattar S. Needle breakage: incidence and prevention. *Dent Clin N Am.* 2010;54:745–756.
- Deleted in Review.
- Malamed SF, Reed K, Poorsattar S. Needle breakage: incidence and prevention. *Dent Clin N Am.* 2010;54:745–756.
- Ethunandan M, Tran AL, Anand R, et al. Needle-breakage following inferior alveolar nerve block: implications and management. *Br Dent J.* 2007;202:395–397.
- Haas DA, Lennon D. A 21-year retrospective study of reports of paresthesia following local anesthetic administration. *J Can Dent Assoc.* 1995;61:329–330, 319–320, 323–326.
- Pogrel MA, Thamby S. Permanent nerve involvement resulting from inferior alveolar nerve blocks. *J Am Dent Assoc.* 2000;131:901–907.
- Pogrel MA, Thamby S. The etiology of altered sensation in the inferior alveolar, lingual, and mental nerves as a result of dental treatment. *J Calif Dent Assoc.* 1999;27:531–538.
- Dower JS Jr. A review of paresthesia in association with administration of local anesthesia. *Dent Today.* 2003;22:64–69.
- Haas DA. Localized complications from local anesthesia. *J Calif Dent Assoc.* 1998;26:677–682.
- Malden NJ, Maidment YG. Lingual nerve injury subsequent to wisdom teeth removal: a 5-year retrospective audit from a high street dental practice. *Br Dent J.* 2002;193:203–205.
- Heller AA, Shankland WE II. Alternative to the inferior alveolar nerve block anesthesia when placing mandibular dental implants posterior to the mental foramen. *J Oral Implantol.* 2001;27:127–133.
- Bataineh AB. Sensory nerve impairment following mandibular third molar surgery. *J Oral Maxillofac Surg.* 2001;59:1012–1017.

40. Kasaba T, Onizuka S, Takasaki M. Procaine and mepivacaine have less toxicity in vitro than other clinically used local anesthetics. *Anesth Analg*. 2003;97:85–90.
41. Hillerup S, Jensen R. Nerve injury caused by mandibular block analgesia. *Int J Oral Maxillofac Surg*. 2006;35:437–443.
42. Stenver DI. Pharmacovigilance Working Party of the European Union—Laegemiddelstyrelsen Danish Medicines Agency. *Adverse Effects From Anaesthetics Used in relation With Dental Care With a Special Focus on Anesthetics Containing Articaine*. 2006.
43. Pogrel MA. Permanent nerve damage from inferior alveolar nerve blocks—an update to include articaine. *J Calif Dent Assoc*. 2007;35:271–273.
44. Pogrel MA. Permanent nerve damage from inferior alveolar nerve blocks—a current update. *J Calif Dent Assoc*. 2012;40:795–797.
45. Garisto GA, Gaffen AS, Lawrence HP, et al. Occurrence of paresthesia after dental local anesthetic administration in the United States. *J Am Dent Assoc*. 2010;141:836–844.
46. National Lightning Safety Institute. Lightning strike probabilities. Available at: http://www.lightningsafety.com/nlsi_pls/probability.html. Accessed April 23, 2018.
47. National Weather Service, Lightning Safety. Odds of becoming a lightning victim. Available at: <http://www.lightningsafety.noaa.gov/medical>. Accessed April 23, 2018.
48. US Food and Drug Administration Center for Drug Evaluation and Research Office of Post-Marketing Drug Risk Assessment: Questions and answers on FDA's adverse event reporting system (FAERS) Available at: <https://www.fda.gov/Drugs/GuidanceComplianceRegulatoryInformation/Surveillance/AdverseDrugEffects>. Accessed April 23, 2018.
49. Katyal V. The efficacy and safety of articaine versus lignocaine in dental treatments: a meta-analysis. *J Dent*. 2010;38:307–317.
50. Local anesthetic market share. 2015-2018 (2nd quarter). data from Septodont, Inc. Lancaster, PA. www.septodont.com.
51. GfK HealthCare. *Deutscher Dentalmarkt Jahresbericht (DDM)*. Nuremberg: GfK HealthCare; 2010.
52. Nickel AA Jr. A retrospective study of paresthesia of the dental alveolar nerves. *Anesth Prog*. 1990;37:42–45.
53. Graff-Radford SB, Evans RW. Lingual nerve injury. *Headache*. 2003;49:975–983.
54. Moore PA, Haas DA. Paresthesia in dentistry. *Dent Clin North Am*. 2010;54:715–730.
55. Malamed SF, Gagnon S, Leblanc D. Safety of articaine: a new amide local anesthetic. *J Am Dent Assoc*. 2001;132:177–185.
56. Shira RB. Surgical emergencies. In: McCarthy FM, ed. *Emergencies in Dental Practice. Prevention and Treatment*. 3rd ed. Philadelphia: W.B. Saunders Company; 1979:521–523.
57. Orr DL II. Legal considerations. In: Malamed SF, ed. *Medical Emergencies in the Dental Office*. 7th ed. St. Louis: Mosby, Elsevier; 2015:113–124.
58. Sisk AL, Hammer WB, Shelton DW, et al. Complications following removal of impacted third molars. *J Oral Maxillofac Surg*. 1986;44:855–859.
59. Pogrel MA, Thamby S. The etiology of altered sensation in the inferior alveolar, lingual, and mental nerves as a result of dental treatment. *J Calif Dent Assoc*. 1999;27:531–535.
60. Pogrel MA. The results of microneurosurgery of the inferior alveolar and lingual nerve. *J Oral Maxillofac Surg*. 2002;60:484–489.
61. Cooley RL, Coon DE. Transient Bell's palsy following mandibular block: a case report. *Quintessence Int*. 1978;9:9.
62. Crean SJ, Powis A. Neurological complications of local anaesthetics in dentistry. *Dent Update*. 1999;26:344–349.
63. Malamed SF. The possible secondary effects in cases of local anesthesia. *Rev Belg Med Dent*. 2000;55:19–28.
64. Alamanos C, Raab P, Gamulescu A, Behr M. Ophthalmologic complications after administration of local anesthesia in dentistry: a systematic review. *Oral Surg Oral Med Oral Pathol Oral Radiol*. 2016;121:e39–e350.
65. Rishiraj B, Epstein JB, Fine D, Nabi S, Wade NK. Permanent vision loss in one eye following administration of local anaesthesia for a dental extraction. *Br J Oral Maxillofac Surg*. 2005;34:220–223.
66. Perez v Jung. *Superior Court of Washington*. King County: 1KNT; 2015:No. 15-2-15011.
67. Williams JV, Williams LR, Colbert SD, Revington PJ. Amaurosis, ophthalmoplegia, ptosis, mydriasis and periorbital blanching following inferior alveolar nerve block. *Oral Maxillofac Surg*. 2011;15:67–70.
68. Uckan S, Cilasun U, Erkman O. Rare ocular and cutaneous complication of inferior alveolar nerve block. *J Oral Maxillofac Surg*. 2006;64:719–721.
69. Sved AM, Wong JD, Donkor P, et al. Complications associated with maxillary nerve block anaesthesia via the greater palatine canal. *Aust Dent J*. 1992;37:340–345.
70. Hustler A, Crone S. Visual phenomena. *Br Dent J*. 2010;209:488.
71. Tveter-as K, Kristensen S. The aetiology and pathogenesis of trismus. *Clin Otolaryngol*. 1986;11:383–387.
72. Dhanrajani PJ, Jonaidel O. Trismus: etiology, differential diagnosis and treatment. *Dent Update*. 2002;29:88–92, 94.
73. Leonard M. Trismus: what is it, what causes it, and how to treat it. *Dent Today*. 1999;18:74–77.
74. Marien M Jr. Trismus: causes, differential diagnosis, and treatment. *Gen Dent*. 1997;45:350–355.
75. Benoit PW, Yagiela JA, Fort NF. Pharmacologic correlation between local anesthetic-induced myotoxicity and disturbances of intracellular calcium distribution. *Toxic Appl Pharmacol*. 1980;52:187–198.
76. Hinton RJ, Dechow PC, Carlson DS. Recovery of jaw muscle function following injection of a myotonic agent (lidocaine-epinephrine). *Oral Surg Oral Med Oral Pathol*. 1986;59:247–251.
77. Jastak JT, Yagiela JA, Donaldson D. Complications and side effects. In: Jastak JT, Yagiela JA, Donaldson D, eds. *Local Anesthesia of the Oral Cavity*. Philadelphia: WB Saunders; 1995.
78. Kitay D, Ferraro N, Sonis ST. Lateral pharyngeal space abscess as a consequence of regional anesthesia. *J Am Dent Assoc*. 1991;122:56–59.
79. Stacy GC, Hajjar G. Barbed needle and inexplicable paresthesias and trismus after dental regional anesthesia. *Oral Surg Oral Med Oral Pathol*. 1994;77:585–588.
80. Mezitis M, Rallis G, Zachariades N. The normal range of mouth opening. *J Oral Maxillofac Surg*. 2009;47:1028–1029.
81. Stone J, Kaban LB. Trismus after injection of local anesthetic. *Oral Surg*. 1979;48:29–32.
82. Eanes WC. A review of the considerations in the diagnosis of limited mandibular opening. *Cranio*. 1991;9:137–144.
83. Luyk NH, Steinberg B. Aetiology and diagnosis of clinically evident jaw trismus. *Aust Dent J*. 1990;35:523–529.
84. Brooke RI. Postinjection trismus due to formation of fibrous band. *Oral Surg Oral Med Oral Pathol*. 1979;47:424–426.
85. Himel VT, Mohamed S, Luebke RG. Case report: relief of limited jaw opening due to muscle spasm. *LDA J*. 1988;47:6–7.
86. Kouyoumdjian JH, Chalian VA, Nimmo A. Limited mandibular movement: causes and treatment. *J Prosthet Dent*. 1988;59:330–333.
87. Carter EF. Therapeutic ultrasound for the relief of restricted mandibular movement. *Dent Update*. 1986;13:508–509, 503, 504, 506.
88. Lund TW, Cohen JI. Trismus appliances and indications for use. *Quintessence Int*. 1993;24:275–279.
89. Harn SD, Durham TM, Callahan BP, Kent DK. The triangle of safety: a modified posterior superior alveolar injection technique based on the anatomy of the PSA artery. *Gen Dent*. 2002;50:554–557.
90. Harn SD, Durham TM, Callahan BP, et al. The posterior superior alveolar injection technique: a report on technique variations and complications. *Gen Dent*. 2002;50:544–550.

91. Malamed SF, Falkel M. Advances in local anesthetics: pH buffering and dissolved CO₂. *Dent Today*. 2012;31:88–93.
92. Comerci AW, Mailer SC, Townsend RD, Teepe JD, Vandewalle KS. Effect of a new local anesthetic buffering device on pain reduction during nerve block injections. *Gen Dent*. 2015;63:74–78.
93. Wahl MJ, Overton D, Howell J, et al. Pain on injection of prilocaine plain vs. lidocaine with epinephrine: a prospective double-blind study. *J Am Dent Assoc*. 2001;132:1398–1401.
94. Wahl MJ, Schmitt MM, Overton DA, et al. Injection pain of bupivacaine with epinephrine vs. prilocaine plain. *J Am Dent Assoc*. 2002;133:1652–1656.
95. Nzeako U, Frigas E, Tremaine W. Hereditary angioedema: a broad review for clinicians. *Arch Intern Med*. 2001;161:2417–2429.
96. Karlis V, Glickman RS, Stern R, et al. Hereditary angioedema: case report and review of management. *Oral Surg Oral Med Oral Pathol Oral Radiol Endodont*. 1997;83:462–464.
97. Hayes SM. Allergic reaction to local anesthetic: report of a case. *Gen Dent*. 1980;28:30–31.
98. Ship JA. Recurrent aphthous stomatitis: an update. *Oral Surg Oral Med Oral Pathol Oral Radiol Endodont*. 1996;82:118.
99. Raborn GW, McGaw WT, Grace M, et al. Herpes labialis treatment with acyclovir 5% modified aqueous cream: a double-blind randomized trial. *Oral Surg Oral Med Oral Pathol*. 1989;67:676–679.
100. Raborn GW, McGaw WT, Grace M, et al. Treatment of herpes labialis with acyclovir: review of three clinical trials. *Am J Med*. 1988;85:39–42.

Systemic Complications

The therapeutic use of drugs is commonplace in dentistry, with the administration of local anesthetics considered essential whenever potentially painful procedures are contemplated. It is estimated (conservatively) that dental professionals in the United States administer in excess of 6 million dental cartridges per week, or more than 300 million per year. Worldwide, almost 2 billion dental cartridges (1,960,000,000) are manufactured annually.¹

Local anesthetics are extremely safe drugs when used as recommended. However, whenever any drug, including a local anesthetic, is used, the potential for unwanted and undesirable responses exists. In this chapter, systemic adverse reactions to drugs in general and local anesthetics in particular are reviewed.

Several general principles of toxicology (the study of the harmful effects of chemicals or drugs on biological systems) are presented to further an understanding of the material in this chapter.

Harmful effects of drugs range from those that are inconsequential to the patient and entirely reversible once use of the drug is withdrawn, to those that are uncomfortable but not seriously harmful, to those that can seriously incapacitate or prove fatal to the patient.

Whenever any drug is administered, two types of actions may be observed: (1) desirable actions, which are clinically sought and usually beneficial; and (2) undesirable actions, which are additional and are not sought.

- Principle 1: No drug ever exerts a single action. All drugs exert many actions, desirable and undesirable. The primary indication for use of any drug is for what it does best (e.g., local anesthetics depress nerve conduction; diazepam depresses the central nervous system [CNS]) In ideal circumstances the right drug in the right dose is administered via the right route to the right patient at the right time for the right reason and does not produce any undesirable effects.² This ideal clinical situation is rarely, if ever, attained, because no drug is so specific that it produces only the desired actions in all patients.
- Principle 2: No clinically useful drug is entirely devoid of toxicity. The aim of rational drug treatment is to maximize the therapeutic effects and to minimize the toxic

effects of any given drug. No drug is completely safe or completely harmful. All drugs are capable of producing harm if handled improperly; conversely, any drug may be handled safely if proper precautions are observed.

- Principle 3: The potential toxicity of a drug rests in the hands of the user. A second factor in the safe use of drugs (after the drug itself) is the person to whom the drug is being administered. Individuals react differently to the same stimulus. Therefore patients differ in their reactions to a drug. Before administering any drug, the doctor must ask the patient specific questions about his or her medical and drug history. Physical evaluation and the ensuing dialogue history related to local anesthetic administration are presented in [Chapters 4 and 10](#).

Classification of Adverse Drug Reactions

Classification of adverse drug reactions (ADR) used to be the object of much confusion; reactions were labeled as *side effects*, *adverse experiences*, *drug-induced disease*, *diseases of medical progress*, *secondary effects*, and *intolerance*. The term *adverse drug reaction* (ADR) is preferred at this time.

[Box 18.1](#) outlines the three major methods by which drugs produce adverse reactions.

Overdose reactions, allergy, and idiosyncrasy are important topics in relation to local anesthetics and pain control in dentistry. A brief overview of each is presented, followed by an in-depth look at overdose and allergy.

Overdose reactions are those clinical signs and symptoms that manifest themselves as a result of an absolute or relative overadministration of a drug, which leads to elevated blood levels of the drug in its target organs. A target organ is a place in the body where the drug exerts its clinical action(s). Signs and symptoms of overdose are related to a direct extension of the normal pharmacologic actions of the drug in its target organs. Local anesthetics are drugs that act to depress excitable membranes (e.g., the CNS and myocardium are the target organs for local anesthetics, in addition to individual nerves). When administered properly and in therapeutic dosages, they cause little or no clinical evidence of CNS or cardiovascular system (CVS) depression. However, signs and symptoms of selective CNS and

• BOX 18.1 Causes of Adverse Drug Reactions

Toxicity caused by the recipient of the drug (pharmacologic effects of the drug):

1. side effects
2. overdose reactions
3. local toxic effects

Toxicity caused by alteration in the recipient of the drug:

1. a disease process (hepatic dysfunction, heart failure, renal dysfunction)
2. emotional disturbances
3. genetic aberrations (atypical plasma cholinesterase, malignant hyperthermia)
4. idiosyncrasy

Toxicity caused by allergic responses to the drug

CVS depression develops with increased blood levels in the cerebral circulation or myocardium. *Toxic reaction* is a synonym for *overdose*. Toxins are poisons. All drugs are poisons when administered to excess, thus the term *toxic reaction*.

Allergy is a hypersensitive state acquired through exposure to a particular allergen (a substance capable of inducing altered bodily reactivity), reexposure to which brings about a heightened capacity to react. Clinical manifestations of allergy differ and include:

- fever
- angioedema
- urticaria
- dermatitis
- depression of blood-forming organs
- photosensitivity
- bronchospasm
- anaphylaxis

In stark contrast to the overdose reaction, in which clinical manifestations are related directly to the normal pharmacology of the causative agent, the clinically observed reaction in allergy is always produced by an exaggerated response of the patient's immune system. Allergic responses to a local anesthetic, an antibiotic, latex, shellfish, bee sting, peanuts, or strawberries are produced by the same mechanism and may present clinically similar signs and symptoms. All allergic reactions receive the same basic management. Overdose reactions to these substances appear clinically dissimilar, necessitating entirely different modes of emergency management.

Another point of contrast between overdose and allergy relates to the amount of “drug” necessary to produce or provoke the reaction. For an overdose reaction to develop, a large enough amount of the drug must be administered to result in excessive blood levels in the drug's target organ(s). *Overdose reactions are dose related*. In addition, the degree of intensity (severity) of the clinical signs and symptoms relates directly to the blood level of the drug. The greater the dose administered, the higher the blood level, and the severer the reaction. By contrast, *allergic reactions are not dose related*. A large dose of a drug administered to a nonallergic patient does not provoke an allergic response, whereas a minuscule

TABLE 18.1 Comparison of Allergy and Overdose

	Clinical Response	
	Allergy	Overdose
Dose	Non-dose related	Dose related
Signs and symptoms	Similar, regardless of allergen	Relate to pharmacology of drug administered
Management	Similar (epinephrine, histamine blockers)	Different: specific for drug administered

amount (e.g., ≤ 0.1 mL) of a drug to which the patient is allergic can provoke life-threatening anaphylaxis.³

Idiosyncrasy, the third category of true ADRs, is a term used to describe a qualitatively abnormal, unexpected response to a drug, different from its usual pharmacologic actions and thus resembling hypersensitivity (a hyperresponder to a drug). However, idiosyncrasy does not involve a proven, or even suspected, allergic mechanism. A second definition considers an idiosyncratic reaction to be any adverse response that is neither overdose nor an allergic reaction. An example is stimulation or excitation that develops in some patients after administration of a CNS-depressant drug (e.g., a histamine blocker such as diphenhydramine [Benadryl]). Unfortunately, it is virtually impossible to predict which persons will have idiosyncratic reactions or the nature of the resulting idiosyncrasy.

It is thought that virtually all instances of idiosyncratic reaction have an underlying genetic mechanism. These aberrations remain undetected until the individual receives a specific drug, which then produces its bizarre (nonpharmacologic) clinical expression.

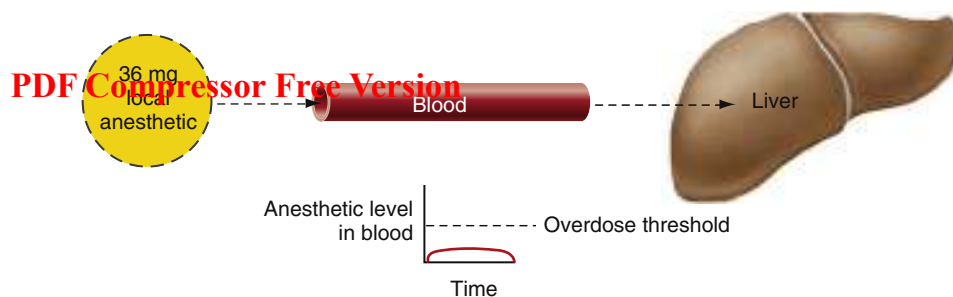
Specific management of idiosyncratic reactions is difficult to discuss because of the unpredictable nature of the response. Treatment is necessarily symptomatic, and includes positioning, circulation, airway, breathing, and definitive care.

Table 18.1 compares allergy versus overdose.

Overdose

A *drug overdose reaction* is defined as those clinical signs and symptoms that result from an overly high blood level of a drug in various target organs and tissues. Overdose reactions are the most common of all true ADRs, accounting for up to 99% in some estimates.⁴

For an overdose reaction to occur, the drug first must gain access to the CVS in quantities sufficient to produce adverse effects on various tissues of the body. Normally, both constant absorption of the drug from its site of administration into the CVS and steady removal of the drug from the blood as it undergoes redistribution (e.g., to skeletal muscle and fat) and biotransformation in other parts of the body (e.g., liver) are noted. Overly high drug levels in the blood and target organs rarely occur (Fig. 18.1) in this situation.



• **Fig. 18.1** Under normal conditions, both constant absorption of local anesthetic from the site of deposition into the cardiovascular system and constant removal of the drug from the blood by the liver occur. Local anesthetic blood level (red line) in its target organs (brain, myocardium) remains low and below the threshold for overdose.

However, this “steady state” can be altered in various ways, leading to rapid or more gradual elevation of the drug’s blood level. In either case a drug overdose reaction is caused by a level of a drug in the blood that is sufficiently high to produce adverse effects in various organs and tissues of the body in which the drug exerts a clinical action (these are termed the *target organs* of the drug). The reaction continues for only as long as the blood level of the drug in the target organs remains above its threshold for overdose.

Predisposing Factors

Overdose of local anesthetics is related to the blood level of the local anesthetic that occurs in certain tissues after the drug is administered. Many factors influence the rate at which this level is elevated and the length of time it remains elevated. The presence of one or more of these factors predisposes the patient to the development of overdose. The first group of factors relates to the patient, and the second group relates to the drug and the area into which the drug is administered (Box 18.2).

Patient Factors

Age

Although ADRs, including overdose, can occur in persons of any age, individuals at both ends of the age spectrum experience a higher incidence of such reactions.⁵⁻¹⁰ The functions of absorption, metabolism, and excretion may be imperfectly developed in very young persons and may be diminished in older-old persons (>85 years), thereby increasing the half-life of the drug, elevating circulating blood levels, and increasing the risk of overdose.¹¹

Weight

The greater the (lean) body weight of a patient (within certain limits), the larger the dose of a drug that can be tolerated before overdose reactions occur (providing the patient responds “normally” to the drug). Most drugs are distributed evenly throughout the body. Larger individuals have a greater blood volume and consequently a lower level of the drug per milliliter of blood. Maximum recommended doses (MRDs) of local anesthetics are normally calculated on the basis of milligrams of drug per kilogram or pound of body weight. One of the major factors involved in producing local anesthetic overdose in the past was lack of consideration of this extremely important

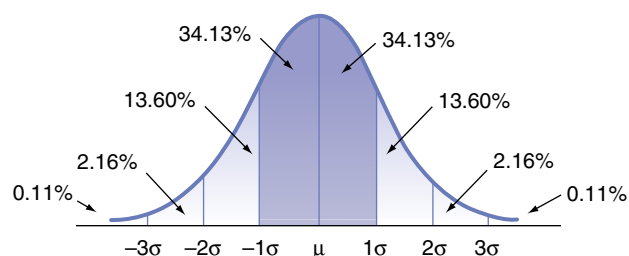
• BOX 18.2 Local Anesthetic Overdose: Predisposing Factors

Patient Factors

- Age
- Weight
- Other drugs
- Sex
- Presence of disease
- Genetics
- Mental attitude and environment

Drug Factors

- Vasoactivity
- Concentration
- Dose
- Route of administration
- Rate of injection
- Vascularity of the injection site
- Presence of vasoconstrictors



• **Fig. 18.2** Normal distribution curve (bell curve).

factor. Determination of maximum doses according to milligrams per kilogram or milligrams per pound of body weight is based on the responses of the “normal-responding” patient, which are determined from the responses of many thousands of patients. An individual patient’s response to drug administration, however, may demonstrate significant variation. The normal distribution curve (Fig. 18.2) illustrates this fact. The usual cerebral blood level of lidocaine necessary to induce seizure activity is approximately $7.5 \mu\text{g/mL}$. However, patients on the hyporesponding side of this curve may not convulse until a significantly higher brain-blood level is reached, whereas others (hyperresponders) may convulse at a brain-blood level considerably lower than $7.5 \mu\text{g/mL}$.

Other Medications

Administration of concomitant medications may influence local anesthetic drug response. Morphine (Demerol), phenytoin (Dilantin), quinidine (an antidysrhythmic), or desipramine (a tricyclic antidepressant) have increased local anesthetic blood levels and thus may experience toxic actions of the local anesthetic at lower administered doses because of protein binding competition. The H₂-histamine blocker cimetidine slows the biotransformation of lidocaine by competing with the local anesthetic for hepatic oxidative enzymes, leading to somewhat elevated lidocaine blood levels.¹²⁻¹⁴

Sex

Studies in animals have shown that sex is a factor in drug distribution, response, and metabolism, although it is not of major significance in humans. In humans the only instance of sexual difference affecting a drug response is pregnancy. During pregnancy, renal function may be disturbed, leading to impaired excretion of certain drugs, their accumulation in the blood, and increased risk of overdose. However, local anesthetic seizure thresholds for the fetus, newborn, and mother are significantly different.¹³⁻¹⁷ In the adult female the seizure threshold is reported to be 5.8 mg/kg, in the newborn it is 18.4 mg/kg, and in the fetus it is 41.9 mg/kg. This is thought to be a result of the efficient placental clearance of lidocaine into the mother's plasma.

Presence of Disease

Disease may affect the ability of the body to transform a drug into an inactive by-product. Hepatic and renal dysfunction impairs the body's ability to break down and excrete the local anesthetic, leading to an increased anesthetic blood level, whereas heart failure decreases liver perfusion (the volume of blood flowing through the liver during a specific period), thereby increasing the half-lives of amide local anesthetics and increasing the risk of overdose.^{18,19}

Genetics

Genetic deficiencies may alter a patient's response to certain drugs. A genetic deficiency in the enzyme serum pseudocholinesterase (serum cholinesterase, plasma pseudocholinesterase, plasma cholinesterase) is an important example. This enzyme, produced in the liver, circulates in the blood and is responsible for biotransformation of the ester local anesthetics. A deficiency in this enzyme quantitatively or qualitatively can prolong the half-life of an ester local anesthetic, thereby increasing its blood level. Approximately 1 in 2820 individuals, or 6% to 7% of patients in most surgical populations, have atypical serum pseudocholinesterase.²⁰

Mental Attitude and Environment

A patient's psychological attitude influences the ultimate effect of a drug. Although of greater importance with regard to antianxiety or analgesic drugs, it is also important with regard to local anesthetics. Psychological attitude affects the patient's response to various stimuli. The apprehensive

patient who overreacts to stimulation (experiencing pain when gentle pressure is applied) is more likely to receive a larger dose of local anesthetic, which would seemingly increase his or her risk of local anesthetic overdose. However, a 2010 study in rats demonstrated that stress-induced changes in arterial carbon dioxide tension (decreased PaCO₂) and in partial pressure of oxygen in arterial blood (increased PaO₂) significantly raised the seizure threshold for both lidocaine and articaine.²¹ Stress significantly increased the latency period for the first tonic-clonic seizure induced by toxic doses of both lidocaine and articaine.²¹

Drug Factors

Vasoactivity

All local anesthetics currently used by injection in dentistry are inherently vasodilators. Injection into soft tissues increases perfusion in the area, leading to an increased rate of drug absorption from the site of injection into the CVS. This causes three undesirable effects: a (1) shorter duration of, (2) not as profound clinical anesthesia, and (3) an increased blood level of the local anesthetic.

Concentration

The greater the concentration (percent solution injected) of the local anesthetic administered, the greater the number of milligrams per milliliter of solution and the greater the circulating blood volume of the drug in the patient. For example, 1.8 mL of a 4% solution contains 72 mg of the drug, but 1.8 mL of a 2% solution contains only 36 mg. If the drug is clinically effective as a 2% concentration, higher concentrations should not be used. The lowest concentration of a given drug that is clinically effective should be selected for use. For commonly used local anesthetics in dentistry, these "ideal" concentrations have been determined and are represented in the commercially available forms of these drugs.

Dose

The larger the volume of a local anesthetic administered, the greater the number of milligrams injected, the higher the resulting circulating blood level. The smallest dose of a given drug that is clinically effective should be administered. For each of the injection techniques discussed in this book, a recommended dose has been presented. Where possible, this dose should not be exceeded. Although "dental" doses of local anesthetics are relatively small compared with those used in many nondental nerve blocks, significantly high blood levels of the local anesthetic can be achieved in dental situations because of the greater vascularity of the intraoral injection site or inadvertent intravascular injection of the drug.

Route of Administration

Local anesthetics, when used for pain control, exert their clinical effects in the area of deposition. Ideally then, a local anesthetic drug should *not* enter the CVS. Almost all other therapeutic agents *must* enter the CVS and achieve a minimum therapeutic blood level before their clinical action(s)

occur. Local anesthetics administered for antidysrhythmic purposes must reach such a therapeutic blood level in the myocardium to be effective. The most common method in terminating pain control by a local anesthetic consists of its diffusion out of the nerve and its subsequent entry into the CVS and removal from the site of deposition.

A factor in local anesthetic overdose in dentistry is “inadvertent” intravascular injection. Extremely high drug levels can be obtained in a short time, leading to serious overdose reactions.

Absorption of local anesthetics through oral mucous membranes is also potentially dangerous because of the rate at which some topically applied anesthetics enter the CVS. Lidocaine hydrochloride and tetracaine hydrochloride are absorbed well after topical application to mucous membranes. Benzocaine, which is not water soluble, is poorly absorbed.

Rate of Injection

The rate at which a drug is injected is a very important factor in the causation or prevention of overdose reactions from intravascular administration. (According to the author, the rate of injection is the single most important factor.) Whereas intravascular injection may or may not produce signs and symptoms of overdose (indeed, lidocaine is frequently administered intravenously in doses of 1.0 to 1.5 mg/kg to treat ventricular ectopy), the rate at which the drug is injected is a major factor in determining whether drug administration will prove clinically safe or hazardous. Malagodi et al.²² demonstrated that the incidence of seizures with etidocaine increased when the rate of intravenous infusion was increased.

Rapid intravenous administration (≤ 15 seconds) of 36 mg of lidocaine produces greatly elevated levels and virtually ensures an overdose reaction. Slow intravenous administration (≥ 60 seconds) produces significantly lower levels in the blood, with a lesser risk that a severe overdose reaction will develop.

Vascularity of the Injection Site

The greater the vascularity of the injection site, the more rapid the absorption of the drug from that area into the circulation. Unfortunately (as regards local anesthetic overdose) for dentistry, the oral cavity is one of the most highly vascular areas of the entire body. However, some areas within the oral cavity are less well perfused (e.g., the site for local anesthetic deposition in the Gow-Gates mandibular nerve block), and these are usually more highly recommended than other, more well-perfused, sites (e.g., those for the inferior alveolar or posterior superior alveolar nerve block).

Presence of Vasoconstrictors

The addition of a vasoconstrictor to a local anesthetic produces a decrease in the perfusion of an area and a decreased rate of systemic absorption of the drug. This, in turn, decreases the clinical toxicity of the local anesthetic (see Table 3.1).

Causes

Elevated blood levels of local anesthetics may result from one or more of the following:

1. Biotransformation of the drug is unusually slow.
2. The unbiotransformed drug is too slowly eliminated from the body through the kidneys.
3. Too large a total dose is administered.
4. Absorption from the injection site is unusually rapid.
5. Intravascular administration.

Biotransformation and Elimination

Ester local anesthetics, as a group, undergo more rapid biotransformation in both the blood and liver than the amides, whose metabolism occurs almost entirely in the liver. Plasma pseudocholinesterase is primarily responsible for their hydrolysis to *p*-aminobenzoic acid.

Atypical pseudocholinesterase occurs in approximately 1 in every 2820 individuals, or 6% to 7% of patients in a surgical population.²⁰ Patients with a familial history of this disorder may be unable to biotransform ester agents at the usual rate, and subsequently, higher levels of ester anesthetics may develop in their blood.

The presence of atypical pseudocholinesterase is a relative contraindication to the administration of ester local anesthetics. Amide local anesthetics may be used without increased risk of overdose in patients with pseudocholinesterase deficiency.

Amide local anesthetics are biotransformed in the liver by hepatic microsomal enzymes. A history of liver disease, however, is not an absolute contraindication to their use. In an ambulatory patient with a history of liver disease (American Society of Anesthesiologists [ASA] physical Status classification system class 2 or 3), amide local anesthetics may be used judiciously (relative contraindication) (Fig. 18.3).

Minimum effective volumes of anesthetic should be used. Average, even low-average, doses may be capable of producing an overdose if liver function is compromised to a great enough degree (ASA class 4 or 5); however, this situation is unlikely to occur in an ambulatory patient.¹⁹

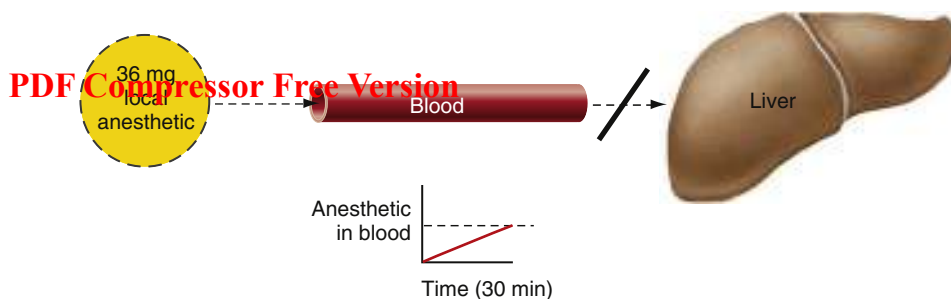
Renal dysfunction can also delay elimination of the active local anesthetic from the blood. A percentage of all anesthetics is eliminated unchanged through the kidneys: 2% procaine, 10% lidocaine, 5% to 10% articaine, and 1% to 15% mepivacaine and prilocaine. Renal dysfunction may lead to a gradual increase in the level of active local anesthetic in the blood.¹⁸

Excessive Total Dose

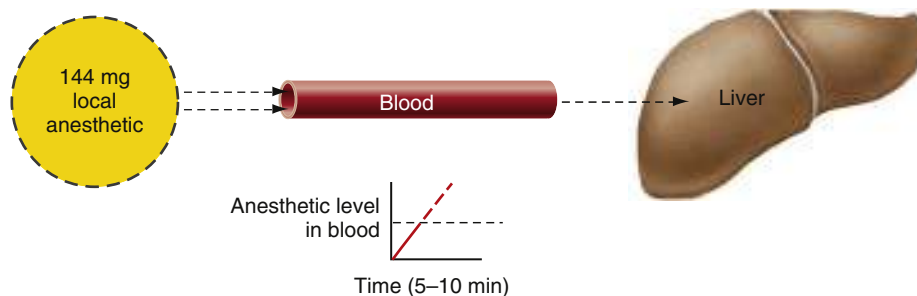
Given in excess, all drugs are capable of producing signs and symptoms of overdose (Fig. 18.4). Precise milligram doses or the blood levels at which clinical effects are noted are impossible to predict. Biological variability has a great influence on the manner in which persons respond to drugs.

The MRD of parenterally administered (injected) drugs is commonly calculated after consideration of a number of factors, including:

1. *Patient's age.* Individuals at either end of the age spectrum (this is commonly stated as younger 6 years and older



• **Fig. 18.3** In patients with significant hepatic dysfunction (American Society of Anesthesiologists class 3 or 4), removal of the local anesthetic from the blood may be slower than its absorption into the blood, leading to a slow but constant elevation in the local anesthetic blood level.



• **Fig. 18.4** Even in a patient with normal liver function, a large dose of local anesthetic may be absorbed into the cardiovascular system more rapidly than the liver can remove it. This produces a relatively rapid elevation of the anesthetic blood level.

TABLE 18.2

Maximum Recommended Doses of Local Anesthetics as per the US Food and Drug Administration

Drug	Formulation	Maximum Recommended Dose (mg)	Dose (mg/kg)
Articaine	With epinephrine	None listed	7
Bupivacaine	With epinephrine	90	None listed
Lidocaine	With epinephrine	500	7
Mepivacaine	Plain or with a vasoconstrictor	400	6.6
Prilocaine	Plain or with a vasoconstrictor	600	8

than 65 years) may be unable to tolerate normal doses, which should be decreased accordingly.

2. *Patient's physical status.* For medically compromised individuals (ASA classes 3, 4, and 5) the calculated MRD should be decreased.
3. *Patient's weight.* The heavier the person (within limits), the greater is the volume of distribution of the drug. With a usual dose the blood level of the drug is lower in the heavier patient, and a larger milligram dose can be administered safely. Although this rule is generally valid, there are always exceptions; care must be exercised whenever any drug is administered.

MRDs of local anesthetics should be determined after consideration of the patient's age, physical status, and body weight. Table 18.2 provides MRDs based on body weight for articaine, bupivacaine, lidocaine, mepivacaine, and prilocaine as per the US Food and Drug Administration (FDA). MRDs for local anesthetics may differ—in some instances significantly—from country to country.

It is highly unlikely that the maximum figures indicated in Table 18.2 will be reached in the typical dental practice. There is rarely an occasion to administer more than three or four cartridges during a dental appointment. Regional block anesthesia is capable of obtunding the full mouth in an adult with six cartridges, and with two cartridges in the primary dentition. Yet despite this ability to achieve widespread anesthesia with minimum volumes of anesthetic, the administration of excessive volumes is the most frequently seen cause of local anesthetic overdose in dentistry.^{23,24}

Rapid Absorption Into the Cardiovascular System

Vasoconstrictors are considered an integral component of all local anesthetics whenever the depth and duration of anesthesia are important. There are but few indications for the use of local anesthetics without a vasoconstrictor in dentistry (e.g., short procedure, minimal depth of “cutting”). Vasoconstrictors increase both the depth and

the duration of anesthesia and reduce the systemic toxicity of most local anesthetics by delaying their absorption into the CVS. PDE Compressor Free Version local anesthetic solutions unless specifically contraindicated by the medical status of the patient or the duration of the planned treatment.²⁵ The American Dental Association and the American Heart Association summarized this as follows: “Vasoconstrictor agents should be used in local anesthetic solutions during dental practice only when it is clear that the procedure will be shortened or the analgesia rendered more profound. When a vasoconstrictor is indicated, extreme care should be taken to avoid intravascular injection. The minimum possible amount of vasoconstrictor should be used.”²⁶ Rapid absorption of local anesthetics may also occur after their topical application to oral mucous membranes. Adriani²⁷ demonstrated that absorption of some topically applied local anesthetics into the circulation is rapid, exceeded in rate only by direct intravascular injection. Local anesthetics designed for topical application are used in a higher concentration than formulations suitable for parenteral administration.

From the perspective of overdose, amide topical anesthetics, when applied to wide areas of mucous membrane, increase the risk of serious reactions. Benzocaine, an ester anesthetic, which is poorly, if at all, absorbed into the CVS, is less likely to produce an overdose reaction than amides, although cases of methemoglobinemia from excessive benzocaine administration have been reported.²⁸⁻³⁰ The risk of allergy (more likely with esters than amides) must be addressed before any drug is used. Serious overdose reactions have been reported after topical application of amide local anesthetics.³¹⁻³⁴

The area of application of a topical anesthetic should be limited. There are few indications for applying a topical anesthetic to more than a full quadrant (buccal and lingual/palatal) at one time. Application of an amide topical anesthetic to a wide area requires a large quantity of the agent and increases the likelihood of overdose.

When a spray topical anesthetic is needed, the use of metered dosage forms is strongly recommended. Disposable nozzles for metered sprays make maintenance of sterility simpler (Fig. 18.5). Ointments or gels, if used in small amounts (as on the tip of a cotton applicator stick), may be applied with minimal risk of overdose.

Intravascular Injection

Intravascular injection may occur with any type of intraoral injection but is more likely when a nerve block is administered³⁵:

Nerve Block	Positive Aspiration Rate (%)
Inferior alveolar	11.7
Mental or incisive	5.7
Posterior superior alveolar	3.1
Anterior superior alveolar	0.7
(Long) buccal	0.5



• Fig. 18.5 Metered spray with disposable nozzle.

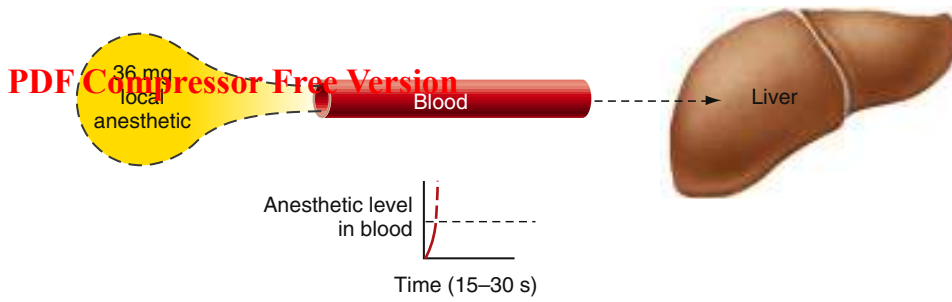
Both intravenous and intra-arterial injections are capable of producing overdose (Fig. 18.6). Aldrete³⁶ demonstrated that a rapidly administered intra-arterial injection may cause retrograde blood flow in the artery as the anesthetic drug is deposited (Fig. 18.7). Intravascular injections of local anesthetic within the usual practice of dentistry should not occur. With knowledge of the anatomy of the site to be anesthetized and a proper technique of aspiration before the anesthetic solution is deposited (aspirate in two planes—see later), overdose as a result of intravascular injection is highly unlikely to occur.

Prevention

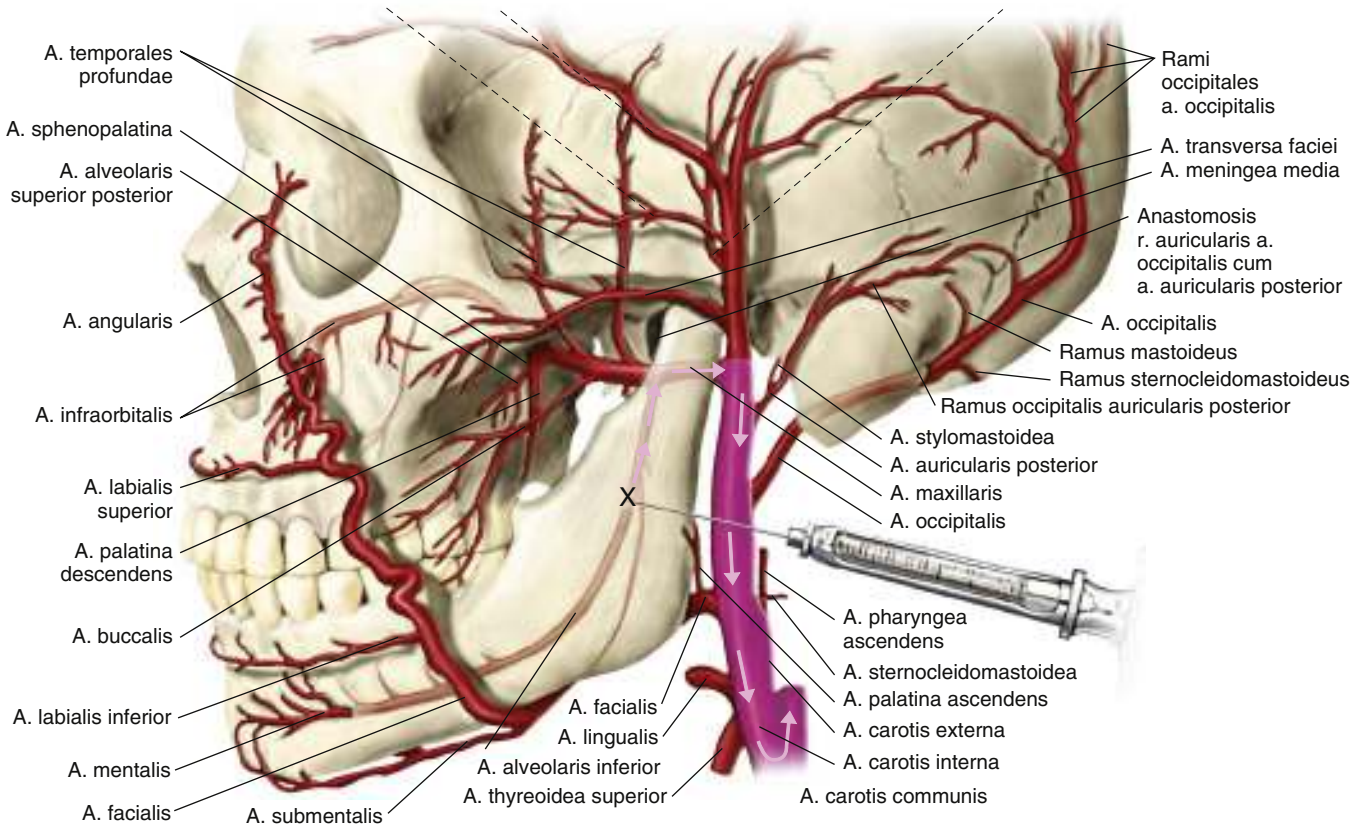
To prevent intravascular injection, *use an aspirating syringe*. In an unpublished survey conducted by the author, 23% of dentists questioned stated that they routinely use nonaspirating syringes to administer local anesthetics. There can be no justification for the use of a nonaspirating syringe for any intraoral injection technique. It is impossible to determine the precise location of the needle tip without aspirating.

Use a needle larger than 27 gauge when the risk of aspiration is high. Although aspiration of blood is possible through smaller-gauge needles, resistance to the return of blood into the lumen of smaller-gauge needles is increased, leading to an increased likelihood of an unreliable aspiration test. Therefore injection techniques with a greater likelihood of positive aspiration dictate the use of a 25-gauge needle. A 27-gauge needle can be used in lieu of a 25-gauge needle as it provides relatively reliable aspiration; however, use of 30-gauge needles should be avoided, if at all possible, when injections are administered into more vascular areas of the oral cavity. Sadly—in this author’s view—the dental profession in the United States has moved away from use of the 25-gauge needle, preferring instead to use the 30-gauge needle for all injections (see Table 6.2).³⁷

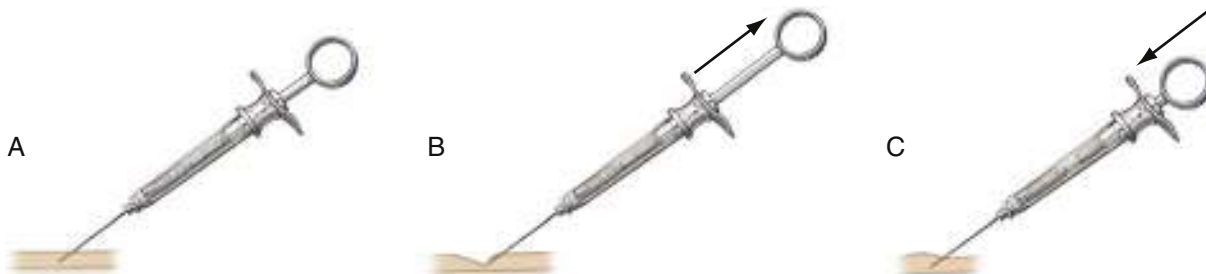Aspirate in at least two planes before injection. Fig. 18.8 illustrates how a single aspiration test may be negative even though the needle tip lies within the lumen of a blood vessel.



• **Fig. 18.6** Rapid intravascular administration of one cartridge of local anesthetic produces marked elevation of the anesthetic blood level in the drug's target organs in a very short time.



• **Fig. 18.7** Reverse carotid blood flow. Rapid intra-arterial deposition of local anesthetic into the inferior alveolar artery (X) produces an overdose reaction. Blood flow in the arteries is reversed because of the high pressure produced by the rate of injection. Arrows indicate the path of the solution into the internal carotid artery and cerebral circulation.



• **Fig. 18.8** Intravascular injection of local anesthetic. (A) Needle is inserted into the lumen of the blood vessel. (B) Aspiration test is performed. Negative pressure pulls the vessel wall against the bevel of the needle; therefore no blood enters the syringe (negative aspiration). (C) Drug is injected. Positive pressure on the plunger of the syringe forces local anesthetic solution out through the needle. The wall of the vessel is forced away from the bevel, and anesthetic solution is deposited directly into the lumen of the blood vessel.

The use of multiple aspiration tests before injection of solution, with the needle bevel in different planes, overcomes this potential problem. The syringe is aspirated with the syringe about 45 degrees (up or down) to reorient the needle bevel relative to the wall of the blood vessel, and reaspirate.

Slowly inject the anesthetic. Rapid intravascular injection of 1.8 mL of a 2% local anesthetic solution produces a blood level in excess of that necessary for overdose. Rapid injection is defined (by the author) as administration of the entire volume of a dental cartridge in 30 seconds or less. The same volume of anesthetic deposited intravascularly slowly (minimum of 60 seconds) produces slightly elevated blood levels that are still below the minimum for serious overdose (seizure). In the event that the level does exceed this minimum, the observed signs and symptoms will be less severe than those noted following more rapid injection. Slow injection is the most important factor in preventing ADRs from intravascular administration—even more important than aspiration. The ideal rate of local anesthetic administration is 1.0 mL/min. Given that many dentists administer local anesthetic more rapidly than this ideal, the recommended rate of local anesthetic administration corresponds to deposition of a 1.8-mL cartridge in not less than 60 seconds. Because the recommended volumes of local anesthetic for most intraoral injection techniques are considerably less than 1.8 mL, most injections can be administered safely (and comfortably) in less than 1 minute.

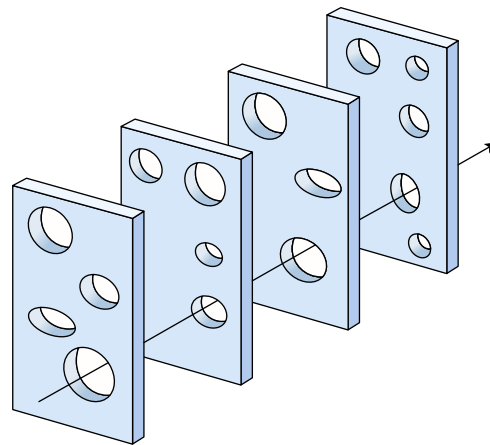
The truth about local anesthetic overdose in dentistry³⁸: Administration of too large a local anesthetic dose relative to the weight (and age) of the patient is the most common cause of serious local anesthetic overdose reactions in dentistry. Although some serious cases of local anesthetic overdose have occurred in adult patients,⁷ an overwhelming majority of problems commonly develop in the child who is young (2 to 6 years), lightweight (<30 kg [<66 lb]), and well behaved; requires multiple procedures in four quadrants; and is managed in the office of an inexperienced general dentist.⁷

Review of the too many cases that resulted in serious morbidity or death reveals a number of shared factors, none of which in themselves might pose a serious problem; however, when added together, they act to produce clinical signs and symptoms of local anesthetic overdose. This is termed the *Swiss-cheese model* of accident causation (Fig. 18.9).³⁹

These factors are presented in Box 18.3.

1. *Treatment plan:* In interviews with trained pediatric dentists (up through and including January 2019), it has been the author's experience that when presented with the patient described in this section (young, lightweight, well behaved), the pediatric dentist (with but very few exceptions) will not treat all four quadrants at one visit using local anesthesia alone. Limiting treatment to one or two quadrants per visit is a more rational approach to this patient's needs and enhances safety.

A general dentist confronted with a (well-meaning) parent or grandparent who complains of the difficulties of getting to the dental office and the inconvenience of having to miss a half-day of work and wanting to



• **Fig. 18.9** Swiss-cheese model of accident causation. (From Adams JG: *Emergency Medicine, Clinical Essentials*. 2nd ed. Philadelphia: Elsevier; 2013.)

• BOX 18.3 Factors Adding to Increased Risk of Local Anesthetic Overdose in Younger Patients

1. Treatment plan where all four quadrants are treated with local anesthetic at one visit.
2. Local anesthetic administered is a plain solution (no vasoconstrictor).
3. Full cartridges (1.8 mL) administered with each injection.
4. Local anesthetic administered to all four quadrants at one time.
5. Exceeding the maximum dose based on patient's body weight.

have the child's dental care accomplished in one visit (not two or more) might feel pressured into agreeing to this request, thus increasing the risk for local anesthetic overdose. This is more likely to occur in offices of younger (by which I mean "inexperienced") dentists who are developing their practice and wish to keep their patients "happy."

2. *Choice of local anesthetic:* In most instances where serious local anesthetic overdose has occurred in children, the local anesthetic administered has been a "plain" drug, either 3% mepivacaine hydrochloride (usually) or 4% prilocaine hydrochloride. Both of these are excellent local anesthetics—when used properly. The rationale behind the clinician's selection of a short-acting drug for children includes that (1) most pediatric appointments are of short duration; and (2) plain local anesthetics have a shorter duration of residual soft tissue anesthesia, minimizing the likelihood of inadvertent soft tissue injury as the child bites or chews his or her numb lip or tongue.

As a rule, the pediatric dentist administers a plain local anesthetic only when treatment is minimal and limited to one quadrant. If treatment extends to two or more quadrants at that same visit, a vasoconstrictor-

TABLE 18.3 Local Anesthetic of Choice for 117 Dentists Who Treat Children

Local Anesthetic Formulation	Percentage Preferentially Using Drug
2% lidocaine + epinephrine	69
3% mepivacaine	11
2% lidocaine	8
2% mepivacaine + levonordefrin	8
Other	4

Data from Cheatham BD, Primosch RE, Courts FJ: A survey of local anesthetic usage in pediatric patients by Florida dentists. *J Dent Child.* 1992;59:401–407.

containing local anesthetic is selected. Prolonged post-treatment soft tissue anesthesia leads to the increased possibility of soft tissue damage; however, this risk is outweighed by benefits accrued through delayed absorption of the local anesthetic into the CVS (the risk of overdose is diminished). Postoperative soft tissue injury can be prevented in many ways, such as by securing a cotton roll in the buccal fold and advising the parent to watch the child (see [Chapters 16 and 17](#)). The local anesthesia reversal agent phentolamine mesylate decreases the residual soft tissue anesthesia duration significantly.^{40,41} Reversal of local anesthesia is discussed fully in [Chapter 20](#).

[Table 18.3](#) presents the local anesthetic of choice for 117 dentists who treat children.⁴²

3. *Volume of local anesthetic administered:* Pain control for the entire primary dentition (four quadrants) can be achieved with approximately two cartridges of local anesthetic. In the lighter weight (<30 kg) child patient, there is rarely a compelling need to administer a 1.8-mL volume of local anesthetic in any one injection. Yet full cartridges are commonly administered when children receive local anesthetic administered by nonpediatric dentists. In many of the instances where a death resulted, a total of five, six, or seven cartridges were administered.⁵

In those few situations where local anesthetic must be administered to all four quadrants of a smaller child, pain control can be achieved with not more than two cartridges, as follows: one-fourth of a cartridge in each case for the right and left incisive nerve blocks (anesthetizing all mandibular primary teeth); or half of a cartridge in each case for the right and left inferior alveolar nerve blocks; one-fourth of a cartridge in each case for the right and left anterior superior alveolar nerve blocks. In lieu of the anterior superior alveolar nerve block, maxillary infiltrations may be administered with one-sixth or less of a cartridge per injection ([Table 18.4](#)).

TABLE 18.4 Recommended Volumes of Local Anesthetic for Intraoral Injections

Technique	Adult Volume (mL)	Child Volume (mL)
Infiltration (supraperio-teal)	0.6	0.3
Inferior alveolar	1.5	0.9
Gow-Gates mandibular	1.8	0.9
Mental or incisive	0.6	0.45
Posterior superior alveolar	0.9	0.45
Anterior superior alveolar (infraorbital)	0.9	0.45
Greater (anterior) palatine	0.45	0.2
Nasopalatine	0.2	0.2
Maxillary (second division)	1.8	0.9

4. *Local anesthetic administered to all four quadrants at one time:* Administration, over 1 or 2 minutes, of four or more cartridges of a local anesthetic without a vasoconstrictor to all four quadrants makes little therapeutic sense while increasing the risk of overdose. Administration of local anesthetic to one quadrant, treating that area, then anesthetizing the next quadrant, and so on, makes considerably more sense from both the therapeutic and the safety perspective. For equal volumes of local anesthetic, administration over a longer time frame (e.g., 1 to 2 hours) results in a lower blood level when compared with administration of the entire dose at one time.
5. *Exceeding the maximum dose based on patient's body weight:* An important factor, especially when younger, lighter-weight patients are managed, is the MRD. Determine the weight of the patient (in kilograms or pounds) before the start of treatment. It is preferable to weigh the child on a scale, because frequently parents can offer only a rough estimate of their child's weight (usually underestimating it). One must always remember that these figures are not absolutes. Exceeding the MRD of a drug does not guarantee that an overdose will happen (see [Table 18.5](#)). On the other hand, administering doses below the maximum calculated by body weight is no guarantee that ADRs will not be seen. The likelihood of ADRs developing is dose related. Smaller doses minimize (but do not eliminate) this risk; larger doses increase (but do not guarantee) it. MRDs of commonly administered local anesthetics are summarized in [Table 18.5](#).

The intrinsic safety of local anesthetics is illustrated in [Table 18.6](#), which presents the volume of local anesthetic administered on 65 occasions by a general dentist who removed third molars from college-aged individuals.

TABLE 18.5

Maximum Recommended Doses of Local Anesthetics as per the US Food and Drug Administration

PDF Compressor Free Version

Drug	Clinical Percent	mg/mL	Amount per 1.8-mL Cartridge (mg)	Recommended Dose		Absolute Maximum Dose (mg)
				mg/kg	mg/lb	
Articaine	4	40	72	7	3.2	None listed
Lidocaine	2	20	36	7	3.2	500
Mepivacaine	2	20	36	6.6	3	400
Mepivacaine	3	30	54	6.6	3	400
Prilocaine	4	40	72	8	3.6	600
Bupivacaine	0.5	5	9	None listed	None listed	90

TABLE 18.6

Local Anesthetic Administration for Removal of Third Molars

Number of Third Molars Extracted at Visit	Number of Patients in Category	Number of Cartridges	Average Number of Cartridges
1	5	4–10	6.2
2	13	4–23	12.18
3	8	10–20	15.33
4	39	6–26	19.24

None of these patients experienced an adverse response to the local anesthetic, although many received doses many times the MRD.⁴³ This is one indication that local anesthetics are extremely safe drugs when administered to healthy, younger adult patients (teenage to mid-20s). Unfortunately, when they are administered in overly large doses to younger, lightweight patients, overdose becomes a significant risk.

Virtually all local anesthetic overdose reactions are preventable if the clinician adheres to the very basic, simple recommendations presented in this section. In the unlikely situation that an overdose reaction develops, adherence to the basic steps of emergency management will lead to a successful outcome in essentially all cases.

Clinical Manifestations

Clinical signs and symptoms of overdose appear whenever the blood level in that drug's target organ(s) becomes overly high for that individual (Box 18.4). Target organs for local anesthetics include the CNS and the myocardium. The rate of onset of signs and symptoms and, to an extent, their severity correspond to this level. Table 18.7 compares the various modes of local anesthetic overdose.

• BOX 18.4 Overdose Levels

Minimal to Moderate Overdose Levels

Signs

Talkativeness
 Apprehension
 Excitability
 Slurred speech
 Generalized stutter, leading to muscular twitching and tremor distal extremities
 Euphoria
 Dysarthria
 Nystagmus
 Sweating
 Vomiting
 Failure to follow commands or be reasoned with
 Disorientation
 Loss of response to painful stimuli
 Elevated blood pressure
 Elevated heart rate
 Elevated respiratory rate

Symptoms (progressive with increasing blood levels)

Lightheadedness and dizziness
 Restlessness
 Nervousness
 Numbness
 Sensation of twitching before actual twitching is observed (see "Generalized Stutter" under "Signs")
 Metallic taste
 Visual disturbances (inability to focus)
 Auditory disturbances (tinnitus)
 Drowsiness and disorientation
 Loss of consciousness

Moderate to High Overdose Levels

Signs

Tonic-clonic seizure activity followed by:

- generalized central nervous system depression
- depressed blood pressure, heart rate, and respiratory rate

Note: It is possible that the "excitatory" phase of the overdose reaction may be extremely brief or may not occur at all, in which case the first clinical manifestation of overdose may be drowsiness progressing to unconsciousness and respiratory arrest. This appears to be more common with lidocaine than with other local anesthetics.⁴⁴

TABLE
18.7

Comparison of Forms of Local Anesthetic Overdose

	Rapid Intravascular	Too Large a Total Dose	Rapid Absorption	Slow Biotransformation	Slow Elimination
Likelihood of occurrence	Common Rare following proper injection technique	Most common	Likely with “high normal” doses if no vasoconstrictors are used	Uncommon	Least common
Onset of signs and symptoms	Most rapid (seconds); intra-arterial faster than intravenous	5–10 min	5–10 min	10–30 min	10 min to several hours
Intensity of signs and symptoms	Usually most intense	Gradual onset with increased intensity; may prove quite severe		Gradual onset with slow increase in intensity of symptoms	
Duration of signs and symptoms	1–2 min	Usually 5–30 min; depends on dose and ability to metabolize or excrete the drug		Potentially longest duration because of inability to metabolize or excrete drug(s)	
Primary prevention	Aspirate twice, slow injection	Administer minimal doses	Use a vasoconstrictor; limit topical anesthetic use or use nonabsorbed type (base)	Adequate pretreatment physical evaluation of patient	
Drug groups	Amides and esters	Amides; esters only rarely	Amides; esters only rarely	Amides and esters	Amides and esters

The Federal Aviation Administration⁴⁵ states the following in its *Guide for Aviation Examiners*:

Do Not Fly. Airmen should not fly while using any of the medications in the Do Not Issue section above or while using any of the medications or classes/groups of medications listed below without an acceptable wait time after the last dose. All of these medications may cause sedation (drowsiness) and impair cognitive function, seriously degrading pilot performance. This impairment can occur even when the individual feels alert and is apparently functioning normally—in other words, the airman can be “unaware of impair.”

For aviation safety, airmen should not fly following the last dose of any of the medications below until a period of time has elapsed equal to:

- 5-times the maximum pharmacologic half-life of the medication; or
 - 5-times the maximum hour dose interval if pharmacologic half-life information is not available. For example, there is a 30-hour wait time for a medication that is taken every 4 to 6 hours (5 times 6).
- “Pre-medication” or “pre-procedure” drugs. This includes all drugs used as an aid to outpatient surgical or *dental procedures* [emphasis added].

The clinical manifestations of local anesthetic overdose will persist until the anesthetic blood level in the affected organs (brain, heart) falls below the minimum value (through redistribution), or until clinical signs and symptoms are terminated through administration of appropriate drug therapy.

Pathophysiology

The blood or plasma level of a drug is the amount absorbed into the CVS and transported in plasma throughout the

body. Levels are measured in micrograms per milliliter (1000 μg equals 1 mg). Fig. 18.10 illustrates clinical manifestations observed with increasing blood levels of lidocaine in the CNS and myocardium. Blood levels are best estimates because significant individual variation is to be expected as per the normal distribution curve.

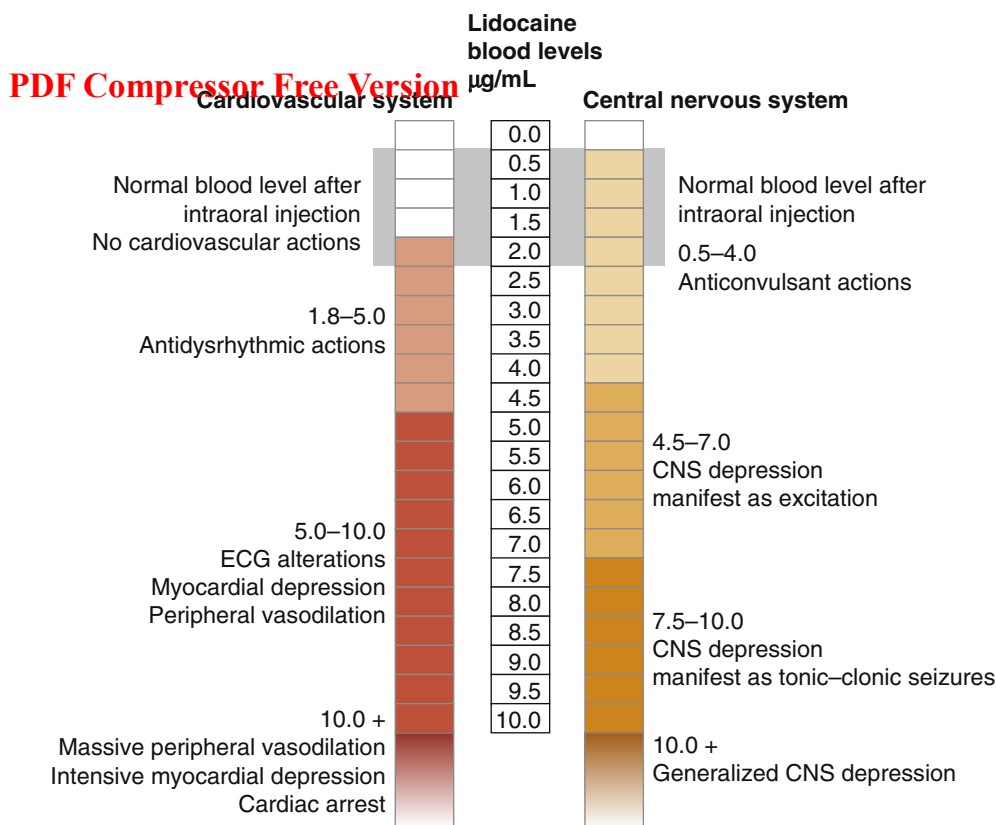
Local anesthetics exert a depressant effect on all excitable membranes. In the clinical practice of anesthesia, a local anesthetic is applied to a specific region of the body, where it produces its primary effect: reversible depression of peripheral nerve conduction. Other actions are related to its absorption into the CVS and its subsequent actions on excitable membranes, including smooth muscle, the myocardium, and the CNS.

Following intraoral administration of 40 to 160 mg of lidocaine, the blood level rises to a maximum of approximately 1 $\mu\text{g}/\text{mL}$. (The usual range is between 0.5 and 2 $\mu\text{g}/\text{mL}$, but remember that response to drugs differs according to the individual.) Adverse reactions to the anesthetic are extremely uncommon in most individuals at these normal blood levels.

Central Nervous System Actions

The CNS is extremely sensitive to the actions of local anesthetics. As the cerebral blood level of local anesthetic increases, clinical signs and symptoms are observed.

Local anesthetics cross the blood-brain barrier, producing CNS depression. At nonoverdose levels of lidocaine (<5 $\mu\text{g}/\text{mL}$), no clinical signs or symptoms of adverse CNS effects are noted. Indeed, therapeutic advantage may be taken at blood levels between 0.5 and 4 $\mu\text{g}/\text{mL}$, because in this range lidocaine demonstrates anticonvulsant actions.⁴⁶⁻⁴⁸ The mechanism of this action is depression of hyperexcitable neurons found in the amygdala of patients experiencing a seizure.



• **Fig. 18.10** Local anesthetic blood levels and actions on the cardiovascular and central nervous systems (CNS). ECG, Electrocardiogram.

Signs and symptoms of CNS toxicity appear at a lidocaine cerebral blood level greater than 4.5 µg/mL. Generalized cortical sensitivity is noted: agitation, talkativeness, and irritability. Tonic-clonic seizures generally occur at levels greater than 7.5 µg/mL. With further increases in the lidocaine blood level, seizure activity ceases and a state of generalized CNS depression develops. Respiratory depression and arrest (apnea) are manifestations of this. [Chapter 2](#) describes the method through which a CNS-depressant drug, such as a local anesthetic, can produce clinical signs and symptoms of apparent CNS stimulation.

Cardiovascular System Actions

The CVS, specifically the myocardium, is considerably less sensitive to the actions of local anesthetics. Adverse CVS responses do not usually develop until long after adverse CNS actions have appeared.

Local anesthetics, primarily lidocaine, may be used in the management of cardiac dysrhythmias, specifically ventricular extrasystoles (premature ventricular contractions) and ventricular tachycardia. The minimum effective level of lidocaine for this action is 1.8 µg/mL, and the maximum is 5 µg/mL—the level at which undesirable actions become more likely.⁴⁹

Higher blood levels (5 to 10 µg/mL) lead to minor alterations on the electrocardiogram, myocardial depression, decreased cardiac output, and peripheral vasodilation. At lidocaine blood levels above 10 µg/mL, these effects are intensified: primarily massive peripheral vasodilation, marked reduction in myocardial contractility, severe bradycardia, and possible cardiac arrest.^{50,51}

Management

Management of all medical emergencies is predicated on attempting to keep the victim alive until he or she recovers, or until help arrives on scene to take over management. With prompt implementation of the basic emergency management protocol, a local anesthetic overdose reaction will resolve within minutes. Management of a local anesthetic overdose is based on the severity of the reaction. In most cases the reaction is mild and transitory, requiring little or no specific treatment beyond basic emergency management. In other instances, however, the reaction may be severer and longer lasting, in which case more aggressive treatment is warranted.

Most local anesthetic overdose reactions are self-limiting because the blood level in the target organs (e.g., brain myocardium) continues to decrease over time as the reaction progresses and the local anesthetic is redistributed (if the heart is still pumping effectively—as it usually is). Only rarely will drugs other than oxygen be necessary to terminate a local anesthetic overdose. Whenever signs and symptoms of overdose develop, do not simply label the patient as “allergic” to local anesthetics because this will further complicate future treatment (see p. 347).

It is well worth repeating that during and after administration of a local anesthetic the patient should remain under continual observation. Careful observation for any change in behavior after the administration of a local anesthetic allows prompt recognition and management, thus minimizing potential hazard for the patient.

Mild Overdose Reaction With Rapid Onset

An overdose in which signs and symptoms develop within 5 to 10 minutes following administration. The reaction is considered rapid in onset. Possible causes include intravascular injection (unlikely with proper injection technique), unusually rapid absorption (likely), or administration of too large a total dose (likely). If clinical manifestations do not progress beyond mild CNS excitation and consciousness is retained, significant definitive care is not necessary. The local anesthetic undergoes redistribution, with its blood level falling below the overdose level in a relatively short time.

The following are diagnostic clues to the presence of mild local anesthetic overdose:

- onset approximately 5 to 10 minutes following drug administration
- talkativeness
- increased anxiety
- facial muscle twitching
- increased heart rate, blood pressure, and respiration

Step 1: Terminate the dental procedure.

Step 2: P (position). The conscious patient is placed in a comfortable position.

Step 3: Reassurance of the patient.

Step 4: C → A → B (circulation-airway-breathing), basic life support (BLS) as needed. Patency of the circulation, airway, and breathing must be assessed and implemented, as needed. In mild local anesthetic overdose, the patient's circulation, airway, and breathing remain adequate, with no intervention necessary.

Step 5: D (definitive care).

Step 5a: Administration of O₂. At this point the fact that a lowered PaCO₂ level elevates the seizure threshold of a local anesthetic may be used to the patient's advantage. The patient should be asked to purposefully hyperventilate by deep breathing on room air or O₂ via a full-face mask or nasal hood. This can decrease the likelihood of seizures developing.

Step 5b: Monitor vital signs. The stage of postexcitation depression is mild in this form of reaction, with little or no definitive treatment required. O₂ may be administered and the patient's vital signs monitored and recorded regularly (e.g., every 5 minutes).

Step 5c: Administration of an anticonvulsant drug, if needed. The administration of an anticonvulsant, such as midazolam or diazepam, is not usually indicated in the mild overdose reaction described here. However, if the doctor is proficient in venipuncture and has little difficulty in accessing a vein, midazolam or diazepam may be administered via the intravenous route, titrated at a rate of 1 mL/min until the clinical reaction abates. Doses of intravenous drugs should always be titrated to clinical effect (in this case the cessation of muscular twitching). Small doses of intravenously administered midazolam or diazepam may prove effective.^{52,53} It must be emphasized, however, that for a mild reaction to a local anesthetic, anticonvulsant drug therapy is normally neither indicated nor desirable.

Step 5d: Summoning of emergency medical assistance. If the doctor deems emergency assistance necessary, such assistance should be sought immediately. The decision to seek help is based solely on the doctor's instinct. My recommendation is that emergency assistance should be obtained whenever an anticonvulsant drug has been administered to terminate the reaction. In addition, if signs and symptoms appear to be increasing in intensity and venous access is not available, emergency assistance is indicated.

Step 6: Recovery and discharge. The patient should be permitted to recover for as long as is necessary. The scheduled treatment may continue or, more likely, be postponed after a thorough evaluation of the patient's physical and emotional status. If the treating doctor has any doubts or concerns about the patient's condition following the reaction, medical evaluation, preferably by an emergency department physician, is indicated before that patient is discharged. If an anticonvulsant drug was administered, the patient should undergo medical evaluation before discharge and must not leave the dental office unescorted.

Mild Overdose Reaction With Delayed Onset (>10 Minutes)

If a patient exhibits signs and symptoms of a mild overdose after local anesthetic administration in the recommended manner, if adequate pain control has resulted, and if dental treatment has begun, the most likely causes are unusually rapid absorption (administration of a plain local anesthetic formulation) or the administration of too large a total dose of the drug.

Step 1: Terminate the procedure.

Step 2: P (position). The conscious patient should be allowed to assume a comfortable position.

Step 3: Reassurance of the patient.

Step 4: C → A → B (circulation, airway, breathing, circulation), basic life support (BLS), as needed. If the patient is conscious, implementation of the steps of BLS is not necessary.

Step 5: D (definitive care).

Step 5a: Administration of O₂ and instruction of the patient to hyperventilate.

Step 5b: Monitoring of vital signs.

Step 5c: Administration of an anticonvulsant, if needed.

Overdose reactions resulting from either unusually rapid absorption or administration of too large a total dose of the drug usually progress in intensity gradually and last longer than those caused by intravascular drug administration. If venous access is available, an intravenous infusion should be established and an anticonvulsant, such as midazolam or diazepam, administered via titration—at a rate of 1 mL/min—until clinical signs and symptoms abate.

Step 5d: Summoning of emergency medical assistance. When venipuncture is not practical, emergency medical assistance should be sought immediately.

Postexcitement depression is relatively mild after a mild excitatory phase. The use of an anticonvulsant to help terminate the reaction may increase the level of

postexcitation depression. Monitoring the patient and adhering to the steps of BLS are normally entirely adequate to successfully manage a mild overdose with delayed onset. In addition, O₂ should be administered. Whenever an anticonvulsant is administered, emergency medical assistance should be sought.

Step 5e: Medical consultation. After successful management of a mild overdose with slow onset, a physician should evaluate the patient's physical status.

Step 6: Recovery and discharge. The patient should be allowed to recover for as long as is necessary and be transported to a local hospital or the primary care physician's office by a responsible adult companion, such as a spouse, relative, or friend. When emergency personnel are present, they make a recommendation as to patient disposition.

Step 7: Subsequent dental treatment. Before scheduling further dental treatment in which local anesthetics may be necessary, a complete evaluation of the patient should be performed to help determine the cause of the overdose reaction.

Severe Overdose Reaction With Rapid Onset

If signs and symptoms of overdose appear almost immediately (within seconds to 1 minute) following local anesthetic administration (e.g., while the anesthetic syringe is still in the patient's mouth or within a few seconds after the injection), intravascular injection—either via the intravenous route or the intra-arterial route—is the most likely cause. Because of the extremely rapid increase in anesthetic blood level, clinical manifestations are likely to be severe. Unconsciousness, likely accompanied by seizure activity, may mark the initial clinical manifestation.

The following are diagnostic clues to the presence of severe overdose to a local anesthetic:

- signs and symptoms appearing either during injection or within seconds of its completion
- generalized tonic-clonic seizures
- loss of consciousness

Step 1: P (position). The syringe should be removed from the patient's mouth (if applicable) and the patient placed in the supine position with the feet elevated slightly. Subsequent management is based on the presence or absence of seizure activity.

Step 2: Summoning of emergency medical assistance. Whenever a seizure develops during or after local anesthetic injection, emergency assistance should be sought immediately.

When loss of consciousness is the sole clinical sign present, the patient should be placed in the supine position with the feet elevated slightly. If consciousness rapidly returns, vasodepressor syncope was the likely cause and medical assistance is usually not required. If the patient does not respond rapidly, emergency assistance should be sought as soon as possible.

Step 3: C→A→B (circulation, airway, breathing), basic life support (BLS), as needed.

Step 4: D (definitive care).

Step 4a: Administration of O₂. Adequate oxygenation and ventilation during local anesthetic-induced seizures are extremely important in terminating seizures and minimizing associated morbidity. O₂ should be administered as soon as it is available.

Ensuring adequacy of ventilation—the removal of carbon dioxide and the administration of O₂—helps minimize and prevent hypercarbia and hypoxia and maintains the seizure threshold of the anesthetic drug (local anesthetic seizure threshold is lowered if the patient becomes acidotic). In most instances of local anesthetic-induced seizures, airway maintenance and assisted ventilation are necessary (A + B), but the heart should remain functional (blood pressure and heart rate are present).

Step 4b: Protection of the patient. If seizures develop, recommended management includes the prevention of injury through protection of the arms, legs, and head. Do not attempt to place any object between the teeth of the convulsing patient. Tight, binding articles of clothing, such as ties, collars, and belts, should be loosened. Prevention of injury is a primary objective of seizure management.

The blood level of local anesthetic decreases as it is redistributed. Assuming the patient is adequately ventilated, the anesthetic blood level should fall below the seizure threshold and the seizure ceases (unless the patient has become acidotic). In most cases of local anesthetic-induced seizure, definitive drug therapy to terminate the seizure is unnecessary.

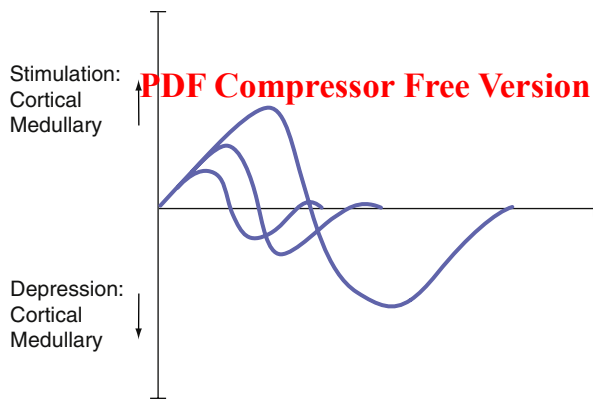
Step 4c: Venipuncture and intravenous anticonvulsant administration. Intravenous anticonvulsant administration should not be considered unless the doctor is proficient in venipuncture, has appropriate drugs available, and can recognize and manage an unconscious, apneic patient during the postseizure period. If possible, the dose of either midazolam or diazepam is titrated slowly until the seizure ends. In certain cases, however, securing a vein in a convulsing patient may prove difficult. In such situations BLS should continue until emergency medical assistance arrives (steps 3, 4a, and 4b).

Step 5: Postictal management. Following the seizure comes a period of generalized CNS depression that is usually equal in intensity to the previous degree of excitation (Fig. 18.11). During this period the patient may be drowsy or unconscious, breathing may be shallow or absent, the airway may be partially or totally obstructed, and blood pressure and heart rate may be depressed or absent (unlikely). Management is predicated on the signs and symptoms present.

The use of anticonvulsants to terminate seizures commonly increases postictal depression. Benzodiazepines—midazolam or diazepam—are the drugs of choice in seizure management.

Step 5a: C→A→B (circulation, airway, breathing), basic life support (BLS), as needed.

Step 5b: Monitoring of vital signs. Management in the postictal period requires adherence to the steps of BLS.



• **Fig. 18.11** Effects of local anesthetics on the central nervous system. Notice that the intensity of depression is equal to the intensity of the preceding stimulation. (From Bennett CR. *Monheim's Local Anesthesia and Pain Control in Dental Practice*. 7th ed. St Louis: Mosby; 1984.)

A patent airway must be maintained and O₂ or controlled ventilation administered, as needed. In addition, vital signs are monitored and recorded (every 5 minutes). If either blood pressure or pulse is absent, chest compressions are started immediately. Most commonly, however, the blood pressure and heart rate are generally depressed in the immediate postictal period, gradually returning toward baseline levels as the patient recovers.

Step 5c: Additional management considerations. If the patient's blood pressure remains depressed for an extended period (>30 minutes) and emergency medical assistance has not yet arrived, administration of a vasopressor to elevate blood pressure may be considered. Once again, this step is an option only when the doctor is well trained in the administration of vasopressors and in the recognition and management of any complications associated with their administration. A vasopressor, such as ephedrine (25 to 50 mg intramuscularly), produces a mild elevation in blood pressure, the effect lasting 1 hour or more. Administration of 1000 mL of either normal saline or a 5% dextrose and water solution via intravenous infusion is another means of elevating blood pressure and may be used in situations where proficiency with venipuncture exists.

Step 6: Recovery and discharge. Emergency medical personnel will stabilize the patient's condition before transfer, via ambulance, to the emergency department of a local hospital for definitive management, observation, and recovery.

Note: As previously discussed, the first clinical sign of a rapid elevation in local anesthetic blood level may be the loss of consciousness. When this occurs, management follows the P→C→A→B (positioning-circulation-airway-breathing) protocol. Follow-up therapy is identical to that suggested for the postseizure patient.

Severe Overdose Reaction With Slow Onset

Local anesthetic overdose that evolves slowly (over 10 minutes or more) is unlikely to progress to a point at which severe clinical signs and symptoms develop if that individual

is observed continuously and prompt management is initiated. Clinical signs and symptoms of overdose usually progress from mild to tonic-clonic seizure activity over a relatively brief period (5 minutes or less); in some cases the progression may be much less pronounced. In all cases dental treatment must cease as soon as signs and symptoms of overdose become evident.

Step 1: Terminate dental treatment. Treatment is likely to have begun before the signs and symptoms of overdose become evident. Immediately terminate the procedure and initiate emergency care.

Step 2: P (positioning). Positioning depends on the status of the patient. If the patient is conscious, initial positioning is based on comfort; however, the unconscious patient is placed in the supine position with the legs elevated slightly.

Step 3: C→A→B (circulation, airway, breathing), basic life support (BLS), as needed.

Step 4: D (definitive care).

Step 4a: Summoning of medical assistance.

Step 4b: Protect the patient from injury.

Step 4c: Administer O₂.

Step 4d: Monitor vital signs.

Step 4e: Venipuncture and administration of intravenous anticonvulsant, if available. If symptoms are mild at the onset but become progressively severer, administration of an anticonvulsant drug should be considered. The intravenous titration of midazolam or diazepam is indicated.

Step 5: Postseizure management.

Step 5a: C→A→B (circulation, airway, breathing), basic life support (BLS), as needed.

Step 5b: Monitor vital signs. Management in the postictal period of CNS, respiratory, and cardiovascular depression requires adherence to the steps of BLS. Airway patency is ensured and O₂ or controlled ventilation provided, as needed. Vital signs continue to be monitored and recorded (every 5 minutes). If blood pressure or pulse is absent, chest compression is initiated immediately. In general, blood pressure and heart rate are depressed in the immediate postictal period, gradually returning to baseline levels as recovery progresses.

Step 5c: Additional management considerations. A vasopressor (e.g., ephedrine) or infusion of intravenous fluids may be indicated if the blood pressure remains depressed for a prolonged period.

Step 6: Recovery and discharge. Emergency medical personnel stabilize and prepare the patient for transport to the emergency department of a local hospital for definitive management, recovery, and discharge.

Local anesthetic-induced seizure activity need not lead to significant morbidity or to death if the patient is properly prepared for the injection; if the individual administering the local anesthetic is well trained in the recognition and management of complications, including seizures; and if appropriate resuscitation equipment is readily available. Administration of local anesthetics without such precautions is contraindicated.

TABLE
18.8

Dilutions of Vasoconstrictors Used in Dentistry

PDF Compressor Free Version

Dilution	Drug Available	Amount (mg/mL)	Amount per 1.8-mL Cartridge (mg)	Maximum No. of Cartridges Used for Healthy Patient and Cardiac-Risk Patient (ASA Class 3 or 4)
1:1000	Epinephrine (emergency kit—anaphylaxis)	1.0	Not applicable	Not available in local anesthetic cartridge
1:10,000	Epinephrine (emergency kit—anaphylaxis)	0.1	Not applicable	Not available in local anesthetic cartridge
1:20,000	Levonordefrin	0.5	0.09	10 (H), 2 (C)
1:50,000	Epinephrine	0.02	0.036	5 (H), 1 (C)
1:100,000	Epinephrine	0.01	0.018	10 (H), 2 (C)
1:200,000	Epinephrine	0.005	0.009	20 (H), 4 (C)

ASA, American Society of Anesthesiologists; C, cardiac risk patient; H, healthy patient.

- Drugs used in management of local anesthetic overdose: O₂, anticonvulsants (e.g., midazolam or diazepam), and vasopressors, such as ephedrine, may be administered in the management of a local anesthetic overdose.
- Medical assistance required: If the reaction is mild, assistance is recommended but not necessary; if, however, the reaction is severe or if an anticonvulsant is administered to terminate the episode, emergency personnel should be sought immediately.

Overdose reactions are the most common “true” ADRs associated with administration of amide local anesthetics. Most overdose reactions are preventable through adequate pretreatment evaluation of the patient and sensible administration of these drugs. In the few instances in which clinical manifestations of overly high local anesthetic blood levels become evident, a successful outcome usually results if the condition is promptly recognized and the patient treated efficiently and effectively. Primary among the steps of management are maintenance of a patent airway and adequate oxygenation. Data indicate that if local anesthetic–induced seizures are brief and well managed, no permanent neurologic or behavioral sequelae remain postictally.⁵⁴ In other words, ischemic CNS damage is not inevitable with well-managed, brief, local anesthetic–induced seizures.

Epinephrine Overdose

Precipitating Factors and Prevention

Epinephrine and levonordefrin are the vasoconstrictors currently included in dental local anesthetic cartridges in the United States and Canada. Table 18.8 outlines the milligram per milliliter concentrations of vasoconstrictors currently used in dentistry in North America.

The optimum concentration of epinephrine for prolongation of pain control (with lidocaine) appears to be 1:400,000.⁵⁵ Use of a 1:50,000 epinephrine concentration for pain control cannot be recommended. Epinephrine

1:50,000 or 1:100,000 is useful via local infiltration for hemostasis when injected directly into the surgical site. Epinephrine or local anesthetic overdose reactions occurring under these conditions are rare.

Epinephrine overdose is more common when epinephrine is used in gingival retraction cord before impressions are taken for a crown and bridge procedure. Currently available cords contain approximately 225.5 µg of racemic epinephrine per inch of cord.⁵⁶ Epinephrine is readily absorbed through gingival epithelium that has been disturbed (abraded) by the dental procedure. About 64% to 94% of applied epinephrine is absorbed into the CVS.⁵⁶ Variability in absorption is extreme, according to the degree and duration of vascular exposure (bleeding). With regard to vasoconstrictors used for gingival retraction purposes, the American Dental Association has stated the following: “Since effective agents which are devoid of systemic effects are available, it is not advisable to use epinephrine for gingival retraction, and its use is contraindicated in individuals with a history of cardiovascular disease.”⁵⁷

Clinical Manifestations

Clinical signs and symptoms of epinephrine overdose are listed in Table 18.9.

Management

Most instances of epinephrine overdose are of such short duration that little or no formal management is necessary. On occasion, however, when the reaction is prolonged, some management is desirable.

Terminate the Procedure. If possible, remove the source of epinephrine. Stopping the injection of local anesthetic does not remove epinephrine that has been deposited; however, release of endogenous epinephrine and norepinephrine from the adrenal medulla and nerve endings is lessened once the fear-inducing stimulus is eliminated. Epinephrine-impregnated gingival retraction cord, if present, should be removed.

TABLE 18.9 Signs and Symptoms of Epinephrine or Other Vasopressor Overdose

Signs	Symptoms
Sharp elevation in blood pressure, primarily systolic	Fear, anxiety
Elevated heart rate	Tenseness
Possible cardiac dysrhythmias (premature ventricular contractions, ventricular tachycardia, ventricular fibrillation)	Restlessness Throbbing headache Tremor Perspiration Weakness Dizziness Pallor Respiratory difficulty Palpitations

Basic management follows the usual P→C→A→B→D algorithm used in the management of all medical emergencies.

P→C→A→B. Position the conscious patient comfortably. The supine position is often not desired by the patient because it tends to accentuate the CVS effects (e.g., elevates blood pressure). A semisitting or erect position minimizes any further elevation in cerebral blood pressure. C, A, and B are assessed as adequate (patient is conscious and talking).

D (definitive care)

1. Reassure the patient that the signs and symptoms are transient and will subside shortly. Anxiety and restlessness are common clinical manifestations of epinephrine overdose.
2. Monitor vital signs and administer oxygen. Blood pressure and heart rate should be monitored and recorded every 5 minutes during the episode. Striking elevations in both parameters may be noted but the levels gradually return toward the baseline. Oxygen may be administered if necessary. The patient may complain of difficulty breathing. An apprehensive patient may hyperventilate (increased rate and depth of breathing). Oxygen is not indicated in the management of hyperventilation because it can prolong symptoms, possibly leading to carpopedal tetany.
3. Recovery. Permit the patient to remain in the dental chair as long as necessary to recover. The degree of postexcitation fatigue with depression noted differs but is usually prolonged. Do not discharge the patient alone if any doubt remains about his or her ability to provide self-care.

- Drugs used in management: O₂ may be used to manage this reaction
- Medical assistance required: If the reaction is minor (only mild elevation in cardiovascular parameters), no assistance is necessary. If, however, the reaction proves severe, emergency medical personnel should be summoned.

Allergy

Allergy is a hypersensitive state, acquired through exposure to a particular allergen (anything that can provoke an allergic response is an allergen), reexposure to which produces a heightened capacity to react. Allergic reactions cover a broad spectrum of clinical manifestations ranging from mild and delayed responses occurring as long as 48 hours after exposure to the allergen to immediate and life-threatening reactions developing within seconds of exposure (Table 18.10).

Predisposing Factors

The overall incidence of allergy in the population is not low: about 15% of patients with allergy have conditions severe enough to require medical management, and some 33% of all chronic disease in children is allergic in nature.⁵⁸

Allergy to local anesthetics does occur, but its incidence has decreased dramatically since the introduction of amide anesthetics in the late 1940s. In a 1981 article, Brown et al.⁵⁹ stated that “the advent of the amino-amide local anesthetics which are not derivatives of para-aminobenzoic acid markedly changed the incidence of allergic type reactions to local anesthetic drugs. Toxic reactions of an allergic type to the amino amides are extremely rare, although cases have been reported in the literature which suggest that this class of agents can on rare occasions produce an allergic type of phenomenon.”

Allergic responses to local anesthetics include dermatitis (more common in dental office personnel), bronchospasm (asthmatic attack), and systemic anaphylaxis. The most frequently encountered are localized dermatologic reactions to topically applied local anesthetics. Life-threatening allergic responses related to local anesthetics are indeed rare.⁶⁰⁻⁶²

Hypersensitivity to the ester-type local anesthetics—procaine, propoxycaine, benzocaine, tetracaine, and related compounds such as procaine, penicillin G, and procainamide—as compared with the amide-type local anesthetics is more frequent, although still quite rare.

Amide-type local anesthetics are essentially free of this risk. However, reports from the literature and from medical history questionnaires indicate that alleged allergy to amide drugs appears to be increasing, even though subsequent evaluation of these reports usually finds them describing cases of overdose, idiosyncrasy, or psychogenic reactions.^{4,63-66} Allergy to one amide local anesthetic does not usually preclude the use of other amides, because cross-allergenicity is extremely rare.⁶⁷ There are a number of case reports that cross-sensitivity among amide local anesthetics did occur.⁶⁸⁻⁷¹ With ester anesthetic allergy, however, cross-allergenicity does occur; thus all ester-type local anesthetics are contraindicated in patients with a documented history of ester allergy.⁶⁷

Allergic reactions have been documented for the various contents of the dental cartridge. Table 18.11 lists the

TABLE 18.10 Gell and Coombs Classification of Hypersensitivity Reactions

PDF Compressor Free Version

Type	Mechanism	Principal Antibody or Cell	Time of Reactions	Clinical Examples
I	Anaphylactic (immediate, homocytotropic, antigen induced, antibody mediated)	IgE	Seconds to minutes	Anaphylaxis (drugs, insect venom, antisera) Atopic bronchial asthma Allergic rhinitis Urticaria Angioedema Hay fever
II	Cytotoxic (antimembrane)	IgG IgM (activates complement)	—	Transfusion reactions Goodpasture syndrome Autoimmune hemolysis Hemolytic anemia Certain drug reactions Membranous glomerulonephrosis
III	Immune complex (serum sickness–like)	IgG (forms complexes with complement)	6–8 h	Serum sickness Lupus nephritis Occupational allergic alveolitis Acute viral hepatitis
IV	Cell-mediated (delayed) or tuberculin-type response	—	48 h	Allergic contact dermatitis Infectious granulomas (tuberculosis, mycoses) Tissue graft rejection Chronic hepatitis

Modified from Gell RGH and Coombs RRA (eds): *Clinical Aspects of Immunology*; Oxford, England: Blackwell; 1963.

TABLE 18.11 Contents of Local Anesthetic Cartridge

Ingredient	Function
Local anesthetic agent	Conduction blockade
Vasoconstrictor	Decreases absorption of local anesthetic into blood, thus increasing depth and duration of anesthesia and decreasing toxicity of anesthetic
Sodium metabisulfite	Antioxidant for vasoconstrictor
Methylparaben ^a	Preservative to increase shelf life; bacteriostatic
Sodium chloride	Isotonicity of solution
Sterile water	Diluent

^aMethylparaben has been excluded from all local anesthetic cartridges manufactured in the United States since January 1984, although it is still found in multidose vials of drugs.

functions of these components. Of special interest with regard to allergy is the bacteriostatic agent methylparaben. The parabens (methylparaben, ethylparaben, and propylparaben) are included, as bacteriostatic agents, in all multiple-use formulations of drugs, cosmetics, and some foods. Their increasing use has led to more frequent sensitization to them. In evaluating local anesthetic allergy, Aldrete and Johnson⁷² demonstrated positive reactions to methylparaben but

TABLE 18.12 Frequency of Dermal Reactions in Patients Exposed to Various Local Anesthetic Agents

Agent	Nonallergic Patients (N = 60)	Allergic Patients (N = 11)
NaCl	0	0
Procaine	20	8
Chloroprocaine	11	8
Tetracaine	25	8
Lidocaine	0	0
Mepivacaine	0	0
Prilocaine	0	0
Methylparaben	8	Not available

Data from Aldrete JA, Johnson DA. Evaluation of intracutaneous testing for investigation of allergy to local anesthetic agents. *Anesth Analg*. 1970;49:173–183.

negative reactions to the amide anesthetic without the bacteriostatic agent. Table 18.12 presents Aldrete and Johnson's dermal reaction findings in patients exposed to various ester and amide local anesthetic solutions. Aldrete and Johnson reported no signs of systemic anaphylaxis occurring in any of the patients. The dental local anesthetic cartridges available in the United States and Canada are single-use items, and as such no longer contain paraben preservatives.

Sodium Bisulfite Allergy

Allergy to sodium bisulfite or sodium metabisulfite is being reported today. Both are antioxidants that are commonly sprayed onto prepared fruits and vegetables to keep them appearing “fresh” for long periods. For example, apple slices sprayed with bisulfite do not turn brown (become oxidized). People who are allergic to bisulfites (most often steroid-dependent asthmatics) may develop a severe response (bronchospasm).^{75,77} In 1986 the FDA enacted regulations limiting use of bisulfites on foods.⁷⁸ A history of allergy to bisulfites should alert the dentist to the possibility of this same type of response if sodium bisulfite or sodium metabisulfite is included in the local anesthetic solution. Sodium bisulfite or sodium metabisulfite is found in all dental local anesthetic cartridges that contain a vasoconstrictor, and is not found in plain local anesthetic solutions (e.g., 3% mepivacaine, 4% prilocaine).

In the presence of a documented sulfite allergy, it is suggested that a local anesthetic solution without a vasoconstrictor (“plain local anesthetic”) should be used (e.g., 3% mepivacaine hydrochloride, 4% prilocaine hydrochloride) if possible.

No cross-allergenicity is present between sulfites and the “sulfa-” type antibiotics (sulfonamides).

Epinephrine Allergy

It is commonly stated that “allergy to epinephrine cannot occur in a living person.” However unlikely true, documented, and reproducible allergy to epinephrine may be, several published case reports seem to show that it can occur.⁷⁹

Questioning of the “epinephrine-allergic” patient (see “Dialogue History,” p. 350) immediately reveals signs and symptoms related to increased blood levels of circulating catecholamines (tachycardia, palpitation, sweating, nervousness), likely the result of fear of receiving injections (release of endogenous catecholamines [epinephrine and norepinephrine]). Management of the patient’s fears of injection (“the shot”) is in order in most of these situations.

Latex Allergy

The thick plunger (also known as the *stopper* or *bung*) at one end of the local anesthetic cartridge and the thin diaphragm at the other end of the cartridge (see Fig. 7.1), through which the needle penetrates, at one time contained latex. Because latex allergy is a matter of concern among all health care professionals, the risk of provoking an allergic reaction in a latex-sensitive patient must be considered. A review of the literature on latex allergy and local anesthetic cartridges by Shojaei and Haas⁷⁶ revealed that latex allergen can be released into the local anesthetic solution as the needle penetrates the diaphragm, but no reports or case studies have described an allergic response to the latex component of the cartridge containing a dental local anesthetic.

All dental local anesthetic cartridges presently available (January 2019) in the United States and Canada are latex-free.

Topical Anesthetic Allergy

Topical anesthetics possess the potential to induce allergy. The most commonly used topical anesthetics in dentistry are esters, such as benzocaine and tetracaine. The incidence of allergy to this class of local anesthetics, though quite low, far exceeds that for amide local anesthetics. However, because benzocaine (an ester topical anesthetic) is poorly absorbed systemically, allergic responses that develop in response to its use are normally limited to the site of application.⁸⁰ When other topical formulations, ester or amide, that are absorbed systemically are applied to mucous membranes, allergic responses may be localized or systemic. Many contain preservatives such as methylparaben, ethylparaben, or propylparaben.

Prevention

Medical History Questionnaire

Most medical history questionnaires contain several questions related to allergy.

Question

Are you allergic to (e.g., have itching, rash, swelling of hands, feet, or eyes) or made sick by penicillin, aspirin, codeine, or any other medications?

Question

Have you ever had asthma, hay fever, sinus trouble, or allergies or hives?

These questions seek to determine whether the patient has experienced any ADRs. ADRs are not uncommon; those most frequently reported are labeled by the patient as an allergy. If the patient mentions any unusual reaction to local anesthetics, the following protocol should be observed before the questionable drug is used. If the patient relates a history of alleged local anesthetic allergy, it is imperative that the dentist consider the following factors:

1. Assume that the patient *is* truly allergic to the drug in question and then take whatever steps are necessary to determine whether the alleged “allergy” is indeed an allergy. A 2010 article on food allergy revealed that 30% of Americans have reported (alleged) one or more food allergies, but true food allergy in the US population actually occurs at a rate of approximately 4% in adults and 5% in children.⁸¹
2. Any drug or closely related drug to which a patient claims to be allergic must not be used until the alleged allergy can be absolutely disproved to the satisfaction of *both* the doctor and the patient.
3. For almost all drugs commonly implicated in allergic reactions, equally effective alternative drugs exist (e.g., antibiotics, analgesics).
4. The only drug group in which alternatives are not equally effective is local anesthetics.

Two major components are useful for determining the veracity of a claim of allergy: (1) dialogue history, whereby additional information is sought directly from the patient; and (2) consultation for a more thorough evaluation if doubt persists.

Dialogue History

The following questions are included in the dialogue history between the dentist and patient in the following case study on local anesthetics. The first two questions are the most critical, for they immediately establish in the evaluator's mind a sense of whether an allergy does or does not exist.⁸²

Question

Describe exactly what happened. (Describe your "allergic" reaction.)

Question

What treatment was given?

Following these two questions, the evaluator may consider others that will help elucidate the actual reaction.

Question

What position were you in during injection of the local anesthetic?

Question

What was the time sequence of events?

Question

Were the services of emergency medical personnel necessary?

Question

What drug was used?

Question

What volume of the drug was administered?

Question

Did the local anesthetic solution contain a vasoconstrictor?

Question

Were you taking any other drugs or medications at the time of the incident?

Question

Can you provide the name, address, and telephone number of the dentist or physician who was treating you when the incident occurred?

Answers to these questions usually provide enough information to permit a doctor to make an informed determination as to whether a true allergic reaction to a drug occurred. This is the initial step in managing alleged local anesthetic allergy. The dialogue history follows.

Question

Describe exactly what happened.

This is probably the most important question because it allows the patient to describe the actual sequence of events. The "allergy," in most instances, is explained by the answer to this question. The symptoms described by the patient should be recorded and evaluated to help

in formulating a tentative diagnosis of the adverse reaction. Did the patient lose consciousness? Did convulsions occur? Was there skin involvement or respiratory distress? The manifestations of allergic reactions are discussed in the following paragraph. Knowing them can aid the evaluator in rapidly determining the nature of the reaction that occurred.

Allergic reactions involve one or more of the following: skin (itching, hives, rash, edema), gastrointestinal system (cramping, diarrhea, nausea, vomiting), exocrine glands (runny nose, watery eyes), respiratory system (wheezing, laryngeal edema), and CVS (angioedema, vasodilation, hypotension).

Most patients describe their local anesthetic "allergy" as one in which they experienced palpitations, severe headache, sweating, and mild shaking (tremor). Such reactions are almost always of psychogenic origin or are related to the administration of overly large doses of a vasoconstrictor (e.g., epinephrine). They are not allergic in nature. Hyperventilation, an anxiety-induced reaction in which patients lose control over their breathing (inhaling and exhaling rapidly and deeply), is accompanied by dizziness, lightheadedness, and peripheral paresthesias (fingers, toes, and lips). Complaints of itching, hives, rash, or edema lead to the presumptive conclusion that an allergic reaction may actually have occurred.

Question

What treatment was given?

When the patient is able to describe his or her management, the evaluator usually can determine its cause. Were drugs injected? If so, what drugs? Epinephrine, histamine blockers, corticosteroids, or anticonvulsants? Was aromatic ammonia used? Was oxygen used? Knowledge of the specific management of these situations can lead to an accurate diagnosis.

The drugs used in the management of allergic reactions include three categories: vasoconstrictors (epinephrine [Adrenalin]), histamine blockers (diphenhydramine [Benadryl] or chlorpheniramine [Chlor-Trimeton]), and corticosteroids (hydrocortisone sodium succinate [Solu-Cortef] or dexamethasone [Decadron]).

Mention of the use of one or more of these drugs increases the likelihood that an allergic response did occur. Anticonvulsants, such as diazepam or midazolam, are administered intravenously to terminate local anesthetic-induced seizures. Aromatic ammonia is frequently used in the treatment of syncopal episodes. Oxygen may be administered in any or all of these reactions but is not specific for allergy.

Question

What position were you in when the reaction occurred?

Injection of a local anesthetic into an upright patient is most likely to produce a psychogenic reaction (vasodepressor syncope). This does not exclude the possibility that another type of reaction may occur, but with the patient supine during the injection, vasodepressor syncope is a less likely cause, even though transient loss of consciousness

may (on very rare occasions) occur in these circumstances.⁸³ In some of the evaluations of “allergy to local anesthetics” that the author has conducted, a patient had been given an intracapsular injection of corticosteroid in the knee. Seated upright on a table in the physician’s treatment room, the patient was able to watch the entire procedure, which was profoundly disturbing. In an effort to make such injections more tolerable, lidocaine or another local anesthetic is added to the steroid mixture. In spite of this, however, the intracapsular injection of corticosteroid and lidocaine is extremely uncomfortable. Many patients experience their “allergic reaction” at this time. Therefore the supine position is recommended as being physiologically best tolerated for the administration of all local anesthetic injections.

Question

What was the time sequence of events?

When, in relation to administration of the local anesthetic, did the reaction occur? Most adverse drug reactions associated with local anesthetic administration occur during or immediately (within seconds) after the injection. Syncope, hyperventilation, overdose, and (sometimes) anaphylaxis are most likely to develop immediately during the injection or within minutes thereafter, although all may occur later, during dental therapy. Also, seek to determine the amount of time that elapsed during the entire episode. Was the patient discharged from the office alone or was an ambulance summoned? How long was it before the patient was discharged from the office? Did dental treatment continue after the episode? The fact that dental treatment continued after the episode indicates that the response was probably minor and of a nonallergic nature.

Question

Were the services of a physician, emergency medical services, or a hospital necessary?

A positive response to this usually indicates the occurrence of a more serious reaction. Most psychogenic reactions are ruled out by a positive answer, although an overdose or allergic reaction may indeed have occurred.

Question

What local anesthetic was administered?

A patient who is truly allergic to a drug should be told the exact (generic) name of the substance. Many persons with documented allergic histories wear a medical alert tag or bracelet (Fig. 18.12) that lists specific items to which they are sensitive. However, some patients respond to this question with, “I’m allergic to local anesthetics” or “I’m allergic to Novocain” or “I’m allergic to all ‘caine’ drugs.” Of 59 patients reporting allergy to local anesthetics, 54 could name one or more local anesthetics they believed were responsible. Five referred to only “caine” drugs.⁸⁴ Novocaine (procaine) and other ester local anesthetics are rarely—if ever—used by injection in dentistry (although the esters maintain some popularity in medicine and the intranasal local anesthetic mist uses tetracaine (see Chapter 20). Amide local



• Fig. 18.12 MedicAlert bracelet. (From <https://www.medicalert.org>.)

anesthetics have replaced the esters in the clinical practice of dentistry. Yet patients throughout the world commonly call the local anesthetics they receive “shots of Novocain.” Two reasons exist for this. First, many older patients at one time received Novocain as a dental local anesthetic, and its name has become synonymous with intraoral dental injections. Second, although US dentists do not inject procaine or procaine-propoxycaïne, many still describe local anesthetics as Novocain when talking with their patients. Thus the usual response of a patient to this question remains, “I’m allergic to Novocain.” This response, received from a patient who had been managed properly in the past after an adverse reaction, indicates that the patient was sensitive to ester local anesthetics but not necessarily to amide local anesthetics. However, the answers are usually too general and vague for any conclusions to be drawn.⁸⁵ Canadian dentists describe the local anesthetic injection in a much more descriptive manner, saying “I’m going to freeze you now.”

Question

What amount of drug was administered?

This question seeks to determine whether there was a definite dose-response relationship, as might occur with an overdose reaction. The problem is that patients rarely know these details and can provide little or no assistance. The doctor who was involved in the prior episode(s) may be of greater assistance.

Question

Did the anesthetic solution contain a vasoconstrictor or preservative?

The presence of a vasoconstrictor might lead to the thought of an overdose reaction (relative or absolute) to this

component of the solution. A preservative, such as methylparaben (if a multidose vial was used) or sodium bisulfite (if the solution was in a cartridge), could lead to the belief that an allergic reaction to the preservative, not to the local anesthetic, did occur. Unfortunately, however, most patients are unable to furnish this information. Today, methylparaben is found only in multidose vials of local anesthetics (and most other drugs). Bisulfites are found in all dental local anesthetic cartridges containing a vasoconstrictor.

Question

Were you taking any other drugs or medications at the time of the reaction?

This question seeks to determine the possibility of a drug-drug interaction or a side effect of another drug being responsible for the reported adverse response. Reidenburg and Lowenthal⁸⁶ reporting in 1968 on adverse nondrug reactions demonstrated that “adverse” effects and side effects, which so often are blamed on medications, occur with considerable regularity in persons who have received no drugs or medications for weeks. This study was replicated by Meyer et al.⁸⁷ in 1996. In other words, many so-called adverse drug reactions may be nothing more than a coincidental event: the person is becoming overly tired, irritable, nauseated, or dizzy for reasons unrelated to drugs. Unfortunately, however, it seems that whenever such symptoms develop in a patient taking a medication, the drug is immediately thought to be responsible, with the label “allergy” often applied.

Question

Can you provide the name and address of the dentist, physician, or hospital treating you at the time of the incident?

If possible, it is usually valuable to speak to the person who managed the previous episode. In most instances, this person is able to locate patient records and describe in detail what transpired. If it is not possible to locate or contact the doctor, the patient’s primary care physician should be consulted. Direct discussion with the patient and the doctor can provide a wealth of information that the knowledgeable dentist can use to determine more precisely the nature of the previous reaction.

QUESTIONS FOR THE PATIENT WITH AN ALLEGED ALLERGY TO LOCAL ANESTHETIC

1. Describe your reaction.

Itching, hives, rash, feeling faint, dizziness, light-headedness, perspiration, shaking, palpitation

2. How was your reaction treated?

Epinephrine, histamine blocker, corticosteroid, oxygen, spirits of ammonia (“smelling salts”), no treatment necessary

3. What position were you in at the time of the reaction?

Supine, upright, partially reclined

4. What is the name, address, and telephone number of the doctor in whose office this reaction occurred?

Consultation and Allergy Testing

Consultation should be considered if any doubt remains as to the cause of the reaction after the dialogue history. Referral to a physician (e.g., allergist, dermatologist) who can test for allergy to local anesthetics is recommended.

Although no form of allergy testing is 100% reliable, skin testing is the primary mode of assessing a patient for local anesthetic allergy. Intracutaneous injections are among the most reliable means available, because they are 100 times more sensitive than cutaneous testing and involve depositing 0.1 mL of test solution into the patient’s forearm.^{4,84,88-91} In all such instances the local anesthetic solutions should contain neither a vasoconstrictor nor a preservative. Methylparaben, if evaluated, should be tested separately.⁹²

The protocol for intracutaneous testing for local anesthetic allergy used at the Herman Ostrow School of Dentistry of the University of Southern California for the past 35 years involves administration of 0.1 mL of each of 0.9% sodium chloride, 1% or 2% lidocaine, 3% mepivacaine, and 4% prilocaine, without methylparaben, bisulfites, or vasoconstrictors. After successful completion of this phase of testing, 0.9 mL of one of the previously mentioned local anesthetic solutions that produced no reaction is injected intraorally via supraperiosteal infiltration atraumatically (but without topical anesthesia) above a maxillary right or left premolar or anterior tooth. This is called an *intraoral challenge test*, and it frequently provokes the “allergic” reaction: fainting, sweating, and palpitations.

After performing 221 local anesthetic allergy testing procedures, the author has encountered four allergic responses to the paraben preservative (before 1984 the protocol included testing for parabens) and none to the amide local anesthetic itself. Numerous psychogenic responses (syncope, hyperventilation, palpitations) have been observed during intracutaneous or intraoral testing phases.

Such testing should be performed by a trained health care professional who is knowledgeable about the procedure and is fully prepared to manage whatever adverse reactions may develop. It must be remembered that skin testing is not without risk. Severe immediate allergic reactions may be precipitated by as little as 0.1 mL of drug in a truly sensitized patient. Emergency drugs, equipment, and trained personnel must always be available whenever allergy testing is performed.

Intracutaneous allergy testing should be performed only after an intensive dialogue history in which the evaluator has become convinced that the prior reaction to the local anesthetic was *not* allergic in nature. The testing procedure is used to confirm this fact for the patient. The intraoral challenge test was added to the protocol when several patients with negative responses to intracutaneous testing stated, “But the dentist will give me a larger amount in my mouth.” It was intended to provide the patient with the psychological support needed to receive intraoral local anesthetic injections safely.

Informed consent is obtained before allergy testing. This consent includes, among other possible complications, acute allergy (anaphylaxis), cardiac arrest, and death.

A continuous intravenous infusion is started before all allergy testing procedures are performed, and emergency drugs and equipment are readily available.

Dental Management in the Presence of Alleged Local Anesthetic Allergy

When doubt persists concerning a history of allergy to local anesthetics, do not administer these drugs to the patient. Assume that allergy exists. Do not use local anesthetics, including topical anesthetics, unless and until allergy has been absolutely disproved—to the patient's satisfaction.

Elective Dental Care

Dental treatment requiring local anesthesia (topical or injectable) should be postponed until a thorough evaluation of the patient's "allergy" is completed. Dental care not requiring either topical or injectable local anesthesia may be completed during this time.

Emergency Dental Care

Pain or oral infection presents a more difficult situation in the "I am allergic to Novocain" patient. Commonly, this patient is new to the dental office, requiring tooth extraction, pulpal extirpation, or incision and drainage of an abscess, with an unremarkable medical history except for the alleged "allergy to Novocain." If, after dialogue history, the "allergy" appears to have been a psychogenic reaction but some doubt remains, consider one of several courses of action.

Emergency Protocol No. 1

The most practical approach to this patient is to provide no treatment of an invasive nature. Arrange an appointment for immediate consultation and allergy testing. Do not perform any dental care requiring the use of injectable or topical local anesthetics. For incision and drainage of an abscess, inhalation sedation with nitrous oxide and oxygen can be an acceptable alternative.

Acute pain may be managed with oral analgesics (e.g., nonsteroidal antiinflammatory drugs), and infection with oral antibiotics. These constitute only temporary measures. After complete evaluation of the "allergy," definitive dental care may proceed.

Emergency Protocol No. 2

Use general anesthesia in place of local anesthesia for management of a dental emergency. When properly used, general anesthesia is a highly effective and relatively safe alternative. Its lack of availability is a major problem in most dental practices.

When general anesthesia is used, be careful to avoid local anesthetics in these procedures:

1. topical application (via spray) to the pharynx and tracheal mucosa immediately before intubation
2. infiltration of the skin with local anesthetic before venipuncture to decrease discomfort

General anesthesia, administered in the dental office or in a hospital operating theater, is a viable short-term alternative to local anesthetic administration in managing the "allergic"

patient, provided adequate facilities and well-trained personnel are available.

Emergency Protocol No. 3

Histamine blockers used as local anesthetics should be considered if general anesthesia is not available, and if it is necessary to intervene physically in the dental emergency. Most injectable histamine blockers have local anesthetic properties. Diphenhydramine hydrochloride in a 1% solution with epinephrine 1:100,000 provides pulpal anesthesia for up to 30 minutes.^{71,93} Although the quality of soft tissue and hard tissue anesthesia attained with diphenhydramine, lidocaine, or prilocaine is equivalent, an undesirable side effect frequently noted during injection of diphenhydramine is a burning or stinging sensation, which limits the use of this agent for most patients to emergency procedures only.⁹⁴⁻⁹⁶ Nitrous oxide and oxygen used along with diphenhydramine minimize patient discomfort while increasing the pain reaction threshold. Another (possibly positive) side effect of diphenhydramine is CNS depression (sedation, drowsiness), which may prove somewhat beneficial during treatment but mandates that a responsible adult guardian be available to take the patient home after treatment.

Management of the Patient With Confirmed Allergy

Management of the dental patient with a confirmed allergy to local anesthetics differs according to the nature of the allergy. If the allergy is limited to ester anesthetics, an amide anesthetic may be used (provided it does not contain a paraben preservative, which is closely related to the esters). No dental local anesthetic cartridge manufactured in the United States since January 1984 contains methylparaben.

If allergy does truly exist to an ester local anesthetic (a much more likely situation), dental treatment may be safely completed via one of the following:

1. administration of an amide local anesthetic
2. use of histamine blockers as local anesthetics
3. general anesthesia
4. alternative techniques of pain control:
 - a. hypnosis
 - b. acupuncture

On occasion, it is reported that a patient is "allergic to all 'caine' drugs." Such a report should provoke close scrutiny by the dentist, and the method by which this conclusion was reached should be reexamined.

All too often, patients are mislabeled as "allergic to local anesthetics." Such patients ultimately must have dental treatment performed in a hospital setting, usually under general anesthesia, when a proper evaluation might have saved the patient time and money and decreased the risk of dental care.^{61,85}

Clinical Manifestations

Table 18.10 lists the various forms of allergic reactions. It is also possible to classify allergic reactions by the time elapsing between contact with the antigen (allergen) and onset

of clinical manifestations of allergy. Immediate reactions develop within seconds to hours of exposure. (They include types I, II, and III.) In contrast, with delayed reactions, clinical manifestations develop hours to days after antigenic exposure (type IV).

Immediate reactions, particularly type I, anaphylaxis, are significant. Organs and tissues involved in immediate allergic reactions include the skin, CVS, respiratory system, and gastrointestinal system. Generalized (systemic) anaphylaxis involves all these systems. Type I reactions may involve only one system, in which case they are referred to as *localized anaphylaxis*. Examples of localized anaphylaxis and their “targets” include bronchospasm (respiratory system) and urticaria (skin).

Time of Onset of Symptoms

The time elapsing between a patient’s exposure to the antigen and the development of clinical signs and symptoms is important. In general, the more rapidly signs and symptoms develop following antigenic exposure, the more intense the reaction is likely to be.⁹⁷ Conversely, the more time between exposure and onset, the less intense the reaction. Cases have been reported of systemic anaphylaxis arising many hours after exposure.⁹⁸

The rate of progression of signs and symptoms once they appear is also significant. Situations in which signs and symptoms rapidly increase in intensity are likely to be more life threatening than situations in which they progress slowly or not at all once they appear.

Signs and Symptoms

Dermatologic Reactions

The most common allergic drug reaction associated with local anesthetic administration consists of urticaria and angioedema. Urticaria is associated with wheals, which are smooth, elevated patches of skin. Intense itching (pruritus) is frequently present. Angioedema is localized swelling in response to an allergen. Skin color and temperature are usually normal (unless urticaria or erythema is present). Pain and itching are uncommon. Angioedema most frequently involves the face, hands, feet, and genitalia, but it can also involve the lips, tongue, pharynx, and larynx. It is more common following application of topical anesthetics to oral mucous membranes. Within 30 to 60 minutes, the tissue in contact with the allergen appears swollen.

Allergic skin reactions, if the sole manifestation of an allergic response, are normally not life threatening; however, those that occur rapidly after drug administration may be the first indication of a more generalized reaction to follow.

Angioedema involving intraoral soft tissues (e.g. tongue, pharynx, larynx) is potentially life-threatening as airway compromise may develop.⁹⁹

Respiratory Reactions

Clinical signs and symptoms of allergy may be solely related to the respiratory tract, or respiratory tract involvement may occur along with other systemic responses.

The signs and symptoms of bronchospasm, the classic respiratory allergic response, include:

- respiratory distress
- dyspnea
- wheezing
- erythema
- cyanosis
- diaphoresis
- tachycardia
- increased anxiety
- use of accessory muscles of respiration

Laryngeal edema, an extension of angioneurotic edema to the larynx, is a swelling of the soft tissues surrounding the vocal apparatus with subsequent obstruction of the airway. Little or no exchange of air from the lungs is possible. Laryngeal edema represents the effects of allergy on the upper airway, whereas bronchospasm represents the effects on the lower airway (smaller bronchioles). Laryngeal edema is a life-threatening emergency.

Generalized Anaphylaxis

The most dramatic and acutely life-threatening allergic reaction is generalized anaphylaxis. Clinical death can occur within a few minutes. Generalized anaphylaxis can develop after administration of an antigen by any route but is more common after parenteral administration (injection). The time of response is variable, but the reaction typically develops rapidly, reaching maximum intensity within 5 to 30 minutes. It is unlikely that this reaction will ever be noted after administration of amide local anesthetics.

The signs and symptoms of generalized anaphylaxis, listed according to their typical progression, are:

- skin reactions
- smooth muscle spasm of the gastrointestinal (cramping) and genitourinary tracts and of respiratory smooth muscle (bronchospasm)
- respiratory distress
- cardiovascular collapse

In fatal anaphylaxis, respiratory and cardiovascular disturbances predominate and are evident early in the reaction. The typical reaction progression is shown in [Box 18.5](#).

In rapidly developing anaphylaxis, all signs and symptoms may occur within a very short time with considerable overlap. In particularly severe reactions, respiratory and cardiovascular signs and symptoms may be the only ones present. The reaction or any part of it can last from minutes to 1 day or longer.^{97,100}

With prompt and appropriate treatment, the entire reaction may be terminated rapidly. However, hypotension and laryngeal edema may persist for hours to days despite intensive therapy. Death, which may occur at any time during the reaction, is usually secondary to upper airway obstruction produced by laryngeal edema.¹⁰¹

Management

Skin Reactions

Management is predicated on the rate at which the reaction appears after antigenic challenge.

• **BOX 18.5** Typical Reaction Progression of Generalized Anaphylaxis
PDF Compressor Free Version

- 1. Early phase: skin reactions:**
 - a. Patient complains of feeling sick
 - b. Intense itching (pruritus)
 - c. Flushing (erythema)
 - d. Giant hives (urticaria) over the face and upper chest
 - e. Nausea and possibly vomiting
 - f. Conjunctivitis
 - g. Vasomotor rhinitis (inflammation of mucous membranes in the nose, marked by increased mucous secretion)
 - h. Pilomotor erection (feeling of hair standing on end)
- 2. Associated with skin responses are various gastrointestinal or genitourinary disturbances related to smooth muscle spasm:**
 - a. Severe abdominal cramps
 - b. Nausea and vomiting
 - c. Diarrhea
 - d. Fecal and urinary incontinence
- 3. Respiratory symptoms usually develop next:**
 - a. Substernal tightness or pain in chest
 - b. Cough may develop
 - c. Wheezing (bronchospasm)
 - d. Dyspnea
 - e. If the condition is severe, cyanosis of the mucous membranes and nail beds
 - f. Possible laryngeal edema
- 4. The cardiovascular system is next to be involved:**
 - a. Pallor
 - b. Lightheadedness
 - c. Palpitations
 - d. Tachycardia
 - e. Hypotension
 - f. Cardiac dysrhythmias
 - g. Unconsciousness
 - h. Cardiac arrest

Delayed Skin Reactions

Signs and symptoms developing 60 minutes or longer after exposure usually do not progress and are not considered life threatening. Examples include a localized mild skin and mucous membrane reaction after application of topical anesthetic. In most instances the patient may already have left the dental office and is calling back later describing these signs and symptoms, or the patient may still be in the dental office at the conclusion of his or her treatment.

Basic management follows the usual P→C→A→B→D algorithm used in management of all medical emergencies—[Box 18.6](#).

P→C→A→B. Position the conscious patient comfortably. C, A, and B are assessed as adequate (patient is conscious and talking).

D (definitive care)

1. Oral histamine blocker: 50 mg diphenhydramine. A prescription for diphenhydramine, 50 mg capsules, one every 6 hours for 3 to 4 days should be given to the patient.
2. If the patient is still in the dental office, the patient should remain in the office under observation for 1 hour before discharge to ensure that the reaction does not progress.

• **BOX 18.6** Basic Emergency Management

P...POSITION

- ↓ Unconscious...supine with feet elevated slightly
- ↓ Conscious...based on patient comfort

C...CIRCULATION

- ↓ Unconscious...assess and provide chest compression if necessary
- ↓ Conscious...assess circulation

A...AIRWAY

- ↓ Unconscious...assess and maintain airway
- ↓ Conscious...assess airway

B...BREATHING

- ↓ Unconscious...assess and ventilate if necessary
- ↓ Conscious...assess breathing

D...DEFINITIVE CARE

Diagnosis

Management: emergency drugs and/or assistance (emergency medical services, dial 9-1-1)

3. Obtain medical consultation, if necessary, to determine the cause of the reaction. A complete list of all drugs and chemicals administered to or taken by the patient should be compiled for use by the allergy consultant.
4. If drowsiness occurs after oral histamine blocker administration, the patient should not be permitted to leave the dental office unescorted.

Immediate Skin Reactions

Signs and symptoms of allergy developing within 60 minutes require more vigorous management. Examples include conjunctivitis, rhinitis, urticaria, pruritus, and erythema.

P→C→A→B. Position the conscious patient comfortably. C, A, and B are assessed as adequate (patient is conscious and talking).

D (definitive care)

1. Administer parenteral (intramuscular, intravenous) histamine blocker: 50 mg diphenhydramine (25 mg if weight up to 30 kg [66 lb]) or 10 mg chlorpheniramine (5 mg if weight up to 30 kg [66 lb]) in the vastus lateralis muscle.
2. Monitor and record vital signs (blood pressure, heart rate and rhythm, respiratory rate) every 5 minutes for 1 hour.
3. Observe the patient for a minimum of 60 minutes for evidence of recurrence. Discharge the patient in the custody of a responsible adult if any parenteral drugs have been given.
4. Prescribe an oral histamine blocker for 3 days.
5. Fully evaluate the patient's reaction before further dental care is provided.
6. If at any time during this period uncertainty exists as to the condition of the patient, activate emergency medical services (dial 9-1-1).

Respiratory Reactions

Bronchospasm

P→C→A→B. Position the conscious patient comfortably. Most persons experiencing respiratory distress prefer to be seated upright to varying degrees. C, A, and B are assessed. C is



• **Fig. 18.13** Bronchodilator inhaler (albuterol).

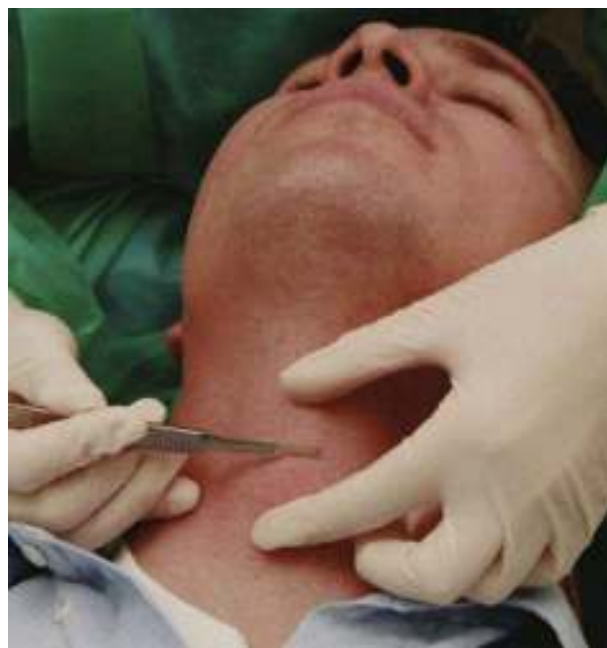assessed as adequate. The airway is patent, although the patient is exhibiting respiratory distress.

D (definitive care)

1. Terminate dental treatment (if started).
2. Administer oxygen via a full face mask, nasal hood, or nasal cannula at a flow of 5 to 6 L/min.
3. Administer epinephrine intramuscularly in the vastus lateralis muscle (0.3 mg if weight more than 30 kg; 0.15 mg if weight up to 30 kg) or another appropriate bronchodilator via a metered dose inhaler (albuterol) (Fig. 18.13). The dose may be repeated every 5 to 10 minutes until recovery or help (emergency medical services) arrives on the scene to take over management.
4. Activate emergency medical services (dial 9-1-1). If you are alone with victim, it is important to administer epinephrine *before* activating emergency medical services.
5. On recovery (bronchospasm resolves), administer a histamine blocker to minimize the risk of relapse (50 mg diphenhydramine intramuscularly [25 mg if weight up to 30 kg]).
6. Emergency medical services will evaluate the patient's status and will determine whether transport to the hospital emergency department for observation or additional treatment is warranted.

Laryngeal Edema

Laryngeal edema may be present when movement of air through the patient's nose and mouth cannot be heard or felt in the presence of spontaneous respiratory movements, or when it is impossible to perform artificial ventilation in the presence of a patent airway (tongue not causing obstruction). Partial obstruction of the larynx produces stridor (a characteristic high-pitched crowing sound), in contrast to the wheezing associated with bronchospasm. A partial obstruction may gradually or rapidly progress to total obstruction accompanied by the ominous "sound" of silence (in the presence of spontaneous respiratory movements). The patient rapidly loses consciousness from lack of oxygen.



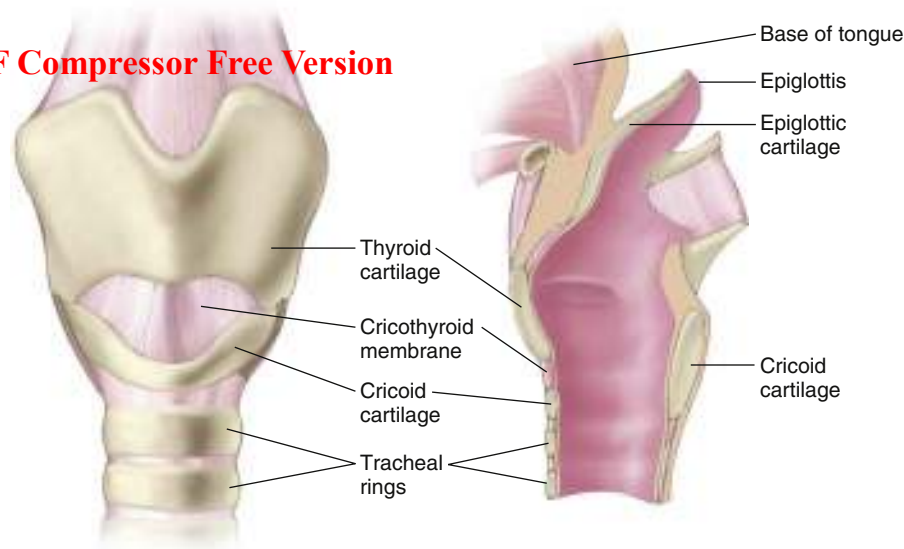
• **Fig. 18.14** With fingers placed on the thyroid and cricoid cartilages, a horizontal incision is made through the cricothyroid membrane to gain access to the trachea.

P→C→A→B. Position the unconscious patient supine. C, A, and B are assessed. If the airway is maintained and spontaneous respiratory movement is seen but no air is being exchanged, immediate and aggressive treatment is required to save the patient's life.

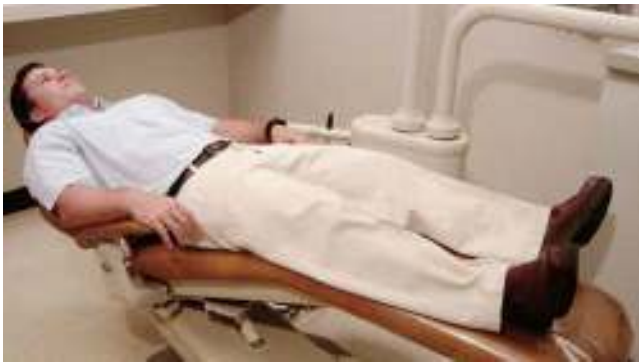D (definitive care)

1. Epinephrine. Administer 0.3 mg (if weight greater than 30 kg or 0.15 mg (if weight up to 30 kg) epinephrine intramuscularly in the vastus lateralis muscle. Epinephrine may be administered every 5 to 10 minutes as needed until recovery, or until help (dial 9-1-1) arrives on the scene to take over management.
2. Following administration of epinephrine, activate emergency medical services. Summon emergency medical assistance and administer oxygen.
3. Maintain the airway. If it is only partially obstructed, epinephrine may halt the progress of the edema through its vasoconstrictive actions.
4. Additional drug management: histamine blocker intramuscularly or intravenously (50 mg diphenhydramine), corticosteroid intramuscularly or intravenously (100 mg hydrocortisone sodium succinate to inhibit and decrease edema and capillary dilation).
5. Perform cricothyrotomy. If the preceding steps have failed to secure a patent airway, an emergency procedure to create an airway is critical for survival. Figs. 18.14 and 18.15 illustrate the anatomy of the region and the technique. Once established, the airway must be maintained, oxygen administered, and artificial ventilation used as needed.
6. Monitor the patient's vital signs. This patient requires hospitalization following transfer from the dental office by paramedical personnel.

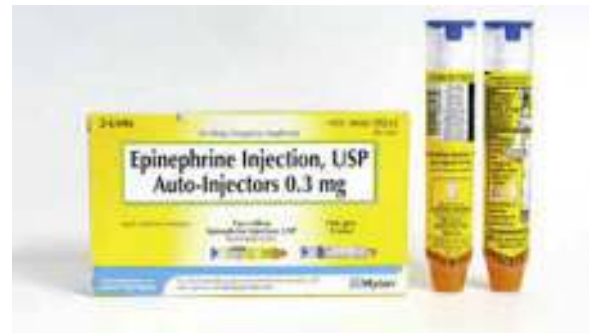PDF Compressor Free Version



• Fig. 18.15 Anatomy of the cricothyrotomy site.



• Fig. 18.16 Positioning for basic life support.



• Fig. 18.17 Syringe preloaded with epinephrine 1:1000.

Generalized Anaphylaxis

Generalized anaphylaxis is highly unlikely to develop in response to local anesthetic administration. Its management is included here, however, for completeness. The most common causes of death from anaphylaxis are parenterally administered drugs, primarily penicillin, and stinging insects (the Hymenoptera: wasps, hornets, yellow jackets, and bees).¹⁰²

Signs of Allergy Present

When signs and symptoms of allergy (e.g., urticaria, erythema, pruritus, wheezing) are present, they should signal an immediate diagnosis of allergy. The patient is likely to be unconscious.

P→C→A→B. Position the unconscious patient supine. Circulation, airway, and breathing (C, A, and B) are assessed and performed as indicated (Fig. 18.16). If the patient is conscious, position the patient comfortably.

D (definitive care)

1. Administer epinephrine. The doctor should have previously called for the office emergency team. Epinephrine from the emergency kit (0.3 mL of 1:1000 solution for

weight greater than 30 kg, 0.15 mL for weight up to 30 kg, and 0.075 mL for weight less than 15 kg) is administered intramuscularly as quickly as possible in the vastus lateralis muscle (anterolateral portion of the thigh) or intravenously (but only if available in a 1:10,000 solution). Because of the immediate need for epinephrine in this situation, a preloaded syringe of epinephrine is recommended for the emergency kit (Fig. 18.17).

2. Summon medical assistance (dial 9-1-1). As soon as a severe allergic reaction is considered a possibility, emergency medical care should be summoned. If you are alone with the victim, it is important to administer the epinephrine first, then activate emergency medical services.
3. Should the clinical picture fail to improve or continue to deteriorate (increased severity of symptoms) within 5 to 10 minutes of the initial epinephrine dose, a second dose is administered. Subsequent doses may be administered as needed every 5 to 10 minutes. There is no absolute contraindication to epinephrine administration in anaphylaxis.⁹⁷
4. Administer oxygen.
5. Monitor vital signs. The patient's cardiovascular and respiratory status must be monitored continuously. Blood pressure and heart rate (at the carotid artery)

should be monitored and recorded every 5 minutes, with chest compression started if no palpable pulse (cardiac arrest) is detected.

PDF Compressor Free Version

During this acute, life-threatening phase of what is obviously an anaphylactic reaction, management consists of epinephrine administration (every 5 to 10 minutes), BLS (as needed), administration of oxygen, and continual monitoring (and recording) of vital signs. Until improvement in the patient's clinical status is noted, no additional drug therapy is indicated.

6. Additional drug therapy. Additional drug therapy may be started once clinical improvement (increased blood pressure, decreased bronchospasm) is noted. This includes administration of a histamine blocker and a corticosteroid (both drugs intramuscularly or, if available, intravenously). They function to prevent a recurrence of signs and symptoms, obviating the need for continued administration of epinephrine. They are not administered during the acute phase of the reaction because they are too slow in onset and they do not do enough immediate good to justify their use at this time. Epinephrine and oxygen are the only drugs that should be administered during the acute phase of the anaphylactic reaction.

No Signs of Allergy Present

If a patient receiving a local anesthetic injection loses consciousness and no signs of allergy are present, the differential diagnosis includes psychogenic reaction (vasodepressor syncope), cardiac arrest, overdose reaction, and allergic reaction involving only the CVS, among other possibilities.

P→C→A→B. Position the unconscious patient supine (see Fig. 18.16).

1. Terminate dental treatment, if started.
2. Position the patient. Management of this situation, which might prove to result from any of a number of causes (see earlier), requires immediate placement of the patient in to the supine position with the legs elevated slightly. Low blood pressure (in the brain) is, by far, the leading cause of unconsciousness in humans, and the supine position (with feet elevated) increases blood flow to the brain.
3. Provide BLS, as indicated. Circulation, airway, and breathing (C, A, and B) and performed as indicated. Patients with vasodepressor syncope or postural hypotension rapidly recover consciousness once properly positioned with a patent airway maintained. Patients who do not recover at this juncture should continue to have the elements of BLS applied (breathing, circulation) as needed.

D (definitive care)

1. Summon emergency medical services. If consciousness does not return rapidly after institution of the steps of BLS, emergency medical services should be sought immediately.
2. Administer oxygen.
3. Monitor vital signs. Blood pressure, heart rate and rhythm, and respirations should be monitored and recorded, at least every 5 minutes, with the elements of BLS started at any time necessary.

4. Provide additional management. On arrival, emergency medical personnel will seek to make a diagnosis of the cause of the loss of consciousness. If this is possible, appropriate drug therapy will be instituted and the patient stabilized and then transferred to a local hospital emergency department.

In the absence of definitive signs and symptoms of allergy, such as edema, urticaria, or bronchospasm, epinephrine and other allergy drug therapy (e.g., histamine blockers, corticosteroids) are not indicated. Any of a number of other situations may be the cause of the unconsciousness; for example, drug overdose, hypoglycemia, cerebrovascular accident, acute adrenal insufficiency, or cardiopulmonary arrest. Continued BLS until medical assistance arrives is the most prudent course of action in this situation.

Summary

Systemic complications associated with local anesthetic drug administration and techniques are frequently preventable. The following is a summary of those procedures recommended to minimize their occurrence:

1. Preliminary medical evaluation should be completed before administration of any local anesthetic.
2. Anxiety, fear, and apprehension should be recognized and managed before administration of a local anesthetic.
3. All dental injections should be administered with the patient supine or semisupine. Patients should not receive local anesthetic injections in the upright position unless special conditions (e.g., severe cardiorespiratory disease) dictate this.
4. Topical anesthetic should be applied before all injections for a minimum of 1 minute.
5. The weakest effective concentration of local anesthetic solution should be injected at the minimum volume compatible with successful pain control.
6. The anesthetic solution selected should be appropriate for the dental treatment contemplated (duration of action).
7. Vasoconstrictors should be included in all local anesthetics unless specifically contraindicated by the desired duration of action (e.g., short-duration procedure) or the patient's physical status (e.g., ASA class 4 as a result of cardiovascular disease).
8. Needles should be disposable, sharp, rigid, capable of reliable aspiration, and of adequate length for the contemplated injection techniques.
9. Aspirating syringes must always be used for all injections.
10. Aspiration should be performed in at least two planes before injection.
11. Injection should be made slowly, over a minimum of 60 seconds if 1.8 mL of local anesthetic is deposited.
12. Observe the patient both during and after local anesthetic administration for signs and symptoms of undesirable reaction. Never give an injection and leave the patient alone while doing other procedures.

References

1. Malamed SF. Axiom: an extended-release medical local anesthetic. *J Dent Educ.* 2018;82(10):1017-1018.
2. Pallasch TJ. *Pharmacology for Dental Students and Practitioners.* Philadelphia: Lea & Febiger; 1980.
3. Warrington R, Silviu-Dan F. Drug allergy. *Allergy Asthma Clin Immunol.* 2011;7(suppl 1):S1-S10.
4. Speca SJ, Boynes SG, Cuddy MA. Allergic reactions to local anesthetic formulations. *Dent Clin North Am.* 2010;54:655-664.
5. Finder RL, Moore PA. Adverse drug reactions to local anesthesia. *Dent Clin North Am.* 2002;46:747-757.
6. Vinckier F. Local anesthesia in children. *Rev Belg Med Dent.* 2000;55:61-71.
7. Malamed SF. Morbidity, mortality and local anesthesia. *Prim Dent Care.* 1999;6:11-15.
8. Meechan J. How to avoid local anaesthetic toxicity. *Br Dent J.* 1998;184:334-335.
9. Meechan J, Rood JP. Adverse effects of dental local anaesthesia. *Dent Update.* 1997;24:315-318.
10. Davis MJ, Vogel LD. Local anesthetic safety in pediatric patients. *N Y State Dent J.* 1996;62:32-35.
11. Prince BS, Goetz CM, Rihn TL, et al. Drug-related emergency department visits and hospital admissions. *Am J Hosp Pharm.* 1992;49:1696-1700.
12. Kishikawa K, Namiki A, Miyashita K, et al. Effects of famotidine and cimetidine on plasma levels of epidurally administered lignocaine. *Anaesthesia.* 1990;45:719-721.
13. Shibasaki S, Kawamata Y, Ueno F, et al. Effects of cimetidine on lidocaine distribution in rats. *J Pharmacobiodyn.* 1988;11:785-793.
14. Dailey PA, Hughes SC, Rosen MA, et al. Effect of cimetidine and ranitidine on lidocaine concentrations during epidural anesthesia for cesarean section. *Anesthesiology.* 1988;69:1013-1017.
15. de Jong RH. Bupivacaine preserves newborns' muscle tone. *JAMA.* 1977;237:53-54.
16. Steen PA, Michenfelder JD. Neurotoxicity of anesthetics. *Anesthesiology.* 1979;50:437-453.
17. Hazma J. Effect of epidural anesthesia on the fetus and the neonate. *Cab Anesthesiol.* 1994;42:265-273.
18. Shamma FV, Dickstein K. Clinical pharmacokinetics in heart failure: an updated review. *Clin Pharmacokinet.* 1988;15:94-113.
19. Hammermeister KE. Adverse hemodynamic effects of antiarrhythmic drugs in congestive heart failure. *Circulation.* 1990;81:1151-1153.
20. Pedersen NA, Jensen FS. Clinical importance of plasma cholinesterase for the anesthetist. *Ann Acad Med Singapore.* 1994;23(suppl 6):120-124.
21. Barcelos KC, Furtado DP, Ramacciato JC, et al. Effect of PaCO₂ and PaO₂ on lidocaine and articaine toxicity. *Anesth Prog.* 2010;57:104-108.
22. Malagodi MH, Munson ES, Embro MJ. Relation of etidocaine and bupivacaine toxicity to rate of infusion in rhesus monkeys. *Br J Anaesth.* 1977;49:121-125.
23. Hersh EV, Helpin ML, Evans OB. Local anesthetic mortality: report of a case. *ASDC J Dent Child.* 1991;58:489-491.
24. Moore PA. Preventing local anesthetic toxicity. *J Am Dent Assoc.* 1992;123:60-64.
25. Yagiela JA. Local anesthetics. In: Dionne RA, Phero JC, Becker DE, eds. *Management of Pain and Anxiety in the Dental Office.* 2nd ed. Philadelphia: WB Saunders; 2002.
26. Kaplan EL, ed. *Cardiovascular Disease in Dental Practice.* Dallas: American Heart Association; 1986.
27. Adriani J, Campbell D. Fatalities following topical application of local anesthetics to mucous membrane. *J Am Med Assoc.* 1956;162:1527.
28. Wilburn-Goo D, Lloyd LM. When patients become cyanotic: acquired methemoglobinemia. *J Am Dent Assoc.* 1999;130:826-831.
29. Moos DD, Cuddeford JD. Methemoglobinemia and benzocaine. *Gastroenterol Nurs.* 2007;30:342-345.
30. Trapp L, Will J. Acquired methemoglobinemia revisited. *Dent Clin North Am.* 2010;54:665-675.
31. Smith M, Wolfram W, Rose R. Toxicity: seizures in an infant caused by (or related to) oral viscous lidocaine use. *J Emerg Med.* 1992;10:587-590.
32. Hess GP, Walson PD. Seizures secondary to oral viscous lidocaine. *Ann Emerg Med.* 1988;17:725-727.
33. Garrettson LK, McGee EB. Rapid onset of seizures following aspiration of viscous lidocaine. *J Pediatr.* 1992;30:413-422.
34. Rothstein P, Dornbusch J, Shaywitz BA. Prolonged seizures associated with the use of viscous lidocaine. *J Pediatr.* 1982;101:461-463.
35. Bartlett SZ. Clinical observations on the effects of injections of local anesthetics preceded by aspiration. *Oral Surg Oral Med Oral Pathol.* 1972;33:520.
36. Aldrete JA, Narang R, Sada T, et al. Reverse carotid blood flow: a possible explanation for some reactions to local anesthetics. *J Am Dent Assoc.* 1977;94:1142-1145.
37. Malamed SF. "Is the 'Mandibular Block' Passe?" Presentation at the American Dental Association Annual Scientific Meeting. Honolulu, HI, October, 2018. Available at: <https://www.malamed@usc.edu>.
38. Malamed SF. Allergic and toxic reactions to local anesthetics. *Dent Today.* 2003;22:114-121.
39. Hamedani AG, Schuur JD, Hobgood CD, Mort EA. Quality and patient safety in emergency medicine. In: Adams JG, ed. *Emergency Medicine: Clinical Essentials.* 2nd ed. Elsevier-Saunders; 2013:1731-1742.
40. Tavares M, Goodson JM, Studen-Pavlovich D, et al. Reversal of soft tissue anesthesia with phentolamine mesylate in pediatric patients. *J Am Dent Assoc.* 2008;139:1095-1104.
41. Moore PA, Hersh EV, Papas AS, et al. Pharmacokinetics of lidocaine with epinephrine following local anesthesia reversal with phentolamine mesylate. *Anesth Prog.* 2008;55:40-48.
42. Cheatham BD, Primosch RE, Courts FJ. A survey of local anesthetic usage in pediatric patients by Florida dentists. *J Dent Child.* 1992;59:401-407.
43. Malamed SF. "Local anesthetics: dentistry's most important drugs" Presentation at the American Dental Association Annual Scientific Meeting. Honolulu, HI, October, 2018. Available at: <https://www.malamed@usc.edu>.
44. Munson ES, Tucker WK, Ausinsch B, et al. Etidocaine, bupivacaine, and lidocaine seizure thresholds in monkeys. *Anesthesiology.* 1975;42:471-478.
45. Aviation Administration Federal. Guide for aviation examiners: pharmaceuticals (therapeutic medications) do not issue - do not fly. Available at: https://www.faa.gov/about/office_org/headquarters_offices/avs/offices/aam/ame/guide/pharm/dni_dnfl/. Accessed April 30, 2018.
46. Rey E, Radvanyi-Bouvet MF, Bodiou C, et al. Intravenous lidocaine in the treatment of convulsions in the neonatal period: monitoring plasma levels. *Ther Drug Monit.* 1990;12:316-320.
47. Aggarwal P, Wali JP. Lidocaine in refractory status epilepticus: a forgotten drug in the emergency department. *Am J Emerg Med.* 1993;11:243-244.
48. Pascual J, Ciudad J, Berciano J. Role of lidocaine (lignocaine) in managing status epilepticus. *J Neurol Neurosurg Psychiatry.* 1992;55:49-51.
49. Jaffe AS. The use of antiarrhythmics in advanced cardiac life support. *Ann Emerg Med.* 1993;22:307-316.
50. Bruelle P, de La Coussaye JE, Eledjam JJ. Convulsions and cardiac arrest after epidural anesthesia: prevention and treatment. *Cab Anesthesiol.* 1994;42:241-246.

51. de La Coussaye JE, Eledjam JJ, Brugada J, et al. Cardiotoxicity of local anesthetics. *Cab Anesthesiol*. 1993;41:589–598.
52. Jaimovich DG, Shabino CL, Noorani PA, et al. Intravenous midazolam suppression of pentylene tetrazol-induced epileptogenic activity in a porcine model. *Crit Care Med*. 1990;18:313–316.
53. Babl FE, Sheriff N, Borland M, et al. Emergency management of paediatric status epilepticus in Australia and New Zealand: practice patterns in the context of clinical practice guidelines. *J Paediatr Child Health*. 2009;45:541–546.
54. Feldman HS, Arthur GR, Pitkanen M, et al. Treatment of acute systemic toxicity after the rapid intravenous injection of ropivacaine and bupivacaine in the conscious dog. *Anaesth Analg*. 1991;73:373–384.
55. Daublander M. *The Role of the Vasoconstrictor*. Munich, Germany: Paper presented at: 3M ESPE Expert Conference; 2011.
56. Kellam SA, Smith JR, Scheffel SJ. Epinephrine absorption from commercial gingival retraction cords in clinical patients. *J Prosthet Dent*. 1992;68:761–765.
57. American Dental Association. *ADA/PDR Guide to Dental Therapeutics*. 5th ed. Chicago: American Dental Association—Physician's Desk Reference; 2009.
58. Gomes ER, Demoly P. Epidemiology of hypersensitivity drug reactions. *Curr Opin Allergy Clin Immunol*. 2005;5:309–316.
59. Brown DT, Beamish D, Wildsmith JA. Allergic reaction to an amide local anaesthetic. *Br J Anaesth*. 1981;53:435–437.
60. Seng GF, Kraus K, Cartwright G, Nerona R, Pacione R. Confirmed allergic reactions to amide local anesthetics. *Gen Dent*. 1996;44:52–54.
61. Aldrete JA, O'Higgins JW. Evaluation of patients with history of allergy to local anesthetic drugs. *South Med J*. 1971;64:1118–1121.
62. Boren E, Teuber SS, Nguwa SM, et al. A critical review of local anesthetic sensitivity. *Clin Rev Allergy Immunol*. 2007;32:119–128.
63. Jackson D, Chen AH, Bennett CR. Identifying true lidocaine allergy. *J Am Dent Assoc*. 1994;125:1362–1366.
64. Doyle KA, Goepferd SJ. An allergy to local anesthetics? The consequences of a misdiagnosis. *ASDC J Dent Child*. 1989;56:103–106.
65. Thyssen JP, Menne T, Elberling J, et al. Hypersensitivity to local anesthetics—update and proposal of evaluation algorithm. *Contact Dermatitis*. 2008;59:69–78.
66. Harboe T, Guttormsen AB, Aarebrot S, et al. Suspected allergy to local anaesthetics: follow-up in 135 cases. *Acta Anaesthesiol Scand*. 2010;54:536–542.
67. Haas DA. An update on local anesthetics in dentistry. *J Can Dent Assoc*. 2002;68:546–551.
68. Bhole MV, Manson AL, Seneviratne SL, Misbah SA. IgE mediated allergy to local anesthetics: separating fact from perception: a UK perspective. *Br J Anaesth*. 2012;108:903–911.
69. Gonzalez-Delgado P, Anton R, Soriano V, Zapater P, Niviero E. Cross-reactivity among amide-type local anesthetics in a case of allergy to mepivacaine. *J Invest Allergol Clin Immunol*. 2006;16:311–313.
70. Venemalm L, Degerbeck F, Smith W. IgE-mediated reaction to mepivacaine. *J Allergy Clin Immunol*. 2008;121:1058–1059.
71. Becker DE. Drug allergies and implications for dental practice. *Anesth Prog*. 2013;60:188–197.
72. Aldrete JA, Johnson DA. Evaluation of intracutaneous testing for investigation of allergy to local anesthetic agents. *Anesth Analg*. 1970;49:173–183.
73. Schwartz HJ, Sher TH. Bisulfite sensitivity manifesting as allergy to local dental anesthesia. *J Allergy Clin Immunol*. 1985;75:525–527.
74. Seng GF, Gay BJ. Dangers of sulfites in dental local anesthetic solutions: warnings and recommendations. *J Am Dent Assoc*. 1986;113:769–770.
75. Perusse R, Goulet JP, Turcotte JY. Sulfites, asthma and vasoconstrictors. *Can Dent Assoc J*. 1989;55:55–56.
76. Shojaie AR, Haas DA. Local anesthetic cartridges and latex allergy: a literature review. *J Can Dent Assoc*. 2002;68:622–626.
77. Perusse R, Goulet JP, Turcotte JY. Contraindications to vasoconstrictors in dentistry. Part II. Hyperthyroidism, diabetes, sulfite sensitivity, cortico-dependent asthma, and pheochromocytoma. *Oral Surg Oral Med Oral Pathol*. 1992;74:687–691.
78. Molotsky I. *U.S. Issues Ban on Sulfites' use in Certain Foods*. New York Times; 1986.
79. Kohase H, Umino M. Allergic reaction to epinephrine preparation in 2% lidocaine: two case reports. *Anesth Prog*. 2004;51:134–137.
80. Bruze M, Gruvberger B, Thulin I. PABA, benzocaine, and other PABA esters in sunscreens and after-sun products. *Photodermatol Photoimmunol Photomed*. 1990;7:106–108.
81. Boyce JA, Assa'ad A, Burks AW, et al. Guidelines for the diagnosis and management of food allergy in the United States: report of the NIAID-Sponsored Expert Panel. *J Allergy Clin Immunol*. 2010;126(suppl 6):S1–S58.
82. Malamed SF. Allergy. In: *Medical Emergencies in the Dental Office*. 7th ed. St Louis: Mosby; 2015:389–391.
83. Peter R. Sudden unconsciousness during local anesthesia. *Anesth Pain Control Dent*. 1993;2:140–142.
84. Chandler MJ, Grammer LC, Patterson R. Provocative challenge with local anesthetics in patients with a prior history of reaction. *J Allergy Clin Immunol*. 1987;79:883–886.
85. Orr DL. It's not Novocain, it's not an allergy, and it's not an emergency!. *Nev Dent Assoc J*. 2009;11:3–6.
86. Riedenburg MM, Lowenthal DT. Adverse nondrug reactions. *N Engl J Med*. 1968;279:678–679.
87. Meyer FP, Troger U, Rohl FW. Adverse nondrug reactions: an update. *Clin Pharmacol Ther*. 1996;60:347–352.
88. Hodgson TA, Shirlaw PJ, Challacombe SJ. Skin testing after anaphylactoid reactions to dental local anesthetics: a comparison with controls. *Oral Surg Oral Med Oral Pathol*. 1993;75:706–711.
89. Rozicka T, Gerstmeier M, Przybilla B, et al. Allergy to local anesthetics: comparison of patch test with prick and intradermal test results. *J Am Acad Dermatol*. 1987;16:1202–1208.
90. Eggleston ST, Lush LW. Understanding allergic reactions to local anesthetics. *Ann Pharmacother*. 1996;30:851–857.
91. Canfield DW, Gage TW. A guideline to local anesthetic allergy testing. *Anesth Prog*. 1987;34:157–163.
92. Swanson JG. An answer for a questionable allergy to local anesthetics. *Ann Emerg Med*. 1988;17:554.
93. Malamed SF. The use of diphenhydramine HCl as a local anesthetic in dentistry. *Anesth Prog*. 1973;20:76–82.
94. Ernst AA, Anand P, Nick T, et al. Lidocaine versus diphenhydramine for anesthesia in the repair of minor lacerations. *J Trauma*. 1993;34:354–357.
95. Uckan S, Guler N, Sumer M, et al. Local anesthetic efficacy for oral surgery: comparison of diphenhydramine and prilocaine. *Oral Surg Oral Med Oral Pathol Oral Radiol Endod*. 1998;86:26–30.
96. Willett J, Reader A, Drum M, et al. The anesthetic efficacy of diphenhydramine and the combination diphenhydramine/lidocaine for the inferior alveolar nerve block. *J Endod*. 2008;34:1446–1450.
97. Lieberman P, Nicklas RA, Randolph C, et al. Anaphylaxis—a practice parameter update 2015. *Ann Allergy Asthma Immunol*. 2015;115:341–384.
98. Oh VM. Treatment of allergic adverse drug reactions. *Singapore Med J*. 1989;30:290–293.
99. Socker M, Boyle C, Burke M. Angio-oedema in dentistry: management of two cases using C1 esterase inhibitor. *Dent Update*. 2005;32:350–352. 354.
100. Adkinson NF, Busse WW, Bochner BS, et al. *Middleton's Allergy: Principles and Practice*. 7th ed. St Louis: Mosby; 2009.
101. Stafford CT. Life-threatening allergic reactions: anticipating and preparing are the best defenses. *Postgrad Med*. 1989;86:235–242, 245.
102. Turner PJ, Jerschow E, Umasunthar T, et al. Fatal anaphylaxis: mortality rate and risk factors. *J Allergy Clin Immunol Pract*. 2017;5(5):1169–1178.

Problems in Achieving Pain Control

Local anesthetics are the safest and most effective drugs in medicine for the prevention and management of pain. Deposit a local anesthetic close enough to a nerve and it *will* block nerve conduction.

If local anesthetics are so effective, then why, on occasion, do we encounter problems achieving profound pulpal anesthesia? Where do these problems happen? And how can inadequate pulpal anesthesia be prevented or corrected?

This chapter explores and seeks to answer these questions.

Stiagailo¹ surveyed 121 dentists, asking how often they “encountered inefficiency of local anesthesia, both infiltration and conduction, during manipulation of various tooth groups?” during conservative dental treatment (Table 19.1). No teeth were pulpally involved.

In the maxilla, 16.5% of the doctors (20 of 121) had difficulty obtaining pulpal anesthesia either “often” or “sometimes” in molar teeth, whereas for premolars the proportion was 7.4% (9 of 121).

Problems (often or sometimes) achieving pulpal anesthesia were significantly more common in the mandible: 8.2% for incisors, 11.5% for canines, 30.5% for premolars, and 55.3% for molars.

In an analysis of anesthesia success rates following either inferior alveolar nerve block (IANB; mandible) or infiltration (maxilla) in 36 randomized controlled trials, it was found that the overall lack of adequate pulpal anesthesia was 29% “by the time clinician is ready to start a dental procedure (15 minutes following IANB, 10 minutes following maxillary infiltration).”² Failure rates for pulpal anesthesia were significantly greater in mandibular teeth than in maxillary teeth (Fig. 19.1). The local anesthetics administered in these randomized controlled trials were either 2% lidocaine with epinephrine 1:100,000 or 4% articaine with epinephrine 1:100,000.

Maxillary Teeth

In the analysis of 36 clinical trials, inadequate pulpal anesthesia following maxillary infiltration (10-minute waiting time to start the procedure) occurred in approximately 18% of instances, with tooth-specific failure rates fairly consistent between lateral incisors (19%), canines (20%), first premolars (15%), and first molars (17%).²

Maxillary Incisors, Canines, and Premolars

Primary Technique(s) for Pulpal Anesthesia

Because of the relative thinness of bone (in most adults) covering the labial or buccal surface of maxillary anterior teeth, infiltration remains the preferred anesthetic technique when one is treating one or two maxillary anterior teeth.

When multiple anterior teeth are to be treated or when infiltration proves ineffective, the anterior superior alveolar nerve block should be considered. When one is treating only premolar teeth, the middle superior alveolar nerve block is recommended.

Why do we miss?

In approximately 15% of adults the cortical plate of bone overlying the maxillary anterior teeth will be thicker than “normal.” Of this 15%, a subset of another 15% will have exceedingly thick bone in this area, minimizing the success of infiltration anesthesia (Fig. 19.2).

Another reason for anesthetic failure following infiltration on a *maxillary canine* (20%)² is underinsertion of the needle with deposition of the anesthetic solution below the apex of the tooth.

On occasion the root apex of a *central incisor* is located under the cartilage and bone of the nasal cavity, minimizing success of infiltration anesthesia.

What are the possible solutions to this problem of failure of infiltration anesthesia?

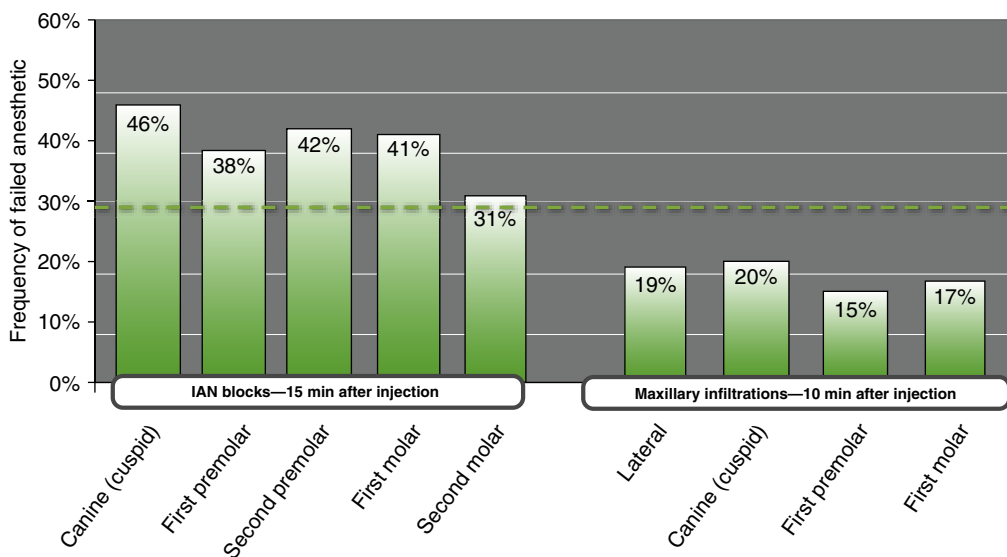
1. The anterior superior alveolar nerve block provides pulpal anesthesia to the maxillary incisor, canine, and—in most patients—premolar teeth. The middle superior alveolar nerve block should be considered when premolars are being treated (see Chapter 13).
2. Use of a buffered local anesthetic solution. As discussed in Chapter 20, injecting local anesthetics at a pH of approximately 7.4 confers several clinical advantages, among which are a more rapid onset of anesthesia and increased success rate.³
3. Infiltration anesthesia using (buffered) articaine hydrochloride. Meta-analysis of studies comparing the effectiveness of articaine versus lidocaine by maxillary infiltration showed articaine has a 3.81 times greater probability of providing successful pulpal anesthesia.⁴
4. Intranasal local anesthetic mist for pulpal anesthesia of maxillary nonmolar teeth. An intranasal mist of 3%

TABLE 19.1

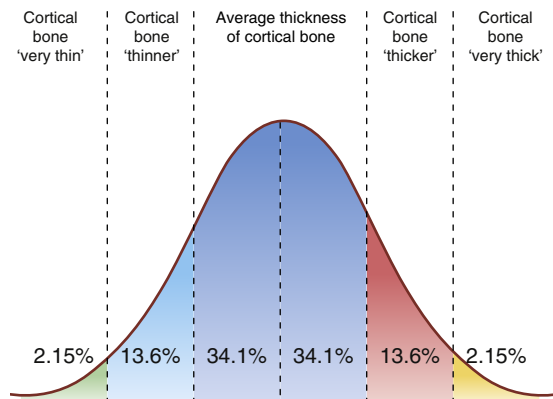
Frequency (%) With Which 121 Dentists Surveyed Encountered Inefficiency of Local Anesthesia, Both Infiltration and Conduction, During Manipulation of Various Tooth Groups During Conservative Dental Treatment

Tooth Group	Often	Sometimes	Rarely	Very Rarely	Never
Maxillary incisors	1	3	17	37	3
Maxillary canines	1	2	23	42	53
Maxillary premolars	1	8	29	40	43
Maxillary molars	1	19	31	41	29
Mandibular incisors	4	6	17	39	55
Mandibular canines	4	10	23	39	45
Mandibular premolars	8	29	18	41	25
Mandibular molars	20	47	32	21	1

Data from Stigiailo SV. Local anesthesia failure problems in conservative dental therapy clinic. *Stomatologija*. 2006;85:6–10.



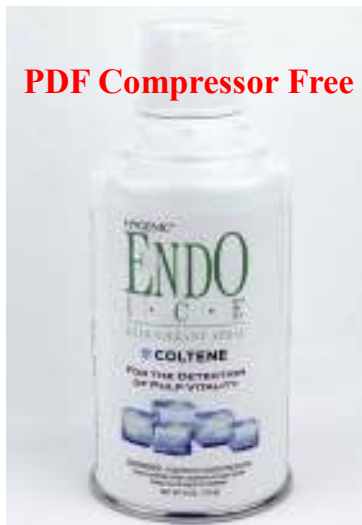• **Fig. 19.1** Average failure rate reported across 36 published studies that report on anesthetic failure using articaine or lidocaine. (Unpublished data, courtesy of Onpharma Co. www.onpharma.com.)



• **Fig. 19.2** Bell curve for bone thickness.

tetracaine with 0.05% oxymetazoline has been proven to provide profound pulpal anesthesia with a high probability of success in maxillary incisors, canines, and premolars.⁵ The intranasal mist is of greatest importance when one is treating trypanophobic patients (those with a fear of needles). The intranasal mist is discussed in depth in Chapter 20.

- To ensure a painless dental experience, evaluate pulpal anesthesia before initiating dental treatment. Following the onset of signs and symptoms (e.g., lip numbness), application of a cold refrigerant (e.g., Endo-Ice) (Fig. 19.3) or an electric pulp tester (EPT) can be used to test the tooth to be treated for pulpal anesthesia.⁶⁻⁹
 - With the refrigerant, use a large cotton pellet and spray it with the refrigerant and place it on the tooth.



PDF Compressor Free Version

• Fig. 19.3 Refrigerant spray. (Courtesy of COLTENE.)

- If the patient responds, consideration should be given to either repeating the injection or use of supplemental techniques to provide profound pulpal anesthesia.⁶⁻⁹
- b. If the tooth does not respond to maximum output from the EPT, profound pulpal anesthesia likely exists.
 6. It is important to note that in situations of irreversible pulpitis, lack of patient response to the refrigerant or the EPT may not always be indicative of pulpal anesthesia.⁹

Maxillary Molars

Primary Technique(s) for Pulpal Anesthesia

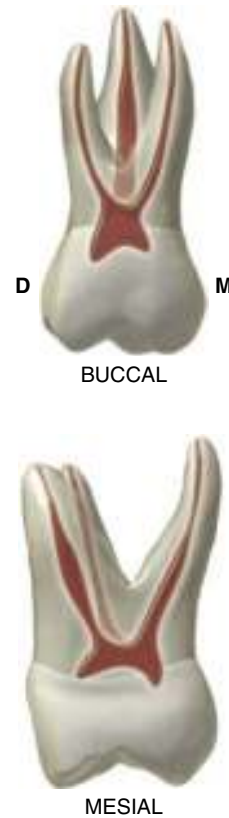
Maxillary infiltration remains the most used technique when maxillary molar teeth are being treated. The posterior superior alveolar nerve block should be considered when treatment includes several maxillary molar teeth.

Why do we miss?

In the study by Stagiailo¹ 16.5% of doctors failed to achieve successful maxillary anesthesia on molar teeth “often” or “sometimes.” The most likely reasons are (1) the thickness of the cortical plate of bone overlying the molar teeth (see discussion earlier), and (2) the radicular anatomy of the maxillary first and second molars.

Maxillary first and second molars have three roots: two buccal roots and one palatal root (Fig. 19.4). When one is infiltrating a maxillary first or second molar, approximately 0.6 to 0.9 mL of local anesthetic is deposited in the buccal fold adjacent to the tooth to be treated. Given a normal configuration of the roots, the local anesthetic diffuses palatally, successfully blocking the nerve, entering all three roots. However, when a variant radicular anatomy is present—the palatal root of a molar deviates (“flares”) more toward the midline than usual—most injected local anesthetics will successfully block the two buccal roots but not the palatal root. This situation will not be known by the doctor until dental treatment (e.g., preparation of the tooth) approaches the unanesthetized palatal aspect of the tooth, at which time the patient will experience pain.

Maxillary First Molar



• Fig. 19.4 Normal anatomy of maxillary molar. (From Wilcox LR. Pulpal anatomy and access preparations. In: Torabinejad M, Fouad A, Walton RE, eds. *Endodontics: Principles and Practice*. 5th ed. St Louis: Saunders; 2014.)

What are the possible solutions to this problem?

1. The posterior superior alveolar nerve block provides pulpal anesthesia to maxillary molar teeth regardless of the anatomy of their roots (see Chapter 13).
2. Use of a buffered local anesthetic solution.
3. Infiltration anesthesia using (buffered) articaine hydrochloride (0.6 to 0.9 mL). Articaine hydrochloride (4% with epinephrine 1:100,000 or 1:200,000) diffuses more reliably through soft and hard tissues and into nerves than lidocaine, mepivacaine, prilocaine, and bupivacaine.⁴
4. To ensure a painless dental experience, evaluate pulpal anesthesia before initiating dental treatment (see earlier).

Comment: Other, “supplemental” anesthesia techniques are available for use in helping to achieve successful maxillary anesthesia, including the periodontal ligament injection, intraseptal anesthesia, and intraosseous injection (see Chapter 15). It has been this author’s experience—50 years as a dentist and dental educator—that because of the effectiveness of infiltration and nerve blocks, these supplemental techniques are rarely required to help achieve pulpal anesthesia in nonpulpally involved maxillary teeth.

Mandibular Teeth

In the analysis of 300 mandibular teeth, anesthesia following IANB (15-minute waiting time to start the procedure) occurred in 39.6% of instances. The failure rates were 46% in canines, 38% in first premolars, 42% in second premolars, 41% in first molars, and 31% in second molars.²

In Stigailo's survey, the rates of "often" or "sometimes" having difficulty achieving pulpal anesthesia were 8.2% for incisors, 11.5% for canines, 30.5% for premolars, and 55.3% for molars.¹

Mandibular Nonmolar Teeth (Incisors, Canines, and Premolars)

Primary Technique(s) for Pulpal Anesthesia

Because of the relative thickness of bone (in most adults) covering the labial or buccal surface of the mandibular incisors, canines, and premolars in the adult patient, infiltration anesthesia is associated with a rather low success rate. For this reason, nerve block techniques have long been the preferred means of achieving mandibular anesthesia. The traditional IANB (commonly, but incorrectly, called the "mandibular block") is most often used for any and all treatment of mandibular teeth.

Why do we miss?

The traditional IANB has a rather high failure rate in mandibular incisors, canines, and premolars.^{1,2}

The thickness of the cortical plate of bone in the adult mandible is such that simple infiltration (as described for the maxilla) has a very low probability of success in most patients.

A lack of definitive and consistent anatomy from patient to patient makes the traditional IANB more of an "iffy" proposition when one is evaluating success rates of different anesthetic techniques.

What are possible solutions to this problem in mandibular nonmolar teeth?

"Mandibular" nerve blocks (e.g., IANB, Gow-Gates nerve block, Vazirani-Akinosi nerve block) need *not* be administered to achieve pulpal anesthesia of mandibular nonmolar teeth.

1. Incisive nerve block. When multiple mandibular nonmolar teeth are being treated, the incisive nerve block is a simple and highly effective technique. Deposit 0.6 to 0.9 mL of local anesthetic outside the mental foramen, followed by the application of finger pressure for minimally 1 minute, preferably 2 minutes (see [Chapter 14](#)).
2. The use of a buffered local anesthetic solution.
3. Buccal infiltration of (buffered) articaine (0.6 mL) when treating mandibular incisors. Articaine has been shown to have extremely high pulpal anesthesia success rates when administered by buccal infiltration in the mandibular incisor region (see [Chapter 20](#)).¹⁰
4. To ensure a painless dental experience, evaluate pulpal anesthesia before initiating dental treatment (see earlier).
 - a. It is important to note that in situations of irreversible pulpitis, lack of patient response to the refrigerant or the EPT may not always be indicative of pulpal anesthesia.⁹

Mandibular Molars

Primary Technique for Pulpal Anesthesia

The traditional "mandibular nerve block" (IANB) is, by far, the technique most commonly used by dentists worldwide when they are seeking anesthesia of mandibular molar teeth.

Why do we miss?

The traditional IANB has a rather high failure rate in mandibular molar teeth.^{1,2}

A lack of definitive and consistent anatomy from patient to patient makes the traditional IANB more of an "iffy" proposition when one is evaluating success rates of different anesthetic techniques.

The thickness of the cortical plate of bone overlying molar teeth in the adult mandible is such that simple infiltration (as described for the maxilla) has a very low probability of success in most adult patients.

What are possible solutions to this problem in mandibular nonmolar teeth?

1. The Gow-Gates mandibular nerve block and Vazirani-Akinosi (closed mouth) nerve block are excellent alternatives to the IANB when one is treating mandibular molars or multiple mandibular teeth, including nonmolar teeth (see [Chapter 14](#)).
2. Slow administration of local anesthetic solution (defined as minimally 1 minute for a 1.8-mL cartridge) has been shown to result in a higher success rate for pulpal anesthesia than a rapid rate (15 seconds for a 1.8-mL cartridge).¹¹
3. The use of a buffered local anesthetic solution.
4. Buccal infiltration of (buffered) articaine (0.6 mL) as a supplement to a previously administered IANB, Gow-Gates mandibular nerve block, or Vazirani-Akinosi nerve block. A volume of 0.6 mL of (buffered) articaine, infiltrated in the buccal fold at the apex of the tooth to be treated, has been shown to significantly increase the success rate of pulpal anesthesia (see [Chapter 20](#)).¹²
5. Buccal infiltration of articaine (buffered, preferred) as the sole anesthetic technique. The buccal infiltration of (buffered) articaine (0.9 mL) at the apex of the mandibular molar to be treated as the sole technique of anesthesia has been demonstrated to be quite successful (see [Chapter 20](#)).¹³
6. Supplemental injection techniques, including the periodontal ligament injection, intraseptal injection, and intraosseous injection, are often important adjuncts to the aforementioned techniques when their success has been less than optimal (see [Chapter 15](#)).
7. To ensure a painless dental experience, evaluate pulpal anesthesia before initiating dental treatment (see earlier).
 - a. It is important to note that in situations of irreversible pulpitis, lack of patient response to the refrigerant or the EPT may not always be indicative of pulpal anesthesia.⁹

Pulpally Involved Teeth

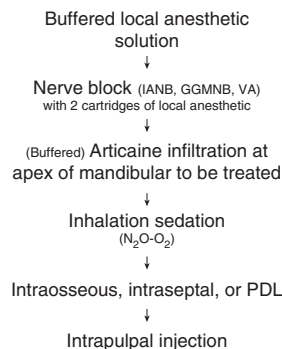
When teeth become pulpally involved (e.g., infected), achieving effective pain control becomes much more problematic. Stigailo's survey¹ of 121 dentists asked about difficulties in achieving effective pain control with

TABLE 19.2 Frequency With Which 121 Dentists Surveyed Had Difficulty in Achieving Effective Pain Control During Treatment of Various Tooth Diseases

Tooth Disease	Almost	Often	Sometimes	Rarely	Never
	Always				
Average caries	0	0	17	46	58
Deep caries	0	2	34	56	29
Chronic pulpitis	1	4	44	42	30
Exacerbated chronic pulpitis	2	22	60	30	7
Acute pulpitis (symptomatic irreversible pulpitis)	2	26	61	26	6

Data from Stagiailo SV. Local anesthesia failure problems in conservative dental therapy clinic. *Stomatologija*. 2006;85:6–10.

• **BOX 19.1** Recommended Sequence for Achieving Pain Control in Pulpally Involved Mandibular Molar Teeth



various tooth diseases (Table 19.2). Exacerbated chronic pulpitis and acute pulpitis (symptomatic irreversible pulpitis) were the most difficult, with reported difficulties of 69% and 74%, respectively, occurring “almost always,” “often,” or “sometimes.”

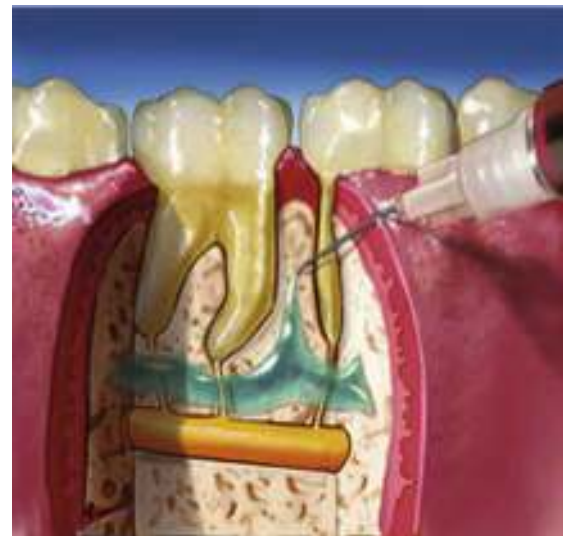In its excellent 2009 monograph “Taking the pain out of restorative dentistry and endodontics: current thoughts and treatment options to help patients achieve profound anesthesia,” the American Association of Endodontists reviews the misconceptions regarding, problems regarding, and solutions to the conundrum of achieving effective pulpal anesthesia in these difficult clinical situations.⁹

As is obvious from Table 19.1 profound pulpal anesthesia is most difficult to attain in any clinical situation in mandibular molars, a problem compounded in the presence of exacerbated chronic or acute pulpitis (Table 19.2).¹

The problem of achieving adequate pain control in pulpally involved teeth is discussed in Chapter 16 along with a suggested protocol for increased success (Box 19.1).

The following should be noted:

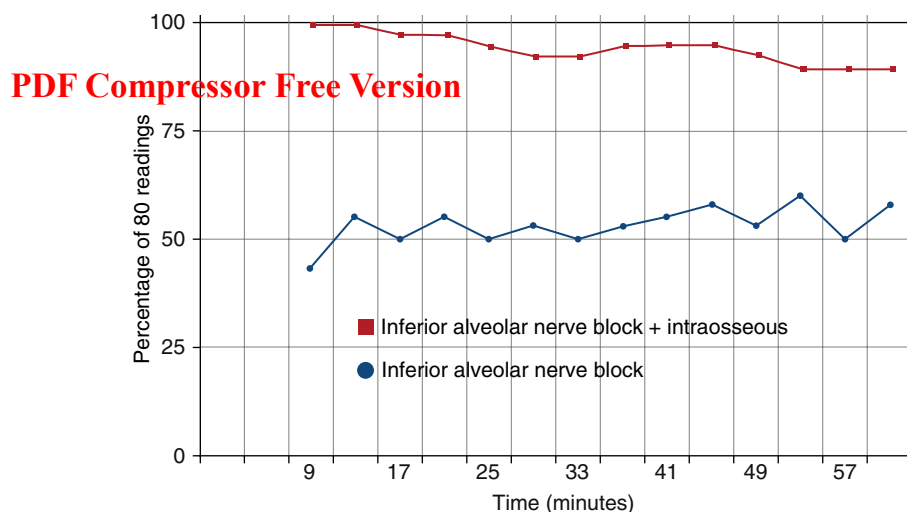
1. The use of sedation, specifically *inhalation sedation* with nitrous oxide (N₂O) and oxygen (O₂), is strongly recommended. Inhalation sedation, in addition to alleviating the patient’s fears of dentistry—as is extremely



• **Fig. 19.5** The intraosseous injection delivers a local anesthetic solution directly into the cancellous bone adjacent to the tooth to be anesthetized. (From Reader A. *Endodontics: Colleagues for Excellence*. Winter 2009. *Taking the Pain Out of Restorative Dentistry and Endodontics: Current Thoughts and Treatment Options to Help Patients Achieve Profound Anesthesia*. Chicago: American Association of Endodontists; 2009.)

common in patients with chronic or acute pulpitis—elevates the pain reaction threshold, moderating the patient’s response to painful stimulation should the local anesthetic injection technique prove less than 100% effective. Stanley et al.,¹⁴ in comparing inhalation sedation with placebo (room air plus oxygen), reported “the results showed that nitrous oxide sedation (30% to 50%) did increase the success of an IAN [inferior alveolar nerve] block (50% vs. 28% placebo) and therefore might be a useful technique to add to the armamentarium used in the treatment of teeth with symptomatic irreversible pulpitis (e.g., in addition to using supplemental anesthesia).”

2. The use of an *intraosseous injection* (Fig. 19.5) following IANB (or Gow-Gates mandibular nerve block) significantly increases successful pulpal anesthesia in mandibular molars (Fig. 19.6).^{6,15-17} Dunbar et al.¹⁵ demonstrated that addition of an intraosseous injection following IANB increased the success rate of pulpal



• **Fig. 19.6** Pulpal anesthesia of the mandibular first molar comparing the combination of intraosseous injection of 2% lidocaine with epinephrine 1:100,000 plus inferior alveolar nerve block to the inferior alveolar nerve block alone. (From Reader A. *Endodontics: Colleagues for Excellence. Winter 2009. Taking the Pain Out of Restorative Dentistry and Endodontics: Current Thoughts and Treatment Options to Help Patients Achieve Profound Anesthesia*. Chicago: American Association of Endodontists; 2009.)

anesthesia from a mid-50% range to approximately 90% for 60 minutes. Other studies have reported success rates (none or mild pain on pulpal access) between 86% and 91%, with immediate onset and a duration adequate for completion of the treatment.¹⁸⁻²¹

References

1. Stagiailo SV. Local anesthesia failure problems in conservative dental therapy clinic. *Stomatologija*. 2006;85:6–10.
2. Stepovich MJ: Success and failure rates by arch, teeth, and local anesthetic agent for inferior alveolar nerve blocks and infiltration, while paper. A meta-data analysis of 36 clinical trial reports. info@onpharma.com.
3. Malamed SF, Falkel M. Buffered local anesthetics: the importance of pH and CO₂. *SAAD Dig*. 2013;29:9–17.
4. Powell V. Articaine is superior to lidocaine in providing pulpal anesthesia. *J Am Dent Assoc*. 2011;142:493–504.
5. Ciancio SG, Hutcheson MC, Ayoub F, et al. Safety and efficacy of a novel nasal spray for maxillary dental anesthesia. *J Dent Res*. 2013;92(suppl 7):43S–48S.
6. Reader A. Intraosseous anesthesia. bonus material F. In: *Endodontics: Colleagues for Excellence. Winter 2009. Taking the Pain Out of Restorative Dentistry and Endodontics: Current Thoughts and Treatment Options to Help Patients Achieve Profound Anesthesia*. Chicago: American Association of Endodontists; 2009.
7. Dreven L, Reader A, Beck M, Meyers W, Weaver J. An evaluation of the electric pulp tester as a measure of analgesia in human vital teeth. *J Endod*. 1987;13:233–238.
8. Certosimo A, Archer R. A clinical evaluation of the electric pulp tester as an indicator of local anesthesia. *Oper Dent*. 1996;21:25–30.
9. Nusstein J, Reader A, Nist R, Beck M, Meyers WJ. Anesthetic efficacy of the supplemental intraosseous injection of 2% lidocaine with 1:100,000 epinephrine in irreversible pulpitis. *J Endod*. 1998;24:487–491.
10. Meechan JG, Ledvinka JI. Pulpal anaesthesia for mandibular incisor teeth: a comparison of infiltration and intraligamentary injections. *Int Endod J*. 2002;35:629–634.
11. Kanaa MD, Meechan JG, Corbett IP, Whitworth JM. Speed of injection influences efficacy of inferior alveolar nerve blocks: a double-blind randomized controlled trial in volunteers. *J Endod*. 2006;32:919–923.
12. Kanaa JM, Whitworth JM, Corbett IP, Meechan JG. Articaine buccal infiltration enhances the effectiveness of lidocaine inferior alveolar nerve block. *Int Endod J*. 2009;42:238–246.
13. Robertson D, Nusstein J, Reader A, Beck M, McCartney M. The anesthetic efficacy of articaine in buccal infiltration of mandibular posterior teeth. *J Am Dent Assoc*. 2007;138:1104–1112.
14. Stanley W, Drum M, Nusstein J, Reader A, Beck M. Effect of nitrous oxide on the efficacy of the inferior alveolar nerve block in patients with symptomatic irreversible pulpitis. *J Endod*. 2012;38:565–569.
15. Dunbar D, Reader A, Nist R, Beck M, Meyers W. Anesthetic efficacy of the intraosseous injection after an inferior alveolar nerve block. *J Endod*. 1996;22:481–486.
16. Giglielmo A, Reader A, Nist R, Beck M, Weaver J. Anesthetic efficacy and heart rate effects of supplemental intraosseous injection of 2% mepivacaine with 1:20,000 levonordefrin. *Oral Surg Oral Med Oral Pathol Oral Radiol Endod*. 1999;87:284–293.
17. Stabile P, Reader A, Gallatin E, Beck M, Weaver J. Anesthetic efficacy and efficacy of the intraosseous injection of 1.5% etidocaine (1:200,000 epinephrine) after inferior alveolar nerve block. *Oral Surg Oral Med Oral Pathol Oral Radiol Endod*. 2000;89:407–411.
18. Reisman D, Reader A, Nist R, Beck M, Weaver J. Anesthetic efficacy of the supplemental intraosseous injection of 3% mepivacaine in irreversible pulpitis. *Oral Surg Oral Med Oral Pathol Oral Radiol Endod*. 1997;84:676–682.
19. Nusstein J, Kennedy S, Reader A, Beck M, Weaver J. Anesthetic efficacy of the supplemental X-tip intraosseous injection in patients with irreversible pulpitis. *J Endod*. 2003;29:724–728.
20. Bigby J, Reader A, Nusstein J, Beck M, Weaver J. Articaine for supplemental intraosseous anesthesia in patients with irreversible pulpitis. *J Endod*. 2006;32:1044–1047.
21. Parente SA, Anderson RW, Herman WW, Kimbrough WF, Weller RN. Anesthetic efficacy of the supplemental intraosseous injection for teeth with irreversible pulpitis. *J Endod*. 1998;24:826–828.

Recent Advances in Local Anesthesia

Providing patients with painless and comfortable dental treatment is a goal sought by all dentists. The importance of pain-free dental care is such that in a 2006 article, de St. Georges¹ noted that the two most important factors used by patients when evaluating dentists are a dentist who does not hurt (second most important) and the ability of the dentist to administer a painless injection (most important) (Box 20.1).

The local anesthetics currently available to the dental profession will, in almost all situations, enable a patient to have dental treatment completed pain free. Articaine hydrochloride, bupivacaine hydrochloride, lidocaine hydrochloride, mepivacaine hydrochloride, and prilocaine hydrochloride are excellent drugs that, when used properly, are safe and highly effective. The clinical properties of these drugs are reviewed in Chapter 4.

As effective as local anesthetics are, clinical situations still arise when it is difficult to achieve adequate pain control. The most common causes of this problem are reviewed in Chapter 19.

Additionally, in addressing the ability of the administrator of the injection (dentist or dental hygienist) to administer it painlessly—the most important factor sought by the patient—research has developed newer and more effective means of achieving painless injections (or to do away with the need for injections entirely).

As an educator, author, and invited speaker at continuing dental education programs in the area of local anesthesia since 1973, I have been approached by dentists and research companies seeking my advice and clinical expertise on new ideas and/or products and drugs they have developed seeking to make dental pain control more effective, safer, and more comfortable for our patients.

This chapter discusses five such “inventions” that I believe represent significant advances in the art and science of pain control in the dental profession (Table 20.1).

Computer-Controlled Local Anesthetic Delivery

Among the factors leading to increased levels of pain during the administration of local anesthetics in the oral cavity are

(1) the speed of injection, and (2) the pressure induced during local anesthetic administration.

The *rate* at which the local anesthetic solution is deposited into the soft tissues has a significant effect on patient comfort or discomfort.² Slow deposition of the anesthetic allows the drug to diffuse through tissues along natural tissue planes rather than tearing tissues if the drug is injected rapidly, leading to a more comfortable experience during the injection and less postinjection “soreness” when the anesthetic effect has resolved.

The *pressure* produced in the soft tissue into which the local anesthetic is being delivered also has an effect on a patient’s perception of pain during injection.³ Deposition of a local anesthetic solution into less dense (“loose”) soft tissues not firmly adherent to bone, such as those in the maxillary labial and buccal folds (e.g., “maxillary infiltration”) and pterygomaxillary space (e.g., posterior superior alveolar [PSA] nerve block), is commonly described by patients as more comfortable. On the visual analog scale to measure pain or comfort, a rating of zero is painless, ratings between 1 and 3 are “comfortable,” and a rating of 10 is the “worst pain ever experienced” (Fig. 20.1).

In contradistinction to experience of a more comfortable injection into “loose” soft tissues, injection of local anesthetics into the palate is commonly rated as considerably more uncomfortable (visual analog scale score commonly between 5 and 10). Many dental patients, and as well as dentists, will make every effort to avoid palatal injections since, in their mind, these injections “hurt.”⁴ Although this author disagrees with the following, another injection technique—the periodontal ligament injection—is frequently thought of, by dentists, as painful. The local anesthetic is being delivered, under pressure, into a very confined space—the periodontal ligament.

Computer-controlled local anesthetic delivery (C-CLAD) technology has made possible the significantly more comfortable administration of potentially painful injections.

In 1997 the first C-CLAD device—The Wand—was introduced (Fig. 20.2). Hochman et al.⁴ compared the comfort of injection during palatal infiltration with a C-CLAD device and a traditional syringe. Fifty dentists were given contralateral palatal injections. Injection on one side was performed with a C-CLAD device, a local

• **BOX 20.1** How Dentists Are Judged by Patients

- 1 A painless injection
- 2 Does not hurt
- 3 Staff who are ... kind, professional, warm, caring, and helpful
- 4 Runs on time
- 5 "Doctor, that was the most thorough examination I've ever had"
- 6 Dentists who listen, allow questions, treat dumb questions with dignity
- 7 Patients who are happy with the results
- 8 Prompt emergency service
- 9 Prompt new patient examination appointment
- 10 High standard of sterilization

From de St. Georges. How dentists are judged by patients. *Dent Today*. 2004;23:96-99.

BDF Compressor Free Version

anesthetic delivery system using a microprocessor and electric motor to precisely regulate the flow rate during administration. Injection on the control side was performed with a standard manual syringe, where the flow rate and pressure are operator dependent and cannot be controlled accurately. The participants used two subjective scales to describe their perceived pain experience. Forty-eight (96%) preferred injections with the C-CLAD device. When their responses were analyzed, use of the C-CLAD device was found to be two to three times less painful than manual injection. The results were statistically significant ($P < .001$) (Fig. 20.3).⁴ Many well-designed clinical trials have since been completed and published demonstrating the effectiveness of C-CLAD technology in minimizing patient discomfort during dental local anesthetic injections.⁵⁻¹⁰

Over the subsequent 20 years, modifications were made to the original device, including, most recently, the inclusion of dynamic pressure-sensing (DPS) technology (Fig. 20.4).^{11,12} DPS technology monitors and controls fluid exit pressure at the needle tip, providing the clinician with real-time audible and visual feedback while a dental injection is being administered.

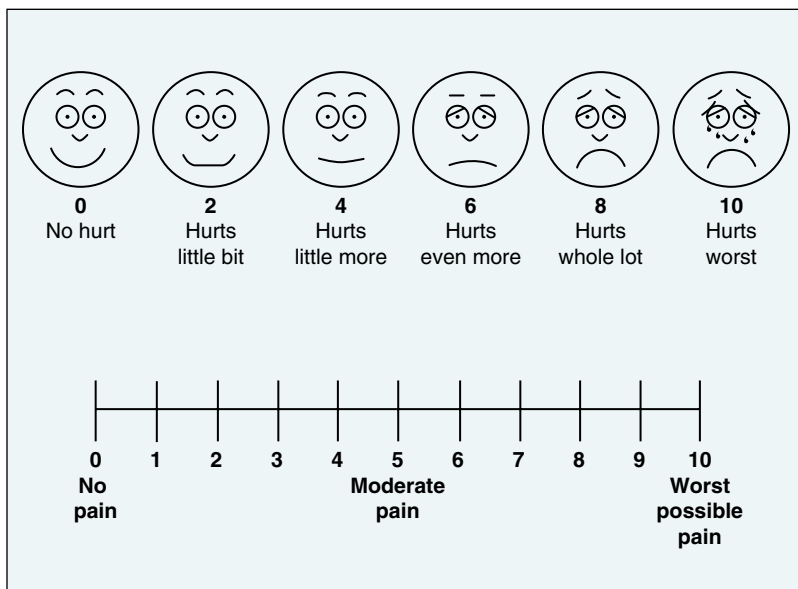
Recent additions to the C-CLAD market in North America, Europe, and Asia have sought to miniaturize the devices (Fig. 20.5).

C-CLAD technology is described in depth in Chapter 5.

The ability to administer local anesthetics slowly and under controlled pressure brought about the development of two new maxillary injection techniques: the anterior middle superior alveolar (AMSA) nerve block and the palatal approach anterior superior alveolar (P-ASA) nerve block.¹³⁻¹⁵ These techniques, both of which involve needle insertion into palatal soft tissues,

TABLE 20.1 Advances in Dental Pain Control

	Year Introduced into Dentistry in the United States
Computer-controlled local anesthetic delivery	1997
Articaine hydrochloride	2000
Local anesthesia reversal (phentolamine mesylate)	2008
Buffering of local anesthetic solutions	2010
Nasal local anesthetic mist for maxillary nonmolar teeth	2016



• **Fig. 20.1** Visual analog scale.

and provide extensive areas of anesthesia of both teeth and palatal soft tissues. Although both can be administered with the C-CLAD technology, patients find it considerably more comfortable when a C-CLAD device is used. The AMSA and P-ASA techniques are described in Chapter 13.



• Fig. 20.2 Original The Wand (1997).

Conclusions

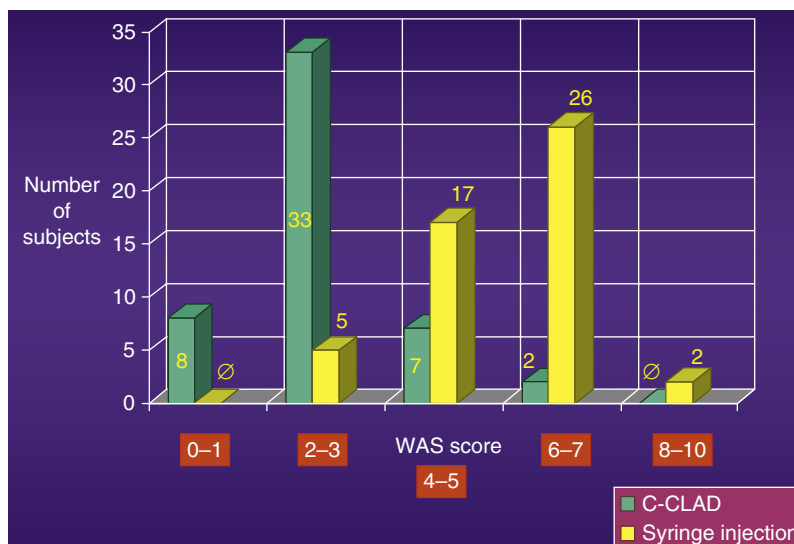
C-CLAD technology has had an impact in helping the dental profession provide patients with safe, effective, and significantly more comfortable local anesthetic injections.

Articaine Hydrochloride

The first known injection of a local anesthetic (1885) was an inferior alveolar nerve block (IANB) administered by the famed medical surgeon Dr. William Stewart Halsted (1852–1922).¹⁶ The drugs injected were a combination of cocaine and epinephrine. The dental profession quickly adopted local anesthesia as its primary means of controlling pain, eschewing general anesthesia, which had been, along with no anesthesia, the technique of choice before 1885.

The introduction in 1905 of procaine (2% with epinephrine 1:50,000) led to a rapid increase in the use of local anesthesia by dentists and to the burgeoning of access to dentistry for millions of people worldwide.¹⁷ Known everywhere by its primary proprietary name Novocain, procaine is synonymous to most people as the “shot” you receive when you visit the dentist.

The amino-ester local anesthetics, primarily procaine, propoxycaine, and tetracaine, were the drugs used by the dental profession from 1906 until the mid-1940s, when Astra Pharmaceuticals, in Sweden, synthesized and introduced the first amino-amide local anesthetic, lidocaine (Xylocaine), in 1948.¹⁸ The demonstrably superior clinical characteristics of lidocaine compared with the most commonly used esters in dentistry led to its rapid adoption and to the development of other drugs in this same category. The amide local anesthetics mepivacaine (1960—US Food and Drug Administration [FDA] approval date), prilocaine (1965), bupivacaine (1972), and etidocaine (1976) were “borrowed” from medicine for use in the dental profession. The ester local

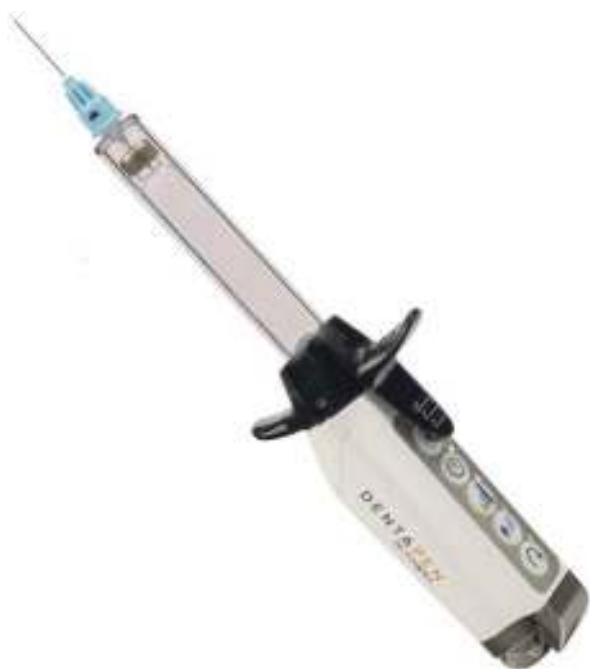

• Fig. 20.3 Pain response following palatal infiltration.

PDF Compressor Free Version



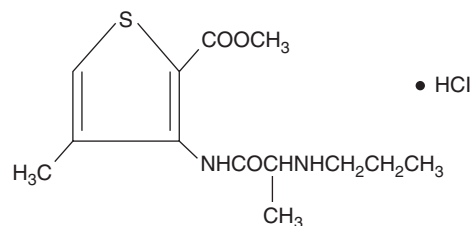
• Fig. 20.4 The Wand STA Single Tooth Anesthesia System (2007).



• Fig. 20.5 DentaPen (2018).

anesthetics are rarely used today for pain control in the dental profession worldwide.

Articaine, first prepared by Rusching and colleagues in 1969, had its generic name changed to *articaine* when it entered clinical practice in Germany in 1976.¹⁹ Its use gradually spread, entering North America in Canada in 1983.²⁰ The United Kingdom launched the drug in 1998, the United States in 2000, and Australia in 2005. Articaine



• Fig. 20.6 Articaine hydrochloride.

TABLE 20.2 Annual Worldwide Manufacture of Dental Local Anesthetic Cartridges

Local Anesthetic	Number of Cartridges Manufactured Annually (Approximation)
Lidocaine hydrochloride	1,000,000,000
Articaine hydrochloride	600,000,000
Mepivacaine hydrochloride	300,000,000
Prilocaine hydrochloride	50,000,000
Bupivacaine hydrochloride	10,000,000

was the first, and is still the only, local anesthetic developed specifically for use in dentistry. The medical profession has started to use articaine in nerve block anesthesia.^{21,22} Although classified as an amide local anesthetic, articaine possesses chemical characteristics of both the amide group and the ester group (Fig. 20.6). It has become an extremely popular local anesthetic wherever it has been made available. In 2018 articaine was the second most used dental local anesthetic in the United States, with a 34.8% market share (lidocaine was first with 49.3%).²³ In Australia 70% of dentists use articaine.²⁴ In 2010 in Germany, where the drug was introduced in 1976, articaine accounted for 97% of local anesthetic use by dentists.²⁵ Worldwide in the dental profession articaine is the second most used anesthetic, with approximately 600,000,000 cartridges manufactured annually (Table 20.2).

Articaine: Chemistry and Pharmacokinetics

Articaine is 4-methyl-3-[2-(propylamino)propionamido]-2-thiophenecarboxylic acid methyl ester, with a molecular weight of 320.84. It is the only amide local anesthetic that contains a thiophene ring. In addition, articaine is the only widely used amide local anesthetic that also contains an ester linkage (see Fig. 20.6). Ester local anesthetics undergo metabolism (biotransformation, detoxification) as soon as the drug diffuses into capillaries and veins (hydrolysis by plasma esterase). Amide local anesthetics on entering the blood circulate throughout the body unchanged—as active drugs—until they pass through the liver, where they undergo metabolism by hepatic microsomal enzymes. Unlike other

TABLE 20.3 Elimination Half-Life of Local Anesthetics

PDF Compressor Free Version

	Half-Life (min)
Chloroprocaine	6
Procaine	6
Tetracaine	18
Articaine	27
Cocaine	42
Prilocaine	90
Lidocaine	90
Mepivacaine	116
Ropivacaine	116
Etidocaine	155
Bupivacaine	210

Ester amide

amide local anesthetics that undergo metabolism in the liver, the biotransformation of articaine occurs in both the liver and, primarily, in plasma.

The elimination (beta) half-life of a drug is the time required to decrease its blood (plasma) level or concentration by 50%. It is commonly stated that a drug is “gone” (eliminated) from the body in six half-lives (The blood level has actually decreased by 98.25% at six half-lives).

The elimination half-lives of esters and amides are found in Table 20.3. Elimination half-lives of esters are short compared with those the amides. Procaine has a beta half-life of 6 minutes; lidocaine has a beta half-life of approximately 90 minutes. It is important to remember that the half-life of a drug has absolutely no relevance to the clinical duration of action of that drug. A drug is clinically effective as long as it remains in its target organ (e.g., inferior alveolar nerve) in a concentration high enough (therapeutic) to prevent the propagated nerve impulse from reaching the brain. The clinical action (e.g., “anesthesia”) of the drug ceases when it diffuses out of its target organ into capillaries and veins. It is then that the elimination half-life starts.

Articaine, possessing both ester and amide characteristics, has an elimination half-life of approximately 27 minutes.²⁶ It is eliminated from the blood in 162 minutes (6 half-life). This is clinically significant when one is treating (1) pregnant patients, (2) nursing mothers, and (3) lighter-weight patients (persons weighing up to 30 kg [66 lb]).

Articaine has many of the physicochemical properties of the most commonly used local anesthetics (lidocaine, mepivacaine, and prilocaine), with the exception of the aromatic ring and its degree of protein binding. Articaine effectively penetrates tissue and is highly diffusible. Its plasma protein binding of approximately 95% is higher than that observed with many local anesthetics. Additionally, the thiophene ring of articaine increases its liposolubility.

Articaine and Allergy

The incidence of true, documented, and reproducible allergy to amide local anesthetics is exceptionally low, although alleged “allergy” is reported occasionally.²⁷ True allergy to the ester local anesthetics is—although still quite rare—more common. The immunogenic potential of articaine is very low. Historical experiences indicate that allergic reactions resulting from sensitivity to articaine are rare. However, all local anesthetic solutions with a vasoconstrictor (e.g., epinephrine) contain the antioxidant sodium bisulfite—a known allergen. Allergic reactions that have been reported with articaine include edema, urticaria, erythema, and anaphylactic shock.²⁸ In three studies (1332 participants) comparing 4% articaine with epinephrine 1:100,000 with 2% lidocaine with epinephrine 1:100,000, reports of rash or pruritus were no more frequent with articaine ($N = 2$) than with lidocaine ($N = 4$), and no serious allergic reactions were seen in either treatment group. Patients allergic to articaine likely would be allergic to lidocaine and the other amide local anesthetics.^{26,29-31} Furthermore, the allergen *p*-amino-benzoic acid, a frequent metabolite of ester metabolism, is not a by-product of the hydrolysis phase of articaine.²⁶

As articaine possesses a sulfur-containing thiophene ring (see Fig. 20.6), this author is frequently asked if a patient having a sulfa, sulfite, or sulfur allergy represents a contraindication to its administration. The answer is “no.” The sulfur in articaine is an integral part of the thiophene ring and as such cannot be “seen” or recognized by the patient’s immune system.

Methemoglobinemia has been shown to develop with some types of local anesthetics. Clinical tests of articaine, bupivacaine, and etidocaine administered as a central nerve block anesthetic for urological procedures ($N = 103$) indicated no elevation of methemoglobin level with articaine.³²

Articaine: Clinical Characteristics

The clinical preparations of articaine in North America—4% with epinephrine 1:100,000 and 1:200,000—are classified as intermediate-duration local anesthetics. Patients responding normally to the drug (normoresponders on a bell-shaped curve) experience pulpal anesthesia of approximately 60 minutes’ duration and soft tissue anesthesia of between 3 and 5 hours’ duration. The duration of pulpal anesthesia is slightly, although not significantly, longer duration following nerve block compared with infiltration.³³ The depth and duration of anesthesia are the same with both epinephrine concentrations.³⁴

Many clinicians report that “in their opinion” the onset of anesthesia following both infiltration and nerve block with articaine is more rapid than with other local anesthetics. This assertion is not supported by clinical research.^{29,35} In studies including a combined 1554 patients there was no clinical difference noted in the onset of pulpal anesthesia following IANB between 2% lidocaine with epinephrine 1:100,000 and 4% articaine with epinephrine 1:100,000.^{26,29-30}

TABLE 20.4 Successful Pulpal Anesthesia³⁶

	Articaine	Lidocaine	P
Mandibular second molar	75%	45%	>.0001
Mandibular first molar	87%	57%	>.0001
Mandibular second premolar	92%	67%	>.0001
Mandibular first molar	86%	61%	>.0001

TABLE 20.5 Onset Time of Pulpal Anesthesia³⁶

Tooth	Articaine Onset ± SD (min)	Lidocaine Onset ± SD (min)	P
Second molar	4.6 ± 4.0	11.1 ± 9.50	.0001
First molar	4.2 ± 3.1	7.7 ± 4.3	.0002
Second premolar	4.3 ± 2.3	6.9 ± 6.6	.0014
First premolar	4.7 ± 2.4	6.3 ± 3.1	.0137

Articaine by Mandibular Infiltration in Adults

The administration of articaine by mandibular infiltration in adults has been shown to be significantly more successful in providing pulpal anesthesia than lidocaine infiltration when used as a sole injection for mandibular anesthesia.³⁶ Successful pulpal anesthesia was assessed (with an electric pulp tester [EPT]) following infiltration of 1.8 mL of articaine or lidocaine in the buccal fold adjacent to the mandibular first molar. Table 20.4 shows the percentages of successful pulpal anesthesia for mandibular premolars and molars. The onset time for pulpal anesthesia was also considerably more rapid with articaine than with lidocaine (Table 20.5). This was attributed to articaine's thiophene ring, which is more lipid soluble than the benzene ring found in other local anesthetics.

Meechan and Ledvinka³⁷ compared the infiltration of 4% articaine with epinephrine 1:100,000 and 2% lidocaine with epinephrine 1:100,000 on mandibular incisors for both the success and the duration of pulpal anesthesia. Infiltrating 0.5 mL in the buccal fold produced a 94% success rate for articaine compared with 70% for lidocaine. Infiltrating 0.5 mL on both the buccal and lingual sides of the lateral incisor increased the success rate to 97% for articaine and to 88% for lidocaine. The duration of pulpal anesthesia was significantly longer with both articaine infiltrations (Tables 20.6 and 20.7 and Fig. 20.7). The increased success rate for infiltration in the adult mandible was thought to be due to the fact that the cortical plate of bone in the incisor region, both labial and lingual, is relatively thin as well as having many small perforations that provide little resistance to infiltration.³⁷

TABLE 20.6 Successful Pulpal Anesthesia With Articaine and Lidocaine by Buccal Infiltration of a Mandibular Incisor (See Also Fig. 20.7)³⁷

	Articaine	Lidocaine
Buccal infiltration only	94%	70%
Buccal and lingual infiltration	97%	88%

TABLE 20.7 Duration and Efficacy at 45 Minutes³⁷

	Minutes Above %	Efficacy at 45 minutes
Lidocaine buccal	>70% = 5 min	~2%
Lidocaine buccal and lingual	>80% = 10 min	~10%
Articaine buccal	>80% = 25 min	~60%
Articaine buccal and lingual	>90% = 25 min	~70%

Minutes above % = Number of minutes efficacy remained above percentage listed (e.g. 70%) **Efficacy:** Percent with pulpal anesthesia at conclusion of study at 45 minutes.

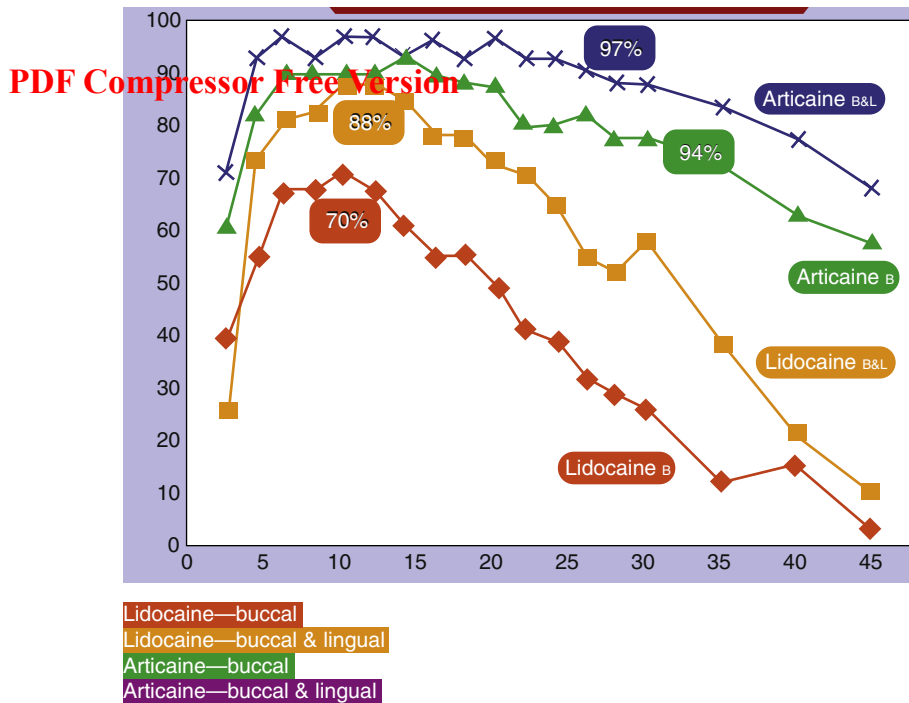
Given articaine's ability to diffuse through the thick cortical plate of bone following infiltration in the adult mandible, Kanaa et al.³⁸ investigated the ability of articaine infiltration to increase the success rate of pulpal anesthesia following an IANB with 2% lidocaine with epinephrine 1:80,000. Patients received IANBs on each of two appointments (2.0 mL lidocaine with epinephrine). They then received either a buccal infiltration of 4% articaine (2.0 mL) with epinephrine 1:100,000 or a dummy injection in the buccal fold by the mandibular first molar. The first molar and first premolar were pulp tested every 3 minutes for 45 minutes. The results are shown in Fig. 20.8. In both teeth the additional articaine infiltration increased the success rate of pulpal anesthesia (55.6% to 91.7% for the first molar; 66.7% to 88.9% for the first premolar). Although the study concluded at 45 minutes, there was no indication that pulpal anesthesia was waning at that time.³⁸

Articaine in Special Patient Populations: Pregnant Women, Nursing Mothers, and Children

In the United States the FDA classifies drugs by their safety during pregnancy and nursing.^{39,40}

Pregnant Women

All injectable local anesthetics, including articaine, and epinephrine, are classified as "B" (caution advised—no evidence of second or third trimester risk; fetal harm possible but unlikely) or "C" (weigh risk/benefit—weigh possible fetal risk vs. maternal benefit; see package insert for drug-specific



• **Fig. 20.7** Duration of successful pulpal anesthesia with articaine and lidocaine by buccal infiltration of a mandibular incisor. (From Meechan JG, Ledvinka JI. Pulpal anaesthesia for mandibular central incisor teeth: a comparison of infiltration and intraligamentary injections. *Int Endod J.* 2002;35:629–634.)

recommendations).³⁹ Lidocaine and prilocaine are rated “B”; all other local anesthetics (including articaine) and epinephrine are rated “C.” To minimize exposure of the fetus to the effects of the local anesthetic drug, a drug with a shorter elimination half-life is preferred. The 27-minute half-life of articaine is preferable to the 90-minute or greater half-life of the other available local anesthetics.

Nursing Mothers

The FDA categories for nursing infants are “S” (safe for nursing infant), “S?” (safety in nursing infants unknown), “S*” (potential for significant effects on nursing infants), and “NS” (not safe for nursing infants).⁴⁰ Lidocaine is the only “S” local anesthetic; all others are “S?” as is epinephrine (in dental concentrations). Because nursing mothers are normally reluctant to expose their infant to any drug the child does not need, it is not uncommon, in the dental environment, to have a nursing mother in need of dental care ask their dentist, “Will the drug [e.g., lidocaine] be in the milk?” The answer will always be “Yes,” although there is no evidence that a newborn nursed child will be harmed by exposure to the local anesthetic drug.⁴¹ The mother immediately states that she does not want the drug. This is problematic when the dental procedure is potentially painful. The concept of “pump and discard” successfully handles this situation. Following exposure to a drug, the nursing mother should pump and discard the milk for a period covering six elimination half-lives of the drug administered. For all dental local anesthetics except articaine, this is a period of 9 hours. The FDA states: “When using articaine, nursing mothers may choose to pump and discard breast milk for approximately 4 hours (based on plasma half-life)

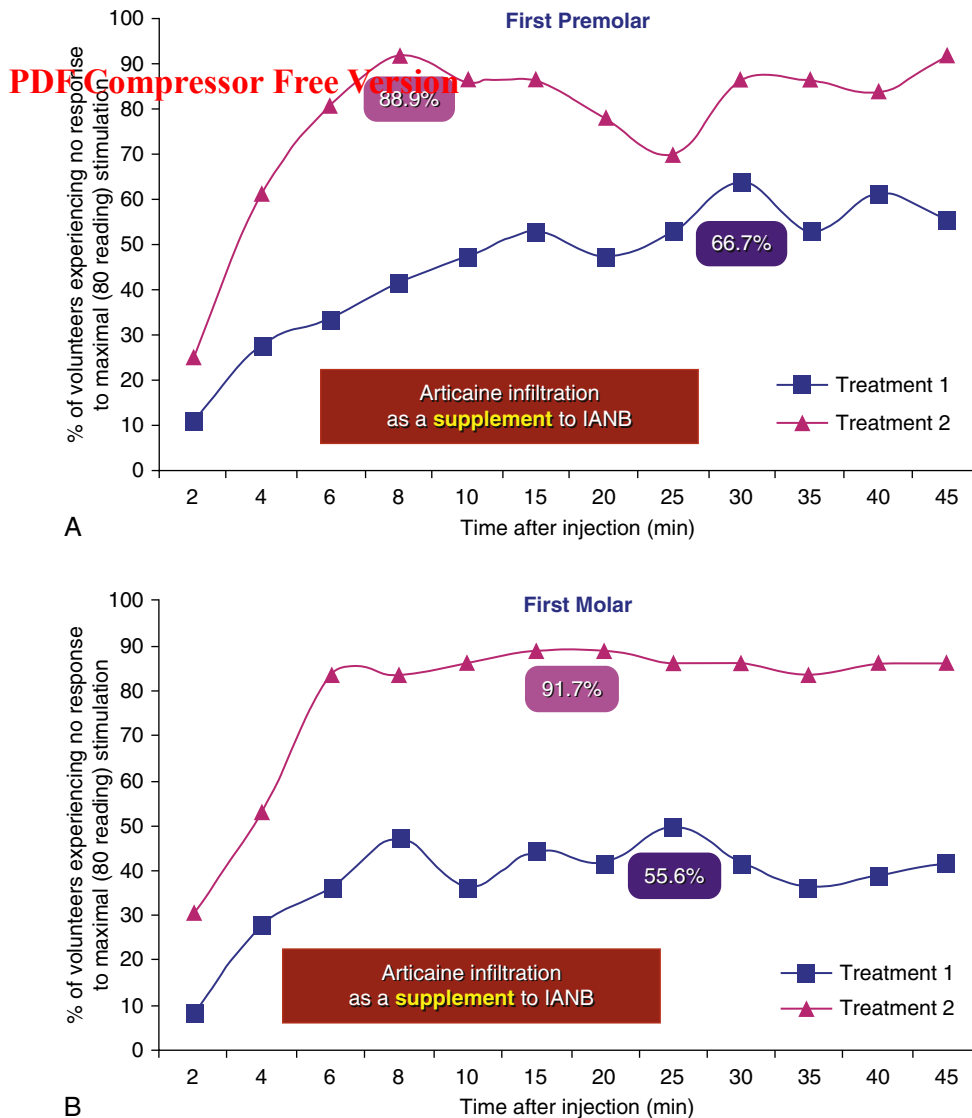
following an injection of articaine (to minimize infant ingestion) and then resume breastfeeding.”⁴⁰

Children

The greatest concern when administering local anesthetics to younger, lighter-weight patients is that of overdose. A typical local anesthetic overdose manifests itself as a generalized tonic-clonic seizure. *All* local anesthetics can produce seizures when their blood level becomes elevated above the seizure threshold for that drug (see [Chapter 18](#)). One cartridge of any local anesthetic administered intravenously in less than 15 seconds would likely induce a rapid onset of severe seizure activity. Proper technique for all injections, including aspirating for blood before administration of a local anesthetic and the slow injection of the drug, can prevent this from occurring.

Most local anesthetic overdoses, however, develop as a result of the overadministration of the drug. Once injected into the oral cavity, the local anesthetic will be absorbed into the cardiovascular system and a blood level of the drug becomes detectable. Local anesthetic overdose is most likely to occur in patients weighing up to 30 kg (66 lb), who are well-behaved, and who need multiple quadrants of dental care (see [Chapter 18](#)). Of the amide local anesthetics, articaine—because of its 27-minute elimination half-life—is the least likely to induce an overdose resulting from the administration of too much anesthetic.

Maximum recommended doses (MRDs) of local anesthetics are established by the FDA (see [Table 18.2](#)). In the United States, articaine’s MRD is 7 mg/kg, with no absolute dose listed (because of its 27-minute elimination half-life). In Canada, articaine’s MRD is also 7 mg/kg; however, the absolute maximum dose is listed as 500 mg.^{33,42}



• **Fig. 20.8** Effect of buccal infiltration of articaine hydrochloride following inferior alveolar nerve block with lidocaine on (A) first premolar and (B) first molar. (From Welsch. *Histologie, Das Lehrbuch*. 5th ed. Munich: Urban & Fischer; 2018. © Elsevier GmbH, Urban & Fischer, Munich.)

As a summary of the clinical characteristics of available articaine formulations in North America, it is a 4% solution containing epinephrine in either a 1:100,000 or a 1:200,000 concentration. Cartridges contain 72 mg of articaine. (Recent changed labeling states the cartridge contains a minimum volume of 1.7 mL.) A clinical study determined the actual volume of both lidocaine and articaine cartridges to be 1.76 ± 0.02 mL.³⁶ Both formulations provide a rapid onset of pulpal anesthesia, pulpal anesthesia of approximately 60 minutes' duration, and residual soft tissue anesthesia lasting between 3 and 5 hours,^{33,42} similar to other amide local anesthetics containing epinephrine. Because of articaine's greater lipid solubility, the drug demonstrates increased clinical success when administered by mandibular infiltration in molars, premolars, and incisors. Reports of palatal soft tissue anesthesia developing after articaine maxillary infiltration in the buccal fold, although anecdotal, can be attributed to the drug's greater lipid solubility.

As a result of it undergoing metabolism in the plasma (as well as in the liver), articaine is a preferred local anesthetic during pregnancy, during nursing, and in lighter-weight patients (up to 30 kg).

Articaine and Paresthesia

As described already, articaine possesses significant advantages over the other currently available local anesthetic formulations. However, there have been case reports that the administration of 4% local anesthetic formulations (e.g., articaine, prilocaine) by IANB is associated with a greater risk of paresthesia than that of 2% and 3% formulations.⁴³⁻⁴⁶ As a result of these reports, regulatory bodies in several jurisdictions, including the province of Ontario, Canada, and in Australia, have enacted regulations recommending against the dental use of 4% local anesthetics by IANB.^{47,48}

What is paresthesia? *Mosby's Medical Dictionary*⁴⁹ defines paresthesia as “any subjective sensation, experienced as numbness, tingling, or burning feeling.” Paresthesias are one of the more general groupings of nerve disorders known as *neuropathies*. Paresthesias may manifest themselves as total loss of sensation (e.g., anesthesia), burning or tingling feelings (e.g., dysesthesia), pain in response to a normally nonnoxious stimulus (e.g., allodynia), or increased pain in response to all stimuli (e.g., hyperesthesia).⁵⁰

For convenience the term *paresthesia* will be used to encompass all forms of nerve dysfunction. We will define paresthesia as a “persistent anesthesia or altered sensation well beyond the expected duration of anesthesia.” A patient's symptoms can vary significantly, including sensations of numbness, swelling, tingling and itching, tongue biting, drooling, loss of taste, and speech impediment.^{43,51-53}

Before we delve into this subject, there are a number of “truisms” regarding anatomy, injections, and local anesthetics that need be considered:

1. Anatomy: *Everybody is different*. We teach injection technique on the basis of “normal” anatomy (e.g., locate landmark, insert needle, advance 25 mm, aspirate, deposit the drug). We hope, or it is assumed that, the nerve is in the area—if the patient's anatomy is “normal.”
2. Injections: *Once a needle penetrates skin or mucous membrane, every injection is blind*. In most intramuscular injections when therapeutic drugs are being administered, the site selected for intramuscular administration is one that it is considered anatomically “safe.” The vastus lateralis muscle (located in the anterior lateral portion of the thigh) is considered the safest place to administer an intramuscular injection with minimal risk of damaging important structures such as nerves, arteries, and veins. The administration of local anesthesia in dentistry is quite different. Consider that with a local anesthetic injection we are taught to “aim for the nerve” and deposit a volume of local anesthetic as close to the target nerve as possible (a few millimeters) so the deposited local anesthetic can diffuse into it and block nerve conduction. Yet, we cannot see where the needle tip actually is located.
3. Local anesthetics: *Local anesthetics are chemicals that transiently (hopefully) interrupt the normal functioning of a nerve* (they interrupt the nerve's ability to conduct a nerve impulse either to [sensory nerve] or from [motor nerve] the brain).
4. Local anesthetics: *All local anesthetics are neurotoxic*—they can damage nerves. Berde and Strichartz⁵⁴ in Miller's seminal textbook on anesthesia state that “all the clinically used local anesthetics can produce direct toxicity to nerves if they achieve sufficiently high intraneural concentrations.” In the United States the dental local anesthetic producing the greatest number of reports of paresthesia on an annual basis is lidocaine. Lidocaine is also the most used local anesthetic in dentistry in the United States.^{23,55,56}
5. Paresthesia: *Paresthesia has existed ever since injections were first administered*. References to paresthesia associated

with the administration of local anesthetics, both in medicine⁵⁷ and in dentistry,^{51-53,58-60} predate the introduction of articaine into North America by decades.

The first publication to address the incidence of paresthesia following the administration of 4% local anesthetics appeared in 1995.⁴³ Reviewing reports of paresthesia from dentists in the province of Ontario, Canada, to the Provincial Insurance Commission, Haas and Lennon⁴³ reported an overall risk of paresthesia following injection of local anesthetic of 1 case in 785,000. Two and three percent local anesthetics (mepivacaine, lidocaine) had an incidence of 1 in 1,250,000. The two 4% local anesthetics prilocaine and articaine had reported risks of 1 in 588,235 and 1 in 440,529, respectively.

This article has become the most cited reference purporting to demonstrate that 4% local anesthetics are associated with a greater risk of paresthesia. Virtually all articles reporting increased risk of paresthesia from articaine ultimately cite this reference.

Articaine was introduced into Denmark in 2001, and by 2005 had a market share of 35%.⁴⁴ In 2006 Hillerup and Jensen⁴⁴ reported that articaine was the drug most often associated with reports of paresthesia by dentists to the Danish Medicines Agency (Laegemiddel Styrelsen). They recommended that “until factual information is available, a preference of other formulations to articaine 4% may be justified, especially for mandibular block analgesia.” As a consequence of this article, the Danish Dental Association recommended that articaine not be used by IANB.⁶¹

The Pharmacovigilance Working Party of the European Union (the European Union's equivalent of the US FDA and Canada's Health Canada) investigated the question of paresthesia and dental local anesthetics, specifically articaine.⁶² After review of the use of articaine in 57 countries, estimating that approximately 100 million dental patients received articaine annually, their findings, published in October 2006 stated “regarding articaine, the conclusion is that the safety profile of the drug has not significantly evolved since its initial launch. Thus, no medical evidence exists to prohibit the use of articaine according to the current guidelines listed (in) the summary of product characteristics.”

The report went on to state: “All local anaesthetics may cause nerve injury (they are neurotoxic in nature). The occurrence of sensory impairment is apparently slightly more frequent following the use of articaine and prilocaine. However, considering the number of patients treated, sensory impairments rarely occur. For example, the incidence of sensory impairment following the use of articaine is estimated to be 1 case in 4.8 million treated patients.”

“Nerve injuries may result from several incidents: Mechanical injury due to needle insertion; Direct toxicity from the drug; Neural ischaemia.”

And finally: “There is no need for new experimental studies or clinical trials.”

In October 2011 the Danish Medicines Agency issued a follow-up report⁶³: “The Danish Medicines Agency's database of side effects contain 160 reports on adverse reactions from articaine that occurred from 2001 to 2005. The adverse reactions are mainly sensory impairment and nerve

TABLE 20.8 Relative Risks of Paresthesia in Ontario, Canada,⁴³ and the United States⁴⁵

	Ontario, Canada	United States
Mepivacaine	1:1,125,000	1:623,112,900
Lidocaine	1:1,125,000	1:181,076,673
Bupivacaine	NA	1:124,286,050
Overall risk	1:785,000	1:13,800,970
Articaine	1:440,000	1:4,159,848
Prilocaine	1:588,000	1:2,070,678

damage. Since 2005, we have seen a drop in the number of reports of new adverse reactions. Up until October 1, 2011, we have received two reports on suspected adverse reactions from articaine which occurred in 2011. In both cases, the patients have experienced sensory impairment after treatment with articaine.”

The preceding is an example of two phenomena: (1) the Weber effect and (2) the effect of publicity, either negative or positive, on drug prescription and use.

Articaine was introduced into the United States in June 2000 and, as in most countries, quickly became a popular dental local anesthetic. In 2018 articaine was the second most administered local anesthetic (34.8% market share) in dentistry in the United States.²³ A 2010 article by Garisto et al.⁴⁵ reviewing 248 reports of paresthesia to the FDA’s Adverse Event Reporting System (FAERS) occurring following dental procedures over an 11-year period (1997 to 2008) concluded that “reports involving 4% prilocaine and 4% articaine were 7.3 and 3.6 times, respectively, greater than expected on the basis of local anesthetic use by US dentists.” The relative risks of paresthesia from this article are given in Table 20.8 compared with the same drugs in the 1995 Ontario article.⁴³

For articaine, it appears from the data in these two articles that the risk of paresthesia is 9.4 times greater in Ontario than in the United States. The overall risk of paresthesia from a dental local anesthetic injection in Ontario is 17.58 times greater.^{43,45}

Regarding the FAERS database, the following is posted on the FDA website⁶⁴: “FAERS data does have limitations. First, there is no certainty that the reported event (adverse event or medication error) was due to the product. FDA does not require that a causal relationship between a product and event be proven.... Furthermore, FDA does not receive reports for every adverse event or medication error that occurs with a product. [Author’s note: it is estimated that only about 10% of all adverse events are ever reported.⁶⁵] Many factors can influence whether or not an event will be reported, such as the time a product has been marketed [Weber effect] and publicity about an event. Therefore, FAERS data cannot be used to calculate the incidence of an adverse event in the U.S. population.”

Resolution of paresthesia was reported in 108 of the 248 cases, with complete resolution occurring between 1 day and 736 days. Confirmed resolution of the paresthesia was

reported in 34 of the 108 cases. Of these, 25 resolved in less than 2 months, with the remaining 9 resolving within 240 days⁴⁵; 92.7% of the reports involved the lingual nerve (89.0% lingual nerve alone, 3.7% both lingual nerve and inferior alveolar nerve).⁴⁵

Articaine was approved for clinical use in 2005 in Australia. It was reported in a January 2012 article that 70% of Australian dentists were using articaine in their clinical practices.²⁴ However, a December 2011 article in the same journal, citing five case reports of paresthesia following local anesthetic administration, concluded that “careful consideration needs to be given before using higher concentration local anaesthetic agents for mandibular and lingual blocks as lower concentration local anaesthetics are safer.... It is safe to use the higher concentration agents for infiltrations away from major nerves.”⁴⁶ Four of the five reported cases involved paresthesia of the lingual nerve only, and in two of these cases an “electric shock” was experienced by the patient during injection.

Citing this paper, the 2012 edition of the Australian Dental Associations *Therapeutic Guidelines: Oral and Dental* stated: “Articaine has been claimed to be more effective, but there are reports of an increased risk of neurotoxicity, presenting as prolonged numbness in the areas of distribution, often with pain. This may be due to the higher concentration of the solution rather than to the anaesthetic itself. Consequently, it is recommended that articaine should not be used for regional blocks (e.g. inferior alveolar).”⁴⁸

The Weber Effect and the Effect of Publicity on Drug Use

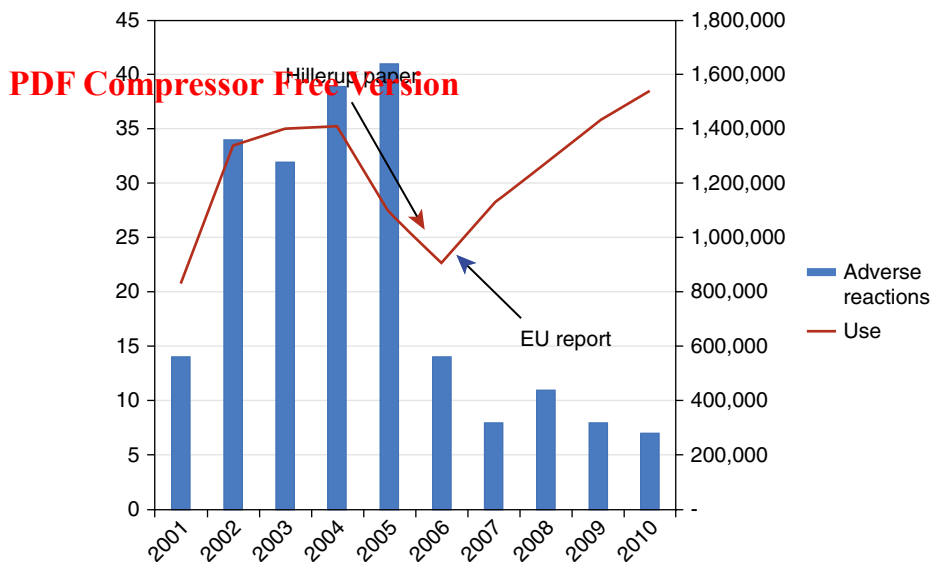
The Weber effect, named for the epidemiologist Dr. J.C.P. Weber,⁶⁶ is an epidemiological phenomenon that states that the number of reported adverse reactions for a new drug rises until about the middle to end of the second year of marketing, peaks, and then steadily declines despite steadily increasing prescribing rates.

The validity of the Weber effect has been challenged and demonstrated to be verifiable.⁶⁷ Hartnell and Wilson⁶⁷ attempted to “validate or refute a widely accepted epidemiological phenomenon known as the Weber effect by replicating Weber’s original observation by using drugs [author’s note: nonsteroidal antiinflammatory drugs] that were marketed in the United States and using reports from a U.S. database.” They concluded: “The Weber effect was replicable.”

Publicity affects drug prescribing and usage habits. Following the Danish Dental Association’s “recommendation” to avoid the use of articaine by IANB, its use in Denmark declined significantly (Fig. 20.9, red line). In 2006, following the European Union’s report stating there was no scientific evidence of an increased risk of paresthesia from articaine, use of articaine increased.

Paresthesia Following Nonsurgical Dental Treatment

Surgery, especially third molar extraction and placement of mandibular implants, is a primary cause of paresthesia



The number of suspected adverse reactions reported to the Danish Medicines Agency for articaine. The chart shows which year a reported adverse reaction began. It also shows the use of articaine in dental practices in mL.

• Fig. 20.9 Articaine use and reports of paresthesia (Denmark).

TABLE 20.9 Lingual Nerve Involvement in Reported Cases of Paresthesia

Authors	Country	Year	Lingual Nerve Involvement (%)
Haas and Lennon ⁴³	Canada	1995	70.6
Hillerup and Jensen ⁴⁴	Denmark	2006	77.0
Garisto et al. ⁴⁵	United States	2010	92.7
Kington et al. ⁴⁶	Australia	2011	80.0

following dental treatment.^{68,69} Informed consent, specifically with discussion of the risk of paresthesia, is required before these procedures.

Given that most dental treatment is nonsurgical (e.g., restorative, periodontal), the primary risk of paresthesia would involve local anesthetic administration.

In a MEDLINE search for reported cases of paresthesia in dentistry dating to 1946, more than 95% of all cases occurred in the mandible.⁷⁰ The overwhelming proportion involve the lingual nerve. Table 20.9 shows lingual nerve involvement in four published articles.

We have been told that 4% articaine appears to be more neurotoxic than other local anesthetics, and that its administration by IANB should be avoided.^{43-48,53} The following needs to be considered: if 4% articaine is more neurotoxic than other local anesthetics, then how do we explain that paresthesia is rarely reported in the maxilla when half of all dental treatment involves maxillary teeth (less than 5% of all cases in the dental literature dating

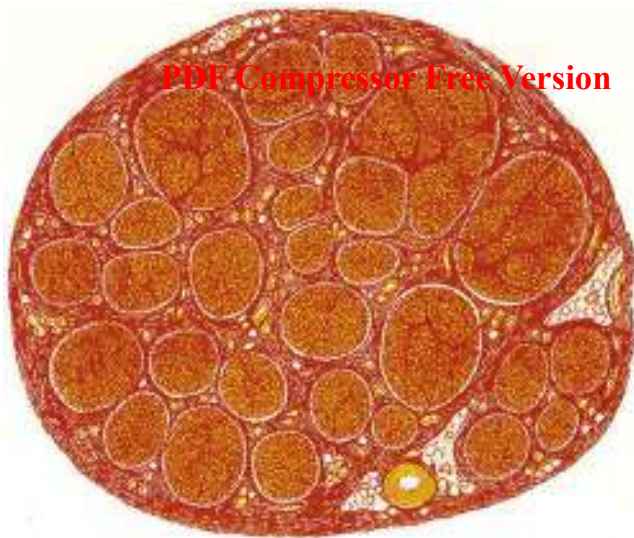to 1946 involve the maxilla).⁷⁰ Considering the mandible, paresthesia has rarely been reported following alternative nerve blocks, such as the Gow-Gates mandibular nerve block.⁷⁰ Articaine has been used increasingly in medicine, primarily dermatology, plastic and reconstructive surgery, ophthalmology, and orthopedic surgery. There are no reported cases of paresthesia following the nondental use of articaine.^{21-22,71}

Is it possible for a drug to be so specifically neurotoxic that it only damages nerves in the oral cavity, specifically in the mandible and more specifically the lingual nerve? Possible, yes, but highly improbable.

The Lingual Nerve

The lingual nerve appears to be involved in reports of dentally related paresthesia in a disproportionate percentage of cases (see Table 20.9). Pogrel has studied paresthesia, with publications dating from the early 1990s.^{51,52} In a 2000 article (before the introduction of articaine in the United States), Pogrel and Thamby⁵¹ estimated the risk of permanent nerve damage following IANB at 1 in 26,762 injections. They stated that “it is reasonable to suggest that during a career, each dentist may encounter at least one patient with an inferior alveolar nerve block resulting in permanent nerve involvement. The mechanisms are unknown and there is no known prevention or treatment.”⁵¹ In the course of a 20- to 30-year dental career, it is estimated that more than 30,000 IANBs will be administered.⁵²

Why is it that the lingual nerve is primarily involved in cases of paresthesia? Considering that when one is administering the IANB the vast majority of local anesthetic volume is deposited close to the inferior alveolar nerve (e.g., 1.3 to 1.5 mL), not the lingual nerve (e.g., 0.2 to 0.3 mL), if



• **Fig. 20.10** Fascicles within a nerve. (From McGill Physiology Virtual Laboratory. <http://www.medicine.mcgill.ca/physio/vlab/>.)

paresthesia were a local anesthetic neurotoxic phenomenon, we would expect the inferior alveolar nerve to be affected much more often than the lingual nerve.

The fact that the lingual nerve is stretched when the patient opens the mouth for an IANB probably prevents the lingual nerve from “getting out of the way” of the needle. The resulting injury is more likely than not to be a result of mechanical trauma to the lingual nerve from the metal needle. Stated in another way: “the lingual nerve is in the way.”

In 2003 Pogrel et al.⁷² attempted to explain why lingual nerve damage was commonly seen as more profound. At the level at which the IANB is administered, the inferior alveolar nerve had five to seven fascicles, whereas the lingual nerve in that area usually had around three, but in one-third of the cases was actually unifascicular in the area where the IANB was given (Fig. 20.10). If a nerve with many fascicles (e.g., inferior alveolar nerve) is damaged, only a small portion of the sensory distribution would be affected. When a nerve with one to three fascicles (e.g., lingual nerve) is damaged, the resulting area of sensory involvement will be considerably larger.

It is this author’s opinion that if paresthesia involves the distribution of the lingual nerve—and especially when an “electric shock” (e.g., “zap”) is experienced during injection, the likely cause is mechanical trauma secondary to contact of the metal needle with the nerve. If paresthesia involves the distribution of the inferior alveolar nerve (e.g., chin, lip, mucous membrane), then possible causes include (1) neurotoxicity of the local anesthetic, (2) mechanical contact of the needle to the inferior alveolar nerve, (3) edema, and (4) hemorrhage.

Local Anesthetics Are Neurotoxins

All local anesthetics are neurotoxic.⁵⁴ If all local anesthetics were equally neurotoxic, then the percentage of reported cases of paresthesia for that drug should approximate its market share. The resulting fraction ideally should be 1.0 (Table 20.10).

TABLE 20.10 Risk of Paresthesia From Local Anesthetic Drugs^{55,56}

	2007	2012	Result
Lidocaine	0.64	0.5	<1.0, less than expected
Articaine	1.19	0.97	~1.0, expected
Mepivacaine	NA	2.2	>1.5, higher than expected
Prilocaine	4.96	3.25	>3.0, higher than expected

The ratio derived from the percentage of reported cases of paresthesia divided the percent market share of the drug.

In 2007 Pogrel⁵⁵ reported on 52 patients with paresthesia. Lidocaine produced the greatest number (20) and percentage (35%) of cases of paresthesia. However, with a market share of 54% at that time, the ratio was 0.64, lower than expected (Table 20.10). Prilocaine, on the other hand, with a 6% market share was involved in 29.8% (17) of the cases of paresthesia (ratio of 4.96). Articaine, with a market share of 25%, was also involved in 29.8% (17) of the cases, for a ratio of 1.19. Pogrel concluded⁵⁵: “Therefore, using our previous assumption that approximately half of all local anesthetic used is for inferior alveolar nerve blocks, then on the figures we have generated from our clinic we do not see a disproportionate nerve involvement from articaine.”

In a 2012 update reporting on a subsequent 38 patients with paresthesia evaluated in his clinic between 2006 and 2011, Pogrel⁵⁶ stated that “articaine is still causing permanent inferior alveolar and lingual nerve damage (36%) which is proportionate to its market share (37%) ... The number of cases caused by lidocaine, on the other hand, appears to be only around 50% of its market share. Prilocaine however by causing 26% of all cases seen since 2005 with a market share of only 8% is somewhat disproportionate to its market share” (see Table 20.10).

Is Articaine a More Effective Local Anesthetic and Does It Have a Greater Risk of Paresthesia?

Meta-analyses comparing articaine with lidocaine have concluded “that articaine as compared with lignocaine provides a higher rate of anaesthetic success, with comparable safety to lignocaine when used as infiltration or blocks for routine dental treatments” and “this meta-analysis thus supports a recommendation for 4% articaine (1:100,000 epinephrine) in routine dental practice over and above 2% lidocaine (1:100,000 epinephrine).”^{73,74}

A 2012 article reporting on a histologic analysis of the neurotoxicity of lidocaine, articaine, and epinephrine on the mental nerve in rats, concluded that “articaine is not toxic to the nervous structure and (that) further studies are necessary to explain the possible relation between articaine injection and paresthesia.”⁷⁵

In a 2013 laboratory study, human neuroblastoma cells were exposed to various concentrations of articaine, lidocaine, and prilocaine at different concentrations.⁷⁶ The results of this in vitro study revealed that 2% lidocaine had a lower neurotoxicity profile than 4% prilocaine and that 4% articaine had a lower neurotoxicity profile than 2% lidocaine. In vitro studies are accurate, sensitive, and reproducible because they are conducted in a controlled environment. However, in vitro studies do not consider other factors, such as (1) local pharmacokinetics (concentration in tissues, local diffusion, absorption), (2) potential influence of other drugs on local pharmacokinetics (e.g., epinephrine), (3) systemic behavior of the drug after absorption (distribution, elimination, metabolism), and (4) all other variables, such as differences between patients.

In 2018 Albalawi et al.⁷⁷ tested the neurotoxicity of lidocaine and articaine in SH-SY5Y cells. They reported that “articaine did not produce a prolonged block of neuronal responsiveness or an increased toxicity as compared with lidocaine in SH-SY5Y cells. The corollary that articaine does not produce a prolonged loss of responsiveness or cell death as compared with lidocaine under these reductionist conditions is perhaps the most relevant conclusion.”

So, What Should You Do?

Doctors must always consider the *benefit* to be gained from use of a procedure or drug versus the *risk* involved in the use of the procedure or drug. Only when, in the opinion of the treating doctor, the benefit to be gained by the patient clearly outweighs the risk should the procedure be undertaken or the drug administered.

All reports claiming an increased risk of paresthesia with articaine are anecdotal, consisting of case reports. No scientific evidence has demonstrated an increased risk of paresthesia following the administration of articaine compared with other local anesthetics.

In a discussion of current controversies in dentistry, Christenson⁷⁸ stated: “There have been allegations of more patients having lingering paresthesia and anesthesia when articaine is used for mandibular block than lidocaine. Studies have not shown this to be true. Also, the observations of practitioners show about the same quantities of paresthesia with articaine versus lidocaine. The controversy is unfounded.”

The choices for IANB include (1) continuing with the use of 4% articaine with epinephrine 1:100,000 or 1:200,000 or (2) if you are unconvinced or still concerned, use of either 2% lidocaine with epinephrine 1:100,000 or 2% mepivacaine with levonordefrin 1:20,000 (United States) or epinephrine 1:100,000 (Canada) for IANB, followed immediately by a buccal infiltration of 0.6 to 0.9 mL of articaine (preferably buffered) at the apex of each tooth to be treated.

The administration of 4% prilocaine with epinephrine appears to be associated with a considerably greater risk of

TABLE 20.11 Comparison of Plain Local Anesthetic Versus Vasoconstrictor-Containing Local Anesthetic

	Plain Local Anesthetic	Local Anesthetic + Vasoconstrictor
Onset of pulpal anesthesia	Somewhat faster	Slower
Duration of pulpal anesthesia	Shorter	Longer
Depth of pulpal anesthesia	Not as profound	More profound
Peak blood level	Higher	Lower

paresthesia to the lingual and/or inferior alveolar nerves when administered by IANB. Its use for IANB is not recommended by this author.

Conclusions

Articaine hydrochloride has become a very popular local anesthetic in dentistry. It provides the same depth and duration of pulpal and soft tissue anesthesia as the other intermediate-acting dental local anesthetics—lidocaine, mepivacaine, and prilocaine. Because the elimination half-life of articaine is considerably shorter than that of other amide local anesthetics, it is the preferred drug in special patient populations, including children, pregnant women, and nursing mothers. Because of the greater lipid solubility of articaine, the buccal infiltration of articaine in the adult mandible has a clinically significant rate of success in providing pulpal anesthesia compared with other amide local anesthetics. Several meta-analyses have concluded that articaine is a preferred dental local anesthetic. Regarding paresthesia, there is no scientific basis for stating that articaine is more neurotoxic than other commonly used dental local anesthetics.

Phentolamine Mesylate: The Local Anesthesia “Off” Switch

All currently used injectable local anesthetics are vasodilators. Three local anesthetics formulations without a vasoconstrictor are available for use in dental cartridges worldwide: 2% lidocaine HCl (not available in dental cartridges in North America); 3% mepivacaine HCl; and 4% prilocaine HCl. These drugs provide—compared with their formulations containing a vasoconstrictor—a short duration of not as profound anesthesia (see [Table 4.17](#)). Additionally, vasodilators increase blood flow in the area in which the drug was deposited as arterioles and capillaries dilate, leading to (1) a more “bloody” surgical field and (2) higher blood levels of the local anesthetic (see [Table 20.11](#)).

A vasoconstrictor (e.g., epinephrine) is added to the local anesthetic to (1) increase the depth and duration of pulpal and soft tissue anesthesia, (2) create a “free” surgical field, and (3) decrease the blood level of the local anesthetic drug, thereby increasing its safety (decreasing the risk of overdose caused by overadministration of the local anesthetic) (see Table 20.11).

For dental procedures on teeth (e.g., restorations, endodontic procedures, extractions, implants) pulpal anesthesia is necessary until such time as the procedure is completed. Soft tissue anesthesia, although necessary for some procedures (e.g., scaling and root planing, periodontal surgery, exodontia) is always of considerably longer duration than pulpal anesthesia.

When one is preparing teeth for placement of restorations—the most common procedure in dentistry⁷⁹—pulpal anesthesia is a necessity for the duration of the preparation (e.g., cutting) of the tooth. Once this is complete, there is no longer a need for continued anesthesia of the tissues, either hard or soft. However, the need for effective intraoperative pain control normally mandates the use of a local anesthetic containing a vasoconstrictor such as epinephrine or levonordefrin, which has become a routine part of dentistry.^{80,81} Patients are commonly discharged from the dental office with residual numbness of their lips and tongue, typically persisting for an additional 3 to 5 hours.⁸²

Residual soft tissue anesthesia is a possible inconvenience or embarrassment to the patient, who is unable to function normally for many hours after leaving the dental appointment. In a survey of patients receiving intraoral local anesthetic, Rafique et al.⁸³ reported that there were several aspects of the post–local anesthetic experience that were disliked by patients, including three major areas: functional, sensory, and perceptual.

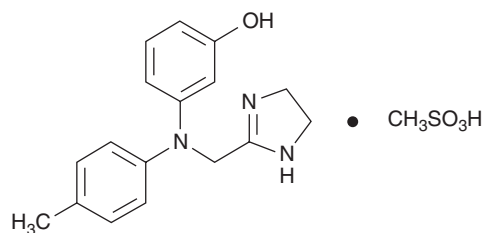
Functionally, patients disliked their diminished ability to speak (lisp), to smile (asymmetric), and to drink (liquid runs from the mouth), and the inability to control drooling while still numb. *Sensorially*, the lack of sensation was described as quite discomfiting, while the *perception* that their body was distorted (e.g., swollen lips) was equally unpleasant. For many patients these sequelae become a significant detriment to their quality of life, making it difficult for them to return to their usual activities for hours after treatment. When the dental appointment concludes at a time approaching the time for a meal, either lunch or dinner, patients must consider whether to eat while numb or postpone their dining until the residual soft tissue anesthesia resolves.

Although not normally a significant problem, residual soft tissue anesthesia may occasionally lead to self-inflicted soft tissue injury in any patient. Self-inflicted soft tissue injury—most commonly of the lip or tongue—is more likely to be noted in younger children and in mentally disabled adult and pediatric patients.⁸⁴

A study of pediatric patients by College et al.⁸⁵ revealed that a significant percentage of IANBs were associated with inadvertent biting of the lips. By age group, the frequency of trauma to the lips was 18% for younger than 4 years, 16% for 4 to 7 years, 13% for 8 to 11 years, and 7% for

TABLE 20.12 Incidence of Self-Inflicted Soft Tissue Injury in Pediatric Populations⁸⁵

Age (Years)	Percentage With Self-Inflicted Soft Tissue Injury
<4	18
4–7	16
8–11	13
≥12	7



• Fig. 20.11 Phentolamine mesylate.

12 years or older (Table 20.12). This can be explained by the fact that the younger patient will test (by biting) their unnumb lip—which hurts—and then test the still-numb side—which does not hurt. Where the adult would normally not proceed beyond this point, the younger child may “play” with this “feeling” and continue to bite ever harder, not realizing the damage being inflicted. Mentally handicapped adults are just as likely to incur self-inflicted soft tissue injury. This author was surprised to learn from dentists who treat geriatric patients that another group—the geriatric patient with dementia—presents a risk of soft tissue injury following local anesthetic injection equal to or greater than that of children and mentally challenged adults.

So, can the numbness produced by local anesthetics be made to resolve more quickly?

The injection of a vasodilating drug into the area of prior local anesthetic administration should accomplish this goal by hastening the redistribution of local anesthetic from the nerve into the cardiovascular system, thereby decreasing the duration of residual soft tissue anesthesia.

Phentolamine Mesylate

Phentolamine mesylate is an α -adrenergic receptor antagonist approved by the FDA in 1952 (Fig. 20.11). Approved uses of phentolamine include diagnosis of pheochromocytoma and treatment of hypertension in pheochromocytoma,^{86,87} prevention of tissue necrosis after norepinephrine extravasation,^{88,89} and reversal of soft tissue anesthesia.⁸⁶ Phentolamine has also been used to treat hypertensive crisis associated with monoamine oxidase inhibitor therapy^{86,89} and in combination with papaverine to treat erectile dysfunction.^{86,90,91}

Phentolamine is a short-acting, competitive antagonist at peripheral α -adrenergic receptors. It antagonizes both α_1 and α_2 receptors, thus blocking the actions of the circulating catecholamines epinephrine and norepinephrine.

Phentolamine also stimulates β -adrenergic receptors in the heart and lungs.

The clinical effects of phentolamine include vasodilation and tachycardia. Vasodilation is a result of both direct relaxation of vascular smooth muscle and α blockade. The drug produces positive inotropic and chronotropic effects, leading to an increase in cardiac output. In smaller doses the positive inotropic effect can predominate and raise blood pressure; in larger doses, peripheral vasodilation can mask the inotropic effect and lower blood pressure. These actions make phentolamine useful in treating hypertension caused by increased circulating levels of epinephrine and norepinephrine, as occurs in pheochromocytoma.⁸⁶

For prevention or treatment of *dermal necrosis* or *sloughing* following extravasation of catecholamines (e.g., epinephrine, norepinephrine), 5 to 10 mg of phentolamine (diluted with 10 to 15 mL of normal saline) is injected into the affected area within 12 hours of extravasation. Visible hyperemia and increased tissue warmth at the site are signs of effective treatment.^{86,92}

For the treatment of *hypertensive emergency* related to any catecholamine excess, such as interactions between monoamine oxidase inhibitors and sympathomimetic amines, phentolamine is administered intravenously as a bolus in a dose of 5 to 15 mg.^{86,93}

Pregnancy and Lactation

As presently used in medicine, phentolamine is categorized by the FDA as a pregnancy category C drug and as “safety unknown” for nursing mothers.^{39,40} (Pregnancy category C—animal studies show adverse fetal effect(s) but no controlled human studies or no animal or human studies; weigh possible fetal risk versus maternal benefit. Lactation category “safety unknown”—inadequate literature available to assess risk; caution advised.)

Phentolamine is available as a 5 mg/mL solution for parenteral administration.

Clinical Trials: Adults and Adolescents

In May 2008 the FDA approved phentolamine mesylate (OraVerse) for dental use to reverse anesthesia following dental injections. Marketed in 1.7-mL dental cartridges, the formulation contains 0.4 mg of phentolamine mesylate (0.235 mg/mL).⁹⁴ The dental formulation of phentolamine is approximately 1/20 the concentration of that used in medicine. In phase 3 randomized, controlled, double-blind clinical trials, patients received a vasoconstrictor-containing local anesthetic on one side of their mouths before a restorative or periodontal maintenance procedure. The primary end point was the elapsed time to the return of normal lip sensation as measured by patient-reported responses to lip palpation. Secondary end points included the patients' perception of altered function, sensation, and appearance, and functional deficits in smiling, speaking, drinking, and drooling, as assessed by both the patient and an observer blinded to the treatment.⁹⁵⁻⁹⁸

Patients were randomized to receive one of four local anesthetics: 2% lidocaine with epinephrine 1:100,000; 2%

mepivacaine with levonordefrin 1:20,000; 4% articaine with epinephrine 1:100,000; or 4% prilocaine with epinephrine 1:200,000.

At the conclusion of the procedure, the patient received either phentolamine mesylate or a control injection. Both patients and all investigators were blinded to the treatment assigned. The study drug was administered at the same site, and in the case of phentolamine mesylate, the same number of cartridges (one or two) as for the previous local anesthetic injection(s). The control was a sham injection in which the plastic needle cap attached to the dental syringe containing an empty cartridge was pushed against, but did not penetrate, the intraoral soft tissue at the site of the previous local anesthetic injection. After receiving phentolamine mesylate or the sham injection, all patients were observed for 5 hours to collect efficacy and safety data, and were then monitored for up to 48 hours.

The 5-hour observation and testing period was a primary determinant in the lower age limit (4 years) for patients. It was felt (correctly, it turned out) that younger patients would be unable to cooperate fully with the assessments required over the 5-hour period of observation.

All patients were trained in assessing the numbness of their lips. Those in the mandibular protocol group were also trained to tap their tongues. The procedure involved a light tapping of these soft tissues with their index or middle finger. Assessments were made every 5 minutes.

The functional assessment battery included measurements of smiling, speaking, and drooling, and drinking 3 ounces of water at various time points during the study.^{97,98} Each functional assessment was rated as normal or abnormal by a research assistant and the patient.

Efficacy of Phentolamine Mesylate: Adolescents and Adults

In the maxillary trial, the median time to recovery of normal sensation in the upper lip was 50 minutes for phentolamine mesylate patients and 132.5 minutes for control patients, a reduction in upper lip anesthesia of 82.5 minutes ($P < .0001$).⁹⁵

In the mandibular trial, the median time to recovery of normal sensation in the lower lip was 70 minutes for phentolamine mesylate patients and 155 minutes for control patients, a reduction in lower lip anesthesia of 85 minutes ($P < .0001$).⁹⁵

Within 30 minutes of phentolamine mesylate administration, 26.7% of maxillary patients reported return of normal lip sensation as compared with 1.7% in the control group. At 1 hour, 59.2% had normal upper lip sensation versus 11.7% for sham patients. At 90 minutes the proportions were 75% and 25%, respectively. Upper lip anesthesia persisting beyond 2 hours occurred in 54.2% of sham patients versus 11.6% of phentolamine mesylate patients.⁹⁵

In the mandible, within 30 minutes of phentolamine mesylate administration, 17.2% of patients reported normal lower lip sensation as compared with 0.8% in the control group. At 1 hour, 41% had normal lower lip sensation versus 7.4% for sham patients. At 90 minutes the proportions were 70.5% and 13.1%, respectively. Lower

lip anesthesia persisting beyond 2 hours occurred in 70.5% of sham patients versus 18.9% of phentolamine mesylate patients.⁹⁵ **PDF Compressor Free Version**

The median time to return of normal sensation to the tongue was 60 minutes for phentolamine mesylate patients and 125 minutes for sham patients, a statistically significant ($P < .0001$) difference of 65 minutes.⁹⁵

Safety of Phentolamine Mesylate: Adolescents and Adults

The overall frequency and the nature of adverse events reported in both the maxillary study and the mandibular study appeared similar in nature and frequency. None of the adverse events in either study was serious or rated severe, and no patient discontinued participation in the study because of an adverse event.^{94,95}

Safety and Efficacy of Phentolamine Mesylate: Children

In a phase 2, double-blinded, randomized, multicenter ($N = 11$), controlled study, pediatric patients between the ages of 4 and 11 years received 2% lidocaine with epinephrine 1:100,000 and either phentolamine mesylate or sham injection. One hundred fifty-two patients were enrolled and completed the study. There were 96 in the phentolamine mesylate group and 56 in the sham injection group. The median time to normal lip sensation was evaluated in patients aged 6 to 11 years who were trainable for lip palpation procedures (see earlier). The reduction in the median time to normal lip sensation for phentolamine mesylate patients ($N = 60$) was 60 minutes compared with 135 minutes in the control group ($N = 43$), representing a reduction of residual soft tissue anesthesia of 75 minutes (55.6%) for both maxillary and mandibular arches. Within 1 hour following administration of phentolamine mesylate, 61% of patients reported normal lip sensation, while only 21% of patients in the sham injection group reported normal lip sensation ($P < .0001$).⁹⁶

Clinical Indications for Reversal of Local Anesthesia

Reversal of local anesthesia should be a treatment option whenever prolonged soft tissue anesthesia presents a potential risk (soft tissue injury) or will negatively impact the patient's lifestyle (e.g., inability to speak or eat) (Table 20.13). Froum et al.⁹⁹ administered phentolamine mesylate following insertion of mandibular implants in an attempt to minimize the risk of postimplant paresthesia along the distribution of the inferior alveolar nerve.

A situation that does not usually represent an indication for soft tissue anesthesia reversal includes postsurgical patients, where prolonged soft tissue anesthesia is desirable as a means of preventing breakthrough pain (see the discussion of postsurgical pain management in Chapter 16). Further, following local anesthetic administration via the periodontal ligament, intraseptal, or intraosseous injection, the localized area of soft tissue anesthesia associated

TABLE 20.13

Indications for Local Anesthesia Reversal

Conservative dental treatment
Nonsurgical periodontal treatment (e.g., scaling and root planing)
Pediatric dentistry
Medically compromised patients (e.g., type 1 diabetic patients)
Geriatric patients
Special needs patients
Postmandibular implant patients
Persons with a need to "return to normal" quickly: <ul style="list-style-type: none"> Business people Social gatherings Lunch or dinner engagements

with these injections obviates the use of phentolamine mesylate.

Clinical Use of Phentolamine Mesylate in Dentistry

Phentolamine mesylate is indicated for the reversal of soft tissue anesthesia (e.g., anesthesia of the lip and tongue) and the associated functional deficits resulting from an intraoral submucosal injection of a local anesthetic containing a vasoconstrictor. Phentolamine mesylate is not recommended for use in children younger than 3 years or weighing less than 15 kg (33 lb).⁹⁴

The recommended dose of phentolamine mesylate is based on the number of cartridges of local anesthetic with vasoconstrictor administered. It is administered in an equal volume, up to a maximum of two cartridges. Phentolamine mesylate is administered at the same location(s) and by the same technique(s) (nerve block or infiltration) used earlier for the local anesthetic administration.⁹⁴

Adverse reactions associated with the administration of phentolamine mesylate were discussed earlier (safety and adverse reaction discussion).^{94,95} Other potential complications are trismus and paresthesia, both of which are related to the act of injection rather than to the drug itself.

Conclusion

Phentolamine mesylate enables the dentist or dental hygienist to significantly decrease the duration of residual soft tissue anesthesia in patients where such numbness may prove to be potentially injurious (children, geriatric, and special needs patients) or may have a negative influence on their quality of life (speaking, eating, negative body image).

Although many patients might not be receptive to the concept of "making it go away faster," the availability in a dental office gives each patient an option to be considered.

TABLE 20.14 Expected Duration of Pulpal Anesthesia

PDF Compressor Free Version

Local Anesthetic Formulation	Approximate Expected Duration of Pulpal Anesthesia by Nerve Block (min)
3% mepivacaine	40
4% prilocaine	40–60
2% lidocaine with a vasoconstrictor	60
4% articaine with a vasoconstrictor	60
2% mepivacaine with a vasoconstrictor	60
4% prilocaine with a vasoconstrictor	60
0.5% bupivacaine with a vasoconstrictor	240–300

Buffering (Alkalinizing) of Local Anesthetics: The Local Anesthetic “On” Switch

The dental profession depends on local anesthetics to provide patients with comfortable and pain-free treatment. Deposit a local anesthetic near to a nerve and it will provide anesthesia. Table 20.14 lists the local anesthetic formulations available with their expected onset of pulpal anesthesia.

Despite the effectiveness of these drugs in providing pain control, there remain a number of vexing “problems” that dentists must cope with, primarily associated with the acidity of the local anesthetic solution itself. These include: (1) pain during the actual administration (injection) of the anesthetic solution, (2) a slower than desired onset of profound (pulpal) anesthesia, and (3) less than optimal effectiveness when one is seeking to anesthetize infected teeth.

Issue 1: Acidity Causes Pain During Injection of Local Anesthetics

Fear of pain is the most common anxiety for dental patients.¹ As effective as local anesthetics can be in preventing pain during treatment, patients fear the act of receiving the anesthetic as much as or more than they fear the dental procedure itself. The dental anesthetic injection also provokes more emergencies than actual dental treatment. Syncope (fainting) was the most common, accounting for 50.3% of all emergencies in a survey of 4307 dentists in North America.¹⁰⁰ Asked for the location and timing of these emergencies, the respondents said that more than half (54.9%) occurred either during or immediately following local anesthetic administration.^{101,102}

Some injection pain can be minimized or eliminated through use of drugs and techniques discussed in previous chapters including: injecting anesthetic slowly,^{103,104} using topical anesthetic, and stretching the tissue before needle penetration.¹⁰⁵

Yet many patients still complain of a burning or stinging sensation as the first drops of anesthetic are injected. This “bee sting effect” is caused by the acidity of the anesthetic solution. On the pH scale, 7.0 is neutral, above 7.0 is basic, and below 7.0 is acidic. Human physiologic pH is 7.4. All injectable local anesthetics (plain drugs with no vasoconstrictor) are slightly acidic. The pH of a plain drug (e.g., 3% mepivacaine HCl, 4% prilocaine HCl) is approximately 6.4, which is closer to physiologic than local anesthetics containing a vasoconstrictor.¹⁰⁶

Vasoconstrictors increase the depth and duration of anesthesia as well as the safety of the local anesthetic. Addition of epinephrine to local anesthetics increases pulpal anesthesia to approximately 60 minutes, with soft tissue anesthesia lasting between 3 and 5 hours or more. However, epinephrine is rapidly oxidized at near physiologic pH values, so the antioxidant sodium bisulfite (NaHSO₃) is added to the solution.¹⁰⁷ The addition of NaHSO₃ lowers the pH of vasoconstrictor-containing solutions to approximately 3.5. Clinical studies have shown pH values ranging between 2.86¹⁰⁷ and 4.16.¹⁰⁸

Alkalinizing (buffering) of local anesthetics has been practiced by the medical profession for more than 100 years.¹⁰⁹ Medical professionals do not use sealed cartridges of local anesthetic solution. Rather, they use plastic syringes and multidose vials of local anesthetic. As the dental profession uses standardized sealed cartridges designed for use in dental syringes, until recently there was no practical means of buffering dental local anesthetics.

Issue 2: Low pH of Local Anesthetic Solutions Slows the Onset of Pulpal Anesthesia

The amide anesthetics are generally stated to have an onset of between 3 and 5 minutes^{110–112}; however, these figures represent the onset of soft tissue anesthesia. Pulpal, or surgical depth, anesthesia develops more slowly.

Following completion of the local anesthetic injection, most dentists report that they wait between 10 and 15 minutes before returning to the treatment room. This is usually long enough for most patients to have achieved sufficient anesthesia for the dentist to start the procedure (the exception being missed blocks, which will require additional injections).

As is known by all practicing dentists (clinical experience), and from the results of well-designed clinical trials, there exists a significant practical and clinical distinction between the onset of soft tissue anesthesia and the onset of pulpal anesthesia.¹⁰⁵ Lai et al.¹¹² found that at 4 minutes after IANB with 2% lidocaine with epinephrine 1:100,000, 70% of patients achieved soft tissue anesthesia (as determined with a sharp dental explorer), yet only 25% had pulpal anesthesia (determined with an EPT). At 6 minutes the proportions were 85% for soft tissue anesthesia and 40% for pulpal anesthesia. Kanaa et al.¹⁰⁴ found that at 8 minutes following IANB with 2% lidocaine with epinephrine 1:80,000, 100% of patients had lingual anesthesia, 93% had

TABLE 20.15 Onset Time of Pulpal Anesthesia

PDF Compressor Free Version

Duration Following Inferior Alveolar Nerve Block With 2% Lidocaine + Epinephrine 1:100,000

Percentage with Pulpal Anesthesia

References

4 minutes	25	103, 107
6 minutes	40	103, 107
10 minutes	60	103, 107
15 minutes	67	103, 107
45 minutes	95	109

lip anesthesia, while only 52% had pulpal anesthesia of the first molar and first premolar, and 27% had pulpal anesthesia of the lateral incisor. These studies, and the extensive clinical experience of all dentists, demonstrate that anesthesia of soft tissues (e.g., lip, tongue) is not a guarantee of pulpal anesthesia.

An analysis of 21 clinical trials looking at the time course of pulpal anesthesia following IANBs with lidocaine with epinephrine (1078 patients) shows that 60% achieved pulpal anesthesia (as determined with EPT) at 10 minutes, increasing to 67% at 15 minutes (Table 20.15).^{104,108}

It appears that 10 to 15 minutes is a reasonable waiting period following IANB to assess a patient's level of anesthesia. Bearing in mind that few general dentists assess a patient with an EPT or freezing spray (e.g., Endo-Ice) before beginning the dental procedure, it can be appreciated that waiting a sufficient amount of time for most patients to become numb is the dentist's best defense against having a patient "jump" while in the chair, when the procedure is begun. "A dentist who doesn't hurt" and "painless injection" were the two most important factors patients considered when evaluating a dentist.¹ It is likely that many patients that are not "completely numb" at the start of the procedure may nevertheless be well on their way toward profound pulpal anesthesia. According to Fernandez et al.¹¹⁰ the peak percentage of patients achieving pulpal anesthesia occurs at 45 minutes, when 95% of patients receiving an IANB had no response to an EPT on a second premolar.

Clinicians have to make a practical choice as they decide when to start the dental procedure. This author has never heard doctors say they wait 45 minutes. The fact that most dentists deliver a block or an infiltration and wait approximately 10 to 15 minutes to start the procedure demonstrates that most dentists have a practical awareness that their patients are generally going to be numb enough by this time for the procedure to begin and, if they are not yet numb, an appropriate amount of time has elapsed to deliver a second injection painlessly.

Issue 3: Acidic Local Anesthetics Work Poorly on Infected Teeth

Providing effective pain control when one is treating infected teeth—specifically mandibular molars—for pulpal extirpation or extraction remains a challenge. This "problem" is

discussed in depth in Chapter 16 and 19. A monograph by the American Association of Endodontists describes several reasons why problems occur in attempting to achieve pulpal anesthesia with IANBs and how to overcome these issues.¹¹¹

Simply put, the lower the pH of the tissue into which a local anesthetic is deposited, the fewer of the "active" base (RN) molecules of the drug are present. The base form of the local anesthetic is able to diffuse through the nerve membrane.

Normal tissue pH is approximately 7.4. In infected tissue, according to De Jong et al.¹¹³ local tissue pH ranges between 5.0 and 6.0.

At the pH (approximately 3.5) in a dental cartridge of lidocaine and epinephrine, only 0.006% of the drug is in the RN form. This is a major reason for the slow onset of anesthesia. However, the buffering capability of the human body is quite effective at raising the pH of the injected solution, albeit quite slowly toward the body's normal pH of 7.4, where a much higher percentage of the drug is in the RN form. This transformation occurs over a 45-minute period.^{108,110}

Buffering: A Possible Solution to These Issues

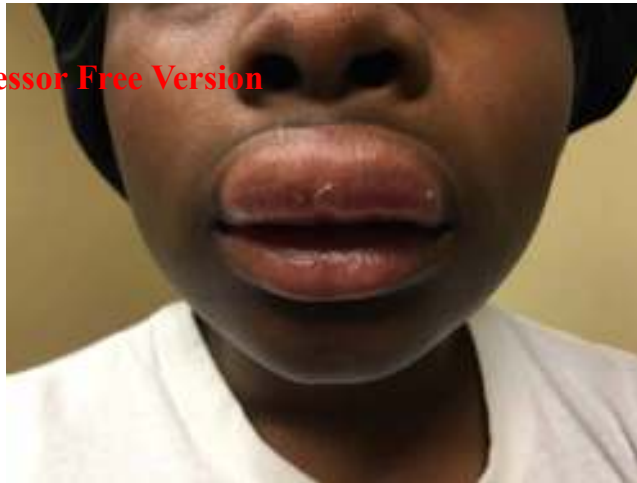Obviously, in terms of onset time, with all other things being equal, injection of a local anesthetic with a pH close to physiologic would be optimal. Since local anesthetics containing epinephrine provide the depth and duration of pain control necessary for most dental procedures, and since local anesthetics containing epinephrine are formulated at a relatively acidic pH for their shelf life to be reasonable, an obvious question is whether the anesthetic can be alkalinized (buffered) just before injection to increase the percentage of the active RN form of the drug immediately available, reducing the time necessary to achieve pulpal anesthesia.

Although dentistry is the health care specialty with the longest history and most regular use of local anesthetics in medicine, it has been the last to embrace the art and science of buffering. Various other medical professionals use local anesthetics, including ear, nose, and throat specialists; plastic and reconstructive surgeons; obstetricians; dermatologists; allergists; critical care specialists; and podiatrists. These specialists use multidose vials of plain lidocaine (primarily) or lidocaine with epinephrine in plastic syringes. They then add a small volume of sodium bicarbonate (the buffering agent) to the syringe, changing the pH of the solution, and inject it. Depending on the mixing and delivery methods, and the pH of the bicarbonate solution, clinical results have been quite varied, ranging from resounding success to utter failure.¹¹⁴⁻¹¹⁷

What Is a Buffer?

A buffer is an aqueous solution consisting of a mixture of a weak acid and its conjugate base or a weak base and its conjugate acid. Its pH changes insignificantly when a small amount of strong acid or base is added to it, and thus a buffer is used to prevent any change in the pH of a solution. As applied to

PDF Compressor Free Version



• **Fig. 20.12** Edema of upper lip following buffering with hypertonic solution.

local anesthetics, a buffer with a basic pH (sodium bicarbonate) is added to the highly acidic local anesthetic solution to raise the anesthetic pH to that of the buffer.

Buffering Local Anesthetics

By raising the pH of the anesthetic solution, it is theoretically possible to eliminate, or at least to minimize, pain on injection, slow onset, and decreased efficacy in the presence of infection.

Davies¹¹⁸ conducted a meta-analysis of 22 prospective, randomized, controlled human trials evaluating pH buffering as a means of reducing anesthetic injection pain that included two dental studies. He concluded that buffering provides a significantly more comfortable injection that may be particularly useful for injections in sensitive areas such as the face and head, or when injection pain can cause difficulty in providing treatment, as with pediatric patients.^{119,120} The Cochrane Collaboration, reviewing 23 clinical trials, concluded that buffering lidocaine with epinephrine improves patient satisfaction.¹²¹

To what pH should the solution be raised to optimize results? Clinical trials generally did not show improvement where the unbuffered anesthetic solution was already near a pH of 7.0 or where the buffered anesthetic was not raised above pH 7.0, suggesting that meaningful improvement is probably achieved by buffering to pH 7.0 or above.

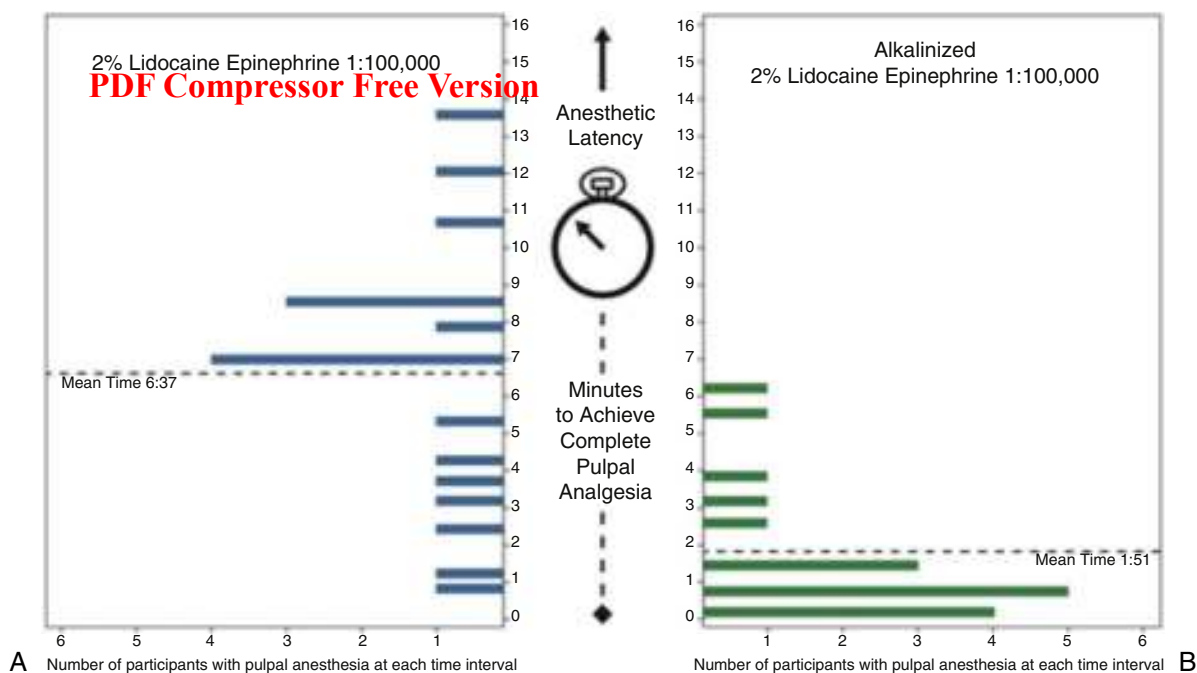
On the other hand, buffering lidocaine with epinephrine above pH 7.6 is known to cause the local anesthetic to precipitate out of solution.

Accordingly, buffering lidocaine and lidocaine with epinephrine to a pH range of approximately 7.4 is probably optimal in terms of efficacy in improving performance, and in terms of safety to avoid overbuffering and production of a hypertonic anesthetic solution that may lead to edema at the injection site (Fig. 20.12). Malamed et al reported on a randomized, controlled clinical trial that evaluated the efficacy of buffering local anesthetic directly in the dental cartridge using an automated compounding pen. (Onset[®] Onpharma, www.onpharma.com)¹²² (Fig. 20.13). The study included 20 participants. Each received one control and one test inferior alveolar nerve block (IANB) with 1.8 mL of the

solution. The control solution was non-alkalinized 2% lidocaine with epinephrine 1:100,000 at pH 3.85 (traditional dental local anesthetic cartridge). The test solution was 2% lidocaine with epinephrine 1:100,000 alkalinized to a pH of 7.31. Time to onset of pulpal anesthesia was measured using an endodontic freezing spray (Endo-Ice[®] Coltene, www.coltene.com) and confirmed with an electric pulp tester (EPT). Injection pain was measured using a 100mm visual analog scale. With the alkalinized anesthetic, 71% of participants achieved pulpal analgesia in 2 minutes or less. (Table 20.16) With non-alkalinized local anesthetic 12% achieved pulpal analgesia in 2 minutes or less ($P=0.001$). Average time to pulpal analgesia for the for alkalinized anesthetic was 1:51 (range 0:11 to 6:10). Average time to pulpal analgesia for non-alkalinized anesthetic was 6:37 (range 0:55 to 13:25) ($P=0.001$).¹²²

72% of the participants rated the alkalinized injection as more comfortable, 11% rated the non-alkalinized injection as more comfortable, and 17% reported no preference ($P=0.013$). Forty-four percent of the patients receiving alkalinized anesthetic rated the injection pain as zero (“no pain”) on a 100mm VAS, compared to 6% of the patients who received non-alkalinized anesthetic ($P=0.056$).¹²²

A collateral benefit of buffering local anesthetics with epinephrine using sodium bicarbonate is that, in addition to reducing injection pain and speeding the onset of analgesia, the buffering process itself creates CO₂ in solution, which becomes part of the injection—provided that the injection is delivered within 30 or 45 seconds after buffering. Bokesch et al.¹²² demonstrated the importance of CO₂ when they showed a significantly more profound conduction block with lidocaine if free CO₂ was present in the solution. Wong et al.¹²³ reported that CO₂ made lidocaine twice as potent, while Condouris and Sakalis¹²⁴ reported that CO₂ in solution created a 10-fold increase in procaine action. This suggests that the creation of CO₂ in the solution may influence the results observed in local anesthetic buffering studies, as well as improving the results that can be achieved by buffering in clinical practice.



• **Fig. 20.13** Time to onset of pulpal anesthesia following inferior alveolar nerve block. (A) Unbuffered lidocaine 2% with epinephrine 1:100,000; (B) Buffered (alkalinized) lidocaine 2% with epinephrine 1:100,000

TABLE 20.16 Occurrence of Syncope During Blood Donation by Age¹³⁰

Age (Years)	Number	Percentage Syncope
50–59	0/21	0
40–49	8/79	10
30–39	24/125	19
20–29	28/117	24
10–19	3/10	30



• **Fig. 20.14** Onset local anesthetic buffering system.

Dental Anesthetic Buffering System

An automated buffering system (Onset, Onpharma, Carson City, Nevada, United States) was introduced in the United States in 2010 using the dental local anesthetic cartridge as the mixing vessel (Fig. 20.14). Buffering using the sealed dental anesthetic cartridge preserves the dissolved CO₂, making it available during the injection. The automated system is also designed to make the cartridge buffering process more precise as well as more convenient for delivering the buffered anesthetic immediately after buffering. Other buffering systems were introduced subsequently (e.g., Anutra, Anutra Medical Inc., Morrisville, North Carolina, United States; Fig. 20.15).

Conclusion

Although anesthetic buffering has been studied since the early 20th century and used regularly for decades in the

medical profession, the relative volatility of the CO₂ present in buffered anesthetic and the buffering solution itself may not have been widely appreciated. This volatility may have affected the outcomes that buffering researchers and clinical practitioners have observed. Other factors, such as the starting pH of the buffering solution, the delay in administering buffered anesthetic, and the adsorption of the base form of the anesthetic in the mixing and delivery armamentarium, may also have had an impact on the results observed in medical studies.

Buffering local anesthetic cartridges benefits both dentists and their patients if the benefits of buffering are consistently reliable and if buffering is available in a system that incorporates the standard dental anesthetic cartridge.



• Fig. 20.15 Anutra local anesthetic buffering system.

The clinical significance of buffering is that it reduces the time to onset of pulpal anesthesia enough such that dentists may administer the anesthetic, remain with their patient, and start the procedure more promptly.

This author is an advocate for the use of buffered local anesthetics in all dental injections, particularly those in the mandibular arch (see Chapter 16 and 19).

Tetracaine and Oxymetazoline: Nasal Mist for Anesthesia of Maxillary Nonmolar Teeth

Local anesthetics are dentistry's most important drugs. Deposited close to a nerve, they will prevent the nerve impulse from being propagated. The problem is that local anesthetics need to be injected for them to reach the target nerve. However, fear of needles—trypanophobia—is a significant problem for many dental patients. The act of receiving the injection is the most traumatic part of their dental experience.¹

All dentists have heard the following from patients:

“Doctor, do you have to give me a ‘shot’ to do this?”

“Doctor, I hate getting ‘shots,’ but once I’m numb I’m OK.”

Syncopal (fainting) represented 50.3% of 30,608 medical emergencies reported by 4307 dentists in North America.¹⁰⁰ More than 54% of medical emergencies occurred either during or immediately following the injection of a local anesthetic.¹⁰¹

Trypanophobia: Fear of Needles

Gatchel et al.¹²⁵ and Dionne et al.¹²⁶ reported that between 30 million to 40 million persons in the United States avoid dental care because of fear of pain and needles. In a Canadian study, 21.2% of females reported mild to intense fear of injections, dentists, physicians, and hospitals, with 4.9% reporting a phobic level of fear.¹²⁷

In a Swedish study, 23% of 200 persons reported needle phobia as the primary reason they would not donate blood.¹²⁸ Similarly, in the United States, in a survey of 177 college-aged students, 27% cited needle phobia as a reason they avoided blood donation.¹²⁹

When persons do donate blood, they are routinely placed in a supine position to help maintain adequate blood flow to their brain. Yet in spite of this precaution, syncope still occurs, primarily in younger persons (Table 20.16): during blood donation, 30% of persons aged between 10 and 19 years fainted, 24% of persons aged between 20 and 29 years fainted, and 19% of persons aged between 30 and 39 years fainted.¹³⁰

Another potential risk associated with local anesthetic injection is needlestick injury. The Needlestick Safety and Prevention Act of 2000 mandates the use of needle-free technology whenever possible.¹³¹

The Nose

Because of the nose's abundant blood supply, instillation of drugs into the nose to achieve a systemic action, although not commonplace, is used in emergency medicine^{132,133} and pediatric dentistry.¹³⁴ Midazolam, a benzodiazepine, is used as a nasal mist in management of status epilepticus in children^{132,133} and as a sedative in uncooperative or preoperative children in pediatric dentistry.¹³⁴

Cocaine has a significant history of abuse when “snorted” into the nose.^{135,136}

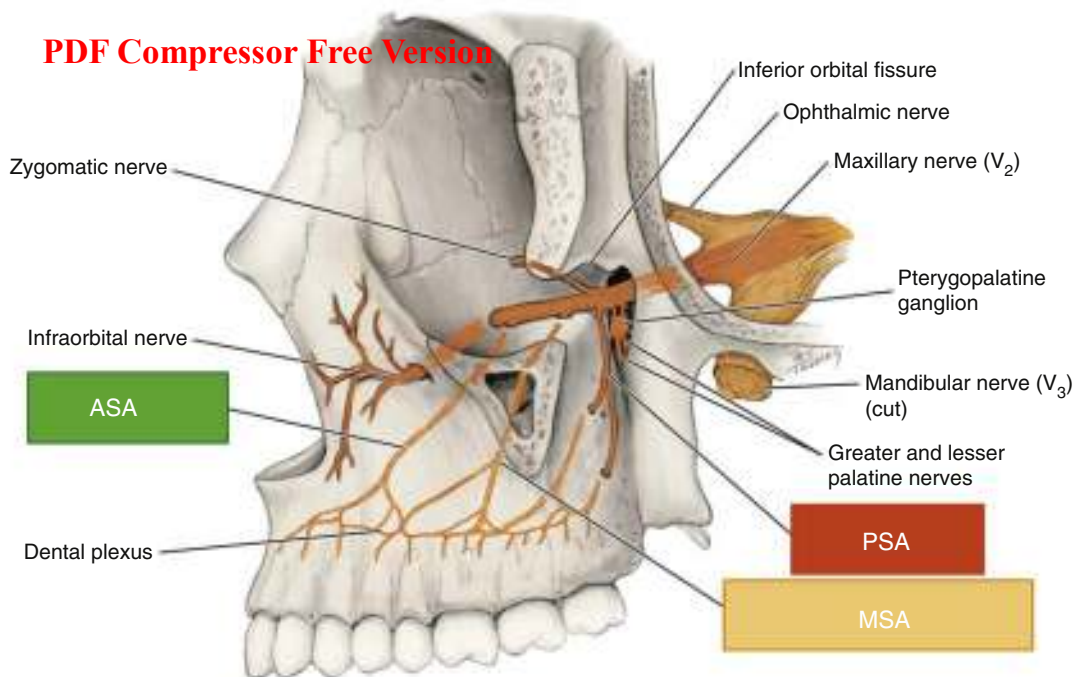
Ear, nose, and throat surgeons (ENT's) use local anesthetics frequently during nasal surgery. Most patients are conscious during the surgery; many receiving moderate sedation. The most frequently used local anesthetics by ENT's are tetracaine, lidocaine, and cocaine. Because of the greater risk of toxicity (overdose) associated with cocaine,^{137,138} tetracaine is preferred in most situations.¹³⁸⁻¹⁴¹ Additionally, a vasoconstrictor is commonly added to the tetracaine to decrease bleeding intraoperatively and to increase the depth and duration of the anesthesia. Epinephrine is rarely used, as its cardiovascular effects are significant when administered intranasally.¹⁴² Oxymetazoline is the most commonly used vasoconstrictor in nasal surgery.^{138,143}

There are anecdotal reports from patients receiving intranasal local anesthetics for nasal surgery that their maxillary teeth “felt different.”

Both tetracaine and oxymetazoline have been approved by the FDA for use as an anesthetic spray for nasal surgery and have been used successfully in nasal surgery for many years. Clinical trials were necessary to demonstrate to the FDA the safety and efficacy of this combination when used for a new indication—dental anesthesia.¹⁴⁴⁻¹⁴⁷

Intranasal Mist for Pulpal Anesthesia of Maxillary Nonmolar Teeth

The third division of the trigeminal nerve—the maxillary nerve (V₂)—provides sensory innervation to the maxillary dentition (see Chapter 12) (Fig. 20.16). The PSA nerve,



• **Fig. 20.16** Innervation of maxillary teeth. ASA, Anterior superior alveolar; MSA, middle superior alveolar; PSA, posterior superior alveolar. (Modified from Fehrenbach M, Herring S. *Illustrated Anatomy of the Head and Neck*. 4th ed. St Louis: Saunders; 2012.)

providing pulpal anesthesia to maxillary molars, does not enter the infraorbital canal on the posterior surface of the maxilla. However, when the maxillary nerve enters the infraorbital canal, it is called the *infraorbital nerve*. The middle superior alveolar (MSA) and anterior superior alveolar (ASA) nerves are branches of the infraorbital nerve arising within the canal. The MSA nerve provides sensory innervation to the two maxillary premolars and, perhaps, to the mesiobuccal root of the first molar as well as the periodontal tissues, buccal soft tissue, and bone in the premolar region. The ASA nerve, a relatively large branch, comes off the infraorbital nerve approximately 6 to 10 mm before the latter exits the infraorbital foramen. Descending within the anterior wall of the maxillary sinus, it provides pulpal innervation to the central and lateral incisors and the canine, and sensory innervation to the periodontal tissues, buccal bone, and mucous membranes of these teeth.

Safety of 3% Tetracaine Plus Oxymetazoline in Dental Nasal Anesthesia

Giannakopoulos et al.¹⁴⁴ studied the pharmacokinetics and cardiovascular effects of 3% tetracaine plus 0.05% oxymetazoline in study participants receiving the MRD and twice the MRD.¹⁴⁵ Physiologic parameters remained stable throughout the testing period, with small but significant ($P < .05$) decreases in heart rate (6.1 beats per minute for twice the MRD and 7.5 beats per minute for the MRD). Systolic blood pressure for the twice the MRD group increased by 5.9 mmHg at 90 minutes. Mean oxygen saturation remained about 99%.

Measured blood levels of tetracaine were undetectable in most participants. Oxymetazoline blood levels of

participants who received twice the MRD were approximately 50% greater than those of participants who received the MRD, with a half-life of 1.72 to 2.32 hours.

They concluded that intranasal tetracaine/oxymetazoline mist was generally well tolerated in the study participants. The safety profile and pharmacokinetics of this intranasal formulation indicate that it appears to be generally well tolerated in patients for achieving anesthesia of the maxilla.^{144,145}

Efficacy of 3% Tetracaine Plus Oxymetazoline in Dental Nasal Anesthesia: Soft Tissue Anesthesia

In two published phase 3 clinical trials, the clinical efficacy of K-305 (the research identifier for the two active ingredients) was compared with that of placebo and/or 3% tetracaine without a vasoconstrictor.^{146,147} A third, as yet unpublished, phase 3 clinical trial evaluated the safety and efficacy of K-305 in a pediatric population aged 3 to 17 years.¹⁴⁸

The primary efficacy end point in all studies was completion of a single standard dental procedure (e.g., drilling and restoring a decayed tooth) without the need for “rescue” by injection of local anesthetic (4% articaine plus epinephrine 1:100,000). K-305 was administered bilaterally, the goal being to achieve pulpal anesthesia of 10 teeth (second premolar to the contralateral second premolar). [Table 20.17](#) presents the overall success rates for these three trials. The duration of the procedures ranged from 5 to 43 minutes.

The success rates for K-305 (12 teeth—second premolar to contralateral second premolar) were significantly higher than those for plain tetracaine or placebo (see [Table 20.17](#)).

TABLE 20.17 Summary of Intranasal Local Anesthetic Spray Studies. Anesthesia Success for 10 Teeth (Second Premolar to Contralateral Second Premolar)

PDF Compressor Free Version

	Success (%)			
	Phase 2 Adult ¹⁴⁵	Phase 3 Adult ¹⁴⁶	Phase 3 Adult ¹⁴⁷	Phase 3 Pediatric ¹⁴⁸ (>40 kg)
K-305	83	84.1	88	90
Tetracaine	—	27.3	—	—
Placebo	—	27.3	28	40

TABLE 20.18 Summary of Intranasal Local Anesthetic Spray Studies by Teeth

	Success (%)			
	Phase 2 Adult ¹⁴⁵	Phase 3 Adult ¹⁴⁶	Phase 3 Adult ¹⁴⁷	Phase 3 Pediatric ¹⁴⁸
First premolar to first premolar (eight teeth)	94	96	96 (canine to canine)	98
First and second premolars (four teeth)	NA	NA	79	NA
Second premolars (two teeth)	75	63	64	64

TABLE 20.19 Results for K-305 Nasal Spray in the Pediatric Population¹⁴⁸

Weight (kg)	Successful Anesthetic Response	
	K-305 (N = 60)	Placebo (N = 30)
10 to <20	88% (14/16)	88% (7/8)
20 to <40	58% (14/24)	42% (5/12)
≥40 kg	90% (18/20)	40% (4/10)

Success rates from the first premolar to the contralateral first premolar were above 95% in all clinical trials, while success rates for the second premolars alone ranged from 63% to 74% (Table 20.18).

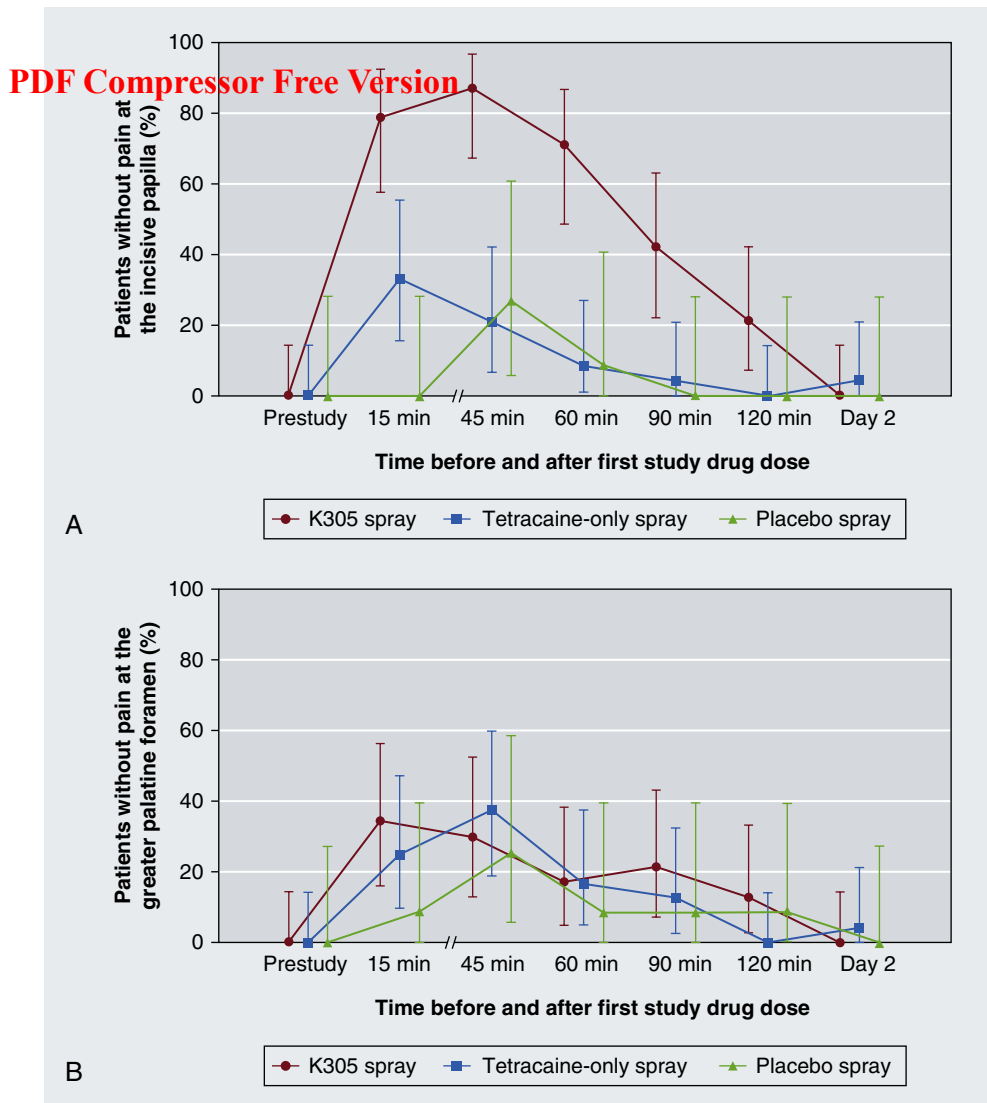
The success rates in the pediatric study were dependent on the weight of the child.¹⁴⁸ The placebo and K-305 success rates were the same (88%) in patients weighing between 10 kg and less than 20 kg. From 20 kg to less than 40 kg a nonsignificant difference was noted (58% for K-305, 42% for placebo), while a significant difference was seen in patients weighing 40 kg or more (90% for K-305, 40% for placebo).¹⁴⁸ It was surmised that the younger, lighter-weight (<40 kg) patients might have been less able to differentiate or to respond appropriately to the questions from the evaluators regarding their level of comfort/discomfort (Table 20.19).

The success rates noted for all clinical trials of K-305 can be explained by the innervation provided by the PSA, MSA, and ASA nerves (see earlier). Maxillary molars are not anesthetized by tetracaine plus oxymetazoline as the PSA nerve is not located in the area in which the spray is

administered. However, for teeth receiving pulpal innervation from the ASA and MSA nerves the success rates are considerably greater up to the first premolars (94% to 98%). Lower success rates are noted in second premolars (63% to 75%) as their apices may be located too distal for the nasal spray to reach them or, when the MSA nerve is absent, pulpal innervation is supplied by the PSA nerve.

Efficacy of 3% Tetracaine Plus Oxymetazoline in Dental Nasal Anesthesia: Palatal Anesthesia

Ciancio et al.¹⁴⁶ tested for palatal soft tissue anesthesia, inserting a sharp probe into the greater palatine foramen and the incisive papilla (Figure 20.16). At the greater palatine foramen there was no clinical difference in palatal soft tissue anesthesia between K-305, tetracaine alone, and placebo. This is explained by the location of the foramen, usually at or distal to the maxillary second molar. At the incisive foramen, however, 79.2% of participants had palatal anesthesia at 15 minutes following spray,



• **Fig. 20.17** Incidence of anesthesia at (A) incisive papilla and (B) greater palatine foramen. (From Ciancio SG, Marberger AD, Ayoub F. Comparison of 3 intranasal mists for anesthetizing maxillary teeth in adults: a randomized, double-masked, multicenter phase 3 clinical trial. *J Am Dent Assoc.* 2016;147:339–347.e1.)

which was significantly greater than with either tetracaine alone (33%) or placebo (0%) (see Fig. 20.17).¹⁴⁶ Palatal anesthesia persisted for 45.9 minutes for participants who received K-305.

Anesthesia of extraoral soft tissues (e.g., upper lip, anterior portion of face) was not observed.

Adverse Events

As might be expected with an intervention involving a nasal spray, the most frequent adverse events were rhinorrhea (52%), nasal congestion (32%), and nasal discomfort, most of which were considered, by the patient, to be mild. By the day after treatment, most patients had returned to baseline status, with no clinically significant problems manifest.¹⁴⁶

Conclusion

K-305 was approved by the FDA in June 2016 for the following indication: a single maxillary restorative procedure on patients weighing at least 40 kg on maxillary nonmolar teeth (second premolar to central incisor) and in all 10 primary maxillary teeth (teeth A through J). The proprietary name is Kovanaze (St. Renatus LLC, Fort Collins, Colorado, United States).

A technique for achieving intraoral pulpal anesthesia without the need for injection can be of great benefit to the many dental patients who have a fear of needles. The lack of any extraoral soft tissue anesthesia combined with the presence of palatal soft tissue anesthesia makes the nasal spray a compelling addition to dentistry's pain management armamentarium.

References

- de St, George J. How do we judge by *Dent Today*. 2004;23(8):96–99.
- Kanaa MD, Meechan JG, Corbett IP, Whitworth JM. Speed of injection influences efficacy of inferior alveolar nerve blocks: a double-blind randomized controlled trial in volunteers. *J Endod*. 2006;32:919–923.
- Pashley EL, Nelson R, Pashley DH. Pressures created by dental injections. *J Dent Res*. 1981;60:1742–1748.
- Hochman MN, Chiarello D, Hochman CB, Lopatkin R, Pergola S. Computerized local anesthesia delivery vs. traditional syringe technique. *NY State Dent J*. 1997;63:24–29.
- Gibson RS, Allen K, Hutfless S, et al. The Wand vs. traditional injection: a comparison of pain related behaviors. *Pediatr Dent*. 2000;22:458–462.
- Nicholson JW, Berry TG, Summitt JB, et al. Pain perception and utility: a comparison of the syringe and computerized local injection techniques. *Gen Dent*. 2001;49:167–172.
- Perry DA, Loomer PM. Maximizing pain control: the AMSA injection can provide anesthesia with few injections and less pain. *Dimens Dent Hyg*. 2003;1:28–33.
- Yogesh Kumar TD, John JB, Asokan S, Geetha Priya PR, Punithavathy R, Praburajan V. Behavioral response and pain perception to computer controlled local anesthetic delivery system and cartridge syringe. *J Indian Soc Pedod Prev Dent*. 2015;3:223–228.
- Kwak EJ, Pang NS, Cho JH, Jung BY, Kim KD, Park W. Computer-controlled local anesthetic delivery for painless anesthesia: a literature review. *J Dent Anesth Pain Med*. 2016;16:81–88.
- Baghlaf K, Alamoudi N, Elashiry E, Farsi N, El Derwi DA, Abdullah AM. The pain-related behavior and pain perception associated with computerized anesthesia in pulp tomies of mandibular primary molars: a randomized controlled trial. *Quintessence Int*. 2015;46:799–806.
- Hochman M. Single-tooth anesthesia: pressure-sensing technology provides innovative advancement in the field of dental local anesthesia. *Compendium*. 2007;28:186–193.
- Hochman M, Friedman M, Williams W, Hochman C. Interstitial pressure associated with dental injections: a clinical study. *Quintessence Int*. 2006;37:469–476.
- Friedman MJ, Hochman MN. The AMSA injection: a new concept for local anesthesia of maxillary teeth using a computer-controlled injection system. *Quintessence Int*. 1998;29:297–303.
- Lee S, Reader A, Nusstein J, et al. Anesthetic efficacy of the anterior middle superior alveolar (AMSA) injection. *Anesth Prog*. 2004;51:80–89.
- Friedman MJ, Hochman MN. P-ASA block injection: a new palatal technique to anesthetize maxillary anterior teeth. *J Esthet Dent*. 1999;11:63–71.
- Lopez-Valverde A, De Vicente J, Cutando A. The surgeons Halsted and Hall, cocaine and the discovery of dental anaesthesia by nerve blocking. *Br Dent J*. 2011;211(10):485–487.
- Ruetsch YA, Boni T, Borgeat A. From cocaine to ropivacaine: the history of local anesthetic drugs. *Curr Top Med Chem*. 2001;1:175–182.
- Lofgren N. *Studies on Local Anesthetics: Xylocaine, a New Synthetic Drug*. Stockholm: Hoegstroems; 1948.
- Muschaweck R, Rippel P. Ein neues Lokalanasthetikum (Carticain) aus der Thiophenreihe [A new local anaesthetic (articaine) in the thiophene series]. *Prakt Anaesth*. 1974;9:135–146.
- Lemay H, Albert G, Helie P, et al. Ultracaine en dentisterie operatoire conventionnelle [Ultracaine in conventional operative dentistry]. *J Can Dent Assoc*. 1984;50:703–708.
- Vree TB, Gielen MJ. Clinical pharmacology and the use of articaine for local and regional anaesthesia. *Best Pract Res Clin Anaesthesiol*. 2005;19:293–308.
- Demircioglu RI, Gozdemir M, Usta B, et al. Comparison of intrathecal plain articaine and levobupivacaine with fentanyl for Caesarean section. *Clin Invest Med*. 2016;39:27516.
- Septodont Inc: *Dental Local Anesthetic Market Share, United States, Calendar Year–2014*. Lancaster: Septodont Inc; 2015.
- Yapp KE, Hopcraft MS, Parashos P. Dentists' perceptions of a new local anaesthetic drug-articaine. *Aust Dent J*. 2012;57:18–22, quiz 109.
- GfK HealthCare. *Deutscher Dentalmarkt Jahresbericht (DDMs)*. Nuremberg: GfK HealthCare; 2010. German dental market annual report 2010. Published 2011.
- Malamed SF, Gagnon S, Leblanc D. Safety of articaine: a new amide local anesthetic. *J Am Dent Assoc*. 2001;132:177–185.
- Bircher AJ, Messmer SL, Surber C, Ruffi T. Delayed-type hypersensitivity to subcutaneous lidocaine with tolerance to articaine: confirmation by in vivo and in vitro tests. *Contact Dermatitis*. 1996;34:387–389.
- El-Qutob D, Morales C, Pelaez A. Allergic reaction caused by articaine. *Allergol Immunopathol (Madr)*. 2005;33:115–116.
- Malamed SF, Gagnon S, Leblanc D. Efficacy of articaine: a new amide local anesthetic. *J Am Dent Assoc*. 2000;131:635–642.
- Malamed SF, Gagnon S, Leblanc D. Articaine hydrochloride in pediatric dentistry: safety and efficacy of a new amide-type local anesthetic. *Pediatr Dent*. 2000;22:307–311.
- Hawkins JM, Moore PA. Local anesthesia: advances in agents and techniques. *Dent Clin N Amer*. 2002;46:719–732.
- Rupieper N, Stocker L. Haemoglobinspiegel unter Lokalanesthetie mit Bupivacain, Carticain und Etidocain [Met-Hb formation and local anesthesia using bupivacaine, carticaine and etidocaine]. *Anaesthesist*. 1981;30:23–25.
- HANSAMED. *Ultracaine DS Forte 1:100,000, Drug Package Insert*. Mississauga: HANSAMED; 2015.
- Kammerer PW, Seeling J, Alshihri A, Daublander M. Comparative clinical evaluation of different epinephrine concentrations in 4% articaine for dental local infiltration anesthesia. *Clin Oral Investig*. 2014;18:415–421.
- Malamed SF, Tavana S, Falkel M. Faster onset and more comfortable injection with alkalized 2% lidocaine with epinephrine 1:100,000. *Compend Contin Educ Dent*. 2013;34:1–11.
- Robertson D, Nusstein J, Reader A, Beck M, McCartney M. The anesthetic efficacy of articaine in buccal infiltration of mandibular posterior teeth. *J Am Dent Assoc*. 2007;138:1104–1112.
- Meechan JG, Ledvinka JJ. Pulpal anaesthesia for mandibular central incisor teeth: a comparison of infiltration and intraligamentary injections. *Int Endod J*. 2002;35:629–634.
- Kanaa JM, Whitworth JM, Corbett IP, Meechan JG. Articaine buccal infiltration enhances the effectiveness of lidocaine inferior alveolar nerve block. *Int Endod J*. 2009;42:238–246.
- Drugs.com. FDA pregnancy categories. Available at: <http://www.drugs.com/pregnancy-categories.html>. Accessed May 18, 2018.
- CDER Small Business and Industry Assistance. Drugs in pregnancy and lactation: improved benefit-risk information; 2015. Available at: <https://www.fda.gov/downloads/Drugs/DevelopmentApprovalProcess/SmallBusinessAssistance/UCM431132.pdf>. Accessed May 18, 2018.
- Giuliani M, Grossi GB, Pileri M, Lajolo C, Casparrini G. Could local anesthesia while breast-feeding be harmful to infants? *J Pediatr Gastroenterol Nutr*. 2001;32:142–144.
- Novocol Pharmaceutical of Canada Inc. Septanest drug package insert. Cambridge: Novocol Pharmaceutical of Canada Inc. 2006.
- Haas DA, Lennon D. A 21 year retrospective study of reports of paresthesia following local anesthetic administration. *J Can Dent Assoc*. 1995;61:319–320, 323–326, 329–330.

44. Hillerup S, Jensen R. Nerve injury caused by mandibular block analgesia. *Int J Oral Maxillofac Surg*. 2006;35:437–443.
45. Garisto GA, Gaffen AS, Lawrence HP, Tenenbaum HC, Haas DA. Occurrence of paresthesia after dental local anesthetic administration in the United States. *J Am Dent Assoc*. 2010;141(7):836–844.
46. Kingon A, Sambrook P, Goss A. Higher concentration local anaesthetics causing prolonged anaesthesia. Do they? A literature review and case reports. *Aust Dent J*. 2011;56:348–351.
47. Practice alert: paraesthesia following local anaesthetic injection. *Dispatch, Royal Coll Dent Surg Ont*. 2005;19:26.
48. Oral and Dental Expert Group. Therapeutic guidelines: oral and dental 2012, version 2. Melbourne: Australian Dental Association; p. 116. 2012.
49. *Mosby's Medical Dictionary*. 10th ed. St Louis: Mosby; 2016.
50. Haas DA. Articaine and paresthesia: epidemiological studies. *J Am Coll Dent*. 2006;73:5–10.
51. Pogrel MA, Thamby S. Permanent nerve involvement resulting from inferior alveolar nerve blocks. *J Am Dent Assoc*. 2000;131:901–907.
52. Pogrel MA, Thamby S. The etiology of altered sensation in the inferior alveolar, lingual, and mental nerves as a result of dental treatment. *J Calif Dent Assoc*. 1999;27:531–538.
53. Dower JS Jr. A review of paresthesia in association with administration of local anesthesia. *Dent Today*. 2003;22:64–69.
54. Berde CB, Strichartz GR. Local anesthetics. In: Miller RD, ed. *Miller's Anesthesia*. 8th ed. Philadelphia: Saunders; 2015:1028–1054.
55. Pogrel MA. Permanent nerve damage from inferior alveolar nerve blocks—an update to include articaine. *J Calif Dent Assoc*. 2007;36:271–273.
56. Pogrel MA. Permanent nerve damage from inferior alveolar nerve blocks: a current update. *J Calif Dent Assoc*. 2012;40:795–797.
57. McDowell AJ. Effective practical steps to avoid complications in face-lifting. Review of 105 consecutive cases. *Plast Reconstr Surg*. 1972;50:563–572.
58. Lagarde P. Paresthesies du territoire mentonnier, secondaires a un traitement endodontique [Paresthesia in the area of the chin, secondary to endodontic treatment]. *Inf Dent*. 1978;60:17–23.
59. Hickel R, Spitzer WJ, Petschelt A, Voss A. Zur Problematik von Sensibilitätsstörungen nach Leitungsanästhesie im Unterkiefer [Sensitivity problems following mandibular conduction anesthesia]. *Dtsch Zahnärztl Z*. 1988;43:1159–1161.
60. Nickel AA Jr. A retrospective study of paresthesia of the dental alveolar nerves. *Anesth Prog*. 1990;37:42–45.
61. Transcript of the record of judgements of the Eastern High Court. CMS-Dental Aps v. *The Danish Dental Association's Patient Insurance Scheme*; 2009. 3rd Branch No. B-3047-05.
62. Stenver DI. *Case Number: 3200-1367, Adverse Effects From Anaesthetics Used in Relation With Dental Care With a Special Focus on Anaesthetics Containing Articaine*. Pharmacovigilance Working Party of the European Union. 20 October 2006.
63. Danish Medicines Agency (Laegemiddel Styrelsen), Report 25. October 2011.
64. US Food and Drug Administration Center for Drug Evaluation and Research. Office of Post-Marketing Drug Risk Assessment; 2009. Available at: <http://www.fda.gov/Drugs/GuidanceComplianceRegulatoryInformation/Surveillance/AdverseDrugEffects/default.htm>. Accessed 8 January 2019.
65. Schatz SN, Weber RJ. Adverse drug reactions. In: *PSAP 2015—CNS/Pharmacy Practice*. American College of Clinical Pharmacy; pp 5–26. Available at: <https://www.accp.com>. Accessed 8 January 2019.
66. Weber JCP. Epidemiology of adverse reactions to nonsteroidal antiinflammatory drugs. In: Rainsford KD, Velo GP, eds. *Advances in Inflammation Research*. Vol 6. New York: Raven Press; 1984:1–7.
67. Hartnell NR, Wilson JP. Replication of the Weber effect using postmarketing adverse event reports voluntarily submitted to the United States Food and Drug Administration. *Pharmacotherapy*. 2004;24:743–749.
68. Alling CC 3rd. Dysesthesia of the lingual and inferior alveolar nerves following third molar surgery. *J Oral Maxillofac Surg*. 1986;44:454–457.
69. Ellies LG. Altered sensation following mandibular implant surgery: a retrospective study. *J Prosthet Dent*. 1992;68:664–671.
70. MEDLINE search: Years 1946–2018, keywords *paresthesia, dentistry*. Search May 24, 2018.
71. Snoeck M. Articaine: a review of its use for local and regional anesthesia. *Local Regional Anesth*. 2012;5:23–33.
72. Pogrel MA, Schmidt BL, Sambajon V, Jordan RC. Lingual nerve damage due to inferior alveolar nerve blocks: a possible explanation. *J Am Dent Assoc*. 2003;134:195–199.
73. Katyal V. The efficacy and safety of articaine versus lignocaine in dental treatments: a meta-analysis. *J Dent*. 2010;38:307–317.
74. Brandt RG, Anderson PF, McDonald NJ, Sohn W, Peters MC. The pulpal anesthetic efficacy of articaine versus lidocaine in dentistry: a meta-analysis. *J Am Dent Assoc*. 2011;142:493–504.
75. Baroni DB, Franz-Montan M, Cogo K, et al. Effect of articaine on mental nerve anterior portion: histological analysis in rats. *Acta Odontol Scand*. 2013;71:82–87.
76. Malet A, Faure MO, Deletage N, Pereira B, Haas J, Lambert G. The comparative cytotoxic effects of different local anesthetics on a human neuroblastoma cell line. *Anesth Analg*. 2015;120:589–596.
77. Albalawi F, Lim JC, DiRenzo KV, Hersh EV, Mitchell CH. Effects of lidocaine and articaine on neuronal survival and recovery. *Anesth Prog*. 2018;65:82–88.
78. Christenson GJ. Observations on current controversies in dentistry. 100, 102 *Dent Today*. 2015;34:104–105.
79. Quora. What are the most common dental procedures? Available at: <https://www.quora.com/What-are-the-most-common-dental-procedures>. Accessed May 21, 2018.
80. Yagiela JA. Local anesthetics. In: Yagiela JA, Dowd FJ, Neidle EA, eds. *Pharmacology and Therapeutics for Dentistry*. 5th ed. St. Louis: Mosby; 2004:251–270.
81. Malamed SF. *Handbook of Local Anesthesia*. 6th ed. St Louis: Mosby; 2013.
82. Hersh EV, Hermann DG, Lamp CJ, et al. Assessing the duration of mandibular soft tissue anesthesia. *J Am Dent Assoc*. 1995;126:1531–1536.
83. Rafique S, Fiske J, Banerjee A. Clinical trial of an air-abrasion/chemomechanical operative procedure for the restorative treatment of dental patients. *Caries Res*. 2003;37:360–364.
84. Malamed SF, Yagiela JA. Pain control in dentistry. *ADA News September*. 2007 (supplement).
85. College C, Feigal R, Wandra A, et al. Bilateral versus unilateral mandibular block anesthesia in a pediatric population. *Pediatr Dent*. 2000;22:453–457.
86. ClinicalKey. Phentolamine. Drug monograph; 2018. Available at: <https://www.clinicalkey.com>. Accessed May 21, 2018.
87. McMillan WD, Trombley BJ, Charash WE, Christian RC. Phentolamine continuous infusion in a patient with pheochromocytoma. *Am J Health Syst Pharm*. 2011;68:130–134.
88. Plum M, Moukhachen O. Alternative pharmacological management of vasopressor extravasation in the absence of phentolamine. *P T*. 2017;42:581–592.
89. James PA, Oparil S, Carter BL, et al. evidence-based guideline for the management of high blood pressure in adults. Report from the panel members appointed to the Eighth Joint National Committee (JNC 8). *J Am Med Assoc*. 2014;311:507–520.
90. Zorngiotti AW. Experience with buccal phentolamine mesylate for impotence. *Int J Impot Res*. 1994;6:37–41.

91. Dinsmore WW, Gingell C, Hackett G, et al. Treating men with predominantly nonpsychogenic erectile dysfunction with intracavernous vasoprotective intrastromal polypeptide and phentolamine mesylate in a novel auto injector system: a multicenter double-blind placebo-controlled study. *BJU Int.* 1999;83:274–279.
92. Simons FE, Lieberman PL, Read EJ Jr, et al. Hazards of unintentional injection of epinephrine from autoinjectors: a systematic review. *Ann Allergy Asthma Immunol.* 2009;102:282–287.
93. Rhoney D, Peacock WF. Intravenous therapy for hypertensive emergencies, part 2. *Am J Health Syst Pharm.* 2009;66:1448–1457.
94. Septodont Inc. *OraVerse (Phentolamine Mesylate) Drug Package Insert.* Louisville: Septodont Inc; 2016.
95. Hersh EV, Moore PA, Papas AS, et al. Reversal of soft-tissue local anesthesia with phentolamine mesylate in adolescents and adults. *J Am Dent Assoc.* 2008;139:1080–1093.
96. Tavares M, Goodson JM, Studen-Pavlovich D, et al. Reversal of soft-tissue local anesthesia with phentolamine mesylate in pediatric patients. *J Am Dent Assoc.* 2008;139:1095–1104.
97. Fisher HB, Logemann JA. *The Fisher-Logemann Test Of Articulation Competence.* Boston: Houghton Mifflin; 1971.
98. DePippo KL, Holas MA, Reding MJ. Validation of the 3-oz water swallow test for aspiration following stroke. *Arch Neurol.* 1992;49:1259–1261.
99. Froum SJ, Froum SH, Malamed SF. The use of phentolamine mesylate to evaluate mandibular nerve damage following implant placement. *Compend Contin Educ Dent.* 2010;31:520,522–528.
100. Malamed SF. Managing medical emergencies. *J Am Dent Assoc.* 1993;124:40–53.
101. Malamed SF. Know your patient. *J Am Dent Assoc.* 2010;142:3S–7S.
102. Malamed SF. Medical emergencies – preparation and management. ed 4. Quality resource guide. *MetLife Dental.* 2016:1–8.
103. Scarfone RJ, Jasani M. Pain of local anesthetics: rate of administration and buffering. *Ann Emerg Med.* 1998;31:36–40.
104. Kanaa MD, Meechan JG, Corbett IP, Whitworth JM. Speed of injection influences efficacy of inferior alveolar nerve blocks: a double blind randomized controlled trial in volunteers. *J Endod.* 2006;32:919–923.
105. Malamed SF. Basic injection technique. In: *Handbook of Local Anesthesia.* 6th ed. St Louis: Mosby; 2007.
106. Peterfreund R. pH adjustment of local anesthetic solutions with sodium bicarbonate: laboratory evaluation of alkalization and precipitation. *Reg Anesth.* 1989;14:265–270.
107. Hondrum SO, Ezell JH. The relationship between pH and concentrations of antioxidants and vasoconstrictors in local anesthetic solutions. *Anesth Prog.* 1992;42:85–91.
108. Malamed SF, Falkel M. Buffered local anaesthetics: the importance of pH and CO₂. *SAAD Dig.* 2013;29:9–17.
109. Davies JR. Buffering the pain of local anaesthetics: a systematic review. *Emerg Med Australas.* 2003;15: 91–88.
110. Fernandez C, Reader A, Beck M, Nussstein J. A prospective, randomized, double-blind comparison of bupivacaine and lidocaine for inferior alveolar nerve blocks. *J Endod.* 2005;31:499–503.
111. Reader A. *Taking The Pain Out Of Restorative Dentistry And Endodontics: Current Thoughts And Treatment Options To Help Patients Achieve Profound Anesthesia.* Endodontics: Colleagues For Excellence Winter 2009. Chicago: American Association of Endodontists; 2009.
112. Lai TN, Lin CP, Kok SH, et al. Evaluation of mandibular block using a standardized method. *Oral Surg Oral Med Oral Pathol Oral Radiol Endod.* 2006;102:462–468.
113. De Jong RH, Cullen SC. Buffer-demand and pH of local anesthetic solutions containing adrenaline. *Anesthesiology.* 1963;24:801–807.
114. Carvahlo B, Fuller A, Brummel C, Cohen SE. Local infiltration of adrenaline-containing lignocaine with bicarbonate reduces superficial bleeding and pain during labor epidural catheter insertion: a randomized trial. *Int J Obstet Anesth.* 2007;16:116–121.
115. Christoph RA, Buchanan L, Begella K, Swartz S. Pain reduction in local anesthetic administration through pH buffering. *Ann Emerg Med.* 1988;17:117–120.
116. Fitton AR, Ragbir M, Milling MAP. The use of pH adjusted lignocaine in controlling operative pain in the day surgery unit: a prospective, randomized trial. *Br J Plast Surg.* 1996;49:404–408.
117. Friedman HE, Jules KT, Springer K, Jennings M. Buffered lignocaine decreases the pain of digital anesthesia in the foot. *J Am Podiatr Med Assoc.* 1997;87:219–223.
118. Davies RJ. Buffering the pain of local anesthetics: a systematic review. *Emerg Med.* 2003;15:81–88.
119. Erramouspe J. Buffering local anesthetic solutions with sodium bicarbonate: literature review and commentary. *Hosp Pharm.* 1996;31:1275–1282.
120. Hanna MN, Elhassan A, Veloso PM, et al. Efficacy of bicarbonate in decreasing pain on intradermal injection of local anesthetics: a meta analysis. *Reg Anesth Pain Med.* 2009;34:122–125.
121. Cepeda MS, Tzortzopoulou A, Thackrey M, et al. Adjusting the pH of lignocaine for reducing pain on injection. *Cochrane Database Syst Rev.* 2010;12:CD006581.
122. Bokesh PM, Raymond SA, Strichartz GR. Dependence of lignocaine potency on pH and pCO₂. *Anesth Analg.* 1987;66:9–17.
123. Wong K, Strichartz GR, Raymond SA. On the mechanisms for potentiation of local anesthetic by bicarbonate buffer: drug structure-activity studies on isolated peripheral nerve. *Anesth Analg.* 1993;76:131–143.
124. Condouris GA, Shakalis A. Potentiation of a nerve-depressant effect of local anaesthetics by carbon dioxide. *Nature.* 1964;204:57–59.
125. Gatchel RJ, Ingersoll BD, Bowman L, Robertson MC, Walker C. The prevalence of dental fear and avoidance: a recent survey study. *J Am Dent Assoc.* 1983;107:609–610.
126. Dionne RA, Gordon SM, McCullagh LM, Phero JC. Assessing the need for anesthesia and sedation in the general population. *J Am Dent Assoc.* 1998;129:167–173.
127. Hamilton JG. Needle phobia: a neglected diagnosis. *J Fam Pract.* 1995;41:169–175.
128. Arvidsson SB, Ekroth RH, Hansby AMC, Kindholm AH, William-Olson G. Painless venipuncture. a clinical trial of iontophoresis of lidocaine for venipuncture in blood donors. *Acta Anaesthesiol Scand.* 1984;28:209–210.
129. Oswald RM, Napoliello M. Motivations of blood donors and nondonors. *J Appl Psychol.* 1974;59:122–124.
130. Graham DT. Prediction of fainting in blood donors. *Circulation.* 1961;23:901–906.
131. Needlestick safety and prevention act. Pub. L. No. 106-430. 114 Stat. 1001. 106th Congress. H.R. 5178. Nov. 6, 2000. Available at: <http://history.nih.gov/research/downloads/PL106-430.pdf>. 2000.
132. McTague A, Martland T, Appleton R. Drug management for acute tonic-clonic convulsions including convulsive status epilepticus in children. *Cochrane Database Syst Rev.* 2018;1: CD001905.
133. Mula M. New non-intravenous routes for benzodiazepines in epilepsy: a clinician perspective. *CNS Drugs.* 2017;31:1–17.
134. Greaves A. The use of midazolam as an intranasal sedative in dentistry. *SAAD Dig.* 2016;32:46–49.
135. Siniscalchi A, Lentidoro W, Pisanil E, De Sarro G, Gallelli L. Intracerebral hemorrhage in a middle-aged cocaine user despite normal blood pressures. *Am J Emerg Med.* 2017;35:516.e3–516.e4.
136. Keskin M, Hayiroglu MI, Keskin U, et al. The most dangerous complication of intranasal cocaine abuse in a young man: cardiac arrest. *Am J Emerg Med.* 2016;34:1731.e5–1731.e7.

137. Rhidian R, Greatorex B. Chest pain in the recovery room, following topical intranasal cocaine solution use. *BMJ Rep.* 2015. <https://doi.org/10.1136/bcr-2015-209698>.
138. Latorre F, Klimek L. Does cocaine still have a role in nasal surgery? *Drug Saf.* 1999;20:9–13.
139. Lachanas VA, Karatzias GT, Pinakas VG, Hatzioannou JK, Sandris VG. The use of tetracaine 0.25% solution in nasal packing removal. *Am J Rhinol.* 2006;20:483–484.
140. Madineh H, Amani S, Kabiri M, Karimi B. Evaluation of the anesthetic effect of nasal mucosa with tetracaine 0.5% on hemodynamic changes and postoperative pain of septoplasty: a randomized controlled trial. *J Adv Pharm Technol Res.* 2017;8:116–119.
141. Noorily AD, Noorily SH, Otto RA. Cocaine, lidocaine, tetracaine: which is best for topical nasal anesthesia? *Anesth Analg.* 1995;81:724–727.
142. Srisawat C, Nakponetong K, Benjasupattananun P, et al. A preliminary study of intranasal epinephrine administration as a potential route for anaphylaxis treatment. *Asian Pac J Allergy Immunol.* 2016;34:38–43.
143. Higgins TS, Hwang PH, Kingdom TT, et al. Systematic review of topical vasoconstrictors in endoscopic sinus surgery. *Laryngoscope.* 2011;121:422–432.
144. Giannakopoulos H, Levin LM, Chou JC, et al. The cardiovascular effects and pharmacokinetics of intranasal tetracaine plus oxymetazoline: preliminary findings. *J Am Dent Assoc.* 2012;143:872–880.
145. Ciancio SG, Hutcheson MC, Ayoub F, et al. Safety and efficacy of a novel nasal spray for maxillary dental anesthesia. *J Dent Res.* 2013;92(suppl 7):43S–48S.
146. Ciancio SG, Marberger AD, Ayoub F, et al. Comparison of 3 intranasal mists for anesthetizing maxillary teeth in adults: a randomized, double-masked, multicenter phase 3 clinical trial. *J Am Dent Assoc.* 2016;147:339–347.
147. Hersh EV, Pinto A, Saraghi M, et al. Double-masked, randomized, placebo-controlled study to evaluate efficacy and tolerability of intranasal K-305 (3% tetracaine plus 0.05% oxymetazoline) in anesthetizing maxillary teeth. *J Am Dent Assoc.* 2016;147:278–287.
148. Evans GD, Yiming L. A phase 3, multi-center, randomized, double-blind, parallel-groups clinical trial comparing the efficacy and safety of intranasally administered K-305 to placebo for anesthetizing maxillary teeth in pediatric patients. 2016. Available at: <https://www.fda.gov/downloads/Drugs/DevelopmentApprovalProcess/DevelopmentResources/UCM513665.pdf>. Accessed June 6, 2018.

Future Trends in Pain Control

Although local anesthesia remains the backbone of pain control techniques in dentistry, research continues in both medicine and dentistry with the goal of improving all areas of the local anesthetic experience, from that of the administrator to that of the patient. Much of this research has focused on improvements in the area of local anesthesia—safer needles and syringes; more successful techniques of regional nerve block, such as the anterior middle superior alveolar and palatal anterior superior alveolar nerve blocks (see [Chapter 13](#)); and newer drugs, such as articaine hydrochloride. These advances have been discussed in some depth in previous editions of this book and in preceding chapters of this edition: intraosseous anesthesia (see [Chapter 15](#)); self-aspirating, pressure, and safety syringes and computer-controlled local anesthetic delivery systems (see [Chapter 5](#)); and articaine hydrochloride (see [Chapters 4 and 19](#)). These drugs, devices, and techniques have become a part of the mainstream of pain control in the United States and elsewhere. Additionally, phentolamine mesylate (the local anesthesia “off switch”), buffered local anesthetic solutions (the local anesthetic “on switch”) and the tetracaine plus oxymetazoline nasal spray for pulpal anesthesia of maxillary non-molar teeth (see [Chapter 19](#)) have become important adjuncts to the pain control armamentarium in dentistry.

Some items discussed in previous editions have not progressed into the dental mainstream: the local anesthetics centbucridine and ropivacaine; the topical anesthetic EMLA (eutectic mixture of local anesthetics); and the technique of electronic dental anesthesia. The reader interested in these items is referred to the fifth edition of this textbook.¹

In this chapter we will look at two areas of current local anesthetic research: (1) the search for longer-acting local anesthetics for postsurgical pain management; and (2) a light-activated, light-inactivated local anesthesia—the ability to provide site-specific anesthesia of any desired duration.

Longer- and Ultra-Long-Acting Local Anesthetics

The most commonly used local anesthetics in dentistry—articaine, lidocaine, mepivacaine, and prilocaine—when combined with a vasoconstrictor such as epinephrine provide pulpal anesthesia of approximately 60 minutes’

duration, with soft tissue anesthesia persisting for approximately 3 to 5 hours. In virtually all instances these drug formulations provide the patient with pain control adequate to receive the dental care—surgical or nonsurgical—painlessly.

The aforementioned drugs are also those most frequently used for perioperative pain control during dental surgical procedures such as exodontia, osseous surgery, periodontal surgery, and endodontic procedures, as the duration of the surgical procedure commonly falls within the expected duration of pulpal anesthesia for these drugs.

The requirement for postsurgical pain control, however, is somewhat more problematic. In [Chapter 16](#) a pain control regimen for dental surgery patients was described ([Box 16.7](#)). It recommends the administration of the long-acting local anesthetic bupivacaine (0.5%) with epinephrine (1:200,000), by nerve block, at the completion of the surgical procedure. In combination with timed doses (by the clock) of an appropriate nonsteroidal antiinflammatory drug (e.g., ibuprofen, 600 to 800 mg) virtually all postsurgical pain can be eliminated or minimized.

However, following some surgical procedures, primarily in medicine, but occasionally in dentistry, the need for pain control can extend for many days. This need, and the realization that we (in the United States) are in the midst of an “opioid epidemic” (opioid abuse and misuse)^{2,3} has fostered research into longer- and ultra-long-acting local anesthetics.

Three areas will be presented: (1) naturally occurring site-1 selective sodium channel blockers, (2) new local anesthetic delivery systems, and (3) novel adjuvants of local anesthetics.

Naturally Occurring Site-1 Selective Sodium Channel Blockers

Tetrodotoxin (TTX), saxitoxin (STX), and neosaxitoxin (NeoSTX) are selective sodium channel blockers that are naturally produced by animals such as the pufferfish (TTX) and shellfish (STX). All are potent neurotoxins commonly known as *paralytic shellfish toxins*.

TTX was “discovered” in 1964 by Narahashi and Moore.⁴ Although found primarily in pufferfish⁵ ([Fig. 21.1](#)), TTX is also found in certain angelfish,⁶ octopi,⁷ cuttlefish, and other sea life.



• **Fig. 21.1** Pufferfish-tetrodotoxin. (From Gupta PK: *Illustrated toxicology*; San Diego, 2018, Elsevier.)



• **Fig. 21.2** Red tide-saxitoxin. (© iStock/TriggerPhoto.)

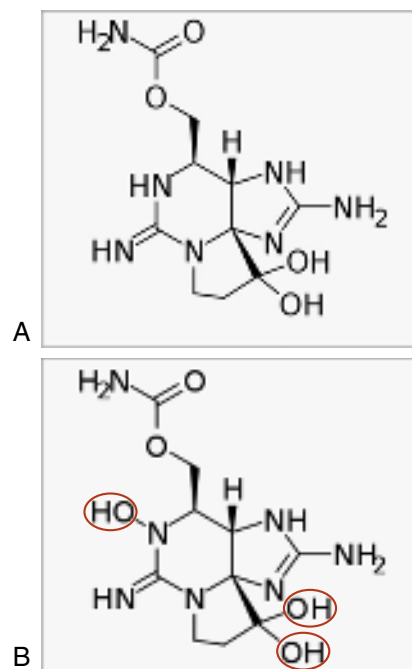
STX is produced by marine dinoflagellates and freshwater cyanobacteria, which can form extensive algal blooms, producing the “red tide” (Fig. 21.2).⁸ Ingestion of shellfish contaminated by such algal blooms is responsible for the human illness known as *paralytic shellfish poisoning*.⁹

NeoSTX differs from STX in that it has a hydroxyl group substituted for a hydrogen (Fig. 21.3).

Similar to the “traditional” local anesthetics, TTX, STX, and NeoSTX are sodium channel blockers. However, where traditional local anesthetics (e.g., lidocaine) diffuse into the nerve through its lipid membrane to block the sodium channel from its inside, TTX, STX, and NeoSTX interact with the extracellular aspect of the sodium channel (Fig. 21.4). As a result of this, these compounds can act in a synergistic manner with traditional local anesthetics.^{10,11}

Because the traditional amide and ester local anesthetics do not reliably provide analgesia beyond 6 to 12 hours following a single injection, NeoSTX and TTX have received renewed attention in the area of postsurgical pain control.^{12,13}

NeoSTX has been demonstrated to be the most potent of the selective sodium channel blockers in both in vitro and in vivo trials.^{14,15} It is termed a “site-1 sodium channel blocker,” binding to the outer pore of the sodium channel,



• **Fig. 21.3** Saxitoxin (A) and neosaxitoxin (B).

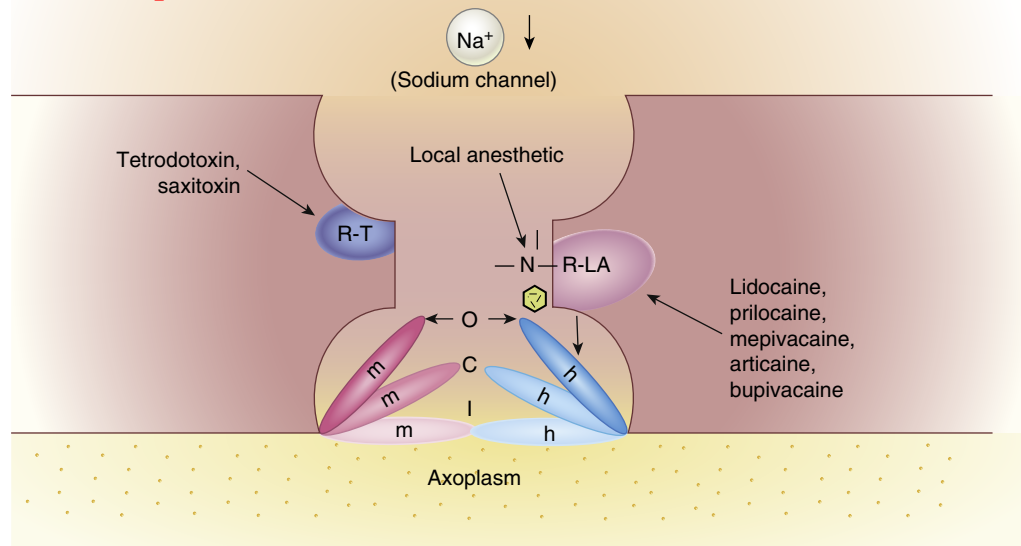
interrupting depolarization of excitable cells and propagation of action potential.^{12,16}

Overdose of traditional local anesthetics—either by direct intravascular administration or by excessive dosage—produces neurologic and myocardial toxicity (see Chapter 18). NeoSTX appears to be devoid of cardiotoxicity.¹⁷ Overdose of NeoSTX (and TTX) produces reversible weakness of skeletal and respiratory muscles, which is treatable with respiratory support (assisted or controlled ventilation) until recovery is complete.¹²

Similar to its effect with traditional local anesthetics, the addition of epinephrine to NeoSTX decreases its blood level, resulting in increased potency and decreased toxicity.¹⁸ In that same clinical trial, in human volunteers subcutaneous injection of NeoSTX produced significantly longer effect on the pain threshold compared with bupivacaine. The addition of epinephrine further increased the duration of anesthesia.¹⁸

In a phase 1 clinical trial, Lobo et al.¹⁹ evaluated the safety and efficacy of NeoSTX alone and NeoSTX combined with 0.2% bupivacaine and epinephrine (NeoSTX-Bup-Epi) and without epinephrine (NeoSTX-Bup). Eighty-four participants completed the trial with no serious adverse events or clinically significant physiologic impairments. The most common adverse events—perioral numbness and tingling—were more frequent with NeoSTX alone and NeoSTX-Bup. All symptoms resolved without intervention. The addition of epinephrine (NeoSTX-Bup-Epi) dramatically reduced symptoms compared with the other NeoSTX combinations (tingling, 0% vs. 70%, $P = .004$; numbness, 0% vs. 60%, $P = .013$) at the same dose. The mean peak plasma NeoSTX concentration for NeoSTX-Bup-Epi was reduced at least twofold compared with that for NeoSTX alone and NeoSTX-Bup (67 ± 14 pg/mL, 134 ± 63 pg/mL, and 164 ± 81 pg/mL, respectively, $P = .016$). NeoSTX-Bup showed a prolonged cutaneous block duration compared with 0.2% bupivacaine,

PDF Compressor Free Version



• Fig. 21.4 Na⁺ channel sites.

NeoSTX alone, or placebo at all doses. The median time to near-complete recovery for 10 μ g NeoSTX-Bup-Epi was almost fivefold longer than for 0.2% bupivacaine (50 hours vs. 10 hours, $P = .007$).¹⁹

In their conclusions, they stated that “an ideal agent for perioperative use should have (1) very rapid onset of dense blockade, permitting surgery under local or regional anesthesia, (2) persistence of dense and reliable blockade through the first postoperative night, and (3) a prolonged period of partial blockade over the next 2 or 3 days.”²⁰ Based on the time course and intensity of block in this phase 1 study, NeoSTX-Bup and NeoSTX-Bup-Epi appear promising for showing these favorable features when used for surgical patients.¹⁹

TTX has also received attention as a long-acting anesthetic with minimal myotoxicity and neurotoxicity.^{21,22} When administered along with a traditional local anesthetic, TTX has demonstrated significant synergism in multiple animal studies. Individually, TTX or bupivacaine each produced 150 minutes of block in a rat sciatic nerve block. Injected together, the duration was increased to 570 minutes.²³

Comment: The site-1 selective sodium channel blockers NeoSTX and TTX provide longer durations of anesthesia than traditional local anesthetics. When TTX is administered in combination with bupivacaine and epinephrine, significant increases in duration are noted. Additionally, these compounds are devoid of cardiotoxicity (NeoSTX) and have minimal myotoxicity and neurotoxicity (TTX). Overdose is noted as various degrees of respiratory depression, which is readily managed through airway maintenance and assisted or controlled ventilation until recovery occurs.

New Local Anesthetic Delivery Systems

Another approach to extending the duration of anesthesia provided by traditional local anesthetics is to use new means

of delivering the drugs.¹² Nanoparticles and liposome microparticles have been used to enhance both the duration and the safety of local anesthetics.¹²

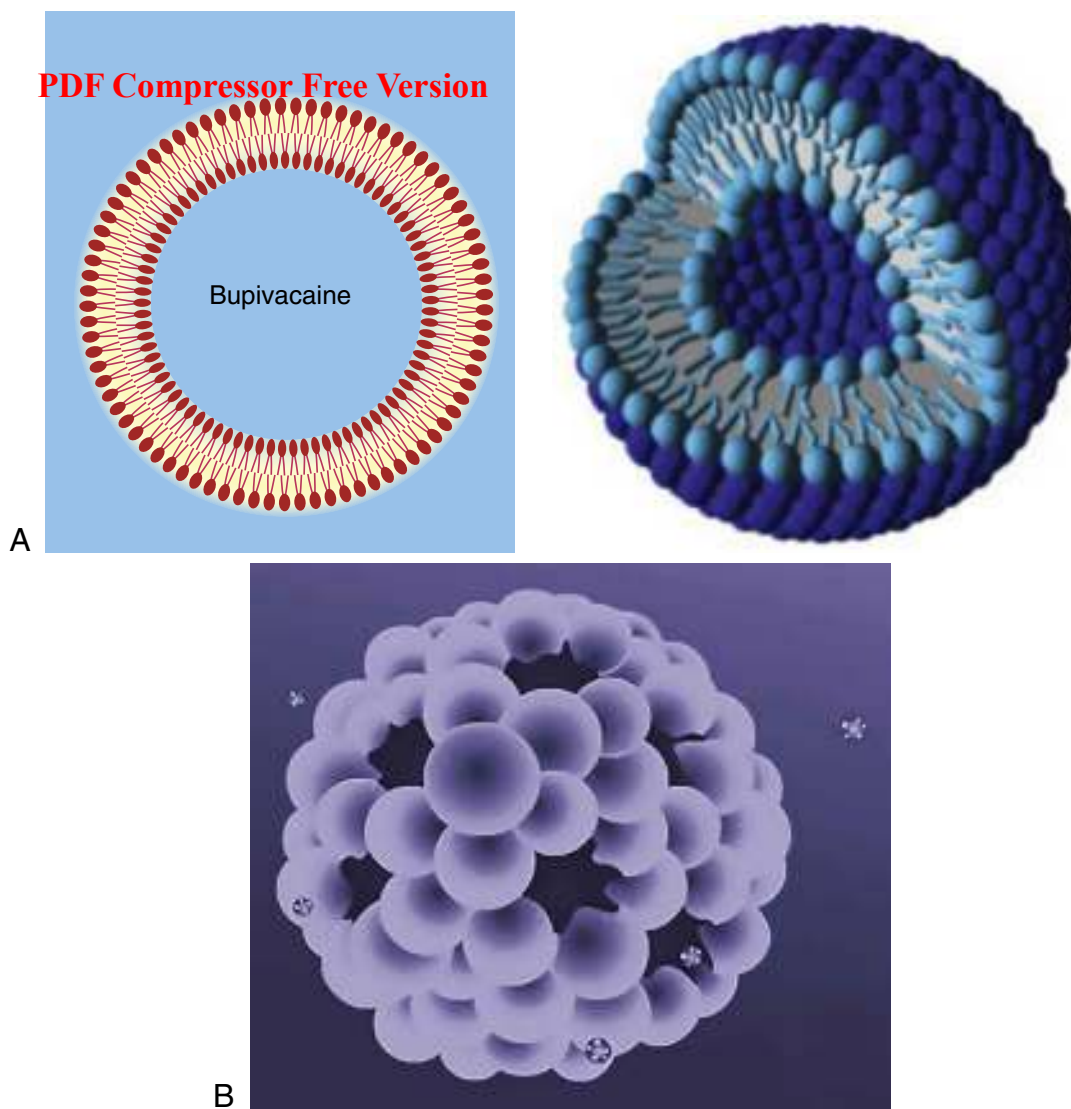
Clinical trials of third molar pain have shown that the severest pain and the greatest analgesic consumption occur during the first 48 to 72 hours after surgery.^{24,25} Hersh et al. stated that “a drug that could significantly reduce or eliminate opioid consumption in patients during this time period would be beneficial to the dentist’s armamentarium by providing prolonged analgesia and reducing the need to prescribe opioids. Liposomal bupivacaine may indeed fit this niche.”²⁶

With proprietary DepoFoam technology, as much as 97% of the bupivacaine in the liposomal formulation is packaged within multivesicular liposomal spheres. Each sphere is surrounded by a lipid bilayer that allows controlled release of the drug over time (Fig. 21.5).^{27,28} The onset of anesthesia is considerably slower than for conventional local anesthetics, at least a couple of hours.^{26,29,30}

Randomized controlled clinical trials comparing liposomal bupivacaine with bupivacaine administered by infiltration postoperatively into surgical sites (total knee arthroplasty, laparoscopic hysterectomy, nephrectomy) have demonstrated the superiority of the liposomal form for pain management, decreased opioid requirement, and decreased occurrence of adverse events.³¹⁻³⁸

Liposomal bupivacaine (Exparel) is strictly indicated for postsurgical pain control by infiltration injections around the surgical incision.³⁹ It is not indicated for administration as a nerve block or by intra-articular injection. It should not be used for intraoperative dental local anesthesia because the drug has a slower onset than conventional bupivacaine and a possible 24- to 72-hour duration of lip and tongue anesthesia if administered by inferior alveolar or Gow-Gates nerve blocks.²⁵

If liposomal bupivacaine and other non-bupivacaine “traditional” local anesthetics are administered at the same site,



• Fig. 21.5 DepoFoam. (B: ©Pacira Pharmaceuticals Inc. All Rights Reserved. Used Under License.)

there may be an immediate release of bupivacaine from the liposomal spheres. The Exparel drug information leaflet states that “the liposomal bupivacaine formulation should not be injected within 20 min into sites where non-bupivacaine-containing local anesthetics, such as lidocaine, have been infiltrated. This increases the risk of damaging the liposomal vesicles and thus potentially increasing free blood levels of bupivacaine to toxic concentrations and/or negating the extended duration of action provided by the liposomes.”³⁹

Comment: Hersh et al.²⁵ stated:

The ‘jury is still out’ regarding the use of liposomal bupivacaine after invasive dental surgery. The cost of a 10-mL vial (133 mg of liposomal bupivacaine) is \$170, roughly 28 times that of 6 standard (1.7 mL) 0.5% bupivacaine/1:200,000 epinephrine cartridges (an amount of local anesthetic that may be necessary to provide anesthesia/analgesia for the surgical removal of 4 dental impactions). On the flip side, providing postoperative pain control potentially for up to 72 h and reducing the need for opioid consumption would have a positive effect on patient quality of life by reducing or

eliminating the known acute side effects of opioids (nausea, vomiting, constipation, psychomotor impairment) and may reduce the chances of opioid abuse in genetically susceptible individuals. Additional randomized, controlled studies following dental impaction surgery, maxillofacial trauma, and periodontal surgery procedures are needed.

Animal trials of liposomal STX (sciatic nerve blockade in Sprague Dawley rats) have demonstrated anesthesia of between 13.5 and 48 hours without signs of toxicity.⁴⁰

Incorporating dexamethasone with the liposomal STX increased the duration of blocks to 7.5 days without signs of toxicity.⁴⁰

The shelf life of liposomal local anesthetics is quite short (less than 1 to 2 months), a result of leakage of the drug from the liposomes.¹² Proliposomal ropivacaine, in which liposome formation occurs only when it comes into contact with aqueous subcutaneous tissue, is being developed.¹² In an in vitro animal (porcine) wound healing study, exposure to saline and plasma effectively transformed the proliposomal oil into a liposomal emulsion. Proliposomal ropivacaine

was able to provide 30 hours of sensory anesthesia, in contrast to 6 hours for plain ropivacaine.⁴¹ Proliposomal ropivacaine was stable at room temperature for more than 24 months.⁴¹ In one human study, proliposomal ropivacaine provided anesthesia for between 29 and 36 hours following subcutaneous infiltration. Plain ropivacaine provided anesthesia for between 12 and 16 hours, both without side effects.⁴²

Novel Adjuvants of Local Anesthetics

The use of adjuvants in local anesthetics is a well-established practice. In dentistry, epinephrine has been added to local anesthetics since the advent of cartridges. In medicine, adjuvants to local anesthetics have included opioids, clonidine, dexamethasone,⁴⁰ and epinephrine.¹²

Magnesium has received considerable attention as a local anesthetic adjuvant in recent years. In clinical trials, patients undergoing surgery (arthroscopic rotator cuff repair, elective open thoracic surgery, elective forearm and arm surgery, total abdominal hysterectomy, and laparoscopic cholecystectomy) received bupivacaine or ropivacaine with magnesium (150 mg) by an appropriate nerve block technique.^{43–47} The addition of magnesium to the local anesthetic increased the duration of pain control in all studies (by 571 minutes following total abdominal hysterectomy⁴⁶), and patients required less rescue anesthesia (e.g., opioids). No magnesium-associated toxicity was observed in the experimental groups.^{43–47}

Comment. The addition of epinephrine to local anesthetics is considered routine in dentistry, as it increases both the depth and the duration of local anesthesia as well as decreasing the toxicity of the local anesthetic. The addition of magnesium to local anesthetics provides a longer duration of anesthesia, lowers patient pain scores, and, in some studies, lowers opioid requirements when used in combination with bupivacaine.

Light-Activated, Light-Inactivated Local Anesthesia

Optogenetics is a biological technique involving the use of light to control cells in living tissue, typically neurons, that have been genetically modified to express light-sensitive ion channels. It is a means of neuromodulation using techniques from both optics and genetics to control and monitor the activities of individual neurons in living tissue—even within freely moving animals—and to precisely measure these manipulation effects in real time.⁴⁸

The use of light to selectively control precise neural activity (action potential) patterns within subtypes of cells in the brain was first described by Francis Crick at the University of California, San Diego in 1999.⁴⁹

In 2010, optogenetics was chosen as the “Method of the Year” across all fields of science and engineering by the interdisciplinary research journal *Nature Methods*.^{50,51} At the same time, optogenetics was highlighted in an article on breakthroughs of the decade in the academic research journal *Science*.⁵²

Primarily a research tool in animals, optogenetics applications include (1) the identification of particular neurons and neural networks, (2) the precise temporal control of interventions, and (3) cellular biology/cell signaling pathways.

One area of interest is its use in the management of cardiac dysrhythmias. Although still in the development stage, optogenetics was applied on atrial cardiomyocytes to terminate dysrhythmias found to occur in atrial fibrillation, with light.⁵³ A recent study explored the possibilities of optogenetics as a means of correcting dysrhythmias and resynchronizing cardiac pacing. Channelrhodopsin-2 was introduced into cardiomyocytes in ventricular areas of hearts of transgenic mice, and in vitro photostimulation studies were performed. Photostimulation led to increased activation of cells, thus increasing ventricular contractions, resulting in increased heart rates. In addition, this approach has been applied in cardiac resynchronization therapy as a new biological pacemaker as a substitute for electrode-based cardiac resynchronization therapy.⁵⁴ More recently, optogenetics has been used in the heart to defibrillate ventricular arrhythmias with local epicardial illumination,⁵⁵ a generalized whole heart illumination,⁵⁶ or with customized stimulation patterns based on arrhythmogenic mechanisms to lower defibrillation energy.⁵⁷ Optogenetic tools have also been proposed as a strategy for restoring vision⁵⁸ as well as for treating Parkinson disease or epilepsy through deep brain optical stimulation.⁵⁹

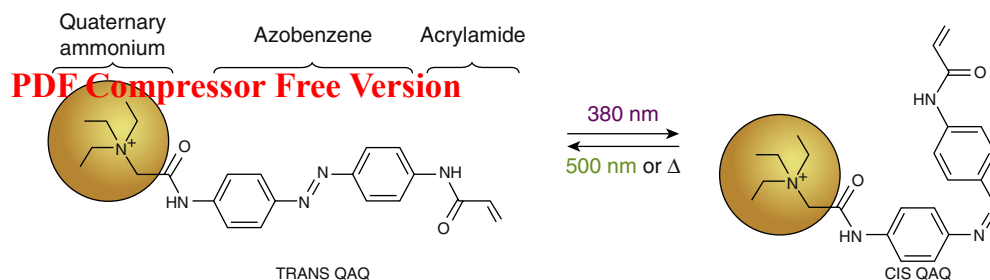
Optogenetics and pain modulation—the ability to instantaneously turn on and turn off anesthesia and to specifically target precise areas for treatment.

In a 180-degree turn from the earlier discussion of longer- and ultra-long-acting local anesthetics used almost exclusively for the management of postsurgical pain, most traditional local anesthetics provide pulpal anesthesia of sufficient duration to permit completion of virtually all dental procedures painlessly. However, soft tissue anesthesia—usually unnecessary and almost always unwanted—persists for many hours following completion of the dental treatment.

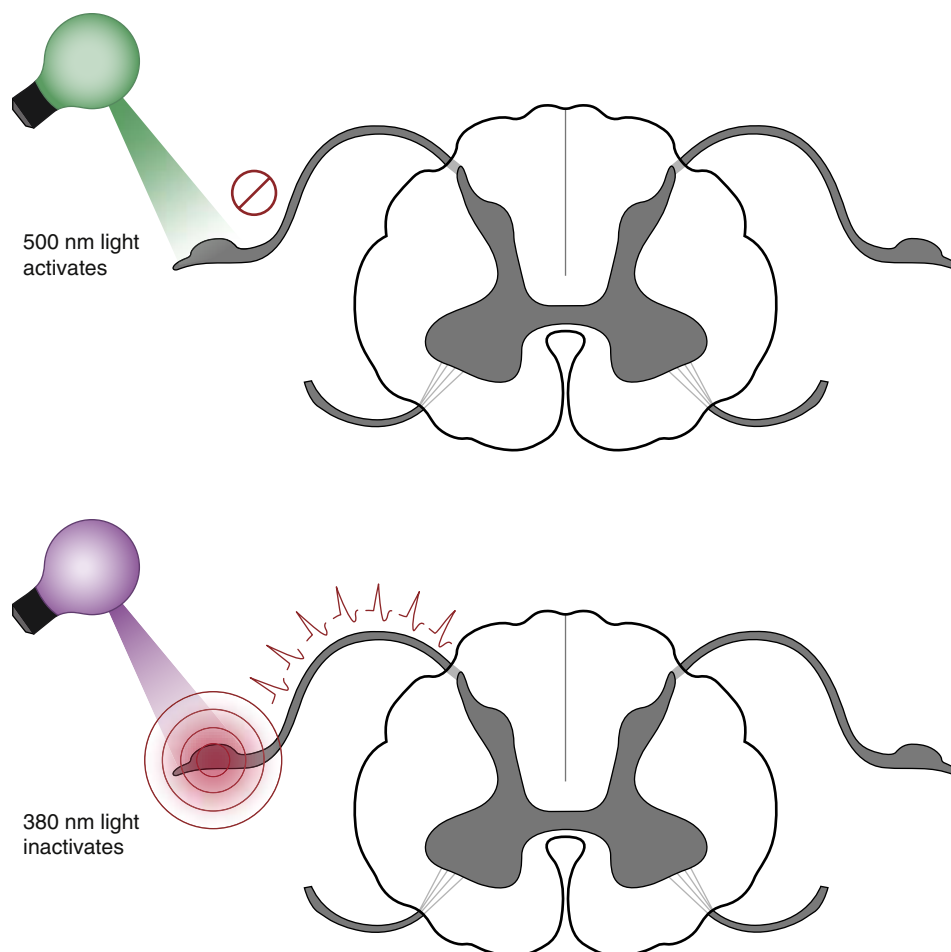
Additionally, injectable local anesthetics are not targeted to a specific site; rather they affect a generalized area. The traditional local anesthetics (e.g., articaine, bupivacaine, lidocaine, mepivacaine, prilocaine) lack specificity for motor neurons versus sensory neurons and for different sensory modalities (e.g., touch sensation), and the duration and intensity of the anesthesia cannot be regulated.⁶⁰

A new option, developed by researchers at the University of California, Berkeley, the University of Munich, and the University of Bordeaux,⁶¹ involves a novel local anesthetic that can be switched on and off with the use of different wavelengths of light, potentially allowing much finer control of exactly which nerves it blocks.⁶²

Chemically, quaternary ammonium–azobenzene–quaternary ammonium (QAQ) resembles lidocaine. QAQ exists in two forms, *cis* and *trans*. In the active *trans* form, the molecule is a straight chain, but exposure to 380-nm light converts it to the *cis* form, which is bent like an *L* (Fig. 21.6).



• **Fig. 21.6** The *cis* and *trans* forms of quaternary ammonium–azobenzene–quaternary ammonium.



• **Fig. 21.7** Light-activated, light-inactivated local anesthetic quaternary ammonium–azobenzene–quaternary ammonium. Redrawn from Gitlin JM. Light-switched local anaesthetic lets scientists turn pain nerve on and off. Available at: <https://www.arstechnica.com/science/2012/02/light-switched-local-anaesthetic-lets-scientists-turn-pain-nerves-on-and-off>. Accessed June 19, 2018.

In the dark, QAQ slowly reverts to the *trans* form; however, this can also be achieved much more rapidly by illumination with 500-nm light (Fig. 21.7).

Once inside a cell, in its *trans* form QAQ blocks many different ion channels, whereas the *cis* form is inactive. The difficulty researchers have found has been in getting QAQ into the cell itself. Being a fairly large molecule, QAQ does not normally cross cell membranes. To demonstrate the effectiveness of photoswitching, researchers had to inject QAQ into the cells they were testing. Although this might be thought of as a factor limiting its potential clinical

usefulness, this lack of membrane permeability actually confers on QAQ the potential to be a very selective local anesthetic.

Because QAQ is selective for pain-sensing neurons, it may block nociception without affecting motor axons or other sensations. Moreover, because QAQ blockade can be precisely modulated by a change in light wavelength or intensity, it may be possible to phototitrate the analgesic effect at will.⁶³

Comment. The ability to provide location-specific pain control without additional involvement of motor nerves

would be a welcome addition to the management of patients with chronic pain syndromes. Further, as most dental treatments are not essential, the potential capability to “switch off” anesthesia at the end of treatment would be appreciated by most dental patients. Although still very early in their development, optogenetics and light-activated/light-inactivated compounds hold promise for a new means of managing perioperative pain.

References

1. Malamed SF. Future considerations. 5th ed. *Handbook of Local Anesthesia*. St Louis: CV Mosby; 2004.
2. Olsen Y. The CDC guideline on opioid prescribing. Rising to the challenge. *J Am Med Assoc*. 2016;315:1577–1579.
3. National Institute on Drug Abuse. Opioid overdose crisis. Available at: <http://www.drugabuse.gov/drugs-abuse/opioids/opioid-overdose-crisis>. Accessed June 18, 2018.
4. Narahashi T, Moore JW, Scott WR. Tetrodotoxin blockage of sodium conductance increase in lobster giant axons. *J Gen Physiol*. 1964;47:965–974.
5. Lago J, Rodriguez LP, Blanco L, et al. Tetrodotoxin, an extremely potent marine neurotoxin: distribution, toxicity, origin and therapeutic uses. *Mar Drugs*. 2015;13:6384–6406.
6. Narahashi T. Tetrodotoxin: a brief history. *Proc Jpn Acad Ser B Phys Biol Sci*. 2008;84(5):147–154.
7. Bane V, Lehane M, Dikshit M, et al. Tetrodotoxin: chemistry, toxicity, source, distribution and detection. *Toxins*. 2014;6:693–755.
8. Wiese M, D’Agostino PM, Mihail TK, et al. Neurotoxic alkaloids: saxitoxin and its analogs. *Mar Drugs*. 2010;8:2185–2211.
9. Centers for Disease Control and Prevention. Epidemiologic notes and reports paralytic shellfish poisoning—Massachusetts and Alaska, 1990. *MMWR Morb Mortal Wkly Rep*. 1991;40:157–161.
10. Stainman AL, Seeman P. Different sites of membrane action for tetrodotoxin and lipid-soluble anesthetics. *Can J Physiol Pharmacol*. 1975;53:513–524.
11. Adams HJ, Blair MRJ, Takman BH. The local anesthetic activity of tetrodotoxin alone and in combination with vasoconstrictors and local anesthetics. *Anesth Analg*. 1976;55:568–573.
12. King CH, Beutler SS, Kaye AD, Urman RD. Pharmacologic properties of novel local anesthetic agents in anesthesia practice. *Anesthesiol Clin*. 2017;35:315–325.
13. Moiniche S, Mikkelsen S, Wetterslev J, et al. A qualitative systematic review of incisional local anaesthesia for postoperative pain relief after abdominal operations. *Br J Anaesth*. 1998;81:377–383.
14. Kohane DS, Lu NT, Gököl-Kline AC, et al. The local anesthetic properties and toxicity of saxitoxin homologues for rat sciatic nerve block in vivo. *Reg Anesth Pain Med*. 2000;2:52–59.
15. Strichartz G, Rando T, Hall S, et al. On the mechanism by which saxitoxin binds to and blocks sodium channels. *Ann NY Acad Sci*. 1986;479:96–112.
16. Andrinolo D, Michea LF, Lagos N. Toxic effects, pharmacokinetics and clearance of saxitoxin, a component of paralytic shellfish poison (PSP), in cats. *Toxicol*. 1999;37:447–464.
17. Wylie MC, Johnson VM, Carpino E, et al. Respiratory, neuromuscular, and cardiovascular effects of neosaxitoxin in isoflurane-anesthetized sheep. *Reg Anesth Pain Med*. 2012;37:152–158.
18. Rodriguez-Navarro AJ, Lagos M, Figueroa C, et al. Potentiation of local anesthetic activity of neosaxitoxin with bupivacaine or epinephrine: development of a long-acting pain blocker. *Neurotox Res*. 2009;16:408–415.
19. Lobo K, Donado C, Cornelissen L, Kim J, et al. A phase 1, dose-escalation, double-blind, block-randomized, controlled trial of safety and efficacy of neosaxitoxin alone and in combination with 0.2% bupivacaine, with and without epinephrine, for cutaneous anesthesia. *Anesthesiology*. 2015;123:873–885.
20. Berde CB. Developing better local anesthetics. *Anesth Analg*. 2015;120:718–720.
21. Padera RF, Tse JY, Bellas E, et al. Tetrodotoxin for prolonged local anesthesia with minimal myotoxicity. *Muscle Nerve*. 2006;34:747–753.
22. Sakura S, Bollen AW, Ciriales R, et al. Local anesthetic neurotoxicity does not result from blockade of voltage-gated sodium channels. *Anesth Analg*. 1995;81:338–346.
23. Kohane DS, Yieh J, Lu NT, et al. A re-examination of tetrodotoxin for prolonged duration local anesthesia. *Anesthesiology*. 1998;89:119–131.
24. Hersh EV, Cooper SA, Betts N, et al. Single dose and multidose analgesic efficacy and safety study of meclofenamate sodium and ibuprofen. *Oral Surg Oral Med Oral Pathol*. 1993;76:680–687.
25. Hersh EV, Saraghi M, Moore PA. Two recent advances in local anesthesia: intranasal tetracaine/oxymetazoline and liposomal bupivacaine. *Curr Oral Health Rep*. 2017;4:189–196.
26. Saraghi M, Hersh EV. Three newly approved analgesics: an update. *Anesth Prog*. 2013;60:178–187.
27. Mantripragada S. A lipid based depot (DepoFoam technology) for sustained release drug delivery. *Prog Lipid Res*. 2002;41:392–406.
28. Ye Q, Asherman J, Stevenson M, Brownson E, Katre NV. DepoFoam technology: a vehicle for controlled delivery of protein and peptide drugs. *J Control Release*. 2000;64:155–166.
29. Chahar P, Cummings KC 3rd. Liposomal bupivacaine: a review of new bupivacaine formulation. *J Pain Res*. 2012;5:257–264.
30. Davidson EM, Barenholz Y, Cohen R, Haroutiunian S, Kagan L, Ginosar Y. High-dose bupivacaine remotely loaded into multivesicular liposomes demonstrates slow drug release without systemic toxic plasma concentrations after subcutaneous administration in humans. *Anesth Analg*. 2010;110:1018–1023.
31. Smoot JD, Bergese SD, Onel E, et al. The efficacy and safety of DepoFoam bupivacaine in patients undergoing bilateral, cosmetic, submuscular augmentation mammoplasty: a randomized, double-blind, active-control study. *Aesthet Surg J*. 2012;32:69–76.
32. Bramlett K, Onel E, Viscusi ER, et al. A randomized, double-blind, dose-ranging study comparing wound infiltration of DepoFoam bupivacaine, an extended-release liposomal bupivacaine, to bupivacaine HCl for postsurgical analgesia in total knee arthroplasty. *Knee*. 2012;19:530–536.
33. Bergese SD, Ramamoorthy S, Patou G, et al. Efficacy profile of liposome bupivacaine, a novel formulation of bupivacaine for postsurgical analgesia. *J Pain Res*. 2012;5:107–116.
34. Kirkness CS, Asche CV, Ren J, et al. Cost-benefit evaluation of liposomal bupivacaine in the management of patients undergoing total knee arthroplasty. *Am J Health Syst Pharm*. 2016;73:e247–e254.
35. Kirkness CS, Asche CV, Ren J, et al. Assessment of liposome bupivacaine infiltration versus continuous femoral nerve block for postsurgical analgesia following total knee arthroplasty: a retrospective cohort study. *Curr Med Res Opin*. 2016;32:1727–1733.
36. Cien AJ, Penny PC, Horn BJ, et al. Comparison between liposomal bupivacaine and femoral nerve block in patients undergoing primary total knee arthroplasty. *J Surg Orthop Adv*. 2015;24:225–229.

37. Hutchins JL, Kesha R, Blanco F, et al. Ultrasound-guided subcostal transverse abdominis plane blocks with liposomal bupivacaine vs. non-liposomal bupivacaine for postoperative pain control after laparoscopic hand-assisted donor nephrectomy: a prospective randomised observer-blinded study. *Anaesthesia*. 2016;71:930–937.
38. Hutchins J, Delaney D, Vogel RI, et al. Ultrasound guided subcostal transverse abdominis plane (TAP) infiltration with liposomal bupivacaine for patients undergoing robotic assisted hysterectomy: a prospective randomized controlled study. *Gynecol Oncol*. 2015;138:609–613.
39. Pacira Pharmaceuticals. Exparel drug package insert. Available at: <https://www.exparel.com/prescribinginformation>. Accessed 23 February 2019.
40. Epstein-Barash H, Shichor I, Kwon AH, et al. Prolonged duration local anesthesia with minimal toxicity. *Proc Natl Acad Sci U S A*. 2009;106:7125–7130.
41. Davidson EM, Haroutounian S, Kagan L, et al. A novel pro-liposomal ropivacaine oil: pharmacokinetic-pharmacodynamic studies after subcutaneous administration in pigs. *Anesth Analg*. 2016;122:1663–1672.
42. Ginosar Y, Haroutounian S, Kagan L, et al. Proliposomal ropivacaine oil: pharmacokinetic and pharmacodynamic data after subcutaneous administration in volunteers. *Anesth Analg*. 2016;122:1673–1680.
43. Lee AR, Yi HW, Chung IS, et al. Magnesium added to bupivacaine prolongs the duration of analgesia after interscalene nerve block. *Can J Anaesth*. 2012;59:21–27.
44. Ammar AS, Mahmoud KM. Does the addition of magnesium to bupivacaine improve postoperative analgesia of ultrasound-guided thoracic paravertebral block in patients undergoing thoracic surgery? *J Anesth*. 2014;28:58–63.
45. Mukherjee K, Das A, Basunia SR, et al. Evaluation of magnesium as an adjuvant in ropivacaine-induced supraclavicular brachial plexus block: a prospective, double-blinded randomized controlled study. *J Res Pharm Pract*. 2014;3:123–129.
46. Rana S, Verma RK, Singh J, et al. Magnesium sulphate as an adjuvant to bupivacaine in ultrasound-guided transversus abdominis plane block in patients scheduled for total abdominal hysterectomy under subarachnoid block. *Indian J Anaesth*. 2016;60:174–179.
47. Al-Refaey K, Usama EM, Al-Hefnawey E. Adding magnesium sulfate to bupivacaine in transversus abdominis plane block for laparoscopic cholecystectomy: a single blinded randomized controlled trial. *Saudi J Anaesth*. 2016;10:187–191.
48. Deisseroth K, Feng G, Majewska AK, et al. Next-generation optical technologies for illuminating genetically targeted brain circuits. *J Neurosci*. 2006;26:10380–10386.
49. Crick F. The impact of molecular biology on neuroscience. *Philos Trans R Soc B*. 1999;354:2021–2025.
50. Primer on Optogenetics, Pastrama E. Optogenetics: controlling cell function with light. *Nat Methods*. 2010;8:24–25.
51. Editorial. Method of the year 2010. *Nat Methods*. 2010;8(1).
52. Staff News. Insights of the decade. Stepping away from the trees for a look at the forest. Introduction. *Science*. 2010;330:1612–1613.
53. Bingen BO, Engels MC, Schaliy MJ, et al. Light-induced termination of spiral wave arrhythmias by optogenetic engineering of atrial cardiomyocytes. *Cardiovasc Res*. 2014;104:194–205.
54. Nussinovitch U, Gepstein L. Optogenetics for in vivo cardiac pacing and resynchronization therapies. *Nat Biotechnol*. 2015;33:750–754.
55. Nyns ECA, Kip A, Bart CI, et al. Optogenetic termination of ventricular arrhythmias in the whole heart: towards biological cardiac rhythm management. *Eur Heart J*. 2017;38:2132–2136.
56. Bruegmann T, Boyle PM, Vogt CC, et al. Optogenetic defibrillation terminates ventricular arrhythmia in mouse hearts and human simulations. *J Clin Invest*. 2016;126:3894–3904.
57. Crocini C, Ferrantini C, Coppini R, et al. Optogenetics design of mechanistically-based stimulation patterns for cardiac defibrillation. *Sci Rep*. 2016;6:35628.
58. Busskamp V, Roska B. Optogenetic approaches to restoring visual function in retinitis pigmentosa. *Curr Opin Neurobiol*. 2011;21:942–946.
59. Gradinaru V, Mogri M, Thompson KR, et al. Optical deconstruction of parkinsonian neural circuitry. *Science*. 2009;324:354–359.
60. Roberson DP, Binshtok AM, Blas F, et al. Targeting of sodium channel blockers into nociceptors to produce long-duration analgesia: a systematic study and review. *Br J Pharmacol*. 2011;164:48–58.
61. Mouroto A, Fehrentz T, Le Feuvre Y, et al. Rapid optical control of nociception with an ion-channel photoswitch. *Nat Methods*. 2012;9:396–402.
62. Gitlin JM. *Light-switched local anaesthetic lets scientists turn pain nerve on and off*. Available at: <https://www.arstechnica.com/science/2012/02/light-switched-local-anaesthetic-lets-scientists-turn-pain-nerve-on-and-off>. Accessed June 19, 2018.
63. Mouroto A, Tochitsky I, Kramer RH. Light at the end of the channel: optical manipulation of intrinsic neuronal excitability with chemical photoswitches. *Front Mol Neurosci*. 2013;6:5.

Frequently Asked Questions

Local Anesthetics

Question

Why is it said that intravascular administration of local anesthetics is dangerous when emergency department physicians frequently administer lidocaine intravenously to treat potentially fatal cardiac dysrhythmias?

Intravenous administration of local anesthetics is potentially hazardous at all times and in all patients. However, intravenous local anesthetics, such as lidocaine and procainamide, do have an important place in the management of prefatal ventricular dysrhythmias, such as premature ventricular contractions and ventricular tachycardia. Several factors, including weighing the risk versus the benefit, must be considered whenever local anesthetics are to be administered “safely” intravenously.

1. *The patient's physical status.* Patients receiving intravenously administered lidocaine or other antidysrhythmic drugs have potentially life-threatening cardiac dysrhythmias. The myocardium is highly irritable (usually secondary to ischemia), which is often the primary cause of the dysrhythmia. Local anesthetics are myocardial depressants. By depressing the myocardium, lidocaine decreases the incidence of dysrhythmias. However, patients with normal cardiac rhythms receiving intravenous local anesthetics will also have their myocardium depressed; their cardiac function may be impaired by the local anesthetic in this circumstance.
2. *The form of lidocaine used.* Lidocaine for intravenous use in the management of ventricular dysrhythmias, so-called cardiac lidocaine, is prepared in single-use ampules or prefilled syringes. These ampules and syringes contain only lidocaine and sodium chloride. The typical dental cartridge of lidocaine contains lidocaine, distilled water, a vasoconstrictor, sodium bisulfite, and sodium chloride. Intravenous injection of these ingredients, in and of itself, might precipitate unwanted cardiovascular responses rather than terminate them.
3. *The rate of injection.* Lidocaine for antidysrhythmic use is titrated slowly intravenously to achieve a therapeutic blood level in the myocardium. The accepted therapeutic blood level of lidocaine is between 1.8 and

5 µg/mL. To achieve this, lidocaine is administered intravenously slowly and is titrated until ventricular dysrhythmias on the electrocardiogram are eliminated—typically, a dose between 1.0 and 1.5 mg/kg. In the typical dental practice, a 1.8-mL cartridge of lidocaine (36 mg) is deposited in 15 seconds or less. The rate at which the drug is administered intravenously has a significant bearing on its peak blood level. Overly rapid intravenous administration results in lidocaine blood levels that quickly approach the overdose range, whereas a more slowly administered dose results in blood levels well within the therapeutic range for terminating dysrhythmias.

4. *Risk versus benefit.* An overdose reaction is possible anytime lidocaine is administered intravenously. Even under controlled conditions in a hospital, adverse reactions related to overly high blood levels do develop.¹⁻⁶ The risk from intravenous administration of local anesthetics must always be weighed against the potential benefit to be gained from their use. For high-risk patients with a specific life-threatening dysrhythmia, the benefit clearly outweighs the risk. For dental patients seeking relief from intraoral pain, intravenous local anesthetic administration confers no benefit yet adds many risks.

Question

What should I do when a patient claims to be allergic to a local anesthetic?

Believe the patient! Do not use any form of local anesthetic (including topical anesthetic preparations) on this patient until you are able to definitively determine whether a true, documented, reproducible allergy exists. Seek to determine what actually happened to the patient to prompt such a claim and how his or her “reaction” was managed. (A detailed discussion of this situation is given in [Chapter 18](#).)

Question

Are any local anesthetics safer than others? Some appear to be implicated more than others in adverse reactions.

No. When used properly, all currently available local anesthetic formulations are extremely safe and effective.

“Used properly” is the key phrase. Aspiration (twice) before injection (to minimize the risk from intravascular administration) and cardiac monitoring when drug are vital. To determine potential contraindications to specific local anesthetics or additives, the patient’s medical history must be obtained and a physical evaluation completed before their use. The maximum dose of a drug should be determined for a given patient and not exceeded. Tables for the most commonly used local anesthetics are found in [Chapters 4](#) and [18](#). The figures cited are maximum recommended doses. The stated maximum recommended dose should be decreased in patients with certain medical complications and in older individuals. Most systemic reactions to local anesthetics are entirely preventable. Overdose reactions that have led to death or significant morbidity frequently result from the administration of too large a dose to a younger, lighter-weight, well-behaved patient requiring multiple quadrants of dental care or, much less commonly, after “accidental” intravenous administration. Psychogenic reactions, by far the most common adverse response to the administration of a local anesthetic, may be virtually eliminated through enhanced rapport with the patient, use of an atraumatic injection technique (see [Chapter 11](#)), placement of the patient in a supine position during injection, and ample doses of empathy.

Question

Do some local anesthetics have a greater risk of producing nerve damage (e.g., paresthesia)?

Discussion in dental circles regarding 4% local anesthetic formulations and the reported incidence of paresthesia has ebbed and flowed since the introduction of articaine into Canada in 1985 and the United States in 2000. Such concern started in 1995 with the publication of an article by Haas and Lennon⁷ that stated the incidence of paresthesia following administration of all local anesthetic solutions was 1 in 785,000. For 0.5%, 2%, and 3% local anesthetics, the calculated risk was 1 in 1,125,000, and for 4% local anesthetics, it was 1 in 485,000.

Discussion of paresthesia associated with nonsurgical dental treatment is presented in [Chapters 17](#) and [20](#).

A meta-analysis comparing articaine hydrochloride with lidocaine (lignocaine) hydrochloride reported that articaine is more likely than lidocaine to achieve anesthetic success in the posterior first molar area, and that there is no difference in postinjection adverse events.⁸ A 2011 review of the articaine literature (116 articles reviewed) concluded that “although there may be controversy regarding its safety and advantages in comparison to other local anaesthetics, there is no conclusive evidence demonstrating neurotoxicity or significantly superior anesthetic properties of articaine for dental procedures.”⁹

For an in-depth look at all aspects of the local anesthetic articaine hydrochloride, the reader is referred to the article “Articaine 30 years later.”¹⁰

Question

How do I select an appropriate local anesthetic for a given patient and procedure?

Two factors are particularly important:

1. The duration of pain control required to complete the procedure painlessly, and the possible need for posttreatment pain control (e.g., after surgical procedures). [Box 4.1](#) lists currently available local anesthetic formulations by their approximate duration of action—for both soft tissue and pulpal anesthesia.
2. The patient’s physical status (e.g., American Society of Anesthesiologists [ASA] classification), hypersensitivity, methemoglobinemia, or sulfur allergy, which may preclude the use of specific drugs.

For most patients the duration of desired pain control is the ultimate deciding factor in local anesthetic selection, because usually there are no contraindications to the administration of any particular agent.

Question

What local anesthetics should be available in my office?

It is suggested that a number of local anesthetics be available at all times. The nature of the dental practice will dictate the number and types of local anesthetics needed. In a typical dental practice, selection of a local anesthetic formulation is based on the desired duration of pulpal anesthesia; for example, less than 30 minutes, approximately 60 minutes, in excess of 90 minutes. One local anesthetic preparation from each group, as necessitated by the nature of the doctor’s practice, should be available. For example, the pediatric dentist has little need or desire for long-acting local anesthetics such as bupivacaine, whereas the oral and maxillofacial surgeon may have little need for shorter-acting drugs such as mepivacaine plain, but a greater need for bupivacaine. Remember that not all patients have similar local anesthetic requirements, and the same patient may require a different local anesthetic for a dental procedure of a different duration. Amide local anesthetics are preferred to ester local anesthetics because of their decreased incidence of allergy.

Question

Do topical anesthetics really work?

Absolutely, if the topical anesthetic preparation is applied to mucous membrane for an adequate length of time.¹¹ The American Dental Association recommends a 1-minute application.¹² The US Food and Drug Administration recommends application for a minimum of 1 minute. Gill and Orr¹³ recommend application for 2 to 3 minutes. Topical anesthetics containing benzocaine are not absorbed from their site of application into the cardiovascular system; therefore the risk of overdose is minimal when benzocaine-containing topical anesthetic preparations are used.

On May 23, 2018, the US Food and Drug Administration issued a warning to consumers not to use teething products containing benzocaine in children younger than 2 years because of the risk of inducing methemoglobinemia when the product is administered in too large of a dose.¹⁴ Many dental topical anesthetics include benzocaine, but when applied appropriately to isolated areas in small amounts (see the following paragraph)—as is done in dental offices—this risk is minimal.

Because of the rapid absorption of some topically applied local anesthetics such as lidocaine, it is recommended that their use be restricted to the following situations:

1. locally, at the site of needle puncture before injection;
2. for scaling or curettage, over not more than one quadrant at a time.

Pressurized sprays of topical anesthetics cannot be recommended unless they release a metered dose of the drug, not a steady uncontrolled dose.¹⁵ Sterilization of the spray nozzle must be possible if a spray is used. Many pressurized topical anesthetic sprays are available in metered form with disposable spray nozzles.

Vasoconstrictors

Question

Are there any contraindications to the use of vasoconstrictors in dental patients?

Yes. Use of local anesthetics with vasoconstrictors should be avoided or kept to an absolute minimum in the following cases¹⁶⁻¹⁸:

1. patients with blood pressure in excess of 200 mmHg systolic or 115 mmHg diastolic
2. patients with uncontrolled hyperthyroidism
3. patients with severe cardiovascular disease
 - a. less than 6 months after myocardial infarction
 - b. less than 6 months after cerebrovascular accident
 - c. with daily episodes of angina pectoris or unstable (preinfarction) angina
 - d. with cardiac dysrhythmias despite appropriate therapy
 - e. after coronary artery bypass surgery less than 6 months ago
4. patients who are undergoing general anesthesia with halogenated agents
5. patients receiving nonspecific β -blockers, monoamine oxidase inhibitors, or tricyclic antidepressants

Patients in categories 1 to 3d are classified as ASA 4 class risks and are normally not considered candidates for elective or emergency dental treatment in the office. (See [Chapters 3 and 10](#) for more detailed discussions, and also see the next question.)

Question

Often medical consultants recommend against inclusion of a vasoconstrictor in a local anesthetic for a cardiovascular risk patient. Why? And what can I do to achieve effective pain control?

As indicated, there are several instances in which it is prudent to avoid the use of vasoconstrictors in local anesthetics. Most of these situations (e.g., severely elevated, untreated high blood pressure; severe cardiovascular disease) are also absolute contraindications to elective dental care because of greater potential risk to the patient. If a dental patient with cardiovascular disease is deemed treatable (ASA class 2 or 3), then local anesthetics for pain control are indicated. The patient's physician often states that although local anesthetics can be used, use of epinephrine should be avoided.

Question

When should use of epinephrine be avoided?

One of the few valid reasons for avoiding use of epinephrine is the patient with cardiac rhythm abnormalities that are unresponsive to medical therapy. The presence of dysrhythmias (especially ventricular) usually indicates an irritable or ischemic myocardium. Epinephrine, exogenous or endogenous, further increases myocardial irritability, thereby predisposing this patient to a greater frequency of dysrhythmias or to more significant types of dysrhythmias, such as ventricular tachycardia or ventricular fibrillation. In these patients, use of epinephrine-containing local anesthetics should be avoided, if at all possible. However, many cardiologists today do not even consider the ischemic myocardium a valid reason for excluding vasoconstrictors from local anesthetics, provided the dose of epinephrine administered is minimal (volume of drug and concentration of epinephrine [1:200,000 preferred]) and intravascular administration is avoided.

It is my recommendation that with a patient who is deemed able to tolerate the stresses involved in the planned dental treatment, a vasoconstrictor should be included in the local anesthetic if there is a valid reason for its inclusion (e.g., depth or duration of anesthesia, need for hemostasis). As Bennett has stated, "the greater the medical risk of a patient, the more important effective control of pain and anxiety becomes."¹⁹

Question

Why do many physicians still recommend against the use of epinephrine (and other vasoconstrictors) in cardiovascular risk patients?

Most physicians never, or at best rarely, use epinephrine in their practice. The only physicians who do so on a regular basis are anesthesiologists, emergency medicine specialists, and surgeons. As used in medicine, epinephrine is almost always used in emergency situations. At those times, the dose is considerably higher than that used in dentistry. The average emergency dose of intramuscularly or intravenously administered epinephrine (used in a 1:1000 or 1:10,000 concentration) for anaphylaxis or cardiac arrest is 0.3 to 1 mg, whereas one dental cartridge with 1:100,000 epinephrine contains only 0.018 mg.

It is therefore understandable that many physicians, lacking intimate knowledge of the practice of dentistry, think of epinephrine in terms of its use in emergency medicine and not in the much more dilute forms used for anesthesia in dentistry.

An example follows. In a hospital situation, a patient with a serious cardiovascular problem (ASA class 4) who requires a surgical procedure (e.g., emergency appendectomy) may be considered too great a risk for general anesthesia. Many anesthesiologists opt to use a regional local anesthetic (spinal) block with an intravenous antianxiety agent (midazolam) for sedation in place of general anesthesia. The local anesthetic usually contains epinephrine in a 1:100,000 or 1:200,000 concentration, added primarily to decrease the rate at which the local anesthetic is absorbed into the cardiovascular system, but also to minimize bleeding and prolong the duration of clinical action.

Question

Why is the use of vasoconstrictors in local anesthetics recommended for cardiac risk patients?

Pain is stressful to the body. During stress, endogenous catecholamines (e.g., epinephrine, norepinephrine) are released from their storage sites into the cardiovascular system at a level approximately 40 times greater than the resting level. (See [Chapter 3](#) for a review of the pharmacology of this group of drugs.)

Release of epinephrine and norepinephrine into the cardiovascular system increases the workload of the heart; thus the myocardial oxygen requirement increases. In patients with compromised (partially occluded) coronary arteries, if this increased myocardial oxygen requirement is not met, ischemia develops, leading to the onset of dysrhythmias, anginal pain (if ischemia is transient), or myocardial infarction (if ischemia is prolonged). Increased cardiac workload may also lead to acute exacerbation of heart failure (acute pulmonary edema). Elevated catecholamine levels can produce a dramatic increase in blood pressure; this can precipitate another life-threatening situation (e.g., a hemorrhagic stroke [cerebrovascular accident, “brain attack”]).

Therefore the goal is to minimize endogenous catecholamine release during dental therapy. The stress-reduction protocol is designed to accomplish this. A local anesthetic without a vasoconstrictor provides pulpal anesthesia of shorter duration than the same drug with a vasoconstrictor. Profound pain control of adequate duration is less likely to be achieved when a vasoconstrictor is excluded from a local anesthetic solution. If the patient experiences pain during treatment, an exaggerated stress response will be observed.

With proper use (aspiration twice and slow injection) of a local anesthetic with minimum volume and concentration of an exogenous vasoconstrictor (e.g., 1:200,000, 1:100,000), pain control of longer duration is virtually guaranteed and an exaggerated stress response avoided or minimized. Levels of catecholamine in the blood are elevated when exogenous

epinephrine is administered, but these levels are usually not clinically significant.

An often repeated and essentially true statement is that the cardiovascularly impaired patient is more at risk from endogenously released catecholamines than from exogenous epinephrine administered in a proper manner.

Question

Can I administer a local anesthetic with a vasoconstrictor even if a physician has advised against it?

Yes. A medical consultation is a request for advice from you to a person with more knowledge of the matter being discussed. You are not obligated to heed this advice if you feel it may be inaccurate. If doubt persists in your mind concerning the proper treatment protocol following this initial consultation, additional opinions should be sought, preferably from a specialist in the “area” of concern, such as a cardiologist, an anesthesiologist, or a dental expert in local anesthesia. Of course, for some patients, exogenous catecholamines may prove too great a risk; in these cases, plain local anesthetic solutions should be administered.

It must always be remembered that the primary responsibility for the care and well-being of a patient rests solely in the hands of the person who performs the treatment, not the one who gives advice.

An incident concerning a medical consultation is worth relating. A periodontal graduate student was planning four quadrants of osseous surgery on a patient whose medical history was within normal limits, except for a torticollis for which she was receiving imipramine, a tricyclic antidepressant. A written consultation was sent to the patient’s physician requesting that the patient stop being treated with imipramine before the surgical procedure was performed. The response was that the patient could not stop taking the drug because it had taken longer than 1 year to get her medical condition stabilized. Moreover, it was recommended that use of epinephrine be avoided during this patient’s surgery. It was decided to contact the physician directly to discuss the matter and to attempt to explain the importance of the use of epinephrine during an osseous surgical procedure. In the ensuing conversation, it was agreed that epinephrine could be used, but in a limited dose, and that the patient was to be monitored (vital signs) throughout the procedure. The surgery proceeded and was completed without incident.

The lesson to be learned from this episode is that the wording of the original consult was too constricting, or indeed might have been construed as threatening, to the physician. Whenever possible, there should be direct contact and discussion between both parties explaining their needs, as this is more likely to lead to a satisfactory compromise and to better and safer patient management.

Question

If epinephrine is used in cardiac risk patients, is there a maximum dose?

Yes. Bennett¹⁹ recommends, and others agree, that the maximum dose of epinephrine in a cardiac risk (ASA 2,3) patient should be 0.04 mg. This is the maximum dose for a patient with a cardiac risk.

- one cartridge of epinephrine 1:50,000
- two cartridges of epinephrine 1:100,000
- four cartridges of epinephrine 1:200,000

I cannot recommend use of epinephrine 1:50,000 for pain control purposes. (Further information on dental management of the cardiovascular risk patient is available.²⁰⁻²²)

Question

What about epinephrine-containing gingival retraction cord?

Racemic epinephrine gingival retraction cord should never be used for cardiovascular risk patients, and it is my opinion that it should not be used in any patient. Gingival retraction cord contains 8% racemic epinephrine. Half of this is the levorotatory form, which provides a concentration of active epinephrine of 4% (or 40 mg/mL). This is 40 times the concentration used in the management of anaphylaxis or cardiac arrest. Absorption of epinephrine through mucous membrane into the cardiovascular system is normally rapid but is even more so with active bleeding, such as that occurring after subgingival tooth preparation. Levels of epinephrine in the blood rise rapidly, leading to cardiovascular manifestations of epinephrine overdose (p. 346).

This increase in cardiovascular activity may prove to be life threatening in patients with preexisting clinically evident or subclinical cardiovascular disease.

Question

If I elect not to use a vasoconstrictor for a patient, which local anesthetics are clinically useful?

The clinically available local anesthetics are listed by their duration of action in [Box 4.1](#). Three percent mepivacaine (via nerve block) can provide up to 40 minutes of pulpal anesthesia for the typical patient, whereas 4% prilocaine (via nerve block) can provide up to 60 minutes.

Syringes

Question

What type of syringe is recommended?

Although a wide variety of syringes are available, two factors have primary importance in their selection:

1. A syringe must be capable of aspiration. Do not use a syringe that does not permit aspiration.
2. A syringe must be sterilizable, unless it is disposable.

In addition, with the introduction of so-called safety syringes, it is my recommendation that every consideration be given to the use of a syringe that is designed to minimize the risk of accidental needlestick after injection has been completed (see [Chapter 6](#)). Although the unit cost of the disposable safety syringe increases office expenses, the decreased liability faced by the doctor for needlestick injuries

should more than cover this consideration. Although in theory, safety syringes are mandatory, the lack of effective devices in the North American dental market has severely limited implementation into clinical practice. Traditional dental syringes continue to represent the standard of care.

Question

Do computer-controlled local anesthetic delivery (C-CLAD) systems work well enough to justify their purchase?

Yes. In most instances, C-CLAD systems enable the patient to receive effective local anesthesia in an entirely pain-free manner (visual analog scale score of 0 to 2). The response from dentists using C-CLAD systems ranges from being extremely ecstatic about their use to the feeling that they are not worth the expense. Most responses are favorable. In my experience, C-CLAD systems make it easier to more comfortably deliver those injections that are “difficult” to administer painlessly. These include all palatal injections and periodontal ligament techniques. C-CLAD systems are discussed extensively in [Chapters 5 and 20](#).

Needles

Question

What gauge and length of needles are recommended for injection?

Selection of a needle depends on several factors, foremost among which are the aspiration potential of the injection and the estimated depth of soft tissue penetration:

1. A long dental needle is recommended for inferior alveolar, Gow-Gates mandibular, Vazirani-Akinosi mandibular, anterior superior alveolar (infraorbital), and maxillary (V₂) nerve blocks in adults. I recommend a 25-gauge needle be used in such cases.
2. A short needle is recommended for posterior superior alveolar, mental, and incisive nerve blocks; maxillary infiltration (supraperiosteal); palatal nerve blocks and infiltration; and periodontal ligament and intraseptal injections. I recommend a 27-gauge needle be used in such cases.

If only two needles were to be available in my dental office, I would opt for a 25-gauge long needle and a 27-gauge short needle. I have absolutely no need or desire to ever use a 30-gauge needle for an intraoral injection. However, this is not the case in dentistry in the United States. Information received from needle manufacturers indicates that the most commonly purchased needles in dentistry in the United States are the 27-gauge long needle and the 30-gauge short needle (see [Table 6.2](#)).

I do not recommend a 30-gauge short needle, but it may be used for local infiltration to produce hemostasis. The major problem, in my opinion, is the increased risk of needle breakage and retention within soft tissues if the 30-gauge needle is used for an injection technique that mandates use of a long dental needle. The management of broken needles is reviewed in [Chapter 17](#).

Cartridges

Question PDF Compressor Free Version

Why do you (the author) call this a cartridge when everyone else calls it a carpule?

Carpule was a proprietary name for the glass cartridge. The name was trademarked by Cook-Waite Laboratories.²³ (See [Chapter 7](#) for the history of the dental local anesthetic “carpule.”)

Question

Can glass cartridges be autoclaved?

No. Autoclaving of glass cartridges destroys their seals. The heat of autoclaving also degrades the heat-labile vasoconstrictor.

Question

Should local anesthetic cartridges be stored in alcohol or cold sterilizing solution?

No. Alcohol or cold sterilizing solution diffuses into the cartridge. Injection of these into tissues may produce burning, irritation, or paresthesia. (The care and handling of local anesthetic cartridges are discussed in [Chapter 7](#).)

Question

Are cartridge warmers effective in making local anesthetic solutions more comfortable on injection?

No. Most cartridge warmers make the local anesthetic solution too warm, leading to increased discomfort on injection, and possible destruction of the heat-sensitive vasoconstrictor. Cartridges of local anesthetic solution stored at room temperature produce no discomfort to patients and are greatly preferred.

Question

Why do some patients complain of a burning sensation when a local anesthetic is injected?

Because of its acidic pH, any local anesthetic may cause a slight burning sensation during the initial injection. The pH of a plain solution is in the range from 5.5 to 6.0, and that of a vasoconstrictor-containing solution is in the mid-3 to mid-4 range. Other causes include an overly warm solution, the presence of alcohol or cold sterilizing solution within the cartridge, or a solution with a vasoconstrictor at or near its expiration date.

The introduction of a simple reliable system of buffering local anesthetic cartridges immediately before injection, raising the pH to a body-compatible 7.4, enables the more comfortable delivery of local anesthetic to patients. Local anesthetic buffering is discussed in [Chapter 20](#).

Question

What causes local anesthetic solution to run down the outside of the needle into a patient's mouth?

Improper preparation of the armamentarium is to blame for this (see [Chapter 9](#)). The recommended sequence for preparation (using a metal syringe and a disposable needle) is as follows:

1. Place the cartridge in the syringe.
2. Embed the aspirating harpoon with finger pressure only. (No tapping or hitting of the plunger is necessary.)
3. Place the needle on the syringe.

This sequence provides a perfectly centric perforation of the rubber diaphragm by the needle, with a tight seal formed around the needle. No leakage of anesthetic occurs.

When the needle is placed onto the syringe first, followed by the cartridge, it is possible for the perforation of the diaphragm to be ovoid, not round. The ovoid perforation does not seal itself as well around the metal needle, leading to leakage of anesthetic around this area as the anesthetic drug is injected.

Question

What causes cartridges to break during injection?

1. Damage during shipping. Visually check cartridges before use.
2. Use of excessive force to engage the aspirating harpoon in the rubber stopper. Proper preparation of the needle, cartridge, and syringe (see the previous question) precludes breakage caused by excessive force. When the needle is placed onto the syringe before the cartridge, it is necessary to “hit” the plunger to embed the harpoon in the rubber stopper. This may cause a cartridge to shatter.
3. An attempt to force a cartridge with an extruded plunger into the syringe.
4. Use of a syringe with a bent aspirating harpoon.
5. A bent needle with an occluded lumen. Always expel a small volume of anesthetic from the syringe before inserting the needle into the patient's tissues to ensure patency of the needle.

Techniques of Regional Anesthesia in Dentistry

Question

What should always be done before local anesthetic administration in a patient?

Review of the patient's medical history questionnaire (visually or verbally) and a physical examination, including vital signs and visual inspection, are recommended when a patient is seen for the first time or after a long absence from the office. This identifies possible

contraindications to the use of local anesthetics or vasoconstrictors and in general determines a patient's ability to tolerate physical compression of the soft tissue of dental care without undue risk.

Question

What are medical contraindications to the use of local anesthetics and vasoconstrictors?

These are discussed in [Chapter 4](#) and in excellent review articles by Perusse et al.¹⁶⁻¹⁸

Question

Should a patient be advised that a local anesthetic injection will hurt before the injection is started?

No. Local anesthetic injections need not hurt. Careful adherence to the atraumatic injection protocol described in [Chapter 11](#) can make virtually all injections, including palatal injections, painless. The recently introduced tetracaine-oxymetazoline nasal spray provides palatal soft tissue anesthesia from the second premolar to central incisor (see [Chapter 20](#)).

Question

Is any specific chair position best for administration of local anesthetics?

Yes, absolutely! Because the most commonly observed adverse reactions to local anesthetics are psychogenic (e.g., syncope), the position of choice during intraoral injections is one in which the patient's chest (heart) and head are parallel to the floor with the feet slightly elevated. Presyncopal episodes may still occur (pallor, lightheadedness), but actual loss of consciousness is extremely unlikely to develop with the patient in this position.

After completion of several mandibular injections (inferior alveolar, Gow-Gates mandibular, and Vazirani-Akinosi mandibular nerve blocks), it is my recommendation that the patient be returned to a comfortable, more upright position during the ensuing 5 to 10 minutes. This change in patient position appears (anecdotally) to help speed the onset of mandibular anesthesia.

Question

Why do you (the author) recommend regional anesthesia in the maxilla instead of infiltration (supraperiosteal) anesthesia?

Regional anesthesia in the maxilla is preferred to infiltration whenever more than two teeth are to be treated. Its advantages include:

1. fewer penetrations of tissue, thus less likelihood of postinjection soreness;
2. smaller volume of local anesthetic (e.g., than for multiple infiltrations of the same area), thereby decreasing the risk of systemic reactions such as overdose;
3. clinically adequate anesthesia more likely when infiltration is ineffective because of the presence of infection.

Question

Do palatal injections always hurt?

No. Careful adherence to the protocol for atraumatic injections can do much to minimize any discomfort associated with palatal anesthesia. In addition, the following are important:

1. topical anesthesia
2. pressure anesthesia
3. control of the needle
4. slow deposition of solution
5. positive attitude of the administrator

An area of considerable interest among practicing dentists is palatal anesthesia and how to increase patient comfort. Over the years, I have received many devices designed by dentists in an attempt to minimize or eliminate pain during palatal injections, and I have been told of many techniques. These include using vibrating wands, letting the needle trace along the palate for a second or two so patients know it is coming and it is not a "shock" to them, and avoiding the use of palatal injections unless they are absolutely necessary.

The clinical introduction of C-CLAD systems (see earlier and [Chapter 5](#)) permits the delivery of local anesthetic injections in any area of the oral cavity in a pain-free manner in most situations. Additionally, the tetracaine-oxymetazoline nasal spray provides significant degrees of palatal soft tissue anesthesia (see [Chapter 20](#)).²⁴

Question

Why do I have a higher failure rate with inferior alveolar nerve blocks than with any other injection?

Of all nerve blocks in dentistry and, with few exceptions, in medicine too, the inferior alveolar nerve block is the most elusive of consistent success. A success rate, bilaterally, of 85% or greater indicates that one's technique is basically correct. However, many factors can, and do, affect this rate of success:

1. *Anatomic variation.* It is well known that if any one aspect of human anatomy is consistent, it is its inconsistency. Strict adherence to injection technique does not always produce adequate inferior alveolar nerve anesthesia.
2. *Technical error.* The most common technical error observed with the inferior alveolar nerve block is insertion of the needle too low on the medial side of the ramus (below the mandibular foramen, where the inferior alveolar nerve enters the mandibular canal). A second common technical error is insertion of the needle too far anteriorly (laterally) on the medial side of the ramus (thus contacting bone quite soon after penetration).
3. *Accessory innervation.* When isolated regions of mandibular teeth remain sensitive when all other areas are insensitive, the possibility of accessory innervation should be considered. The technique used in eliminating this problem (which is usually produced by the mylohyoid nerve) is described in [Chapter 14](#).

In September 2011 a supplement to the *Journal of the American Dental Association* titled *Is the Mandibular Block Passé?* was published. **PDF Compressor Free Version** It could be argued that it had not yet arrived to bid farewell to the traditional inferior alveolar nerve block, sufficient alternative techniques are available to enable the doctor to provide successful pain control in the mandible in virtually all treatment situations: Gow-Gates, Vazirani-Akinosi, and incisive (mental) nerve blocks; intraosseous, intraseptal, and periodontal ligament injections; and the use of articaine by mandibular infiltration in adults. The introduction of a reliable and simple system for buffering local anesthetic cartridges has added to success. These techniques are discussed in Chapters 14, 15, and 20.

It is my opinion, in 2019, that the traditional inferior alveolar nerve block *is* indeed passé!

Question

Why do I have a much higher failure rate with the inferior alveolar nerve block on one side than on the other?

Because of significantly different operator positions during administration of the inferior alveolar nerve block on contralateral sides of the mouth, it is not uncommon for some doctors to encounter significant differences in their success rates. The inferior alveolar nerve block is the only intraoral nerve block for which significant differences in success rates are noted on opposite sides of the mouth. Although basic protocols are the same on the right and left sides, the view of the target area as seen by the administrator, the angle of needle entry, and other factors may be responsible for an increased failure rate on one side. The solution to this problem is to critically evaluate one's technique on the less successful side and to seek to correct it without interfering with success on the opposite side. Patience is often necessary.

Question

How can I achieve adequate pain control when gaining access in pulpally involved teeth?

The recommended sequence of injection techniques for pulpally involved teeth is as follows (Box 19.1):

1. Buffered local anesthetic solution.
2. Local infiltration, if possible and not contraindicated.
3. Regional nerve block (inferior alveolar nerve block, Gow-Gates mandibular nerve block, posterior superior alveolar nerve block, etc.). For mandibular molars start with two cartridges of buffered local anesthetic, followed by:
4. (Buffered) articaine infiltration at the apex of the mandibular tooth to be treated.
5. Inhalation sedation (N₂O-O₂).
6. Intraosseous, intraseptal, or periodontal ligament injection (if not contraindicated by the presence of infection).
7. Intrapulpal injection.
8. Prayer...when nothing else works! However, with the introduction of intraosseous anesthesia, this step is rarely, if ever, needed.

For all teeth in the mouth, with the probable exception of mandibular molars, clinically adequate pain control for pulpal extirpation can be obtained with local infiltration or nerve block injection. Difficulties arise most often in the infected mandibular molar (symptomatic irreversible pulpitis). A working knowledge of alternative mandibular anesthesia techniques, such as the Gow-Gates mandibular block or the Vazirani-Akinosi mandibular block, increases the likelihood of obtaining anesthesia. In addition, the use of intraosseous anesthesia greatly increases success rates in mandibular molars.

Mandibular premolars and anterior teeth can be anesthetized adequately for pulpal extirpation with the incisive nerve block.

Question

What special concerns are involved with local anesthesia in pediatric dentistry?

Pain control is generally easier to achieve in pediatric dentistry. However, two concerns should always be considered:

1. *Increased potential for overdose* exists because (most) children are smaller and weigh less than adults. Use milligram-per-weight formulas to minimize maximum doses in children.
2. *Prolonged anesthesia* can lead to self-inflicted soft tissue injury of the lips and tongue, unless shorter-duration drugs are used and both the patient and the parent are made aware of this possible complication. The administration of the local anesthesia reversal drug phentolamine mesylate at the conclusion of treatment significantly decreases the duration of residual soft tissue anesthesia (see Chapter 20).

A third concern relates to injection technique and the appropriate needle to be used in specific techniques. A long dental needle is recommended for the injections described in this book for which a considerable thickness of soft tissue is to be penetrated. The rationale for this is the rule of thumb that "a needle should not be inserted into tissue all the way to its hub, unless it is absolutely necessary for the success of that injection." If it is possible for an injection technique to be administered in a child with a short needle (~20 mm long) within the parameters of this rule, then use of this needle is warranted. Psychologically, however, the sight of a long needle is more traumatic than the sight of a short needle (in point of fact, needles and syringes should always be kept out of a patient's line of sight, if possible).

Question

What is the recommended method of achieving hemostasis in surgical areas?

The recommended technique is local infiltration of a vasoconstrictor-containing anesthetic into the region of the surgery. Only small volumes are necessary for this purpose. Epinephrine in a concentration of 1:100,000 is recommended (although 1:50,000 may also be used).

References

1. Radowicka A. Intra-oral infiltration with 2% xylocaine. Reversible systolic cardiac arrest after administration of xylocaine. *Kardiol Pol.* 1981;24:237–242.
2. Applebaum D, Halperin E. Asystole following a conventional therapeutic dose of lidocaine. *Am J Emerg Med.* 1986;4:143–145.
3. Mishima S, Kasai K, Yamamoto M, et al. Cardiac arrest due to lidocaine. *Masui.* 1989;38:1365–1368.
4. Gilbert TB. Cardiac arrest from inadvertent overdose of lidocaine hydrochloride through an arterial pressure line flush apparatus. *Anesth Analg.* 2001;93:1534–1536.
5. Doumiri M, Moussaoui A, Maazouzi W. Cardiac arrest after gargling and oral ingestion of 5% lidocaine. *Can J Anaesth.* 2008;55:882–883.
6. Yang JJ, Shen J, Xu J. Cardiac asystole after nasal infiltration of lidocaine with epinephrine in a transsphenoidal hypophysectomy patient with hypertrophic cardiomyopathy. *J Neurosurg Anesthesiol.* 2010;22:81–82.
7. Haas DA, Lennon D. A 21 year retrospective study of reports of paresthesia following local anesthetic administration. *J Can Dent Assoc.* 1995;61:319–320, 323–326, 329–330.
8. Katyal V. The efficacy and safety of articaine versus lignocaine in dental treatments: a meta-analysis. *J Dent.* 2010;38:307–317.
9. Yapp KE, Hopcraft MS, Parashos P. Articaine: a review of the literature. *Br Dent J.* 2011;210:323–329.
10. Malamed SF. Articaine 30 years later. *Oral Health.* 2016;106:42–68.
11. Meechan JG. Intra-oral topical anaesthetics: a review. *J Dent.* 2000;28:1–14.
12. Ciancio SG, ed. *ADA/PDR Guide to Dental Therapeutics.* 5th ed. Chicago: American Dental Association; 2012.
13. Gill CJ, Orr DL. A double blind crossover comparison of topical anesthetics. *J Am Dent Assoc.* 1979;98:213.
14. FDA warns consumers against using benzocaine products. *ADA News.* 2018;49(11):14.
15. Gunter JB. Benefits and risks of local anesthetics in infants and children. *Paediatr Drugs.* 2002;4:649–672.
16. Perusse R, Goulet JP, Turcotte JY. Contraindications to vasoconstrictors in dentistry: part I. Cardiovascular diseases. *Oral Surg.* 1992;74:692–697.
17. Perusse R, Goulet JP, Turcotte JY. Contraindications to vasoconstrictors in dentistry: part II. Hyperthyroidism, diabetes, sulfite sensitivity, cortico-dependent asthma, and pheochromocytoma. *Oral Surg.* 1992;74:587–691.
18. Perusse R, Goulet JP, Turcotte JY. Contraindications to vasoconstrictors in dentistry: part III. Pharmacologic interactions. *Oral Surg.* 1992;74:592–697.
19. Bennett CR. *Monheim's Local Anesthesia and Pain Control in Dental Practice.* 7th ed. St Louis: Mosby; 1984.
20. Anonymous. Cardiovascular effects of epinephrine in hypertensive dental patients. *Evid Rep Technol Assess (Summ).* 2002;48:1–3.
21. Silvestre FJ, Verdu MJ, Sanchis JM, et al. Effects of vasoconstrictors in dentistry on systolic and diastolic arterial pressure. *Med Oral.* 2001;6:17–63.
22. Yagiela JA. Adverse drug interactions in dental practice: interactions associated with vasoconstrictors. Part V of a series. *J Am Dent Assoc.* 1999;130:701–709.
23. Hyson JM Jr, Whitehorne JWA, Greenwood JT. *A History of Dentistry in the US Army to World War II.* Washington, DC: Office of The Surgeon General; 2008:508–509.
24. Ciancio SG, Marberger AD, Ayoub F, et al. Comparison of 3 intranasal mists for anesthetizing maxillary teeth in adults: a randomized, double-masked, multicenter phase 3 clinical trial. *J Am Dent Assoc.* 2016;147:339–347.
25. Malamed SF. Is the mandibular block passé? *J Am Dent Assoc.* 2011;142(suppl 9):35–75.
26. Haas D. Alternative mandibular block techniques: a review of the Gow-Gates mandibular nerve block and Akinos-Vazirani closed-mouth mandibular nerve block techniques. *J Am Dent Assoc.* 2011;142(suppl 9):8S–12S.
27. Moore PA, Cuddy MA, Cooke MR, et al. Intraosseous anesthesia techniques: alternatives to mandibular nerve blocks. *J Am Dent Assoc.* 2011;142(suppl 9):13S–18S.
28. Meechan JG. Mandibular infiltration anesthesia in adults. *J Am Dent Assoc.* 2011;142(suppl 9):19S–26S.

Legal Considerations

There exist several legal theories, which may give rise to lawsuits by potential plaintiffs against defendant health professionals. A legal theory is the cause of action under which a lawsuit is brought.

Contract Law

Contract law has provided a basis for suits in which a health care professional is accused of guaranteeing a result related to treatment; for example, promising that administration of local anesthesia, or any subsequent procedure, will be pain-free. When the result does not meet the plaintiff's personal satisfaction, remedy may be sought in court. Because the contract in this example was based on the patient's subjective opinion, the defendant doctor must prove that the patient never felt pain—an extremely difficult task. Plaintiff suits based in contract law against health providers are relatively rare.

Criminal Law

Recent history has seen a disturbing and dramatic increase in the number of suits filed under criminal law theories by government prosecutors in areas such as alleged fraudulent activity on the part of the health care provider and for plaintiff morbidity or death. Historically, prosecutors criminally attacking health providers must be able to prove that a criminal mind (*mens rea*) exists and that society has been injured. The current trend is to enact new legislation to not require proof of criminal *mens rea* but instead require a *mens rea* of strict liability (such as in the Patient Protection and Affordable Care Act, or “Obamacare”) to negate any real analyses of intent. This change bodes ill for health professionals and others in that they now have the burden of proof that requires defendants to prove their innocence, rather than requiring prosecutors to prove guilt. This singularly significant change in criminal law is exacerbated by the fact that the forum for such controversies may be a regulatory agency, rather than a courtroom with its attendant constitutional safeguards.

Tort Law

The legal theory covering most health professional lawsuit activity is that of tort. A *tort* is a private civil wrong not

normally arising from a contract. The tort may or may not lead to further prosecution under criminal or other legal theories, such as trespass to the person. Classically, a viable suit in tort usually falls under the negligence theory, and requires the defendant's conduct meet four essential elements: duty, a breach of that specific duty, proximate cause leading to damage, and damage related to the specific breach of duty. A health professional may successfully defend a suit in tort by proving that no duty existed, that no breach of duty occurred, that the health professional's conduct was not the cause of damage, or that no damage exists. In addition, the elements must be logically linked. For instance, if a doctor negligently administers a drug that the patient is historically allergic to and the patient contemporaneously develops agoraphobia, the doctor would not be liable for the agoraphobia.

Duty

Briefly, the health professional owes a duty to the patient if the health professional's conduct created a foreseeable risk to the patient. Generally, a duty is created when a patient and a health professional personally interact for health care purposes. Face-to-face interaction at the practitioner's place of practice most likely would fulfill the requirement of a created duty; interaction over the telephone, Internet, etc. may not be as clear-cut regarding establishment of duty.

Breach of Duty

A breach of duty occurs when the health care professional fails to act as a reasonable health care provider, and this in medical or dental malpractice cases is proved to the jury by comparison of the defendant's conduct with the reasonable conduct of a similarly situated health professional. Testimony for this aspect of a suit for malpractice is usually developed by expert witnesses. Exceptions to the rule requiring experts are cases in which damage results after no consent was given or obtained for an elective procedure, and cases in which the defendant's conduct is obviously erroneous and speaks for itself (*res ipsa loquitur*) such as wrong-sided surgery. In addition, some complications are defined as malpractice per se by statute, such as unintentionally leaving a foreign body in a patient after a procedure.

Standard of Care

Experts testifying as **PDF Compressor Free Version** about *standard-of-care* issues. It is often mistakenly assumed that the standard of the practitioner's community is the one by which he or she will be judged. Today, the community standard is the national standard. If specialists are reasonably accessible to the patient, the standard will be the national standard for specialists, whether or not the practitioner is a specialist. The standard of care may also be illustrated by professional literature. Health care professionals are expected to be aware of current issues in the literature, such as previously unreported complications with local anesthetics. Often articles will proffer preventative suggestions and will review treatment options.

Simply because an accepted writing recommends conduct other than that which the health care provider used is not necessarily indicative of a breach of duty. For instance, specific drug use other than that recommended by the *Physicians' Desk Reference* is commonplace and legally acceptable as long as the health care provider can articulate a reasonable purpose for his or her conduct. Part of this reasoning may likely include a benefit-risk analysis of various treatment options for a specific patient.

In addition, there is no single standard-of-care treatment plan for a given situation. Several viable treatment plans may exist, and all may be within the standard of care, such as the option of choosing different local anesthetic formulations for a procedure.

Finally, ultimately, the standard of care may be determined by the jury itself after it weighs expert opinion, the professional literature, opinions of professional societies or boards, and so forth.

Proximate Cause

Proximate cause is the summation of actual cause and legal cause. Actual cause exists if a chain of events factually flows from the defendant's conduct to the plaintiff's injury. Legal cause is present if actual cause exists, and if the plaintiff's attorney can prove that the harm sustained was foreseeable or was not highly extraordinary in hindsight.

Damage

Damage is the element of the cause of action that is usually easiest to identify because it is most often manifested physically. Simply because damage is present does not mean that malpractice has been committed, but damage must be present to fulfill all elements of the tort.

The nation has seen a dramatic rise not only in tort-based malpractice lawsuits over the past several years but also in regulatory activity (the Patient Protection and Affordable Care Act alone will result in the creation of at least 159 new regulatory agencies), both of which result in the predictable sequelae of increased costs and decreased access to doctors for patients. Trauma centers have closed, doctors

are actively and passively (i.e., by limiting their practice or opting for early retirement) leaving lawsuit-friendly communities or states, and patient consumers are now starting to feel directly the loss of health professional availability and other consequences of a litigation system that has never been busier.

The administration of local anesthesia is a procedure that is not immune to the liability crisis. Although extremely safe, given estimates that more than 300,000,000 dental local anesthetic administration procedures are performed annually in the United States, the administration of local anesthesia will at times result in unintended damage to the patient. If the elements of duty, breach of duty, and proximate cause accompany that damage, malpractice may have been committed. However, complications most often occur with no fault on the part of the local anesthetic administrator. In these situations, most complications are still foreseeable, and because they are predictable, the reasonable practitioner needs to be aware of optimal immediate and long-term treatment for the complications of local anesthetic administration.

The purpose of this chapter is not to describe in great detail the prevention or treatment of various local anesthetic complications but is to simply mention foreseeable complications and comment on the standard of care with regard to appropriate prevention and treatment. Obviously, some complications are common and others are rare, and frequency is an issue that would be considered in legal evaluation of a case. In any case, the health care professional administering potent local anesthetics by definition tells the public that it can trust in that professional while under his or her care. When pretreatment questions arise, it is the health care professional's duty to investigate controversial or unknown areas to minimize risk and maximize the benefits of his or her therapeutic decisions. When foreseen or unforeseen complications arise, the health care professional must be able to act in a reasonable manner to address these untoward events.

Adequate legal response to a local anesthetic complication or emergency is often equivalent to adequate dental or medical response. However, when damage persists, plaintiff attorneys will argue that the dental or medical response was not an adequate legal response and will seek damages. The fact that the treatment rendered by the practitioner may be recognized by most of the profession as optimal may not convince a jury when the plaintiff can find an expert who offers an opposite opinion. However, damage alone will not prove malpractice. The tort can be successfully defended by showing no duty, no breach of duty, or no proximate cause. In many cases, no matter what the complication discussed in this chapter, these legal defenses are the same in theory and are applicable across the board, although the dental/medical responses are more tailored to the specific situation.

If one is uncomfortable with any of the various situations mentioned in this chapter, further individual research in that area may be warranted.

In addition to the civil, or tort, remedies available to the plaintiff patient, a health care practitioner may have to defend conduct in a criminal forum. Depending on the disposition of the plaintiff and his or her representative, the conduct of the health care practitioner may be predictably evaluated not only civilly, but perhaps criminally, or via other governmental agencies such as licensing boards and better business bureaus. In theory, the arguments presented by competing sides in these various forums are the same no matter what the forum. However, very real differences are involved; in particular, the penalties and the burden of proof may be significantly different.

If the case is taken to a state agency, typically the board that issued the health professional's license, the rules of evidence are not onerous as far as admission by the plaintiff. Essentially, the regulatory agency can accept any evidence it deems relevant, including hearsay, which means the defendant may not have the right of facing an accuser. The burden of proof, which typically rests with the moving party or plaintiff, may even be arbitrarily assigned to the defendant by the agency. The reason why the rules of evidence are so liberal in state agency forums is because the issuance of an agency professional license may be deemed a privilege and not a right. The significance of proper representation and preparation if one is called before a regulatory agency cannot be understated when one considers the very real possibility of loss of a license and subsequent loss of ability to practice.

If one is summoned to a civil forum, the rules of evidence and the burden of proof are more strictly defined. Rules of evidence are subject to state and federal guidelines, although this is an area that is not black and white, and attorneys are frequently required to argue zealously for or against admission of evidence.

In a civil forum the burden of proof generally remains with the plaintiff, and the plaintiff is required to prove his or her allegations by a preponderance of evidence. Expressed mathematically, a preponderance is anything over 50%. This essentially means that anything that even slightly tips the scales in favor of the plaintiff in the jury's opinion signifies that the plaintiff has met the burden and thus may prevail.

In criminal cases, which again may be initiated for exactly the same conduct that may place the defendant in other forums, the burden of proof rests squarely with the prosecution (i.e., the state or federal government). In addition, the burden is met only by proof that is beyond a reasonable doubt, not simply a preponderance of evidence. Although the definition of *reasonable doubt* is open to argument, reasonable doubt is a more difficult standard to meet than is found in agency or civil forums.

Consent

The consent process is an essential part of patient treatment for health care professionals. Essentially, consent involves explaining to the patient the advantages and disadvantages

of differing treatment options, including the benefits and risks of no treatment at all. Often treatment planning will result in several viable options that may be recommended by the doctor. The patient makes an informed decision as to which option is most preferable to that patient, and treatment can begin.

Consent is essential because many of the procedures that doctors perform would be considered illegal in other settings; for instance, an incision developed by a doctor during surgery versus an equivalent traumatic wound placed during commission of a criminal battery.

Consent may be verbal or written, but when a controversy presents itself at a later date, written consent is extremely beneficial (Fig. 23.1). Because many times consent is required to fulfill the standard of care for a procedure, lack of written consent may reduce the fact finding to a "he said/she said" scenario. This circumstance may greatly diminish the plaintiff's burden of proving the allegations and may even shift the burden of proof to the defendant.

When mentally challenged persons or children younger than the age of majority are treated, consent from a legal guardian is necessary for elective procedures. Whenever restraint is planned or anticipated, consent is warranted.

Consent obtained before one procedure is performed may not be assumed for the same procedure at a different time, or for a different procedure at the same time. In addition, consent obtained for one health care provider to treat a patient may not be transferable to another health care provider, such as a partner doctor or an employee dental hygienist or registered nurse.

Consent is not necessary at times. When a patient is treated in an emergency setting (e.g., a spontaneously or traumatically unconscious patient), consent is implied. However, when possible, consent may be obtained from a legal guardian. The possibility of obtaining consent from a guardian before an emergency procedure is performed is time dependent. In an urgent situation, time may be available to discuss treatment options with a guardian. However, during a more emergent situation, taking time to discuss treatment options may actually compromise the patient.

Generally, emergency aid rendered in nondental or nonmedical settings does not require consent secondary to Good Samaritan statutes, which apply to "rescues." However, a source of liability even when one is being a Good Samaritan is reckless conduct. Reckless conduct in a rescue situation often involves leaving the victim in a situation that is worse than when the rescuer found the victim. An example of such conduct is seen when a rescuer offers to transport a victim to a hospital for necessary treatment and then abandons the victim farther from a hospital than where the victim was initially found.

The patient who offers to sign a waiver to convince a practitioner to provide treatment, for instance, will not likely be held to that waiver if malpractice is suspected and then is adjudicated to exist; it is a recognized principle that a patient may not consent to malpractice because such consent goes against public policy.

INFORMED CONSENT

PDF Compressor Free Version

I hereby request that _____ provide treatment for me for the following condition: _____.

I have been afforded the time and opportunity to discuss this proposed treatment, the alternatives, and risks with _____, and I understand:

1. The means of treatment will be: _____

2. The alternative means of treatment are: _____

3. The advantages of proposed treatment over alternative treatment are:

4. That all treatments including the one proposed have some risks. The risks of importance involved in my treatment have been explained to me, and they are: _____

5. The risks of nontreatment are: _____

Signature of Patient

Date

Signature of Witness

Signature of Healthcare Practitioner

• Fig. 23.1 Sample informed consent form.

Some may reasonably inquire if consent is even necessary for administration of local anesthesia. Consent is required for any procedure that poses a foreseeable risk to the patient. If the administration of local anesthetic could foreseeably result in damage to the patient, consent should be considered.

Further, some patients prefer to not be given any local anesthesia, even for significant operative procedures, thus at times truly rendering the administration of local anesthesia for dentistry optional and not necessarily required. In fact, the administration of local anesthetic in dentistry did not become routine until the 1930s. It

cannot be assumed that local anesthesia is automatically part of most dental procedures. If a patient is forced to have a local anesthetic without consent, technically the tort of battery has occurred. On the other hand, if a patient is forced to undergo a procedure without or with inadequate local anesthesia, a battery may also have occurred.

At times, local anesthetic administration is used for certain diagnostic or therapeutic procedures, such as differential diagnosis or treatment of atypical facial pain syndromes, thus establishing the administration of local anesthesia as both diagnostic and therapeutic in and of itself.

Finally, local anesthetic administration involves injecting or otherwise administering potent pharmaceutical agents. These agents may inadvertently damage a patient. Any health professional conduct that may reasonably be expected to predictably result in damage requires consent.

Health Insurance Portability and Accountability Act of 1996

The Health Insurance Portability and Accountability Act (HIPAA) of 1996 was signed into law by former President Bill Clinton on August 21, 1996. Conclusive regulations were issued on August 17, 2000, to be instated by October 16, 2002. HIPAA requires that the transactions of all patient health care information be formatted in a standardized electronic style. In addition to protecting the privacy and security of patient information, HIPAA includes legislation on the formation of medical savings accounts, the authorization of a fraud and abuse control program, the easy transport of health insurance coverage, and the simplification of administrative terms and conditions.

HIPAA encompasses three primary areas, and its privacy requirements can be broken down into three types: (1) privacy standards, (2) patients' rights, and (3) administrative requirements.

Privacy Standards

A central concern of HIPAA is the careful use and disclosure of protected health information (PHI), which generally is electronically controlled health information that is able to be distinguished individually. PHI also refers to verbal communication, although the HIPAA Privacy Rule is not intended to hinder necessary verbal communication. The US Department of Health and Human Services (USDHHS) does not require restructuring, such as soundproofing and architectural changes, but some caution is necessary when health information is exchanged by conversation.

An Acknowledgment of Receipt Notice of Privacy Practices, which allows patient information to be used or divulged for treatment, payment, or health care operations (TPOs), should be procured from each patient. A detailed and time-sensitive authorization also can be issued; this allows the dentist to release information in special circumstances other than TPOs. Written consent is also an option. Dentists can disclose PHI without acknowledgment, consent, or authorization in very special situations; for example, perceived child abuse, public health supervision, fraud investigation, or law enforcement with valid permission (e.g., a warrant). When divulging PHI, a dentist must try to disclose only the minimum necessary information, to help safeguard the patient's information as much as possible.

Dental professionals must adhere to HIPAA standards because health care providers (as well as health care clearinghouses and health care plans) who convey electronically formatted health information via an outside billing service

or merchant are considered covered entities. Covered entities may be dealt serious civil and criminal penalties for violation of HIPAA legislation. Failure to comply with HIPAA privacy requirements may result in civil penalties of up to \$100 per offense, with an annual maximum of \$25,000 for repeated failure to comply with the same requirement. Criminal penalties resulting from illegal mishandling of private health information can range from \$50,000 and/or 1 year in prison to \$250,000 and/or 10 years in prison.

Patients' Rights

HIPAA allows patients, authorized representatives, and parents of minors, as well as minors, to become more aware of the health information privacy to which they are entitled. These rights include, but are not limited to, the right to view and copy their health information, the right to dispute alleged breaches of policies and regulations, and the right to request alternative forms of communicating with their dentist. If any health information is released for any reason other than TPO, the patient is entitled to an account of the transaction. Therefore dentists must keep accurate records of such information and provide them when necessary.

The HIPAA Privacy Rule indicates that the parents of a minor have access to their child's health information. This privilege may be overruled, for example, in cases in which child abuse is suspected, or when the parent consents to a term of confidentiality between the dentist and the minor. Parents' rights to access their child's PHI may be restricted also in situations in which a legal entity, such as a court, intervenes, and when the law does not require a parent's consent. To obtain a full list of patients' rights provided by HIPAA, a copy of the law should be acquired and well understood.

Administrative Requirements

Complying with HIPAA legislation may seem like a chore, but it does not need to be so. It is recommended that health care professionals become appropriately familiar with the law, organize the requirements into simpler tasks, begin compliance early, and document their progress in compliance. An important first step is to evaluate current information and practices of the dental office.

Dentists should write a privacy policy for their office—a document for their patients that details the office's practices concerning PHI. The American Dental Association (ADA) HIPAA Privacy Kit includes forms that the dentist can use to customize his or her privacy policy. It is useful to try to understand the role of health care information for patients and the ways in which they deal with this information while visiting the dental office. Staff should be trained and familiar with the terms of HIPAA and the office's privacy policy and related forms. HIPAA requires a designated privacy officer—a person in the practice who is responsible for applying the new policies in the office, fielding complaints, and making choices involving the minimum necessary requirements. Another person in the role of contact person will process complaints.

A *Notice of Privacy Practices*—a document that details the patient’s rights and the dental office’s obligations concerning PHI—must be developed. The role of a third party with access to PHI must be clearly documented. This third party is known as a *business associate* and is defined as any entity who, on behalf of the health care provider, takes part in any activity that involves exposure of PHI. The HIPAA Privacy Kit provides a copy of the USDHHS “Business Associate Contract Terms”; this document provides a concrete format for detailing business associate interactions (Fig. 23.2).

The main HIPAA privacy compliance date, including all staff training, was April 14, 2003, although many covered entities who submitted a request and a compliance plan by October 15, 2002, were granted 1-year extensions. Local branches of the ADA may be contacted for details. It is recommended that dentists prepare their offices ahead of time for all deadlines, including preparation of privacy policies and forms, business associate contracts, and employee training sessions (Fig. 23.3).

For a comprehensive discussion of all terms and requirements, a complete list of HIPAA policies and procedures,

BUSINESS ASSOCIATE CONTRACT

This contract between the office of Dr. _____ (the *entity*) and _____ (the *business associate*) discloses the conditions to satisfactorily ensure compliance with the Privacy Rule of the Health Insurance Portability and Accountability Act (HIPAA).

During the contract period the business associate must observe the following responsibilities with respect to protected health information:

1. A business associate must limit requests for protected health information on behalf of the covered entity to that which is reasonably necessary to accomplish the intended purpose, a covered entity is permitted to reasonably rely on such requests from a business associate of another covered entity as the minimum necessary.
2. Make information available including information held by business associate as necessary to determine compliance by the covered entity.
3. Fulfill an individual’s rights to access and amend his or her protected health information contained in a designated record set, including information held by a business associate, if appropriate, and receive an accounting of disclosures by a business associate.
4. Mitigate, to the extent practicable, any harmful effect that is known to the covered entity of an impermissible use or disclosure of protected health information by its business associate.
5. A business associate cannot use protected health information for his or her own purposes. This includes, but is not limited to, selling protected health information to third parties for the third party’s own marketing activities, without authorization.
6. The covered entity is required to ensure, in whatever reasonable manner deemed effective by the covered entity, the appropriate cooperation by his or her business associate in meeting these requirements.
7. If the covered entity discovers a material breach of violation of the contract by the business associate, it will take reasonable steps to cure the breach or end the contract with the business associate. If termination is not feasible the covered entity will report the problem to the Department of Health and Human Services Office for Civil Rights.

• Fig. 23.2 Sample business associate contract for compliance with the Privacy Rule of the Health Insurance Portability and Accountability Act.

For the health professional, responsibility may be shared by clerical staff, surgical or other assistants, dental hygienists, laboratory technicians, and others. Various liability will be applied between employer doctors and employee doctors if the employee doctors are agents of the employer doctor within a practice.

Respondeat superior does not relieve the employee of responsibility for employee conduct; it simply enables a plaintiff to litigate against the employer.

An employer is not responsible for employee conduct that is not related to employment. What type of employee conduct is related to the job is an arguable proposition, as are most legal issues. For instance, the question of whether an employer is responsible for employee conduct outside the normal workplace is open to a case-by-case evaluation. Conduct during trips to and from the workplace may or may not be related to employment. For example, an employer probably would not be responsible for employee conduct when the employee is driving home from the place of employment. However, if the employer asked the employee to perform a task on the way home, responsibility for that employee conduct may attach. An employer generally is not responsible for statute violation or criminal conduct by employees.

An employer may not be responsible for an independent contractor. One test used to evaluate the relationship between an employer and another is to discern whether the employer has the authority to direct how a task is done, as opposed to simply requesting that a task be completed. For instance, a dentist may request that a plumber make repairs, but likely will not direct how the repairs are to be accomplished, so the plumber would likely be independent. The same dentist will request that a dental hygienist perform hygiene duties, but the dentist may choose to instruct how the duties will be performed, thus rendering the hygienist less independent.

With regard to the administration of local anesthesia, dentists and dental hygienists routinely accomplish this task. Generally speaking, and subject ultimately to state statutes, although a dental hygienist may be an independent contractor according to many elemental definitions, the dental hygienist generally is not an independent contractor with regard to the provision of health care services. This includes the administration of local anesthetics. Thus the employee dentist may be adjudicated responsible for any negligent conduct that causes damage to a patient during the course of hygiene treatment.

With regard to the degree of supervision, one must consult the state statutes. Often verbiage such as *direct* or *indirect* supervision is used, and understanding the definitions of these or other terms is paramount for both supervising and supervised health care providers.

Statutory Violations

Violation of a state or federal statute usually leads to an assumption of negligence, and/or criminality, if statute-related

damage to a patient occurs. In other words, the burden of proof now requires the defendant to prove affirmative defenses, showing that the statute violation was not such that it caused any damage claimed.

Two basic types of statutes exist: *malum in se* and *malum prohibitum*. *Malum in se* (“bad in fact”) statutes restrict behavior that in and of itself is recognized as harmful, such as driving while inebriated. *Malum prohibitum* (“defined as bad”) conduct in and of itself may not be criminal, reckless, wanton, etc., but is regulated simply to, for instance, promote social order. Driving at certain speeds is an example of a *malum prohibitum* statute. The difference between legally driving at 15 mph in a school zone and driving at 16 mph in a school zone is not the result of a criminal mind but is a social regulatory decision.

For instance, if one is speeding while driving, several sequelae may result when that statute violation is recognized. First, the speeder may simply be warned to stop speeding. Second, a citation may be issued and the speeder may have to appear in court, argue innocence, pay a fine if found guilty, attend traffic school, etc. Third, if the speeder’s conduct causes damage to others, additional civil or criminal sanctions may apply. Fourth, the situation may be compounded civilly or criminally if multiple statute violations are present, such as speeding and driving recklessly or driving while intoxicated.

Occasionally, statute violation is commendable. For instance, a driver may swerve to the “wrong” side of the centerline to avoid a child who suddenly runs into the street from between parked cars. At times, speeding may be considered a heroic act, such as when a driver is transporting a patient to a hospital during an emergency. However, even if the speeder has felt that he or she is contributing to the public welfare somehow, the statute violation is still subject to review.

For health professionals, for instance, administration of local anesthetic without a current health professional license or Drug Enforcement Agency certification is likely a violation of statute. If the type of harm sustained by the patient is the type that would have been prevented by the health professional obeying the statute, additional liability may attach to the defendant.

Conversely, an example of a beneficial statute violation occurred when a licensee did not fulfill mandatory basic life support (cardiopulmonary resuscitation) training but chose to complete advanced cardiac life support (ACLS) training instead. When admonished by the state board that a violation of statute had occurred, potentially putting the public at greater risk, the licensee pointed out to the regulatory board that ACLS certification is actually more beneficial to the public than basic life support certification. The licensing board then changed the statute to allow cardiopulmonary resuscitation or ACLS certification as a requirement to maintain a license.

Generally, employers are not responsible for statute violations of employees. An exception to this guideline is seen in the health professions. When employees engage in the

practice of dentistry or medicine, even without the knowledge or approval of the employer, both that employee and the employer may be held liable for damages. Employer sanctions may be magnified, such as loss of one's professional license, if an employee practices dentistry or medicine with employer knowledge.

Finally, at times some types of specific conduct are defined statutorily as malpractice per se. For instance, unintentionally leaving a foreign body in a patient after a procedure may be deemed malpractice per se. In these types of cases, theoretically simply the plaintiff's demonstration of the foreign body, via radiograph, a secondary procedure to remove the foreign body, etc. may be all that is required to establish malpractice.

Legal Considerations Relating to Local Anesthesia Administration

Third Parties

When any untoward reaction occurs, including during local anesthetic administration, the complication will be treated more ideally by a responsive team trained to handle such events rather than by the local anesthetic administrator alone.

Along with providing additional trained hands, third parties are witnesses and can testify to events leading up to, during, and after the event in question, and may prove invaluable in describing an event such as a psychogenic patient phenomenon.

Overdose

The term *local anesthesia* actually describes the desired effect of such a drug, not what actually occurs physiologically. Administration of a local anesthetic may or may not produce the desired depression of area nerve function, but it will definitely produce systemic effects. One must be prepared to articulate systemic considerations with regard to injection of these "local" agents.

The doses of local anesthetic drugs administered to patients are most properly given and recorded in milligrams, not in milliliters, carpules, cartridges, cubic centimeters, and so forth. The most standard limiting factor in the administration of certain doses of local anesthetics to a patient is the patient's weight. Other factors that need to be considered include medical history, particularly cardiovascular disease, and previous demonstration of allergy or sensitivity to normal dosing. The presence of acute or chronic infection and concomitant administration of other oral, parenteral, or inhaled agents may alter the textbook recommendations for local anesthetic doses. The reasonable practitioner needs to be able to readily determine the proper dosage levels to be administered to patients before the time of administration. At times, one local anesthetic formulation may be significantly more advantageous than another. The minimal amount of local anesthetic, and of

vasoconstrictor contained therein if applicable, needed to achieve operative anesthesia should be used. An inability to properly dose most patients leads to provision of health care below the standard of care.

An overdose may occur without health professional error, as in a previously undiagnosed hypersensitive patient, or in a patient who gives an incomplete medical history. Intra-vascular injection can occur even with judicious negative aspiration and following slow injection and may result in overdose.

Generally, the initial presentation of overdose is physiologic excitement, which is followed by depression. Depending on the timing of the diagnosis of overdose, the treatment protocol will differ. Rapid, accurate evaluation is very beneficial as opposed to a delayed diagnosis, and speaks favorably for the responsible health care provider. It is much more desirable to treat syncope secondary to overdose rather than cardiac arrest, which may follow inadequately treated syncope and respiratory arrest.

Adding to the diagnostic challenge is the fact that often more than one chemical is present within the local anesthetic solution that may cause overdose (e.g., lidocaine and epinephrine). The administrator must be cognizant of the latency and duration of different components of the local anesthetic solution.

However, no matter the particular manifestation or whether fault is or is not included in the origin of any case of overdose, the reasonable practitioner needs to be prepared to effectively handle the overdose. An inability to reasonably treat complications that are foreseeable, such as overdose, is a breach of duty.

If an overdose occurs, results can range from no damage whatsoever to death, and can often depend on the preparedness of the health practitioner for this foreseeable emergency.

Allergy

Related to overdose, but not a dose-dependent manifestation of local anesthetic administration, allergic reactions are foreseeable, although relatively rare, particularly for severe allergic responses such as anaphylaxis.

An accurate medical history is mandatory in minimizing the occurrence of allergy. Patients, in part because doctors do not take the time to explain the difference between allergy, overdose, and sensitivity, often list any adverse drug reaction as an "allergy." Inaccurate reporting of drug-related allergy by patients is not rare. In fact, more than half of patient-reported allergies are not allergies at all but are some other reaction that may not have even been drug related.

The duty of the health professional when administering local anesthetics includes avoiding known allergenic substances, including the local anesthetic in particular and any chemical additions to the local anesthetic solution. If an allergic reaction occurs, whether fault is present or not, the health care provider must be able to treat the drug-related allergy in a reasonable manner. Reasonable treatment may be the difference between resultant transient rhinorrhea versus death.

Instruments

Syringe **PDF Compressor Free Version**

A compromised syringe may still be usable in administering a local anesthetic. But if, for instance, the syringe cannot be controlled in a normal manner (e.g., secondary to an ill-fitting thumb ring), any damage resulting from such lack of control would be foreseeable and a breach of duty. A properly prepared and functioning syringe is mandatory for safe local anesthetic administration. Factors to be aware of in evaluating a syringe include all components of the syringe from the thumb ring, to the slide assembly, to the harpoon, to the threads that engage the needle, and so forth.

Local Anesthetic Cartridge

Originally, cartridges were much different than they are now. Problems that have been identified through the years include the fact that chemicals can leach from or into the solution within the cartridge, and that the contents are subject to extremes of heat or cold. Cartridges are now coated with a protective film, thus helping to prevent any shattered glass effect from cartridge fracture, which can occur even with normal injection pressures.

Local Anesthetic Needle

Disposable needles have been the norm for decades; although they avoid many problems formerly manifest with reusable needles, malfunction can still occur. Needle breakage can occur with or without fault from the administrator. Absent intentional bending and hubbing of the needle into loose mucosa, underlying muscle, and bone, needles still occasionally break for other reasons, as when a patient grabs the administrator's hand during an injection. Also, latent manufacturing defects will occasionally be noted during routine inspection of the needle before local anesthetic administration. In addition to needle barbs, the author has discarded preoperatively inspected needles with defects such as those seen in needles with patency in the needle shaft; needles that were partially or totally occluded; needles loose within the plastic hub; and needles with plastic hubs that did not effectively engage the metal threads of the syringe.

One type of needle-related complication is a plastic barb that may be present when one separates the plastic casings of the needle preparatory to threading the needle hub onto the syringe. Such a barb may be present at the point where the heat sear secures the two casings together. Those who prepare the needle/syringe delivery system need to be aware of this barb not only when separating the casings but also when recovering the needle after use.

Once again, broken needle instrument damage is foreseeable, as are other instrument failures. The prudent administrator will be prepared to deal with this complication and will prevent further morbidity by means such as using appropriate airway protection, not hubbing the needle, and having a prepared assistant who can pass a hemostat to the administrator in a fashion that does not require the administrator to take his or her eyes from the field. If a needle is

lost in tissue, protocols have been established for retrieval of such foreign bodies, and if the administrator is not comfortable with these procedures, an expeditious referral should be considered.

Contamination of the local anesthetic solution or delivery system (i.e., the needle) can certainly produce complications, and thus should be assiduously avoided. It would be reasonable to expect a practitioner to be able to intelligently describe in some detail, if called on to do so, the methods used to minimize any potential contamination. Limiting contamination has the added benefit of not compromising the health of the practitioner or any member of his or her team.

Any damage resulting from an unorthodox use of the syringe, needle, or cartridge may lead to an open argument that a breach of the standard of care and thus breach of duty had occurred.

Alternative Delivery Systems/Techniques

At times practitioners may elect to use alternative delivery systems or techniques, such as periodontal ligament, intraosseous, or extraoral injections via different armamentaria. The standard of care, which includes the reasoning that a practitioner will, all things considered, choose the best treatment for his or her patient, certainly includes these alternative local anesthetic delivery systems or techniques.

As with any other routine or less than routine clinical treatment plan, the practitioner should be able to intelligently articulate the reasoning for the decision. This is mandatory not only if a disgruntled patient seeks legal recourse, but also for nonlitigious patients who simply want to know why they have "never seen that before."

Although promotional materials from a drug or equipment manufacturer may be helpful to the clinician in identifying advantages of new drugs or equipment, it is incumbent on the health professional to make an independent and reasonable effort to identify potential disadvantages of new modalities.

Local Reactions to Local Anesthetic Administration

Topical or injected local anesthetics can cause reactions ranging from erythema to tissue sloughing in local areas secondary to several factors, including multiple needle penetrations, hydraulic pressure within the tissues, or a direct tissue reaction to the local anesthetic. Topical anesthetics in particular are generally more toxic to tissues than injected solutions, and doses must be carefully administered. For instance, the practice of letting the patient self-administer a prescription-strength topical anesthetic at home could certainly be criticized if an adverse reaction occurs.

Local tissue reactions may be immediate or delayed by hours or days; thus it is mandatory in this situation, as it is in others, for the patient to have access to a professional familiar with such issues, even during off hours. Simply

letting patients fend for themselves or advising them to go to the emergency department may not be the best option in providing optimal care.

Finally, one should be able to reasonably justify the use of topical anesthetics for intraoral injection purposes because some authors have opined that these relatively toxic agents are not objectively effective.

Lip Chewing

Local tissue maceration secondary to lip chewing most often occurs in children and special needs patients after an inferior alveolar nerve or other trigeminal nerve third division injection. Tissue maceration may also be seen in patients whose mental status has been compromised by sedatives, general anesthetics, or central nervous system trauma or during development. A prudent practitioner will advise any patient who may be prone to such an injury, and that patient's guardian, to be aware of the complication. If this complication is not prevented, it must be properly treated when diagnosed.

Subcutaneous Emphysema

Emphysema or air embolism can occur when air is introduced into tissue spaces. This complication is usually seen after incisions have been made through skin or mucosa, but it can also occur via needle tracts, particularly when gas-propelled pressure sprays, pneumatic handpieces, and so forth are used near the needle tract. The sequelae of air embolism is usually fairly benign although disconcerting to the patient. An unrecognized and progressive embolism can be life threatening. When a progressive embolism is diagnosed, the practitioner will not be criticized for summoning paramedics and for accompanying the patient to the hospital.

Vascular Penetration

Even with the most careful technique, excessive bleeding can occur when vessels are partially torn by needles. The fact that aspirating syringes are used reveals that placing needles into soft tissues is indeed a blind procedure. At times, the goal of an injection is intravenous or intra-arterial injection. This is not typically the case with the use of local anesthetics for pain control, and a positive aspiration necessitates that additional measures be taken for a safe injection. The prepared health professional should be able to articulate exactly what the goal of administration of a local anesthetic is, and how that is technically accomplished. For instance, why a particular anesthetic and needle were chosen, what structures might be encountered by the needle during administration of a nerve block, and what measures are taken if a structure is inadvertently compromised by a needle. Even with optimal preparation, vascular compromise can result in tumescence, ecchymosis, or overt hemorrhage that may need to be addressed. These conditions can be magnified by bleeding dyscrasia. The patient's medical history may

reveal certain prescriptions that may alter bleeding time, which may indicate the need for preoperative hematologic consultation.

Neural Penetration

Just as a rich complex of vessels is present in the head and neck area, so it is with nerves. Neural anatomy can differ considerably from the norm, and penetration of a nerve by a needle can occur on rare occasions, even in the most careful and practiced hands. Permanent changes in neural function can result from a single needlestick; although this complication does not necessarily imply a deviation from the standard of care, the practitioner must be prepared to treat the complication as optimally as possible.

Lingual nerve injury is an event that has been zealously contested in the courts in recent years. Typically, rare instances of loss or change in lingual nerve function have occurred during mandibular third molar surgery. Some plaintiff experts readily opine that but for negligence (i.e., malpractice) this injury will not occur, period. In these experts' opinions, lingual nerves are damaged only secondary to unintentional manipulation with a surgical blade, periosteal elevator, burr, and so forth, when the operator is working in an anatomic area that should have been avoided. In spite of the fact that defense experts routinely counter these plaintiff opinions, occasionally juries will rule for the plaintiff, and lingual nerve awards have exceeded \$1,000,000.

Although lingual nerve injury occasionally happens secondary to unintentional instrument contact with an unintended anatomic structure, it is more likely that the injury results secondary to other means. For instance, lingual nerve anatomy has been shown to be widely variant from the average position lingual to the lingual plate in the third molar area. Lingual nerve position has been shown to range from within unattached mucosal tissue low on the lingual aspect of the lingual plate, to firmly adherent within lingual periosteum high on the lingual plate, to within soft tissues over the buccal cusps of impacted third molars.

Permanent lingual nerve injury also occurs in the absence of third molar surgery and secondary to local anesthetic administration during inferior alveolar/lingual nerve blocks. Lingual nerve injury can result from pressure placed on the nerve during operative procedures (e.g., with lingual retractors).

A higher incidence of lingual nerve injury has been noted with certain local anesthetic solution formulations over others. The practitioner whose patient develops paresthesia after routine use of, for instance, 4% local anesthetic solutions instead of 2% solutions must be prepared to explain such a decision. Practitioners occasionally use solutions that are more concentrated, yet the efficacy of such solutions remains similar to the less concentrated option. Obviously, the suggestion here is that no treatment should be routine; rather, treatment should be planned on a patient-by-patient basis after a thoughtful risk-benefit analysis has been performed.

Finally, lingual nerve injury can occur when no health care professional treatment whatsoever is provided. Paresthesia can occur with compression, and a chief complaint of anesthesia can occur spontaneously. Both of these conditions may be rectified by dealing with the disorder associated with the change in function, such as by removing impacted third molars or freeing the lingual nerve from an injury-susceptible position within the periosteum.

However, no matter what the cause, the prudent administrator will be prepared to address neural injury effectively when it occurs.

Chemical Nerve Injury

It is not surprising that potent chemicals such as local anesthetics occasionally will compromise nerve function to a greater degree than they are designed to do. Local anesthetics, after all, are specifically formulated in an effort to alter nerve function, albeit reversibly. Just as systemic toxicity differs from local anesthetic to local anesthetic, so limited nerve/local toxicity at times may alter nerve function in a way that is not typically seen. Deposition of local anesthetic solutions directly on a nerve trunk or too near a nerve trunk in a susceptible patient may result in long-term or permanent paresthesia. Local anesthetic toxicity generally increases as potency increases. In addition, nontargeted nerves in the head and neck may be affected by local anesthetic deposition, as when transient amaurosis occurs after maxillary or mandibular nerve block when the optic nerve is affected. One should not be particularly surprised at the various neural manifestations of these potent agents given that toxic overdose is actually a compromise of higher neural functions. Anyone who chooses to use agents designed to relieve pain directly on or near nerve tissue must be prepared for even the rare complications seen. Adequate treatment may range from reassuring a patient who has transient amaurosis to treating or referring for treatment a patient with permanent anesthesia resulting from an adverse chemical compromise of the nerve caused by the local anesthetic solution or other agents.

Local Anesthetic Drug Interaction

Use of other local or systemic agents certainly will predictably affect and alter the latency, effect, duration, and overall metabolism of local anesthetics. Modern polypharmacy usually complicates the situation. However, the health care professional must be aware of specific well-known drug interactions, in addition to the pharmacology of common drug classes. Oral contraceptives, β -blockers, calcium channel blockers, angiotensin-converting enzyme inhibitors, other cardiovascular prescriptions, such as antihypertensives and anticoagulants, thyroid medications, antihistamines, antibiotics, anabolic steroids or corticosteroids, psychogenic medications, and various street drugs, may be considered common to the routine dental population.

Drugs interact with various receptor sites; drug therapy is based on potentiation or inhibition of normal physiologic responses to stimuli. Ideally, with local anesthetic, no unwanted systemic reactions occur, and local nerve tissues are reversibly inhibited for a relatively brief time, after which the tissues regain full function. Concomitant use of other agents can change the usually predictable course of a local anesthetic and vice versa.

For instance, the commonly used β -blocker propranolol has been shown to create a chemically induced decrease in liver function, specifically, hepatic blood flow, which can decrease lidocaine metabolism by as much as 40%. Long-term alcohol use induces enzymes dramatically. Methemoglobinemia has been reported to result from the use of topical local anesthetics and over-the-counter Anbesol.

Therapeutic areas of special concern arise in patients who are obviously ill, who report a significant medical history, who report significant drug use (whether prescribed, over-the-counter, or herbal drugs), and who are at the extremes of age. The incidence of adverse local anesthetic drug interaction increases with patients who report risk factors, particularly cardiovascular risk factors, as opposed to the general population. Before the time of treatment, clinicians should acquire the knowledge needed to optimally treat such patients with increased potential for adverse drug reactions.

Psychogenic Reactions

At times the practitioner may have to deal with psychogenic reactions ranging from mild to severe in presentation. For instance, the initial manifestation of a toxic overdose, whether noted or not, is excitement. Excitement may also occur secondary to nothing other than stress resulting from a situation in which the patient is not comfortable. Excitement may be manifested, for instance, by controlled or uncontrolled agitation, disorientation, hallucination, or somnolence.

Such reactions may be potentiated by pharmaceuticals administered during the appointment by the health professional, or by authorized or unauthorized agents taken by the patient before an appointment. The incidence of such reactions is increased with increased use of pharmaceuticals, particularly those that may affect the central nervous system, such as local anesthetics. These reactions can occur in children, adolescents, and adults (including elderly persons).

Psychogenic reactions are often frustrating to diagnose and treat. It may be difficult to determine whether the reaction is occurring secondary to an administered drug, including local anesthesia, or as the result of other causes.

Treatment may require restraint if the patient is in danger of inflicting harm on himself or herself, as might be seen in an epileptic seizure. Fortunately, most of these reactions are short term (i.e., often lasting only moments). However, occasionally, they may occur regularly over long periods. Some, such as hysterical conversion manifest by unresponsiveness, may require hospitalization.

Although many practitioners may diagnose such an event, prudence requires that one be aware of the cause and treatment of such reactions. If such reactions are handled appropriately, patients may assume that the health care professional “did something wrong” and may seek the advice of an attorney.

Eroticism

A singularly troublesome psychogenic reaction to potent agents is observed in which the patient reacts with sexual affections that may or may not be recalled at a later time. Historically, such reactions were fairly common during administration of cocaine solutions. Generally speaking, these reactions appear to be rare and are usually of relatively short duration. However, as with other psychogenic or hysterical phenomena, rapid diagnosis and treatment is optimal.

Although concomitant use of agents such as nitrous oxide or the administration of minor tranquilizers may be of general benefit during administration of local anesthesia, these and many other agents have been reported to produce erotic hallucinations or behaviors in patients so predisposed.

In the case of eroticism, the practitioner who has administered local anesthetic or other agents without a neutral third party present when such reactions occur will have more difficulty exonerating conduct than the practitioner who had witnesses to the reaction. In addition, with regard to eroticism, it has historically been more optimal to have witnesses of the same sex as the patient.

Occasionally, a patient may request to speak with or be treated privately by the health practitioner. Absent unusual circumstances, such as treating a close relative, practitioners may want to consider avoidance of situations such as treating an emergency patient alone after hours, or even speaking to a patient behind closed doors.

Postprocedure Evaluation

Any time that potent agents are used, an evaluation of the patient is necessary. This evaluation consists of at least a preoperative assessment, continuous examination during treatment when the drugs used are at peak effect, and a postoperative appraisal.

Although most adverse reactions to local anesthetics occur rapidly, delayed sequelae are possible. Just as patients who have been given agents by intravenous, inhalation, oral, or other routes are evaluated after the procedure, so too should patients who have been given local anesthetics. Any question about a less than optimal recovery from local anesthesia should be addressed before the patient is released from direct care.

For instance, it is widely accepted that patients may drive after administration of local anesthesia for dental purposes. Occasionally, a postprocedure concern that may arise secondary to local anesthesia and/or other procedures may dictate that a patient who was not accompanied may need to obtain assistance before leaving the place of treatment. Patients

whose employment requires higher than normal mental or physical performance may be cautioned about the potential effects of local anesthetic administration. As an example, US Air Force and US Navy pilots are restricted from flying for 24 hours after local anesthetic administration.

Some practitioners routinely call each patient after release and several hours after treatment has been terminated to ensure that recovery is uneventful. Such calls are usually welcomed by patients as a sign that their health care provider is truly concerned about his or her welfare. Occasionally, the practitioner's call may enable one to address a developing concern or an objective complication early on.

If Malpractice Exists

Although attorneys and doctors do not always agree on when all the elements of malpractice are present, occasionally the health professional may feel that he or she has made a mistake that has damaged a patient. As can be easily and successfully argued, simply the fact that a patient has damage, even significant damage, does not fulfill all requirements of the tort of malpractice.

If, however, the practitioner determines that a duty existed, the duty was breached, and breach was the proximate cause of damage, it is likely that malpractice has occurred. In this instance, the health professional is likely ethically, if not yet legally, responsible for making the patient “whole.” If the damage is minimal (e.g., transient ecchymoses), nominal recompense, perhaps even a judicious apology, may be all that is required. If, however, the damage is significant, significant recompense may be required.

Certainly, any significant damage whatsoever from malpractice requires that the health professional contact his or her liability carrier as soon as possible. The same holds true, even if damage is not evident, when the health care professional receives notice of patient dissatisfaction, often in the form of a request for records. The liability insurance carrier's representative will help evaluate the situation and will provide valuable insight from a significant experience pool. In all likelihood the carrier will be more successful in negotiating a settlement to any case that is controversial as far as damages are concerned. The practitioner should be very cautious about undertaking any such negotiations without his or her carrier's input. Such unauthorized negotiations, or similar conduct, such as not informing the carrier about a potential complaint in a timely fashion, may even cause liability coverage to become the practitioner's sole responsibility. At times, if the practitioner and the patient still have a good working relationship, the carrier will allow the practitioner to negotiate a reasonable settlement. This course of action is advantageous in that the patient receives immediate financial aid that may be necessary for additional expenses or time off work. In addition, the plaintiff patient will not be required to overcome the assumption that the health care provider acted reasonably and to prove malpractice, which may be very difficult.

No matter whether the damage is secondary to negligence, the practitioner must try to treat the patient optimally. It is hoped that the patient will not immediately seek treatment elsewhere because this course of action may simply prolong recovery and aggravate future legal considerations. One near universal finding in filed and served malpractice actions is criticism, usually unwarranted, by a nontreating health professional. If, on the other hand, referral would be beneficial, the practitioner should facilitate that referral for the patient and not just send the patient out to fend alone. After a referral is made, continued care as needed for the patient is advisable if possible.

Once legal action has been initiated, it may be wise to refuse further treatment for the patient because the patient has now effectively expressed the opinion that the practitioner's conduct was below the level of the standard of care and has resulted in damage. It is an unfortunate circumstance when a plaintiff patient realizes that the perceived malpractice did not exist and is unable to continue care with the health professional most familiar with the intricacies of that patient's individual circumstances.

Many patients shortsightedly and unintentionally limit their health care options by pursuing malpractice actions. Most malpractice cases take years to resolve and involve great expense for both the defendant and the plaintiff. Ultimately, a vast majority of alleged malpractice claims result in adjudication in favor of the defendant doctor. No matter who prevails in a malpractice claim, for both the defendant and the plaintiff the victory is often Pyrrhic when the temporal, social, and economic costs are factored in.

Conclusion

The administration of local anesthetics may undergo change with time secondary to new drugs, new instrumentation, and new knowledge bases. The law is even more subject to variation, often with each session of a legislative body or secondary to a significant court case. For instance, the philosophy of detailed versus general informed consent has undergone several permutations over the years. The decision of one court in a contractual, criminal, or civil tort proceeding may be appealed by the losing party and eventually reversed by another court secondary to a new fact pattern or simply as the result of reevaluation of the same fact pattern under different legal formulae.

However, one thing that never changes is that reasonable and responsible health care practitioners will continue to be informed as to the current standard of care and will attempt to optimize their decision making and treatment planning for patients on an individual basis after a realistic risk versus benefit analysis. The opinions given in this chapter and in this book are meant as guidelines and may be subject to modification on an individual patient treatment basis by knowledgeable practitioners and informed patients.

Selected Bibliography

- Arroliga ME, Wagner W, Bobek MB, et al. A pilot study of penicillin skin testing in patients with a history of penicillin allergy admitted to a medical ICU. *Chest*. 2000;118:1106–1108.
- Associated Press. *Jury Acquits Pasadena Dentist of 60 Child Endangering Charges*; 2002.
- Bax NDS, Tucker GT, Lennard MS, et al. The impairment of lignocaine clearance by propranolol: major contribution from enzyme inhibition. *Br J Clin Pharm*. 1985;19:597–603.
- Burkhart CG, Burkhart KM, Burkhart AK. The Physicians' Desk Reference should not be held as a legal standard of medical care. *Arch Pediatr Adolesc Med*. 1998;152:609–610.
- Cohen JS. Adverse drug effects, compliance, and initial doses of antihypertensive drugs recommended by the joint national committee vs the physicians' desk reference. *Arch Intern Med*. 2001;161:880–885.
- Cohen JS. Dose discrepancies between the Physicians' Desk Reference and the medical literature, and their possible role in the high incidence of dose-related adverse drug events. *Arch Intern Med*. 2001;161:957–964.
- College C, Feigal R, Wandera A, et al. Bilateral versus unilateral mandibular block anesthesia in a pediatric population. *Pediatr Dent*. 2000;22:453–457.
- Covino BG, Vassallo HG. *Local Anesthetics Mechanisms of Action and Clinical Use*. New York: Grune & Stratton; 1976.
- Daublander M, Muller R, Lipp MD. The incidence of complications associated with local anesthesia in dentistry. *Anesth Prog*. 1997;44:132–141.
- Dyer C. Junior doctor is cleared of manslaughter after feeding tube error. *BMJ*. 2003;325:414.
- Evans IL, Sayers MS, Gibbons AJ, et al. Can warfarin be continued during dental extraction? Results of a randomized controlled trial. *Br J Oral Maxillofac Surg*. 2002;40:248–252.
- Faria MA. *Vandals at the Gates of Medicine*. Macon: Hacienda Publishing; 1994.
- Fischer G, Reithmuller RH. *Local Anesthesia in Dentistry*. 2nd ed. Philadelphia: Lea & Febiger; 1914.
- Gill CJ, Orr DL. A double-blind crossover comparison of topical anesthetics. *J Am Dent Assoc*. 1979;98:213–214.
- Gilman CS, Veser FH, Randall D. Methemoglobinemia from a topical oral anesthetic. *Acad Emerg Med*. 1997;4:1011–1013.
- Goldenberg AS. Transient diplopia as a result of block injections: mandibular and posterior superior alveolar. *N Y State Dent J*. 1997;63:29–31.
- Kern S. Saying I'm sorry may make you sorry. *NV Dent Assoc J*. 2010–2011;12:18–19. Winter.
- Lang MS, Waite PD. Bilateral lingual nerve injury after laryngoscopy for intubation. *J Oral Maxillofac Surg*. 2001;59:1497–1498.
- Lee TH. By the way, doctor...My hair has been thinning out for the past decade or so, but since my doctor started me on Lipitor (atorvastatin) a few months ago for high cholesterol, I swear it's been falling out much faster. My doctor discounts the possibility, but I looked in the Physicians' Desk Reference (PDR) and alopecia is listed under "adverse reactions." What do you think? *Harv Health Lett*. 2000;25(8).
- Lustig JP, Zusman SP. Immediate complications of local anesthetic administered to 1,007 consecutive patients. *J Am Dent Assoc*. 1999;130:496–499.
- Lydiatt DD. Litigation and the lingual nerve. *J Oral Maxillofac Surg*. 2003;61:197–199.
- Malamed SF. *Handbook of Local Anesthesia*. 4th ed. St Louis: Mosby; 1997.

- Malamed SF, Gagnon S, Leblanc D. Efficacy of articaine: a new amide local anesthetic. *J Am Dent Assoc.* 2000;131:635–642.
- Meechan JG. Introral topical anesthetics: a review. *J Dent.* 2000;28:3–14.
- Meechan JG, Cole B, Welbury RR. The influence of two different dental local anaesthetic solutions on the haemodynamic responses of children undergoing restorative dentistry: a randomised, single-blind, split-mouth study. *Br Dent J.* 2001;190:502–504.
- Meyer FU. Complications of local dental anesthesia and anatomical causes. *Anat Anz.* 1999;181:105–106.
- Moore PA. Adverse drug interactions in dental practice: interactions associated with local anesthetics, sedatives, and anxiolytics. Part IV of a series. *J Am Dent Assoc.* 1999;130:541–554.
- Mullen WH, Anderson IB, Kim SY, et al. Incorrect overdose management advice in the physicians' desk reference. *Ann Emerg Med.* 1997;29:255–261.
- Olson WK. *The Litigation Explosion, What Happened when America Unleashed the Lawsuit.* New York: Penguin Books; 1991.
- Orr DL. Airway, airway, airway. *NV Dent Assoc J.* 2008;9:4–6.
- Orr DL. The broken needle: report of case. *J Am Dent Assoc.* 1983;107:603–604.
- Orr DL. Conversion part I. *Pract Rev Oral Maxillofac Surg.* 1994;8(7) [audiocassette].
- Orr DL. Conversion part II. *Pract Rev Oral Maxillofac Surg.* 1994;8(8) [audiocassette].
- Orr DL. Conversion phenomenon following general anesthesia. *J Oral Maxillofac Surg.* 1985;43:817–819.
- Orr DL. Intraseptal anesthesia. *Compend Cont Educ Dent.* 1987;8:312.
- Orr DL. Is there a duty to rescue? *NV Dent Assoc J.* 2010;12:14–15.
- Orr DL. It's not Novocain, it's not an allergy, and it's not an emergency!. *NV Dent Assoc J.* 2009;11(3).
- Orr DL. Medical malpractice. *Pract Rev Oral Maxillofac Surg.* 1988;3(4) [audiocassette].
- Orr DL. Paresthesia of the second division of the trigeminal nerve secondary to endodontic manipulation with N₂. *J Headache.* 1987;27:21–22.
- Orr DL. Paresthesia of the trigeminal nerve secondary to endodontic manipulation with N₂. *J Headache.* 1985;25:334–336.
- Orr DL. PDL injections. *J Am Dent Assoc.* 1987;114:578.
- Orr DL. Pericardial and subcutaneous air after maxillary surgery. *Anesth Analg.* 1987;66:921.
- Orr DL. A plea for collegiality. *J Oral Maxillofac Surg.* 2006;64:1086–1092.
- Orr DL. Protection of the lingual nerve. *Br J Oral Maxillofac Surg.* 1998;36:158.
- Orr DL. Reduction of ketamine induced emergence phenomena. *J Oral Maxillofac Surg.* 1983;41(1).
- Orr DL. Responsibility for dental emergencies. *NV Dent Assoc J.* 2008;10:34.
- Orr DL, Curtis W. Frequency of provision of informed consent for the administration of local anesthesia in dentistry. *J Am Dent Assoc.* 2005;136:1568–1571.
- Orr DL, Park JH. Another eye protection option. *Anesth Analg.* 2011;112:739–740.
- Orr TM, Orr DL. Methemoglobinemia secondary to over the counter anbesol. *Oral Surg Oral Med Oral Pathol Oral Radiol Endod.* 2011;111:e7–e11.
- Penarrocha-Diago M, Sanchis-Bielsa JM. Ophthalmologic complications after intraoral local anesthesia with articaine. *Oral Surg Oral Med Oral Pathol Oral Radiol Endod.* 2009;90:21–24.
- Pogrel MA, Schmidt BL, Sambajon V, et al. Lingual nerve damage due to inferior alveolar nerve blocks: a possible explanation. *J Am Dent Assoc.* 2003;134:195–199.
- Pogrel MA, Thamby S. Permanent nerve involvement resulting from inferior alveolar nerve blocks. *J Am Dent Assoc.* 2000;131:901–907.
- Rawson RD, Orr DL. *A Scientific Approach to Pain Control.* University Press: Las Vegas, NV; 2000.
- Rawson RD, Orr DL. Vascular penetration following intraligamental injection. *J Oral Maxillofac Surg.* 1985;43:600–604.
- Rosenberg M, Orr DL, Starley E, et al. Student-to-student local anesthesia injections in dental education: moral, ethical, and legal issues. *J Dent Educ.* 2009;75:127–132.
- Sawyer RJ, von Schroeder H. Temporary bilateral blindness after acute lidocaine toxicity. *Anesth Analg.* 2002;95:224–226.
- Webber B, Orlansky H, Lipton C, et al. Complications of an intra-arterial injection from an inferior alveolar nerve block. *J Am Dent Assoc.* 2001;132:1702–1704.
- Wilkie GJ. Temporary uniocular blindness and ophthalmoplegia associated with a mandibular block injection: a case report. *Aust Dent J.* 2000;45:131–133.
- Younessi OJ, Punnia-Moorthy A. Cardiovascular effects of bupivacaine and the role of this agent in preemptive dental analgesia. *Anesth Prog.* 1999;46:56–62.

A

- Abducens nerve (CN VI), 188t
- Abscesses
causes of, 49f
sterile, 325
- Absolute refractory period, 8
- Absorption of local anesthetics. *See also*
Systemic complications
distribution pattern after, 29f
elimination after, 29f
half-life, 29, 30t
lidocaine, 79
overdoses due to rapid absorption,
335–336
through oral mucous membranes,
334
uptake, 27–29, 28t
distribution, 29, 29t
injection, 28
oral route, 27, 28f
topical route, 27–28
- Accessory innervation, 409
- Acetylcholine theory, 11–12
- ACLS. *See* Advanced cardiac life support
- Acquired methemoglobinemia, 169
- Actions of local anesthetics
concept behind, 3
convulsive stage, 34, 35f
desirable/undesirable, 330
direct cardiac action, 36, 36t
effect of decreased tissue pH on, 18f
factors affecting, 24t
final stage, 36f
onset of action, 17t
preconvulsive stage, 35f
systemic, 31–39
termination of, 27
- Active aspiration, 130–132, 131f
- Active forms of local anesthetics,
14–19
actions on nerve membranes,
17–18, 17f
dissociation of local anesthetics, 15–17,
16f, 17t
local anesthetic molecules, 14–15,
15f–16f
pH and local anesthesia activity, 18–19
- ADA. *See* American Dental Association
- Administration of local anesthetics
accuracy of, 58, 101
to all four quadrants, 339t
by hygienists, 304
intravascular, 86
position of administrator
buccal nerve block, 248f
inferior alveolar nerve block (IANB),
243f
mental (incisive) nerve block,
260f
readministration, 24–25
difficulty reachieving profound
anesthesia, 25
recurrence of immediate profound
anesthesia, 24
of third molars, for removal, 340t
volume administered, 339
- Administrator, position of
for anterior superior alveolar nerve block,
214f
for middle superior alveolar nerve block,
212f
for nasopalatine nerve block, 222f
- Adolescents. *See also* Pediatric dentistry
NSAID dosages for, 303t
phenolamine mesylate in
clinical trials of, 381
efficacy of, 381–382
safety of, 382
- Adrenal squeeze, 147
- Adrenaline, allergy to, 147
- Adrenergic neuronal blocker, vasoconstrictor
with, 165–166
- Adrenergic receptors, 42
- α -Adrenoceptor blocker, vasoconstrictor
with, 165
- ADRs. *See* Adverse drug reactions
- Adult health history questionnaire,
136f
- Adults, phenolamine mesylate in
clinical trials of, 381
efficacy of, 381–382
safety of, 382
- Advanced cardiac life support (ACLS),
certification of, 419
- Adverse drug reactions (ADRs), 146. *See also*
Allergic reactions/sensitivity; Drug
interactions; Systemic complications
causes of, 331b
classification of, 330–331
- Adverse Event Reporting System (AERS),
313–314
- Adverse reaction, of local anesthetics, 403
- Advil, 303t
- AERS. *See* Adverse Event Reporting System
- Agency for Healthcare Research and Quality,
47
- AIDS, history of, 147
- Air embolism, 422
- Akinosi mandibular blocks, 104
- Albuterol inhalers, 356f
- Alcohol, use of, history of, 151
- Aleve, 303t
- Allergic reactions/sensitivity, 331
to amides, 64
clinical manifestations of, 353–354
confirmed, 353
consultations and allergy testing, 352–353
dental management in presence of
elective dental care, 353
emergency dental care, 353
dermal, 348t
dialogue history of, 350–352
epinephrine, 349
generalized anaphylaxis for, 357–358
incidence of, 347
latex, 349
management of, 354–358
bronchodilators (albuterol), 356f
generalized anaphylaxis, 357–358
no signs of allergy present, 358
respiratory reactions, 355–356
skin reactions, 354–355
medical alert bracelets, 351f
medical history questionnaire of, 349
mepivacaine, 67
overdose *vs.*, 331t
predisposing factors of, 347–349
prevention of, 349–352
procaine, 63
questions for evaluation of history of,
349–352

- Allergic reactions/sensitivity (*Continued*)
 signs/symptoms of, 354
 by classification of, 348c
 dermatologic reactions, 354
 generalized anaphylaxis, 354, 355b
 respiratory reactions, 354
 sodium bisulfite, 349
 testing for, 352–353
 time of onset of symptoms of, 354
 topical anesthetic, 349
- Allergy
 angioneurotic edema and, 324
 articaine and, 371
 to bisulfites, 114
 edema and, 324
 epinephrine, 54
 history of, 146–147
 latex, 113
 legal considerations of, 420
 patient claim of, 403
- Alpha (α) adrenergic receptors, 42, 45
 in epinephrine, 53
- Aluminum cap, in cartridge, 112
- American Dental Association (ADA)
 color-coding of local anesthetic cartridges,
 111, 112t
 HIPAA Privacy Kit, 416
 syringe criteria, 86
- American Society of Anesthesiologists
 (ASA), Physical Status Classification
 System, 47–48, 66, 161–163, 162f
 ASA class 1, 161
 ASA class 2, 161
 ASA class 3, 161–162
 ASA class 4, 162–163, 405
 ASA class 5, 163, 164t
- Amide local anesthetics, 30–31, 31t, 32f–33f
 with inhibitors of metabolism, 163
- Amide-type local anesthetics, 15, 15f,
 22t–23t
 biotransformation of, 334
 duration of, 63–75
 hypersensitivity to, 347
 overdose of topical, 336
 preference for, 81
- Amines, sympathomimetic, 42b
- Anaphylaxis, 147
- Anaprox, 303t
- Anatomic considerations, 186–203
 anterior superior alveolar (ASA) nerve,
 196f
 bifid mandibular canals, 199f
 blood and nerve supply to hard and soft
 palate, 195f
 cranial fossa, 191f
 cranial nerves, 188t, 189f–190f
 cutaneous nerves of face, 193f
 hard palate, 201f
 mandible, 202–203, 202f
 mandibular nerve
 branches of, 197f
 pathway of, 197f
- Anatomic considerations (*Continued*)
 maxilla, 200–202
 inferotemporal aspect of, 201f
 maxillary nerve, 194f
 nasal wall and pterygopalatine canal, 195f
 orbit, 193f
 skull, 191f, 200f
 trigeminal nerve, 186–200
 mandibular division (V_3), 196–200
 maxillary division (V_2), 188
 motor root, 186, 192f
 pathway of, 187f
 sensory root, 186–200
- Anatomy
 of cerebral circulation, 337f
 facial nerve distribution, 315f
 neural, 422
 variations in, 58–59, 62
- Anemia, history of, 147
- Aneroid manometers, 153
- Anesthetic
 techniques, maxillary teeth and available
 local, 237t
 topical, armamentarium in, 121–122,
 122f
- Angina, history of, 141
- Angioedema, hereditary, 324
- Anterior division, branches from, 198
- Anterior middle superior alveolar nerve
 block, 227–230
 advantages of, 229
 alternatives of, 229
 anatomy of, 228f
 areas anesthetized, 228, 228f
 common name, 228
 complications of, 230
 contraindications to, 229
 disadvantages of, 229
 failure of, 230
 indications, 229
 location of injection site for, 227f
 nerves anesthetized, 228
 positive aspiration, 229
 precautions for, 230–237
 prepuncture technique, 229f
 safety features for, 230
 sequential palatal infiltrations, 227f
 signs and symptoms of, 230
 technique, 229–230, 230f
- Anterior superior alveolar injection, palatal
 approach, 231
 advantages, 231–232
 alternatives for, 232
 areas anesthetized, 231–233, 231f
 common names, 231
 complications of, 233
 contraindications, 231
 disadvantages, 232
 failure of, 233
 indications, 231
 needle insertion, area of, 232f
 nerves anesthetized, 231
- Anterior superior alveolar injection, palatal
 approach (*Continued*)
 positive aspiration, 232
 precautions of, 233
 safety features of, 233
 signs and symptoms, 233
 syringe, orientation of, 232, 233f
 technique, 232–233
- Anterior superior alveolar nerve block, 104,
 193, 196f, 213–216
 advantages of, 213, 229
 alternatives for, 214
 areas anesthetized, 213, 213f
 common name, 213
 complications of, 216
 contraindications to, 213
 disadvantages of, 214
 failures of, 216
 indications for, 213
 needle
 advancement of, 215f
 insertion of, 215f
 needle tip, position of, 216f
 nerve anesthetized, 213
 palpation of infraorbital notch, 215f
 positive aspiration, 214
 rate of, 336t
 precautions for, 216
 safety features of, 216
 signs and symptoms for, 216
 technique for, 214–216, 215f
- Anterior superior alveolar (infraorbital)
 nerve block, for hematoma, 322
- Antibiotic prophylaxis, 145t
- Antioxidant, in cartridge, 114
- Antipsychotic, vasoconstrictor with, 165
- Antirust tablets, 117
- Antiseptic, topical, armamentarium
 in, 121
- Antiviral agents, 326
- Anxiety, pain on injection and, 323
- Aphthous stomatitis, 326, 326f
- Applicator sticks, 122, 122f
- Armamentarium
 additional, 121–124
 applicator sticks in, 122, 122f
 cotton gauze in, 122–123, 123f
 hemostat in, 123, 123f
 needle-recapping device in, 123, 124f
 topical anesthetic in, 121–122, 122f
 topical antiseptic in, 121
 preparation of, 125–132
 aspiration, 130–132
 active, 130–132, 131f
 passive, 130, 131f
 breech-loading, metallic or plastic,
 cartridge-type syringe in,
 125–128, 125f–127f
 recapping the needle in, 127, 128f
 unloading, 128, 129f–130f
 cartridge, in (traditional) syringe,
 placing, 128

- Armamentarium (*Continued*)
 self-aspirating syringe in, 128
 Ultra Safety Plus XL Safety Syringe in, 128–132, 130f
- Arteries, hardening of, history of, 145
- Arthritis, history of, 147
- Articaine, 13t, 16f, 22t–23t
 allergy and, 371
 buffered, buccal infiltration of, 291
 chemistry of, 370–371, 370f
 clinical characteristics of, 371
 by mandibular infiltration in adults, 372, 372t, 373f–374f
 maximum recommended doses of, 295t, 335t
 more effective local anesthetic, 378–379
 overdose reactions of, 340t
 paresthesia and, 314, 374–376, 376t
 pharmacokinetics of, 370–371
 risk of nerve damage with, 404
 in special patient populations, 372–374
 children, 373–374
 nursing mothers, 373
 pregnant women, 372–373
- Articaine hydrochloride (HCl), 57, 58t, 72t, 73f–74f, 290, 369–379, 370f, 370t
 4% with epinephrine, 73t, 80t
 anesthetic half-life, 72
 calculation of milligrams per dental cartridge, 60t
 chemical formula, 71, 71f
 classification of, 71
 duration of anesthesia, 71–74
 effective dental concentration, 72
 excretion of, 72
 FDA approval of, 72
 introduction of, 72
 maximum recommended dose, 60t, 61b–62b, 72
 metabolism of, 72
 onset of action, 72
 pH of plain solution, 72
 pH of vasoconstrictor-containing solution, 72
 pK_a, 72
 potency of, 72
 pregnancy classification of, 72
 prepared by, 72
 proprietary names, 81t
 safety during lactation, 72
 topical anesthetic action, 72
 toxicity of, 72
 vasodilating properties of, 72
 what should you do, 379
- Artificial joint, history of, 150, 150t
- ASA. *See* American Society of Anesthesiologists
- Aspirating syringes, 90f
 harpoon devices, 86
- Aspiration, 130–132, 181–182, 181f–182f, 406
 at the time of, 130–132, 131f
 disengagement of harpoon from plunger during, 96
 gauge size and, 101
 harpoon-aspirating syringes, 181
 passive, 130, 131f
 percentage of dentists who aspirate before injection, 88t
- Asthma, history of, 146
- Atrial fibrillation, irregular irregularity of, 157
- Atypical plasma cholinesterase, 168–169
- Auditory feedback, 274
- Auditory (vestibulocochlear) nerve (CN VIII), 188t
- Auriculotemporal nerve, 198
- Auscultatory gap, 154, 154f
- Autoclaving, in cartridge, 114
- Availability of local anesthetics in North America, 58t
 lidocaine, 64
 procaine HCl + propoxycaine HCl, 63
- Available drugs in the United States, efficacy of, 302t
- Axon
 depolarization, 10f
 description of, 3–6
 structure of, 6f
- Axoplasm, 4
- B**
- Bacteriostatic agent, 114
- Bad in fact (*malum in se*), 419
- Base (uncharged molecules), 15
- Baseline vital signs, 152–153
- Basic life support, positioning for, 357f
- “Bathing” of the nerve, 273
- Bell curves, 57, 59f, 332f
 for bone thickness, 362f
- Benzocaine (ethyl aminobenzoate), 13f, 13t, 16f, 17t
 about, 76, 76f
 with butamben and tetracaine, 76, 77f
 interaction with sulfonamides, 76
 topical anesthetics with, 77f
- Benzoyl methyl ecgonine (cocaine), 76–77
- Beta (β) adrenergic receptors, 42, 45, 53
- Bifid mandibular canals, 199f
- Bilateral inferior alveolar nerve block, 240
- Binding ability, 17
- Biological classification of local anesthetics, 13
- Biological membranes, 5f
- Biotoxins, 13f, 13t
- Biotransformation, 29–31
 of amide-type local anesthetics, 334
 elimination of anesthetics and, 334
 of ester-type local anesthetics, 334
- Birth control pills, history of, 151, 151t, 151b
- Bisulfites, allergy to, 114
- Bladder disease, history of, 148, 148b
- Bleeding
 excessive, 422
 problems, history of, 142
- Blister packs, in cartridge, 114, 115f
- Block injections, 92
- Blocking process, 13f, 21
- Blood pressure, 153–155, 154f–155f, 154t, 156t
 effects of sympathomimetic amines in, 43t
- Blood pressure cuff, 153, 154t
- Blood supply to hard and soft palate, 195f
- Blood transfusions, history of, 150
- Blurred vision, history of, 143
- BMI. *See* Body mass index
- Body mass index (BMI), 158–159, 159t–160t, 159b
- Bradypnea, 157
- Breach of duty, 412
- Breath, shortness of, history of, 141
- Breech-loading syringes
 metallic cartridge-type
 aspirating, 86, 87f, 87t
 self-aspirating, 86–88, 87b, 88t
 metallic or plastic, cartridge-type, 125–128, 125f–127f
 recapping the needle in, 127, 128f
 plastic, cartridge-type, aspirating, 86, 87t, 87b
 unloading, 128, 129f–130f
- Bronchospasm, 146, 355–356
- Bruising, history of, 142
- Bubble, in cartridge, 116, 117f
- Buccal anesthesia, 297–298
- Buccal infiltration of (buffered) articaine, 364
- Buccal nerve block, 198, 247
 advantages of, 248
 alternatives, 248
 areas anesthetized, 247, 247f
 common names, 247
 complications of, 249
 contraindication to, 248
 disadvantages of, 248
 failures of anesthesia, 249
 for hematoma, 322
 indication of, 248–249
 nerves anesthetized, 247
 position of administrator, 248f
 positive aspiration rate of, 248, 336t
 precautions, 249
 safety features, 249
 signs and symptoms, 249
 syringe alignment, 249f
 technique of, 248–249
- Buffer, definition of, 384–385
- Buffered local anesthetic solution, 290, 361
- Buffering (alkalinizing), of local anesthetic, 383–387, 383t, 385f
 possible solution to, 384

- Buffering capacity, 18–19
of mucous membranes, 19
- Bungs. *See* Plungers
- Bupivacaine, 13f, 13t, 16f, 17t, 30f
maximum recommended doses of, 295t, 335t
overdose reactions of, 340t
for paresthesia, 376t
- Bupivacaine HCl, 57, 58t, 75f, 75t
with 4% with epinephrine, 80t
anesthetic half-life, 74
calculation of milligrams per dental cartridge, 60t
chemical formula, 74, 74f
classification of, 74
duration of anesthesia, 60t, 74–75
effective dental concentration, 74
excretion of, 74
FDA approval of, 74
maximum recommended dose, 60t, 75
metabolism of, 74
onset of action, 74
pH of plain solution, 74
pH of vasoconstrictor-containing solution, 74
 pK_a , 74
potency of, 74
pregnancy classification of, 74
prepared by, 74
proprietary names, 81t
safety during lactation, 74
topical anesthetic action, 74
toxicity of, 74
vasodilating properties, 74
- Burning, on injection, 117
- Business associate, 417
- Business Associate Contract Terms, 417, 417f
- Butamben, with benzocaine and tetracaine HCl, 76, 77f
- C**
- Calcium displacement theory, 11–12
- Calcium ions, 14
- Caldolor, 303t
- California Dental Association, 135
- Cambia, 303t
- Cancer, history of, 147
- Canine teeth, 265t
- Canines, 361–363
- Cardiac conditions, endocarditis and, 145b
- Cardiac dysrhythmias, 403
- Cardiac pacemakers, 150
- Cardiovascular system (CVS)
blood levels and actions of local anesthetics on, 342f
effects of sympathomimetic amines in, 43t
- Care and handling of syringes, 95
bent harpoons, 96, 96f
bent needles, 96f
broken cartridges, 95–96
- Care and handling of syringes (*Continued*)
disengagement of harpoon during application, 96
leakage during injection, 95, 96f
surface deposits, 96
- Carpule, 111, 408. *See also* Cartridges
- Carticaine, 370
- Cartridges, 88f, 111–120, 408. *See also*
Injections/injection techniques;
Needles; Syringes
autoclaving in, 114
blister packs in, 114, 115f
breakage of, during injection, 408
broken, 95–96, 118–119, 118f
bubble in, 116, 117f
burning on injection, 117
calculation of milligrams per, 114t
dental cartridge, 60t
care and handling of, 114–116, 115f–116f
color-coding of, as per the American Dental Association Council, 112t
components of, 111–113, 112f
contamination of, 323
contents of, 113–114, 348t
corroded cap in, 118
cracked glass on, 119f
currently available, 57
dental local anesthetic, 370, 370t
extruded stopper in, 116–117
glass, 408
labels/labeling, 113, 113f
articaine, 74
changes in, 61
leakage during injection, 118
local anesthetic solution, composition of, 113t
plastic, 111
plunger in, 112f
extruded, 117f
rubber, 119f
problems in, 116–119
recommendations for, 119
rust on the cap in, 118
sticky stoppers in, 111, 118
storage of, 323, 408
in (traditional) syringe, placing, 128
with volumes, 112f
warmers, 115, 408
- Cataflam, 303t
- Catechol *O*-methyltransferase (COMT), 46
- Catecholamines
release of, 42–43
synthetic, 41
- Catechols, 41
- Cations (positively charged molecules), 15
- C-CLAD. *See* Computer-controlled local anesthetic delivery
- Celebrex, 303t
- Celecoxib, 303t
- Cell body, 3–4
- Central nervous system (CNS)
blood levels and actions of local anesthetics on, 342f
effects of local anesthetics on, 345f
lidocaine toxicity and, 66
signs/symptoms of toxicity, 341–342
- Centruroides* scorpion venom, 13f
- Cerebral circulation, 337f
- Channel entry, 14f
- Channel specificity, 9–10
- Chemical configuration of local anesthetics, 16f, 22t–23t
- Chemical nerve injury, 423
- Chest pain (angina), history of, 141
- Children. *See also* Pediatric dentistry
articaine in, 373–374
phentolamine mesylate in, safety and efficacy of, 382
- Chloride, 8
- Chloroprocaine, 17t, 22t–23t
- Choline ester substrates, 168
- Chronic obstructive lung disease, 146
- Chronotropic effects of local anesthetics, 45
- Circulatory system
cerebral circulation, 337f
transport of anesthesia through, 27
uptake rates into, 32
- Civil forum, 414
- Classification of local anesthetics
biological, 13
Class A–D, 13t
cause of effects of Class D, 13
by mode of action, 11–14, 13t
by reaction with receptor sites, 12
by site of action, 11–14, 13t
- Clinical action, of specific agents, 57–84
- CNS. *See* Central nervous system
- Cocaine (benzoyl methyl ecgonine), 27, 28b, 36, 76–77
habituation and, 36
overdoses, 77
vasoconstrictor with, 165
- Combination products
articaine HCl with, 4% with epinephrine, 80t
lidocaine with
2% with epinephrine, 65–66
2% without vasoconstrictor (Lidocaine Plain), 64–65
epinephrine, 64f, 65–66, 65t–66t
mepivacaine HCl with
2% with levonordefrin, 80t
2% with vasoconstrictor, 67, 69t
3% without vasoconstrictor, 67, 68t
prilocaine HCl with
4% with epinephrine, 80t
4% without vasoconstrictor, 71t
procaine/procaine, 62–63
procaine/propoxycaine, 57, 63
- Complete conduction blockade, 20–21

- Complications
- burning on injection, 323
 - causes of, 323
 - management of, 323
 - prevention of, 323
 - problem of, 323
 - edema, 324–325
 - causes of, 324
 - management of, 325
 - prevention of, 324
 - problem of, 324
 - facial nerve paralysis, 316–317, 317f
 - causes of, 316
 - management of, 317
 - prevention of, 316–317
 - problem of, 316
 - hematoma, 321–322, 321f
 - cause of, 321
 - management of, 322
 - prevention of, 321
 - problem of, 321
 - infection, postinjection, 323–324
 - causes of, 323–324
 - management of, 324
 - prevention of, 324
 - problem of, 324
 - injecting local anesthetic solution into an area of infection, 324
 - local, 307–329
 - malpractice per se, 412
 - needle breakage, 101, 106, 308–310, 309f–310f
 - management, 309, 312f
 - prevention of, 310
 - problem of, 309, 311f
 - reports of, 308–309, 309t
 - nerve damage, 313t
 - ocular, 317–318, 317t
 - anatomic basis of, 318
 - management of, 318
 - pain on injection, 322–323
 - causes of, 322–323
 - management of, 323
 - prevention of, 323
 - problem of, 323
 - paresthesia
 - with alveolar nerve block, 73–74
 - with articaine, 73–74
 - postanesthetic intraoral lesions, 326–327
 - causes of, 326, 326f
 - management of, 327
 - problem of, 326
 - prolonged anesthesia, 310–316
 - causes of, 310–314, 313t
 - management of, 315–316
 - prevention of, 314
 - problem of, 314
 - reports of, 312, 314t
 - self-inflicted soft tissue injury, 296, 296f, 297t
- Complications (*Continued*)
- sloughing of tissues, 325–326
 - causes of, 325
 - management of, 326
 - prevention of, 325, 325f
 - problem of, 325
 - soft tissue injury, 319–321, 320f
 - cause of, 320
 - management of, 321
 - prevention of, 320, 320f
 - problem of, 320
 - self-inflicted, 75
 - systemic. *See* Systemic complications
 - trauma
 - to nerve sheath, 311–312
 - paresthesia and, 310–311
 - trismus, 254, 318–319
 - causes of, 318–319
 - management of, 319
 - prevention of, 319
 - problem of, 319
 - Computer-controlled local anesthetic delivery (C-CLAD), 269, 367–369, 368f–370f, 407, 409
 - Computer-controlled local anesthetic delivery devices, 292–293
 - Computer-controlled local anesthetic delivery systems, 91–95, 93f
 - Wand/STA System (STA-Single Tooth Anesthesia System), 91f, 92–94, 95f, 95t
 - Computer-generated medical history questionnaire, 135
 - COMT. *See* Catechol *O*-methyltransferase
 - Conduction velocity, 5t, 14
 - Congenital methemoglobinemia, 147
 - Consent/informed consent, 352, 414–416, 415f
 - Constipation, history of, 142
 - Consultation form, medical, 140f
 - Contact lenses, history of, 150
 - Contract law, 412
 - Contraindications for local anesthetics
 - articaine with epinephrine, 74
 - EMLA, 78
 - medical problem and alternatives, 59t
 - relative/absolute, 81
 - ConZip, 303t
 - Core bundles, 20
 - Corroded cap, 118
 - Cotton gauze, 122–123, 123f
 - Coughing up blood, history of, 142
 - Cranial fossa, 191f
 - Cranial nerves, 188t, 189f–190f
 - CN I (olfactory nerve), 188t
 - CN II (optic nerve), 188t
 - CN III (oculomotor nerve), 188t
 - CN IV (trochlear nerve), 188t
 - CN V (trigeminal nerve), 188t, 193f
 - motor root, 186
 - pathway of posterior trunk of mandibular nerve, 197f
- Cranial nerves (*Continued*)
- V₁ (ophthalmic division), 186–187
 - V₂ (maxillary division), 187–196, 194f
 - V₃ (mandibular division), 196–200
 - CN VI (abducens nerve), 188t
 - CN VII (facial nerve), 188t
 - distribution of, 315f
 - paralysis of, 316–317, 317f
 - CN VIII (vestibulocochlear (or auditory) nerve), 188t
 - CN IX (glossopharyngeal nerve), 188t
 - CN X (vagus nerve), 188t
 - CN XI (spinal accessory nerve), 188t
 - CN XII (hypoglossal nerve), 188t
 - organs innervated by, 189f–190f
 - type and function, 188t
- Cranium, 188–189
- Criminal case, 414
- Criminal law, 412
- Criteria, for ideal local anesthetics, 2
- CVS. *See* Cardiovascular system
- Cytoplasm, 4
- D**
- Damage, 413–414
 - if malpractice exists, 424
- Defined as bad (*Malum prohibitum*), 419
- Definitive care
 - for allergy present, 357–358
 - for bronchospasm, 356
 - for delayed skin reactions, 355
 - for epinephrine overdose, 347
 - for immediate skin reactions, 355
 - for laryngeal edema, 356
- Dendritic zone (peripheral process), 3–4
- Dental anesthetic buffering system, 386, 386f
- Dental Furniture, Instruments, and Materials*, 268
- Dental hygiene
 - anesthesia for, 302–304
 - local anesthesia map for, 303f
- Dental pain control, advances in, 368t
- Dental plexus, 194
- Dental Practice Act, 302–304
- Dental treatment, problems with, 141
- DentalVibe, 179f
- DentaPen, 368, 370f
- Dentist, judged by patients, 368b
- Dentistry
 - atypical plasma cholinesterase in, 168–169
 - phentolamine mesylate in, 382
- DepoFoam technology, 397, 398f
- Depolarization, 9f
 - phases of, 6
 - wave of, 10
- Desirable actions, of local anesthetics, 330
- Desirable properties of local anesthetics, 2
- Detoxification, 29–31
- Diabetes, history in, 147–148
- Dialogue history, 159–160

- Diaphragm, in cartridge, 112
- Diarrhea, history of, 142
- Diclofenac potassium, 305t
- Diffusibility, 17
- Diffusion of solution, 19
rate of, 19
- Direct-acting sympathomimetic amines, 42, 42b
- Discomfort of injections, studies on, 92
- Disposable syringes, 90, 90t
computer-controlled local anesthetic delivery systems (C-CLAD), 91–95, 93f
plastic, 90f
non-cartridge-containing, 90
safety syringes, 90–91, 91t
STA-Single Tooth Anesthesia System (Wand/STA System), 91f, 92–94, 95f, 95t
Wand/STA System (STA-Single Tooth Anesthesia System), 91f, 92–94, 95f
- Dissociation constants, 17t
- Distilled water, in cartridge, 114
- Dizziness, history of, 142–143
- Documentation/records/charts, recording injections, 184
- Doses, presentation of, 59–60
- Drug-drug interactions, 163–166
amide local anesthetics with inhibitors of metabolism, 163
local anesthetic-induced
methemoglobinemia, 164
opioid sedation, local anesthetics with, 164
sulfonamides and esters, 163
summation interactions with local anesthetics, 163
vasoconstrictor
with adrenergic neuronal blocker, 165–166
with antipsychotic or another α -adrenoceptor blocker, 165
with cocaine, 165
with hydrocarbon inhalation anesthetic, 165
with monoamine oxidase, 166, 166t
nonselective β -adrenoceptor antagonist and, 165, 165t
with thyroid hormone, 166
tricyclic antidepressant and, 164, 165t
- Drug interactions, 423
overdose reactions due to, 331
- Drugs
allergies to, 146–147
fetal effects of, 151t
use of
effect of publicity on, 376, 377f
history of, 150–151
- Dry mouth, history of, 143
- Duration of anesthesia, 2, 22t–23t, 58t
amide-type local anesthetics, 63–75
ester-type local anesthetics, 62–63
Duration of anesthesia (*Continued*)
factors for, 57
influences on, 58–59
pulpal and soft tissue, 80t, 297t
short/intermediate/long, 58b
- Duty, 412
breach of, 412
- Dwarfs, 158
- Dyclonine, 2
- Dynamic pressure-sensing (DPS) technology, 92
- Dysesthesia, 314
- E**
- Ears, ringing in, history of, 143
- Edema, 324–325
allergy and, 324
antitrust tablets in, 117
causes of, 324
laryngeal, 356, 356f
management of, 325
prevention of, 324
problem of, 324
- Efficacy
enhancing, 19
Oxford League Table of, 301–302, 302t
- Electric shock, 311–312
- Electrochemistry, nerve conduction, 7–10
- Electrophysiology, 6–7
- Elimination of anesthetics,
biotransformation and, 334
- Emergencies, 413
air embolism, 422
basic management of (PABCD system), 347, 355b
cricothyrotomy, 357f
fear-related, 135
- Emergency dental care, protocols for patients with allergies, 353
- EMLA. *See* Eutectic mixture of local anesthetics
- Emphysema, 422
history of, 146
subcutaneous, 422
- Employee
respondeat superior in, 419
statutory violations in, 419–420
- Endocarditis prophylaxis, 145b
- Endodontics, 289–293
effects of inflammation on local anesthesia, 289–290
methods of achieving anesthesia in, 290–293
mandibular molars, 291–293, 291b, 294b
mandibular teeth, 291
at or anterior to the mental foramen, 291, 291b
maxillary teeth, 290–291, 290b–291b
- Endoneurium, 21t
- Enzymatic hydrolysis, 20–21
- Epinephrine (Adrenalin), 18, 44–48
2% lidocaine with, 65
for allergic reaction, 325
allergy to, 147
availability in dentistry, 46
avoiding use of, 405
physicians and, 405
beta (β) adrenergic receptors in, 53
chemical structure, 44–48, 45f
clinical applications, 46–48
dilutions of, 46t
effects on peak local anesthetics levels in blood, 42t
hemostasis, 48
for hemostasis, 53
lidocaine combined with, 65t–66t
maximum dose, 46–48, 47t
in cardiac risk patients, 406
mode of action, 45
overdose, 346–347
signs/symptoms of, 347t
proprietary names, 44
systemic actions, 43t, 45–46
blood pressure, 45, 47t
cardiovascular dynamics, 45
central nervous system, 46
coronary arteries, 45
heart rate, 47t
hemostasis, 45–46
metabolism of, 46
myocardium, 45
pacemaker cells, 45
respiratory system, 46
side effects and overdose, 46
termination of action and elimination, 46
vasculature, 45
- Epinephrine-containing gingival retraction cord, 407
- Epineurial sheath, 19, 21t
- Epineurium, 19, 21t
- Epithelial desquamation, 325
- Eroticism, 424
- Ester local anesthetics
of benzoic and para-aminobenzoic acid, 28b
development of, 31f
drug interactions of, 38
effects of, 27
hydrolysis of, 29, 30f, 30t
metabolism of, 29–30
- Esters, sulfonamides and, 163
- Ester-type local anesthetics, 15, 15f, 22t–23t
biotransformation of, 334
duration of anesthesia, 62–63
hypersensitivity to, 347
- Ethyl aminobenzoate (benzocaine)
about, 76, 76f
with butamben and tetracaine, 76, 77f
topical anesthetics with, 77f
- Etidocaine, 17t

- Eutectic mixture of local anesthetics (EMLA), 19, 78, 78f, 121–122
 contraindications for patients with phobias, 78
- Evaluation
 physical, 133–172
 additional, 159–161
 for atypical plasma cholinesterase, 168–169
 contraindications and, 163–166
 dialogue history in, 159–160
 drug-drug interactions in, 163–166, 164b
 goals of, 134–135
 for malignant hyperthermia, 166–167
 medical risk, determination of, 160–161
 for methemoglobinemia, 169–170
 vital signs in, 153–159
 psychological, 133–172
 goals of, 134–135
- Excessive thirst, history of, 143
- Excitable membranes, 341
- Extinction (inactivation), 8
- Extracellular ionic concentrations, 7t
- Extruded stopper, 116–117
- Eye disease, history of, 147
- F**
- Face
 cutaneous nerves of, 193f
 infraorbital nerve branches on, 194–195
- Facial nerve (CN VII), 188t
 distribution of, 315f
 paralysis of, 316–317, 317f
 causes of, 316
 management of, 317
 prevention of, 316–317
 problem of, 316
- Failure of anesthesia, causes of, 62
- Fainting, 135
- Fainting spells, history of, 143
- Fasciculi, 19, 21t
- Fatalities, in children, 294
- FDA (U.S. Food and Drug Administration)
 dental safety syringe systems approved by, 91
 maximum recommended dosages, 60t
 pregnancy categories, 151, 151b
- Fearful patients
 distraction techniques, 176
 pain reaction threshold (PRT) of, 180
- Felypressin, 42, 50–51
 availability in dentistry, 51
 chemical structure, 50, 50f
 clinical applications, 51
 for hemostasis, 53
 mode of action, 50
 proprietary names, 50
 source, 50
 systemic actions, 50–51
- Felypressin (*Continued*)
 central nervous system, 51
 coronary arteries, 51
 maximum doses, 51
 myocardium, 50
 pacemaker cells, 50
 side effects and overdose, 51
 uterus, 51
 vasculature, 51
- Fetal effects, of drugs, 151t
- Fever, history of, 142
- Firing (threshold) potential, 6, 8
- Fishhook bards, 107
- Fixed prosthodontics, 300, 300f
- Fixed-rate pacemakers, 150
- Foods, allergies to, 146–147
- Frontal nerve, 187
- Future trends in pain control, 395–402
- G**
- Gastrointestinal tract
 absorption of local anesthetics from, 27
- Gauze, cotton, 122–123, 123f
- General anesthesia, use of, reasons for, 300
- General health, history of, 141
- Genitourinary system, 43t
- GGMNB. *See* Gow-Gates mandibular nerve block
- Giants, 158
- Gingival retraction cords, 346
- Glaucoma, 147
- Glossopharyngeal nerve (CN IX), 188t
- Gonorrhea, history of, 147–148
- Gow-Gates mandibular nerve block (GGMNB), 25, 88, 104, 249–254, 298, 364
 advantages of, 251
 alternatives, 251
 areas anesthetized, 250, 250f
 common names, 250
 complications of, 254
 contraindications to, 251
 disadvantages, 251
 extraoral landmarks for, 251f
 failures of anesthesia, 254
 indications for, 250–251
 intraoral landmarks for, 252f
 needle position, 253f
 nerves anesthetized, 250
 patient position of, 252f
 positive aspiration rate, 251
 precautions of, 254
 safety features of, 254
 signs and symptoms, 254
 syringe barrel location, 253f
 target area for, 251f
 technique of, 251–254
- Greater palatine foramen, incidence of anesthesia at, 390f
- Greater palatine nerve block, 218–221
 advantages of, 218
 alternatives, 218
- Greater palatine nerve block (*Continued*)
 angle of needle entry, 220f
 areas anesthetized, 218, 218f
 common name, 218
 complications of, 221
 contraindications to, 218
 disadvantages of, 218
 failures of, 221
 indications for, 218
 location of, 220t
 nerve anesthetized, 218
 patient position for, 220f
 position of the administrator for, 219f
 positive aspiration, 218
 precautions for, 221
 prepuncture technique for, 220f
 safety features for, 221
 safety precautions for, 221
 signs and symptoms of, 221
 target area for, 219f
 techniques for, 218–220, 221f
- H**
- Handbook of Local Anesthesia*, 57
- Hard palate, 201f
 inferior view of, 201f
- Harpoon-aspirating syringes, 181
- Harpoons, 86
 bent, 96, 96f, 119
 disengagement during aspiration of, 96
- Harpoon-type aspirating syringes, 87f
- Headaches, history of, 143
- Health, changes in, 141
- Health and Human Services, 416
- Health history
 adult, 136f
 interview sheet, 139f
 pediatric, 137f
 Spanish, 138f
- Health Insurance Portability and Accountability Act (HIPAA) of 1996, 416–420
 administrative requirements in, 416–418
 “Business Associate Contract Terms”, 417, 417f
 Notice of Privacy Practices in, 417
 patient’s rights in, 416
 Privacy Rule, 416, 417f
 privacy standards of, 416, 417f
 sample staff training registry, 418f
- Heart attack, history of, 144
- Heart defects, history of, 144
- Heart disease, history of, 144
- Heart murmurs, history of, 144, 145t, 145b
- Heart problems, history of, 147
- Heart rate and rhythm, 155–157, 156f
- Height, 157–158, 159t
- Hematoma, 297, 321–322, 321f
 after bilateral mental nerve blocks, 321f
 cause of, 321
 management of, 322
 prevention of, 321
 problem of, 321

- Hemodialysis letter, 148b
- Hemorrhage
 as cause of trismus, 318
 into or around the neural sheath, 312
 soft tissue manipulation and, 299
- Hemostasis
 anesthetics for, 30-gauge short needle for, 299
 method of achieving, 410
 preferred solutions, 67
 recommended solutions, 66
- Hemostat, 123, 123f
- Henderson-Hasselbalch equation, 16, 16f
- Hepatitis, history of, 146
- Hereditary angioedema, 324
- Herman Ostrow School of Dentistry of University of Southern California, 173
 physical evaluation summary form, 162f
- Herpes, history of, 147–148
- Herpes simplex, lesion of palate, 326, 326f
- High blood pressure, history of, 145–146
- History
 AIDS, 147
 alcohol, 151
 allergies, 146–147
 anemia, 147
 arthritis, 147
 artificial joint, 150, 150t
 asthma, 146
 birth control pills, 151, 151t, 151b
 bleeding problems, 142
 blood transfusions, 150
 blurred vision, 143
 bruising, 142
 cancer, 147
 chest pain (angina), 141
 constipation, 142
 contact lenses, 150
 coughing up blood, 142
 diabetes, 147–148
 diarrhea, 142
 dizziness, 142–143
 drugs, 150–151
 dry mouth, 143
 ears, ringing, 143
 emphysema, 146
 excessive thirst, 143
 eye disease, 147
 fainting spells, 143
 fever, 142
 general health, 141
 gonorrhea, 147–148
 headaches, 143
 heart attack, 144
 heart defects, 144
 heart disease, 144
 heart murmurs, 144, 145t, 145b
 heart problems, 147
 hepatitis, 146
 herpes, 147–148
 high blood pressure, 145–146
 hospitalization, 141, 150
- History (*Continued*)
 jaundice, 143
 joint pain, 143–144
 kidney, bladder disease, 148, 148b
 liver disease, 146
 lung disease, 146
 medical history questionnaire, 135–141
 computer-generated, 135
 example of, 135, 136f–140f
 long-form, 135
 non-English version, 135–137
 short-form, 135
 medical problems not listed, 151–152
 medications, 150–151
 natural remedies, 150–151
 nausea, 142
 night sweats, 142
 over-the-counter medicines, 150–151
 pacemaker, 150
 persistent cough, 142
 prosthetic heart valve, 149
 psychiatric care, 148, 149t
 recreational drugs, 150
 rheumatic fever, 144
 rheumatism, 147
 seizures, 143
 shortness of breath, 141
 sinus problems, 142
 skin diseases, 147
 stiffness, 143–144
 stomach problems, 146
 stools, blood, 142
 stroke, hardening of arteries, 145
 surgeries, 150
 swallowing, difficulty, 142
 swollen ankles, 141
 syphilis, 147–148
 TB, 146
 thyroid, adrenal disease, 148
 tumors, 147
 ulcers, 146
 urination
 difficulty, 142
 frequent, 143
 urine, blood, 142
 vomiting, 142
 weight loss, 142
- HIV. *See* Human immunodeficiency virus
- Hospitalization, history of, 141, 150
- Hubbing the needle, 308–309
- Human immunodeficiency virus (HIV), 147
- Hydrocarbon inhalation anesthetic,
 vasoconstrictor with, 165
- Hydrolysis, enzymatic, 20–21
- Hydroxyl (OH) substitutions, 41
- Hygiene, dental, 302–304
- Hyperesthesia, 314
- Hyperresponders, 57–58
- Hypertensive emergency, 381
- Hypertensive patients, 47, 47t
- Hypoglossal nerve (CN XII), 188t
- Hyporesponders, 57–58
- I**
- IANB. *See* Inferior alveolar nerve block
- Ibuprofen, 301, 303t
- Idiopathic methemoglobinemia, 147
- Immune complex reactions, 348t
- Impulse spread, 10–11
 myelinated nerves, 11, 11f
 unmyelinated nerves, 10–11, 11f
- Impulses, 6
 propagation of, 10, 10f
- Inactivation (extinction), 8
- Inadequate anesthesia
 acidification of tissue, 15
 inflamed or infected tissue, 18
- Incisive (mental) nerve block, 261–264,
 291, 364
 advantages of, 262
 alternatives, 263
 areas anesthetized, 262, 263f
 common names, 262
 complications of, 264, 264f
 contraindication to, 262
 disadvantages of, 263
 for hematoma, 322
 indication of, 262
 lingual anesthesia, 262f
 lip retraction, 264f
 nerves anesthetized, 262
 positive aspiration rate of, 263, 336t
 precaution of, 264
 safety features of, 264
 signs and symptoms, 264
 technique of, 263–264
 tongue retraction, 262f
- Incisors, 265t
- Indirect-acting sympathomimetic amines,
 42, 42b
- Induction process, concentration gradient
 during, 20f
- Induction time, 21
- Infected teeth, 319
 acidic local anesthetic on, 384
- Infections, 323–324
 causes of, 323–324
 edema and, 324
 injecting local anesthetic solution into an
 area of, 324
 local anesthesia and, 289
 management of, 324
 postinjection, in topical antiseptic, 121
 prevention of, 324
 problem of, 324
- Inferior alveolar nerve, 199
- Inferior alveolar nerve block (IANB), 20–21,
 25, 87–88, 104, 198, 240–247, 409
 advantages of, 241
 alternatives, 241
 areas anesthetized, 241, 241f
 common names, 240
 complications of, 246–247
 contraindications to, 241
 depth of penetration, 244f

- Inferior alveolar nerve block (IANB)
(Continued)
disadvantages of, 244f
failure of anesthesia, 245–246
failure rates with, 361, 410
for hematoma, 322
indications, 241
needle and syringe placement, 243f
needle breakage during, 106, 107f
needle location, 244f
nerves anesthetized, 241
osseous landmarks for, 242f
overinsertion of needle, 245f
pediatric, 298
position of administrator, 242f
positive aspiration rate, 241, 336f
precautions, 245
pterygomandibular raphe, 242f
safety features, 245
signs and symptoms of, 245
syringe barrel placement, 243f
technique, 242f
tongue retraction, 246f, 262f
trismus after, 318–319
- Infiltration anesthesia, 361
- Inflammation, effects of, on local anesthesia, 289–290
- Informed consent, 352, 415f
- Infraorbital canal, branches in, 193–194
- Infraorbital nerve, 387–388
- Infraorbital nerve block, 213–216
advantages of, 213
alternatives for, 214
areas anesthetized, 213, 213f
common name, 213
complications of, 216
contraindications to, 213
disadvantages of, 214
failures of, 216
indications for, 213
needle
 advancement of, 215f
 insertion of, 215f
needle tip, position of, 216f
nerve anesthetized, 213
palpation of infraorbital notch, 215f
positive aspiration, 214
precautions for, 216
- Inhalation sedation, 290
- Injections/injection techniques, 173–185, 179f
atraumatic technique, 184b
breakage of cartridge during, 408
broken cartridge in, 118
burning on, 117
burning sensation in, 408
changing direction of needle, 106
DentalVibe, 179f
effective concentrations for, 76f
hand positions
 incorrect, 179f
 palm up/palm down, 177f
- Injections/injection techniques (Continued)
leakage during, 95, 96f, 118
maxillary, 204–205
multiple insertions, 106
needles for, 407
rate of, 403
recapping needle after use, 183f
recommended needles for, 109t
resistance, 106
steps for
 step 1: using sterilized sharp needle, 174f–175f
 step 2: checking flow of anesthetic solution, 174
 step 3: determine whether to warm syringe or cartridge, 174
 step 4: positioning the patient, 174
 step 5: drying the tissue, 174–175, 175f
 step 6: applying topical antiseptic, 175
 step 7A: applying topical anesthetic, 175, 175f
 step 7B: communicating with patient, 175–176
 step 8: establishing firm hand rest, 176, 177f–178f
 step 9: making tissue taut, 179f
 step 10: keeping syringe out of patients line of sight, 176, 180f
 step 11A: inserting needle into mucosa, 176
 step 11B: watching and communicating with patient, 176–180, 180f
 step 12: injecting several drops of solution, 180
 step 13: advancing needle toward target, 180
 step 14: depositing drops of anesthetic before touching periosteum, 181
 step 15: aspiration, 181–182, 181f–182f
 step 16A: slowly deposit local anesthetic solution, 182
 step 16B: communicate with patient, 182–183
 step 17: slowly withdraw the syringe, 183
 step 18: observing the patient, 183–184
 step 19: recording injection on chart, 184
supplemental. *See* Supplemental injection techniques
tissue preparation, 176
use as topical, 75–80
VibraJect, 179f
- Injury (Continued)
cause of, 320
management of, 321
prevention of, 320, 320f
problem of, 320
self-inflicted, 296, 296f, 297t
- Innervations, of cranial nerves, 189f–190f
- Insult, biting or thermal or chemical, 314
- Interdental (perforating) branches, 194
- Intermediate duration local anesthetics, 57, 58b
- Intracellular ionic concentrations, 7t
- Intracutaneous allergy testing, 352
- Intranasal local anesthetic, 361–362
- Intranasal local anesthetic spray studies, 389t
- Intraoral challenge test, 352
- Intraoral lesions, postanesthetic, 326–327
causes of, 326, 326f
management of, 327
problem of, 326
- Intraosseous anesthesia, 268–285
alternative for, 271
areas anesthetized, 271
common names, 271
complications of, 273
contraindications to, 271
disadvantages, 271
drill, components, 282f
duration of expected, 273
failures of anesthesia, 273
indications, 271
nerve anesthetized, 271
periodontal ligament injection, 268–273
positive aspiration with, 271
precautions with, 272
safety features of, 272
signs and symptoms of, 272
technique, 271–272
- Intraosseous injection, 280–285, 292, 365–366, 365f–366f
advantages of, 282
alternatives for, 282
area anesthetized by, 282f
complications of, 284, 284f
contraindication to, 282
disadvantages of, 282
drill hole, 283f
duration of, 284–285
failures of, 284
indication, 282
needle, insertion in, 283f
periodontal ligament injection, 270f
positive aspiration, 282
precautions for, 284
safety feature of, 283–284
signs and symptoms of, 283
- Stabident, 292f
 components, 282f
 doses, 284t
 technique, 282–283
 withdrawn, drill, 283f
- X-Tip, 292f

- Intrapapillary injection, 297–298
- Intrapulpal anesthesia, 293
- Intrapulpal injection, 285, 286, 293, 293f
 - alternative for, 285
 - areas anesthetized, 285
 - common names, 285–286
 - complications of, 286
 - contraindications, 285
 - disadvantages, 285
 - failures of anesthesia, 286
 - indications, 285
 - nerve anesthetized, 285
 - positive aspiration with, 285
 - precautions with, 286
 - safety features of, 286
 - signs and symptoms of, 286
 - technique for, 285, 286f
- Intraseptal injection, 278–280, 281t, 292, 293f
 - advantages of, 279
 - alternatives, 279
 - area of insertion for, 280f
 - areas anesthetized by, 279, 279f
 - common names, 278
 - complication of, 280
 - contraindication to, 279
 - disadvantages of, 279
 - duration of, 280
 - failures of, 280
 - indication for, 279
 - nerves anesthetized by, 278
 - orientation of the needle in, 280f
 - positive aspiration, 279
 - precautions for, 280
 - safety feature of, 280
 - signs and symptoms for, 280
 - technique, 279–280
- Intravenous (IV) administration, 86, 337f
 - hazards of, 86
 - prevention of, 336
 - risk factors of, 403
- Ion (sodium) channels, 9, 13f
 - transition stages, 9f
- Ion-conducting stage, 9f
- Ionic forms, of local anesthetics, 7t, 16
- Ischemia, of gingival soft tissues, 325
- J**
- Jaundice, history of, 143
- Jet injectors, 89–90, 90t
 - MadaJet, 90f
- Joint pain, history of, 143–144
- K**
- K-305 nasal spray, 389, 389t
- Ketorolac, 303t
- Kidney disease, history of, 148, 148b
- Kidney function/dysfunction, 334
- Kinetics of onset of action, 19–25
 - diffusion of solution, 19
 - induction, 19–24
- Korotkoff sounds, 155, 155f
- L**
- Lacrimal nerve, 187
- Local anesthetic safety of local anesthetics during
 - articaine HCl, 72
 - bupivacaine HCl, 74
 - lidocaine HCl, 64
 - mepivacaine HCl, 67
 - prilocaine HCl, 70
- Laryngeal edema, 356, 356f
- Latex allergy, 113, 146–147
- Law
 - contract, 412
 - criminal, 412
 - tort, 412–416
- Leakage, during injection, 118
- Legal considerations, 412–426
 - actual cause, 413
 - allergy and, 420
 - chemical nerve injury in, 423
 - consent/informed consent, 352, 414–416, 415f
 - criminal case, 414
 - damage in, 413–414
 - duty in, 412
 - breach of, 412
 - Health Insurance Portability and Accountability Act (HIPAA) of 1996, 416–420
 - administrative requirements in, 416–418
 - “Business Associate Contract Terms”, 417, 417f
 - Notice of Privacy Practices in, 417
 - patient’s rights in, 416
 - Privacy Rule, 416, 417f
 - privacy standards of, 416, 417f
 - sample staff training registry, 418f
 - instruments and, 421
 - local anesthetic cartridge, 421
 - local anesthetic needle, 421
 - syringe, 421
 - license in, 414
 - lip chewing and, 422
 - local anesthetic drug interaction, 423
 - local reactions to local anesthetic administration, 421–422
 - malpractice
 - existence of, 424–425
 - per se, 412
 - specific conducts, 420
 - negligence, 412
 - neural penetration in, 422–423
 - overdose, 420
 - postprocedure evaluations, 424
 - proximate cause, 413
 - psychogenic reactions, 423–424
 - eroticism as, 424
 - regulatory agency, 414
 - respondeat superior, 418–419
 - standard of care and, 413
 - statutory violations in, 419–420
 - subcutaneous emphysema, 422
- Legal considerations (*Continued*)
 - third parties in, 420
 - vascular penetration in, 422
- Leirus* scorpion venom, 13f
- Levonordefrin, 50
 - availability in dentistry, 50
 - chemical structure, 50, 50f
 - clinical applications, 50
 - maximum doses, 50
 - mode of action, 50
 - propriety name, 50
 - source, 50
 - systemic actions, 50
 - central nervous system, 50
 - coronary arteries, 50
 - heart rate, 50
 - metabolism, 50
 - myocardium, 50
 - pacemaker cells, 50
 - respiratory system, 50
 - side effects and overdose, 50
 - termination of action and elimination, 50
 - vasculature, 50
- License, 414
- Lidocaine, 2, 27, 28b, 30–31, 121
 - absorption of, 405
 - administration of, 36
 - anticonvulsant blood levels, 33t
 - disposition of, 31t
 - form of, 403
 - hypotensive effects, 37–38
 - maximum recommended dose of, 295t, 335t
 - metabolic pathways, 32f
 - overdose reactions of, 340t
 - for paresthesia, 376t
 - paresthesia and, 314
- Lidocaine HCl, 57, 58t, 64f, 64t
 - 2% lidocaine with epinephrine, 65
 - 2% without vasoconstrictor (Lidocaine Plain), 64–65
 - absorption of, 79
 - anesthetic half-life, 64
 - calculation of milligrams per dental cartridge, 60t
 - chemical formula, 63, 63f
 - classification of, 63
 - duration of anesthesia, 63–66, 80t
 - effective concentrations for, 76t
 - effective dental concentration, 64
 - with epinephrine, 64f, 65t–66t, 66–67
 - excretion of, 63
 - FDA approval of, 63
 - maximum recommended dose, 60t, 61b–62b, 64
 - metabolism of, 63
 - onset of action, 64
 - pH of plain solution, 63
 - pH of vasoconstrictor-containing solution, 63
 - pK_a, 63

- Lidocaine HCl (*Continued*)
 potency of, 63
 pregnancy classification for, 64
 prepared by, 63
 proprietary names, 81t
 safety during lactation, 64
 topical preparations, 79
 toxicity, 63
 vasodilating properties, 63
- Lidocaine plain, 64–65
- Light-activated local anesthetics, 399–401, 400f
- Light-inactivated local anesthetics, 399–401, 400f
- Lingual nerve, 198, 377–378, 377t, 378f
 injury, 422
- Lingual teeth, 265t
- Lipid solubility of local anesthetics, 21, 22t–24t
- Lipoprotein framework, membrane, 5f
- Liposomal bupivacaine (Exparel), 397
- Lips
 chewing of, 422
 self-inflicted soft tissue injury to, 296, 296f, 297t
 self-inflicted trauma to, 319, 320f
- Liver disease, history of, 146
- Liver function/dysfunction, 334
 complications for patients with, 335f
- Local activity of local anesthetics, 18–19
- Local anesthetic cartridges, 114
- Local anesthetic drug, in cartridge, 113–114
- Local anesthetic-induced
 methemoglobinemia, 164
- Local anesthetic solutions, composition of, 113t
- Local anesthetics, 361
 acidity causes pain during, 383
 administration of, position for, 409
 availability of, 404
 in cardiovascular system, 36–38, 36t, 37b
 in central nervous system, 32–36, 37b
 analgesia, 35–36
 anticonvulsant properties of, 33, 33t
 convulsive phase, 34, 34t–35t
 mood elevation, 36
 preconvulsive signs and symptoms, 33–34, 33b, 35f
 choice of, 338–339
 classification of, 28b
 clinically useful, 407
 delivery systems, 397–399
 dental drug interactions with, 149t
 development of, 31, 31f
 elimination half-life of, 371t
 excretion of, 31
 four quadrants at one time, 339
 intravascular, 337f
 light-activated, 399–401, 400f
 light-inactivated, 399–401, 400f
 in local tissue toxicity, 38
 longer- and ultra-long-acting, 395–399
- Local anesthetics (*Continued*)
 low pH of, 383–384
 metabolism of, 29–31
 miscellaneous actions of, 38–39
 more effective, articaine as, 378–379
 neurotoxins, 377t–378t, 378
 novel adjuvants of, 399
 “off” switch, 379–382, 379t–380t
 “on” switch, 383–387, 383t
 overdose
 comparison of, 341t
 in younger patients, 338b
 pharmacokinetics of, 27–31
 pharmacology of, 27–40
 recent advances in, 367–394
 in respiratory system, 38
 reversal of, clinical indications for, 382, 382t
 selection of, 404
 summation interactions with, 163
 systemic actions of, 31–39
 with a vasoconstrictor, 406
 vasoconstrictor, plain *vs.*, 379, 379t
 work poorly on infected teeth, acidic, 384
- Local infiltration, 290
- Local reactions to local anesthetic
 administration, 421–422
- Long buccal nerve block, 198, 247, 336t
- Long-duration local anesthesia, 58b, 300–302
 postsurgical management of pain with, 301–302
 prolonged dental or surgical procedures for, 300–301
- Long-form medical history questionnaire, 135
- Lung disease, history of, 146
- M**
- Maceration, local tissue, 422
- MadaJet, 90f
- Magnesium, 399
- Malignant hyperthermia (MH), 38–39, 166–167
 causes of, 167
 dental management of, 167
 recognition of the high-risk, 167
 safe anesthetics for, 168b
- Malpractice per se, 412
- Malum in se (bad in fact), 419
- Malum prohibitum (defined as bad), 419
- Mandible, 202–203, 202f
- Mandibular anesthesia techniques
 available techniques, 265t
 buccal nerve block, 247
 Gow-Gates mandibular nerve block, 249–254
 incisive nerve block, 261–264
 incisive (mental) nerve block, 261–264
 inferior alveolar nerve block (IANB), 240–247
 mental nerve block, 258–261
- Mandibular anesthesia techniques
 (*Continued*)
 mental (incisive) nerve block, 258–261
 pediatric, 298
 recommended volumes of solution for, 266t
 Vazirani-Akinosi closed-mouth
 mandibular block, 251, 254–256
- Mandibular canals, 199
 bifid, 199f
- Mandibular infiltration, in adults, articaine
 by, 372, 372t, 373f–374f
- Mandibular molars, 364
- Mandibular nerve
 branches of, 197f
 motor and sensory branches, 197f
 pathways of, 197f
- Mandibular nonmolar teeth, 364
 “Mandibular slump”, 268
- Mandibular teeth, 364
 average tooth length, 207t
- Mantle bundles, 19
- Mantle fibers, 20–21
- Maxilla, 200–202, 200f
 anatomy of, 200–202
 infratemporal aspect of, 201f
- Maxillary anesthesia techniques, 104, 204–238
 anterior middle superior alveolar nerve
 block, 227–230
 anterior superior alveolar nerve block
 (infraorbital nerve block), 213–216
 field blocks, 204, 205f
 greater palatine nerve block, 218–221
 local infiltration in, 204, 205f
 middle superior alveolar nerve block, 211–213
 nerve block, 204, 205f
 pediatric, 298
 posterior superior alveolar nerve block, 207–211
 suprapariosteal injection, 205–207
- Maxillary incisors, 361–363
- Maxillary injection techniques, 204–205
- Maxillary molars, 363, 363f
- Maxillary nerve, 194f
- Maxillary nerve block, 233–237
 advantages of, 234
 alternatives for, 234
 areas anesthetized, 234, 234f
 common names, 233
 complications of, 237
 contraindications to, 234
 failures of, 237
 greater palatine canal approach, 235–236, 235f–236f, 236t
 high-tuberosity approach, 234–235, 234f
 indications for, 234
 maxillary teeth, 237t
 precautions for, 237
 safety features of, 236
 signs and symptoms, 236

- Maxillary nonmolar teeth
 intranasal mist for pulpal anesthesia of, 387–388, 390
 nasal mist for anesthesia of, 387–390
- Maxillary techniques, recommended
 volumes of, 238t
- Maxillary teeth, 361–363
 average tooth length, 207t
- Maxillofacial and oral surgery, 299–300
- Maximum recommended dose (MRD), 59–62, 60t, 294, 295t
 calculating, 61b–62b, 62
 drug formulations of, 335t
 factors for calculating, 334
 patient's age, 334–335
 patient's physical status, 335
 patient's weight, 335
 for local anesthetic, 340t
- Mechanisms of action
 local anesthetic molecules, 17f
 sequence of, 14
- Medical consultation form, 140f
Medical Emergencies in the Dental Office, 160
- Medical history questionnaire, 135–141
 of allergic reactions, 349
 computer-generated, 135
 example of, 135, 136f–140f
 long-form, 135
 non-English version in, 135–137
 short-form, 135
- Medical risk, determination of, 160–161
- Medications
 allergies to, 146–147
 history of, 150–151
- Membrane
 action of local anesthetics on, 14f
 configuration of biological, 5f
 nerve cell, 4
 organization of biological, 4–5
- Membrane channels, 8–10, 9f–10f
- Membrane excitation, 8
 depolarization, 7f, 8
 repolarization, 7f, 8, 9f
- Membrane expansion theory, 12, 12f
- Menstridol, 303t
- Mental (incisive) nerve block, 258–264
 advantages of, 259, 262
 alternatives, 259, 263
 areas anesthetized, 259, 259f, 262, 263f
 common names, 262
 complications of, 261, 264, 264f
 contraindication to, 259, 262
 disadvantages of, 259, 263
 failures of anesthesia, 261, 264
 indication of, 259, 262
 lingual anesthesia, 262f
 lip retraction, 264f
 locating the mental foramen, 260f–261f
 needle penetration site, 261f
 nerves anesthetized, 259, 262
 position of administrator, 260f
 positive aspiration rate, 259, 263
- Mental (incisive) nerve block (*Continued*)
 precaution of, 261, 264
 safety features of, 260, 264
 signs and symptoms of, 260, 264
 technique of, 259–260, 263–264
 tongue retraction, 262f
- Mepivacaine, 13f, 13t, 16f, 17t, 22t–23t
 maximum recommended dose of, 295t, 335t
 overdose reactions of, 340t
 for paresthesia, 376t
- Mepivacaine HCl, 57, 58t, 67t, 68f
 2% with levonordefrin, 80t
 2% with vasoconstrictor, 67, 69t
 3% without vasoconstrictor, 67, 68t
 anesthetic half-life, 67
 calculation of milligrams per dental cartridge, 60t
 chemical formula, 66, 66f
 classification of, 66
 duration of anesthesia, 60t, 66–67, 80t
 effective concentrations for, 67, 76t
 excretion of, 67
 FDA approval of, 67
 maximum recommended dose, 60t, 61b–62b, 67
 onset of action, 67
 overdoses, 67
 pH of vasoconstrictor-containing solution, 67
 pK_a, 67
 potency of, 67
 pregnancy classification of, 67
 prepared by, 66
 proprietary names, 81t
 safety during lactation, 67
 topical anesthetic action, 67
 toxicity of, 67
 vasodilating properties of, 67
- Mercury manometers, 153
- Metabolic effects of agents, 43t
- Metabolism
 inhibitors of, amide local anesthetics with, 163
 of local anesthetics, 57–58
- Metallic cartridge-type syringe, breech-loading, 125–128, 125f–127f
 recapping the needle in, 127, 128f
 unloading, 128, 129f–130f
- Metered sprays, of topical anesthetics, 122
- Methemoglobin, 169
- Methemoglobin reductase, 169
- Methemoglobinemia, 169–170, 423
 acquired, 169
 causes of, 169
 clinical signs and symptoms of, 169–170
 local anesthetic-induced, 164
 management of, 169–170
- Methylparaben, in cartridge, 114
- MetLife Dental, 135
- MH. *See* Malignant hyperthermia
- Middle superior alveolar nerve block, 211–213
 administrator, position of, 212f
 advantages of, 208–209
 alternatives, 209
 areas anesthetized, 211, 211f
 branches, 193
 complications of, 213
 contraindications to, 211
 disadvantages of, 211
 failures of, 212–213
 indications for, 211
 needle, position of, 212f
 needle penetration, 213f
 nerves anesthetized, 211
 positive aspiration, 209
 positive of the administrator for, 212f
 precaution for, 211
 safety features of, 211
 signs and symptoms of, 211
 techniques for, 212
- Mixed-acting sympathomimetic amines, 42, 42b
- Modes of action, 11–14
 classification of local anesthetics by, 13t
 theories of, 3
 vasoconstrictors, 42–43
- Molars
 available techniques, 265t
 removal of third, 340t
- Molecular weight, of local anesthetics, 22t–23t
- Monoamine oxidase, vasoconstrictor with, 166, 166t
- Mosby's Medical Dictionary*, 375
- Motor neurons, 4
- Motrin, 303t
- MRD. *See* Maximum recommended dose
- Mucous membranes
 absorption of local anesthetics through, 334
 buffering capacity of, 19
- Myelinated axons, 11f
- Myelinated nerve fibers, 5–6, 6f
- Mylar plastic label, in cartridge, 113, 113f
- Mylohyoid nerve branches, 199
- Myocardium, local anesthetics in, 36–37
- N**
- Naprelan, 303t
- Naproxen sodium, 303t
- Nasal mist, for anesthesia of maxillary nonmolar teeth, 387–390
- Nasal wall
 anatomy of, 195f
 and pterygopalatine canal, 195f
- Nasociliary nerve, 187
- Nasopalatine nerve block, 221–226
 advantages of, 222
 alternatives, 222
 areas anesthetized, 222, 222f

- Nasopalatine nerve block (*Continued*)
 common names, 222
 complications of, 224
 contraindications to, 222
 disadvantages of, 222
 failures of, 224
 indications for, 222
 multiple needle penetration for, 224–225, 224f–225f
 advantage of, 225
 complications of, 226f
 disadvantage of, 225–226
 failures of, 226
 precautions for, 226
 safety features of, 225
 signs and symptoms of, 225
 nerves anesthetized, 222
 position, of patient, 223f
 position of administrator for, 222f
 positive aspiration, 222
 single-needle penetration, 222–223, 223f
 failure of, 224
 precautions for, 223–224
 safety features of, 223
 signs and symptoms, 223
 target area for, 222f
- Natural remedies, history of, 150–151
 Nausea, history of, 142
 Needle cap holders, 127
 Needle-recapping device, 123, 124f
 Needles, 99–110, 407
 anatomy of, 99–104, 100f
 bevel, 99
 cartridge-penetrating end, 99
 hub, 99
 shaft, 99
 attachment of, 90
 barbs, 108f
 bent, 96f
 breakage of, 101, 106, 308–310, 309f–310f, 421
 management, 309, 312f
 prevention of, 310
 problem of, 309, 311f
 reports of, 308–309, 309t
 care and handling of, 104–106
 contamination of, 324
 deflection of, 100f, 103–104
 bi-rotational insertion technique (BRIT), 103–104, 103f
 BRIT (bi-rotational insertion technique), 103–104, 103f
 in hydrocolloid tubes, 101t
 disposable, 100f, 173–174, 309f
 determination of, 174
 disposal of, 105, 105f
 fishhook-type barb, 173
 gauges of, 88, 99–104, 407
 color-coding by, 99, 101f
 larger *versus* smaller, 102b
 specifications for, 102t
 hubbing of, 308–309
- Needles (*Continued*)
 injection techniques, 109t
 injuries to patients or administrators, 107
 insertion of, 103
 lengths of, 104, 104f, 104t, 310, 407
 nondeflecting, 101f, 102–103
 pain
 on insertion of, 106
 on withdrawal of, 107
 palm-thumb grasp, 103f
 plastic, cap holder, 105f
 recommendations for using, 107, 109t
 reusable, 99
 safety needles, 99
 with scalpel bevel, 106f
 studies, 101
 types of, 99, 100f
 U.S. dentistry purchases of, 102t
 use of EMLA for patients with phobias, 78
- Needlestick injuries, 123
 Negative aspiration, 181f
 Negligence, 412
 Neosaxitoxin (NeoSTX), 396, 396f
 Nerve block, positive aspiration rate of, 336t
 Nerve block anesthesia, 291
 Nerve branches, mylohyoid, 199
 Nerve conduction
 electrochemistry of, 7–10, 7t
 electrophysiology of, 6–7, 7f, 7t
 Nerve damage, 313t
 risk of, 404
 Nerve fibers, 19, 21t
 classes of, 5t
 composition of, 20f
 myelinated, 5–6, 6f
 unmyelinated, 6, 6f
 Nerve injuries/damage
 facial nerve paralysis as, 316–317, 317f
 causes of, 316
 management of, 317
 prevention of, 316–317
 problem of, 316
 lingual, 422
 Nerve membranes, 4
 Nerve sheaths, 19
 diffusion of local anesthetic through, 17
 trauma to, 311–312
 Nerve supply to hard and soft palate, 195f
 Nerves
 impulses, 6
 normal functioning, 15
 peripheral, 5t
 Neural anatomy, 422
 Neural penetration, 422–423
 Neuron, 3–4
 axonal process of, 4
 motor, 4
 multipolar motor, 4f
 unipolar sensory, 4f
 Neuropathies, 375
 Neurophysiology, 1–26
- Neurotoxins, local anesthetics, 377t–378t, 378
 New local anesthetic delivery systems, 397–399
 NH₂ amine group, 41
 Night sweats, history of, 142
 Nodes of Ranvier, 5–6, 6f, 11, 13
 Nondepolarizing nerve block, 14
 Nondisposable syringes, 86–90
 breech-loading
 metallic
 cartridge-type aspirating, 86, 87f, 87t
 cartridge-type self-aspirating, 86–88, 87b, 88t
 plastic, cartridge-type, aspirating, 86, 87t, 87b
 harpoon-type aspirating, 87f
 jet injectors, 89–90, 90t
 MadaJet, 90f
 pressure syringes, 88–89, 89f, 89t
 Nonmyelinated axons, 11f
 Nonnervous tissue, diffusibility of, 24t
 Nonselective β -adrenoceptor antagonist, vasoconstrictor and, 165, 165t
 Nonsteroidal antiinflammatory drugs (NSAIDs), 301, 303t
 Norepinephrine (Levaterenol), 48–49
 availability in dentistry, 49
 chemical structure, 48, 48f
 clinical applications of, 49
 for hemostasis, 53
 maximum doses, 49
 mode of action, 48
 proprietary names, 48
 for sloughing of tissues, 325
 source, 48
 systemic actions, 48–49
 blood pressure, 49
 cardiovascular dynamics, 49
 central nervous system, 49
 coronary arteries, 48
 heart rate, 48
 metabolism of, 49
 myocardium, 48
 pacemaker cells, 48
 respiratory system, 49
 side effects and overdose, 49
 termination of action and elimination, 49
 vasculature, 49, 49f
 systemic effects of, 43t
 tissue necrosis/sloughing with, 53
 Normoresponders, 57–58
 Nose, 387
 Novel adjuvants of local anesthetics, 399
 NSAIDs. *See* Nonsteroidal antiinflammatory drugs
 Nursing mothers, articaine in, 373

- O**
- Obesity, comorbidities associated
 - with, 159b
 - Octocaine ointment, 79f
 - Ocular complications, 317–318, 317t
 - anatomic basis of, 318
 - management of, 318
 - Oculomotor nerve (CN III), 188t
 - ODT, 303t
 - “Off” switch (phentolamine mesylate), 379–382, 379t–380t
 - OH (hydroxyl) substitutions, 41
 - Olfactory nerve (CN I), 188t
 - “On” switch (buffered anesthetics), 383–387, 383t
 - Onset of action, 17t
 - Ophthalmic division (V_1) (CN V) of trigeminal nerve, 186–187
 - frontal nerve, 187
 - lacrimal nerve, 187
 - nasociliary nerve, 187
 - Opioid sedation, local anesthetics
 - with, 164
 - Optic nerve (CN II), 188t
 - Optogenetics, 399
 - Oral and maxillofacial surgery, 299–300
 - Oraqix, 78–79, 78f
 - Orbit, 193f
 - Osseous anesthesia, 280
 - Osteology
 - mandible, 202–203
 - maxilla, 200–202
 - Overdoses/overdose reactions, 420
 - age factors of, 332, 332b
 - allergy *vs.*, 331t
 - causes of, 334–340
 - biotransformation and elimination, 334
 - excessive total dose, 334–335
 - intravascular injection, 336–340
 - prevention, 336–340
 - rapid absorption, into cardiovascular system, 335–336
 - clinical signs/symptoms of, 340
 - cocaine, 77
 - comparison of forms of, 341t
 - definition of drug overdose reaction, 331
 - drug factors of, 332b, 333–334
 - concentration of solution, 333
 - dose volume, 333
 - presence of vasoconstrictors, 334
 - rate of injection, 334
 - route of administration, 333–334
 - vascularity of injection site, 334
 - vasoactivity, 333
 - due to drug interactions, 331
 - due to rapid absorption, 336
 - epinephrine, 346–347
 - factors determining, 61, 332, 332b
 - genetics factors of, 333
 - increased potential for, 410
 - Overdoses/overdose reactions (*Continued*)
 - of lidocaine, 403
 - management of, 342–347
 - delayed onset, mild reaction with, 343–344
 - mild reaction, with rapid onset, 343
 - severe reactions, with rapid onset, 344–345
 - slow onset, severe reactions with, 345–346
 - mental attitude and environment, 333
 - other medications as factors of, 333
 - pathophysiology of, 341–342
 - cardiovascular system actions, 342
 - central nervous system actions, 341–342
 - physiologic effects of local anesthetics, 60–61
 - predisposing factors of, 332–334
 - presence of disease, 333
 - recommended volumes for intraoral injection, 339t
 - sex factors of, 333
 - signs/symptoms
 - minimal to moderate overdose levels, 340b
 - vasopressors, 347t
 - systemic reactions, 331–347, 332f
 - weight factors of, 332
 - Over-the-counter medicines, history of, 150–151
 - Overweight, comorbidities associated with, 159b
 - Oxford League Table of Analgesic Efficacy, 301–302, 302t
 - Oxymetazoline, 79, 387–390
 - adverse events of, 390
 - in dental nasal anesthesia
 - efficacy of, 388–390, 389t
 - safety of, 388
- P**
- Pacemaker, history of, 150
 - Pain, 141, 200
 - on injection, 322–323
 - causes of, 322–323
 - management of, 323
 - prevention of, 323
 - problem of, 323
 - on insertion of needle, 106
 - mechanism of blocking, 3f
 - postsurgical
 - control of, protocol for, 301–302, 302b
 - management of, 301–302
 - regimens for, 75
 - process of experience of, 3f
 - response following palatal infiltration, 367–368, 369f
 - stress and, 406
 - trismus and, 318
 - on withdrawal of needle, 107
 - Pain control, problems in achieving, 361–366, 362f
 - mandibular teeth, 364
 - maxillary teeth, 361–363
 - pulpally involved teeth, 362t, 364–366, 365t, 365b
 - Palatal anesthesia, 216–230, 217f–218f, 388f, 389–390
 - Palatal injections, 409
 - for hematoma, 322
 - Palatal lesions
 - abscess, 49f
 - herpes simplex, 326, 326f
 - Palate, local infiltration of, 226–227
 - advantages of, 226
 - alternatives for, 226
 - area of insertion for, 226f
 - areas anesthetized, 226, 226f
 - common names, 226
 - complications of, 227
 - contraindications to, 226
 - disadvantages of, 226
 - failure of hemostasis in, 227
 - indications for, 226
 - nerves anesthetized, 226
 - positive aspiration, 226
 - precaution for, 227
 - safety features of, 227
 - signs and symptoms, 227
 - technique, 226–227
 - Papilla, incidence of anesthesia at, 390f
 - Paraben preservatives, 352
 - Paralytic shellfish poisoning, 396
 - Paralytic shellfish toxins, 395
 - Paresthesia, 310–316
 - with alveolar nerve block, 73–74
 - with articaine, 73–74
 - articaine and, 374–376, 376t
 - causes of, 310–314, 313t
 - defined, 310
 - following nonsurgical dental treatment, 376–377, 377t
 - greater risk of, 378–379
 - management of, 315–316
 - meta-analysis of, 404
 - prevention of, 314
 - problem of, 314
 - reports of, 312, 314t
 - risk of, 404
 - Parotid gland, deposition of local anesthetic into, 317
 - Passive aspiration, 130, 131f
 - Patient, appropriate anesthetic for, selection of, 404
 - Pediatric dentistry, 293–298
 - administration of anesthetics for, 295t
 - bone density and, 297
 - bupivacaine use, 74
 - choice of anesthetics, 338
 - complications of, 296–297, 296f
 - factors in risk of overdose, 338b
 - fatalities in, 294

- Pediatric dentistry (*Continued*)
 local anesthesia in, concerns for, 410
 local anesthetic choice for, 296f
 local anesthetic selection in, 298
 local anesthetics of choice, 339t
 overdose in, 294–296
 increased risk of, 296b
 techniques of, 297–298
 mandibular anesthesia, 298
 maxillary anesthesia, 298
 upper and lower jaws in 4-year old child, 297f
- Pediatric medical history questionnaire, 137f
- Perforating (interdental) branches, 194
- Peridental injection, 269f
- Perilemma, 21t
- Perineurium, 21t
- Periodontal ligament, 270f
- Periodontal ligament (PDL) injections, 88, 92–93, 105, 194, 268–273, 292–293
 area anesthetized by, 271f–272f
 complications with, 270
 needle breakage during, 106
 single tooth anesthesia system, 273–278, 275f
 studies on, 93–94
 syringes, 89f
 designed for, 269f, 270
 use of conventional, 270
- Periodontics, 298–299
- Peripheral circulation, 43t
- Peripheral nerves
 classification of, 5t
 composition of nerve fibers and bundles in, 20f
- Peripheral process (dendritic zone), 3–4
- Peripheral vasculature, local anesthetics in, 37–38, 38t
- Persistent cough, history of, 142
- pH
 alkalinization (elevating), 15
 in burning on injection, 117
 clinical applications of, 19
 of dental cartridge, 114
 effect of decreased tissue pH, 18f
 elevating (alkalinization), 15
 importance to atraumatic injections of, 173
 local anesthetics without vasoconstrictors, 18–19
 for pulpal anesthesia, 289
- Pharmacologic properties of local anesthetics, 22t–23t
- Pharmacovigilance Working Committee of the European Union, 312
- Phentolamine mesylate (OraVerse), 296–297, 380–382, 380f
 in dentistry, clinical use of, 382
 efficacy of, 381–382
 during lactation, 381
 during pregnancy, 381
- Phentolamine mesylate (OraVerse) (*Continued*)
 safety of
 adolescents and adults, 382
 children, 382
- Phenylephrine, for hemostasis, 53
- Phenylephrine hydrochloride, 51–52
 availability in dentistry, 52
 chemical structure, 51, 51f
 clinical applications, 52
 maximum doses, 52
 mode of action, 51
 propriety name, 51
 source, 51
 systemic actions, 51–52
 blood pressure, 51
 cardiovascular dynamics, 51
 central nervous system, 51
 coronary arteries, 51
 heart rate, 51
 metabolism, 51
 myocardium, 51
 pacemaker cells, 51
 respiratory system, 51
 side effects and overdose, 52
 termination of action and elimination, 52
- Physical evaluation, 133–172
 additional, 159–161
 for atypical plasma cholinesterase, 168–169
 contraindications to, 163–166
 dialogue history in, 159–160
 drug-drug interactions in, 163–166, 164b
 for malignant hyperthermia, 166–167
 medical risk, determination of, 160–161
 for methemoglobinemia, 169–170
 vital signs in, 153–159
- Physical Status Classification System, 47–48, 66, 161–163, 162f
 ASA class 1, 161
 ASA class 2, 161
 ASA class 3, 161–162
 ASA class 4, 162–163
 ASA class 5, 163, 164t
- Physician, treatment by, 141
- Physicochemical properties, of local anesthetics, 21, 22t–23t
- Physiologic effects of local anesthetics, 60–61
- Physiology
 nerve conduction, 6–7
 of peripheral nerves, 5t, 6
 pK_a, 17t, 22t–23t
 in local anesthetic action, 24t
 local anesthetics with high/low, 17 values, 15
 “Plain” local anesthetic solution, 113t
- Plasma cholinesterase, atypical, 168–169
- Plastic cartridge, 111
- Plastic cartridge-type syringe, breech-loading, 125–128, 125f–127f
 recapping the needle in, 127, 128f
 unloading, 128, 129f–130f
- Plungers (stoppers, bungs), latex, 349
- Position of administrator of local anesthetics
 buccal nerve block, 248f
 inferior alveolar nerve block (IANB), 243f
 mental (incisive) nerve block, 260f
- Positive aspiration, 181f
- Positively charged molecules (Cations), 15
- Postanesthetic intraoral lesions, 326–327
 causes of, 326, 326f
 management of, 327
 problem of, 326
- Posterior division, branches from, 198–199
- Posterior superior alveolar nerve block, 188, 207–211, 208f
 advantages of, 208–209
 alternatives, 209
 areas anesthetized, 208f
 common names, 208
 complications of, 208, 211
 contraindications to, 208
 disadvantages of, 209
 failures of, 211
 for hematoma, 322
 indications for, 208
 nerves anesthetized, 208
 position of the administrator for, 209f
 positive aspiration, 211
 rate of, 336t
 precaution for, 212
 safety features of, 212
 signs and symptoms of, 212
 target area, needle at, 209f
 techniques for, 210f, 212
 tissue retraction and, 210f
 use of “long” needle for, 210f
- Postinjection infection, 323–324
 causes of, 323–324
 injecting local anesthetic solution into an area of, 324
 management of, 324
 prevention of, 324
 problem of, 324
 in topical antiseptic, 121
- Postprocedure evaluations, 424
- Postsurgical pain management, 301–302
 control of, protocol for, 301–302, 302b
 regimens for, 75
- Practice management, Dental Practice Act and, 302–304
- Pregnant patients, pregnancy classifications and safety
 articaine HCl, 72
 bupivacaine HCl, 74
 lidocaine HCl, 64
 mepivacaine HCl, 67
 prilocaine HCl, 70
- Pregnant women, articaine in, 372–373
- Preloaded syringes, 357f

- Premature ventricular contraction (PVC), 45, 156–157
- Premaxilla, 201–202
- Premolars, 361–363
 - available techniques, 265t
- Pressure devices, 88–89
- Pressure syringes, 88–89, 89f, 89t, 269f
- Prilocaine, 13f, 13t, 16f, 17t, 22t–23t, 169
 - maximum recommended dose of, 295t, 335t
 - metabolic pathways, 33f
 - overdose reactions of, 340t
 - for paresthesia, 376t
- Prilocaine HCl, 57, 58t, 70f, 70t
 - 4% with epinephrine, 80t
 - 4% without vasoconstrictor, 71t
 - anesthetic half-life, 69
 - calculation of milligrams per dental cartridge, 60t
 - chemical formula, 67, 67f
 - classification of, 67
 - duration of anesthesia, 60t, 80t
 - effective dental concentration, 69
 - excretion of, 69
 - FDA approval of, 69
 - maximum recommended dose, 60t, 70
 - metabolism of, 69
 - onset of action, 69
 - pH of plain solution, 69
 - pH of vasoconstrictor-containing solution, 69
 - pK_a, 69
 - potency of, 69
 - pregnancy classification of, 70
 - prepared by, 69
 - proprietary names, 81t
 - safety during lactation, 70
 - topical anesthetic action, 69
 - toxicity of, 69
 - vasodilating properties of, 69
- Procainamide, 15, 17t
- Procaine, 15, 17t, 22t–23t
- Procaine HCl
 - anesthetic half-life, 62
 - chemical formula, 62, 62f
 - classification of, 62
 - combined with, with propoxycaine HCl, 63
 - duration of anesthesia, 62–63
 - anesthetic half-life, 62
 - effective concentrations for, 76t
 - effective dental concentration, 62
 - excretion, 62
 - metabolism of, 62
 - onset of action, 62
 - pH of plain solution, 62
 - pH of vasoconstrictor-containing solution, 62
 - pK_a, 62
 - potency of, 62
 - topical anesthetic action, 62
 - toxicity, 62
 - vasodilating properties, 62
- Product identification package insert, in local anesthetic containers, 116, 116f
- Prolonged anesthesia, 310–316, 410
 - causes of, 310–314, 313t
 - management of, 315–316
 - prevention of, 314
 - problem of, 314
 - reports of, 312, 314t
- Prophylaxis
 - antibiotic, 145t
 - in cardiac conditions, 145b
 - endocarditis, 145b
 - orthopedic, 150t
- Propoxycaine, 17t
- Propoxycaine HCl, 63
 - anesthetic half-life, 63
 - chemical formula, 63, 63f
 - classification of, 63
 - combined with, with procaine HCl, 63
 - duration of anesthesia, 63
 - effective dental concentration, 63
 - excretion, 63
 - metabolism, 63
 - onset of action, 63
 - pH of plain solution, 63
 - potency of, 63
 - prepared by, 63
 - topical anesthetic action, 63
 - vasodilating properties, 63
- Propranolol, 423
- Prosthetic heart valve, history of, 149
- Prosthodontics, fixed, 300, 300f
- Protein binding, 21–24, 22t–24t
- Proteins, classification of, 4–5
- Proximate cause, 413
- Psychiatric care, history of, 148, 149t
- Psychogenic reactions, 423–424
 - eroticism as, 424
- Psychological attitude, adverse drug reactions due to, 333
- Psychological evaluation, 133–172
- Psychological issues, temperature of metal syringes, 174
- Pterygopalatine canal, 195f
- Pterygopalatine fossa, branches of, 189–193, 194f
- Pterygopalatine nerves, 190
 - branches, 190
 - branches of, 190
- Pulpal (hard tissue) anesthesia, 67, 265t
 - duration of, 57–59, 58b, 60t, 80t, 297t
 - expected duration of, 383, 383t
 - of maxillary nonmolar teeth, 387–388, 388f
 - onset time of, 372t, 383–384, 384t
 - primary techniques for
 - mandibular molars, 364
 - mandibular nonmolar teeth, 364
 - maxillary incisors, canines, and premolars, 361–363
 - maxillary molars, 363
 - successful, 372t
- Pulpally involved teeth, pain control for, 410
- Pulsus alternans, 157
- PVC. *See* Premature ventricular contraction
- ## Q
- Quaternary ammonium-azobenzene-quaternary ammonium, 399–400, 400f
- ## R
- Radial pulse, 153
- Readministration of local anesthetics, 24–25
 - difficulty reaching profound anesthesia, 25
 - recurrence of immediate profound anesthesia, 24
- Real-time exit pressure, 273–274
- Receptor sites, classification of local anesthetics by reaction with, 12
- Records/charts, allergic reactions, 350
- Recovery, from local anesthetic block, 24
- Recreational drugs, history of, 150
- Recurrent aphthous stomatitis, 326
- Refractory periods, 8
- Refrigerant spray, 363f
- Regional anesthesia in dentistry, 408–410
 - for maxilla, infiltration (supraperiosteal) anesthesia and, 409
 - patient's medical history questionnaire and, 408–409
- Regional nerve block, 290
- Regulatory agency, 414
- Relative refractory period, 8
- Renal function/dysfunction, 334
- Repolarization, 7f, 8, 9f
- Repulsion (surface charge) theory, 11–12
- Respiratory rate, 157
- Respiratory system, effects of sympathomimetic amines in, 43t
- Respondeat superior, 418–419
- Resting potential, 7f
- Resting state, of nerves, 8, 14f
 - membrane channels in, 9f
 - membranes in, 8
- Rheumatic fever, history of, 144
- Rheumatism, history of, 147
- Risk factors
 - of intravascular administration, 86
 - of nerve damage, 404
 - non-aspirating syringes, 86
 - overdose reactions, 403
 - selection of local anesthetics, 81
- RNH⁺ ions, 21–24
- Ropivacaine, 17t, 22t–23t
- Routes of administration, 333–334
 - intravascular administration, hazards of, 86
- Rust, on cap, in cartridge, 117f, 118
- Rybix, 303t
- Ryzolt, 303t
- ## S
- Safety issues
 - needle handling, 104–106
 - recapping needles, 183

- Safety syringes/needles, 90–91, 91t, 407
- Saltatory conduction, 11
- Saltatory propagation, 11f
- Saxitoxin (STX), 396, 396f
- Schwann cells, 5–6, 6f
- Scoop technique, 127, 128f
for recapping needles, 183, 183f
- Scorpion venom, 13f, 13t
- Sea anemone venom, 13f
- Seizures, 342
history of, 143
- Selection of local anesthetics, 57, 80–82, 81b
- Self-aspirating (passive) syringes, 87–88, 88f, 128
- Self-aspiration, 130
- Self-inflicted injuries, 75
- Self-inflicted soft tissue injury, 296, 296f, 297t
- Sensory nerves, excitability of, 4
- Sharps containers, 184f
- Shelf life of local anesthetics, 18
- Short duration local anesthetics, 58b
- Short-form medical history questionnaire, 135
- Sickle cell anemia, 147
- Single Tooth Anesthesia (STA) C-CLAD system, 91f, 92–94, 94f, 95t
- Single tooth anesthesia system
advantages of, 276–277, 279b
areas anesthetized, 276
common names, 276
complications of, 278
computer-controlled local anesthetic delivery devices, 269
contraindications to, 276
disadvantages of, 277, 279b
duration of, 278
failures of, 277–278
indications for, 276
nerves anesthetized, 276
pediatric use of, 274–276
periodontal ligament injection, 273–278, 275f
positive aspiration in, 277
precautions for, 277
safety feature of, 277
signs and symptoms for, 277
suggested drug/ volume for, 278
technique for, 277
- Sinus dysrhythmia, 157
- Sinus problems, history of, 142
- Site of action, 11–14
classification of local anesthetics by, 11–14, 13t
myelinated nerve fibers, 13–14
- Skeletal muscle, 43t
- Skin, reactions to allergic response
delayed, 355
from generalized anaphylaxis, 354–355
immediate, 355
management of, 354–358
- Skin diseases, history of, 147
- Skull, 191f, 196f, 200f
- Sloughing of tissues, 325–326
causes of, 325
management of, 326
prevention of, 325, 325f
problem of, 325
- Sodium
inhibition of peak permeability of, 14
migration of, 8
- Sodium bisulfate, 114
- Sodium channel blockers, 395–397, 397f
- Sodium (ion) channels, 9, 13f
transition stages, 9f
- Sodium chloride, in cartridge, 114
- Soft tissue anesthesia (STA), 57, 67
available techniques, 265t
duration of, 57–59, 80t, 297t
- Soft tissue injury, 319–321, 320f
cause of, 320
management of, 321
prevention of, 320, 320f
problem of, 320
self-inflicted, 75, 296, 296f, 297t, 380, 380t
- Solutions
contamination of, 421
excessive volumes of, 319
local anesthetic, composition of, 113t
into patient's mouth, 408
- Spanish health history questionnaire, 138f
- Specific receptor theory, 12
- Spinal accessory nerve (CN XI), 188t
- Spray forms of topical anesthetics, 76, 336, 336f
- STA. *See* Soft tissue anesthesia
- Stabident, 292f
components, 282f
system, 281
- Standard of care, 413
- Statutory violations, 419–420
- Sterile abscess, 325
- Sticky stoppers, in cartridge, 111, 118
- Stiffness, history of, 143–144
- Stomach problems, history of, 146
- Stomatitis, aphthous, 326, 326f
- Stools, blood in, history of, 142
- Stoppers. *See* Plungers
- Stress, pain and, 406
- Stroke, history of, 145
- Structure, of local anesthetics, 14–15, 15f–16f
- Subcutaneous emphysema, 422
- Sulfonamide, esters and, 163
- Supplemental injection techniques, 268–288
intraosseous anesthesia, 268–285
intraosseous injection, 280–285
intraseptal injection, 278–280
single tooth anesthesia system, 273–278, 275f
- Supraperiosteal injection, 205–207, 290
advantages of, 206
alternatives for, 206
areas anesthetized by, 205, 206f
common names, 205
complications of, 207
contraindications to, 206
direction of needle tip, 247f
disadvantages of, 206
failures of, 207
indications for, 206
needle, insertion of, 206f
nerves anesthetized by, 205
positive aspiration, 206
precautions for, 207
safety features of, 207
signs and symptoms, 207
technique, 206, 206f
- Surface charge (repulsion) theory, 11–12
- Surgical procedures
history of, 150
long-duration anesthesia for, 299
oral and maxillofacial surgery as, 299–300
postsurgical management of pain in, 301–302
control of, protocol for, 301–302, 302b
postsurgical pain management, regimens for, 75
prolonged, 300–301
self-mutilation after, 75
- Swallowing, difficulty in, history of, 142
- Swiss-cheese model, of accident causation, 338, 338f
- Swollen ankles, history of, 141
- Sympathomimetic amines
blinded/guided approaches, 92–93
categories of, 42, 42b
systemic effects of, 43t
- Sympathomimetic drug classification, 41
- Syphilis, history of, 147–148
- Syringes, 85–98, 407
aspirating, 90f
harpoon devices, 86
available types, 87b
breach-loading, 86
metallic or plastic, cartridge-type, 125–128, 125f–127f
care and handling of, 95
bent harpoons, 96, 96f
bent needles, 96f
broken cartridges, 95–96
disengagement of harpoon during aspiration, 96
leakage during injection, 95, 96f
surface deposits, 96
cartridge, placing, 128
C-CLAD, 269
depression of diaphragm, 88f
disposable, 90, 90t
computer-controlled local anesthetic delivery systems (C-CLAD), 91–95, 93f

- Syringes (*Continued*)
 plastic, 90f
 plastic non-plunger containing, 90
 safety syringes, 90–91, 91t
 Wand/STA System (STA-Single Tooth Anesthesia System), 91f, 92–94, 95f, 95t
 dynamic pressure-sensing (DPS) technology, 92
 harpoon-type aspirating, 87f, 181
 nondisposable, 86–90
 breach-loading metallic
 cartridge-type aspirating, 86, 87f, 87t
 cartridge-type self-aspirating, 86–88, 87b, 88t
 breach-loading plastic, cartridge-type, aspirating, 86, 87t, 87b
 jet injectors, 89–90, 90f, 90t
 pressure syringes, 88–89, 89f, 89t
 for periodontal ligament injection, 89f, 269f
 pressure devices, 88–89
 safety, 407
 self-aspirating, 87–88, 88f, 128
 type of, 407
 Ultra Safety Plus XL Safety, 128–132, 130f
- Systemic absorption of lidocaine, 79
 Systemic complications, 330–360
 adverse drug reactions. *See* Adverse drug reactions
 allergies. *See* Allergic reactions/sensitivity
 intravascular injection, 337f
 overdose reactions, 330–347, 332f
 causes of, 334–340
 predisposing factors of, 332–334
 patients with liver dysfunction, 335f
 rapid intra-arterial deposition, 337f
 recommended volumes for intraoral injections, 339t
 spray topical anesthetics, 336f
 systemic toxicity, 2
- Systolic blood pressure, 153
- T**
 Tachyphylaxis, 25, 43
 Tachypnea, 157
 Target organs, of drug, 332
 Techniques, lingual, 265t
 Temperature, 157, 158f
 Terminals, axon, 4
 Tertiary amine local anesthetics, 13f
 Tetracaine, 2, 387–390
 adverse events of, 390
 in dental nasal anesthesia
 efficacy of, 388–390, 389t
 safety of, 388
 Tetracaine HCl
 effective concentrations for, 76t, 77f
 intranasal, 79
 topical preparations, 79
- Tetrodotoxin (TTX), 395, 396f
 Tetrodotoxin saxitoxin, 13f
 The Wand, 367–368, 369f
 The Wand STA Single Tooth Anesthesia System, 368, 370f
- Theories
 acetylcholine theory, 11–12
 calcium displacement theory, 11–12
 membrane expansion theory, 12, 12f
 mode of action theory, 3
 specific receptor theory, 12
 surface charge (repulsion) theory, 11–12
- Third molars, removal of, 340t
 Third parties, 420
 Thirst, excessive, history of, 143
 Threshold (firing) potential, 6
 Thyroid, adrenal disease, history of, 148
 Thyroid hormone, vasoconstrictor with, 166
 Tissue, local, maceration of, 422
 Tissue status of deposited anesthesia, 58
 TNN Needle Guide, 106, 106f
- Tooth
 infected, 319
 length, average, 207t
- Topical anesthetics, 19, 75–80, 404
 absorption of, 19
 area of application of, 336
 armamentarium in, 121–122, 122f
 with benzocaine, 77f
 concentrations of, 76
 dyclonine, 2
 effective concentrations for, 76t
 lidocaine, 79f
 Octocaine ointment, 79f
 overdoses of, 336
 spray forms, 76, 336, 336f
 use of, justification of, 422
- Topical antiseptic, armamentarium in, 121
 Toradol, 303t
 Tort law, 412–416
 Total (soft tissue) anesthesia, 57, 67
 Toxic reaction, 330–331
 Toxicology principles, 330
- Toxins/toxicity
 blocking actions of toxins, 13f
 causes of, 331b
 chemical nerve injury and, 423
 idiosyncratic reactions, 331
 lidocaine, 66, 342f
 in pediatric dentistry, 294
- Tramadol, 303t
 Transfusions, of blood, history of, 150
 Treatment planning, 338
 Triazolam, 292
 Tricyclic antidepressant, vasoconstrictor and, 164, 165t
- Trigeminal nerve (CN V), 186–200, 188t, 193f
 mandibular division (V₃), 196–200
 branches, 198–199
 origins, 188
 maxillary division (V₂), 187–196, 191f
- Trigeminal nerve (CN V) (*Continued*)
 motor root, 186, 192f
 ophthalmic division (V₁), 186–187
 pathways of, 187f
 posterior trunk of mandibular nerve, 197f
 sensory root, 186–200
- Trismus, 254, 318–319
 causes of, 318–319
 management of, 319
 prevention of, 319
 problem of, 319
- Trochlear nerve (CN IV), 188t
 Trypanophobia, 387, 387t
 Tuberculin-type allergic responses, 348t
 Tuberculosis (TB), history of, 146
 Tumors, history of, 147
- U**
 Ulcers, history of, 146
 Ultra Safety Plus XL safety syringe, 128–132, 130f
 Ultram, 303t
 Ultram ER, 303t
 UltraSafety Plus XL aspirating syringe, 90f
 Uncharged molecules (base), 15
 Undesirable actions, of local anesthetics, 330
 Undivided nerve, branches from, 198
 University of the Pacific (UOP) School of Dentistry, 135
 Unmetered sprays, of topical anesthetics, 122
 Unmyelinated nerve fibers, 6, 6f
 Urination, history of
 difficulty in, 142
 frequent, 143
 Urine, blood in, history of, 142
 U.S. Food and Drug Administration (FDA), 313–314
 US Department of Health and Human Services (USDHHS), 416
 websites for, 418
- V**
 Vagus nerve (CN X), 188t
 Variations in anatomy, 58–59, 62
 Vascular penetration, 422
 Vascular uptake, 295
 Vasoactivity, 24
 Vasoconstrictors, 41–56, 405–407
 with adrenergic neuronal blocker, 165–166
 adrenergic receptor activity of, 42t
 with antipsychotic or another α -adrenoceptor blocker, 165
 for cardiac risk patients, 406
 in cartridge, 114
 chemical structure of, 41–42, 41f, 42t
 cocaine, 76, 165
 concentrations of clinically used, 44t
 containing local anesthetic solution, 117
 contraindications to, 405

- Vasoconstrictors (*Continued*)
 dilutions of, 43–44, 346t
 drug interactions with, 44
 effects of, 42t
 epinephrine. *See* Epinephrine
 excessive use of, 49f
 felypressin. *See* Felypressin
 with hydrocarbon inhalation anesthetic, 165
 inclusion of, recommendation against, 405
 as integral component, 335–336
 length of procedure and, 52, 52t
 levonordefrin. *See* Levonordefrin
 local anesthetic with, 406
 medical status of patient and, 53–54
 modes of action, 42–43
 adrenergic receptors, 42
 release of catecholamines, 42–43
 with monoamine oxidase, 166, 166t
 nonselective β -adrenoceptor antagonist and, 165, 165t
 norepinephrine. *See* Norepinephrine (Levarterenol)
 oxidation of, 18
 phenylephrine hydrochloride. *See* Phenylephrine hydrochloride
 reasons for use of, 41
 requirement for hemostasis, 53
 selection of, 52–54, 52b
 sympathomimetic amines
 categories of, 42, 42b
 systemic effects of, 43t
 with thyroid hormone, 166
 tricyclic antidepressant and, 164, 165t
- Vasodilation
 rebound, 299
 vasodilator activity, 24t
- Vasopressor-containing local anesthetic solution, 113t
- Vasopressors, dental drug interactions with, 149t
- Vasovagal syncope, 135
- Vazirani-Akinosi closed-mouth mandibular block, 251, 254–256, 364
 advantages of, 256
 alternatives, 256
 areas anesthetized, 256, 256f
 common names, 255
 complications of, 258
 contraindications to, 256
 disadvantages of, 256
 facial nerve paralysis and, 316
 failures of anesthesia, 258
 indications for, 256–258
 lateral approach through sigmoid notch, 255f
 modification of, 255
 needle advancement, 258f
 needle insertion area, 257f
 nerves anesthetized, 255
 pediatric, 298
 position of barrel of syringe, 257f
 precautions of, 258
 safety features, 258
 signs and symptoms, 258
 technique of, 256–258
- Venom, 13f
- Ventricular dysrhythmias, 403
 epinephrine and, 405
- Ventricular tachycardia, 45
- Vestibulocochlear (auditory) nerve (CN VIII), 188t
- VibraJect, 179f
- Visual analog scale, 92f
 C-CLAD, 367, 368f
- Visual inspection, 159
- Vital signs, in physical evaluation, 153–159
 blood pressure, 153–155, 154f–155f, 154t, 156t
 body mass index, 158–159, 159t–160t, 159b
 heart rate and rhythm, 155–157, 156f
 height and weight, 157–158, 159t
 temperature, 157, 158f
- Volume
 of local anesthetic administered, 339
 for intraoral injections, 339t
 of local anesthetic solution, excessive, 319
 for single tooth anesthesia system, 278
 of solution administered
 for mandibular anesthesia techniques, 266t
- Vomiting, history of, 142
- W**
- Wand STA system, 279b
- Warmed syringes/cartridges, 174
- Warmers, cartridge, 115
- Weber effect, 376
- Websites
 HIPAA information, 418
 UOP, 135
- Weight, 157–158, 159t
- Weight loss, history of, 142
- X**
- X-Tip, 292f
- Z**
- Zipsor, 303t
- Zygomatic nerve, 189

This page intentionally left blank

PDF Compressor Free Version

This page intentionally left blank

PDF Compressor Free Version

This page intentionally left blank

PDF Compressor Free Version